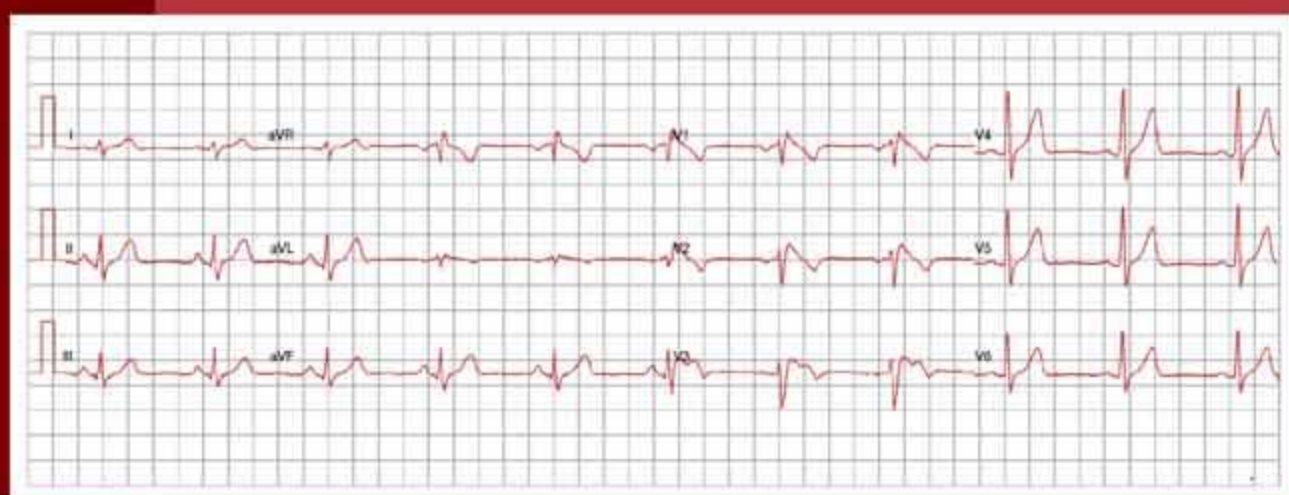

Rapid ECG Interpretation

THIRD EDITION

M. Gabriel Khan

MD, FRCP(LONDON), FRCP(C), FACP, FACC



 HUMANA PRESS

RAPID ECG INTERPRETATION

CONTEMPORARY CARDIOLOGY

CHRISTOPHER P. CANNON, MD

SERIES EDITOR

ANNEMARIE M. ARMANI, MD

EXECUTIVE EDITOR

- Nuclear Cardiology: The Basics: How to Set Up and Maintain a Laboratory, Second Edition**, by Frans Wackers, MD, PhD, Barry L. Zaret, MD, PhD, and Wendy Bruni, CNMT, 2008
- Rapid ECG Interpretation, Third Edition**, by M. Gabriel Khan, MD, FRCP (London), FRCP(C), FACP, FACC, 2008
- Therapeutic Lipidology**, edited by Michael H. Davidson, MD, Kevin C. Maki, PhD, and Peter P. Toth, MD, PhD, 2007
- Essentials of Restenosis: For the Interventional Cardiologist**, edited by Henricus J. Duckers, PhD, MD, Patrick W. Serruys, MD, and Elizabeth G. Nabel, MD, 2007
- Cardiac Drug Therapy, Seventh Edition**, by M. Gabriel Khan, MD, FRCP (London), FRCP(C), FACP, FACC, 2007
- Cardiovascular Magnetic Resonance Imaging**, edited by Raymond Y. Kwong, MD, 2007
- Essential Echocardiography: A Practical Handbook With DVD**, edited by Scott D. Solomon, MD, 2007
- Cardiac Rehabilitation**, edited by William Kraus, MD, and Steven Keteyian, MD, 2007
- Management of Acute Pulmonary Embolism**, edited by Stavros Konstantinides, MD, 2007
- Stem Cells and Myocardial Regeneration**, edited by Marc S. Penn, MD, PhD, 2007
- Handbook of Complex Percutaneous Carotid Intervention**, edited by Jacqueline Saw, MD, Jose Exaire, MD, David S. Lee, MD, Sanjay Yadav, MD, 2007
- Preventive Cardiology: Insights Into the Prevention and Treatment of Cardiovascular Disease, Second Edition**, edited by JoAnne Micale Foody, MD, 2006
- The Art and Science of Cardiac Physical Examination: With Heart Sounds and Pulse Wave Forms on CD**, by Narasimhan Ranganathan, MD, Vahe Sivacyan, MD, and Franklin B. Saksena, MD, 2006
- Cardiovascular Biomarkers: Pathophysiology and Disease Management**, edited by David A. Morrow, MD, 2006
- Cardiovascular Disease in the Elderly**, edited by Gary Gerstenblith, MD, 2005
- Platelet Function: Assessment, Diagnosis, and Treatment**, edited by Martin Quinn, MB BCh BAO, PhD, and Desmond Fitzgerald, MD, FRCP, FESC, APP, 2005
- Diabetes and Cardiovascular Disease, Second Edition**, edited by Michael T. Johnstone, MD, CM, FRCP(C), and Aristidis Veves, MD, DSc, 2005
- Angiogenesis and Direct Myocardial Revascularization**, edited by Roger J. Laham, MD, and Donald S. Baim, MD, 2005
- Interventional Cardiology: Percutaneous Noncoronary Intervention**, edited by Howard C. Herrmann, MD, 2005
- Principles of Molecular Cardiology**, edited by Marschall S. Runge, MD, and Cam Patterson, MD, 2005
- Heart Disease Diagnosis and Therapy: A Practical Approach, Second Edition**, by M. Gabriel Khan, MD, FRCP(LONDON), FRCP(C), FACP, FACC, 2005
- Cardiovascular Genomics: Gene Mining for Pharmacogenomics and Gene Therapy**, edited by Mohan K. Raizada, PhD, Julian F. R. Paton, PhD, Michael J. Katovich, PhD, and Sergey Kasparov, MD, PhD, 2005
- Surgical Management of Congestive Heart Failure**, edited by James C. Fang, MD and Gregory S. Couper, MD, 2005
- Cardiopulmonary Resuscitation**, edited by Joseph P. Ornato, MD, FACP, FACC, FACEP and Mary Ann Peberdy, MD, FACC, 2005
- CT of the Heart: Principles and Applications**, edited by U. Joseph Schoepf, MD, 2005
- Coronary Disease in Women: Evidence-Based Diagnosis and Treatment**, edited by Leslee J. Shaw, PhD and Rita F. Redberg, MD, FACC, 2004
- Cardiac Transplantation: The Columbia University Medical Center/New York-Presbyterian Hospital Manual**, edited by Niloo M. Edwards, MD, Jonathan M. Chen, MD, and Pamela A. Mazzeo, 2004
- Heart Disease and Erectile Dysfunction**, edited by Robert A. Kloner, MD, PhD, 2004
- Complementary and Alternative Cardiovascular Medicine**, edited by Richard A. Stein, MD and Mehmet C. Oz, MD, 2004
- Nuclear Cardiology, The Basics: How to Set Up and Maintain a Laboratory**, by Frans J. Th. Wackers, MD, PhD, Wendy Bruni, BS, CNMT, and Barry L. Zaret, MD, 2004
- Minimally Invasive Cardiac Surgery, Second Edition**, edited by Daniel J. Goldstein, MD, and Mehmet C. Oz, MD, 2004
- Cardiovascular Health Care Economics**, edited by William S. Weintraub, MD, 2003
- Platelet Glycoprotein IIb/IIIa Inhibitors in Cardiovascular Disease, Second Edition**, edited by A. Michael Lincoff, MD, 2003
- Heart Failure: A Clinician's Guide to Ambulatory Diagnosis and Treatment**, edited by Mariell L. Jessup, MD and Evan Loh, MD, 2003
- Management of Acute Coronary Syndromes, Second Edition**, edited by Christopher P. Cannon, MD, 2003
- Aging, Heart Disease, and Its Management: Facts and Controversies**, edited by Niloo M. Edwards, MD, Mathew S. Maurer, MD, and Rachel B. Wellner, MPH, 2003
- Peripheral Arterial Disease: Diagnosis and Treatment**, edited by Jay D. Coffman, MD and Robert T. Eberhardt, MD, 2003
- Cardiac Repolarization: Bridging Basic and Clinical Science**, edited by Ihor Gussak, MD, PhD, Charles Antzelevitch, PhD, Stephen C. Hammill, MD, Win K. Shen, MD, and Preben Bjerregaard, MD, DMSc, 2003

RAPID ECG INTERPRETATION

Third Edition

M. GABRIEL KHAN, MD, FRCP

(LONDON), FRCP(C), FACP, FACC

Associate Professor of Medicine, University of Ottawa

Cardiologist, The Ottawa Hospital

Ottawa, Ontario, Canada

With a Foreword by

Christopher P. Cannon, MD

TIMI Study Group, Brigham and Women's Hospital

Harvard Medical School

Boston, MA



HUMANA PRESS
TOTOWA, NEW JERSEY

© 2008 Humana Press Inc., a part of Springer Science+Business Media, LLC
999 Riverview Drive, Suite 208
Totowa, New Jersey, 07512

Copyright © 2003, 1997, Elsevier Science (USA). All Rights Reserved

www.humanapress.com

All rights reserved. No part of this book may be reproduced, stored in a retrieval system, or transmitted in any form or by any means, electronic, mechanical, photocopying, microfilming, recording, or otherwise without written permission from the Publisher.

The content and opinions expressed in this book are the sole work of the authors and editors, who have warranted due diligence in the creation and issuance of their work. The publisher, editors, and authors are not responsible for errors or omissions or for any consequences arising from the information or opinions presented in this book and make no warranty, express or implied, with respect to its contents.

This publication is printed on acid-free paper. ☺

ANSI Z39.48-1984 (American Standards Institute) Permanence of Paper for Printed Library Materials.

For additional copies, pricing for bulk purchases, and/or information about other Humana titles, contact Humana at the above address or at any of the following numbers: Tel.: 973-256-1699; Fax: 973-256-8341; E-mail: orders@humanapr.com; or visit our Website: www.humanapress.com

Photocopy Authorization Policy:

Authorization to photocopy items for internal or personal use, or the internal or personal use of specific clients, is granted by Humana Press Inc., provided that the base fee of US \$30.00 per copy is paid directly to the Copyright Clearance Center at 222 Rosewood Drive, Danvers, MA 01923. For those organizations that have been granted a photocopy license from the CCC, a separate system of payment has been arranged and is acceptable to Humana Press Inc. The fee code for users of the Transactional Reporting Service is: [978-1-58829-979-6/08 \$30.00].

9 8 7 6 5 4 3 2 1

eISBN: 978-1-59745-408-7

Library of Congress Control Number: 2007922066

Translations: Czech, Chinese, Farsi, Japanese, Polish, Russian, Spanish

To my wife, Brigid

FOREWORD

The electrocardiogram (ECG) is the first test performed on most cardiac patients—one that helps make the first part of the diagnosis and one that can frequently direct treatment decisions. Thus, for any physician, a solid understanding of the ECG is critical. Learning the basics and subtleties of the ECG is a right of passage for all physicians and healthcare providers during their training.

So, what would we want from a book on ECGs? Ideally, such a book would be comprehensive, yet concise, practically oriented, and explain pathophysiology and its application to practice.

Dr. Khan has written such a book. *Rapid ECG Interpretation* is comprehensive, yet concise, and very practically oriented. More important, it takes a step-by-step approach, walking the reader through a thorough evaluation of the ECG. This, as many of us have been taught, is the “right” way to look at an ECG. This edition includes a new opening chapter that covers basic concepts. This quickly orients the reader to the physiology, anatomy, and geometry of the electrical system of the heart.

After reviewing each component of the ECG, the next section describes the unique ECG patterns of specific cardiac conditions, including pulmonary embolism and long QT syndrome. This is followed by a chapter with each of the arrhythmias. Finally, Dr. Khan includes an invaluable section—an ECG Board Review and Self-Assessment Quiz. With this, the reader can really see if the basic concepts and ECG fundamentals have been learned.

Dr. Khan is to be congratulated on an outstanding text that will help readers at all levels become very familiar and facile in rapid interpretation of the ECG.

Christopher P. Cannon, MD
TIMI Study Group, Brigham and Women’s Hospital
Harvard Medical School, Boston, MA

PREFACE

A new approach for the interpretation of the electrocardiogram (ECG), *a step-by-step method for the accurate interpretation of the ECG*, is outlined in this text.

The most important addition in the second edition of *Rapid ECG Interpretation* was a new chapter, Basic Concepts. This chapter gives considerable practical details with 16 instructive illustrations so that the reader can fully understand the genesis of each wave and deflection of the ECG and the reason 12 carefully positioned leads are needed to capture 12 views of the heart's electrical currents and vector forces. Also, more than 35 new ECG tracings were added to the chapters that discuss topics that will be of value to postgraduates and internists.

The major addition in this third edition is a new chapter: ECG Board Self-Assessment Quiz. The chapter provides 90 selected ECG tracings that should sharpen the skills of all who wish to interpret ECGs. This small-volume text contains more than 320 ECGs and instructive illustrations.

The ECG is the oldest cardiologic test, but even 100 years after its inception, it continues as the most commonly used cardiologic test. Despite the advent of expensive and sophisticated alternatives, the ECG remains the most reliable tool for the confirmation of acute myocardial infarction (MI). The ECG—not CK-MB, troponins, echocardiogram, or SPECT or PET scan—dictates the timely administration of life-saving PCI or thrombolytic therapy. There is no test to rival the ECG in the diagnosis of arrhythmias, which is a common and bothersome clinical cardiologic problem. Also, the clinical diagnosis of pericarditis and myocardial ischemia is made mainly by ECG findings.

This text gives a systematic step-by-step approach but departs somewhat from the conventional sequence and gives steps that are consistent with the changes in cardiology practice that have evolved over the past decade. The early diagnosis of acute MI depends on astute observation for ST segment changes. New terms have emerged: ST elevation MI and non-ST elevation MI (non-Q wave MI). The ST segment holds the key to the diagnosis. Currently, ambulance crews are being trained in Europe, the United States, and Canada to recognize ST segment abnormalities and to make the diagnosis of ST elevation MI (STEMI)

and non-ST elevation MI. Thus, patients can be rapidly shuttled to special cardiac centers for coronary angiography and angioplasty/stent or thrombolytic therapy; rapid triage in emergency rooms is crucial. These lifesaving measures depend on the accurate and rapid interpretation of the ECG by clinicians who must be adequately trained to interpret tracings.

This text describes ST segment abnormalities in detail. For example, the recent observation that ST segment elevation in lead aVR (a commonly ignored lead) is a marker for left main coronary artery (LMCA) occlusion is of lifesaving value. Because LMCA occlusion is a serious condition, any noninvasive diagnostic clue represents a valuable addition to our armamentarium. Thus, only after detailed assessment of the ST segment is completed are the QRS complex, T waves, atrial and ventricular hypertrophy, and lastly the axis assessed. This change in the analytical sequence is necessary so that the most crucial diagnoses can be made accurately and rapidly.

In addition, the standard teaching is for the interpreter to assess all leads and all deflections and waves before entertaining diagnoses. This text gives presumptive diagnoses as soon as a clue is uncovered in the tracing. Also, a few rare but life-threatening conditions are excluded early in the assessment sequence. For example, although Wolff-Parkinson-White (WPW) syndrome is uncommon, it is an important diagnosis that may be missed by computer analysis and by physicians. Because WPW syndrome is a result of widening of the QRS complex, it is logical to consider this diagnosis in the same framework as bundle branch blocks; this approach avoids the danger and embarrassment of missing the diagnosis. No text considers WPW syndrome in the assessment of the 10 essential ECG features. Most important, it is imperative to exclude mimics of MI early in the sequence. WPW syndrome may mimic MI. Right bundle branch block (RBBB) may reveal Q waves in leads III and aVF that may be erroneously interpreted as MI. Left bundle branch block (LBBB) may mimic MI and must be quickly documented because its presence hinders the accurate diagnosis of acute coronary syndromes. Furthermore, the ECG manifestation of acute MI may be a new LBBB pattern. Thus, the assessment for blocks is performed early, in step 2 of the 11 steps outlined.

Because RBBB and LBBB are best revealed in leads V_1 and V_2 , the clinician is advised to screen these leads before assessing other leads. The text advises the clinician or senior resident that the assessment of V_1 and V_2 may assist with the diagnosis of Brugada syndrome and right ventricular dysplasia, which may display particular forms of right

bundle branch block and recently have been shown to be causes of sudden death in young adults. Many rare syndromes are described in medicine, but those that cause sudden death should be made familiar to trainees and clinicians. We should not fear divulging information about such rare syndromes at an early stage to students and residents, because these topics may serve to motivate them to higher levels of excellence.

This text presents a unique 11-step method for accurate and rapid ECG interpretation in a user-friendly synopsis format. Medical house staff should welcome this step-by-step method, because it simplifies ECG interpretation and provides for greater accuracy than the approaches given in texts published over the past 50 years. The succinct writing style allows a wealth of information to be presented in a small text that is highlighted with bullets to allow for rapid retrieval. The 11 steps are illustrated in algorithms and outlined in Chapter 2 with references to later chapters, each of which expands on one of the steps and provides advanced material for senior internal medicine residents, cardiology residents, and internists. The text moves rapidly from basics to advanced material.

All diagnostic ECG criteria are given with relevant and instructive ECGs, providing a quick review or refresher for proficiency tests and for physicians preparing for the ECG section of the Cardiovascular Diseases Board Examination. This text can be a valuable tool for all those who wish to be proficient in the interpretation of ECGs.

M. Gabriel Khan

ACKNOWLEDGMENTS

I had the privilege of borrowing several ECG tracings from *Electrocardiography in Clinical Practice* by the late Dr. Te-Chuan Chou and from *Practical Electrocardiography* by Dr. Henry J.L. Marriott; I am grateful to these authors. A special note of thanks to my editor, Paul Dolgert.

ABOUT THE AUTHOR

Dr. M. Gabriel Khan is a cardiologist at the Ottawa Hospital and an Associate Professor of Medicine, at the University of Ottawa. Dr. Khan graduated MB, BCh, with First-Class Honours at The Queen's University of Belfast. He was appointed Staff Physician in charge of a Clinical Teaching Unit at the Ottawa General Hospital and is a Fellow of the American College of Cardiology, the American College of Physicians, and the Royal College of Physicians of London and Canada. He is the author of *On Call Cardiology*, 3rd ed., Elsevier, Philadelphia (2006); *Heart Disease Diagnosis and Therapy*, 2nd ed., Humana Press (2006); *Cardiac and Pulmonary Management*, Elsevier, Philadelphia, PA (1993), *Medical Diagnosis and Therapy* (1994), *Heart Attacks, Hypertension and Heart Drugs* (1986), *Heart Trouble Encyclopedia* (1996), and *Encyclopedia of Heart Diseases* (2006), Academic Press/Elsevier, San Diego; and *Cardiac Drug Therapy*, 7th ed., Humana Press (2007).

Dr. Khan's books have been translated into Chinese, Czech, Farsi, French, German, Greek, Italian, Japanese, Polish, Portuguese, Russian, Spanish, and Turkish. He has built a reputation as a clinician-teacher and has become an internationally acclaimed cardiologist through his writings.

His peers have acknowledged the merits of his books by their reviews of *Cardiac Drug Therapy*: Review of the 5th edition in *Clinical Cardiology*: "this is an excellent book. It succeeds in being practical while presenting the major evidence in relation to its recommendations. Of value to absolutely anyone who prescribes for cardiac patients on the day-to-day basis. From the trainee to the experienced consultant, all will find it useful. The author stamps his authority very clearly throughout the text by very clear assertions of his own recommendations even when these recommendations are at odds with those of official bodies. In such situations the 'official' recommendations are also stated but clearly are not preferred."

And for the fourth edition a cardiologist reviewer states that it is "by far the best handbook on cardiovascular therapeutics I have ever had the pleasure of reading. The information given in each chapter is up-to-date, accurate, clearly written, eminently readable and well referenced."

CONTENTS

Foreword <i>by Christopher P. Cannon</i>	vii
Preface	ix
Acknowledgments	xiii
About the Author	xv
1 Basic Concepts	1
2 Step-by-Step Method for Accurate Electrocardiogram Interpretation	25
3 P Wave Abnormalities	81
4 Bundle Branch Block	87
5 ST Segment Abnormalities	107
6 Q Wave Abnormalities	137
7 Atrial and Ventricular Hypertrophy	179
8 T Wave Abnormalities	193
9 Electrical Axis and Fascicular Block	209
10 Miscellaneous Conditions	223
11 Arrhythmias	249
12 ECG Board Self-Assessment Quiz	297
Index	401

1

Basic Concepts

CONTENTS

ELECTRICAL ACTIVITY OF THE HEART
ELECTROCARDIOGRAM
HOW ARE THE WAVES OF THE
ELECTROCARDIOGRAM PRODUCED?
WHY USE 12 LEADS TO RECORD THE
ELECTROCARDIOGRAM?
LEADS AND ELECTRODES
GENESIS OF THE QRS COMPLEX
VECTOR FORCES
QRS NORMAL VARIANTS AND ABNORMALITIES

ELECTRICAL ACTIVITY OF THE HEART

Each contraction of the heart is preceded by excitation waves of electrical activity that originate in the sinoatrial (SA) node. Figure 1-1 depicts the radial spread of activation from the SA node. The waves of electrical activity spread through the atria and reach the atrioventricular (AV) node. Note that the SA node tracing shows no steady resting potential, as does the ventricular muscle tracing. The SA node's spontaneous depolarization and repolarization provides a unique and miraculous automatic pacemaker stimulus that activates the atria and the AV node, which conducts the activation current down the bundle branches to activate the ventricular muscle mass. Cardiac cells outside the SA node normally do not exhibit spontaneous depolarization; thus they must be activated.

Depolarization

In a resting cardiac muscle cell, molecules dissociate into positively charged ions on the outer surface and negatively charged ions on the

From: *Contemporary Cardiology: Rapid ECG Interpretation, 3e*
by: M. Gabriel Khan © Humana Press Inc., Totowa, NJ

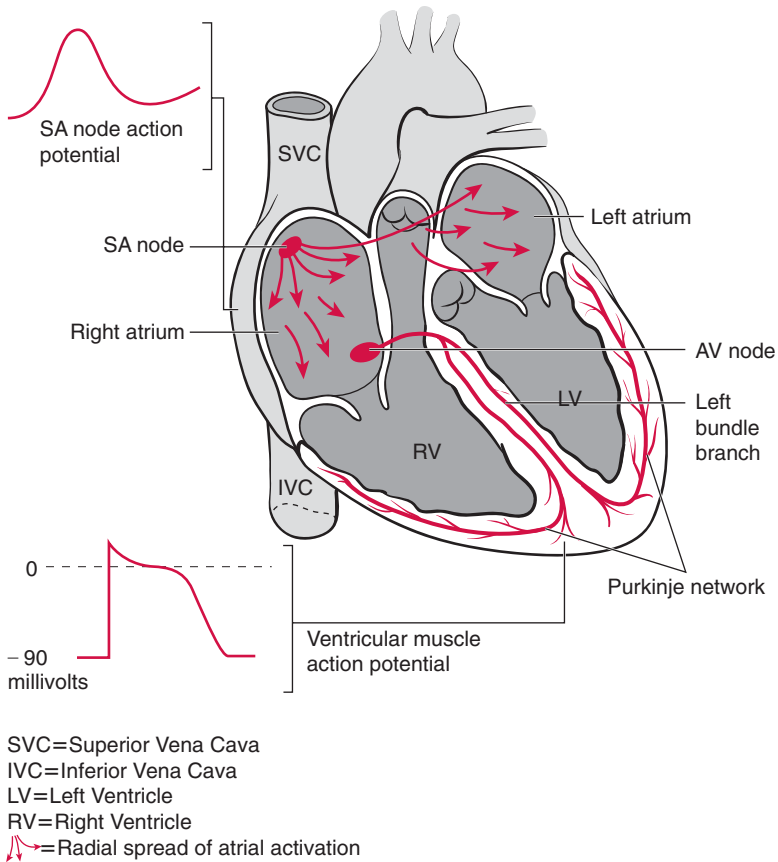


Fig. 1-1. Electrical activation of the heart by the sinoatrial (SA) node. The current of activation (arrows) spreads radially from the SA node across the atria to the atrioventricular (AV) node and down the bundle branches to the ventricular muscle and Purkinje network. The SA node tracing shows no steady resting potential and is characterized by spontaneous depolarization.

inner surface of the cell membrane; the cell is in an electrically balanced or polarized resting state (Fig. 1-2).

- When the cell is stimulated by an excitatory electrical wave, the negative ions migrate to the outer surface of the cell and the positively charged ions pass into the cell; this reversal of polarity is called depolarization (see Fig. 1-2).
- If an electrode is placed so that the depolarization wave flows toward the electrode, a galvanometer will record an upward or positive deflection (Fig. 1-3).

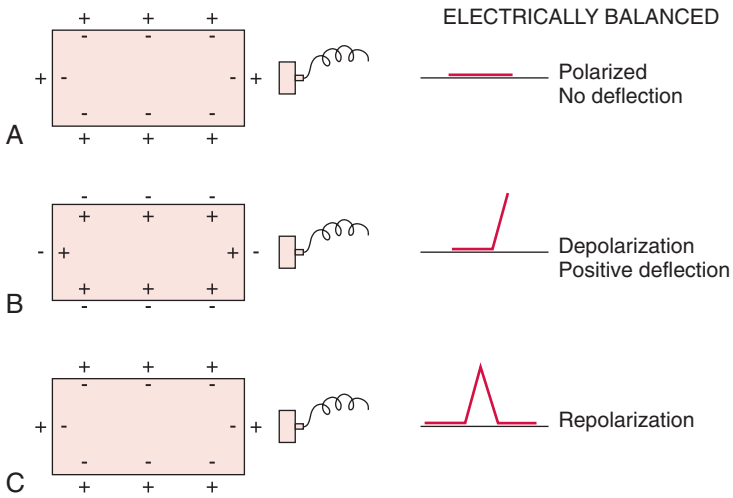


Fig. 1-2. **A,** Resting cell: Positive ions on the outer surface and negative ions inside equal an electrically balanced or polarized cell. **B,** Depolarized cell: Negative ions on the outer surface and positive ions inside. **C,** Repolarization of cell: Positive ions return to the outside.

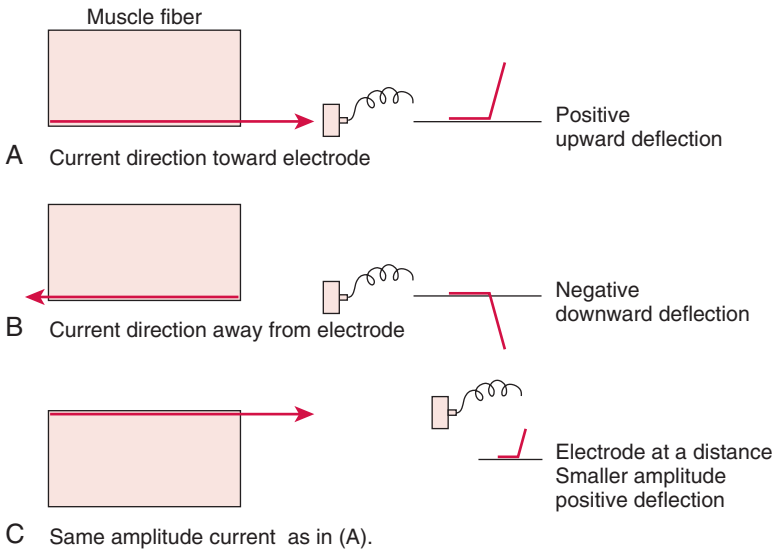


Fig. 1-3. Recording of the effects of electrical activation process. **A,** Current flows toward the electrode produce a positive upward deflection. **B,** Current flows away from the electrode produce a negative deflection. **C,** Current flows toward an electrode placed at a distance produce a positive but smaller amplitude deflection than in (A).

- When a depolarization current is directed away from an electrode, a negative or downward deflection is recorded (*see* Fig. 1-3).

Repolarization

- During a recovery period, positively charged ions return to the outer surface and negatively charged ions move into the cell. The electrical balance of the cell is restored; this process is called repolarization (*see* Fig. 1-2).
- The transfer of sodium (Na^+) and potassium (K^+) ions across the cell membrane plays an important role in generating cardiac electrical activity. In Fig. 1-4, the relative magnitudes of the concentration of Na^+ and K^+ ions are indicated. Intracellular concentration of K^+ is 30 times greater than extracellular K^+ . Na^+ concentration is 30 times less inside the cell than outside. Because of this ionic composition, the membrane of the resting cardiac fiber is in an electrically balanced or polarized state. The potential difference across the cell membrane can be measured by a microelectrode and is observed on an oscilloscope to be -90 mV .

The Action Potential

- The inward Na^+ current results in a change in transmembrane potential; results in depolarization; and is shown as the upstroke, phase 0 of the action potential. With a decrease in Na^+ and K^+ permeability, the membrane potential remains close to 0; this represents phases 1 and 2 of the action potential (*see* Fig. 1-4). The $\text{Na}^+\text{-K}^+\text{-ATPase}$ (adenosine triphosphatase) sodium pump, depicted in Fig. 1-4, pumps Na^+ from the intracellular to the extracellular fluid compartment; K^+ passes from the extracellular fluid to the intracellular fluid.
- Phase 3 is the phase of rapid repolarization and is followed by a period of stable resting potential, phase 4 of the action potential.

The appreciation of these four phases is important for the understanding of abnormal heart rhythms (arrhythmias) and the therapeutic actions of antiarrhythmics. For example, digoxin or excess catecholamines increase the slope of spontaneous phase 4 depolarization and therefore increase automaticity of ectopic pacemakers (Fig. 1-5); β -blockers cause inhibition or depression of spontaneous phase 4 diastolic depolarization and thus suppress catecholamine-induced arrhythmias, particularly those related to ischemia. Digitalis causes inhibition of the cellular Na^+ pump, which causes increased intracellular Na^+ , which is then exchanged for calcium via the $\text{Na}^+\text{-calcium}$ exchanger. Increased intracellular calcium during cardiac systole increases myocardial muscle contractility. Digitalis toxicity causes cellular calcium overload that potentiates arrhythmias.

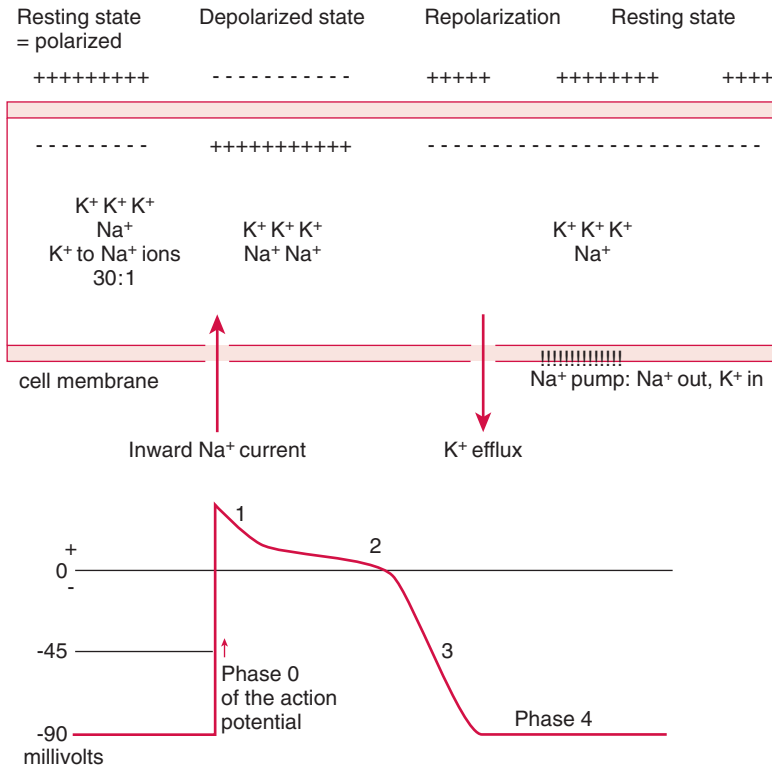


Fig. 1-4. A simplified concept of ionic exchange; the polarized, depolarized, and repolarized state of a myocardial cell; and the action potential. An electrical current arriving at the cell causes positively charged ions to cross the cell membrane, which causes depolarization, followed by repolarization, which generates an action potential: phases 0, 1, 2, 3, and 4. This electrical event traverses the heart and initiates mechanical systole, or the heartbeat (*see also* Fig. 1-7).

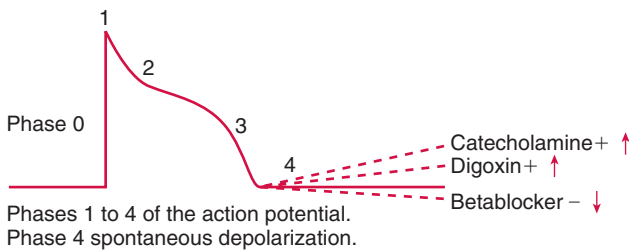


Fig. 1-5. Effects of catecholamines, digoxin, and β -blockers on spontaneous phase 4 depolarization. β -Blockers inhibit or decrease spontaneous phase 4 depolarization caused by catecholamines, especially that caused by ischemia.

Sinoatrial Node

The SA node is unique and has no steady resting potential. After repolarization, slow, spontaneous depolarization occurs during phase 4 that causes the automaticity of the SA node fibers (*see* SA node waveform in Fig. 1-1). Thus, the unique pacemaker provides individuals with an automatic infinitesimal current that sets the heart's electrical activity and contractions. The SA discharge rate, usually 50 to 100 per minute, is under autonomic, chemical, and hormonal influence.

Atrioventricular Node

The AV node provides a necessary physiologic delay of the electrical currents, which allows the atria to fill the ventricles with blood before ventricular systole.

- From the AV node and bundle of His, the excitatory electrical current rapidly traverses the right and left bundle branches, the specialized conductive tissues of the ventricles, and the Purkinje system, and the entire ventricular muscle is depolarized (*see* Fig. 1-1).
- Depolarization spreads down the intraventricular septum toward the apex of the heart and then along the free wall of the left ventricular myocardium; it always proceeds from the endocardium toward the pericardium. The specialized fine arborization of branches that constitute the Purkinje network spreads over the endocardial surfaces of the ventricles.
- The transient halt and slowing of conduction through the specialized AV node fibers play an important protective role in patients with atrial flutter and atrial fibrillation. In these common conditions, a rapid atrial rate of approximately 300 to 600 beats/min reaches the AV node; this AV “toll-gate” reduces the electrical traffic that reaches the superhighway that traverses the ventricles to approximately 120 to 180 beats/min, and serious life-threatening events are prevented.

ELECTROCARDIOGRAM

The heart muscle is made up of several thousand muscle elements, about 10^{10} cells. Each instant of depolarization or repolarization represents different stages of activity for a large number of cells. The electrical activity of each element can be represented by a vector force.

- A vector is defined as a force that can be represented by direction and magnitude. The sum total of cardiac vectors is considered the electrical activity of the entire heart (Fig. 1-6). The ECG records the sequence of such instantaneous vectors.

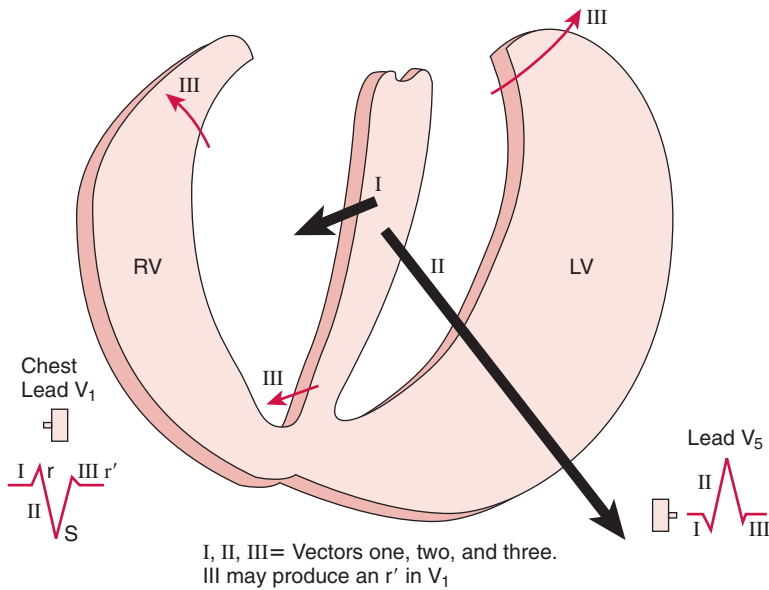


Fig. 1-6. Electrical activation of the heart: resultant vector forces. Vector III may produce an r' in V_1 .

- The heart muscle is arranged in three muscle masses: the intraventricular septum, a large left ventricular muscle mass, and a small right ventricular muscle mass. The magnitude or amplitude of the deflections recorded is influenced by the size of the muscle mass depolarized and the distance from the recording electrode (*see* Figs. 1-3 and 1-6).

The graphic representation of the heart's electrical activity recorded through electrodes positioned at strategic points on the body constitutes the electrocardiogram (ECG). The recording of the electrical currents, their direction, and their magnitude, as well as the rate of the heart's contractions, is made by the machine and electrocardiograph, which is essentially a galvanometer whose deflections are recorded on moving, specially prepared paper.

The ECG is the recording obtained, and to simplify interpretation, it suffices to state that the ECG displays the following:

- Three major deflections or waves: the P wave, the QRS complex, and a T wave (Fig. 1-7).
- Two time intervals of clinical importance: the PR interval and QRS duration (*see* Fig. 1-7).

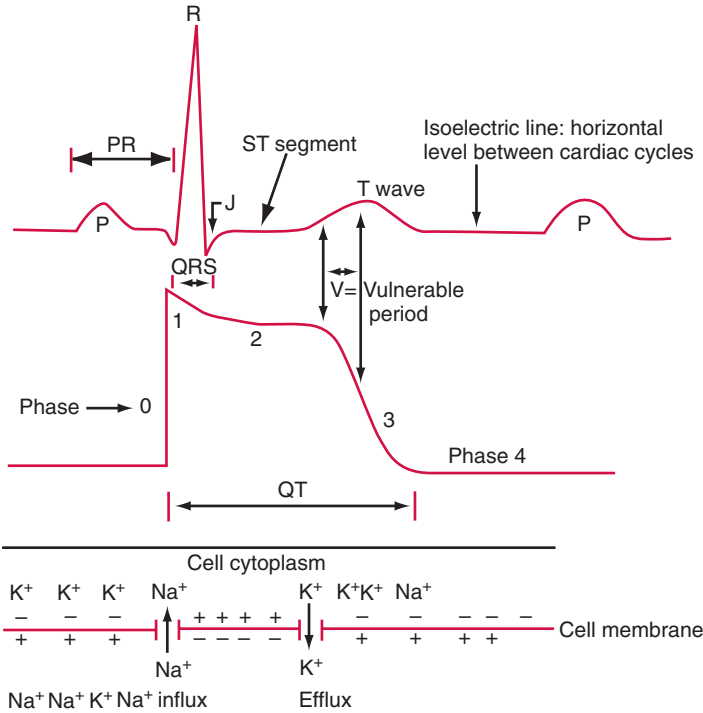


Fig. 1-7. Sodium influx, potassium efflux, the action potential, and the electrocardiogram. (From Khan, M. Gabriel: *On Call Cardiology*, 3rd ed., Philadelphia, 2006, WB Saunders, Elsevier Science.)

- The ST segment, a most important ECG component. The study of abnormalities of the ST segment reveals the early diagnosis of acute myocardial infarction (MI) and myocardial ischemia. Thus, this text devotes an in-depth chapter to abnormalities of the ST segment and does so early in the interpretive sequence; that is, before analysis of abnormalities of the P wave, ventricular hypertrophy, QRS abnormalities, and the electrical axis, all of which are discussed early in other textbooks. This approach simplifies ECG interpretation and is a strategy that is now embraced by physicians who render acute care to patients with acute MI and those with myocardial ischemia.

HOW ARE THE WAVES OF THE ELECTROCARDIOGRAM PRODUCED?

P Wave

The early part of the P wave represents the electrical activity generated by the right atrium; the middle portion of the P wave represents

completion of right atrial activation and initiation of left atrial activation; and the late portion is generated by the left atrium. The P wave is the first deflection recorded and is a small, smooth, rounded deflection that precedes the spiky-looking QRS complex (Fig. 1-8). (See Chapter 3 for an in-depth discussion of P waves.)

PR Interval

The PR interval involves the time required for the electrical impulse to advance from the atria through the AV node, bundle of His, bundle branches, and Purkinje fibers until the ventricular muscle begins to depolarize (*see* Figs. 1-7 and 1-8).

QRS Complex

The QRS complex represents the spread of electrical activation through the ventricular myocardium; the resultant electrical forces generated from ventricular depolarization is recorded on the ECG as a spiky deflection (*see* Figs. 1-7 and 1-8). The sharp, pointed deflections are labeled QRS regardless of whether they are positive (upward) or negative (downward).

Figure 1-9 indicates the conventional labeling of the QRS complex: q or Q, r or R, s or S, depending on the size of the components that

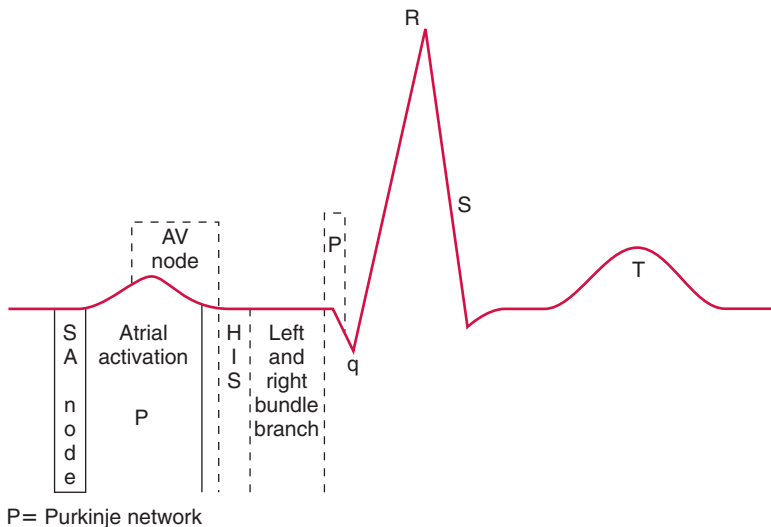


Fig. 1-8. Relationship of P wave, PR interval, and QRS complex to activation from the sinoatrial (SA) node, atrioventricular (AV) node, bundle of His (HIS), and bundle branches. Note that the normal ST segment curves imperceptibly into the ascending limb of the T wave and is not a horizontal line.

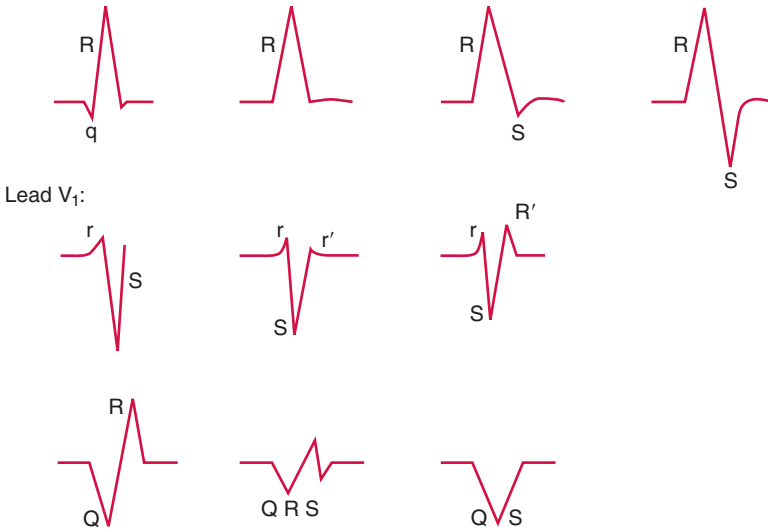


Fig. 1-9. Variation in QRS wave form. Uppercase letters are used to denote large deflection; R or r is used for first positive deflection; and R' or r' for second positive wave. Q or q is used for negative deflection before an r or R wave.

may be recorded (i.e., those influenced by the electrode position) and the direction of the resultant vector forces. Large deflections are labeled with uppercase letters.

The genesis of the QRS complex is intricate and is better understood after the reader has been presented with information on leads and lead positions and why 12 leads are used to capture 12 views of the heart's electrical activity. Thus the genesis of the QRS complex is discussed at the end of this chapter.

ST Segment

The ST segment is the segment that lies between the end of the QRS complex and the beginning of the T wave (*see* Figs. 1-7 and 1-8). It represents the period when all parts of the ventricles are in the depolarized state or a stage in which the terminal depolarization and the starting repolarization are superimposed and thus neutralize each other. Early repolarization may encroach on the ST segment to a variable degree. The part at which the ST segment takes off from the QRS complex is called the J, or the junction point. The ST segment normally curves imperceptibly into the ascending limb of the T wave and should not form a horizontal line nor form a sharp angle with the proximal

limb of the T wave. The student must be aware of this important diagnostic point.

This important diagnostic ECG segment is discussed in detail in Chapters 2 and 5.

T Wave

The T wave represents electrical recovery, repolarization of the ventricles, and is a broad, rounded wave (*see* Figs. 1-7 and 1-8). The T wave follows each QRS complex and is separated from the QRS by an interval that is constant for that ECG. Because ventricular recovery proceeds in the general direction of ventricular excitation, the polarity of the resultant T vector is similar to that of the QRS vector. The T wave is recorded during ventricular systole, whereas the QRS occurs immediately before mechanical systole.

- The T wave process is energy consuming, but the QRS process is not. During repolarization, cellular metabolic work and energy consumption occurs to accomplish the ionic flux associated with repolarization. Thus several metabolic, hemodynamic, and physiologic factors may affect the repolarization process and alter the morphology of the T wave. The student or clinician interpreting ECGs should be aware of the normal variations in T wave morphology and the influence of a host of factors that may alter the T wave and lead to erroneous diagnoses.
- Levine listed approximately 67 causes for T wave changes, which include the patient drinking ice water, eating, exercising, or fasting or having infections, fever, tachycardia, anoxia, shock, electrolyte derangements, acidemia, alkalemia, hormonal imbalances, subarachnoid hemorrhage, or drug or alcohol abuse.

Because of the unreliable diagnostic yield derived from the scrutiny of T waves, further details on this topic are relegated to Chapter 8.

U Wave

The U wave is a wave that follows the T wave and is observed only in the ECG tracings of some individuals. It is a small, often indistinct wave, and its source is uncertain (*see* Chapter 8).

WHY USE 12 LEADS TO RECORD THE ELECTROCARDIOGRAM?

Einthoven's discovery in 1901 was of paramount importance. His landmark paper was published in 1901, and a further paper on the galvanometric registration of the human electrocardiogram was published

in 1903. However, the initial work of Galvani (1791), Muller (1856), and Waller (1887) initiated Einthoven's accomplishment. Einthoven recognized that the heart possessed electrical activity, and he recorded this activity using two sensors attached to the two forearms and connected to a silver wire that ran between two poles of a large permanent magnet. He noted that the silver wire moved rhythmically with the heartbeats, but to visualize the small movements Einthoven shone a light beam across the wire, and the wavy movements of the wire were recorded on moving photographic paper. Einthoven recorded the waves and spiky deflection and labeled the first smooth, rounded wave, P; the spiky deflection, QRS; and the last recorded wave, T.

- Einthoven labeled the waves P, Q, R, S, and T; his lettering obeyed the convention used by geometers: curved lines were labeled beginning with P, and points on straight lines were labeled beginning with Q.

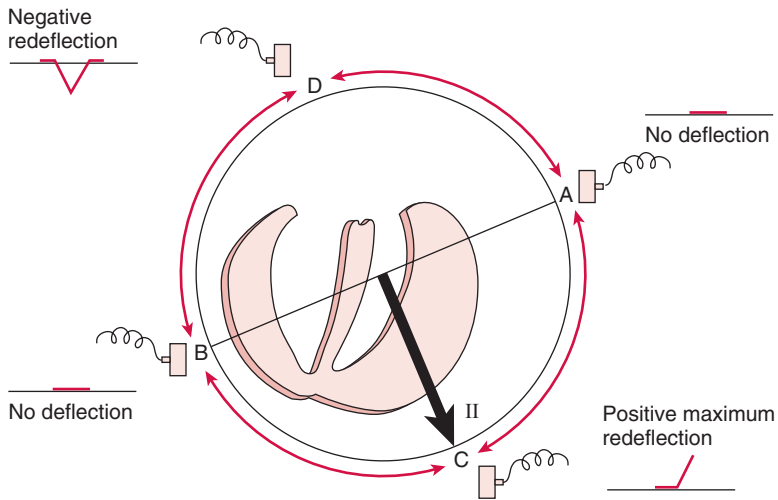
Einthoven, Sir Thomas Lewis, and others correlated the ECG waves with the contracting heart and correlated that the P wave was related to atrial contraction and that the QRS deflection was associated with ventricular contraction. Improvements in the quality of recordings resulted from the immense work and technique of Frank Wilson, who studied with Lewis and, in Michigan (1934), described the unipolar leads that include the precordial V leads and VR, VL, and VF.

LEADS AND ELECTRODES

Why Are 12 Leads Necessary?

Figure 1-10 shows the infinite number of electrode positions arranged in a continuous circle, at the center of which is the origin of the depolarization wave. The illustration indicates that the electrode position has a profound influence on the size, or amplitude, of the recording.

- Twelve ECG leads are used to obtain 12 views of the heart's electrical activity. The heart may be considered to lie at the center of an equilateral triangle (Fig. 1-11). The leads attached to the limbs, the limb leads, act as linear conductors and have virtually identical voltages at all points along their lengths. The limbs can be regarded as extensions of a lead wire. Thus, the left arm electrode placed at the wrist, arm, or shoulder displays the same ECG record. Because the limb leads act as linear conductors, the effective sensing points and electrode locations are at the left and right shoulders and left groin, but are usually positioned and labeled as follows:



II = Vector II
 AB perpendicular to electrical current

Fig. 1-10. Effect of varied electrode positions on the amplitude and direction of deflections recorded: Leads between C and A or C and B give positive deflection less than at C. Leads at D and A or D and B record negative deflection of varying size. The line AB is perpendicular to the electrical current.

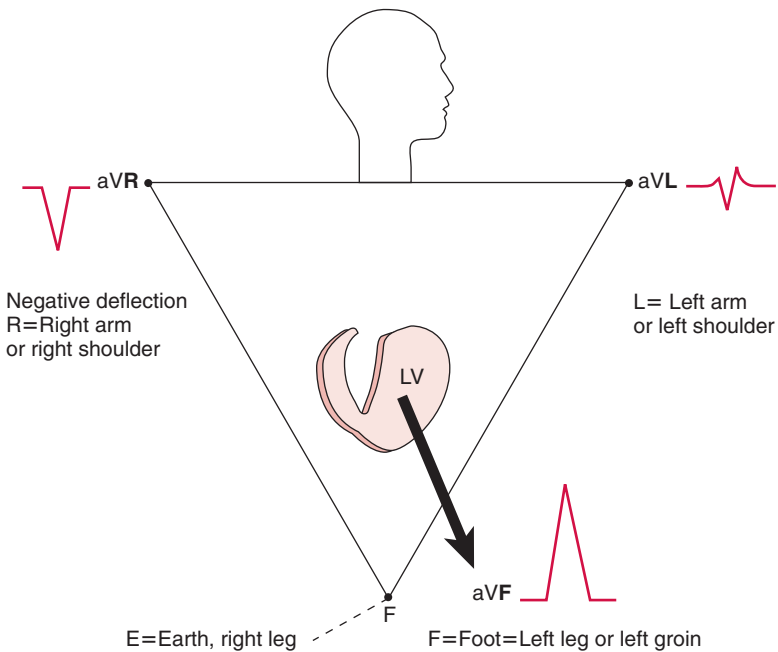


Fig. 1-11. The heart depicted as a three-muscle mass that lies in the center of an equilateral triangle. The two shoulders and left groin are sensing positions.

- R = right arm lead
- L = left arm lead
- F = foot = left leg lead

These leads lie along the frontal plane of the body and display action potential only in the frontal plane. (See discussion of frontal plane axis in Step 9 in Chapter 2 and in Chapter 9.)

Two important concepts must be reemphasized:

- If the excitatory depolarization head of the current (vector force) flows toward a unipolar electrode, a galvanometer will record an upward or positive deflection (*see* Fig. 1-3).
- When an excitatory depolarization process is directed away from the electrode, a downward or negative deflection is recorded (*see* Fig. 1-3).

Figure 1-11 displays deflections that can be recorded by limb leads R, L, and F. The main electrical current of activation flows toward the F (left leg) electrode and records an upward or positive deflection of large amplitude. The current flows away from the right shoulder (R) electrode and records a downward deflection. The right shoulder lead (R) looks into the interior of the heart toward the endocardium, and as mentioned previously, the current of activation flows from the endocardium and traverses the myocardium toward the pericardium and thus displays a negative deflection. The student should notice that aVR is always relatively negative and aVF is always relatively positive.

- Lead L at the left shoulder or left arm usually displays a small positive or equiphase deflection, but the heart hangs in the chest and is subject to rotational changes, and the main current direction may be altered; thus, this lead may show a large-amplitude positive deflection in some individuals, and a negative deflection if the heart's position is vertical.

Why Augmented Leads?

- Why is a V added to the R, L, and F? These leads are termed unipolar limb leads, but voltage measurements are virtually never unipolar. The connection formed by attaching the R, L, and F electrodes together acts as a reference connection, and the lead formed is termed a V lead (V = voltage); thus the convention VR, VL, and VF, and the V is also used for the leads positioned on the chest, V₁ to V₆.
- Goldberger (1942) augmented Wilson's unipolar extremity leads that gave low-amplitude records; Goldberger's strategy increased the amplitude of the deflections by 50%. Thus, the letter a is used to denote the

augmented lead (e.g., aVL = augmented-voltage left arm lead [V = voltage]).

Standard Bipolar Limb Leads I, II, and III

Figure 1-12 shows the views of the heart obtained by leads I, II, and III.

- Lead I connects the two arms and is formed by connecting L to the positive terminal and R to the negative terminal of the galvanometer; thus, $I = aVL = aVR$. Lead I looks at the heart from the left, inferior to lead aVL, the lead of the left shoulder (arm), and displays the electrical tracing produced by a combination of the right arm and left arm electrodes. The right leg electrode is an earth (or ground) and minimizes interference.
- Lead II looks at the heart from a position to the left of the left groin, foot lead F (see Fig. 1-12).
- Lead III looks at the heart from a position to the right of the left groin, foot lead F. Thus, leads II, III, and aVF look at the inferior surface of the heart from different angles, and they usually show some similarities. Lead III is the most unreliable of the leads II, III, and aVF. Thus, many errors are made from the observation of the QRS and T wave in lead

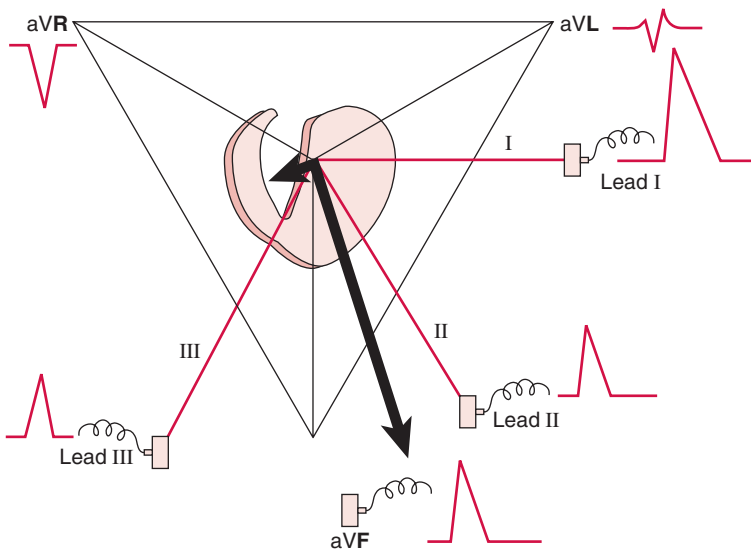


Fig. 1-12. Standard limb leads I, II, and III. Note that aVF leads II and III look at the inferior surface of the heart and deflections show minor variation. Leads I and aVL look at the anterolateral aspect of the heart.

- III. Normal yet pathologic-appearing Q waves and T wave inversion may be observed frequently in lead III as a normal variant (*see* Chapters 6 and 8).
- The six leads display six photographs of the heart's electrical activity taken from six angles (one every 30 degrees). The six leads can be visualized as traversing a flat plane over the chest of the patient (i.e., the frontal plane). Importantly, if only two of the six leads are recorded, the most informative pair are I and aVF.

Vertical Versus Horizontal Heart Position

Figure 1-13 shows the changes in QRS waveform caused by alteration of the position of the heart:

- Both aVR and aVL face the ventricular cavity and show a QS complex.
- A qR complex in lead aVL indicates a horizontal heart position, and the QRS morphology in aVL resembles that in V₅.
- A qR complex in aVF and a QS complex in aVL indicate a vertical heart position, and the QRS morphologies in leads aVF and V₅ resemble each other.
- The position of the heart varies between horizontal and vertical.

Chest Leads/Precordial or V Leads

The six chest leads give six more views of the heart's electrical activity and vector forces; they are positioned around the anterior and left chest wall in a horizontal plane. Figures 1-14 and 1-15 indicate the position of the precordial chest leads that overlie the right and left ventricles.

V₁ and V₂ face and lie close to the wall of the right ventricle. V₂ and V₃ lie near the intraventricular septum. V₄ and V₃ look at the anterior parts of the left ventricle, with V₄ close to the apex. V₅ and V₆ (leads I and aVL) view the anterolateral region of the left ventricle and often appear similar to each other. The recording in lead aVL, however, varies depending on a horizontal or vertical heart position. If V₇ is taken, it is positioned in the posterior axillary line.

The precordial electrodes V₁ to V₆ are so close to the electrical currents of the heart that no augmentation is necessary. Lead V₆ is far around (in the axilla) and is separated from the free wall of the left ventricle by a significant distance. Figure 1-15 indicates the approximate relationship of the ventricular myocardium and the precordial chest leads V₁ to V₆.

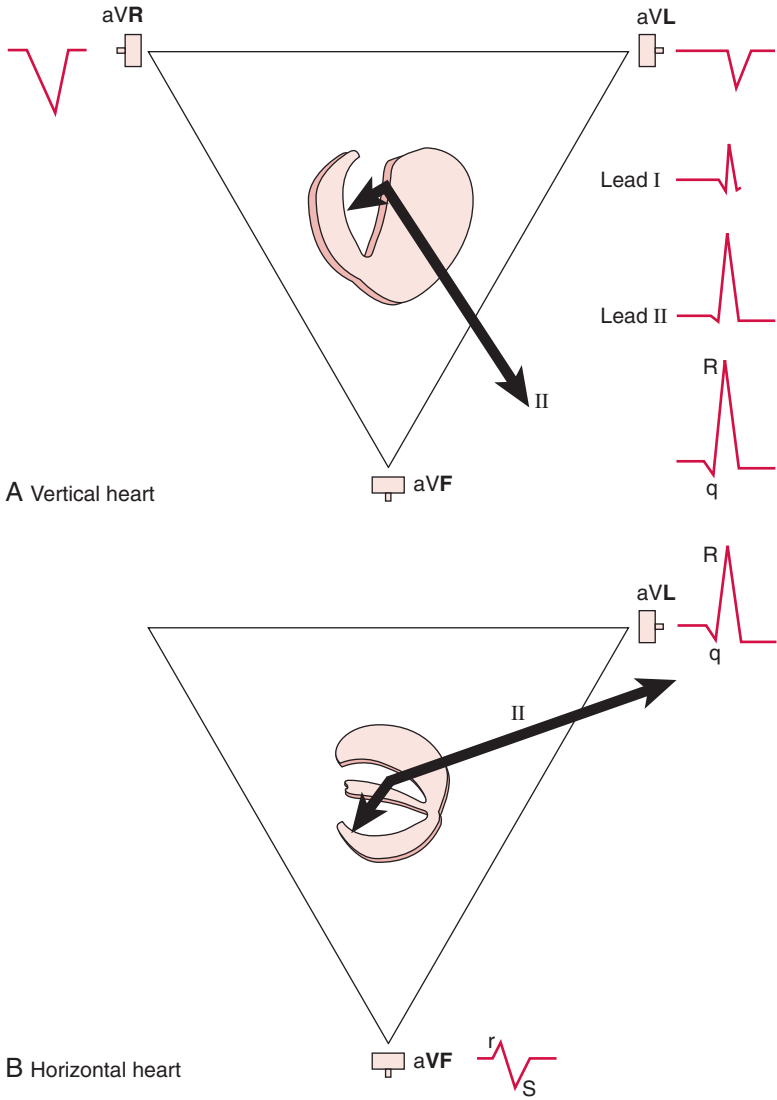


Fig. 1-13. Changes in deflections with the heart in a vertical (A) and a horizontal (B) position. In the vertical position (A), both the aVR and aVL face the cavity of the ventricles and record a QS complex. A QRS complex in aVF indicates a heart that is positioned close to vertical; qRS in aVL indicates a horizontal heart position (B).

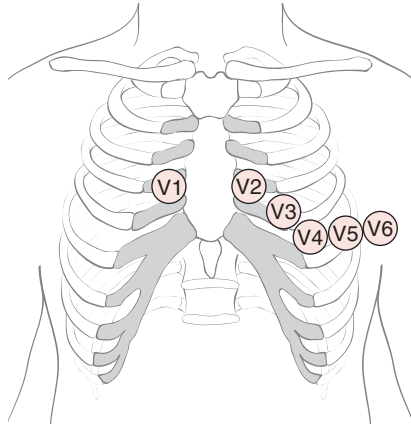


Fig. 1-14. Position of precordial chest leads.

Figure 1-16 reemphasizes that the position of leads aVL and aVF and other limb leads are in the same frontal plane. The chest leads V₁ to V₆ encircle the left thorax in a horizontal plane (see Fig. 1-15).

Caution: The entire chest, with the heart within it, acts as a volume conductor, and thus voltage varies appreciably at locations only a centimeter apart. Therefore, the leads placed on the chest wall V₁ to V₆

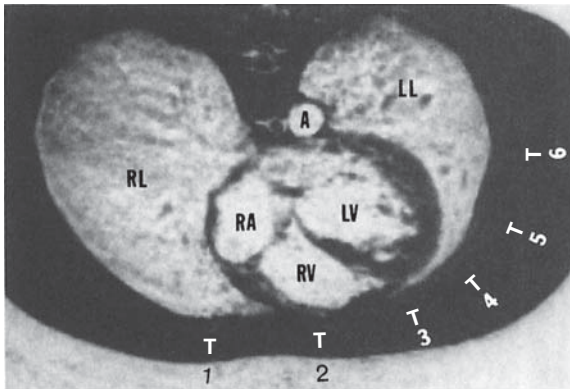


Fig. 1-15. Magnetic resonance image of heart to illustrate approximate relationship of chest electrodes to cardiac chambers. Points 1 to 6 represent sites of the six precordial electrodes V₁ to V₆. RA, right atrium; RV, right ventricle; LV, left ventricle; RL, right lung; LL, left lung; A, aorta. (From Marriott HJL: *Practical Electrocardiography*, 8th ed., Philadelphia, 1988, Williams & Wilkins.)

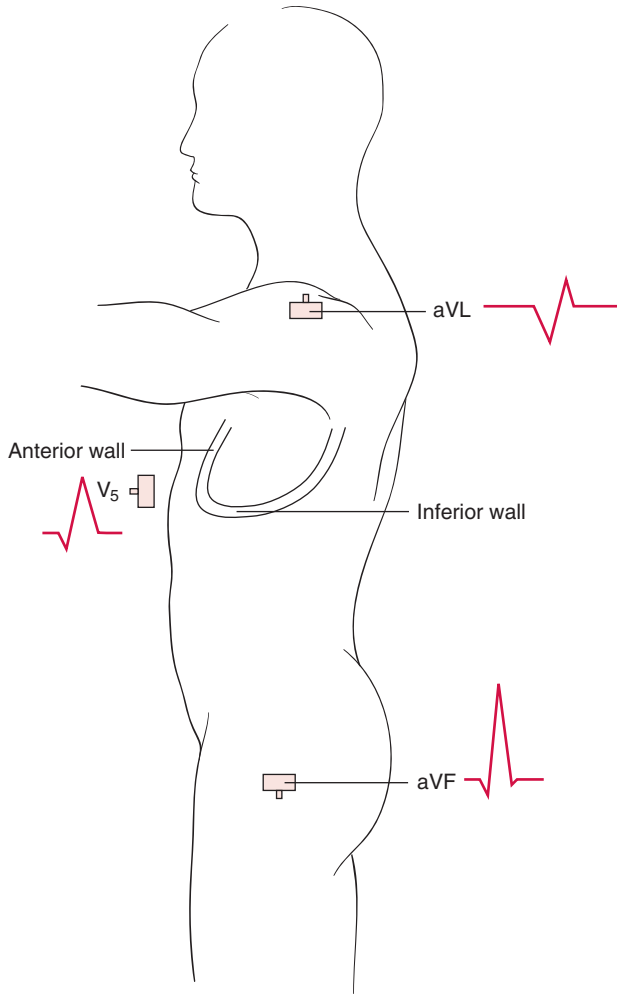


Fig. 1-16. aVF and aVL are in the same frontal plane. The chest leads encircle the left thorax in a horizontal plane.

must be positioned meticulously so that when the ECG is repeated days or years later, accurate comparison can be made. Caution is required so that the V_5 and V_6 electrodes are not placed too anteriorly. V_5 must be placed in the anterior axillary line; V_6 should be placed in the midaxillary line at the level of V_4 in the fifth intercostal space or in line with the apex beat.

If lead V_3 is placed too close to V_2 or is positioned near the left third intercostal space, no positive deflection or a reduced-amplitude R wave may be recorded, which can falsely simulate an anterior MI. If lead V_2 is positioned too close to V_1 , no R wave may be recorded in lead V_2 , and the erroneous diagnosis of anteroseptal MI may be made. These errors are made commonly in the ECGs of females, and they may be interpreted as “loss or poor R wave in V_3 , consider anteroseptal MI.” An ECG with faulty recording may lead to serious errors in interpretation.

GENESIS OF THE QRS COMPLEX

Understanding the genesis of the QRS complex is a fundamental step. Knowledge of the normal sequence of activation or depolarization of the ventricles is crucial to an understanding of the normal and abnormal QRS complex. The accurate diagnosis of acute and old MI, right and left bundle branch block, hemiblocks, and ventricular hypertrophy depends on knowledge of resultant vectors that dictate the components of the QRS complex.

The electrical impulse that proceeds from the SA node activates the atria, producing the P wave, the first wave of the ECG. The electrical impulse is briefly slowed in the AV node, then progresses rapidly down the bundle of His, the right and left bundle branches, and the Purkinje fibers of the ventricular myocardium. The spread of the electrical impulses through the septum and ventricular muscle is called depolarization, which produces the QRS complex of the ECG.

VECTOR FORCES

The electrical impulses that activate each area of heart muscle have direction and magnitude and can be represented by a vector force. The direction of the resultant force can be represented by an arrow, the length of which represents the magnitude of the force. The term *vector* does not imply vector cardiography.

Three Caveats

A vector describes a force in terms of its duration and magnitude. The following three caveats must be considered:

1. An electrical impulse traveling toward an electrode causes a positive deflection or R wave (Fig. 1-17).
2. When the impulse is traveling away from the electrode, a negative deflection occurs (i.e., an S, a small Q, or a QS wave is recorded).
3. Three resultant vectors dictate the inscription of the QRS complex.

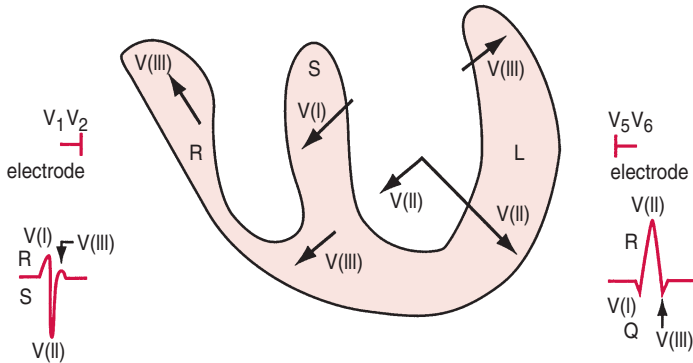


Fig. 1-17. Genesis of the normal QRS complex. V(I), vector I produces a small r wave in leads V_1 and V_2 , Q in leads V_5 and V_6 ; V(II), vector II produces an S wave in lead V_1 and an R wave in lead V_5 or V_6 ; V(III), vector III produces the terminal S in leads V_5 and V_6 and the terminal r or r' in V_1 , V_2 , and aVR; V_1 , lead V_1 electrode; V_6 , lead V_6 electrode; R, right ventricle muscle mass; L, left ventricle muscle mass; S, septum. (From Khan, M. Gabriel: *On Call Cardiology*, 3rd ed., Philadelphia, 2006, WB Saunders, Elsevier Science.)

Vector I

- The ventricular septum is activated from left to right; electrodes or leads positioned over the right ventricle (V_1 or V_2) face the wave of depolarization and inscribe a positive wave, a small R wave (see Fig. 1-17).
- Because the force of the activation impulse (vector I) is small, the positive deflection is small; the R wave recorded in V_1 and V_2 is small and ranges from 1 to 4 mm in V_1 and from 1 to 7 mm in V_2 in normal individuals older than age 30 years (see Table 2-1). Incorrect lead placement of V_1 , V_2 , and V_3 , especially in women, may cause the ECG tracing to falsely show diminished or loss of R or r waves in V_2 and V_3 , which is often incorrectly interpreted as anteroseptal MI.
- The initial depolarizing current travels away from leads V_5 and V_6 and thus inscribes a small negative deflection, a small Q wave in leads V_5 , V_6 , and I.

Vector II

- After septal depolarization, both ventricular walls are activated simultaneously.
- The impulse depolarizes the thin-walled right ventricle; however, the magnitude of the forces is small in comparison with the forces that activate the thick left ventricular free wall. Thus, the resultant force, vector II, is directed toward and through the left ventricular free wall (see Fig. 1-17).

- The resultant force, vector II, is indicated by an arrow directed toward the left; the electrodes V₅ and V₆ face the left ventricle and show a positive wave, an R wave, the height of which depends on the thickness of the left ventricular muscle. The height of the R wave in V₄ through V₆ ranges from 10 to 25 mm and may exceed 30 mm in individuals with left ventricular hypertrophy and in normal subjects younger than age 25 years. The R wave in V₄ through V₆ is lost or is reduced to less than 3 mm in height in patients with anterior MI.
- Because the electrical current represented by vector II travels away from an electrode overlying the right ventricle, V₁ and V₂ record a negative deflection, an S wave.
- The larger the left ventricular muscle, the deeper the S wave in V₁ and V₂.

Vector III

- Activation of the posterobasal right and left ventricular free walls and the basal right septal mass, including the crista supraventricularis, represents vector III.
- The resultant force is directed to the right, is small in magnitude, and may record a small S wave in V₅ and V₆ and a terminal r' wave in lead V₁ or V₂; thus, an Rsr' pattern in V₁ may occur in normal individuals.

QRS NORMAL VARIANTS AND ABNORMALITIES

Clockwise and Counterclockwise Rotation

- Variations in the normal QRS configuration are shown in Fig. 1-18. If the heart undergoes strong clockwise or counterclockwise rotation, changes in QRS morphology occur. Failure to recognize these normal variants may result in incorrect interpretation of the ECG.
- With clockwise rotation, the V₁ electrode, like aVR, faces the cavity of the ventricle and records a QS complex; therefore Q waves can occur as a normal finding if there is extreme clockwise rotation of the heart (*see* Fig. 1-18). The normal Q wave in V₆ disappears because the resultant force of the initial vector I is not directed toward the electrode V₁.

Tall R Waves

- If the left ventricle is hypertrophied, the magnitude of vector force II increases; thus, a tall R wave is recorded in V₅ and V₆ (*see* Fig. 2-25). With right ventricular hypertrophy, the magnitude of vector force I increases and tall R waves occur in V₁ and V₂ (*see* Fig. 2-26 and Table 2-3).

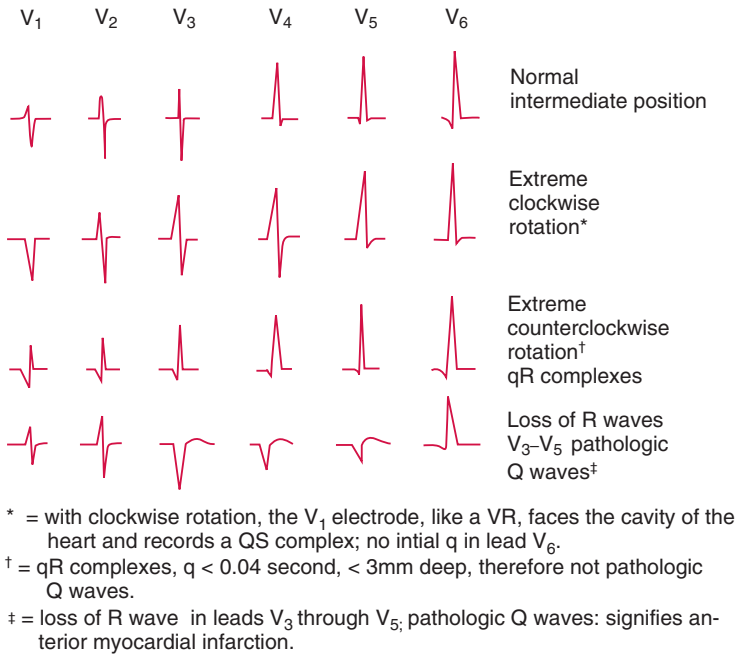


Fig. 1-18. Variations in the normal precordial QRS configuration and correlations with abnormals. (*) With clockwise rotation, the V₁ electrode, like a VR, faces the cavity of the heart and records a QS complex; no initial q in lead V₆. (†) qR complexes: q < 0.04 second, < 3 mm deep; therefore not pathologic Q waves. (‡) Loss of R wave in leads V₃ through V₅; pathologic Q waves: signifies anterior myocardial infarction. (From Khan, M. Gabriel: *On Call Cardiology*, 3rd ed., Philadelphia, 2006, WB Saunders, Elsevier Science.)

Q Waves

A myocardial infarct is an area of necrotic cells caused by the blood supply to that area of heart muscle being cut off. The necrotic area is an electrical window:

- If there is necrosis of the left ventricular muscle facing electrodes V₄ through V₆, no R waves (i.e., Q waves) will be produced (*see* Figs. 1-18, 2-18, and 2-19) or the R in V₃ through V₅ may be considerably decreased; this is termed poor R wave progression (*see* Chapter 6). Loss of R waves or poor R wave progression in leads V₃ through V₅ may indicate anterior MI (*see* Fig. 2-18).
- R waves should increase in amplitude from V₂ through V₄. If R waves are present in leads V₁ and V₂ and are not present in V₄ through V₆, a diagnosis of anterolateral MI should be considered (*see* Fig. 2-19).

- Infarction of the ventricular septum causes the loss of vector I, as well as loss of the normal R wave in leads V_1 and V_2 (i.e., pathologic Q waves), indicating anteroseptal infarction (*see* Fig. 2-18A).
- Normal Q waves are less than 0.04 second in duration and are less than 3 mm deep. These small Q waves are recorded when a small activation current is directed away from the electrode. Small Q waves are found normally in leads V_5 , V_6 , and I (*see* Fig. 2-2). Changes in the position of the heart may cause small Q waves in leads III, aVF, and aVL; with extreme counterclockwise rotation, small Q waves occur in V_1 through V_6 (*see* Fig. 1-18).
- Leads III and aVL may record narrow Q waves up to 10 mm deep in normal individuals. In lead III, the Q wave can be normally ≤ 0.04 second wide (*see* Fig. 2-2D). In all other leads, Q waves should be considered normal if they are less than 0.04 second wide and less than 3 mm deep. If Q waves are not observed in leads II or aVF, a Q wave in lead III should be considered normal (*see* Table 2-1).
- Hypertrophy of the interventricular septum occurs in hypertrophic cardiomyopathy, and the ECG often reveals deep Q waves that can mimic MI (*see* discussion of pathologic Q waves and QS patterns given under Step 6 in Chapter 6).
- When the arm leads are inadvertently placed on the legs and vice versa, Q waves are recorded in leads II, III, and aVF; consider this technical error if there is no deflection in lead I (*see* Fig. 2-39).
- Replacement of ventricular muscle by tumor; fibrosis; or amyloid, sarcoid, or other granuloma may cause an electrical window and Q waves that simulate infarction.
- Lead aVR normally records a negative QRS or QS complex because aVR looks into the cavity of the ventricle and faces the endocardial surface; the activating current flows from endocardium to pericardium (*see* Fig. 2-2B).
- See Chapter 5 for the recently observed importance of ST segment elevation in aVR and the diagnosis of acute MI.

2

Step-by-Step Method for Accurate Electrocardiogram Interpretation

CONTENTS

INTRODUCTION

BRIEF HIGHLIGHTS OF AN 11-STEP METHOD

THE NORMAL ELECTROCARDIOGRAM

STEP 1: ASSESS RHYTHM AND RATE (FIG. 2-3)

STEP 2: ASSESS INTERVALS AND BLOCKS (FIG. 2-4)

STEP 3: ASSESS FOR NONSPECIFIC

INTRAVENTRICULAR CONDUCTION DELAY AND
WOLFF-PARKINSON-WHITE SYNDROME (FIG.
2-9)

STEP 4: ASSESS FOR ST SEGMENT ELEVATION OR
DEPRESSION (FIG. 2-12)

STEP 5: ASSESS FOR PATHOLOGIC Q WAVES (THAT
IS, LOSS OF R WAVES) (FIG. 2-16)

STEP 6: ASSESS P WAVES (FIG. 2-21)

STEP 7: ASSESS FOR LEFT AND RIGHT

VENTRICULAR HYPERTROPHY (FIG. 2-24)

STEP 8: ASSESS T WAVES (FIG. 2-27)

STEP 9: ASSESS ELECTRICAL AXIS (FIG. 2-30)

STEP 10: ASSESS FOR MISCELLANEOUS
CONDITIONS (FIG. 2-32)

STEP 11: ASSESS ARRHYTHMIAS (FIG. 2-37)

ELECTROCARDIOGRAM TECHNIQUE

INTRODUCTION

Conventional Sequence Regarding Interpretation

The time-honored advice to students and staff is as follows: In every ECG, the following features should be examined systematically:

From: *Contemporary Cardiology: Rapid ECG Interpretation, 3e*
by: M. Gabriel Khan © Humana Press Inc., Totowa, NJ

- Rate
- Rhythm
- P wave morphology
- PR interval
- QRS interval, QRS complex morphology
- ST segment
- T wave
- Electrical axis
- U wave, and QT duration

Some authors, advise the following sequence:

Assess: rate, rhythm, axis, hypertrophy, infarction

but this is not the conventional teaching of cardiology tutors.

New Sequence for Interpretation

This text departs somewhat from the conventional sequence and gives a new approach consistent with the changes in cardiology practice that have evolved over the past decade. The early diagnosis of acute MI depends on astute observation for abnormal changes in the ST segment. Determination of creatinine kinase MB (CK-MB) and troponins is not relevant in the early phase of acute MI, because these cardiac enzymes are not elevated and are nondiagnostic within the crucial first hour of onset of MI. The door-to-needle or balloon time must be minimized if maximal life-saving is to be achieved. Diagnosis depends on symptoms and ST segment changes. Thus, this text rushes the interpreter to the assessment of ST segment morphology and suggests an *11-step method* or sequence for the rapid yet accurate interpretation of ECGs.

BRIEF HIGHLIGHTS OF AN 11-STEP METHOD

Figure 2-1 defines the ECG waveform; Fig. 2-2A–F shows features of the normal ECG; and Table 2-1 gives normal ECG intervals and parameters.

An 11-step method is advised to ensure accurate, yet rapid, interpretation of the ECG. Algorithms, illustrations, and many sample ECGs make the 11 steps easy to understand and apply. The 11 steps are briefly outlined in this chapter, and each step receives in-depth coverage in later chapters, which also give advanced diagnostic features for postgraduates.

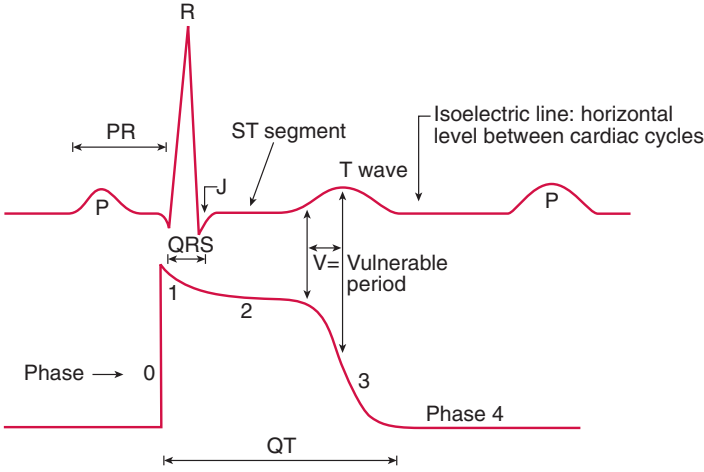


Fig. 2-1. Sodium influx, potassium efflux, the action potential, and the ECG. (From Khan, M. Gabriel: *On Call Cardiology*, 3rd ed., Philadelphia, 2006, WB Saunders, Elsevier Science.)

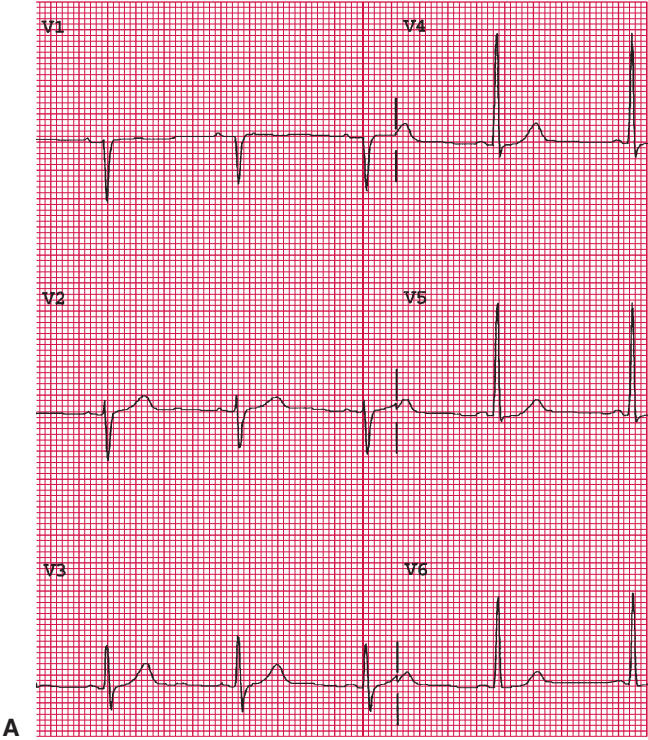
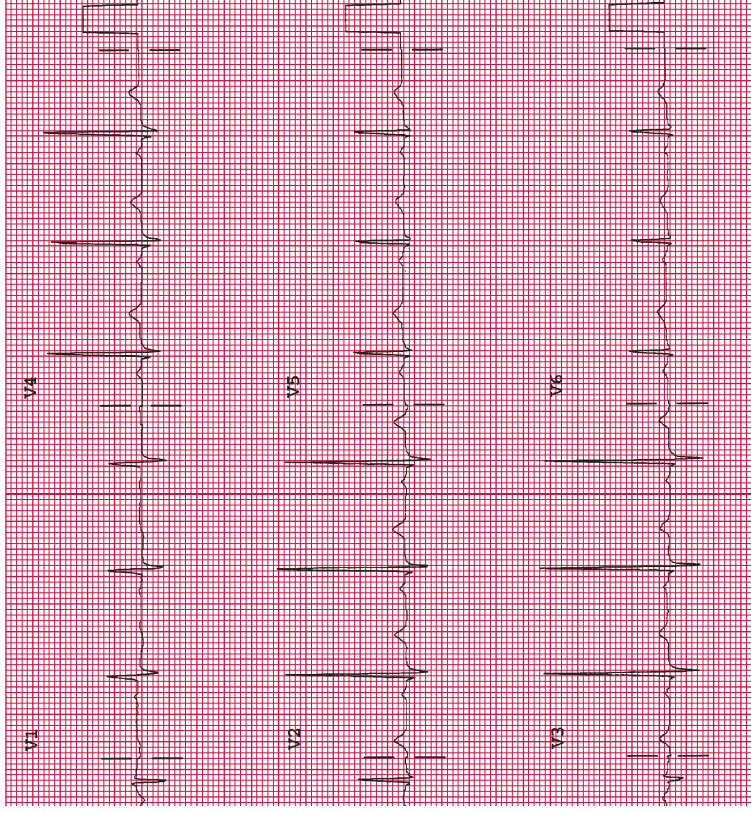
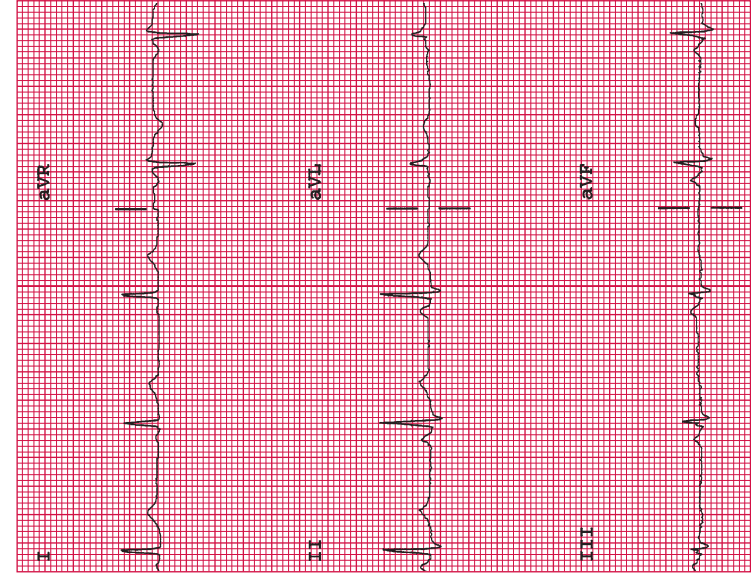


Fig. 2-2. A, Chest leads V₁ through V₆.

(continued)



B

C

Fig. 2-2. Continued **B**, Limb leads I through aVF. Sinus rhythm, rate 65 beats/min; PR interval, 0.14 second; QRS duration, 0.08 second; QT interval, 0.36 second; axis, +30 degrees. **C**, Chest leads of a normal ECG with a QRS complex in V_2 that is positive, indicating early transition. Compare with (A), in which transition is normal, occurring in lead V_3 ; tall R waves in V_1 and V_2 are not caused by posterior infarction (see Table 2-3). Heart rate, 75 beats/min (see Table 2-2). Note normal small Q wave in V_4 through V_6 .

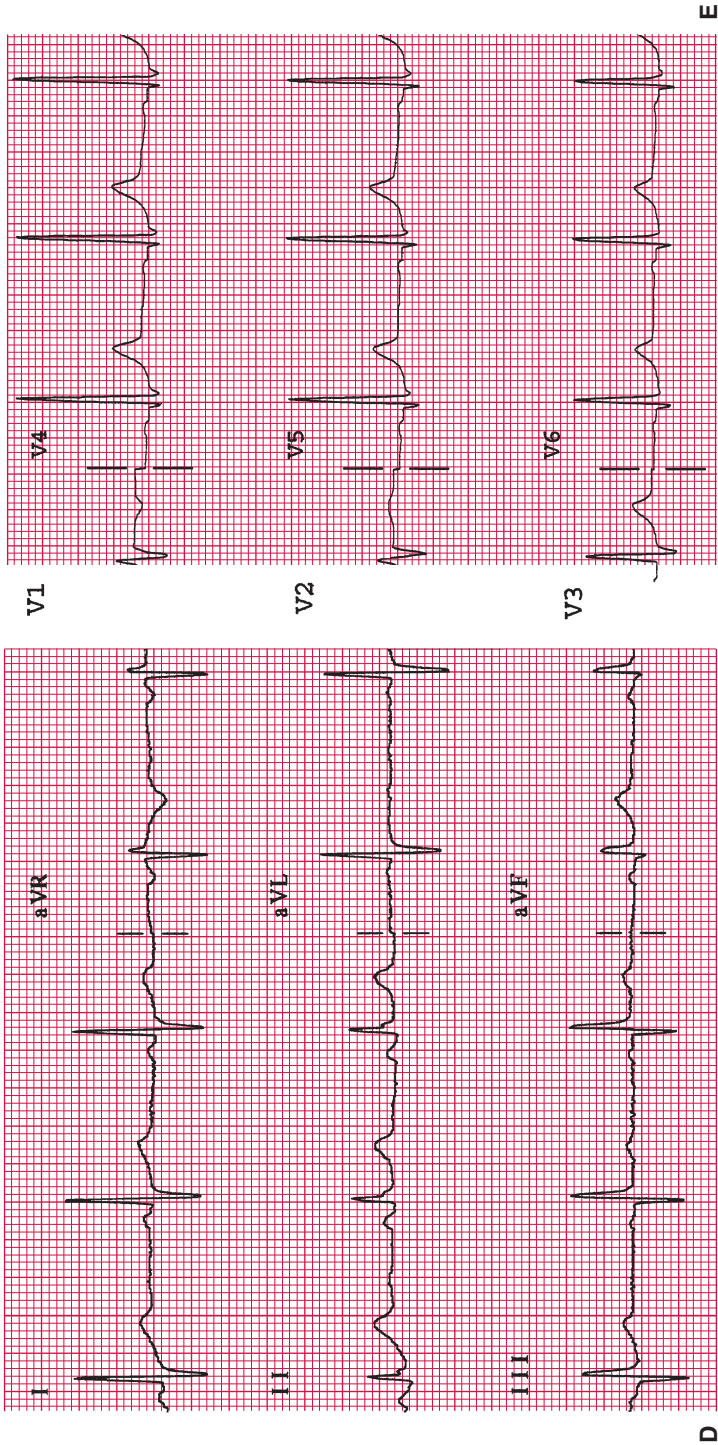
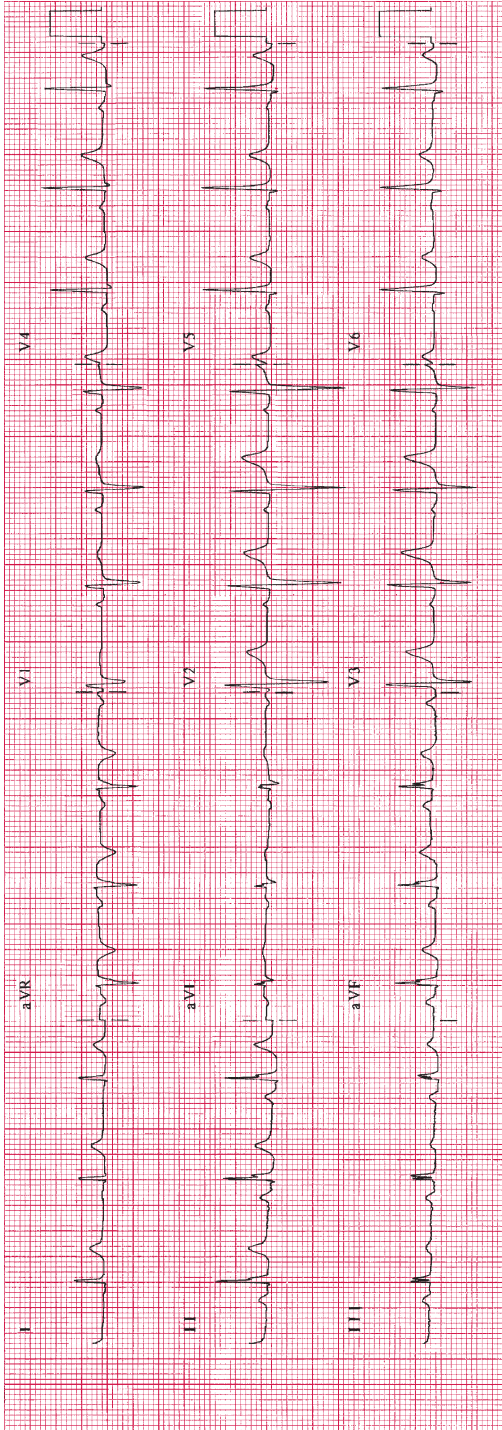


Fig. 2-2. D, Limb leads of a normal ECG showing a deep but normal Q wave in lead III (see Table 2-1 for normal parameters). **E,** Leads V₄ through V₆ show small, normal Q waves less than 4 mm deep; leads V₁ through V₃ show normal R wave progression.

(continued)



F

Fig. 2-2. *Continued* F, Normal ECG, sinus rhythm 75 beats/min; PR interval, 0.16; QRS duration, 0.08; normal QRS axis +60 degrees; QT interval, 0.35. The small notch on the R wave of leads II, III, and aVF is a normal finding in some individuals and does not indicate intraventricular conduction delay (see Chapter 4).

Table 2-1
Important Normal ECG Intervals and Parameters*

PR interval	0.12 to 0.2 second (up to 0.22 second in adults).
P waves	<3 small squares (0.12 second) in duration, and amplitude <3 mm. Upright in lead I, inverted in aVR (if opposite, suspect reversed arm leads [†] or dextrocardia) (<i>see</i> Step 6, Figs. 2-21 and 2-36).
QRS duration	0.05 to 0.1 second; ≥ 0.1 second, consider incomplete LBBB, incomplete RBBB, or WPW syndrome (<i>see</i> Steps 2 and 3, Figs. 2-4, 2-9, and 2-10).
Q waves	Normally present in aVR; occasionally in V ₁ or in aVL (vertical heart) (<i>see</i> Chapter 6). Often present in lead III: should be ≤ 0.04 second duration. Other leads except lead I: <0.04 second duration and ≤ 3 mm deep; lead I ≤ 1.5 mm in patients older than age 30. Q waves may be up to 5 mm deep in several leads in individuals age <30.
R waves	V ₁ : 0 to 15 mm, age 12 to 20 (<i>see</i> Table 2-3). 0 to 8 mm, age 20 to 30. 0 to 6 mm, age >30. [‡] V ₂ : 0.2 to 12 mm, age <30 [‡] (<i>see</i> Step 5, Fig. 2-16). V ₃ : 1 to 20 mm, age >30. [‡]
ST segment	Isoelectric or <1 mm elevation in limb leads and <1 mm in precordial leads except for normal variant (<i>see</i> Step 4, Fig. 2-12).
T wave	Inverted in aVR; upright in I, II, and V ₃ through V ₆ . Variable in III, aVF, aVL, V ₁ , and V ₂ (<i>see</i> Step 8, Fig. 2-27).
Axis	0 degrees to +110 degrees age <40. -30 degrees to +90 degrees age >40 (<i>see</i> Step 9, Fig. 2-30).
QT interval	See Table 2-5.

*ECG paper speed 25 mm/s.

[†]Precordial leads remain normal.

[‡]Age >30 is relevant to the diagnosis of myocardial infarction (*see* Fig. 2-20 and compare with Fig. 2-18, poor R wave progression).

Step 1: *see* Fig. 2-3.

Assess:

- Rhythm, then the rate.
- Note that rhythm is assessed before rate, because it is clinically more important, and a normal rate of 60 to 100 beats/min is easily spotted.

Step 2: *see* Fig. 2-4.

Assess:

- PR and QRS intervals for blocks.
- Widening of the QRS duration suggests right bundle branch block (RBBB) or left bundle branch block (LBBB) (*see* Table 2-1 and Fig. 2-4).

Step 3: *see* Fig. 2-9.

If the QRS duration is increased in the absence of LBBB or RBBB, assess:

- For nonspecific intraventricular conduction delay (IVCD), a cause of which is Wolff-Parkinson-White (WPW) syndrome (*see* Fig. 2-9).
- Although WPW syndrome is uncommon, it is an important diagnosis that may be missed by computer analysis and by physicians. Because WPW syndrome is a cause of widening of the QRS complex, it is logical to consider this diagnosis in the same frame as bundle branch blocks; this approach avoids the embarrassment of missing the diagnosis. No other text considers WPW syndrome in the assessment of the 10 essential ECG features, and conventional teaching does not give the approach outlined in Step 3.
- Most importantly, it is imperative to exclude mimics of MI early in the assessment sequence. WPW syndrome may mimic MI. RBBB may reveal Q waves in leads III and aVF that may be erroneously interpreted as MI. The diagnosis of LBBB must be documented quickly, because the presence of LBBB obviates many diagnoses, particularly ischemia and hypertrophy, and the diagnosis of MI is difficult.
- Because ECG changes of bundle branch block may be observed in V_1 and V_2 , the reader is requested to first focus on V_1 and V_2 . Importantly, V_1 usually reveals the morphology of P waves and is an excellent lead for the assessment of sinus rhythm and arrhythmia. Thus, sinus rhythm or rhythm disturbances can be rapidly documented; in addition, the PR interval can be assessed, and left atrial enlargement may be revealed.

- The thorough assessment of V_1 and V_2 provides considerable information.
- In addition, the assessment of V_1 , V_2/V_3 may assist with the diagnosis of Brugada syndrome and right ventricular dysplasia, which may display particular forms of RBBB and have been shown to be causes of sudden death in young adults. We should not fear to divulge rare syndromes at an early stage to students, because these topics may serve to motivate them to higher levels of excellence. The steps that discuss these rare but important topics are directed to senior trainees and internists. It is logical to discuss basics mixed with advanced material because this may appeal to students and medical residents.

Step 4: *see* Fig. 2-12.

Assess:

- The all-important ST segment.
- The early diagnosis of acute MI depends on observation for ST segment changes. New terms have emerged: ST elevation MI (STEMI) and non-ST elevation MI (previously termed non-Q wave MI). The ST segment holds the key to the diagnosis. This text describes ST segment abnormalities in detail in this chapter and provides further discussion in Chapter 5.

Step 5: *see* Fig. 2-16.

Assess:

- For pathologic Q waves, which, with the prior assessment of the ST segment should determine the presence or absence of new or old MI.
- Search the V leads for the loss of R waves or poor R wave progression, which may indicate MI, lead placement errors, or other cause (*see* later discussion, figures in this chapter, and Chapter 6).

Step 6: *see* Figs. 2-21 and 2-22.

Assess:

- P waves for atrial hypertrophy.

Step 7: *see* Fig. 2-24.

Assess:

- For left ventricular hypertrophy (LVH) and right ventricular hypertrophy (RVH).

Step 8: *see* Fig. 2-27.

Assess:

- T waves for inversion, which can have many causes (*see* later discussion in this chapter and Chapter 8).

Step 9: *see* Fig. 2-30.

Assess:

- The axis and for fascicular blocks.
- The axis provides no specific diagnosis and is of ancillary assistance only. In the 21st century, I believe conventional teaching should change a little. We should not lose sight of the fact that medical students and interns are bright individuals who desire to move quickly to clinical problem solving. Thus boring topics, particularly difficult ones to grasp such as axis determination, which provides little diagnostic yield, should be assessed after most others. Thus determination of the axis is relegated to Step 9.

Step 10: *see* Fig. 2-32.

Assess:

- Miscellaneous conditions, such as long QT, pericarditis, pacing, and pulmonary embolism (*see* later discussion and Chapter 10).

Step 11: *see* Fig. 2-37.

Assess:

- For arrhythmia.
- Step 11 is indeed Step 1 if an abnormal rhythm is revealed in Step 1: assessment of rhythm (*see* later discussion in this chapter and detailed coverage in Chapter 11).

Switching the Sequence

Most importantly, these steps can be switched. After the assessment of the important ST segment in Step 4 and for Q waves indicative of acute or old MI in Step 5, Step 7 can switch with Step 9. Thus, the conventional approach is restored, with assessment of the P wave followed by that of the T wave, axis, hypertrophy, and miscellaneous conditions. Therefore, in essence, this text covers the 11 ECG features systematically with minor changes to the conventional approach and

offers relevant and important diagnoses during the sequence, which allows the reader to interpret ECGs with greater accuracy.

Close attention to the 11 steps for ECG interpretation outlined in this chapter and reference to detailed explanations given in subsequent chapters should allow students, staff, and practicing clinicians to be competent interpreters of most ECGs. Accurate, yet rapid, interpretation of the ECG requires a methodic approach.

THE NORMAL ELECTROCARDIOGRAM

Figure 2-2A–F shows normal ECG tracings. Figure 2-1 and Table 2-1 list important ECG intervals and parameters. The ECG interpretation should end with one of the following statements:

- Normal ECG
- ECG within normal limits
- Borderline ECG
- Abnormal ECG

STEP 1: ASSESS RHYTHM AND RATE (FIG. 2-3)

Focus on leads V_1 , V_2 , and II (*see* Fig. 2-2). Leads V_1 and II are best for visualization of P waves to determine the presence of sinus rhythm or an arrhythmia, and V_1 and V_2 are best to observe for bundle branch block. If P waves are not clearly visible in V_1 , assess them in lead II, which usually shows well-formed P waves. Identification of the P wave and then the RR intervals allows the interpreter to discover immediately whether the rhythm is sinus or other and to take the following steps:

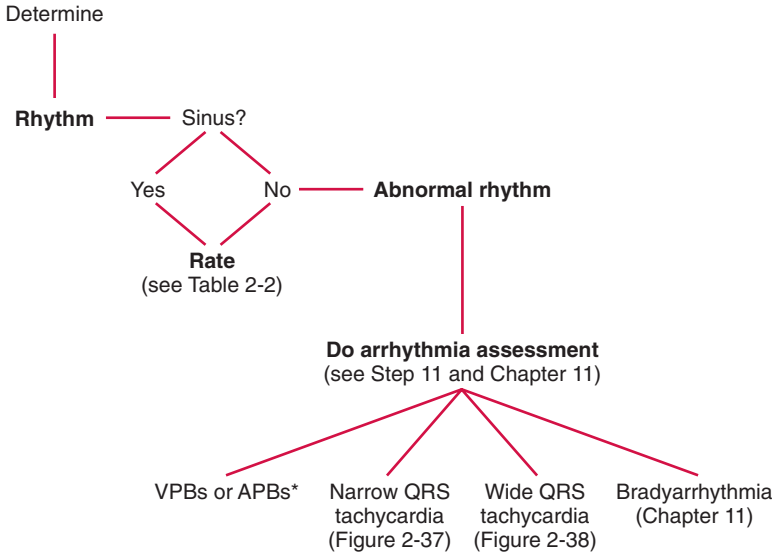
- Confirm, if the rhythm is sinus, that the RR intervals are equidistant (*see* Fig. 2-2A), that the P wave is positive in lead II, and that the PP intervals are equidistant and equal to the RR interval.
- Do an arrhythmia assessment if the rhythm is abnormal (*see* Fig. 2-3, Step 11 [Fig. 2-37], and Chapter 11).
- Determine the heart rate (Table 2-2).

STEP 2: ASSESS INTERVALS AND BLOCKS (FIG. 2-4)

- Determine the PR interval; if it is abnormal (>0.2 second), consider first-degree atrioventricular (AV) block (Table 2-1).
- Assess the QRS duration for bundle branch block; if it is ≥ 0.12 second, bundle branch block is present; assess both V_1 and V_6 . Understanding the genesis of the QRS complex is an essential step and clarifies the ECG manifestations of bundle branch blocks (*see* Figs. 2-5 to 2-8 and Chapter 4).

STEP 1

Look at P waves and RR intervals in leads II and V₁.
Look at leads V₁ and V₂; best for bundle branch block.



*Ventricular premature beats, atrial premature beats

Fig. 2-3. Step-by-step method for accurate ECG interpretation. Step 1: Assess rhythm and rate.

Right Bundle Branch Block

The ECG criteria for RBBB are as follows:

- QRS duration ≥ 0.12 second.
- M-shaped complex in V₁ and V₂.
- Slurred S wave in leads I, V₅, V₆; and an S wave that is of greater amplitude (length) than the preceding R wave (*see* Figs. 2-4, 2-6, and 2-7 and Chapter 4, Fig 4-2).

Left Bundle Branch Block

The ECG criteria for LBBB are as follows:

- QRS duration ≥ 0.12 second.
- A small R or QS wave in V₁ and V₂.

Table 2-2
Determination of Heart Rate

<i>Heart rate (bpm)</i>	
Number of large squares (bold boxes) in one RR interval*	
1	300
1.5	200
2	150
3	100
4	75
5	60
6	50
7	42
8	38
9	33
10	30
Number of QRS complexes in 6 seconds [†]	
5 × 10	50
6	60
7	70
10	100
15	150
20	200

*Normal paper speed 25 mm/s. One large box or five small squares (0.2 second) = 300 bpm (*see* Fig. 2-2C); four large boxes = 75 bpm.

[†]If the ECG paper has markers at 3-second intervals, count the number of QRS complexes in two of these 3-second periods (6 seconds) and multiply by 10 (*see* Fig. 2-2C). This method is advisable if there is bradycardia or irregular rhythm. For 5-second interval, multiply the number of QRS complexes by 12.

For regular rhythm: start with a complex that lies on a bold vertical grid line.

Rate = 300 bpm ÷ number of large boxes (0.2 second) in one RR interval.

Normal rate is between 60 bpm (five boxes) and 100 bpm (three boxes); therefore, no need to calculate exact rate.

Or: rate = 1,500 ÷ number of small (1 mm, 0.04 second) squares in one RR interval.

- A notched R wave in leads 1, V₅, and V₆ (*see* Figs. 2-4 and 2-8 and Chapter 4).

In the presence of LBBB, vector forces are deranged and the ECG cannot be used for the diagnosis of ischemia or ventricular hypertrophy. The diagnosis of acute MI in the presence of LBBB is difficult to make and can be erroneous (*see* discussion of LBBB and acute MI in Chapter 6).

STEP 2

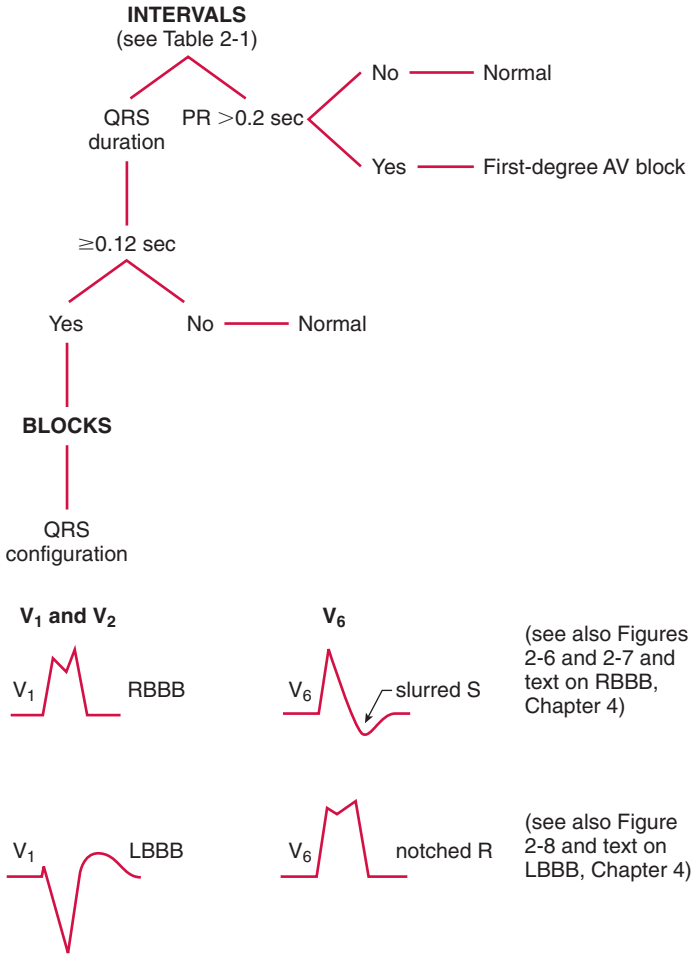
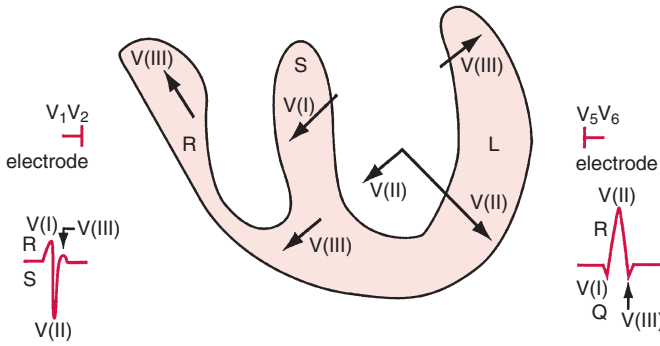


Fig. 2-4. Step-by-step method for accurate ECG interpretation. Step 2: Assess intervals and blocks.



- $V(I)$ = vector I produces a small r wave in leads V_1 and V_2 , Q in leads V_5 and V_6 .
 $V(II)$ = vector II produces an S wave in lead V_1 and an R wave in lead V_5 or V_6 .
 $V(III)$ = vector III produces the terminal S in leads V_5 and V_6 and the terminal r or r' in V_1 , V_2 , and aVR.
 V_1 = lead V_1 electrode.
 V_5 = lead V_5 electrode.
R = right ventricle muscle mass.
L = left ventricle muscle mass.
S = septum.

Fig. 2-5. Vectors I, II, and III, labeled $V(I)$, $V(II)$, and $V(III)$, underlie the genesis of the normal QRS complex. (From Khan, M. Gabriel: *On Call Cardiology*, 3rd ed., Philadelphia, 2006, WB Saunders, Elsevier Science.)

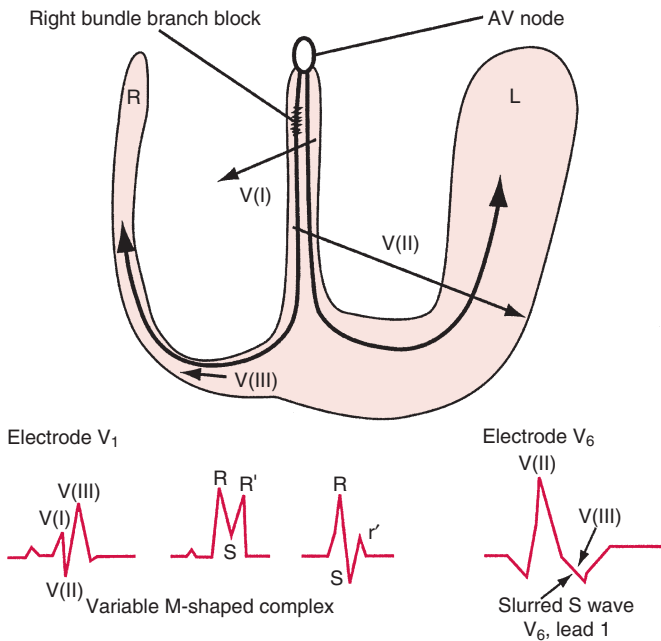


Fig. 2-6. Genesis of the QRS complex in right bundle branch block. (From Khan, M. Gabriel: *On Call Cardiology*, 3rd ed., Philadelphia, 2006, WB Saunders, Elsevier Science.)

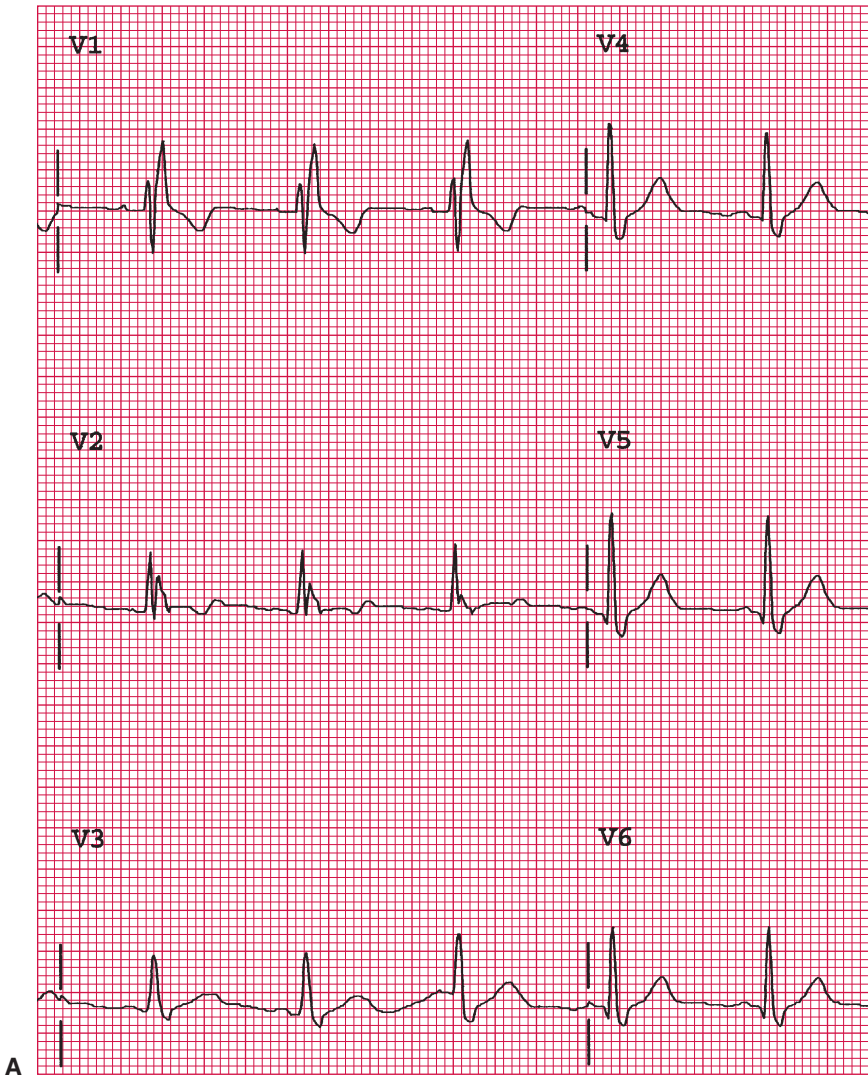


Fig. 2-7. A, QRS duration in $V_1 \geq 0.12$ second; RSR' (M-shaped complex) in V_1 ; and wide, slurred S wave in leads 1, V_5 , and V_6 indicate right bundle branch block.

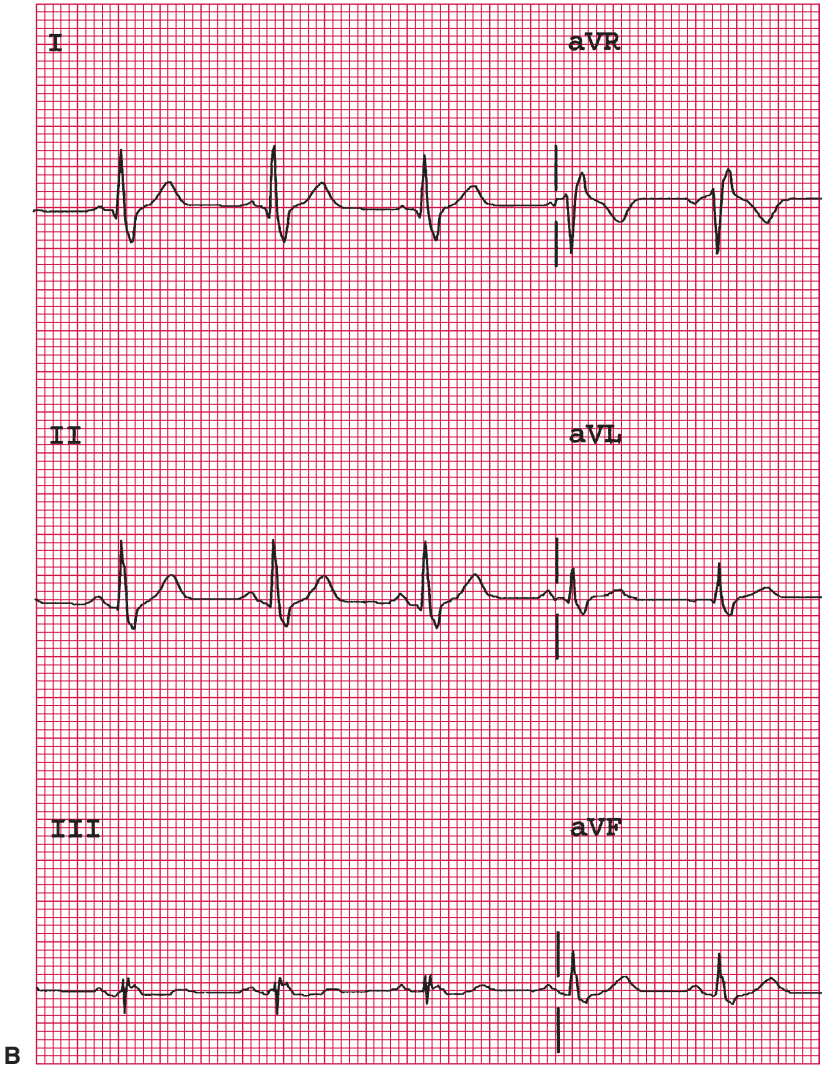


Fig. 2-7. B, Limb leads; slurred, wide S wave in lead I, and the amplitude (length or duration) of the S wave is greater than the preceding R wave.

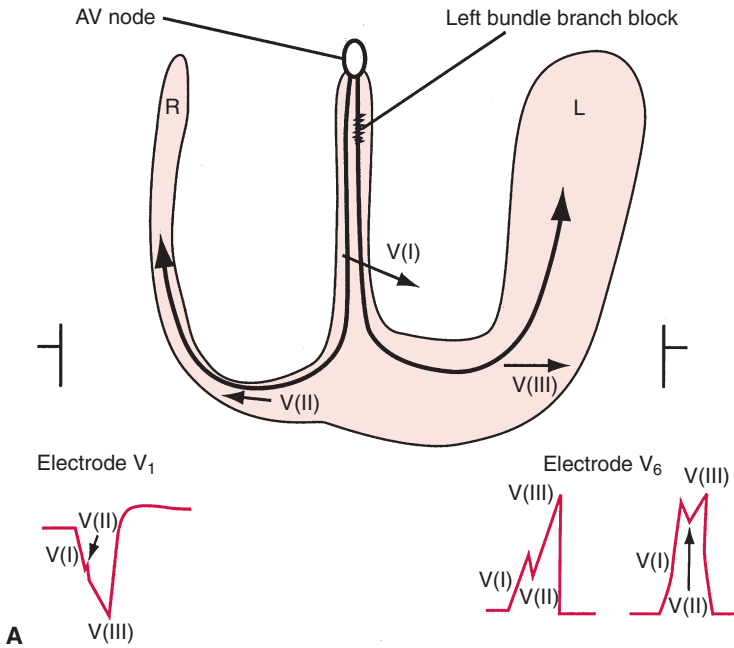


Fig. 2-8. **A**, The contribution of vectors I, II, and III, labeled V(I), V(II), and V(III), to the genesis of left bundle branch block. (From Khan, M. Gabriel: *On Call Cardiology*, 3rd ed., Philadelphia, 2006, WB Saunders, Elsevier Science.). **B**, QRS duration >0.12 second; small R waves in V_1 to V_3 ; and notched R wave in V_5 indicate left bundle branch block.

STEP 3: ASSESS FOR NONSPECIFIC INTRAVENTRICULAR CONDUCTION DELAY AND WOLFF-PARKINSON-WHITE SYNDROME (FIG. 2-9)

- If the QRS duration is prolonged ≥ 0.11 second and bundle branch block appears to be present but is atypical, consider WPW syndrome, particularly if there is a tall R wave in V_1 and V_2 (Table 2-3; *see also* Figs. 11-27 and 11-28).
- Assess for a short PR interval ≤ 0.12 second and for a delta wave (Fig. 2-10).

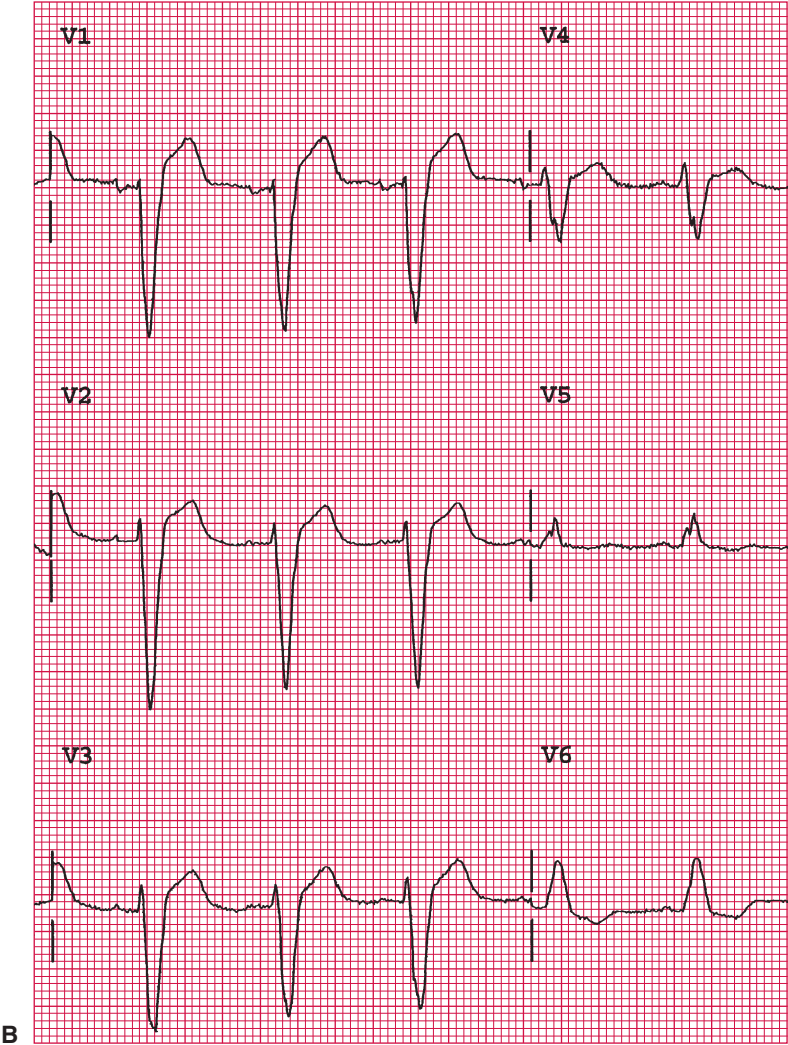


Fig. 2-8. *Continued*

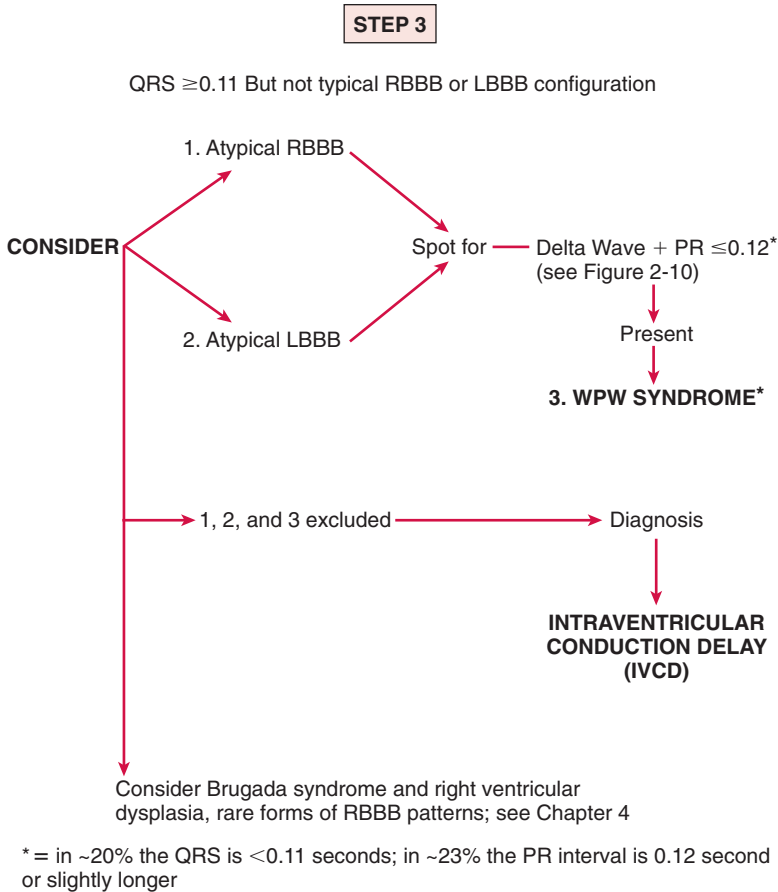


Fig. 2-9. Step-by-step method for accurate ECG interpretation. Step 3: Assess for nonspecific intraventricular conduction delay and Wolff-Parkinson-White (WPW) syndrome (*see* Figs. 2-10 and 2-11). (See Chapter 4 for Brugada syndrome and right ventricular dysplasia, rare forms of right bundle branch block [RBBB] patterns, and Chapter 11 for Wolff-Parkinson-White syndrome.)

WPW syndrome may mimic an inferior MI (*see* Chapters 6 and 11 for discussion of WPW syndrome). If WPW syndrome, RBBB, or LBBB is not present, interpret as nonspecific intraventricular conduction delay (IVCD) and assess for the presence of electronic pacing (*see* Figs. 2-7, 2-8, 2-11, and 10-16).

Table 2-3
Causes of Tall R Waves in V_1 and V_2

1. Thin chest wall or normal variant, age <20, early transition (*see* Fig. 2-2C)
2. Right bundle branch block (*see* Fig. 2-7)
Note: Slurred S wave in leads I, V_5 , and V_6
3. Right ventricular hypertrophy (*see* Fig. 7-8)
No slurred S wave in leads I, V_5 , and V_6
4. Wolff-Parkinson-White syndrome (*see* Fig. 2-10)
5. True posterior infarction (*see* Fig. 6-19)
Note: Associated inferior MI, no slurred S in V_5 and V_6 , and T upright in V_1 and V_2
6. Hypertrophic cardiomyopathy
7. Duchenne muscular dystrophy
8. Low placement of leads V_1 and V_2
9. Dextroposition (*see* Fig. 10-9)

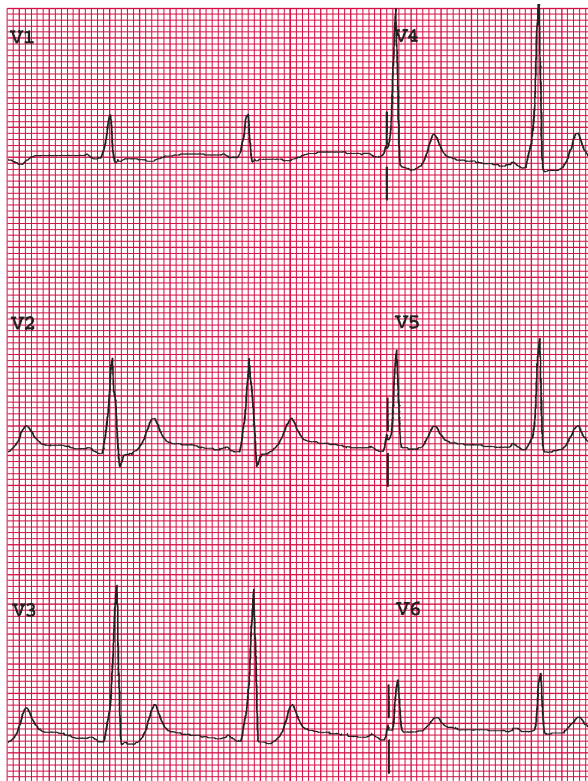


Fig. 2-10. Tall R waves in leads V_1 and V_2 ; QRS duration ≥ 0.11 second; and delta wave in V_3 through V_5 indicate Wolff-Parkinson-White syndrome.

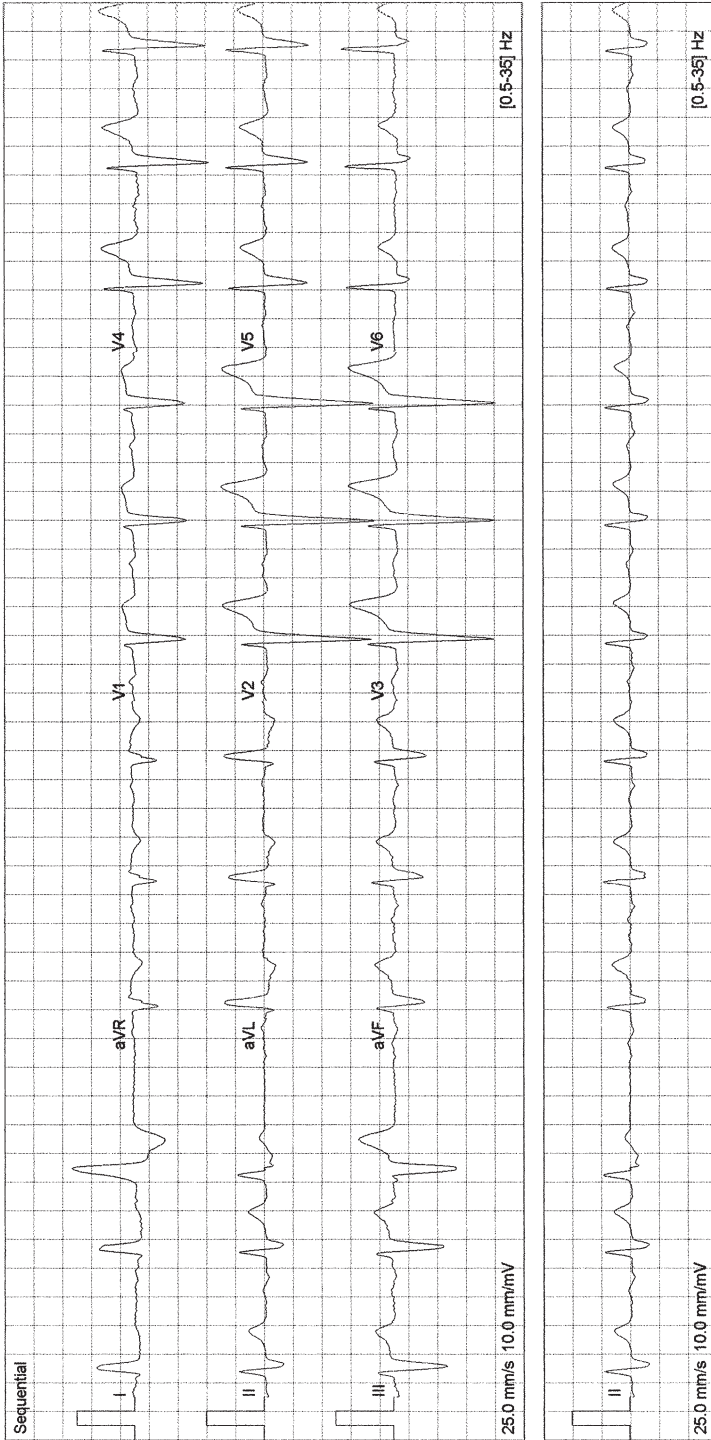
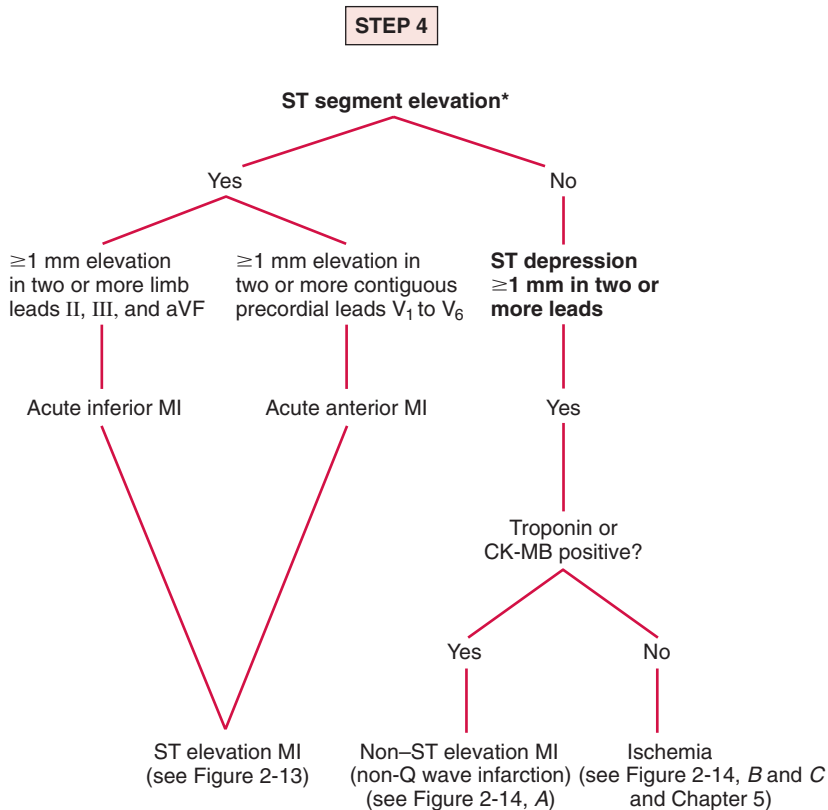


Fig. 2-11. Sinus rhythm 72/min; ventricular premature beats; QRS duration 0.14s, 140ms; Intraventricular conduction delay (IVCD). Abnormal ECG.

STEP 4: ASSESS FOR ST SEGMENT ELEVATION OR DEPRESSION (FIG. 2-12)

- Focus on the ST segment for elevation or depression (*see* Fig. 2-12). ST elevation ≥ 1 mm (0.1 mV) in two or more contiguous ECG leads in a patient with chest pain indicates ST elevation MI (STEMI). The diagnosis is strengthened if there is reciprocal depression (Fig. 2-13).
- Figure 2-13A shows marked ST elevation in leads II, III, and aVF, with marked reciprocal depression in leads I and aVL, diagnostic of acute inferior MI.
- Figure 2-13B shows marked ST segment elevation in V₁ through V₅, caused by extensive acute anterior MI.



*Reciprocal depression increases probabilities of acute myocardial infarction (MI).

Fig. 2-12. Step-by-step method for accurate ECG interpretation. Step 4: Assess for ST segment elevation or depression.

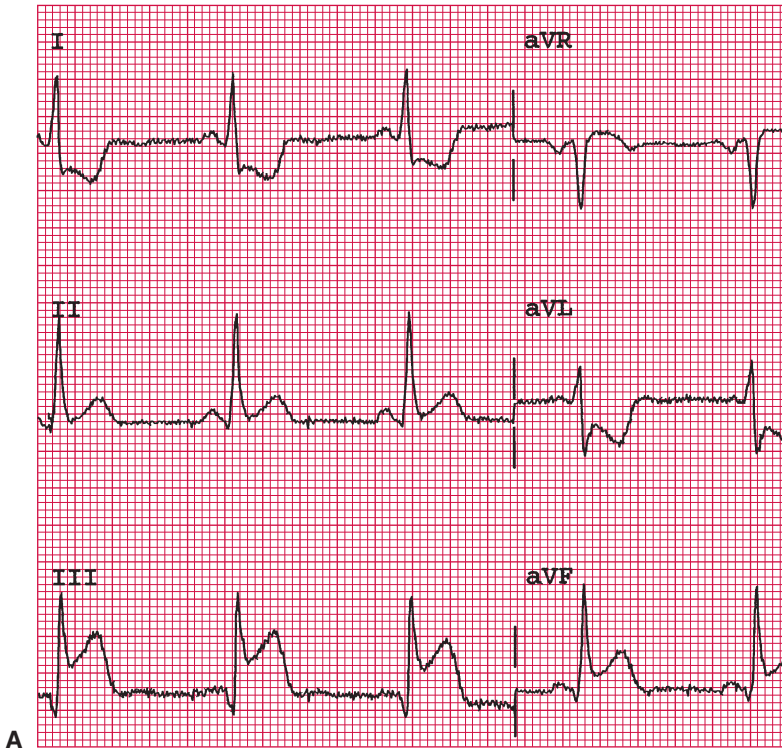


Fig. 2-13. **A**, Marked ST segment elevation in leads II, III, and aVF with reciprocal depression in leads I and aVL indicate acute inferior infarction. **B**, Marked ST segment elevation in leads V₁ through V₅ indicates acute anterior infarction. **C**, Electrocardiogram of a 79-year-old woman with an apparent acute subendocardial myocardial infarction attributed to subtotal occlusion of the left main coronary artery, associated with global hypokinesia and an estimated left ventricular ejection fraction of 10%. ST segment is depressed in leads I, II, III, aVL, aVF, and V₂ through V₆. Apparent “reciprocal” ST segment elevation is seen in leads aVR and V₁. (From Surawicz B, Knilans TK: *Chou’s Electrocardiography in Clinical Practice*, 5th ed., Philadelphia, 2001, WB Saunders, Elsevier Science.)

- Figure 2-13C shows the ECG of a patient with a subtotal occlusion of the left main coronary artery. Note the ST elevation in aVR is greater than the ST elevation in V₁, a recently identified marker of left main coronary disease. (See Chapter 5, particularly Figs. 5-11 and 5-12, for an in-depth discussion of Step 4: ST segment elevation.)
- Figure 2-14A shows features of non-ST elevation MI (non-Q wave MI).
- Figures 2-14B and 2-14C illustrate ECG features diagnostic of myocardial ischemia.

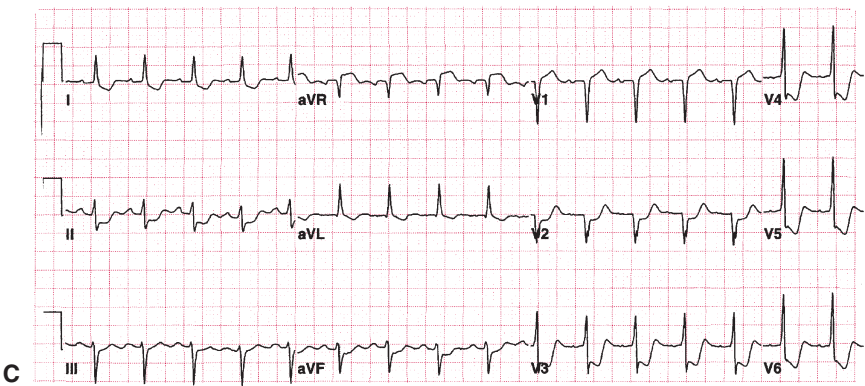
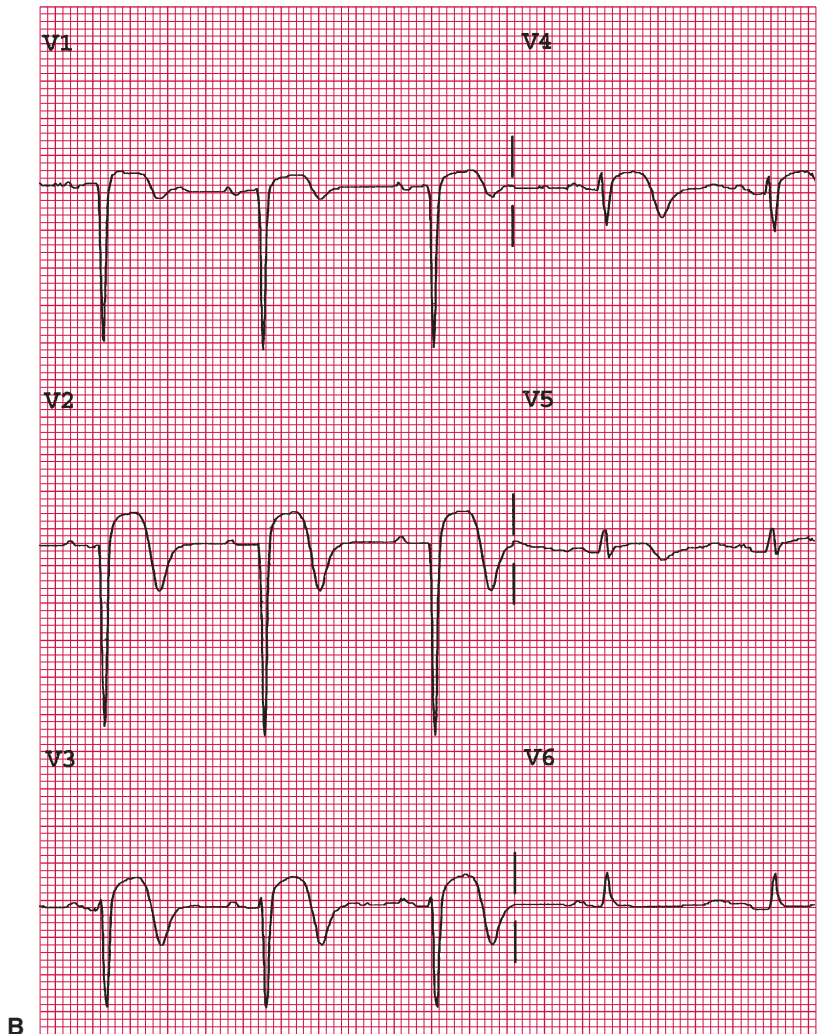


Fig. 2-13. Continued

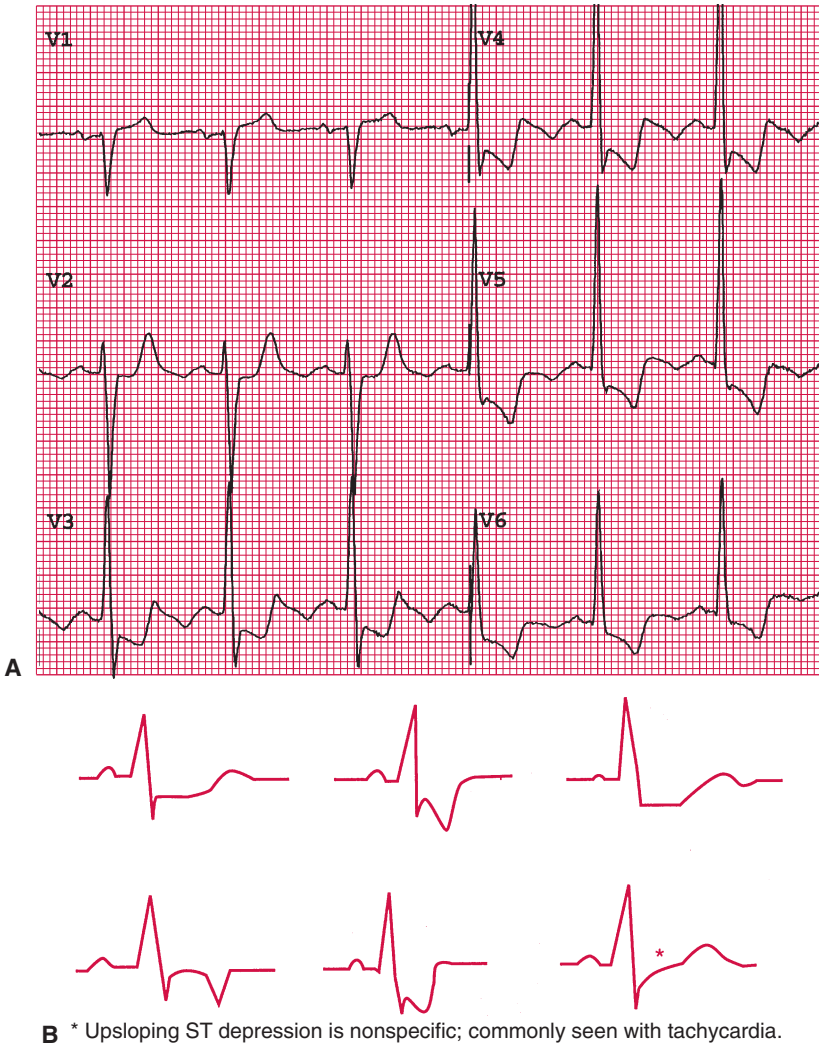


Fig. 2-14. **A**, Marked ST segment depression and elevated creatine kinase (CK) and CK-MB indicate non-Q wave myocardial infarction. **B**, ECG patterns of myocardial ischemia. *Upsloping ST depression is nonspecific; commonly seen with tachycardia. (From Khan, M. Gabriel: *On Call Cardiology*, 3rd ed., Philadelphia, 2006, WB Saunders, Elsevier Science.) **C**, Leads V₄ through V₆ show ST segment depression; V₄ through V₆ are in keeping with myocardial ischemia from a patient known to have unstable angina.

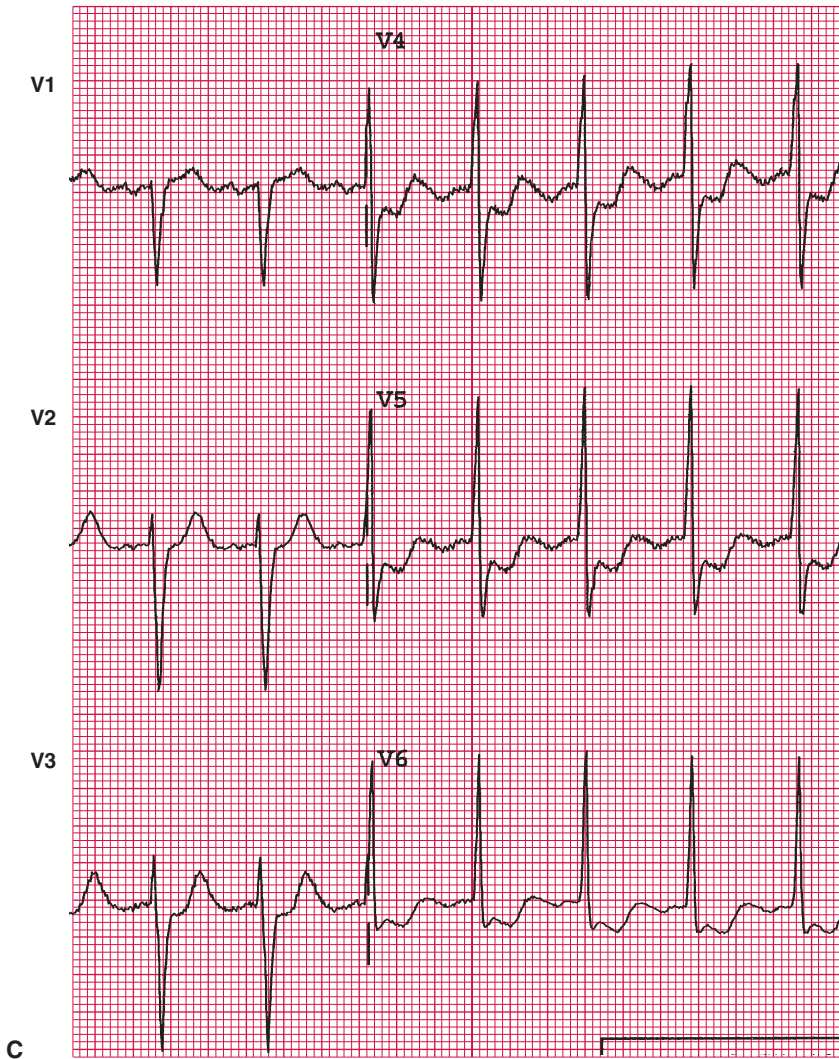


Fig. 2-14. *Continued*

- Elevation of the ST segment may occur as a normal variant (Fig. 2-15). See Chapters 5 and 6 for further discussion of ST segment abnormalities and MI.

Note: This text advises scrutiny of the ST segment before assessment of T waves, electrical axis, QT interval, and hypertrophy because the diagnosis of acute MI or ischemia is vital and depends on careful assessment of the ST segment.

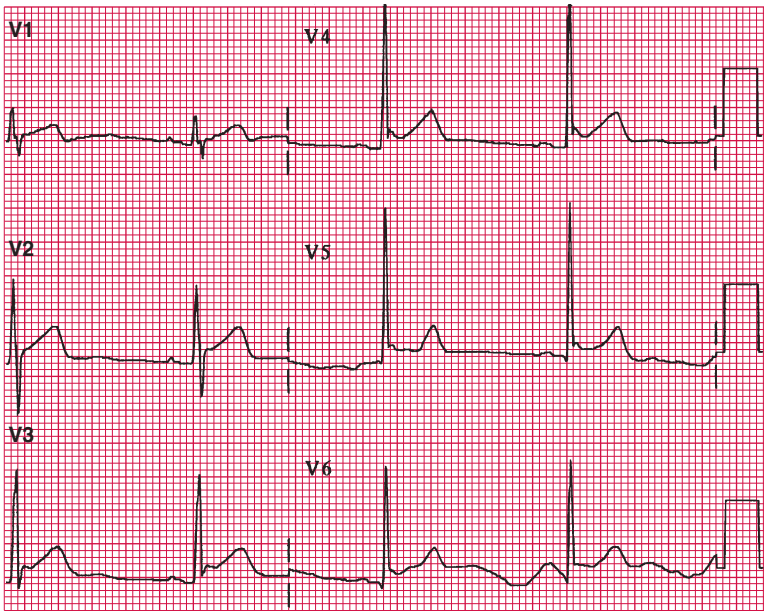


Fig. 2-15. ST elevation with typical fishhook appearance in the V leads is a normal variant.

Exclude other causes of ST elevation:

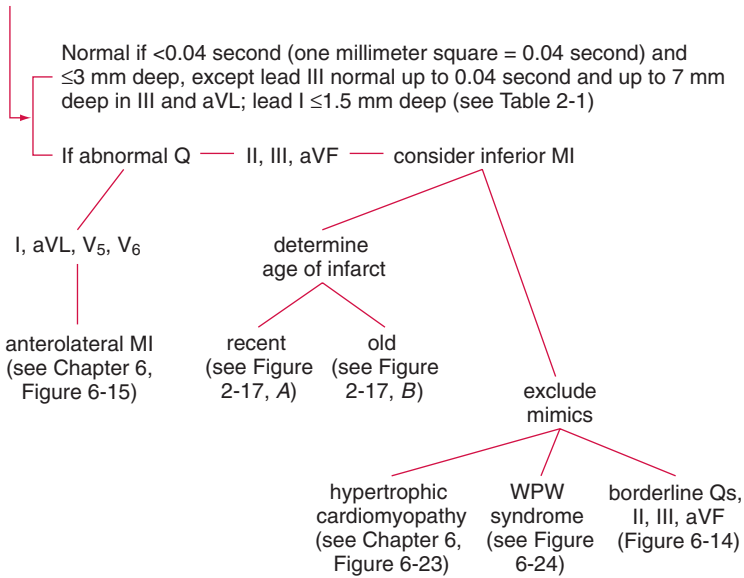
- Normal variant: 1- to 2-mm ST segment elevation, mainly in leads V₂ through V₄, nonconvex, and with fishhook appearance. Common in African Americans: even 4-mm ST segment elevation (*see* Fig. 2-15 and sections on acute myocardial infarction in Chapters 5 and 6).
- Coronary artery spasm: ST returns to normal with nitroglycerin or with pain relief.
- LBBB: QRS >0.12 second and typical configuration (*see* Fig. 2-8B, and Chapter 4).
- Left ventricular aneurysm and known old infarct with old Q waves (*see* Chapter 6).

STEP 5: ASSESS FOR PATHOLOGIC Q WAVES (THAT IS, LOSS OF R WAVES) (FIG. 2-16)

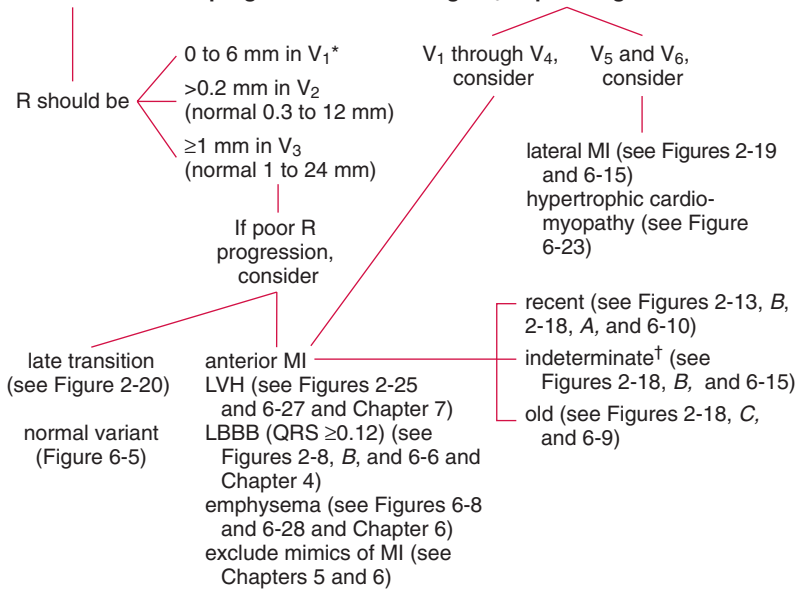
- Assess for the loss of R waves—pathologic Q waves—in leads I, II, III, aVL, and aVF (*see* Figs. 2-17A and 2-17B and Chapter 6 for detailed discussion).

STEP 5

a. Assess for Q waves, leads I, II, III, aVF, and aVL.



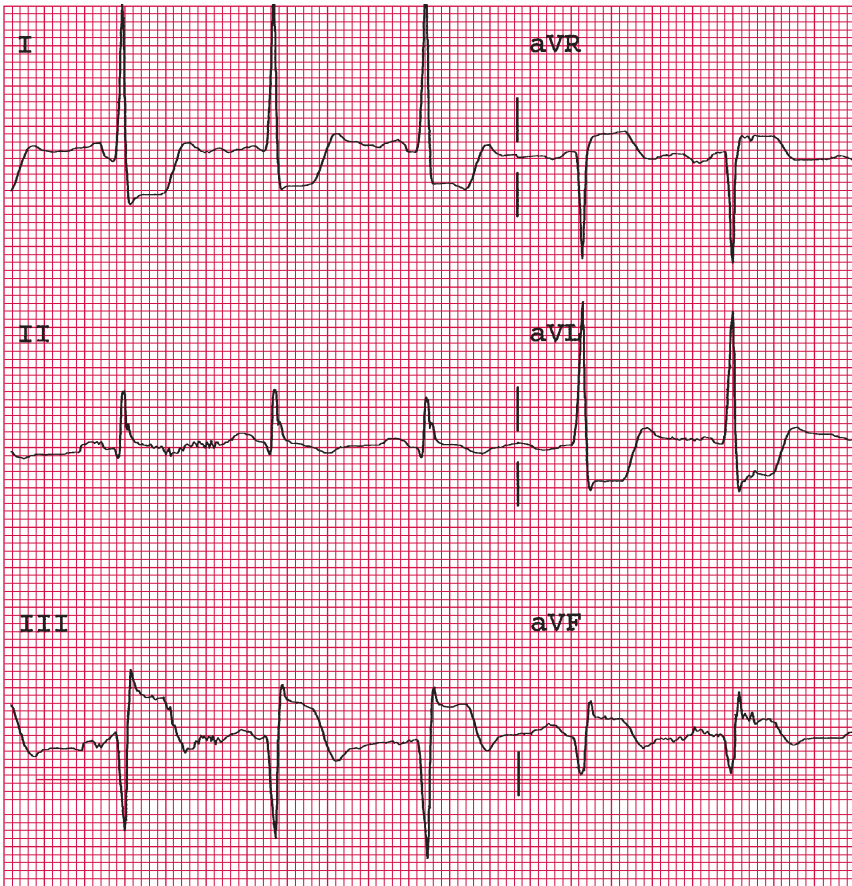
b. Assess for R wave progression in V₁ through V₆ or pathologic Q waves.



*Age >30 ; see Chapter 6 and Table 2-1 for exceptions and normal parameters.

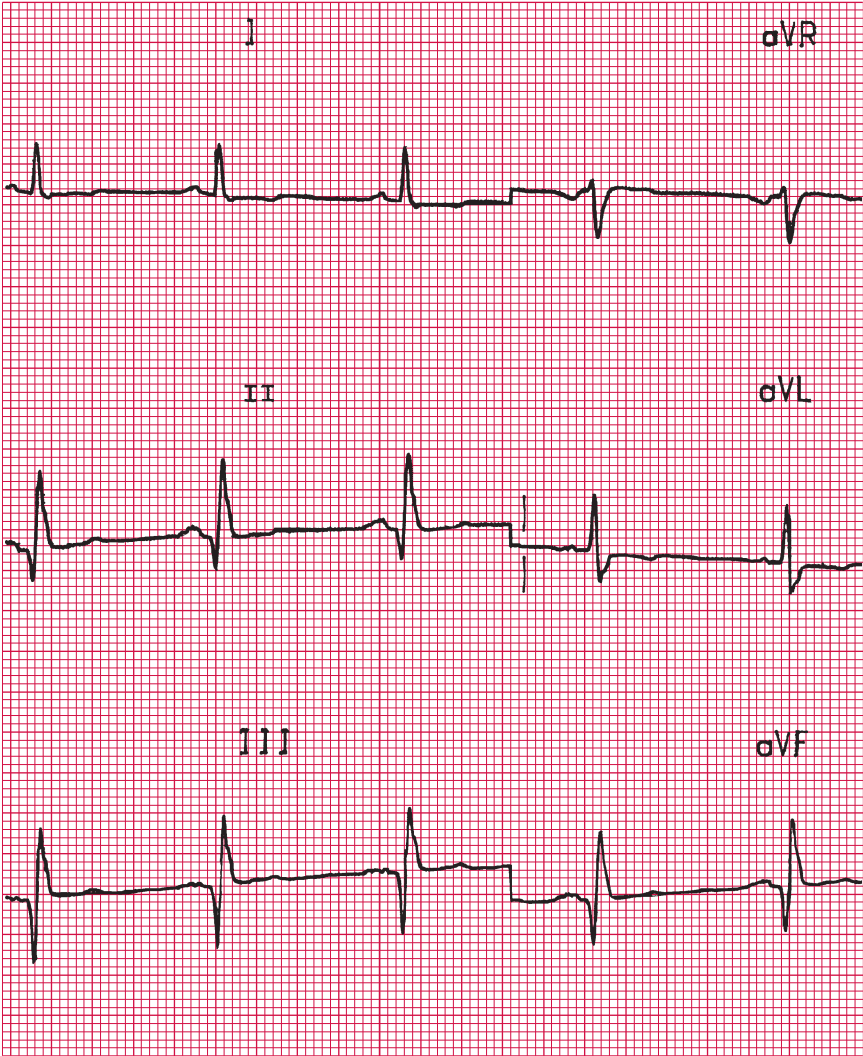
[†]Compare old ECGs.

Fig. 2-16. Step-by-step method for accurate ECG interpretation. Step 5: Assess for pathologic Q waves (i.e., loss of R waves).



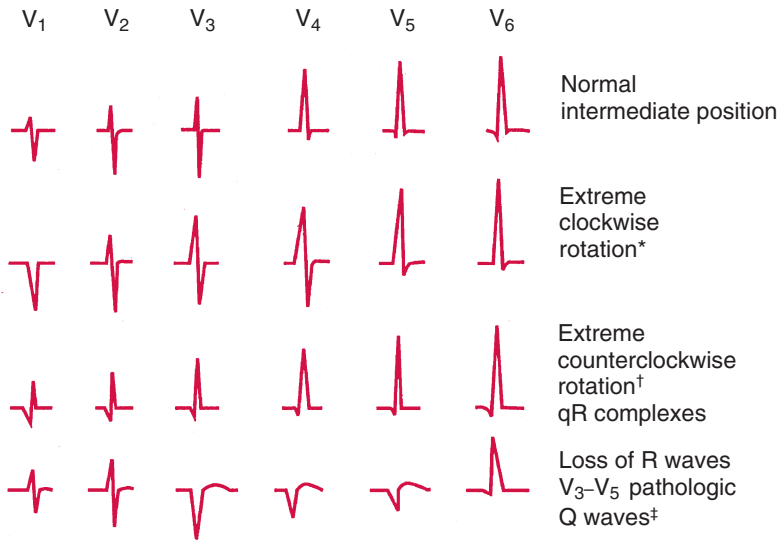
A

Fig. 2-17. A, Loss of R wave in leads III and aVF (i.e., pathologic Q waves associated with marked ST segment elevation in leads III and aVF) and minimal elevation in lead II and reciprocal depression in leads I and aVL indicate typical acute Q wave inferior infarction. **B**, Wide, deep pathologic Q waves in leads II, III, and aVF and isoelectric ST segment indicate old inferior myocardial infarction. **C**, Variation in QRS configuration caused by rotation. (From Khan, M. Gabriel: *On Call Cardiology*, 2nd ed., Philadelphia, 2001, WB Saunders, Elsevier Science.)



B

Fig. 2-17. Continued



* = with clockwise rotation, the V₁ electrode, like aVR, faces the cavity of the heart and records a QS complex; no initial q in lead V₆.

† = qR complexes, q < 0.04 second, < 3 mm deep, therefore not pathologic Q waves.

‡ = loss of R wave V₃ to V₅ pathologic Q waves: signifies anterior myocardial infarction.

C

Fig. 2-17. *Continued*

- Assess for R wave progression in V₂ through V₄. Figure 2-17C illustrates the variation in the normal QRS configuration that occurs with rotation. The R wave amplitude should measure from 1 mm to at least 20 mm in V₃ and V₄ (*see* Table 2-1). Loss of R waves in V₁ through V₄ with ST segment elevation indicates acute anterior MI (Fig. 2-18A).
- Loss of R wave in V₁ through V₃ with the ST segment isoelectric and the T wave inverted may be interpreted as anteroseptal MI age indeterminate (i.e., infarction in the recent or distant past) (Fig. 2-18B). Features of old anterior MI are shown in Fig. 2-18C and lateral infarction is shown in Fig. 2-19.

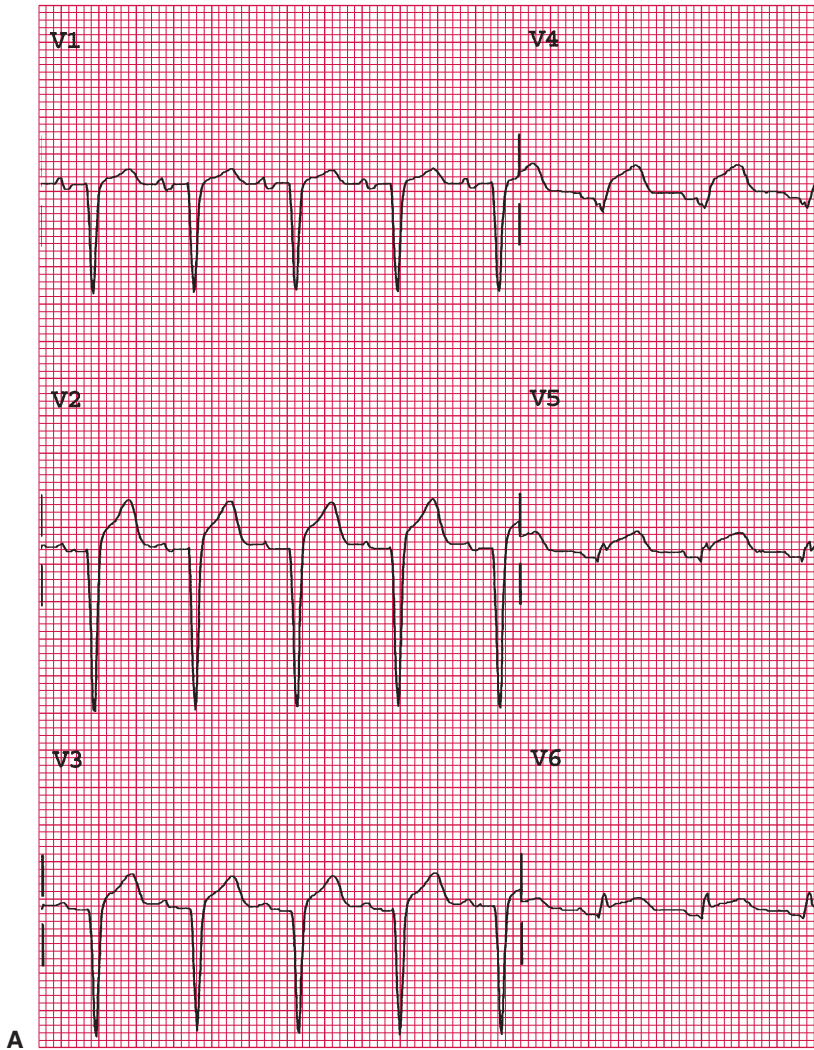
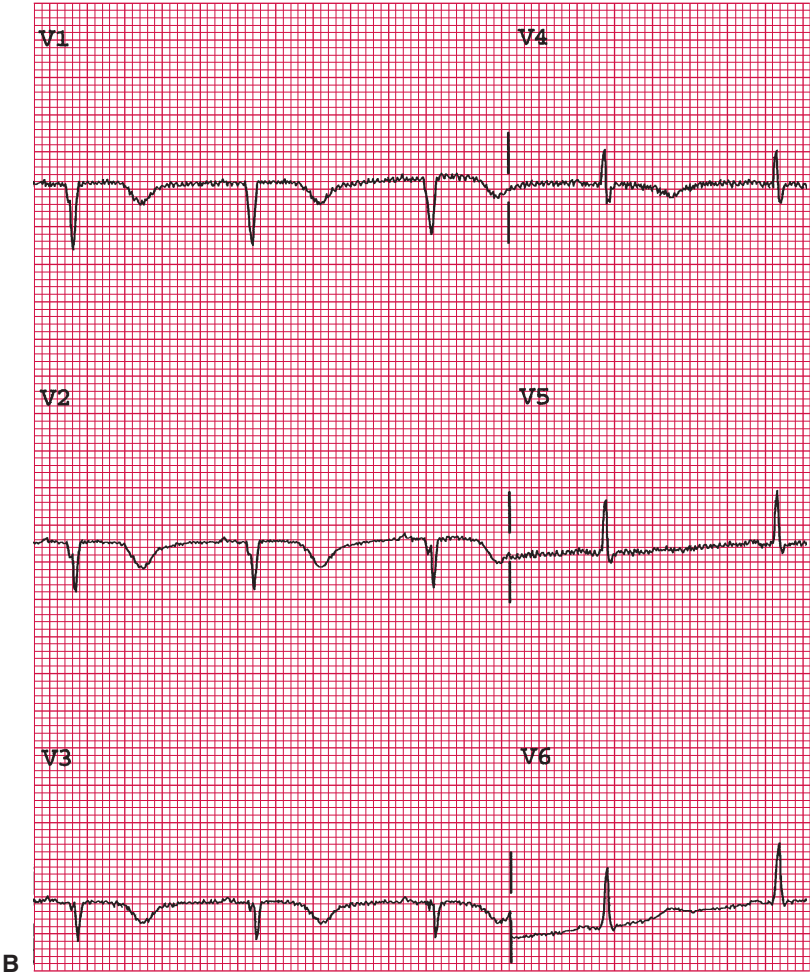


Fig. 2-18. A, Loss of R waves in V_2 through V_5 (i.e., pathologic Q waves associated with abnormal ST segment elevation) indicates acute anterior infarction. **B**, Loss of R wave in V_1 through V_3 (i.e., pathologic Q waves associated with an isoelectric ST segment) and T wave inversion indicate anteroseptal infarction, age indeterminate, infarction occurring approximately 1 to 12 months before the recording of this tracing; comparison with previous ECGs and clinical history required to determine the age of infarction. **C**, Loss of R waves in V_2 through V_5 (i.e., pathologic Q waves in V_2 through V_4 not associated with acute ST segment changes) indicates old anterior infarction. **D**, Loss of R waves in V_4 and V_5 indicate anterior myocardial infarction, age indeterminate.

(continued)



B

Fig. 2-18. *Continued*

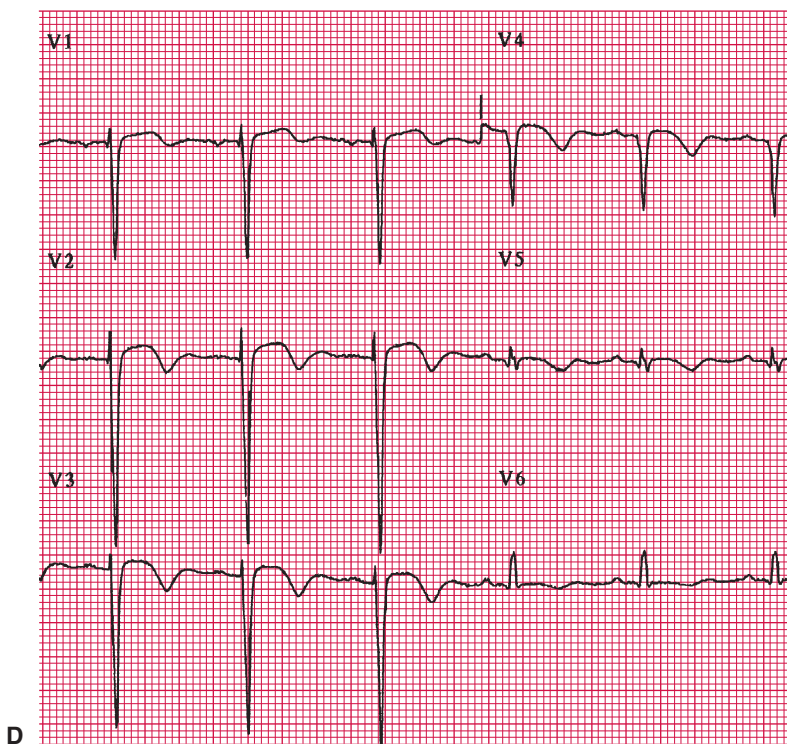
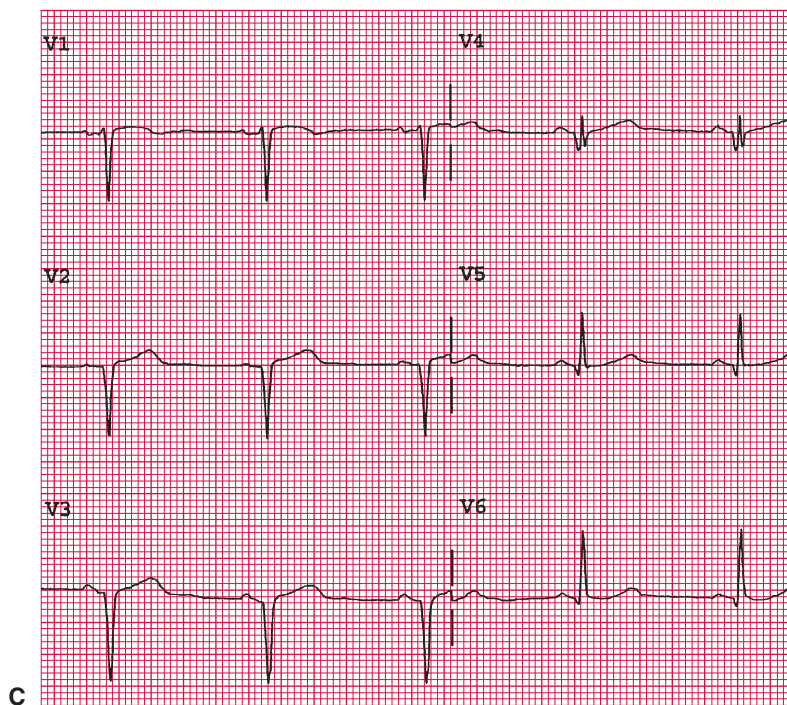


Fig. 2-18. *Continued*

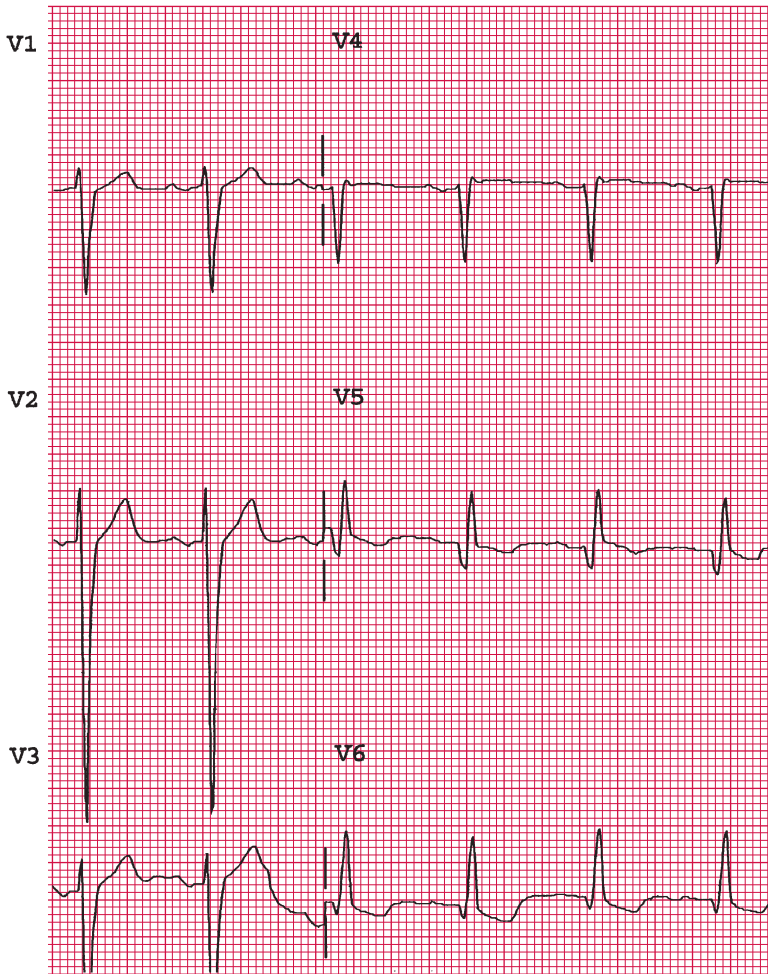


Fig. 2-19. Pathologic Q waves in V_4 through V_6 and ST segment in keeping with an old anterolateral infarct; clinical correlation necessary to confirm the presence of an old infarction.

Poor R wave progression in V_2 through V_4 may be caused by the following:

- Improper lead placement.
- Late transition (Fig. 2-20).
- Anteroseptal or anteroapical MI.
- LVH (see Chapter 7).
- Severe chronic obstructive pulmonary disease, particularly emphysema—emphysema may cause QS complexes in leads V_1 through V_4 ,

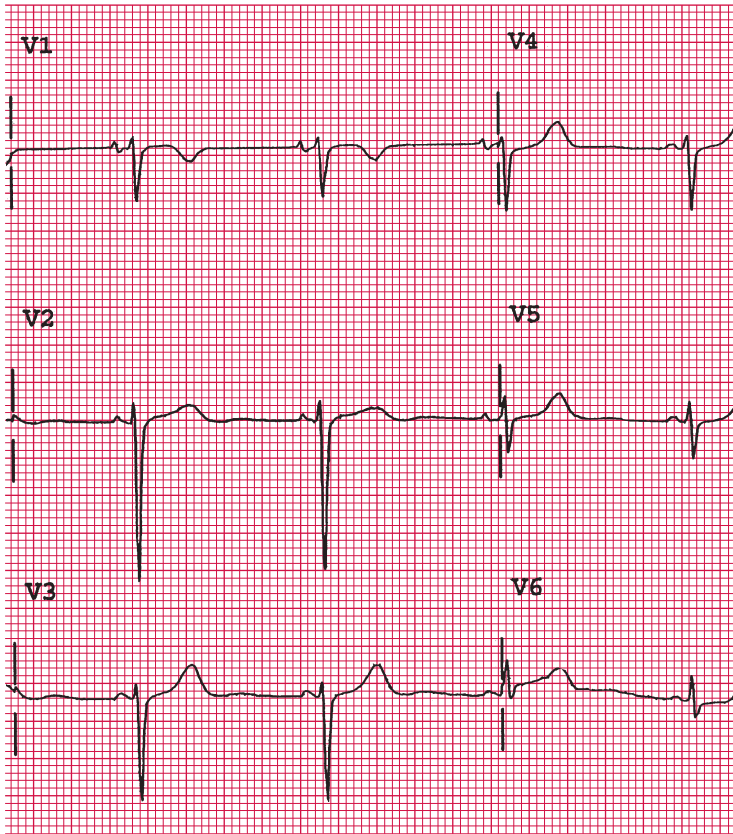


Fig. 2-20. Poor R wave progression in leads V_2 through V_5 . *Note:* The negative QRS complex in V_5 is caused by late transition and not by other causes of poor R wave progression such as anterior infarction. ECG within normal limits.

which may mimic MI; a repeat ECG with recording electrodes placed one intercostal space below the routine locations should cause R waves to be observed in leads V_2 through V_4 (see Chapter 6)

- Hypertrophic cardiomyopathy.
- LBBB (Fig. 2-8B).

In women, albeit rarely, the R wave in V_2 or V_3 may be less than 1 mm tall; this may cause an erroneous diagnosis of anteroseptal infarction.

In summary: An abnormal, pathologic Q wave is defined in adults as one that has a duration of >40 ms, but the definition does not apply to leads aVR and V_1 , which may normally lack the initial R wave. In

addition, in leads III, aVF, and aVL, the initial R wave may be absent; the resultant QS or QR pattern represents a normal variant. A QS pattern is disturbing to students and clinicians. The student is warned: Sound knowledge of normal variants and features of normal ECG deflections that look abnormal but are indeed normal must be mastered by the competent interpreter of ECGs. A QS is often observed in lead aVL in thin subjects with a vertical heart. A QS in lead III is common in individuals with a horizontal heart position, some of whom are obese. See Chapter 6 for an in-depth discussion of Step 5: Q wave abnormalities.

STEP 6: ASSESS P WAVES (FIG. 2-21)

- Assess the P waves for abnormalities including atrial hypertrophy (Figs. 2-22 and 2-23; *see also* Fig. 3-3).

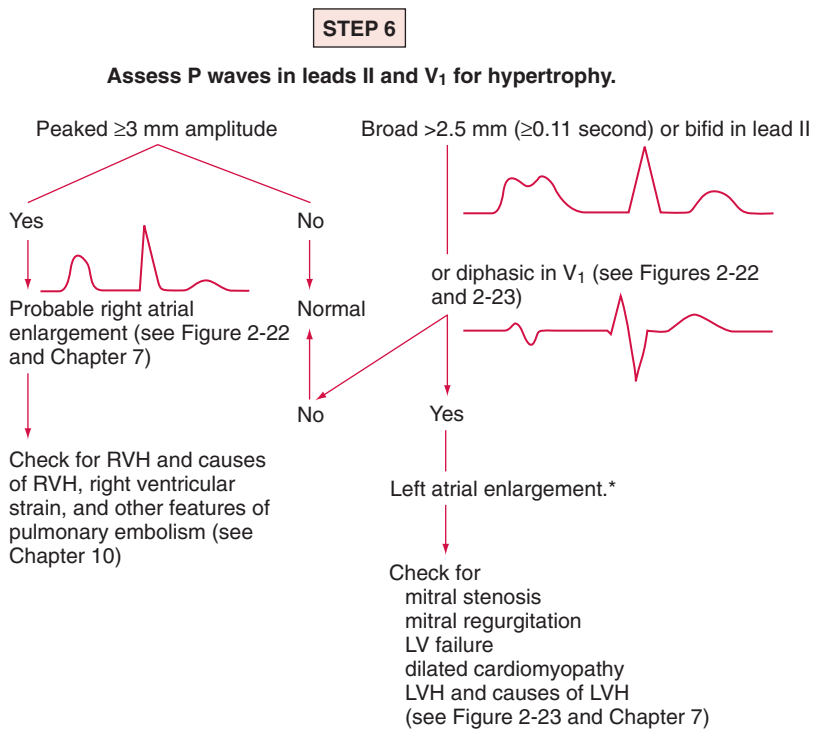


Fig. 2-21. Step-by-step method for accurate ECG interpretation. Step 6: assess P waves.

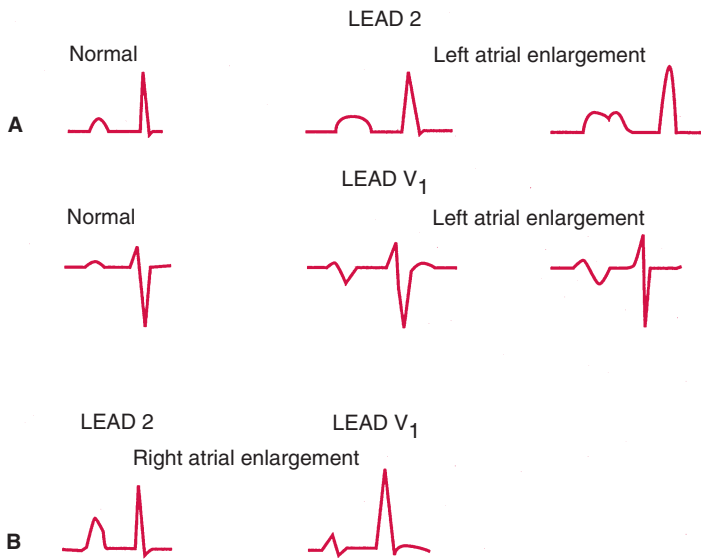


Fig. 2-22. A, Left atrial enlargement: P wave duration greater than three small squares (0.12 second) in lead 2; in lead V₁ the negative component of the P wave occupies at least one small box: 1 mm × 0.04 second = P terminal force ≥ -0.04 mm s. B, Right atrial enlargement: lead 2 shows P amplitude >3 mm; in V₁, the first half of the P wave is positive and >1 mm wide (see Figs. 2-23, 7-2, and 7-3). (From Khan, M. Gabriel: *On Call Cardiology*, 3rd ed., Philadelphia, 2006, WB Saunders, Elsevier Science.)

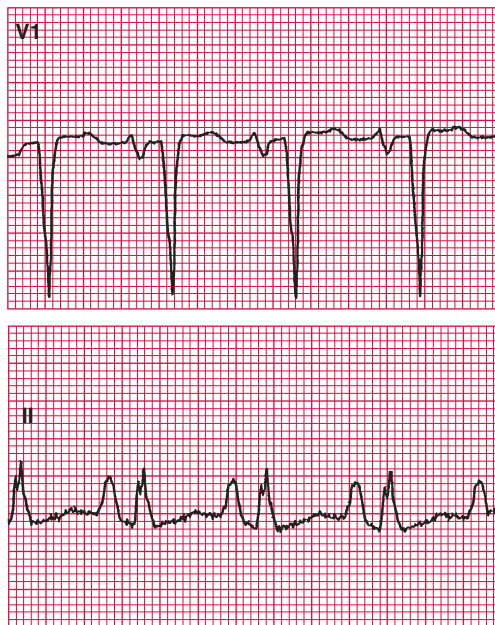


Fig. 2-23. Lead V₁ shows right and left atrial hypertrophy. Lead II shows peaked P waves caused by right atrial enlargement.

STEP 7: ASSESS FOR LEFT AND RIGHT VENTRICULAR HYPERTROPHY (FIG. 2-24)

- Assess for LVH (*see* Figs. 2-24 and 2-25 and Chapter 7) and RVH (*see* Fig. 2-26 and Chapter 7 for further details).
- Criteria for LVH and RVH are not applicable if bundle branch block is present. Thus, it is essential to exclude LBBB and RBBB early in the interpretive sequences as delineated previously in Steps 2 and 3.

STEP 8: ASSESS T WAVES (FIG. 2-27)

- Assess the pattern of T wave changes (*see* Fig. 2-27). T wave changes are usually nonspecific (Fig. 2-28). T wave inversion associated with ST segment depression or elevation indicates myocardial ischemia (Fig. 2-29). See Chapter 8 for further information on T wave abnormalities.

STEP 7

a. Assess for left ventricular hypertrophy (LVH).*

- (1) S wave in V_1 + R wave in V_5 or V_6 >35 mm = LVH $\approx 90\%$ specificity; sensitivity $<40\%$
- (2) R wave in aVL + S wave in men ≥ 24 mm and in women ≥ 18 mm = LVH $\approx 90\%$ specificity; sensitivity $<40\%$
- (3) Specificity of (1) or (2) increased to $\approx 98\%$ in presence of
 - (a) Left atrial enlargement *or*
 - (b) ST segment depression and T wave inversion (strain pattern) in V_5 or V_6 (*see* Figures 2-23 and 2-25)

b. Assess for right ventricular hypertrophy (RVH).

- (1) R wave in V_1 ≥ 7 mm[†]
- (2) S wave in V_5 or V_6 ≥ 7 mm
- (3) R/S ratio in V_1 ≥ 1
- (4) R/S ratio in V_5 or V_6 ≤ 1
- (5) Right axis deviation $\geq +110^\circ$
Any two of above = RVH likely (*see* Figure 2-26)
- (6) Specificity increased if ST depression and T wave inversion in V_1 to V_3 or right atrial hypertrophy (*see* Figures 2-26, 7-7, and 7-8)

*Age >30 ; ≥ 40 mm, age 20 to 30.

†Age >30 ; *see* Table 2-1,

Fig. 2-24. Step-by-step method for accurate ECG interpretation. Step 7: Assess for left ventricular hypertrophy (LVH) and right ventricular hypertrophy (RVH) (not applicable if QRS duration ≥ 0.12 second or in presence of LBBB or RBBB).

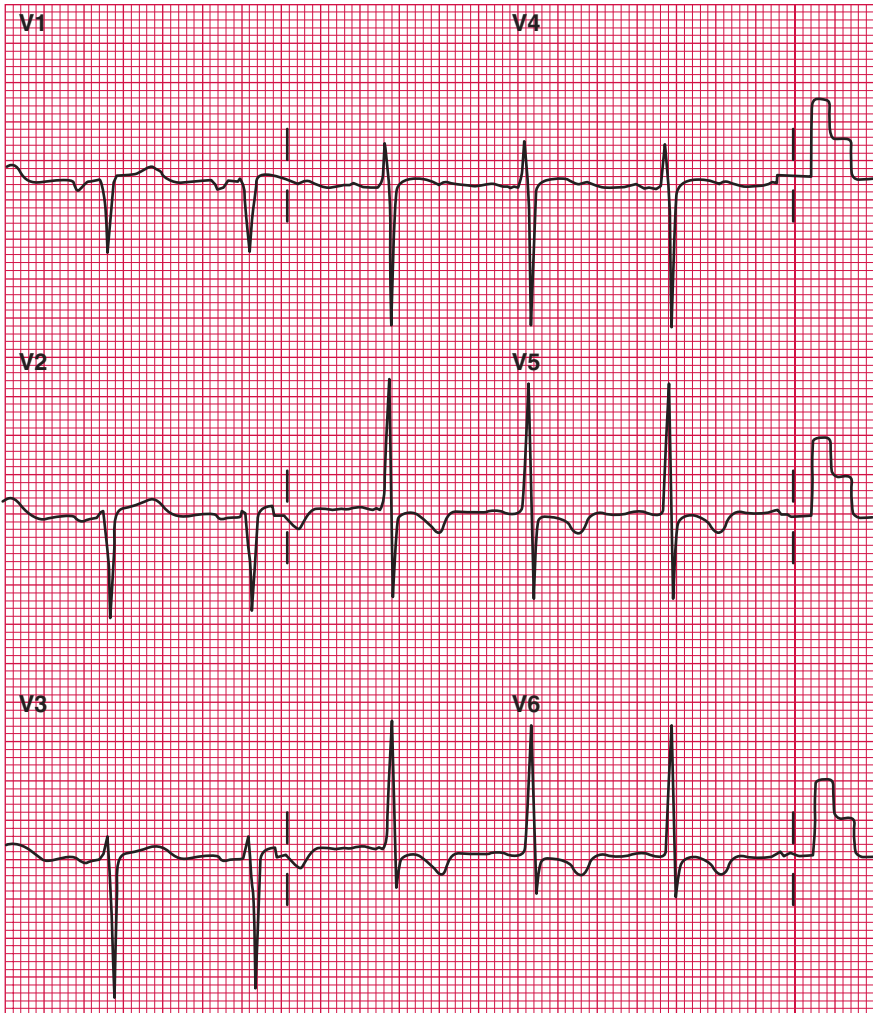


Fig. 2-25. Note that the standardization at half voltage in V_1 through V_6 is markedly increased; ST-T strain pattern in V_5 and V_6 and left atrial enlargement are typical features of left ventricular hypertrophy.

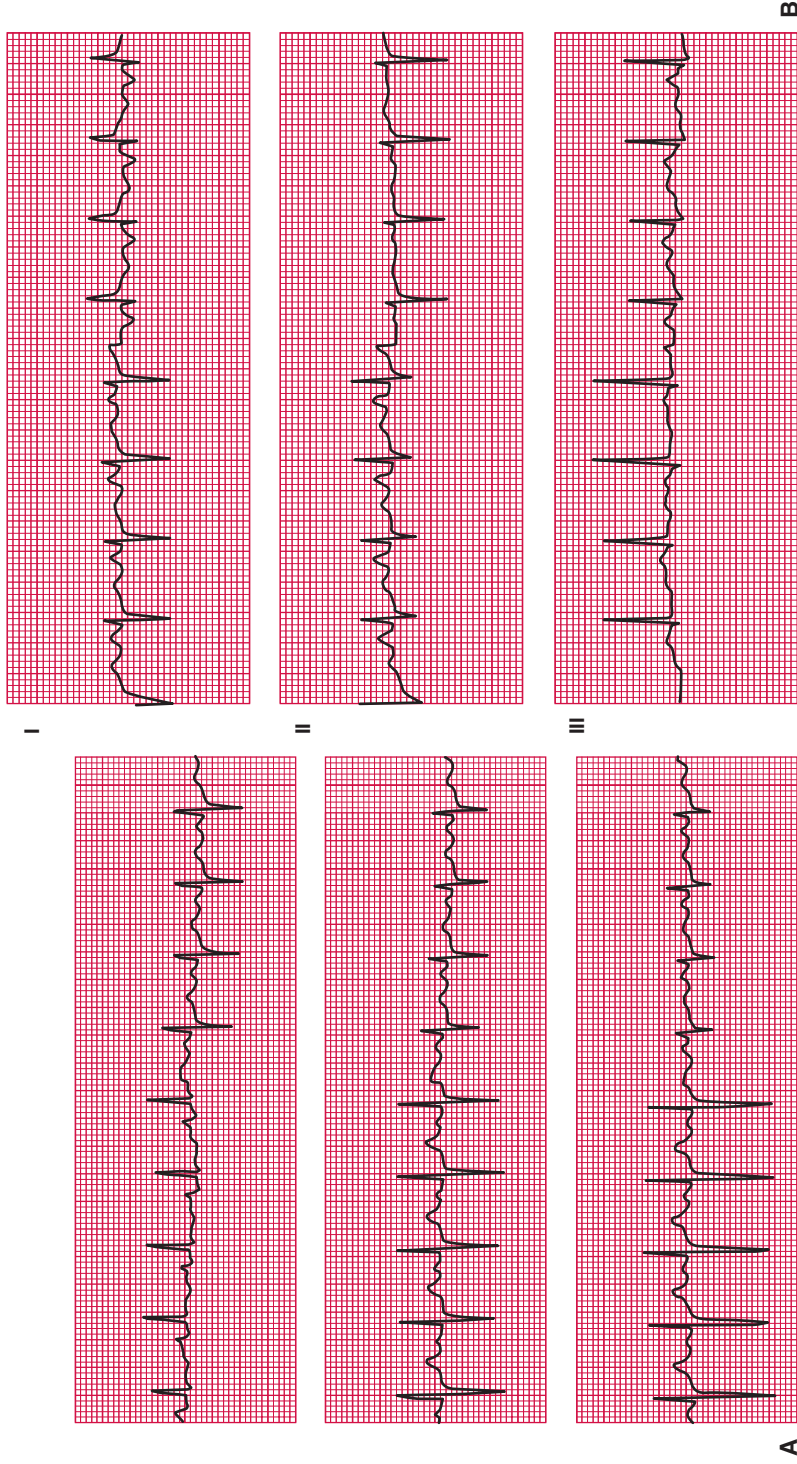


Fig. 2-26. **A,** Leads V_1 through V_6 : A tall R wave in V_1 , R/S ratio in $V_1 > 1$, and R/S ratio in V_5 or $V_6 < 1$ are features of right ventricular hypertrophy. **B,** Limb leads: right-axis deviation $+140$ degrees, peaked P wave in lead II, and right atrial enlargement are all in keeping with right ventricular hypertrophy.

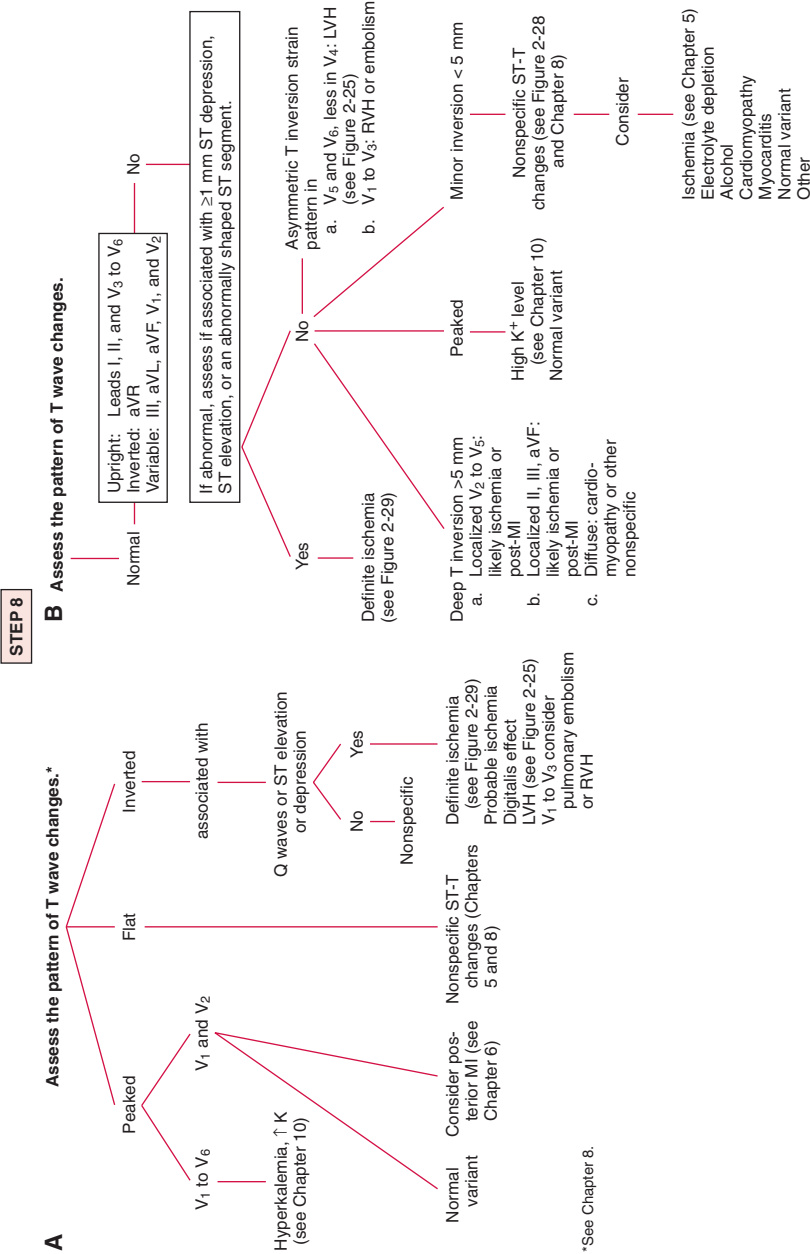


Fig. 2-27. Step-by-step method for accurate ECG interpretation. **A**, Step 8: Assess T wave changes. **B**, Step 8: Alternative approach for the assessment of T wave changes.

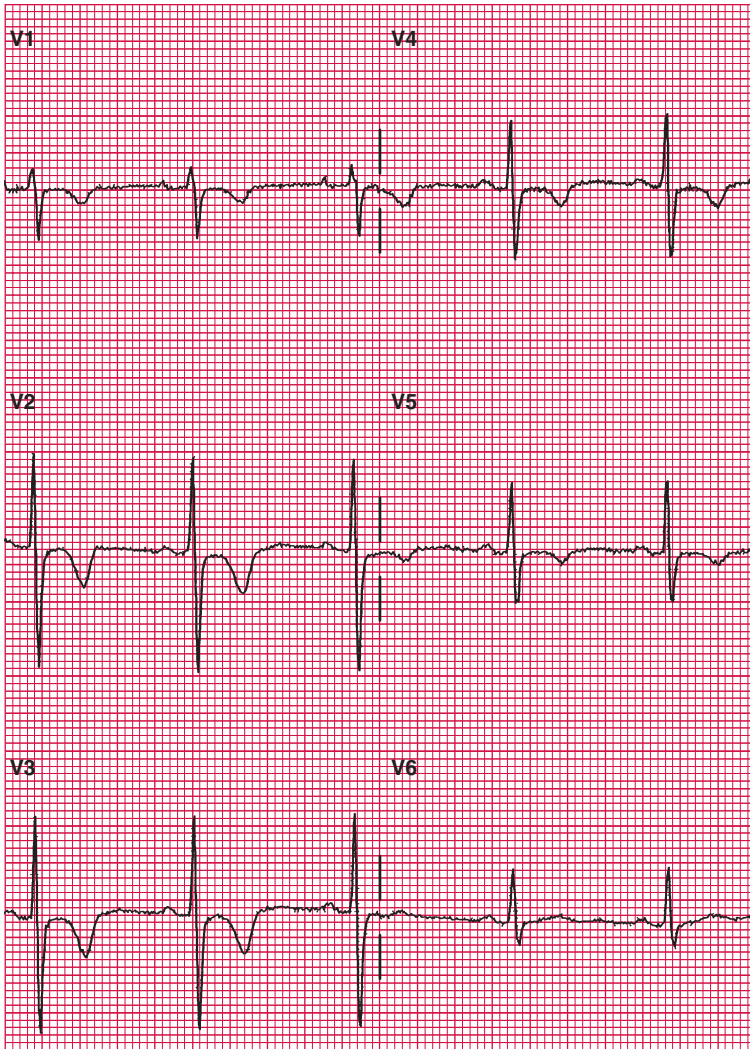


Fig. 2-28. T wave inversion in V_2 through V_5 not associated with ST segment depression or elevation; nonspecific ST-T wave changes; cannot exclude ischemia, but the tracing is not diagnostic. Abnormal ECG.

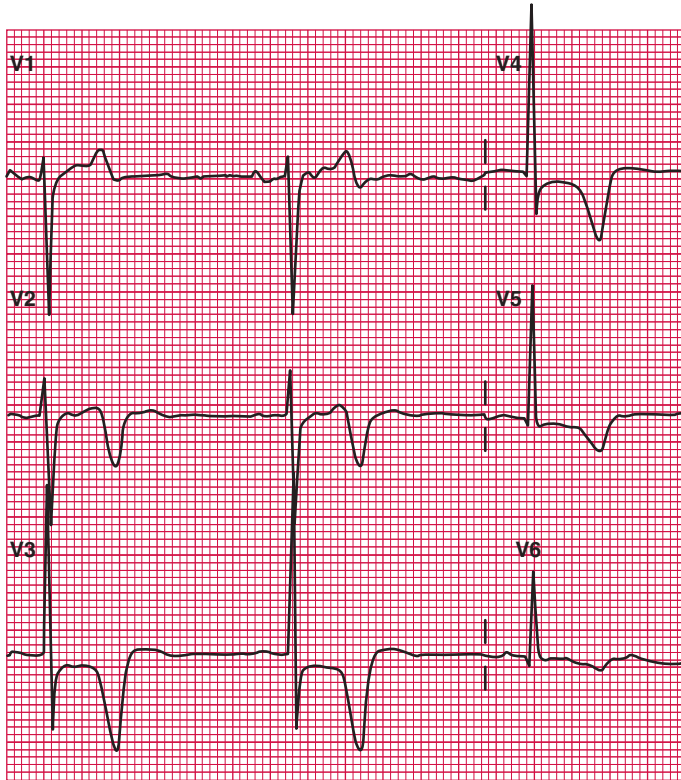
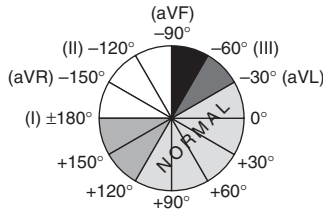
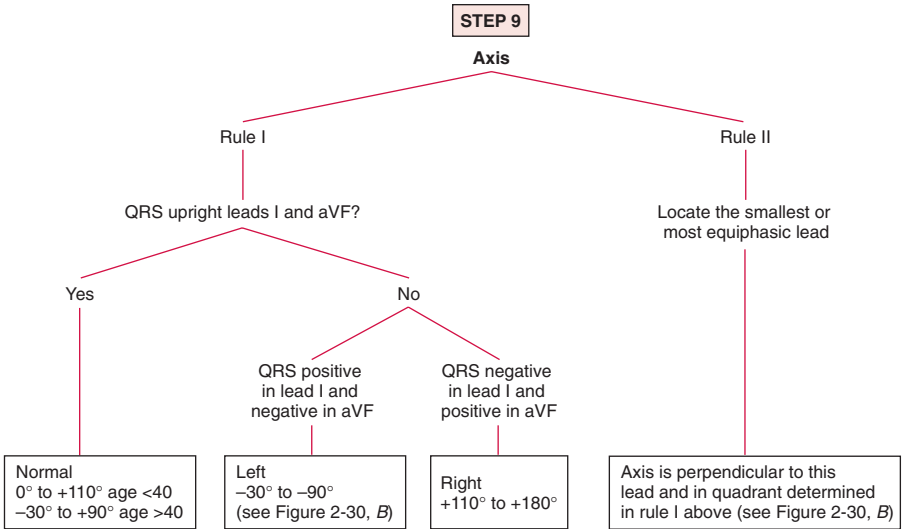


Fig. 2-29. The deep T wave inversion in V_2 through V_5 , which is associated with an abnormal ST segment that is hitched up in V_2 and abnormally shaped in V_3 and V_4 , is in keeping with myocardial ischemia and likely left anterior descending artery obstruction. Tracing from a 52-year-old woman with unstable angina; tracing taken in the absence of chest pain.

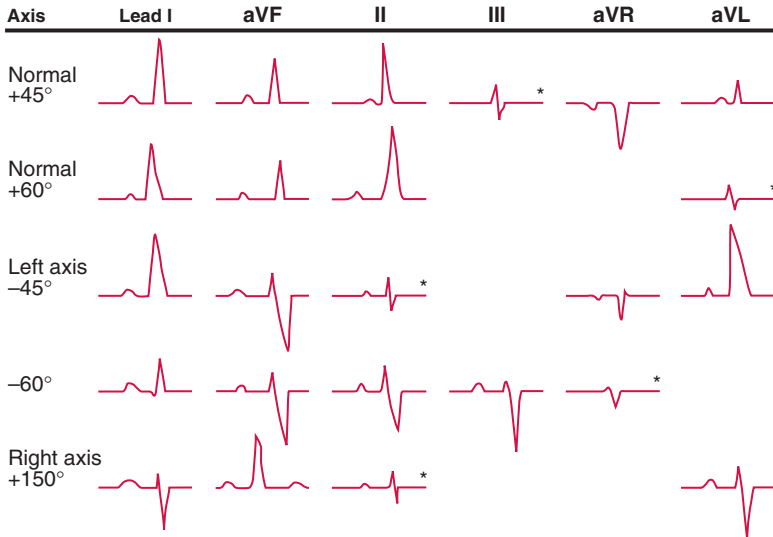
STEP 9: ASSESS ELECTRICAL AXIS (FIG. 2-30)

Assess the electrical axis (*see* Fig. 2-30 and Table 2-4) using two simple clues:

1. If leads I and aVF are upright, the axis is normal.
2. The axis is perpendicular to the lead with the most equiphasic or smallest QRS deflection (*see* Fig. 2-30B). Figure 2-31 shows left-axis deviation and the commonly associated left anterior fascicular block (*see* Chapter 9 and Figs. 9-5, 9-8, 9-10).



A



B *Most equiphase lead.

Table 2-4
Electrical Axis

<i>Most equiphasic lead</i>	<i>Lead perpendicular*</i>	<i>Axis</i>
		Leads I and aVF positive = normal axis
III	aVR	Normal = +30 degrees
aVL	II	Normal = +60 degrees Lead I positive and aVF negative = Left axis
II	aVL (QRS positive)	Left = -30 degrees
aVR	III (QRS negative)	Left = -60 degrees
I	aVF (QRS negative)	Left = -90 degrees Lead I negative and aVF positive = right axis
aVR	III (QRS positive)	Right = +120 degrees
II	aVL (QRS negative)	Right = +150 degrees

*Lead perpendicular (at right angles) to the most equiphasic (isoelectric) lead usually has the tallest R or deepest S wave.

←

Fig. 2-30. A, Step-by-step method for accurate ECG interpretation. Step 9: Assess the electrical axis. Leads are indicated in parentheses. **B**, See Table 2-4 and Figs. 2-3 and 9-5.

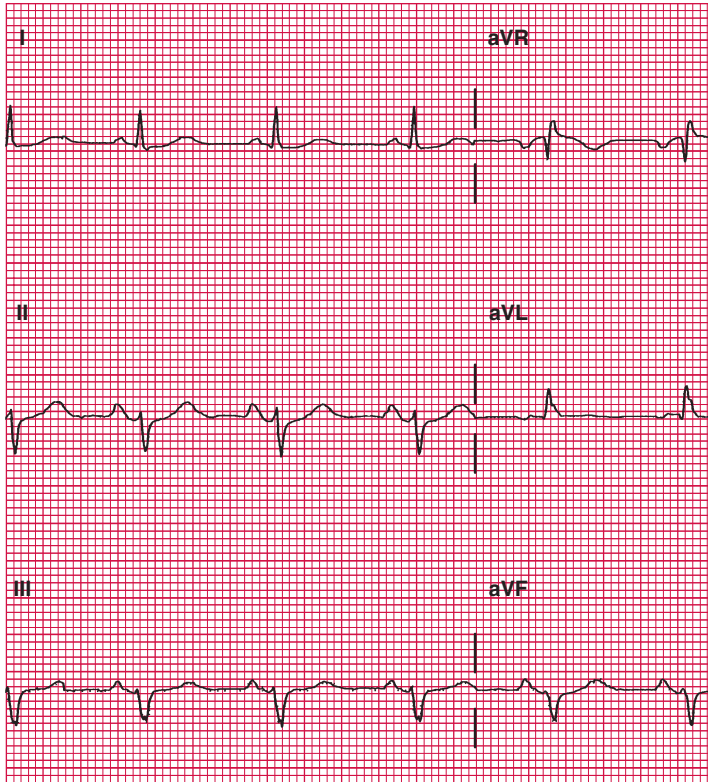


Fig. 2-31. Lead aVR is the most equiphasic: The lead perpendicular to aVR is lead III, indicating a left axis of -60 degrees. There is a small normal Q wave in lead I and a small R wave in lead III in keeping with left anterior fascicular block (hemiblock). Borderline ECG.

STEP 10: ASSESS FOR MISCELLANEOUS CONDITIONS (FIG. 2-32)

Perform a rapid screen for miscellaneous conditions (*see* Fig. 2-32). Chapter 10 gives details and relevant ECGs.

- Artificial pacemakers: If electronic pacing is confirmed, usually no other diagnosis can be made from the ECG (*see* Chapter 10).
- Prolonged QT syndrome: See normal QT parameters listed in Table 2-5. No complicated formula is required for assessment of the QT intervals (*see* Chapter 10 for further details). Some miscellaneous conditions are illustrated in Figures 2-33 to 2-36.

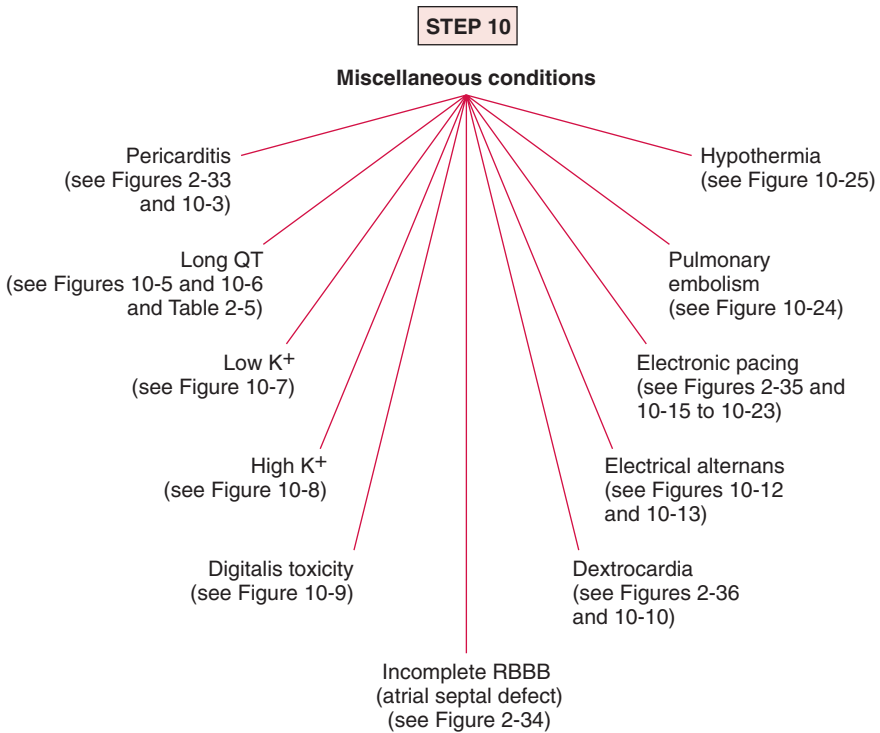


Fig. 2-32. Step-by-step method for accurate ECG interpretation. Step 10: Assess for miscellaneous conditions (see Chapter 10).

Table 2-5
QT Intervals*

Clinically useful approximation of upper limit of QT interval (s)

<i>Heart rate (bpm)</i>	<i>Male</i>	<i>Female</i>
45–65	<0.47	<0.48
66–100	<0.41	<0.43
>100	<0.36	<0.37

*ECG paper speed 25 mm/s. No complicated formula required.

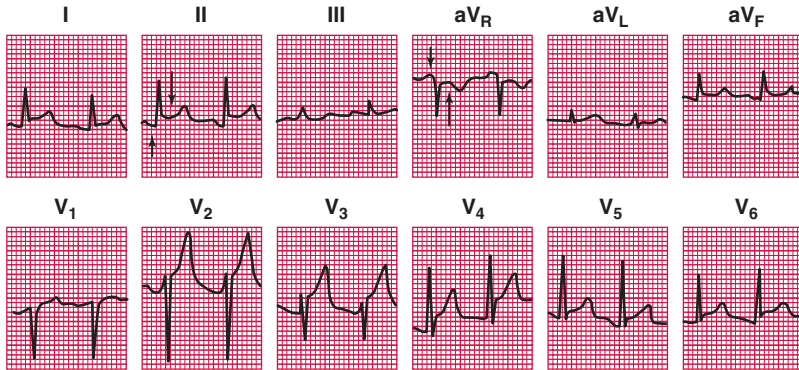


Fig. 2-33. Stage I electrocardiographic changes from patient with acute pericarditis. Diffuse ST segment elevation, which is concave upward, is present in all leads except aVR and V₁. Depression of the PR segment, an electrocardiographic abnormality that is common in patients with acute pericarditis, is not evident because of the short PR interval. (From Braunwald E: *Heart Disease: A Textbook of Cardiovascular Medicine*, 5th ed., Philadelphia, 1997, WB Saunders, Elsevier Science.)

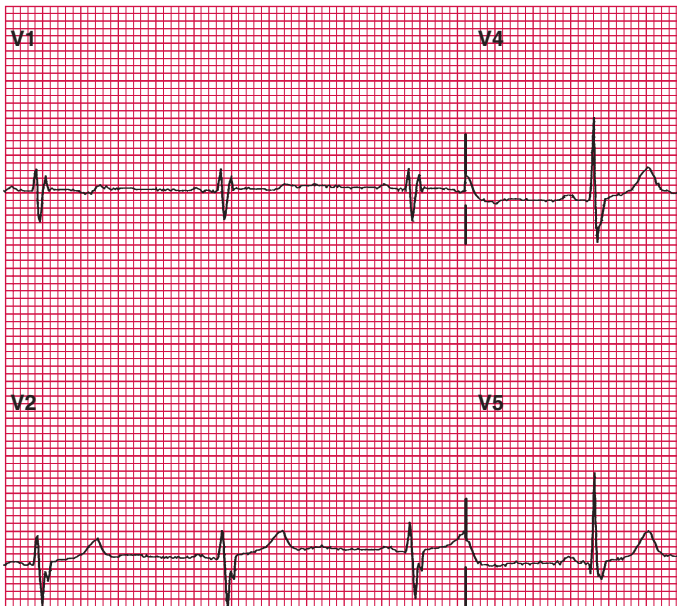


Fig. 2-34. V leads of a 39-year-old woman who had a large atrial septal defect repaired 5 years earlier. Note the Rsr' in lead V₁ and a wide, slurred S wave in V₅; the QRS duration is 0.1 second: incomplete right bundle branch block.

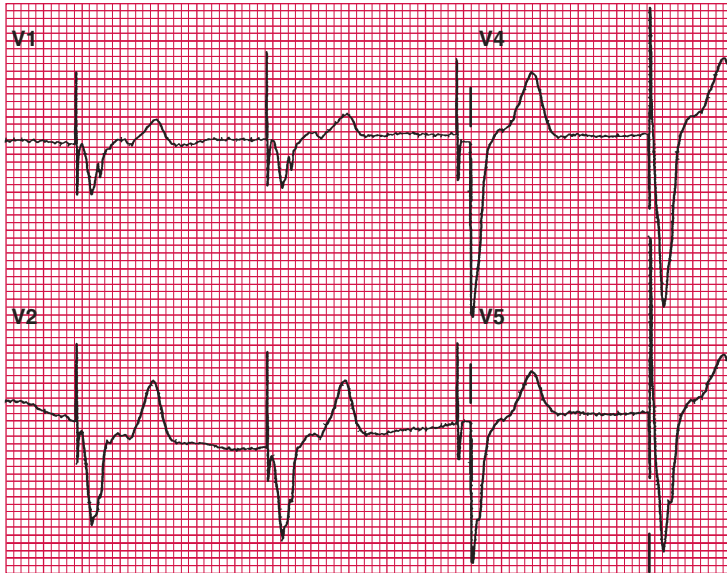


Fig. 2-35. ECG showing electronic pacing and ventricular capture; rate is 60 beats/min. No further analysis is possible because of pacemaker rhythm.

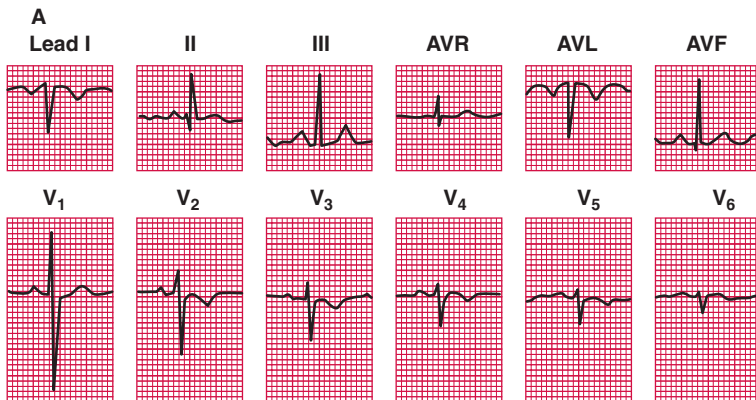


Fig. 2-36. Mirror-image dextrocardia with situs inversus. The patient is a 15-year-old girl. There is no evidence of organic heart disease. **A**, Tracing recorded with conventional electrode placement. **B**, Tracing obtained with the left and right arm electrodes reversed. The precordial lead electrodes also were located in the respective mirror-image positions on the chest. The tracing is within normal limits. (From Chou TC: *Electrocardiography in Clinical Practice*, 4th ed., Philadelphia, 1996, WB Saunders, Elsevier Science.)

(continued)

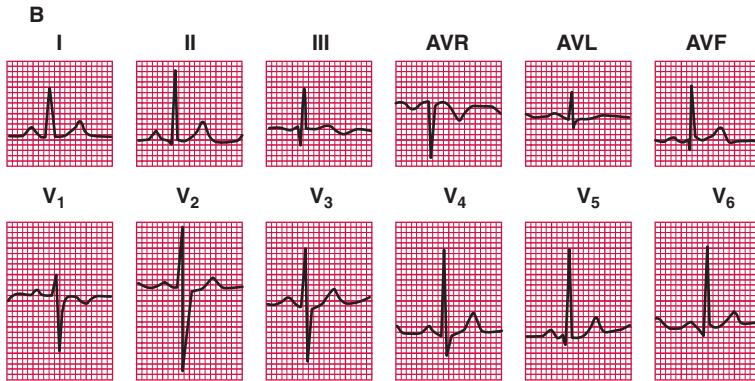


Fig. 2-36. *Continued*

STEP 11: ASSESS ARRHYTHMIAS (FIG. 2-37)

Tachyarrhythmias should be analyzed as the following:

- Narrow complex tachycardia: Figure 2-37A gives the differential diagnosis of narrow QRS complex tachycardia.
- Wide complex tachycardia: Figure 2-37B gives the differential diagnosis of wide QRS complex tachycardia. See Chapter 11 for relevant ECGs

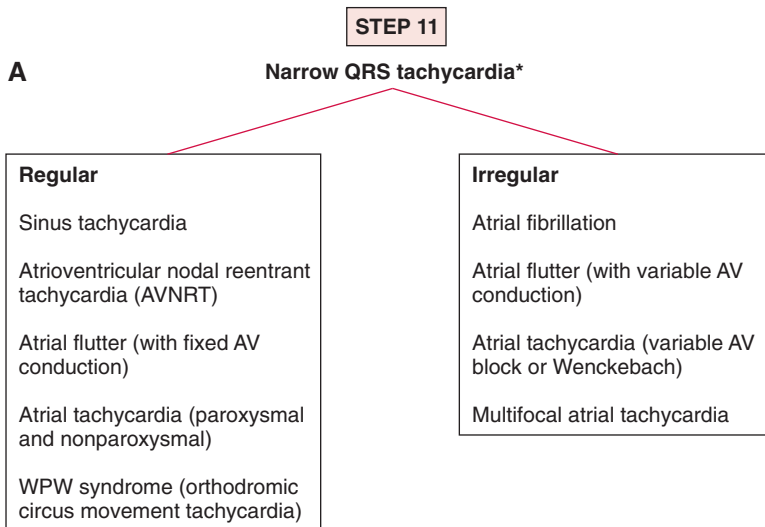
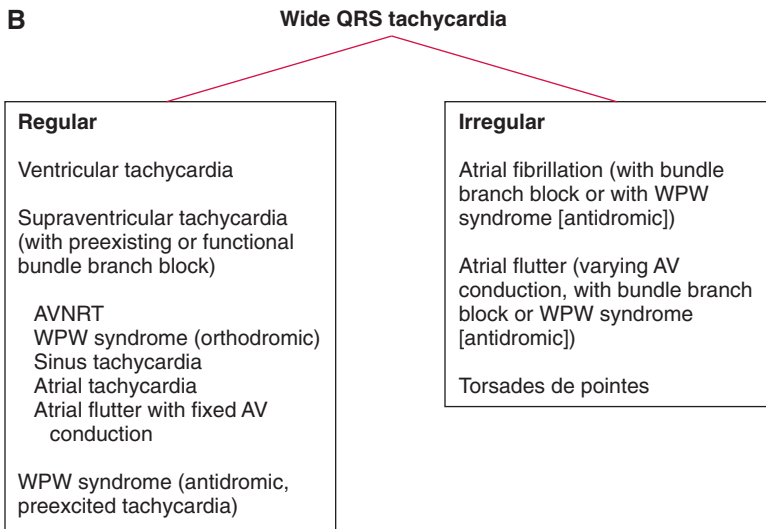


Fig. 2-37. Step-by-step method for accurate ECG interpretation. Step 11: Assess arrhythmias: differential diagnosis of narrow QRS tachycardia (A) and wide QRS tachycardia (B).



*See Chapter 11.

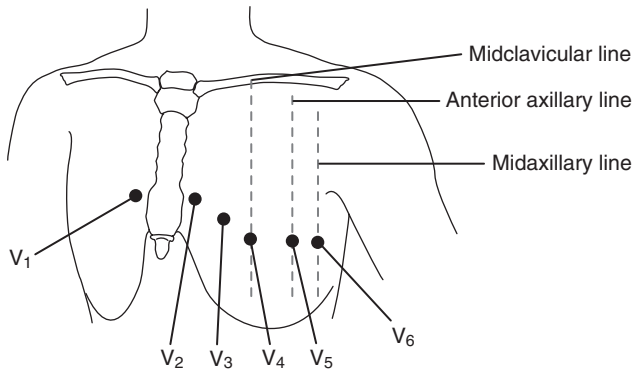
Fig. 2-37. *Continued*

and detailed discussion of arrhythmia diagnosis including that of bradyarrhythmias.

ELECTROCARDIOGRAM TECHNIQUE

- Ensure the standardization is 1 mV displayed as a 10-mm deflection (10 small squares in amplitude).
- Always record the ECG at a standard paper speed of 25 mm/s.
- Remember that artifacts such as baseline drift are often caused by loose or improperly installed sensors.
- Most ECG machines have two modes of operation: automatic or manual. Familiarize yourself with the procedure in the ECG department of your hospital so that you can do the ECG, if called, when there is no technician or nurse available to do the procedure.
- Attach the electrodes (bulb suction cup or flat sensors) on a smooth, fleshy part of the lower arm or forearm and on the fleshy parts of the lower leg.
- Attach the chest lead sensors as indicated in Fig. 2-38 (bulb sensor suction cups or flat sensors).

Ensure that electrodes are properly placed. Incorrect lead placement can lead to serious errors with interpretation (Fig. 2-39).



- V_1 = 4th interspace at the right margin of the sternum
 V_2 = 4th interspace at the left margin of the sternum
 V_3 = Midway between positions for V_2 and V_4
 V_4 = 5th interspace at junction of left midclavicular line (apex)
 V_5 = At horizontal level of position V_4 at left anterior axillary line
 V_6 = Same horizontal line as for position V_4 but in the midaxillary line

Fig. 2-38. Chest leads placement. V_1 , 4th interspace at the right margin of the sternum; V_2 , 4th interspace at the left margin of the sternum; V_3 , midway between positions for V_2 and V_4 ; V_4 , 5th interspace at junction of left midclavicular line (apex); V_5 , at horizontal level of position V_4 at left anterior axillary line; V_6 , same horizontal line as for position V_4 but in the midaxillary line.

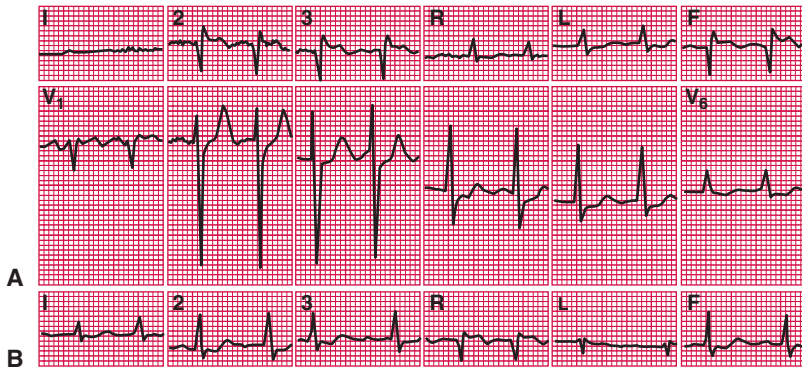


Fig. 2-39. **A**, Atrial fibrillation and pseudo-inferior infarction resulting from electrode misplacement. With Q waves and ST elevation in leads 2, 3, and aVF and with reciprocal depression of the ST segment in aVL and chest leads, this tracing suggests acute inferior infarction. However, lead 1, with virtually no deflections, is the tip-off: The two arm electrodes are on the two legs (and the leg electrodes are on the arms). **B**, Limb leads with the electrodes attached correctly. (From Marriott JLH: *Practical Electrocardiography*, 8th ed., Baltimore, 1988, Williams & Wilkins.)

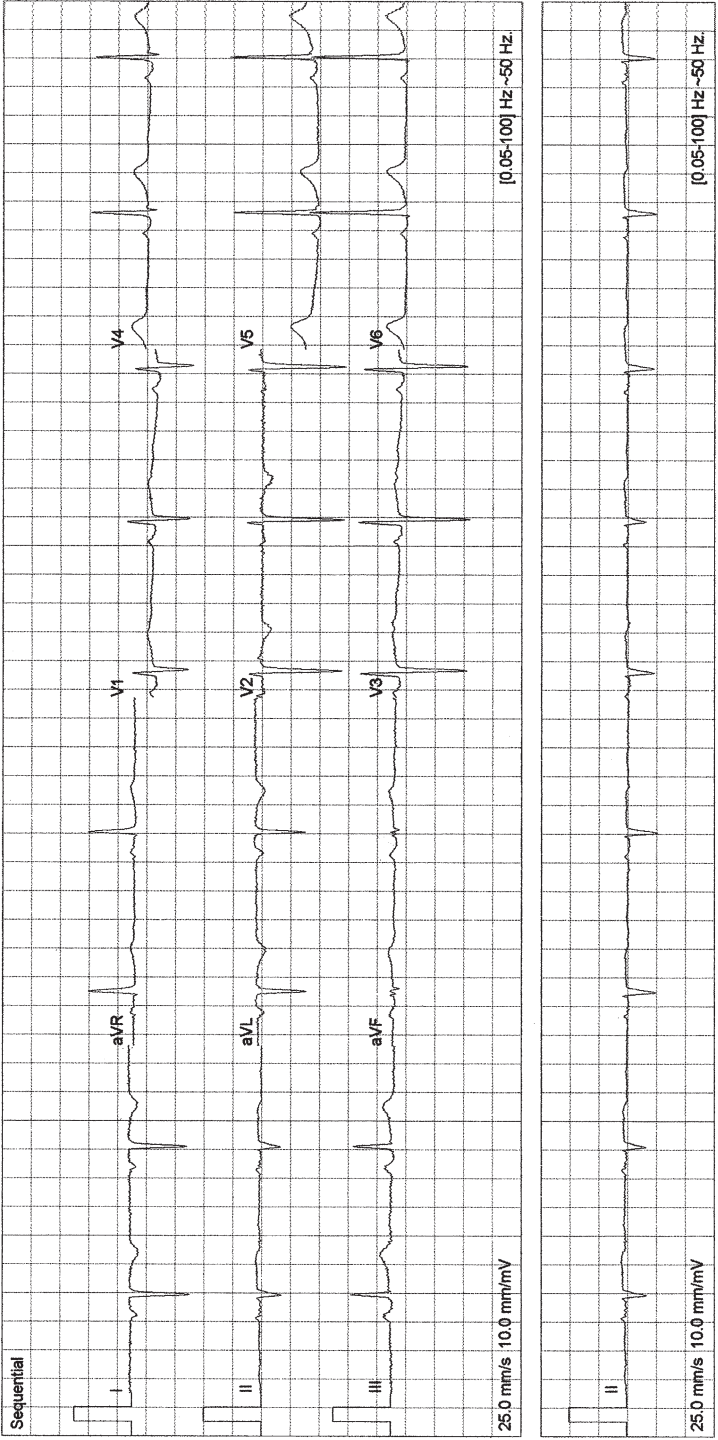


Fig. 2-40. Arm electrodes interchanged. Otherwise ECG within normal limits.

Untrained technicians often place leads V_5 and V_6 too anteriorly; this may not give a true recording of the left ventricular muscle mass. The leads must be placed in the anterior and midaxillary line (*see* Fig. 1-15). Incorrect placement of V_2 and V_3 may render a false interpretation of old anteroseptal MI. Thus, much care is needed in placing the chest leads. Feel for the bony points (*see* Fig. 1-14) to position V_2 , V_3 , and V_4 . Small changes in electrode position can cause significant changes in the record obtained with these leads.

The most common error is the reversal of the left and right arm leads. The ECG records the following: the P wave is negative in lead I and upright in aVR; lead I is a mirror image of I, and therefore the entire complex that is usually positive becomes negative; there is reversal of lead aVR and aVL (aVR is aVL: aVL shows a negative P wave and a relatively negative complex because it is aVR); and there is reversal of leads II and III (lead II is III and lead III is II). Figure 2-40 shows the effect of the reversal of the arm leads. The P, QRS, and T waves are inverted in leads I and aVL; the precordial (V) leads remain normal, however, and thus rule out dextrocardia, in which the limb leads are similar but there is loss of R waves or poor R wave progression from V_2 through V_6 (*see* Fig. 2-36).

3

P Wave Abnormalities

CONTENTS

FEATURES OF THE NORMAL P WAVE
FEATURES OF ABNORMAL P WAVES
(See FIGS. 2-21 AND 2-22)

The P wave represents the spread of the electrical impulse through both atria (*see* Fig. 1-8). The electrical impulse begins in the SA node and depolarizes the right atrium and then the left atrium. Thus, the first part of the P wave reflects right atrial activity, and the late portion of the P wave represents electrical potential generated by the left atrium.

FEATURES OF THE NORMAL P WAVE

The following are some features of the normal P wave:

- It should be upright in leads I and II, as well as in the precordial leads V₃ through V₆ (Figs. 3-1 and 3-2).
- It is always inverted in aVR.
- It is usually upright in aVF and V₃, but occasionally a diphasic or flat P wave may be seen.
- It is variable in leads III, aVL, V₁, and V₂; upright, inverted, or diphasic. (A P or T wave that is partly above the baseline and partly below it is referred to as diphasic.)

FEATURES OF ABNORMAL P WAVES

(SEE FIGS. 2-21 AND 2-22)

- Inverted in II, III, and aVF and upright in aVR: diagnostic of an atrio-ventricular (AV) junctional (*see* Fig. 3-2) or ectopic atrial rhythm. When there is abnormal propagation of the electrical impulse through the atria, the polarity or axis of the P wave is abnormal.

From: *Contemporary Cardiology: Rapid ECG Interpretation, 3e*
by: M. Gabriel Khan © Humana Press Inc., Totowa, NJ

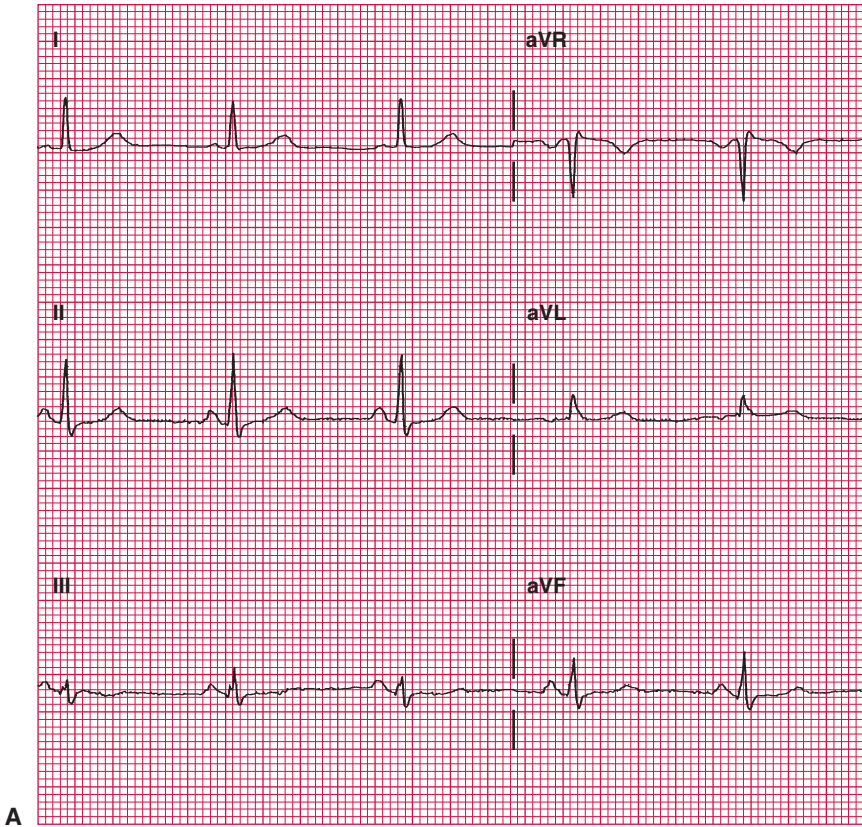


Fig. 3-1. A, Limb leads of a normal tracing. Normal upright P waves are seen in lead I but are best seen in lead II, are inverted in aVR, and usually are variable in aVL and lead III.

- Inverted in lead I and upright in aVR, with lead I being the mirror image of I: caused by reversed arm leads or dextrocardia, but in true dextrocardia there is a loss of R wave in V_4 through V_6 (see Figs. 2-36 and 2-40).
- Duration ≥ 0.12 second (three small squares). Most prominent in leads II, III, and aVF; caused by left atrial enlargement (see Figs. 2-21 and 2-40). P waves are seen best in leads II and V_1 ; thus, these leads should be used for rhythm strips and arrhythmia detection.
- Notching of a wide P wave in lead II, III, or aVF: a distance between peaks >0.04 second usually indicates left atrial enlargement (see Fig. 2-22).

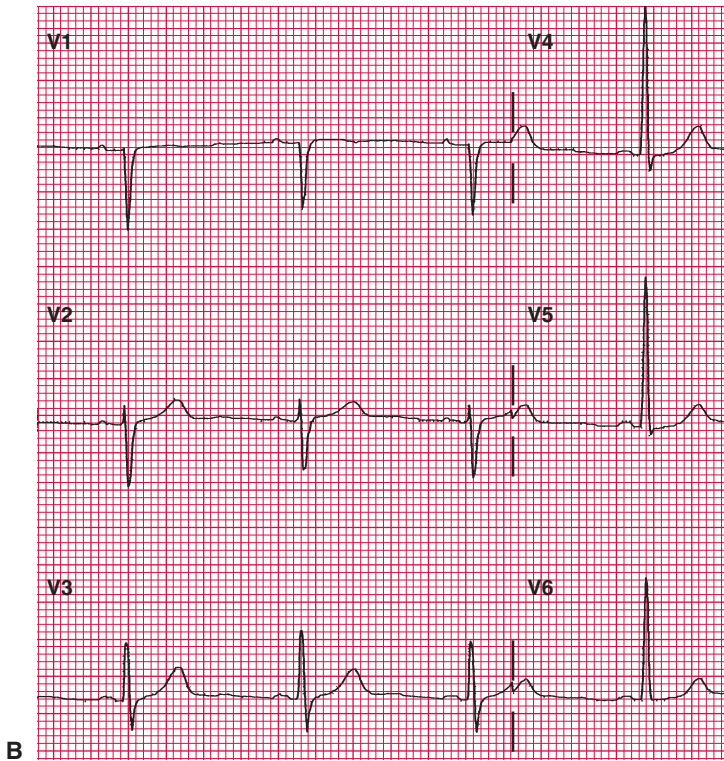


Fig. 3-1. B, Same tracing as in (A) showing normal upright P waves in leads V_3 through V_6 .

- Diphasic in V_1 : the second half of the P wave is dominantly negative and wide (*see* Figs. 2-22, 2-23, and 3-3). The depth of the inversion multiplied by the width represents the P terminal force; if it is ≥ -0.04 mm (i.e., a negative amplitude of 1 mm with duration of 0.04 second), consider left atrial enlargement (*see* Figs. 2-22, 2-23, and 3-3). In V_1 , the negative deflection is normally < 1 mm.
- Large diphasic in V_1 : if the first half of the P wave is positive ≥ 1.5 mm and the second half is negative ≥ 1 mm and wide, consider biatrial enlargement (*see* Fig. 2-23).
- High amplitude, peaking (*see* Figs. 2-22 and 2-23): tall, pointed P waves, taller in lead III than in lead I; high amplitude (≥ 2.5 mm), particularly in lead II, III, or aVF, indicates right atrial enlargement. Consider the presence of right ventricular hypertrophy, cor pulmonale, pulmonary hypertension, or pulmonary and tricuspid stenosis. Positive amplitude of the first half of the P wave in V_1 or $V_2 \geq 1.5$ mm indicates right atrial enlargement (Figs. 3-4 and 3-5).

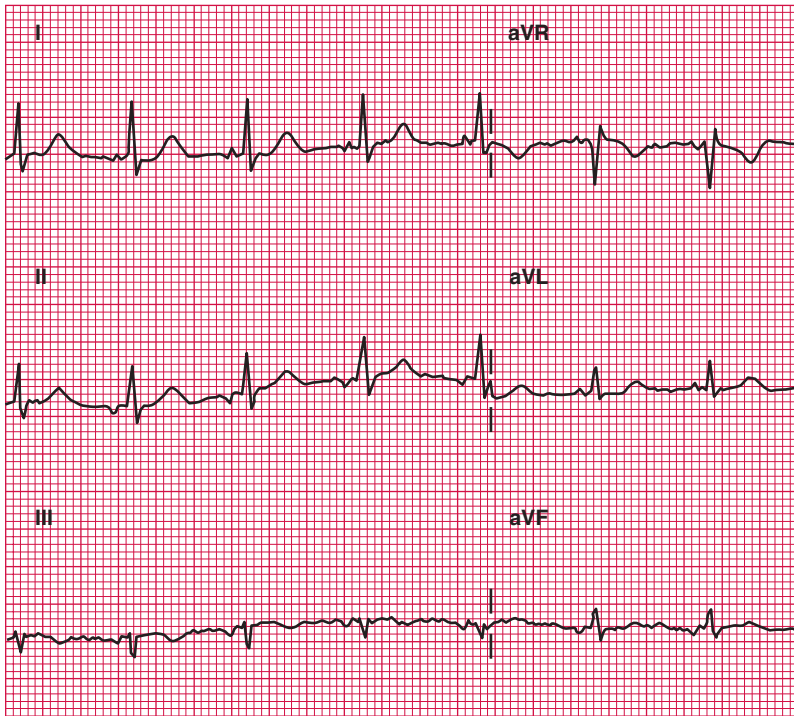


Fig. 3-2. P wave is inverted in leads II, III, and aVF and is upright in aVR, indicating junctional rhythm.

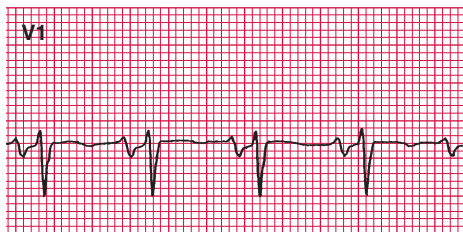

Fig. 3-3. The second half of the P wave in V_1 is dominantly negative and wide, indicating left atrial enlargement.

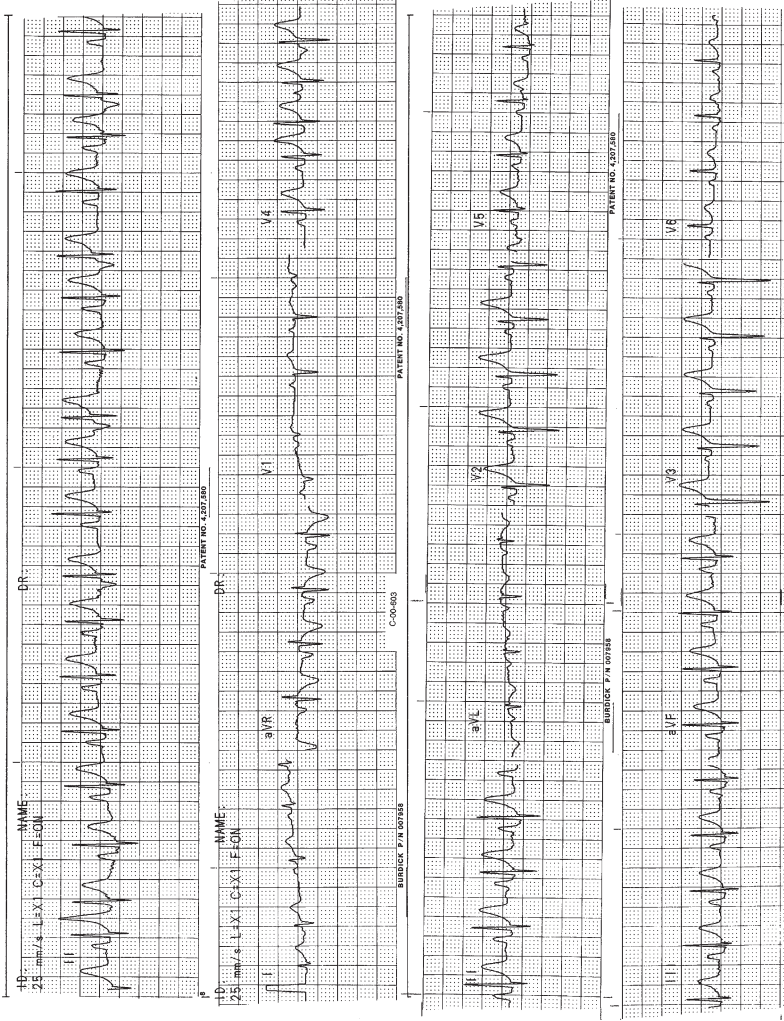


Fig. 3-4. Tall pointed P waves, high amplitude (>2.5 mm), particularly in leads I, II and aVF. Note the P wave is much taller in lead III than in lead I; typical features of right atrial hypertrophy (enlargement).

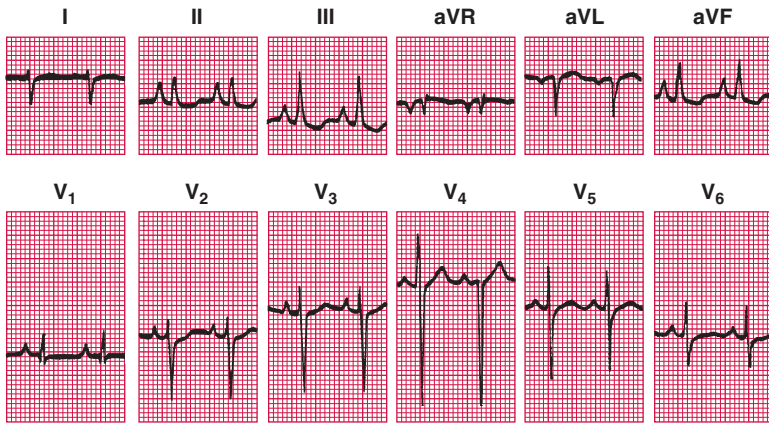


Fig. 3-5. Right atrial enlargement in a 33-year-old man with pulmonary fibrosis, chronic cor pulmonale, and right ventricular failure. P pulmonale pattern is present in the limb leads with abnormally tall and peaked P waves also in leads V₁ through V₃. (From Chou TC: *Electrocardiography in Clinical Practice*, 4th ed., Philadelphia, 1996, WB Saunders, Elsevier Science.)

- Absent P waves: consider SA block and AV junctional rhythms. If the rhythm is irregular, consider atrial fibrillation (*see* Chapter 11).
- Different morphologies: at least three different P wave morphologies in the same lead: consider multifocal atrial tachycardia (*see* Chapter 11).

4

Bundle Branch Block

CONTENTS

RIGHT BUNDLE BRANCH BLOCK (RBBB)
LEFT BUNDLE BRANCH BLOCK (LBBB)

RIGHT BUNDLE BRANCH BLOCK (RBBB)

Diagnostic Criteria

- Wide QRS ≥ 0.12 second.
- A secondary R wave (R') in V_1 or V_2 (i.e., an rSR', rsR', or rsr' complex that often is M-shaped). The secondary R wave (R') is usually taller than the initial R wave (Figs. 4-1, 4-2A, and 2-7A).
- A wide, slurred S wave in leads V_5 , V_6 , and I with duration >40 ms; the S wave is longer in duration (length) than the preceding R wave in leads V_6 and I (see Figs. 2-7 and 4-2).
- The axis may be normal, right, or left. If left axis is present, consider left anterior fascicular block (hemiblock) (see Chapter 9).

Genesis of the QRS in RBBB

The typical M-shaped complex in V_1 or V_2 is derived from an alteration of the normal vector forces (see Figs. 1-17 and 4-1).

- The initial impulse depolarizes the septum normally from left to right. With RBBB, vector I remains intact; the electrical current traveling toward the electrode V_1 positioned over the right ventricle registers an initial small R wave in leads V_1 and V_2 (see Fig. 4-1). Because the right bundle branch does not conduct the electrical impulse, vector II is directed leftward only, activates the left ventricle, and records an S wave in V_1 and V_2 . Right ventricular activation occurs later (i.e., unopposed by left ventricular activation); the resultant force, vector III, causes a large R, termed R' in V_1 or V_2 . Thus, the rsR' or rSR' complex depicts an M shape. The deflection R' is usually greater than the amplitude of the small R produced by vector I septal depolarization.

From: *Contemporary Cardiology: Rapid ECG Interpretation, 3e*
by: M. Gabriel Khan © Humana Press Inc., Totowa, NJ

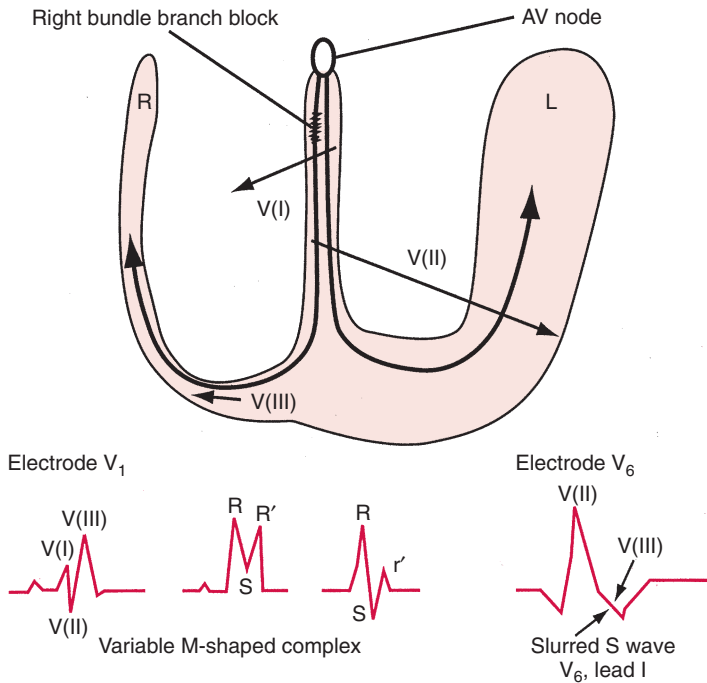


Fig. 4-1. Genesis of the QRS complex in right bundle branch block. (From Khan, M. Gabriel: *On Call Cardiology*, 2nd ed., Philadelphia, 2001, WB Saunders, Elsevier Science.)

- The unopposed late depolarization of the right ventricle, which causes the R' in V₁ or V₂, is recorded as a wide, slurred S wave in leads V₅, V₆, and I, the electrodes overlying the left ventricle (see Figs. 2-7, 4-1, and 4-2).
- Because of delayed right ventricular activation, the QRS duration is increased to 0.12 second or more. Figure 4-2D shows typical features of RBBB.
- *Brugada syndrome* is a special form of incomplete or complete RBBB pattern. Although the condition is rare, it is a common cause of idiopathic ventricular fibrillation and sudden cardiac death in young adults, particularly of Asian origin, and notably in individuals without evidence of structural heart disease. Attention must be given to any condition that causes sudden death, particularly in young individuals. The typical ECG features are illustrated in Figs. 4-3 to 4-5. Note the RBBB pattern and persistent ST segment elevation in V₁, V₂, and V₃ that has a typical pattern: coved or saddle-back shaped, a marker for sudden death in individuals without demonstrable structural heart disease. Note that this

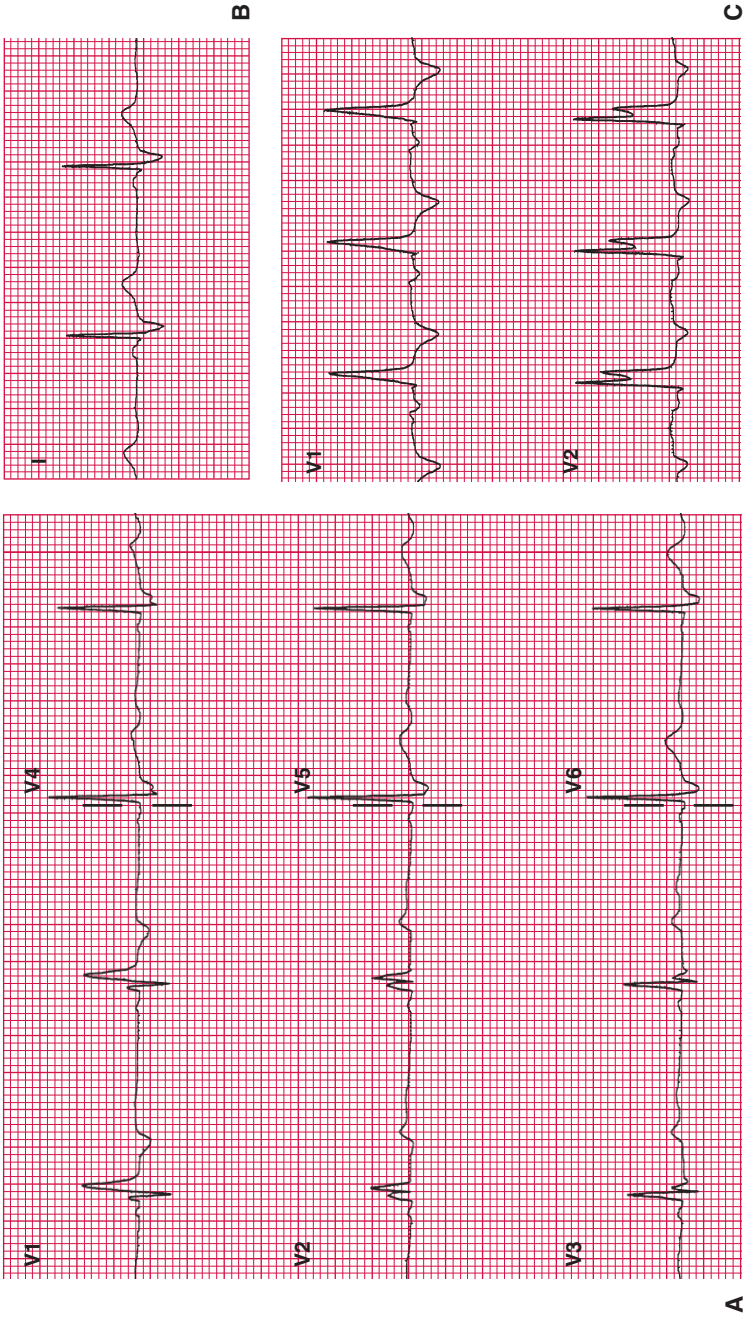
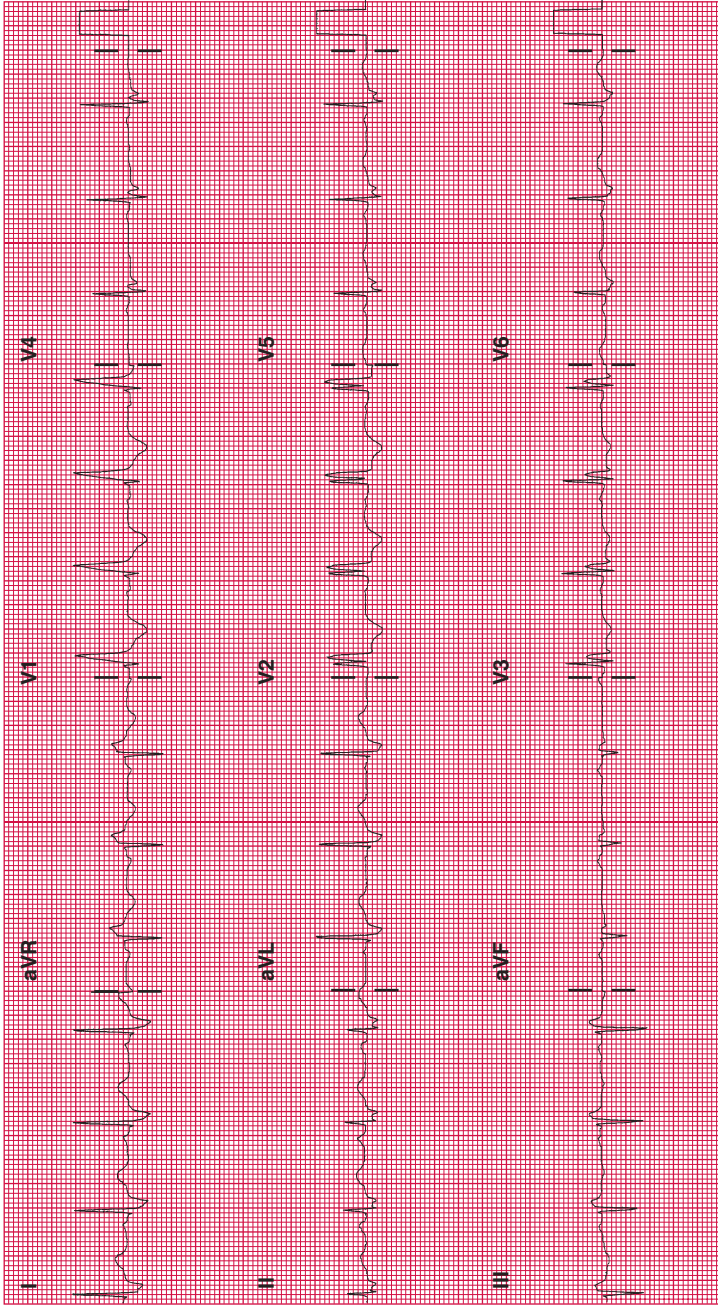


Fig. 4-2. A, An rSR' in V₁; M-shaped complex in V₁ and V₂; QRS duration ≥ 0.12 second; and wide, slurred S waves in V₅ and V₆ indicate right bundle branch block (RBBB). B, Same patient as in (A). Lead I, wide, slurred S wave indicates RBBB. C, Right bundle branch block.

(continued)



D

Fig. 4-2. Continued D, Typical right bundle branch block: QRS, 0.14 second; rsR' in V1; M-shaped complex in lead V2; and a slurred S wave in V5 and V6. The S wave in lead I and V6 is longer in duration (length) than the preceding R wave.

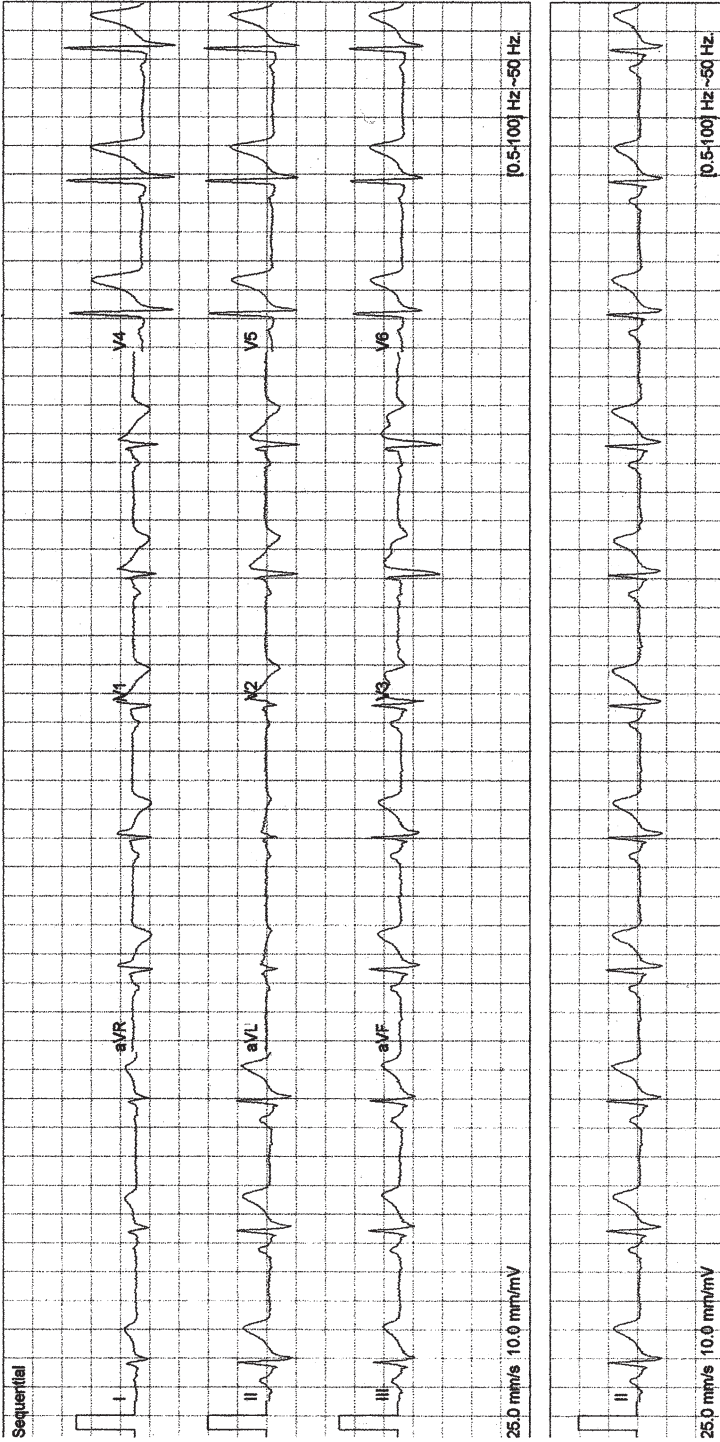


Fig. 4-3. Typical features of Brugada syndrome. Atypical, incomplete right bundle branch block with a curious (odd shape) ST segment elevation / deformity in V₁ to V₃, described as the coved (in V₁, V₂) and saddle-back patterns (V₃). Note there is no widened S wave in V₅ or in V₆, as seen in true incomplete or complete RBBB. Thus if you recognize an atypical RBBB think of Brugada syndrome and reassess for the characteristic features of this rare but important diagnosis. ECG from a 40 year old man with episodes of syncope / collapse. No recurrence of syncope over 3 years following ICD.

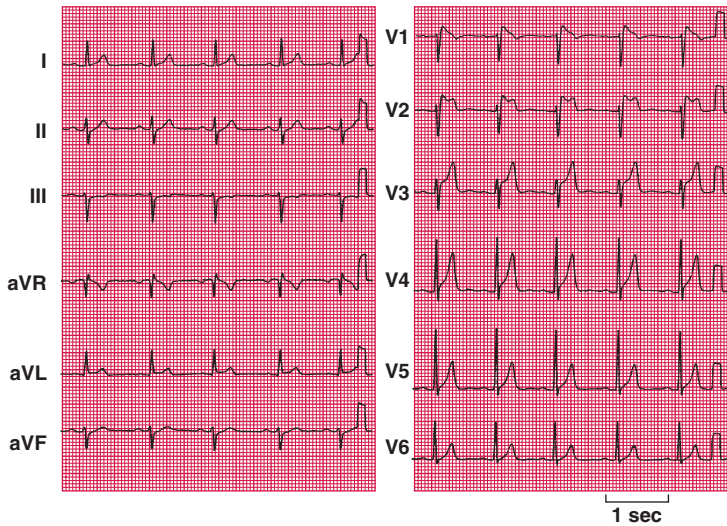


Fig. 4-4. Electrocardiograms from patient during sinus rhythm. ST segment elevation of the coved (lead V₁) and saddle-back types (lead V₂) can be seen. (From Miyazaki T et al.: *J Am Coll Cardiol* 27:1063, 1996.)

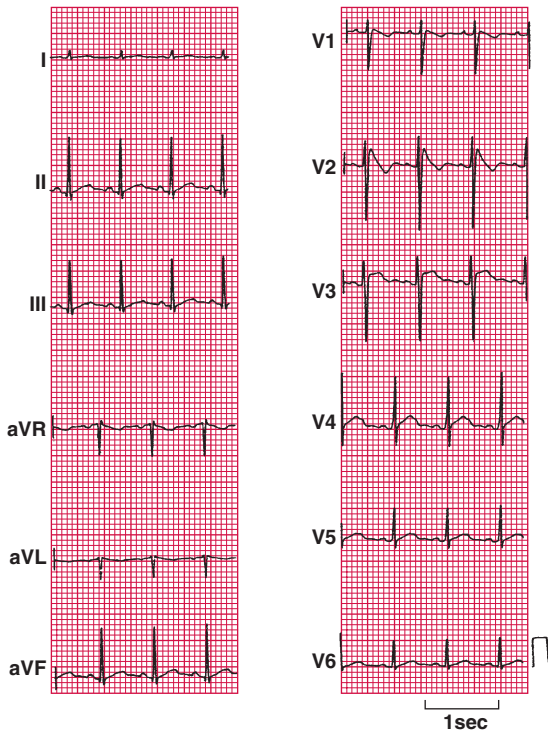


Fig. 4-5. Electrocardiograms from patient during sinus rhythm. Coved-type ST segment elevation can be seen in leads V₁ and V₂. (From Miyazaki T et al.: *J Am Coll Cardiol* 27:1063, 1996.)

is an atypical incomplete or complete RBBB pattern, because there are usually no widened S waves in V_5 and V_6 of true RBBB: the S wave in V_6 or lead I in RBBB is longer in duration than the preceding R wave. The ST segment elevation appears to be caused by an early high take-off (J wave) and mimics RBBB.

- Arrhythmogenic right ventricular dysplasia, another rare condition that shows an atypical RBBB pattern, is a marker for sudden cardiac death in younger individuals. With this condition, there is structural heart disease caused by a type of cardiomyopathy that involves the right ventricle and the left ventricle at a later stage. Fatty and fibro-fatty degeneration occurs in the right ventricular inflow and outflow tracts and in the apex. The typical ECG finding is shown in Fig. 4-6. Either incomplete or complete RBBB is observed. In approximately 40% of cases, a characteristic terminal notch is observed in the QRS of V_1 and V_2 (termed an epsilon wave) that is a result of slowed intraventricular conduction. Another feature is T wave inversion in V_1 , V_2 , and V_3 . The echocardiogram may show an abnormal right ventricle as the disease progresses.

Causes of RBBB

- A normal finding in adults of all ages.
- Coronary artery disease and hypertensive and rheumatic heart disease.
- Congenital heart disease, often associated with ventricular septal defect (VSD) and Fallot tetralogy. With secundum atrial septal defect (ASD), more than 90% of individuals have incomplete RBBB.
- Coarctation of the aorta.
- Pericarditis and myocarditis including Chagas disease.
- Pulmonary embolism and cor pulmonale.
- Cardiomyopathy.
- Brugada syndrome and right ventricular dysplasia (atypical RBBB pattern).

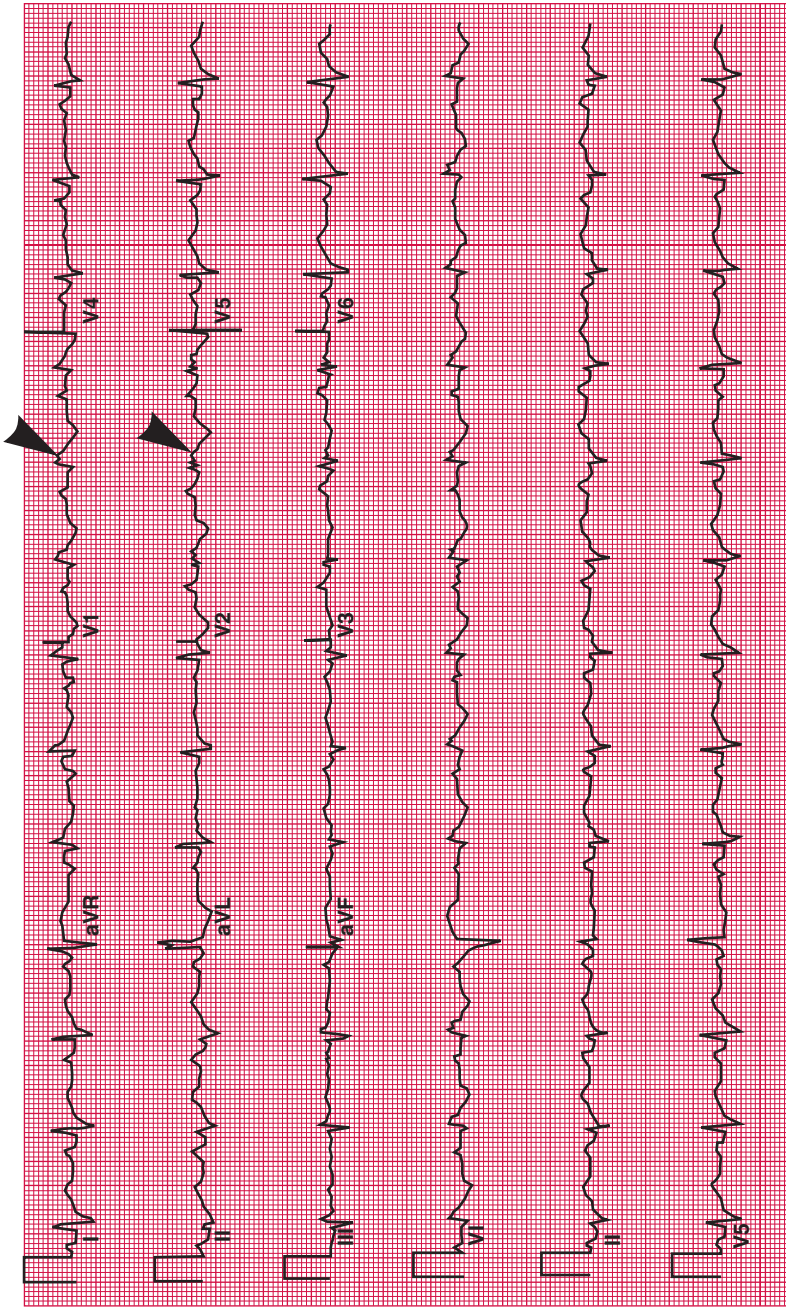
Incomplete RBBB

DIAGNOSTIC CRITERIA

- The presence of an rSR' (i.e., RBBB pattern) in V_1 or V_2 and an S wave in leads I and V_6 should be confirmed.
- The QRS duration should be 0.08 to 0.11 second.

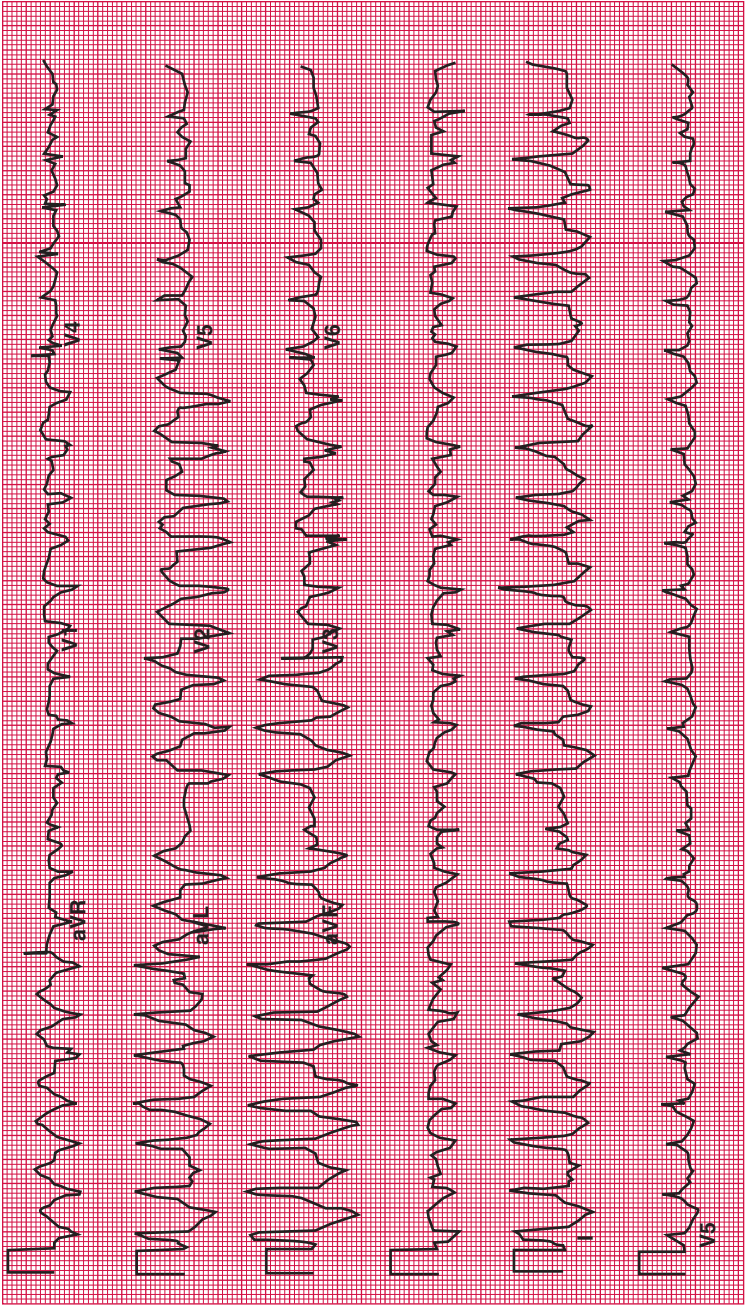
CAUSES OF INCOMPLETE RBBB

- Incomplete RBBB is a common ECG finding in normal individuals.
- More than 90% of patients with a secundum ASD show incomplete RBBB (*see* Figs. 2-34 and 4-3).



A

Fig. 4-6. A, Normal sinus rhythm in a patient with arrhythmogenic right ventricular dysplasia. The arrowheads point to late right ventricular activation called an epsilon wave. (From Braunwald E: *Heart Disease: A Textbook of Cardiovascular Medicine*, 6th ed., Philadelphia, 2001, WB Saunders, Elsevier Science.)



B

Fig. 4-6. B, Ventricular tachycardia in the same patient with right ventricular dysplasia. (From Braunwald E: *Heart Disease: A Textbook of Cardiovascular Medicine*, 6th ed., Philadelphia, 2001, WB Saunders, Elsevier Science.)

- WPW syndrome may mimic incomplete RBBB.
- Brugada syndrome and right ventricular dysplasia.

RSr' Variant

More than 5% of individuals without heart disease show an RSr' in V₁ or V₂. If the QRS duration is ≥ 0.08 second and there is an S wave in V₅ or V₆ (*see* Fig. 4-3), the diagnosis of incomplete RBBB should be made. The diagnosis is strengthened if there is a slurred S wave in I, V₅, or V₆.

- If a slurred S wave is absent in leads I, V₅, or V₆ with QRS duration < 0.08 second, the ECG is interpreted as an rSR', RSR', or RSr' variant, borderline ECG (*see* Fig. 4-4). An R' < 6 mm with an R'/S ratio < 1 suggests normality.

CAUSES OF rSR', RSR', AND RSr' IN V₁ OR V₂: QRS DURATION ≤ 0.11 SECOND

- Idiopathic; a normal finding in 5% of individuals without heart disease.
- Incomplete RBBB
- Straight back syndrome or pectus excavatum
- ASD
- Rarely, VSD and coarctation of the aorta
- Mitral stenosis and other acquired heart diseases
- Right ventricular hypertrophy
- Right ventricular volume overload
- Cor pulmonale or pulmonary embolism
- WPW syndrome (may mimic incomplete RBBB)
- Atrioventricular nodal reentrant tachycardia (*see* Chapter 11).
- Muscular dystrophy
- Late activation of the outflow tract of the right ventricle, the crista supraventricularis (may cause r' wave in V₁)
- Incorrect placement of the V₁ electrode

The RSr' may appear if V₁ is placed in the third interspace and may disappear with the electrode in the fifth interspace, or incomplete RBBB may be recorded (*see* Figs. 2-34 and 4-8). The appearance at a higher intercostal space may be the only abnormality in some patients with a secundum ASD (*see* Figs. 2-34, 4-7, 4-9, and 10-1).

RBBB and Myocardial Infarction

- With acute anterior MI, pathologic Q waves occur in V₁, V₂, V₃, or V₄. A Q wave in V₁ and V₂ is not sufficient evidence for the diagnosis of MI.

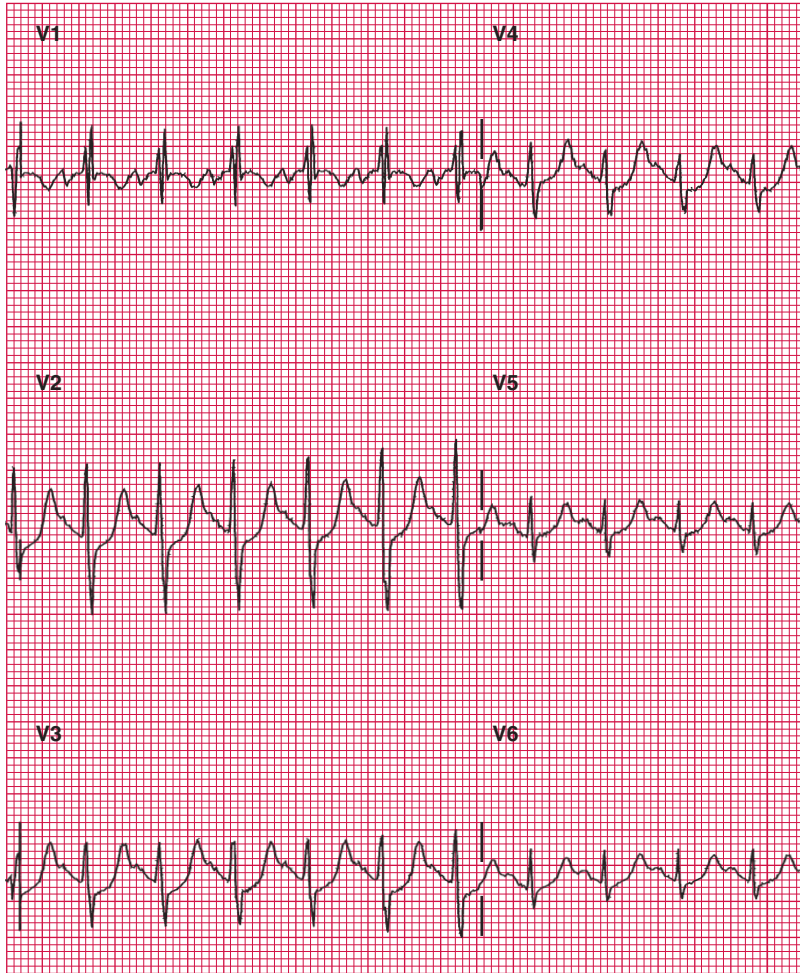


Fig. 4-7. Sinus tachycardia, rate 147 beats/min. QRS duration 0.10 second and rSR' in V₁ indicate incomplete right bundle branch block.

- Consider inferior MI only if pathologic Q waves are present in leads II, III, and aVF. Q waves in leads III and aVF are not diagnostic.
- The right bundle branch and the septum are supplied blood by the same artery; thus anteroseptal infarction commonly is associated with RBBB. In anteroseptal MI, the initial septal force, vector 1, is lost. Thus, a loss of the initial r wave occurs in V₁ with resultant q or Q wave in V₁, V₂. In addition, the normal small q wave in V₆ disappears (Fig. 4-10).

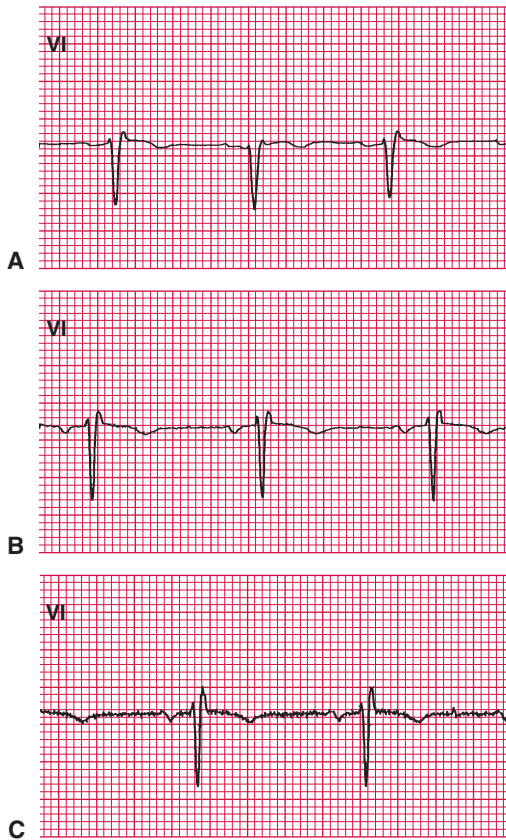


Fig. 4-8. RSR' and rSR' in V₁; recorded in different intercostal spaces.

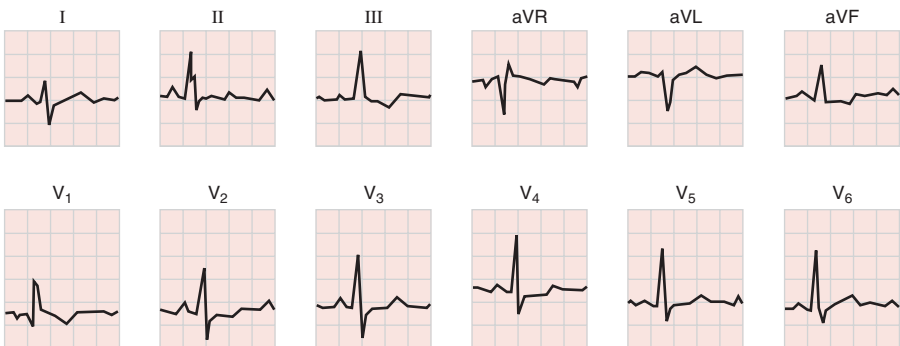


Fig. 4-9. Atrial septal defect. The patient is a 21-year-old woman with atrial septal defect proved by cardiac catheterization. The pulmonary arterial pressure was normal. The ECG shows a frontal plane QRS axis of 90 degrees and rSR' pattern in lead V₁. There also are ST and T changes in the right and middle precordial leads and inferior leads. (From Chou TC: *Electrocardiography in Clinical Practice*, 4th ed., Philadelphia, 1996, WB Saunders, Elsevier Science.)

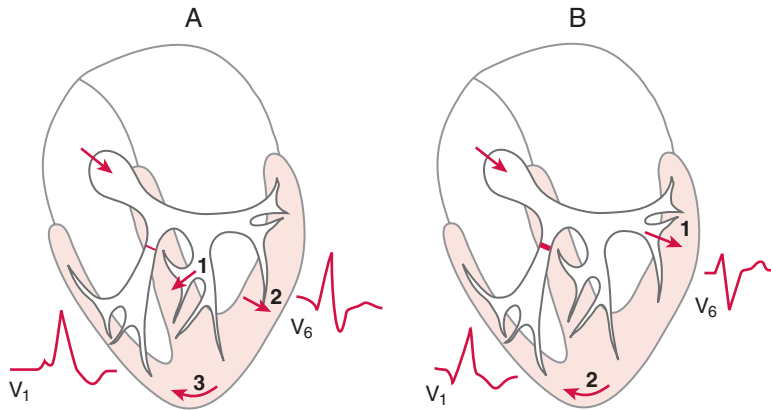


Fig. 4-10. Mechanism of right bundle branch block. **A**, Note that the right ventricle is activated last and without any opposing forces, resulting in the late R' in lead V₁ and the S wave in lead V₆. **B**, In anteroseptal infarction, a QR pattern develops in lead V₁. Loss of anterior wall tissue causes an R/S pattern in lead V₆. (From Wellens HJ et al.: *The ECG in Emergency Decision Making*, Philadelphia, 1992, WB Saunders, Elsevier Science.)

LEFT BUNDLE BRANCH BLOCK (LBBB)

Diagnostic Criteria

- QRS duration ≥ 0.12 second.
- A broad monophasic R wave that is often notched or slurred in lead I, aVL, V₅, or V₆ (Figs. 4-11 to 4-13 and Fig. 2-8B).
- Late intrinsicoid deflection in leads I, V₅, and V₆ greater than 0.05 second.
- Leads V₁ and V₂ reveal QS or rS pattern with poor R wave progression in V₂ and V₃ (see Figs. 4-11 to 4-13). Figure 4-14A shows notching of lead I. Figure 4-14B shows all the typical features of LBBB.
- A presumptive diagnosis of incomplete LBBB may be made if the QRS duration is 0.10 to 0.11 second with notching of the R wave in V₅ or V₆.

Genesis of the QRS Complex in LBBB

- Depolarization of the left ventricle is delayed, and the QRS duration is prolonged to ≥ 0.12 second.
- The septum and left ventricle are activated by the electrical impulse from the right bundle.
- The normal direction of septal activation from left to right is reversed.

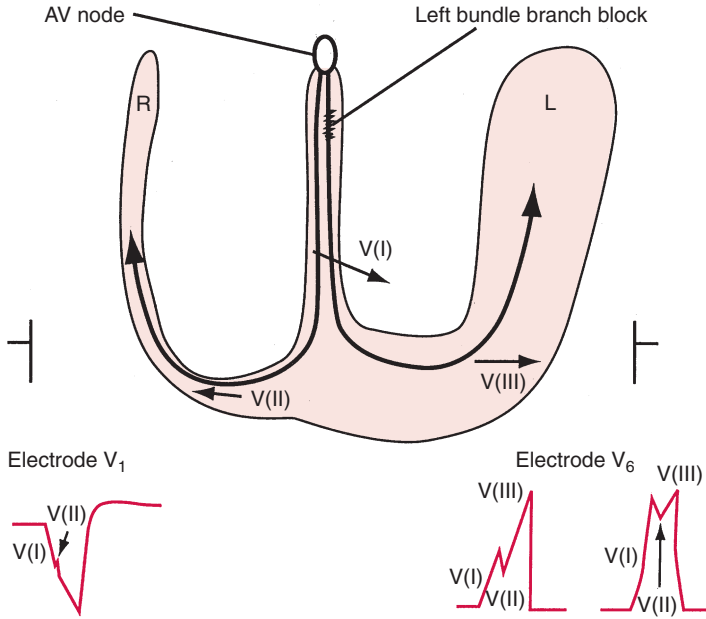


Fig. 4-11. Genesis of the QRS complex in left bundle branch block. AV, atrioventricular. (From Khan, M. Gabriel: *On Call Cardiology*, 2nd ed., Philadelphia, 2001, WB Saunders, Elsevier Science.)

- Vector I flows from right to left through the lower septum rather than from left to right. Thus, an electrode over the left ventricle records an R wave in V_5 , V_6 , and I and a QS or rS in V_1 (see Figs. 4-11, 4-12, and Fig. 2-8B).
- Vector II travels from left to right through the right ventricular mass and may cause a slur or notch in the R wave of leads I, aVL, V_5 , and V_6 [marked V(II) in Fig. 4-11]. The notched R and R' may result in an M-shaped complex in lead I, V_4 , V_5 , or V_6 (see Figs. 4-11 to 4-14).
- Vector III travels right to left and causes an R' in V_6 [marked V(III) in Fig. 4-11].
- The marked derangement in depolarization of the left ventricle causes the ST segment in leads V_1 through V_4 to be abnormally elevated (see Fig. 4-13).
- The direction of the ST segment and T waves is opposite the direction of the terminal QRS (see Figs. 4-11 to 4-13).
- Because LBBB deranges normal vector forces, the diagnosis of left ventricular hypertrophy (LVH) cannot be made in the presence of LBBB. ST elevation, poor R wave progression in V_1 through V_3 , and increased

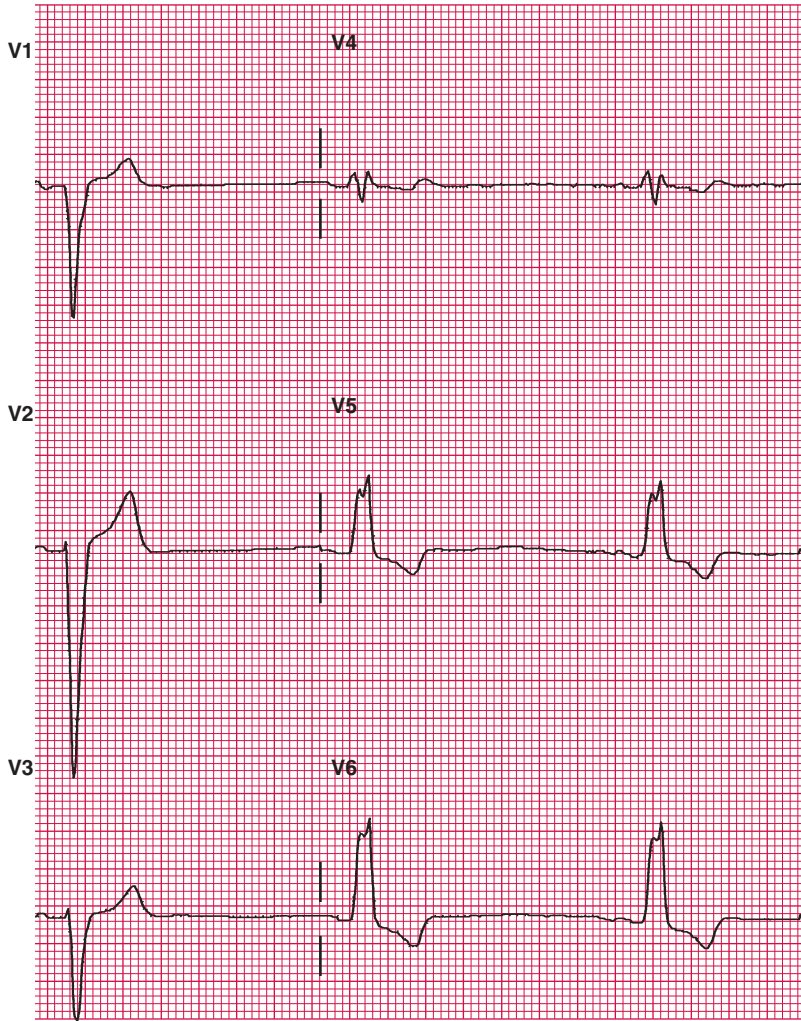


Fig. 4-12. Sinus bradycardia, 40 beats/min; QRS duration >0.12 second. Note the broad, monophasic R wave, notched in V_3 and V_6 , and poor R wave progression in V_2 and V_3 , typical features of left bundle branch block.

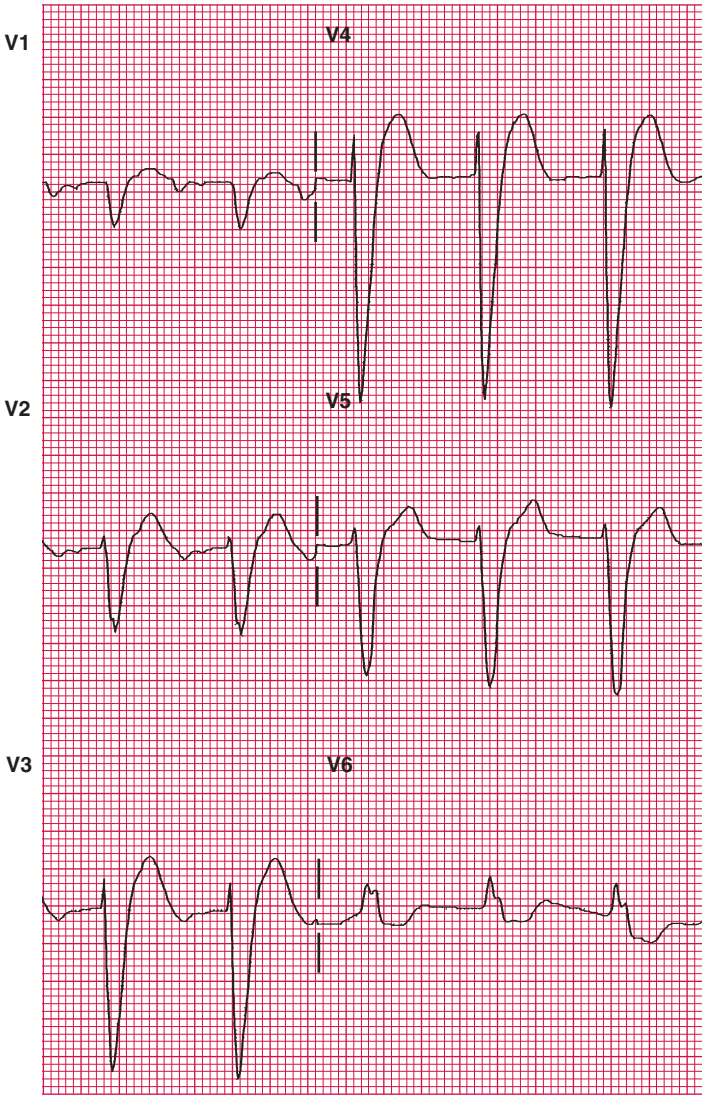


Fig. 4-13. QRS duration ≥ 0.12 second; poor R wave progression; and notched R wave in V₆. Note ST segment elevation in V₁ through V₅, typical of left bundle branch block that mimics anterior myocardial infarction.

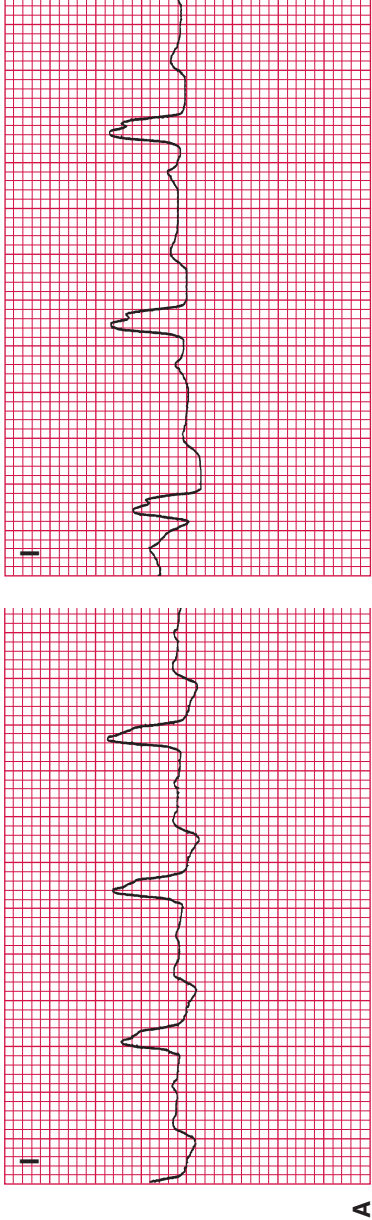
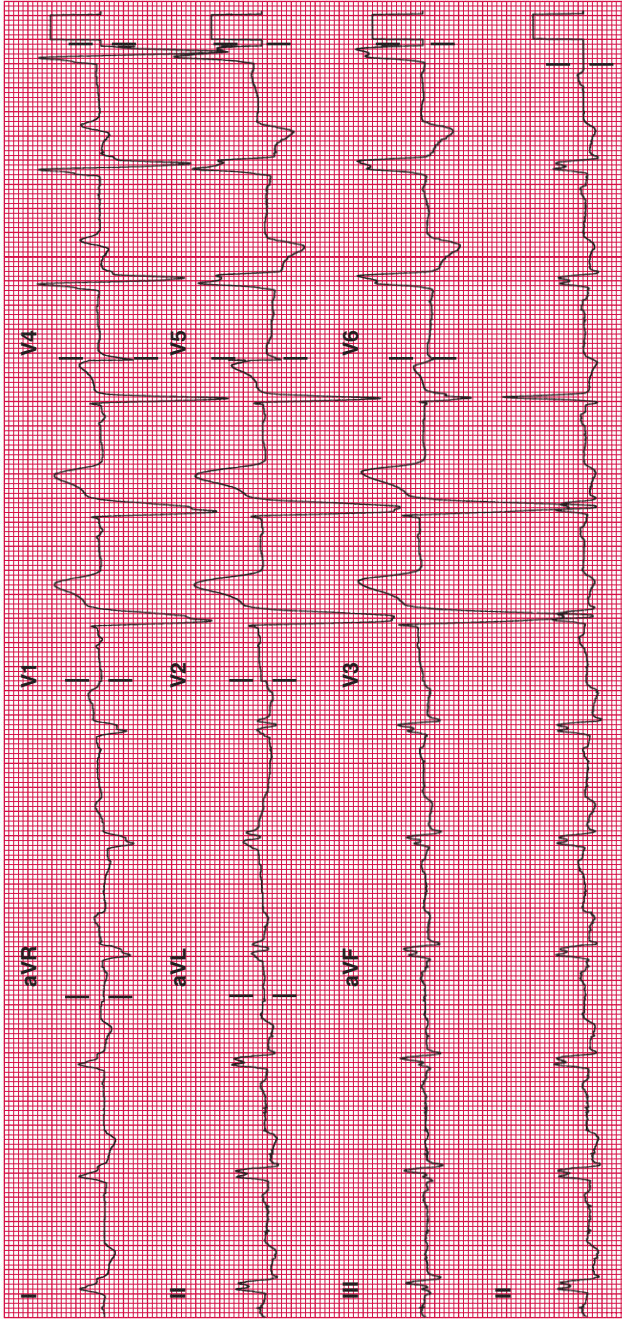


Fig. 4-14. A, Notching in lead I indicates left bundle branch block (two patients).

(continued)



B

Fig. 4-14. Continued **B**, All of the typical electrocardiographic features of LBBB. Note the absence of normal q waves in V₅ and V₆.

voltage are common features of LBBB and do not indicate LVH, myocardial injury, or MI (see Figs. 4-12, 4-13, and Fig. 2-8B and Chapter 6).

Causes of LBBB

- Cardiomyopathies and degenerative diseases.
- Coronary artery disease (CAD); patients with CAD and LBBB have a high incidence of left ventricular dysfunction and congestive heart failure.

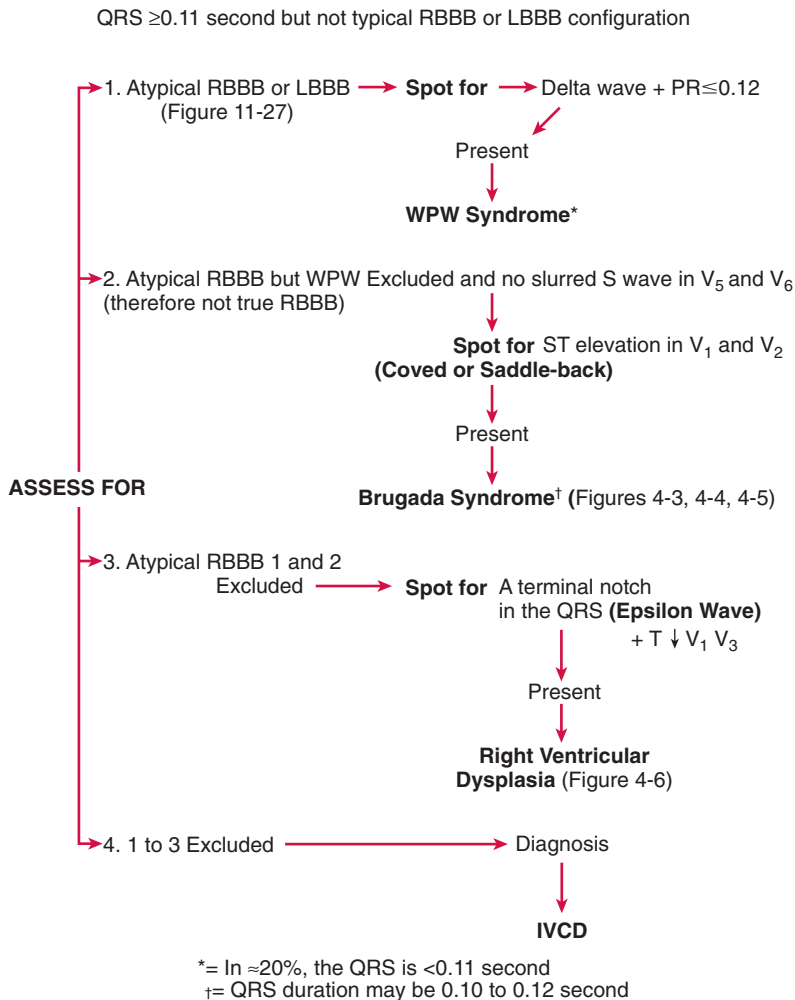


Fig. 4-15. Before making the diagnosis of nonspecific IVCD, consider steps 1, 2, and 3.

- Hypertensive heart disease.
- Advanced valvular heart disease.
- Congenital heart disease.
- Idiopathic in patients with structurally normal hearts. Although LBBB usually occurs in patients with underlying heart disease, the condition may occasionally occur in individuals with structurally normal hearts. These individuals fall primarily into a category of young, healthy adults with idiopathic LBBB or older subjects with primary disease of the conducting system. New LBBB that develops at age 45 or later is likely caused by a significant disease process. In the Framingham study, 55 individuals developed new LBBB at an average age of 62, and coronary heart disease was evident in 89% of these; 50% died within 10 years of onset of LBBB.

Nonspecific Intraventricular Conduction Delay

DIAGNOSTIC CRITERIA

- QRS duration >0.11 with QRS morphology that does not satisfy the criteria for either RBBB or LBBB.
- Figure 4-15 illustrates steps to consider before making the diagnosis of nonspecific IVCD. Notching of a QRS complex with a QRS duration <0.11 should not be classified as nonspecific IVCD.

CAUSES OF IVCD

- Coronary heart disease
- Hypertensive heart disease
- Severe valvular heart disease
- Congenital heart disease
- Cardiomyopathies
- Heart failure (all causes)
- Antiarrhythmic agents
- Tricyclic antidepressants

5

ST Segment Abnormalities

CONTENTS

WHY EMPHASIZE THE ST SEGMENT?

STEP 4

ST ELEVATION MYOCARDIAL INFARCTION
(STEMI)

NON-ST SEGMENT ELEVATION MI

ISCHEMIA

NONSPECIFIC ST CHANGE

The ST segment begins after the final deflection of the QRS complex and ends at the ascending limb of the T wave (*see* Fig. 2-1).

WHY EMPHASIZE THE ST SEGMENT?

Because important cardiac ECG diagnoses are made from observation of abnormalities of the ST segment, the interpreter should rapidly focus on the ST segment. This assessment is Step 4 in the method for accurate ECG interpretation (Fig. 5-1). This step is carried out before the assessment for loss of R waves or for the presence of pathologic Q waves, T wave abnormalities, hypertrophy, and axis determination. The diagnosis of acute MI, ischemia, and pericarditis depends on careful scrutiny of the ST segment.

STEP 4

Assess the ST segment for the following:

- Elevation
- Depression
- Nonspecific changes

The PR segment is usually used to assess the degree of ST segment elevation or depression. The commencement of the ST segment is

From: *Contemporary Cardiology: Rapid ECG Interpretation, 3e*
by: M. Gabriel Khan © Humana Press Inc., Totowa, NJ

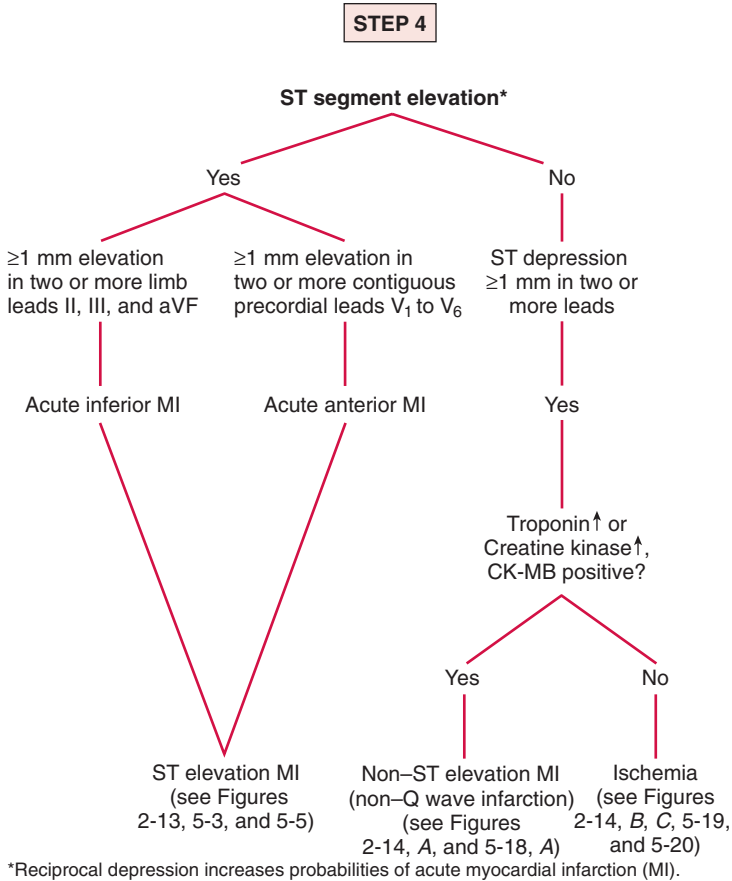


Fig. 5-1. Step-by-step method for accurate ECG interpretation. Step 4: Assess for ST segment elevation or depression. Exclude other causes of ST elevation:

- Normal variant: 1- to 2-mm ST elevation, mainly in leads V₂ through V₄, nonconvex, and with fishhook appearance. Common in African Americans: even 4-mm ST elevation (see Fig. 2-15).
- Coronary artery spasm: ST returns to normal with nitroglycerin or pain relief.
- Left bundle branch block: QRS ≥0.12 second and typical configuration (see Fig. 2-8B and Chapter 4).
- LV aneurysm: known old infarction with old Q waves (see Chapter 6).

usually located at the same horizontal level as the T-P (the isoelectric interval, see Fig. 2-1).

Abnormal ST elevation can be caused by the following:

- Acute MI
- Coronary artery spasm

- Acute pericarditis
- Left ventricular (LV) aneurysm
- Left bundle branch block (LBBB)
- Left ventricular hypertrophy (LVH)

ST ELEVATION MYOCARDIAL INFARCTION (STEMI)

The early diagnosis of acute MI is paramount to successful percutaneous coronary intervention (PCI) or for the timely administration of thrombolytic therapy. This early diagnosis depends on the observation of abnormalities of the ST segment and not on the presence of Q waves or on the results of cardiac enzymes. Reliance on the presence of pathologic Q waves stems from the proven electrocardiographic principles that were used appropriately from 1930 to the late 1980s.

- ST segment depression = ischemia
- ST segment elevation = injury current
- Q waves = necrosis = infarction

With the advent of thrombolytic therapy and PCI, it became necessary to diagnose acute MI within 1 hour of onset of symptoms, and the diagnosis has to be made without reliance on the presence of abnormal Q waves. Most patients with chest pain and abnormal ST segment elevation in two or more contiguous leads develop Q waves from 4 to 24 hours after the onset of symptoms.

Currently, two descriptive terms are used and recognized internationally:

- ST elevation MI (STEMI)
- Non-ST segment elevation MI (probable non-Q wave infarction)

The acute-injury current of infarction elevates the ST segment and deforms its shape. ST segment elevation patterns of infarction and a normal variant are illustrated in Fig. 5-2.

Diagnostic Criteria

Diagnostic criteria for ST elevation MI (probable Q wave infarction) are as follows:

- Abnormal ST elevation of ≥ 1 mm in two or more contiguous limb leads.
- Elevation in leads II, III, and aVF indicates inferior infarction (Figs. 5-3, 5-4, and Fig. 2-13A). ST elevation in leads I, aVL, V₅, and V₆ indicates anterolateral infarction (*see* Fig. 2-18A).

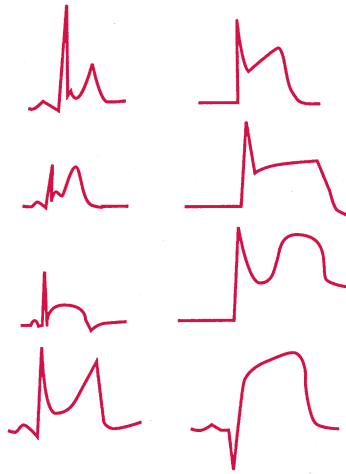


Fig. 5-2. A, ST segment elevation, pattern of normal variant. Note fishhook appearance; the ST segment usually retains the normal concave shape; the T waves are often prominent and peaked. B, Abnormal ST elevation caused by acute myocardial infarction. (From Khan, M. Gabriel: *On Call Cardiology*, 3rd ed., Philadelphia, 2006, WB Saunders, Elsevier Science.)

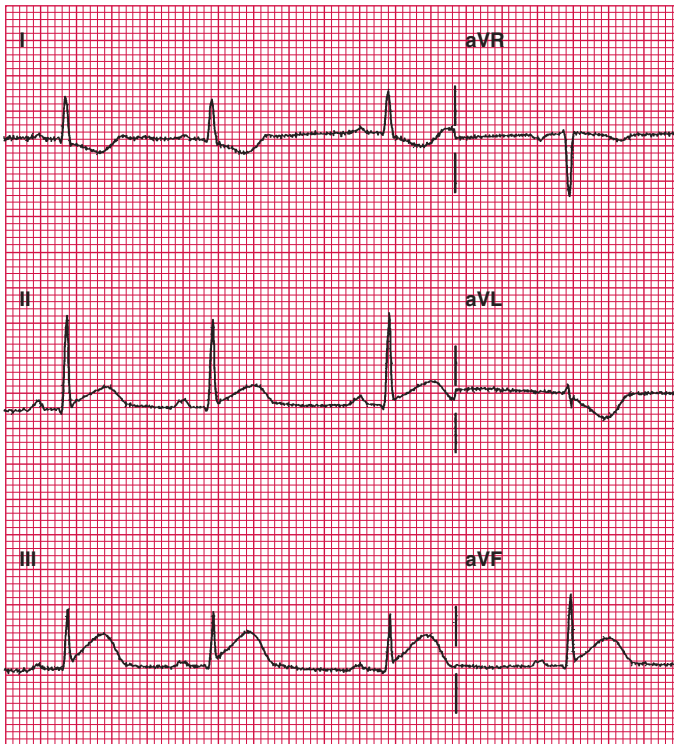


Fig. 5-3. ST segment elevation in leads II, III, and aVF is diagnostic of acute inferior myocardial infarction. Note reciprocal depression in leads I and aVL, which strengthens the diagnosis.

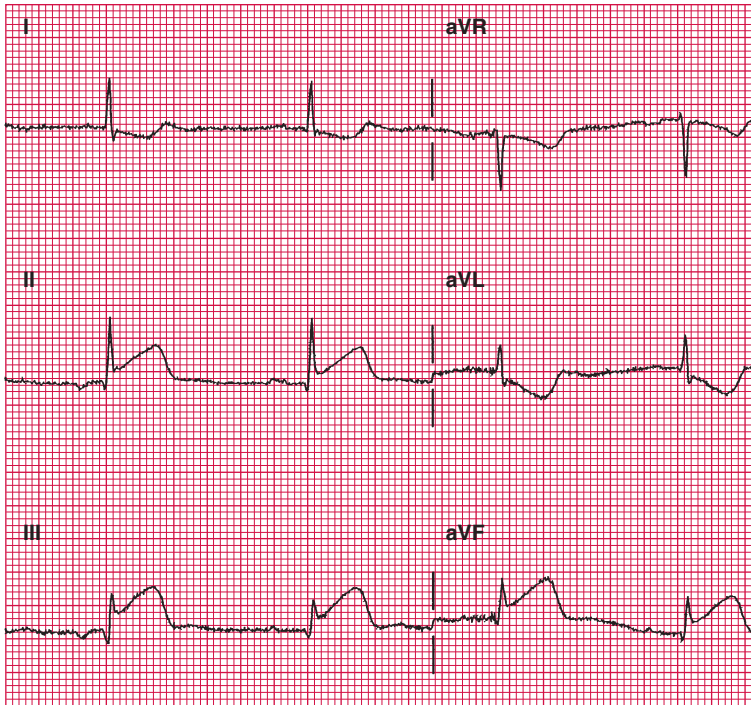


Fig. 5-4. Marked abnormal ST segment elevation in leads II, III, and aVF is diagnostic of acute inferior infarction. Note reciprocal depression in leads I and aVL.

- Abnormal ST elevation of ≥ 1 mm in two or more contiguous precordial leads indicates anterior infarction (*see* Fig. 5-1). ST elevation in V_1 through V_3 indicates anteroseptal infarction or anteroapical MI. Recent studies indicated that the area of necrosis is more likely to be anteroapical rather than anteroseptal (Fig. 5-5). Elevation in V_3 through V_6 (may involve V_2 and V_1) indicates anterior infarction (Fig. 5-6 and Fig. 2-13B).

Extensive anterior infarction is denoted by ST elevation in eight or more leads (Fig. 5-7).

- ST elevation in V_{3R} and V_{4R} associated with inferior infarction indicates added right ventricular infarction (Fig. 5-8). It is advisable to record V_{4R} if the patient with an acute inferior infarct has hemodynamic deterioration.
- Tall R waves in V_1 and V_2 associated with ST elevation in II, III, aVF, or V_{4R} may indicate added posterior infarction. Posterior infarction

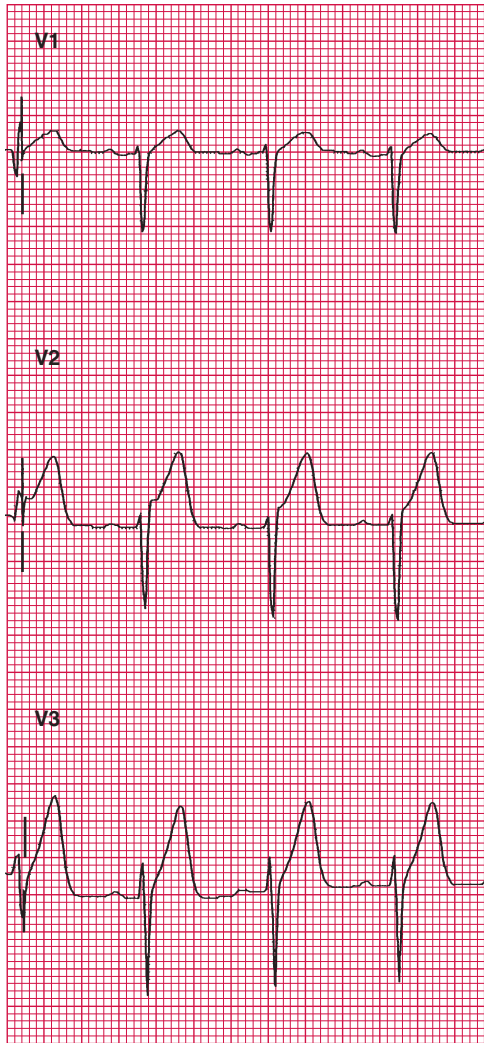


Fig. 5-5. Abnormal ST segment elevation in V₁ through V₃: consider acute antero-septal or anteroapical myocardial infarction (*see* text for discussion of anteroapical MI). This patient's ECG showed reciprocal depression in leads II, III, and aVF, which strengthens the diagnosis of acute infarction.

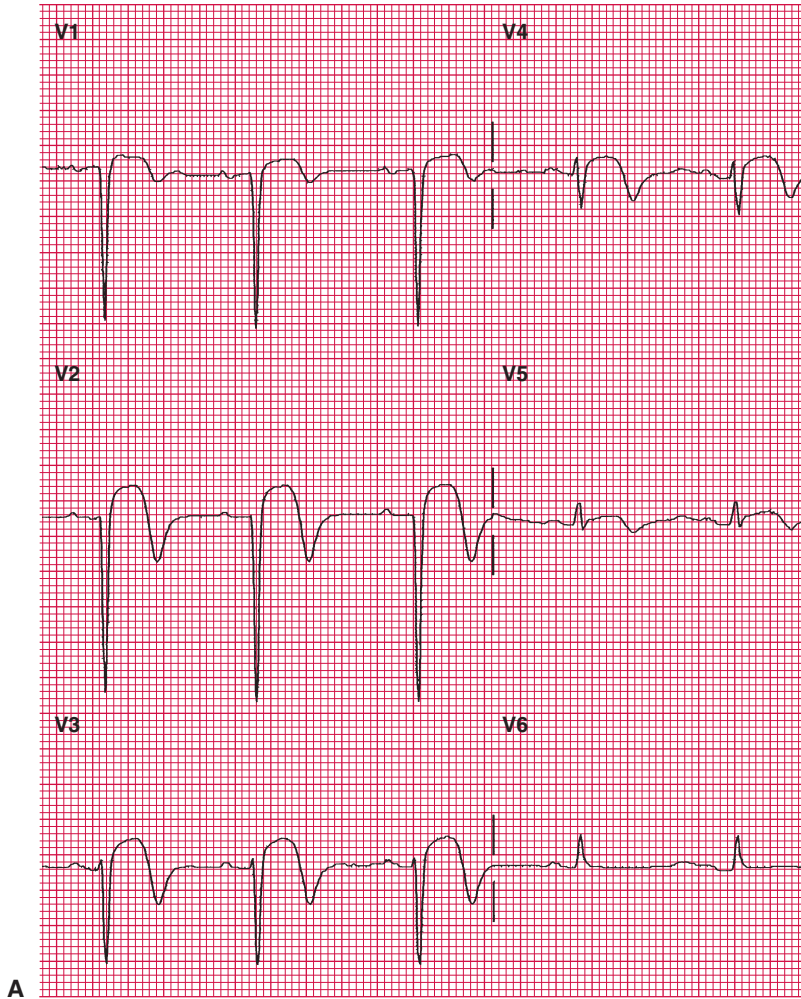


Fig. 5-6. A, ST segment elevation in V_1 through V_5 and poor R wave progression in V_2 through V_4 typical of recent anterior infarction.

(continued)

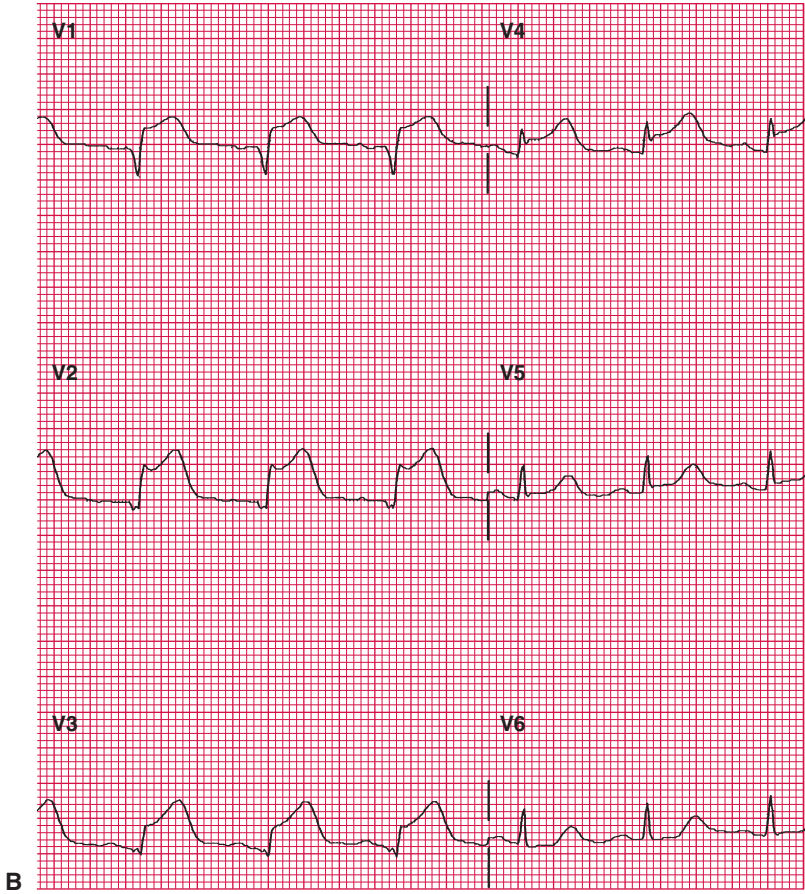


Fig. 5-6. *Continued* B, Variation in shapes of ST elevation.

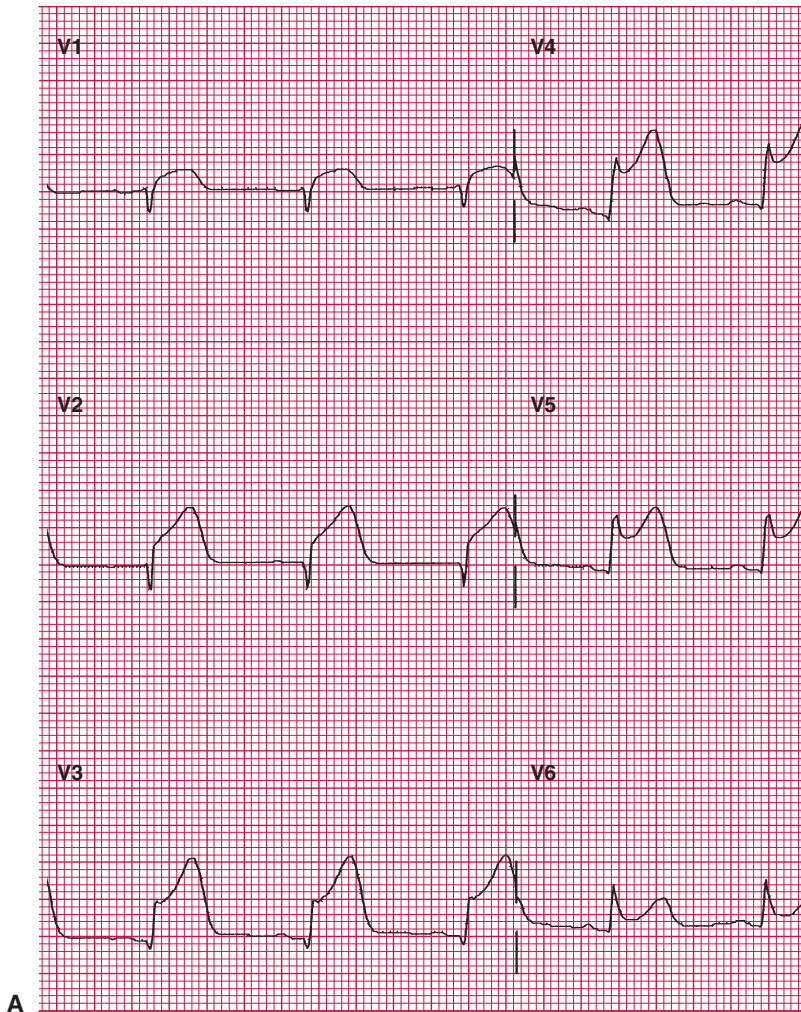


Fig. 5-7. (A) Marked ST segment elevation in eight leads, V₁ through V₆ and leads I and aVL (shown in 7B), indicate extensive anterior MI. The tracing also showed reciprocal depression in the inferior leads. (From Khan, M. Gabriel: *Heart Disease Diagnosis and Therapy*, Baltimore, 1996, Williams & Wilkins.)

(continued)

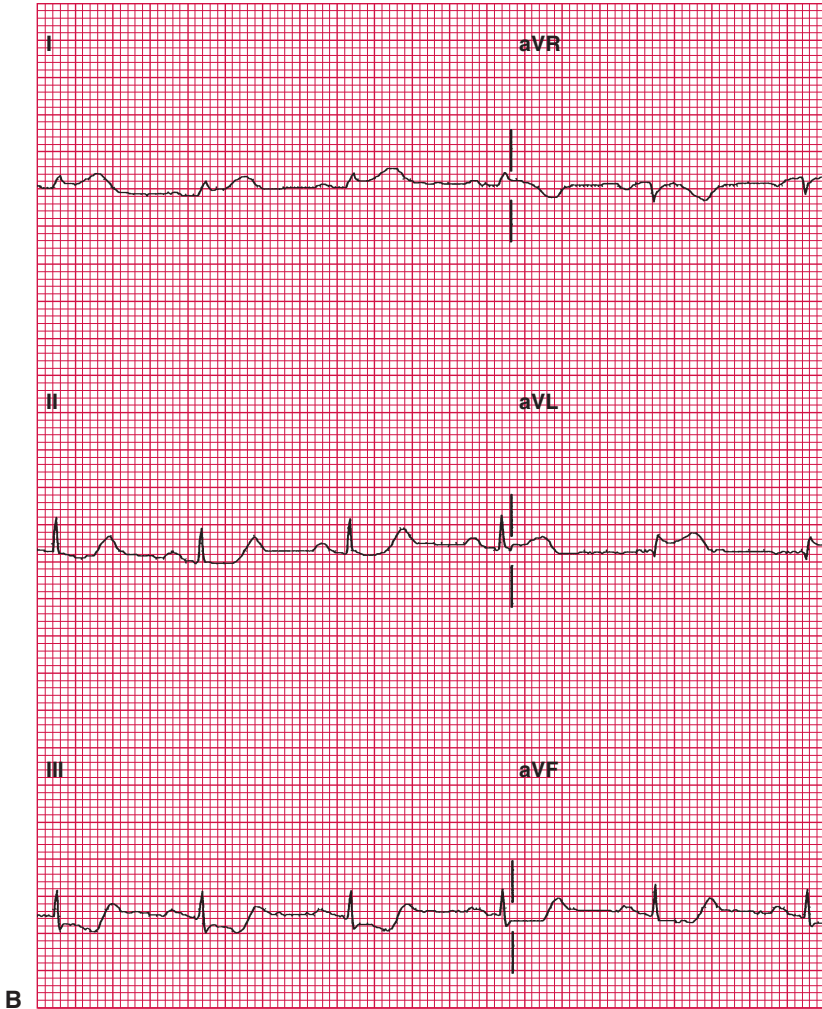
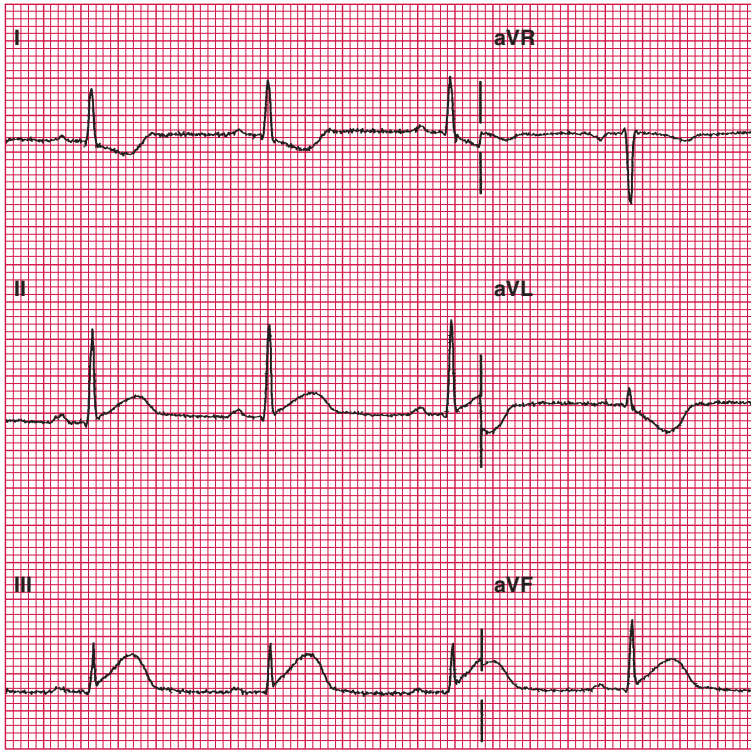
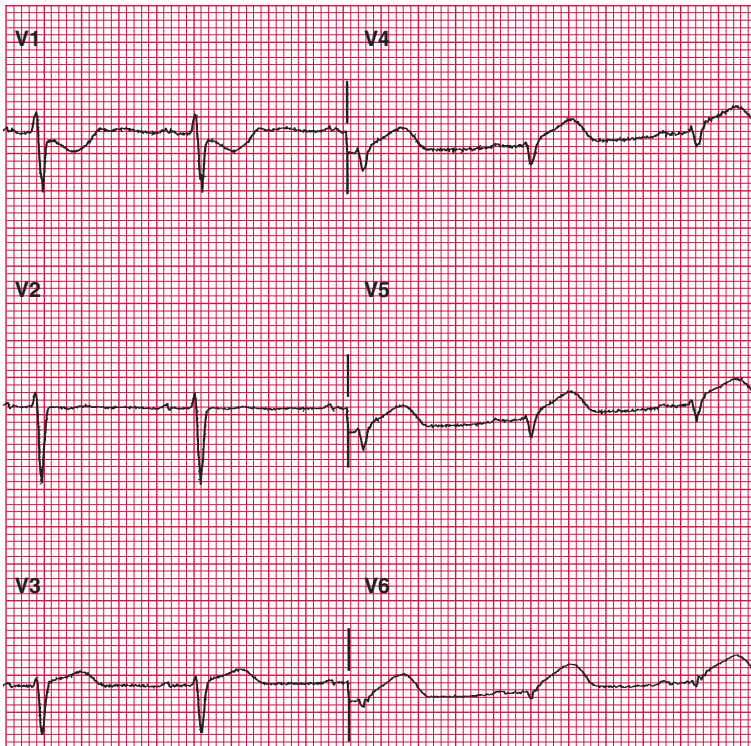


Fig. 5-7. Continued **B.** See legend on page 125. (From Khan, M. Gabriel: *Heart Disease Diagnosis and Therapy*, Baltimore, 1996, Williams & Wilkins.)

Fig. 5-8. **A.** Abnormal ST segment elevation in leads II, III, and aVF indicates recent inferior myocardial infarction. **B.** Same patient as in (A). Leads V₄ through V₆ as labeled were appropriately placed on the right side of the chest: leads V_{4R} and V_{5R} show abnormal ST segment elevation, which indicates acute inferior and right ventricular infarction. This tracing was read incorrectly by the computer and cardiologist as “widespread ST elevation, consider pericarditis; changes in V₄ through V₆ indicate lateral infarction.” (Note: V₄ through V₆ were right-sided chest leads and should have been labeled V_{4R}, 4V_{5R}, and V_{6R}. ST elevation in leads V_{3R} and V_{4R} is the main electrocardiographic feature of right ventricular infarction that may occur in association with inferior MI; see Fig. 6-18.)



A



B

occurs virtually always in association with inferior or right ventricular infarction. Tall R waves in V_1 and V_2 and T wave upright with no other ECG evidence of MI requires cardiac enzyme confirmation.

Other signs that strongly support the diagnosis of acute MI include the following:

- The simultaneous presence of reciprocal depression is not diagnostic for MI but helps confirm the diagnosis. This is of particular diagnostic importance because ST elevation that may occur as a normal variant is not associated with reciprocal ST depression. With acute pericarditis, ST depression occurs only in lead aVR and sometimes in V_1 (see Fig. 2-33, Chapter 10, and further discussion in this chapter).
- Evolving Q waves. Q waves may become fully developed in 2 to 24 hours from onset of symptoms (Figs. 5-9 and 5-10). In many patients with acute ST elevation MI, Q waves may not develop, particularly

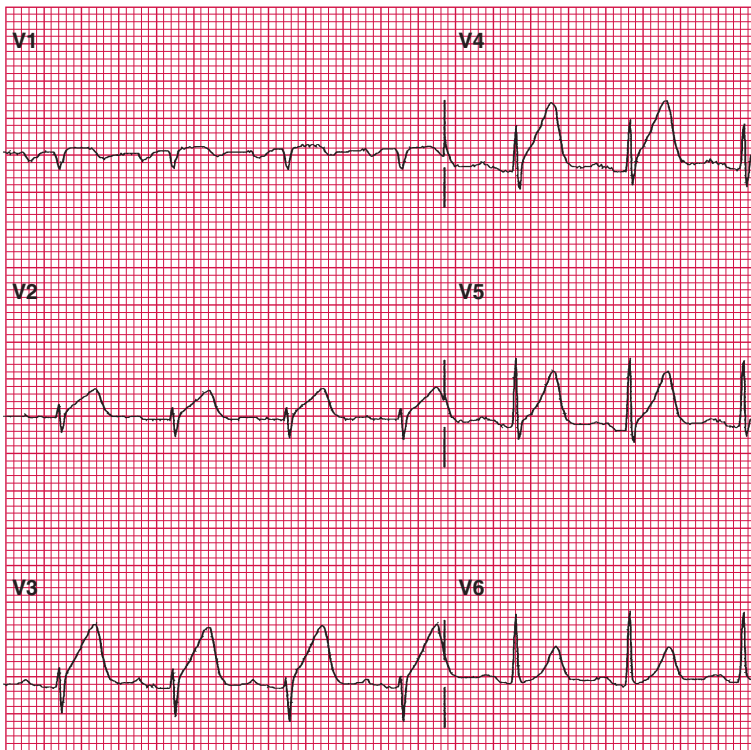


Fig. 5-9. ST segment elevation in V_1 through V_4 indicates acute anteroseptal infarction, anteroapical MI, or anterior MI.

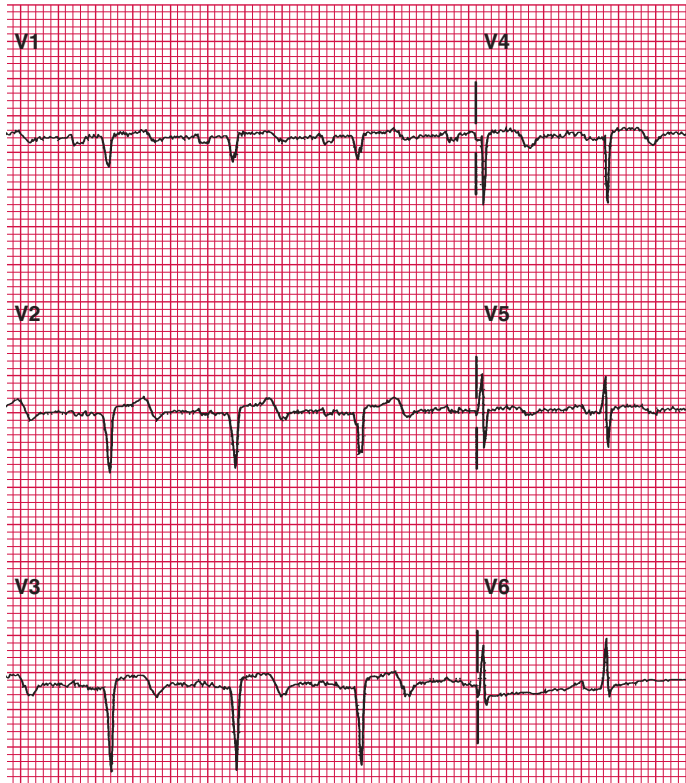


Fig. 5-10. Same patient as in Fig. 5-9. ECG taken 10 hours later shows evolutionary changes: Q waves are present in V₁ through V₄, which indicates anterior infarction; convex ST segment elevation is decreased; and T wave inversion has emerged. (From Khan, M. Gabriel: *Heart Disease Diagnosis and Therapy*, Baltimore, 1996, Williams & Wilkins.)

when thrombolytic agents are used. After 12 hours, Q waves may be smaller or appear in fewer leads, and the reduced R wave amplitude (loss of R) is less pronounced in patients with reperfusion than in those without. Nonetheless, Q wave regression in patients with acute anterior MI who have been administered thrombolytic therapy does not correlate with improvement in left ventricular function and appears to have no prognostic significance.

- Diminution of R waves in V₂ through V₄ (i.e., poor R wave progression), especially if an R wave is present in V₁ or V₂ and disappears or becomes smaller in V₃ or V₄.

- Evolutionary ST-T wave changes that occur during the 10 to 30 hours after the onset of infarction (*see* Fig. 5-10).
- A decrease in ST segment elevation of 2 mm (0.2 mV) or more may be observed within 30 minutes after the beginning of thrombolytic treatment and may continue for 6 hours.

Infarct Size

An approximation of the size of the infarction can be gauged from the extent of ST elevation:

- Small MI: ST elevation in two or three leads
- Moderate MI: four or five leads
- Large MI: six or seven leads
- Extensive MI: eight or nine leads (*see* Fig. 5-7)

Value of Lead aVR in Diagnosis of Acute Myocardial Infarction

- aVR is a lead that is often ignored but recently has gained importance in the diagnosis of left main coronary artery (LMCA) occlusion.
- Figures 5-11 and 5-12 show ST elevation in aVR that is greater than the elevation in V₁, a marker of LMCA obstruction. This criterion is not specific: specificity is 80% and sensitivity is 81%. Circumflex branch occlusion also may cause ST elevation in aVR, but with no elevation in V₁. In addition, right ventricular overload may reveal ST elevation in aVR, but the clinical scenario is easily differentiated. Subendocardial infarction with marked ST segment depression in V₄ through V₆ that is not caused by left main coronary occlusion may reveal ST segment elevation in aVR, but the elevation may be less than that observed in V₁.
- Because LMCA occlusion is a highly serious condition, any noninvasive diagnostic clue represents a valuable addition to the diagnostic armamentarium.

Reciprocal ST segment depression in aVR with PR segment elevation in aVR with reciprocal PR segment depression in other leads is a feature of acute pericarditis (*see* Chapter 10).

Mimics of ST Elevation Infarction

- Normal variants: ST segment elevation is often observed as a normal variant in healthy African Americans, Hispanics, and some other ethnic

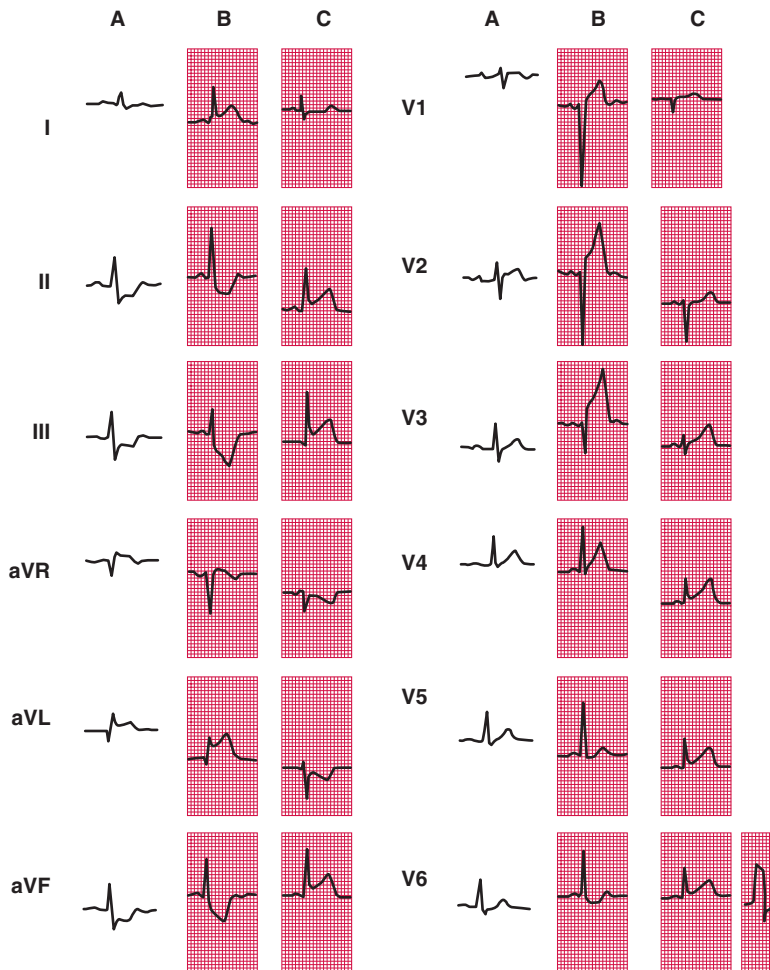


Fig. 5-11. Representative 12-lead ECG tracings at admission in a patient in the left main coronary artery (LMCA) group (A), the left anterior descending coronary artery (LAD) group (B), and the right coronary artery (RCA) group (C). In the patient in the LMCA group, ST segment elevation is apparent in lead aVR. In the patient in the LAD group, significant ST segment elevation in the precordial leads is seen, whereas ST segment shift in lead aVR is negligible. In the patient in the RCA group, ST segment elevation in the inferior leads is marked. (From Yamaji H et al.: *J Am Coll Cardiol* 38:1351, 2001.)

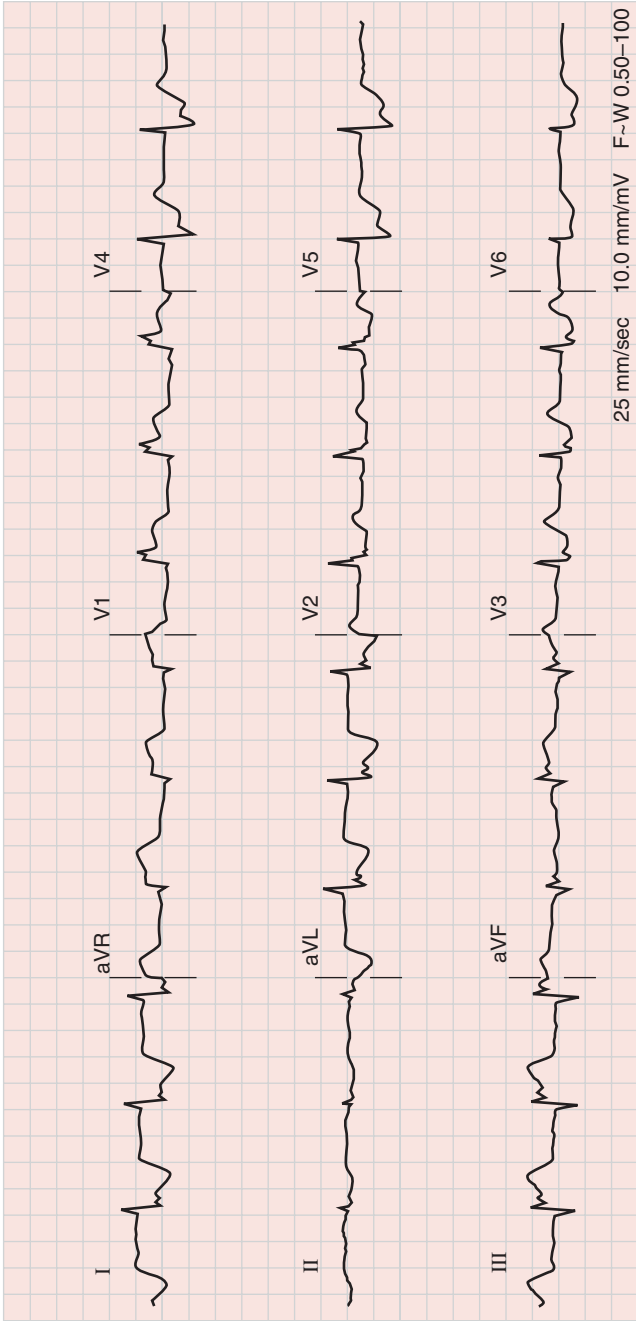


Fig. 5-12. Patient with chest pain for 3 hours. Inferior myocardial infarction and ST elevation in aVR and V₁. Left main occlusion.

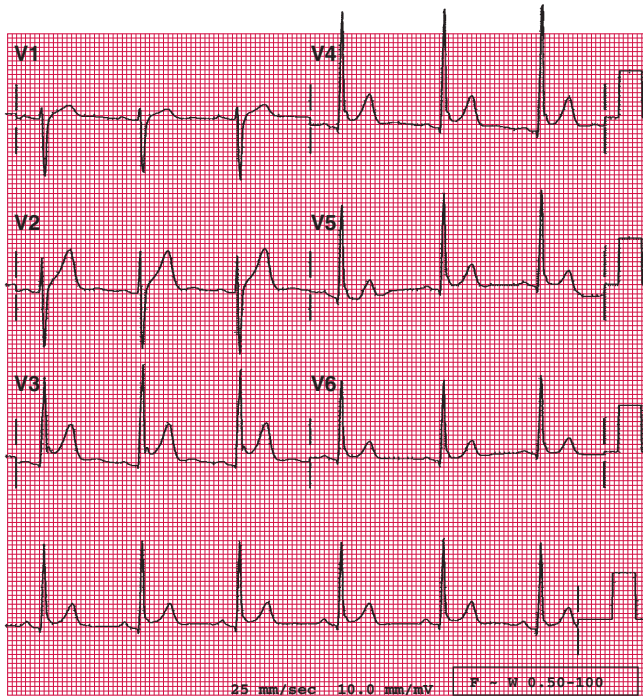


Fig. 5-13. ST segment elevation in a normal 25-year-old: normal variant. Note the notched J-point, fishhook appearance in lead V₃. (From Khan, M. Gabriel: *On Call Cardiology*, 3rd ed., Philadelphia, 2006, WB Saunders, Elsevier Science.)

groups. The ST elevation commonly seen in V₂ through V₅ often shows a notched J-point, fishhook appearance. This normal variant is inappropriately termed early repolarization changes. ST elevation may occur in leads II, III, and aVF, but reciprocal depression does not occur. The degree of ST elevation is variable, often 1 to 4 mm; the normal concave shape remains, but it may end in a prominent, peaked T wave (see Figs. 5-2, 5-13, and Fig. 2-15). Occasionally, ST elevation with T wave inversion is observed in one or two precordial leads in healthy athletes (Fig. 5-14).

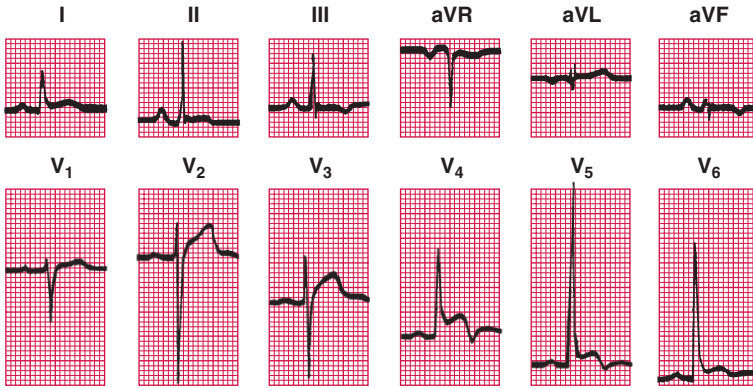


Fig. 5-14. Benign ST and T wave changes in a healthy 24-year-old professional athlete. The changes, especially in V_4 and V_5 , mimic myocardial injury and ischemia and remained the same 15 months later. (From Chou TC: *Electrocardiography in Clinical Practice*, 4th ed., Philadelphia, 1996, WB Saunders, Elsevier Science.)

- Acute pericarditis causes diffuse ST segment elevation that is not confined to an anatomic coronary blood supply; thus ST elevation is observed in leads I through III, lead aVF, and most precordial leads. The ST segment retains a normal concave shape. Reciprocal depression may be observed in aVR and sometimes in V_1 (see Fig. 2-33 and discussion under “Pericarditis” in Chapter 10).
- MI age indeterminate (see Fig. 2-18B) in the absence of LV aneurysm may exhibit mild ST elevation, and the differentiation from acute infarction requires clinical correlation and comparison with previous ECGs.
- Coronary artery spasm, Prinzmetal angina, causes ST elevation during the brief period of chest pain (Fig. 5-15).
- LV aneurysm: ST elevation can persist 3 days to 4 weeks after acute infarction; persistence beyond 4 weeks suggests LV aneurysm (Figs. 5-16 and 5-17).

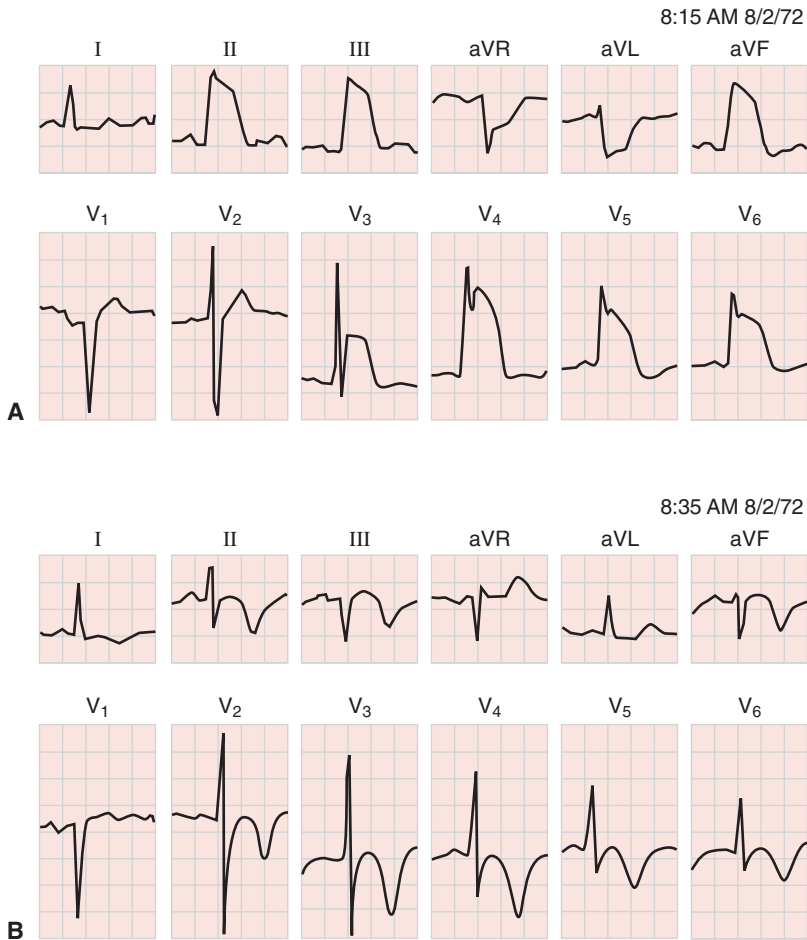


Fig. 5-15. Variant angina. The patient had severe coronary artery disease involving all three major vessels, especially the anterior descending branch, as demonstrated by coronary arteriogram. **A**, Tracing recorded during angina at rest. **B**, Tracing recorded 20 minutes later, after the pain had subsided. The latter tracing is representative of the patient's baseline ECG. During angina (**A**), marked ST segment elevation is present in leads II, III, aVF, and V₃ through V₆, with reciprocal ST segment depression in leads aVR and aVL. There is also an increase of the amplitude of the R wave in leads II, III, and aVF, with the disappearance of the S waves in leads showing significant ST segment elevation. The resulting complexes resemble the monophasic transmembrane potential. Many similar episodes were observed in this patient. (From Chou TC: *Electrocardiography in Clinical Practice*, 4th ed., Philadelphia, 1996, WB Saunders, Elsevier Science.)

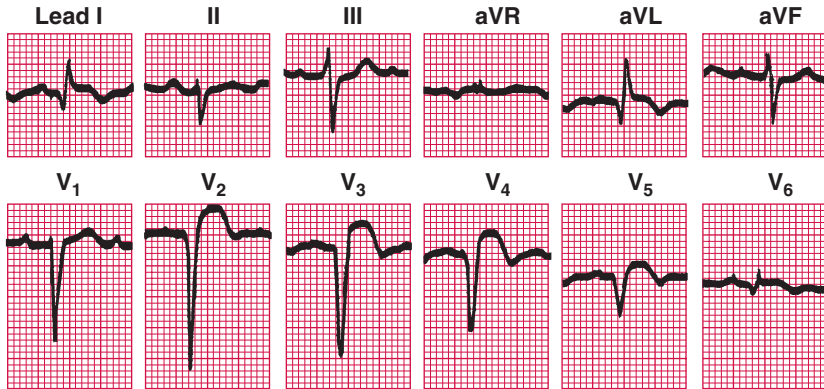


Fig. 5-16. Ventricular aneurysm. The patient is a 52-year-old man who had an acute extensive anterior myocardial infarction 5 months before the recording of this ECG. Note the persistent ST segment elevation in the precordial leads and in leads I and aVL. Left anterior hemiblock also is present. (From Chou TC: *Electrocardiography in Clinical Practice*, 4th ed., Philadelphia, 1996, WB Saunders, Elsevier Science.)

- LBBB nearly always causes abnormal ST elevation in leads V₁ through V₄ and can mimic acute or old infarction (*see* Fig. 4-13).
- LVH may cause poor R wave progression in V₁ through V₃, and occasionally ST elevation is observed (*see* Figs. 2-23 and 2-25).
- Hypertrophic cardiomyopathy causes Q waves, but, occasionally, persistent ST segment elevation is present (*see* Chapter 6).
- Acute myocarditis in persons with acquired immunodeficiency syndrome may cause nonspecific ST-T changes; ST elevation and Q waves may occur (*see* Chapter 6).
- Cocaine abuse may cause ST elevation and, in some individuals, frank infarction (*see* Chapter 6).
- Pulmonary embolism may cause ST elevation, albeit rarely (*see* Chapter 10 and Fig. 10-20).

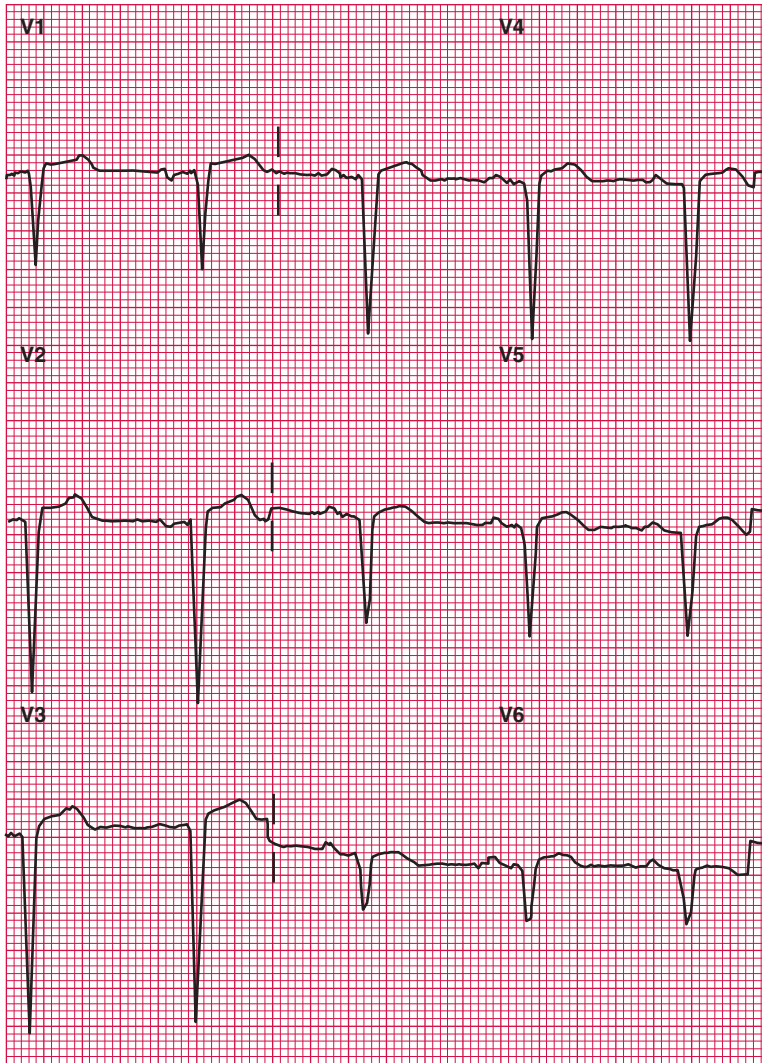


Fig. 5-17. V leads of a patient who sustained an anterior infarction 6 months earlier. Pathologic Q waves are present from V₁ through V₆, and the ST segment is elevated in V₁ through V₅. The tracing is in keeping with an old anterior myocardial infarction with left ventricular aneurysm.

NON-ST SEGMENT ELEVATION MI

- ST segment depression ≥ 1 mm in two or more leads in a patient with chest discomfort and an abnormal troponin or CK-MB is diagnostic of non-ST segment elevation MI (non-Q wave MI) (see Fig. 5-18 and Fig. 2-14A).

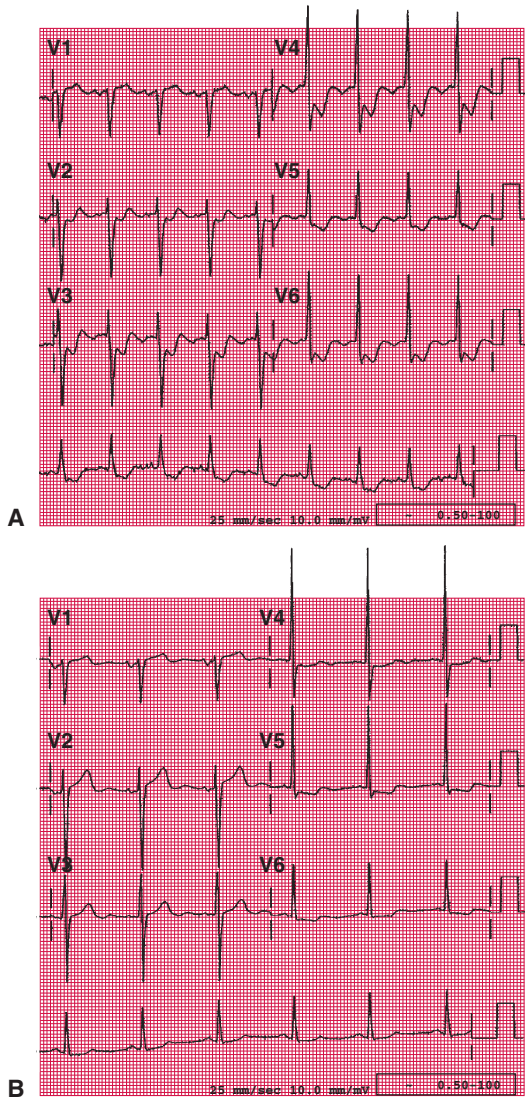


Fig. 5-18. A, Non-Q wave infarction (acute subendocardial infarction) in a patient with a clinical picture of infarction and elevated CK-MB. Note widespread ST-T depression in the limb and chest leads but no associated Q waves. B, The same patient's ECG tracing 18 hours earlier than depicted in (A). (From Khan, M. Gabriel: *On Call Cardiology*, 3rd ed., Philadelphia, 2006, WB Saunders, Elsevier Science.)

- Transient ST segment changes >0.05 mm (mV), associated with angina at rest and positive troponin or CK-MB indicate non-ST segment elevation MI. In patients with negative cardiac enzymes within 6 hours of onset of pain, another sample should be drawn between 6 and 12 hours. Patients with acute coronary syndrome, particularly those with rest pain ≥ 20 minutes accompanied by ECG changes are further risk-stratified depending on troponin levels as follows:
 1. High risk: troponins (TnT or TnI) >0.1 ng/mL (elevated troponin levels indicate myocardial necrosis, MI).
 2. Intermediate risk: troponin slightly elevated >0.01 but <0.1 ng/mL.
 3. Low risk: troponin normal.

ISCHEMIA

ST segment depression indicative of definite myocardial ischemia should fulfill the following criteria:

- Greater than 1 mm depression.
- Present in two or more leads.
- Present in two or more consecutive QRS complexes.
- Flat (horizontal) or down-sloping with or without T wave inversion (these patterns of ischemia are all shown in Figs. 5-19, 5-20, and Fig. 2-14B).
- Abnormal convex coving of the ST segment in V_1 through V_3 or V_2 through V_4 associated with T wave inversion.

The terminal portion of the abnormal ST segment may show a typical hitched-up pattern (Fig. 5-21); this pattern is often caused by a tight obstruction in the proximal left anterior descending artery.

NONSPECIFIC ST CHANGE

Minor ST segment depression ≤ 1 mm is not an uncommon finding in normal individuals. Consider ST segment changes to be nonspecific if the following prevails:

- ST depression ≤ 1 mm in the absence of typical symptoms of unstable angina, including rest pain ≥ 20 minutes (Fig. 5-22)
- Accompanied by baseline drift
- With or without T wave inversion
- Commonly associated with low, flat, or slightly inverted T waves

T waves normally should be ≥ 0.5 mm in height in leads I and II (*see* “T Waves” in Chapter 8). Figure 5-23 depicts nonspecific ST-T changes.

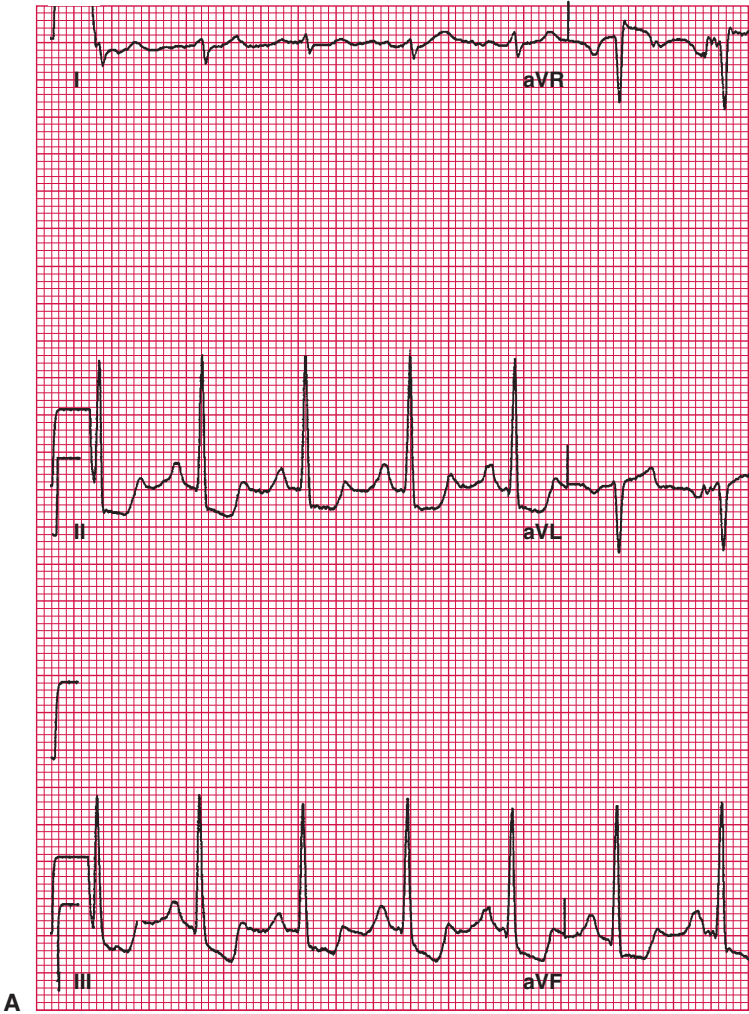

Fig. 5-19. Flat (horizontal) and down-sloping ST segment depression greater than 1 mm in a patient with proven angina and obstructive coronary artery disease. A, Limb leads.

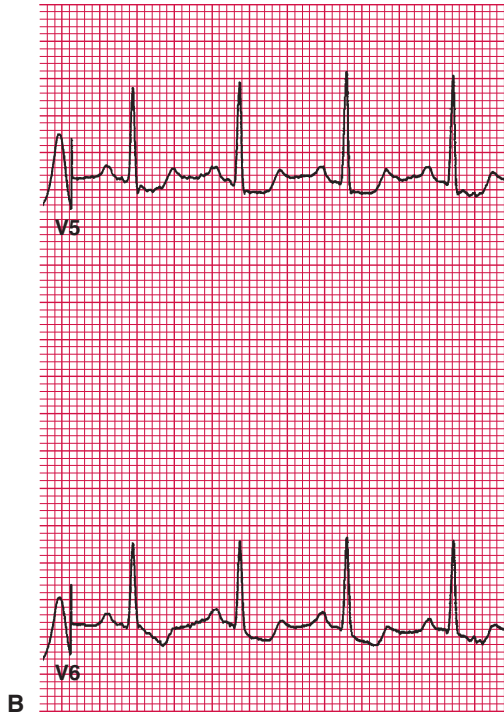

Fig. 5-19. B, Leads V₅ and V₆.

Causes of Nonspecific ST-T Wave Changes

Nonspecific ST-T wave changes can be caused by a number of conditions, such as the following:

- Improper electrode contact
- Ischemia (must be considered; the ECG must be interpreted in regard to the clinical findings)
- Electrolyte abnormalities
- Arrhythmias
- Myocarditis
- Pericarditis, constrictive pericarditis
- Intraventricular conduction defects
- Cardiomyopathy
- Pulmonary embolism

(text continues on pg. 135)

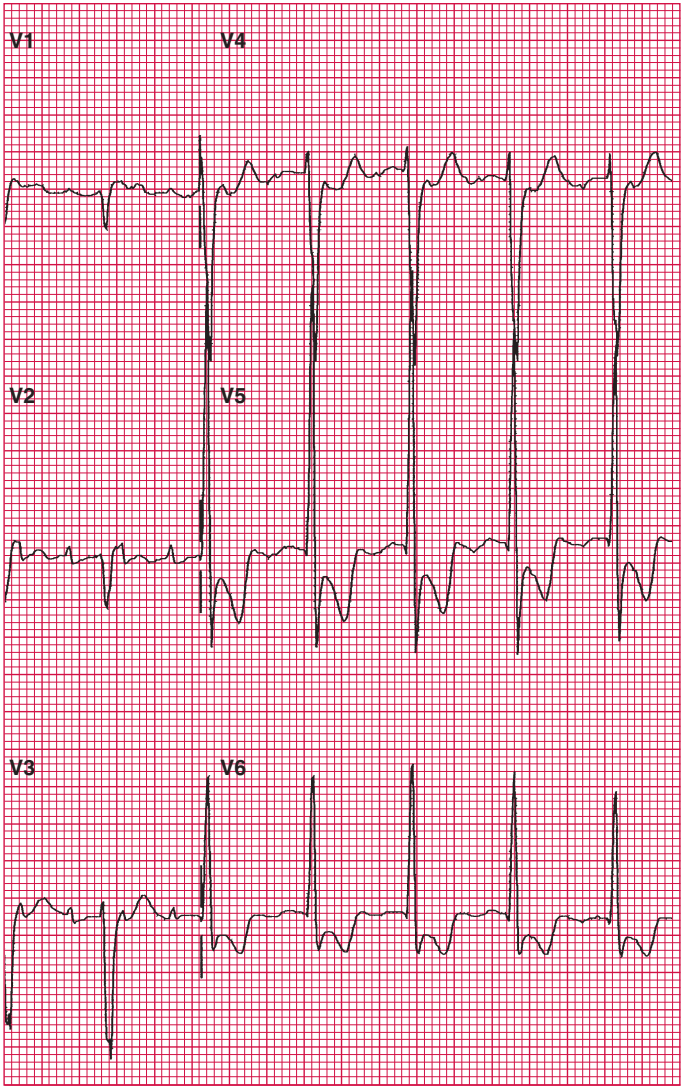


Fig. 5-20. V leads of a patient with severe angina and left ventricular hypertrophy. Note increased voltage and marked ST segment depression in V₄ through V₆.

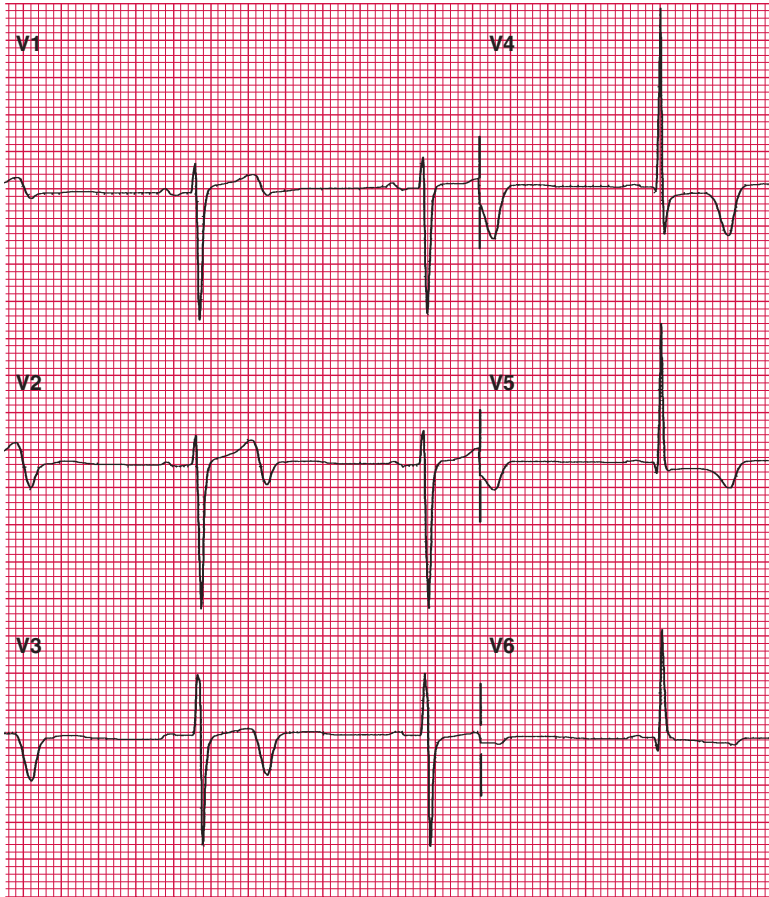


Fig. 5-21. V leads in a patient with unstable angina. ST-T segment abnormalities seen in V₁ through V₄. The tracing was taken when the patient was pain free. Note the “hitched up” ST segment in V₂ and V₃ with deep T inversion: The pattern is typical of significant proximal left anterior descending coronary artery stenosis.

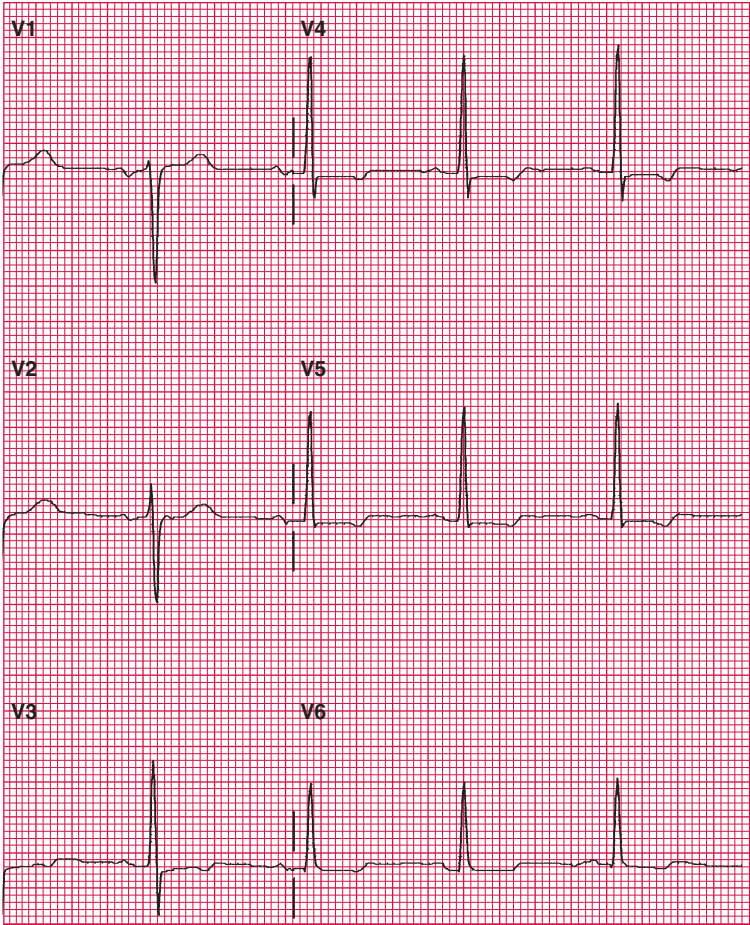


Fig. 5-22. V leads in a patient with no history of heart disease. ST segment is flat in V₄ through V₆ with minimal T wave inversion; similar findings were observed in leads I and aVL: The anterolateral ST-T wave abnormalities are nonspecific; note that ischemia cannot be excluded. Abnormal ECG.

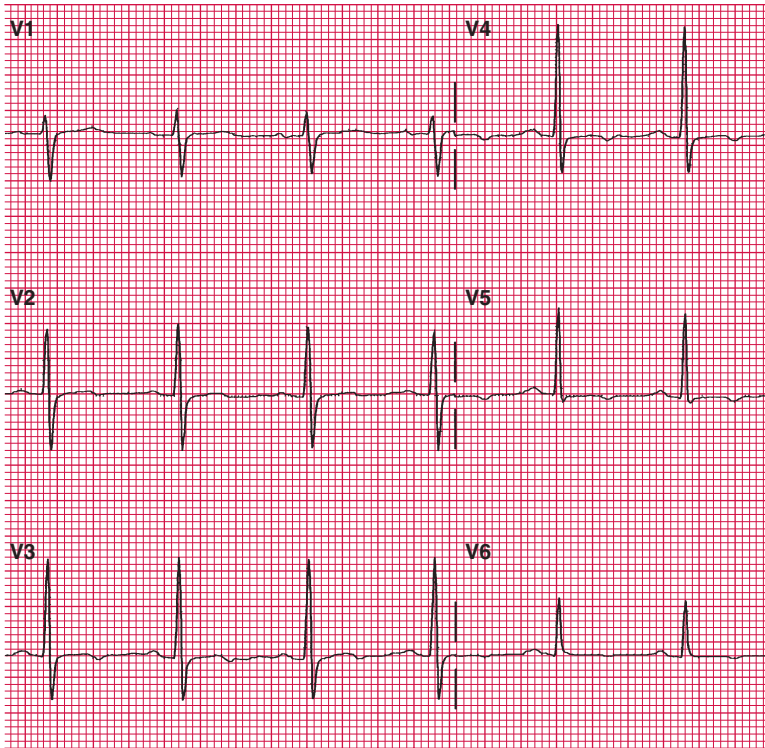


Fig. 5-23. The ST segment is borderline flat but not depressed and is associated with minimal T wave inversion in leads V₃ through V₆; similar findings were present in leads I and aVL: nonspecific ST-T wave changes. Borderline ECG.

- Drink of cold water
- Hyperventilation
- Drug use, including ethanol abuse
- Digoxin
- Subarachnoid hemorrhage or cerebral hemorrhage (*see* Fig. 8-14)

6

Q Wave Abnormalities

CONTENTS

CRITERIA FOR NORMAL AND ABNORMAL Q WAVES
Q WAVE MYOCARDIAL INFARCTION
MIMICS OF Q WAVE MYOCARDIAL INFARCTION
LEFT BUNDLE BRANCH BLOCK AND INFARCTION
RIGHT BUNDLE BRANCH BLOCK AND INFARCTION
LOW-VOLTAGE QRS

CRITERIA FOR NORMAL AND ABNORMAL Q WAVES

The QRS complex should be assessed for the presence of normal and abnormal Q waves and for normal or abnormal R wave progression as outlined in Step 5 of the method for accurate ECG interpretation (Fig. 6-1).

The assessment of pathologic Q or normal q waves should take into account the following:

- Their width
- Their depth
- The leads in which they are observed
- The age of the individual
- Relevant clinical findings

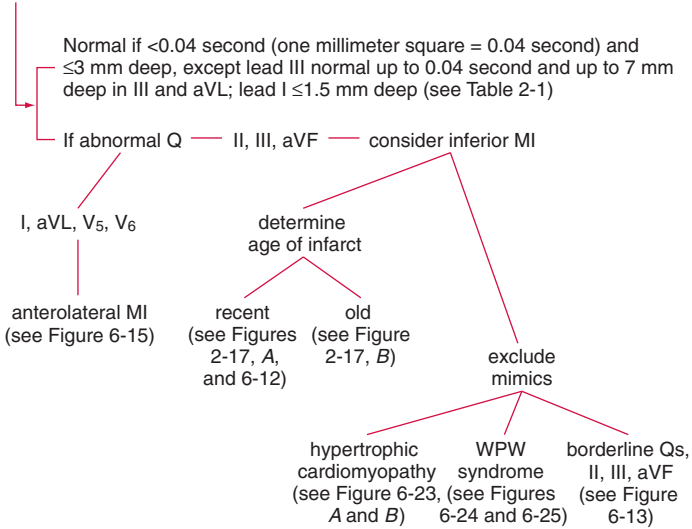
Normal Parameters

- In general, a Q wave that is wider than 0.03 second is considered abnormal, except in leads III, aVR, and V₁, in which Q waves may be wide and deep in normal individuals (*see* Fig. 6-2A and Table 2-1).
- Lead aVR normally records a negative QRS, QS, or QR complex (*see* Fig. 6-2 and Fig. 2-2).
- Normal QS complexes occasionally are found in leads III and V₁ and rarely in V₂.

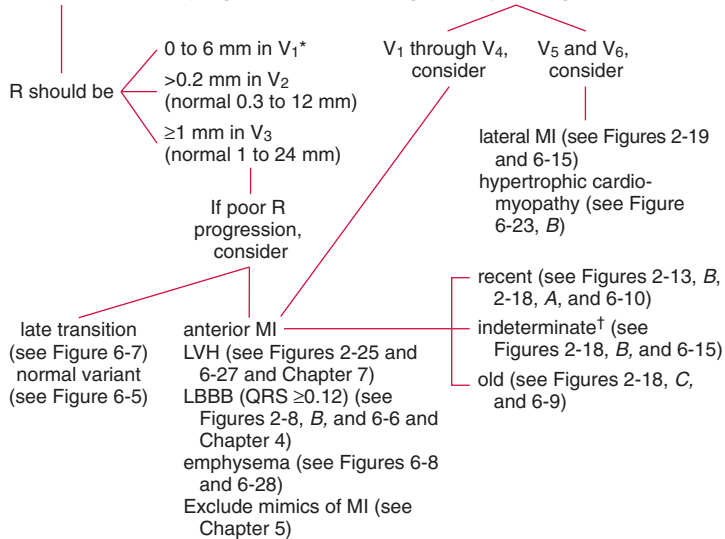
From: *Contemporary Cardiology: Rapid ECG Interpretation, 3e*
by: M. Gabriel Khan © Humana Press Inc., Totowa, NJ

STEP 5

a. Assess for Q waves, leads I, II, III, aVF, and aVL.



b. Assess for R wave progression in V₁ through V₆ or pathologic Q waves.



*Age >30 ; see text and Table 2-1 for exceptions and normal parameters.

[†]Compare old ECGs.

Fig. 6-1. Step-by-step method for accurate ECG interpretation. Step 5: Assess for Q waves and R wave progression.

- A narrow Q wave may occur as a normal finding in lead III; this should be ≤ 0.04 second in duration (1 square), < 10 mm deep, and not accompanied by abnormal Q waves in leads II and aVF (see Fig. 6-2 and Fig. 2-2D). The depth of the Q wave is not as important as the width.
- Lead aVL may record a Q wave < 0.04 second and up to 7 mm deep in individuals older than age 30 years and up to 10 mm deep in children.

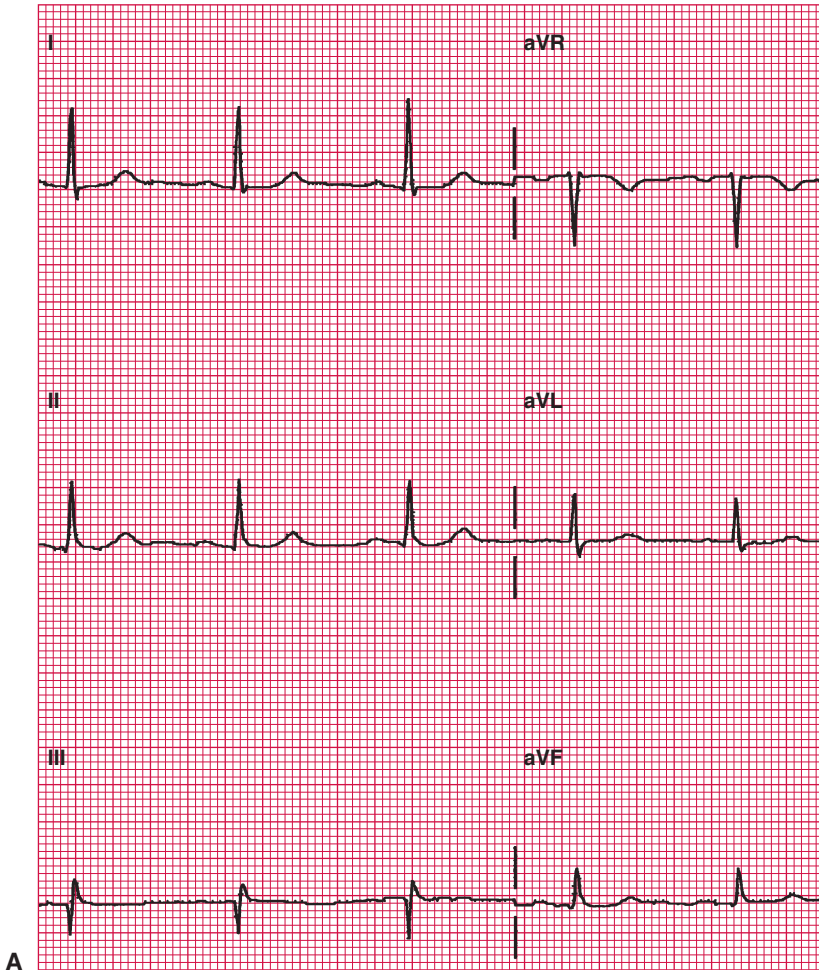


Fig. 6-2. A, Isolated, deep, narrow Q wave in lead III is ≤ 0.04 second as part of a normal ECG. Note the absence of abnormal Q waves in leads II and aVF. B, Note small, normal q waves < 0.04 second and < 2 mm deep in duration in leads II and aVF. Normal ECG.

(continued)

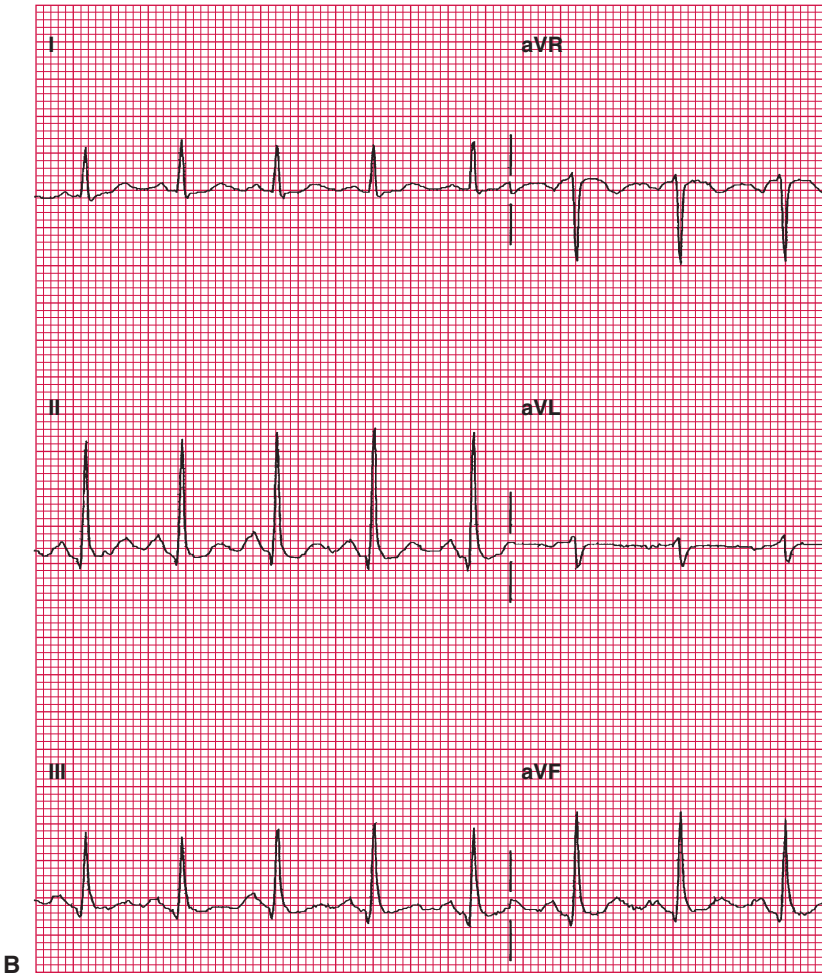


Fig. 6-2. *Continued*

A negative P wave followed by a QS or QR deflection with a negative T wave may be recorded in a normal vertical heart.

- In leads II and aVF, small, narrow Q waves may occur but should be ≤ 0.03 second in duration and < 4 mm deep (*see* Fig. 6-2). Occasionally, the Q in leads II, III, and aVF are borderline width and the ECG is interpreted as follows: inferior Qs noted; clinical correlation required; borderline ECG.
- In lead I, the depth of a Q wave should not exceed 1.5 mm in adults older than age 30 years (*see* Fig. 6-2A).

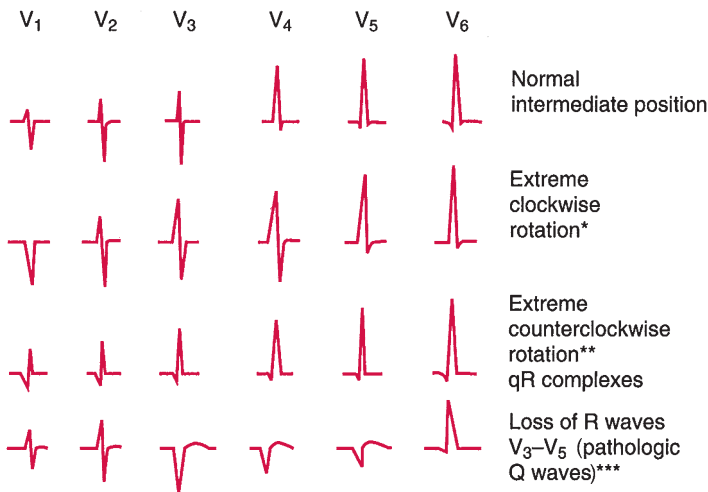
- A small q wave in $V_6 \leq 0.03$ second is present in more than 75% of normal individuals. In leads V_5 and V_6 and rarely in V_4 , normal q waves ≤ 0.03 second and < 3 mm deep may occur (Fig. 6-3). Normal Q waves should be < 3 mm in adults older than age 40 years; they should not exceed a depth of 4 mm in those younger than age 30 years. Rarely, an amplitude > 4 mm may be seen in healthy teenagers.
- In contrast, Figure 6-23B shows abnormal Q waves in V_4 through V_6 ; they are 0.04 second wide and 3 mm deep in a 52-year-old woman with

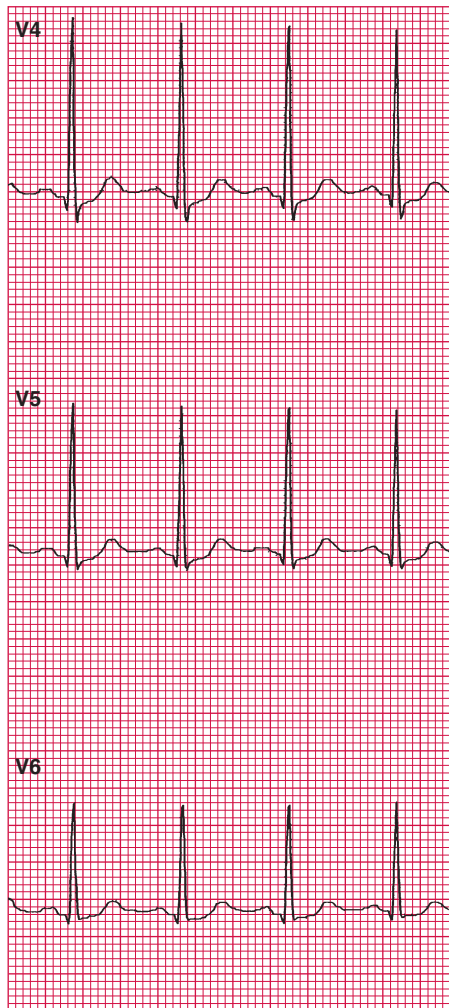

Fig. 6-3. Normal q wave in V_4 through $V_6 \leq 0.03$ second, < 4 mm deep.

proven hypertrophic cardiomyopathy. Small Q waves may occur in V_2 through V_6 with extreme counterclockwise rotation (Fig. 6-4).

- A Q wave of less than 0.03 second and greater than 2 mm deep in V_2 through V_4 is abnormal if V_1 shows an initial R and there is no significant shift of the transitional zone to the left or right.
- Poor R wave progression may simulate infarction patterns (pseudoinfarction).
- Poor R wave progression in V_2 through V_4 with minute R waves may mimic QS complexes and lead to incorrect diagnoses and uncertainties for cardiologists, the attending physician trainee, or the family physician. Causes of poor R wave progression include the following:
 - In women, and rarely in men younger than age 30 years, minute R waves may be present in leads V_1 , V_2 , and sometimes, V_3 ; this poor R wave progression is not uncommon and may lead to an erroneous diagnosis of anteroseptal infarction (Fig. 6-5).



* = with clockwise rotation, the V_1 electrode, like aVR, faces the cavity of the heart and records a QS complex; no initial q in lead V_6 .

** = qR complexes; q < 0.04 second, < 3 mm deep; therefore not pathologic Q waves.

*** = loss of R wave in V_3 through V_5 (pathologic Q waves): signifies anterior MI.

Fig. 6-4. Variations in normal QRS configuration and correlation with abnormalities. (From Khan, M. Gabriel: *On Call Cardiology*, 3rd ed., Philadelphia, 2006, WB Saunders, Elsevier Science.)

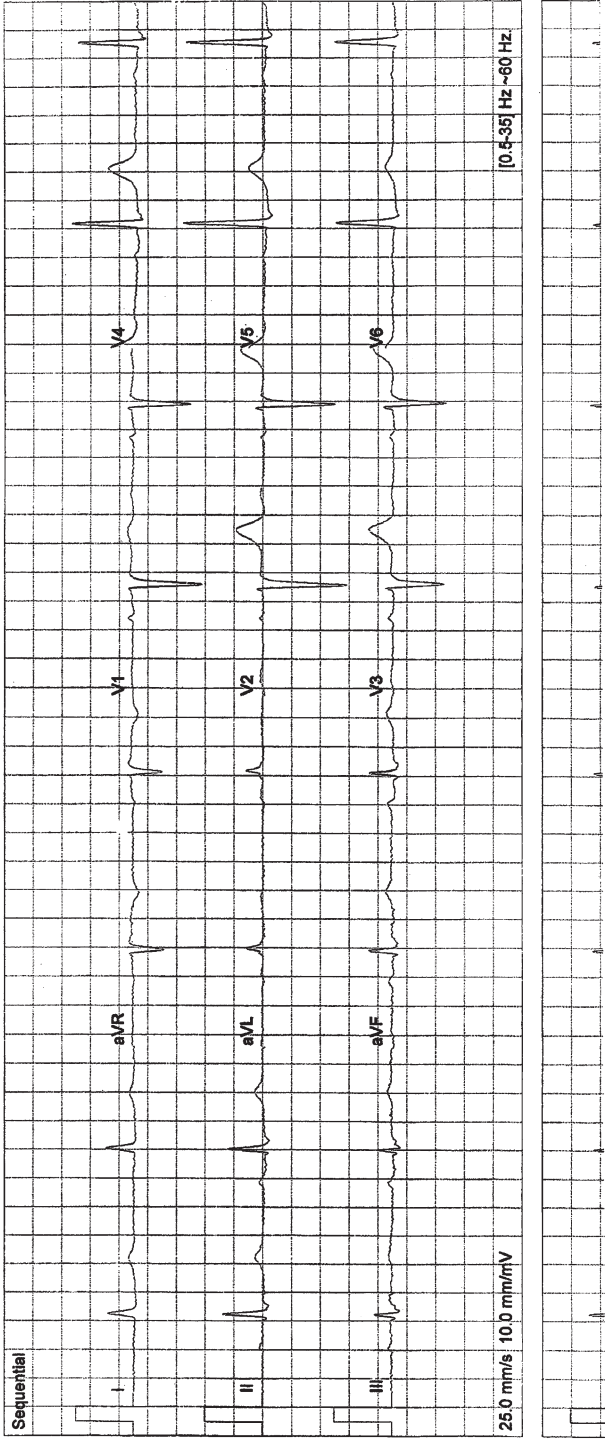


Fig. 6-5. ECG from a healthy 74 year old female. Poor wave progression V_2-V_3 is a not uncommon finding in females and may mimic old anteroseptal MI. Caution is needed in positioning leads V_1 and V_2 in both females and males.

- Improper lead placement of V_2 and V_3 , particularly in women, may cause decreased R wave amplitude, often incorrectly assessed as anteroseptal infarction.
- Old anteroseptal and anterior infarction.
- Left bundle branch block (LBBB) (Fig. 6-6).
- Left ventricular hypertrophy (LVH) (*see* Fig. 7-6).
- Severe chronic obstructive pulmonary disease (COPD), particularly emphysema (Fig. 6-8).
- Late transition (Fig. 6-7).
- Left anterior fascicular block.

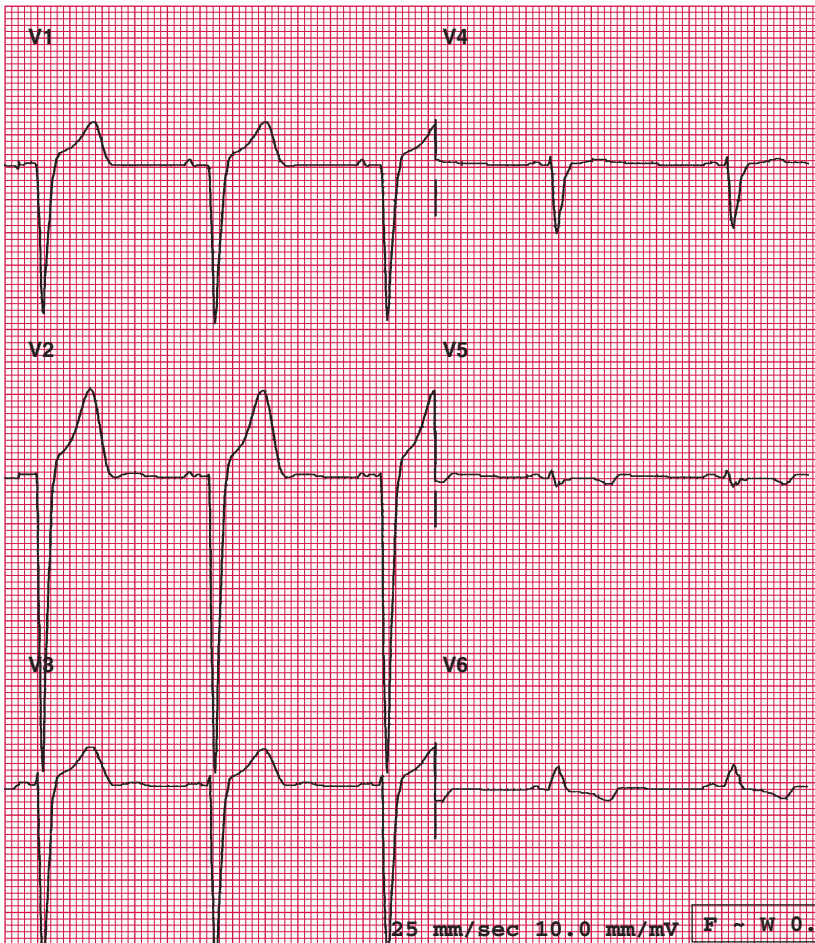


Fig. 6-6. Poor R wave progression in V_1 through V_4 and QRS duration >0.12 second indicate left bundle branch block.

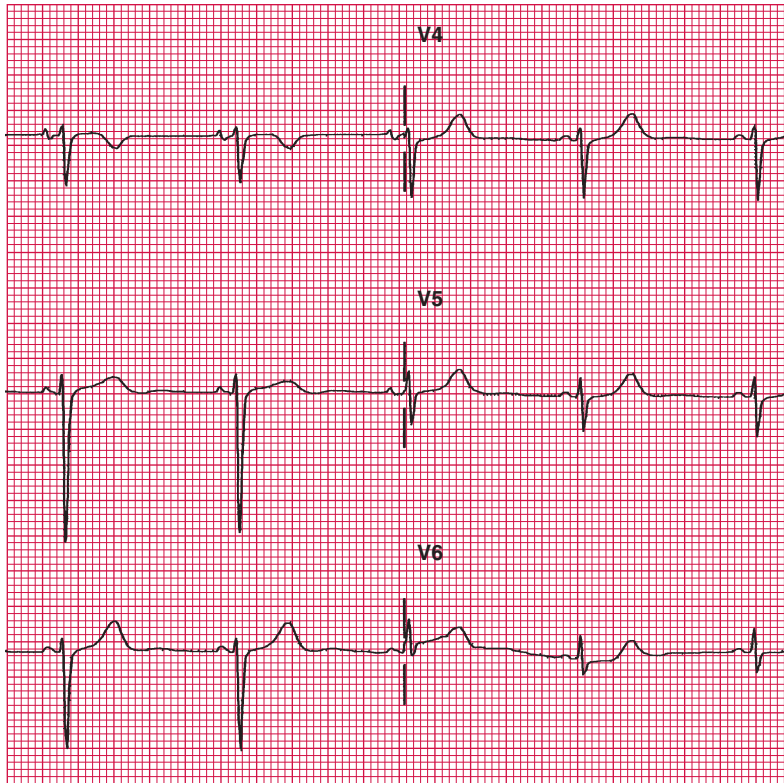


Fig. 6-7. Poor R wave progression in V_2 through V_4 with normal QRS duration. Note that the transition, instead of occurring normally in lead V_3 , occurs in V_5 as indicated by a negative QRS in V_5 . Tracing from a normal 48-year-old woman. Normal ECG.

A net negative QRS complex in V_5 or V_6 in the absence of right ventricular hypertrophy (RVH) indicates late transition (Fig. 6-7). Severe COPD is considered if the P wave amplitude is greater than 2.5 mm in any of lead II, III, or aVF (Fig. 6-8). Severe COPD, particularly that caused by emphysema, may reveal poor R wave progression in V_1 through V_4 , or Q waves may indicate pseudoinfarction (*see* Fig. 6-8). Note the P waves of right atrial hypertrophy, characteristic of P pulmonale, which strengthens the diagnosis of COPD pseudoinfarction.

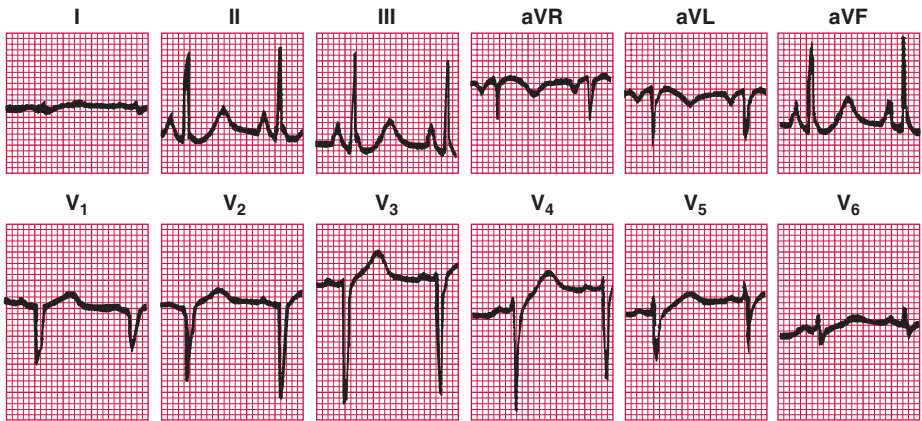


Fig. 6-8. Chronic obstructive pulmonary disease with pulmonary hypertension. The patient is a 58-year-old man with a pulmonary arterial pressure of 42/25 mm Hg at rest. The ECG shows P pulmonale with a vertical P axis. The QRS complexes in lead I are small, and the frontal plane QRS axis is +90 degrees. There is poor progression of the R wave in the precordial leads, with an R/S ratio in leads V₅ and V₆ of less than 1. The amplitude of the QRS complexes in V₆ also is small. (From Chou TC: *Electrocardiography in Clinical Practice*, 4th ed., Philadelphia, 1996, WB Saunders, Elsevier Science.)

- Note that poor R wave progression in V₂ through V₄ in the absence of late transition, LVH, or COPD suggests a diagnosis of anterior infarction (Fig. 6-9), but consideration of lead placement error and clinical correlation is required always.

Q WAVE MYOCARDIAL INFARCTION

Abnormal Q waves caused by myocardial necrosis occur as early as 2 hours and as late as 24 hours after the onset of clinical symptoms of acute MI. Q waves of acute infarction are always associated with abnormal ST elevation.

Diagnostic Criteria

- The presence of ST segment elevation ≥ 1 mm with or without Q waves in two or more contiguous leads in a patient with acute chest discomfort is diagnostic of ST elevation MI (STEMI), probable Q wave MI (Fig. 6-10A and B, and Fig. 2-13B).

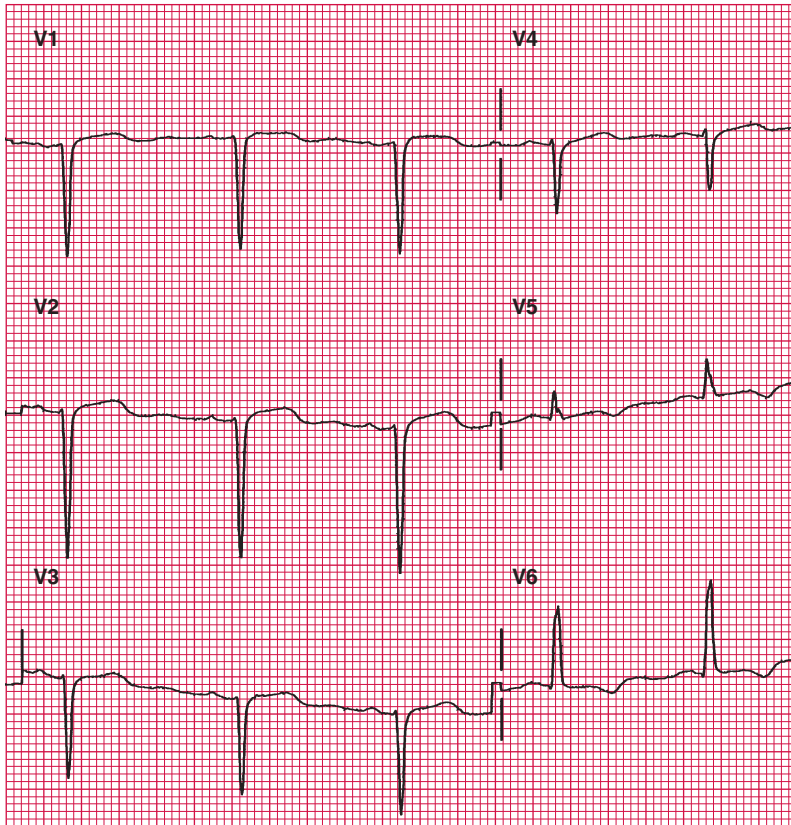


Fig. 6-9. Poor R wave progression in V₂ through V₄ with abnormality of the ST segment: consider old anteroseptal myocardial infarction. Note the transition zone is not late, in that the QRS complex is not negative in V₅ or V₆. Comparison with old ECGs and clinical correlation is required. Abnormal ECG.

- From 6 to 12 hours after onset of symptoms, ST segment elevation recedes, but Q waves become more prominent (Fig. 6-11).
- Pathologic Q waves and ST elevation in leads II, III, and aVF indicate inferior infarction (Fig. 6-12).
- The Q waves in leads II, III, and aVF are >0.03 second in duration; the Q wave in lead III is >0.04 second wide. Figure 6-13 shows acute inferior MI with ST-T wave abnormalities and evolutionary changes.
 - An abnormal Q wave in lead III (≤ 0.04 second in duration) not associated with pathologic Q waves in lead II or aVF should be considered a normal variant.

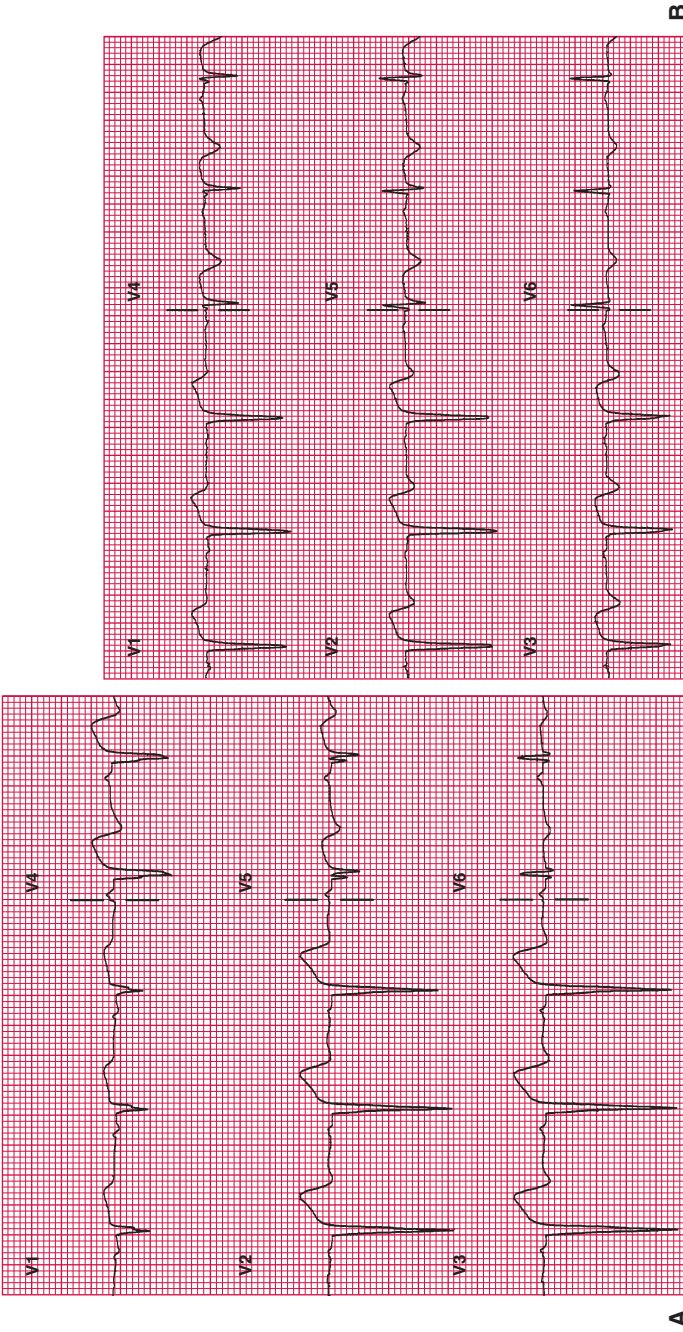


Fig. 6-10. **A**, Q waves in leads V₁ and V₂ with marked abnormal ST segment elevation in V₁ through V₄ indicates acute anterior myocardial infarction. **B**, Pathologic Q waves in leads V₁ through V₃ and abnormal ST segment elevation in V₁ through V₅ indicate large acute anterior myocardial infarction. **C**, Acute anterior myocardial infarction. **D**, Same patient as in (C). Tracing made 1 hour later.

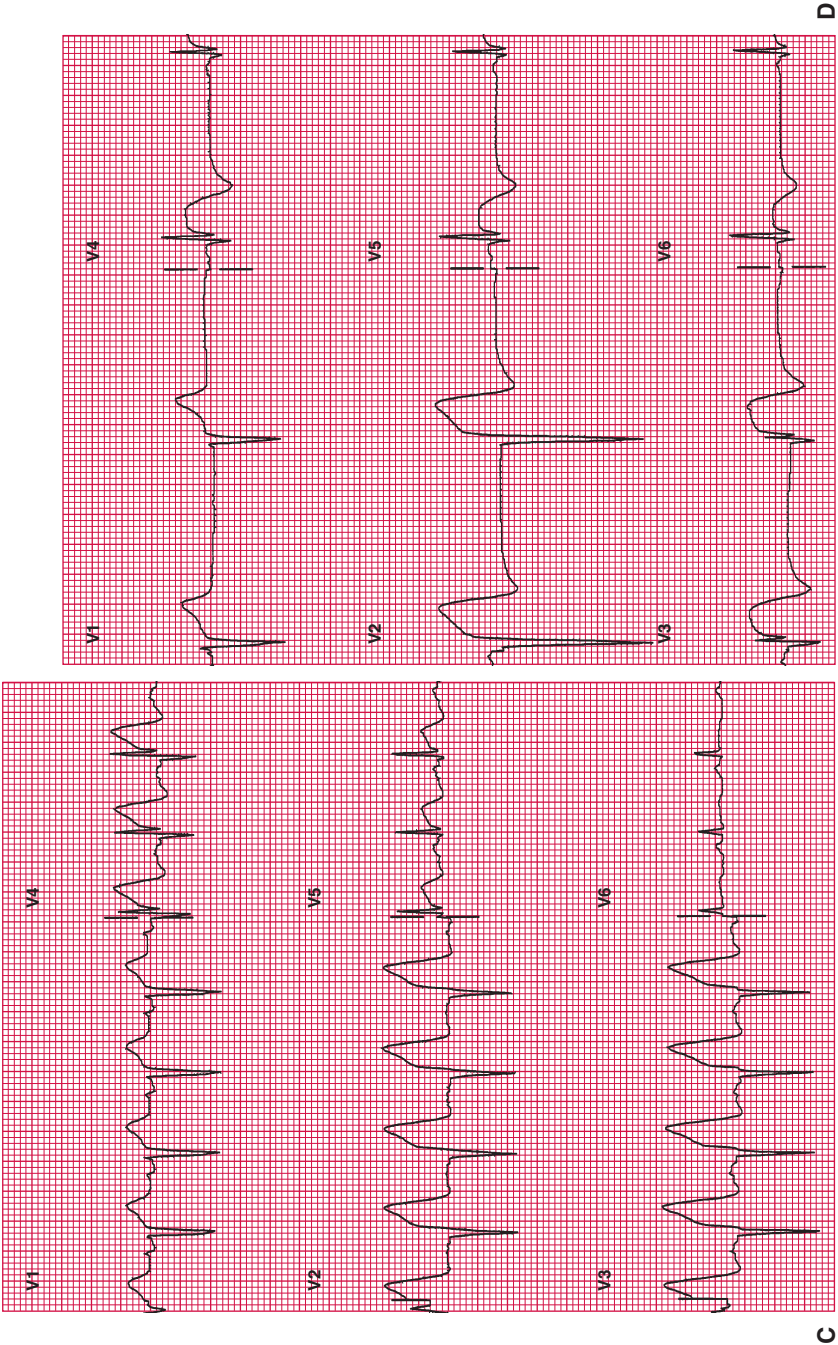


Fig. 6-10. Continued

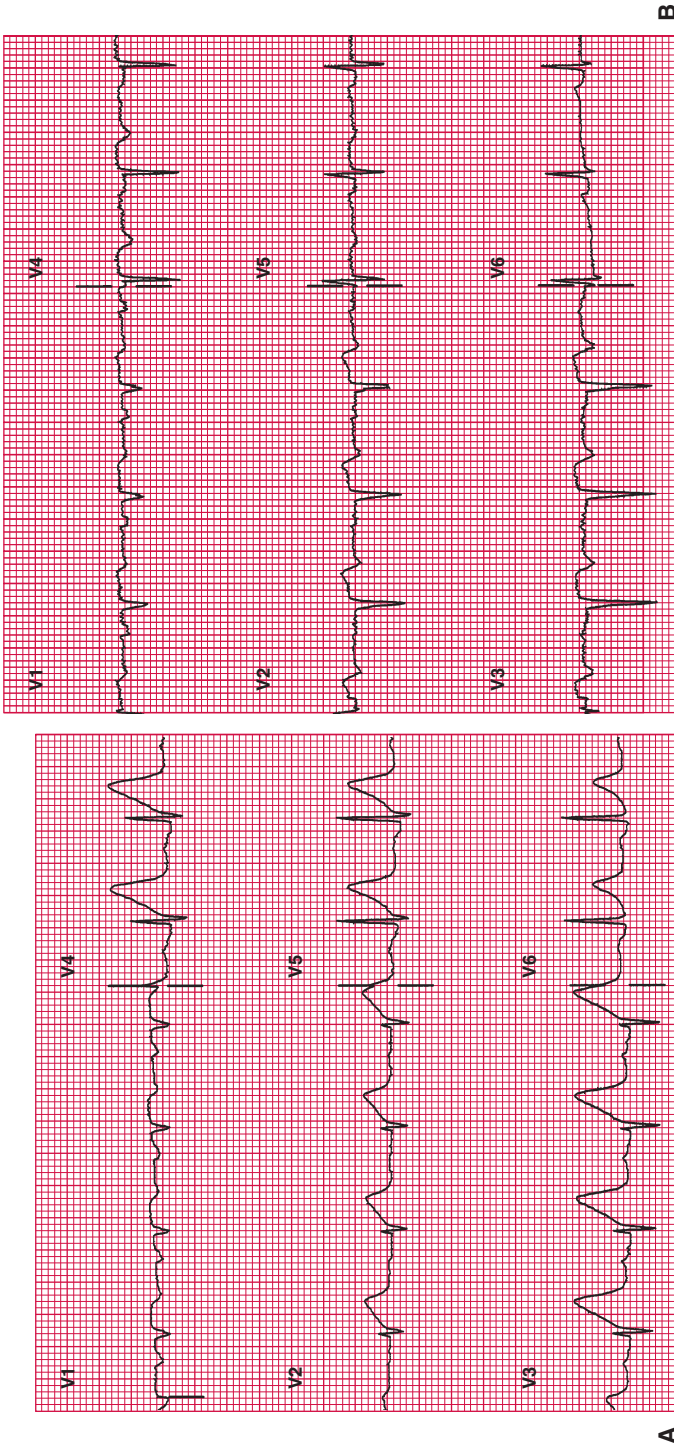


Fig. 6-11. A, A patient with chest pain and ST elevation in V₁ through V₄, acute anterior myocardial infarction. (From Khan MG: *Heart Disease Diagnosis and Therapy*, Totowa, NJ, 2005 Humana Press.) B, Same patient as in (A). Tracing taken 10 hours later indicates evolutionary changes: Q waves have developed in V₁ through V₄, and T wave inversion has emerged. Acute anterior infarction confirmed. (From Khan, M. Gabriel: *Heart Disease Diagnosis and Therapy*, Totowa, NJ, 2005 Humana Press.)

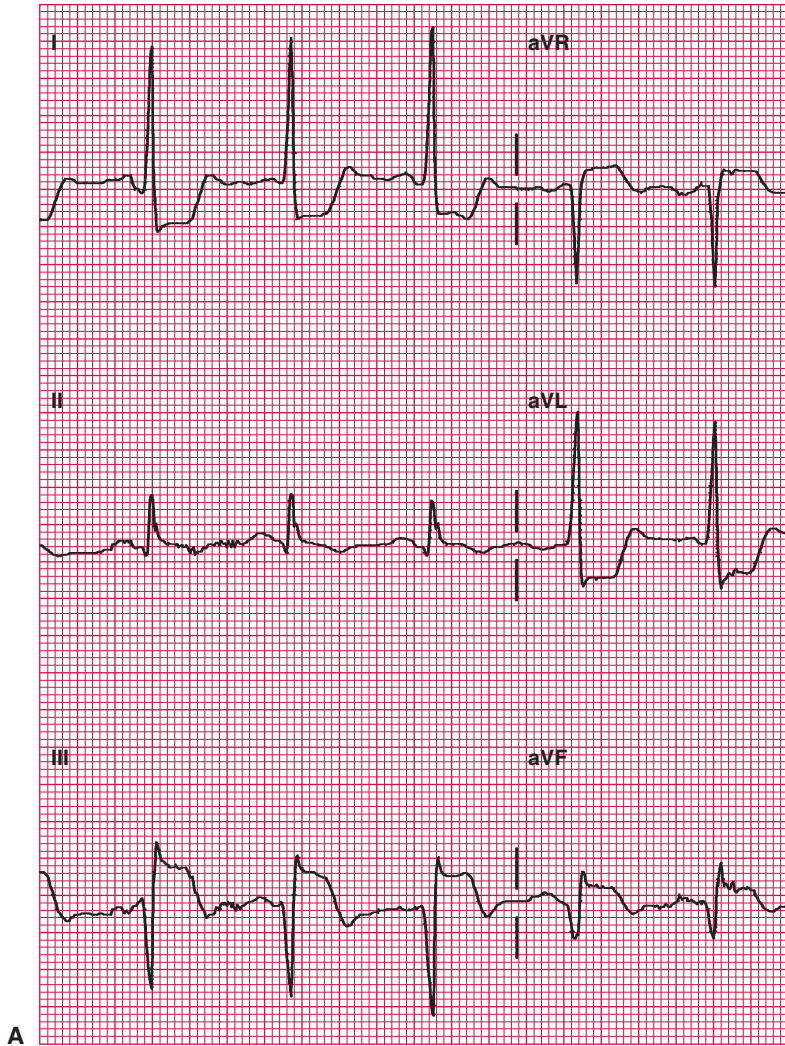


Fig. 6-12. A, Deep pathologic Q waves in II, III, and aVF with marked ST segment elevation indicate acute inferior myocardial infarction. B, Same patient as in (A). ECG taken 1 hour later shows decrease in ST segment after thrombolytic therapy; ST-T wave abnormality indicative of evolutionary changes.

(continued)

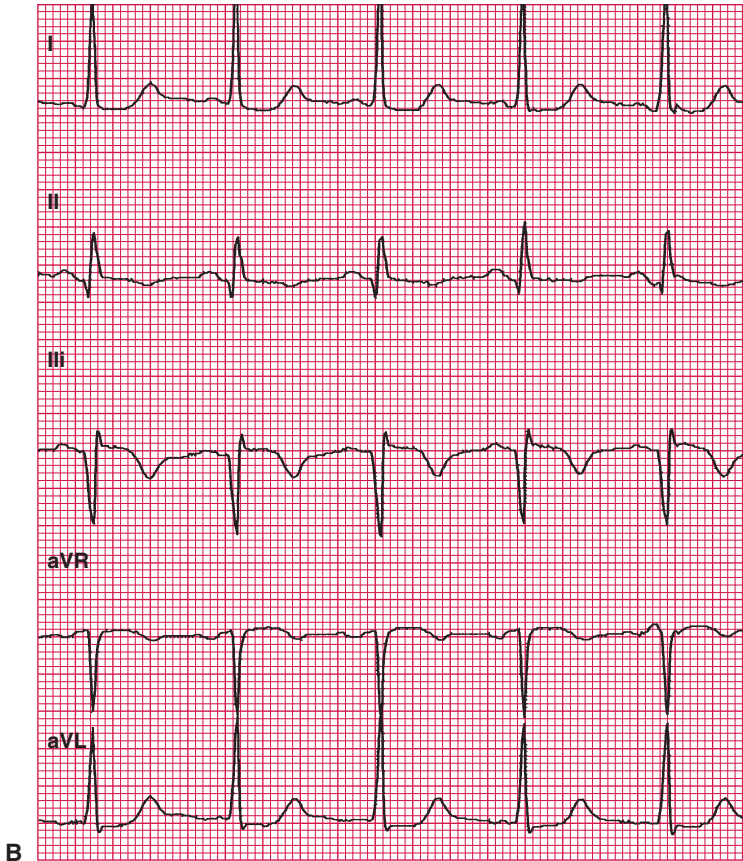


Fig. 6-12. *Continued*

- Most of the erroneous diagnoses of infarction are made based on findings of nondiagnostic Q waves in leads III and aVF (Fig. 6-14 and 6-11).
- Figure 6-10 shows features of acute anterior MI.
- Pathologic Q waves of infarction may diminish in amplitude and duration during the years after acute infarction. Pathologic Q waves persist in more than 80% of patients 4 to 5 years after acute MI. In some patients, abnormal coving of the ST segment and T wave inversion persist for several years and may be difficult to differentiate from a recent infarct. The tracing is often interpreted as infarction age indeterminate (Fig. 6-15 and Fig. 2-18B). In 10% of patients, Q waves become nondiagnostic but still suspicious; in the remaining 10%, Q waves disappear. In approximately 5% of patients with Q wave infarction, the ECG returns to normal.

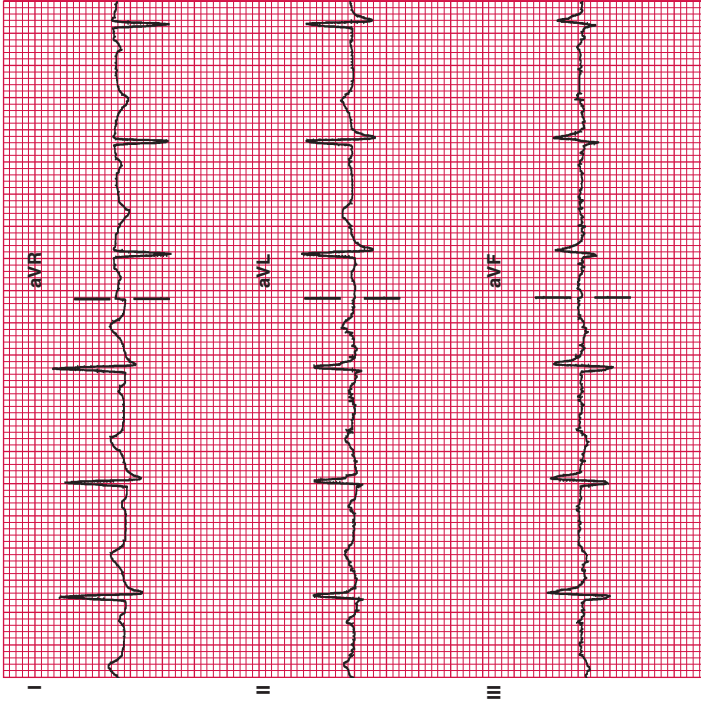


Fig. 6-13. Tracing from a 49-year-old man with no evidence of heart disease; note narrow small Q waves in leads II, III, and aVF <math><0.04</math> second. Diagnosis: inferior Q waves noted, nondiagnostic, clinical correlation required: borderline ECG.

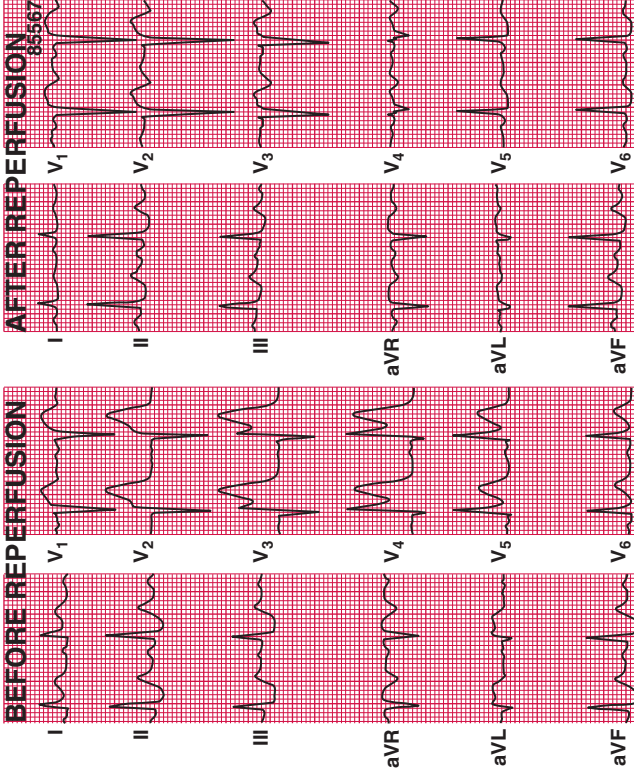


Fig. 6-14. Acute anteroseptal infarction in a patient presenting to the hospital 2 hours after the onset of chest pain. Note the presence of Q waves in leads V₂ to V₄ (left panel). After successful thrombolytic therapy, these Q waves disappear (right panel), indicating that the tissue was still salvageable. (From Wellens JI, Conover MB: *The ECG in Emergency Decision Making*, Philadelphia, 1992, WB Saunders, Elsevier Science.)

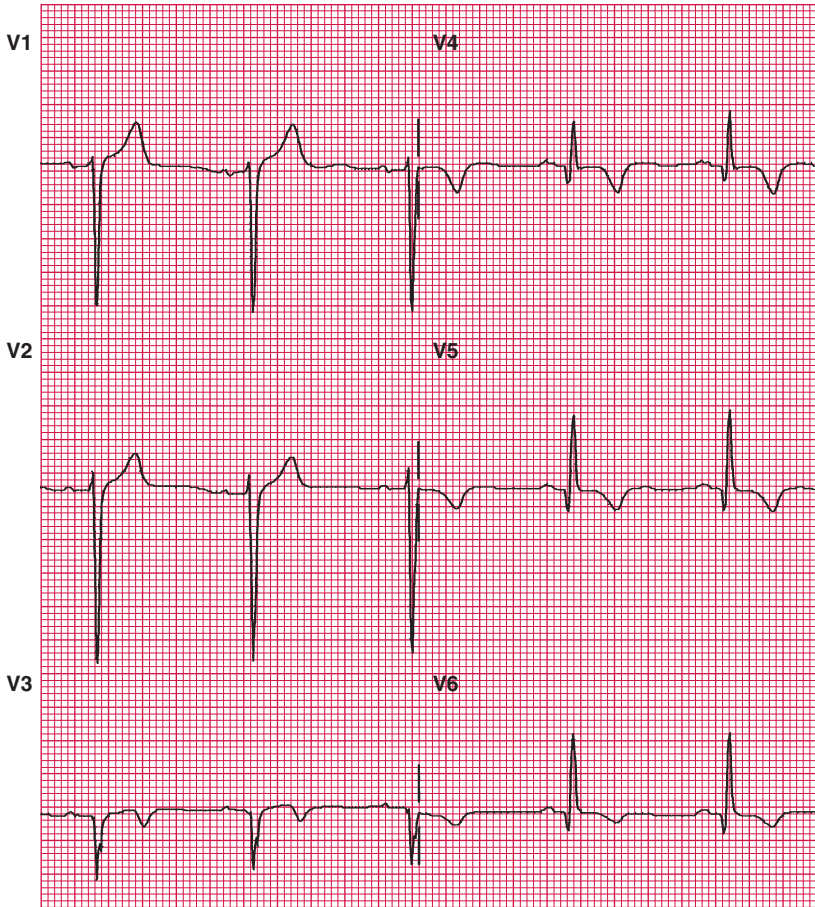


Fig. 6-15. Loss of R wave in V₃ through V₆ indicates anterolateral infarction; note the isoelectric ST segment. However, the ST segment has an abnormal shape with deep T wave inversion, localized to leads I, aVL, and V₃ through V₆, which indicates anterolateral infarction age indeterminate. Comparison with old ECGs and clinical correlation are required to date the time of infarction.

Nonatheromatous Cause of MI

Rarely, infarction may occur in the absence of atherosclerotic coronary artery disease and can be caused by:

- Severe coronary artery spasm.
- Cocaine abuse (Fig. 6-16).

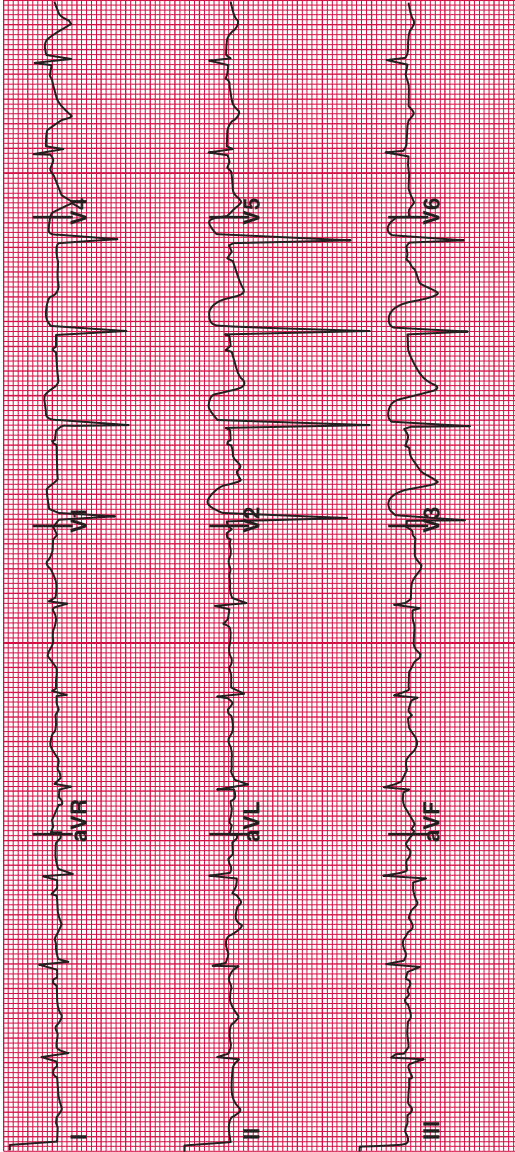


Fig. 6-16. Acute anteroseptal and inferior MI related to cocaine abuse. The patient is a 30-year-old woman known to be a cocaine user. She developed severe chest pain, and the ECG recorded 90 minutes after the onset of pain revealed ST segment elevation in the anteroseptal and inferior leads (not shown here). Coronary arteriogram revealed complete thrombotic occlusion of the proximal left anterior descending artery. Percutaneous transluminal angioplasty was performed with satisfactory result. The visualized artery was long and wrapped around the apex of the heart to supply a substantial part of the inferior wall. The ECG recorded on the next day shows signs of acute anteroseptal and inferior MI. There is a QS deflection in lead V_1 , and the R waves in leads V_2 and V_3 are very small. The ST segment in leads V_1 through V_3 is elevated, and the T waves are inverted in all the precordial leads and in lead I. In the inferior leads, Q waves are present with ST segment elevation and T wave inversion. (From Chou TC: *Electrocardiography in Clinical Practice*, 4th ed., Philadelphia, 1996, WB Saunders, Elsevier Science.)

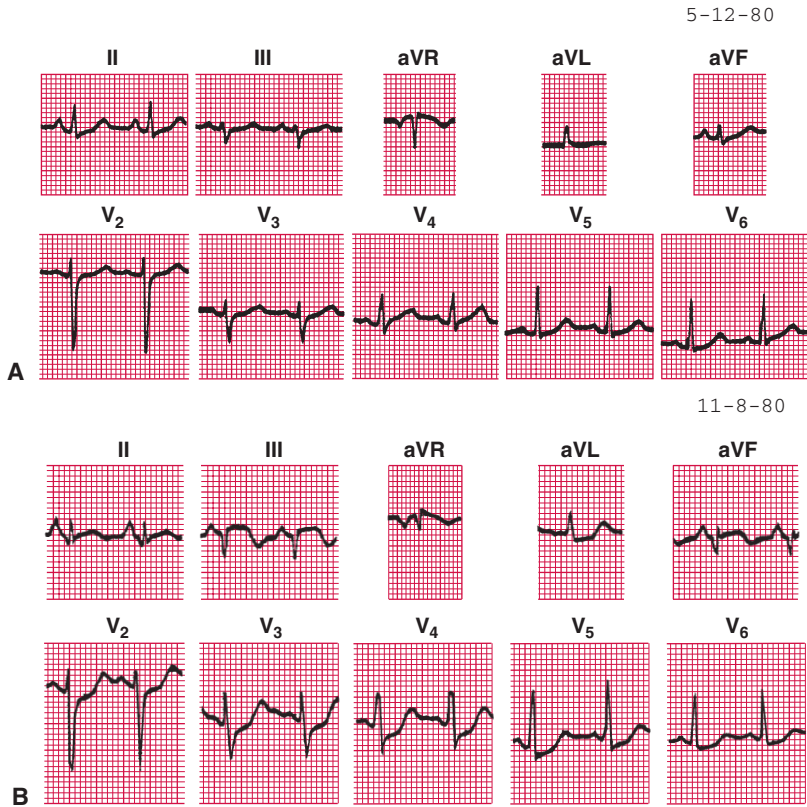


Fig. 6-17. Acute inferior MI in a 16-year-old girl with Kawasaki disease and coronary artery aneurysm. The aneurysm was demonstrated by coronary arteriogram before the development of MI. The ECG on 5-12-80 (**A**) was obtained before and that on 11-8-80 (**B**), after the infarction occurred. Note the appearance of Q waves with ST segment elevation and T wave inversion in the inferior leads on the tracing of 11-8-80. (Courtesy Dr. Samuel Kaplan. From Chou TC: *Electrocardiography in Clinical Practice*, 4th ed., Philadelphia, 1996, WB Saunders, Elsevier Science.)

- Kawasaki disease may cause coronary artery aneurysm and MI (Fig. 6-17). A Q wave duration >0.03 second, depth >4 mm in children with symptoms suggestive of an angina can be caused by Kawasaki disease or anomalous left coronary artery arising from the pulmonary artery.

Location of Infarction

It is important to emphasize that localization of the infarcted area from the electrocardiographic findings is far from precise, particularly for anterolateral, anteroseptal, and posterior infarctions.

INFERIOR INFARCTION

- Pathologic Q waves in leads II, III, and aVF
 - Acute infarction: ST segment elevation in II, III, and aVF; diagnostic specificity is enhanced if there is reciprocal depression in leads I, aVL, V₁, and V₂ (*see* Figs. 2-13A, 5-3, 5-4, 5-8, and 6-12) during the early hours of infarction. Only ST segment elevation caused by the current of injury may be observed with no Q waves or only small emerging Q waves visible.
 - Old infarction: Pathologic Q waves may be associated with nonspecific ST-T wave changes in leads II, III, and aVF (*see* Fig. 2-17B), but these changes may be minor, being present in only two of the three leads; lead III is the most unreliable lead. The ST segment may be normal; the T wave inversion of acute infarction may persist indefinitely, but the ST segment and T waves may both normalize. The specificity of a Q wave of >0.03 second in leads II and aVF is 96% and the sensitivity is approximately 50%.

ANTERIOR INFARCTION

- Pathologic Q, QS, or QR waves in leads V₂ through V₄ or V₅, or V₁ through V₆, with extensive anterior infarction.
 - Acute infarction: ST segment elevation in leads V₂ through V₄ or V₅ (*see* Figs. 5-6, 5-9, 6-10, and 6-11). Also, V₁ through V₆ may show ST elevation with extensive anterior infarction (*see* Fig. 5-7). Reciprocal depression may develop in leads II, III, and aVF during the early hours of infarction. Only ST segment elevation caused by the current of injury may be observed with no Q waves or small emerging Q waves visible.
 - Old infarction: the following: pathologic Q waves, QS complexes in V₂ through V₄ or V₅; the ST segment is usually isoelectric but some deformity of the segment often remains to raise suspicion of an old infarct (*see* Figs. 2-18B-D, 6-9, and 6-15). In most patients, the ST segment is not elevated, but if it persists more than 1 month after infarction and is >1 mm in one or more leads, this suggests the presence of a left ventricular aneurysm (*see* Fig. 5-17). T wave inversions may partially normalize but may persist indefinitely (*see* Figs. 2-19, 2-18B and D, and 6-15).

ANTEROSEPTAL OR ANTEROAPICAL INFARCTION

- Pathologic Q waves, QS deflection in leads V_1 through V_3 in the absence of lead misplacement, and rotational changes that may occur in some conditions, including severe emphysema (*see* Figs. 6-8, 6-9, and 6-14).
- Acute infarction: ST segment elevation in V_1 through V_3 in patients with acute onset of chest pain (*see* Fig. 5-5). This abnormality has long been attributed to anteroseptal infarction. Recent echocardiographic and angiographic findings in patients whose disorders were classified as acute anteroseptal infarction showed that 92% of patients with ST segment elevation in leads V_1 through V_3 had an anteroapical infarct with a normal septum.
- Old infarction: QS in V_1 through V_3 with deformity of the ST segment, which may be isoelectric with abnormal or normal T waves (*see* Fig. 6-9).

ANTEROLATERAL INFARCTION

- Pathologic Q waves in leads V_5 , V_6 , I, and aVL may reflect anterolateral infarction, but the pattern has low specificity. There are many conditions that can produce this electrocardiographic finding. The ECG pattern often reflects an anteroapical infarct; it may be found in patients with septal fibrosis and hypertrophic cardiomyopathy (*see* Fig. 6-23).
 - Acute infarction: ST segment elevation in leads I, aVL, V_5 , and V_6 .
 - Old infarction: Pathologic Q waves associated with an ST segment abnormality. The ST segment may be isoelectric with or without T wave inversion.
- A QS pattern in V_4 increases the specificity (Figs. 2-19 and 6-15).

RIGHT VENTRICULAR INFARCTION

- Right ventricular infarction is usually associated with inferior infarction. Diagnostic ECG features are ST elevation in V_{4R} and V_{3R} in association with ST elevation and emerging Q waves in leads II, III, and aVF (Figs. 6-18 and 6-19). The ST elevation in V_{4R} recedes within 8 hours of onset of symptoms (*see* Fig. 6-18 and Fig. 5-8B).

POSTERIOR INFARCTION

- True posterior infarction often occurs in association with inferior MI, and this association increases the specificity and makes other possibilities for tall R waves in V_1 and V_2 less likely. The possibilities must always be examined, however (*see* Table 2-3).

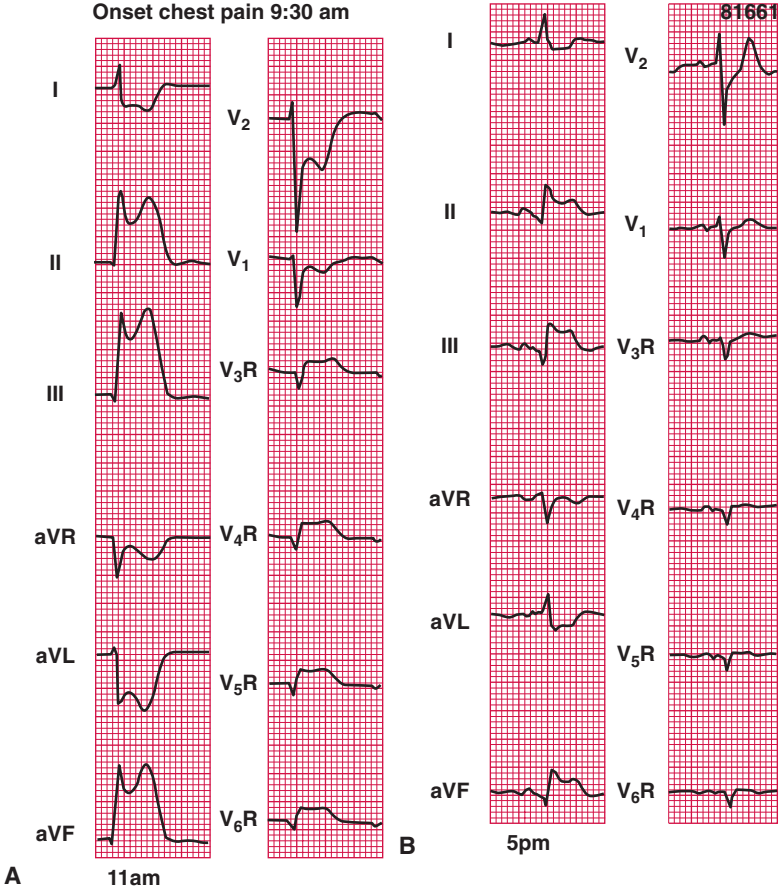


Fig. 6-18. A, Serial tracings from a patient with acute inferoposterior and right ventricular infarction. B, Note that the diagnostic changes of right ventricular infarction seen in lead V_{4R} have disappeared 7½ hours after the onset of pain. (From Wellens JJH, Conover MB: *The ECG in Emergency Decision Making*, Philadelphia, 1992, WB Saunders, Elsevier Science.)

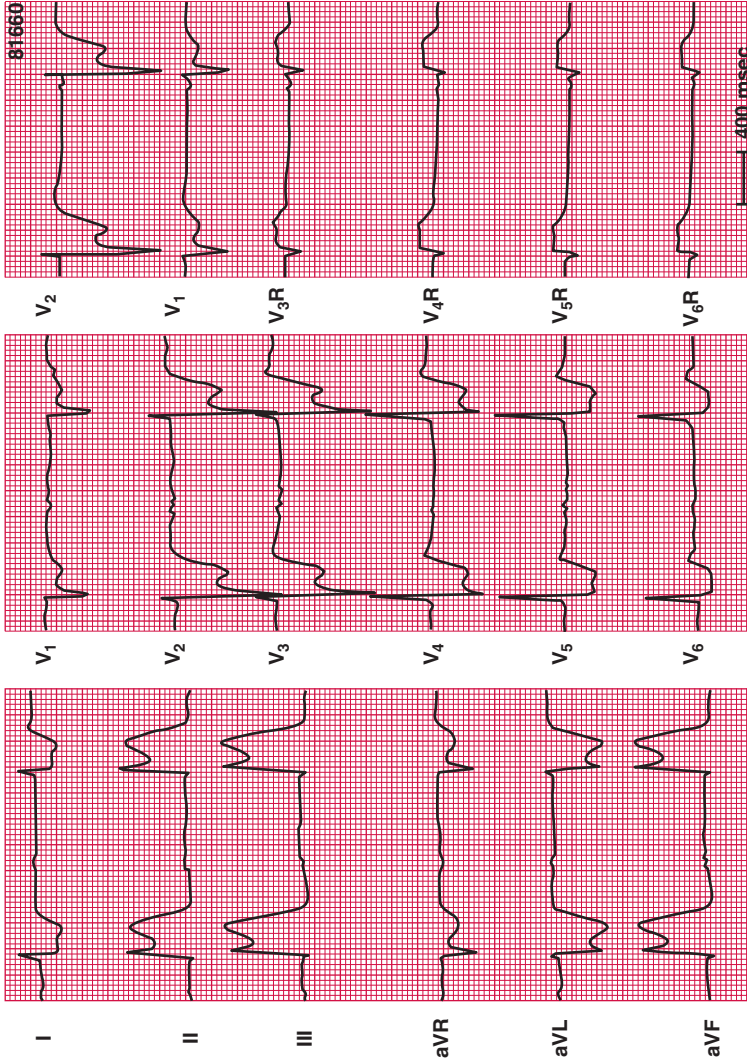


Fig. 6-19. Example of complete atrioventricular nodal block in a patient with an acute inferior-posterior myocardial infarction and right ventricular involvement. (From Wellens JHJ, Conover MB: *The ECG in Emergency Decision Making*, Philadelphia, 1992, WB Saunders, Elsevier Science.)

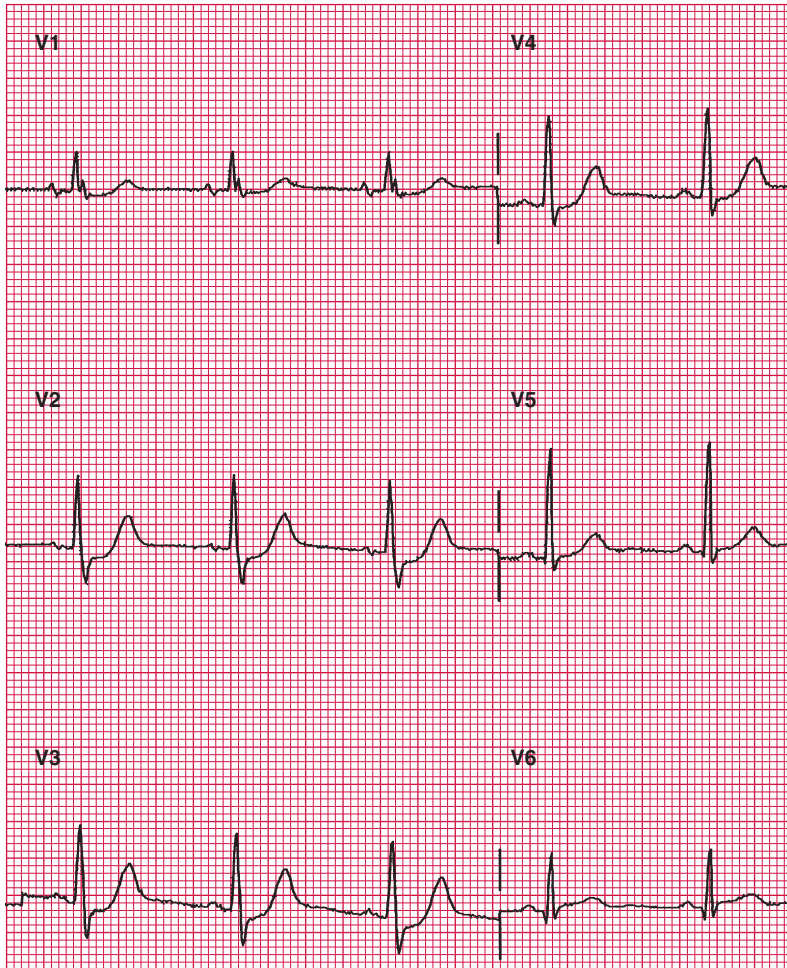


Fig. 6-20. Note tall R waves in V_1 and V_2 in the absence of right ventricular hypertrophy, Wolff-Parkinson-White syndrome, or right bundle branch block, in keeping with posterior infarction. Note upright T wave in V_1 and V_2 ; limb leads showed inferior myocardial infarction. (From Khan, M. Gabriel: *Heart Disease Diagnosis and Therapy*, Baltimore, 1996, Williams & Wilkins.)

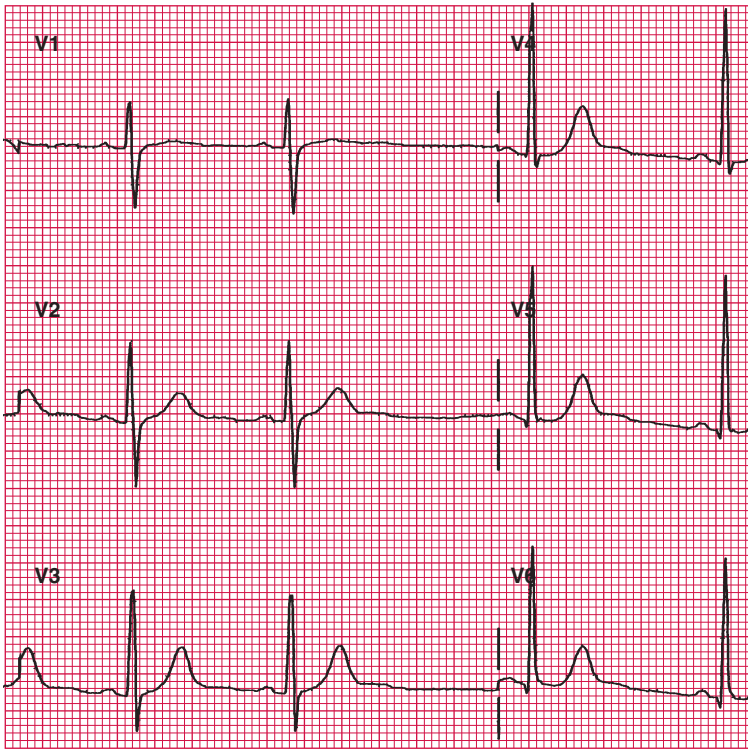


Fig. 6-21. V leads in a normal 26-year-old woman. Note the R wave is tall in V_1 ; QRS is positive in V_2 , indicating early transition; there is no posterior infarction; R/S ratio in V_1 is less than 1; the limb leads showed no pathologic Q waves in II, III, and aVF; and there is no indication of inferior or right ventricular infarction. Normal ECG.

- In lead V_1 , the R wave is $>S$, and the R/S is >1 . The T wave that is often negative is upright and may be peaked (Fig. 6-20); the R wave should be >0.04 second.
- In lead V_2 , the R wave is tall, and the usual positive T wave may be peaked.
- Specificity is increased if the ST segment is elevated in leads V_7 to V_9 in the presence of the ECG pattern of acute inferior infarction. The following must receive consideration:
 - A tall R wave in V_2 and occasionally in V_1 is not an uncommon normal variant, particularly if transition is early (see Fig. 2-2 and Fig. 6-21).
 - Right ventricular hypertrophy, Wolff-Parkinson-White syndrome, and other causes of tall T waves in V_1 and V_2 must be excluded (see Table 2-3).

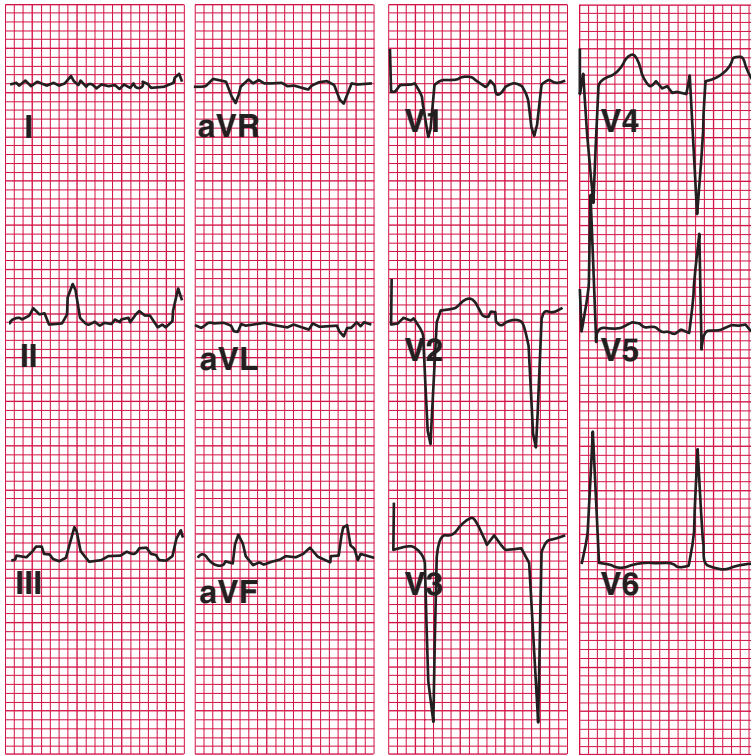


Fig. 6-22. Acquired immunodeficiency syndrome myocarditis simulating an anteroseptal myocardial infarction. (From Braunwald E: *Heart Disease: A Textbook of Cardiovascular Medicine*, 5th ed., Philadelphia, 2001, WB Saunders, Elsevier Science.)

- Presence of the diagnostic right ventricular infarction changes in V_{3R} and V_{4R} outlined previously increase the specificity.

MIMICS OF Q WAVE MYOCARDIAL INFARCTION

- Myocarditis, including Chagas disease and acquired immunodeficiency syndrome (Fig. 6-22), may cause pathologic Q waves.
- Pathologic Q waves may occur in patients with hypertrophic cardiomyopathy (Fig. 6-23).
- Pseudo-Q waves in leads II, III, and aVF in Wolff-Parkinson-White syndrome may mimic inferior MI (Figs. 6-24 to 6-26).
- In LVH, QS may occur in lead V_1 , V_2 , or V_3 and simulate MI (Fig. 6-27).

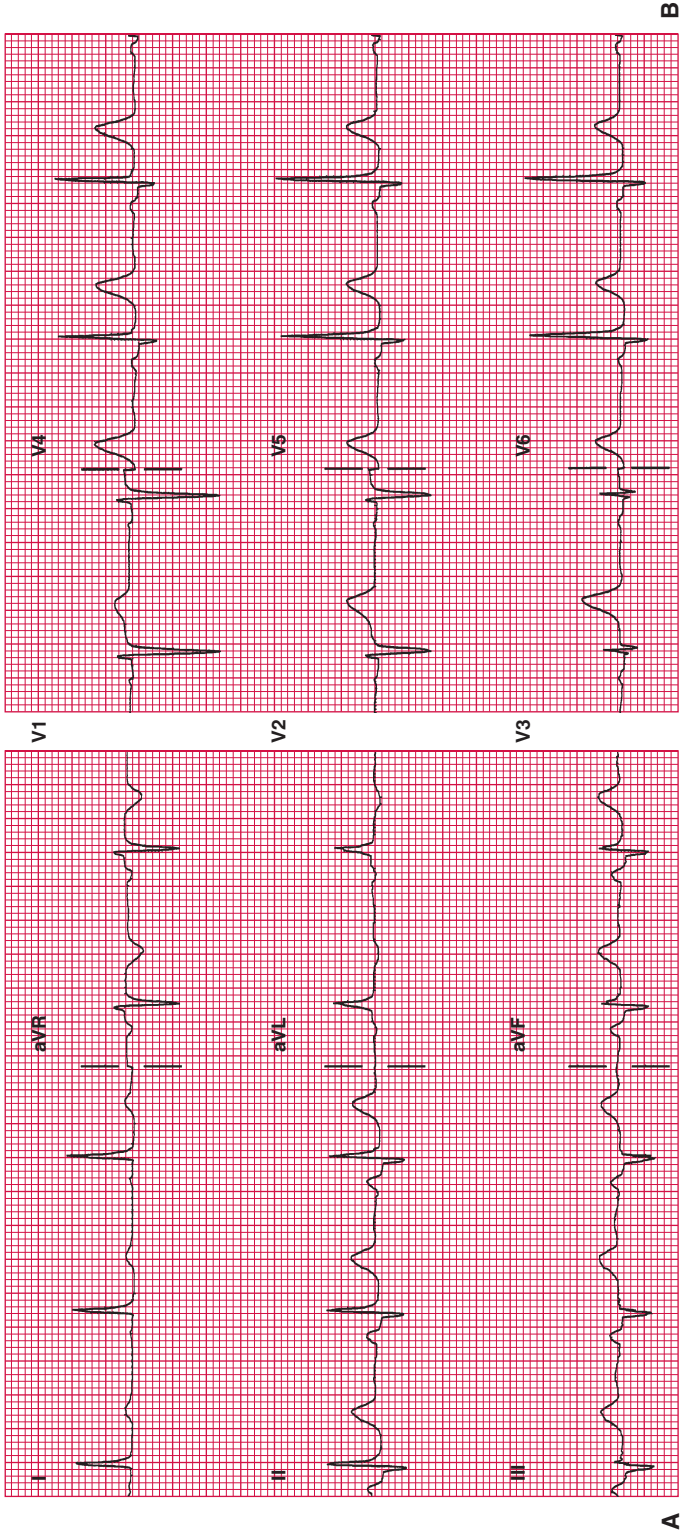


Fig. 6-23. A, Deep, wide pathologic Q waves in leads II, III, and aVF in a 52-year-old woman with known hypertrophic cardiomyopathy. B, Same patient as in (A). Wide, deep pathologic Q waves in leads V₄ through V₆.

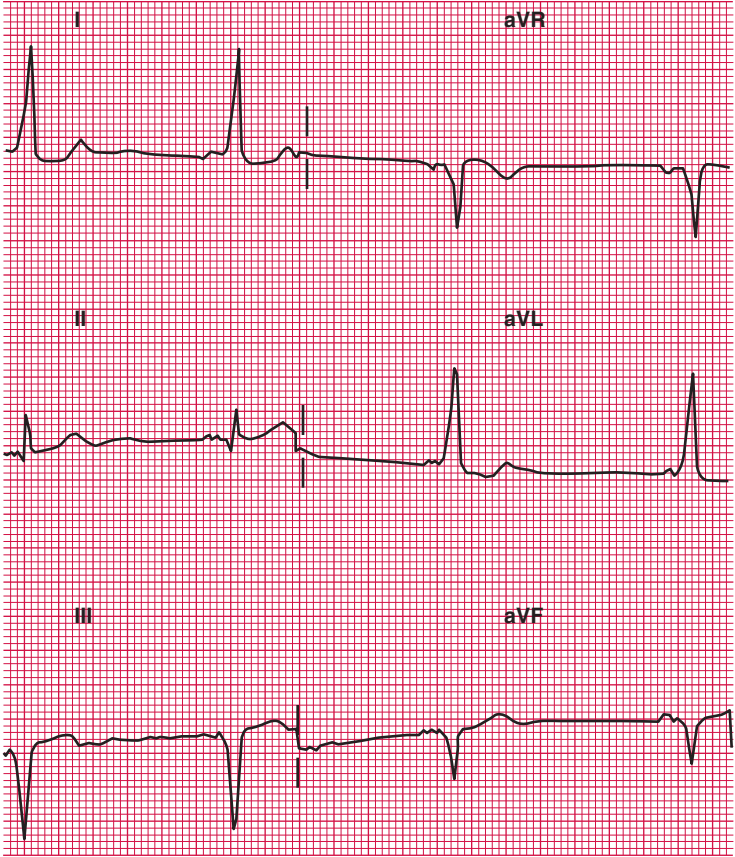


Fig. 6-24. Tracing from a 42-year-old woman with Wolff-Parkinson-White syndrome; note pseudo-Q waves in leads II, III, and aVF, which can mimic inferior myocardial infarction.

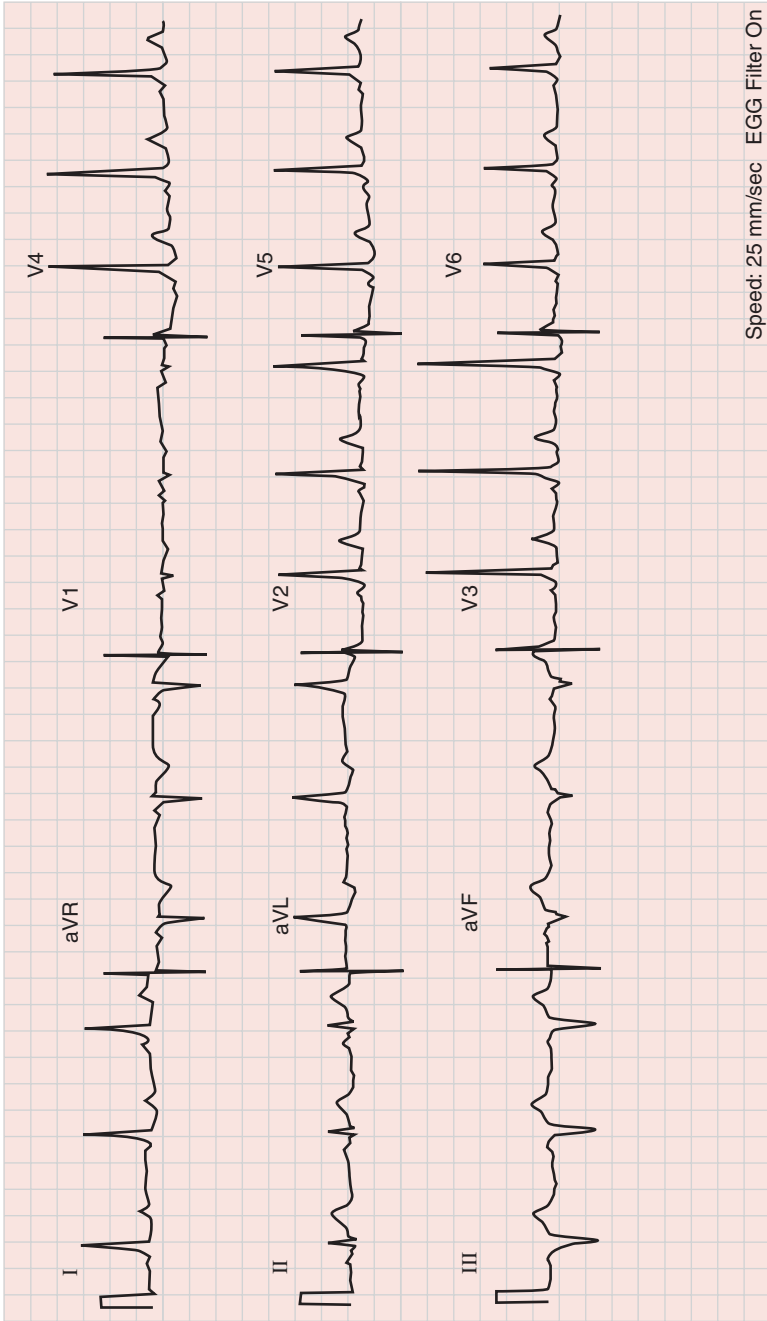


Fig. 6-25. Wolff-Parkinson-White syndrome mimics inferior myocardial infarction.

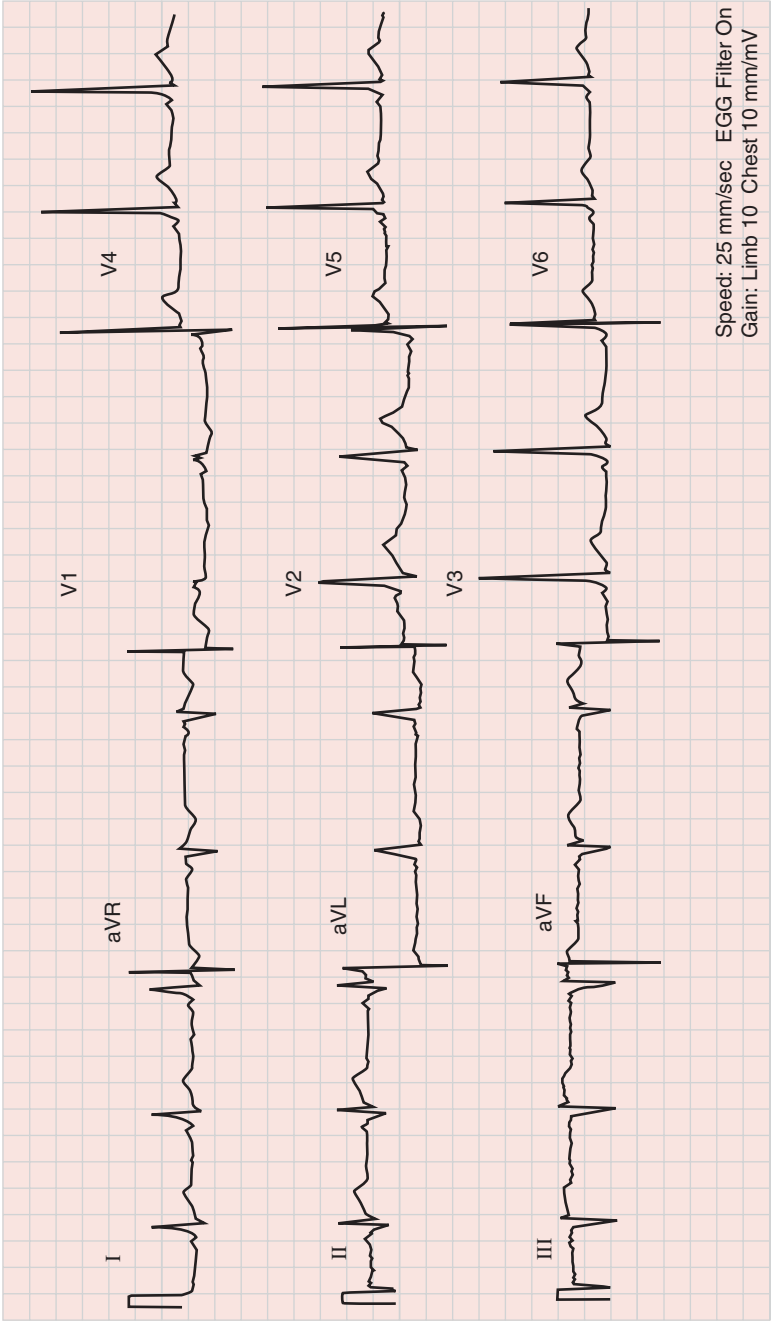


Fig. 6-26. Wolff-Parkinson-White syndrome; deep Q waves in leads II, III, and aVF. Mimics inferior MI. See Step 3 of the step-by-step method for accurate ECG interpretation. See also discussion in Chapter 2 regarding the necessity to include WPW syndrome early in the interpretive sequence, at the same time as assessment for blocks.

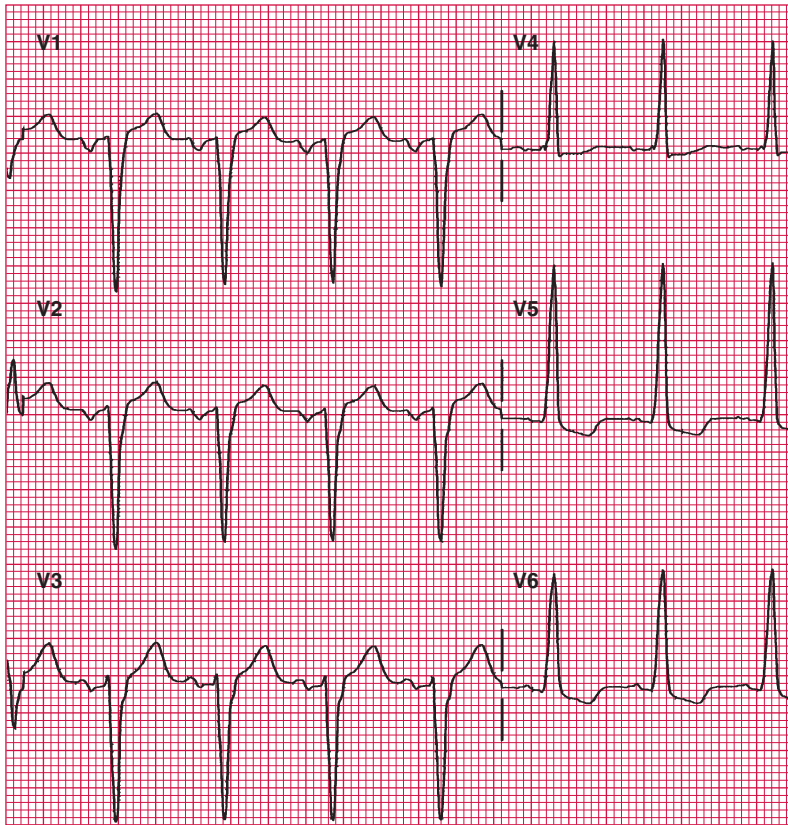


Fig. 6-27. Left ventricular hypertrophy: QS complexes in V_1 and V_2 and a minute R wave in V_3 . The tracing can mimic old anteroseptal myocardial infarction, a common error of interpretation.

- Typically in LBBB, R waves are absent or minute in V_1 through V_3 . LBBB can simulate anteroseptal infarction (*see* Figs. 2-8B and 6-6). In addition, Q waves may occur in leads II, III, and aVF in the absence of infarction.
- In some patients with emphysema, a QS pattern may be recorded in leads V_1 through V_4 and mimic anterior MI. The precordial leads should be placed one intercostal space lower than usual (Fig. 6-28).
- A left-sided pneumothorax may cause a QS pattern in leads V_1 through V_4 .
- Massive pulmonary embolism may cause a QS pattern in leads V_1 through V_4 (*see* Chapter 10).
- Nonpenetrating chest trauma may cause Q waves simulating MI. Conditions that may cause pseudoinfarction patterns are given in Table 6-1.

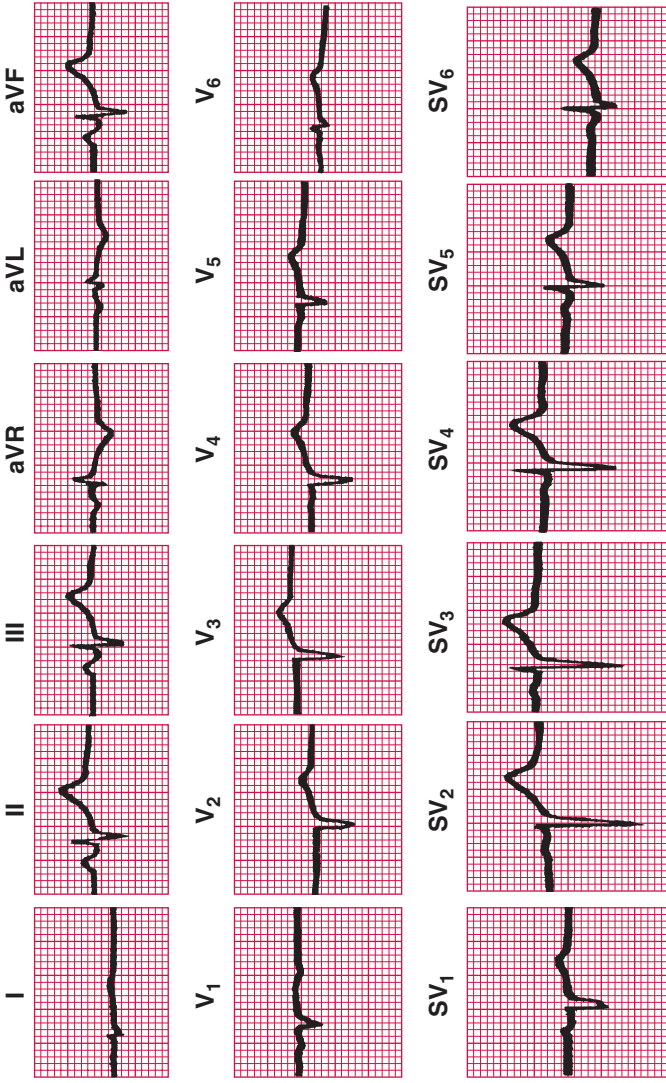


Fig. 6-28. QS deflections in leads V₁ through V₄ mimic anterior myocardial infarction. Additional precordial leads were recorded one intercostal space below the levels of the routine electrode locations. ECG of a 58-year-old man with severe emphysema. The QRS complexes are partially normalized. (From Chou TC: *Cardiovasc Clin* 5:199, 1973.)

Table 6-1
Noncardiac Conditions Causing Pseudoinfarction

Cardiac tumors, primary and secondary
Cardiomyopathy, particularly hypertrophic (<i>see</i> Fig. 6-23) and dilated
Chagas disease
Chest deformity
Chronic obstructive pulmonary disease, particularly emphysema (<i>see</i> Figs. 6-8 and 6-28)
HIV infection (<i>see</i> Fig. 6-22)
Hyperkalemia
Left anterior fascicular block
Left bundle branch block (<i>see</i> Figs. 2-9 and 6-6)
Left ventricular hypertrophy (<i>see</i> Fig. 6-27)
Myocarditis and pericarditis
Normal variant (<i>see</i> Figs. 5-13, 5-14, and 6-5)
Pneumothorax
Poor R wave progression, rotational changes (<i>see</i> Fig. 6-7), and lead placement errors
Pulmonary embolism (<i>see</i> Fig. 10-24)
Trauma to the chest (nonpenetrating)
Wolff-Parkinson-White syndrome (<i>see</i> Figs. 6-25, 6-26, 11-27, and 11-29)
Other causes, although rare, include acute pancreatitis, amyloidosis, sarcoidosis, scleroderma

LEFT BUNDLE BRANCH BLOCK AND INFARCTION

The diagnosis of MI in the presence of LBBB is difficult but often can be made. The usual finding in LBBB is a QS pattern in V_1 and V_3 or very small R waves in V_1 through V_3 simulating infarction or LVH.

ECG Features Suggestive of Left Bundle Branch Block with Infarction

- Figure 6-29 shows the replacement of the constantly present R wave in V_5, V_6 , with a Q wave of infarction in LBBB caused by anteroseptal MI. Figure 6-30 shows LBBB with inferior infarction.
- Q waves in leads I, aVL, V_5 , and V_6 indicate an anterior (anterolateral or anteroseptal) infarction (Figs. 6-31 and 6-32), but a false-positive diagnosis is common. These findings often occur in the absence of infarction and may occur in patients with severe LVH or nonspecific fibrosis.

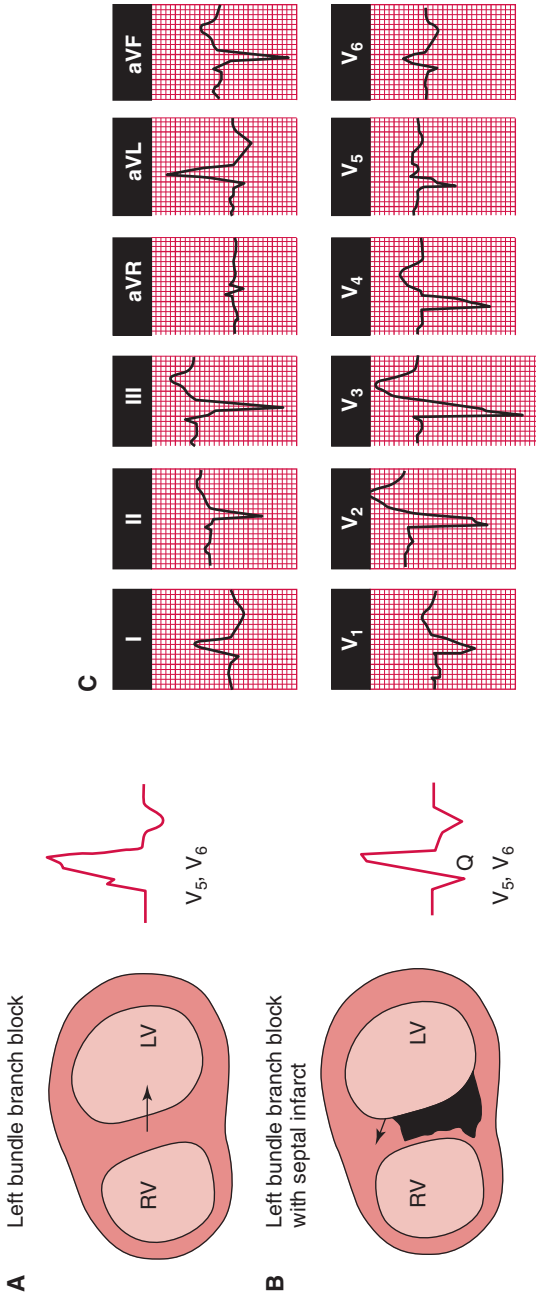


Fig. 6-29. A, With uncomplicated LBBB, early septal forces are directed to the left. Therefore, no Q waves will be seen in V₅ and V₆ (right panel). B, With LBBB complicated by anteroseptal infarction, early septal forces may be directed posteriorly and rightward (left panel). Therefore, prominent Q waves may appear in V₅ and V₆ as a paradoxical marker of septal infarction (right panel). (Adapted from Dunn MI, Lipman BS: *Lipman-Massie Clinical Electrocardiography*, 8th ed., Chicago, 1989, Year Book.) C, Anterior wall infarction (involving septum) with LBBB. Note the presence of QR complexes in leads I, aVL, V₅, and V₆.

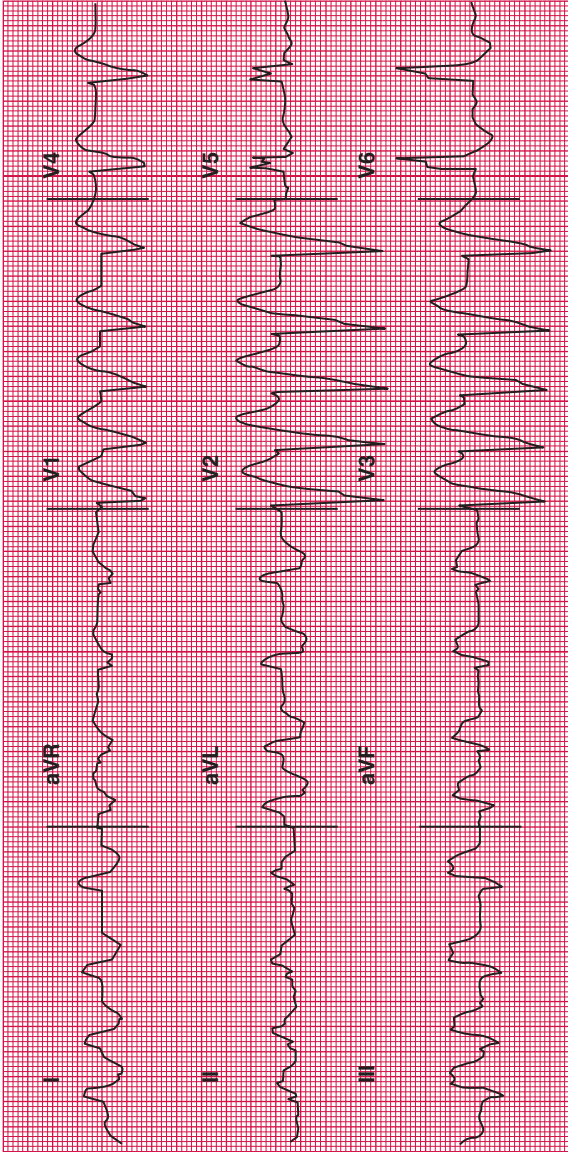


Fig. 6-30. Complete left bundle branch block with acute inferior myocardial infarction. Note the prominent ST segment elevation in leads II, III, and aVF, with reciprocal ST segment depression in I and aVL superimposed on secondary ST-T changes. The underlying rhythm is atrial fibrillation. (From Braunwald E: *Heart Disease: A Textbook of Cardiovascular Medicine*, 6th ed., Philadelphia, 2001, WB Saunders, Elsevier Science.)

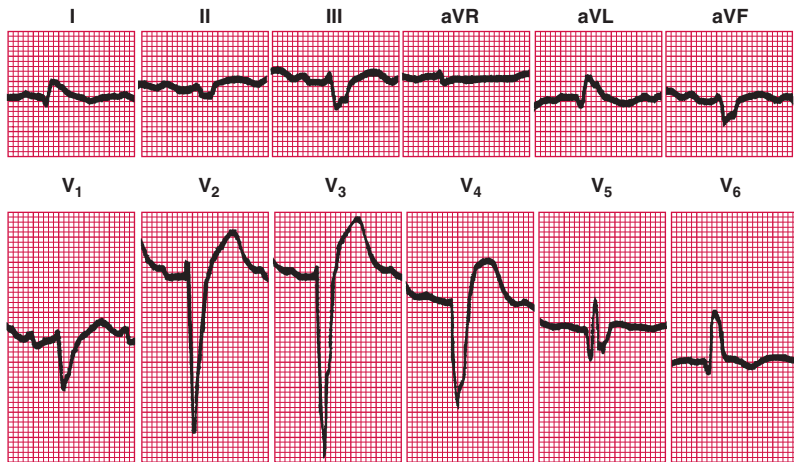


Fig. 6-31. Complete left bundle branch block with MI proved by autopsy. The ECG diagnosis of MI is based on the Q waves in leads I, aVL, V₅, and V₆. An autopsy performed 10 days later showed severe generalized atherosclerosis with total occlusion of the left circumflex artery. There was an extensive recent lateral wall MI in addition to a previous one. Left ventricular hypertrophy also was present. (From Chou TC: *Electrocardiography in Clinical Practice*, 4th ed., Philadelphia, 1996, WB Saunders, Elsevier Science.)

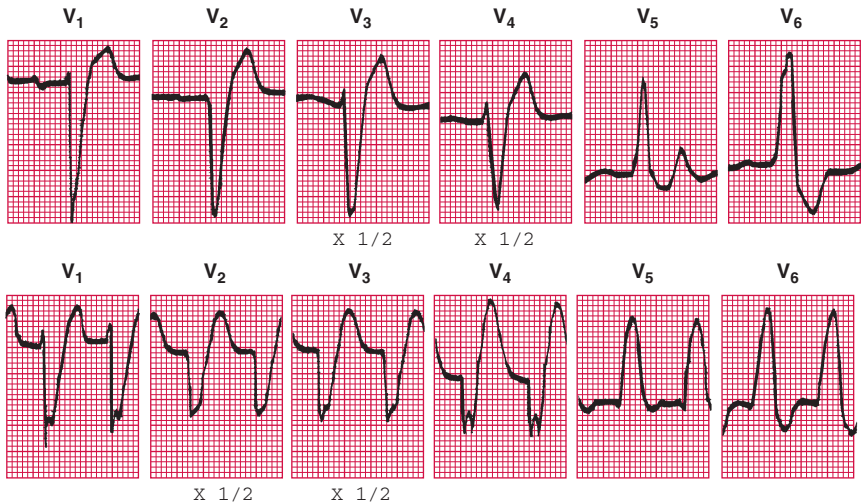


Fig. 6-32. Left bundle branch block and myocardial infarction. The patient was a 57-year-old man with a history of hypertension and coronary artery disease. The tracing at top was recorded after he developed congestive heart failure and experienced more frequent attacks of angina pectoris. It shows first-degree atrioventricular block, complete LBBB with a QRS duration of 0.18 second, and a digitalis effect. Six weeks later, he developed severe substernal chest pain and episodes of ventricular tachycardia. The ECG at bottom shows the loss of R waves in leads V₃ and V₄ and the development of a small Q wave in lead V₅. The patient died 5 days later. At autopsy, the heart weighed 1,200 g with notable biventricular hypertrophy. Severe coronary artery disease was present, with a massive acute anterior MI. An old inferior MI and fatty degeneration and infiltration of the interventricular septum also were observed.

- A reversal of R wave progression in the right and midprecordial leads (R waves in V_1 and V_2 that decrease in amplitude in V_3 and V_4) may indicate anterior infarction, but false-positive diagnoses are common.

New Diagnostic Information

Abnormal ST segment deviations occur during infarction and ischemia in patients with LBBB, and these deviations having been documented during percutaneous interventions in patients with LBBB.

- Discordant ST segment deviations are an exaggeration of normal ST segment elevation in leads V_1 to V_4 that possess a dominant S wave. Figures 6-33 and 6-34 show extensive ST segment elevation in leads V_2 , V_3 , and V_4 indicating acute injury pattern manifested by discordant ST segment elevation, which is equal to or exceeds the QRS amplitude in leads V_2 through V_4 .
- In patients with LBBB and acute onset of chest pain, electrocardiographic features of inferior infarction are reflected by ST segment eleva-

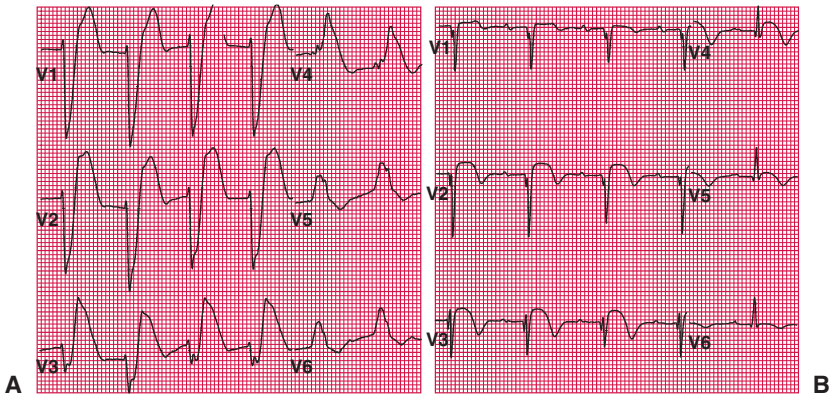


Fig. 6-33. Precordial leads of an 84-year-old man with acute myocardial infarction of the anterior wall. **A**, LBBB with acute injury pattern causes discordant ST segment elevation, which in leads V_2 and V_3 exceeds 1 mV. **B**, One day later, there is evolution of the infarction pattern without LBBB. Cardiac catheterization revealed severe three-vessel coronary artery disease with apical akinesis and a left ventricular ejection fraction of 30%. (From Chou TC: *Electrocardiography in Clinical Practice*, 5th ed., Philadelphia, 2001, WB Saunders, Elsevier Science.)

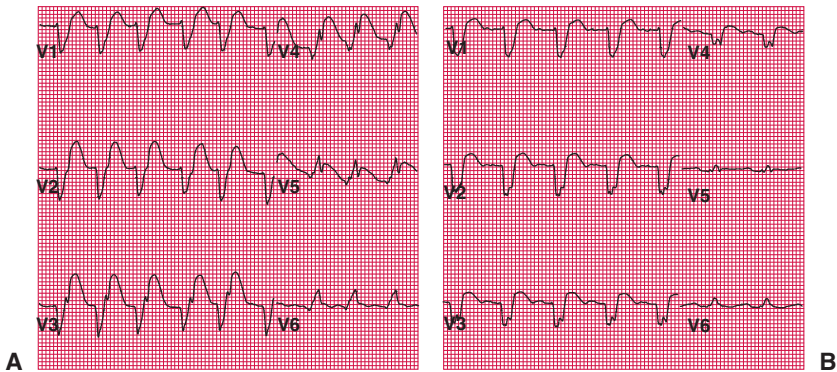


Fig. 6-34. Precordial leads of a 45-year-old man with LBBB and acute myocardial infarction of the anterior wall. **A**, Acute injury pattern manifested by discordant ST segment elevation, which is equal to or exceeds the QRS amplitude in leads V_2 through V_4 . **B**, One day later, there is evolution of the infarction pattern with decreasing ST segment elevation and beginning terminal T wave inversion in leads V_2 through V_4 . Note the Cabrera sign (notch on the S ascent in leads V_2 through V_4). Coronary angiography revealed a high-grade complex stenotic lesion in the proximal left anterior descending coronary artery. There was anterior apical akinesis with an estimated left ventricular ejection fraction of 40%. (From Chou TC: *Electrocardiography in Clinical Practice*, 5th ed., Philadelphia, 2001, WB Saunders, Elsevier Science.)

tion observed in inferior leads with concordant reciprocal ST segment depression in leads V_1 through V_4 . The concordant reciprocal ST segment depression is in the opposite direction to the usual secondary ST segment elevation observed in V_1 through V_4 in patients with LBBB. These discordant and concordant patterns appear to have a specificity of 92% to 96%; the sensitivity is, however, low.

RIGHT BUNDLE BRANCH BLOCK AND INFARCTION

- Right bundle branch block (RBBB) occurs in approximately 15% of patients with acute MI.
- RBBB may be associated with deep Q waves in leads III and aVF without infarction. MI is likely only if there is an added Q wave in lead II.
- RBBB with infarction is often accompanied by left anterior fascicular block (see Fig. 9-8).

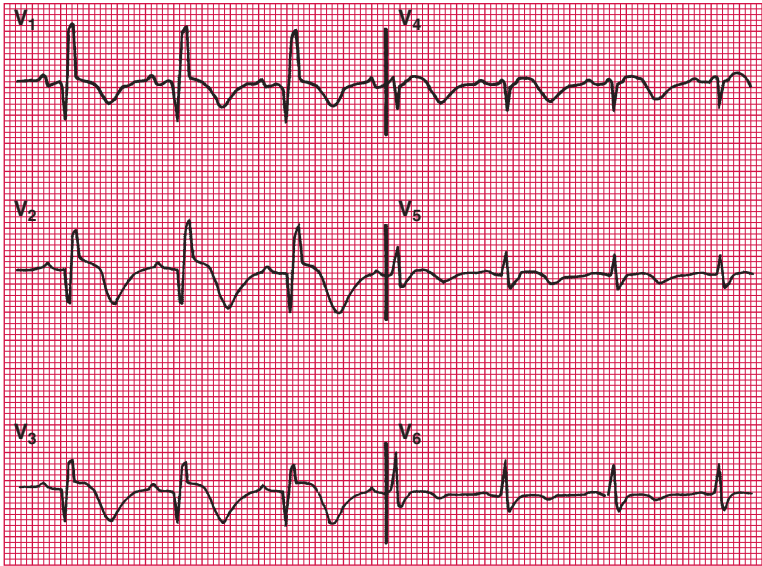


Fig. 6-35. Right bundle branch block with acute anterior infarction. Loss of anterior depolarization forces results in QR-type complexes in the right precordial to midprecordial leads, with ST elevations and evolving T wave inversions (V_1 through V_6). (From Braunwald E: *Heart Disease: A Textbook of Cardiovascular Medicine*, 6th ed., Philadelphia, 2001, WB Saunders, Elsevier Science.)

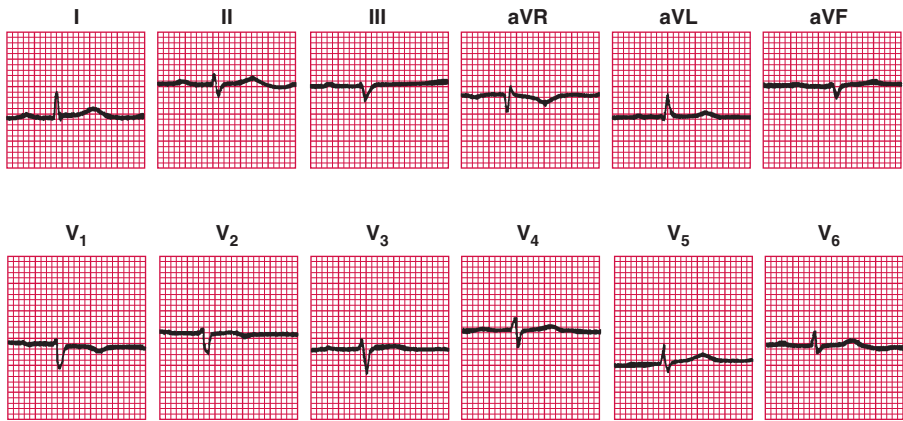
- RBBB can be associated with Q waves in leads V_1 and V_2 without infarction. Added Q waves in V_3 and beyond suggests infarction. Figure 4-10 indicates vector forces; Fig. 6-35 shows RBBB and acute anterior MI.

LOW-VOLTAGE QRS

ECGs should be recorded with the graph paper moving at 25 mm/s. At this speed, a 1-mm square on the horizontal plane equals 0.04 second. The voltage of the P wave, QRS complex, and T wave are measured vertically with reference to the calibration or standardization, which should be set at 1 mV = 10 mm. With this universal standardization, a 1-mm square in a vertical direction measures 0.1 mV.

Criteria for Low-Voltage QRS

- In all limb leads, the amplitude of the entire QRS complex (R + S) is <5 mm.
- In each of the precordial leads, the amplitude of the entire QRS complex (R + S) is <10 mm.



3156 70F

Fig. 6-36. Myxedema heart disease. The patient is a 70-year-old woman with a 15-year history of myxedema. Symptoms and signs of myxedema recurred 1 year after she stopped taking her medication. She has no symptoms of coronary artery disease. The heart is not enlarged on radiographic examination. The ECG shows first-degree atrioventricular block. There is low voltage of the P waves and the QRS complexes, with abnormal left-axis deviation. The T waves are inverted in leads V_1 through V_3 . (From Chou TC: *Electrocardiography in Clinical Practice*, 4th ed., Philadelphia, 1996, WB Saunders, Elsevier Science.)

Causes of Low-Voltage QRS

- Obesity
- Pericardial effusion
- Constrictive pericarditis
- Myxedema (Fig. 6-36)
- Amyloidosis and other restrictive cardiomyopathy and diffuse myocardial diseases
- Pleural effusion
- COPD

7

Atrial and Ventricular Hypertrophy

CONTENTS

ATRIAL HYPERTROPHY

VENTRICULAR HYPERTROPHY

ATRIAL HYPERTROPHY

Left Atrial Hypertrophy

DIAGNOSTIC CRITERIA

- The P wave duration is ≥ 0.12 second (3 small squares) in leads II, III, or aVF. The P wave may be widely notched. These features are most apparent in lead II.
- The terminal deflection of the P waves in V_1 is downward and its duration is prolonged ≥ 0.04 second (Fig. 7-1).
- The depth of the terminal negative deflection in V_1 is ≥ 1 mm.
- The product of the depth of the terminal negative deflection in V_1 (in millimeters) and the duration in seconds (the P terminal force) is ≥ -0.04 mm s.
- The P terminal force (PTF- V_1) is determined rapidly by observation of the P wave in V_1 . The P wave terminal negative duration equal to 1 small square (0.04 second) and a depth of 1 small square (1 mm) yield a P terminal force of -0.04 mm s (Figs. 7-1 and 7-2).

RELIABILITY OF CRITERIA

The diagnostic changes are observed in patients with left atrial enlargement or hypertrophy without significant enlargement and in patients with an increase in left atrial pressure and volume.

- The combined sensitivity of PTF- $V_1 \geq -0.04$ mm s and P wave duration in II, III, or aVF > 0.10 second (100 ms) has been shown to be 82%.
- A PTF- V_1 of > -0.06 has been shown to correctly predict left atrial enlargement in 80% of cases.

From: *Contemporary Cardiology: Rapid ECG Interpretation, 3e*
by: M. Gabriel Khan © Humana Press Inc., Totowa, NJ

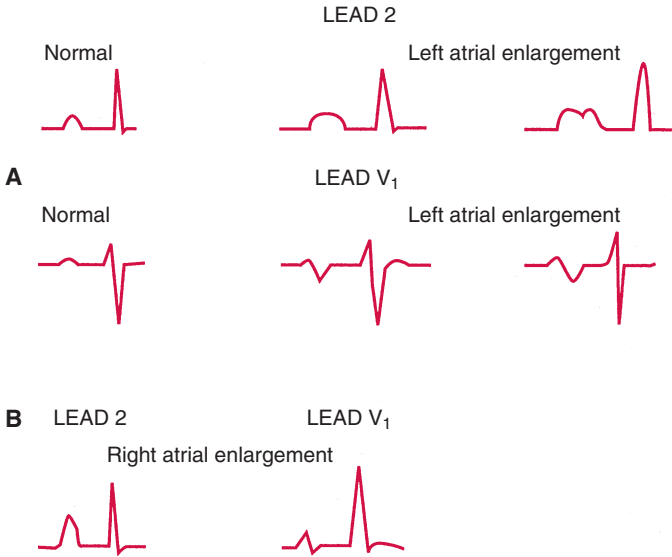


Fig. 7-1. A, Left atrial enlargement: P wave duration ≥ 3 mm (0.12 second) in lead 2. In lead V_1 , the negative component of the P wave occupies at least one small box = 1 mm \times 0.04 = P terminal force > -0.04 mm s (see Fig. 7-2). B, Right atrial enlargement: lead 2 shows P amplitude ≥ 3 mm. In V_1 , the first half of the P wave is positive and > 1 mm wide. (From Khan, M. Gabriel: *On Call Cardiology*, 3rd ed., Philadelphia, 2006, WB Saunders, Elsevier Science.)

- P wave duration > 0.10 second appears to have a specificity of approximately 85% but with a low sensitivity of $< 33\%$.

Importantly, these relationships relate to echocardiographic left atrial enlargement > 4 cm; left atrial hypertrophy may occasionally occur without significant echocardiographic enlargement, and the electrocar-

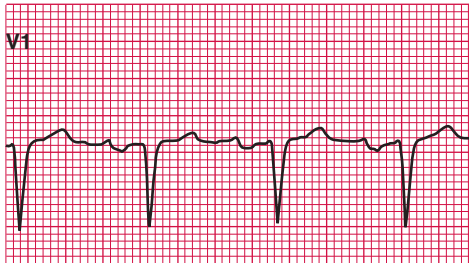


Fig. 7-2. Lead V_1 shows typical P wave pattern of left atrial enlargement.

diographic findings may be the only sign of left ventricular disease caused by hypertension and other cardiac diseases. Thus, the term left atrial abnormality is preferred to cover enlargement, hypertrophy, or increase in atrial volume or pressure.

CAUSES

It is most important to assess for the electrocardiographic features of left atrial hypertrophy, because this may be the only abnormality in the electrocardiogram in patients with various forms of heart disease. It may be the only clue to the diagnosis of underlying left ventricular hypertrophy, valvular heart disease, congenital heart disease, ischemic heart disease that has caused heart failure, left ventricular dysfunction, the various cardiomyopathies, or constrictive pericarditis. Left atrial hypertrophy is a common ECG finding. Causes of left atrial abnormality include the following:

- Mitral stenosis.
- Mitral regurgitation.
- Left ventricular failure, particularly acute pulmonary edema in which the abnormality may decrease or disappear after approximately 1 week of successful therapy.
- Left ventricular hypertrophy (LVH). (The atrium hypertrophies in response to altered left ventricular compliance).
- Aortic valve disease.

Right Atrial Hypertrophy

DIAGNOSTIC CRITERIA

- The P wave is tall and peaked with a height ≥ 2.5 mm in lead II, III, or aVF and is of normal duration (Fig. 7-3).
- The positive component of the P wave in lead V_1 , V_2 , or V_3 is tall and peaked with a height ≥ 1.5 mm.
- The P wave frontal axis is greater than 75 degrees.

HELPFUL GUIDES

- An abnormally tall P wave in leads V_1 , V_2 , and sometimes V_3 ≥ 1.5 mm is a more specific electrocardiographic sign for right atrial hypertrophy than the usual diagnostic criteria based on peaked P waves in leads II, III, or aVF (P pulmonale).
- An initial positive component of the P wave in V_1 or V_2 ≥ 0.04 second is an indication of right atrial hypertrophy. The findings in the right chest leads are not common with cor pulmonale, however; it is more

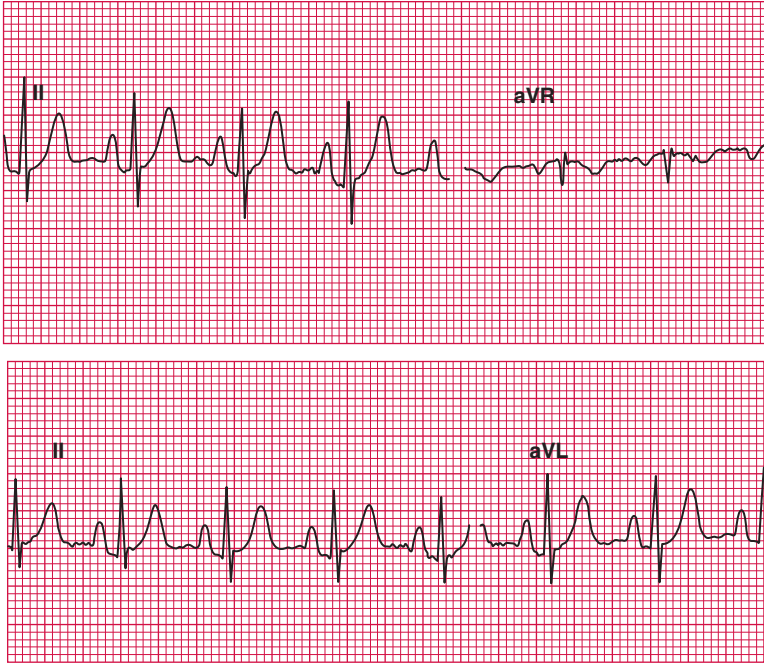


Fig. 7-3. Leads II, III, and aVF show tall, peaked P waves >2.5 mm right atrial hypertrophy.

commonly seen in children with significant congenital heart disease and in individuals with right ventricular hypertrophy.

- The typical pattern of P pulmonale seen in leads II, III, and aVF is less specific for right atrial hypertrophy than the findings in the right chest leads, but because cor pulmonale and some conditions may show no abnormalities in leads V_1 to V_3 , it is absolutely necessary to pay attention to findings in leads II, III, and aVF.
- Right atrial hypertrophy is not a common disorder, but it is important to search diligently for electrocardiographic signs of right atrial hypertrophy because the finding may lead to the discovery of significant underlying congenital heart disease and is an important clue to the presence of right ventricular hypertrophy.

CAUSES

The causes of right atrial hypertrophy include the following:

- Congenital heart disease (some forms)
- Cor pulmonale

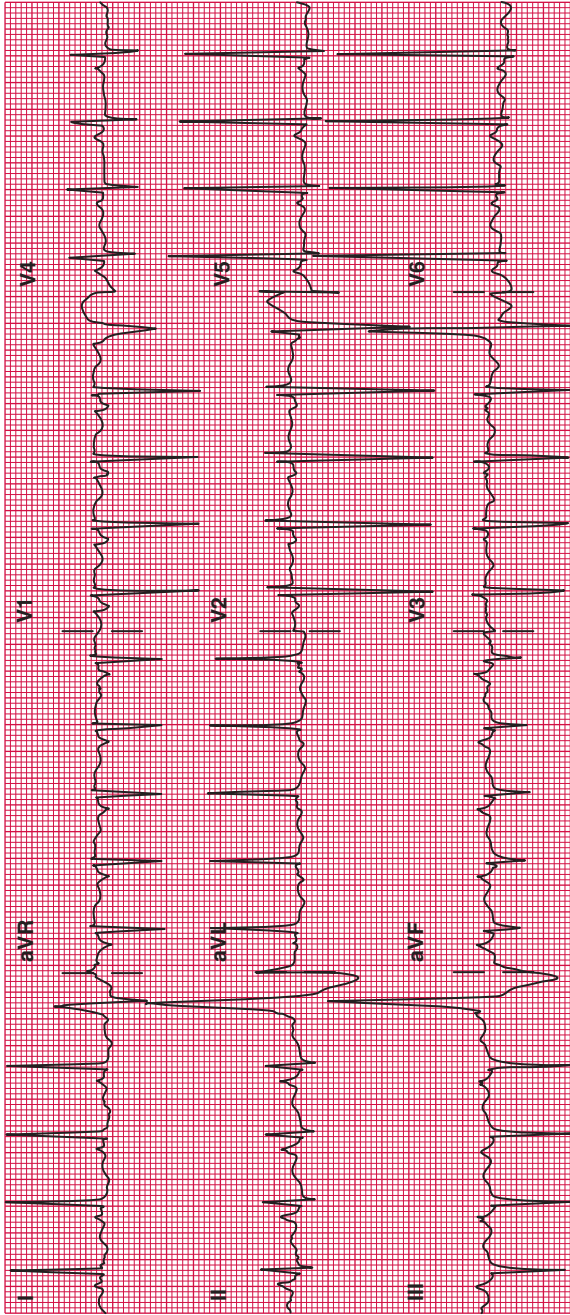


Fig. 7-4. Sinus tachycardia 120 beats/min, ventricular premature beats, RSR', V₁, V₂. Lead V₁ shows characteristics of right and left atrial hypertrophy. Voltage increased in V leads that satisfies the criteria for LVH; ST-T changes V₄ and V₅, which can be caused by LVH or ischemia.

- Pulmonary stenosis
- Pulmonary hypertension
- Tricuspid stenosis
- Tricuspid regurgitation
- Right ventricular hypertrophy (RVH)

Bilateral Atrial Hypertrophy

Bilateral enlargement is indicated by the following:

- A large biphasic P wave in lead V₁, with the positive component >1.5 mm and the initial terminal negative deflection reaching 1 mm in depth and with a duration of 0.04 second (see Figs. 7-1, 7-2, 7-4, 7-9, and Fig. 3-3).
- Peaked P waves ≥ 1.5 mm in V₁, V₂, and V₃.
- Notched P waves in V₄ to V₆.
- P wave amplitude ≥ 2.5 mm and duration ≥ 0.12 second in the limb leads.

VENTRICULAR HYPERTROPHY

Left Ventricular Hypertrophy

The genesis of the normal QRS complex is described in Chapter 1, and the genesis of the QRS complex in LVH is shown in Fig. 7-5. In LVH, the left atrium becomes hypertrophied to compensate for decreased compliance of the compromised left ventricle. Left atrial hypertrophy is an early ECG manifestation of LVH.

DIAGNOSTIC CRITERIA FOR PATIENTS OLDER THAN 35 YEARS OF AGE

The electrocardiographic voltage criteria for the diagnosis of left ventricular hypertrophy are imprecise and unreliable and have a low sensitivity of approximately 50%; the specificity approaches 94%.

SUPPORTING EVIDENCE

Asymmetric ST segment depression and T wave inversion in V₅ and V₆: left ventricular strain pattern; the proximal descending limb of the inverted T wave has a slow descent, and the ascending limb rises steeply. These changes should be maximal in V₅ and V₆ and minimal in V₄ (see Figs. 7-6, 2-25, and 6-27). Note that ST-T changes that are prominent in V₃ and V₄ most likely reflect ischemia. Changes in V₅ and V₆ with no changes in V₃ and V₄ may be caused by LVH, ischemia, or both (see Fig. 8-12A and B).

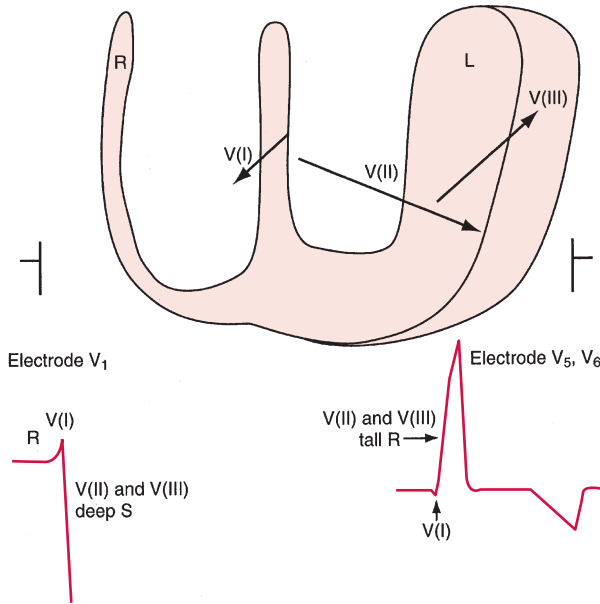


Fig. 7-5. The contribution of vector II to the ECG features of left ventricular hypertrophy. The thicker the left ventricular muscle, the greater the magnitude of vector II; thus, the deep S wave in lead V_1 and tall R wave in leads V_5 and V_6 . Note that the T wave has a gradual descending and a steep ascending limb “strain pattern.” (From Khan, M. Gabriel: *On Call Cardiology*, 2nd ed., Philadelphia, 2001, WB Saunders, Elsevier Science.)

The QRS duration must be <0.12 second.

1. Sokolow-Lyon Voltage Criteria

- R wave in lead I + S wave in lead III >25 mm (2.5 mV)
- R wave in aVL >11 mm (1.1 mV)
- R wave in V_6 >26 mm (2.6 mV)
- R wave in V_6 + S wave in V_1 >35 mm (3.5 mV) (Figs. 7-6 and 2-25)

The criteria reportedly have a 49% sensitivity and a specificity of approximately 90%.

- Left axis is supportive of LVH but is not necessary for the diagnosis.
- Onset of intrinsicoid deflection in V_5 or V_6 >0.05 second.

2. Cornell Voltage Criteria

- S wave in V_3 + R wave in aVL >28 mm (2.8 mV) in men or >20 mm (2.0 mV) in women; the sensitivity is approximately 49% and the specificity is approximately 90%.

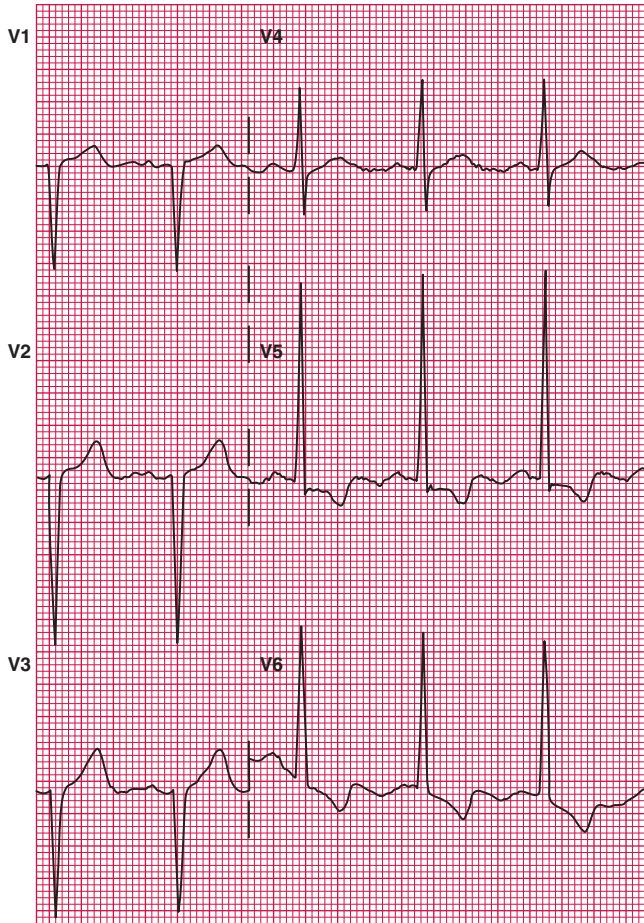


Fig. 7-6. Significant increase in voltage of R wave in V_5 or V_6 and S wave in V_1 or V_2 >35 mm. There is asymmetric ST segment depression and T wave inversion in V_5 and V_6 , features typical of left ventricular hypertrophy; note the lack of ST-T changes in V_4 .

3. Author's Criteria for Patients Older Than 35 Years of Age: 3 points = probable LVH; 4 points = significant LVH
 - S wave in V_1 + R wave in V_6 ≥ 35 mm = 2 points
 - R wave in aVL + S wave in V_3 >28 mm in men or >20 mm in women = 3 points
 - Left atrial enlargement with P terminal force ≥ -0.04 mm/s or P wave duration ≥ 0.12 in leads II, III, or aVF = 2 points
 - Asymmetric ST depression in V_5 and V_6 = 2 points

4. Romhilt-Estes Scoring System

- R wave in the limb leads ≥ 20 mm, S wave in lead V_1 or $V_2 \geq 30$ mm, or R wave in lead V_5 or $V_6 \geq 30$ mm = 3 points
- Negativity of P wave in $V_1 > 1$ mm in depth with duration > 0.03 second = 3 points
- ST-T wave changes (if patient is not taking digoxin) = 3 points (if patient is taking digoxin = 1 point)
- Presence of left axis = 2 points
- A score of 4 points indicates probable LVH, and a score of 5 or more points indicates LVH. The sensitivity is approximately 30% and the specificity is approximately 90%.

PITFALLS IN DIAGNOSIS OF LEFT VENTRICULAR HYPERTROPHY

The preceding criteria do not apply in subjects younger than age 35 years, because QRS voltage can be notably increased in healthy young individuals (Fig. 7-7; *see* Table 2-1).

- QRS voltage appears to be increased by left anterior fascicular block.
- QRS voltage is higher in African Americans than in Caucasians.
- Conditions that decrease QRS voltage and that may mask the ECG signs of LVH include severe chronic obstructive pulmonary disease; pericardial effusion; large, old anterior infarctions; myxedema (*see* Fig. 6-34); and heart muscle diseases such as dilated cardiomyopathy, amyloidosis, and scleroderma.

Right Ventricular Hypertrophy

The QRS duration must be < 0.12 second because the diagnosis of RVH cannot be made accurately in the presence of right bundle branch block (RBBB) or Wolff-Parkinson-White (WPW) syndrome, posterior MI, dextroposition.

DIAGNOSTIC CRITERIA FOR PATIENTS OLDER THAN 30 YEARS OF AGE

Two or more of the following criteria are required for the diagnosis of RVH:

- Right-axis deviation greater than $+110$ degrees
- Tall R wave in $V_1 \geq 7$ mm (can be a normal variant), S wave in $V_1 \leq 2$ mm, R/S ratio in $V_1 > 1$, R/S ratio in V_5 or $V_6 \leq 1$ (Fig. 7-8), patient older than age 30 years (*see* Table 2-1)
- S wave in V_5 or $V_6 > 2$ mm
- qR pattern in V_1 (not commonly observed but increases specificity) (Figs. 7-9 and 7-10)

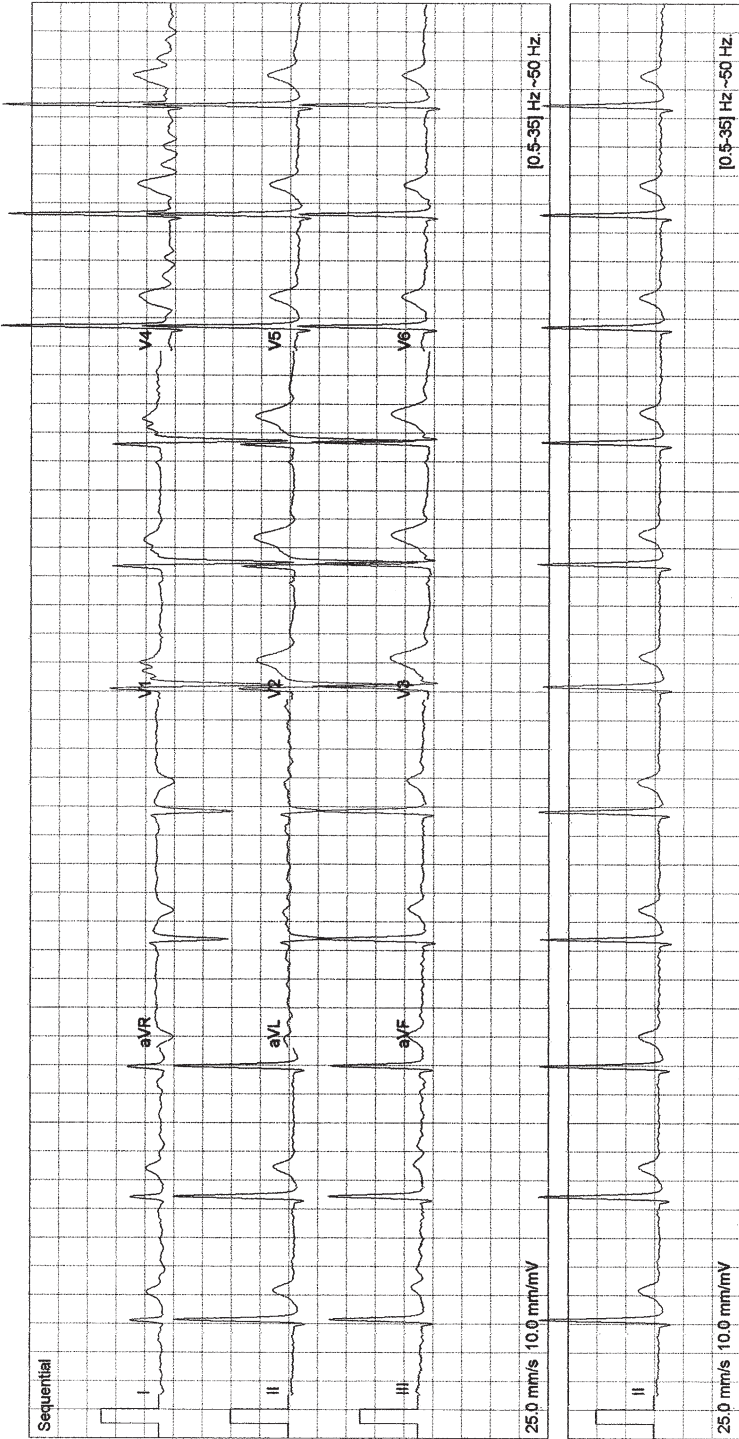


Fig. 7-7. High QRS voltage: S in $V_1 + R$ in V_5 or $V_6 = 54\text{ mm}$ (5.4 mV) in a normal 24 year old male. Caution with voltage criteria in individuals younger than age 30 and think of LVH if additional features are present (left atrial hypertrophy, and /or ST-T changes, the strain pattern).

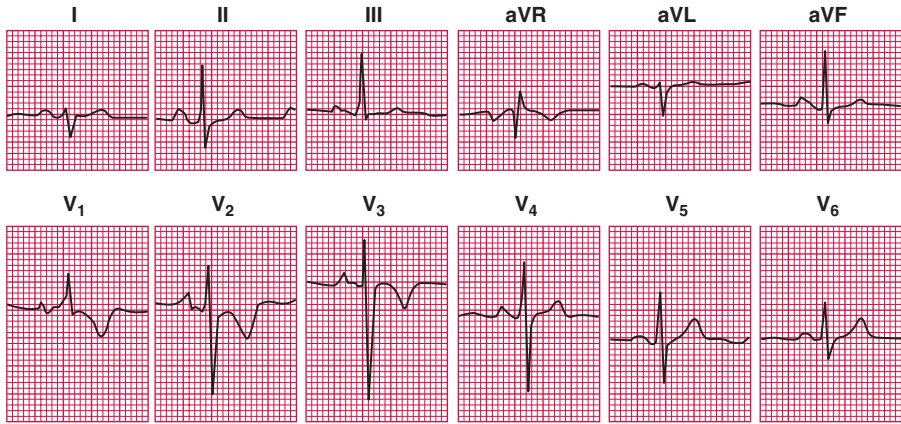


Fig. 7-8. Severe mitral stenosis. The patient is a 47-year-old man with severe mitral stenosis proved at surgery. In the ECG, the P waves are consistent with biatrial enlargement. The abnormal right axis deviation with an R/S ratio greater than 1 in lead V₁ and the T wave inversion in the right precordial leads are consistent with right ventricular hypertrophy. (From Chou TC: *Electrocardiography in Clinical Practice*, 4th ed., Philadelphia, 1996, WB Saunders, Elsevier Science.)

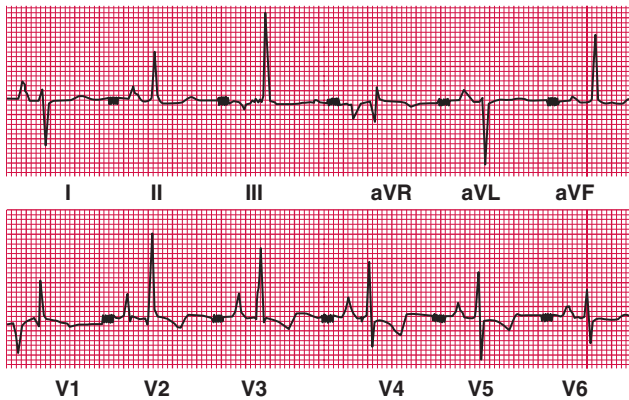


Fig. 7-9. Right ventricular hypertrophy. Q wave in V₁ suggests that the right ventricular pressure exceeds the left ventricular pressure. The left axis of the P wave and the prominent negative P wave in lead V₁ are unusual and most likely are a result of a markedly enlarged right atrium projecting to the left and posteriorly. The prominent P waves in leads V₂ and V₃ are diagnostic of right atrial enlargement. (From Braunwald E: *Heart Disease: A Textbook of Cardiovascular Medicine*, 5th ed., Philadelphia, 2001, WB Saunders, Elsevier Science.)

- Most important is scrutiny for right atrial hypertrophy: peaked P waves with an amplitude in V_1 , V_2 , or $V_3 \geq 1.5$ mm (*see* Fig. 7-9) or ≥ 2.5 mm in II, III, or aVF (this increases specificity)

SUPPORTING EVIDENCE

- Onset of intrinsicoid deflection in $V_1 = 0.035$ to 0.055 second
- ST-T strain pattern in V_1 through V_3 (*see* Fig. 7-9)
- Right atrial enlargement

PITFALLS IN DIAGNOSIS OF RIGHT VENTRICULAR HYPERTROPHY

RVH and right atrial enlargement are uncommon ECG diagnoses; cardiologists should refrain from making an ECG diagnosis of RVH in the presence of the following conditions:

- RBBB
- WPW syndrome
- True posterior myocardial infarction
- In children (the preceding ECG findings can be a normal variant)
- Early transition (the R wave is increased in V_1 and V_2 , but the R/S ratio in V_5 or V_6 is greater than 1)
- Dextroposition (*see* Table 2-3)
- Hypertrophic cardiomyopathy (a tall R wave in V_1 with an R/S ratio greater than 1 may be observed)

8

T Wave Abnormalities

CONTENTS

NORMAL DIRECTION OF T WAVE
ABNORMALITIES OF T WAVE
U WAVES

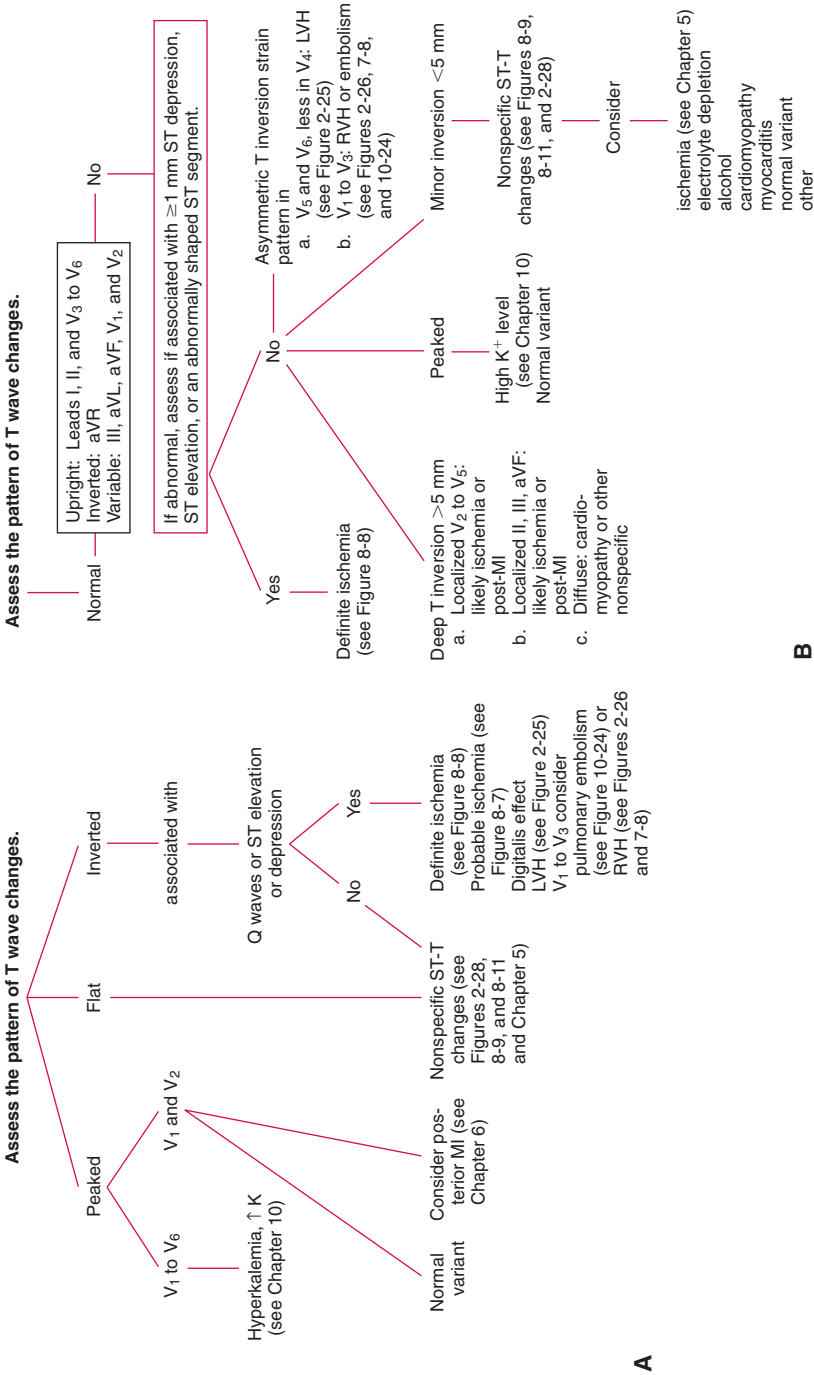
The T wave represents repolarization, the recovery period of the ventricles. As emphasized in Chapter 5, the skillful interpreter focuses on the ST segment and does not try to make diagnoses based on T wave changes. T wave changes often are nonspecific and always should be interpreted in light of associated abnormalities of the ST segment and clinical findings. An algorithmic approach for the interpretation of T wave changes is depicted in Fig. 8-1.

NORMAL DIRECTION OF T WAVE

- The T wave is always upright (positive) in leads I (1), II (2), and V₄ through V₆ (Figs. 8-2 and 8-3).
- The T wave is normally upright in lead aVF if the QRS complex is <5 mm tall, but the T wave can be flat or inverted.
- The T wave is variable in leads III and aVL.
- The T wave is always inverted in aVR (*see* Fig. 8-2).
- The T wave in V₁ is inverted in approximately 50% of women and in <33% of men (*see* Fig. 8-2).
- In women with a persistent juvenile pattern, the T wave is inverted in V₁ and V₂ and sometimes in V₃ (Fig. 8-4). This finding is common in African-American women.
- Diagnoses based solely on the appearance of abnormal-looking T waves are fraught with danger. Figures 8-4 to 8-6 indicate errors that can be made in the interpretation of T or ST-T wave changes.

From: *Contemporary Cardiology: Rapid ECG Interpretation, 3e*
by: M. Gabriel Khan © Humana Press Inc., Totowa, NJ

STEP 8



B

Fig. 8-1. Step-by-step method for accurate ECG interpretation. **A**, Step 8: Assessment of T wave changes. LVH, Left ventricular hypertrophy; MI, myocardial infarction; RVH, right ventricular hypertrophy. **B**, Step 8: Alternative methods for the assessment of T wave changes.

A

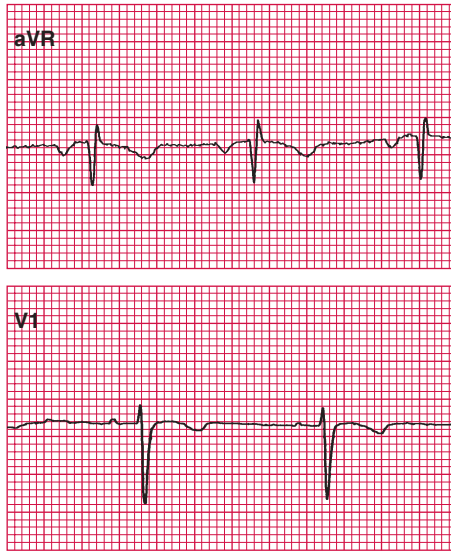
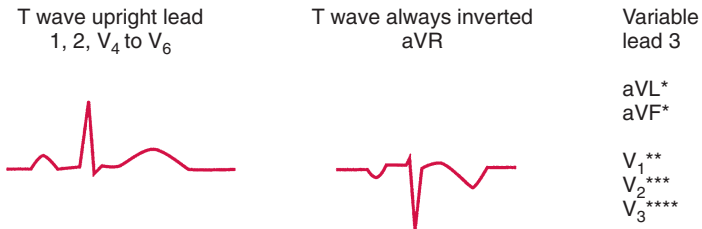


Fig. 8-2. Normally occurring negative T waves in aVR and V₁.



- * = usually upright; can be inverted if R wave <5 mm.
- ** = inverted in >50% of women and <20% of men who are >30 years of age.
- *** = usually upright; can be inverted with juvenile pattern.
- **** = usually upright; rarely flat or biphasic in women or with juvenile pattern.

Fig. 8-3. T wave, normal variability. (From Khan, M. Gabriel: *On Call Cardiology*, 3rd ed., Philadelphia, 2006, WB Saunders, Elsevier Science.)

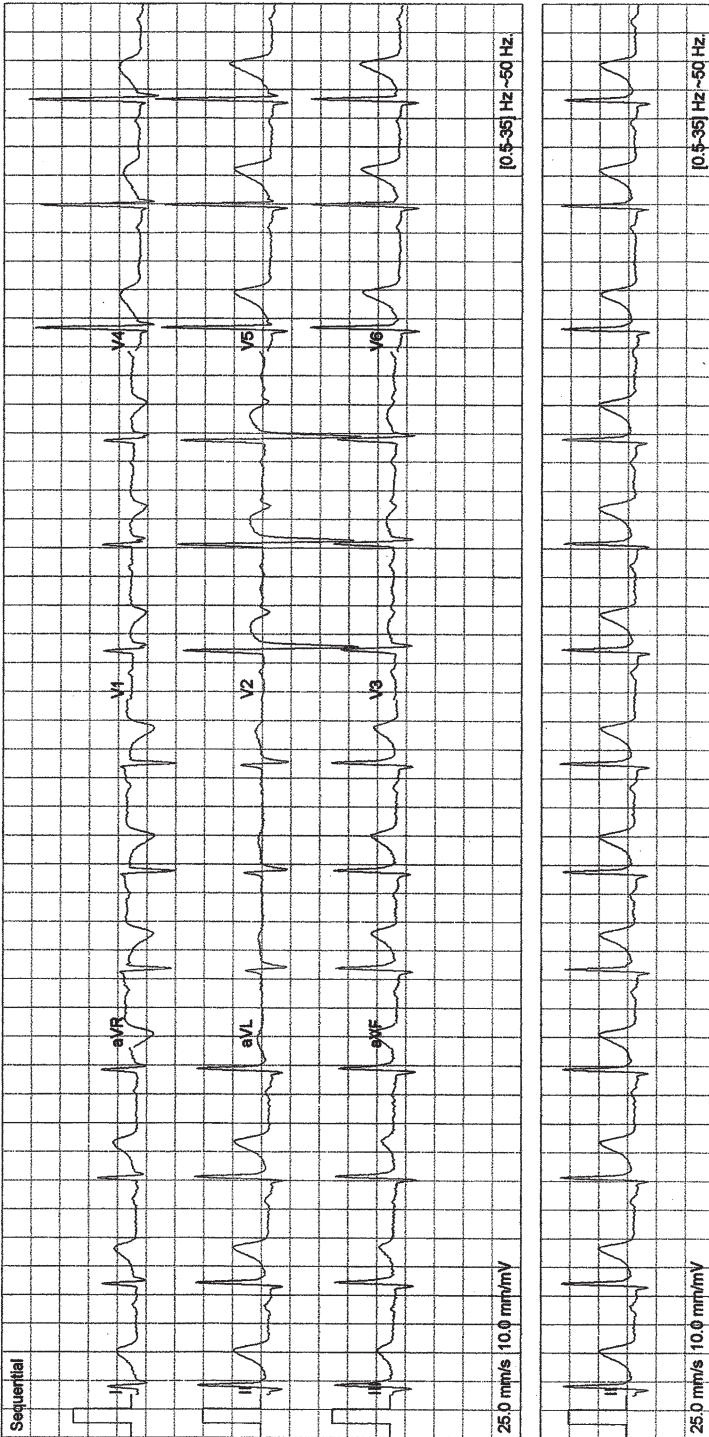


Fig. 8-4. Sinus rhythm 80/min; ST segment coving with juvenile T wave inversion in leads V₁-V₃; normal variant in this 10 year old male. Also, normal variant ST elevation in I, II, III, aVF, V₅, V₆ (so called early repolarization changes) The diffuse ST segment elevation and PR elevation in aVR might suggest pericarditis. But, in pericarditis the J point level almost equals the height of the T wave in V₆. Clinical correlation required.

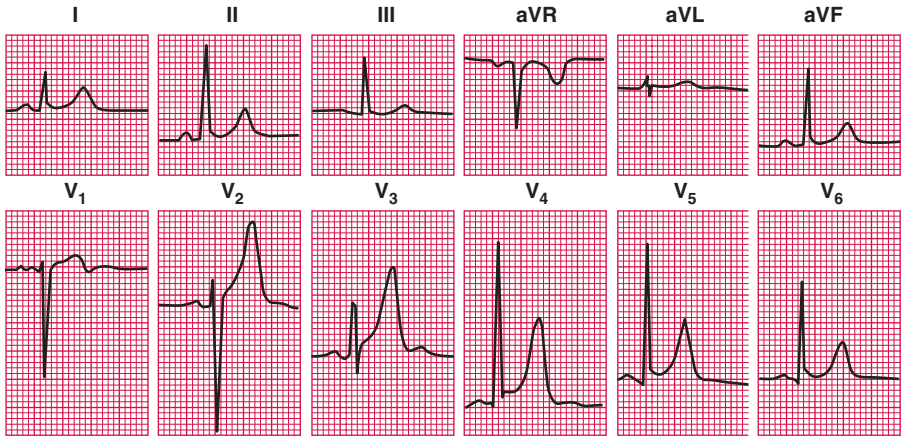


Fig. 8-5. Prominent T waves in a healthy 31-year-old man. ST segment elevation also is present in the precordial leads. They may be mistaken as signs of myocardial injury and ischemia or acute pericarditis. (From Chou TC: *Electrocardiography In Clinical Practice*, 4th ed., Philadelphia, 1996, WB Saunders, Elsevier Science.)

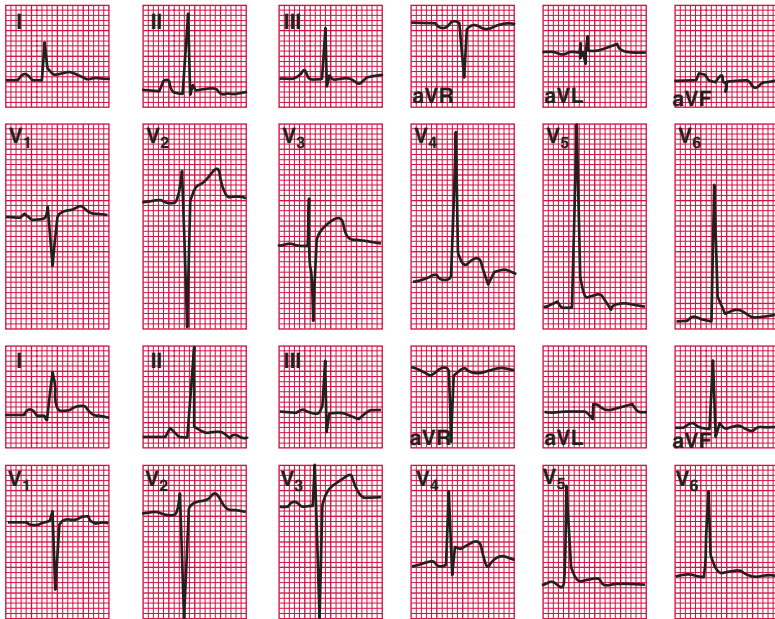


Fig. 8-6. Benign ST and T wave changes in a healthy 24-year-old professional athlete. The changes, especially in leads V₄ and V₅, mimic myocardial injury and ischemia and remained the same 15 months later. (From Chou TC: *Electrocardiography in Clinical Practice*, 4th ed., Philadelphia, 1996, WB Saunders, Elsevier Science.)

ABNORMALITIES OF T WAVE

Inverted T Wave

- T wave inversion in leads I, II, and V₃ through V₆ is abnormal.
- If T wave inversion is accompanied by abnormal coving of the ST segment (horizontal or down-sloping ST segment depression >1 mm; Figs. 8-7 and 8-8), a diagnosis of ischemia can be made with confidence.

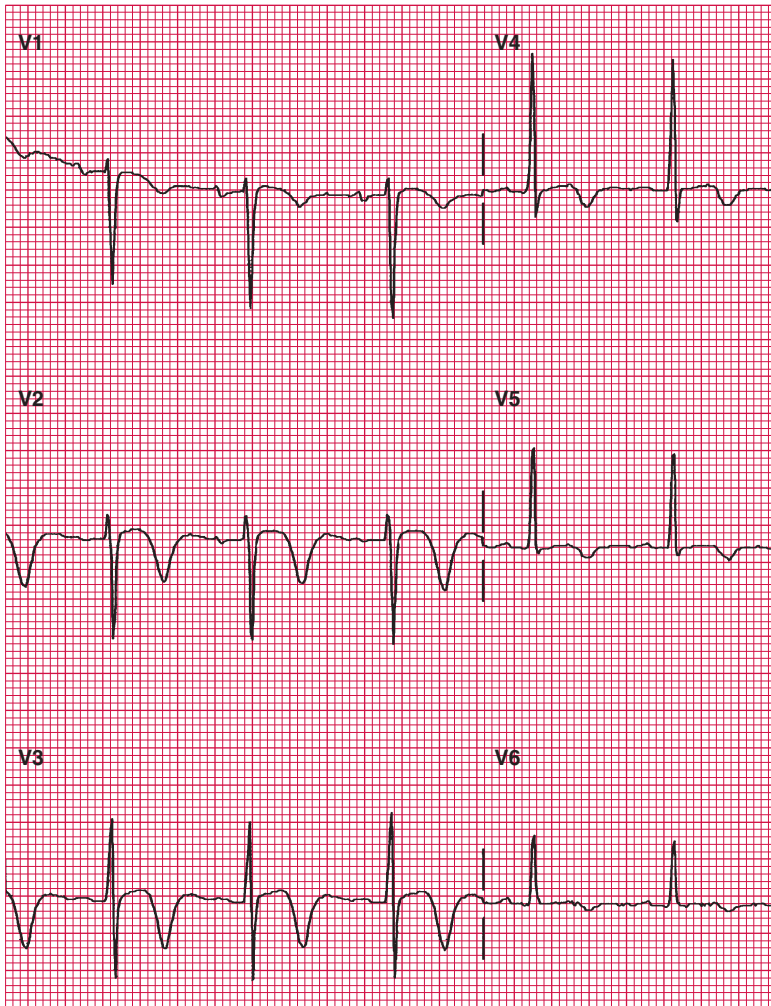


Fig. 8-7. T wave inversion in V₂ through V₅ associated with abnormal curvature of the ST segment; likely caused by ischemia.

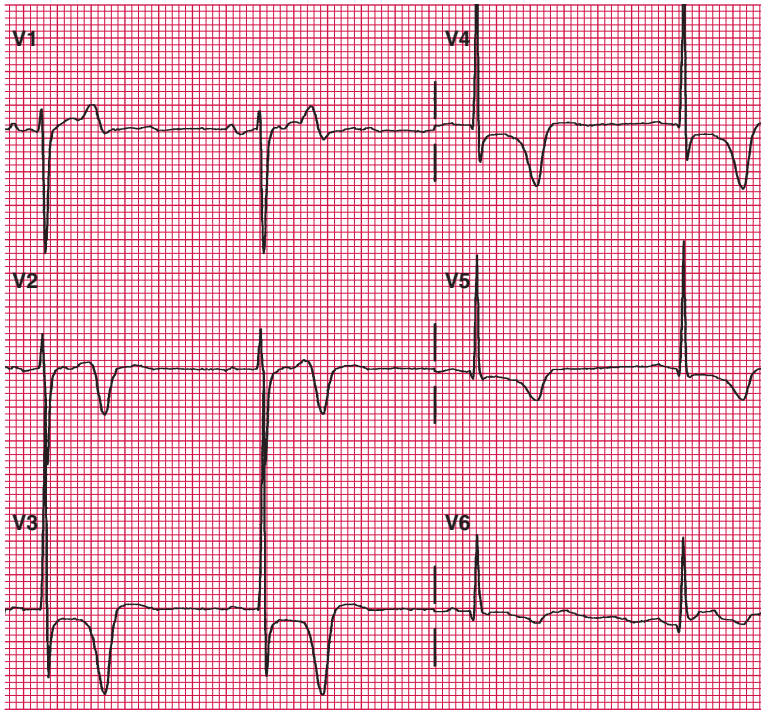


Fig. 8-8. Tracing from a 53-year-old woman with a 1-week history of unstable angina. Tracing taken in the absence of pain. Deep T wave inversion in V₂ through V₄. Note the abnormal coving of the ST segment and “hitched-up” ST segment in V₁ and V₂. Definite ischemia is indicated.

- If T wave inversion is associated with <1-mm ST depression or an upsloping depression, the finding is nonspecific (Fig. 8-9) and can be caused by a host of cardiac and noncardiac conditions.
- Isolated T wave inversion is nonspecific (Figs. 8-10 and 8-11) but ischemia cannot be excluded.
- The 5-year mortality rate in patients with moderate T wave inversion associated with the presence of heart disease reportedly is 21% versus 3% when heart disease is absent.

Diffuse, deep T wave inversion in the absence of ST segment elevation or significant depression is not diagnostic (*see* Fig. 8-10) and can be associated with the following:

- Ischemia
- Post-MI evolutionary changes

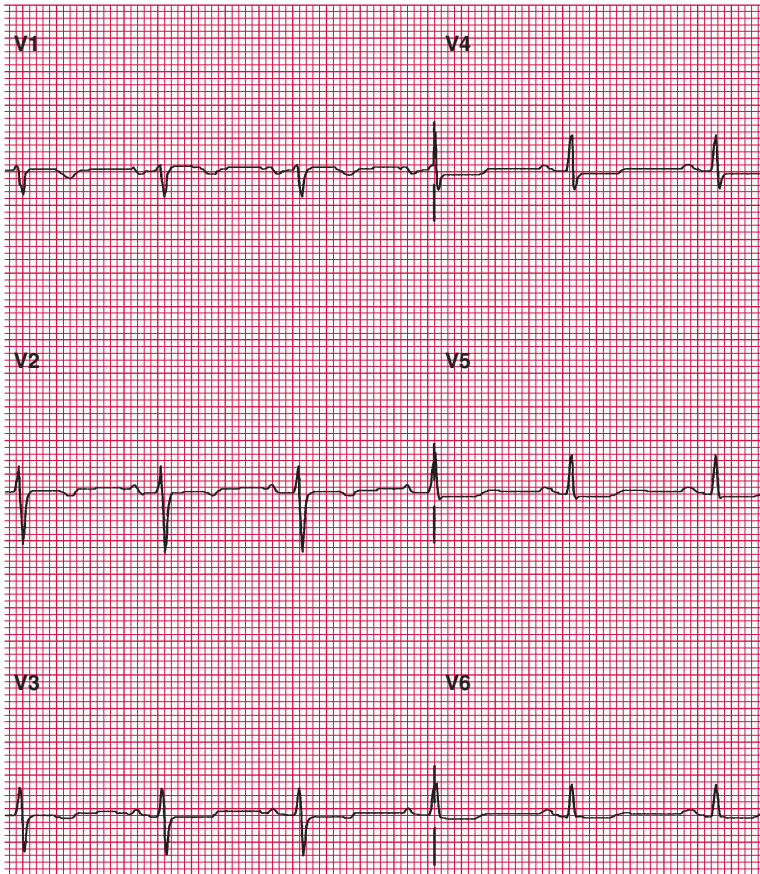


Fig. 8-9. Minimal T wave inversion in V_2 through V_4 with <1 -mm ST depression: nonspecific ST-T changes; cannot exclude ischemia.

- Left ventricular hypertrophy with or without ischemia (Fig. 8-12)
- Post–Stokes-Adams attack
- Post–supraventricular tachycardia or ventricular tachycardia
- Myocarditis
- Pericarditis
- Apical cardiomyopathy (causes giant T wave inversion) (Fig. 8-13)
- Pulmonary embolism
- Cardiomyopathies
- Primary or secondary cardiac tumors
- Cocaine abuse

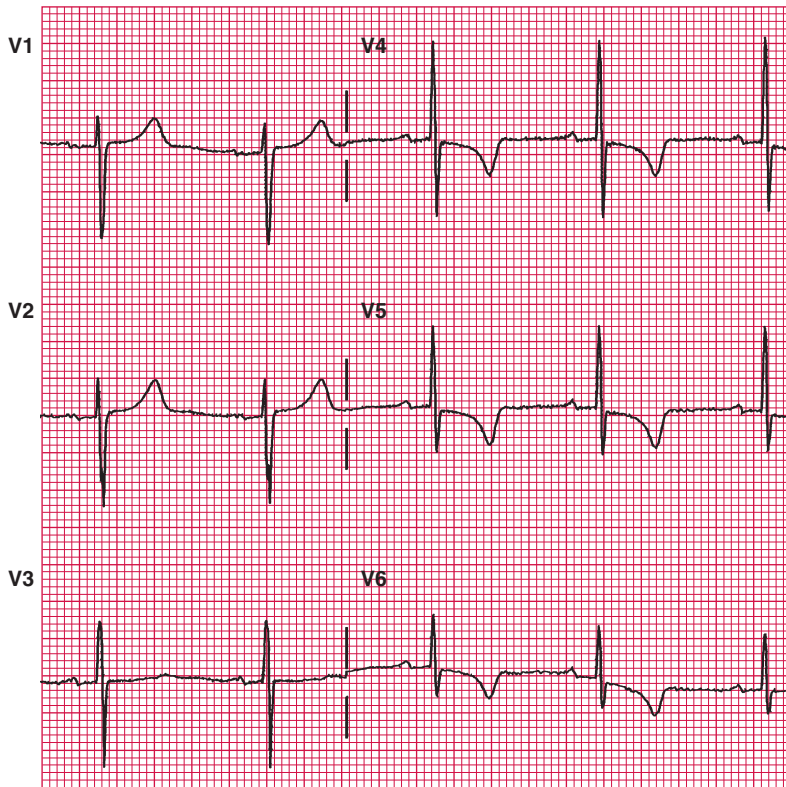


Fig. 8-10. T wave inversion in V₄ through V₆; similar changes were observed in leads aVL, II, III, and aVF: nonspecific ST-T changes; cannot exclude ischemia.

- Alcohol abuse
- Electrolyte imbalance
- Subarachnoid hemorrhage (*see* Figs. 8-13 and 8-14)
- Acute pancreatitis and gallbladder disease
- Pheochromocytoma
- Other causes

Symmetric T wave inversion is four times more common in women than it is in men. Interpreting symmetric, deep T wave inversion as a sign of ischemia without considering other diagnoses is a common error.

Minor T wave inversion not associated with significant ST segment changes can be caused by all of the aforementioned conditions, as well as by the following:

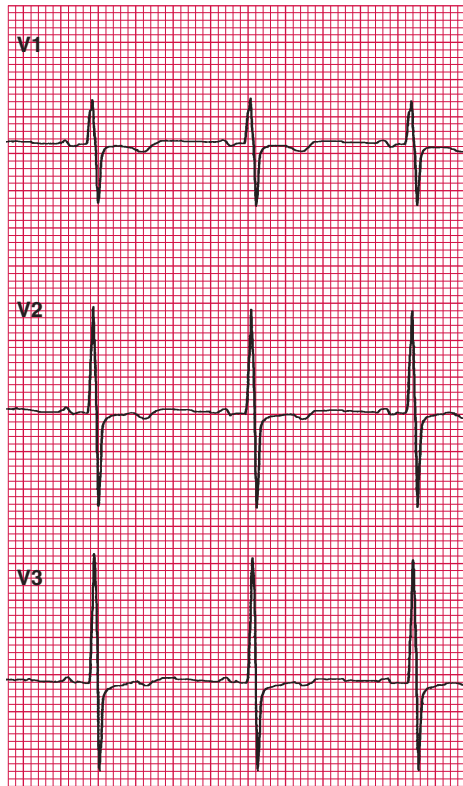


Fig. 8-11. Tracing from a 50-year-old man with no history of heart disease; non-specific ST-T wave changes as seen from V₁ through V₃; the limb leads show no abnormality. Abnormal ECG.

- Hyperventilation
- Postprandial (after the patient has a meal or a cold drink, the tracing normalizes in the fasting state)
- Mitral valve prolapse
- Intraventricular conduction defects
- Pneumothorax
- Ventricular hypertrophy (*see* Chapter 7)

Minor T wave inversion not associated with significant ST segment changes also can be a normal variant. T wave inversion occurs in V₁ through V₃ in some young adults as a persistent juvenile pattern; this is more common in women (*see* Fig. 8-4). Benign T wave inversion in V₄ through V₆ may be observed in healthy young adults and may be associated with ST elevation as a normal variant (*see* Chapter 5).

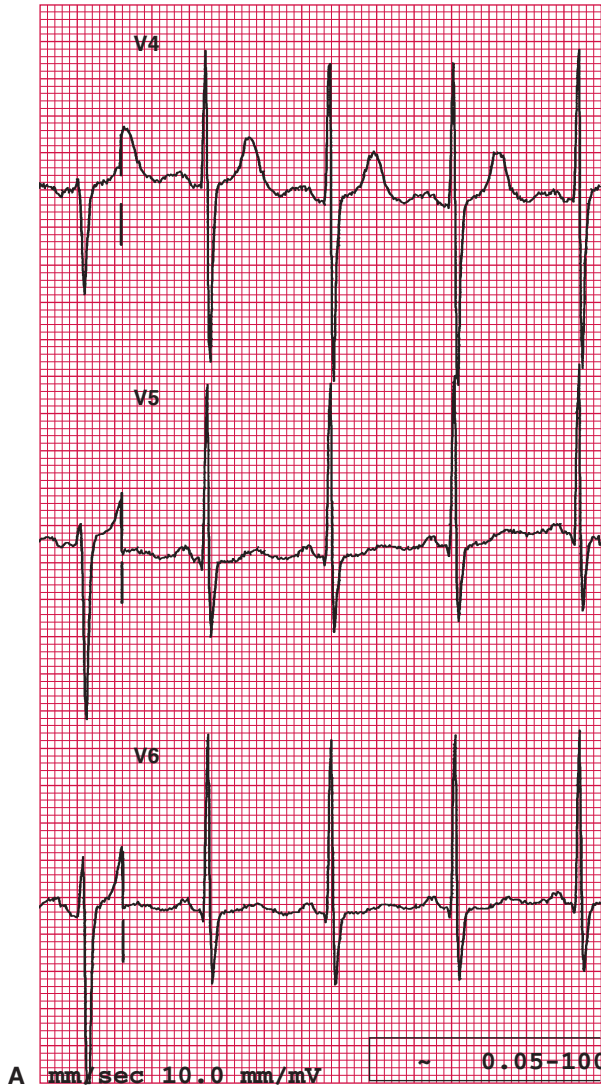


Fig. 8-12. A, Voltage increase: probable left ventricular hypertrophy; compare with (B). B, Same patient 12 hours later: The ST-T in V₄ through V₆, which was caused by ischemia, may have been interpreted incorrectly as left ventricular hypertrophy with “strain” pattern if no comparison was available.

(continued)

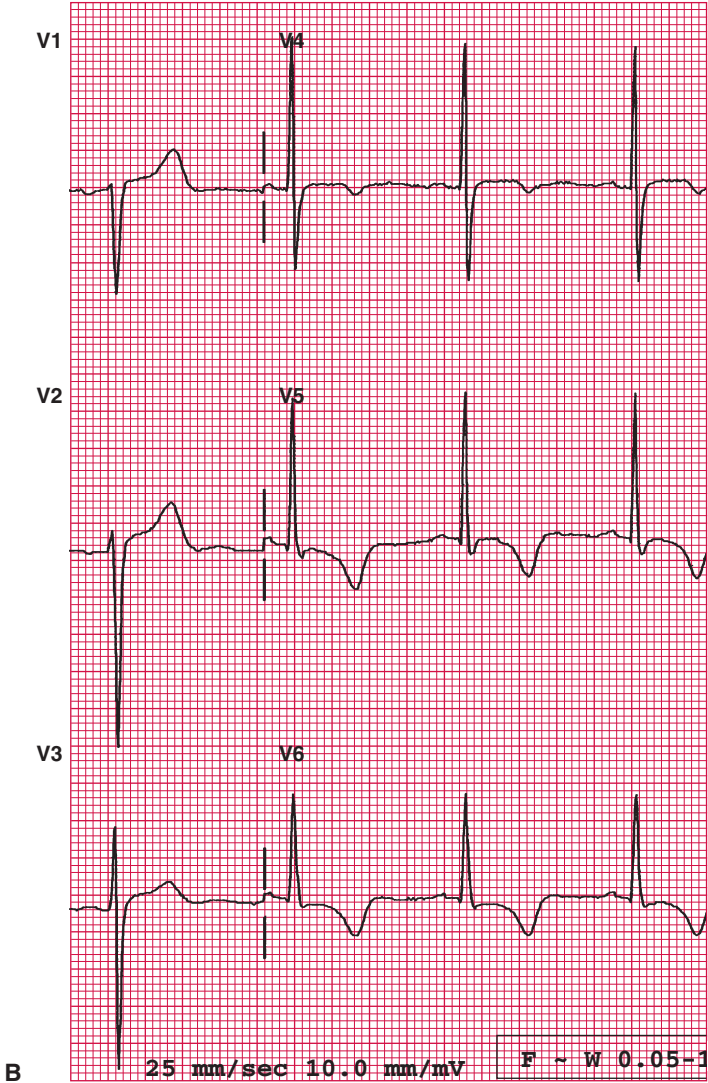


Fig. 8-12. Continued

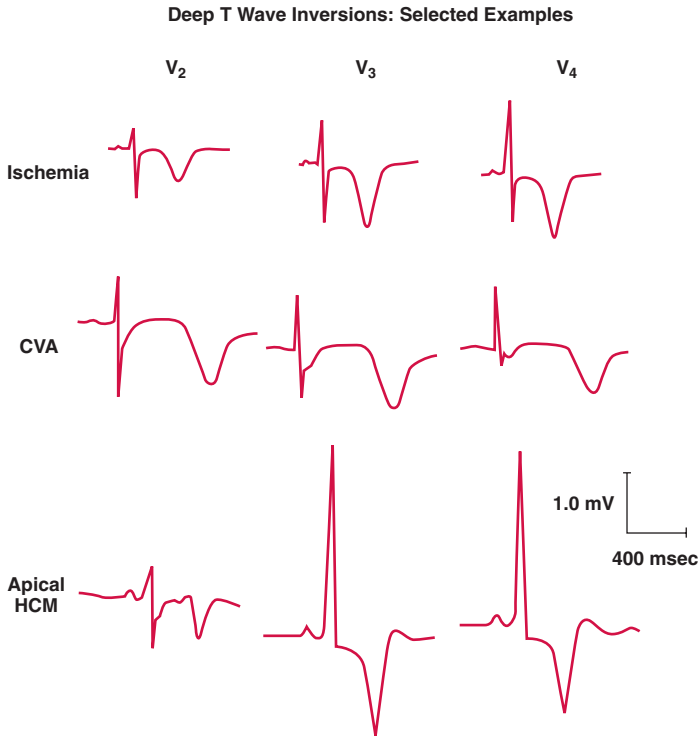


Fig. 8-13. Deep T wave inversion can result from a variety of causes. Note the significant QR prolongation in conjunction with the cerebrovascular accident (CVA) T wave pattern caused here by subarachnoid hemorrhage. Apical hypertrophic cardiomyopathy (HCM) is another cause of deep T wave inversion that can be mistaken for coronary disease. (From Goldberger AL: ACC Curr J Rev Nov/Dec:28, 1996.)

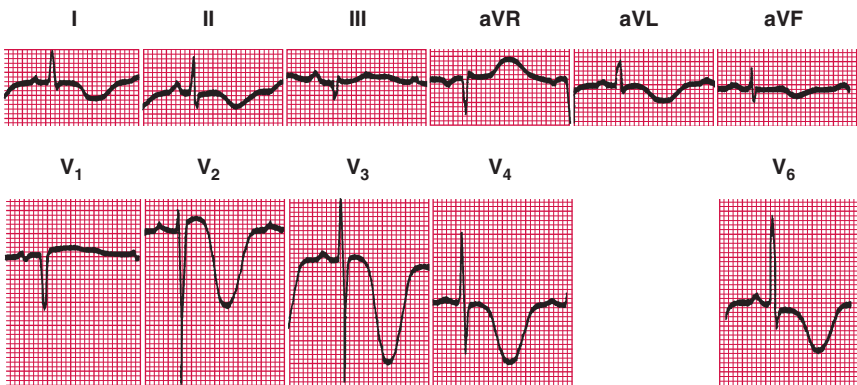


Fig. 8-14. Patient with subarachnoid hemorrhage. ECG shows many of the findings commonly associated with central nervous system lesion. Careful autopsy examination revealed mild left ventricular hypertrophy and dilation but no myocardial damage. (From Chou TC, Susilavorn B: *J Electrocardiol* 2:193, 1969. By permission.)

Tall T Waves

The height of the normal T wave is usually <5 mm in the limb leads and <10 mm in any precordial lead. T waves that are >6 mm in the limb leads or >10 mm in the precordial leads may occur as follows:

- In V_2 through V_5 in some normal individuals. Note the base of normal peaked T waves is not narrow, as it is with hyperkalemia (see Fig. 8-5 and Fig. 10-8). Peaked T waves occasionally may be associated with ST elevation occurring as a normal variant; the ST elevation is commonly and inappropriately interpreted as repolarization changes (see Chapter 5).
- In patients with severe myocardial ischemia or acute MI (hyperacute T waves may occur).
- In patients with hyperkalemia (see Fig. 10-8 and Chapter 10).
- In patients with left ventricular overload, as in severe mitral regurgitation.
- Occasionally, in patients with cerebrovascular accidents.

U WAVES

Figure 8-15 shows a variety of U waves.

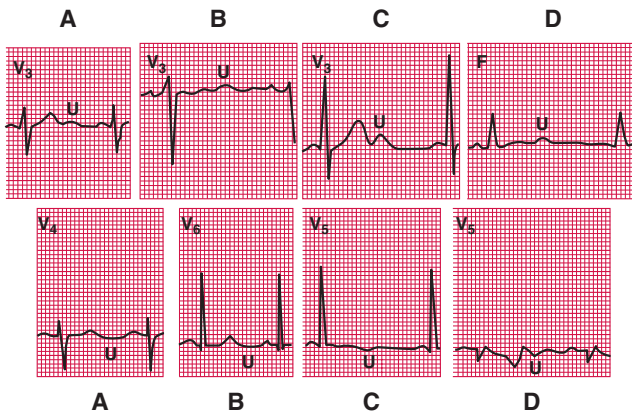


Fig. 8-15. U waves. *Upper row*, Upright U waves: **A**, Normal. **B**, **C**, and **D**, Prominent U waves in hypokalemia. *Bottom row*, Inverted U waves: **A**, Tracing from which this was taken showed no abnormalities except for U wave inversion in several leads. This situation is referred to as isolated U wave inversion. **B**, From a patient with hypertension whose tracing showed left ventricular strain including inverted U waves. **C**, From a patient with coronary insufficiency but without hypertension. **D**, Note marked inversion of T wave and U wave; from a patient with hypertension. (From Marriott JHL: *Practical Electrocardiography*, Baltimore, 1988, Williams & Wilkins.)

Normal U Waves

- The U wave is a very small wave that follows the T wave and is observed only in some individuals. In the normal subject, the U wave is virtually always upright if the T wave is upright.
- The U wave is best visible in leads V_3 and V_2 (looks like the hump on a camel's back; *see* Fig. 8-15 and Fig. 10-7). It is barely visible in other leads, and its electrophysiologic source remains uncertain.
- The U wave may merge with the T wave, and the QU interval may be measured, causing a falsely lengthened QT interval.
- The U wave coincides with the phase of supernormal excitability during ventricular recovery, and most ventricular premature beats occur around the time of the U wave.

Causes

U waves are considered large when the amplitude is ≥ 1.5 mm. The causes of prominent U waves include the following:

- Hypokalemia
- Digitalis use
- Quinidine use
- Hypercalcemia
- Intracranial hemorrhage
- Thyrotoxicosis

Abnormal U Waves

A negative U wave is rarely recorded in normal individuals.

- The most common cause of U wave inversion is severe hypertension, systolic or diastolic overload.
- Rarely, U wave inversion may be the earliest ECG sign of acute coronary syndrome.
- U wave inversion may be the only ECG finding in acute ischemia.
- Exercise-induced transient U wave inversion has been correlated with left anterior descending artery stenosis.

9

Electrical Axis and Fascicular Block

CONTENTS

ELECTRICAL AXIS
FASCICULAR BLOCK

ELECTRICAL AXIS

The electrical axis is discussed early and extensively in most books on ECG interpretation. Although the electrical axis is an important parameter that should be documented, it provides little or no assistance in the diagnosis of most cardiac conditions, particularly those that require specific therapy.

Determination of the electrical axis is useful mainly in the supporting diagnosis of 4 of the 100 or more diagnoses made from ECG tracings:

1. Left anterior fascicular block (LAFB) (hemiblock).
2. Right ventricular hypertrophy (RVH). Right-axis deviation (RAD) is usually a feature. The electrical axis is of minor assistance in the diagnosis of left ventricular hypertrophy (LVH); left axis is not necessary for the diagnosis of LVH.
3. Ventricular tachycardia (VT). Some forms of VT are associated with left-axis deviation (LAD) or an axis in “no man’s land,” but RAD may occur in some.
4. Left posterior fascicular block (LPFB). Criteria for the diagnosis of LPFB are imprecise and unreliable.

Figure 9-1 shows the vectorial genesis of the QRS complex and axis. The addition of all the vectors of ventricular depolarization produces one large mean QRS vector. The QRS axis represents the direction of the mean QRS vector in the frontal plane. The electrical axis is determined by using the hexaxial reference system, which was derived from Einthoven’s equilateral triangle (Fig. 9-2).

From: *Contemporary Cardiology: Rapid ECG Interpretation, 3e*
by: M. Gabriel Khan © Humana Press Inc., Totowa, NJ

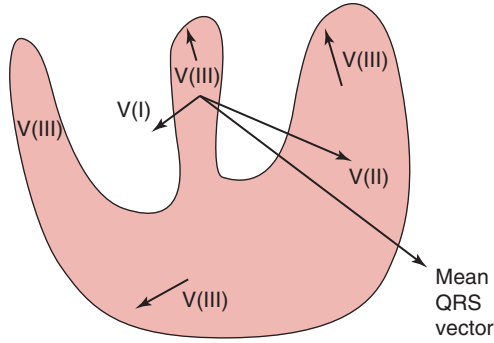


Fig. 9-1. The mean QRS vector.

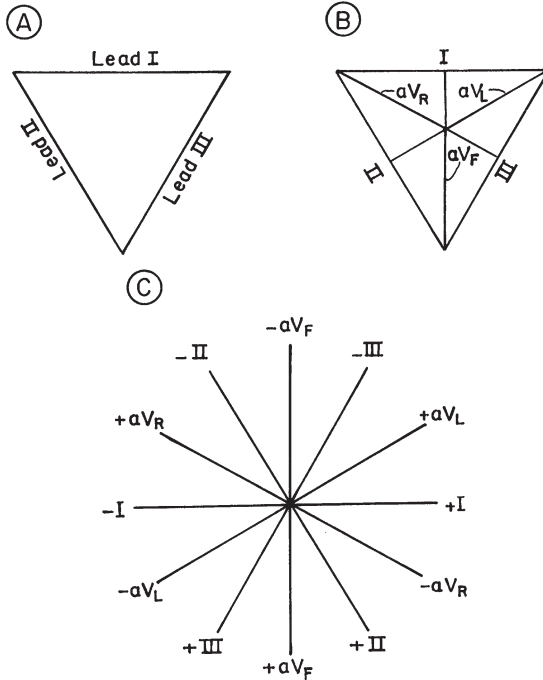
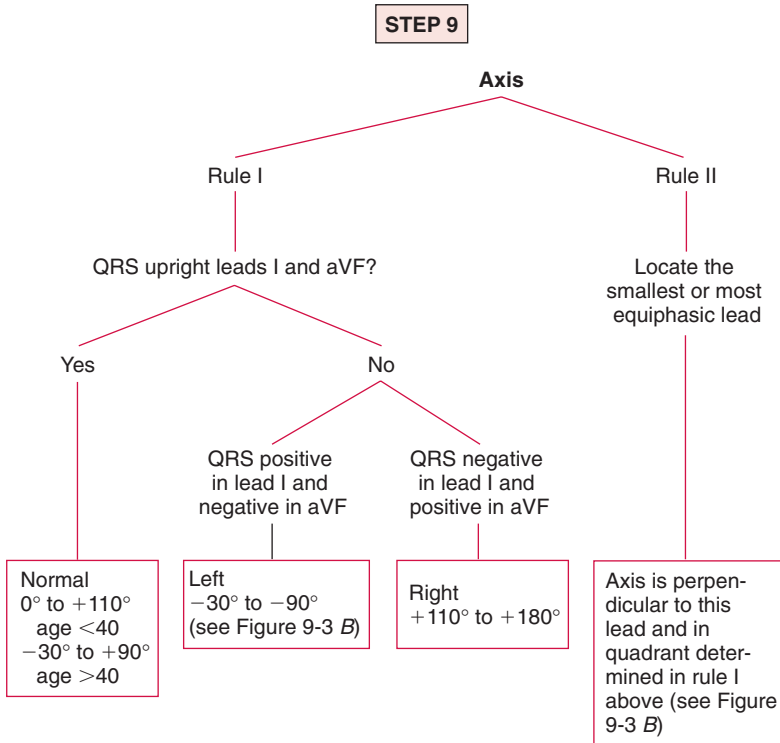


Fig. 9-2. A, Einthoven's equilateral triangle formed by leads I, II, and III. B, The unipolar limb leads are added to the equilateral triangle. C, The hexaxial reference system derived from (B). (From Chou TC: *Electrocardiography in Clinical Practice*, 4th ed., Philadelphia, 1996, WB Saunders, Elsevier Science.)

Because of the minor contribution of the electrical axis to clinical cardiologic diagnosis, this topic is discussed late in this text and is relegated to Step 9 in the 11-step method for accurate ECG diagnosis. See Fig. 9-3, Table 9-1, and instructions given in Chapter 2 for the determination of the electrical axis.



A

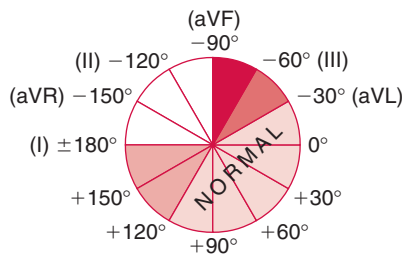
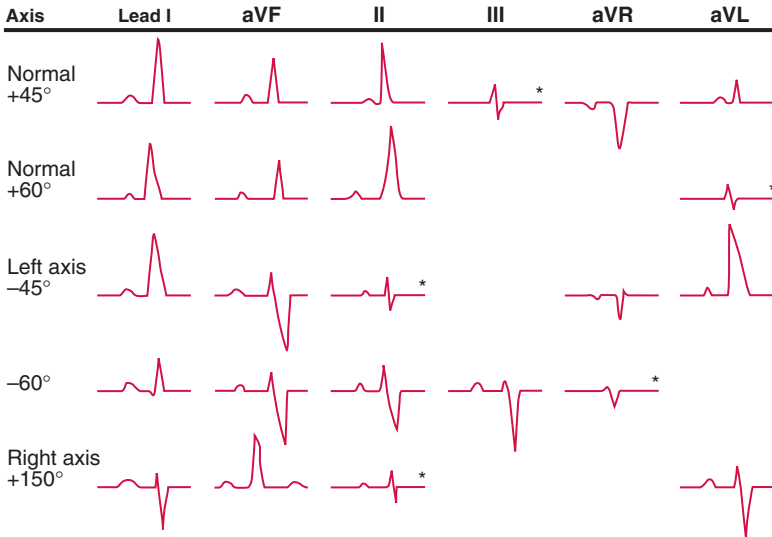


Fig. 9-3. A, Step-by-step method for accurate ECG interpretation. Step 9: Detection of the electrical axis. Leads are indicated in parentheses. See Table 9-1.

(continued)

STEP 9 Continued



B *Most equiphase lead.

Fig. 9-3. Continued B, See Table 9-1 and Figs. 9-4 and 9-5.

Table 9-1
Electrical Axis

<i>Most equiphase lead</i>	<i>Lead perpendicular*</i>	<i>Axis</i>
III aVL	aVR II	Leads I and aVF positive = normal axis Normal = +30 degrees Normal = +60 degrees Lead I positive and aVF negative = left axis
II aVR I	aVL (QRS positive) III (QRS negative) aVF (QRS negative)	Left = -30 degrees Left = -60 degrees Left = -90 degrees Lead I negative and aVF positive = right axis
aVR II	III (QRS positive) aVL (QRS negative)	Right = +120 degrees Right = +150 degrees

*Lead perpendicular (at right angle) to the most equiphase (isoelectric) lead usually has the tallest R or deepest S wave.

- The range of the electrical axis in the majority of normal adults older than the age of 40 years is -30 degrees to $+90$ degrees (*see* Fig. 9-3); for those younger than age 40, the range is 0 degrees to $+105$ degrees. Normal children may have an axis of up to $+110$ degrees. Most normal individuals have values between $+30$ degrees and $+75$ degrees.

Left-Axis Deviation

An axis of -15 degrees to -30 degrees, which is relatively normal for individuals older than the age of 40 years, is sometimes termed leftward axis to distinguish it from LAD. An axis of -30 degrees to -90 degrees is termed marked LAD (Fig. 9-4).

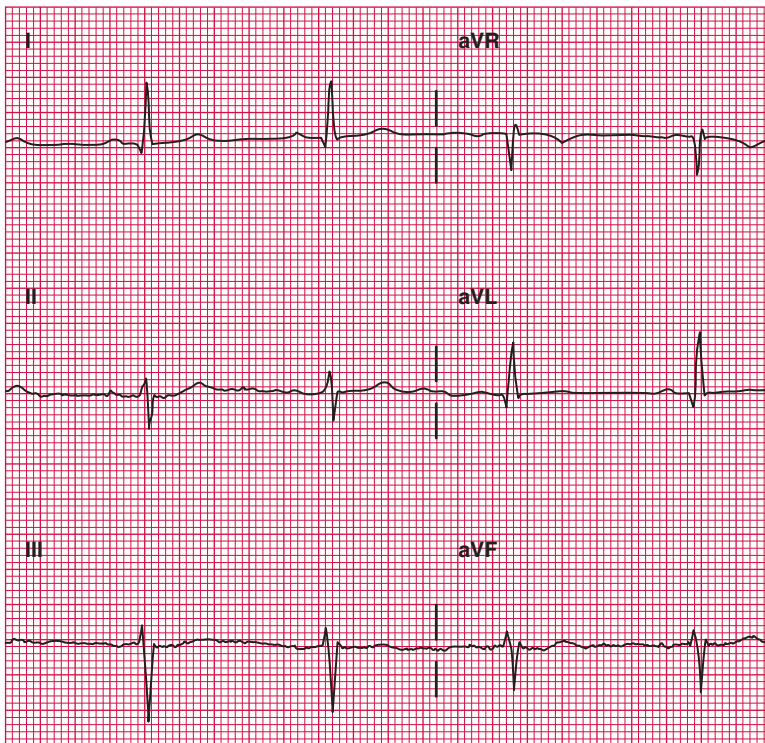


Fig. 9-4. Left-axis deviation -45 degrees; lead II is the most equiphaseic QRS; aVL is perpendicular and lies at -30 degrees; aVR is the next most equiphaseic; lead III is perpendicular at -60 degrees; therefore, the axis that lies between $= -45$ degrees (*see* Fig. 9-3B).

CAUSES

- Normal variation
- LAFB (hemiblock)
- Left bundle branch block
- LVH
- Mechanical shifts causing a horizontal heart; high diaphragm; pregnancy, ascites
- Some forms of VT
- Endocardial cushion defects and other congenital heart disease

Right-Axis Deviation

- Criteria for RAD in adults include an axis of $+100$ degrees to $+180$ degrees (Fig. 9-5)

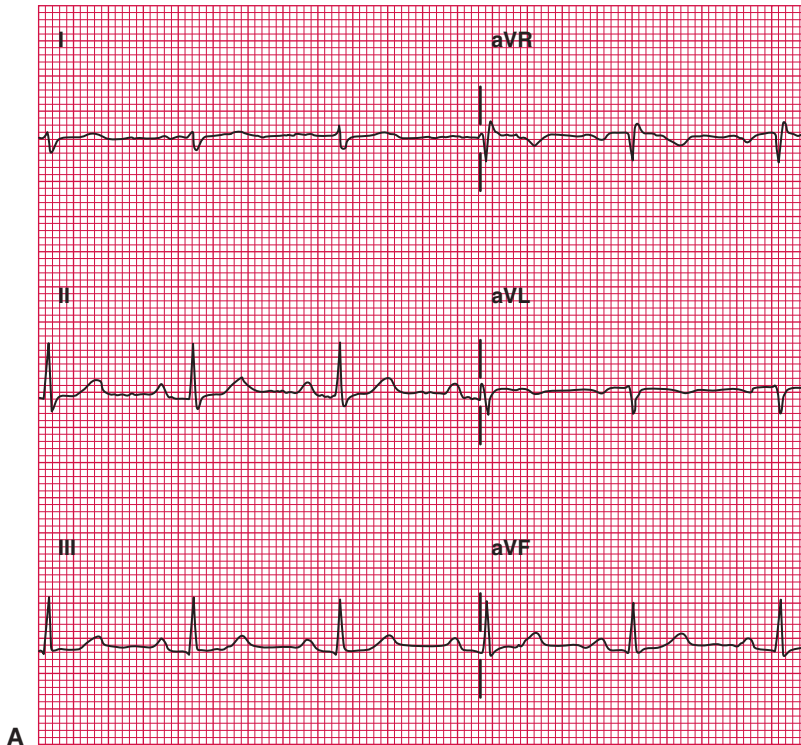
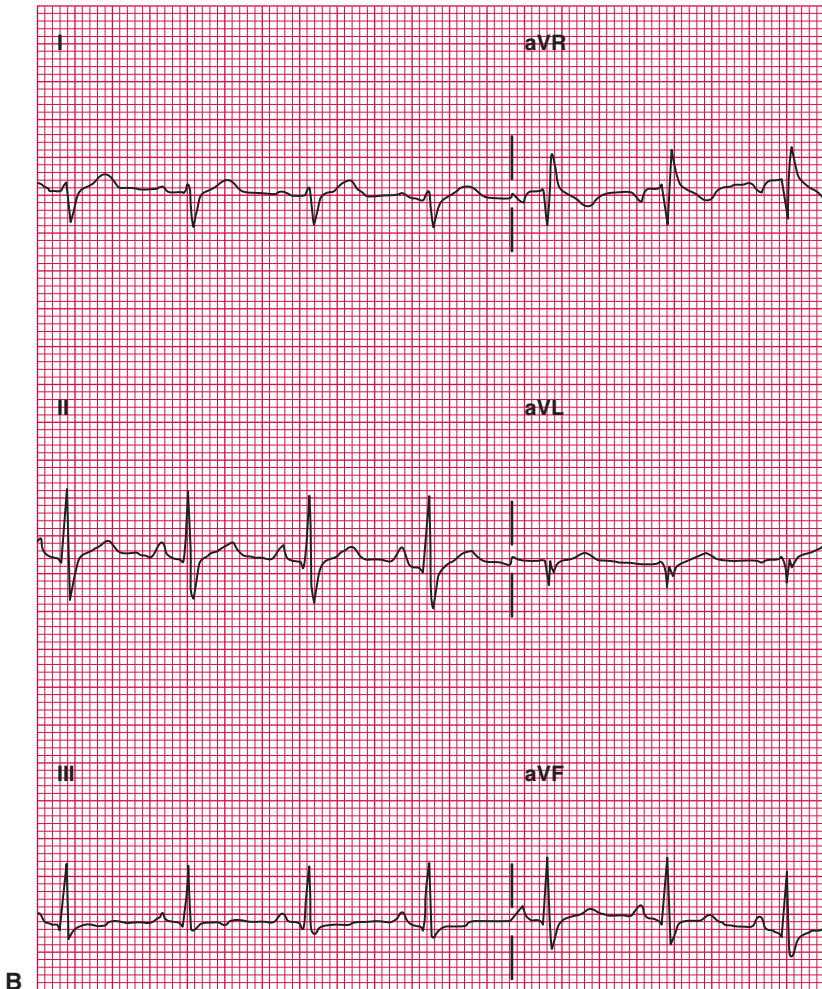


Fig. 9-5. A, Right-axis deviation; QRS axis $+110$ degrees; lead I is the most equiphaseic; aVF is perpendicular at $+90$ degrees; aVR is the next most equiphaseic, with lead III being perpendicular at $+120$ degrees. The exact axis lies somewhere between $+90$ degrees and $+120$ degrees (i.e., at $+110$ degrees). Patient is older than 40 years of age. B, Right-axis deviation. ECG from a 26-year-old healthy man.

CAUSES

- Normal variation
- RVH
- LPFB
- Lateral MI
- Pulmonary embolism
- Dextrocardia
- Normal variants: mechanical shifts or emphysema causing a vertical heart

**Fig. 9-5.** *Continued*

FASCICULAR BLOCK

Left Anterior Fascicular Block (Hemiblock)

Figure 9-6 illustrates the division of the left bundle branch into anterior and posterior fascicles. The anterior fascicle traverses an antero-superior course and ends at the base of the anterior papillary muscle. The anterior fascicle is thin and long, has a single blood supply, and is commonly damaged by ischemic-disease fibrosis and other pathologic processes, resulting in LAFB. Rosenbaum initially called the block left anterior hemiblock, and because this term is easy to write, many cardiologists use it rather than LAFB.

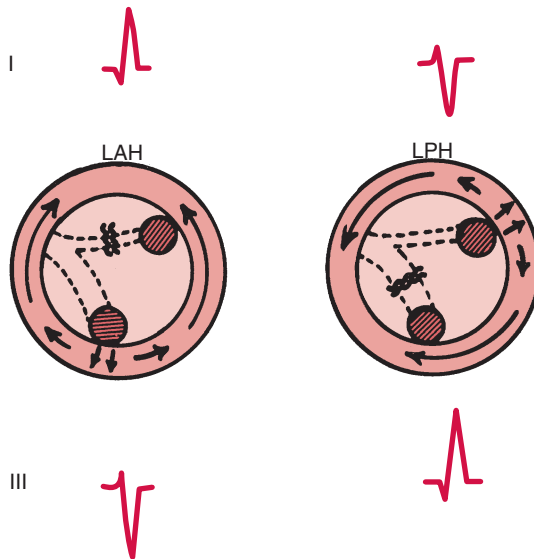


Fig. 9-6. Hemiblock patterns in the limb leads: left anterior hemiblock (LAH) and left posterior hemiblock (LPH). The “anterior” papillary muscle is above and lateral to the “posterior” papillary muscle, and the two divisions of the left bundle branch course toward their respective papillary muscles. Thus, if the anterior division is blocked, initial electromotive forces are directed downward and to the right, inscribing a small Q wave in leads I and aVL and an S wave in leads II, III, and aVF. The subsequent forces are directed mainly upward and to the left, writing an R wave in I and aVL and an S in II, III, and aVF, to produce a left-axis deviation. In LPH, the initial forces spread upward and to the left to write an R in I and aVL and a small Q in II, III, and aVF while subsequent forces are directed downward and to the right to produce right-axis deviation. (From Marriott JLH: *Practical Electrocardiography*, 8th ed., Baltimore, 1988, Williams & Wilkins.)

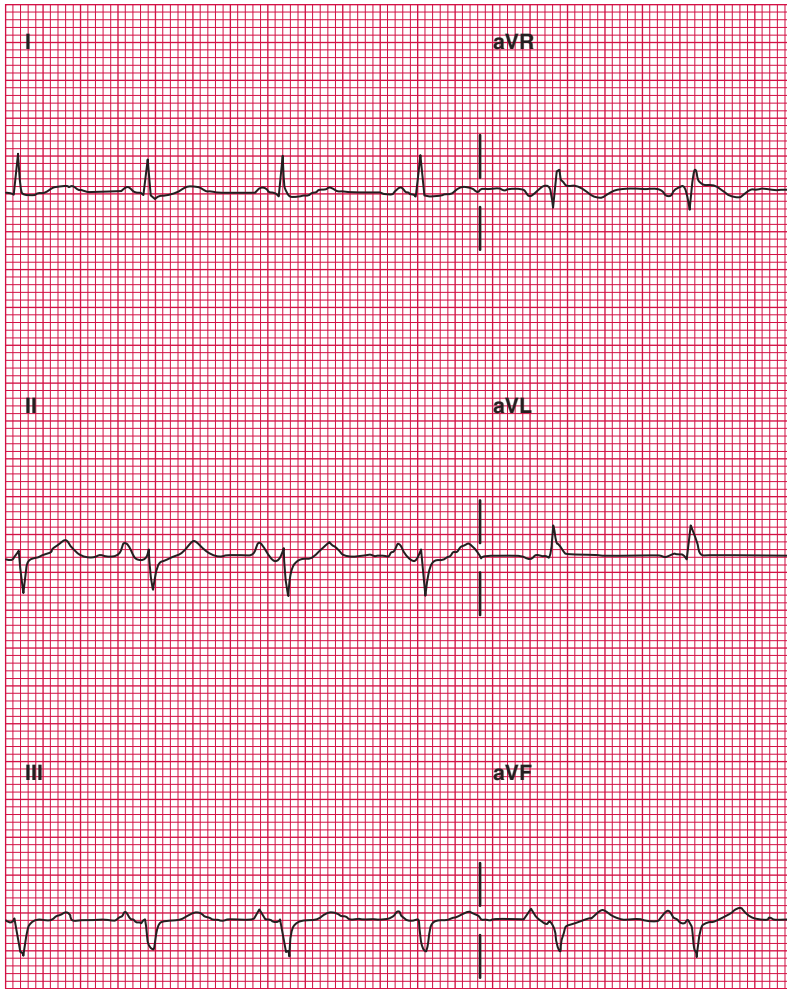


Fig. 9-7. Left-axis deviation -60 degrees. There is a small q wave in lead I and a small r wave in lead III. These are the criteria for the diagnosis of left anterior fascicular block: borderline ECG.

DIAGNOSTIC CRITERIA

- LAD, -45 degrees to -90 degrees (preferably -60 degrees to -90 degrees)
- A small q wave, 0.5 to less than 2 mm deep in lead I, qR in I (Fig. 9-7)

- A small r wave, 1 to 4 mm tall in lead III, rS in III
- A normal QRS duration, provided right bundle branch block (RBBB) or other conduction defects are absent (other fascicles conduct normally; thus depolarization of the ventricles is not delayed)

Figure 9-6 shows how the ECG configuration of LAFB is derived. With block of the anterior fascicle, depolarization starts at the posterior papillary muscle and inferior wall and proceeds upward, superiorly and to the left to activate the left ventricular muscle mass that lies above the papillary muscle. Thus, the electrical axis is directed strongly to the left at -60 degrees to -90 degrees. Because the electrical impulse originating from the posterior papillary muscle travels initially downward from endocardium to epicardium, it registers a small r wave of <4 mm in lead III. The small impulse is directed away from lead I and thus causes a small q wave in lead I. The current then travels upward to the left and causes an r wave in lead I and an s wave in lead III, because electrical impulse travels away from the inferior leads (see Figs. 9-4 and 9-6).

CAUSES

- Acute or chronic ischemic heart disease
- Cardiomyopathy and specific heart muscle disease
- Chagas disease
- Myocarditis

LAFB is a normal finding in approximately 1% of men older than age 40 years.

PITFALLS IN DIAGNOSIS OF LEFT ANTERIOR FASCICULAR BLOCK

- Acute or old MI: When LAFB occurs during acute inferior MI, the initial small r wave caused by LAFB in leads II, III, and aVF masks the Q wave of infarction.
- Hypertensive heart disease: LAFB lowers the QRS voltage in the pre-cordial leads and may mask LVH; conversely, LAFB increases QRS voltage in the limb leads and may mimic LVH.

Left Posterior Fascicular Block

LPFB or posterior hemiblock occurs rarely, because the posterior bundle is thick and short and has a double blood supply. The fascicle runs to the base of the posterior papillary muscle (see Fig. 9-6). The

diagnosis can be made only after excluding RVH and chronic obstructive pulmonary disease (COPD). The following are criteria for the diagnosis of LPFB:

- RAD, +120 degrees to +180 degrees
- A small r wave <4mm in leads I and aVL and an S wave in lead I
- A small q wave in lead II or III
- A normal QRS duration
- Absence of RVH or cor pulmonale, COPD, a vertical heart, and other causes of RAD (thus, a confident diagnosis of LPFB is not often made)

Bifascicular Block

- The combination of LAFB and RBBB occurs commonly (Fig. 9-8) but rarely progresses to serious block; thus pacing is rarely required.
- The combination of LPFB and RBBB occurs rarely (Figs. 9-9 and 9-10).

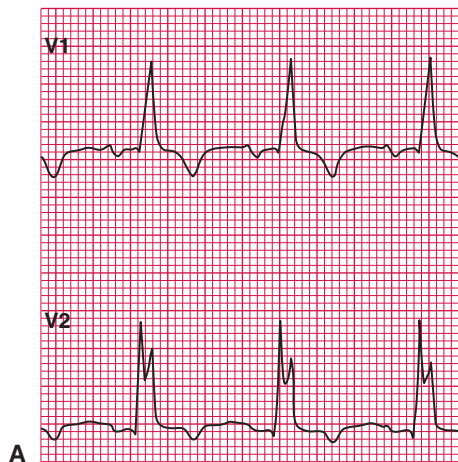


Fig. 9-8. A, V leads from a patient with right bundle branch block (RBBB). B, Features of left anterior fascicular block (LAFB). The QRS axis is -75 degrees with a small Q wave in lead I and a small R wave in lead III, which is in keeping with LAFB. Diagnosis: bifascicular block: RBBB and LAFB.

(continued)

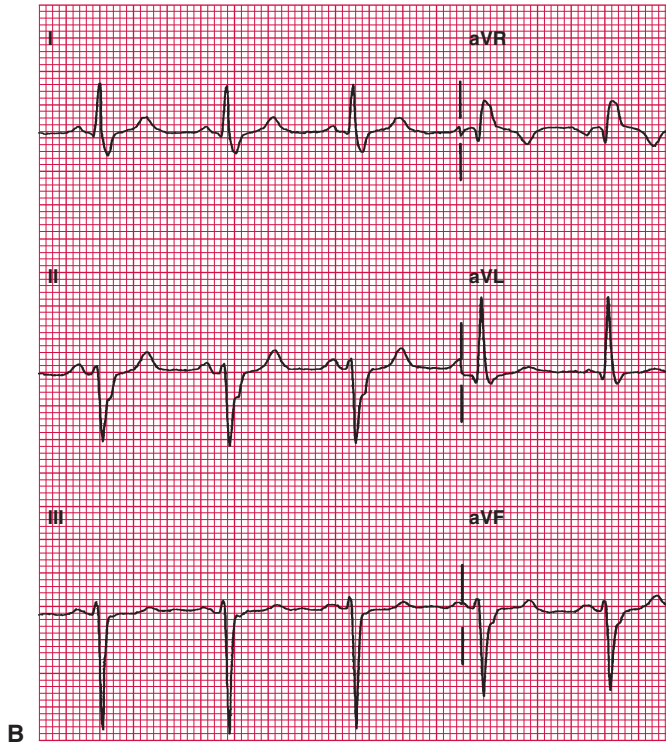


Fig. 9-8. *Continued*

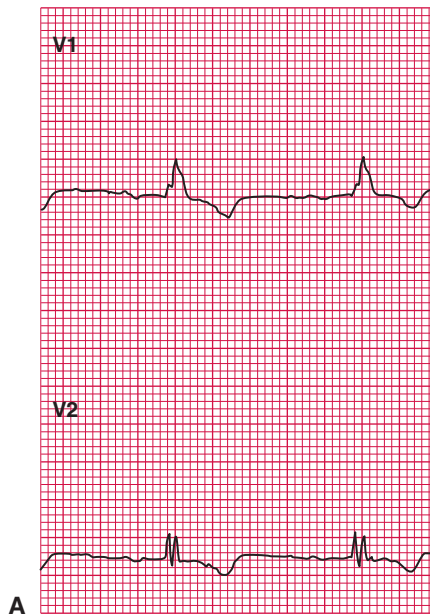


Fig. 9-9. **A,** Tracing of a patient with right bundle branch block and left posterior fascicular block: bifascicular block. **B,** Left posterior fascicular block.

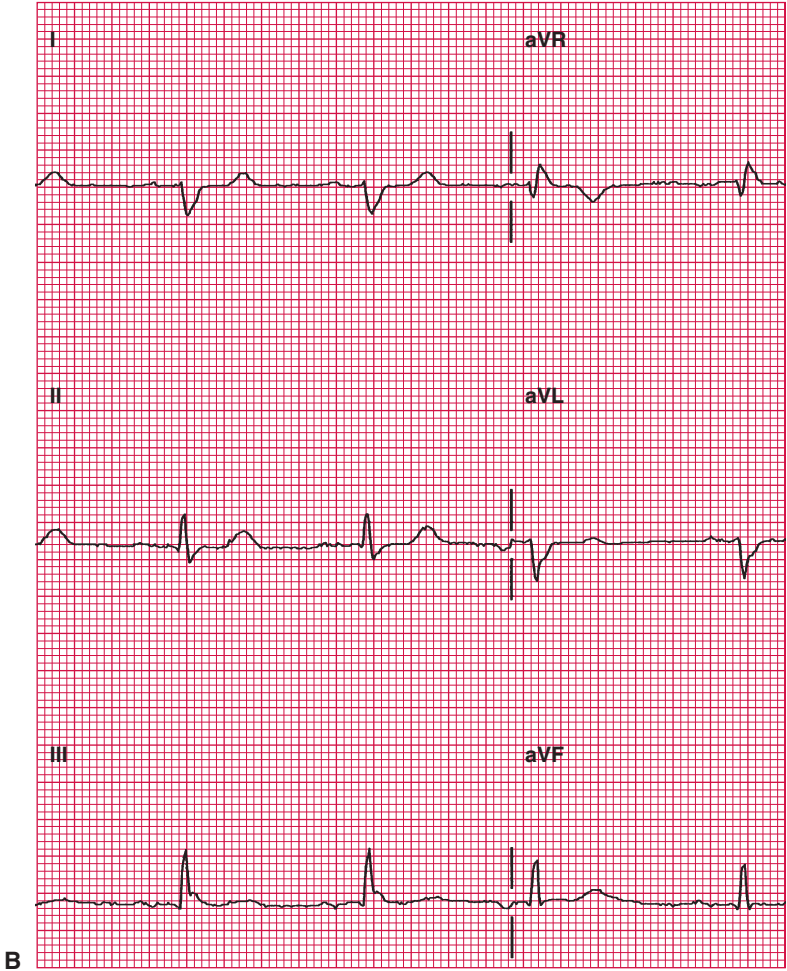


Fig. 9-9. *Continued*

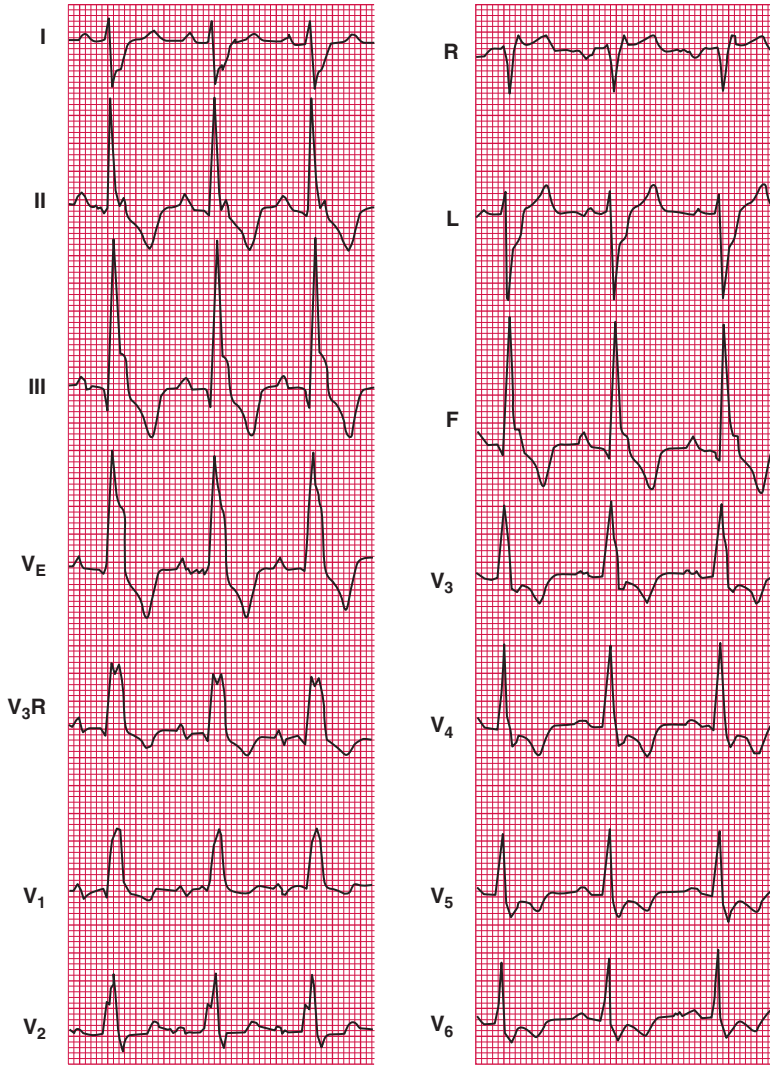


Fig. 9-10. Left posterior hemiblock. Note the right-axis deviation, the small r in leads I and aVL, and the small q in lead II. Complete right bundle branch block is also present in this patient. (From Wellens JJH, Conover MB: *The ECG in Emergency Decision Making*, Philadelphia, 1992, WB Saunders, Elsevier Science.)

10 Miscellaneous Conditions

CONTENTS

ATRIAL SEPTAL DEFECT
PERICARDITIS
LONG QT INTERVAL
HYPOKALEMIA
HYPERKALEMIA
DIGITALIS
DEXTROCARDIA: TRUE DEXTROCARDIA
(WITH SITUS INVERSUS)
ELECTRICAL ALTERNANS
ELECTRONIC PACING
PULMONARY EMBOLISM
HYPOTHERMIA
HYPERCALCEMIA
HYPOCALCEMIA

After a methodical assessment of the P waves, the QRS duration for bundle branch blocks (left and right), the ST segment, Q waves, hypertrophy, and the electrical axis has been completed, an assessment for miscellaneous conditions is appropriate. A search for miscellaneous conditions is logically performed at Step 10 (Fig. 10-1).

The ECG may reveal clues to the diagnosis of 12 or more miscellaneous conditions:

- Atrial septal defect
- Acute pericarditis
- Long QT interval
- Hypokalemia
- Hyperkalemia
- Digitalis toxicity
- Dextrocardia
- Electrical alternans

From: *Contemporary Cardiology: Rapid ECG Interpretation, 3e*
by: M. Gabriel Khan © Humana Press Inc., Totowa, NJ

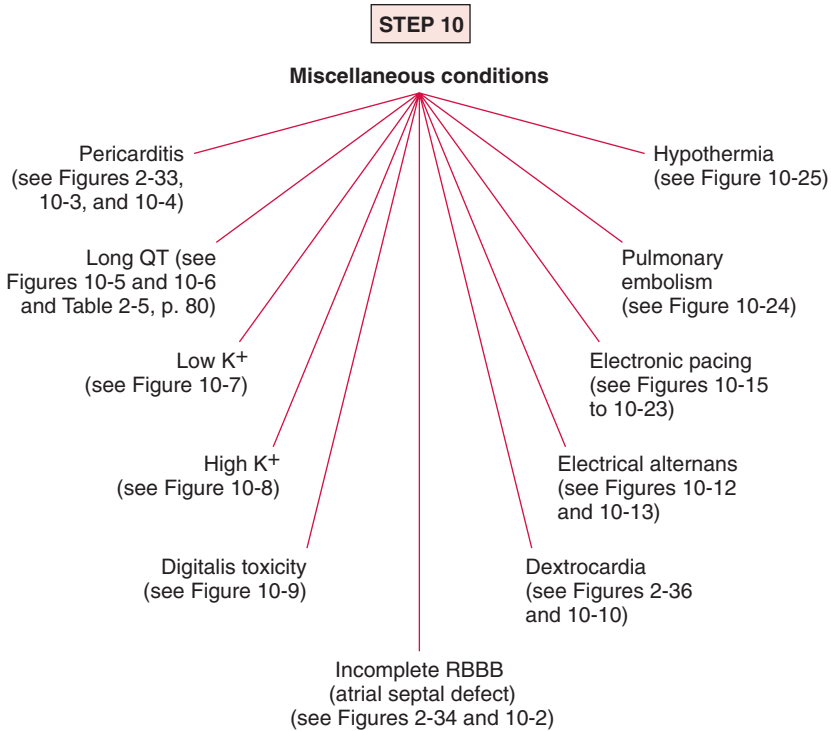


Fig. 10-1. Step-by-step method for accurate ECG interpretation. Step 10: Assess for miscellaneous conditions. RBBB, right bundle branch block.

- Electronic pacing
- Pulmonary embolism (PE) (the ECG is not diagnostic)
- Hypothermia and hyperthermia
- Hypercalcemia and hypocalcemia

ATRIAL SEPTAL DEFECT

Incomplete right bundle branch block (RBBB) is a common and well-known finding in atrial septal defect (*see* Fig. 2-34).

A New Diagnostic Sign

A characteristic “crochetage” on the R wave of leads II, III, and aVF has been reported (Fig. 10-2).

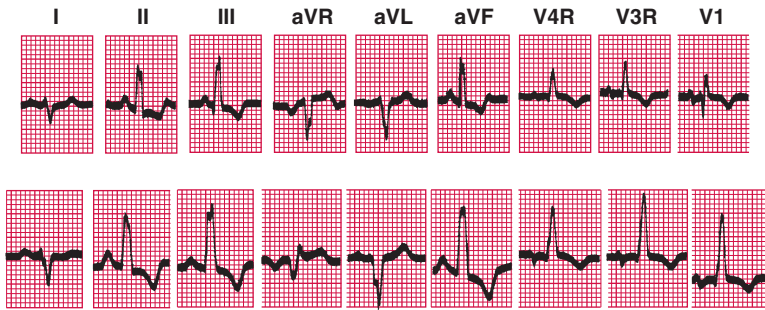


Fig. 10-2. Electrocardiographic tracings from a 16-year-old girl with an atrial septal defect and partial anomalous venous return. Preoperative mean pulmonary artery pressure was 15 mm Hg, and the Qp/Qs ratio was 2:1. Note the “crochetage” on the R wave tracing in inferior limb leads II, III, and aVF and the incomplete bundle branch block pattern in the V₁ lead on the ECG before operation (top). Three days after atrial septal defect surgical repair, the crochetage pattern disappeared, whereas the incomplete right bundle branch block pattern persisted (bottom). (From Heller J, Hagege AA, Besse B, et al.: *J Am Coll Cardiol* 27(4):880, 1996.)

PERICARDITIS

Diagnostic Criteria

- Stage 1: Widespread ST segment elevation, generally upwardly concave in all leads except aVR and occasionally V₁. ST segment elevation may persist for a few days (Figs. 10-3, 10-4, and Fig. 2-33). Reciprocal ST segment depression occurs in aVR and sometimes in V₁ (see Figs. 10-3 and 10-4). The PR segment is elevated in aVR, and PR segment depression generally occurs in all leads except occasionally V₁.
- Stage 2: A few days later, the ST and PR segments become normal (isoelectric); the T wave remains normal or may be decreased in amplitude and may become flattened.
- Stage 3: After normalization of the ST segment, diffuse T wave inversion occurs.
- Stage 4: This stage lasts from days to weeks. The T waves normalize; rarely do they remain inverted.

Other Clues Suggestive of Acute Pericarditis

- Early PR segment depression, particularly in leads II, aVF, and V₄ through V₆, is suggestive of pericarditis.
- Sinus tachycardia may be the only finding if ST segment elevation has resolved and the T waves remain normal.

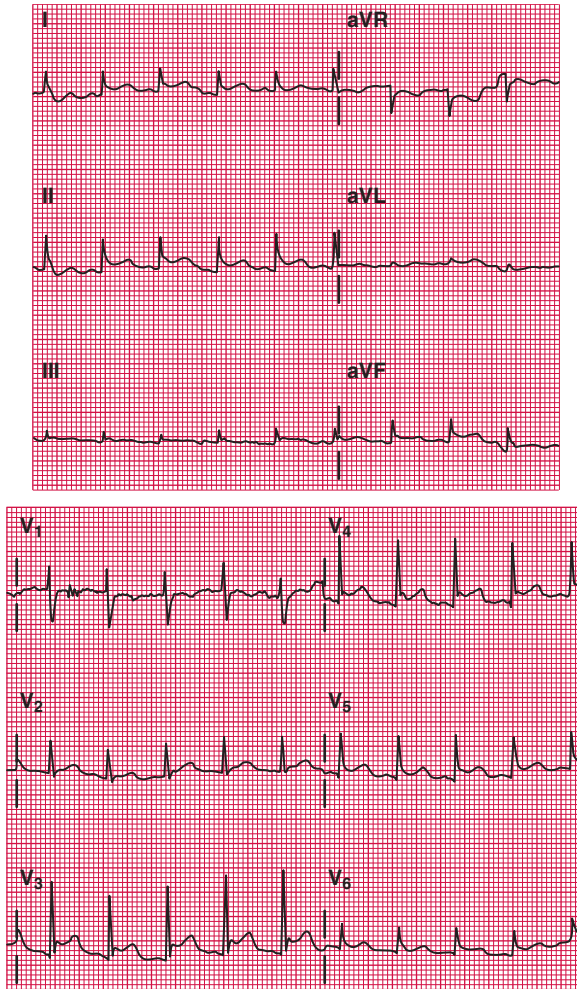


Fig. 10-3. Widespread ST segment elevation, generally upwardly concave in all leads except aVR and V₁: acute pericarditis. (From Khan, M. Gabriel: *Heart Disease Diagnosis and Therapy*, Baltimore, 1996, Williams & Wilkins.)

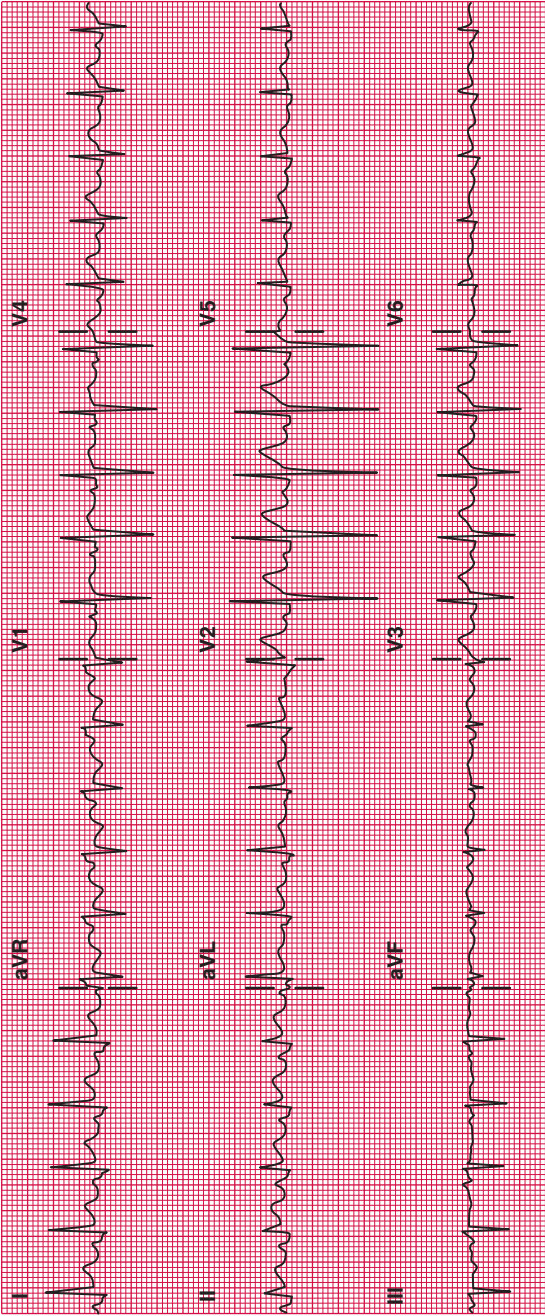


Fig. 10-4. Characteristic features of acute pericarditis: ST segment elevation in most leads: I, II, aVL, aVF, V₅, and V₆, with reciprocal ST depression and PR segment elevation in aVR. In addition, note sinus tachycardia commonly seen with acute pericarditis.

- Electrical alternans usually involves the QRS complex. Total alternans with involvement of the P, QRS, and T waves may occur with cardiac tamponade (*see* Fig. 10-14).
- Low-voltage QRS may occur when pericardial fluid accumulates.

LONG QT INTERVAL

The QT interval indicates the total duration of ventricular systole. A prolonged QT interval represents delayed repolarization of the ventricles and predisposes to reentrant arrhythmias, such as torsades de pointes (*see* Fig. 11-46).

Diagnostic Criteria

- A rough guideline to remember is that the QT interval should be less than half the preceding RR interval at heart rates of 60 to 100 beats/min.
- The QT interval varies with heart rate, and several formulas have been used to provide a corrected QT interval (QTc).
- The QTc also has limitations because of difficulties with obtaining exact measurements. Because it is difficult sometimes to define the end of the T wave, the measurement is often inaccurate, particularly when a U wave merges with the T. Thus in clinical practice, the QT interval should be assessed mainly for excessive prolongation, using a lead that does not show a U wave (Figs. 10-5 and 10-6).
- See Table 2-5 for a clinically useful approximation of QT intervals.

Causes

A prolonged QT interval may be caused by the following:

- Drugs
 - Class 1 antiarrhythmics (e.g., disopyramide, procainamide, quinidine)
 - Class 3 antiarrhythmics (e.g., amiodarone, sotalol)
- Tricyclic antidepressants
 - Phenothiazines
 - Astemizole
 - Terfenadine
 - Adenosine
 - Antibiotics (e.g., erythromycin and other macrolides)
 - Antifungal agents
 - Pentamidine, chloroquine
- Ischemic heart disease
- Cerebrovascular disease

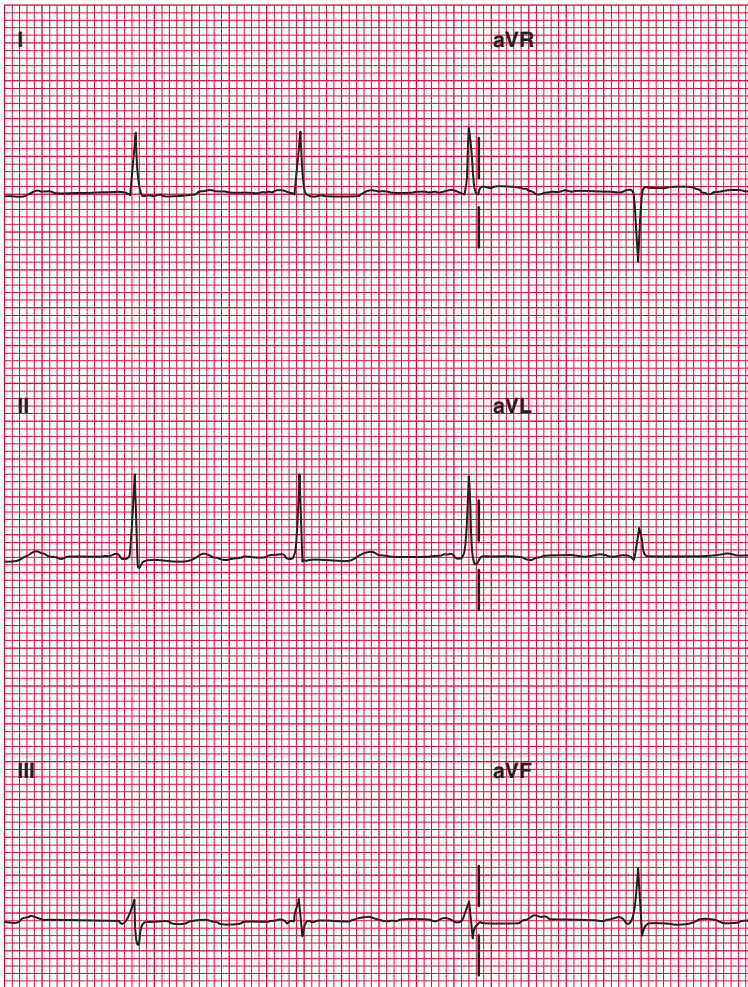


Fig. 10-5. QT interval 0.46 second; the heart rate is 67 bpm. The normal range of a QT interval at a heart rate of 67 to 100bpm is 0.33 to 0.42 second (see Table 2-5).

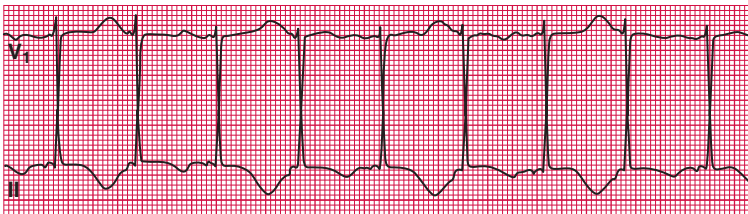


Fig. 10-6. The QT interval is prolonged, measuring approximately 600 milliseconds, with T wave alternans. The tracing was recorded in a patient with chronic renal disease shortly after dialysis. (From Braunwald E: *Heart Disease: A Textbook of Cardiovascular Medicine*, 5th ed., Philadelphia, 1997, WB Saunders, Elsevier Science.)

- Rheumatic fever
- Myocarditis
- Mitral valve prolapse
- Electrolyte abnormalities
- Hypocalcemia
- Hypothyroidism
- Liquid protein diets
- Organophosphate insecticides
- Congenital prolonged QT syndrome

A short QT interval is not of great concern and occurs rarely with the following:

- Hypercalcemia, a feature of malignancy and hyperparathyroidism
- Digitalis intoxication

HYPOKALEMIA

Diagnostic Criteria

- Progressive ST segment depression: A small U wave normally has the same polarity as the T wave; when the serum potassium level falls to <3.5 mEq/L, the amplitude of the T wave decreases.
- A marked increase in U wave amplitude with potassium <3 mEq/L: the U wave becomes taller than the T wave: with serum potassium <1.5 mEq/L, the T and the U wave may become fused. The changes are seen best in leads V_2 through V_5 (Figs. 10-7 and 10-8C).

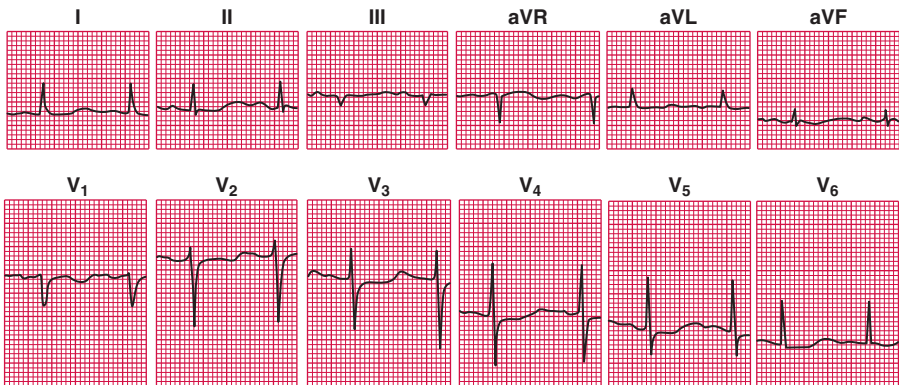


Fig. 10-7. Hypokalemia produced by diuretics. The serum potassium level was 2.7 mEq/L, sodium was 124 mEq/L, and calcium was 9.2 mg/dL. The ECG shows diffuse ST segment depression, T wave flattening, and prominent U waves. The prominent U waves may be mistaken for T waves. (From Chou TC: *Electrocardiography in Clinical Practice*, 4th ed., Philadelphia, 1996, WB Saunders, Elsevier Science.)

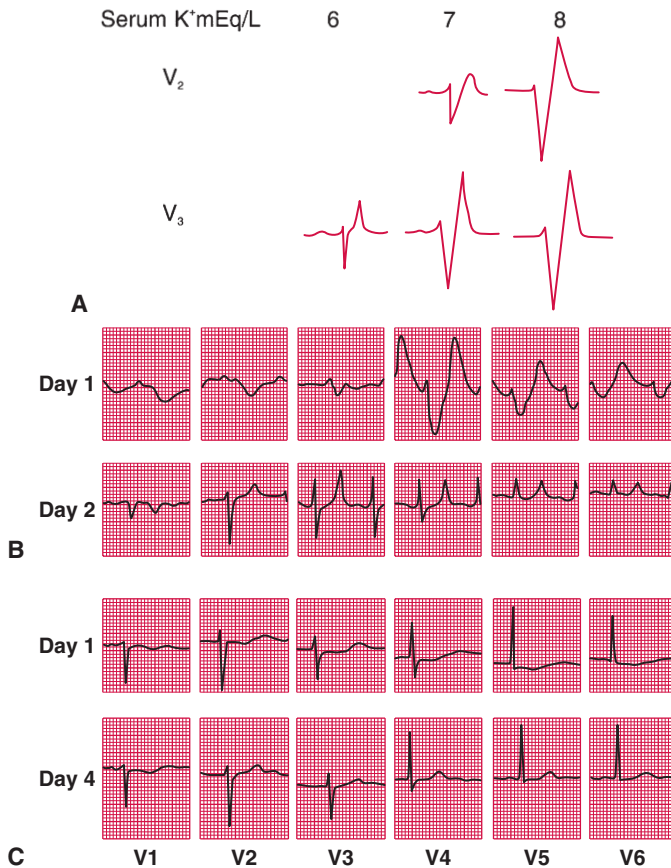


Fig. 10-8. A, ECG signs of hyperkalemia.

- $K^+ > 5.7 \text{ mEq/L}$: Earliest signs are T wave peaked and narrow base (“tenting”); PR interval may be prolonged.
- $K^+ > 7 \text{ mEq/L}$: P wave flat or absent; QRS widens; prominent S wave.
- $K^+ > 8 \text{ mEq/L}$: S wave becomes wider and deeper and moves steeply into the T wave; there is virtually no isoelectric ST segment; occasionally ST segment elevation.

B, ECG changes in hyperkalemia. On day 1, at a K^+ level of 8.6 mEq/L , the P wave is no longer recognizable and the QRS complex is diffusely prolonged. Initial and terminal QRS delay is characteristic of K^+ -induced intraventricular conduction and is best illustrated in leads V_2 and V_6 . On day 2, at a K^+ level of 5.8 mEq/L , the P wave is recognizable with a PR interval of 0.24 second, the duration of the QRS complex is approximately 0.10 second, and the T waves are characteristically tented. **C**, ECG changes in hypokalemia. On day 1, at a K^+ level of 1.5 mEq/L , the T and U waves are merged. The U wave is prominent and the QU interval is prolonged. On day 4, at a K^+ level of 3.7 mEq/L , the tracing is normal. (A from Khan, M. Gabriel: *Medical Diagnosis and Therapy*, Philadelphia, 1994, Lea & Febiger; B and C from Braunwald E: *Heart Disease: A Textbook of Cardiovascular Medicine*, 5th ed., Philadelphia, 1997, WB Saunders, Elsevier Science.)

- ST segment depression.
- An increase in the QRS duration.
- Slight prolongation of the PR interval.

HYPERKALEMIA

Diagnostic Criteria

- Mild hyperkalemia: At a serum potassium level of approximately 5.7 to 6.5 mEq/L, the P wave widens; tall, peaked, narrow-based, “tented” T waves appear in many leads; and first-degree atrioventricular (AV) block occurs (*see* Fig. 10-8A and B).
- Severe hyperkalemia: At a serum potassium level >6.5 mEq/L, the second portion of the QRS complex shows significant widening, which may show notching or slurring, and thus the wide QRS merges with the tall, tented T waves. The ST segment may be elevated (*see* Fig. 10-8).
- High-degree AV block: P waves disappear.
- Ventricular tachycardia (VT), ventricular fibrillation (VF), or idioventricular rhythm.

DIGITALIS

Digitalis Effect

- Digitalis effect revealed by the ECG does not imply toxicity and is suggested by the following:
 - Sagging ST segment depression with upward concavity
 - Decreased amplitude of T wave, which may be biphasic
 - Shortening of the QT interval
 - Prolonged PR interval; first-degree AV block
 - Increased amplitude of the U wave

Digitalis Toxicity

- Digitalis toxicity is suggested by the occurrence of almost any type of arrhythmia or conduction defect, with the exception of bundle branch block.
- Common arrhythmias include the following:
 - Excitant disturbances such as ventricular premature beats (VPBs), especially bigeminy and multifocal VPBs; atrial tachycardia; AV junctional tachycardia; accelerated junctional rhythm; VT; bidirectional tachycardia; and VF.
 - Suppressant disturbances such as sinus bradycardia, first-degree AV block, second-degree AV block, Mobitz type I (Wenckebach) block, and complete AV block.

- Combined disturbances such as atrial tachycardia with AV block (i.e., paroxysmal atrial tachycardia [PAT] with block) and regular, accelerated junctional rhythm in the presence of atrial fibrillation (Fig. 10-9).

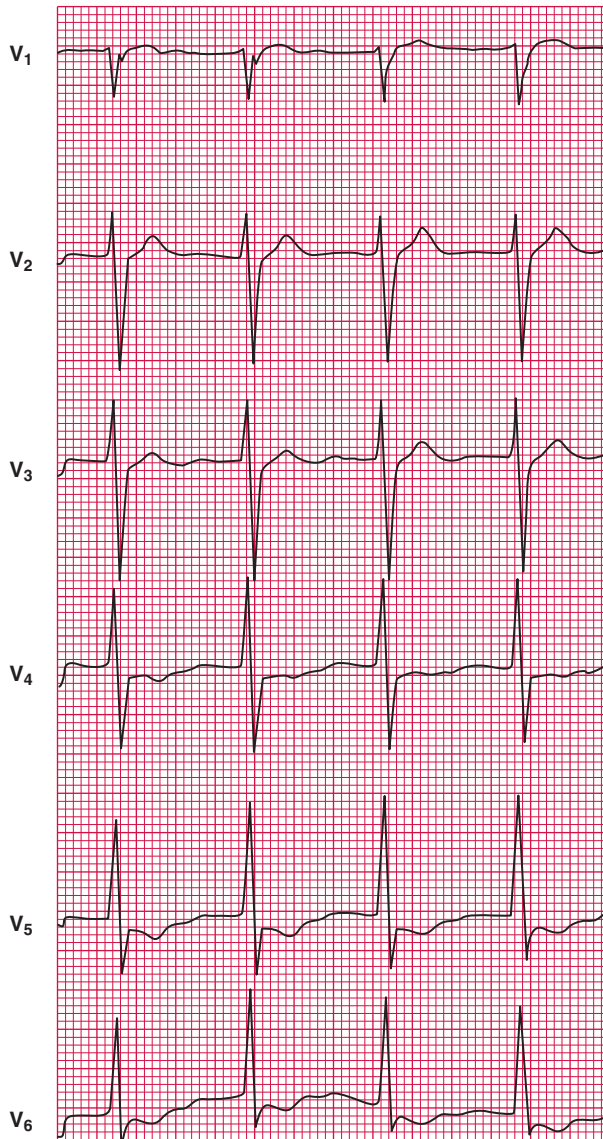


Fig. 10-9. Atrial fibrillation with junctional tachycardia (rate, 95 bpm) resulting from digitalis toxicity. Note the absolute regularity of the rhythm. (From Wellens JJH, Conover MB: *The ECG in Emergency Decision Making*, Philadelphia, 1992, WB Saunders, Elsevier Science.)

DEXTROCARDIA: TRUE DEXTROCARDIA (WITH SITUS INVERSUS)

Diagnostic Criteria

- In lead I, the P, QRS, and T waves are inverted or upside down (Fig. 10-10).
- Leads aVR and aVL are reversed (aVL is now aVR); thus prominent negative deflections are recorded in aVL with positive deflections in aVR.
- Lead II represents the usual lead III and vice versa.
- Lead aVF is unaffected.
- There is decreasing R wave amplitude from leads V₁ through V₆. V₁ is the equivalent of the usual V₂ and vice versa.

Diagnostic Confirmation

The ECG should be repeated with the right and left arm leads reversed. Placing the V leads in the equivalent positions on the right side of the chest is necessary for accurate interpretation of the ECG.

Diagnostic Pitfalls

- Incorrect arm lead placement: Reversal of the arm leads can produce similar recordings in leads I, aVR, and aVL as observed with true dextrocardia but not in V₁ through V₆. A tip off to this error is the normal R wave progression in V₂ to V₆ and the marked dissimilarity of the record in leads I (negative complex) and V₆ with a normal amplitude R wave.
- Isolated dextrocardia without situs inversus invariably is associated with complicated cardiac malformations and is rarely seen in adults.
- In dextroposition, the heart is displaced to the right by lung disease. The ECG is normal, but R waves are prominent in V₁ through V₃ and decrease in amplitude from V₂ through V₆ (Fig. 10-11).

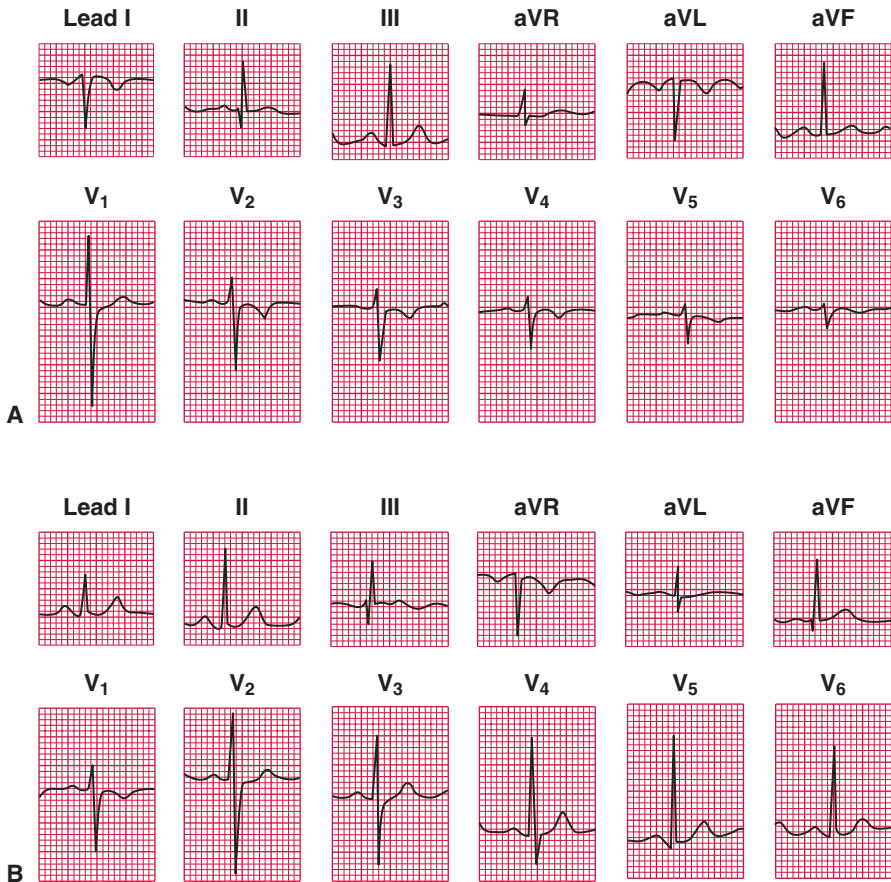


Fig. 10-10. Mirror-image dextrocardia with situs inversus. The patient is a 15-year-old girl. There is no evidence of organic heart disease. **A**, Tracing recorded with the conventional electrode placement. **B**, Tracing obtained with the left and right arm electrodes reversed. The precordial lead electrodes also were relocated in the respective mirror-image positions on the chest. The tracing is within normal limits. (From Chou TC: *Electrocardiography in Clinical Practice*, 4th ed., Philadelphia, 1996, WB Saunders, Elsevier Science.)

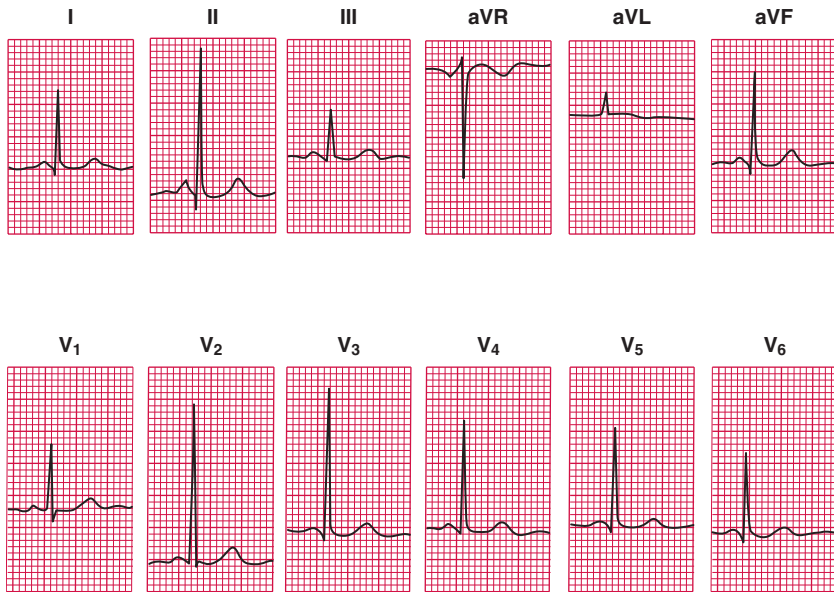


Fig. 10-11. Dextroposition. The patient is a 40-year-old woman with hypoplastic right pulmonary artery and right lung, probably of congenital origin. The heart and mediastinum are displaced to the right side of the chest. In the ECG, the limb leads are normal except for a relatively large R wave in lead II and S wave in lead aVR. The precordial leads show tall R waves in leads V₁ through V₃; the amplitude of the R waves decreases from V₂ through V₆. (From Chou TC: *Electrocardiography in Clinical Practice*, 4th ed., Philadelphia, 1996, WB Saunders, Elsevier Science.)

ELECTRICAL ALTERNANS

- Electrical alternans refers to regular alternation in the amplitude, direction, or configuration of the QRS complexes in any or all leads (Figs. 10-12 to 10-14). The RR intervals remain unchanged (regular).
- Total electrical alternans refers to involvement of the P, QRS, and T waves and occasionally the U wave.

Causes

- Alternans of the QRS complex is rare in patients with cardiac tamponade and occurs in some patients with a large pericardial effusion, particularly with malignancy.
- Total electrical alternans is almost diagnostic of cardiac tamponade, although it occurs in fewer than 10% of patients with tamponade and may be associated with a “swinging heart” on echocardiography.

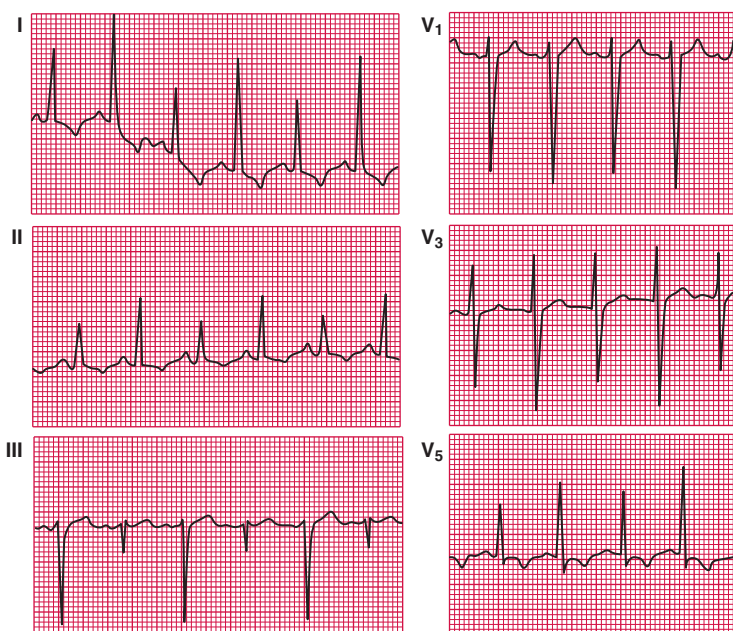


Fig. 10-12. Electrical alternans in postpericardiotomy syndrome. The patient is a 30-year-old man who developed pericarditis and pericardial effusion 3 weeks after aortic valve surgery. In the ECG, in addition to the alternation of the QRS complex, T wave alternans can be seen in lead III. (From Chou TC: *Electrocardiography in Clinical Practice*, 4th ed., Philadelphia, 1996, WB Saunders, Elsevier Science.)

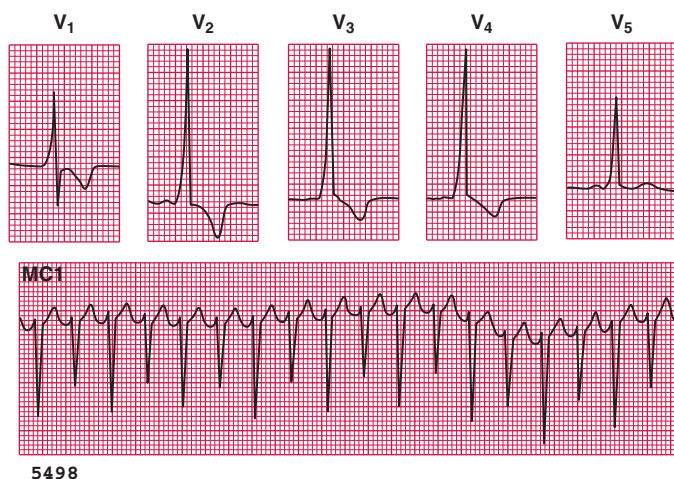


Fig. 10-13. Electrical alternans during supraventricular tachycardia (orthodromic atrioventricular reentrant tachycardia). The patient is a 23-year-old woman with type A Wolff-Parkinson-White syndrome without other evidence of organic heart disease. Alternation of the QRS complex is seen during the tachycardia. (From Chou TC: *Electrocardiography in Clinical Practice*, 4th ed., Philadelphia, 1996, WB Saunders, Elsevier Science.)

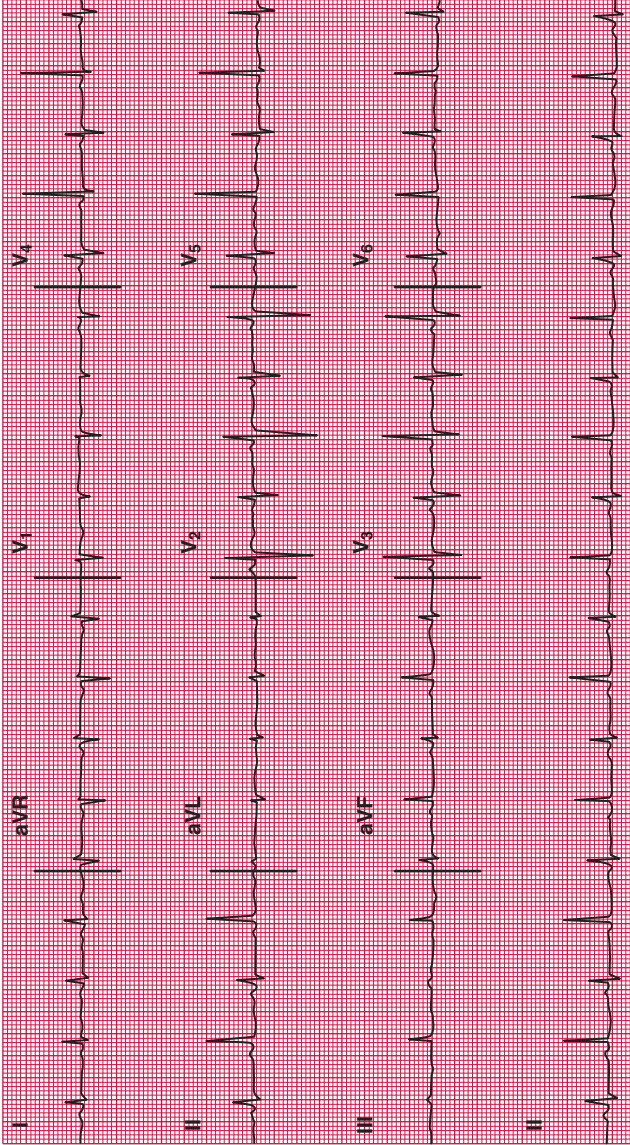


Fig. 10-14. Total electrical alternans (P-QRS-T) caused by pericardial effusion with tamponade. This finding, particularly in concert with sinus tachycardia and relatively low voltage, is a highly specific, although not sensitive, marker of cardiac tamponade. (From Braunwald E: *Heart Disease: A Textbook of Cardiovascular Medicine*, 5th ed., Philadelphia, 1997, WB Saunders, Elsevier Science.)

- Severe coronary artery and hypertrophic heart disease is a rare cause of electrical alternans.
- Supraventricular tachycardia with a very rapid ventricular rate, mainly occurring in patients with Wolff-Parkinson-White syndrome (orthodromic) reentrant tachycardia (*see* Fig. 10-13), is another cause.

ELECTRONIC PACING

Ventricular Pacing

- The pacemaker impulse, a sharp narrow spike, is followed by a QRS complex of different morphology than the intrinsic QRS. With right ventricular pacing, the QRS complex is similar to that of left bundle branch block (Figs. 10-15 and 10-16).
- With left ventricular epicardial myocardial pacing, the QRS shows a RBBB morphology.
- Pacemakers in a “unipolar pacing mode” cause a larger amplitude spike than that of bipolar pacing.

VENTRICULAR DEMAND PACING (VVI)

Pacing output is inhibited by sensed ventricular signal (*see* Fig. 10-20).

Atrial Pacing

Pacemaker spike is followed by P wave and narrow paced QRS complexes in response to paced atrial beats (Fig. 10-17).

ATRIAL DEMAND PACING (AAI)

Pacing output is inhibited by sensed atrial signal.

Atrioventricular Sequential Pacing

- Atrial followed by ventricular pacing (Fig. 10-18).
- Could be pacing in both atrium and ventricle; senses R waves only (DVI pacing mode).
- Pacing in and senses both atrium and ventricle (DDD mode); synchronizes with atrial activity and paces ventricle after preset AV interval (Fig. 10-19).
- Output inhibited by sensed atrial signal (AAI) and by sensed ventricular signal (VVI), but tracking of atrial rate by ventricular sensing does not occur (DDI pacing mode).
- Fixed-rate (asynchronous) atrial and ventricular pacing at specific AV interval (DOO pacing mode).

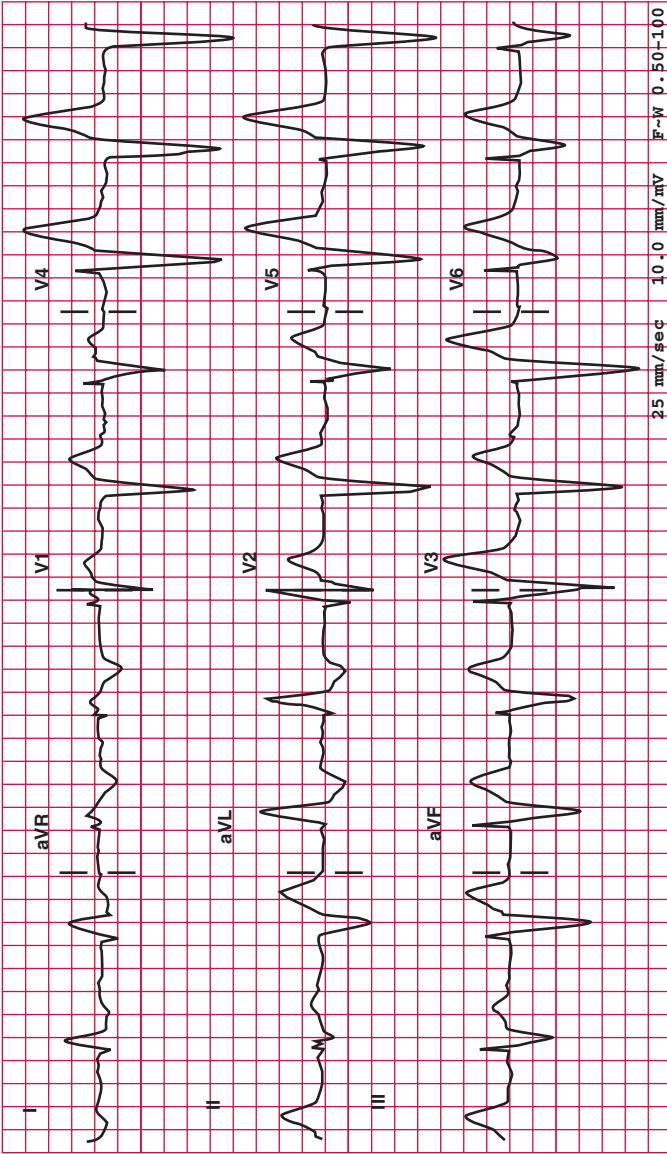


Fig. 10-15. Electronic pacing; capture rate = 60bpm.

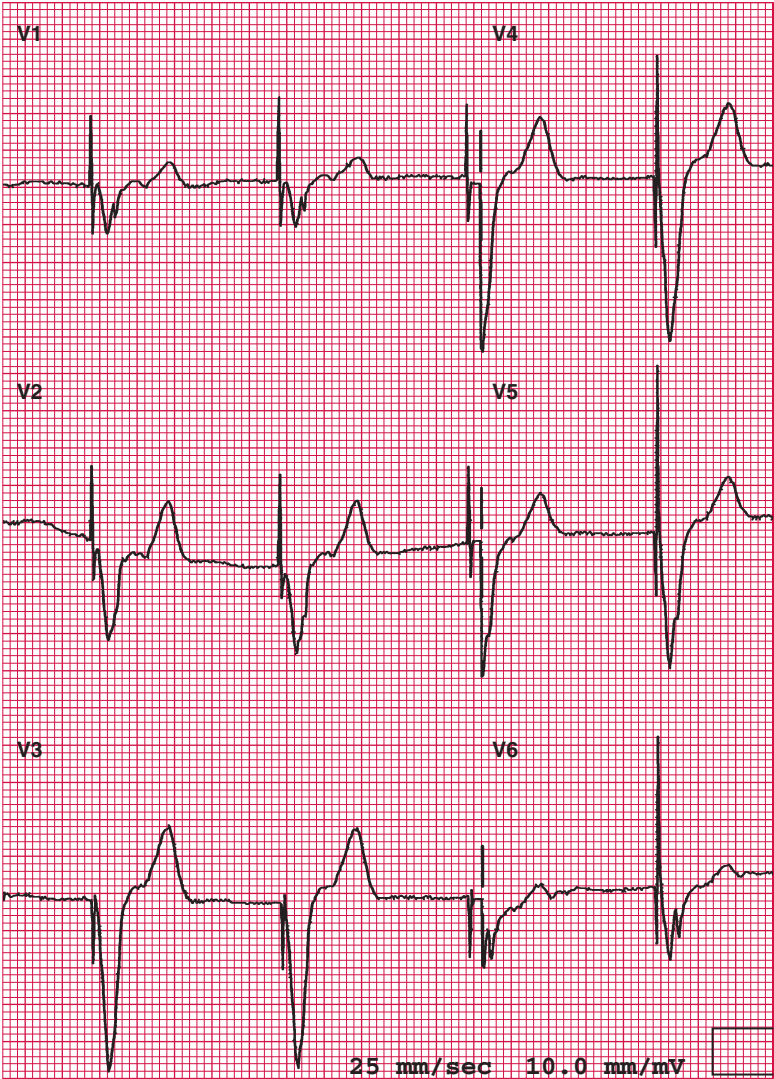


Fig. 10-16. Electronic pacemaker, ventricular capture; rate = 60bpm. No further analysis is attempted because of pacemaker rhythm.

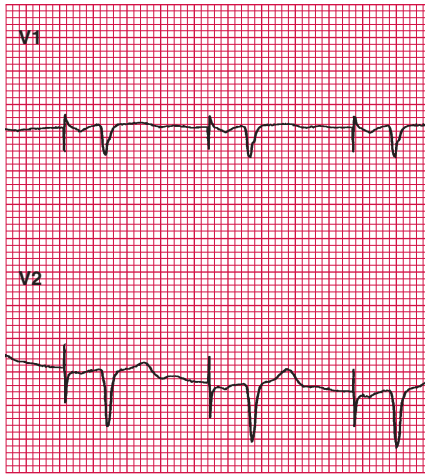
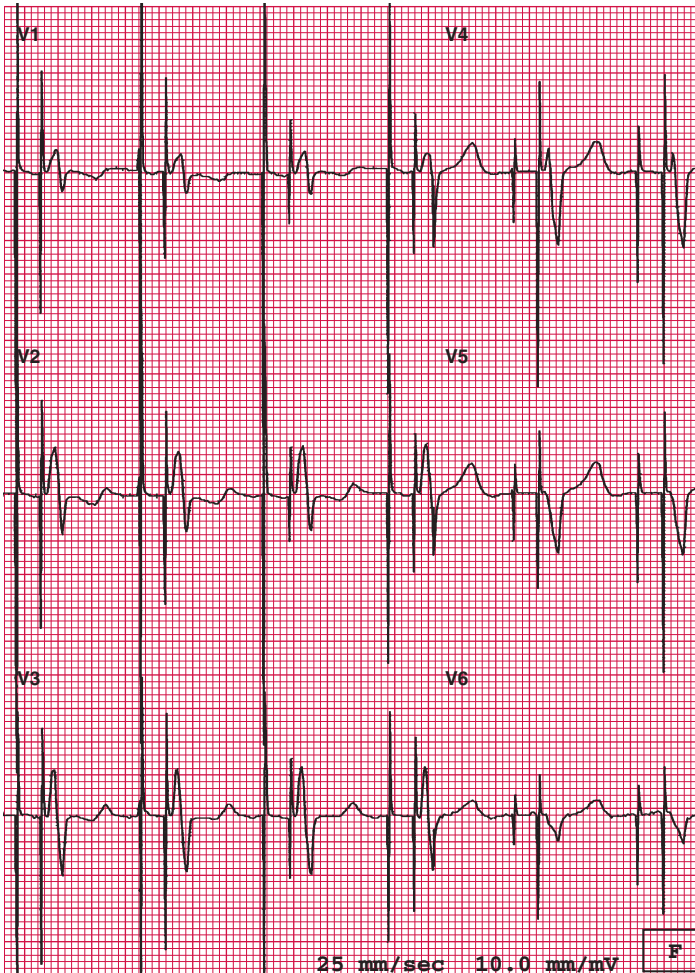


Fig. 10-17. Electronic pacemaker, atrial pacing; rate = 70 bpm.



Pacemaker Malfunction

UNDERSENSING MALFUNCTION

For a pacemaker in the inhibited mode, undersensing is diagnosed on ECG by a pacemaker spike at an inappropriately short interval after a spontaneous (intrinsic) event (i.e., a failure of the pacemaker to be inhibited by an appropriate intrinsic atrial or ventricular depolarization [QRS]). Figure 10-20 shows accurate sensing. With sensing malfunction, the pacemaker operates like a fixed-rate pacemaker; the spontaneous intrinsic QRS complexes are not sensed (Fig. 10-21).

Pacing Malfunction

- **Not firing:** failure of appropriate pacemaker output, which may be caused by failure of the pacemaker impulse to depolarize the ventricle because of inadequate voltage output from the pulse generator, a broken lead wire, or electrode displacement (Fig. 10-22).

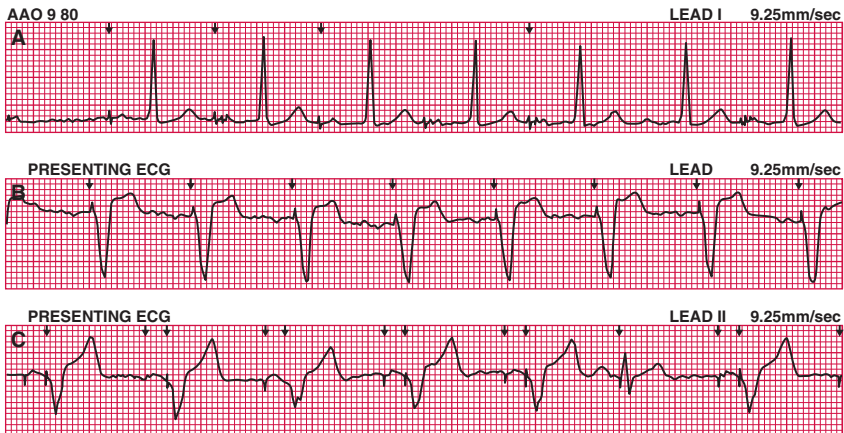


Fig. 10-19. Different modes of pacemaker function are shown. **A**, AAO, fixed rate atrial pacing. Note narrow, paced QRS complexes in response to paced atrial beats. **B**, VDD, the pacemaker senses the atrium and the ventricle and paces the ventricle. Each spontaneous P wave is followed by a paced ventricular complex. **C**, DDD, the pacemaker senses and paces in the atrium and the ventricle. The sixth complex of this strip represents a spontaneous P wave that conducts to the ventricle, resulting in a narrow QRS complex with the pacing spike occurring in the ventricular refractory period. Arrows indicate pacing stimulus artifacts. (From Saksena S: In Khan, M. Gabriel: *Heart Disease Diagnosis and Therapy*, Baltimore, 1996, Williams & Wilkins.)



Fig. 10-18. Electronic pacemaker, ventricular capture; rate = 72 bpm; atrioventricular sequential pacemaker.

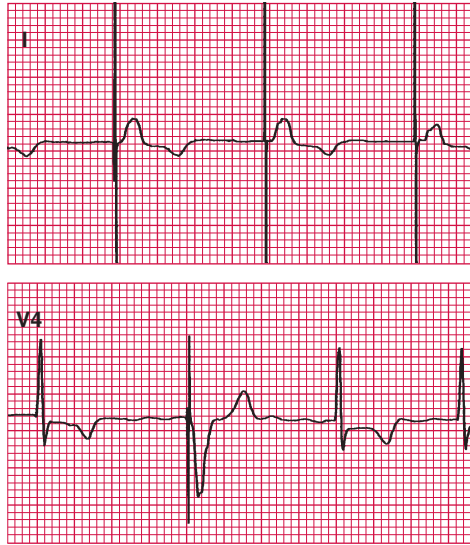
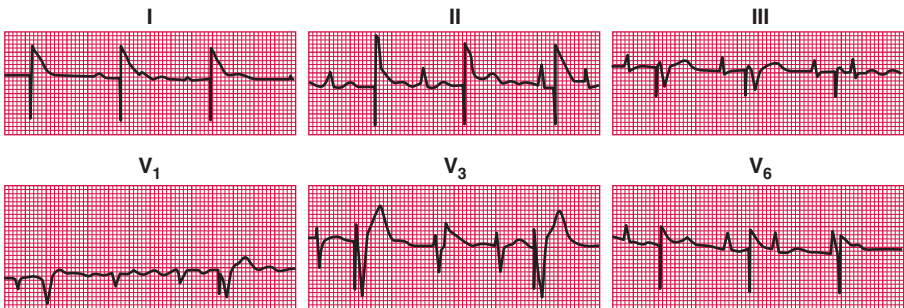


Fig. 10-20. Electronic pacemaker, demand mode; ventricular capture rate = 75 bpm. Note the spontaneous beat in V_4 is followed by sensing and pacemaker capture at the appropriate interval, which is equal to that shown in lead I. The pacemaker output is inhibited appropriately in response to the intrinsic QRS complex (the first beat in lead V_4).



570909 64F

Fig. 10-21. Ventricular demand pacemaker (VVI) with sensing malfunction. The pacemaker operates like a fixed-rate pacemaker. The spontaneous ventricular beats are not sensed. The spontaneous rhythm is atrial fibrillation. (From Chou TC: *Electrocardiography in Clinical Practice*, 4th ed., Philadelphia, 1996, WB Saunders, Elsevier Science.)

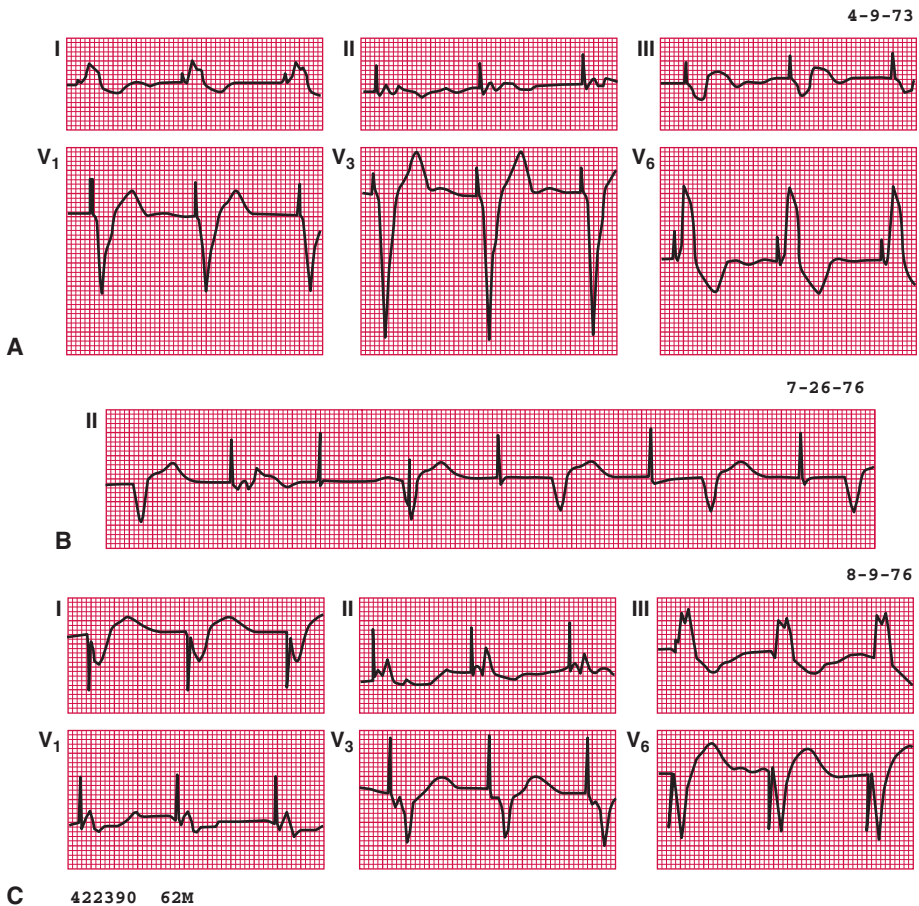


Fig. 10-22. Right and left ventricular pacemakers and pacemaker malfunction. These tracings were obtained from the same patient. **A**, Tracing recorded when the patient had a transvenous right ventricular demand pacemaker that was functioning properly. Because there are no spontaneous beats, the demand function of the pacemaker cannot be demonstrated. **B**, Tracing showing intermittent pacing failure. The first QRS complex is a spontaneous beat. The second complex is pacemaker induced. The next pacemaker spike appears prematurely and is not followed by ventricular depolarization. A pseudofusion beat follows. None of the last three pacemaker stimuli captures the ventricle. The sensing function of the pacemaker appears intact. The pacing malfunction was found to be the result of a broken lead. (From Chou TC: *Electrocardiography in Clinical Practice*, 4th ed., Philadelphia, 1996, WB Saunders, Elsevier Science.) **C**, Tracing recorded after the patient received an epicardial left ventricular pacemaker. (From Chou TC: *Electrocardiography in Clinical Practice*, 4th ed., Philadelphia, 1996, WB Saunders, Elsevier Science.)

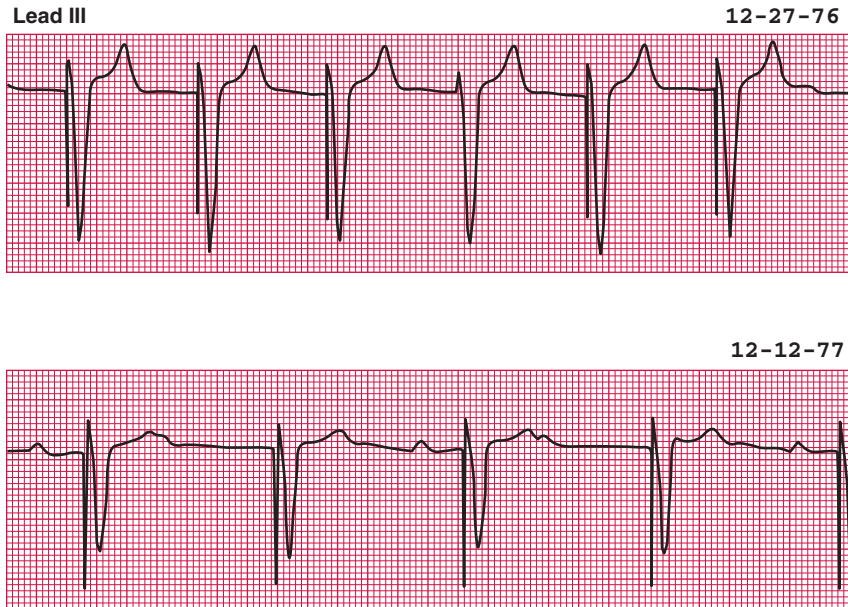


Fig. 10-23. Battery failure. The battery power failure is indicated by a decrease of the pacing rate from 70 to 47 bpm. (From Chou TC: *Electrocardiography in Clinical Practice*, 4th ed., Philadelphia, 1996, WB Saunders, Elsevier Science.)

- Battery power failure: indicated by a decrease of the pacing rate (Fig. 10-23).

PULMONARY EMBOLISM

The ECG findings are nonspecific; more importantly, the transient occurrence of the following should heighten clinical suspicion of PE:

- Sinus tachycardia
- Symmetrical T wave inversion; strain pattern in leads V_1 through V_3 or V_4
- ST depression in leads I, II, and V_3 through V_6
- S_1Q_3 or $S_1Q_3T_3$ pattern (Fig. 10-24)
- Incomplete or complete RBBB pattern
- Q waves in leads V_1 , III, and aVF but not in lead II
- QR in V_1
- ST segment elevation in leads V_1 through V_2 or V_3 , aVR, and III (*see* Fig. 10-24)
- ST segment depression in V_3 through V_5 or V_6 because of associated myocardial ischemia

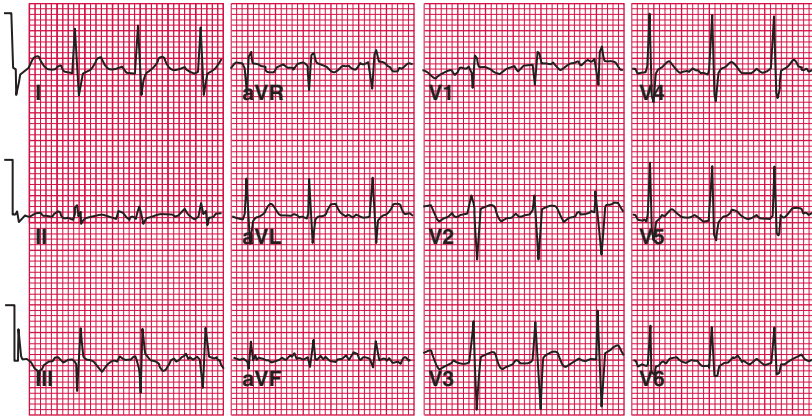


Fig. 10-24. Acute massive pulmonary embolus with the characteristic S_1Q_3 pattern and the more common but nonspecific changes, including incomplete right bundle branch block and ST segment elevation in leads V_1 through V_3 with terminal T wave inversion. (From Braunwald E: *Heart Disease: A Textbook of Cardiovascular Medicine*, 5th ed., Philadelphia, 1997, WB Saunders, Elsevier Science.)

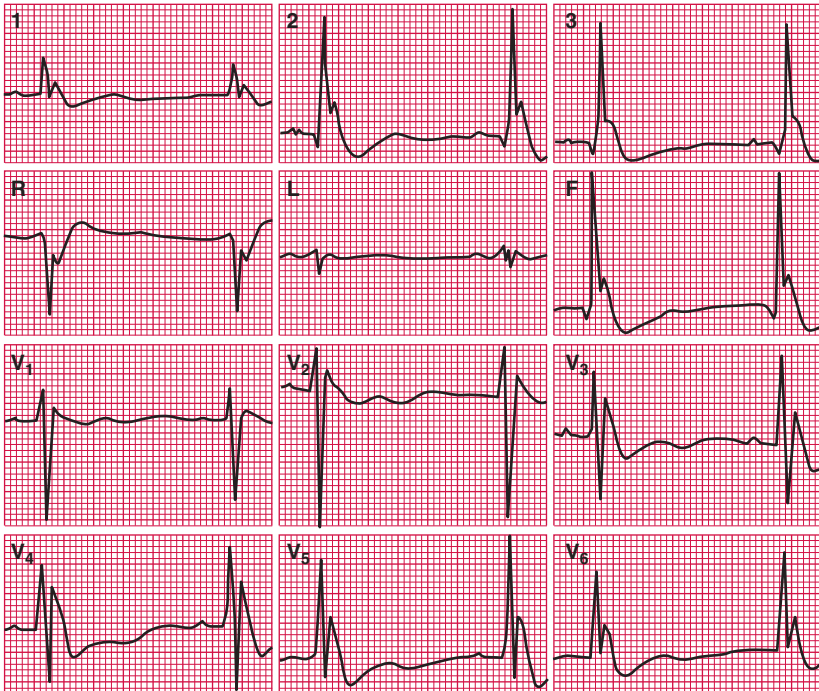


Fig. 10-25. Hypothermia. Note marked elevation of the J deflection is maximal in midprecordial leads. (From Marriott JLH: *Practical Electrocardiography*, 8th ed., Baltimore, 1988, Williams & Wilkins.)

- S₁, S₂, S₃ pattern
- Arrhythmias that include premature beats, atrial flutter or atrial fibrillation, and VF
- Right atrial enlargement
- Right-axis deviation

In the presence of submassive PE, the ECG may show no significant abnormality. With massive PE causing syncope, cardiogenic shock, or acute right-sided heart failure, at least two of the preceding ECG changes usually occur.

HYPOTHERMIA

- All intervals (PR, RR, QRS, and QT) may lengthen.
- Elevated “T waves” (Osborn waves) appear (Fig. 10-25); the start of the ST segment, especially in V₃ and V₄, is elevated, hitched-up, representing distortion of early repolarization.
- Atrial fibrillation occurs often with body temperatures below 32°C.

HYPERCALCEMIA

- Typically causes a shortened QT interval, reflected by an abrupt ascending slope and a gradual downslope of the descending limb of the T wave. This causes a virtual absence of the ST segment.

HYPOCALCEMIA

- Typically causes a prolonged QT interval. The T wave remains normal.

11

Arrhythmias

CONTENTS

ATRIAL PREMATURE BEATS
JUNCTIONAL OR NODAL PREMATURE BEATS
VENTRICULAR PREMATURE BEATS
BRADYARRHYTHMIAS
NARROW QRS TACHYCARDIAS
WIDE QRS TACHYCARDIA
REGULAR WIDE QRS TACHYCARDIA

ATRIAL PREMATURE BEATS

ECG Diagnostic Points

- The morphology of an atrial premature P wave is different from that of the sinus P wave (Fig. 11-1).
- The premature P wave is usually followed by a QRS complex similar to that with the normally conducted sinus beat. The premature P wave may be unrecognizable because it is hidden in the preceding T wave, hence the admonition “search the T for the P” (Figs. 11-2 and 11-3).
- The PR interval of an atrial premature beat (APB) is more than 0.11 second; if the P wave is inverted in leads II, III, and aVF, the PR should be more than 0.11 second to distinguish an APB from a junctional premature beat.
- Early occurring APBs may trigger atrial tachycardia (*see* Fig. 11-2), atrial flutter, or atrial fibrillation.
- APBs that follow every sinus beat cause atrial bigeminy (*see* Fig. 11-1).
- The atrial premature P wave may not be conducted, resulting in a pause (*see* Fig. 11-3).

Nonconducted APBs are the most common cause of pauses. If the premature P waves are not identified, the rhythm may be misinterpreted as sinus bradycardia.

From: *Contemporary Cardiology: Rapid ECG Interpretation, 3e*
by: M. Gabriel Khan © Humana Press Inc., Totowa, NJ

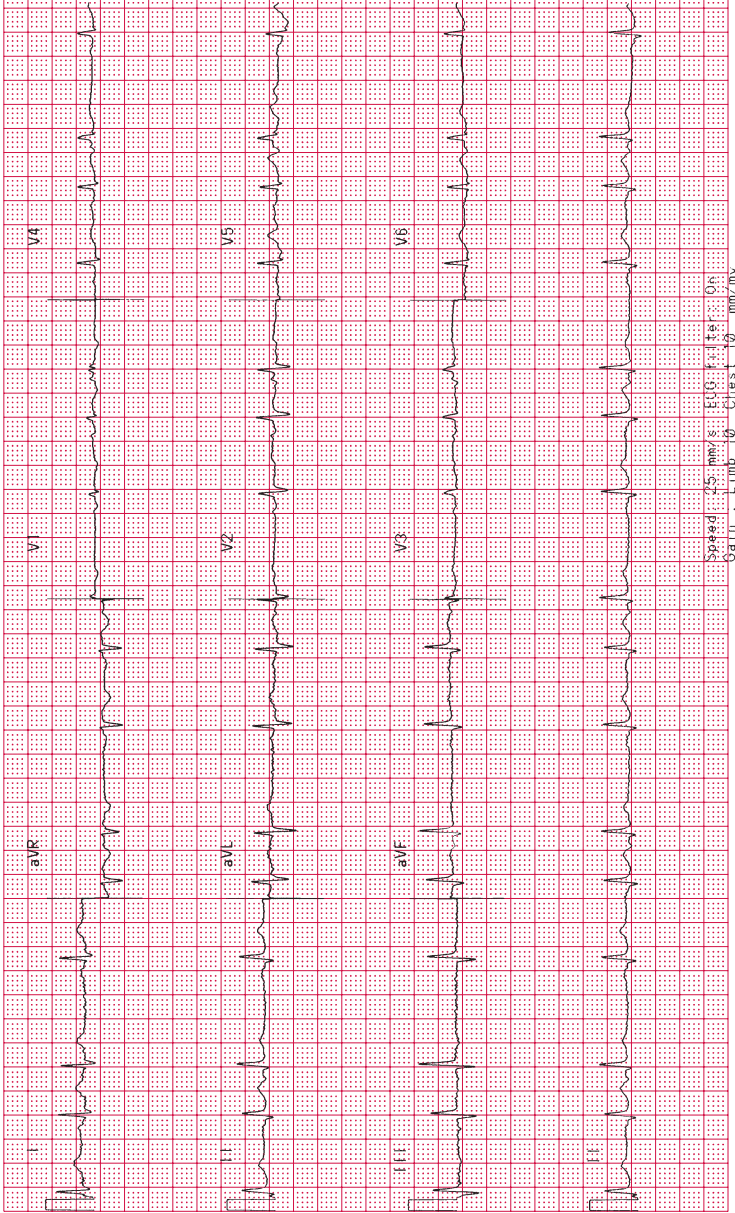


Fig. 11-1. Atrial trigeminy: each sinus beat is followed by a pair of atrial premature beats (APBs); this is true atrial trigeminy. If every third beat is an APB but not a pair of APBs the condition should not be termed atrial trigeminy. Non diagnostic inferior Q waves noted.

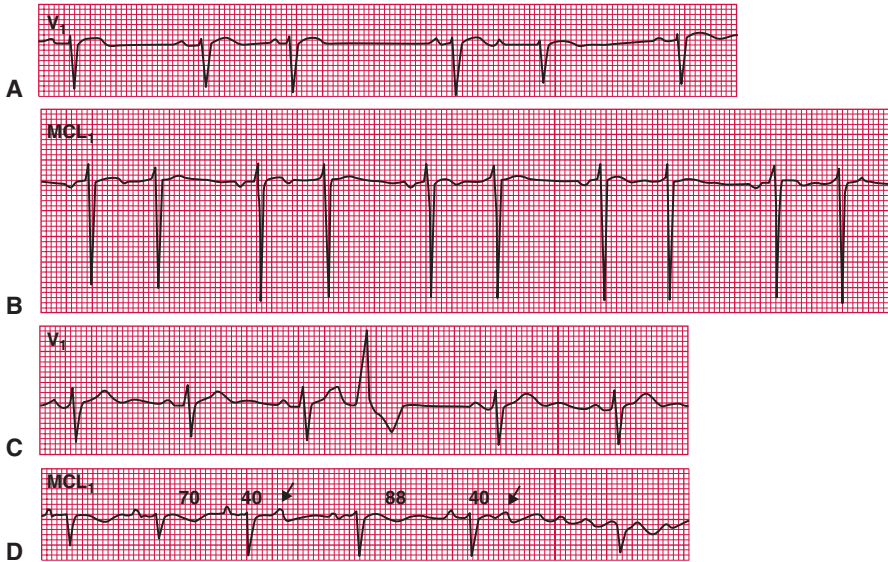


Fig. 11-2. **A**, The third and fifth beats are atrial premature beats (APBs). Note that the shorter RP of the second APB is complemented by a much prolonged PR interval. **B**, Atrial bigeminy in which the PR of the APBs is much prolonged compared with the normal PR of the sinus beats. **C**, The fourth beat is an APB with right bundle branch block aberration. Note the deformed T wave and the less than compensatory postectopic cycle. **D**, When the APB is premature enough to make the PP interval (40) less than half the preceding PP interval (88), an atrial tachyarrhythmia is triggered. (From Marriott JLH: *Practical Electrocardiography*, 8th ed., Baltimore, 1988, Williams & Wilkins.)

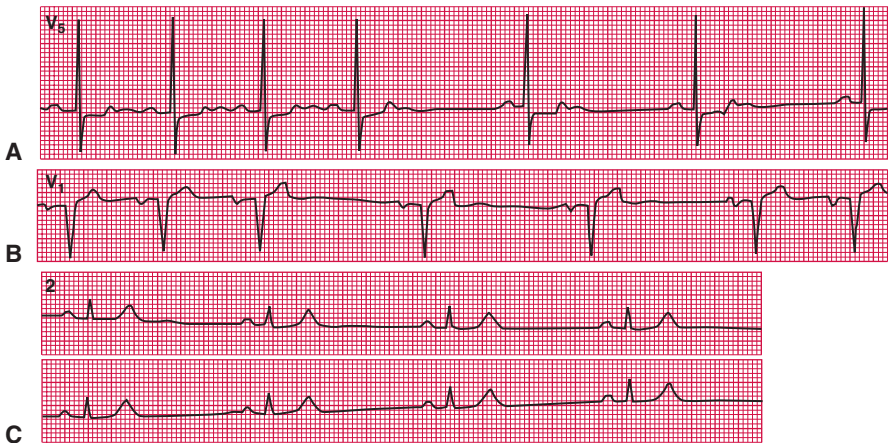


Fig. 11-3. After four sinus beats in (**A**) and after three sinus beats in (**B**), a run of nonconducted atrial bigeminy develops. Note in each strip the subtle deformity of the T wave compared with the preceding T waves, resulting from superimposed P' waves. In (**C**), the T waves look a little too pointed for natural T waves; however, when no previous T waves are available for comparison, it is impossible to diagnose the atrial bigeminy. (From Marriott JLH: *Practical Electrocardiography*, 8th ed., Baltimore, 1988, Williams & Wilkins.)

- If the APB traverses the atrioventricular (AV) junction at a time when one of the bundle branches is still refractory, aberrant ventricular conduction may occur. The QRS is wide and resembles a ventricular premature beat (VPB) (*see* Fig. 11-2C). Examination of the preceding T wave may reveal a deformity caused by a P wave stuck on the T wave, as shown in Fig. 11-2C. In addition, a postectopic cycle that is less than compensatory points to atrial ectopy with aberration.
- Multiple APBs may cause an irregularly irregular pulse.

JUNCTIONAL OR NODAL PREMATURE BEATS

ECG Diagnostic Points

- Junctional P waves may activate the atria retrogradely, and the retrograde P wave may precede the QRS complex (Fig. 11-4). Retrograde conduction may not be observed, and the P wave may become lost in the QRS complex (Fig. 11-5). Occasionally, the P wave follows the QRS complex.
- The P wave, when visible, is inverted in leads II, III, aVF, V₁, V₅, and V₆ and is upright in leads I, aVR, and aVL.
- The P wave may precede the QRS complex by less than 0.11 second.
- The terms upper-, mid-, or lower-nodal rhythm have been replaced by the term junctional rhythm.

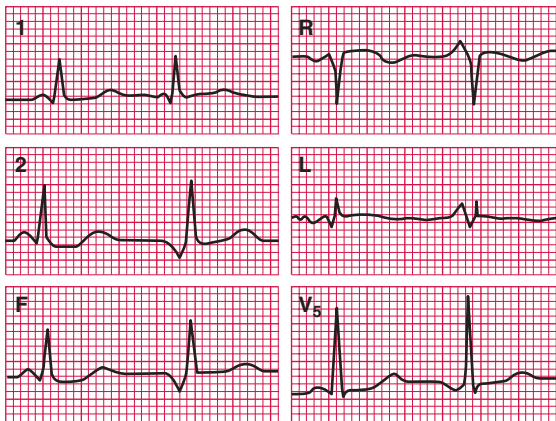


Fig. 11-4. Junctional premature beats with antecedent P' waves. In each lead, the first beat is a sinus beat and the second is a junctional premature beat with a short PR interval and typical P wave polarity. (From Marriott JLH: *Practical Electrocardiography*, 8th ed., Baltimore, 1988, Williams & Wilkins.)

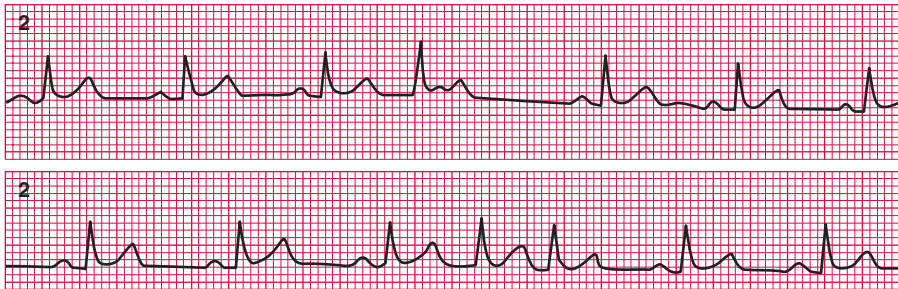


Fig. 11-5. Junctional premature beats (JPBs) without retrograde conduction. In the upper strip, the fourth beat is a junctional extrasystole. In the lower strip, the fourth and fifth beats are a pair of JPBs. In neither strip is the regular sinus discharge interrupted by retrograde conduction. (From Marriott JLH: *Practical Electrocardiography*, 8th ed., Baltimore, 1988, Williams & Wilkins.)

VENTRICULAR PREMATURE BEATS

ECG Diagnostic Points

- There is a wide, bizarre, premature QRST complex, with ST segment sloping off in the direction opposite the abnormal QRS complex (Figs. 11-6 to 11-8).
- There have been no preceding premature P waves. Retrograde conduction of ectopic ventricular impulses occurs often. The retrograde P wave is usually hidden in the ventricular complex but occasionally can cause retrograde capture of the atria, and the inverted P wave may be observed following the VPB (*see* Fig. 11-7).
- A VPB usually is followed by a fully compensatory pause, but this rule is often broken, and pauses may be less than compensatory.
- VPB duration generally is greater than 0.11 second, but occasionally, VPBs can be as short as 0.1 second in duration.
- If in V_1 the abnormal-looking QRS shows a left “rabbit ear” larger than the right “rabbit ear” (*see* Fig. 11-6), a diagnosis of VPB is certain. If the left “rabbit ear” is smaller than the right, no firm conclusion can be made from the morphology alone.
- Figure 11-8 shows ventricular bigeminy.
- A run of two beats is called a couplet; of three consecutive beats, a triplet or a salvo of three (Fig. 11-9); more than three consecutive VPBs is called ventricular tachycardia (VT) (Fig. 11-10).

With multifocal VPBs, the coupling intervals vary; with unifocal VPBs, the coupling intervals are equal. Unifocal VPBs are of little consequence. VPBs that occur early, close to the T wave or R on T, and

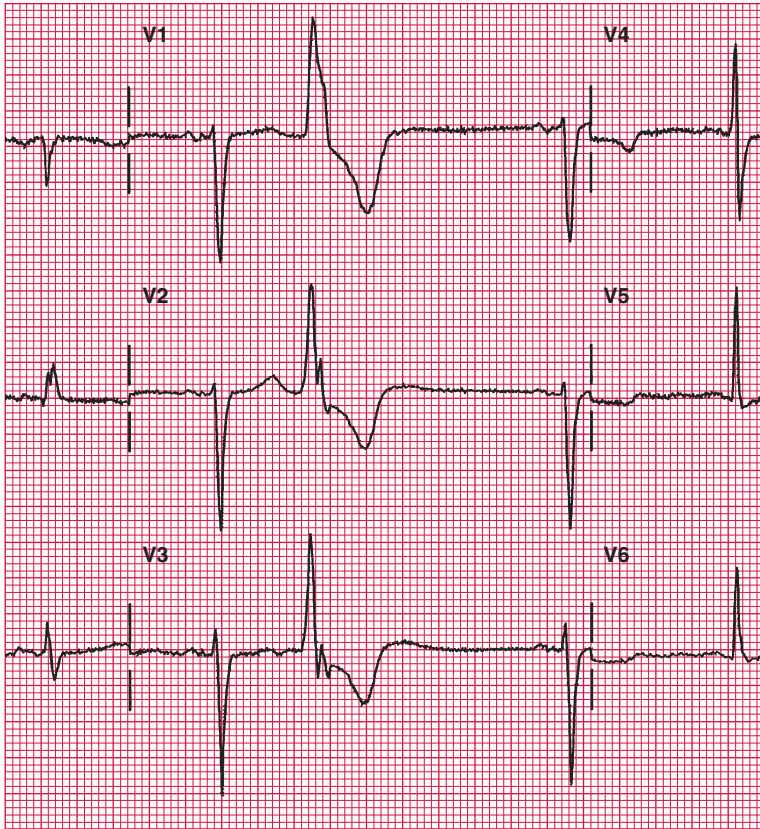


Fig. 11-6. A ventricular premature beat: The ST segment slopes in the direction opposite the slope of the abnormal QRS complex; V_1 shows a left “rabbit ear” larger than the right “rabbit ear.”

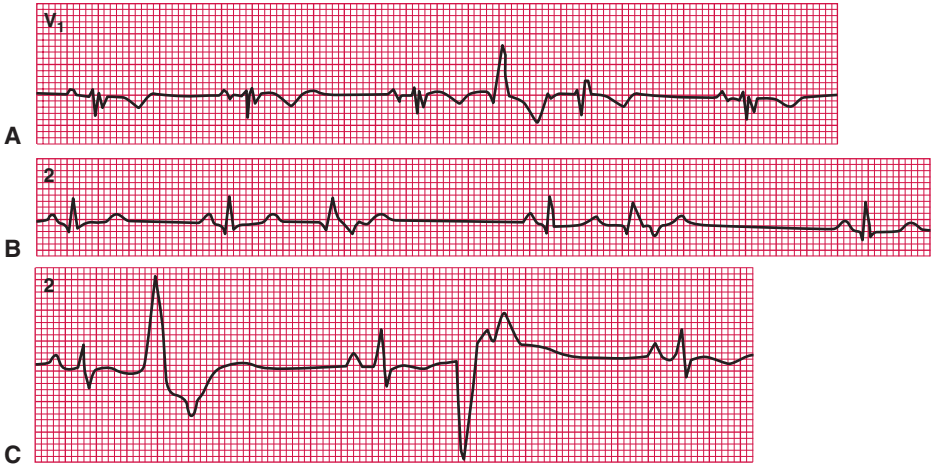


Fig. 11-7. **A**, The fourth beat is an interpolated ventricular premature beat (VPB). Note that it lengthens the PR interval of the next sinus beat (from 0.15 to 0.22 second)—evidence of “concealed” (retrograde) conduction into the atrioventricular junction. **B**, The two ventricular extrasystoles are followed by retrograde (inverted) P waves at normal RP intervals of 0.17 and 0.19 second. **C**, Both VPBs are followed by retrograde P waves at abnormally prolonged RP intervals (0.28 and 0.22 second). (From Marriott JLH: *Practical Electrocardiography*, 8th ed., Baltimore, 1988, Williams & Wilkins.)

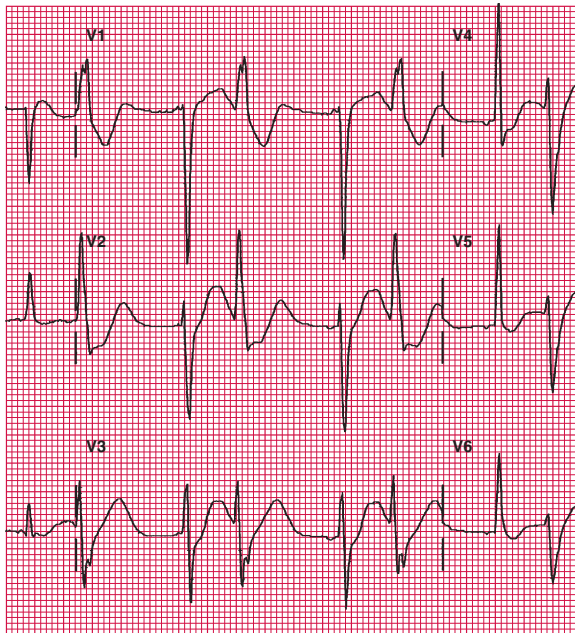


Fig. 11-8. Ventricular bigeminy.

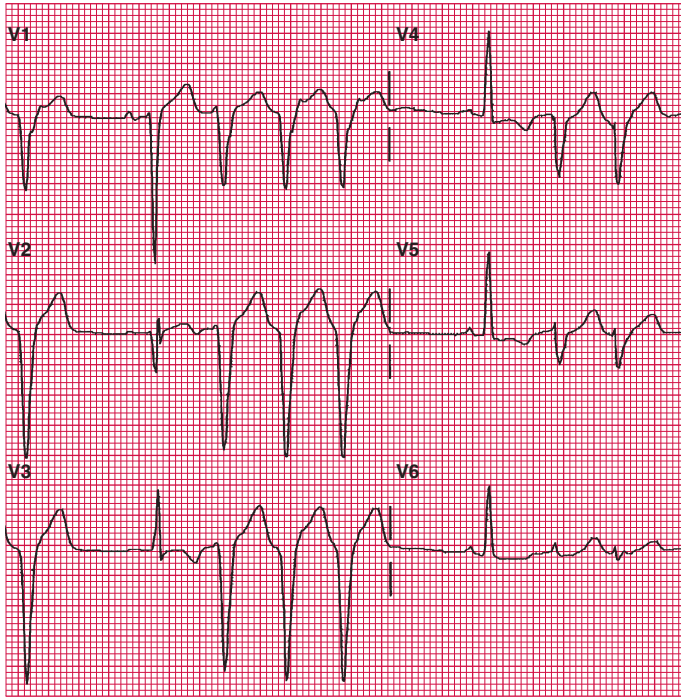


Fig. 11-9. Ventricular premature beats occur in pairs (couplets) and in salvos of three (triplets).

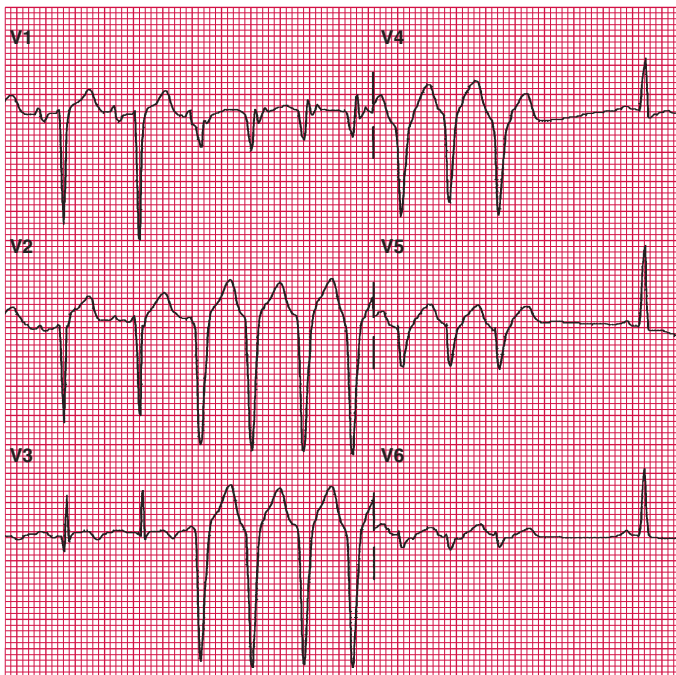


Fig. 11-10. Short run of nonsustained ventricular tachycardia.

that are multifocal or multiform, occurring as couplets or triplets, may trigger VT (Fig. 11-11).

VPBs occur commonly in normal and abnormal hearts. The word *beat* denotes an electrical and mechanical event and is preferred to the word *contraction*, which implies a mechanical event. This text uses the terms VPBs and APBs, not VPCs and APCs.

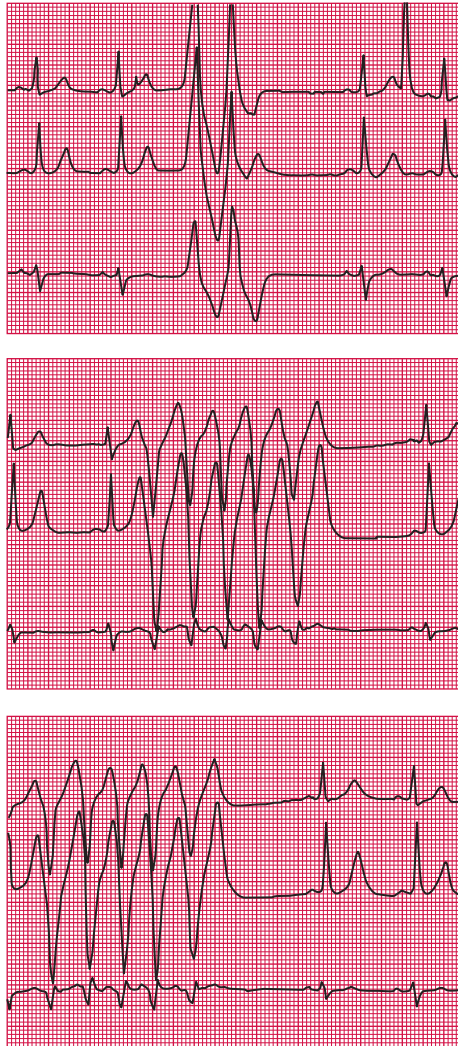


Fig. 11-11. Holter monitor showing multifocal ventricular premature beats: couplet, salvos of three, nonsustained ventricular tachycardia. (From Khan, M. Gabriel: *On Call Cardiology*, 3rd ed., Philadelphia, 2006, WB Saunders, Elsevier Science.)

BRADYARRHYTHMIAS

First-Degree Atrioventricular Block

ECG DIAGNOSTIC POINTS

- PR interval is longer than 0.2 second; usually 0.22 to 0.48 second, but can be as long as 0.8 second (Fig. 11-12). Some normal individuals have intervals up to 0.22 second.
- The PR interval should be constant.
- Each P wave should be followed by a QRS complex.

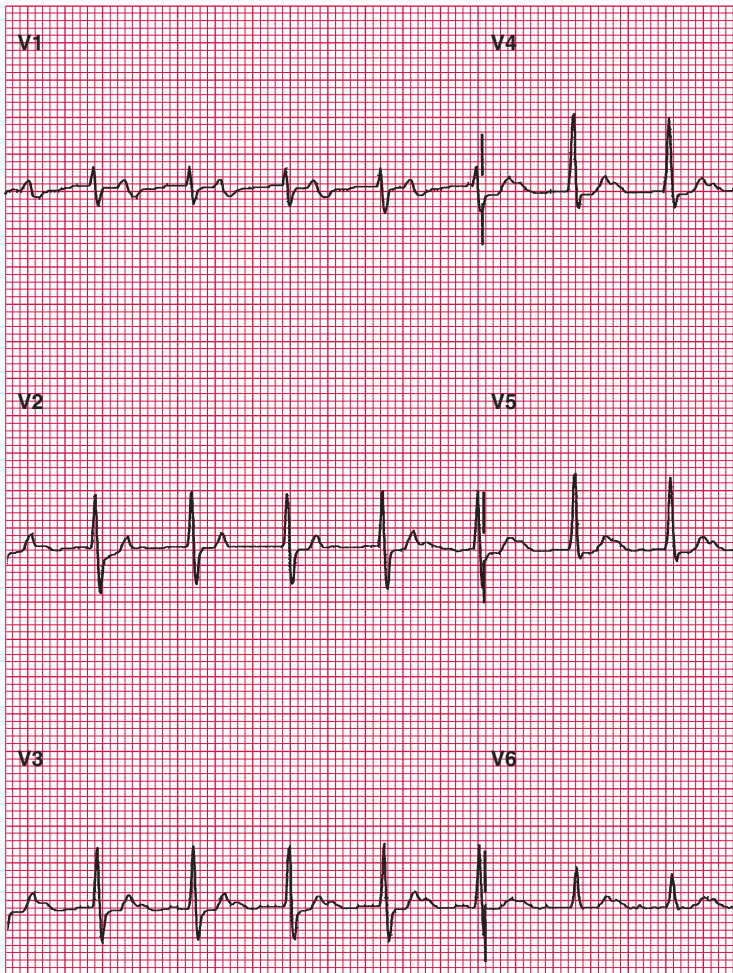


Fig. 11-12. Sinus tachycardia: rate, 118bpm; PR is prolonged to 0.28 second: first-degree atrioventricular block.

Second-Degree Atrioventricular Block: Mobitz Type I (Wenckebach) Block

ECG DIAGNOSTIC CRITERIA

- There is progressive prolongation of the PR interval until the P wave is blocked, the impulse fails to conduct to the ventricles, and the QRS beat is dropped.
- After the dropped QRS beat, the PR interval reverts to near normal; the PR interval that follows the blocked P wave is always short.
- The RR interval containing the nonconducted P wave is shorter than two of the shorter cycles (i.e., shorter than the sum of two PP intervals) (Fig. 11-13).
- Because there is usually a progressive shortening of the RR interval before a P wave is blocked, beats often are grouped in pairs (bigeminy) or trios (trigeminy). This group pattern is a hallmark of Wenckebach but is not necessary for the diagnosis (Fig. 11-14).

Second-Degree Atrioventricular Block: Mobitz Type II Block

ECG DIAGNOSTIC CRITERIA

- At least two regular and consecutive atrial impulses are conducted with the same PR interval before the dropped beat (Fig. 11-15).

Lead aVF

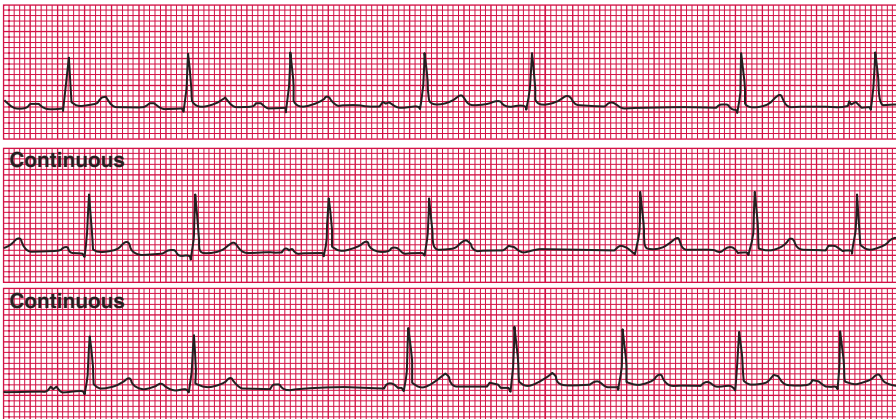
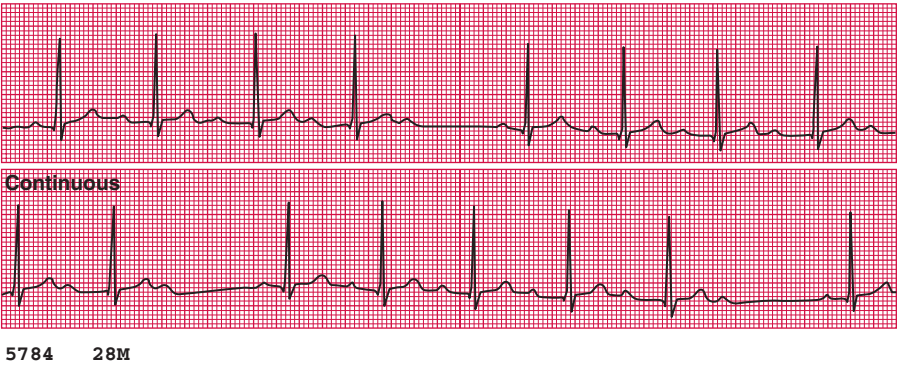


Fig. 11-13. Mobitz type I second-degree atrioventricular block without the typical Wenckebach phenomenon. Note the random variation of the PR and RR intervals except that the PR interval that follows the blocked P waves is always short. The QRS complexes that terminate the pauses may be junctional escape beats. (From Chou TC: *Electrocardiography in Clinical Practice*, 4th ed., Philadelphia, 1996, WB Saunders, Elsevier Science.)

II



5784 28M

Fig. 11-14. Mobitz type I second-degree atrioventricular block without the typical Wenckebach phenomenon. There is no progressive shortening of the RR interval before the block. (From Chou TC: *Electrocardiography in Clinical Practice*, 4th ed., Philadelphia, 1996, WB Saunders, Elsevier Science.)

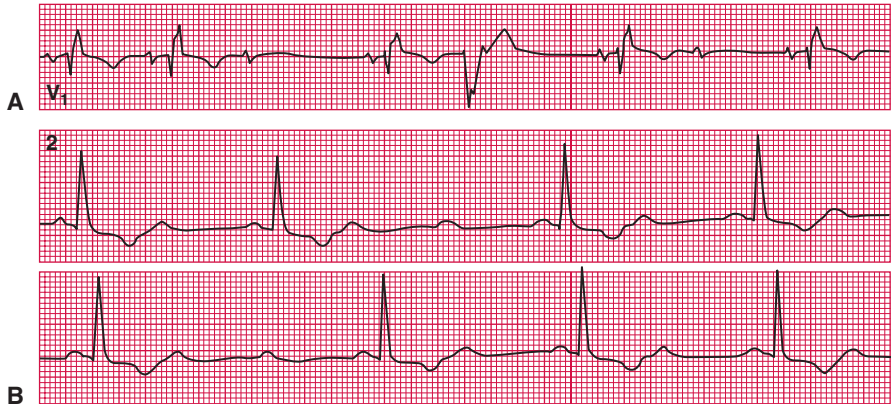


Fig. 11-15. **A**, Mobitz type II second-degree atrioventricular (AV) block. Two consecutive PR intervals are unchanged before the dropped beat. The conducted beats have a normal PR interval and show right bundle branch block. The fourth beat is a right ventricular premature beat. **B**, High-grade second-degree AV block. Sinus rhythm with 2:1 and 3:1 AV block. (From Marriott JLH: *Practical Electrocardiography*, 8th ed., Baltimore, 1988, Williams & Wilkins.)

- With type II, high-grade second-degree AV block (Fig. 11-15B), two or more consecutive atrial impulses fail to be conducted because of the block itself. The diagnosis is strengthened if the atrial rate is slow (less than 135 beats/min [bpm]) in the absence of interference by an escaping subsidiary pacemaker that may prevent conduction.
- Intermittent nonconducted P waves are observed, but with no evidence for atrial prematurity.
- The RR interval containing the nonconducted P wave is equal to two PP intervals.
- The PR interval remains constant and is normal or slightly prolonged.
- The ventricular rhythm is irregular because of nonconducted beats.
- If the conduction problem is in the bundle of His, the QRS complex remains narrow, but it will be longer than 0.12 second if the lesion is below the bundle of His.

Complete (Third-Degree) Atrioventricular Block

ECG DIAGNOSTIC CRITERIA

- P waves are sinus and plentiful with few QRS complexes.
- There is AV dissociation: no relationship between P waves and QRS complexes: complete absence of AV conduction (Figs. 11-16 and 11-17).

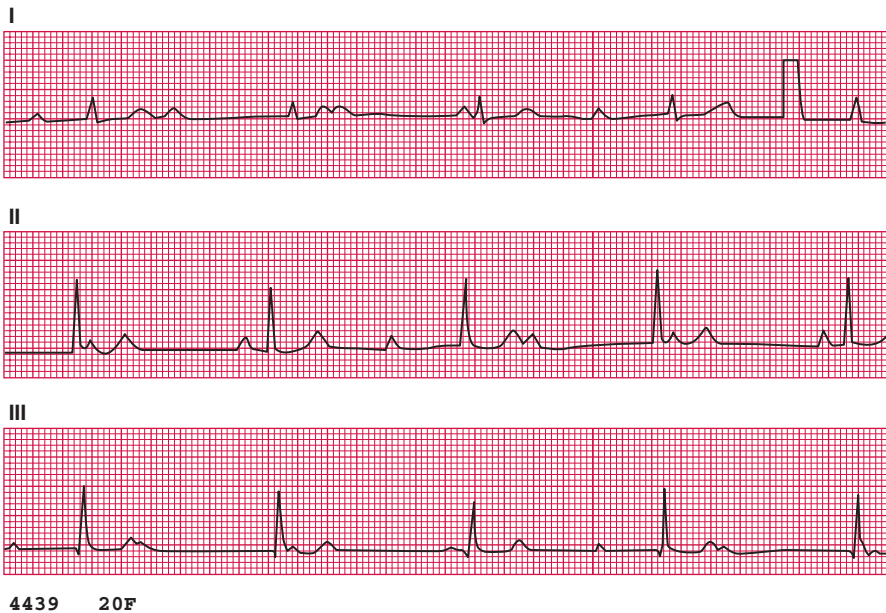
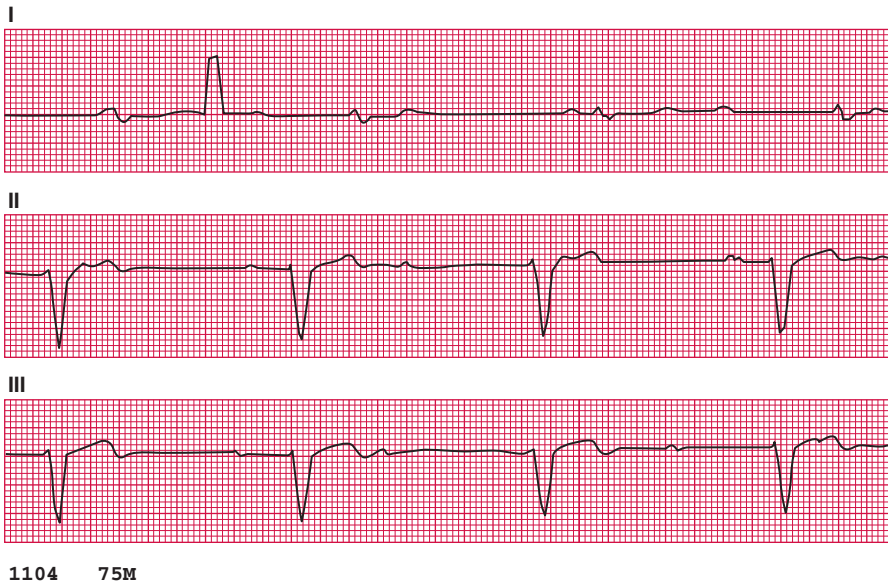


Fig. 11-16. Congenital complete atrioventricular block. The narrow QRS complexes suggest that the escape pacemaker is junctional in origin. (From Chou TC: *Electrocardiography in Clinical Practice*, 4th ed., Philadelphia, 1996, WB Saunders, Elsevier Science.)



1104 75M

Fig. 11-17. Complete atrioventricular block with idioventricular rhythm. The QRS complexes are abnormally wide and are different from those seen during sinus rhythm. The ventricular rate is 36bpm. (From Chou TC: *Electrocardiography in Clinical Practice*, 4th ed., Philadelphia, 1996, WB Saunders, Elsevier Science.)

Note that AV dissociation may occur in the absence of third-degree AV block; the clue here is that the ventricular rate is faster than the atrial rate.

- The RR intervals are regular. The QRS complex is narrow if the site of block is in the AV node with an escape rhythm originating in the AV junction. The QRS is wide if the escaped rhythm originates from the ventricle or in the AV junction in the presence of bundle branch block.
- The atrial rate is faster than the ventricular rate.
- The ventricular rate usually is very slow (less than 45 bpm), but with congenital AV block, rates may be 40 to 60 bpm (*see* Fig. 11-16).
- With complete AV block, anterograde conduction never occurs, but in less than 20% of complete AV blocks, retrograde conduction to the atria occurs.

Note that AV dissociation may occur in the absence of third-degree AV block.

NARROW QRS TACHYCARDIAS

Tachycardias should be differentiated as narrow QRS or wide QRS, then as regular or irregular (Fig. 11-18).

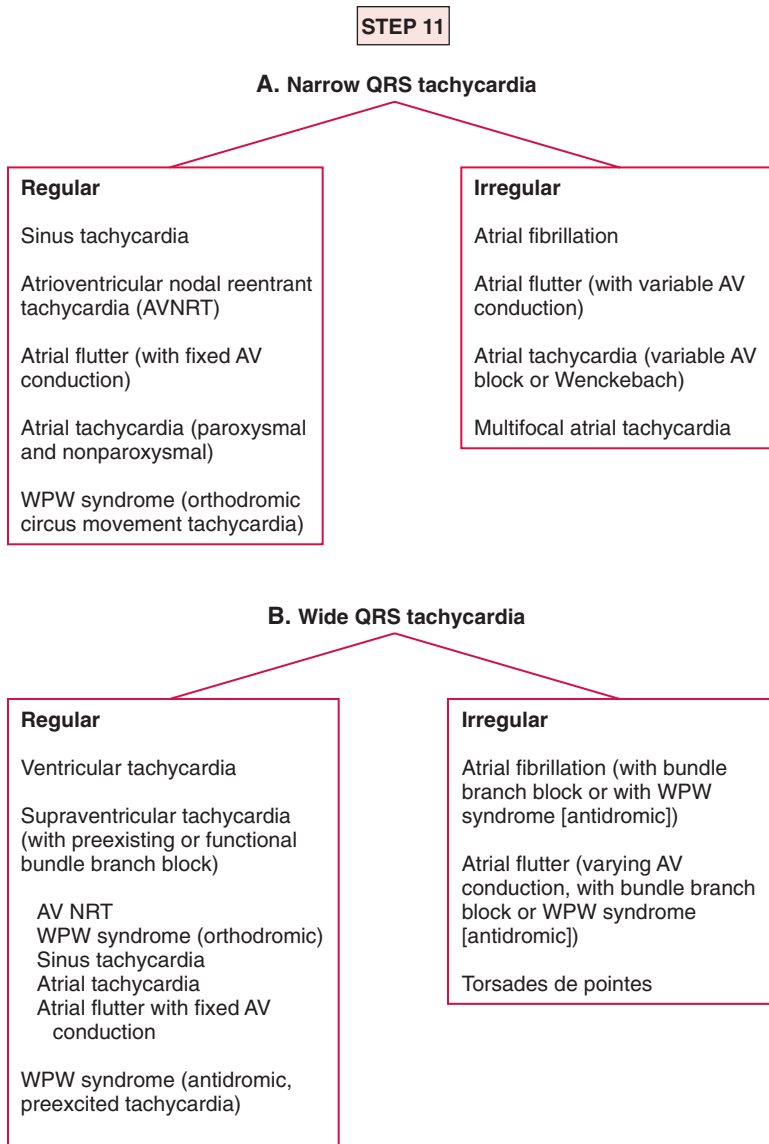


Fig. 11-18. Step-by-step method for accurate ECG interpretation. Step 11: Assess arrhythmias: differential diagnosis of narrow QRS tachycardia (A) and wide QRS tachycardia (B). AV, atrioventricular; WPW, Wolff-Parkinson-White. (Modified from Khan, M. Gabriel: *Heart Disease Diagnosis and Therapy*, New Jersey, 2006, Humana Press.)

A comparison of the entire 12-lead ECG during tachycardia with the ECG in sinus rhythm is most helpful for clarifying the diagnosis. Careful assessment of leads II, III, aVF, V₁, and V₆ should reveal clues to the diagnosis.

Sinus Tachycardia

Sinus tachycardia always should be considered if the rate is 100 to 130bpm because it is the most common cause of narrow QRS tachycardia (Fig. 11-19). With faster rates, the sinus P wave may be hidden in the T waves and mimic supraventricular tachycardia (SVT) or atrial flutter. The sinus P wave can be revealed by carotid massage.

Atrioventricular Nodal Reentrant Tachycardia

Atrioventricular nodal reentrant tachycardia (AVNRT) is the most common cause of a paroxysmal, narrow, regular QRS tachycardia. The

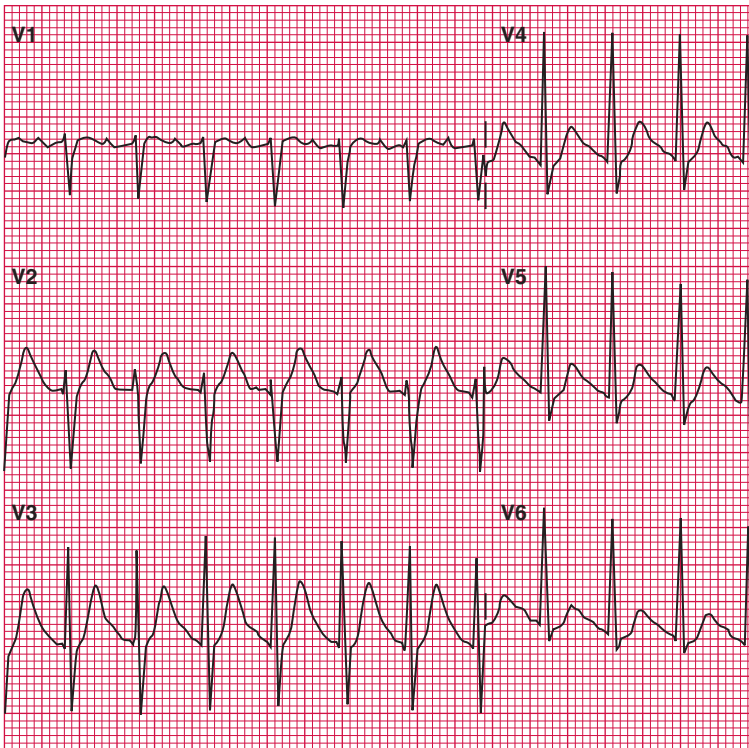


Fig. 11-19. Sinus tachycardia; rate, 165 bpm.

ventricles are activated from the anterograde path of the circuit, with activation of the atrium by the retrograde path (Fig. 11-20).

ECG DIAGNOSTIC POINTS

- A rapid, regular rhythm, usually 150 to 225 bpm, is present. A rate greater than 230 bpm should prompt the search for Wolff-Parkinson-White (WPW) syndrome.
- QRS is less than 0.12 second.
- In more than 50% of cases, P waves are hidden within the QRS complex and are not visible; the QRS complex is identical to that of a tracing during sinus rhythm (*see* Fig. 11-20).
- In approximately 45% of cases, P waves appear hidden, but on careful scrutiny they are visible at the end of the QRS in leads II, III, and aVF

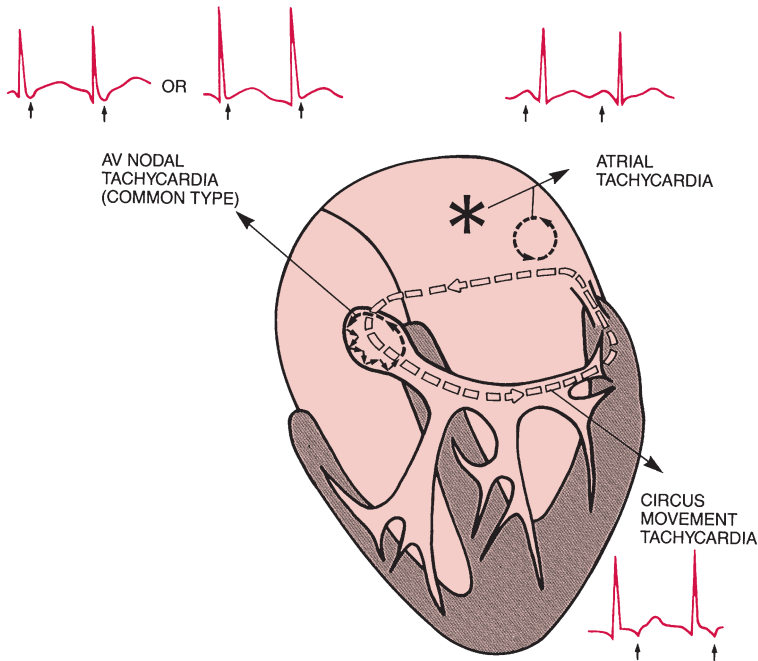


Fig. 11-20. A representation of the sites of origin and mechanism of paroxysmal supraventricular tachycardia as determined by the position and polarity of the P waves in relation to the QRS complexes. In atrial tachycardia, the P wave precedes the QRS; its polarity in lead III depends on its location. In AV nodal reentry tachycardia, the P wave is buried within the QRS or may distort the end of the QRS; that portion of the QRS is then negative in lead III. In circus movement tachycardia, the P wave follows the QRS. (From Wellens JJH, Conover MB: *The ECG in Emergency Decision Making*, Philadelphia, 1992, WB Saunders, Elsevier Science.)

as they distort the terminal forces of the QRS complex, resulting in pseudo-S waves in leads II, III, and aVF (see Figs. 11-20 and 11-21). The distortion causes a pseudo r' wave in lead V₁ that mimics RSr' or incomplete right bundle branch block (RBBB) (see Figs. 11-20, 11-21B, and 11-22).

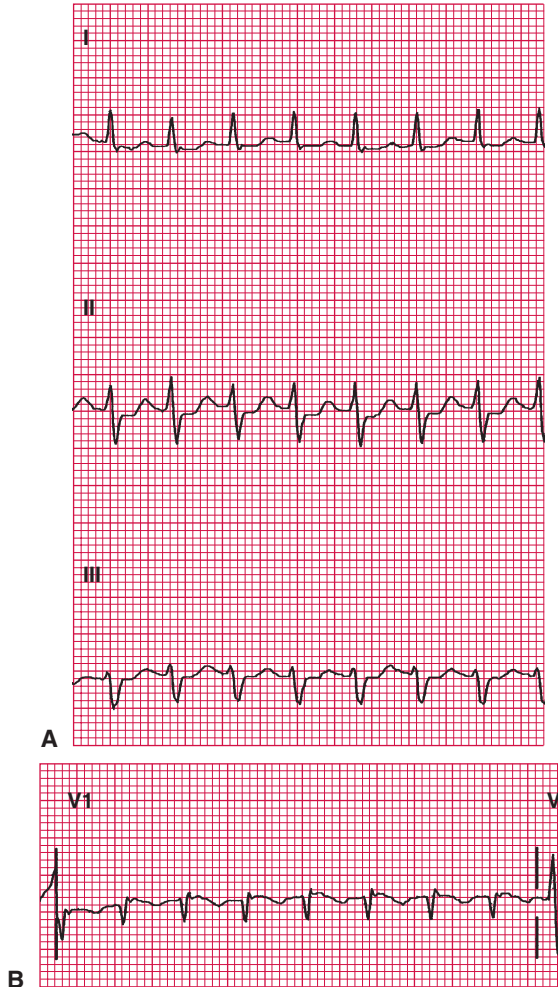


Fig. 11-21. **A**, The limb leads of a patient with supraventricular tachycardia: rate, 184 bpm. Note the distortion of the terminal QRS in lead III, a pseudo-S wave: typical features of the common form of atrioventricular nodal reentrant tachycardia (AVNRT). **B**, The V₁ lead in the same patient. Note the distortion of the terminal QRS resulting in a pseudo-r' wave: typical feature of the common form of AVNRT.

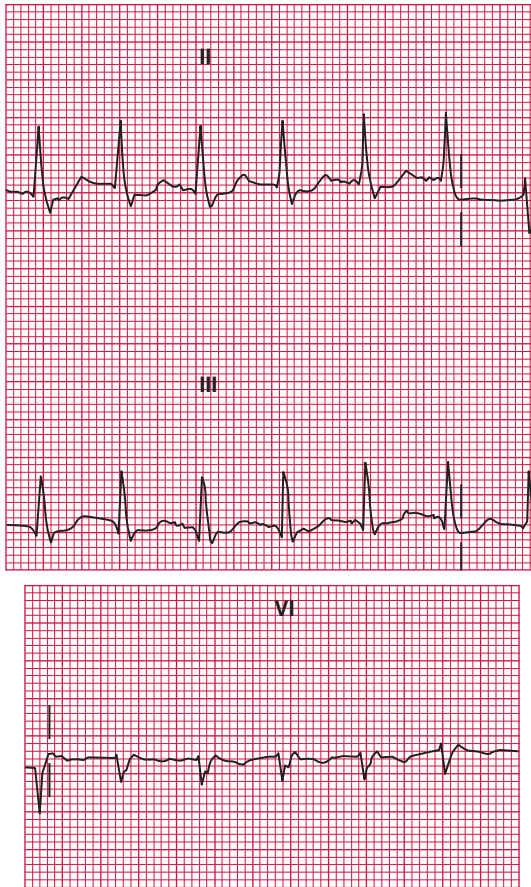


Fig. 11-22. Atrioventricular nodal reentrant tachycardia (AVNRT): rate, 140 bpm. Note pseudo-R' wave in V₁, typical of the common type of AVNRT.

- In fewer than 5% of cases, P waves are discernible at the beginning of the QRS and cause pseudo-Q waves in leads II, III, and aVF.
- In a rare form of AVNRT, P waves are negative in leads II, III, and aVF but follow the QRS after a prolonged duration such that the RP interval is greater than the PR interval. It is impossible to distinguish this rare form of AVNRT from the rare type of WPW circus movement tachycardia using the retrograde, slow accessory pathway to activate the atria (see subsequent section on Wolff-Parkinson-White syndrome).

Paroxysmal Atrial Tachycardia with or without Atrioventricular Block

ECG DIAGNOSTIC POINTS

- The P wave precedes the QRS, and its contour is different from that of the sinus P wave. P waves are often small, are not easily identified, and may be hidden in the T wave or QRS; the arrhythmia may be mistaken for sinus tachycardia or AV junctional tachycardia. The PR interval is normal or prolonged.
- The morphology of the P waves depends on the location of the ectopic atrial pacemaker (Fig. 11-23). The RR intervals are equal except for a warm-up period in the automatic type.

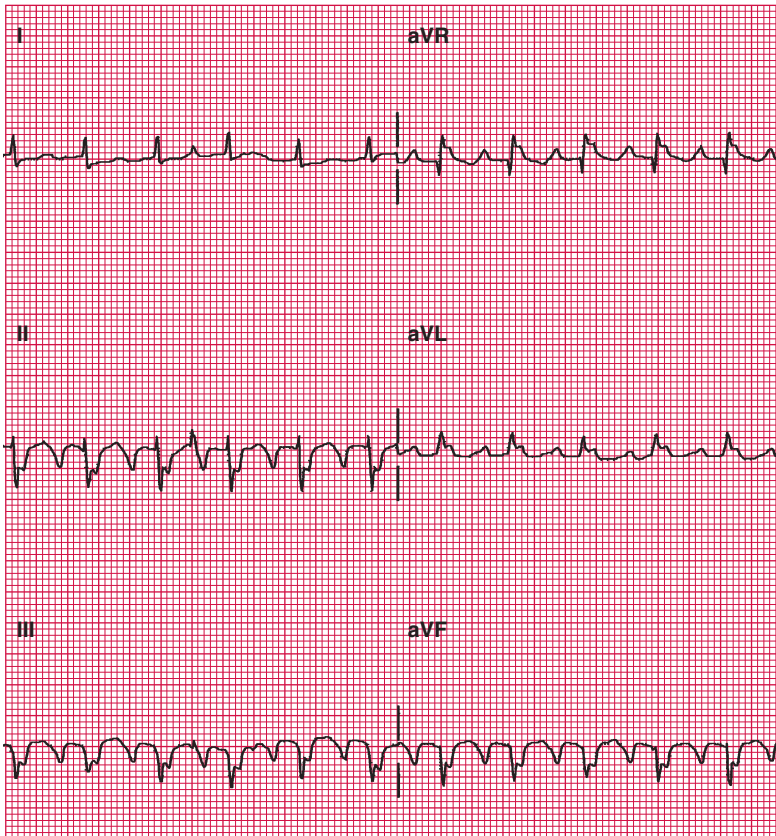


Fig. 11-23. Atrial tachycardia. The P waves are barely discernible in lead I and are inverted in II, III, and aVF. There is 2:1 atrioventricular block. The atrial rate is 264 bpm; ventricular rate is 132 bpm. Note the isoelectric baseline between the P wave and the QRS complex.

- The atrial rate may range from 110 to 260bpm. If the atrial rate is not rapid and AV conduction is not depressed, each P wave may conduct to the ventricle. With digitalis excess, AV conduction may be delayed, resulting in paroxysmal atrial tachycardia with block, but digitalis toxicity is not the only cause of this arrhythmia (Fig. 11-24).
- Variable AV conduction occurs: a 2:1 conduction is common; a 3:1 conduction or Wenckebach phenomenon may occur, causing an irregular rhythm (Fig. 11-25). At times, the varying AV block may result in an irregular ventricular rhythm that may be mistaken for atrial fibrillation.
- An isoelectric baseline exists between the P wave and the QRS complex (*see* Figs. 11-23 to 11-25).
- The differentiation of atrial tachycardia and atrial flutter may be difficult if the atrial rate is rapid; carotid sinus massage or adenosine brings out the flutter waves if atrial flutter is present.
- Atrial tachycardia persists despite the development of AV block, and this feature excludes WPW syndrome.

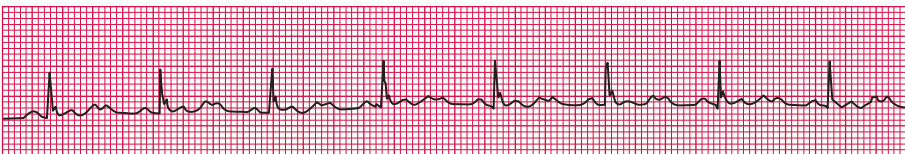
Persistent (Incessant) Atrial Tachycardia

The incessant nature of atrial tachycardia, a rare tachycardia, may cause dilated (congestive) cardiomyopathy.

ECG DIAGNOSTIC POINTS

- The rhythm is regular.
- The P wave precedes the QRS complex. The P wave polarity depends on the site of origin in the atrium.

Lead II



Continuous

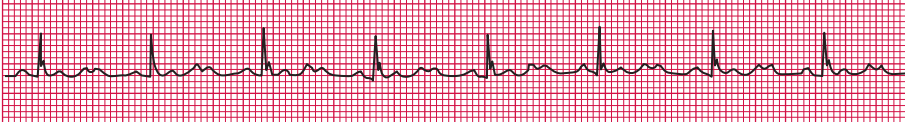

Fig. 11-24. Paroxysmal atrial tachycardia with block. There is 3:1 atrioventricular conduction. The patient was not receiving digitalis. (From Chou TC: *Electrocardiography in Clinical Practice*, 4th ed., Philadelphia, 1996, WB Saunders, Elsevier Science.)

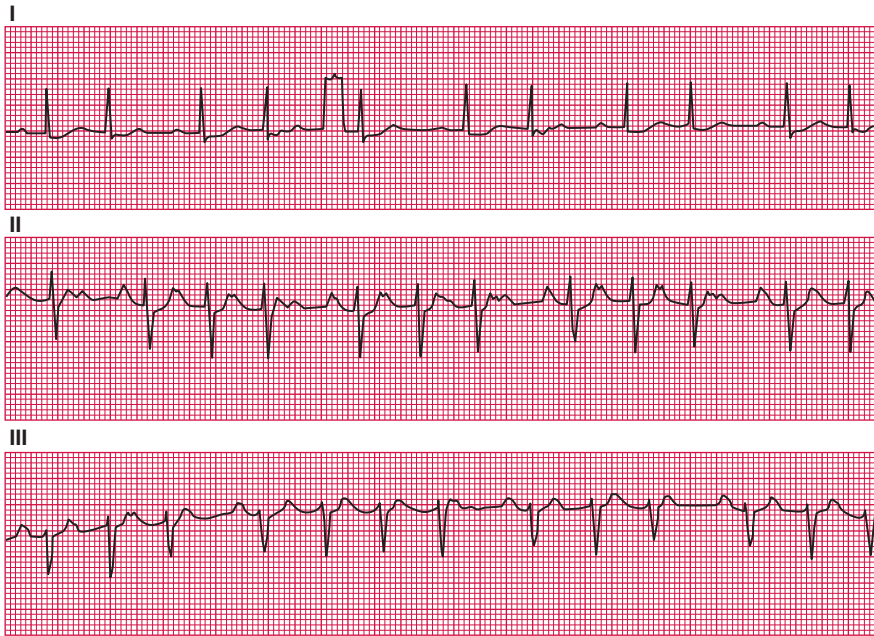


Fig. 11-25. Paroxysmal atrial tachycardia with block. A Wenckebach phenomenon is present. There is a gradual lengthening of the PR interval and shortening of the RR interval before the block occurs; therefore the rhythm is irregular. (From Chou TC: *Electrocardiography in Clinical Practice*, 4th ed., Philadelphia, 1996, WB Saunders, Elsevier Science.)

- There is variable AV conduction of 1 : 1 and 2 : 1, including Wenckebach phenomenon.
- Carotid sinus massage or adenosine increases AV block and facilitates the diagnosis.

Multifocal Atrial Tachycardia (Chaotic Atrial Tachycardia)

ECG DIAGNOSTIC POINTS

- Atrial rate is 100 to 140 bpm.
- There are frequent multifocal premature beats, at least three different P wave morphologies with changing PR intervals in one lead (Fig. 11-26), and isoelectric baseline between P waves.
- The rhythm is completely irregular; PR, RR, and RP intervals are variable.
- One dominant atrial pacemaker, such as sinus rhythm, is absent, and multifocal APBs are present.

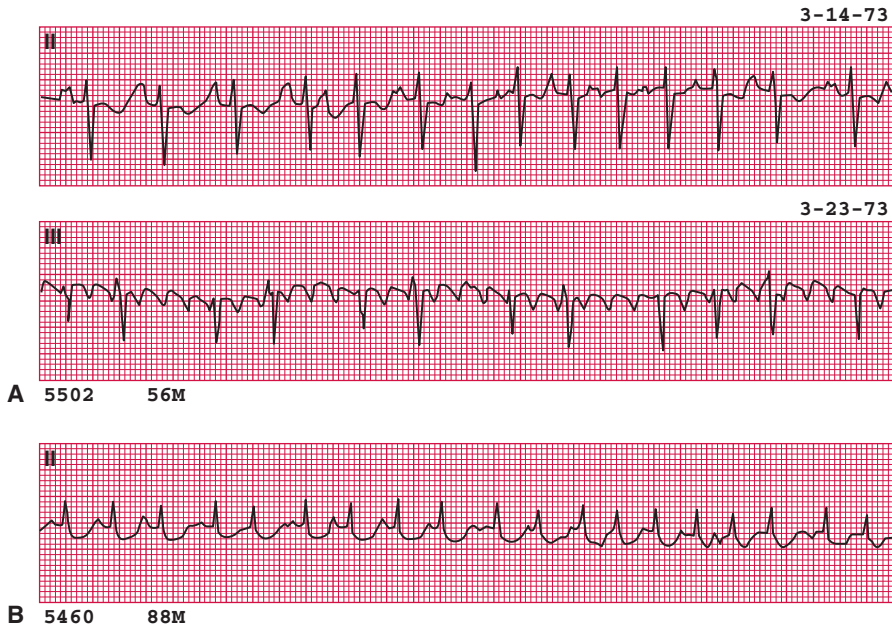


Fig. 11-26. Multifocal atrial tachycardia. **A**, The patient has chronic obstructive pulmonary disease. The tracing on 3-14-73 shows multifocal atrial tachycardia. The rhythm changes to atrial flutter with varying atrioventricular conduction on 3-23-73. **B**, Tracing obtained from an 88-year-old man with mitral insufficiency. The multifocal atrial tachycardia closely resembles atrial fibrillation with rapid ventricular response. (From Chou TC: *Electrocardiography in Clinical Practice*, 4th ed., Philadelphia, 1996, WB Saunders, Elsevier Science.)

- Causes of multifocal atrial tachycardia include chronic obstructive pulmonary disease, theophylline, and digitalis (rarely).

Wolff-Parkinson-White Syndrome

ECG DIAGNOSTIC CRITERIA

- The QRS complex duration is ≥ 0.11 second; in approximately 20% of individuals, the QRS complex may not be >0.1 second. PR is <0.12 second.
- A delta wave is prominent, often in V_3 through V_6 , and is a subtle finding in some leads (Fig. 11-27).
- In type A WPW syndrome, a tall R wave present in V_1 and V_2 can mimic right ventricular hypertrophy, RBBB, or posterior infarction (see Fig. 11-27 and Table 2-3).

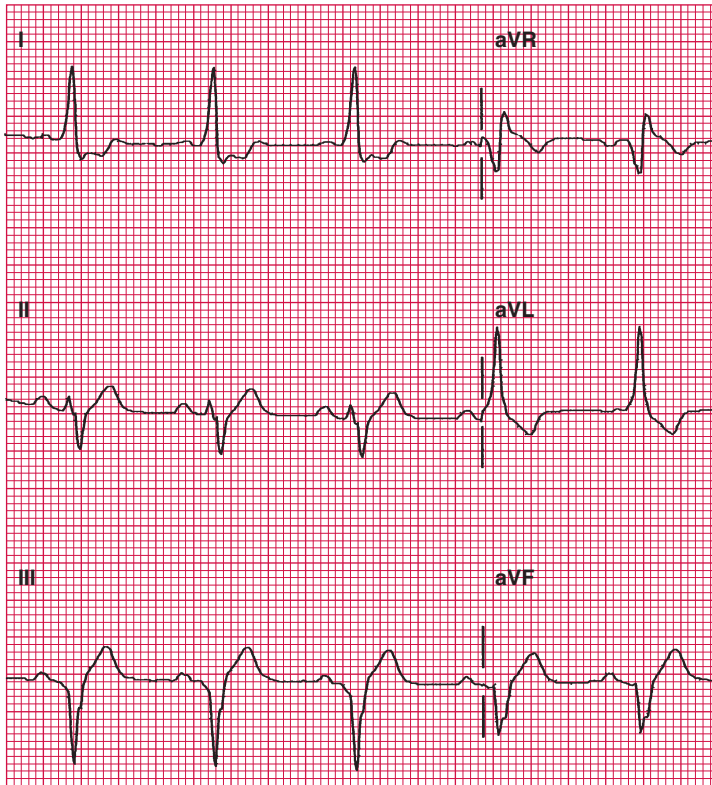


Fig. 11-27. Features of Wolff-Parkinson-White syndrome. Prominent delta waves in V_2 through V_5 and very short PR interval. Note how this mimics inferior infarction.

- In type B WPW pattern, the QRS complex is predominately negative in V_1 through V_3 and upright in V_5 and V_6 . The pattern may resemble left bundle branch block (Fig. 11-28).
- Pseudo-Q waves in inferior leads may mimic inferior myocardial infarction (see Figs. 11-27 and 11-29).

CLUES DURING TACHYCARDIA

- There is narrow QRS complex tachycardia, with regular rhythm.
- P waves follow the QRS at a distance; shape depends on the location of the accessory pathway. With a left lateral accessory pathway, the P wave is negative in lead I. If the location is posteroseptal, P waves are negative in leads II, III, and aVF and positive in aVR and aVL.
- In the common orthodromic circus movement tachycardia, the RP interval is shorter than the PR interval because of retrograde use of the

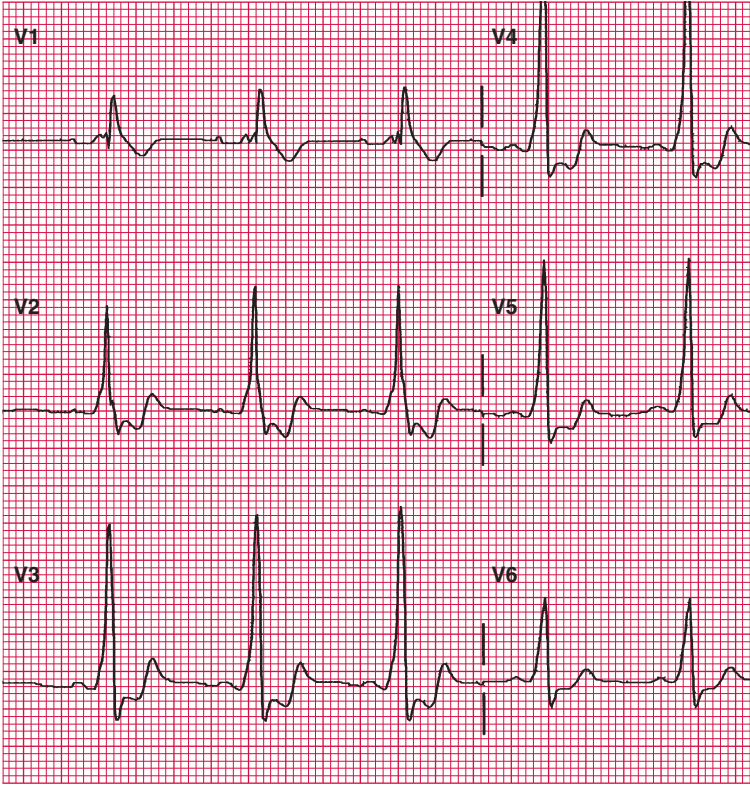


Fig. 11-27. Continued

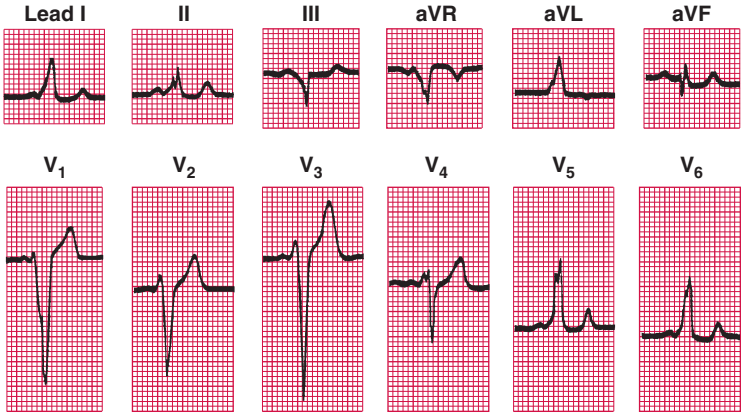


Fig. 11-28. Type B Wolff-Parkinson-White pattern in a healthy 35-year-old man. The tracing resembles closely that of complete left bundle branch block. (From Chou TC: *Electrocardiography in Clinical Practice*, 4th ed., Philadelphia, 1996, WB Saunders, Elsevier Science.)

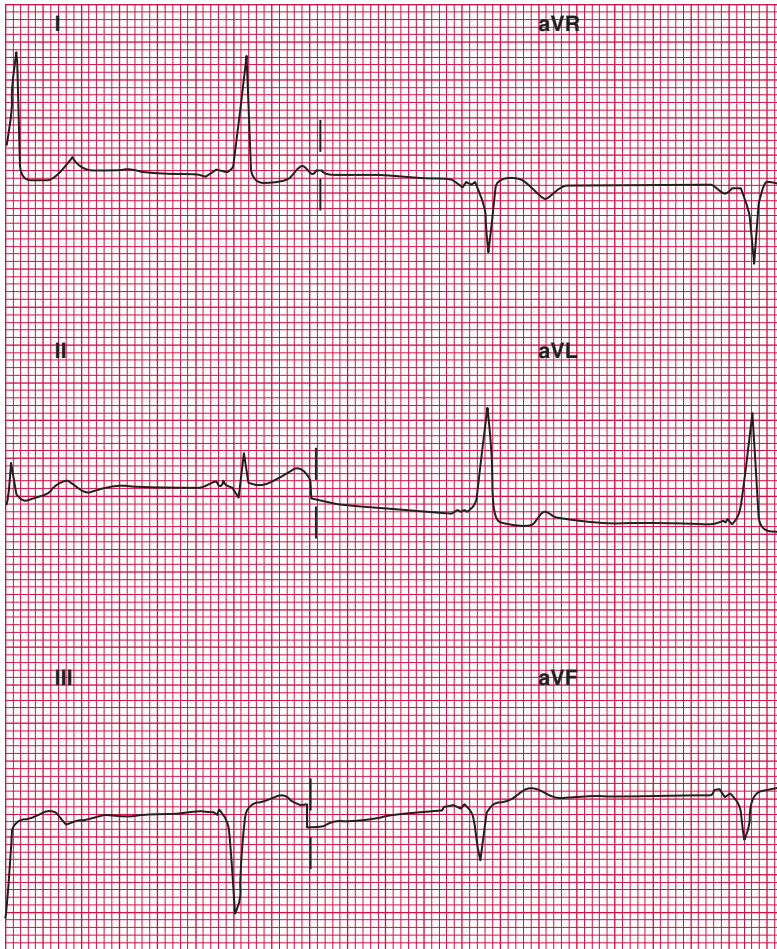


Fig. 11-29. Limb leads in patient with Wolff-Parkinson-White syndrome mimic inferior infarction.

fast accessory pathway to activate the atria (*see* Figs. 11-20 and 11-30).

- In a rare form of orthodromic circus movement tachycardia with retrograde activation of the atria through a slowly conducting accessory pathway, the P wave occurs late retrogradely. Thus, the RP interval is longer than or equal to the PR interval and the P wave is negative in leads II, III, aVF, and V₄ through V₆. This arrhythmia pattern is similar to the rare form of AVNRT described previously. This rare type of WPW syndrome may manifest as a persistent (incessant) orthodromic circus movement tachycardia and cause a dilated cardiomyopathy with congestive heart failure (Fig. 11-31).

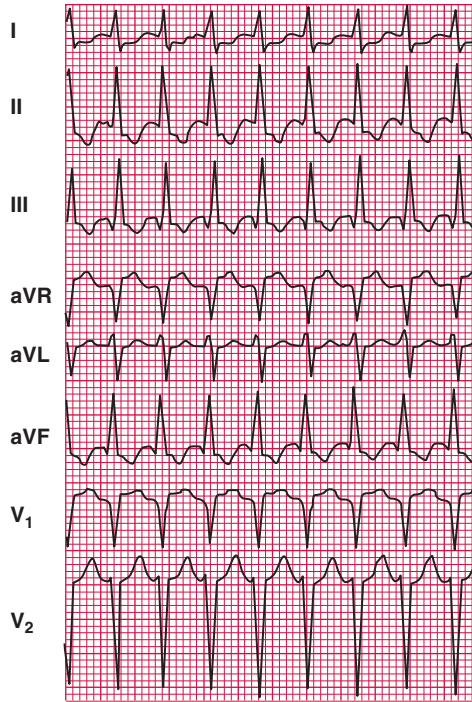


Fig. 11-30. An example of a circus movement tachycardia using a concealed accessory pathway. The diagnosis is based on the position of the P wave during the tachycardia. Negative P waves are clearly visible in leads II, III, and aVF following the QRS complex. The P waves during the tachycardia are positive in leads aVR and aVL, indicating a posteroseptal atrial insertion of the accessory pathway. (From Wellens JJH, Conover MB: *The ECG in Emergency Decision Making*, Philadelphia, 1992, WB Saunders, Elsevier Science.)

- Electrical alternans sometimes occurs during orthodromic circus movement tachycardia but rarely occurs with other narrow QRS tachycardias (see Fig. 10-13).

Summary Differential Diagnosis of Narrow QRS Regular Tachycardia

- If AV block is present or can be produced by carotid sinus massage or adenosine, WPW syndrome can be ruled out; atrial flutter and atrial tachycardia persist despite AV block.
- If the P wave is hidden within the QRS or is distorting the terminal QRS, causing a pseudo-S in leads II, III, and aVF or a pseudo r' in V₁, the diagnosis is the common form of AVNRT (see Figs. 11-20 to 11-22).

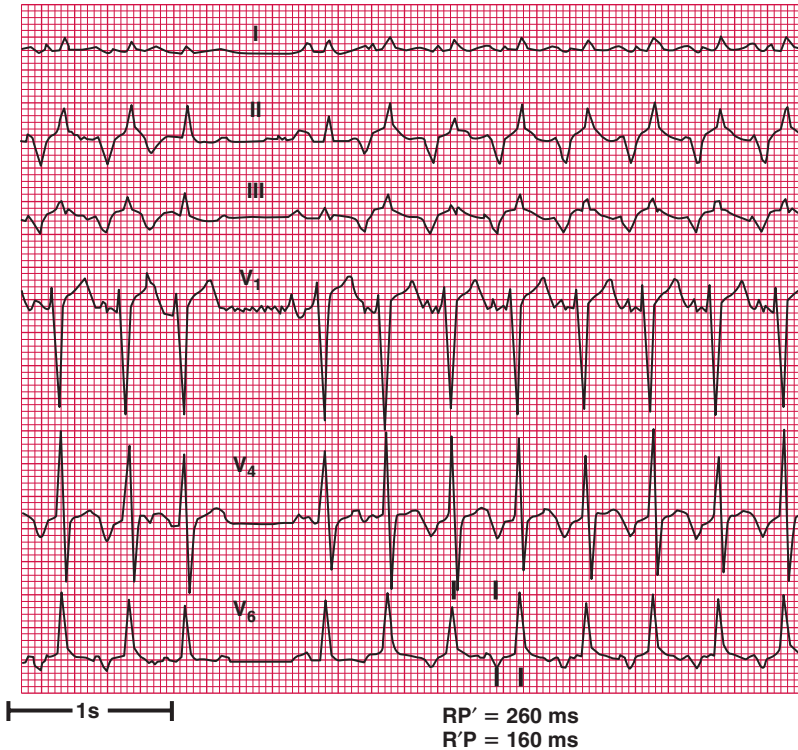


Fig. 11-31. Incessant circus movement tachycardia using a slowly conducting concealed accessory pathway for retrograde conduction. The diagnosis is made because the patient is in tachycardia most of the time with an RP interval greater than the PR interval. The tachycardia is temporarily terminated by an atrial premature beat, which is conducted to the ventricle. There is a pause resulting from retrograde block in the accessory pathway, then the sinus node escapes for one beat and the circus movement tachycardia begins again. (From Wellens JJH, Conover MB: *The ECG in Emergency Decision Making*, Philadelphia, 1992, WB Saunders, Elsevier Science.)

- A negative P wave in lead I suggests WPW syndrome or left atrial tachycardia.
- A P wave following the QRS complex distinctly with an RP interval shorter than the PR interval is diagnostic of the most common type of WPW syndrome, orthodromic circus movement tachycardia (see Fig. 11-30).
- An RP interval that is greater than the PR interval indicates the rare WPW orthodromic type, the rare type of AVNRT, or atrial tachycardia (see Fig. 11-31).

- Positive P waves in leads II, III, and aVF with atrial tachycardia rule out AVNRT or WPW syndrome tachycardia.
- P waves negative in leads II, III, and aVF suggest AVNRT or WPW syndrome.
- A ventricular rate greater than 220bpm with QRS alternans usually indicates WPW syndrome (*see* Fig. 10-13).
- A ventricular rate greater than 250bpm with RR intervals less than 240 milliseconds (six small squares) suggests WPW syndrome.

FOUR TYPES OF WOLFF-PARKINSON-WHITE SYNDROME TACHYCARDIA

1. Orthodromic circus movement tachycardia: This is the most common tachycardia. The ventricles are activated via the AV node and bundle of His, and the impulse retrogradely uses the fast accessory tract to activate the atria; thus the P wave is close to the preceding QRS complex, and the RP interval is shorter than the PR interval.
2. Rare orthodromic tachycardia: The activation of the ventricles via the AV node and His bundle is similar to that in circus movement tachycardia, but the impulse returns to the atria via the slow accessory tract. Therefore, the P wave follows the QRS at a distance, making the RP interval greater than the PR interval. This arrhythmia mimics the rare form of AVNRT.
3. Rare antidromic tachycardia: The ventricle is activated by anterograde (preexcited tachycardia) use of the bypass tract, causing tachycardia similar to VT, atrial flutter, or atrial fibrillation with a wide QRS complex (*see* discussion of wide QRS tachycardia).
4. Rare antidromic anterograde conduction: The ventricle is activated by two or more accessory pathways, resulting in wide QRS tachycardia.

DIAGNOSIS BASED ON CAROTID SINUS MASSAGE OR INTRAVENOUS ADENOSINE

- AVNRT converts to sinus rhythm or no effect.
- Circus movement tachycardia reverts to sinus rhythm or no effect.
- Persistent atrial tachycardia: Increased AV block facilitates recognition of the atrial origin, temporary slowing of heart rate with AV block, or no effect.
- Atrial flutter: Temporary slowing of the ventricular rate reveals flutter waves if not previously visible, or no effect.

Atrial Flutter

- A sawtooth pattern is seen in leads II, III, and aVF (Figs. 11-32 and 11-33). The downward deflection of the F waves has a gradual slope

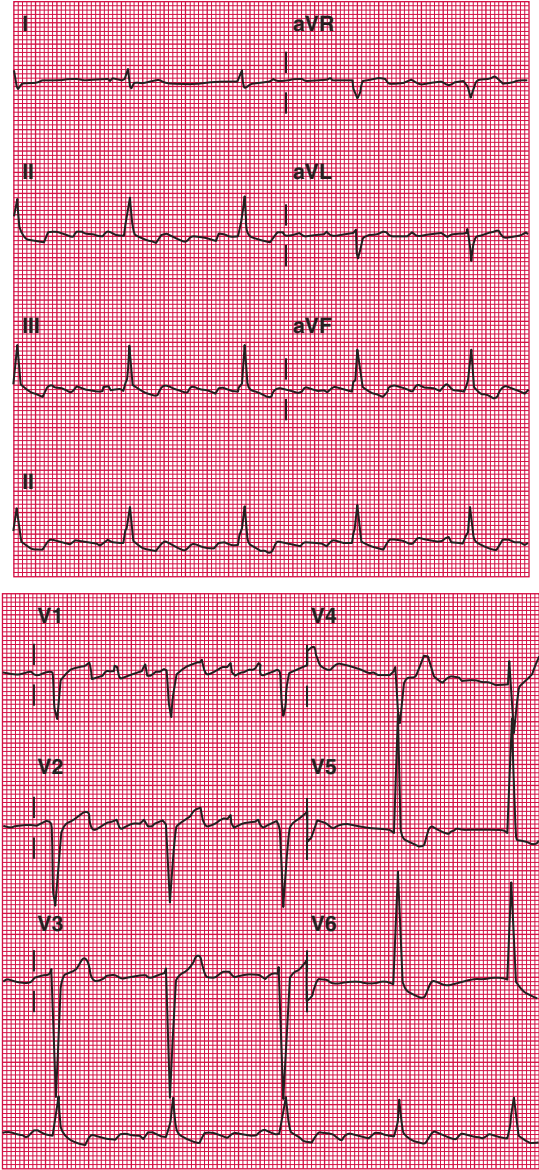


Fig. 11-32. Atrial flutter. (From Khan, M. Gabriel: *On Call Cardiology*, 3rd ed., Philadelphia, 2006, WB Saunders, Elsevier Science.)

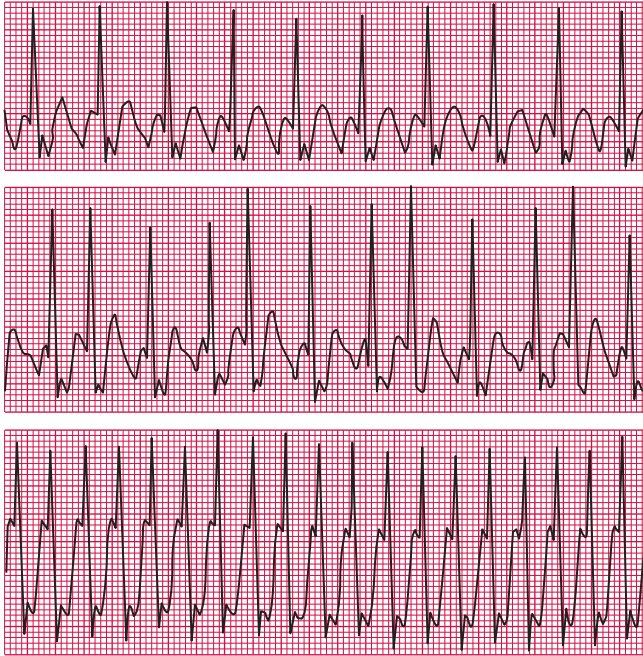


Fig. 11-33. Atrial flutter with 1:1 conduction caused by flecainide. **Top**, Atrial flutter occurs with 2:1 conduction. **Middle**, 2:1 conduction alternates with 3:2 conduction. **Bottom**, Flecainide administration has been started, and the atrial flutter rate slows, with subsequent 1:1 conduction. (From Braunwald E: *Heart Disease: A Textbook of Cardiovascular Medicine*, 6th ed., Philadelphia, 2001, WB Saunders, Elsevier Science.)

followed by an abrupt upward deflection. This results in the typical sharp spikes of the sawtooth pattern: There are positive, “spiky” P-like waves in lead V_1 and negative P-like waves in leads V_5 and V_6 . There is almost no atrial activity in lead I, and leads V_5 and V_6 often show negligible atrial activity (see Fig. 11-32).

- A ventricular response of 150 bpm is typical of atrial flutter. The atrial rate is often 300 bpm. With 2:1 AV conduction, the ventricular response is 150 bpm. This 2:1 ratio may not be apparent because an F wave may be partially obscured by the QRS complex and the second F wave is hidden in the T wave (Fig. 11-34). This pattern mimics sinus tachycardia or reentrant junctional tachycardia. Carotid sinus massage should reveal sinus P waves or F waves. Conduction ratios of 2:1 and 4:1 may occur. The ventricular rate may vary from 100 to 230 bpm. A ventricular response of greater than 250 bpm suggests WPW syndrome.

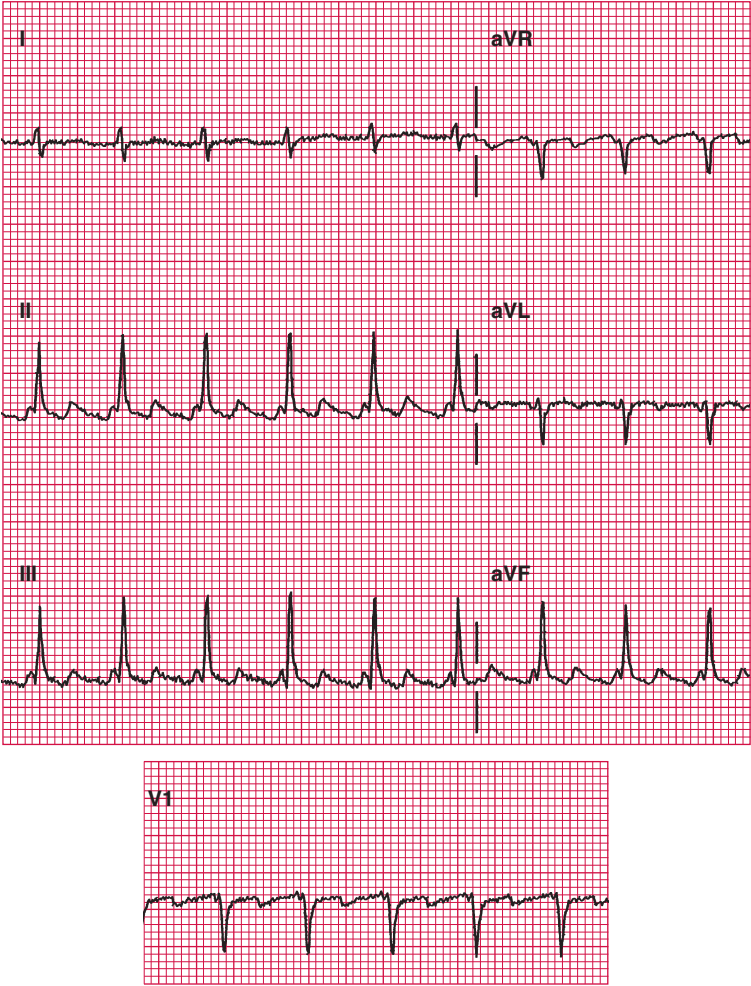


Fig. 11-34. Atrial flutter: atrial rate, 270bpm; ventricular rate, 135bpm. Note the downward deflection of F waves in leads II, III, and aVF has a gradual slope followed by an abrupt upward deflection. This causes the sawtooth pattern. Alternate F waves coincide with the QRS complex, and the diagnosis may be missed.

- The rhythm is regular but becomes irregular when there is variable AV conduction.
- The atrial rate varies from 250 to 400 bpm but can be less than 200 bpm in patients taking quinidine.

Atrial Fibrillation

ECG DIAGNOSTIC POINTS

- RR intervals are completely irregular (irregularly irregular) (Figs. 11-35 and 11-36).
- Irregular undulations of the baseline are usually most prominent in V₁; these may be gross (Fig. 11-37) or barely perceptible, described as coarse and fine fibrillation, respectively. Occasionally, there may be no recognizable undulations of the baseline, and careful measurement of the RR interval is necessary to detect slight irregularities.
- The atrial rate ranges from 400 to 700 bpm; there is variable AV conduction, resulting in a chaotic ventricular response.
- QRS complexes often vary in amplitude.

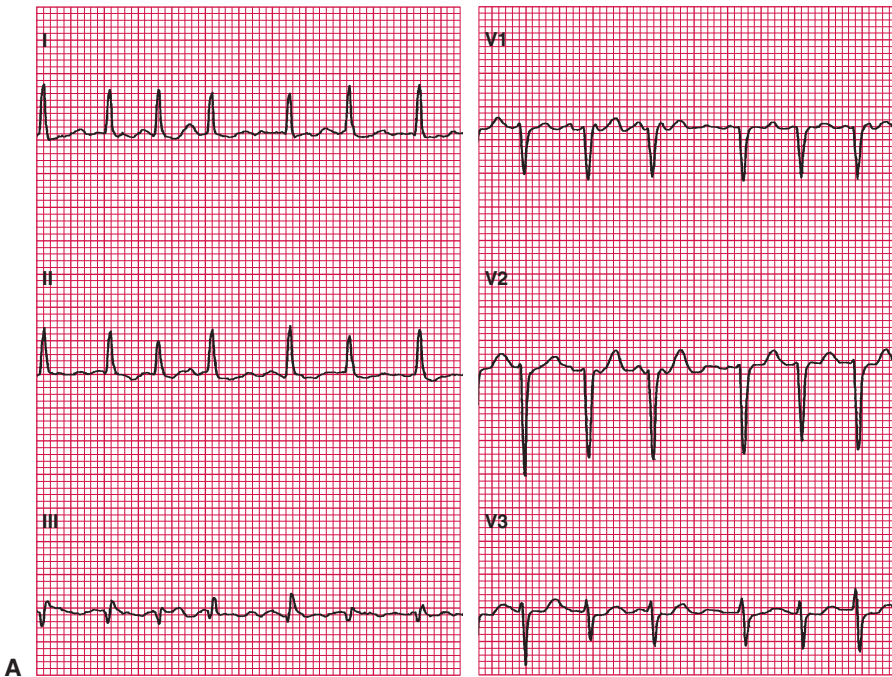


Fig. 11-35. **A**, Atrial fibrillation with a ventricular response of 156 bpm. **B**, [See legend on opposite page]. **B**, Atrial fibrillation with a rapid ventricular rate of 175 bpm. **C**, Atrial fibrillation, same patient as in (**B**); controlled ventricular rate of 108 bpm.

(continued)

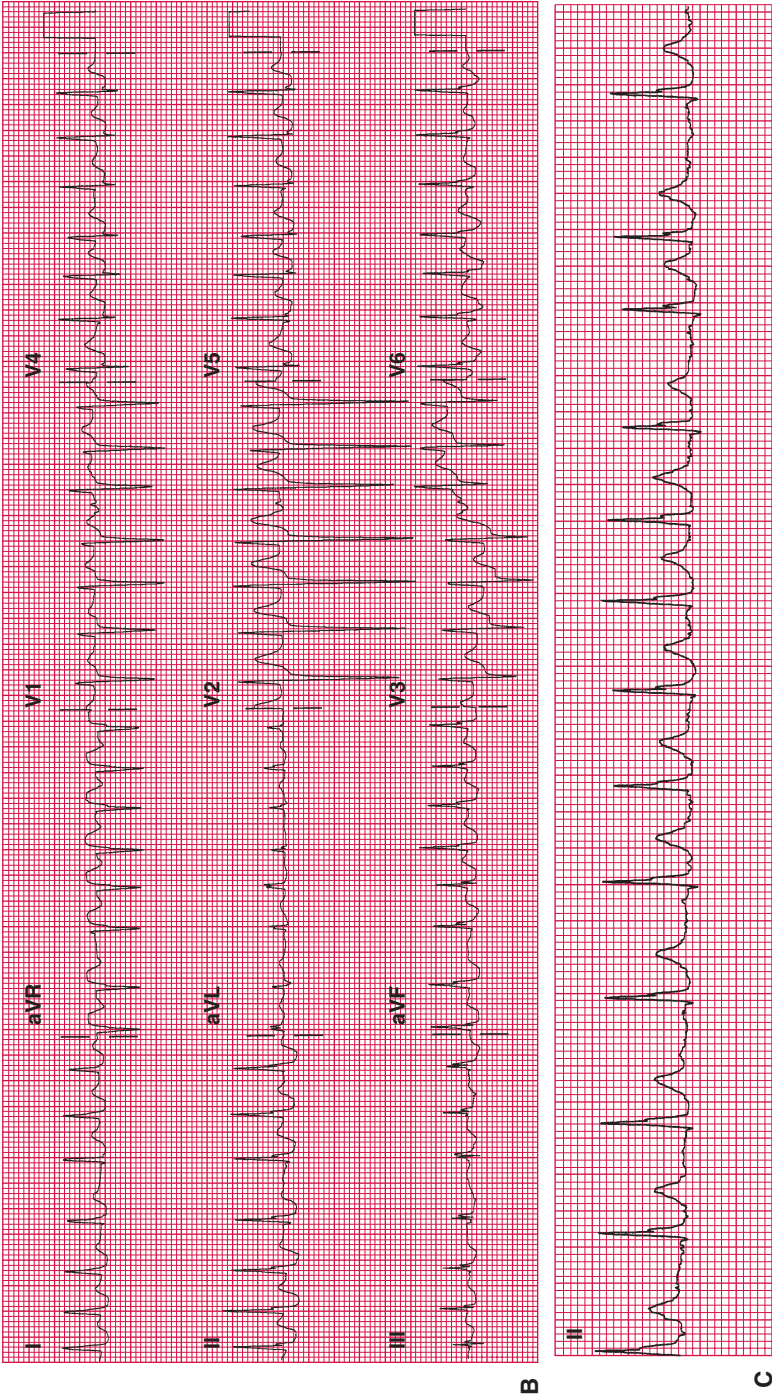


Fig. 11-35. *Continued*

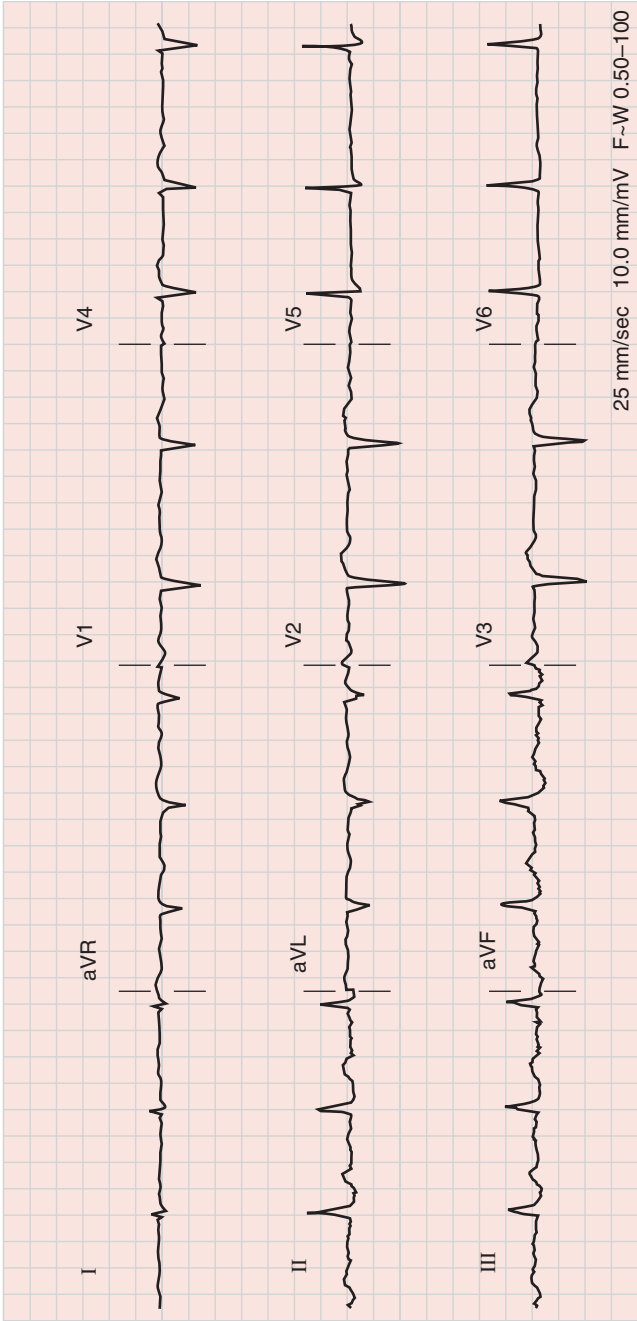


Fig. 11-36. Atrial fibrillation with slow ventricular response; rate, 70bpm. Patient is 80 years old and is not taking digoxin or a β -blocker. Rates <70bpm commonly seen in older adults who are not taking cardiac medications should raise suspicion of sick sinus syndrome.

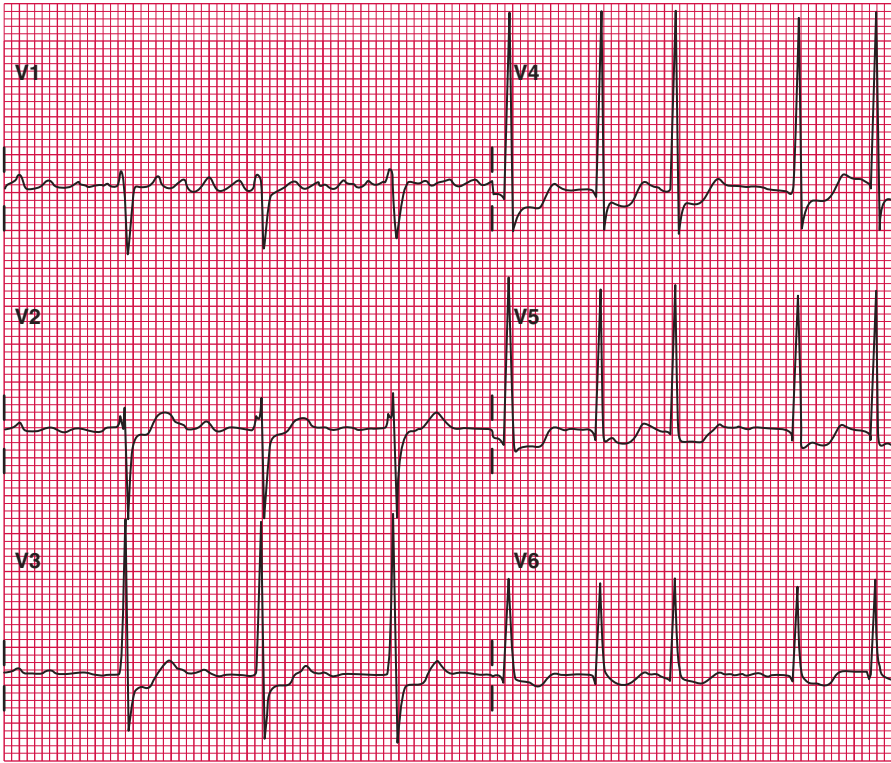


Fig. 11-37. Atrial fibrillation with a ventricular response rate of 104bpm. Note the coarse atrial fibrillation in V_1 .

- The heart rate is commonly 100 to 180bpm but can accelerate to more than 200bpm. Rates of >240 bpm with the QRS complex ≥ 0.10 second should suggest WPW syndrome. With WPW antidromic tachycardia, wide QRS tachycardia with rates of 250 to 320bpm may occur.

Figure 11-38 gives clues that assist with the diagnosis of supraventricular arrhythmias.

WIDE QRS TACHYCARDIA

ECG Diagnostic Steps

- Define the QRS duration as ≥ 0.12 second.
- Define the tachycardia as regular or irregular (see Fig. 11-18B).

REGULAR WIDE QRS TACHYCARDIA

Regular wide QRS tachycardia includes the following:

- Ventricular tachycardia: Consider all wide QRS regular tachycardias as VT until proven otherwise.
- SVT with preexisting or functional bundle branch block: These tachycardias include AVNRT, orthodromic circus movement tachycardia (WPW), atrial tachycardia, and atrial flutter with fixed AV conduction.
- Antidromic circus movement tachycardia or preexcited tachycardia (WPW) is usually exhibited by a very rapid rate >250 beats/min and may be irregular due to atrial fibrillation.

Ventricular Tachycardia

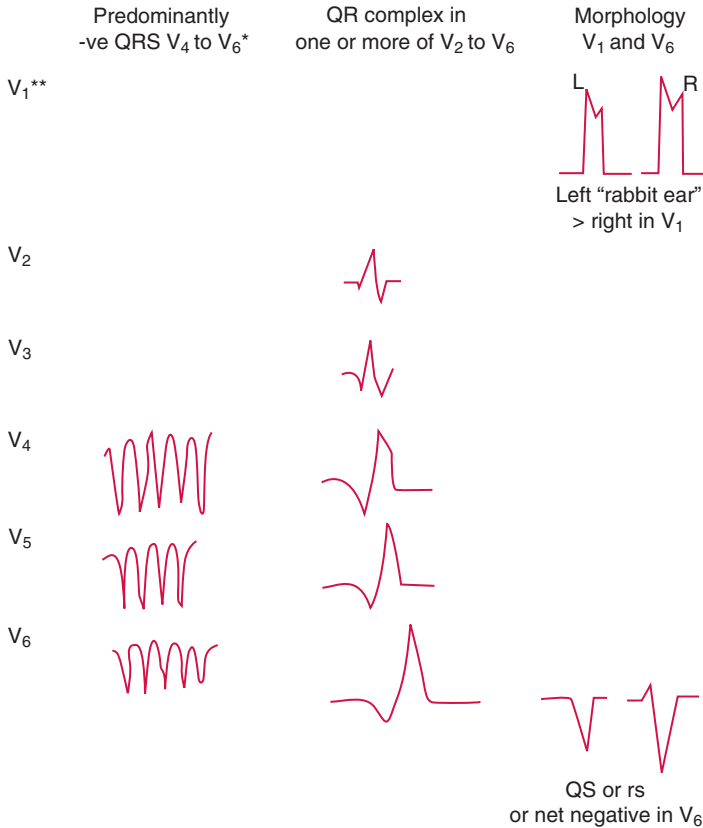
The ECG diagnosis of VT requires the assessment of all 12 ECG leads. The precordial leads are more diagnostic than lead II or other limb leads.

The diagnosis of VT can be confidently made by careful scrutiny of the morphologic pattern of the QRS complexes in V_1 through V_6 .

- If the QRS complexes are all negative in V_1 through V_6 (i.e., negative precordial concordance), the diagnosis of VT is certain (see Figs. 11-39, 11-40, and 11-41). Negative precordial concordance excludes WPW regular wide complex tachycardia during anterograde conduction over an accessory pathway.
- Finding of predominately negative QRS complexes in V_4 through V_6 is diagnostic of VT (see Fig. 11-39).
- The presence of a QR complex in one or more of precordial leads V_2 through V_6 is diagnostic of VT (Figs. 11-39 and 11-40).
- Note that negative precordial concordance is diagnostic of VT but that positive concordance (all complexes positive in V_1 through V_6) can result from VT or circus movement antidromic tachycardia WPW syndrome.

Findings in V_6 are most useful clues:

- A QS or rS in V_6 (net negative complex) (see Figs. 11-39 and 11-40).



* = or concordant negativity in leads V₁ through V₄. Positive concordance in leads V₁ through V₆ can be caused by VT or Wolff-Parkinson-White anti-dromic (preexcited) tachycardia.

** = it is necessary to study the entire 12-lead tracing with particular emphasis on leads V₁ through V₆; lead II may be useful for assessment of P waves and AV dissociation.

Fig. 11-40. Electrocardiographic hallmarks of ventricular tachycardia (VT). (From Khan, M. Gabriel: *On Call Cardiology*, 3rd ed., Philadelphia, 2006, WB Saunders, Elsevier Science.)

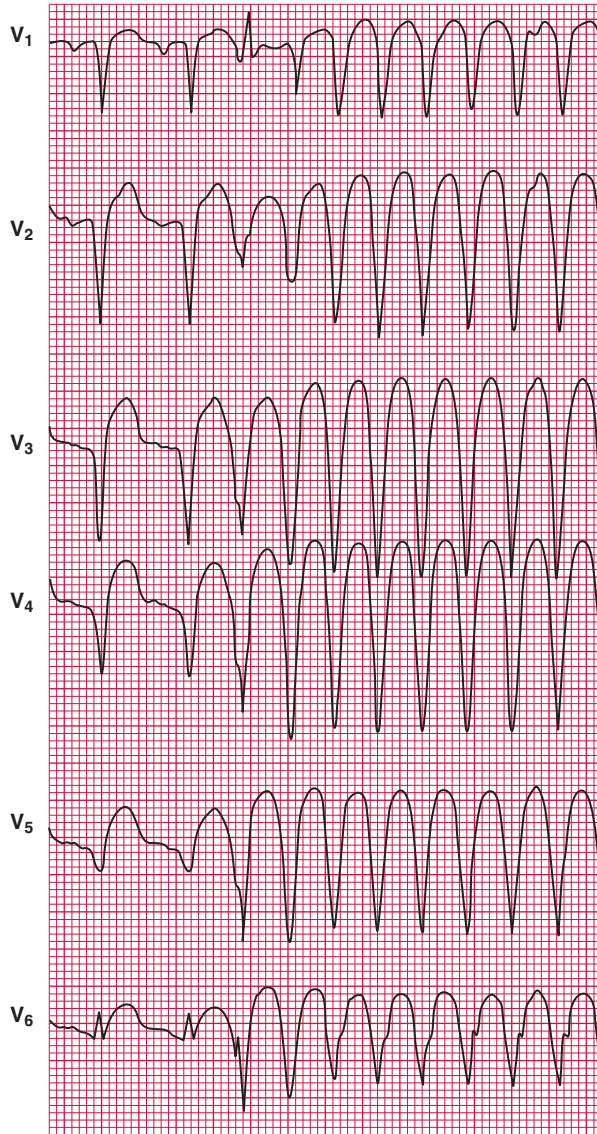


Fig. 11-41. Onset of a tachycardia with negative precordial concordance. Negative precordial concordance indicates ventricular tachycardia, because such a pattern does not occur during anterograde conduction over an accessory pathway. (From Wellens JJH, Conover MB: *The ECG in Emergency Decision Making*, Philadelphia, 1992, WB Saunders, Elsevier Science.)

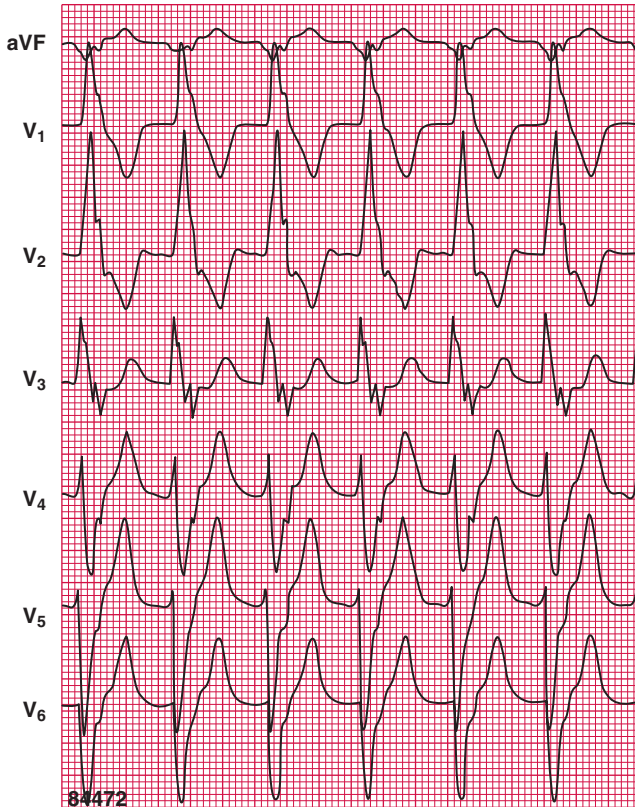


Fig. 11-42. Ventricular tachycardia. Note the steep monophasic R wave in lead V_1 (left “rabbit ear”) and the deep S in lead V_6 , signs of ventricular tachycardia. The northwest axis is also a helpful clue. (From Wellens JJH, Conover MB: *The ECG in Emergency Decision Making*, Philadelphia, 1992, WB Saunders, Elsevier Science.)

Findings in V_1 are useful clues:

- A wide small r wave >0.03 second (see Fig. 11-39).
- An RS interval longer than 0.1 second, measured from the R wave to the nadir of the S wave in any precordial lead.
- A steeper R wave upstroke than downstroke in V_1 (taller left “rabbit ear”). The morphology in V_1 may be helpful: If the left “rabbit ear” is taller than the right in lead V_1 , VT is the most likely diagnosis (Figs. 11-39 and 11-42). Note that the rabbit ear may be subtle. Figure 11-42 shows other characteristic features in V_1 , V_2 and V_6 .

Other helpful features include:

- AV dissociation: The presence of more QRS complexes than P waves supports the diagnosis of VT, but P wave identification may be difficult.

The terminal portion of the T wave or initial parts of the QRS may resemble P waves, leading to an incorrect diagnosis of SVT. In addition, in some cases of VT, 1:1 ventricular/atrial conduction may be observed because retrograde impulse conduction to the atria from the ventricular focus often occurs. AV dissociation is not a reliable diagnostic point and is observed in <45% of VTs.

- With VT, the axis is commonly -90 degrees to ± 180 degrees. However, the axis may be normal in patients with idiopathic VT and other varieties of VT.
- Positive concordance: A positive QRS complex in V_1 through V_6 is suggestive of VT, but this pattern can be seen with WPW syndrome (Fig. 11-43). Negative precordial concordance is diagnostic of VT because

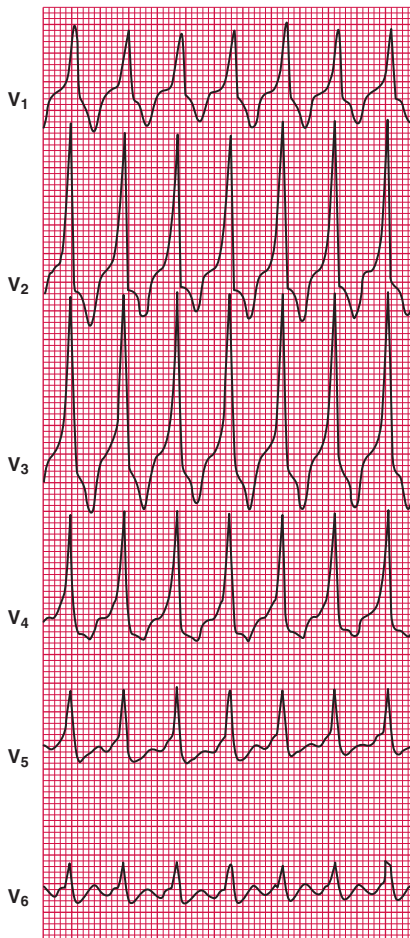


Fig. 11-43. Broad QRS tachycardia with positive precordial concordance. The mechanism is atrial flutter with 2:1 conduction over a left-sided accessory pathway. (From Wellens JJH, Conover MB: *The ECG in Emergency Decision Making*, Philadelphia, 1992, WB Saunders, Elsevier Science.)

this pattern does not occur during antidromic circus movement tachycardia (WPW syndrome) in which conduction is anterograde over the bypass tract.

IRREGULAR WIDE QRS TACHYCARDIA

Irregular wide QRS tachycardias include the following:

- Torsades de pointes.
- Atrial fibrillation with bundle branch block or with the antidromic variety of WPW, anterograde conduction over the bypass tract (Fig. 11-44).
- Atrial flutter with varying AV conduction and bundle branch block or atrial flutter and varying AV conduction in the WPW syndrome with anterograde conduction (antidromic) over the bypass tract (Fig. 11-45).

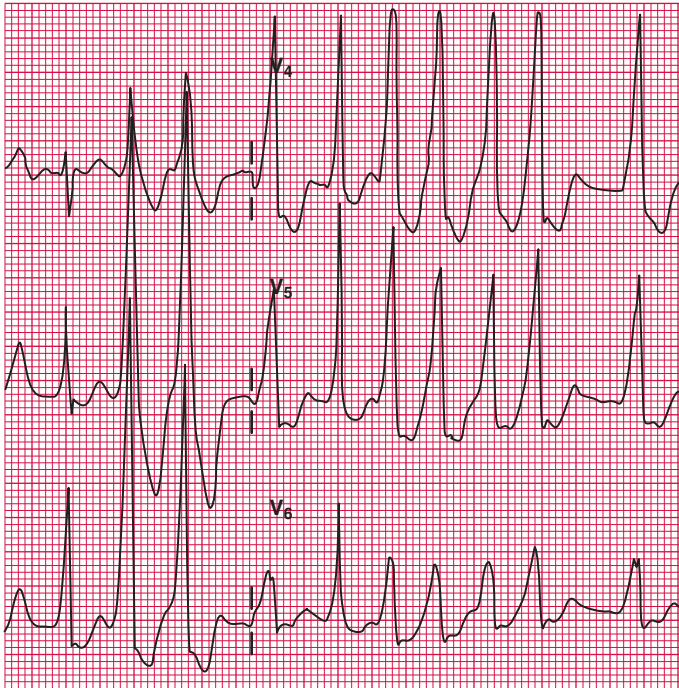


Fig. 11-44. Atrial fibrillation with wide QRS tachycardia in a patient with Wolff-Parkinson-White syndrome: antidromic tachycardia.

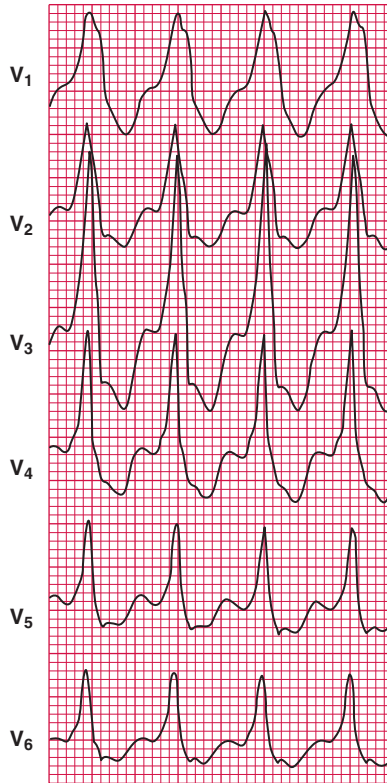

Fig. 11-45. A 12-lead ECG from a patient with antidromic circus movement tachycardia. (From Wellens JJH, Conover MB: *The ECG in Emergency Decision Making*, Philadelphia, 1992, WB Saunders, Elsevier Science.)

Torsades de Pointes

- Torsades is a polymorphic VT that usually occurs in the presence of a prolonged QT interval.
- The RR interval is irregular; the QRS complexes show a typical twisting of the points.
- The amplitudes of the complexes vary and appear alternately above and below the baseline (Fig. 11-46).
- The ventricular rate varies from 200 to 300 bpm, but can reach 400 bpm, and is usually not sustained (lasting 30 seconds to 1 minute).
- Longer episodes degenerate into ventricular fibrillation.
- Drugs and conditions that may precipitate torsades include the following:

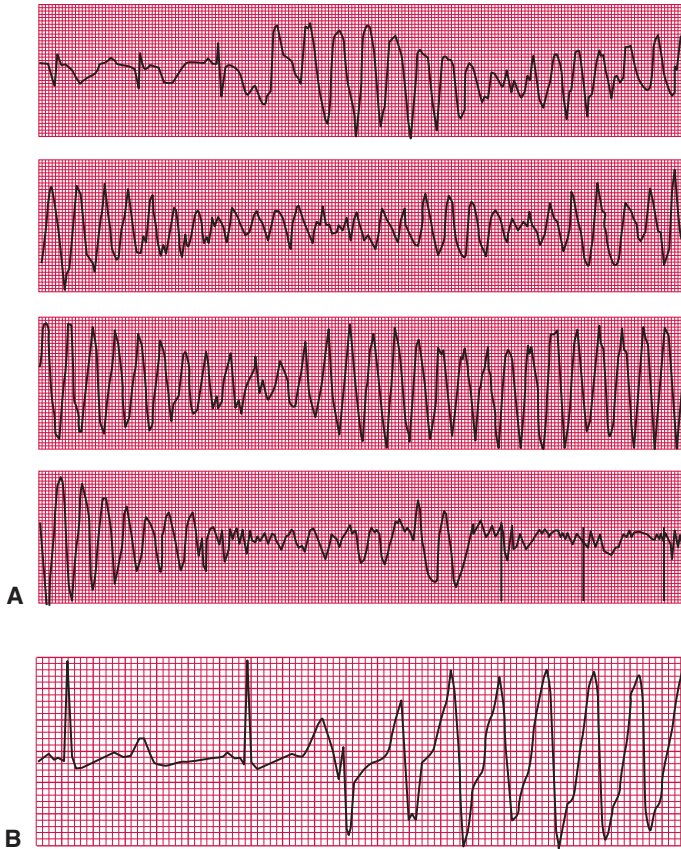


Fig. 11-46. Torsades de pointes. **A**, Continuous recording monitor lead. A demand ventricular pacemaker (VVI) has been implanted because of Mobitz type II second-degree AV block. After treatment with amiodarone for recurrent ventricular tachycardia (VT), the QT interval became prolonged (approximately 640 milliseconds during paced beats), and the patient developed episodes of torsades de pointes. In this recording, the tachycardia spontaneously terminates, and a paced ventricular rhythm is restored. Motion artifact is noted at the end of the recording as the patient lost consciousness. **B**, Tracing from a young boy with a congenital long QT syndrome. The QTU interval in the sinus beats is at least 600 milliseconds. Note TU wave alternans in the first and second complexes. A late premature complex occurring in the downslope of the TU wave initiates an episode of VT. (From Braunwald E: *Heart Disease: A Textbook of Cardiovascular Medicine*, 5th ed., Philadelphia, 1997, WB Saunders, Elsevier Science.)

- Antiarrhythmics known to increase the QT interval (e.g., quinidine, procainamide, amiodarone, disopyramide, sotalol)
- Tricyclic antidepressants and phenothiazines
- Histamine (H₁) antagonists (e.g., astemizole, terfenadine)
- Antiviral and antifungal agents and antibiotics
- Hypokalemia, hypomagnesemia
- Insecticide poisoning
- Bradyarrhythmias
- Congenital long QT syndrome
- Subarachnoid hemorrhage
- Chloroquine, pentamidine
- Cocaine abuse

12 ECG Board Self-Assessment Quiz

CONTENTS

ECG BOARD SELF-ASSESSMENT QUIZ

ANSWERS TO ECG BOARD SELF-ASSESSMENT
QUIZ

(Note: See pages 391–399 for answers.)

From: *Contemporary Cardiology: Rapid ECG Interpretation, 3e*
by: M. Gabriel Khan © Humana Press Inc., Totowa, NJ

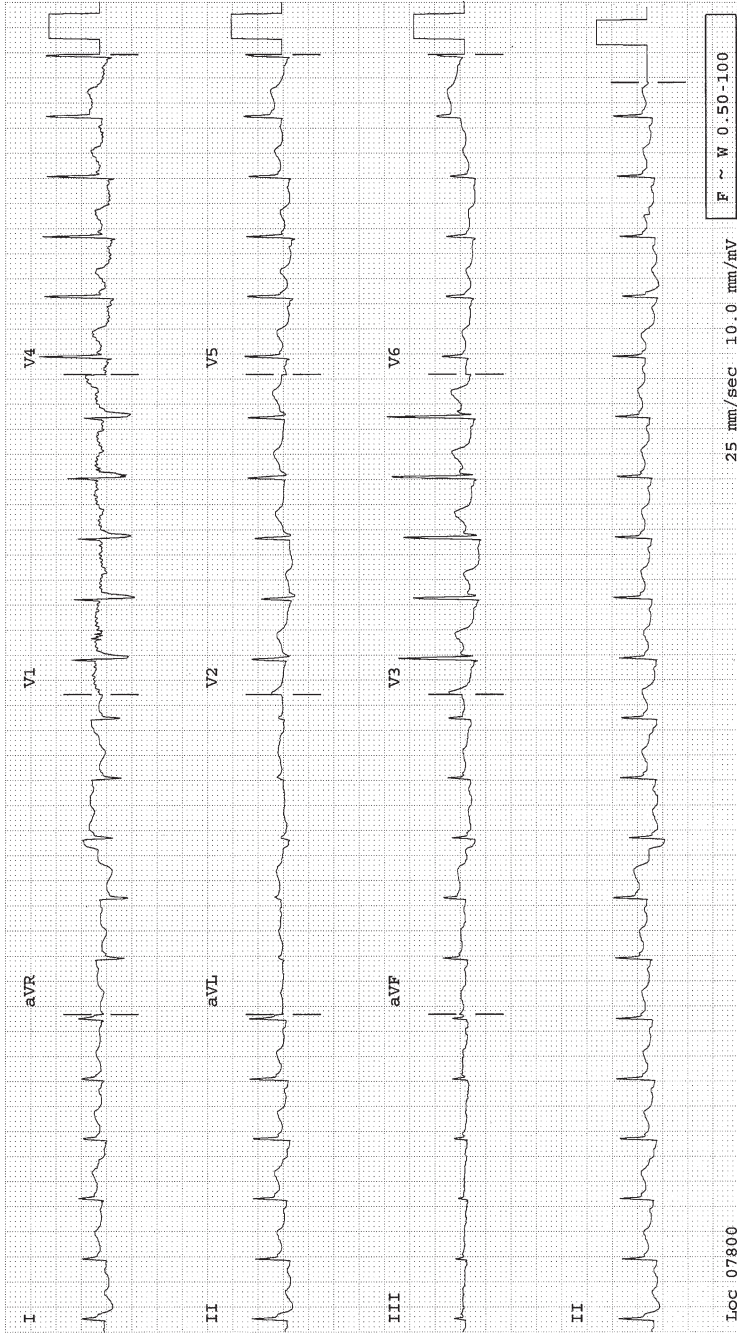


Fig. 12-1.

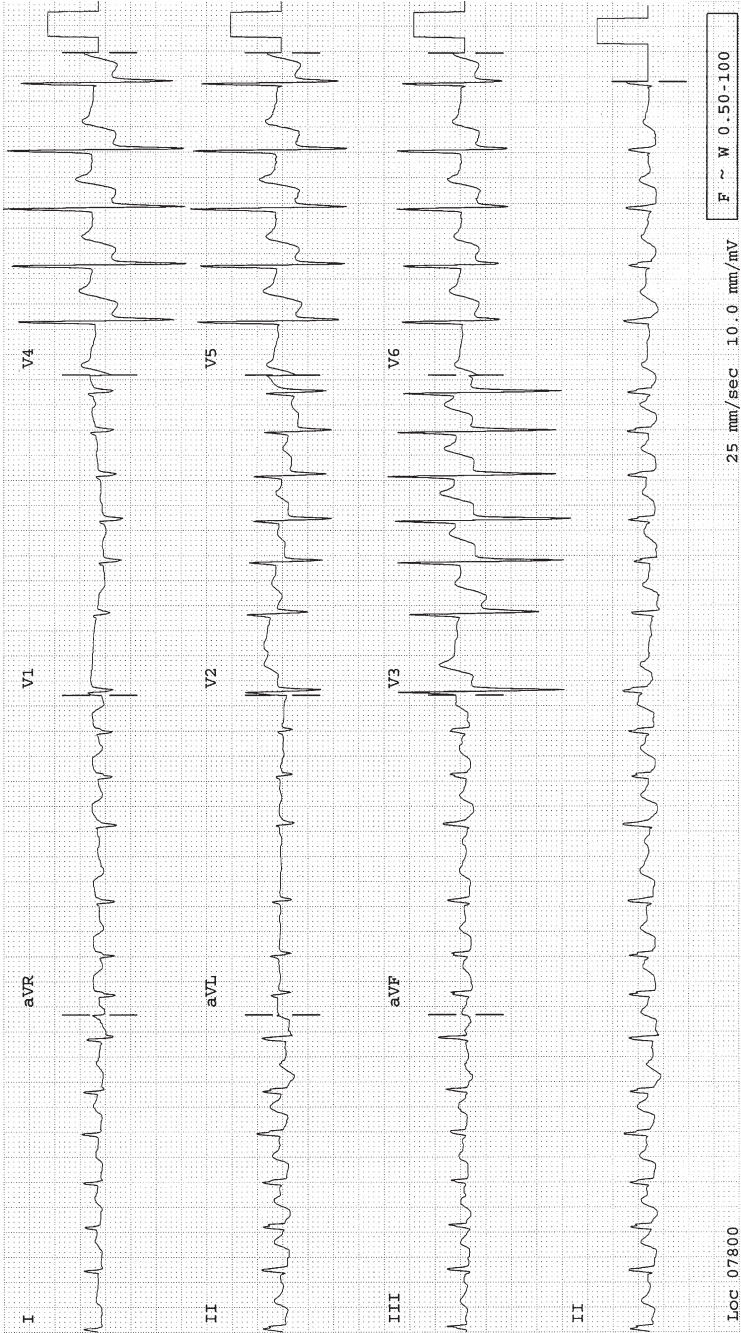


Fig. 12-2.

Loc 07800

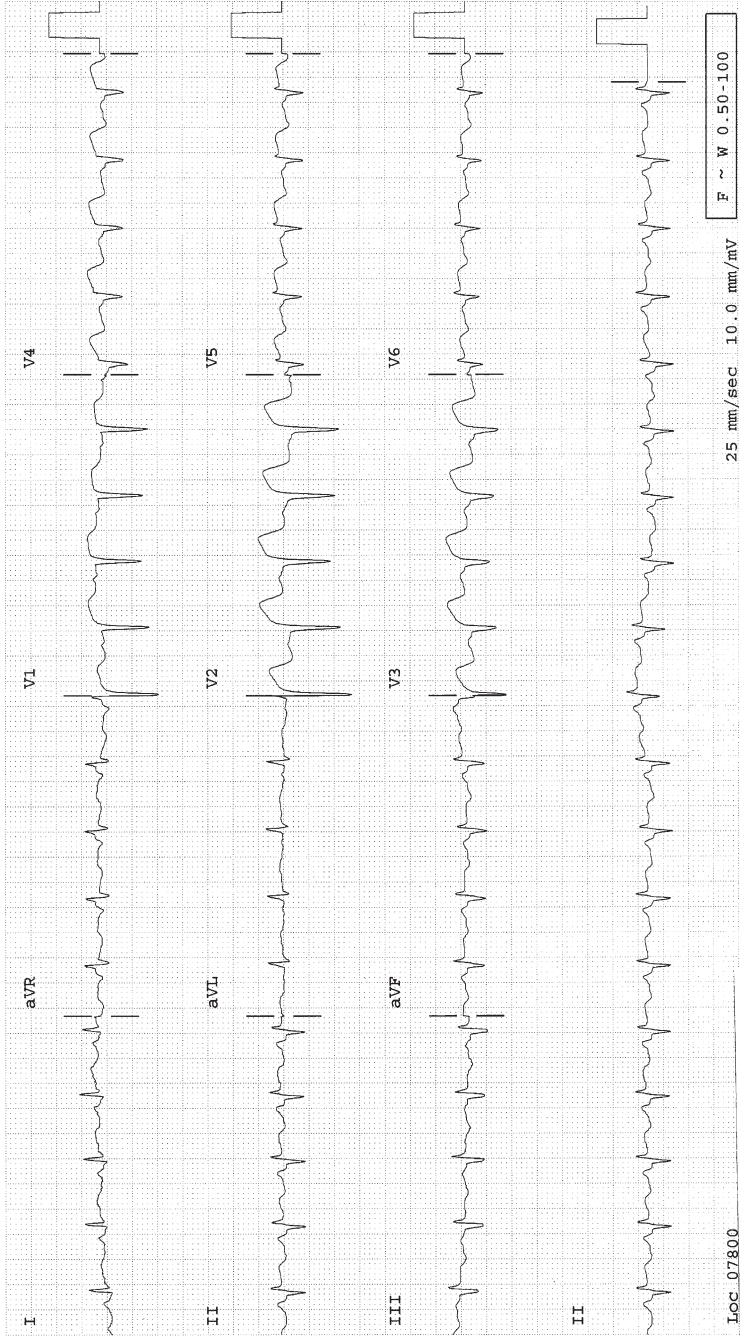


Fig. 12-3.

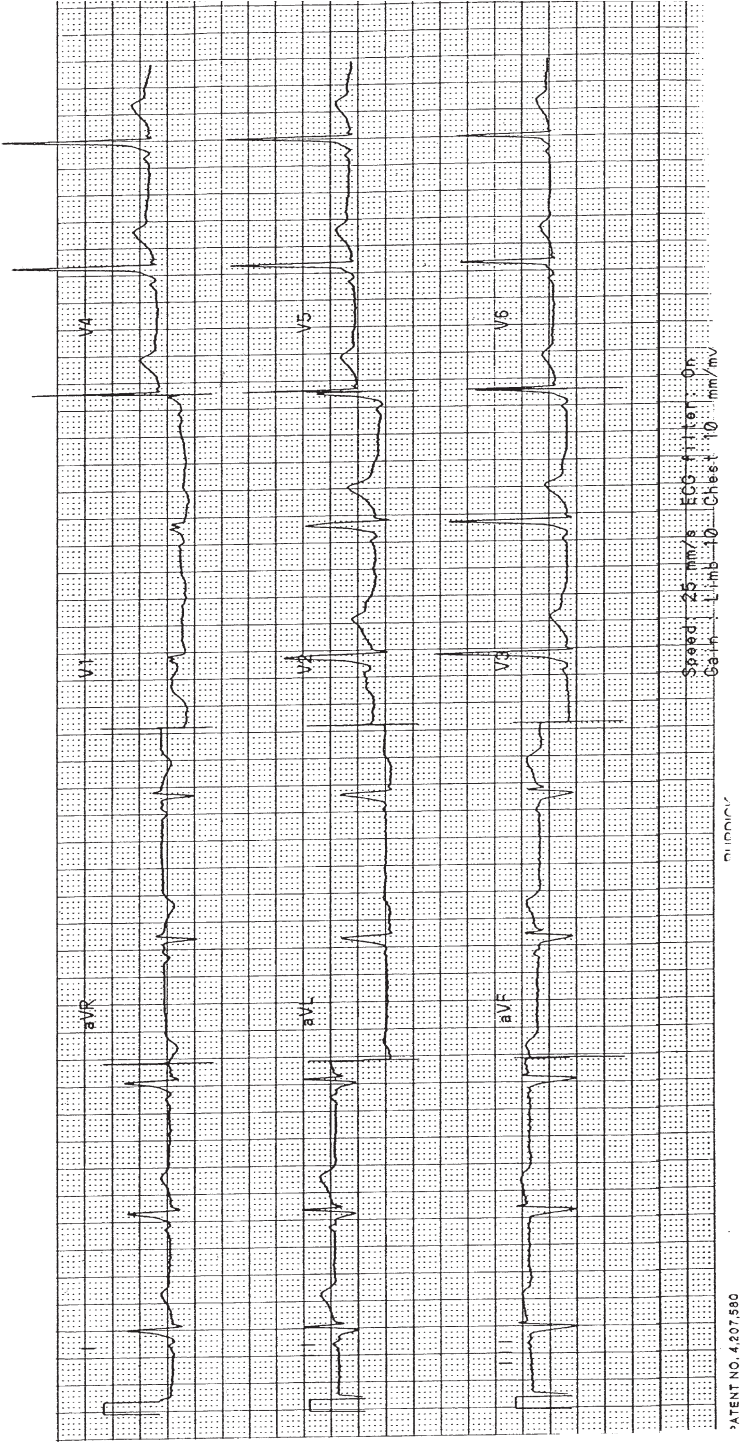


Fig. 12-4.

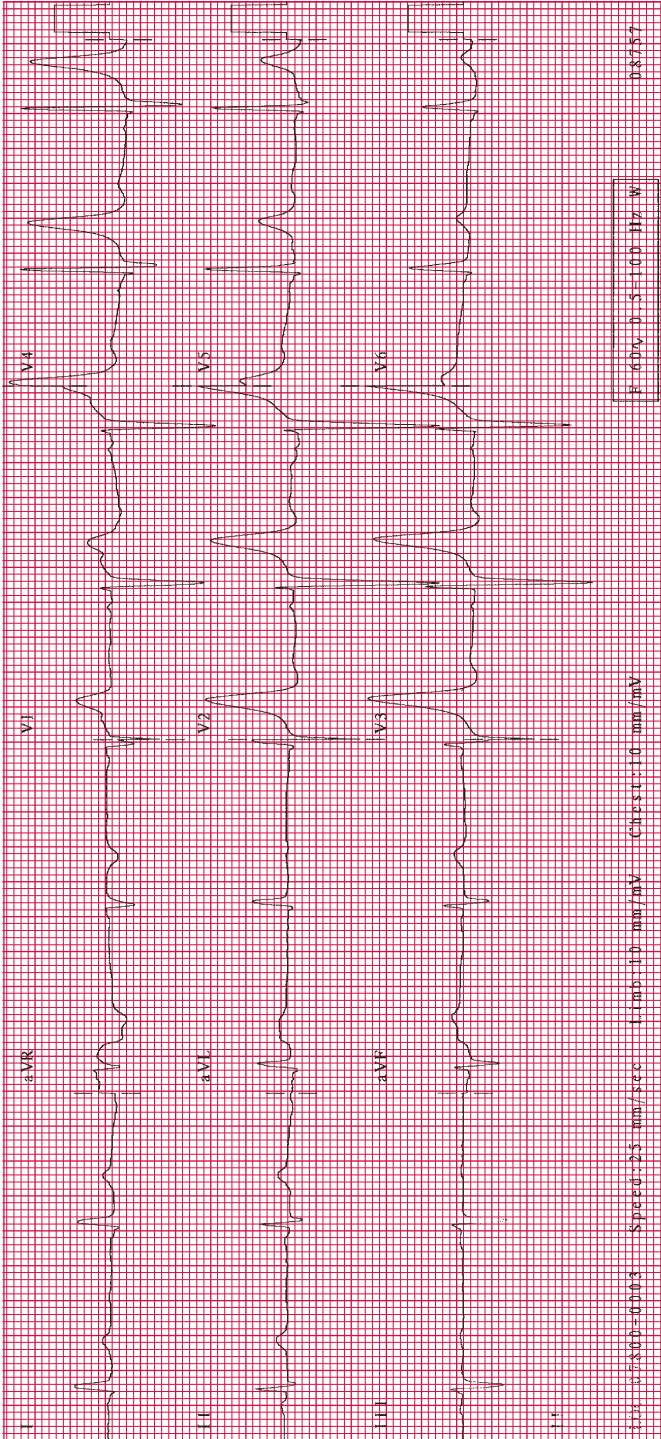


Fig. 12-5.

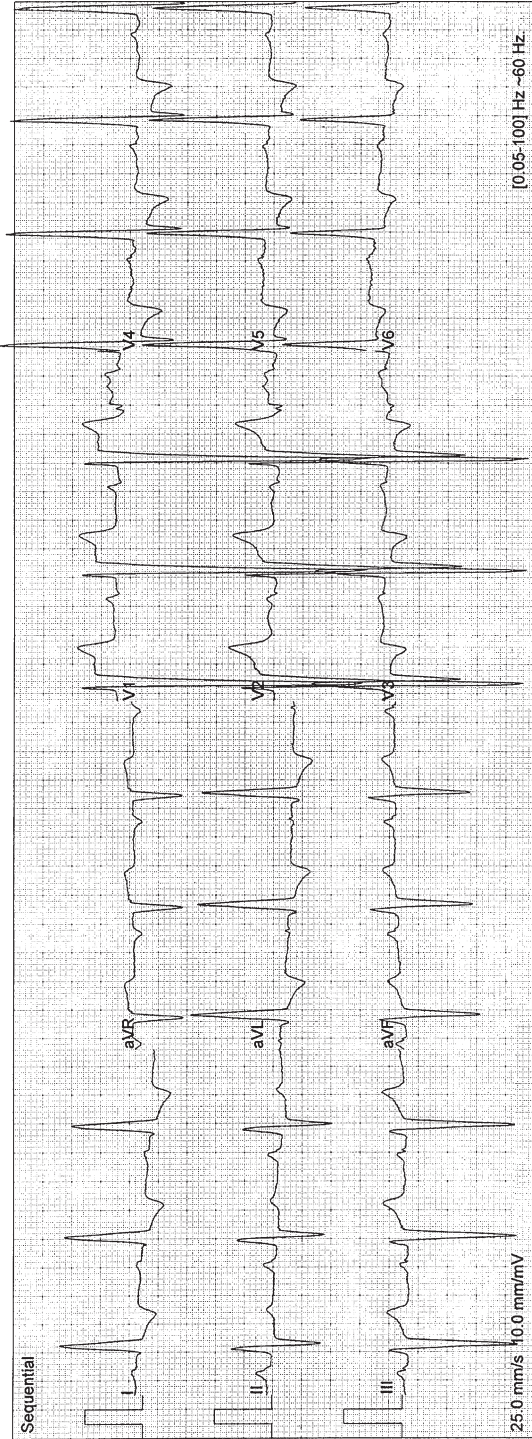


Fig. 12-6.


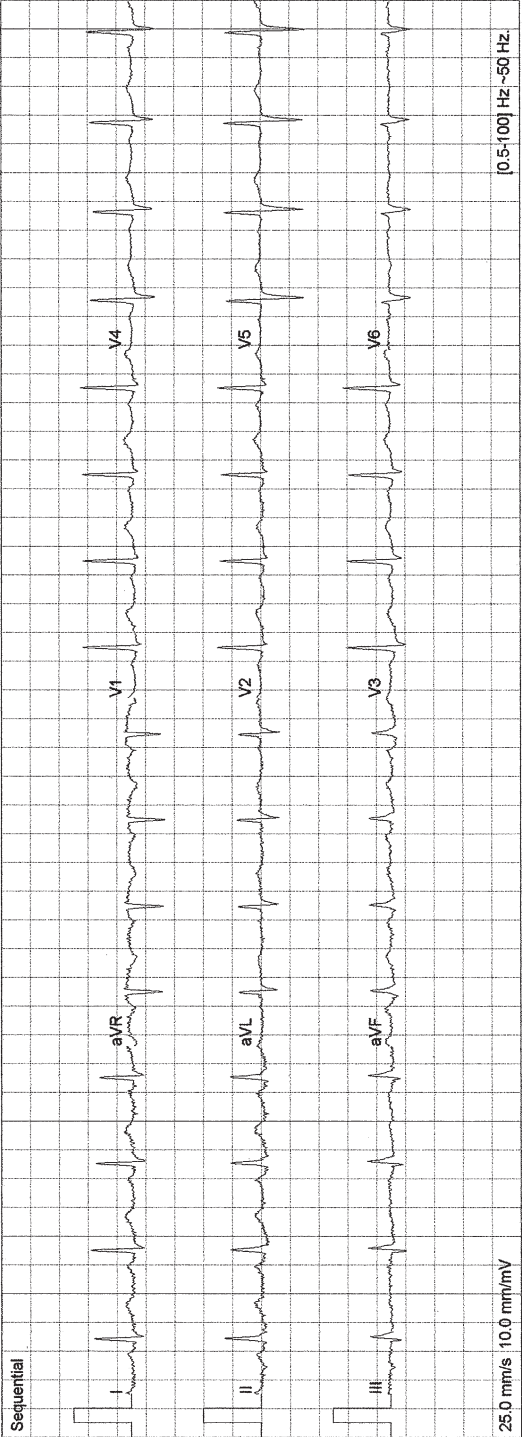


Fig. 12-7.



A

Fig. 12-8A.

(continued)

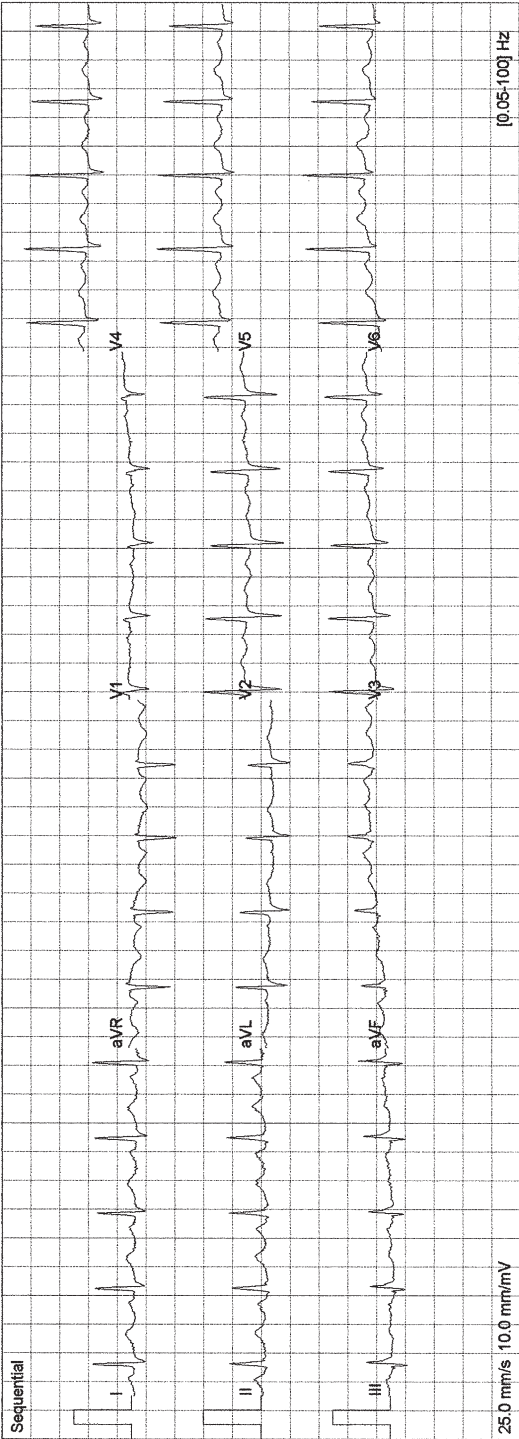


Fig. 12-8B Continued

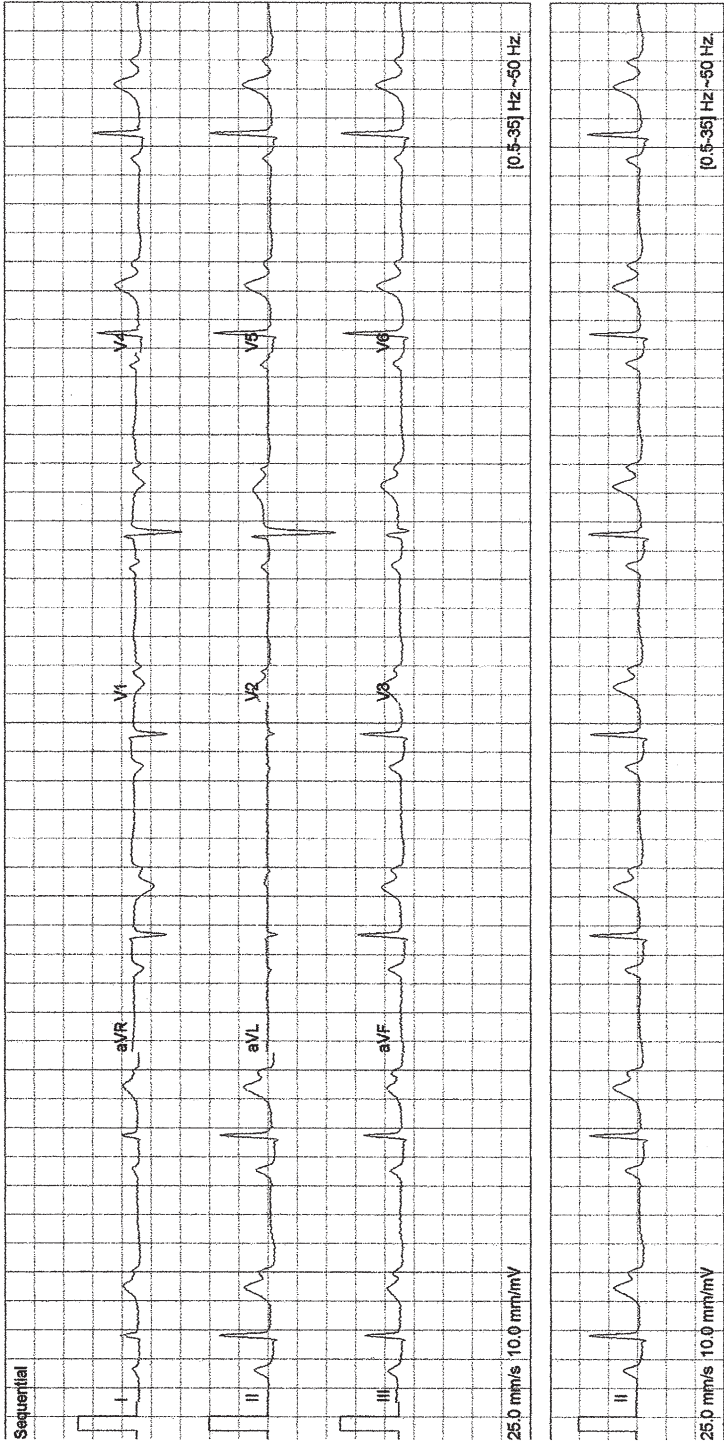


Fig. 12-9.

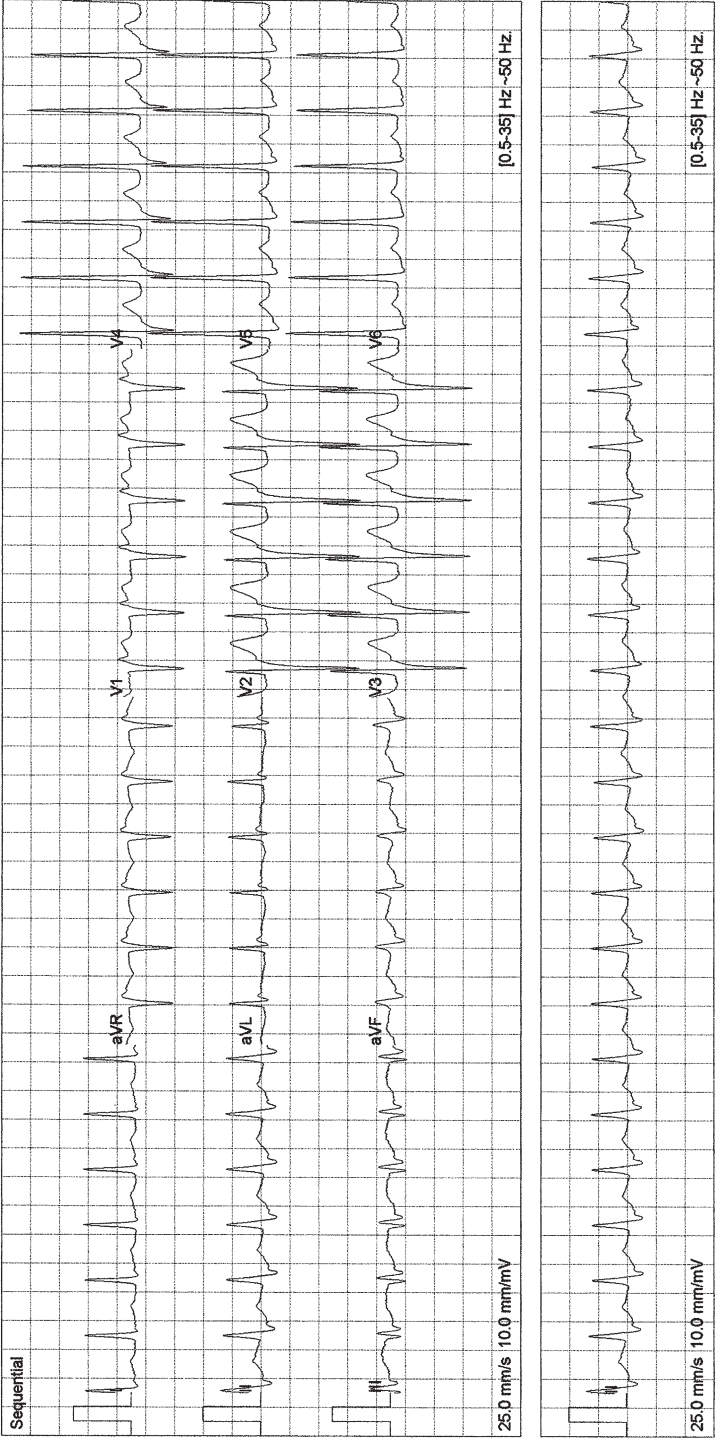


Fig. 12-10.

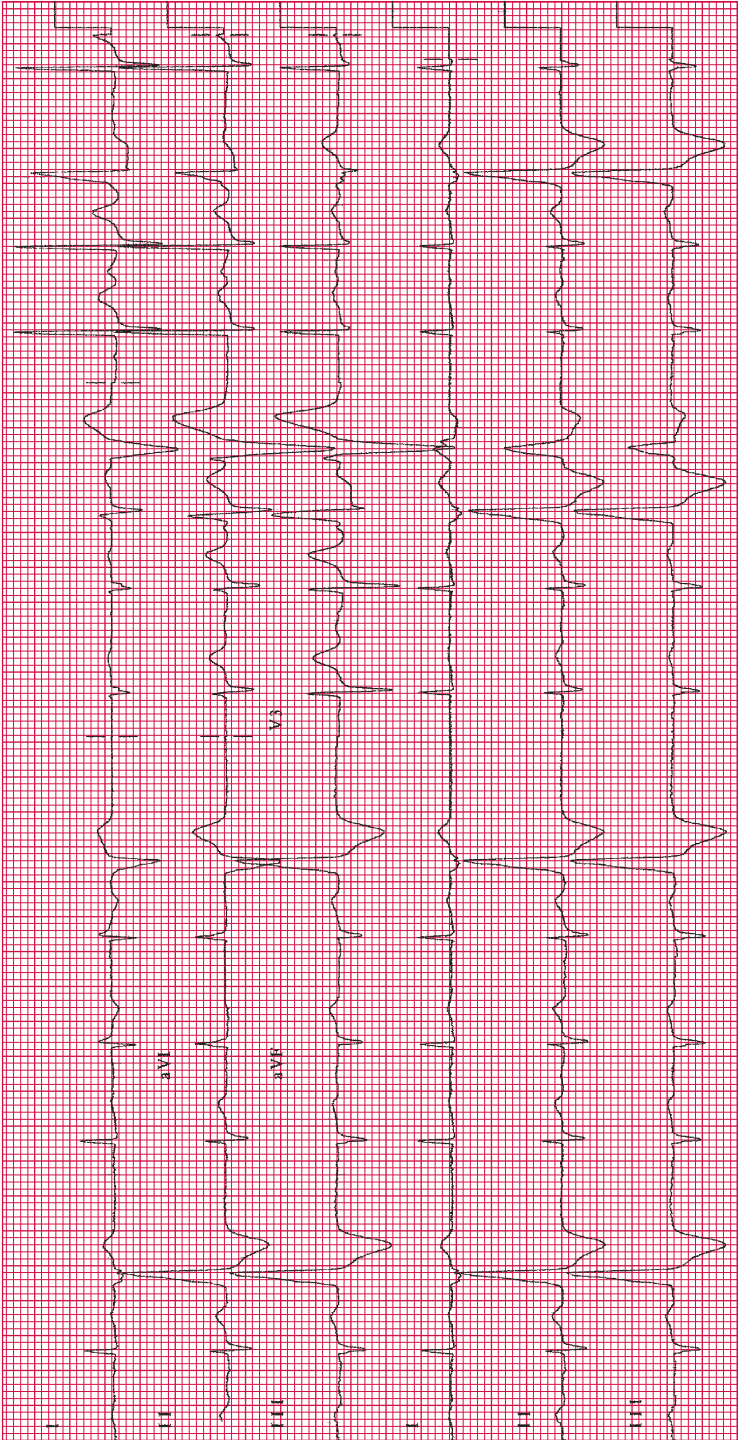


Fig. 12-11.

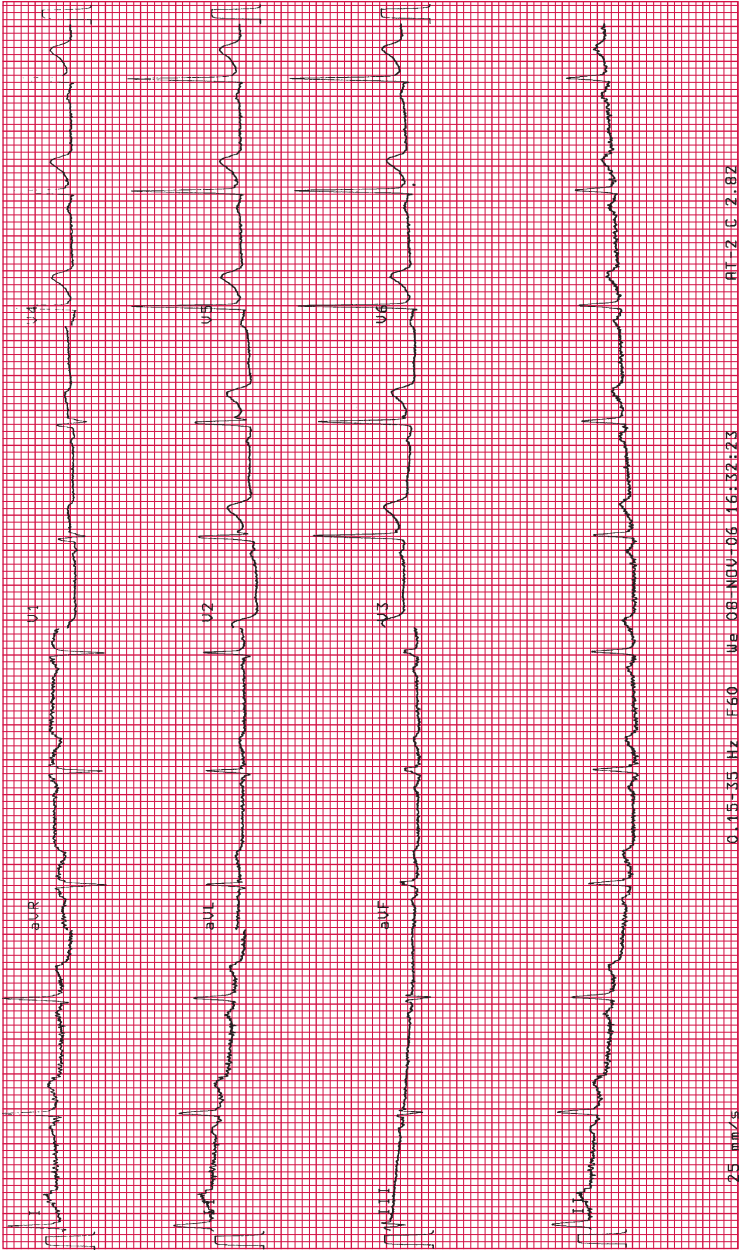


Fig. 12-12.

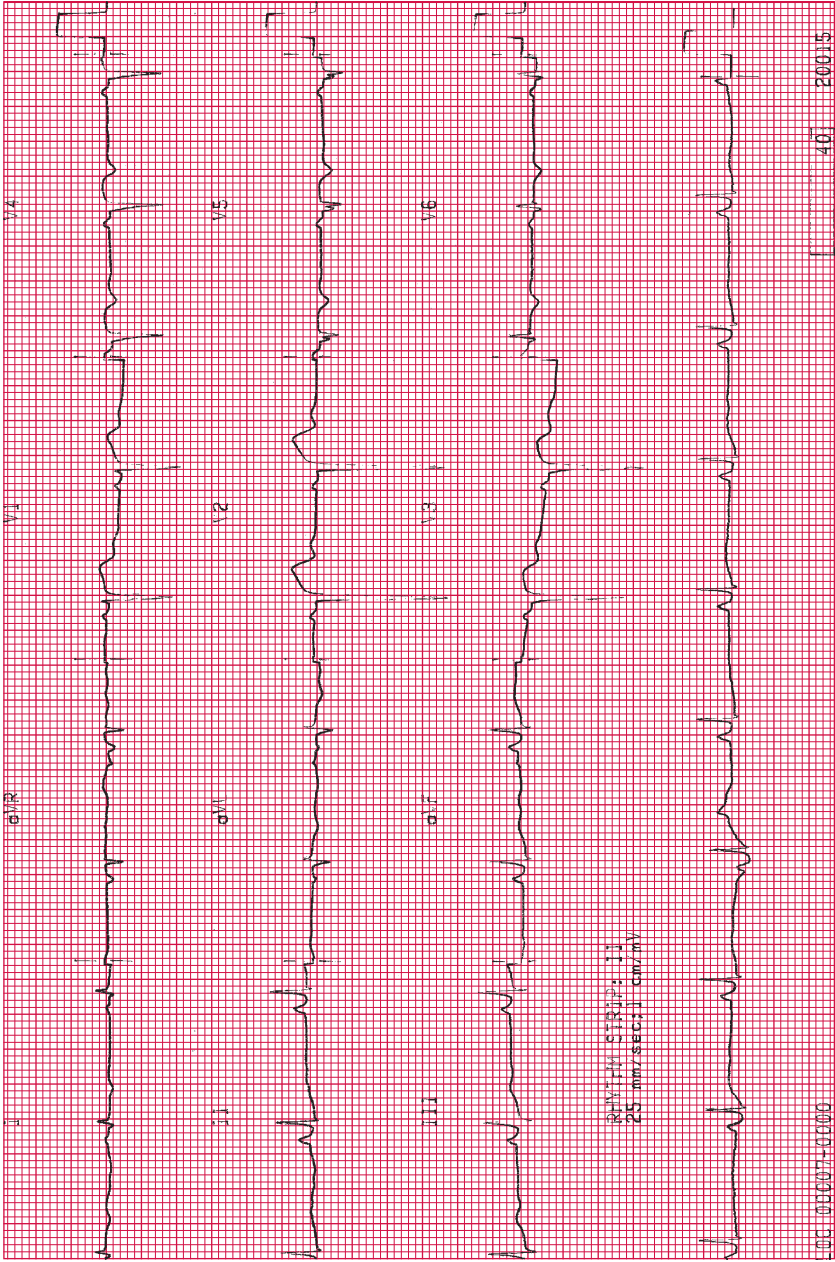


Fig. 12-13.

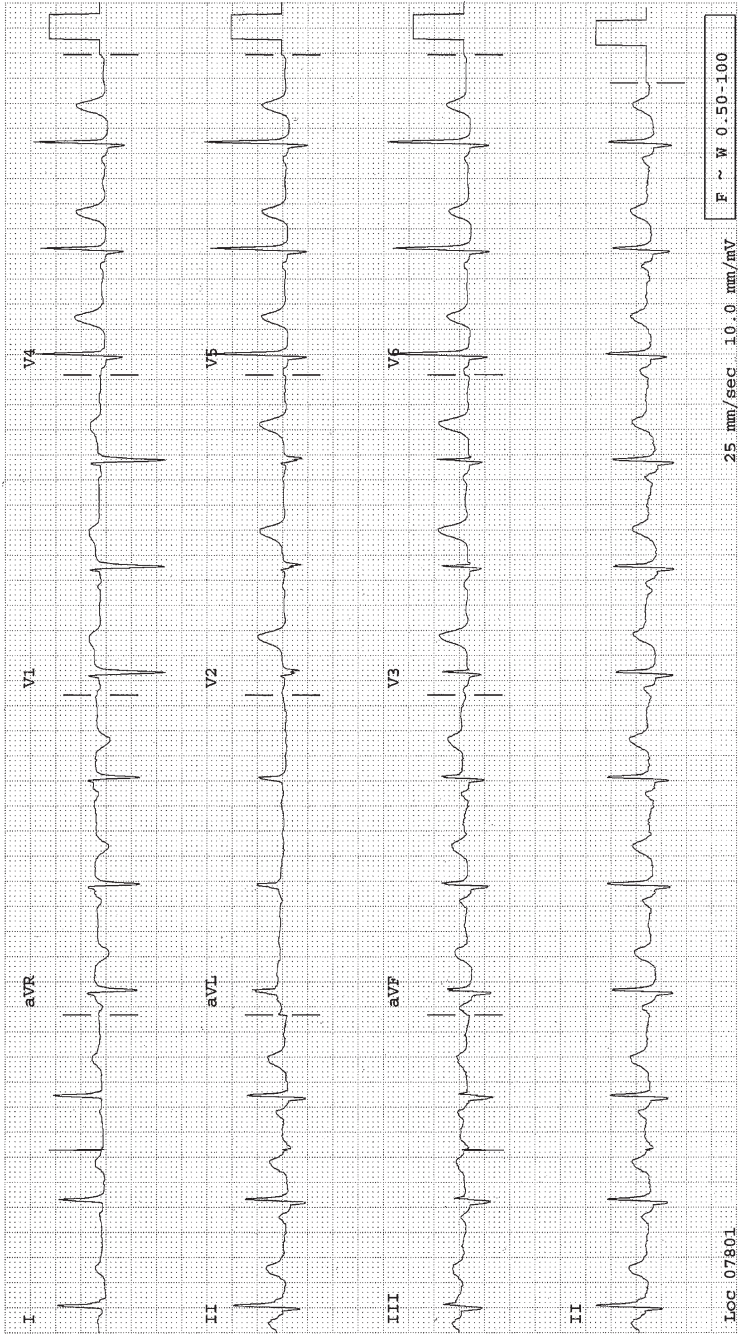


Fig. 12-14.

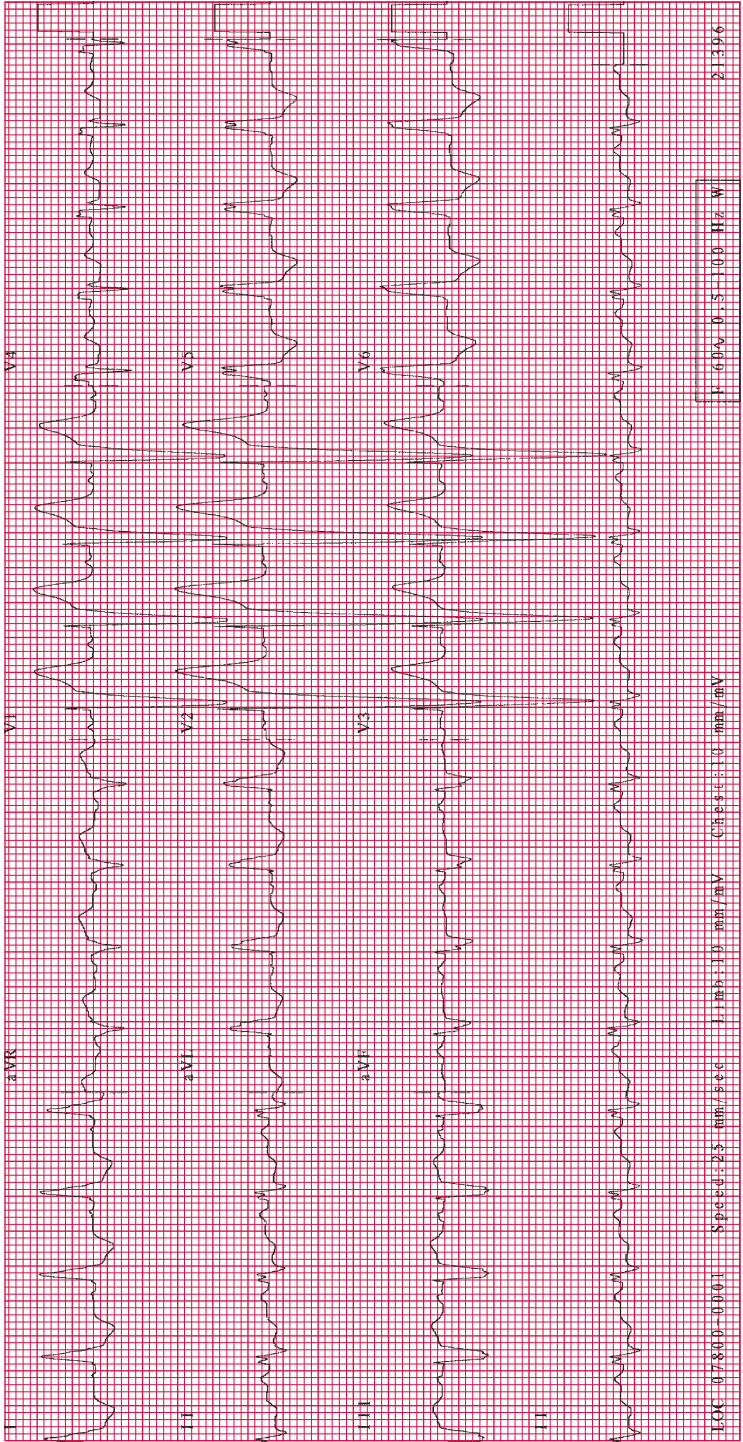


Fig. 12-15.

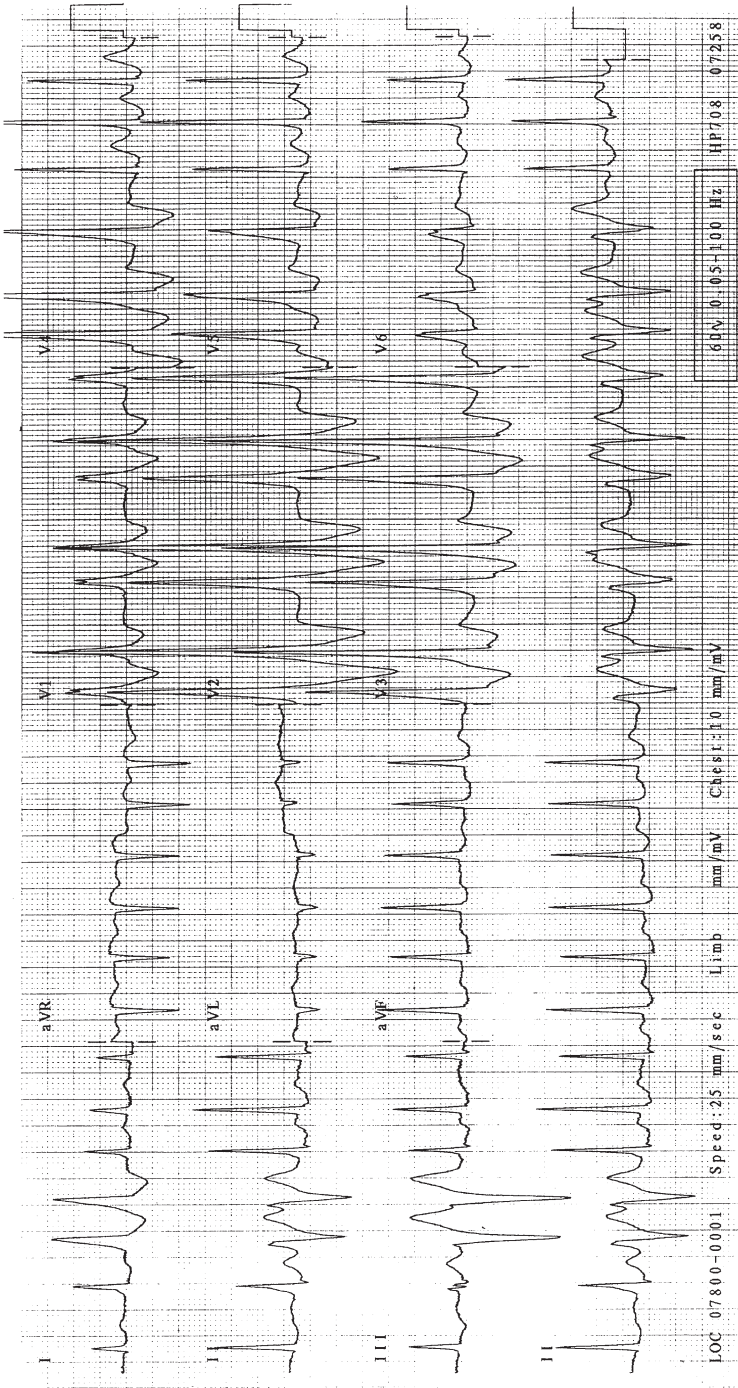

Fig. 12-16.

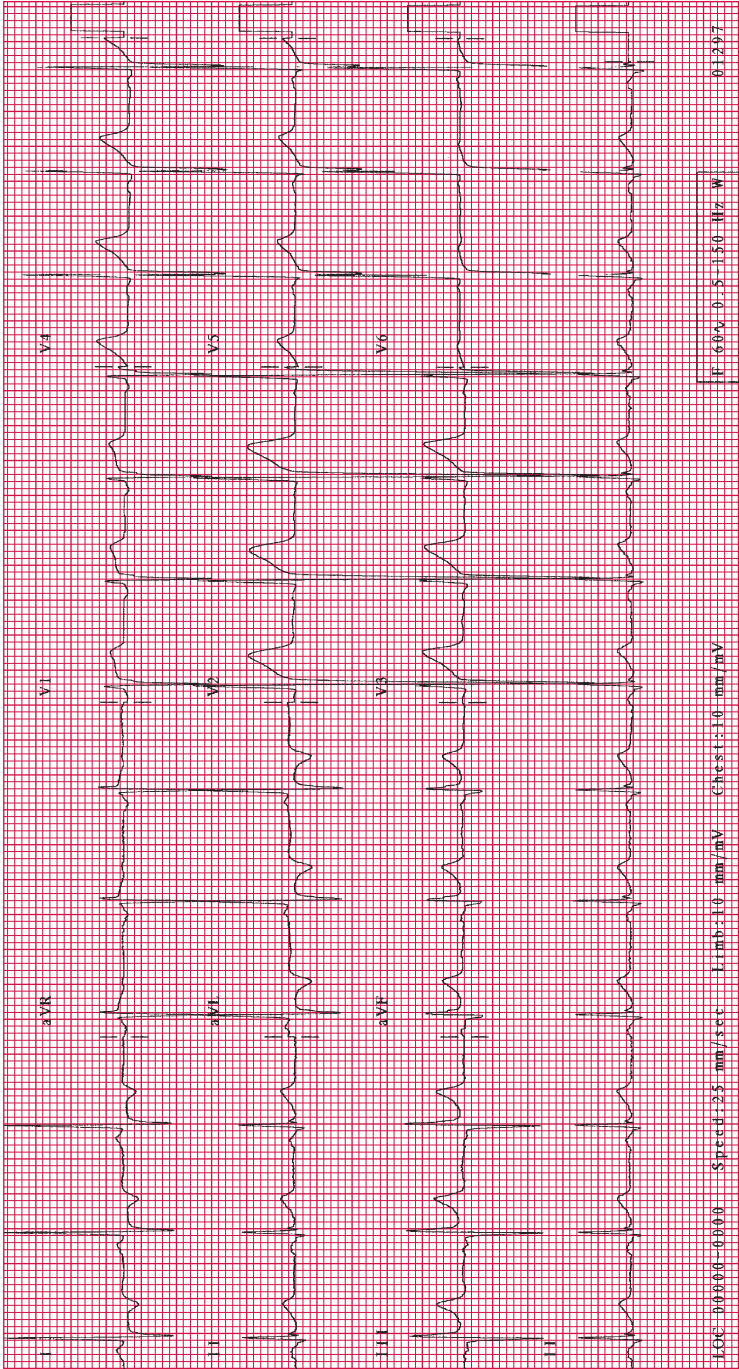


Fig. 12-17.

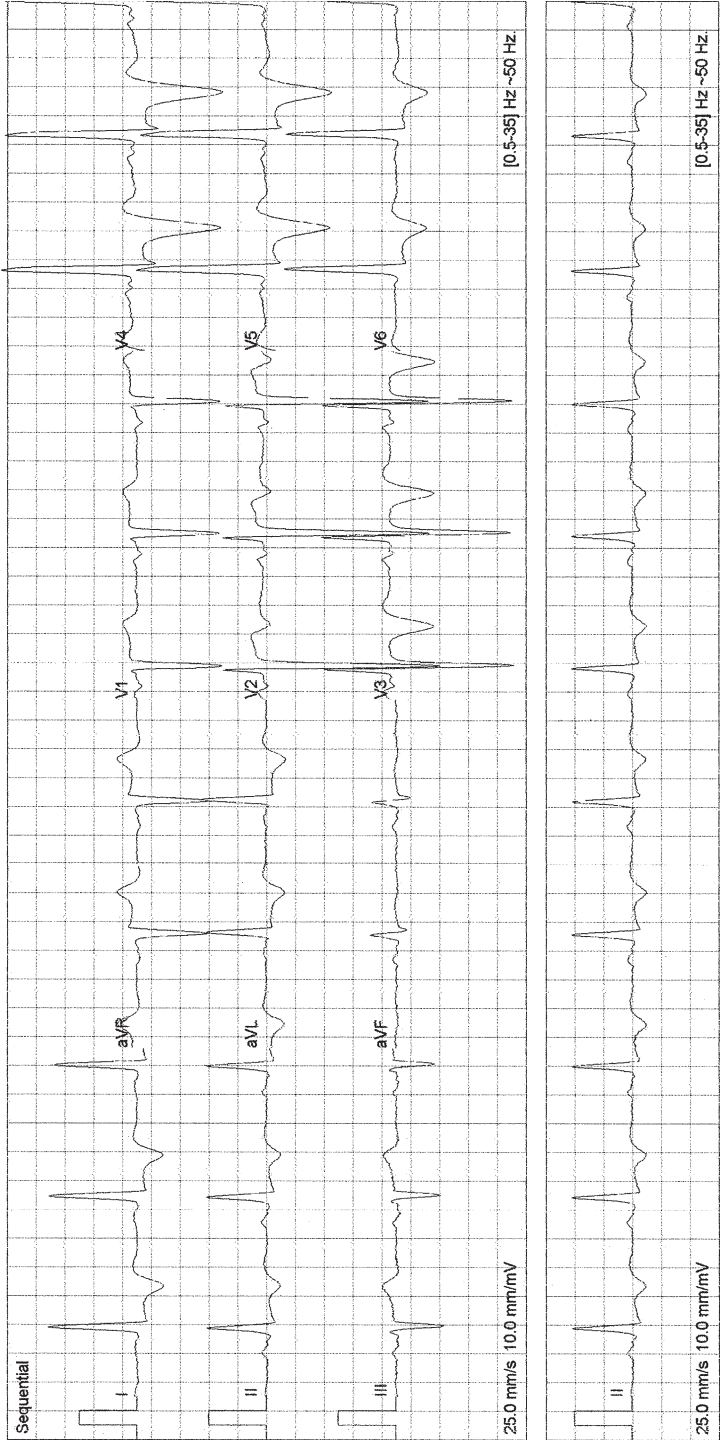


Fig. 12-18.

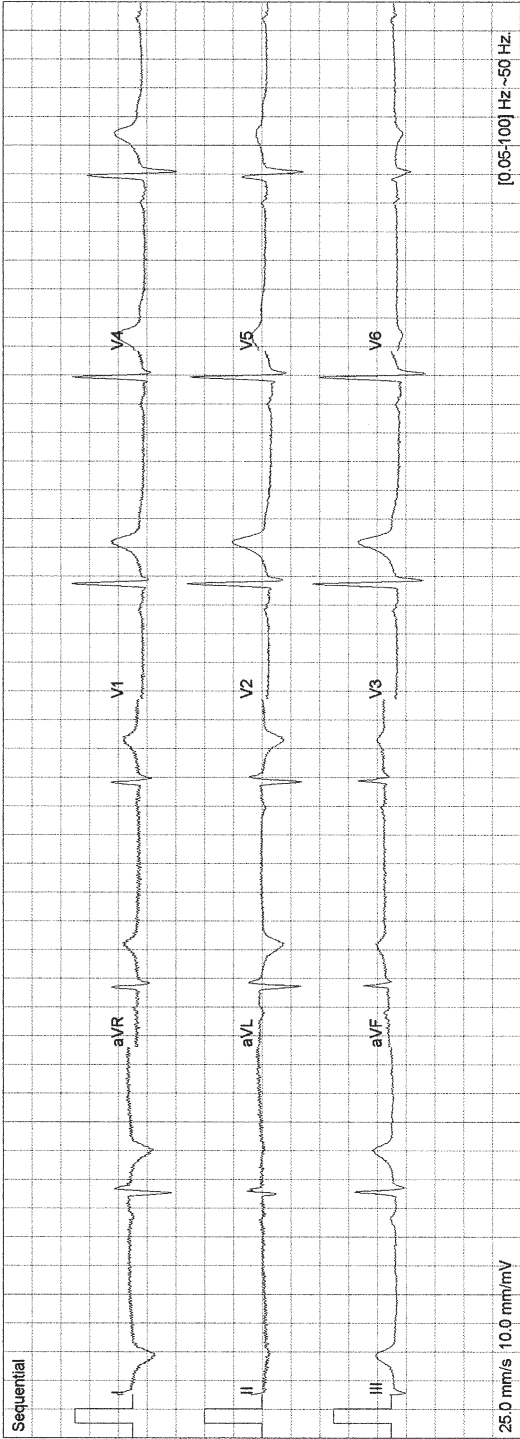


Fig. 12-19.

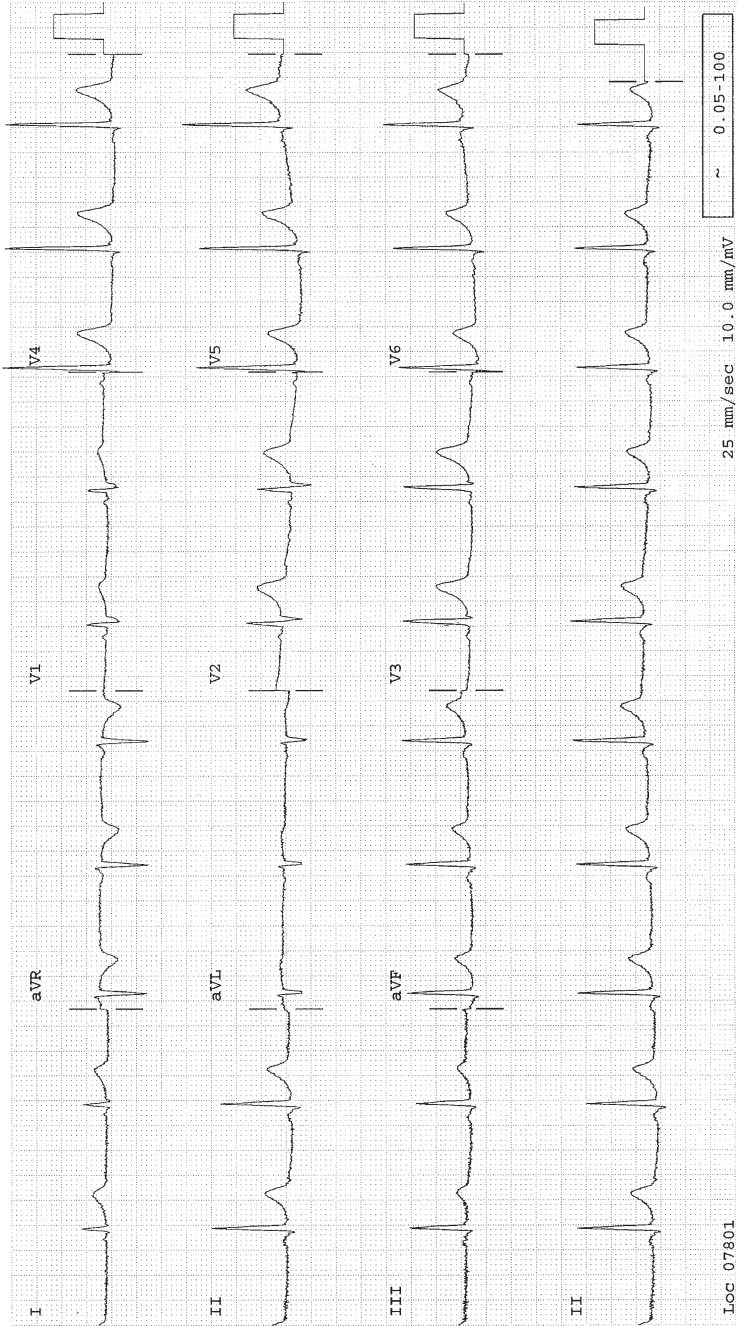


Fig. 12-20.

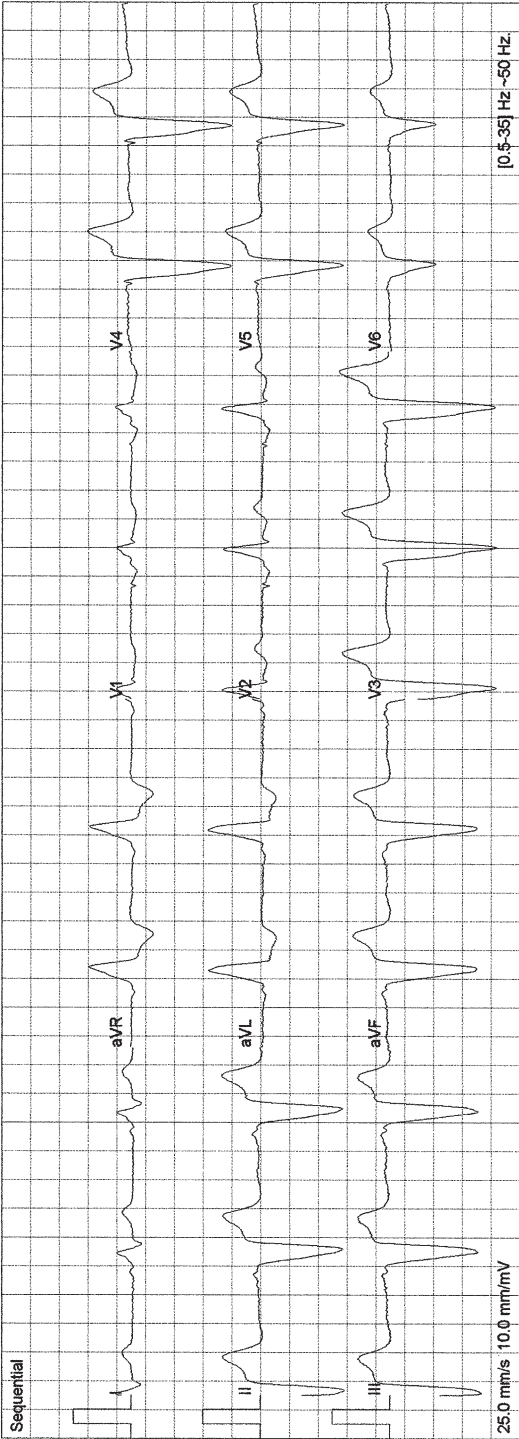


Fig. 12-21.

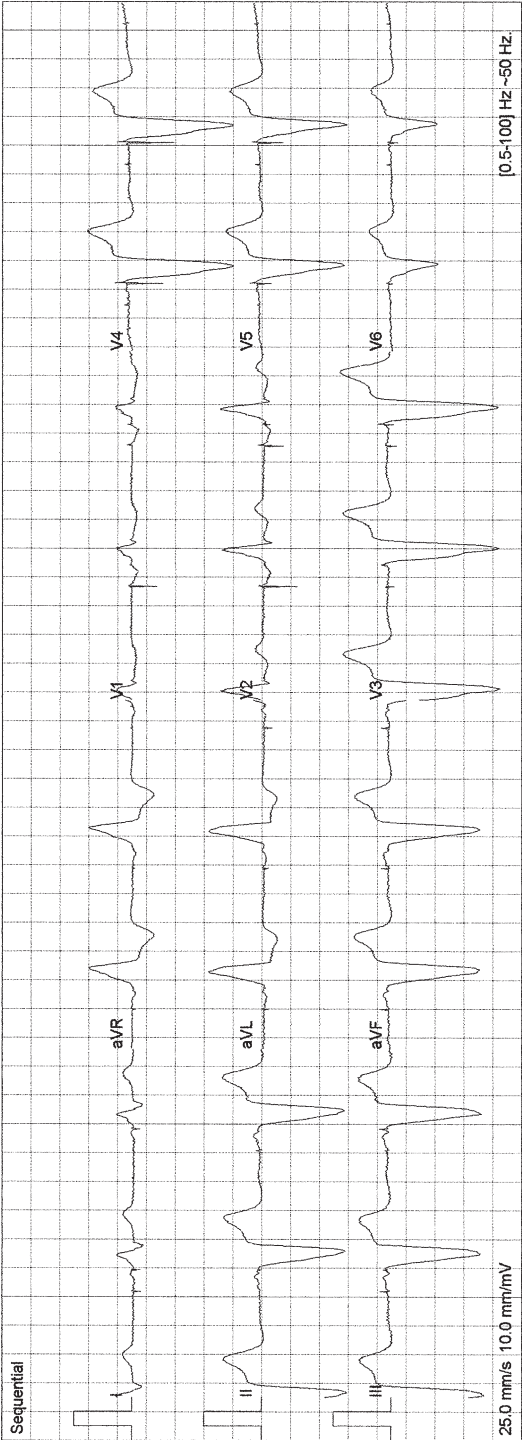


Fig. 12-22.

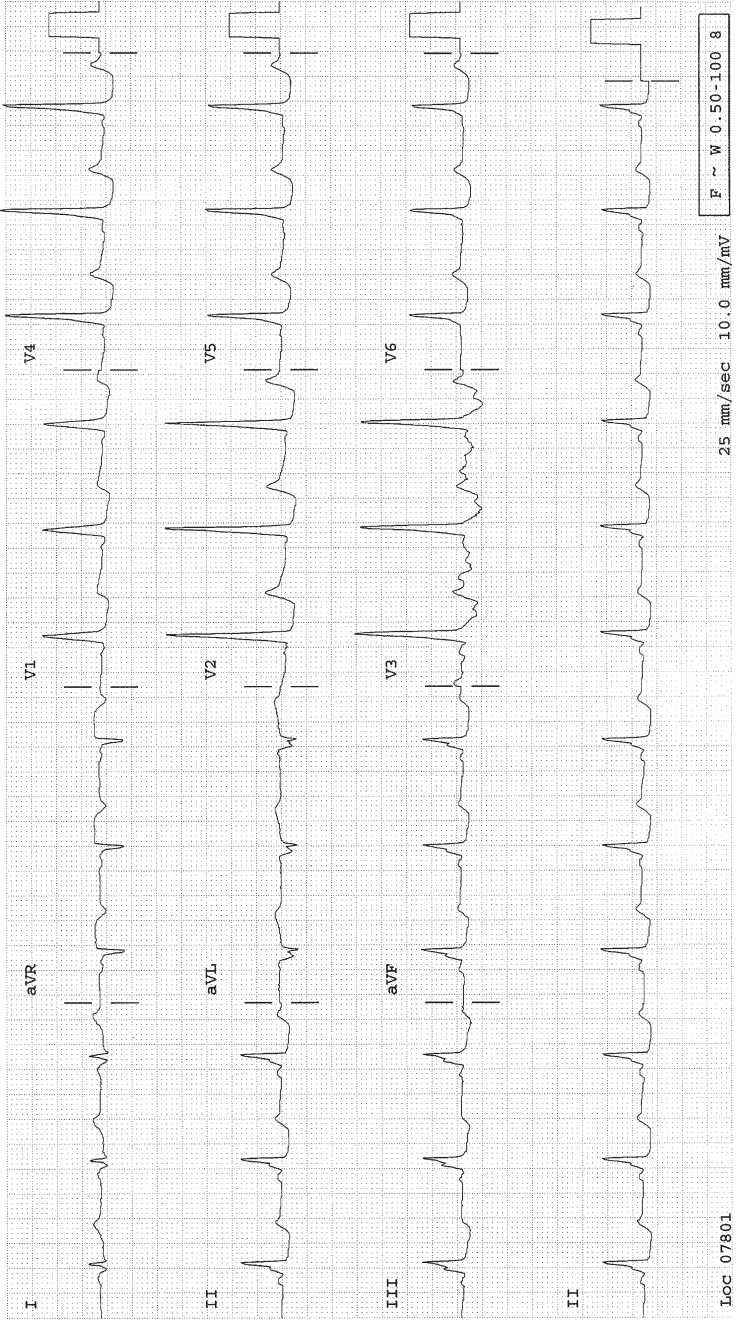


Fig. 12-23.

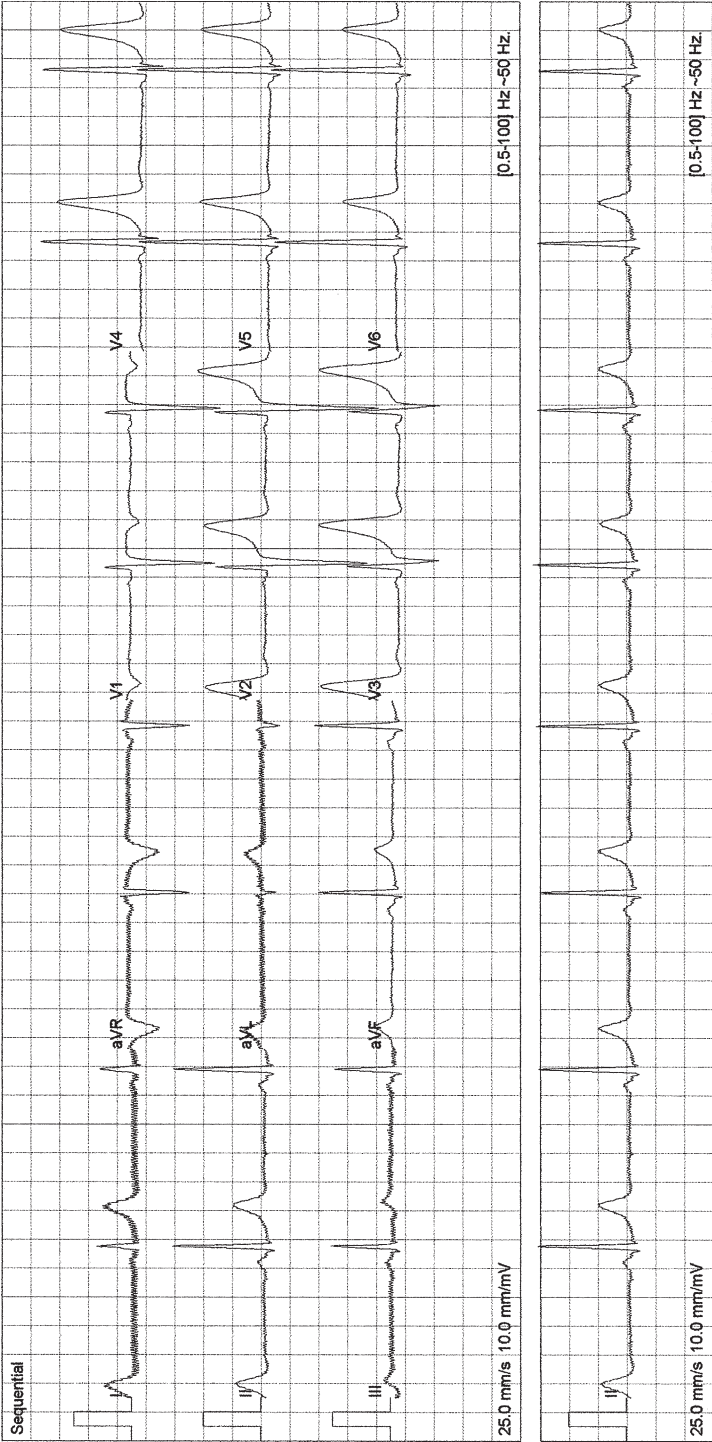


Fig. 12-24.

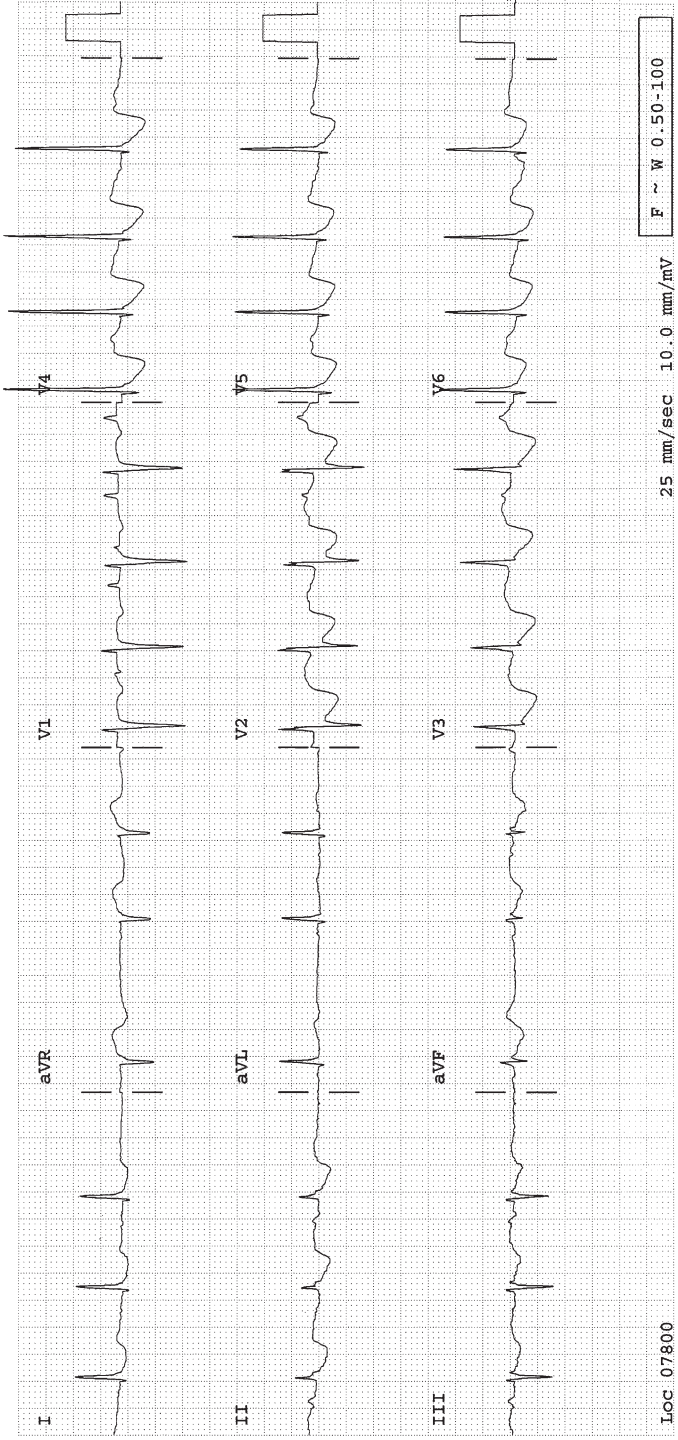


Fig. 12-25.

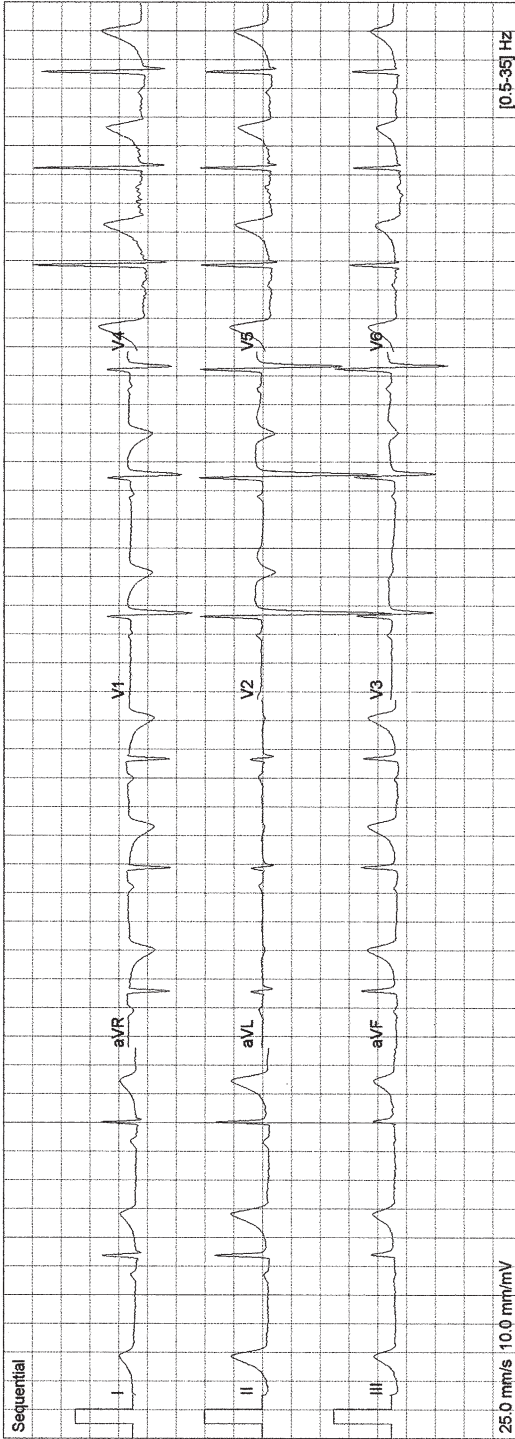


Fig. 12-26.

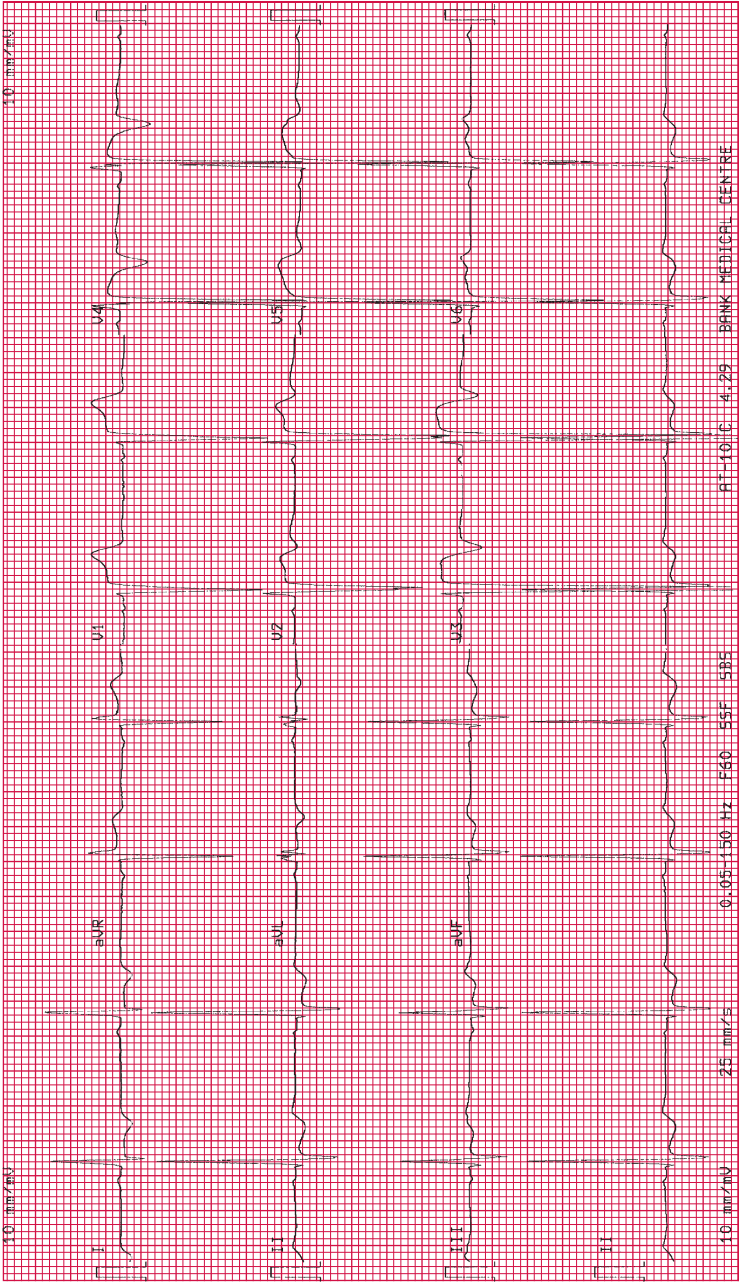


Fig. 12-27.

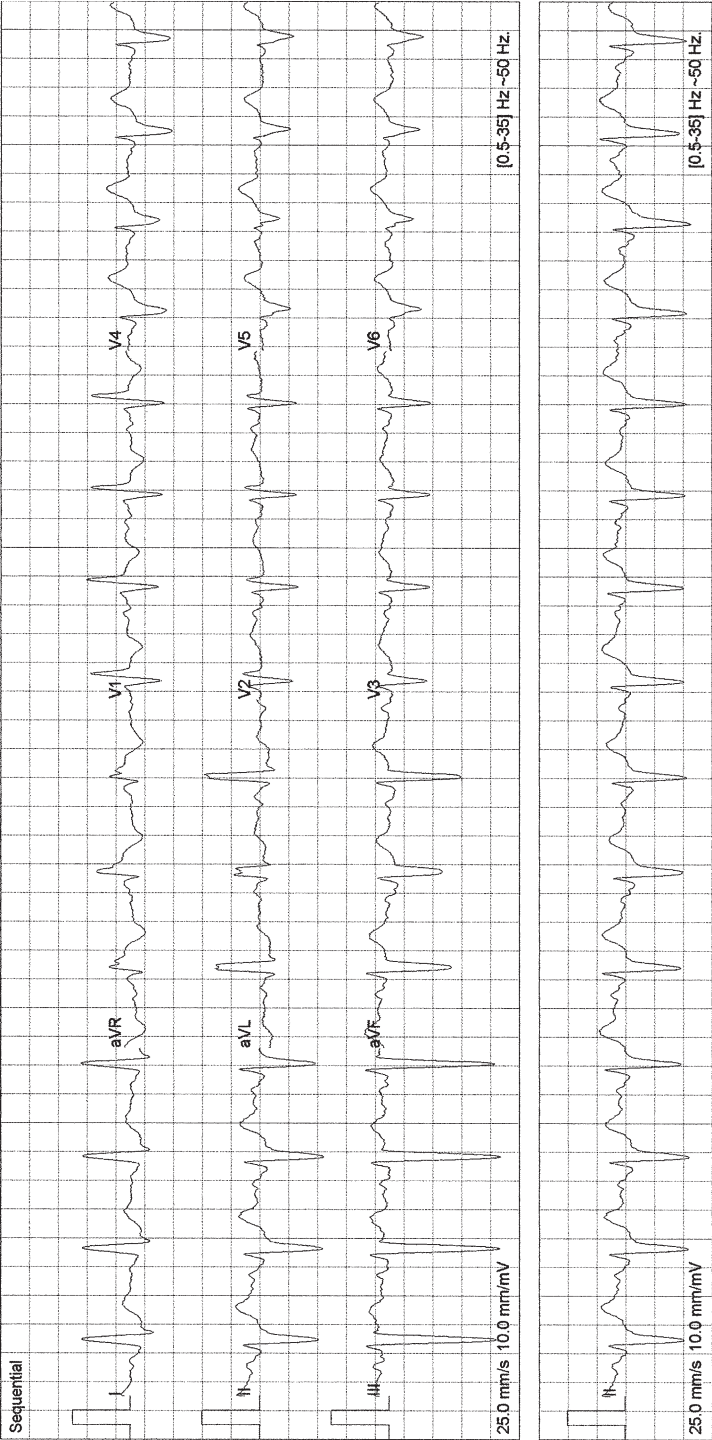


Fig. 12-28.

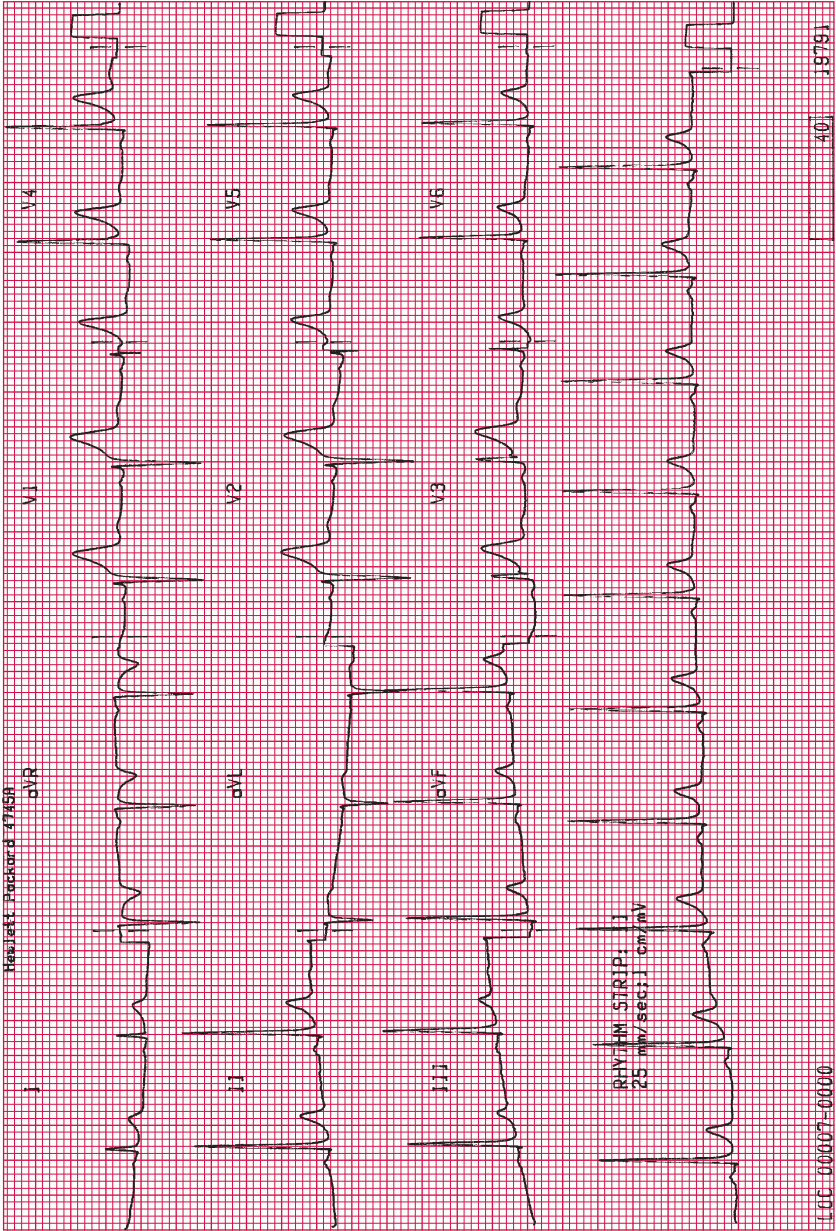


Fig. 12-29.

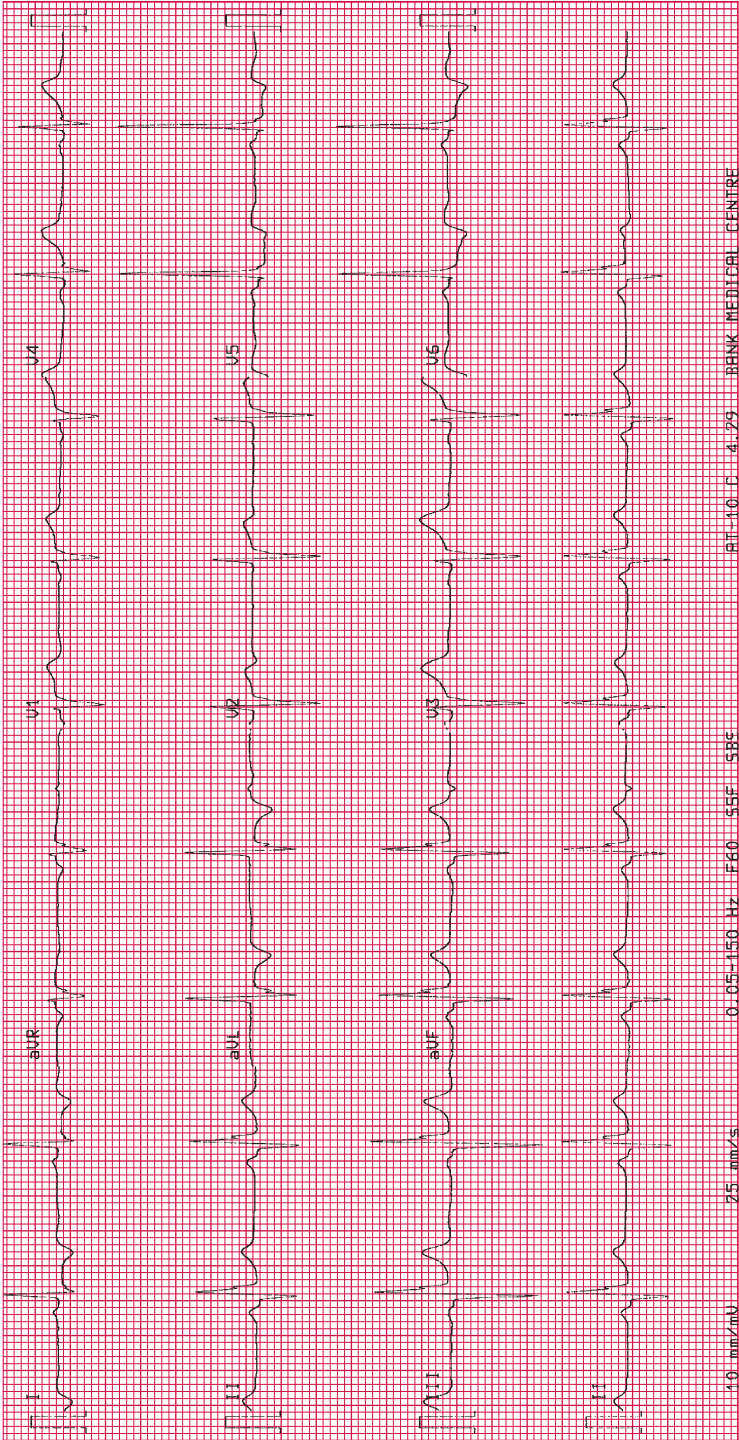


Fig. 12-30.

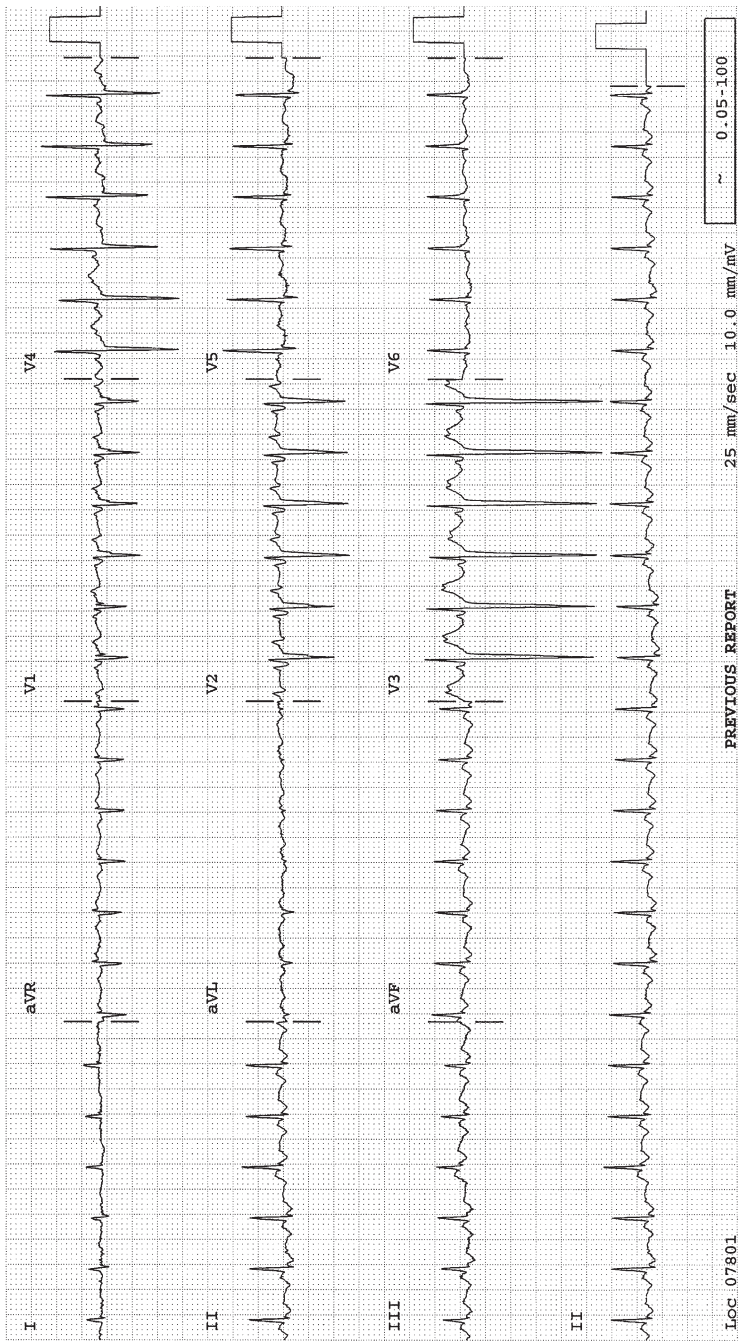


Fig. 12-31.

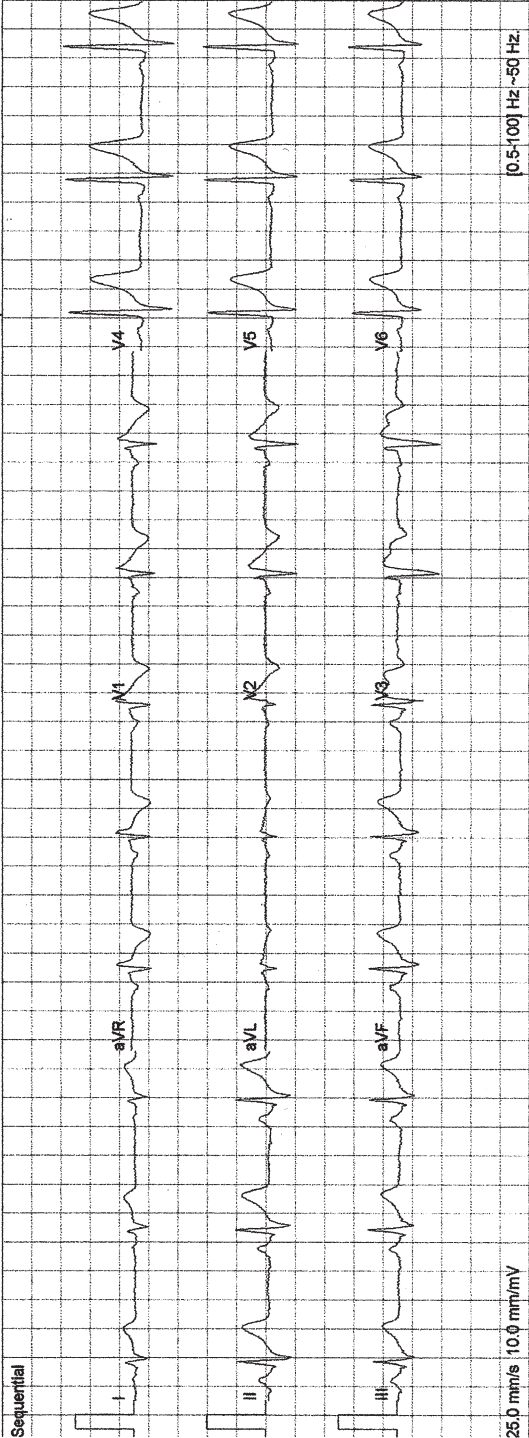


Fig. 12-32.

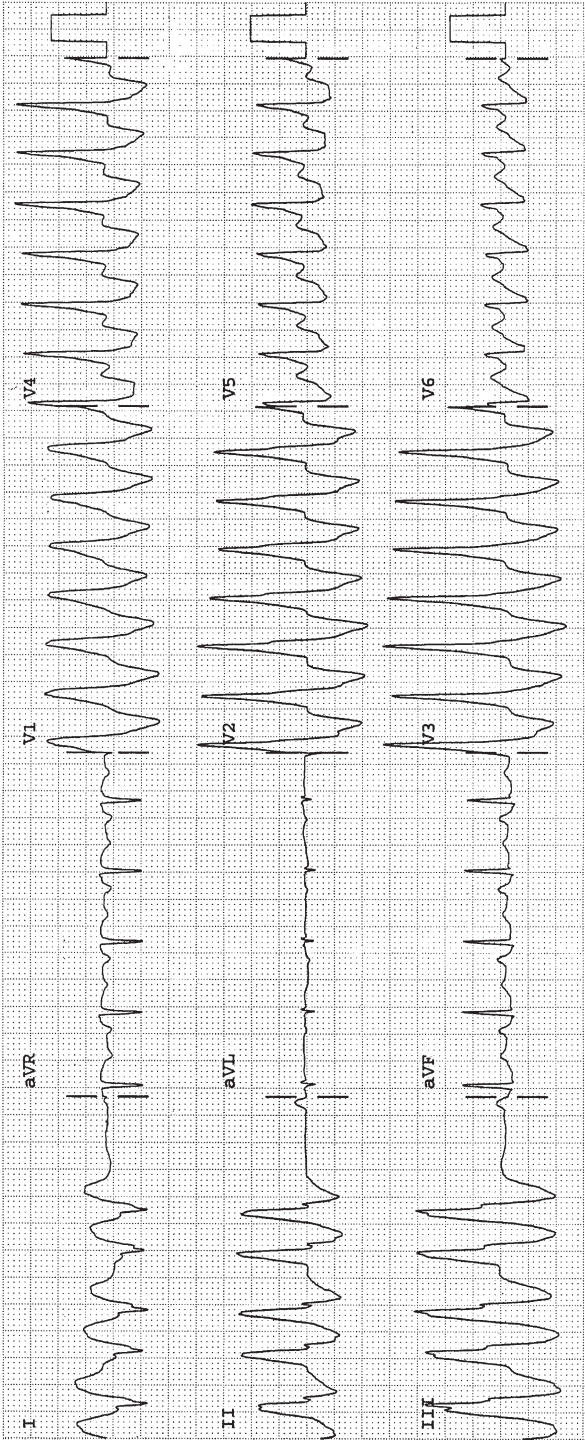


Fig. 12-33.

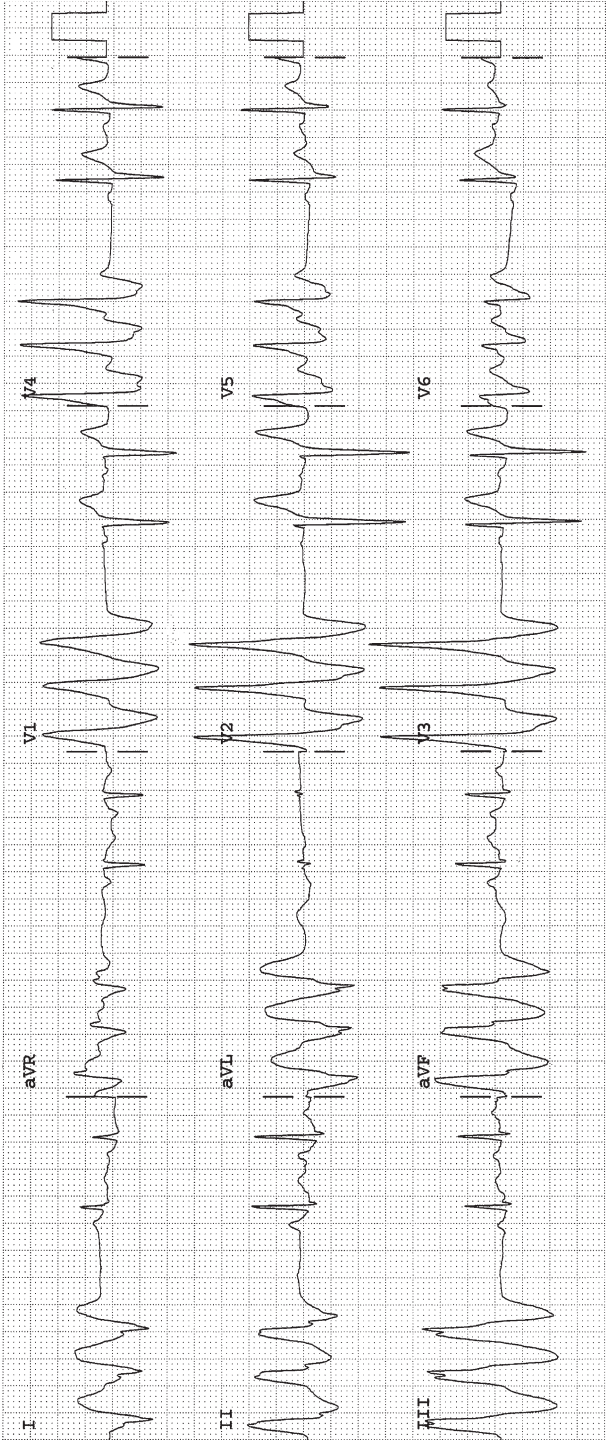


Fig. 12-34.

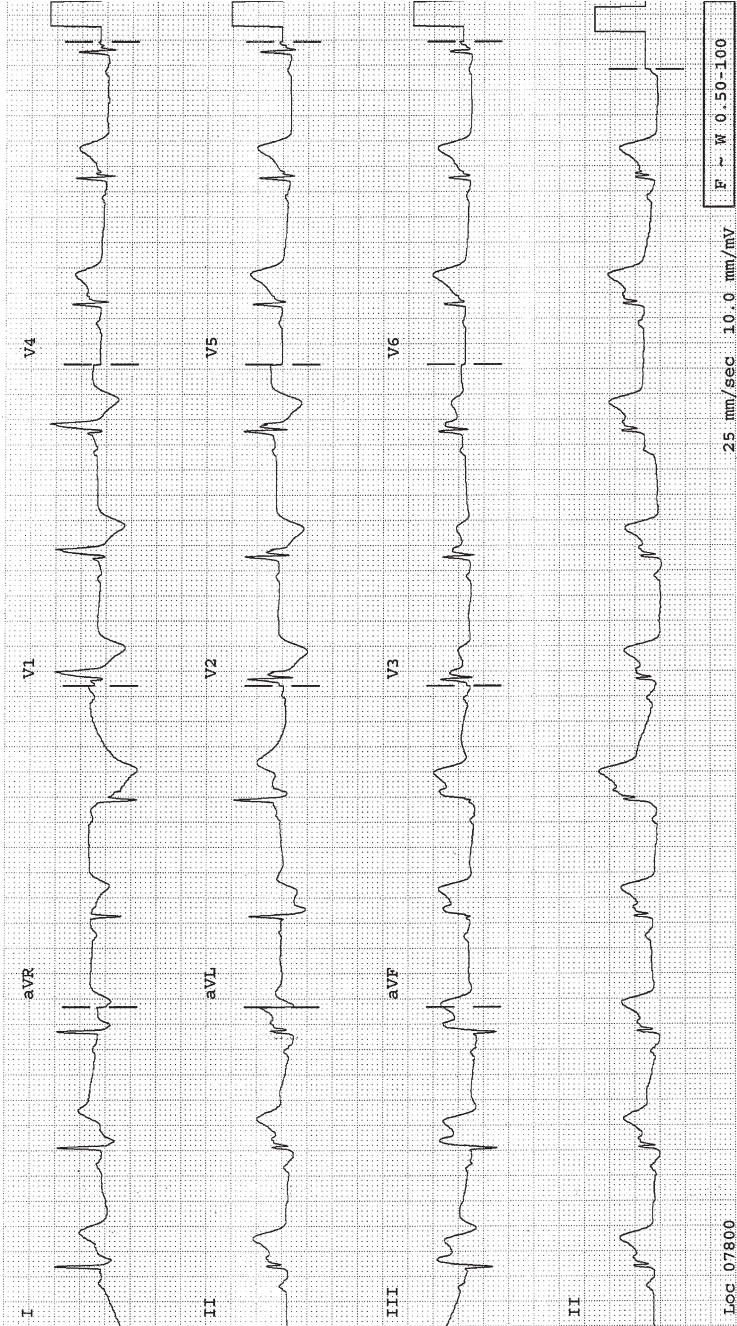


Fig. 12-35.

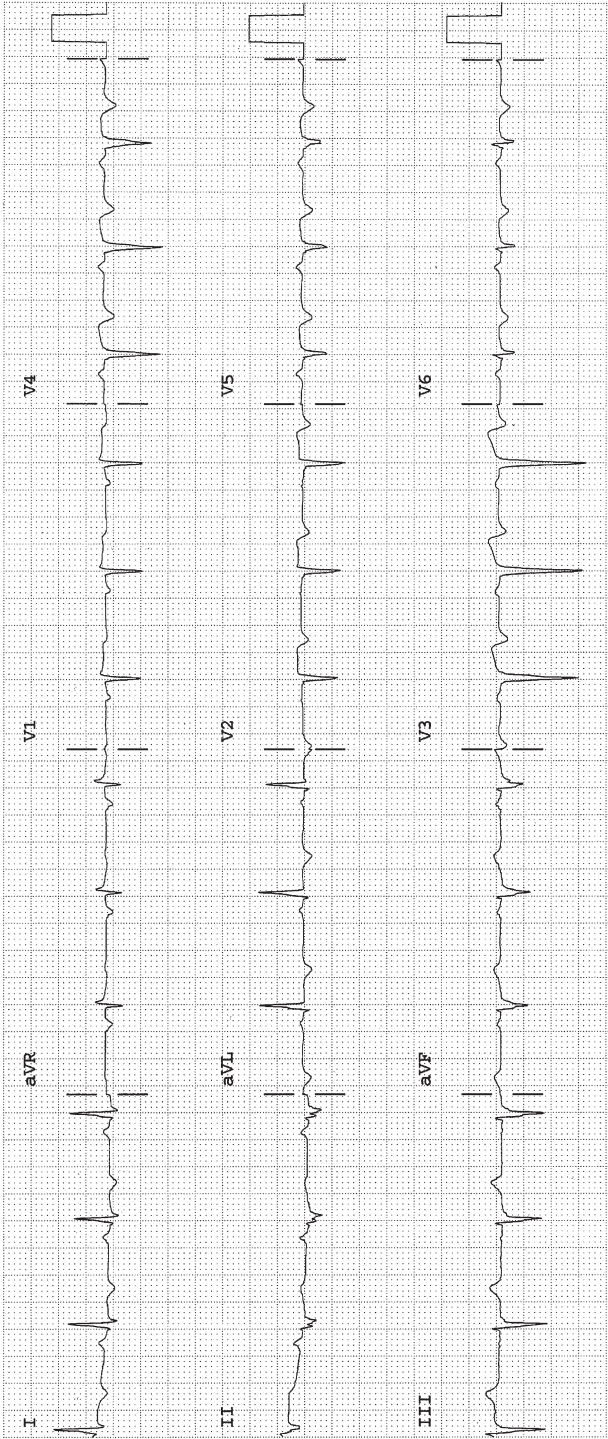


Fig. 12-36.

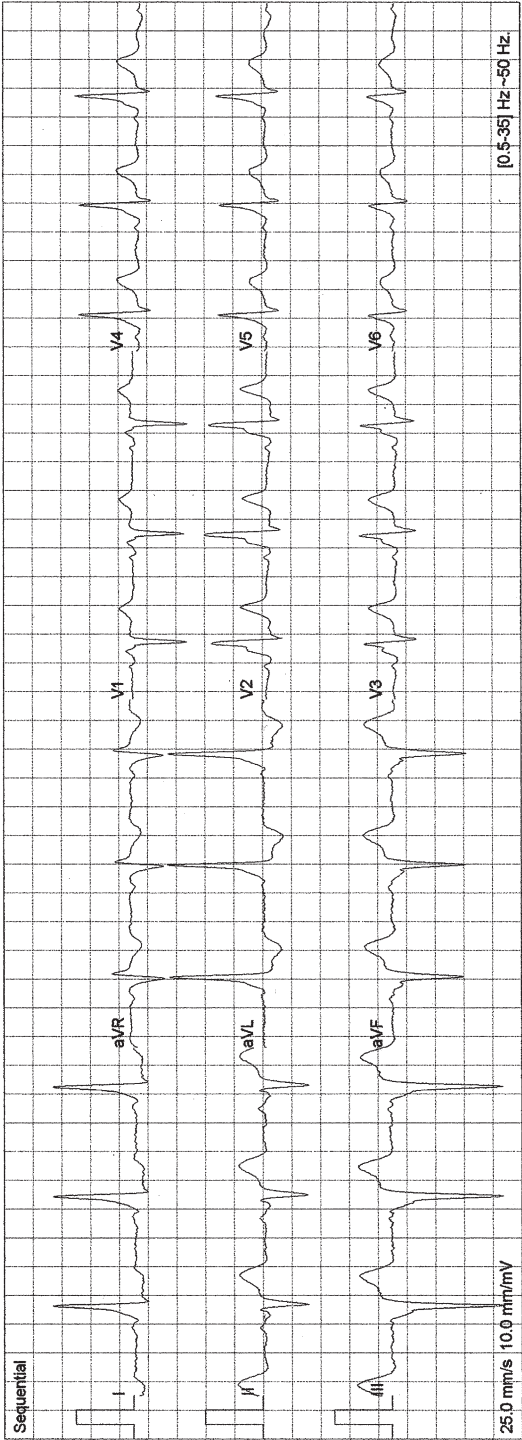


Fig. 12-37.

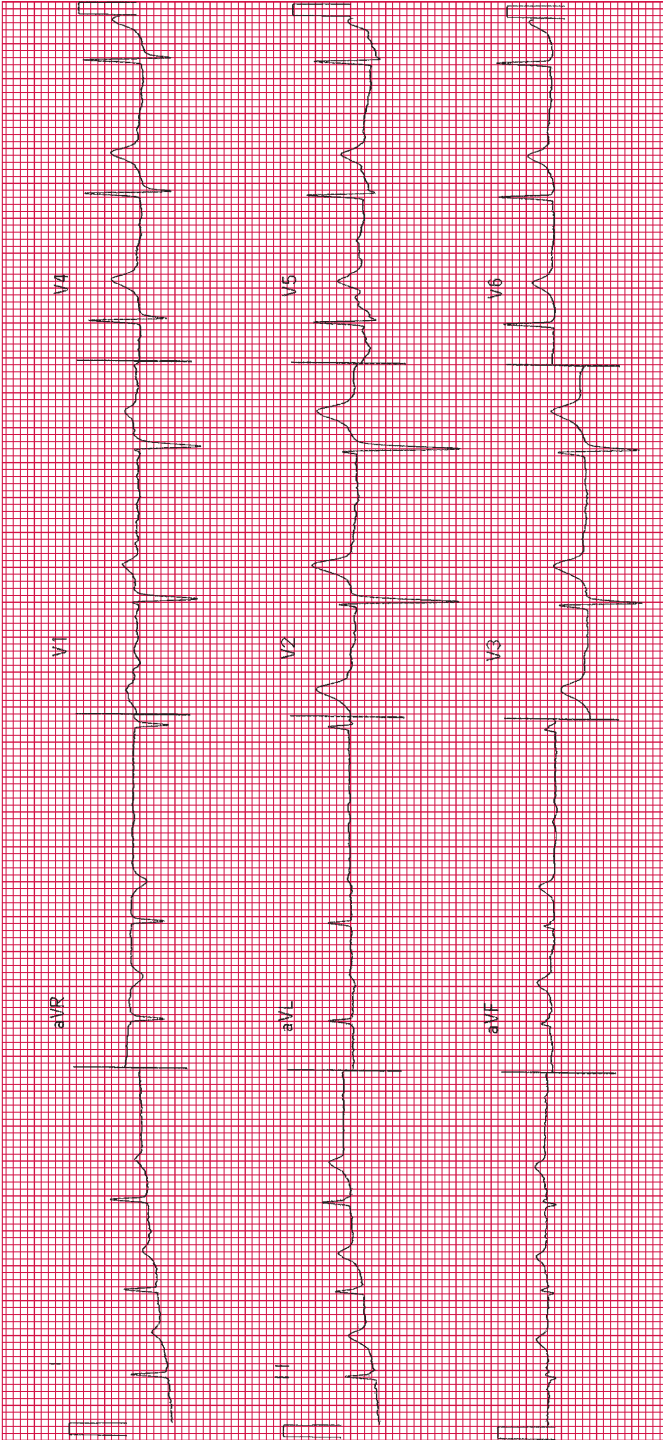


Fig. 12-38.

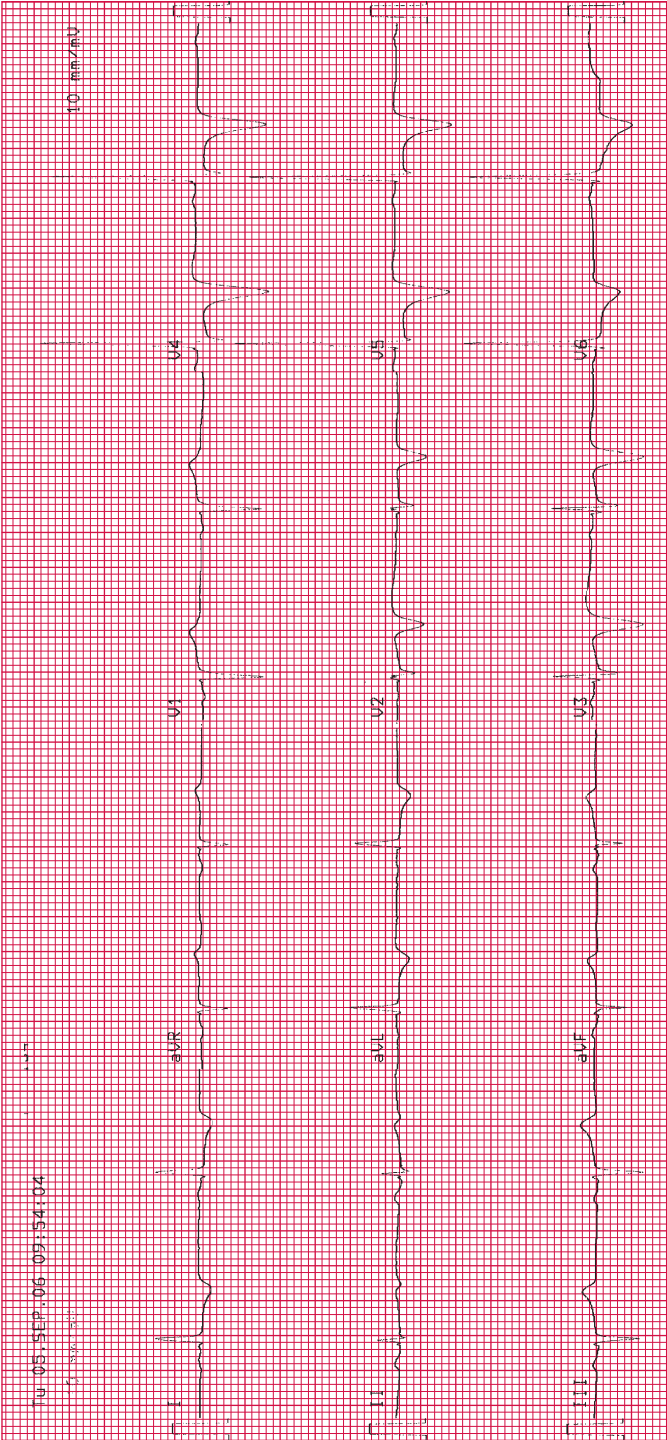

Fig. 12-39.

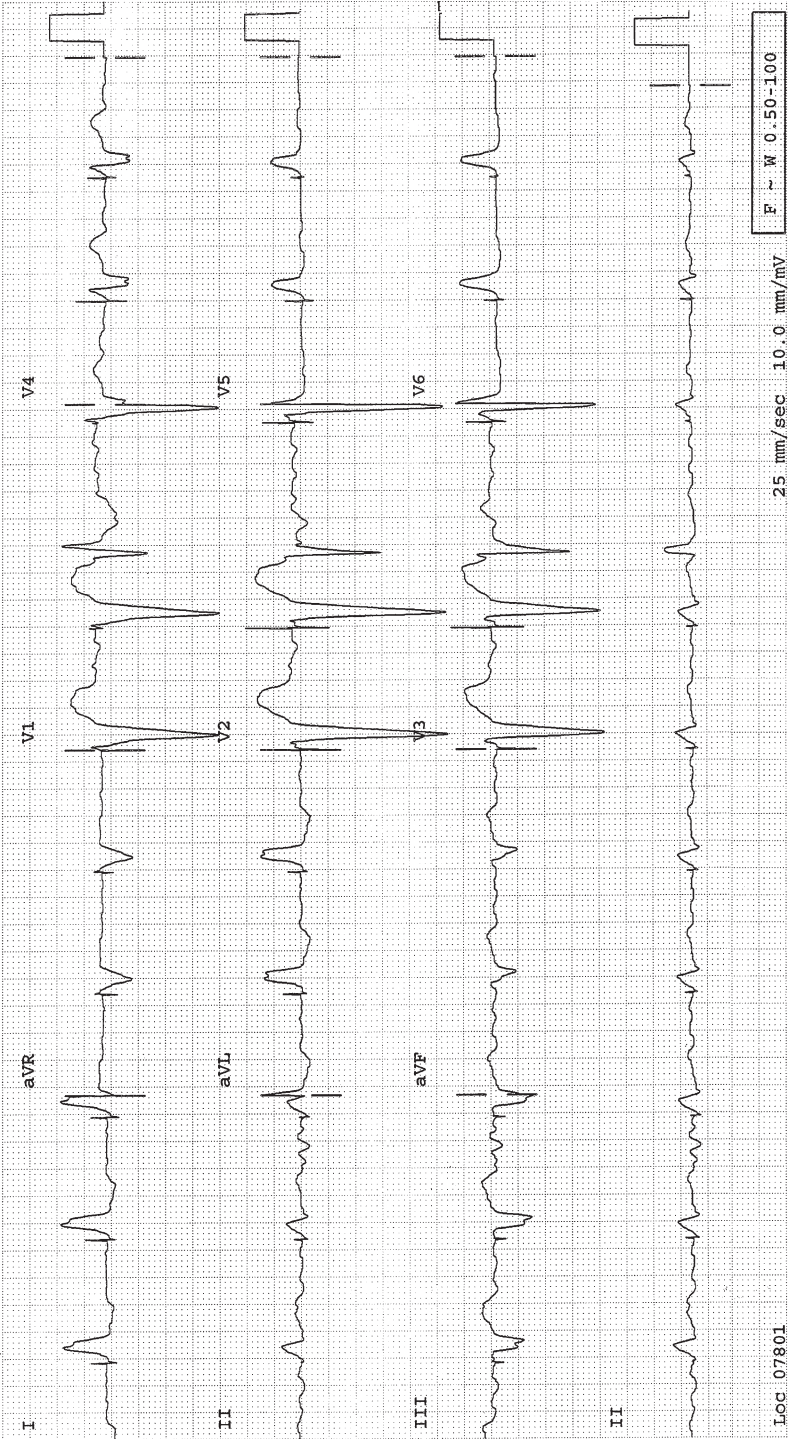


Fig. 12-40.

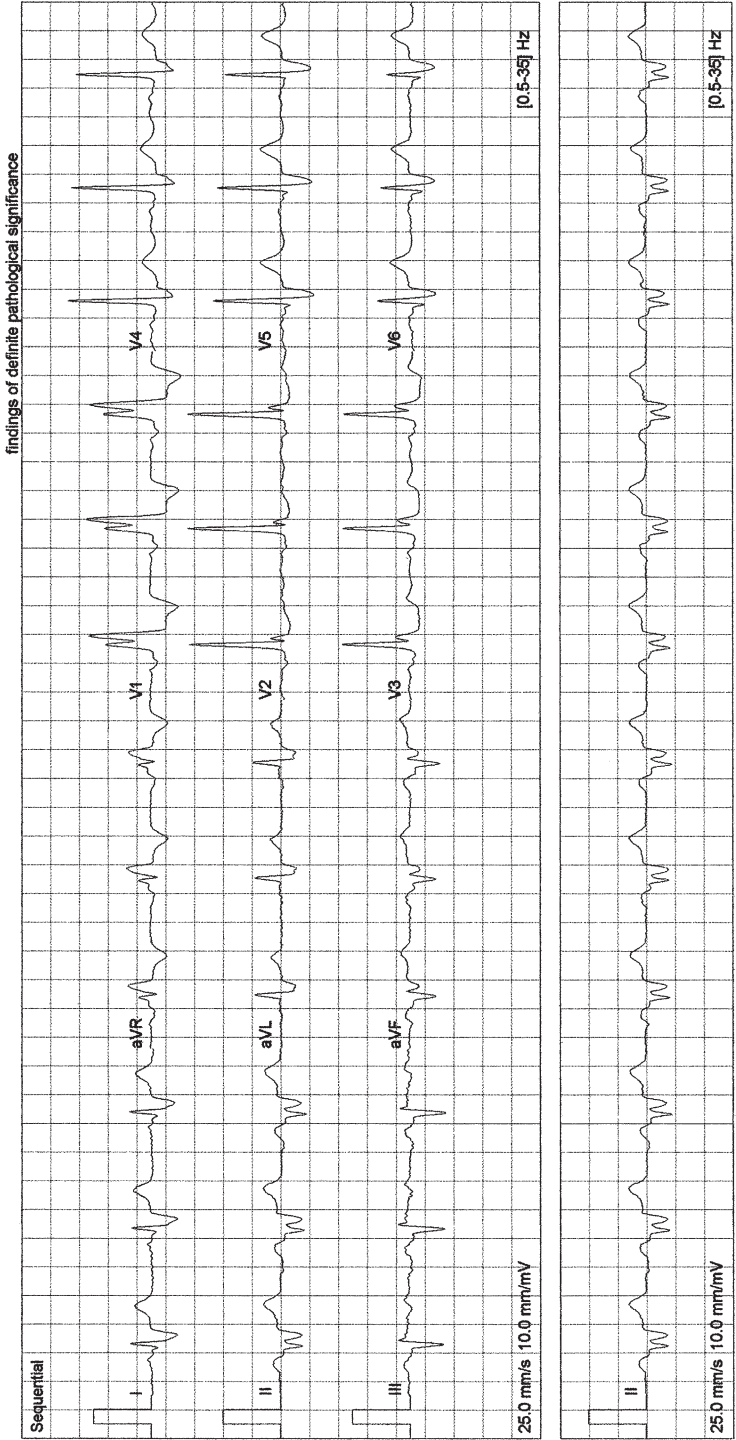


Fig. 12-41.

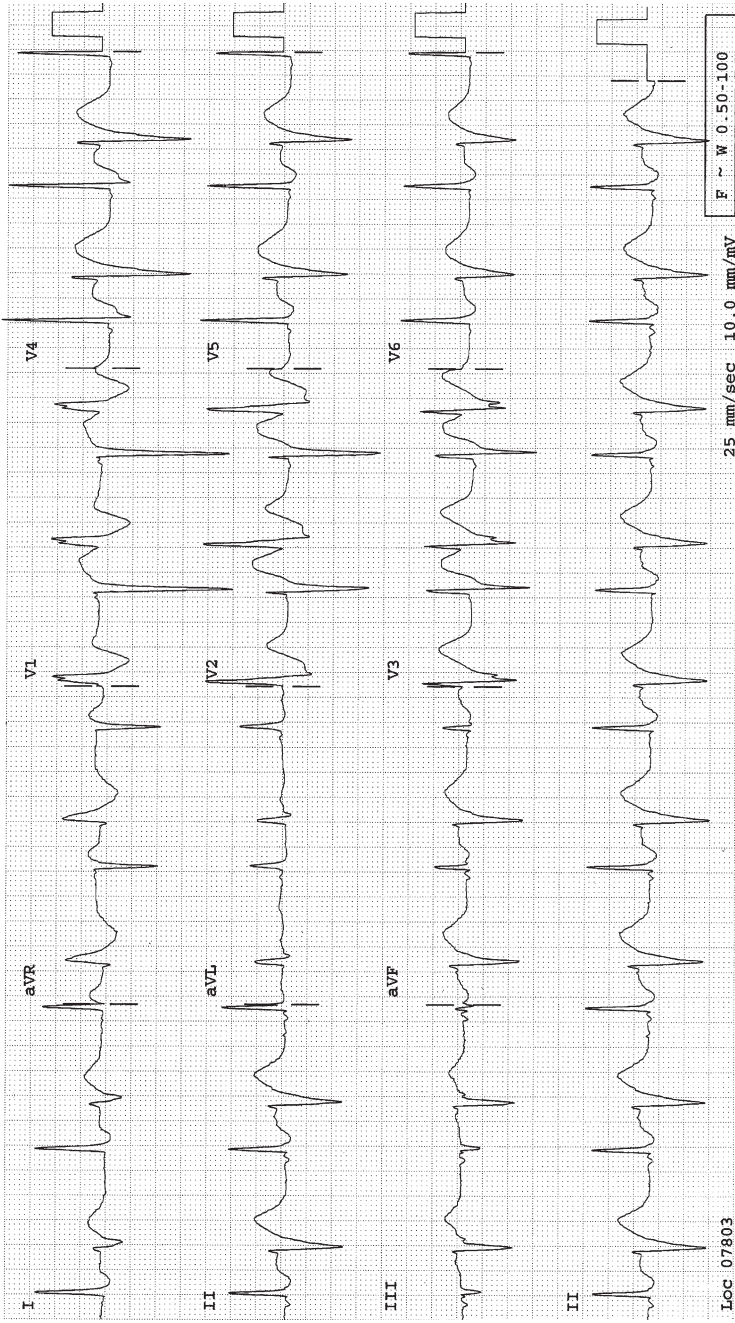


Fig. 12-44.

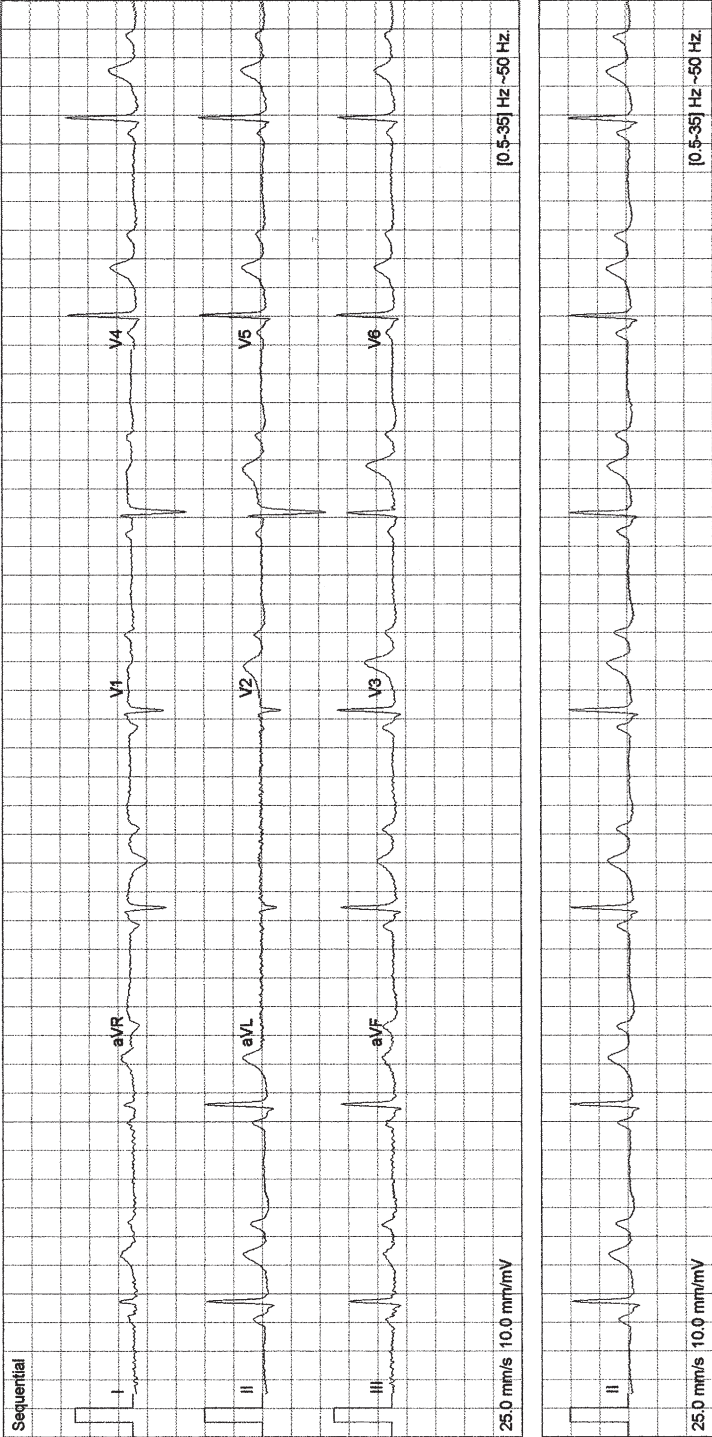


Fig. 12-45.

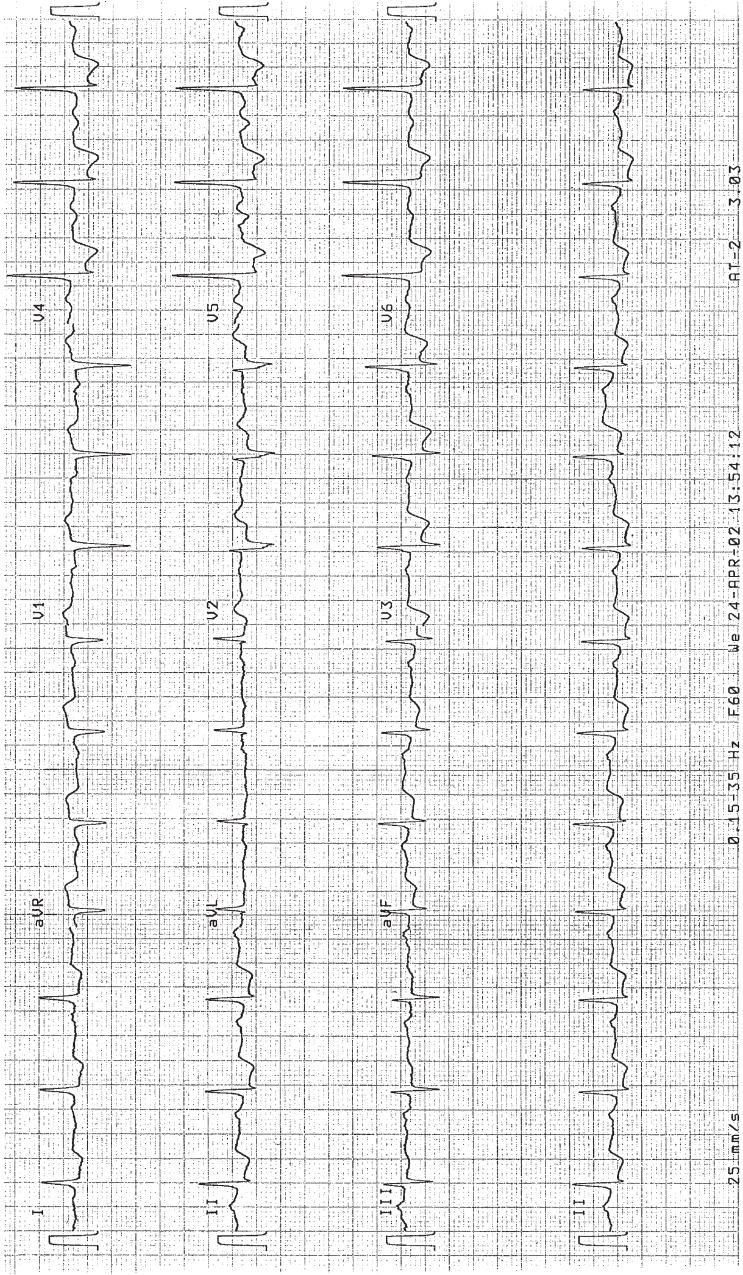


Fig. 12-46.

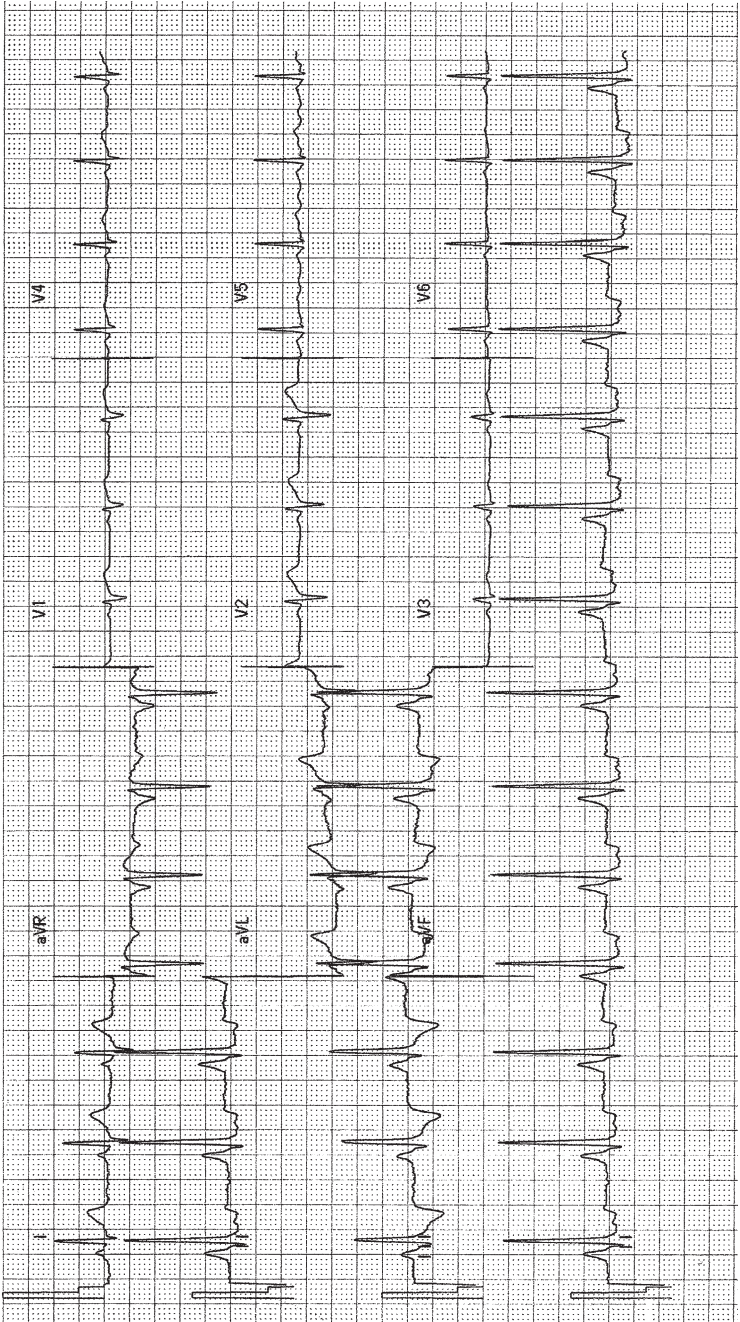


Fig. 12-47.

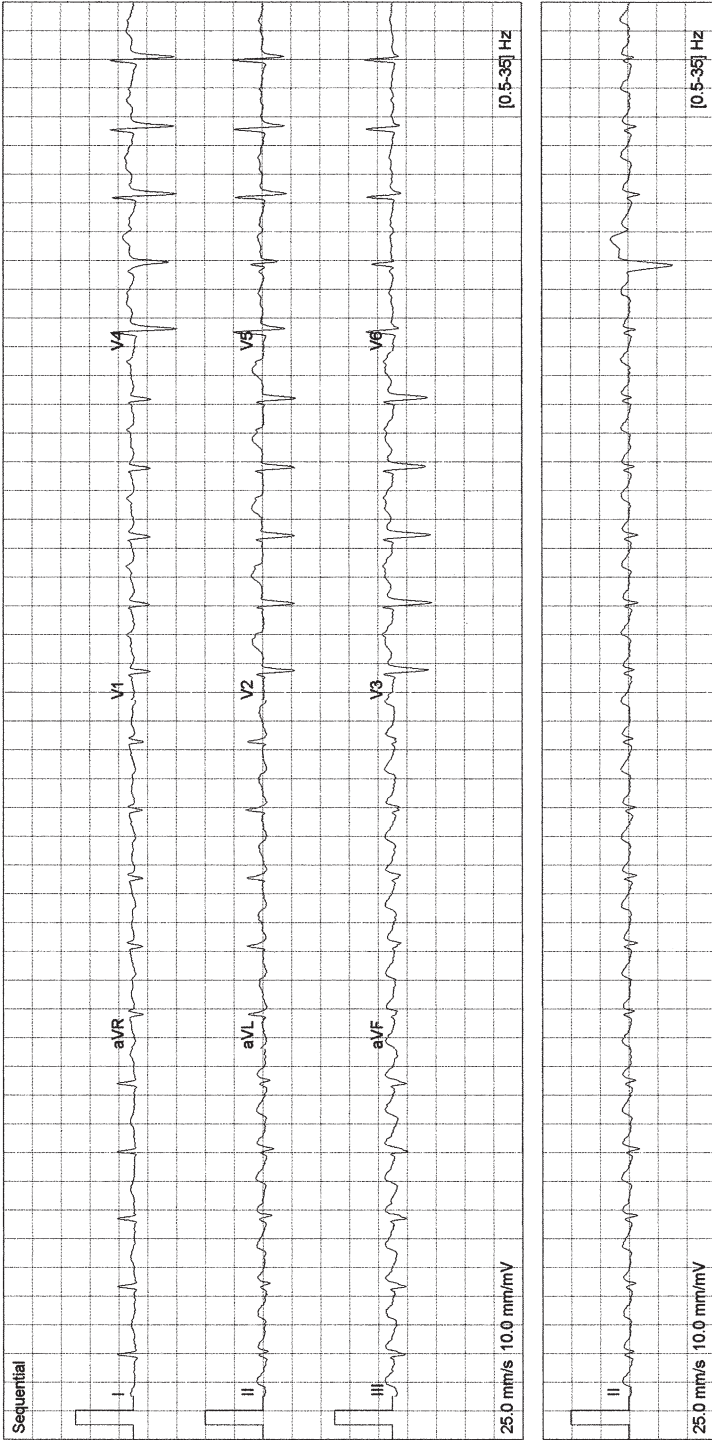


Fig. 12-48.

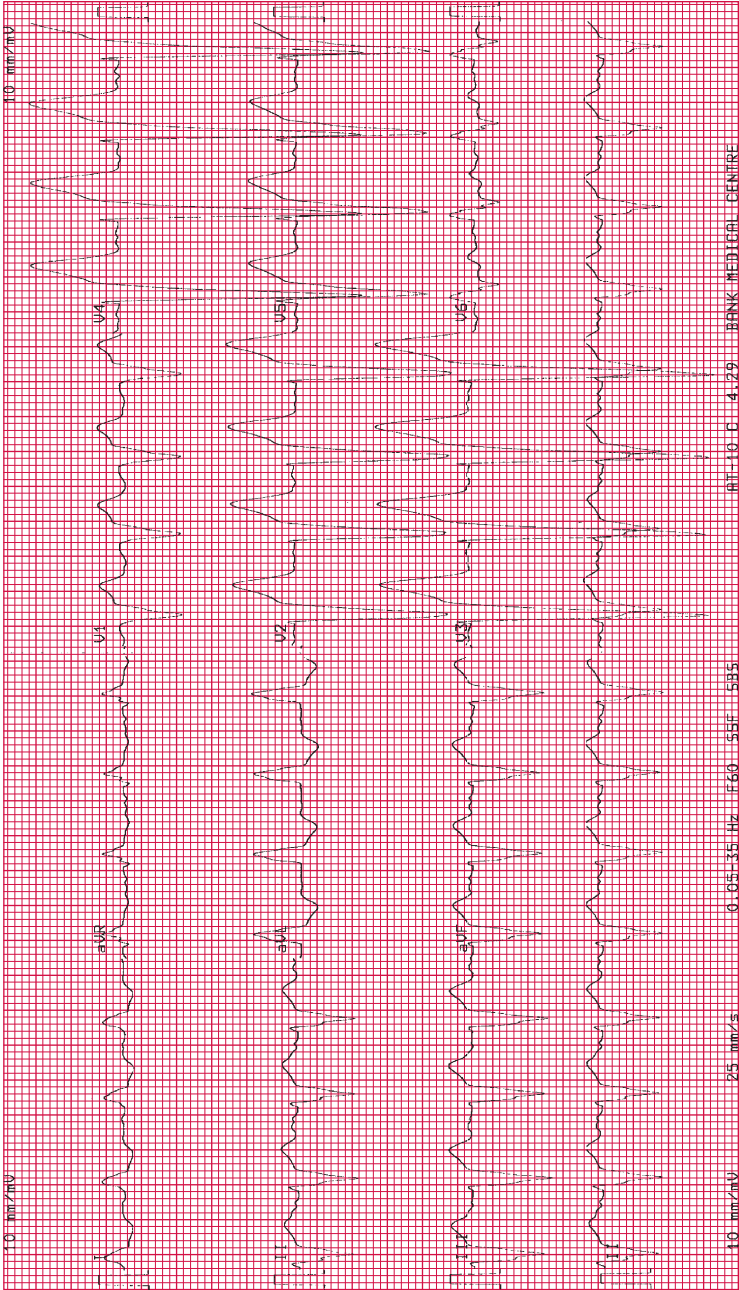


Fig. 12-49.

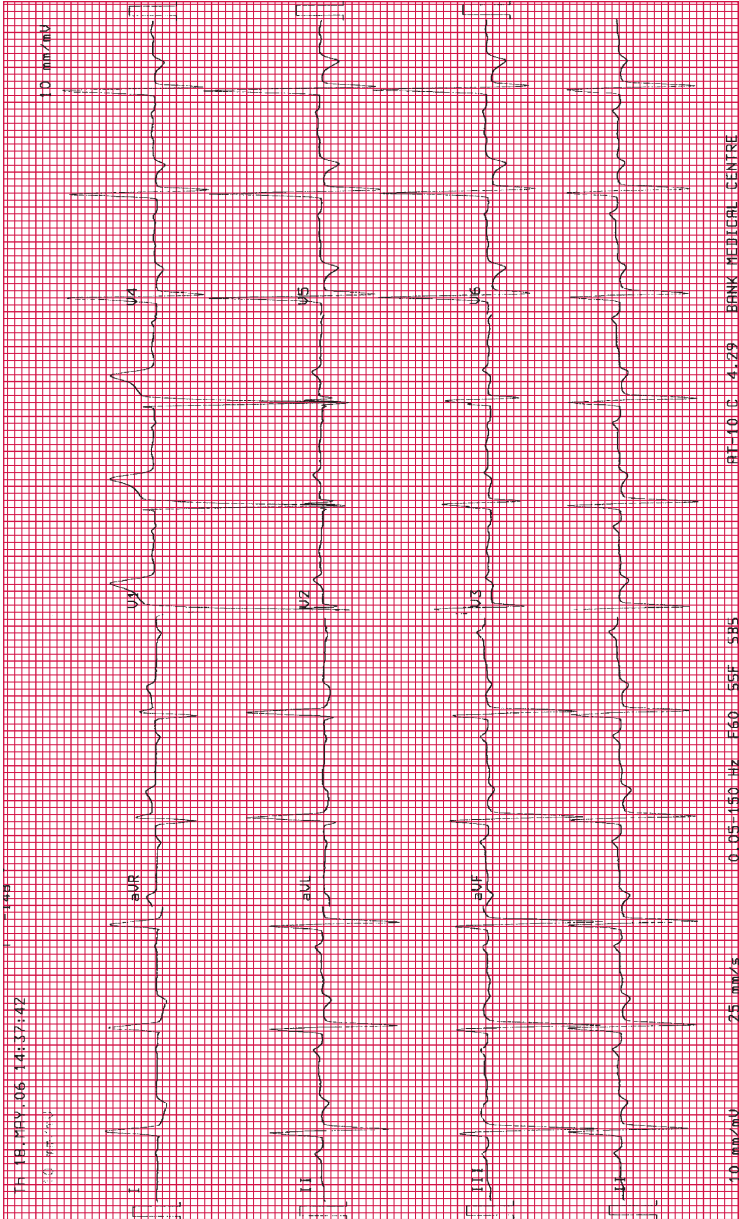


Fig. 12-50.

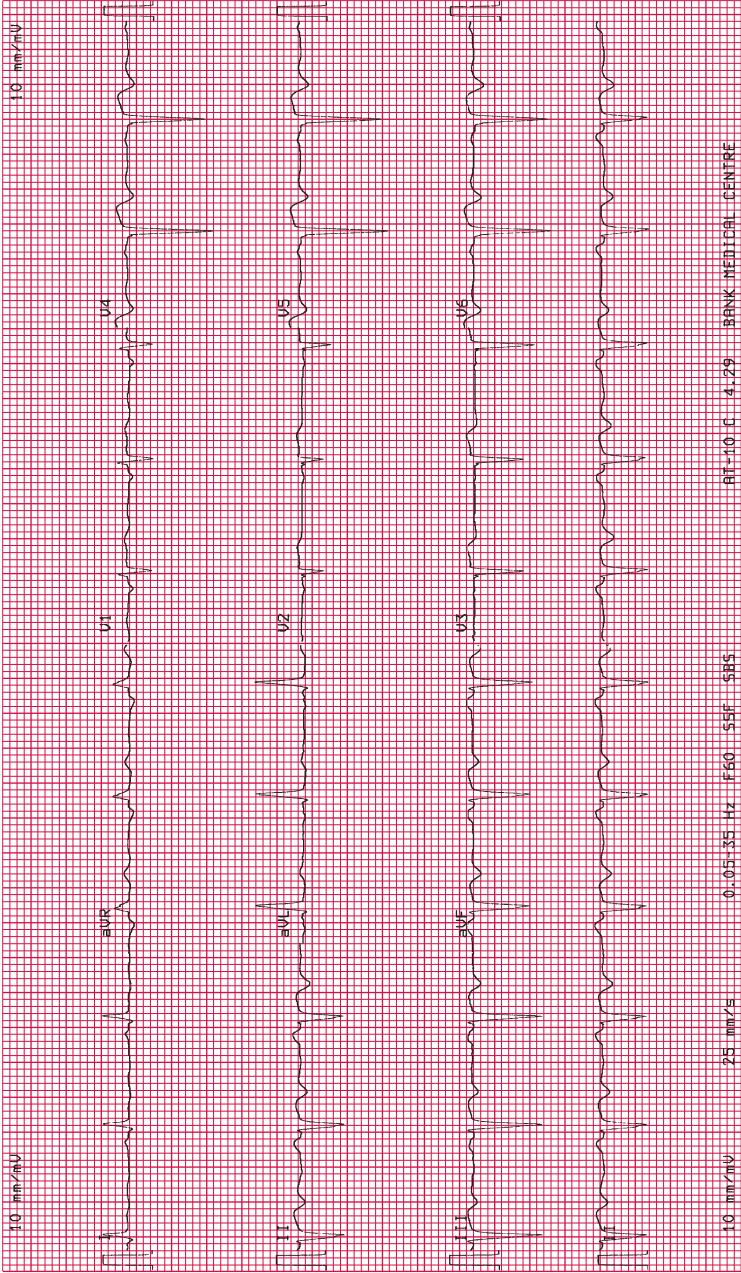


Fig. 12-51.

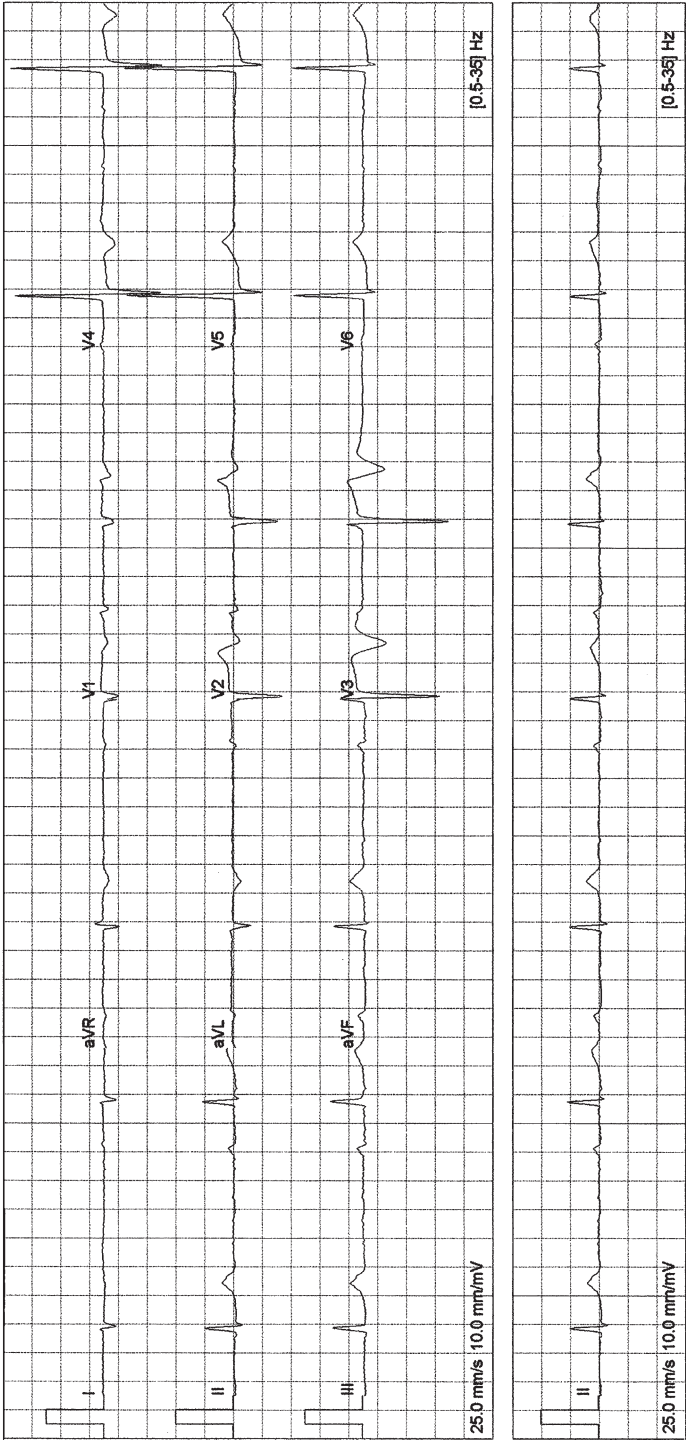


Fig. 12-52.

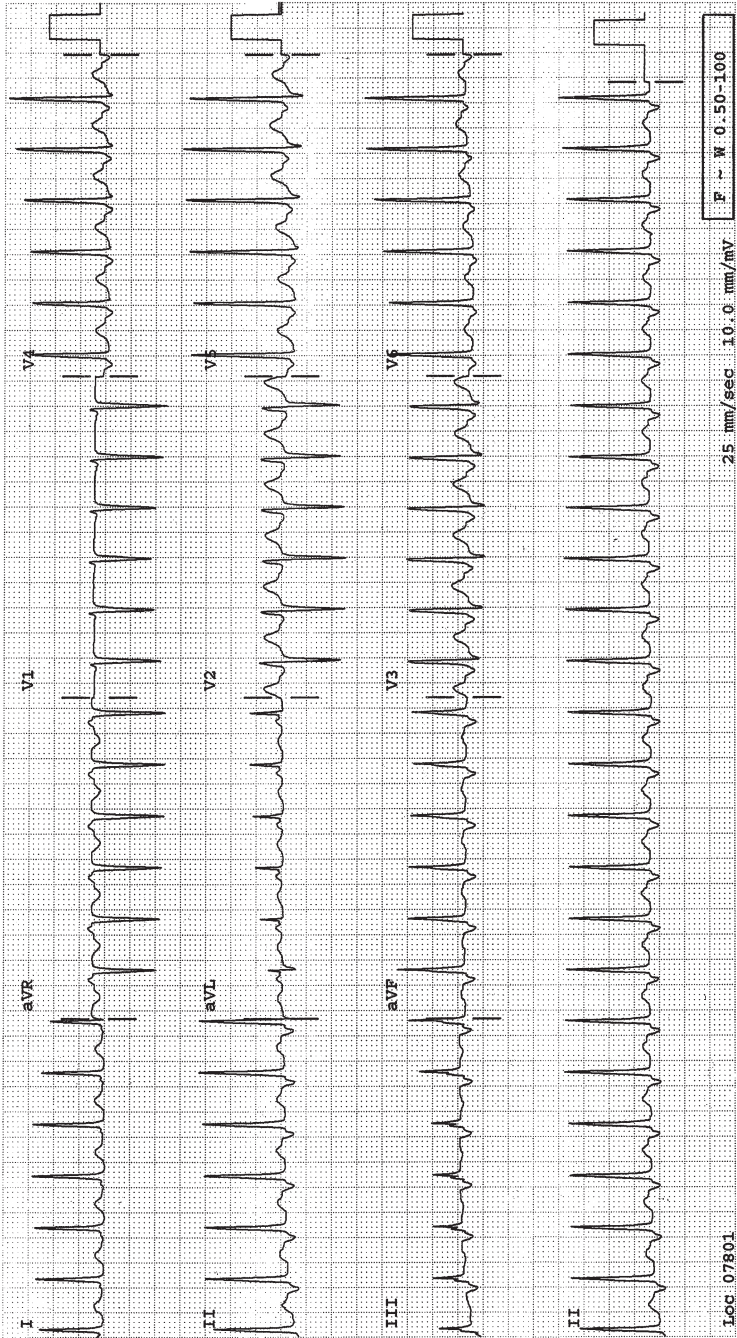


Fig. 12-53.

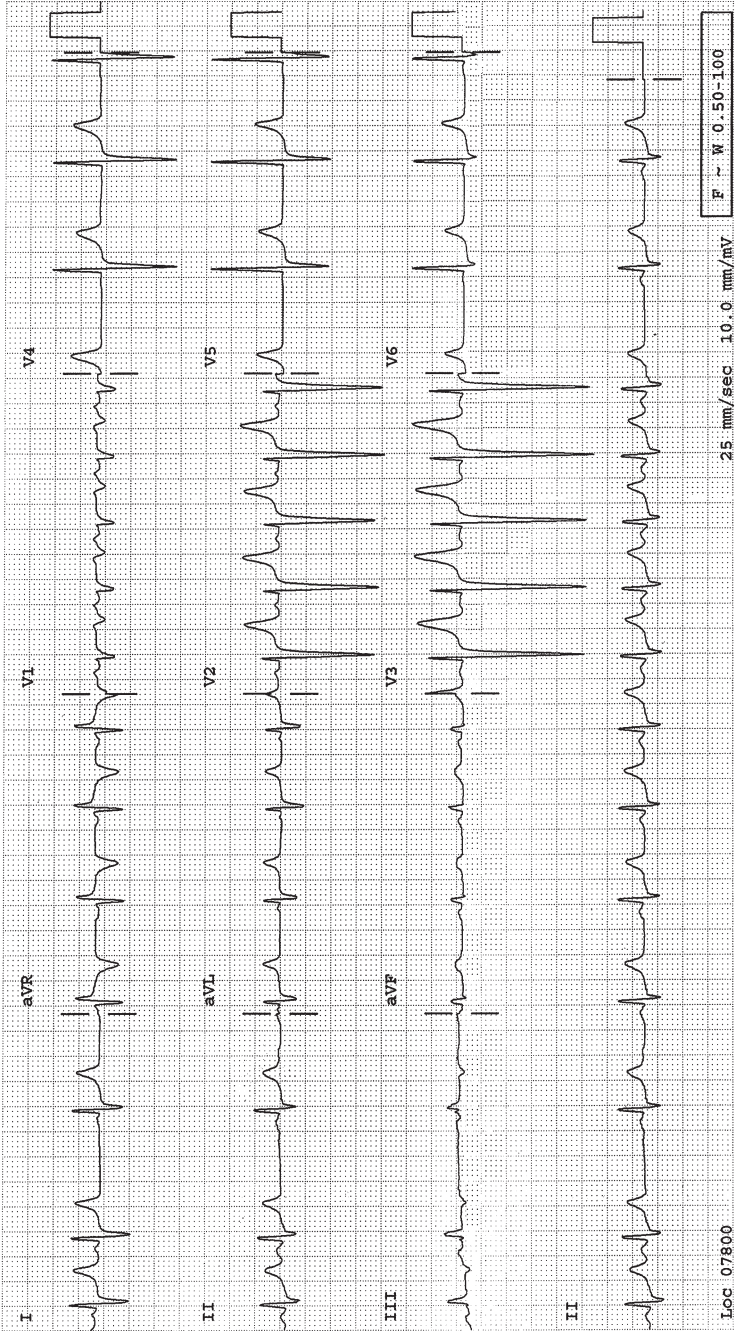


Fig. 12-54.

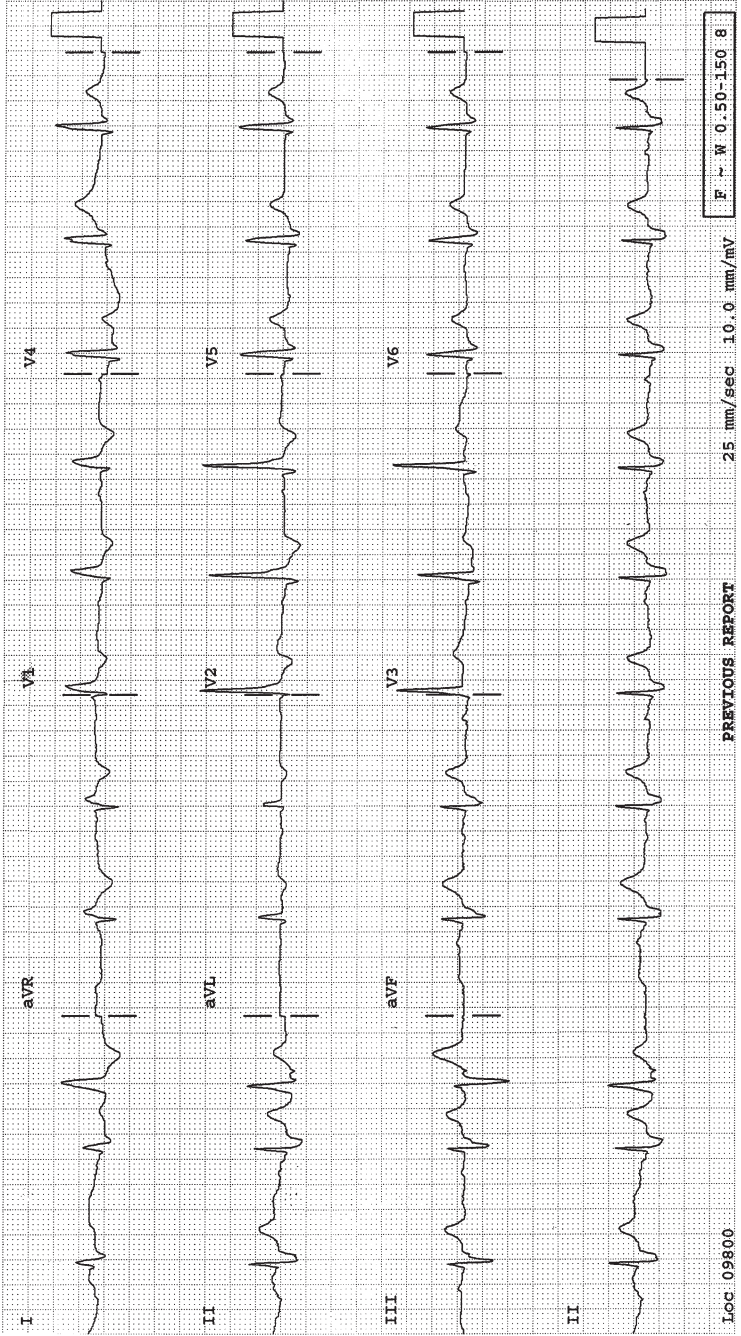


Fig. 12-55.

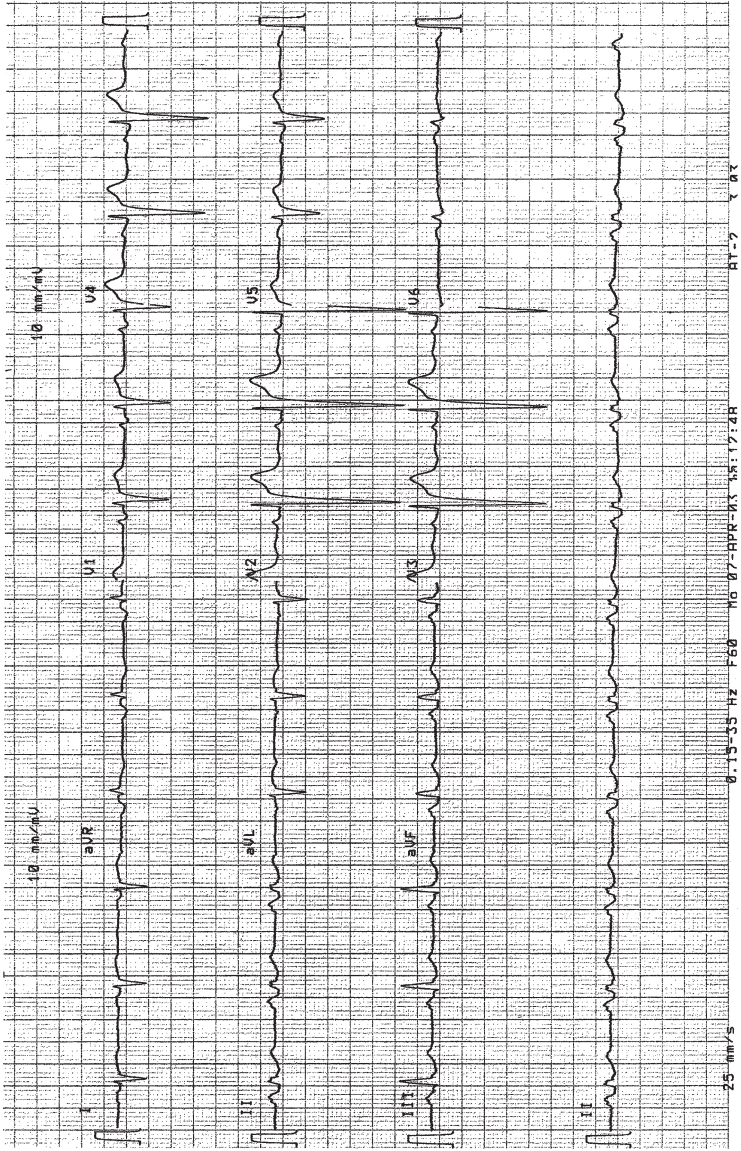


Fig. 12-56.

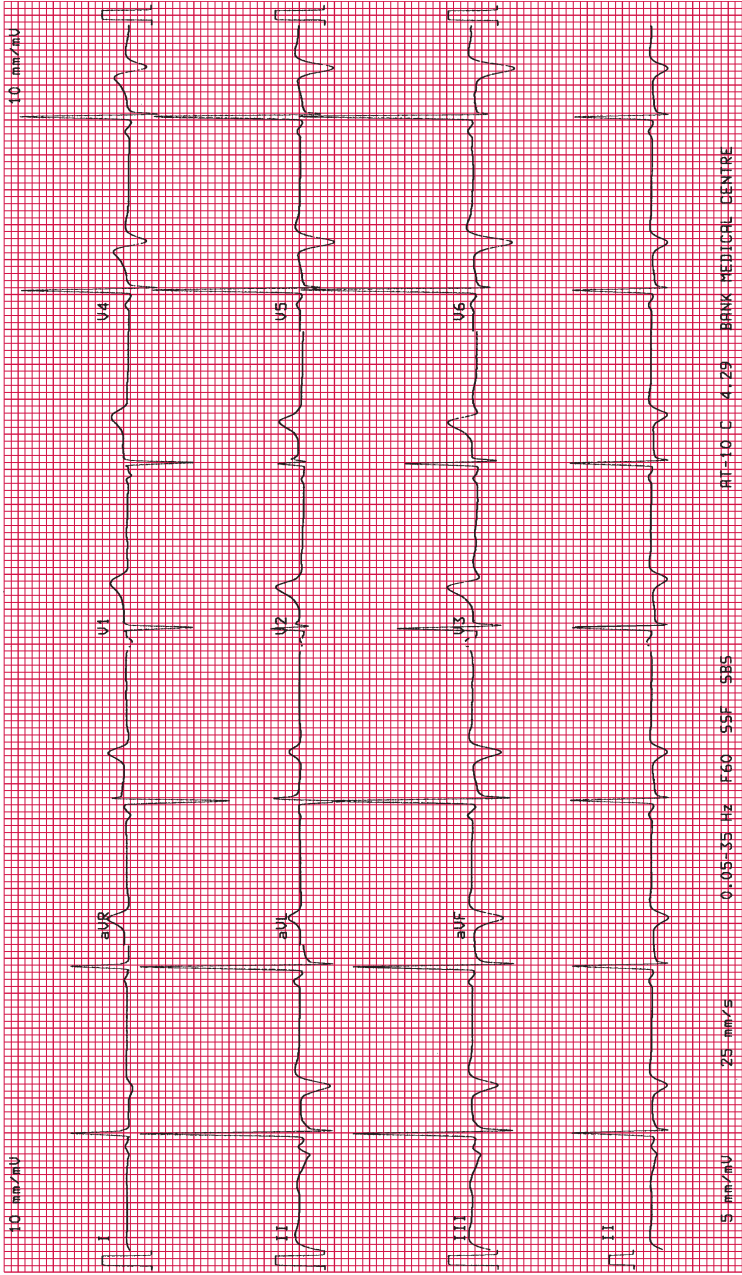


Fig. 12-57.

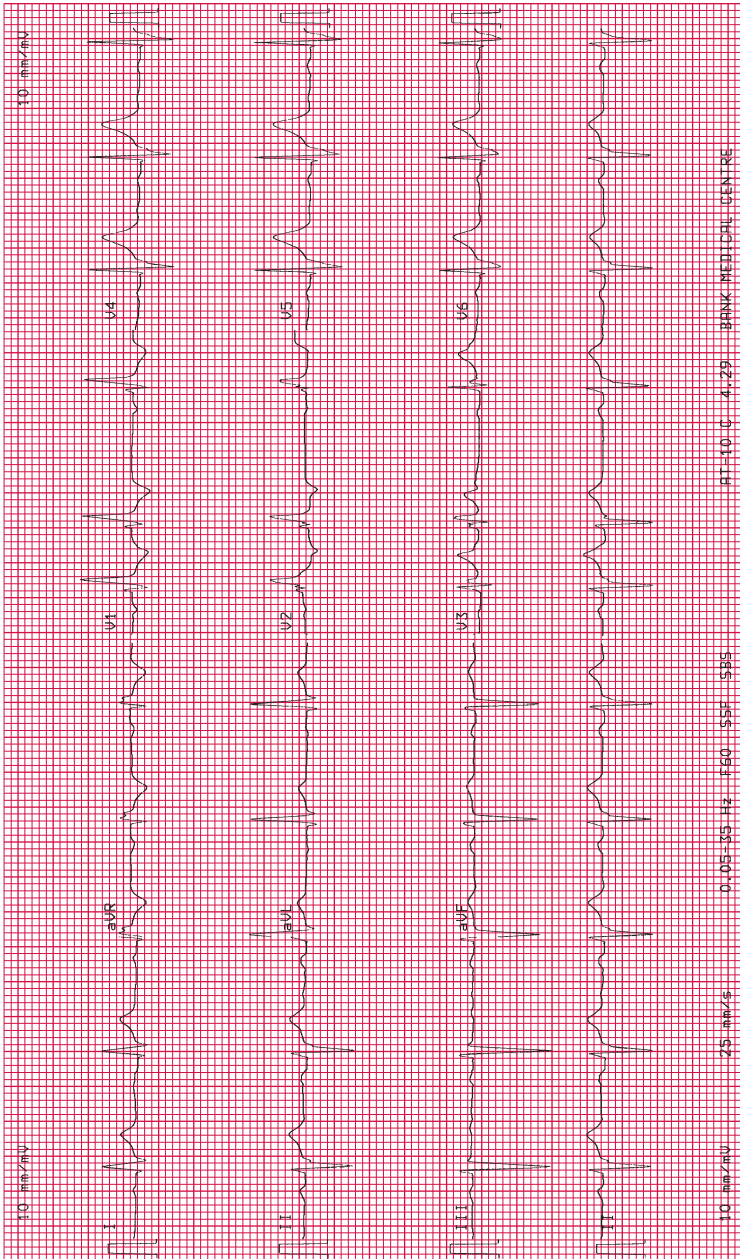


Fig. 12-58.

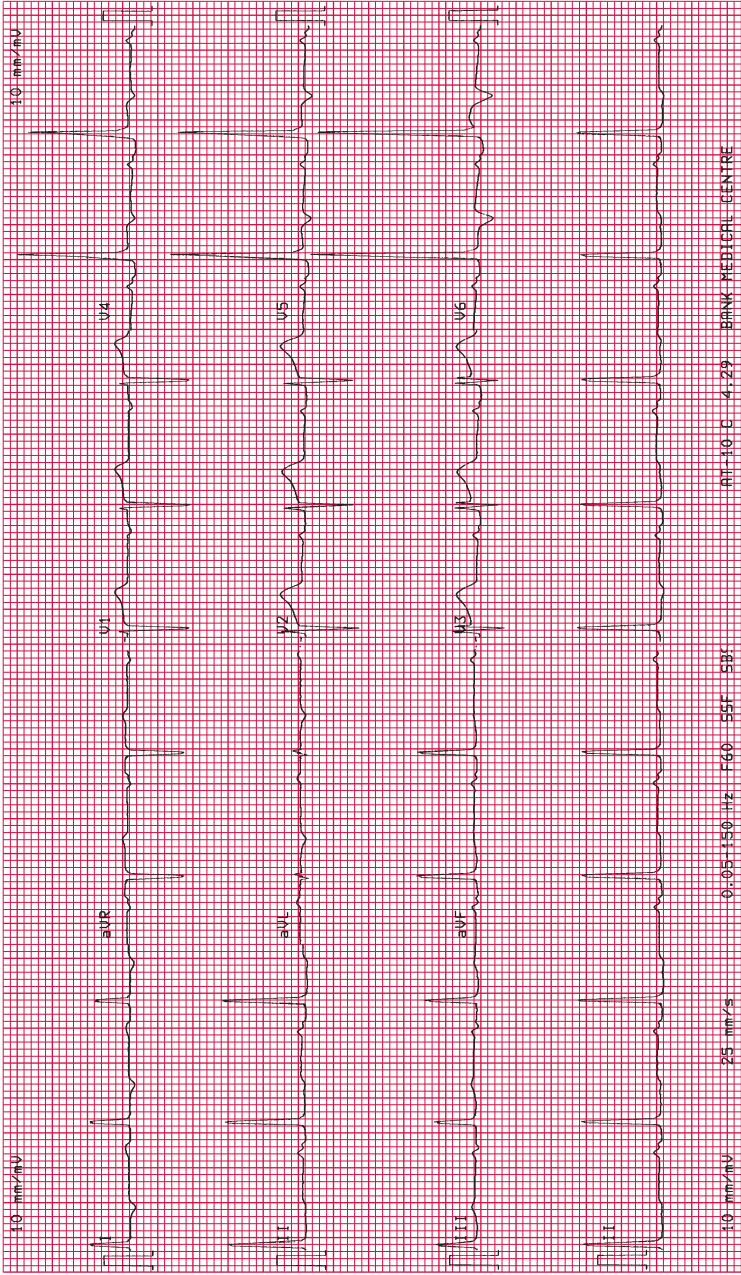


Fig. 12-59.

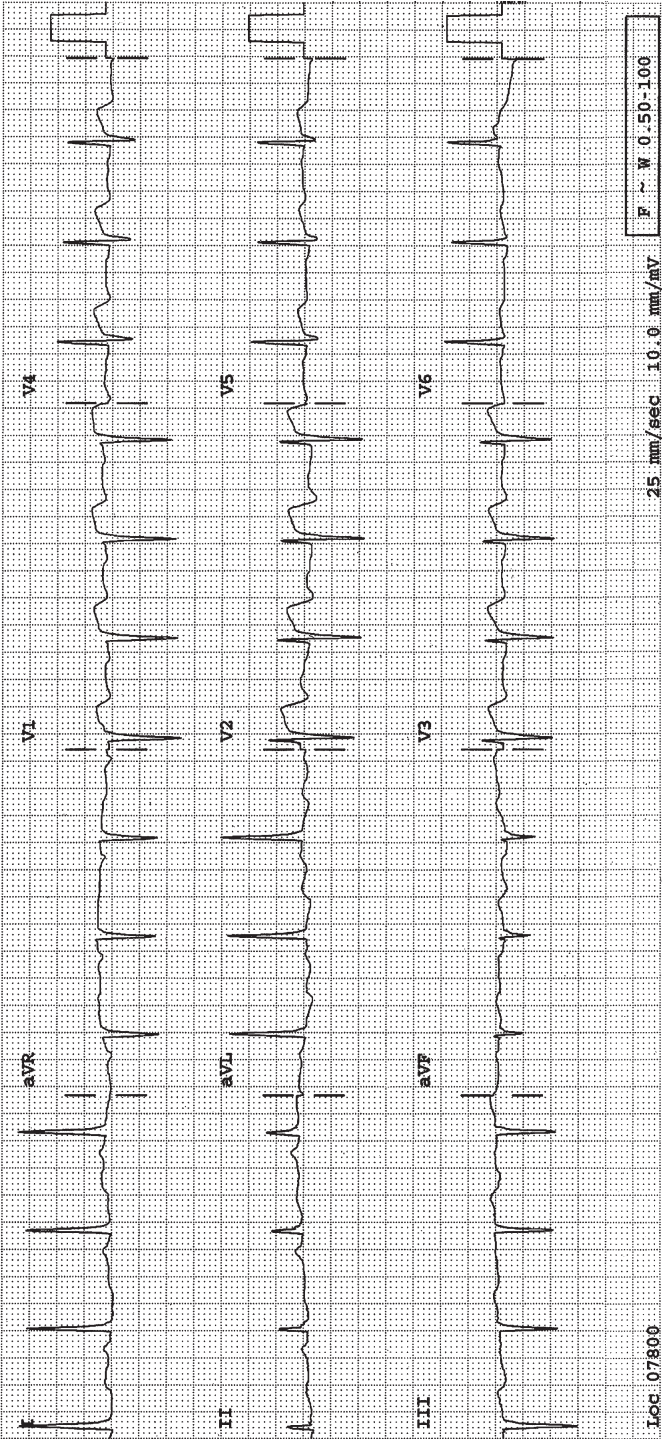


Fig. 12-60.

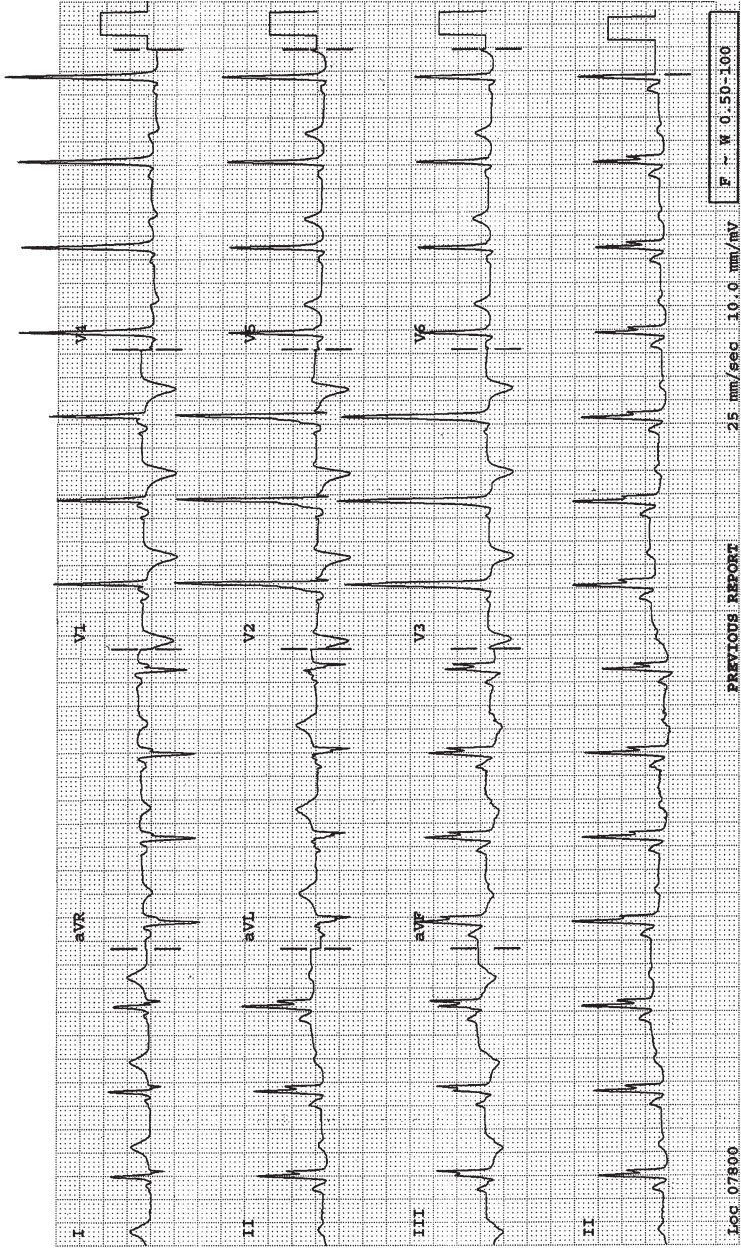


Fig. 12-61.

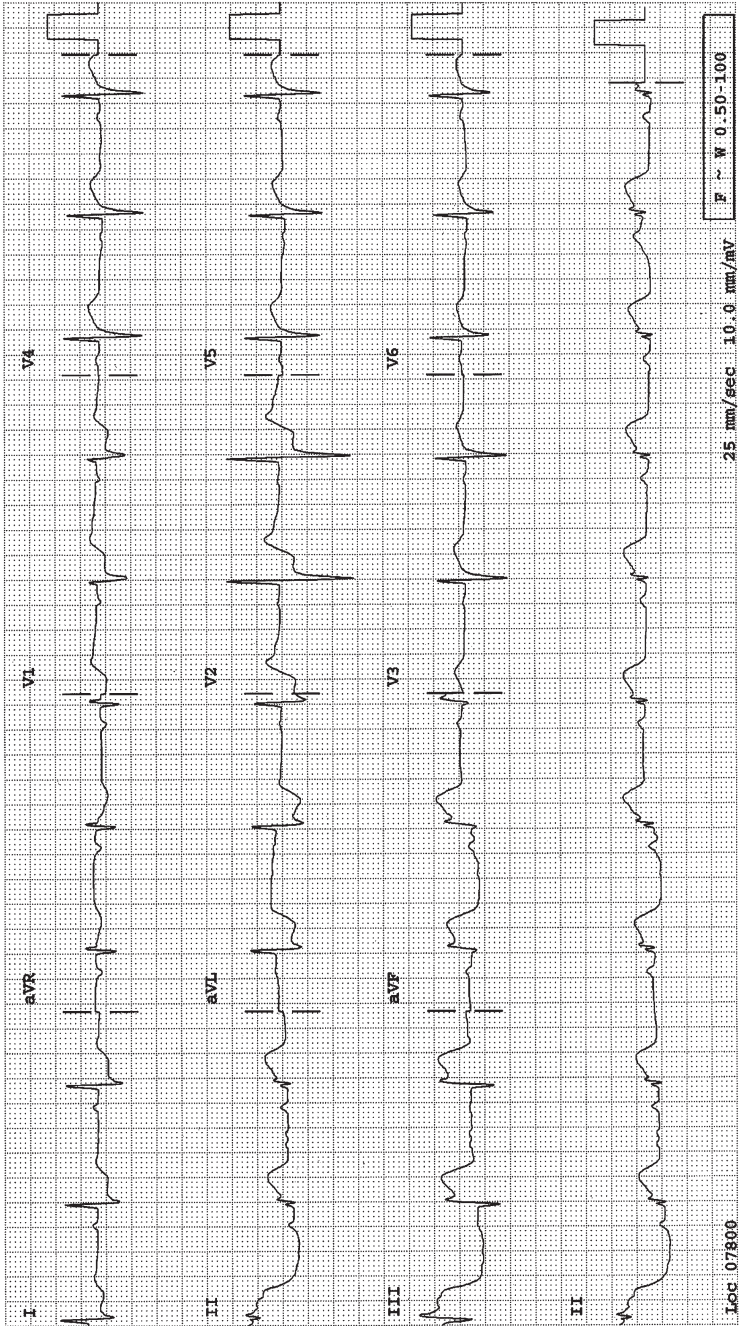


Fig. 12-62.

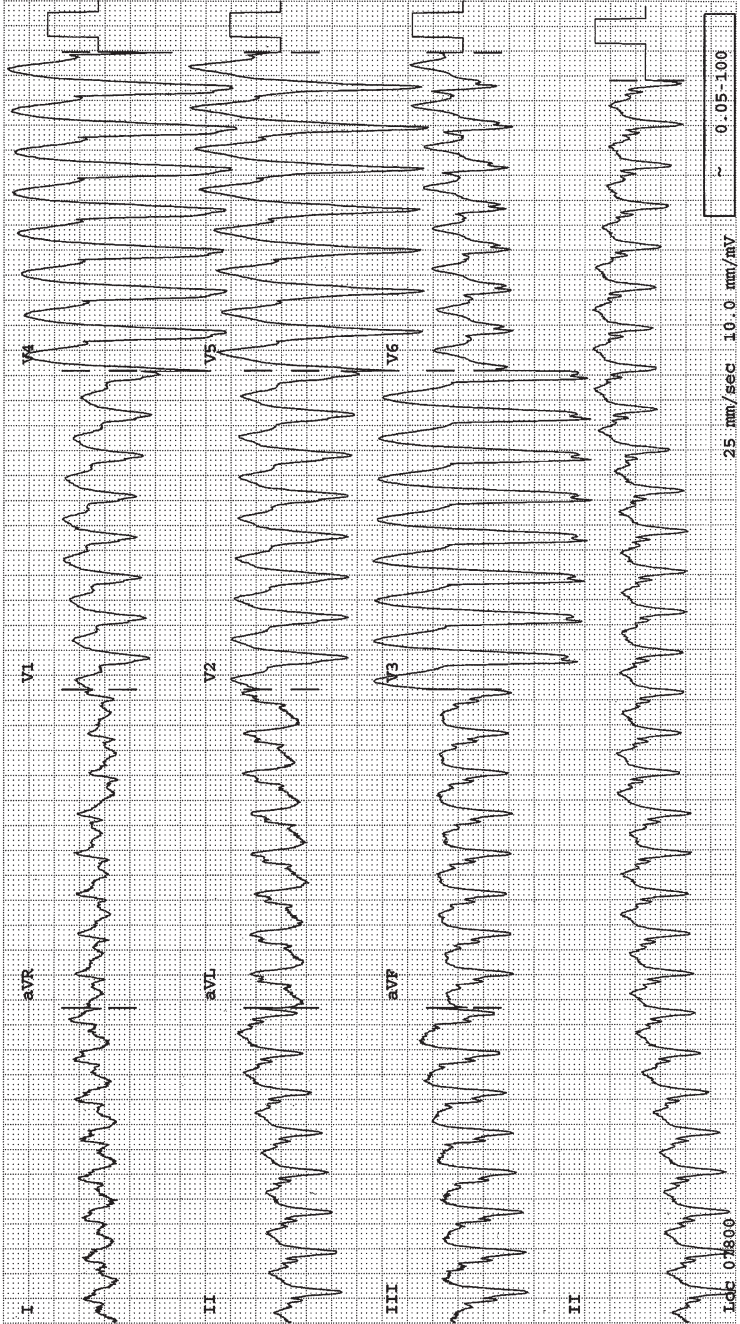


Fig. 12-63.

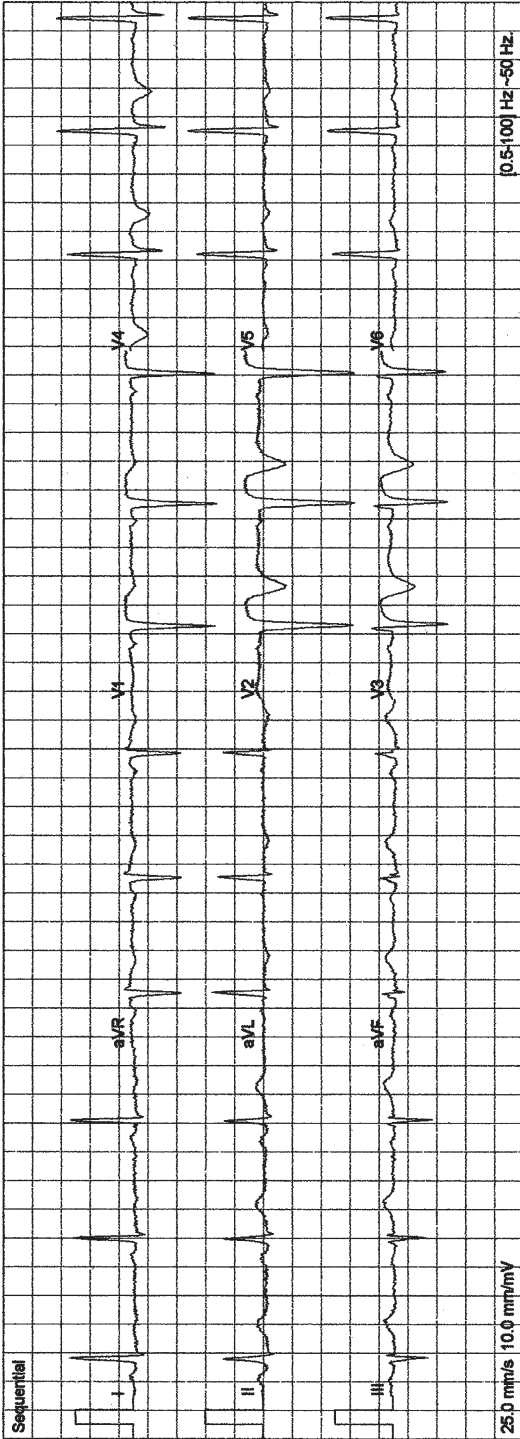


Fig. 12-64.

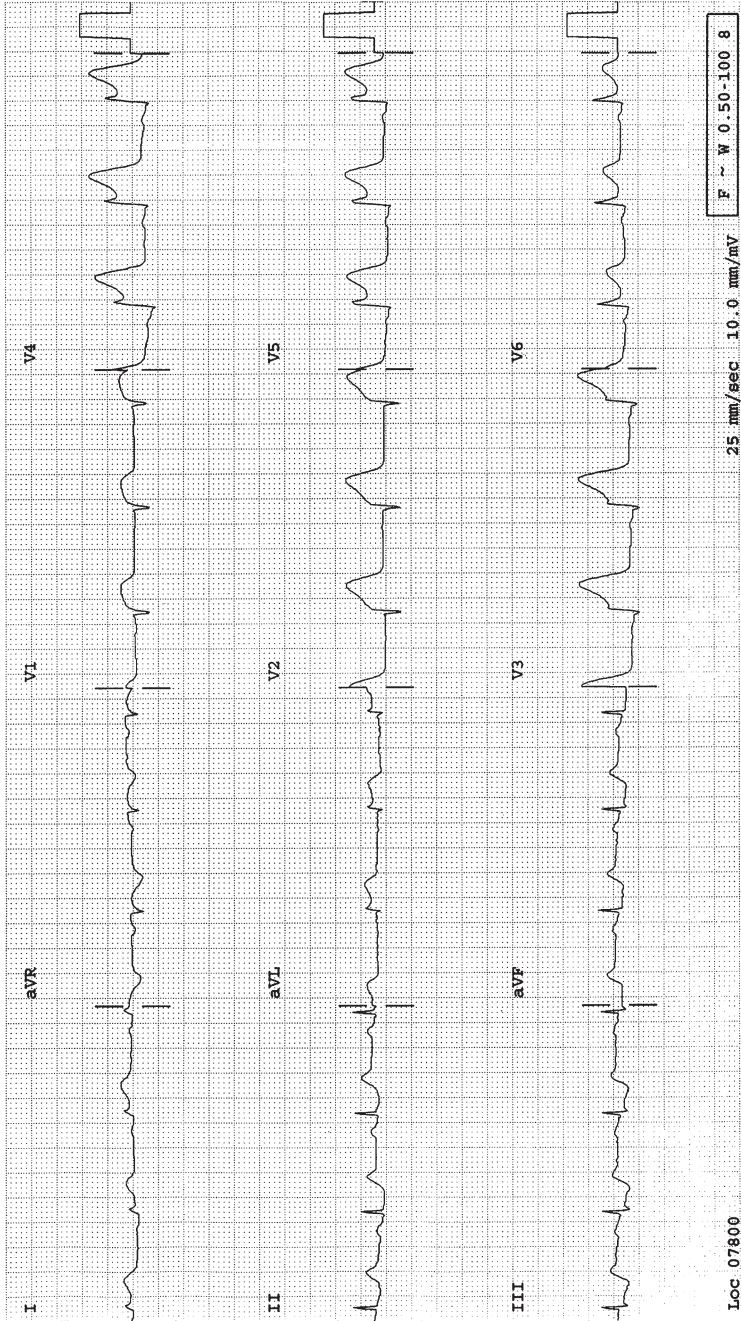


Fig. 12-65.

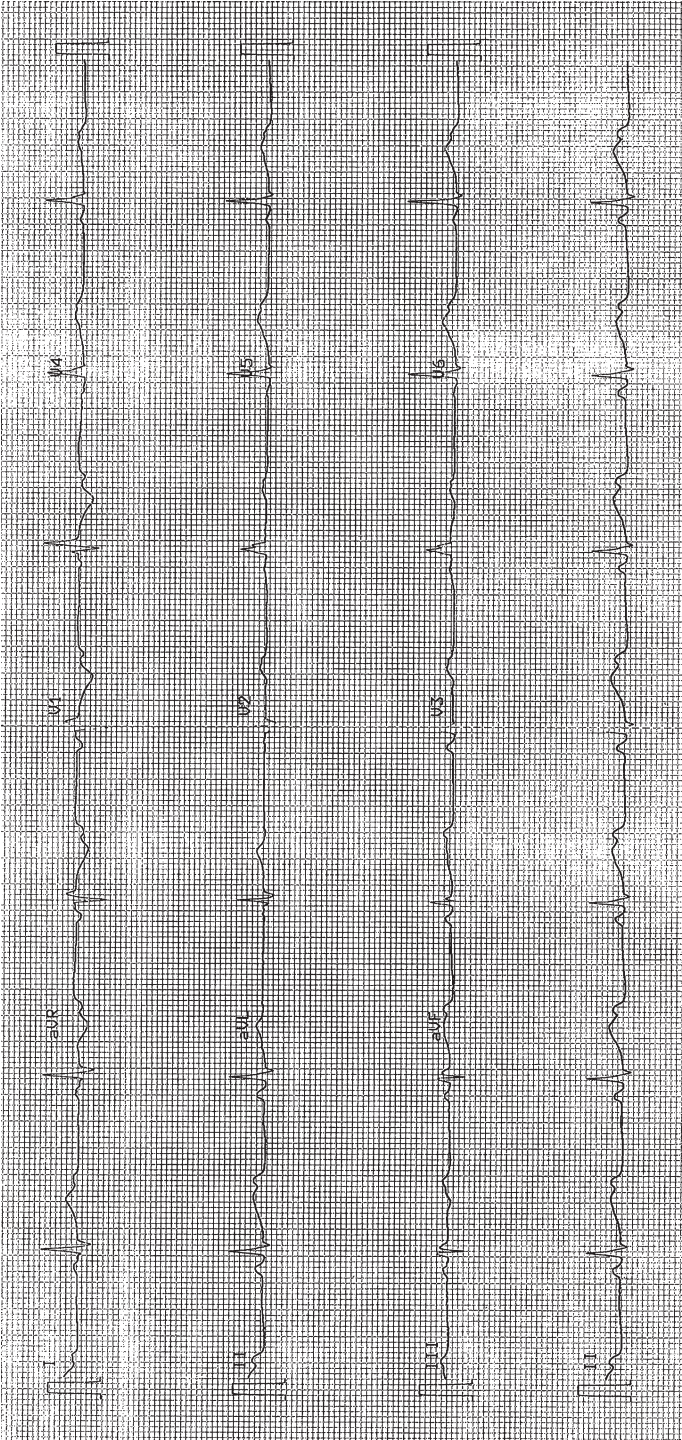


Fig. 12-66.

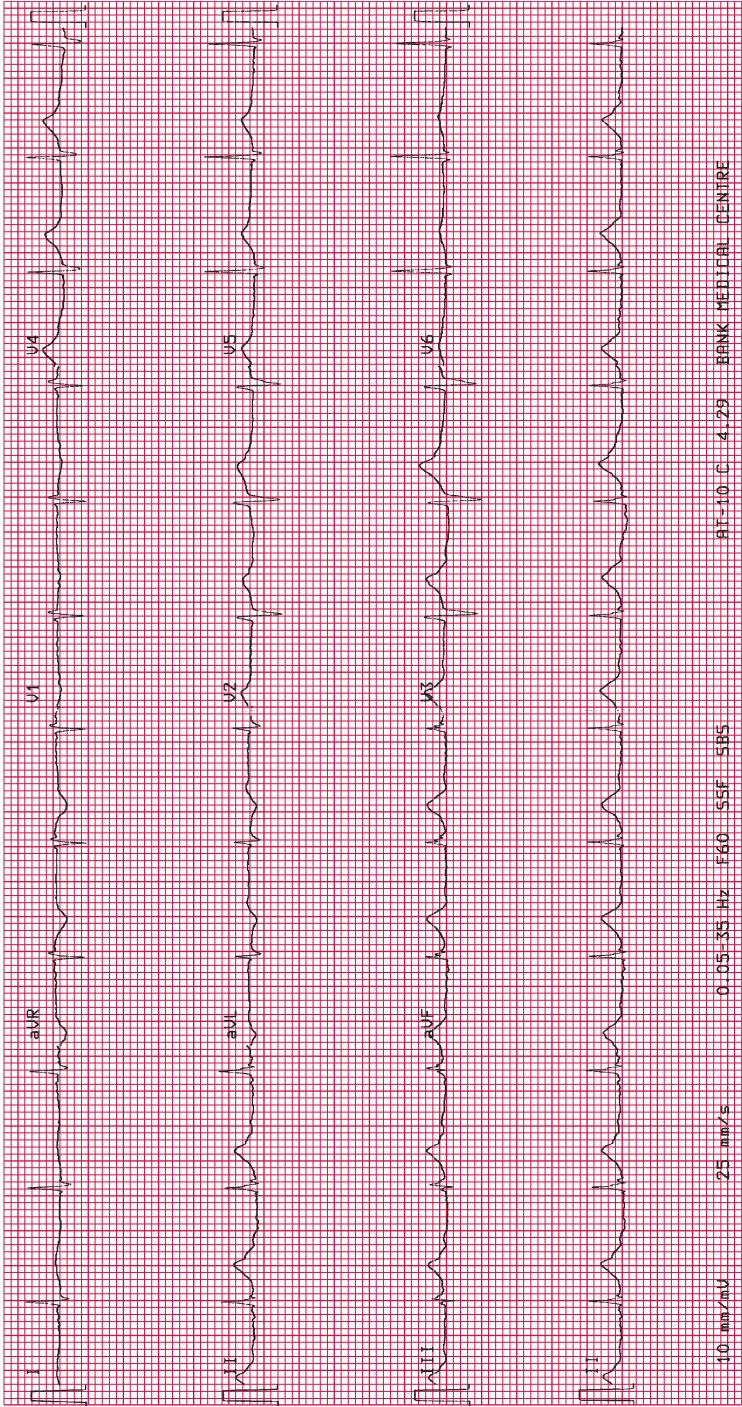


Fig. 12-67.

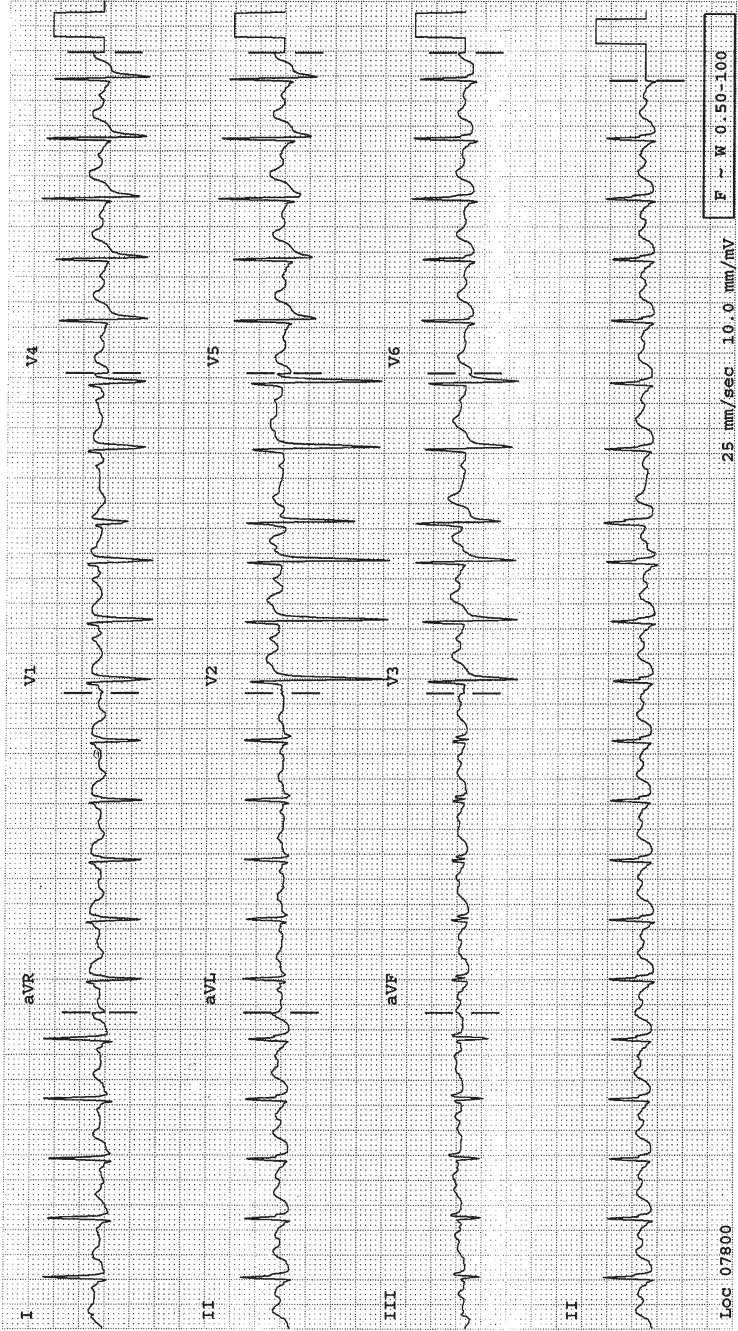


Fig. 12-68.

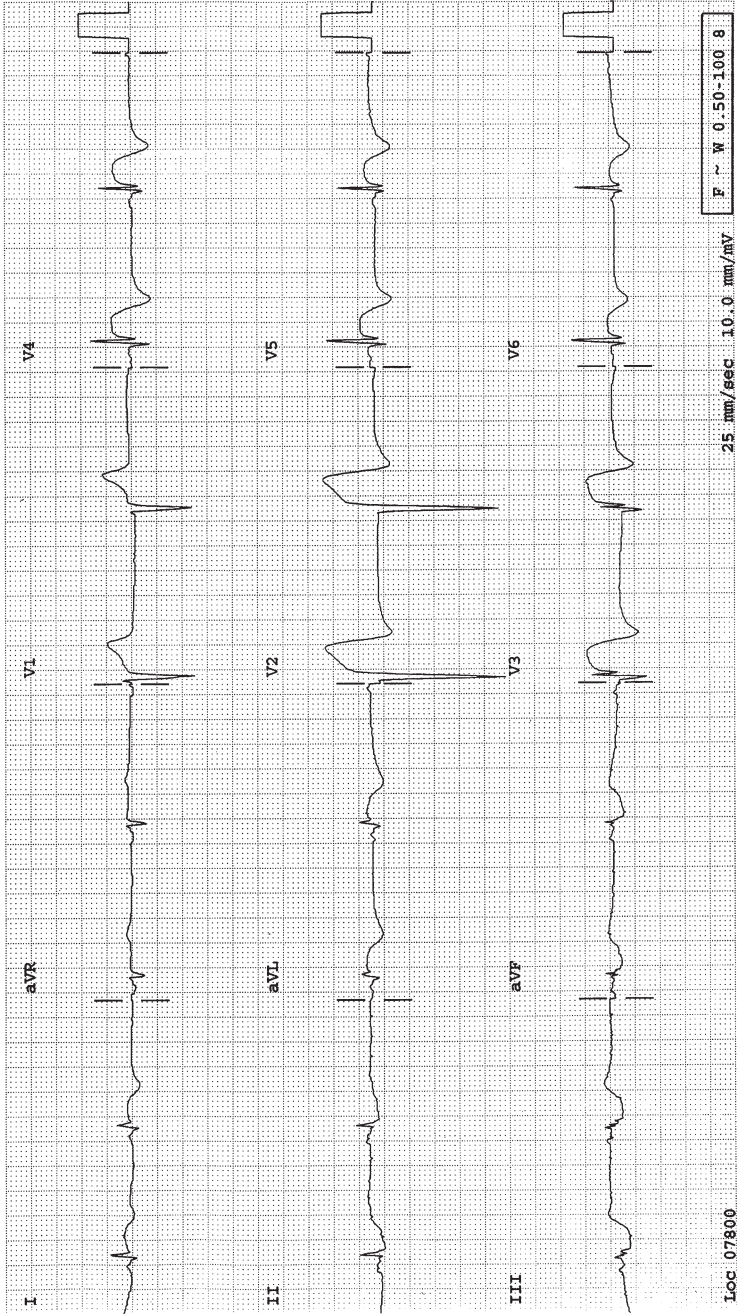


Fig. 12-69.




Fig. 12-70.

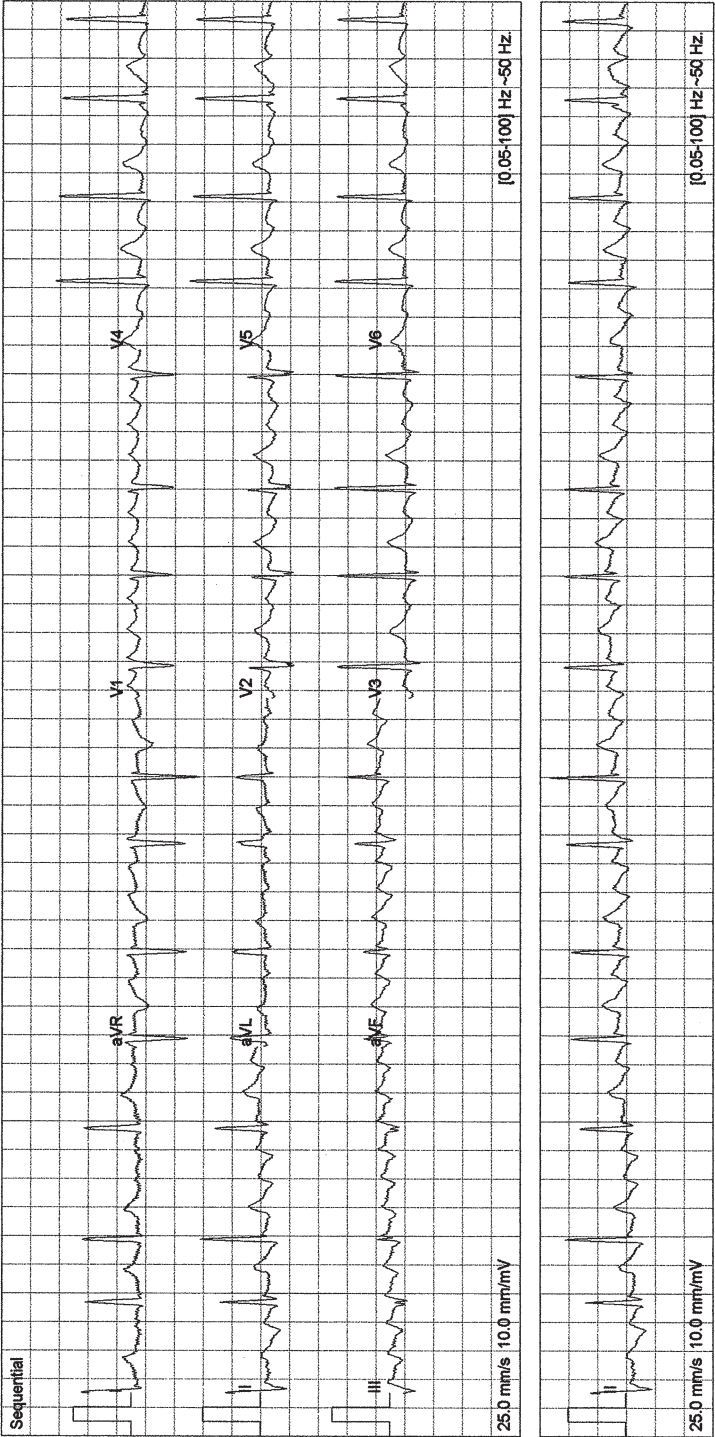


Fig. 12-71.

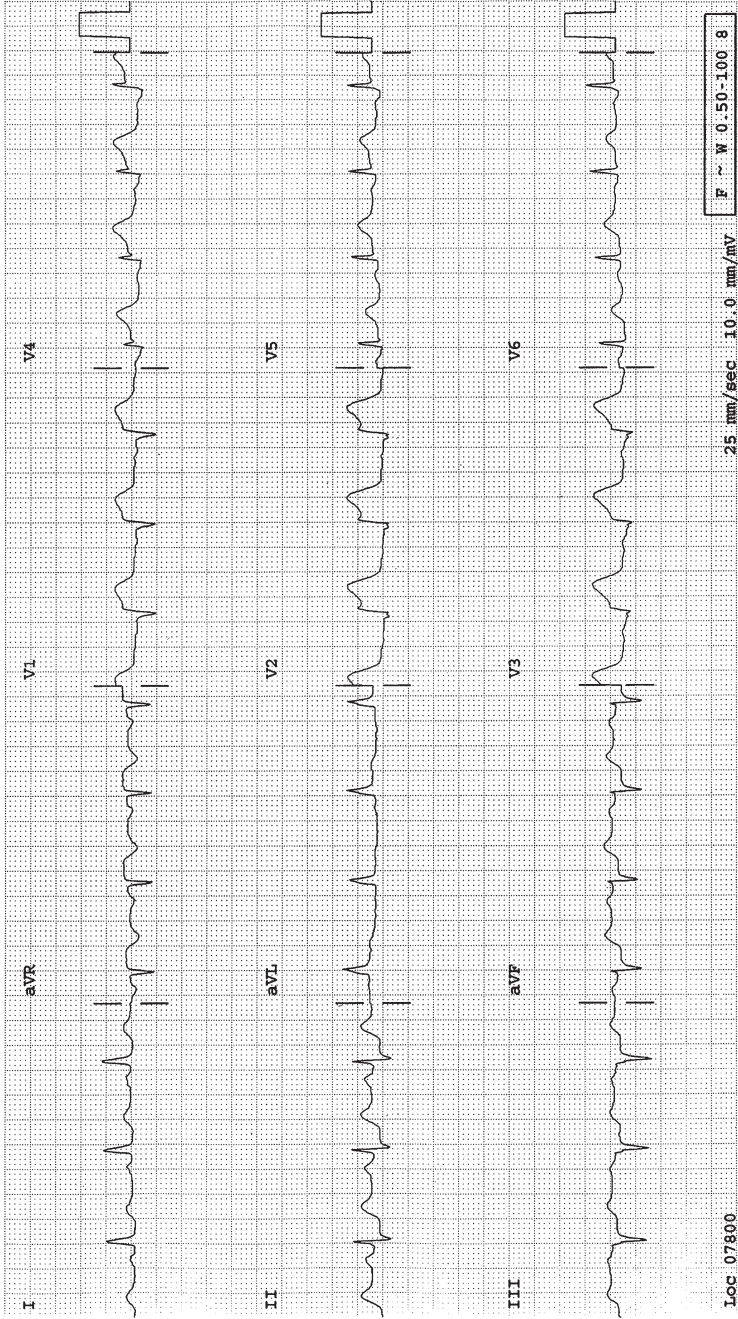


Fig. 12-72.

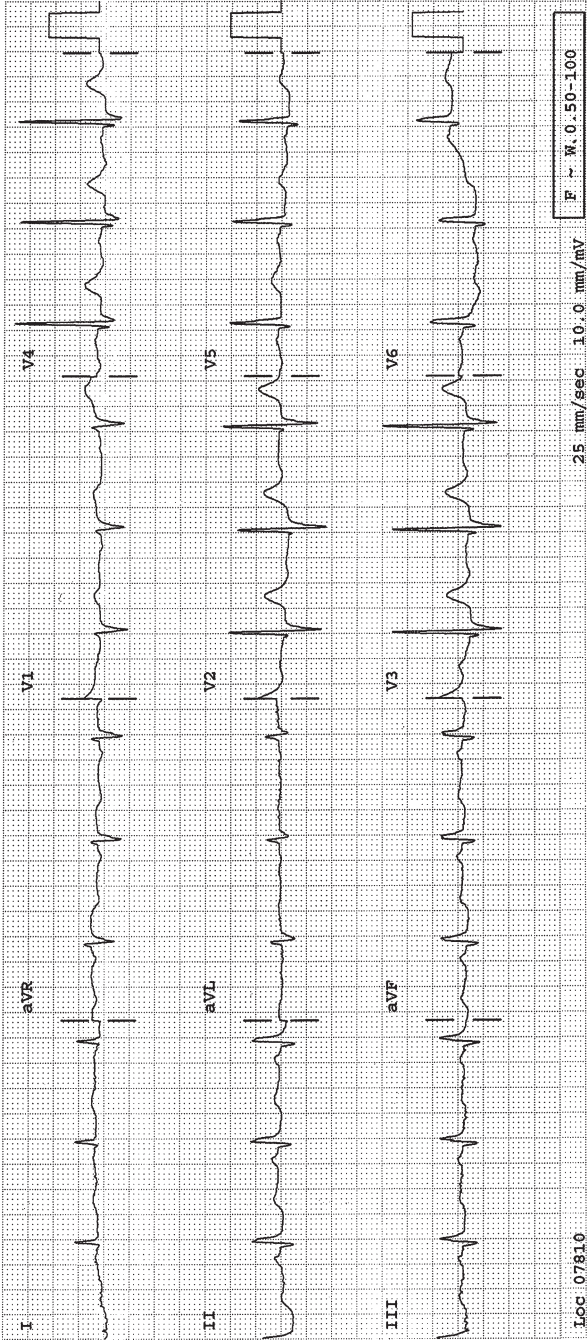


Fig. 12-73.

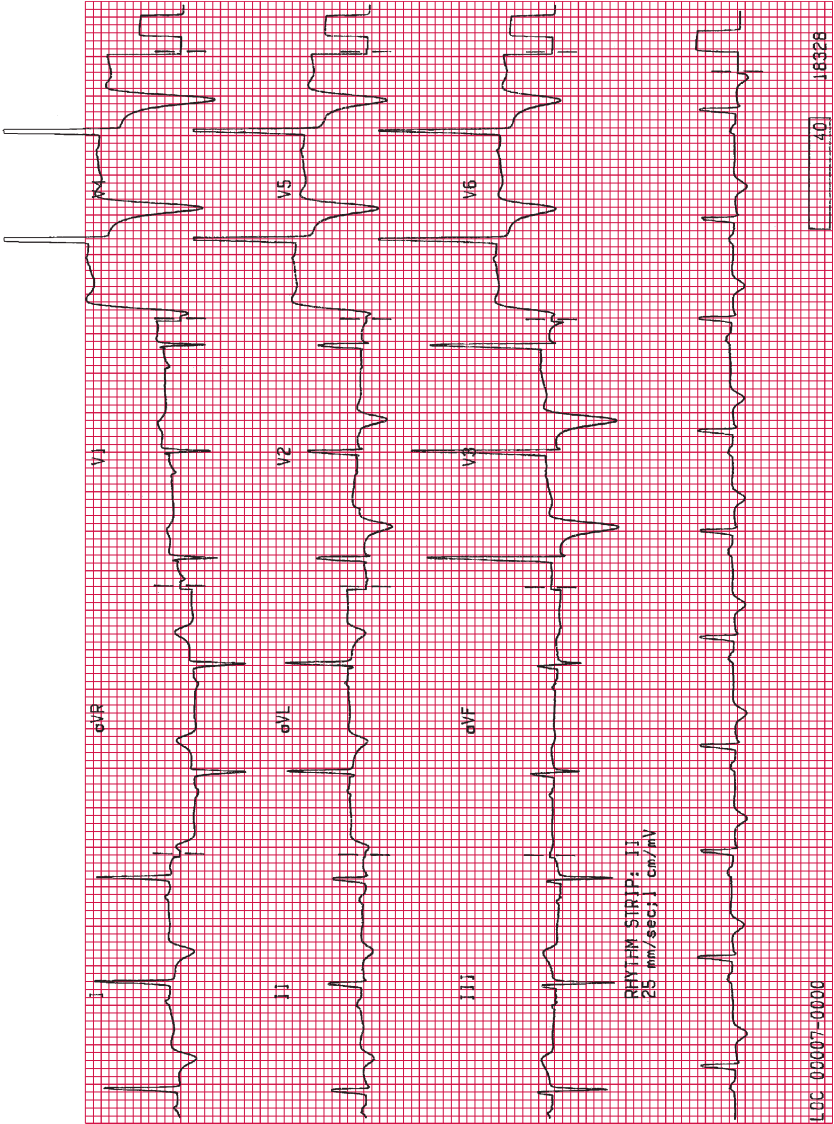


Fig. 12-74.

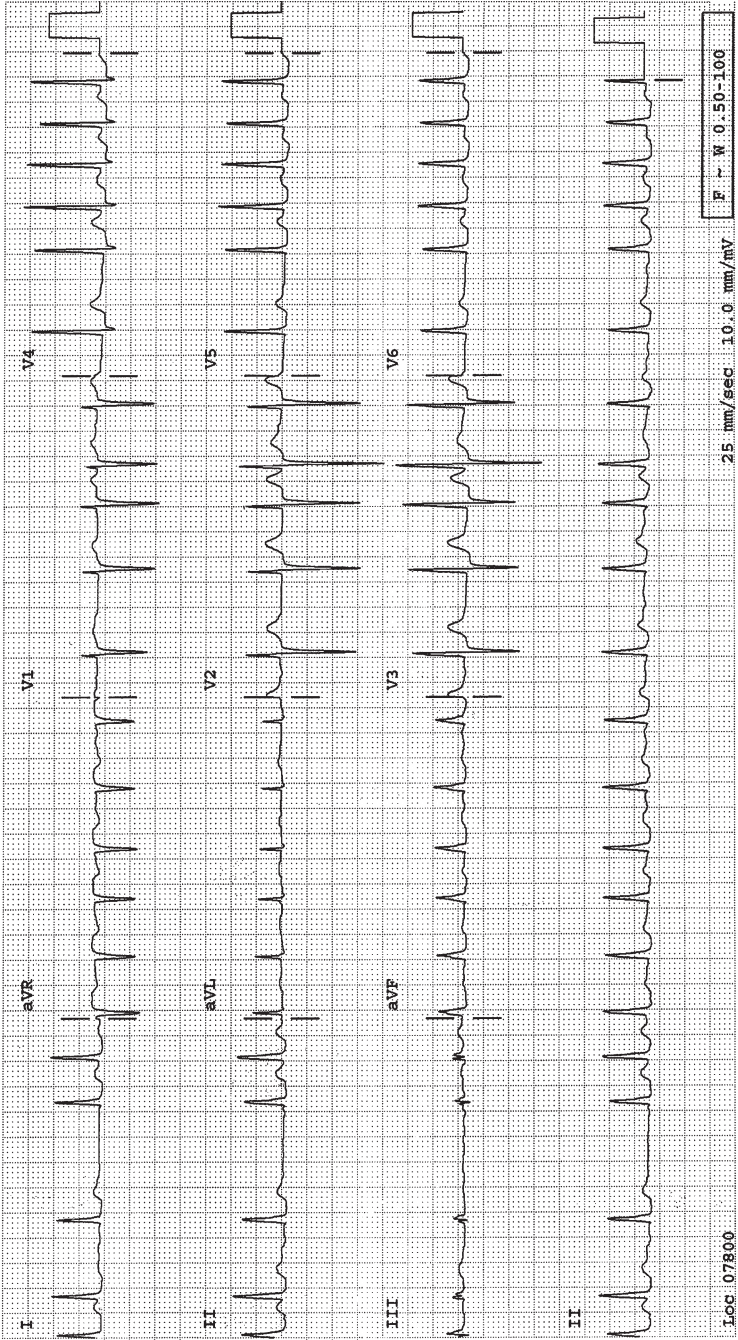


Fig. 12-75.

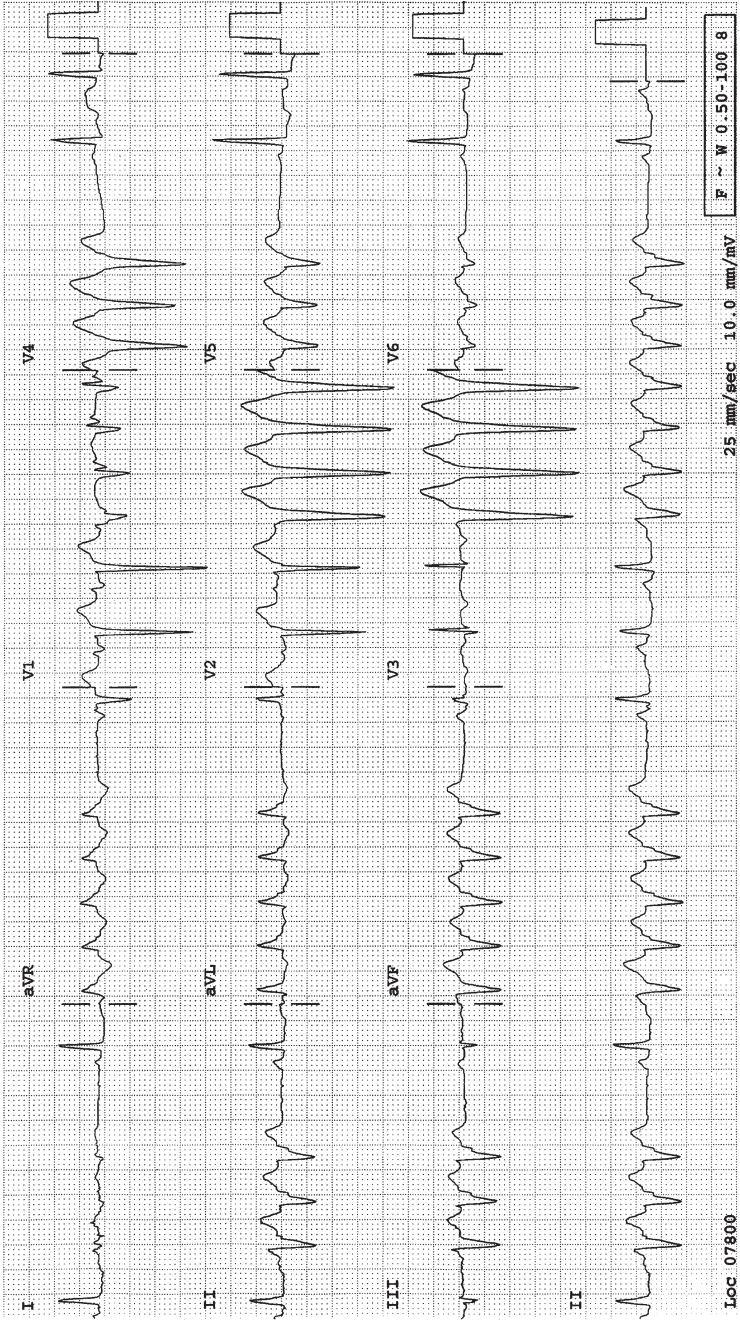


Fig. 12-76.

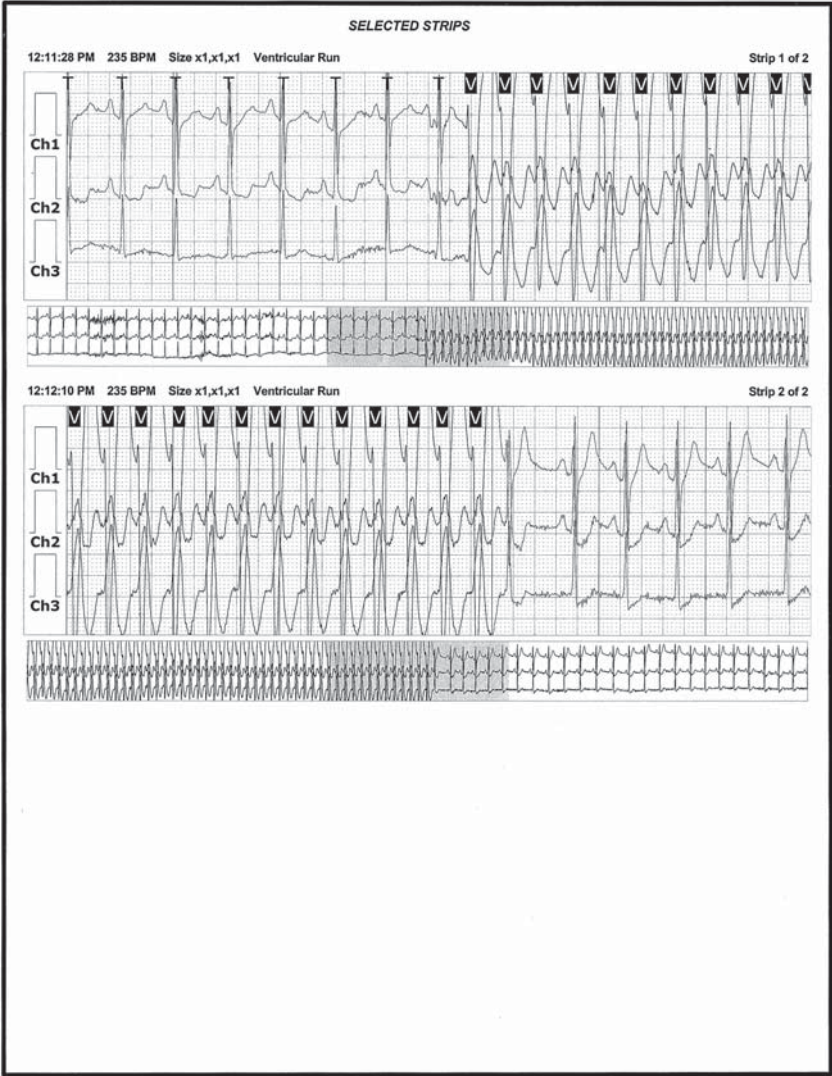


Fig. 12-77A.

(continued)

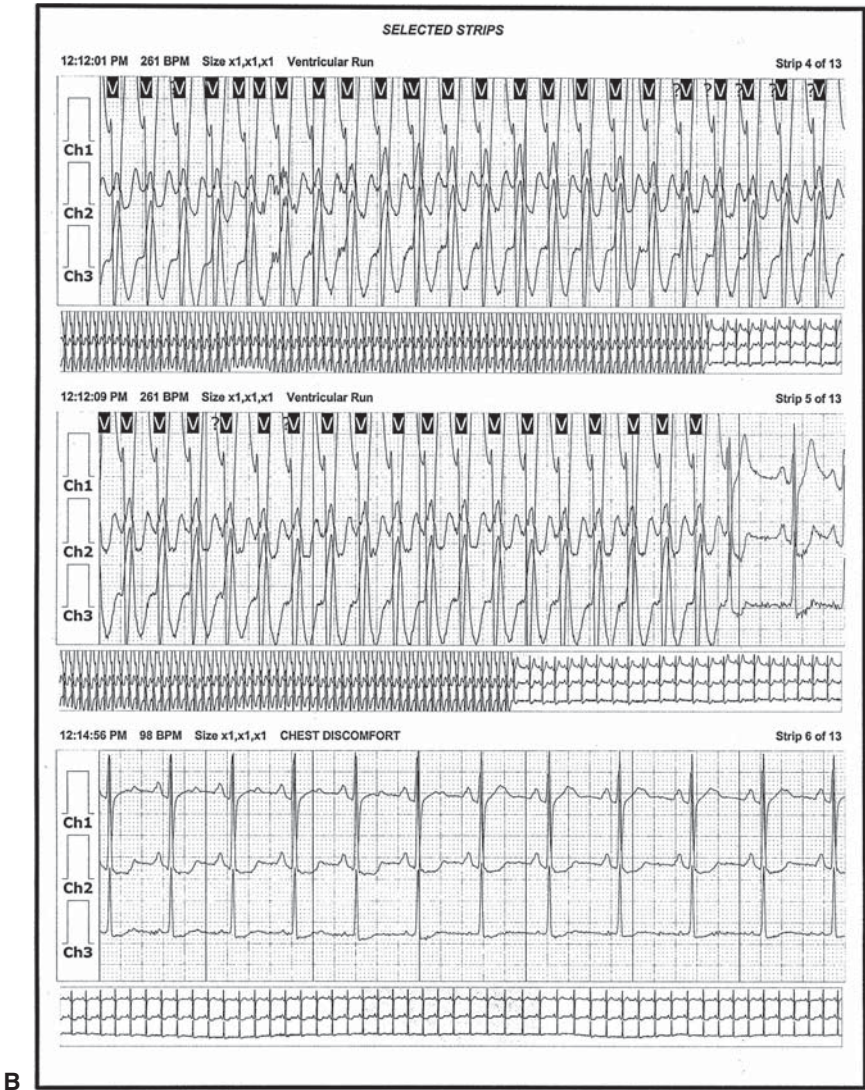


Fig. 12-77B. *Continued*

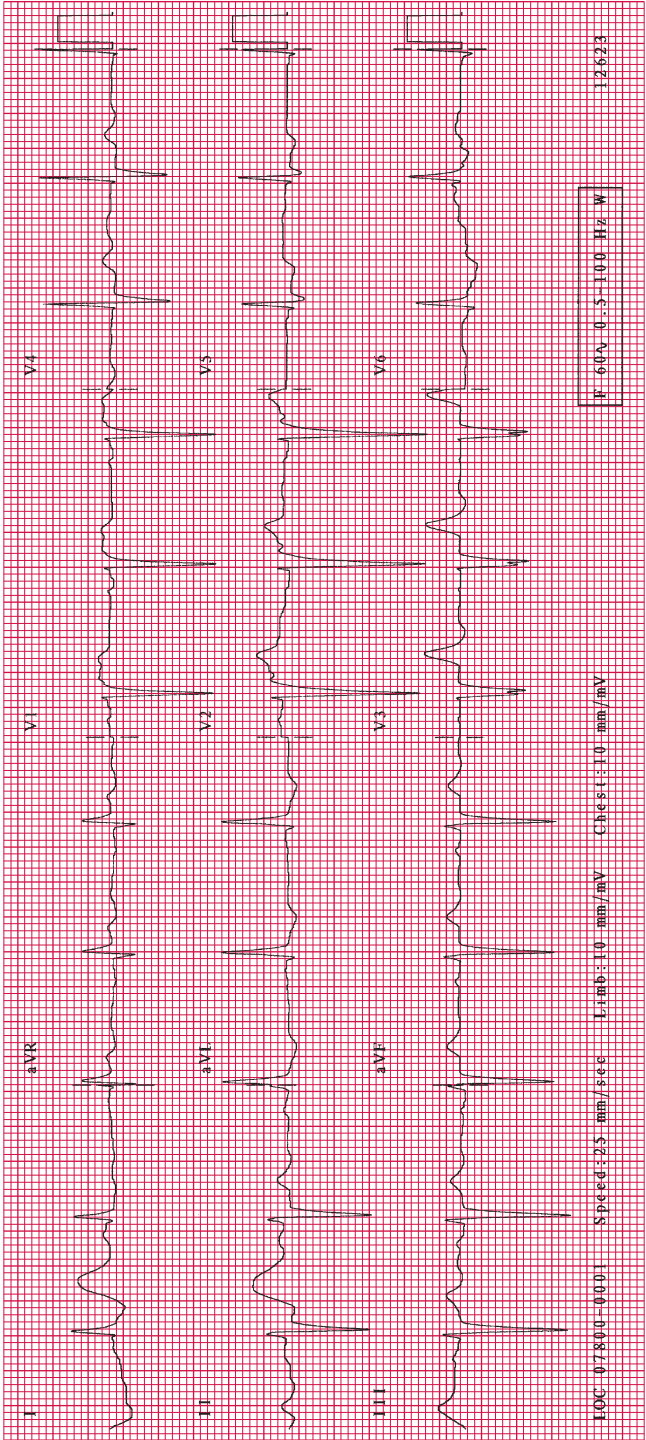


Fig. 12-78.




Fig. 12-79.

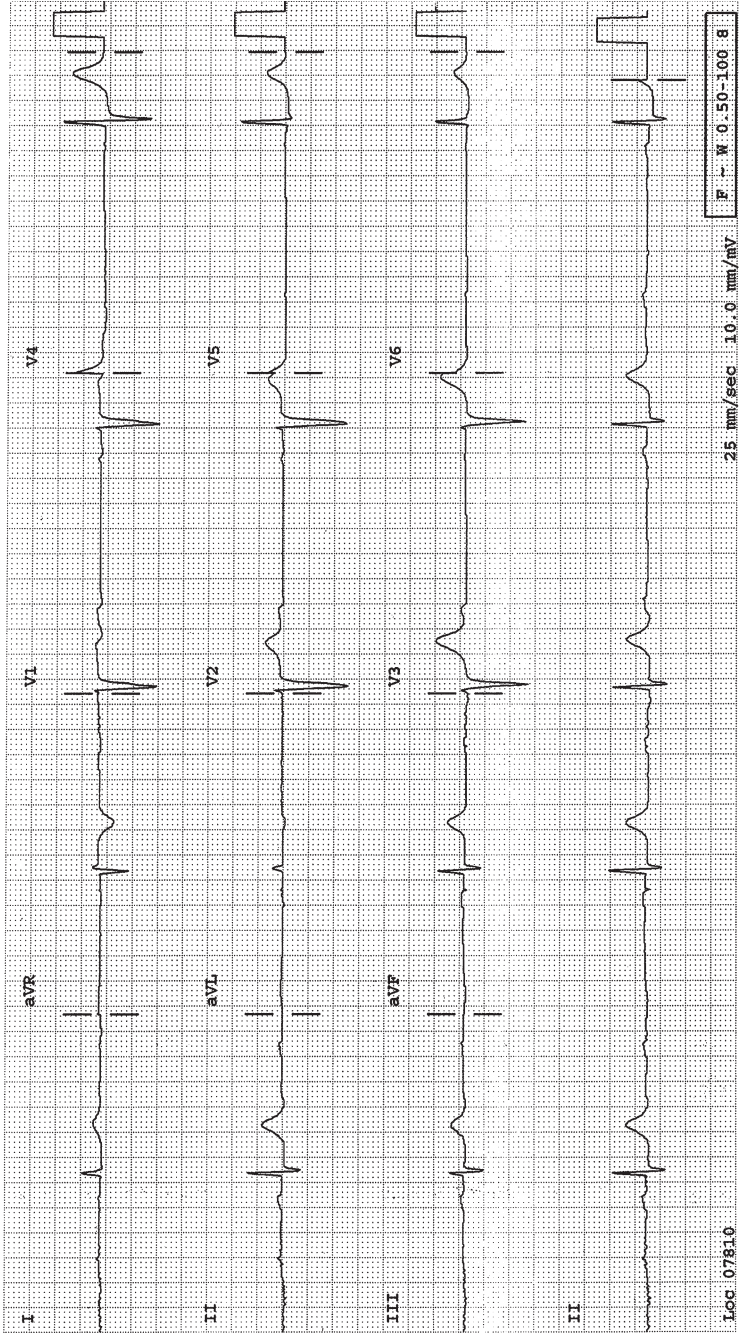


Fig. 12-80.

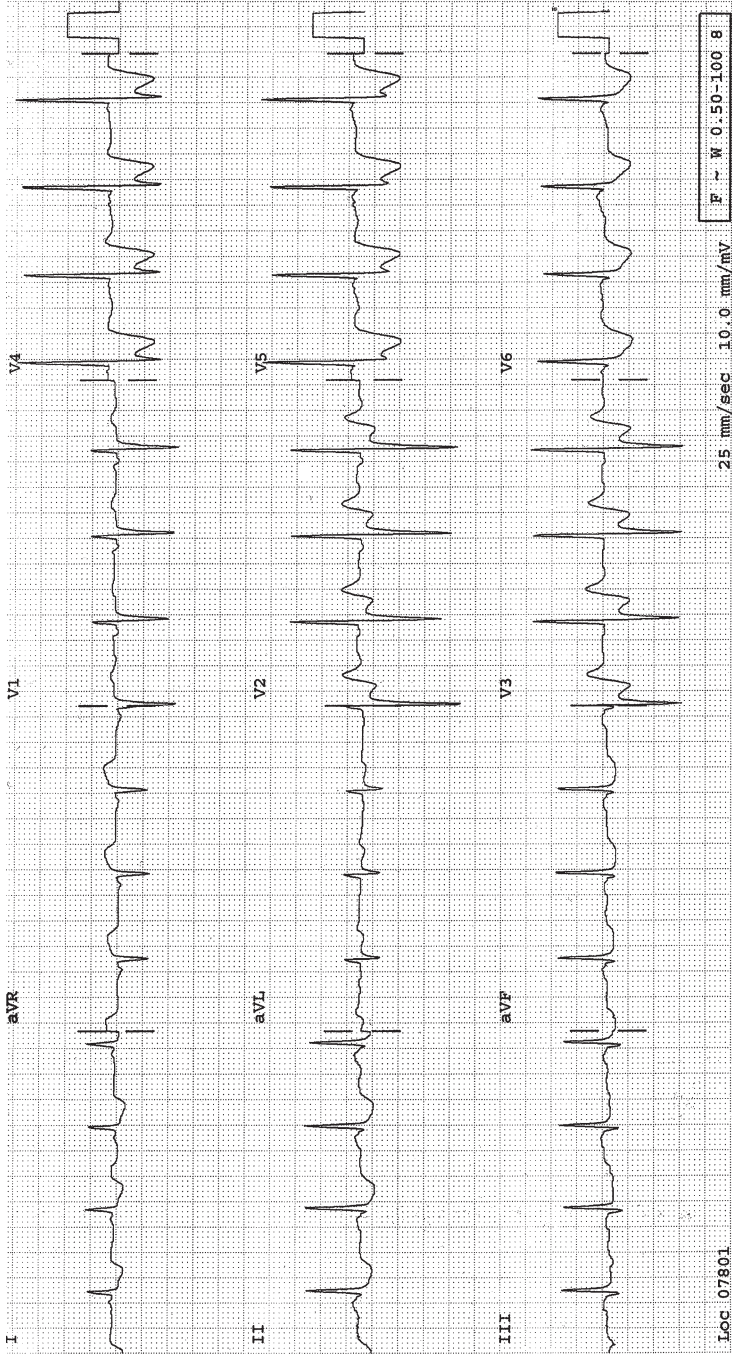


Fig. 12-81.

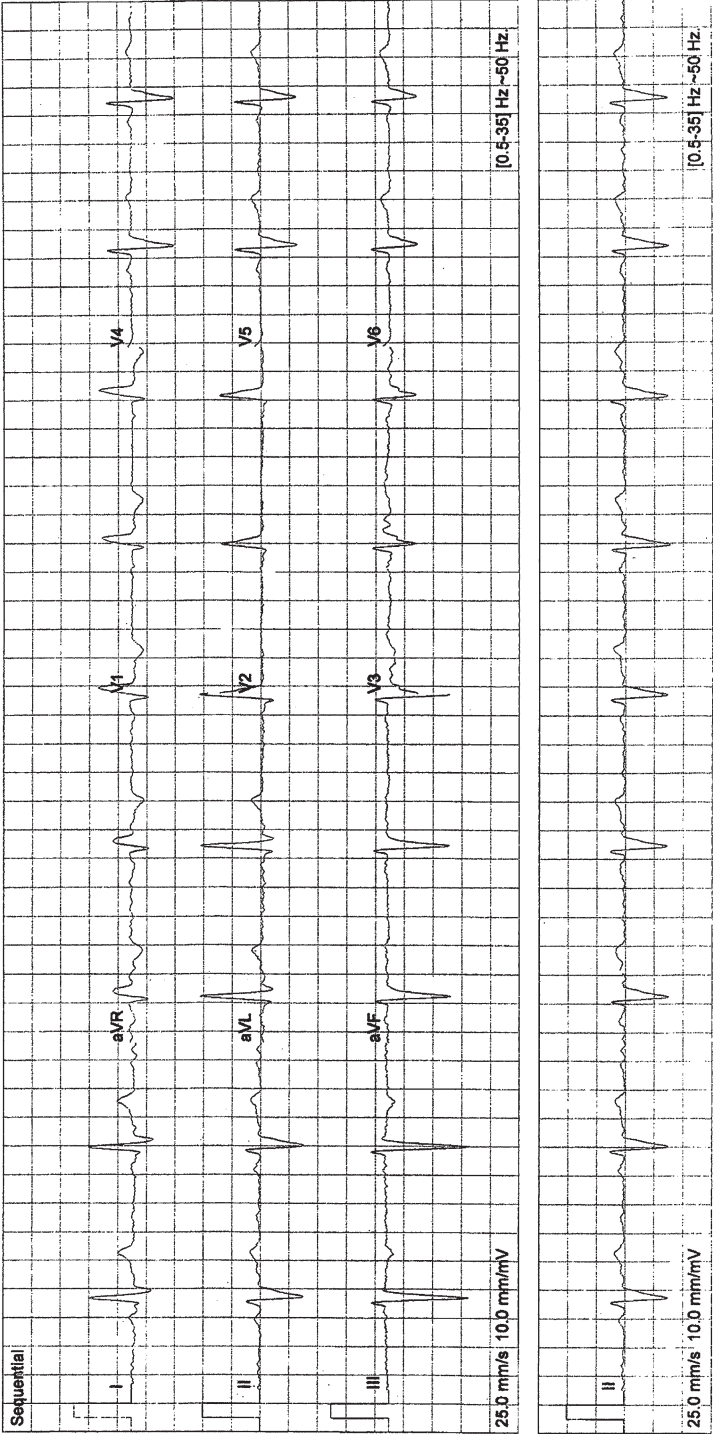


Fig. 12-82.

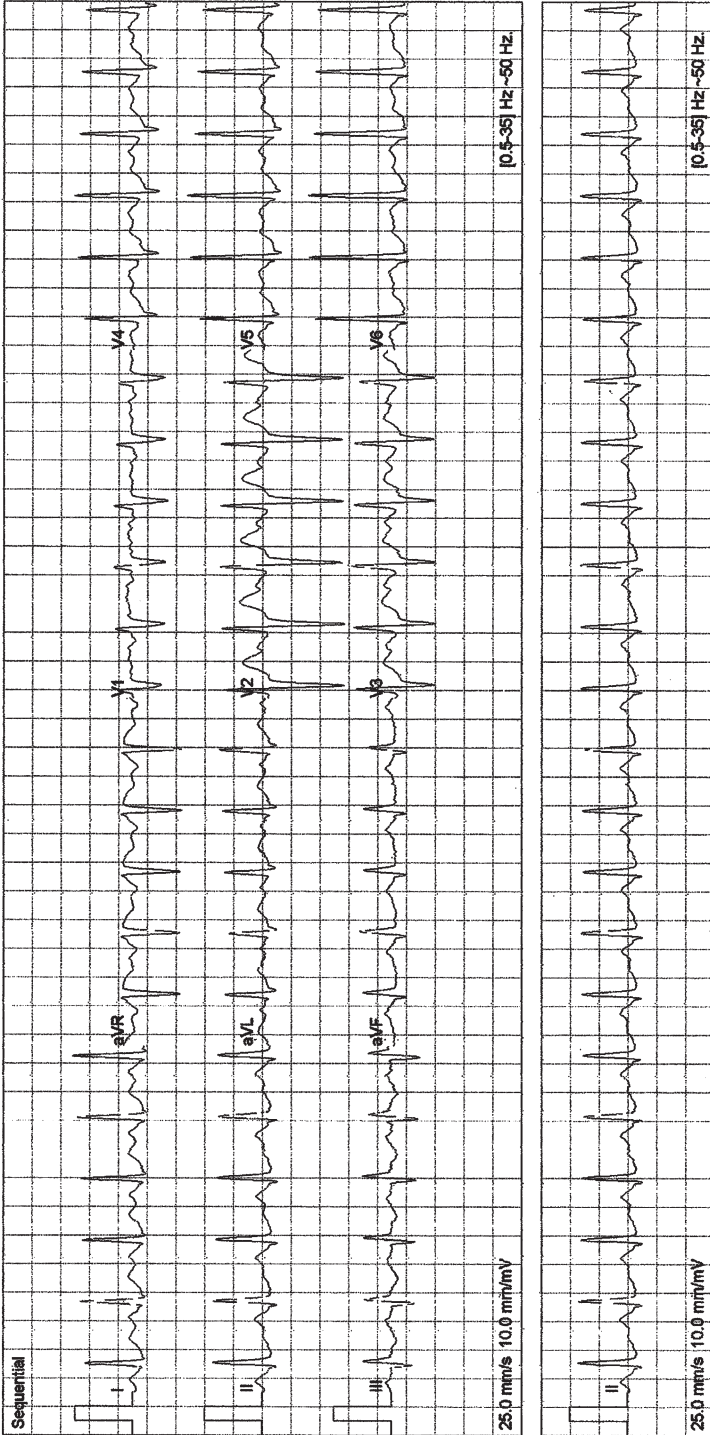


Fig. 12-83.

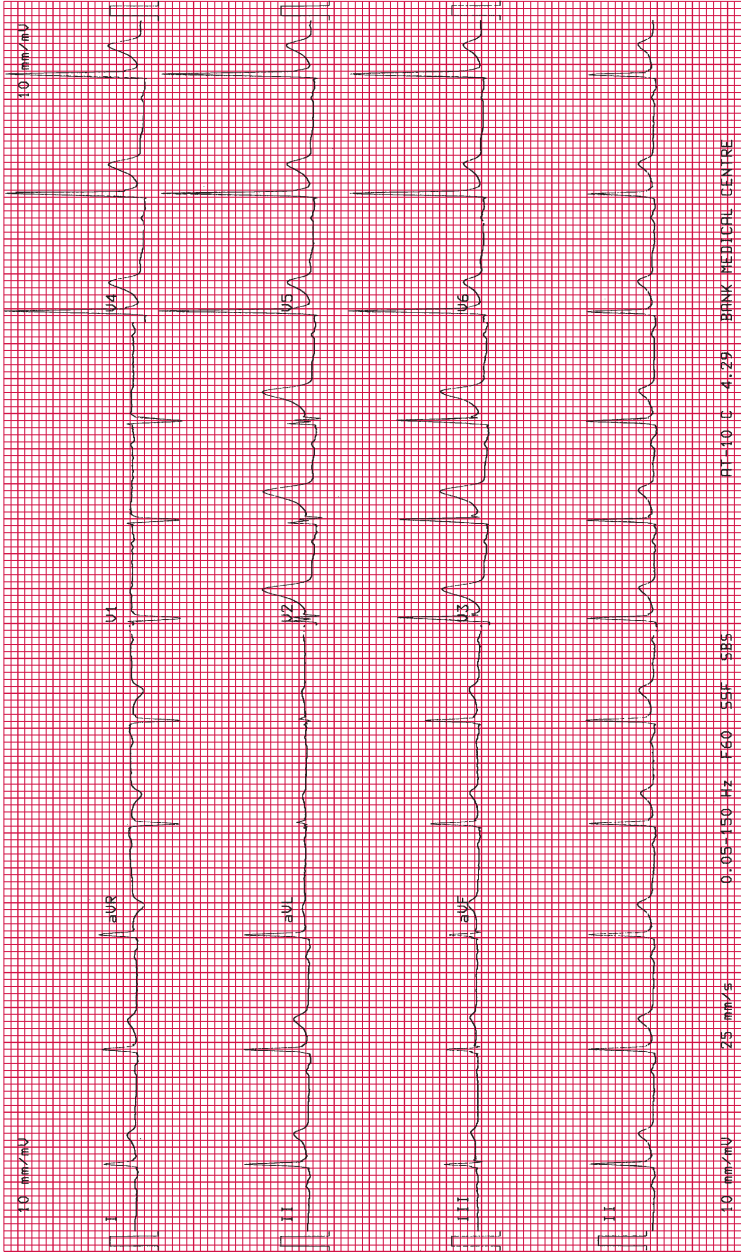


Fig. 12-84.

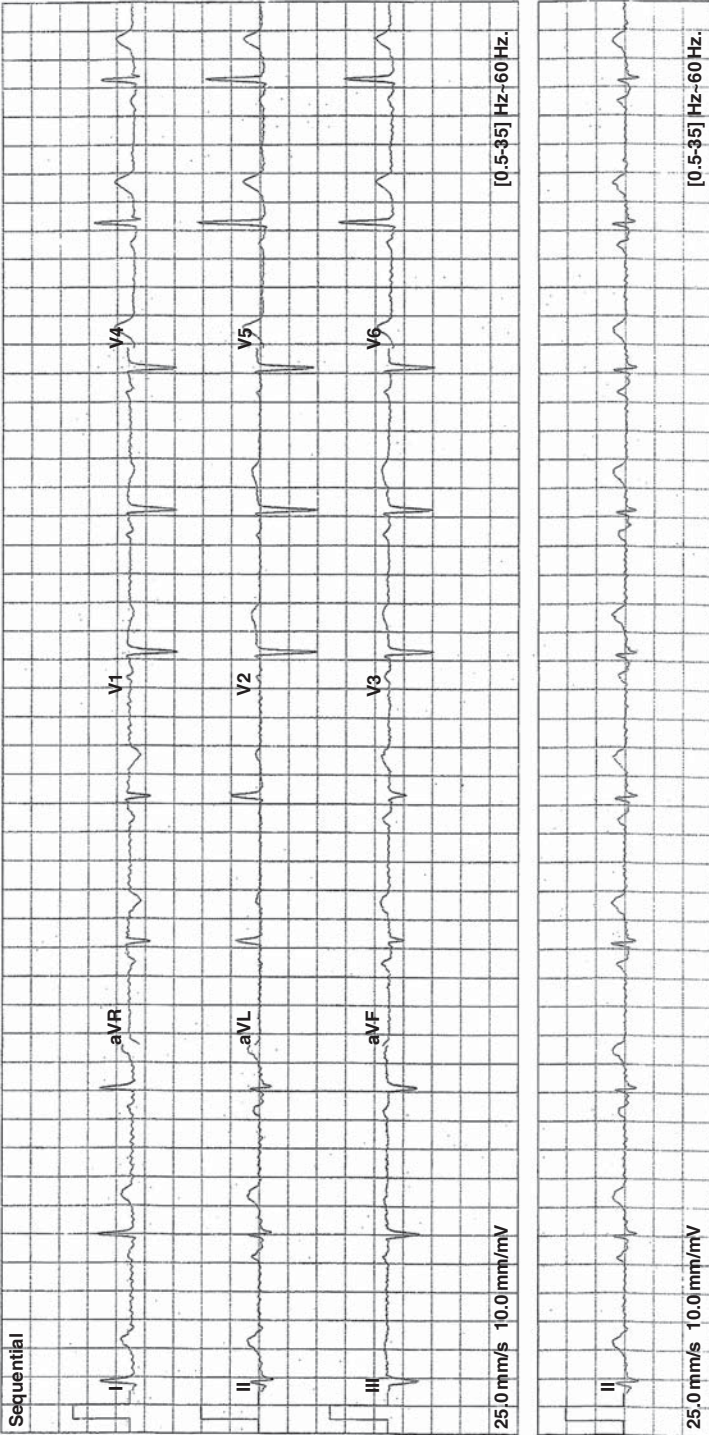


Fig. 12-85.

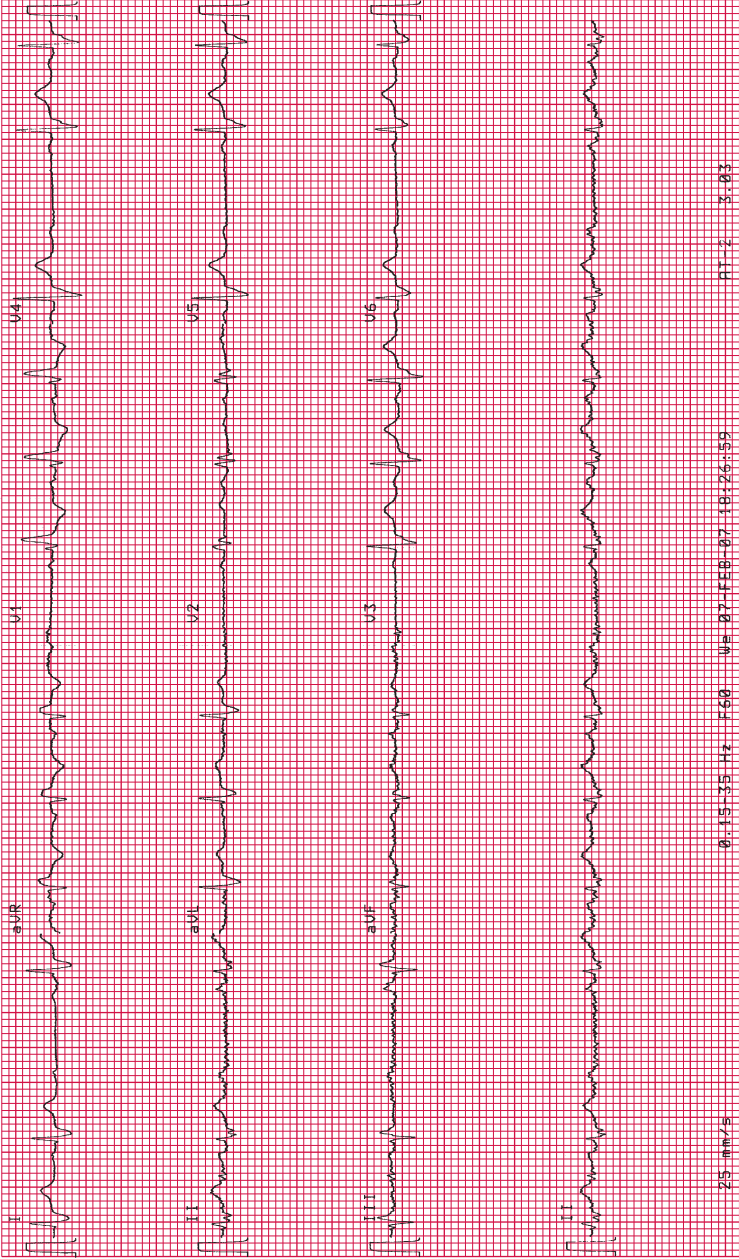
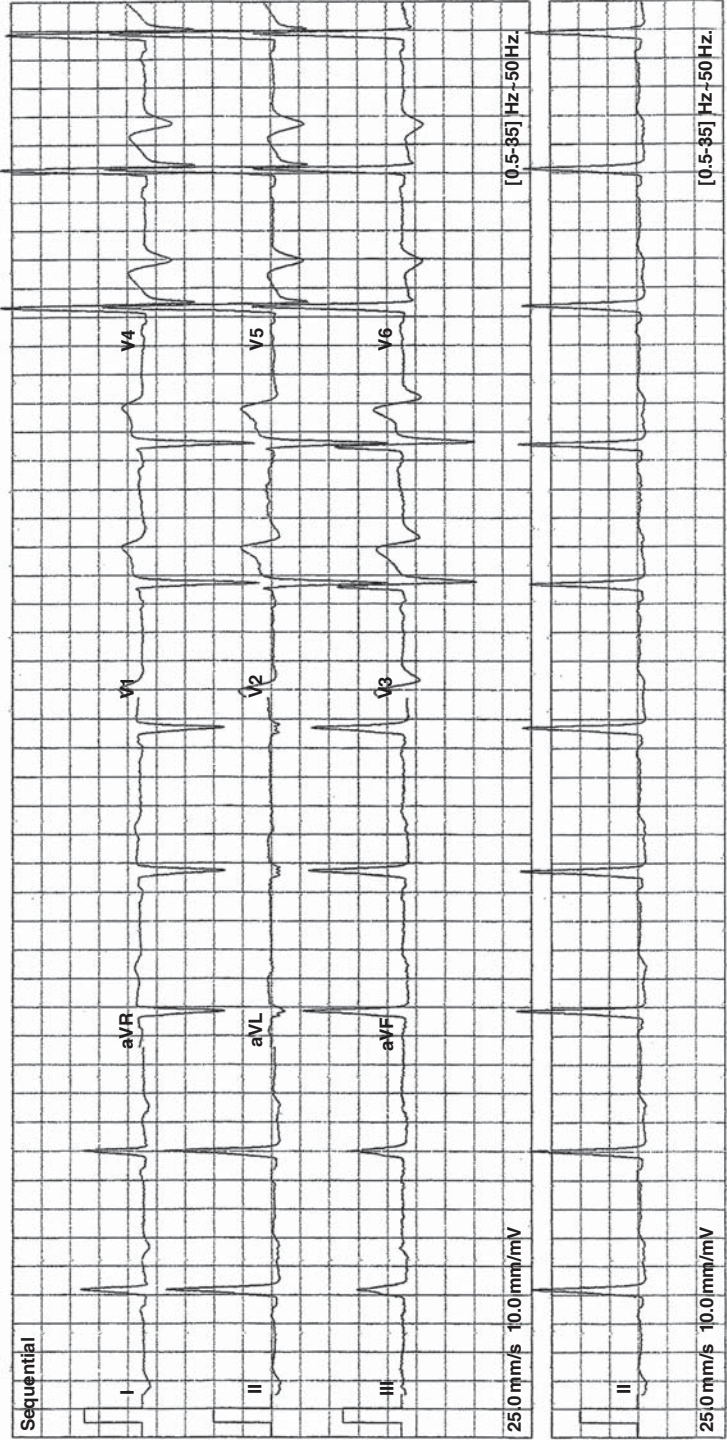
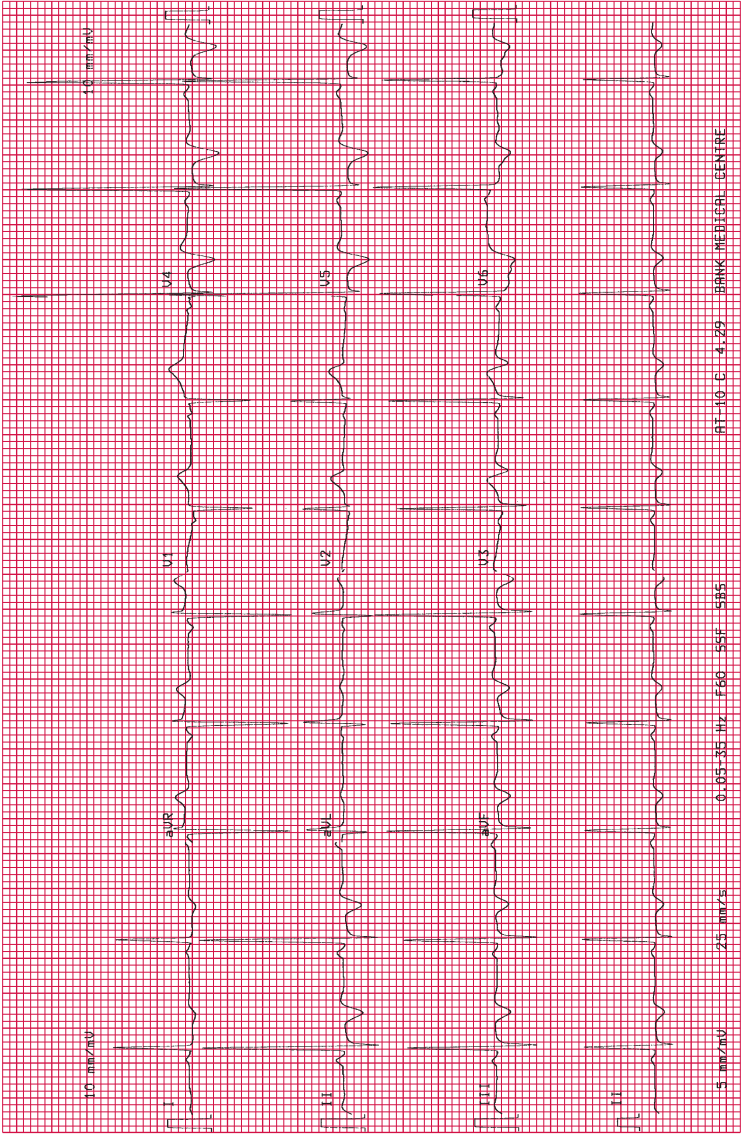


Fig. 12-86.



A

Fig. 12-87A.



B

Fig. 12-87B.

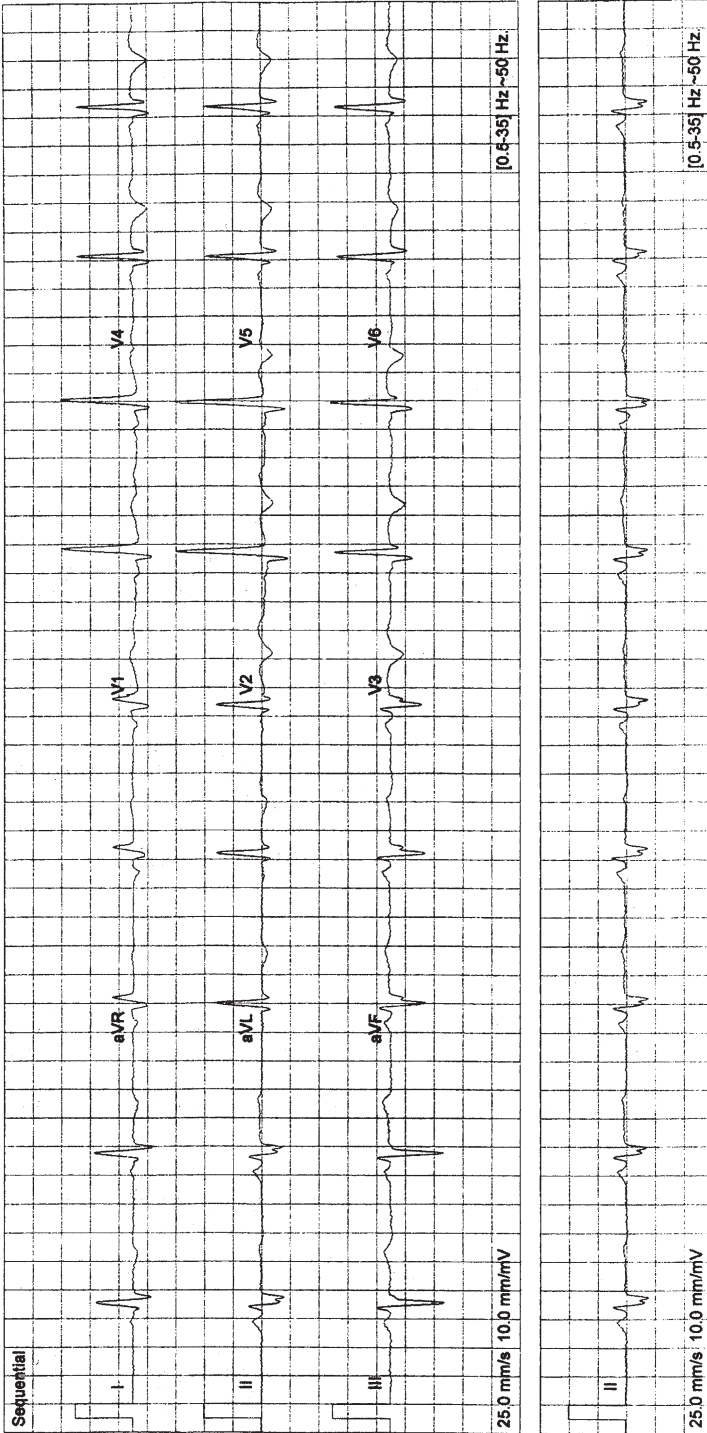


Fig. 12-88.

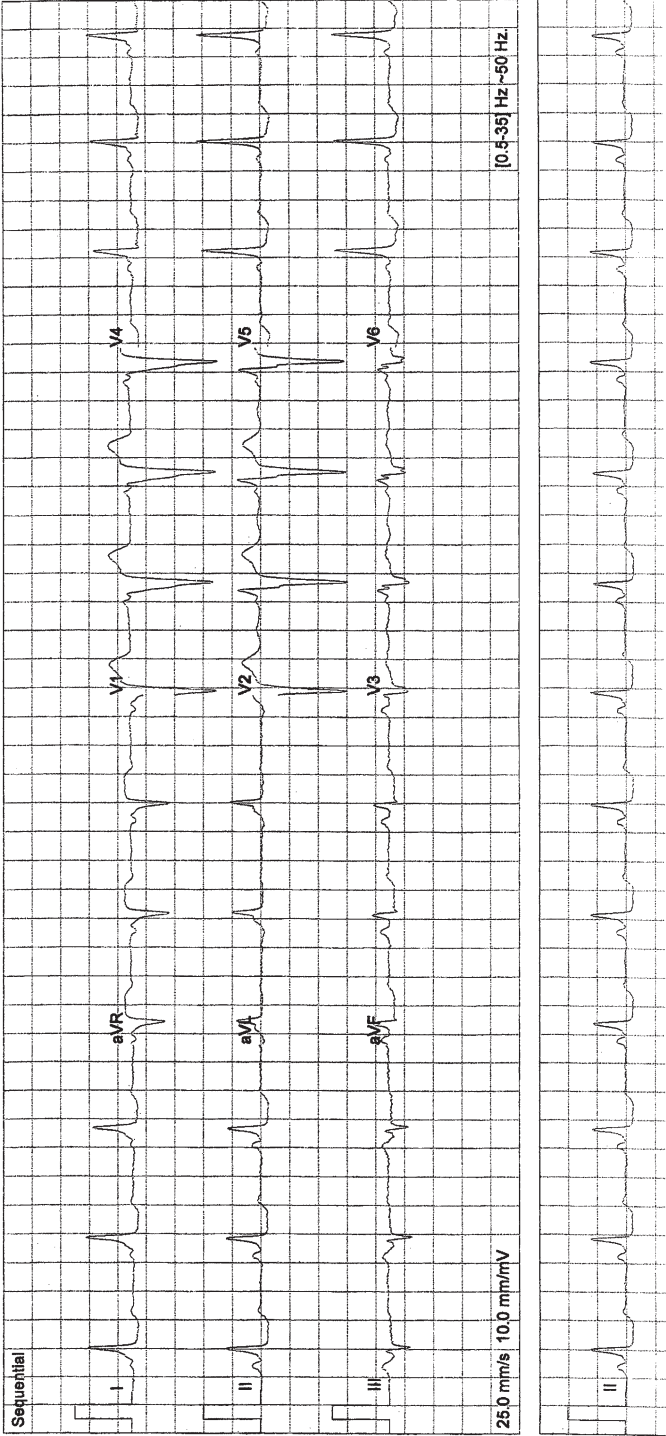


Fig. 12-89.

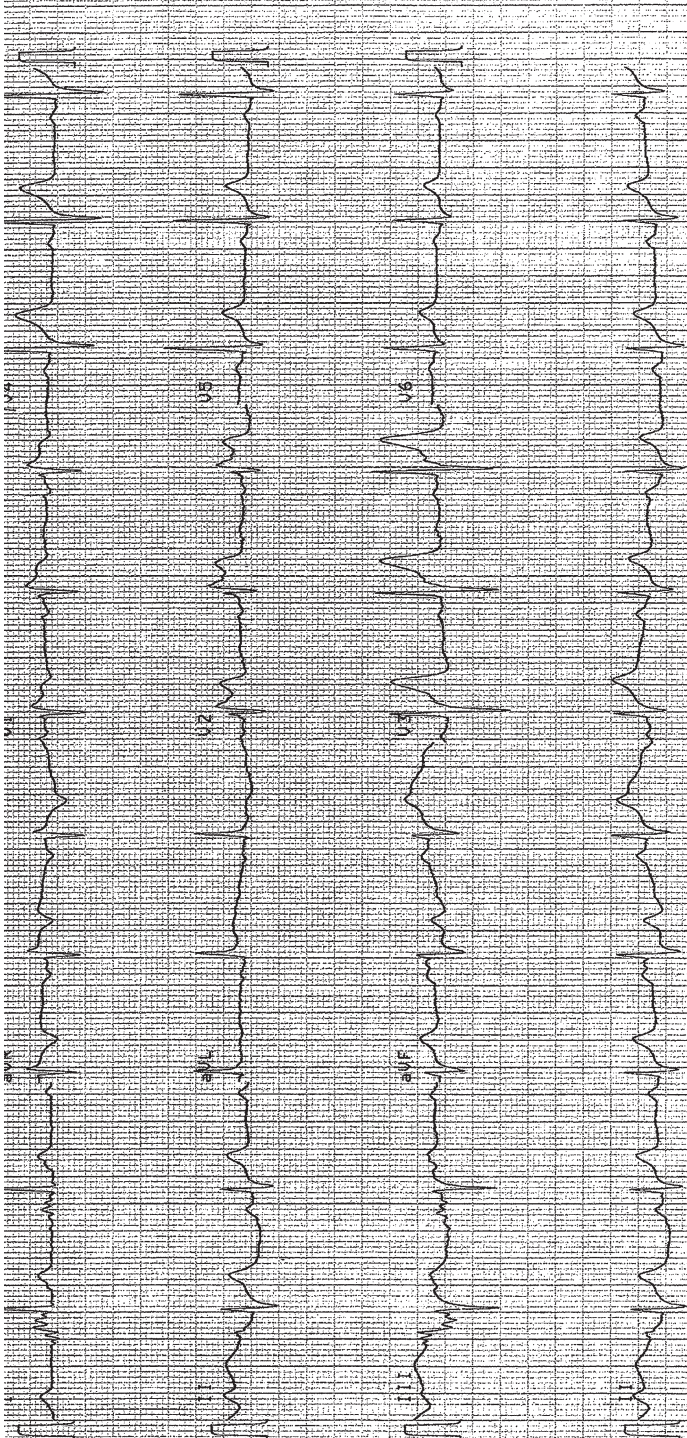


Fig. 12-90.

ANSWERS TO ECG SELF-ASSESSMENT QUIZ

Fig. 12-1. Acute pericarditis: sinus tachycardia 126/min; typical features: widespread ST elevation and PR segment elevation in aVR, which shows ST segment depression. Note: The J-point level almost equals the height of the T wave in V₆.

Causes of ST segment elevation include:

- Normal variant
- Acute ST segment elevation MI (STEMI)
- Coronary artery spasm: Prinzmetal angina
- Left ventricular aneurysm
- Acute pericarditis
- Left ventricular hypertrophy
- Left bundle branch block
- Acute myocarditis
- Hyperkalemia
- Brugada syndrome; ST elevation V₁–V₃

Fig. 12-2. Atrial fibrillation with rapid ventricular response 152 beats/min; marked ST segment depression in V₂ to V₆, in keeping with subendocardial ischemia, probable non–ST segment elevation MI.

Fig. 12-3. Acute extensive anterior infarct. Marked ST elevation and pathologic Q-waves in V₁ to V₆. Inferior MI, age indeterminate, sinus tachycardia 115/min.

Fig. 12-4. WPW syndrome: prominent Delta wave, short PR interval, tall R wave in V₂. Note the features in II, III, and aVF mimic inferior MI, and the pattern in V₁ mimics IRBBB.

- Thus, the assessment for WPW syndrome is done early in the interpretive sequence (Step 3) soon after the assessment for bundle branch block.

Fig. 12-5. Hyperkalemia; note the tall tented T waves in V₂–V₄; serum potassium 5.9 mmol/L.

Fig. 12-6. Left ventricular hypertrophy; note also, left atrial hypertrophy. The ST segment depression in lead V₃ suggests the presence of underlying ischemia.

Fig. 12-7. Supraventricular tachycardia; rate 230/min; orthodromic circus movement tachycardia. Patient with WPW syndrome.

Fig. 12-8. A, Note tall R wave in V₁–V₂, small R and deep S in V₆ interpreted by the computer as right ventricular hypertrophy. Findings are caused by incorrect placement of the precordial leads; this is a rare error for technicians. **B,** Normal ECG; same patient as in (A), correct placement of V leads.

Fig. 12-9. A 2:1 AV block, probably Mobitz type I in view of a normal narrow QRS; approximately 30% of Mobitz II exhibits a narrow QRS complex. Thus type II block cannot be excluded.

The diagnosis of Mobitz type II block is certain when at least two regular and consecutive atrial impulses (P waves) are conducted with a constant PR interval before the occurrence of the dropped beat. Two or more consecutive PR intervals are unchanged before the dropped QRS beat. Note that Wenckebach did not have the use of electrocardiography when he cleverly deduced two forms of blocks from studies of the jugular venous waves in 1906. Mobitz in 1924 using the ECG described type I and type II blocks. Mobitz type I includes Wenckebach phenomenon (with each successive beat, the PR interval gradually lengthens and a beat is dropped). Importantly, not all Mobitz type I AV block reveal Wenckebach phenomenon (*see* Figs. 11-13, 11-14, and 11-15 for Mobitz type II block).

Fig. 12-10. Supraventricular tachycardia (SVT). Rate 155/min. Note the diagnostic pseudo- r' wave in V_1 , and the small distortion of the terminal QRS complex (pseudo-S wave) in leads II, III, aVF. These are typical features of AV nodal reentrant tachycardia (AVNRT) observed in ~45% of SVTs.

Fig. 12-11. Atrial fibrillation and ventricular premature beats (VPBs); note the couplets; multiform VPBs. Also left axis. Abnormal ECG.

Fig. 12-12. ST segment elevation V_1 , V_2 , V_3 ; normal variant in a 46-year-old man. Note the fishhook pattern in V_2 .

Fig. 12-13. Anterior MI, probably in recent past: age indeterminate. Consider LV aneurysm if ST elevation V_2 - V_4 has persisted beyond 6 months.

Fig. 12-14. Female age 68 with mild hypertrophic cardiomyopathy confirmed by echocardiography at age 45. Note the significant pathologic Q waves in V_4 - V_6 , and leads II, III, aVF. Incorrectly interpreted by computer as old inferolateral MI.

Fig. 12-15. LBBB.

Fig. 12-16. Wide QRS tachycardia, irregular rhythm: Atrial fibrillation with a ventricular response, 160 beats/min in a patient with Wolff-Parkinson-White syndrome. Clues to WPW syndrome antidromic, preexcited tachycardia: irregular, wide-complex tachycardia, often with runs at rapid rates exceeding 250 beats/min.

Fig. 12-17. Mimics inferior MI. The ST-T abnormality in lead I cannot be explained by an inferior MI. Fishhook-type pattern in II and concave ST segment elevation in III, aVF, are unlike acute MI. Treadmill cardiac nuclear perfusion imaging is normal; echocardiogram

shows mild LVH in this 31-year-old male known to have a VSD patch.

Fig. 12-18. LVH, left atrial hypertrophy. Note the shape of the ST segment and deep T wave inversion V_4 – V_6 and the extension of these changes to V_3 are in keeping myocardial ischemia and not simply hypertrophy. Also, consider apical HCM.

Fig. 12-19. Mimics dextrocardia. Error by technician: The reversed placement of arm leads is a common error; the reversal of V leads is a rare error and can cause incorrect interpretation of the ECG. Computer interpretation, dextrocardia. In this tracing, $V_1 = V_6$.

Fig. 12-20. Accelerated AV conduction, early transition: normal ECG.

Fig. 12-21. Tracing interpreted by computer as LBBB. Note absence of pacing spikes, because the muscle filter is activated. Deactivation of the computer muscle filter should expose the pacing spikes. (*see* Fig. 12-22.) The atypical IVCD, the negative concordance V_3 – V_6 and in II, III, and aVF are pacing clues.

Fig. 12-22. Electronic pacing; the same patient as in Fig. 12-21 but with muscle filter turned off. Capture rate 61/min.

Fig. 12-23. WPW syndrome (type A). Note the tall R waves V_1 – V_3 .

Causes of tall R wave in V_1 include:

- Normal variants, thin chest wall, detroposition
- Misplacement of chest leads: V_6 placed in V_1 position; fortunately a rare technician's error.
- WPW syndrome: type A pattern caused by lateral or posterior accessory pathways.
- RBBB
- Posterior MI; inferoposterior MI
- Right ventricular hypertrophy
- Hypertrophic cardiomyopathy
- Duchenne muscular dystrophy

Fig. 12-24. Normal ECG; tall peaked precordial T waves in a healthy 35-year-old with normal serum potassium.

Fig. 12-25. Severe myocardial ischemia; probable non–ST elevation MI?

Causes of ST depression include:

- Acute non–ST segment elevation MI (non–Q wave MI)
- Acute myocardial ischemia without infarction (subendocardial ischemia)

- Chronic myocardial ischemia
- Reciprocal ST depression associated with STEMI
- LVH with “strain” pattern
- Conduction defects: LBBB, RBBB, IVCD, WPW
- Digoxin and other drugs
- Hypokalemia
- Cardiomyopathy

Fig. 12-26. Normal ECG from a healthy 7 year old. ST-T changes V_1 to V_3 are normal findings.

Fig. 12-27. Hypertrophic cardiomyopathy. An asymptomatic 20 year old; played soccer, rugby, and hockey for the past 5 years. Routine physical revealed a grade II systolic murmur. Echocardiogram: asymmetric LVH; marked septal hypertrophy: septal thickness 36 mm (normal <11 mm).

Fig. 12-28. Right bundle branch block, left axis -60 , left anterior fascicular block (hemiblock).

Fig. 12-29. Normal variant ST elevation V_2 – V_5 in a 24-year-old male. Note the J-point fishhook in V_3 . Normal variant ST elevation is common in males and rare in females. Many cardiologists and interpreters refer to the ST change as “early repolarization.”

Fig. 12-30. Old inferior MI: Deep wide Q wave changes in II, III, aVF have persisted for more than 15 years. Also, features of LVH and anterolateral ischemia are present.

Fig. 12-31. Atrial flutter. Note: a ventricular rate of 150/min is a clue to atrial flutter with 2:1 AV conduction; the prominent sawtooth pattern in II, III, aVF is typically absent in I, V_5 , V_6 .

Fig. 12-32. Brugada syndrome. Note the atypical incomplete RBBB pattern with a curious coved ST segment elevation in V_1 , V_2 , and saddle-back type elevation in V_3 . A 40-year-old Algerian male who collapsed; following an episode of syncope; an ICD was placed. Brugada and WPW syndrome should be considered along with assessments of blocks and is thus put as Step 3 of the 11-step strategies. Readers may wonder why interpreters should be on the watch for these rare conditions. They can cause death in young individuals, and these deaths and/or hospitalizations can be prevented.

Fig. 12-33. Nonsustained ventricular tachycardia in a 38-year-old male presenting with chest pain at 3:14:41 AM.

Fig. 12-34. Ventricular premature beats, triplets. ECG at 3:13:29 AM on presentation to the ER. Same patient as in Fig. 12-33; ECG taken a minute later.

Fig. 12-35. Acute inferior myocardial infarction. Note the reciprocal depression in leads I and aVL. Right bundle branch block.

Fig. 12-36. Extensive anterior infarct probably in recent past; age indeterminate; left anterior fascicular block (hemiblock).

Fig. 12-37. WPW mimics inferior MI.

Fig. 12-38. Atrial fibrillation, normal ventricular rate.

Fig. 12-39. Severe myocardial ischemia. A 52-year-old female with angiographic proven severe obstructed coronary artery disease. Current ECG similar to 4 years prior and unchanged over 6 years. Received PTCA and stent at age 48.

Fig. 12-40. Electronic pacing; capture rate 66/min. Note the premature beat in V_1 is followed by a correctly timed paced QRS and indicates that the pacemaker is sensing correctly. The paced beat after the premature beat occurs at the correct pacing interval equal to the distance between the pacing spikes.

Fig. 12-41. RBBB and Q waves II, III, aVF: probable old inferior MI.

Fig. 12-42. A 41-year-old African male with long-standing restrictive cardiomyopathy. T wave changes caused by myocardial disease mimic LVH and ischemia. Borderline IVCD.

Fig. 12-43. Old anterior MI. Left atrial abnormality; APB, left axis, left anterior fascicular block (hemiblock).

Fig. 12-44. VPBs, bigeminy.

Fig. 12-45. A 2:1 AV block. Note the P-P intervals are constant. Computer interpreted as nonconducted APBs. ECG from a 44-year-old female with some shortness of breath, no presyncope. ECG tracing November 30, 2005. Note the heart rate, 43/min, is identical in a tracing done 1 year later, shown in Fig. 12-9. If the heart rate is <45/min, screen for bradycardias.

The differential diagnosis for marked bradycardia, slow rate of <45/min include:

- Sinus bradycardia
- Nonconducted APBs (bigeminy)
- Sinoatrial block (SA block)
- A variety of AV block (2:1 AV block, 3:1 block, complete AV block, and atrial fibrillation or flutter with complete AV block during which the ventricular rate becomes regular because of an idioventricular rhythm)

Fig. 12-46. Acute MI. Marked diffuse ST segment depression; note the ST elevation in aVR and little less so in V_1 , a clue to the diagnosis of left main coronary artery occlusion.

Fig. 12-47. Right atrial hypertrophy.

Fig. 12-48. Atrial flutter. Note: Usually there is little visible evidence of flutter waves in lead I; V_5 and V_6 also tend to be silent or may reveal negative P-like waves.

Fig. 12-49. LBBB in a man with mitral valve bioprosthesis >20 years duration, marked precordial rocky motion caused by left ventricular aneurysm.

Fig. 12-50. LVH, and ischemia, axis 50, left anterior hemiblock, IRBBB, in a 65-year-old man with severe aortic regurgitation.

Fig. 12-51. Old anterior and lateral MI; left atrial hypertrophy; left axis -60 , small q in I, small r in III: left anterior hemiblock.

Fig. 12-52. Complete heart block. Rate 38/min.

Fig. 12-53. Junctional tachycardia, rate 148/min. Note: P wave inverted in II, III, and aVF, positive in aVR, aVL.

Fig. 12-54. Atrial premature beats, with runs, also, junctional escape beats in V_4 – V_6 .

Fig. 12-55. RBBB with abnormal Q waves V_1 , V_2 , V_3 : old anterior MI; APB, left axis -75 , left anterior fascicular block (hemiblock).

Fig. 12-56. Left atrial hypertrophy: bifid P lead II, left atrial abnormality shown in V_1 . Right axis, small r wave in lead I, small q in lead III: indicates probable left posterior hemiblock.

Fig. 12-57. Sinus bradycardia 44/min. Left ventricular hypertrophy and left atrial hypertrophy. A 50-year-old Vietnamese female with well controlled very mild hypertension for 10 years; semigiant T wave inversion V_5 – V_6 is likely caused by apical hypertrophic cardiomyopathy as unlikely to be caused by very mild controlled hypertension. Echocardiogram shows some apical hypertrophy.

Fig. 12-58. RBBB; small Q in I, small r in III, and left axis -70 = left anterior fascicular block (hemiblock), atrial premature beat.

Fig. 12-59. Nonspecific ST-T wave changes and LVH. ECG 1-12-06 from a 69-year-old man. Very active exercise. From 1996 to 2004, he was able to walk 10 km without pain. ECG 1998, nonspecific ST-T wave changes: mild LVH and probable ischemia. During 2005, atypical chest ache, not related to exertion. Angiograms October 2005, 95% proximal LAD occlusion. Stented successfully. ECG during 2006 similar to 2004 through 2005. Note serious coronary disease with nonspecific ST-T wave changes.

Fig. 12-60. Acute anterior MI. ST elevation V_1 through V_4 (STEMI).

Fig. 12-61. WPW syndrome mimicking RBBB; ECG from a 26-year-old male. A good reason to assess for WPW early in the interpre-

tive sequence (Step 3) done soon after the assessment for RBBB and LBBB.

Fig. 12-62. Acute inferior MI (STEMI); abnormally shaped high ST segment in inferior leads. Note the reciprocal depression in leads I, aVL, V₁, V₂.

Fig. 12-63. Ventricular tachycardia.

Fig. 12-64. Anteroseptal MI; age indeterminate. ECG from a 60-year-old man; ECG done during annual assessment, silent MI; the patient had a normal ECG 1 year earlier.

Fig. 12-65. Extensive anterior MI in a 50-year-old female. Note ST elevation in 8 leads.

Fig. 12-66. A 2:1 AV block, IRBBB; erroneously read by computer as APBs nonconducted. Note: With second degree AV (type I or type II block), the PP interval remains constant and the P wave morphology is unchanged. Note the P waves stuck to the T waves are not premature in time, and with nonconducted APBs, the PP interval will vary. Nonconducted APBs should not be mistaken for second degree AV block and vice versa. A 2:1 AV block can be either type I or type II.

Fig. 12-67. Accelerated junctional rhythm; IRBBB.

Fig. 12-68. Sinus tachycardia 125/min; APB.

Fig. 12-69. Acute anterior MI (SEMI). Sinus bradycardia 49; ECG from a 39-year-old male.

Fig. 12-70. Old inferior MI. Note the Q waves in II, III, aVF may be interpreted as “non diagnostic inferior Q waves noted.” The tracing is similar to 5 years prior. ECG from a 55-year-old female with severe hyperlipidemia (total cholesterol >8 mmol/L, 300 mg/dL from age 20 to 30). She had a proven inferior MI at age 32 with typical inferior Qs. Subsequent angina and CABG. Stable for the past 15 years. LDL maintained <2.5 mmol/L past 20 years. Wide inferior Q waves have become narrower and less deep over a 5-year period postinfarction.

Fig. 12-71. Atrial flutter.

Fig. 12-72. Acute anterior MI (STEMI).

Fig. 12-73. Old inferior MI. Note the Q waves in II, III, and aVF are distinct and diagnostic (*see* Fig. 12-70).

Fig. 12-74. Apical hypertrophic cardiomyopathy. Note the giant T wave inversion in keeping with apical HCM seen mainly in Japanese people. Despite the sinister looking ECG with giant T waves and high precordial QRS voltage, an outflow tract gradient does not develop and the prognosis is good compared with obstructive HCM. ECG from an 80-year-old Vietnamese woman with minimal cardiac symptoms over 10 years, during which time the ECG remained similar.

Fig. 12-75. Atrial fibrillation, ventricular rate 140/min.

Fig. 12-76. Nonsustained ventricular tachycardia.

Fig. 12-77. **A** and **B.** Wide complex regular tachycardia, rapid rate 235 to 260/min. Computer incorrectly interpreted Holter record as ventricular runs. Note in **B** the tachycardia is triggered by an APB. The wide complex rapid rate suggests preexcited antidromic tachycardia. An accessory pathway was documented and ablation was successful in this 28-year-old with 3-year duration of recurrent palpitations. He had presented once to ER with atrial fibrillation, ventricular rate 160/min.

Fig. 12-78. Hypertrophic cardiomyopathy. Poor R wave progression V_2 – V_3 , nonspecific ST-T wave changes, borderline IVCD, left anterior hemiblock, left atrial hypertrophy.

A constellation of abnormal findings in a 51-year-old female with shortness of breath. Echocardiogram showed asymmetric septal hypertrophy, septal thickness 1.7 cm, posterior wall 1.4 cm, left atrium 5.0 cm, systolic anterior motion of the mitral valve (SAM) with leaflets touching the septum, resting outflow gradient 75 mmHg, increasing to 146 mmHg after amyl nitrate.

Fig. 12-79. APBs. Atrial bigeminy.

Fig. 12-80. Complete AV block. Ventricular rate 28/min.

Fig. 12-81. ECG from a 74-year-old man who presented with chest pain. The marked diffuse ST segment depression in 10 leads accompanied by ST elevation in aVR greater than in V_1 suggested probable acute left main coronary occlusion and proved true on coronary angiograms.

Fig. 12-82. RBBB: note the prolonged duration of the S wave in lead I, V_5 , V_6 , >30 ms.

Left axis -60 ; left anterior fascicular block.

Fig. 12-83. Sinus tachycardia 140/min. Non diagnostic inferior Q waves noted in a 31-year-old male with chest infection.

Fig. 12-84. ST segment elevation V_2 – V_5 (fish hook feature in V_3): normal variant in a 30 year old male.

Fig. 12-85. Tracing from a healthy 60-year-old female. Poor R wave progression V_2 , V_3 is a not uncommon finding caused by lead placement of V_2 , V_3 in females. Mimics a probable old anteroseptal MI.

Fig. 12-86. Sinus rhythm, RBBB; atrial premature beats nonconducted: These are a common cause of an unexpected pause. It is preferable to use the term non conducted APB rather than blocked APB.

Fig. 12-87. **A.** ECG from a 47-year-old man. Age corrected Sokolow index ($SV_1 + RV_5$ or $V_6 = 57$ mm, 5.7 mV). The abnormal ST–T

change in V3 and the abnormal coving of the ST segment in V4–V6 should prompt a diagnosis of ischemia. See Figure 12-87 B: definitely LVH.

12-87 B. LVH proven in a 50-year-old female with long duration hypertension. Note the so called typical “strain pattern” in V4 to V6: asymmetric ST segment depression; the T wave has a gradual descending and a steep ascending limb, a hallmark of LVH.

Fig. 12-88. RBBB, pathologic Q waves in V1–V4 indicates definite old anteroseptal MI.

In the presence of RBBB a q wave in V1–V2 may occur in the absence of MI. Also, the tracing shows left anterior fascicular block.

Fig. 12-89. Figure 12-82. WPW syndrome: changes mimic incomplete LBBB. The atypical bundle branch block, or conduction delay should prompt search for short PR and delta waves (I, II, aVL).

Fig. 12-90. RSR' in V1–V2 suggests incomplete RBBB, but there is no slurred or widened S wave (the S wave is not of prolonged duration) in leads I, V5 or V6 to indicate true RBBB. This should alert the interpreter to assess for atypical RBBB, a feature of Brugada syndrome. Scrutiny of the ST segment in V1, V2 reveals a coved and saddle-back deformity, characteristic features of the syndrome.

INDEX

A

- Acquired immunodeficiency syndrome (AIDS), 126, 163
- Action potentials, 1, 5, 27
- Acute coronary syndromes, 123t, 129
- Adenosine, intravenous, 277
- Alcohol abuse, as T wave inversion cause, 199
- Aneurysm, left ventricular, 52, 109, 123, 126, 127, 157
- Angina
 - Prinzmetal, 123
 - ST segment depression in, 130, 132
 - ST segment elevation in, 123, 125
 - unstable, 50, 133, 199
 - variant, 125
- Aortic coarctation, 93
- Arrhythmia, 249; *see also specific types of arrhythmia*
 - assessment, 28, 34, 35, 76, 76–77, 76–77t
 - cardiac electrical activity in, 4
 - digitalis toxicity-related, 232–233
 - lead aVR values in, 123t
 - in pulmonary embolism, 248
- Atrial bigeminy, 249
- Atrial fibrillation, 6
 - bundle branch block with, 292
 - diagnostic points, 281, 281–284
 - digitalis toxicity-related, 233
 - in hypothermia, 248
 - pseudo-inferior infarction with, 78, 172
 - in pulmonary embolism, 248
- Atrial flutter, 6, 76, 277, 291
 - differentiated from atrial tachycardia, 269
 - flecainide-related, 279
 - in pulmonary embolism, 248
 - sawtooth pattern, 277, 278–279, 280
 - sinus tachycardia as mimic of, 264
- Atrial hypertrophy
 - bilateral, 184
 - causes, 182, 184
 - diagnostic criteria, 181
 - guides to, 181–182
 - left
 - causes, 181
 - diagnostic criteria, 179–181
 - left ventricular hypertrophy with, 65, 184
 - P wave in, 63, 82, 84
 - P wave in, 33, 62, 62–63, 179, 180
 - right
 - causes, 182, 184
 - diagnostic criteria, 181
 - guides, 181–182
 - P wave in, 83, 85, 86, 145, 146, 181, 182
- Atrial premature beats, 249, 250–251, 252
 - multifocal, 270
 - nonconducted, 249, 250

- Atrial septal defect, 74, 98, 223
 new diagnostic sign of, 224, 225
 right bundle branch block in, 74, 224
 secundum, 74, 93
- Atrial tachycardia; *See* Tachycardia, atrial
- Atrial trigeminy, 250
- Atrioventricular block
 atrial tachycardia with, 269
 complete, digitalis toxicity-related, 232
 digitalis toxicity-related, 232, 233
 first-degree, 35, 232
 digitalis toxicity-related, 232
 in narrow QRS tachycardia, 275
 second-degree (Mobitz), 294
 digitalis toxicity-related, 232
 type II, 259, 260, 294
 type I (Wenckebach), 259, 259, 260
- Atrioventricular dissociation, 262, 290
- Atrioventricular nodal reentrant tachycardia (AVNRT), 264–267, 275, 276
 comparison with orthodromic circus movement tachycardia, 274, 277
 diagnostic points, 265, 265–267, 266, 267
- Atrioventricular node
 action potential, 5
 activation, 2
 electrical activity, 6
- Augmented leads, 14–15
- AVNRT; *see* Atrioventricular nodal reentrant tachycardia (AVNRT)
- B**
- β -blockers, 4, 5
- Bradyarrhythmias, 76–77
- first-degree atrioventricular block, 258
- second-degree atrioventricular block, 259, 259–260, 261
- third-degree atrioventricular block, 261, 261–262, 262
- Brugada syndrome, 88–89, 91, 93, 105
- Bundle branch block (BBB); *see also* Left bundle branch block (LBBB); Right bundle branch block (RBBB)
 atrial flutter with, 292
 QRS complex in, 35, 39
- C**
- CAD; *see* Coronary artery disease
- Cardiac enzymes, 128, 129
- Cardiomyopathy
 apical, T wave inversion in, 199, 205
 dilated (congestive), 269, 274
 hypertrophic, 24, 191
 poor R wave progression, 61
 Q wave in, 141–142, 163, 164, 168
 as left anterior fascicular block cause, 218
 as left bundle branch block cause, 105
 as right bundle branch block cause, 93
- Carotid sinus massage, 270, 275, 277, 279
- Catecholamines, in depolarization, 4, 5
- Cerebrovascular accidents, T waves, 206
- Chagas' disease, 93, 163, 218
- Chaotic atrial tachycardia; *see* Multifocal atrial tachycardia
- Chest electrodes-cardiac chamber relationship, 16, 18

- Chest trauma, as myocardial infarction mimic, 168
- Children
- Q waves in, 139
 - right ventricular hypertrophy diagnosis in, 191
- Chronic obstructive pulmonary disease (COPD); *see also* Emphysema
- differentiated from left anterior fascicular block, 218–219
 - multifocal (chaotic) atrial tachycardia in, 271, 271
 - P wave in, 145, 146
 - QRS complex in, 60–61, 145, 146
- Cocaine abuse
- as myocardial infarction cause, 154, 155
 - ST segment elevation in, 126
 - T wave inversion in, 199
- Congenital heart disease
- as right atrial hypertrophy cause, 182
 - as right bundle branch block cause, 93
- Congestive heart failure, 105, 274, 276
- COPD; *see* Chronic obstructive pulmonary disease
- Cornell voltage criteria, 185
- Coronary artery aneurysm, 156, 156
- Coronary artery disease (CAD), 125
- as left bundle branch block cause, 105, 106, 173
 - as right bundle branch block cause, 93
 - ST segment depression in, 130
- Coronary artery spasm, 52, 108, 123, 154
- Cor pulmonale, 83, 86, 93, 182
- D**
- Depolarization
- β -blocker effects, 4, 5
 - catecholamines effects, 4, 5
 - description, 1–2, 2, 3, 4
 - digoxin effects, 4, 5
 - ST segment in, 10
- Dextrocardia, 82
- diagnostic confirmation, 234
 - diagnostic criteria, 234, 235
 - diagnostic pitfalls, 234
 - mirror-image, 75–76
 - as right deviation electrical axis cause, 215
 - situs inversus with, 75–76, 234, 235
 - true, 234, 235
- Dextroposition, 191, 234, 236
- Digitalis
- action mechanism, 4
 - effects, 173, 232
 - toxicity, 4, 232–233, 233
 - as multifocal (chaotic) atrial tachycardia cause, 271
 - U waves, 207
- Digoxin
- in depolarization, 5
 - toxicity, 135
- Diuretics, as hypokalemia cause, 230
- Drugs; *see also names of specific drugs*
- as long QT interval cause, 228
- E**
- ECG; *see* Electrocardiogram
- Einthoven, 11–12
- Electrical activation
- current flows, 3
 - effects of, 3
 - vector forces in, 6, 7
- Electrical alternans, 228, 236, 237–238, 238, 239

- Electrical alternans (*cont.*)
 in orthodromic circus movement
 tachycardia, 276
 total, 236, 238
- Electrical axis
 assessment, 69, 70–72, 71t
 detection of, step-by-step
 method, 211, 211
 determination of, 209, 211
 leads in, 212t
 left deviation, 213, 213–214, 217
 range of, 213
 right deviation, 214–215,
 214–215
- Electrocardiogram (ECG)
 artifacts, 77
 definition, 7
 development, 11–12
 electrode positions, 12, 13, 14
 interpretation
 normal, 35
 normal interval, 28–30
 sequence, conventional,
 25–26
 sequence, new, 25–26
 step 1 (rhythm and rate), 29,
 32, 35, 36
 step 2 (intervals and block),
 2, 31, 32, 35–42, 38, 44
 step 3 (atypical BBB; WPW
 syndrome), 32, 44
 step 4 (ST segment), 33, 34,
 47–52, 107–109, 108
 step 5 (Q wave), 33, 34,
 52–62, 137, 138
 step 6 (P wave), 33, 62–63
 step 7 (ventricular
 hypertrophy), 33, 34,
 64, 64
 step 8 (T wave) 34, 64, 67,
 68, 70t, 194
 step 9 (electrical axis), 34, 60,
 69, 70–72, 70t, 211,
 211–212
 step 10 (miscellaneous
 conditions), 34, 72,
 73–76, 76–77t
 step 11 (assess arrhythmias),
 76–77, 76–77, 263
 step-by-step method, 25–80,
 62
 intervals, normal, 31
 Na⁺/K⁺ efflux, 4, 5, 27
 parameters, normal, 31
 recording speed, 77
 sequence switching in, 34–35
 technique, 77, 78–70
 vector forces, 6, 7
- Electrocardiography machines,
 modes of operation, 77
- Electrodes
 attachment, 77
 positioning, 12, 13, 14
 interchanged, 79
- Electronic pacing, 44, 72, 239
 atrial, 239, 242, 268
 atrioventricular sequence, 239,
 242
 battery failure, 246
 capture rate, 240
 demand mode, 243, 244, 245
 function, different modes, 243
 malfunctions, 243, 244–246
 ventricular, 239, 240–241
 capture, 239, 240, 241
 demand, 239, 244
 with ventricular pacing, 75
- Emphysema, 60–61, 145, 215
 as myocardial infarction mimic,
 60–61, 168, 169
 Q wave in, 158
- F**
- Fascicular block
 bifascicular, 219, 219–221
 left anterior (hemiblock),
 216–218
 causes, 218

- description, 216
 - diagnostic criteria, 217–218
 - electrical axis, 69, 72
 - left-deviated electrical axis, 214
 - patterns, 216
 - right bundle branch block
 - with, 175, 219
 - left posterior (hemiblock), 216, 218–219, 220–222
- F**
- Fibrosis, pulmonary, 86
 - Flecainide, as atrial flutter cause, 279
 - F wave, in atrial flutter, 279, 280
- G**
- Galvani, Luigi, 12
- H**
- Heart
- electrical activation, 1–6, 2, 3, 5
 - muscle mass, 7, 13
 - position
 - within equilateral triangle, 13
 - horizontal *versus* vertical, 62
 - rate
 - assessment, 37t
 - QT interval in, 73t
- Heart failure, right-sided, 248
- Hemorrhage
- intracranial, U waves in, 207
 - subarachnoid, 135, 205
- Hyperkalemia
- diagnostic criteria, 231, 232
 - T waves in, 206
- Hypertension, 206
- pulmonary, 83, 146
- Hypokalemia
- diagnostic criteria, 230–232
 - diuretics-related, 230
 - U waves in, 207
- Hypothermia, 247, 248
- I**
- Interventricular septum, hypertrophy, 24
 - Intraventricular conduction delay (IVCD), 46
 - nonspecific, 44, 105, 106
 - Ionic exchange, 5
 - Ischemia; *see* Myocardial ischemia
 - Ischemic heart disease, 218
- J**
- J deflection, in hypothermia, 247
 - Junctional or nodal premature beats, 252, 252–253
 - Junctional rhythm, P wave in, 84
- K**
- Kawasaki disease, 156, 156
- L**
- LBBB; *see* Left bundle branch block
- Leads
- augmented, 14–15
 - aVL, Q wave recordings, 139
 - aVR, 120, 121, 122, 123t
 - chest
 - in normal ECG, 28, 29
 - positioning, 77, 78
 - V₁ through V₂, 27
 - deflections recorded by, 13, 14
 - limb
 - normal, 82
 - standard (I, II, III), 15, 15–16
 - notching, 103
 - positioning, 77, 78
 - erroneous, 24, 60, 80
 - precordial, 16, 18
 - 12, necessity for, 12–14
- Left anterior descending coronary artery stenosis, 133, 155
- Left bundle branch block (LBBB)
- atypical configuration, 44, 105
 - causes, 105–106

- Left bundle branch block (LBBB)
 (*cont.*)
 diagnostic criteria, 99, 100
 ECG criteria, 36
 idiopathic, 106
 left ventricular, 109
 as myocardial infarction mimic,
 102, 168, 170, 171–173,
 174
 myocardial infarction with, 37
 notching in, 42–43, 103
 poor R wave progression in, 42,
 61, 144
 QRS complex in, 32, 36, 38,
 99–100, 100–102
 Q wave in, 144, 170, 171
 ST segment elevation in, 41, 52,
 102, 108, 109, 126, 172
 typical ECG features, 104
 vector forces, 100, 105
 ventricular hypertrophy with, 64,
 64
 Wolff-Parkinson-White
 syndrome as mimic of, 273
- Left coronary artery
 anomalous, 156
 occlusion, 48, 48, 120, 121
- Left ventricular aneurysm, 123,
 126, 127
- Left ventricular dysfunction/failure,
 105, 181
- Lewis, Thomas, 12
- Long QT interval
 causes, 228, 230
 in chronic renal disease, 229
 diagnostic criteria, 228, 229
- M**
- MI; *see* Myocardial infarction
- Mitral insufficiency, 271
- Mitral regurgitation, as atrial
 hypertrophy cause, 181
- Mitral stenosis
 as atrial hypertrophy cause, 181
 severe, 189
- Multifocal atrial tachycardia, 86,
 270–271, 271
- Myocardial infarction (MI)
 acute
 early diagnosis, 109
 mimics of, 102, 126
 R waves in, 119
 ST segment depression in,
 118
 ST segment elevation in, 108,
 110, 118
 age indeterminate, 57, 123
 anterior
 mimics of, 169
 poor R wave progression,
 146, 147
 Q waves in, 127, 148–149,
 150, 157
 ST segment elevation in, 108,
 111, 113, 115–116, 117,
 118, 127
 T wave inversion in, 119
 ventricular aneurysm with,
 126
 anteroapical
 poor R wave progression in,
 60
 ST segment elevation in, 111,
 112, 118
 anterolateral
 Q wave in, 23, 60, 168
 R wave in, 23, 60
 R wave loss in, 60
 ST segment elevation in, 57
 anteroseptal
 cocaine abuse-related, 155
 erroneous diagnosis, 61, 142,
 143
 mimics of, 168, 168
 poor R wave progression in,
 60, 142, 143
 Q wave in, 57, 147, 153,
 158

- right bundle branch block
 - with, 97, 99
 - ST segment elevation in, 111, 112, 118
- cocaine abuse-related, 154, 155
- definition, 23
- erroneous diagnosis,
 - nondiagnostic Q wave in, 152, 153
- inferior
 - acute, 78
 - cocaine abuse-related, 155
 - left anterior fascicular block with, 218
 - left bundle branch block, 174–175
 - mimics of, 44, 163, 163–167, 271, 272, 274
 - pseudo-, 78
 - Q wave in, 147, 151–152
 - right ventricular infarction with, 117
 - ST segment depression in, 117
 - ST segment elevation in, 109, 110, 111, 111, 117, 122
 - Wolff-Parkinson-White syndrome as mimic of, 44, 274
- inferoposterior, 158, 159, 160
- left bundle branch block as mimic of, 102
- left bundle branch block with, 37
- mimics of, 102, 124
- necrotic area, 23
- nonatheromatous cause, 154, 155, 156, 156
- non-Q wave, 48, 48, 50
- non-ST segment elevation, 33, 48, 48, 109, 127, 128, 129
- old
 - left anterior fascicular block with, 218
 - mimics of, 102, 126
 - Q wave in, 33, 52
- posterior
 - Q wave in, 158
 - R wave in, 161
 - tall R wave in, 111, 118
 - Q wave in, 23, 109, 146, 148–149
 - anterior, 157
 - inferior
 - mimics of, 147, 152, 163, 163–168, 168
 - location of infarction, 157
 - old, 33, 52, 55, 157
 - right bundle branch block and, 96–97
 - ST segment, 108
 - elevation (STEMI), 33, 47, 47
 - acute, 47, 47, 109, 112, 118, 146, 158
 - age indeterminate, 57, 123
 - anterior, 47, 47, 127, 148–149
 - anterolateral, 57, 109, 110, 111, 112
 - anteroseptal, 155, 111, 112
 - diagnostic criteria, 109, 110
 - early diagnosis of, 109
 - infarct size, 115, 120
 - inferior, 47, 48, 48, 110, 122, 155
 - lead aVR in, 120, 121, 122
 - mimics, 120, 123, 126
 - Q wave in, 146, 147, 150
 - wave patterns, 110–119
 - subendocardial, 120
 - true posterior, 191
 - T wave inversion in, 152, 199
- Myocardial ischemia, 50–51
 - mimic of, 124
 - ST segment in, 69, 129
 - T wave in, 198, 199

- Myocarditis
 in AIDS patients, 126, 163
 as left anterior fascicular block
 cause, 218
 Q wave in, 163, 163
 as right bundle branch block
 cause, 93
 T wave inversion in, 199
- Myxedema heart disease, 177, 177
- O**
- Osborn waves, 248
- P**
- Pacemakers; *see* Electronic pacing
- Paroxysmal atrial tachycardia, 268, 268–269
- Paroxysmal supraventricular tachycardia, 266
- Pericardial effusion, electrical alternans in, 238
- Pericarditis
 acute, features, 225–228
 diagnostic criteria, 225
 electrical alternans in, 237
 PR depression in, 74
 as right bundle branch block
 cause, 93
 ST segment depression in, 118
 ST segment elevation in, 74, 109, 123, 226, 227
 T wave inversion in, 199
- Pneumothorax, left-sided, 168
- P pulmonale, 145, 146
- Precordial leads, 16, 18
- PR interval, 7, 8
 assessment, 35
 in atrial premature beats, 249, 251
 in atrioventricular nodal reentrant tachycardia, 267
 in circus movement tachycardia, 276
 description, 9, 9
 in first-degree atrioventricular block, 35, 258
 in hyperkalemia, 230, 231
 in junctional or nodal premature beats, 252, 252
 in multifocal (chaotic) atrial tachycardia, 270
 normal, 31
 in paroxysmal atrial tachycardia, 270
 in second-degree atrioventricular block, 259, 259, 260, 261
 in ventricular premature beats, 254
 in Wolff-Parkinson-White syndrome, 271, 272, 274
- Prolonged QT syndrome, 72
- PR segment, in pericarditis, 225
- Pseudoinfarction, 142, 145
- Pulmonary embolism, 123t, 246, 247, 248
 QS pattern in, 168
 as right bundle branch block
 cause, 93
 ST segment elevation in, 126
- Pulmonary hypertension, 83, 146
- Pulmonary stenosis, 83
- P wave, 7, 8, 12
 abnormal, features, 81–83, 83, 84–86, 86
 absent, 86
 assessment, 33, 62–63, 62–63
 in atrial hypertrophy, 62, 62–63, 179, 180
 in atrial premature beats, 249, 250, 252
 in atrial tachycardia, 277
 in atrioventricular nodal reentrant tachycardia (AVNRT), 265, 267
 in bilateral atrial hypertrophy, 184

- in chronic obstructive pulmonary disease (COPD), 145, 146
 - in circus movement tachycardia, 265, 276
 - description, 8–9, 9
 - in first-degree atrioventricular block, 258
 - in hyperkalemia, 231
 - in junctional or nodal premature beats, 252, 252
 - in junctional rhythm, 84
 - in left atrial hypertrophy, 63, 82, 84
 - limb leads, 82–86
 - in multifocal (chaotic) atrial tachycardia, 270
 - in narrow QRS tachycardia, 275
 - normal, features, 81, 82
 - in normal vertical heart, 140
 - in paroxysmal atrial tachycardia, 268, 268
 - in persistent (incessant) atrial tachycardia, 269
 - in right atrial hypertrophy, 83, 85, 86, 181, 182
 - in right ventricular failure, 86
 - in right ventricular hypertrophy, 62, 63
 - in severe mitral stenosis, 189
 - in sinus tachycardia, 264
 - in third-degree atrioventricular block, 261, 261
 - in ventricular premature beats, 253, 254
 - in ventricular tachycardia, 290
 - in Wolff-Parkinson-White syndrome, 272, 276, 277
 - in atrial fibrillation, 281
 - in atrial flutter, 76
 - in atrial premature beats, 249, 252
 - in atrioventricular nodal reentrant tachycardia (AVNRT), 264, 265
 - in bundle branch block, 35, 39
 - in chronic obstructive pulmonary disease, 60–61, 145, 146
 - in circus movement tachycardia, 276
 - clockwise rotation, 22, 23
 - counterclockwise rotation, 22, 23
 - description, 9, 9–10
 - duration, 7, 8
 - in electrical alternans, 228
 - in electrical pacing, 239, 242
 - in first-degree atrioventricular block, 258
 - genesis, 20, 21
 - in hyperkalemia, 232
 - in junctional or nodal premature beats, 252
 - in left bundle branch block, 36, 38, 99–100, 100–102, 173
 - in left ventricular hypertrophy, 185
 - low-voltage
 - causes, 177
 - criteria, 176
 - in myxedema heart disease, 177
 - normal, 31
 - genesis, 39
 - with poor R wave progression, 145
 - variants, 22–24, 23, 142
 - in paroxysmal atrial tachycardia, 268, 268
 - in pericardial effusion, 238
 - in persistent (incessant) atrial tachycardia, 269
- Q**
- QR pattern, 62
 - QRS complex, 7, 8
 - abnormalities, 22–24
 - alternans of, 277

- QRS complex (*cont.*)
- in right bundle branch block, 36, 39, 40, 87–88, 88, 89–92, 93, 96
 - in right ventricular hypertrophy, 187, 188
 - rotation-related variations, 54–56
 - R wave as mimic of, 142
 - in second-degree atrioventricular block, 259, 259, 261
 - in supraventricular tachycardia, 266
 - in tachycardia, 262, 263, 264, 286–295
 - in third-degree atrioventricular block, 261, 261, 262, 262
 - in torsades de pointes, 295
 - in ventricular premature beats, 253, 254
 - in Wolff-Parkinson-White syndrome, 271, 272, 273, 284
- QS pattern, 62, 154, 163, 168, 168, 169
- QT interval
- assessment, 72, 73t
 - long
 - causes, 228, 230
 - in chronic renal disease, 229
 - diagnostic criteria, 228, 229
 - normal range, 229
- Quinidine, 207, 281
- Q wave
- abnormal pathologic, 61–62
 - in adolescents, 141
 - assessment, 33, 137, 138
 - counterclockwise rotation, 142, 142
 - in hypertrophic cardiomyopathy, 141–142, 163, 164, 168
 - inferior, 140, 153
 - in left bundle branch block, 144, 170, 171
 - in myocardial infarction, 23, 109
 - acute, 119, 146
 - anterior, 127, 148–149, 150, 157
 - anterolateral, 23, 60, 168
 - anteroseptal, 57, 147, 153, 158
 - diagnostic criteria, 146–147, 152
 - inferior, 48, 111, 147, 151–152
 - mimics of, 163, 163–168, 168
 - normal ECG in, 152
 - old, 33, 157
 - persistence of, 152
 - with right bundle branch block, 96
 - ST elevation myocardial infarction, 118–119, 119
 - in myocarditis, 126
 - nondiagnostic, 152, 153
 - normal, 24, 31
 - assessment, 137, 138
 - deep, 28, 29
 - depth, 139, 139–140, 140, 141
 - narrow, 29, 139, 139–140
 - parameters, 31t, 137, 139, 139–141
 - pathologic; *see* R wave, loss of pseudo-, 267, 272, 274
 - in pulmonary embolism, 246
 - in right ventricular infarction, 158, 159–160
 - small, 24, 28, 29
 - in ventricular septum infarction, 24
- R**
- RBBB; *see* Right bundle branch block
- Repolarization
- in sinoatrial node, 1, 3, 4, 5

- ST segment in, 10
- T wave in, 11
- Rhythm, assessment, 29, 32, 35, 36
- Right bundle branch block (RBBB), 87–99
 - atrial septal defect with, 74, 224
 - atypical configuration, 44, 105
 - Brugada syndrome of, 88–89, 91
 - causes, 93
 - complete, in pulmonary embolism, 246
 - diagnostic criteria, 87
 - ECG criteria, 36, 38
 - incomplete, 74, 90, 91, 93, 96
 - in pulmonary embolism, 246, 247
 - sinus tachycardia in, 97
 - left anterior fascicular block
 - with, 219, 220–222
 - mimics of, 266, 271
 - as myocardial infarction mimic, 32
 - myocardial infarction with, 96–97, 97, 99, 175–176, 176
 - in pulmonary embolism, 246, 247
 - QRS complex genesis in, 87–88, 88, 89–92, 93
 - QRS complex in, 32, 36, 38, 39, 40
 - right ventricular hypertrophy
 - and, 191
 - RSr' variant, 74, 93, 96, 98
 - typical, 90
- Right ventricular dysplasia, 94–95
- Right ventricular failure, P wave in, 86
- Romhilt-Estes scoring system, 187
- RR interval
 - in atrial fibrillation, 281, 281
 - in second-degree atrioventricular block, 259, 259, 260, 261
 - in third-degree atrioventricular block, 262
 - in torsades de pointes, 295
- R wave
 - in acute myocardial infarction, 119
 - in anterior myocardial infarction, 113
 - assessment, 138
 - in left anterior fascicular block, 72
 - in left ventricular hypertrophy, 64, 126
 - loss of, 52–62
 - in anterior myocardial infarction, 56, 59
 - in anteroseptal myocardial infarction, 56, 57
 - in myocardial infarction, 23
 - normal, 30, 31
 - notched, in left bundle branch block, 42–43
 - poor progression of, 60–61, 61
 - in anterior myocardial infarction, 146, 147
 - in left bundle branch block, 144
 - in pseudoinfarction, 142
 - as QRS complex mimic, 142
 - in right bundle branch block, 87, 90
- tall
 - description, 22
 - in left ventricular hypertrophy, 22, 65, 185
 - in posterior myocardial infarction, 111, 118, 161
 - in right ventricular hypertrophy, 66
 - in V₁ and V₂, 45t

- R wave (*cont.*)
 in Wolff-Parkinson-White syndrome, 42, 45, 271
 in ventricular tachycardia, 290
- R' wave, pseudo-, 266, 267
- S**
- Sick sinus syndrome, 283
- Sinoatrial node
 action potential, 1, 5
 depolarization, 2, 3, 6
 electrical activation, 1, 3, 20
 repolarization, 1, 3, 4, 5
- Sinus arrhythmia, 92
- Sinus bradycardia
 digitalis toxicity-related, 232
 in left bundle branch block, 101
- Sinus rhythm, 196
 in arrhythmogenic right ventricular dysplasia, 94
- Sinus tachycardia, 183, 258, 264, 264
 as atrial flutter mimic, 264
 in incomplete right bundle branch block, 97
 mimics of, 268
 in pericarditis, 225
 in pulmonary embolism, 246
 as supraventricular tachycardia mimic, 264
- Situs inversus, dextrocardia with, 75–76, 234, 235
- Sodium/potassium efflux, 4, 5, 27
- Sokolow-Lyon voltage criteria, 185
- Stokes-Adams attacks, 200
- ST segment, 8
 assessment, 33, 51, 107–109, 108
 benign, in healthy athlete, 197
 changes, nonspecific, 107, 129, 130–135
 depression, 107
 in angina, 132
 assessment, 108
 in coronary artery disease, 130
 digitalis-related, 232
 in hyperkalemia, 232
 in hypokalemia, 230, 230
 in left ventricular hypertrophy, 132, 184, 186, 186
 minor, 129
 minor, normal, 129
 in myocardial infarction
 acute, 118
 non-Q wave, 50
 non-ST segment elevation, 127
 in myocardial ischemia, 109, 129
 in pericarditis, 118, 123, 227
 in pulmonary embolism, 246
 in tachycardia, 50
 T wave inversion with, 198, 199, 200
 description, 8, 9, 10–11, 107
 elevation, 107, 197
 in angina, 123, 125
 assessment, 108
 in cocaine abuse, 126
 in coronary artery spasm, 52, 108, 123
 in hyperkalemia, 231, 232
 in hypothermia, 248
 in left bundle branch block, 41, 52, 108
 in left coronary artery occlusion, 48, 48, 120, 121
 in left ventricular aneurysm, 52, 123, 126, 127
 in myocardial infarction (STEMI), 47, 47
 acute, 109, 112, 118, 146, 158

- in acute anterior MI, 47, 47
 - in acute inferior MI, 47, 47, 48
 - age indeterminate, 57, 123
 - anterior, 127, 148–149
 - anterolateral, 57, 109, 110, 111, 112
 - anteroseptal, 111, 112, 155
 - inferior, 110, 122, 155
 - Q wave in, 146, 147, 150
- in myocarditis, 126
- normal variants, 51, 52, 52, 109, 110, 118, 120, 123, 124
- in pericarditis, 74, 123, 226, 227
- in Prinzmetal angina, 123
- in pulmonary embolism, 126, 247
- Q wave in, 57–59
- in right bundle branch block, 91
- in right ventricular infarction, 117, 158, 159
- with R wave loss, 57–58
- with T wave inversion, 202
- variations in shape, 114
- flat, 134, 135
- isoelectric
 - in myocardial infarction, 154, 157
 - in old inferior myocardial infarction, 54–56
 - with R wave loss, 54–56
- J (junction point), 10
- in myocardial infarction, 108
 - elevation (STEMI), 33, 47, 47
 - acute, 47, 47, 109, 112, 118, 146, 158
 - age indeterminate, 57, 123
 - anterior, 47, 47, 127, 148–149
 - anterolateral, 57, 109, 110, 111, 112
 - anteroseptal, 155, 111, 112
 - diagnostic criteria, 109, 110
 - early diagnosis of, 109
 - infarct size, 115, 120
 - inferior, 47, 48, 48, 110, 122, 155
 - lead aVR in, 120, 121, 122
 - mimics, 120, 123, 126
 - Q wave in, 146, 147, 150
 - wave patterns, 110–119
 - in myocardial ischemia, 69, 109, 129
 - normal, 31
 - in ventricular premature beats, 253, 254
- Subarachnoid hemorrhage, 135, 205
- Sudden cardiac death, 88
- Supraventricular arrhythmia,
 - diagnostic clues, 284, 285
- Supraventricular tachycardia, 264
 - electrical alternans in, 237
 - paroxysmal, 265
 - QRS complex in, 266
 - sinus tachycardia as mimic of, 264
- S wave
 - pseudo-, 266, 266, 275
 - in right bundle branch block, 74, 87, 89, 90
 - in right ventricular hypertrophy, 187
 - wide, 41
- T**
- Tachycardia
 - antidromic, 277
 - atrial, 76, 276
 - as atrial premature beat trigger, 249, 251

- Tachycardia (*cont.*)
- differentiated from atrial flutter, 269
 - digitalis toxicity-related, 232
 - multifocal (chaotic), 86, 270–271, 271
 - paroxysmal, 268, 268–269
 - persistent (incessant), 269–270, 274, 276, 277
 - atrioventricular junctional, 268
 - atrioventricular nodal reentrant (AVNRT), 264–267, 275, 276
 - comparison with orthodromic circus movement tachycardia, 274, 277
 - diagnostic points, 265, 265–267, 266, 267
 - circus movement, 265, 267, 274, 276
 - antidromic, 286, 291–292, 292, 293
 - concealed accessory pathway in, 276
 - orthodromic, 76, 274, 276, 277
 - narrow QRS, 76, 76, 262, 263, 264
 - differential diagnosis, 275–277
 - orthodromic, 277
 - reentrant junctional, 279
 - ST segment depression in, 50
 - ventricular, 253, 286
 - diagnostic clues, 287
 - ECG hallmarks, 288
 - nonsustained, 256, 257
 - with right ventricular dysplasia, 95
 - wave patterns, 289–290
 - wide QRS complex in, 76, 76, 262, 263, 264
 - irregular, 292–294, 292–295
 - regular, 286, 287–291, 292
- Tetralogy of Fallot, 93
- Theophylline, as multifocal (chaotic) atrial tachycardia cause, 271
- Thrombolytic therapy, 118–119, 120, 151–152, 153
- Torsades de pointes, 228, 292, 293, 294, 295
- Tricuspid stenosis, 83
- Tricyclic antidepressants, as long QT interval cause, 228
- Tumors, cardiac, T wave inversion in, 199
- T wave, 7, 8, 193–207
 - alternans of, 237
 - in apical cardiomyopathy, 199, 205
 - assessment, 34, 64, 67, 68, 194
 - in atrial premature beats, 249, 250, 252
 - changes, causes for, 11
 - description, 8, 9, 11
 - in healthy athlete, 197
 - in hyperkalemia, 206, 230, 231
 - in hypokalemia, 230
 - inverted, 68, 69, 198–199, 198–202, 200, 206
 - with flat ST segment, 135
 - in left ventricular hypertrophy, 184
 - in myocardial infarction, 57, 152
 - anterior, 119, 150
 - anterolateral, 154
 - old, 60, 157
 - in myocardial ischemia, 129
 - with nonspecific ST segment changes, 129
 - in unstable inversion, 133
 - in left ventricular hypertrophy, 199, 203–204
 - normal, 31

- normal direction, 193, 195
 - normal height, 206
 - in normal vertical heart, 140
 - in pulmonary embolism, 246, 247
 - relationship with ST segment, 10–11, 197
 - in sinus tachycardia, 264
 - tall, 197, 199, 206
 - in right ventricular hypertrophy, 187
 - in Wolff-Parkinson-White syndrome, 162
 - in ventricular tachycardia, 291
 - “T wave,” elevated (Osborn wave), 248
- U**
- U wave
 - abnormal, 207
 - causes, 207
 - description, 11
 - in hyperkalemia, 230, 231
 - normal, 206, 207
- V**
- Vector forces, 14, 20–22
 - definition, 20
 - I, 21, 21, 39, 42–43
 - II, 21, 21–22, 39, 42–43
 - III, 21, 22, 39, 42–43
 - in left bundle branch block, 100, 105
 - Venous return, anomalous, 225
 - Ventricular bigeminy, 255
 - Ventricular capture, 75
 - Ventricular fibrillation, idiopathic, 88
 - Ventricular hypertrophy
 - assessment, 33, 64
 - left, 188
 - assessment, 33, 64, 64, 65
 - Cornell voltage criteria, 185
 - diagnostic criteria, 184
 - diagnostic pitfalls, 187
 - left atrial hypertrophy with, 184
 - as myocardial infarction mimic, 163, 168
 - in patients over 35 years of age, 184, 186
 - poor R wave progression in, 60
 - Q wave in, 170
 - Romhilt-Estes scoring system, 187
 - Sokolow-Lyon voltage criteria, 185
 - ST segment depression in, 132
 - tall R waves in, 22, 65
 - T wave inversion in, 199, 203–204
 - vector II factors, 185
 - right
 - assessment, 33, 64, 64
 - diagnostic criteria, 187, 191
 - diagnostic pitfalls, 191
 - differentiated from left anterior fascicular block, 218–219
 - P wave in, 62, 63, 83
 - as right atrial hypertrophy cause, 184
 - R wave in, 22, 66
 - wave patterns, 188–190
 - Ventricular infarction, right
 - with inferior myocardial infarction, 117
 - Q wave in, 158, 159–160
 - ST segment elevation in, 117
 - Ventricular premature beats
 - diagnostic points, 253, 257
 - digitalis toxicity-related, 232
 - with intraventricular conduction delay, 46

- multifocal, 253, 257, 257
- PR interval in, 254
- P wave in, 253, 254
- “rabbit ear,” 253, 254
- right, 260
- ventricular bigeminy, 255
- Ventricular septal defect, 93
- Ventricular septum
 - activation, 21–22
 - infarction, Q waves in, 24
- V (precordial) leads, 16, 18
- W**
- Wernicke phenomenon, in
 - paroxysmal atrial tachycardia, 269, 270
- Wilson, Frank, 12
- Wolff-Parkinson-White syndrome, 76
 - antidromic, 277
 - circus movement, 267, 272, 274
 - antidromic, 286, 291–292, 292
 - orthodromic, 277
 - comparison with left bundle branch block, 273
 - diagnostic criteria, 271–272
 - ECG assessment, 42, 44
 - electrical alternans in, 237
 - as inferior myocardial infarction mimic, 44, 163, 165–167
 - as left bundle branch block mimic, 273
 - as myocardial infarction mimic, 271
 - orthodromic, 276, 277
 - PR interval in, 272
 - pseudo- Q wave in, 165
 - P wave in, 276
 - QRS complex in, 32, 42, 44, 291
 - as right bundle branch block mimic, 96, 271
 - right ventricular hypertrophy and, 191
 - tachycardia in, 272
 - tall R wave in, 45
 - type B, 273
 - ventricular response, 279
- Women, poor R wave progression in, 142, 143