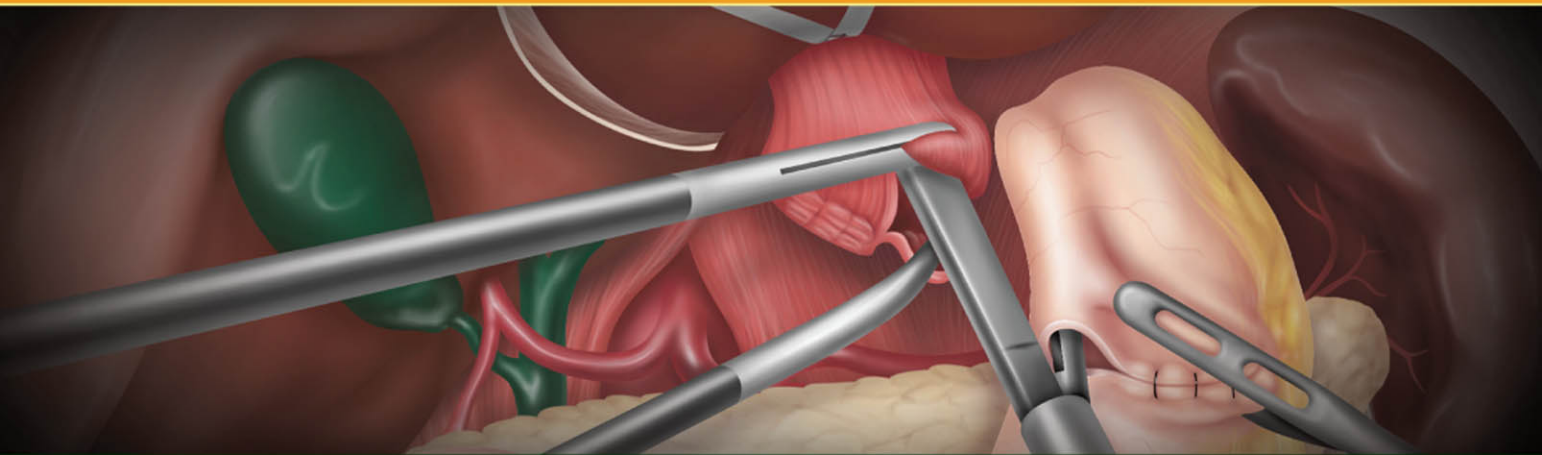


12<sup>TH</sup> EDITION

MAINGOT'S  
ABDOMINAL  
OPERATIONS



MICHAEL J. ZINNER  
STANLEY W. ASHLEY

*Maingot's*  
ABDOMINAL  
OPERATIONS



### **Notice**

Medicine is an ever-changing science. As new research and clinical experience broaden our knowledge, changes in treatment and drug therapy are required. The authors and the publisher of this work have checked with sources believed to be reliable in their efforts to provide information that is complete and generally in accord with the standards accepted at the time of publication. However, in view of the possibility of human error or changes in medical sciences, neither the authors nor the publisher nor any other party who has been involved in the preparation or publication of this work warrants that the information contained herein is in every respect accurate or complete, and they disclaim all responsibility for any errors or omissions or for the results obtained from use of the information contained in this work. Readers are encouraged to confirm the information contained herein with other sources. For example and in particular, readers are advised to check the product information sheet included in the package of each drug they plan to administer to be certain that the information contained in this work is accurate and that changes have not been made in the recommended dose or in the contraindications for administration. This recommendation is of particular importance in connection with new or infrequently used drugs.

# *Maingot's* ABDOMINAL OPERATIONS

*Twelfth Edition*

Editors

**Michael J. Zinner, MD, FACS**

Moseley Professor of Surgery  
Harvard Medical School  
Clinical Director  
Dana-Farber/Brigham and Women's Cancer Center  
Surgeon-in-Chief  
Brigham and Women's Hospital  
Boston, Massachusetts

**Stanley W. Ashley, MD, FACS**

Frank Sawyer Professor of Surgery  
Harvard Medical School  
Chief Medical Officer  
Senior Vice President for Medical Affairs  
Brigham and Women's Hospital  
Boston, Massachusetts



New York Chicago San Francisco Lisbon London Madrid Mexico City Milan  
New Delhi San Juan Seoul Singapore Sydney Toronto

Copyright © 2013 by The McGraw-Hill Companies, Inc. All rights reserved. Except as permitted under the United States Copyright Act of 1976, no part of this publication may be reproduced or distributed in any form or by any means, or stored in a database or retrieval system, without the prior written permission of the publisher.

ISBN: 978-0-07-163987-3

MHID: 0-07-163987-X

The material in this eBook also appears in the print version of this title: ISBN: 978-0-07-163388-8, MHID: 0-07-163388-X.

All trademarks are trademarks of their respective owners. Rather than put a trademark symbol after every occurrence of a trademarked name, we use names in an editorial fashion only, and to the benefit of the trademark owner, with no intention of infringement of the trademark. Where such designations appear in this book, they have been printed with initial caps.

McGraw-Hill eBooks are available at special quantity discounts to use as premiums and sales promotions, or for use in corporate training programs. To contact a representative please e-mail us at [bulksales@mcgraw-hill.com](mailto:bulksales@mcgraw-hill.com).

Previous editions copyright © 2007 by The McGraw-Hill Companies, Inc., and copyright © 1997 by Appleton & Lange.

#### TERMS OF USE

This is a copyrighted work and The McGraw-Hill Companies, Inc. (“McGraw-Hill”) and its licensors reserve all rights in and to the work. Use of this work is subject to these terms. Except as permitted under the Copyright Act of 1976 and the right to store and retrieve one copy of the work, you may not decompile, disassemble, reverse engineer, reproduce, modify, create derivative works based upon, transmit, distribute, disseminate, sell, publish or sublicense the work or any part of it without McGraw-Hill’s prior consent. You may use the work for your own noncommercial and personal use; any other use of the work is strictly prohibited. Your right to use the work may be terminated if you fail to comply with these terms.

THE WORK IS PROVIDED “AS IS.” McGRAW-HILL AND ITS LICENSORS MAKE NO GUARANTEES OR WARRANTIES AS TO THE ACCURACY, ADEQUACY OR COMPLETENESS OF OR RESULTS TO BE OBTAINED FROM USING THE WORK, INCLUDING ANY INFORMATION THAT CAN BE ACCESSED THROUGH THE WORK VIA HYPERLINK OR OTHERWISE, AND EXPRESSLY DISCLAIM ANY WARRANTY, EXPRESS OR IMPLIED, INCLUDING BUT NOT LIMITED TO IMPLIED WARRANTIES OF MERCHANTABILITY OR FITNESS FOR A PARTICULAR PURPOSE. McGraw-Hill and its licensors do not warrant or guarantee that the functions contained in the work will meet your requirements or that its operation will be uninterrupted or error free. Neither McGraw-Hill nor its licensors shall be liable to you or anyone else for any inaccuracy, error or omission, regardless of cause, in the work or for any damages resulting therefrom. McGraw-Hill has no responsibility for the content of any information accessed through the work. Under no circumstances shall McGraw-Hill and/or its licensors be liable for any indirect, incidental, special, punitive, consequential or similar damages that result from the use of or inability to use the work, even if any of them has been advised of the possibility of such damages. This limitation of liability shall apply to any claim or cause whatsoever whether such claim or cause arises in contract, tort or otherwise.



Contributors ix  
Preface xvii

## **I** INTRODUCTION 1

1. A Focused History of Surgery 3  
*Seymour I. Schwartz*
2. Preoperative and Postoperative Management 7  
*Zara Cooper / Edward Kelly*
3. Endoscopy and Endoscopic Intervention 31  
*Jeffrey M. Marks / Jeffrey L. Ponsky*
4. Fundamentals of Laparoscopic Surgery 63  
*Ashley H. Vernon / John G. Hunter*
5. Laparoscopic Staging and Approaches to Cancer 75  
*Kevin C. Conlon / Tom K. Gallagher*

## **II** ABDOMINAL WALL 97

6. Incisions, Closures, and Management of the Abdominal Wound 99  
*Robert E. Roses / Jon B. Morris*
7. Hernias 123  
*Patrick J. Javid / Jacob A. Greenberg / David C. Brooks*
8. Perspective on Hernias 157
  - A) Laparoscopic Incisional Hernia 157  
*Alex Escalona / David W. Rattner*
  - B) Laparoscopic Inguinal Hernia Repair 160  
*Lokesh Bathla / Robert J. Fitzgibbons, Jr.*
9. Intestinal Stomas 163  
*Ira J. Kodner / Thomas E. Read / Donna L. Loehner*

## 10. Abdominal Abscess and Enteric Fistulae 197

*Patrick S. Tawadros / Jory Simpson / Josef E. Fischer / Ori D. Rotstein*

11. Gastrointestinal Bleeding 217  
*Anita Balakrishnan / Ali Tavakkoli / Stanley W. Ashley*
12. Management of Abdominal Trauma 239  
*L. D. Britt / Robert A. Maxwell*
13. Abdominal Vascular Emergencies 261  
*John J. Ricotta / Cameron M. Akbari*

## **III** ESOPHAGUS 289

14. Benign Esophageal Disorders 291  
*Saurabh Khandelwal / Brant K. Oelschlager*
15. Gastroesophageal Reflux Disease and Hiatal Hernia (Including Paraesophageal) 319  
*Toshitaka Hoppo / Shamus R. Carr / Blair A. Jobe*
16. Perspective on Benign Esophageal Disease 351  
*John G. Hunter / Erin Gilbert*
17. Cancer of the Esophagus 355  
*Simon Law*
18. Surgical Procedures to Resect and Replace the Esophagus 389  
*Jon O. Wee / David J. Sugarbaker*
19. Video-Assisted Thoracic Surgery of the Esophagus 413  
*Ryan M. Levy / James D. Luketich*
20. Perspective on Malignant Esophageal Disease 433  
*A) Thomas R. DeMeester B) Lee L. Swanstrom*

## **IV** STOMACH AND DUODENUM 441

### 21. Benign Gastric Disorders 443

*Ian S. Soriano / Daniel T. Dempsey*

### 22. Gastric Adenocarcinoma and Other Gastric Neoplasms (Except Gastrointestinal Stromal Tumors) 463

*John T. Langell / Sean J. Mulvihill*

### 23. Perspective on Gastric Cancer 489

*Mitsuru Sasako / Hisashi Shinohara*

### 24. Gastrointestinal Stromal Tumors 493

*Chandrajit P. Raut*

### 25. Perspective on Gastrointestinal Stromal Tumors 507

*Ronald P. DeMatteo*

### 26. Stomach and Duodenum: Operative Procedures 509

*David I. Soybel / Michael J. Zinner*

### 27. Morbid Obesity and Its Surgical Treatment 545

*Bruce Schirmer / Peter Hallowell*

### 28. Perspective on Morbid Obesity and Its Surgical Treatment 579

*Stacy A. Brethauer / Philip R. Schauer*

## **V** INTESTINE AND COLON 583

### 29. Small Bowel Obstruction 585

*Guido M. Sclabas / George A. Sarosi / Saboor Khan / Michael G. Sarr / Kevin E. Behrns*

### 30. Tumors of the Small Intestine 611

*Craig Fischer / Barbara Lee Bass*

### 31. Appendix, Meckel's, and Other Small Bowel Diverticula 623

*William H. Peranteau / Douglas S. Smink*

### 32. Diverticular Disease and Colonic Volvulus 649

*Thang C. Nguyen / Frank A. Frizelle*

### 33. Crohn's Disease 665

*Fabrizio Michelassi / Roger D. Hurst / Alessandro Fichera*

### 34. Ulcerative Colitis 693

*Shawn Forbes / David Messenger / Robin S. McLeod*

### 35. Perspective on Inflammatory Bowel Disease 725

*A) Anthony J. Senagore B) Patricia L. Roberts*

### 36. Tumors of the Colon 731

*Andreas M. Kaiser / David Etzioni / Robert W. Beart Jr.*

### 37. Laparoscopic Colorectal Procedures 767

*Rajesh Pendlimari / Heidi Nelson*

### 38. Perspective on Colonic Neoplasms 795

*A) José G. Guillem / Jeannine A. Ruby B) David J. Schoetz, Jr.*

## **VI** RECTUM AND ANUS 801

### 39. Benign Disorders of the Anorectum (Pelvic Floor, Fissures, Hemorrhoids, and Fistulas) 803

*Anne Y. Lin / James W. Fleshman, Jr.*

### 40. Cancer of the Rectum 833

*Joel Goldberg / Ronald Bleday*

### 41. Perspective on Rectal Cancer 869

*A) Julio Garcia-Aguilar B) Mark Welton*

### 42. Cancer of the Anus 879

*Joshua I. S. Bleier / Najjia N. Mahmoud / Robert D. Fry*

## **VII** LIVER 899

### 43. Hepatic Abscess and Cystic Disease of the Liver 901

*Kathleen K. Christians / Henry A. Pitt*

### 44. Benign and Malignant Primary Liver Neoplasms 927

*Clifford S. Cho / Yuman Fong*

### 45. Hepatic Colorectal Metastases: Resection, Pumps, and Ablation 955

*Michael A. Choti*

### 46. Perspective on Liver Surgery 969

*A) Steven A. Curley B) Richard S. Swanson*

### 47. Portal Hypertension 981

*J. Michael Henderson*

## **VIII** GALLBLADDER AND BILE DUCTS 993

48. Cholecystitis and Cholelithiasis 993  
*Edward D. Auyang / Nathaniel J. Soper*
49. Choledocholithiasis and Cholangitis 1009  
*Antonio di Carlo / David W. McFadden*
50. Choledochal Cyst and Benign Biliary Strictures 1029  
*Purvi Y. Parikh / Keith D. Lillemoe*
51. Cancer of the Gallbladder and Bile Ducts 1061  
*Edward E. Whang / Mark Duxbury / Flavio G. Rocha / Michael J. Zinner*
52. Laparoscopic Biliary Procedures 1077  
*Jin S. Yoo / Theodore N. Pappas*
53. Perspective on Biliary Diseases 1089  
*A) Douglas W. Hanto B) Steven M. Strasberg*

## **IX** PANCREAS 1095

54. Management of Acute Pancreatitis 1097  
*Thomas E. Clancy / Stanley W. Ashley*
55. Complications of Acute Pancreatitis (Including Pseudocysts) 1119  
*John A. Windsor / Benjamin P. T. Loveday*

56. Chronic Pancreatitis 1147  
*Marshall S. Baker / Jeffrey B. Matthews*
57. Perspective on Management of Patients with Severe Acute Pancreatitis 1167  
*Timothy R. Donahue / Howard A. Reber*
58. Cystic Neoplasms of the Pancreas 1171  
*Warren R. Maley / Charles J. Yeo*
59. Cancers of the Periampullary Region and the Pancreas 1187  
*Christopher L. Wolfgang / Richard D. Schulick / John L. Cameron*
60. Endocrine Tumors of the Pancreas 1211  
*Taylor S. Riall / B. Mark Evers*
61. Perspective on Pancreatic Neoplasms 1227  
*A) Douglas B. Evans B) Andrew L. Warshaw*

## **X** SPLEEN AND ADRENAL 1237

62. The Spleen 1239  
*Ali Tavakkoli*
63. Adrenalectomy 1271  
*Matthew A. Nehs / Atul A. Gawande / Francis D. Moore, Jr. / Daniel T. Ruan*
- Index 1283



*This page intentionally left blank*

# CONTRIBUTORS

**Cameron M. Akbari, MD, MBA, FACS**

Senior Attending Physician, Vascular Surgery  
Director, Vascular Diagnostic Laboratory  
MedStar Washington Hospital Center  
Washington, DC

**Stanley W. Ashley, MD, FACS**

Chief Medical Officer  
Senior Vice President for Medical Affairs  
Brigham and Women's Hospital  
Frank Sawyer Professor of Surgery  
Harvard Medical School  
Boston, Massachusetts

**Edward D. Auyang, MD, MS**

Assistant Professor of Surgery  
Department of Surgery  
University of New Mexico School of Medicine  
Albuquerque, New Mexico

**Marshall S. Baker, MD, MBA**

Assistant Clinical Professor of Surgery  
University of Chicago, Pritzker School of Medicine  
NorthShore University Health System  
Evanston, Illinois

**Anita Balakrishnan, BMedSci (Hons), BMBS, MRCS**

Research Fellow, Brigham and Women's Hospital and Harvard  
Medical School  
Specialist Registrar in General Surgery  
East of England Deanery  
United Kingdom

**Barbara Lee Bass, MD**

Bookout Distinguished Endowed Chair  
Chair, The Methodist Hospital Department of Surgery  
Houston, Texas  
Professor of Surgery  
Weill Cornell Medical College  
New York, New York

**Lokesh Bathla, MD**

Fellow, Section of Transplant Surgery  
Department of Surgery  
University of Nebraska Medical Center  
Omaha, Nebraska

**Robert W. Beart, Jr., MD, FACS, FASCRS**

Professor Emeritus  
Colorectal Institute  
Glendale Memorial Hospital  
Glendale, California

**Kevin E. Behrns, MD**

Edward R. Woodward Professor  
Chairman of Surgery  
University of Florida  
Gainesville, Florida

**Ronald Bleday, MD**

Chief, Section of Colon and Rectal Surgery  
Brigham and Women's Hospital Boston  
Associate Professor of Surgery, Harvard Medical School  
Brigham and Women's Hospital  
Boston, Massachusetts

**Joshua I. S. Bleier, MD, FACS, FASCRS**

Assistant Professor of Surgery  
Division of Colon and Rectal Surgery  
University of Pennsylvania Health System  
Hospital of the University of Pennsylvania  
Philadelphia, Pennsylvania

**L. D. Britt, MD, MPH, FACS, FCCM, FRCS Eng (Hon), FRCS  
Ed (Hon), FWACS (Hon), FRCSI (Hon), FCS (SA) (Hon)**

Brickhouse Professor and Chairman  
Department of Surgery  
Eastern Virginia Medical School  
Norfolk, Virginia

**David C. Brooks, MD**

Associate Professor of Surgery  
Harvard Medical School  
Brigham and Women's Hospital  
Division of General/GI Surgery  
Boston, Massachusetts

**John L. Cameron, MD, FACS**

Alfred Blalock Distinguished Service Professor  
Department of Surgery  
The Johns Hopkins Medical Institutions  
Baltimore, Maryland

**Shamus R. Carr, MD**

Assistant Professor of Surgery  
University of Utah and Huntsman  
Cancer Institute  
Salt Lake City, Utah

**Clifford S. Cho, MD**

Assistant Professor  
Section of Surgical Oncology  
University of Wisconsin School of  
Medicine and Public Health  
Madison, Wisconsin

**Michael A. Choti, MD, MBA, FACS**

Jacob C. Handelsman Professor of Surgery  
Vice Chair, Department of Surgery  
Johns Hopkins University  
Baltimore, Maryland

**Kathleen K. Christians, MD**

Medical College of Wisconsin  
Department of General Surgery  
Milwaukee, Wisconsin

**Thomas E. Clancy, MD**

Associate Surgeon  
Brigham and Women's Hospital  
Assistant Professor of Surgery  
Harvard Medical School,  
Boston, Massachusetts

**Kevin C.P. Conlon, MA, MCh,  
MBA, FRCSI, FACS, FRCS, FTCD**

Professor of Surgery  
The University of Dublin  
Trinity College  
Dublin, Ireland

**Zara Cooper, MD, MSc, FACS**

Assistant Professor of Surgery  
Brigham and Women's Hospital  
Boston, Massachusetts

**Steven A. Curley, MD, FACS**

Professor of Surgical Oncology  
Charles Barker Endowed Chair in Surgical Oncology  
Chief, Gastrointestinal Tumor Surgery  
The University of Texas M.D. Anderson Cancer Center  
Houston, Texas

**Ronald P. DeMatteo, MD**

Vice Chair, Department of Surgery  
Chief, Division of Surgical Oncology  
Leslie H. Blumgart Chair in Surgery  
Memorial Sloan-Kettering Cancer Center  
New York, New York

**Thomas R. DeMeester, MD**

Emeritus Professor and Chairman  
Department of Surgery  
University of Southern California  
Los Angeles, California

**Daniel T. Dempsey, MD**

Professor of Surgery  
Chief of Gastrointestinal Surgery  
Assistant Director of Perioperative Services  
Hospital of the University of Pennsylvania  
Philadelphia, Pennsylvania

**Antonio di Carlo, MD, CM, FRCSC, FACS**

Associate Professor of Surgery  
University of Vermont  
Director of Hepatobiliary Surgery  
Fletcher Allen Health Care  
Burlington, Vermont

**Timothy R. Donahue, MD**

Assistant Professor of Surgery, and Molecular and Medical  
Pharmacology  
David Geffen School of Medicine  
University of California at Los Angeles  
Los Angeles, California

**Mark S. Duxbury, MA, DM, FRCS Ed (Gen Surg)**

Clinician Scientist & Honorary Consultant  
Hepatobiliary and Pancreatic Surgeon  
Clinical Surgery  
University of Edinburgh  
Royal Infirmary  
Edinburgh, United Kingdom

**Alex Escalona, MD**

Assistant Professor  
Department of Digestive Surgery  
Faculty of Medicine  
Pontificia Universidad Católica de Chile  
Santiago, Chile

**David Etzioni, MD, MPH**

Associate Professor  
Mayo Clinic  
Phoenix, Arizona

**Douglas B. Evans, MD**

Donald C. Ausman Family Foundation  
Professor of Surgery  
Chairman, Department of Surgery  
Medical College of Wisconsin  
Milwaukee, Wisconsin

**B. Mark Evers, MD**

Director, Markey Cancer Center  
Professor and Vice-Chair for Research, University of Kentucky  
Department of Surgery  
Physician-in-Chief, Oncology Service Line  
University of Kentucky  
Lexington, Kentucky

**Alessandro Fichera, MD**

Professor of Surgery  
University of Washington  
Seattle, Washington

**Craig P. Fischer, MD**

Chief, Surgical Oncology  
Associate Professor of Surgery  
Weill Medical College of Cornell University  
New York, New York  
Department of Surgery  
The Methodist Hospital  
Houston, Texas

**Josef E. Fischer, MD, FACS**

William V. McDermott Professor of Surgery  
Harvard Medical School  
Boston, Massachusetts

**Robert J. Fitzgibbons, Jr., MD, FACS**

Harry E. Stuckenhoff Professor of Surgery  
Chief of the Division of General Surgery and  
Associate Chairman  
Department of Surgery  
Creighton University School of Medicine  
Omaha, Nebraska

**James W. Fleshman, Jr., MD**

Professor of Surgery  
Chief of Colon and Rectal Surgery  
Washington University in St Louis  
Chief of Surgery, Barnes Jewish West County Hospital  
St. Louis, Missouri

**Yuman Fong, MD**

Murray F. Brennan Chair in Surgery  
Memorial Sloan-Kettering Cancer Center  
Professor of Surgery  
Weill-Cornell Medical College  
New York, New York

**Shawn Forbes, MD, MSc, FRCS**

Resident in Colorectal Surgery  
University of Toronto  
Toronto, Ontario, Canada

**Frank A. Frizelle, MBChB,  
MMedSc, FRACS, FACS, FNZMA**

Professor/Head of University Department of Surgery  
University of Otago; Christchurch  
Christchurch, New Zealand

**Robert D. Fry, MD**

Emilie & Roland deHellebranth Professor of Surgery  
Chairman, Department of Surgery, Pennsylvania Hospital  
Chief, Division of Colon and Rectal Surgery  
University of Pennsylvania Health System  
Philadelphia, Pennsylvania

**Tom K. Gallagher, MCh, MRCS**

Specialist Registrar in Hepatobiliary Surgery  
Department of Surgery, Adelaide & Meath Hospital  
incorporating the National Children's Hospital, Tallaght  
Dublin, Ireland

**Julio Garcia Aguilar, MD, PhD**

Chief, Colorectal Service  
Department of Surgery  
Memorial Sloan-Kettering Cancer Center  
New York, New York

**Atul Gawande, MD, MPH**

Surgeon, Brigham and Women's Hospital  
Professor, Harvard Medical School and Harvard  
School of Public Health  
Boston, Massachusetts

**Joel Goldberg, MD, FACS**

Colon and Rectal Surgery  
Brigham and Women's Hospital  
Dana Farber Cancer Institute  
Gastrointestinal Cancer Center  
Harvard Medical School  
Boston, Massachusetts

**Jacob A. Greenberg, MD, EdM**

Assistant Professor of Surgery  
Department of Surgery  
University of Wisconsin  
Madison, Wisconsin

**José G. Guillem, MD, MPH**

Department of Surgery  
Memorial Sloan-Kettering Cancer Center  
New York, New York

**Peter T. Hallowell, MD**

Assistant Professor  
Director of Bariatric Surgery  
University of Virginia  
Charlottesville, Virginia

**Douglas W. Hanto, MD, PhD**

Lewis Thomas Professor of Surgery  
Harvard Medical School  
Chief, Division of Transplantation  
Beth Israel Deaconess Medical Center  
Boston, Massachusetts

**J. Michael Henderson, MD**

Chief Quality Officer, Professor of Surgery  
Cleveland Clinic  
Cleveland, Ohio

**Toshitaka Hoppo, MD, PhD**

Research Assistant Professor  
Department of Cardiothoracic Surgery  
University of Pittsburgh  
Pittsburgh, Pennsylvania

**John G. Hunter, MD, FACS**

Mackenzie Professor and Chairman of Surgery  
Oregon Health & Sciences University  
Portland, Oregon

**Roger D. Hurst, MD**

Professor of Surgery  
University of Chicago  
Pritzker School of Medicine  
Chicago, Illinois

**Patrick J. Javid, MD**

Assistant Professor of Surgery  
University of Washington, Seattle Children's Hospital  
Seattle, Washington

**Blair A. Jobe, MD, FACS**

Professor of Surgery  
Division of Thoracic and Foregut Surgery  
Department of Cardiothoracic Surgery  
University of Pittsburgh  
Shadyside Medical Center  
Pittsburgh, Pennsylvania

**Saboor Khan, PhD, FRCS Eng (Gen), FACS**

HPB Scholar  
Mayo Clinic  
Rochester, Minnesota  
Consultant, Hepatobiliary and  
Pancreatic Surgeon  
University Hospital Coventry and Warwickshire  
Coventry, Warwickshire, United Kingdom

**Andreas M. Kaiser, MD, FACS, FASCRS**

Associate Professor  
Department of Colorectal Surgery  
Keck School of Medicine  
University of Southern California  
Los Angeles, California

**Edward Kelly, MD, FACS**

Department of Surgery  
Director, Acute Care Surgery  
Brigham and Women's Hospital  
Assistant Professor of Surgery  
Harvard Medical School  
Boston, Massachusetts

**Saurabh Khandelwal, MD**

Assistant Professor  
Department of Surgery  
Director, UWMC Bariatrics Center  
University of Washington  
Seattle, Washington

**Ira J. Kodner, MD**

Solon and Bettie Gershman Professor of  
Colon and Rectal Surgery  
Washington University School of Medicine  
St. Louis, Missouri

**John T. Langell, MD, PhD, MPH**

Assistant Professor of Surgery  
University of Utah Health Sciences Center  
Salt Lake City, Utah

**Simon Law, MS(HK), MBBChir, MA(Cantab),  
FRCS(Edin), FCSHK, FHKAM, FACS**

Cheung Kung-Hai Professor in  
Gastrointestinal Surgery  
Chief, Division of Esophageal and Upper  
Gastrointestinal Surgery  
Department of Surgery  
The University of Hong Kong  
Hong Kong

**Ryan M. Levy, MD**

Assistant Professor of Thoracic Surgery  
Department of Cardiothoracic Surgery  
University of Pittsburgh Medical Center  
Pittsburgh, Pennsylvania

**Keith D. Lillemoe, MD**

Surgeon-in-Chief  
Chief, Department of Surgery  
Massachusetts General Hospital  
W. Gerald Austen Professor of Surgery  
Harvard Medical School  
Boston, Massachusetts

**Anne Y. Lin, MD**

Assistant Professor of Surgery  
Department of Surgery, Section of Colon and Rectal Surgery  
University of California Los Angeles  
Los Angeles, California

**Donna Loehner, RN, BSN, CWOCN**

Lahey Clinic Medical Center  
Burlington, Massachusetts

**Benjamin P.T. Loveday, MBChB, PhD**

Honorary Lecturer; Senior Registrar  
Department of Surgery  
University of Auckland, New Zealand  
Waikato Hospital  
Hamilton, New Zealand

**James D. Luketich, MD**

Professor of Surgery, Chief  
Heart, Lung, & Esophageal Surgery Institute  
University of Pittsburgh Medical Center  
Pittsburgh, Pennsylvania

**Najjia N. Mahmoud, MD**

Associate Professor of Surgery  
Hospital of the University of Pennsylvania  
Philadelphia, Pennsylvania

**Warren R. Maley, MD**

Associate Professor  
Department of Surgery  
Jefferson Pancreas, Biliary and Related Cancer Center  
Thomas Jefferson University  
Philadelphia, Pennsylvania

**Jeffrey M. Marks, MD,  
FACS, FASGE**

Professor of Surgery  
 Director of Surgical Endoscopy  
 Program Director, Case Surgery  
 University Hospitals  
 Case Medical Center  
 Cleveland, Ohio

**Jeffrey B. Matthews, MD**

Surgeon-in-Chief and Chairman,  
 Department of Surgery  
 Dallas B. Phemister Professor of Surgery  
 Medicine & Biological Sciences  
 The University of Chicago  
 Chicago, Illinois

**Robert A. Maxwell, MD, FACS**

Professor of Surgery  
 University of Tennessee, Chattanooga  
 Chattanooga, Tennessee

**David W. McFadden, MD, MBA**

Professor and Chair  
 Department of Surgery  
 University of Connecticut  
 Farmington, Connecticut

**Robin S. McLeod, MD, FRCSC, FACS**

Angelo and Alfredo  
 De Gasperis Families Chair in  
 Colorectal Cancer and IBD Research  
 Professor of Surgery and Health Policy,  
 Management and Evaluation  
 Vice Chair, Quality and Performance  
 Department of Surgery  
 University of Toronto  
 Toronto, Ontario, Canada

**Fabrizio Michelassi, MD**

Lewis Atterbury Stimson Professor  
 Chairman, Department of Surgery  
 Weill Cornell Medical College  
 Surgeon-in-Chief  
 New York Presbyterian Hospital at Weill  
 Cornell Medical Center  
 New York, New York

**Francis D. Moore, Jr., MD**

Professor of Surgery  
 Harvard Medical School  
 Vice Chair, Surgery  
 Chief, General and Gastrointestinal Surgery  
 Brigham and Women's Hospital  
 Boston, Massachusetts

**Jon B. Morris, MD**

Professor and Vice Chair of Education  
 Department of Surgery  
 Hospital of the University of Pennsylvania  
 Philadelphia, Pennsylvania

**Sean J. Mulvihill, MD**

Associate Vice President for Clinical Affairs  
 Chief Executive Officer  
 University of Utah Medical Group  
 University of Utah  
 Salt Lake City, Utah

**Matthew A. Nehs, MD**

Chief Resident, General Surgery  
 Brigham and Women's Hospital  
 Clinical Fellow in Surgery  
 Harvard Medical School  
 Boston, Massachusetts

**Heidi Nelson, MD**

Professor  
 Department of Surgery  
 Mayo Clinic  
 Rochester, Minnesota

**Thang C. Nguyen, MBBS, FRACS**

Consultant Colorectal Surgeon  
 Southern and Eastern Health  
 Victoria, Australia

**Brant K. Oelschlager, MD**

Byers Endowed Professor of Esophageal Research  
 Chief, Gastrointestinal/General Surgery and  
 Center for Videoendoscopic Surgery  
 Department of Surgery  
 University of Washington  
 Seattle, Washington

**Theodore N. Pappas, MD**

Professor of Surgery  
 Duke University  
 Durham, North Carolina

**Purvi Y. Parikh, MD**

Assistant Professor of Surgery  
 Albany Medical Center  
 Albany, New York

**Rajesh Pendlimari, MBBS**

Research Fellow  
 Colon and Rectal Surgery  
 Mayo Clinic  
 Rochester, Minnesota

**William H. Peranteau, MD**

Fellow  
 Department of Surgery  
 Children's Hospital of Philadelphia  
 Philadelphia, Pennsylvania

**Henry A. Pitt, MD**

Professor and Vice Chairman  
 Department of Surgery  
 Indiana University School of Medicine  
 Indianapolis, Indiana



**Jeffrey L. Ponsky, MD, FACS**

Oliver H. Payne Professor and Chairman  
Department of Surgery  
Case Western Reserve University  
Surgeon-in-Chief  
University Hospitals Case Medical Center  
Cleveland, Ohio

**David W. Rattner, MD**

Chief, Division of General and Gastrointestinal Surgery  
Massachusetts General Hospital  
Warshaw Family Professor of Surgery, Harvard Medical School  
Boston, Massachusetts

**Chandrajit P. Raut, MD, MSc, FACS**

Associate Surgeon, Division of Surgical Oncology  
Brigham and Women's Hospital  
Center for Sarcoma and Bone Oncology  
Dana-Farber Cancer Institute  
Assistant Professor of Surgery  
Harvard Medical School  
Boston, Massachusetts

**Thomas E. Read, MD, FACS, FASCRS**

Staff Surgeon, Department of Colon and Rectal Surgery  
Program Director, Residency in Colon and Rectal Surgery  
Lahey Clinic Medical Center  
Burlington, Massachusetts  
Professor of Surgery  
Tufts University School of Medicine  
Boston, Massachusetts

**Howard A. Reber, MD**

Professor of Surgery  
David Geffen School of Medicine  
University of California at Los Angeles  
Los Angeles, California

**Taylor S. Riall, MD, PhD**

Associate Professor  
John Sealy Distinguished Chair in Clinical Research  
University of Texas Medical Branch  
Galveston, Texas

**John J. Ricotta, MD, FACS**

Harold H. Hawfield Chair of Surgery  
Department of Surgery  
MedStar Washington Hospital Center  
Washington, DC

**Patricia L. Roberts MD**

Chair, Division of Surgery  
Chair, Department of Colon and Rectal Surgery  
Lahey Clinic Medical Center  
Burlington, Massachusetts  
Professor of Surgery  
Tufts University School of Medicine  
Boston, Massachusetts

**Flavio G. Rocha, MD**

Staff Surgeon, HPB Service  
Virginia Mason Medical Center  
Seattle, Washington

**Robert E. Roses, MD**

Assistant Professor of Surgery  
Hospital of the University of Pennsylvania  
University of Pennsylvania School of Medicine  
Philadelphia, Pennsylvania

**Ori D. Rotstein, MD**

Surgeon-in-Chief  
Department of Surgery and Division of General Surgery  
St. Michael's Hospital  
Toronto, Ontario, Canada

**Daniel T. Ruan, MD**

Associate Surgeon  
Brigham and Women's Hospital  
Boston, Massachusetts

**Jeannine A. Ruby, MD**

Department of Surgery  
Memorial Sloan-Kettering Cancer Center  
New York, New York

**George A. Sarosi, MD**

Associate Professor and the Robert H. Hux Professor  
General Surgery/GI, Oncologic and Endocrine Surgery  
University of Florida  
Gainesville, Florida

**Michael G. Sarr, MD**

J. C. Masson Professor of Surgery  
Mayo Clinic and Mayo Foundation  
Rochester, Minnesota

**Mitsuru Sasako, MD, PhD**

Professor, Chairman  
Upper Gastrointestinal Surgery  
Hyogo College of Medicine  
Nishnomiya, Japan

**Philip R. Schauer, MD**

Professor of Surgery, Lerner College of Medicine  
Director, Advanced Laparoscopic and Bariatric Surgery  
Bariatric and Metabolic Institute  
Cleveland Clinic  
Cleveland, Ohio

**Bruce Schirmer, MD**

Stephen H. Watts Professor of Surgery  
University of Virginia Health System  
Charlottesville, Virginia

**David J. Schoetz, Jr., MD**

Chairman Emeritus, Department of Colon and Rectal Surgery  
Professor of Surgery, Tufts University School of Medicine  
Lahey Clinic  
Burlington, Massachusetts

**Richard D. Schulick, MD, MBA, FACS**

The Aragón/Gonzalez-Giustí Chair  
Professor and Chair  
Department of Surgery  
University of Colorado Anschutz Medical Campus  
Aurora, Colorado

**Seymour I. Schwartz, MD, FACS**

Distinguished Alumni Professor of Surgery  
University of Rochester School of  
Medicine and Dentistry  
Rochester, New York

**Guido M. Sclabas, MD, MS**

Consultant  
Department of Surgery  
Mayo Clinic Health System Austin  
Austin, Minnesota

**Anthony J. Senagore, MD, MS, MBA**

Professor, Clinical Scholar  
Charles W. and Carolyn Costello Chair in  
Colorectal Diseases  
Program Director, LAC and USC General  
Surgery Residency  
Division Chief, Division of Colorectal Surgery  
Vice-Chair, Department of Surgery  
Keck School of Medicine  
University of Southern California  
Los Angeles, California

**Jory S. Simpson, MD, FRCS**

St. Michael's Hospital  
University of Toronto  
Toronto, Ontario

**Douglas S. Smink, MD, MPH**

Assistant Professor of Surgery  
Brigham and Women's Hospital  
Harvard Medical School  
Boston, Massachusetts

**Nathaniel J. Soper, MD**

Loyal and Edith Davis Professor and Chair  
Department of Surgery  
Northwestern University  
Feinberg School of Medicine  
Chicago, Illinois

**Ian S. Soriano, MD, FACS, FSPSA, FPALES (Hon.)**

Laparoscopic and Bariatric Surgery  
Department of Surgery  
Einstein Medical Center  
Einstein Healthcare Network  
Philadelphia, Pennsylvania  
Visiting Professor of Surgery  
Department of Surgery  
Philippine General Hospital and  
University of the Philippines College of Medicine  
Manila, Philippines

**David I. Soybel, MD**

Nahrwold Professor of Surgery  
Chief, Division of General Surgery Specialties  
Penn State Hershey Medical Center  
Hershey, Pennsylvania

**Steven M. Strasberg, MD,  
FRCS(C), FACS, FRCS(Ed)**

Pruett Professor of Surgery  
Section of Hepato-Pancreato-Biliary Surgery,  
Department of Surgery  
Washington University in St. Louis  
St. Louis, Missouri

**David J. Sugarbaker, MD**

The Richard E. Wilson Professor of Surgical Oncology  
Harvard Medical School  
Chief, Division of Thoracic Surgery  
Brigham and Women's Hospital  
Boston, Massachusetts

**Richard S. Swanson, MD**

Director, Program in Hepatobiliary and Pancreatic Cancer  
Division of Surgical Oncology  
Brigham and Women's Hospital  
Dana Farber Cancer Institute  
Associate Professor of Surgery  
Harvard Medical School  
Boston, Massachusetts

**Lee L. Swanstrom, MD**

Clinical Professor  
Department of Surgery  
Oregon Health and Sciences University  
GI/MIS Division  
The Oregon Clinic  
Portland, Oregon

**Ali Tavakkoli, MD, FRCS, FACS**

Assistant Professor of Surgery  
Harvard Medical School  
Minimally Invasive and Gastrointestinal Surgery  
Brigham and Women's Hospital  
Boston, Massachusetts

**Patrick S. Tawadros, MD, PhD, FRCS(C)**

Assistant Professor  
Division of Colon and Rectal Surgery  
Department of Surgery  
University of Minnesota  
Minneapolis, Minnesota

**Ashley Haralson Vernon, MD**

Associate Surgeon  
Brigham and Women's Hospital  
Harvard Medical School  
Boston, Massachusetts

**Andrew L. Warshaw, MD**

Senior Consultant  
International and Regional Clinical Relations  
Massachusetts General Hospital and  
Partners Healthcare  
W. Gerald Austen Distinguished Professor of Surgery  
Harvard Medical School  
Surgeon-in-Chief Emeritus  
Massachusetts General Hospital  
Boston, Massachusetts

**Jon O. Wee, MD**

Co-Director of Minimally Invasive Thoracic Surgery  
Division of Thoracic Surgery  
Brigham and Women's Hospital  
Instructor in Surgery  
Harvard Medical School  
Boston, Massachusetts

**Mark Lane Welton, MD, MHCM**

Professor  
Department of Surgery  
Stanford University School of Medicine  
Stanford, California

**Edward E. Whang, MD**

Associate Professor of Surgery  
Brigham and Women's Hospital  
Harvard Medical School  
Boston, Massachusetts

**John A. Windsor, BSc, MBChB, MD, FRACS, FACS**

Professor of Surgery  
University of Auckland  
Auckland, New Zealand

**Christopher L. Wolfgang, MD, PhD, FACS**

Chief, Hepatobiliary and Pancreatic Surgery  
Johns Hopkins Hospital  
Associate Professor of Surgery, Pathology and Oncology  
Johns Hopkins University  
Baltimore, Maryland

**Charles J. Yeo, MD**

Samuel D. Gross Professor and Chairman  
Department of Surgery  
Jefferson Medical College  
Philadelphia, Pennsylvania

**Jin S. Yoo, MD, FACS**

Assistant Professor of Surgery  
Duke University Health System  
Durham, North Carolina

**Michael J. Zinner, MD, FACS**

Professor, Harvard Medical School  
Clinical Director  
Dana-Farber/Brigham and Women's Cancer Center  
Surgeon-in-Chief  
Brigham and Women's Hospital  
Boston, Massachusetts



*Maingot's Abdominal Operations* has always filled a unique niche. For many surgeons, including the editors, the text has consistently offered a comprehensive discussion of surgical diseases of the abdomen with a focus on operative strategy and technique. The book has served as a needed reference to refresh our knowledge before a common operation or in preparation for a novel one. Our intended audience for this edition is the same as for the original publication; the book is meant for the surgical trainee as well as the practicing surgeon. We continue to have an international audience and have made every effort to produce a product that is equally valuable to readers in Malaysia and Montana. For both of us, in this third effort together, it continues to be both an honor and a privilege to have the opportunity to edit the twelfth edition of this classic textbook.

Abdominal surgery has clearly changed since Rodney Maingot's first edition in 1940. Not only has our knowledge base increased substantially but the procedures themselves have become more complex. The current subspecialization in abdominal surgery, a consequence of these changes, might even challenge the need for such a comprehensive text. Abdominal disease has been increasingly parceled up between foregut, hepatobiliary, pancreatic, colorectal, endocrine, acute care, and vascular. We continue to believe, however, that the basic principles of surgical care in each of the anatomical regions have more similarities than differences. Experience in any one of these organs can inform and strengthen the approach to each of the others. Few would question the need for the abdominal surgeon to be well versed in dealing with any unexpected disease that is encountered in the course of a planned procedure. For many of us, *Maingot's Abdominal Operations* has consistently helped to fill that need. We also intend for this textbook to remain disease-focused in addition to its organ/procedure format. In keeping with the growing opinion that minimally invasive surgery should be viewed not as a distinct subspecialty but rather as one tool employed in each of the anatomic or disease-based subspecialties, in this edition we have incorporated the chapters on minimally invasive surgery throughout the text rather than in a distinct section.

The new edition of this textbook is a significant revision—in most areas a completely new book. We have attempted to focus the text on operative procedures as well as on new

concepts in diagnosis and management of abdominal disease. Although the new edition, like the last edition, is condensed compared with previous versions, we have continued to present the opinions and knowledge of more than one expert. In an effort to enhance this feature, in areas where opinions and approaches differ, we have added "Perspective" commentaries by experts in the field who we expected might have distinct opinions about approaches and/or operative techniques. In response to our international readers, we have added chapters on gastrointestinal bleeding, abdominal trauma, and vascular emergencies, all of which were removed for the previous edition. We have attempted to maintain an international flavor and have included a cross-section of both seasoned senior contributors and new leaders in gastrointestinal surgery. We continue to present a contemporary textbook on current diagnostic procedures and surgical techniques related to the management and care of patients with all types of surgical digestive disease.

An extensive artwork program was undertaken for this edition. Many line drawings have been recreated to reflect the contributors' preferred method for performing certain surgical procedures. Some of these drawings are new and give the book a more modern and overall consistent look. In addition, this edition is the first with full-color text and color line art.

In the preface to the sixth edition, Rodney Maingot noted, "As all literature is personal, the contributors have been given a free hand with their individual sections. Certain latitude in style and expression is stimulating to the thoughtful reader." Similarly, we have tried to maintain consistency for the reader, but the authors have also been given a free hand in their chapter submissions.

We would like to thank the publisher, McGraw-Hill, and in particular Robert Pancotti, for their unwavering support during the lengthy time of development of this project. Their guidance was invaluable to completing this project in a single comprehensive volume. Their suggestions and attention to detail made it possible to overcome the innumerable problems that occur in publishing such a large textbook.


Finally, to our editorial assistant who has survived the trials of this book, Linda Smith; she has been invaluable and we never would have been able to do it without her. Patricia Tucker and Colleen Larkin have also stepped up and made this project possible. We owe them a great debt of gratitude

for helping with every step of the work—from typing manuscripts to editing and reading page proofs, and providing encouragement during the prolonged dry periods and preparation of this textbook.

To all of those who have participated in the creation and publication of this text, we thank you very much.

Michael J. Zinner, MD, FACS

Stanley W. Ashley, MD, FACS



# INTRODUCTION



*This page intentionally left blank*

# A FOCUSED HISTORY OF SURGERY

Seymour I. Schwartz

The word *surgery* derives from the French term “chirurgien,” which came from the Latin and in turn from the Greek words “cheir,” meaning “hand” and “ergon,” meaning work. Surgery has a long history beginning with what is said to be the earliest scientific document known, *The Edwin Smith Surgical Papyrus*, dating from the 17th century before Christ, actually a copy of an Egyptian manuscript originally written circa 3000–2500 BC. The document deals with a variety of wounds and cauterization for breast cancer. No intraperitoneal operation is mentioned.

Although *Maingot's Abdominal Operations* had its genesis in England, elective abdominal operations had their beginning in Danville, Kentucky, a town of 1000 at the time, with the removal of a 22½-lb ovarian tumor by Ephraim McDowell on December 25, 1809. Throughout the 19th century, surgeons from Great Britain and the United States, the two countries that would eventually play major roles in the development of the multiple editions of *Maingot's Abdominal Operations*, contributed significantly to the evolution of abdominal operations. In 1804, Sir Astley Cooper published a *Treatise on Hernia*. In 1833, William Beaumont, an American military surgeon, published *Experiments and Observations on the Gastric Juice and the Physiology of Digestion*. The experiments conducted through a permanent gastric fistula constituted the first controlled clinical study on a human being and defined the process of intragastric digestion. On October 16, 1846, at the Massachusetts General Hospital, the birth of ether anesthesia took place and ushered in a new generation of possibilities for all of surgery. In 1867, John Stough Bobbs of Indianapolis reported the first successful elective operation on the gallbladder, a cholecystectomy with removal of stones and closure of the organ. The patient remained relatively asymptomatic for over 40 years. The 1886 landmark paper by the Boston pathologist Reginald H. Fitz established the entity of appendicitis and championed early operation. As the 19th century came to a close, the German schools of surgery became increasingly dominant, in large part related to Theodor Billroth and the surgeons he trained. Billroth is often referred to as “the father of abdominal surgery” based on his first resection of cancer of the pylorus in 1881 and also the numerous intestinal resections and enterorrhaphies that he performed.

As the first decade of the 21st century has come to an end, it is appropriate to focus on the developments that took place during the preceding 20th century, by dividing this period into two time spans: one before 1940, the year that the first edition of *Maingot's Abdominal Operations* was published, and the other considering the progress that has taken place in the ensuing 60 years.

In discussing the history of surgical advances pertaining to the gastrointestinal tract per se, it is reasonable to proceed aborally from esophagus to rectum. In regard to the esophagus, the first significant operation was reported in 1913 by Franz Torek of New York City, who removed the entire thoracic esophagus and connected the cervical esophagus with the stomach by means of an external tube. Although in 1935 Winkelstein first defined the clinical picture of esophageal reflux and indicted the erosive action of gastric juice as the culprit, the issue of a functioning gastroesophageal sphincter was not appreciated. Consequently, no corrective operation was devised prior to the publication of *Maingot's* first edition.

The surgical treatment of reflux esophagitis was first popularized by Allison, who defined a repair in 1951, mainly consisting of correction of the hiatal herniation. The high recurrence rate associated with that operation led to a consideration of fundoplication procedures, which were introduced in 1966 by Nissen and subsequently modified by Belsey, Hill, and Toupet. Since the advent of minimally invasive surgery in 1989, the majority of these fundoplications have been performed laparoscopically.

During the first four decades of the 20th century, there was considerable interest in the surgical treatment of peptic ulcer disease. Gastric resection was often the most commonly performed indexed operative procedure in a residency program. The operations were outgrowths of the procedures that were initially applied by Billroth and his associates for gastric cancer. In the early decades of the 20th century, excision of a gastric ulcer was widely practiced. When the excision, as was frequently the case, was extensive, there were problems with gastric emptying, prompting William Mayo in 1911 to add a complemental gastrojejunostomy. Then as now, the indications for surgical intervention in patients with peptic ulcer were obstruction, bleeding, perforation, and intractability.

Pyloroplasty and gastrojejunostomy were the most frequently performed procedures for obstruction, and as early as 1925 Lewisohn reported a 34% incidence of neostomal ulcer after gastrojejunostomy. Before 1940, the surgeons at the Mayo Clinic continued to champion the procedure for duodenal ulcer. In 1937, R.R. Graham introduced his patch procedure for perforation. Gradually partial gastrectomy became the preferred surgical treatment for the complications of peptic ulcer disease.

The modern era of vagotomy in the management of peptic ulcer began in January 1943, when Dragstedt performed a subdiaphragmatic resection of the vagal trunks in a patient with an active duodenal ulcer. Dragstedt's earlier approach was transthoracic. Later, when he appreciated that a significant percentage of his patients developed gastric stasis, Dragstedt added a drainage procedure, either gastroenterostomy or pyloroplasty, as an accompaniment to the truncal vagotomy. Farmer and Smithwick recommended a two-pronged attack against the ulcer diathesis, combining truncal vagotomy with hemigastrectomy. In 1960, Griffith introduced the concept of selective gastric vagotomy, preserving the nerve of Laterjet and thereby obviating the need for a gastric drainage procedure.<sup>1</sup>

The applicability of vagotomy and partial gastric resection has been greatly reduced over the past two decades by the introduction of acid suppressive pharmaceuticals, including the histamine receptor antagonists and proton pump inhibitors. The use of these preparations has also generally obviated partial gastrectomy for ulcer diathesis and total gastrectomy for the intractable ulcers associated with the Zollinger–Ellison syndrome. Perhaps the most significant factor causing a marked reduction in the need for surgical management of peptic ulcer disease was the discovery by Warren and Marshall in 1983 of an association between *Helicobacter pylori* and peptic ulcer that is readily treatable with the hopes of totally eradicating peptic ulcer disease. This transition of gastric surgery from the 19th-century understanding of anatomy, to the 20th-century understanding of physiology and pathophysiology, to the 21st-century understanding of pharmacology mirrors the growth, development, and progress of the understanding of surgical diseases.<sup>2</sup>

The greatest increase in gastric surgery since 1940 is the application of gastric reduction for obesity. The initial surgical approach to the management of extreme obesity, jejunoileal bypass, was introduced by Kremen, Linner, and Nelson in 1954. The procedure was popularized by Payne and DeWind in 1969, but had many hazardous consequences and has been essentially discarded. Gastric bypass, introduced by Mason in 1966, has been the preferred method of surgical management for the past four decades and has become increasingly popular with the advent of minimally invasive surgery.

The principles of intestinal anastomosis are in large part based on Halsted's late-19th century studies on the importance of the submucosa as the layer providing strength for the suture line. Most of the early-20th century procedures on the small intestine were related to the treatment of obstruction. In 1932, Crohn, Ginzburg, and Oppenheimer introduced a

newly recognized pathologic entity they called regional ileitis, which has come to be known as Crohn's disease or regional enteritis.

The major operative changes in small intestinal surgery that have taken place over the past two decades have been brought about by the introduction of stapling techniques. These were preceded by John B. Murphy's button, when it was described in 1892. Mechanical suture instruments using staples began with Humer Hüttl of Budapest, who in 1908 described an instrument for use in distal gastrectomy. It was modified by von Petz in 1924 and enjoyed a period of popularity in many centers. The next major step in stapling was the result of the dedicated efforts of the Scientific Research Institute for Experimental Surgical Apparatus and Instruments in Moscow. The investigators developed magazine-loaded instruments for vascular anastomosis, side-to-side intestinal anastomosis, and end-to-end intestinal anastomosis. These were imported to the United States and modified, beginning in 1958, largely due to the leadership of Ravitch and Steichen.<sup>3</sup> The introduction and widespread application of stapling devices helped revolutionize the technical aspects of surgery that have allowed minimally invasive procedures to be developed.

In the realm of colorectal surgery, although in 1883 Czerny introduced a technique for combined abdominal-peritoneal excision of rectal tumors, Miles' method, reported in 1907, popularized the procedure. The advent of stapling techniques during the past two decades has allowed for more anal preservation operations. The ileal pouch procedure represents a significant advance in the management of ulcerative colitis and familial polyposis. In 1947, Ravitch and Sabiston performed total colectomy, proximal proctectomy, mucosal distal proctectomy, and ileal anal anastomosis, but the results were generally not satisfactory with regard to frequency of defecation. The introduction in 1978 of a valveless ileal reservoir anastomosed to the anus addressed the problem and has become the standard.<sup>4</sup>

Over the past two decades, there have also been changes in the pathologic definitions of tumors of the gastrointestinal (GI) tract and there has been an increased recognition of gastrointestinal stromal tumors (GIST) in all regions of the GI tract.

The first successful elective hepatic resection for tumor was performed by Langenbuch in 1888. The first collective review of hepatic resections for tumor was reported by Keen in 1899 and included only 20 cases. In 1911, Wendell reported the first case of near total right lobectomy for a primary hepatic tumor, but the modern age of hepatic resection is generally dated to the 1952 report of Lortat-Jacob and Robert that detailed a right lobectomy using a technique designed to control hemorrhage with ligation of the blood vessels and bile ducts to the right lobe in the hepatoduodenal ligament followed by extrahepatic ligation of the right hepatic vein prior to transection of the hepatic parenchyma. In 1967, using corrosion casts, Couinaud demonstrated that the liver is made up of eight distinct segments, thereby opening the door for segmental hepatic resections. The recent applications

of new instruments such as the harmonic scalpel and Liga-Sure vessel sealing system have expedited the performance of major hepatic resections without a need for transfusion.<sup>5</sup>

The year 1945 marked the beginning of the modern era of surgical intervention for portal hypertension with the report by Whipple and associates of the performance of end-to-side portacaval anastomoses and end-to-end splenorenal anastomoses. In 1953 Marion and in 1955 Clatworthy and colleagues independently described a shunt between the proximal transected end of the inferior vena cava and the side of the superior mesenteric vein. In 1967, Gleidman performed the first Dacron interposition mesocaval shunt, and the same year, Warren and colleagues introduced the selective (distal) splenorenal shunt as a method of preserving flow to the liver. The shunt procedures are now performed infrequently, and are generally reserved for patients with massively bleeding esophagogastric varices and normal hepatocellular function. By contrast, in patients with uncontrollable bleeding varices and significant hepatocellular dysfunction, a TIPS (transjugular intrahepatic portosystemic shunt) procedure is generally used as a bridge to orthotopic liver transplantation. In 1959, Kasai and Suzuki introduced hepatic portoenterostomy for the management of biliary atresia. More recently, orthotopic liver transplantation has been employed for these patients because of uncorrectable hepatocellular dysfunction.

Fifteen years elapsed between Bobbs' cholecystotomy and the first successful cholecystectomy, which was performed by Carl Langenbuch in 1882. By 1919, William J. Mayo was able to report on 2147 cholecystectomies. In 1923, Graham and Cole introduced cholecystography, leading to a marked increase in biliary surgery. Operations for injuries and strictures of the common duct have undergone many refinements over the past century. An obstructed common bile duct was first successfully drained by a lateral anastomosis to the duodenum by Sprengel in 1891. A variety of plastic procedures and intestinal flap advancements were applied to bridge a gap between the common duct and the duodenum with minimal success. Beginning in 1941, Vitallium tubes were inserted into bile ducts as conduits, but all the tubes eventually became obstructed with sludge. The groups at the Mayo Clinic and Lahey Clinic, who both had extensive experience with these procedures, expressed a preference for choledochoduodenostomy, while most surgeons now employ a mucosal-to-mucosal anastomosis between the proximal duct and a Roux limb of jejunum.

Operations on the pancreas directed at the management of pancreatitis and neoplasms generally evolved subsequent to the publication of the first edition of Maingot's textbook. In 1958, Puestow introduced the popular lateral pancreaticojejunostomy. In 1965, Fry and Child reported their results with a 95% distal pancreatectomy. In 1985, Beger proposed resection of the head of the pancreas with duodenal preservation for pathology that was most marked in the head of the pancreas. In regard to the neuroendocrine tumors of the pancreas, Roscoe Graham performed the first successful resection of an insulinoma in 1929. In 1955, Zollinger and Ellison reported that nonbeta islet cell tumors produced an

"ulcerogenic humoral factor." The pathophysiology often mandated total gastrectomy to control the massive gastric hypersecretion, but the therapy has been markedly altered with the advent of proton pump inhibitors.<sup>6,7</sup>

Although in 1912 Kausch successfully performed a partial pancreatectomy in two stages, the name of Allen O. Whipple has achieved eponymic status as far as resection of pancreatic neoplasms is concerned. In 1935, Whipple initially carried out a two-stage operation for carcinoma of the ampulla consisting of an initial cholecystojejunostomy followed by total duodenectomy. By 1945, he advocated a one-stage pancreatoduodenectomy as the treatment of choice.

Splenectomy is performed for trauma or hematologic disorders. The first recorded successful splenectomy for trauma is credited to a British naval surgeon, E. O'Brien, in 1816, who tied off the pedicle and removed a protruding spleen while stationed in San Francisco. In 1892, Reigner performed the first successful intraperitoneal splenectomy for trauma. In 1867, Péan successfully removed a spleen containing a large cyst. In 1911, Micheli reported the first splenectomy for a hematologic disorder in a patient with hemolytic anemia. Five years later, at the suggestion of Kaznelson, a Czech medical student, Schloffer, performed the first splenectomy for idiopathic thrombocytopenic purpura, the most common hematologic indication. The most recent changes in splenic surgery relate to an increased willingness to observe patients, particularly children, with blunt trauma to the spleen, and the fact that elective splenectomies are generally being performed laparoscopically, as championed by Phillips and Carroll, Cuschieri and associates, and Thibault and coworkers.<sup>8</sup>

Intra-abdominal vascular surgery traces its modern origin to Dubost and colleagues' 1951 resection of an abdominal aortic aneurysm with reestablishment of continuity. The introduction of a prosthetic material to create a conduit is credited to Voorhees, Jaretzki, and Blakemore, who used Vinylon "N" cloth in 1969. The same year, Wylie and associates described autogenous tissue revascularization techniques for correction of renovascular hypertension.

The major advances in abdominal surgery that took place in the second half of the 20th century relate to the fields of organ transplantation and minimally invasive procedures. On December 23, 1954, Murray, Merrill, and Harrison performed the first renal transplant in identical twins. Eight years later, the first successful cadaveric kidney transplant was performed by Murray in an immunosuppressed patient. The liver was the second visceral organ to be transplanted. In 1963, Starzl performed the first human liver transplant in a patient with biliary atresia. The patient died as did four other patients operated on by Starzl and one by Moore that year. In 1968, Starzl achieved the first success. The field recently has been extended by the use of live donors who provide a lobe for the recipient.

The first successful clinical pancreas transplant was performed by Kelly and Lillehei in 1966. In 1973, Gliedman and associates suggested using the ureter for exocrine pancreatic drainage. In 1982, the group at the University of Wisconsin developed the technique of direct drainage of the

pancreas into the urinary bladder. Now, most whole organ pancreas transplants use the intestine for drainage. Recently improved results have been reported with islet cell transplants.

The small intestine was the last of the abdominal organs to be transplanted successfully. In 1987, Starzl and associates performed a multivisceral organ transplant, including the small intestine. The following year, the same group performed a successful combined liver and small intestine transplant, and Grant reported a successful isolated intestinal transplant from a live donor. In 1989, the Pittsburgh group performed the first successful cadaveric small intestinal transplant.

Doubtless, the most dramatic development in abdominal surgery is the introduction and expansion of laparoscopic procedures. Kelling was the first to examine the peritoneal cavity with an endoscope. In 1901, using a Nitze cystoscope, he entered and visualized the peritoneal cavity of a dog and referred to the procedure as “Koelioskopie.” The first major series of laparoscopies in humans is attributed to Jacobaeus, who in 1911 reported examining both the abdominal and thoracic cavities with a “Lapaorthorakoskopie.” In 1937, Ruddock published a paper on “Peritoneoscopy” in which he detailed his experience with 500 cases including 39 in which biopsies were performed.

Laparoscopy essentially remained a procedure performed by gynecologists for many years. In fact, it was a gynecologist, Mouret, who in 1987 performed the first laparoscopic cholecystectomy, using four trocars. But credit is generally assigned to Dubois, who described the procedure in 1988, for initiating interest in the procedure. In the 25 years that have ensued, there has been an explosive increase in the use of laparoscopic techniques for abdominal operations. Basic laparoscopic procedures include cholecystectomy, appendectomy, and hernia repair. Advanced procedures include fundoplication, Heller myotomy, gastrectomy, bariatric surgery, esophagectomy, enteral access, bile duct exploration, partial hepatectomy, partial pancreatectomy, colectomy, splenectomy, adrenalectomy, and nephrectomy in addition to the standard gynecologic applications.<sup>9</sup>

The most recent refinement has been the addition of robotics, or more currently, computer-assisted remote mechanical devices. The appropriateness of the application of robotics to cholecystectomy has not been demonstrated. An advantage, however, has been ascribed to robotics for adrenalectomy.<sup>10</sup> Paralleling the expansion of laparoscopic surgery, there has been an increased application of endovascular techniques for the repair of aneurysm of the abdominal aorta. Endovascular abdominal aortic repair was introduced independently by Parodi and associates and Volodos and coworkers in 1991. Over a dozen endovascular grafts have been developed, and in 2002, there were more abdominal aortic aneurysms repaired in the state of New York by endovascular procedures than open operations.<sup>11</sup>

The expansion in surgery that has occurred during the 20th and early 21st centuries has been a consequence of contributions by surgeons, unrelated to technical improvements. The

critical maintenance of blood volume was instated by James Blundell in London over 150 years ago. In 1883, Halsted reported the first successful autoreinfusion of blood. In 1908, George W. Crile published a book detailing his laboratory and clinical experiences with transfusion. In 1915, Richard Lewisohn, a New York surgeon, introduced the sodium citrate method of blood preservation. The use of frozen blood was first reported in 1965 by Charles Huggins of Massachusetts General Hospital.

In reference to the use of intraoperative and postoperative fluid therapy, early contributions were made by John H. Gibbons in 1907, and Wilder Penfield and David Teplitzky in 1923. A year later, Rudolph Matas prescribed the intravenous administration of 4000–5000 mL of 5% glucose solution over 24 hours. After a period in which saline was avoided, the importance of saline and potassium was demonstrated by Francis D. Moore, Henry T. Randall, and G. Tom Shires. In 1959, Moore’s *Metabolic Care of the Surgical Patient* brought into focus the importance of body composition, homeostasis, and endocrinology of the traumatized and surgical patient. The problem of nutritional support was resolved by Dudrick and associates in 1968 when they demonstrated that nutritional requirements could be satisfied totally by administration of high caloric fluid by a catheter position in the superior vena cava.

Over seven decades have elapsed since the first edition of *Maingot’s Abdominal Operations* was published. As is true for all of the sciences, growth recently has been geometric. During the time from the initial publication to the present, there have been more new and refined operations introduced than throughout the preceding years. The accelerated rate of change can only ensure the viability of future editions.

## REFERENCES

1. Nyhus LM, Wastell C (eds). *Surgery of the Stomach and Duodenum*. Boston, MA: Little Brown and Co; 1986.
2. Modlin IM. *The Evolution of Therapy in Gastroenterology*. Montreal, Canada: Axcan Pharma; 2002.
3. Steichen FM, Ravitch MM. *Stapling in Surgery*. Chicago, IL: Year Book Medical; 1971.
4. Goligher J. *Surgery of the Anus Rectum and Colon*. 5th ed. London, England: Baillière Tindall; 1984.
5. McDermott WV. *Surgery of the Liver*. Cambridge, England: Blackwell Scientific; 1988.
6. Schwartz SI, et al. *Principles of Surgery*. 7th ed. New York, NY: McGraw-Hill; 1989.
7. Schwartz SI. *Gifted Hands*. Amherst, New York: Prometheus Books; 2009.
8. Hiatt JR, Phillips EH, Morgenstern L. *Surgical Diseases of the Spleen*. New York, NY: Springer; 1997.
9. Laparoscopy for the general surgeon. *Surg Clin North Am*. 1992;72: 997–1186.
10. Jacob BP, Gagner M. Robotics and general surgery. *Surg Clin North Am*. 2003;83:1405–1419.
11. Krupinski WC, Rutherford RB. Update on open repair of abdominal aortic aneurysms: the challenges for endovascular repair. *J Am Coll Surg*. 2004;199:946–960.



# PREOPERATIVE AND POSTOPERATIVE MANAGEMENT

Zara Cooper • Edward Kelly

Modern advances in patient care have enabled surgeons to treat more challenging and complicated surgical problems. In addition, surgical treatment can be offered to more fragile patients, with successful outcomes. In order to achieve these good results, it is vital to master the scientific fundamentals of perioperative management. The organ system–based approach allows the surgeon to address the patient’s pre- and postoperative needs, and ensures that these needs are part of the surgical plan.

## MANAGEMENT OF PAIN AND DELIRIUM

The most common neuropsychiatric complications following abdominal surgery are pain and delirium. Moreover, uncontrolled pain and delirium prevent the patient from contributing to vital aspects of his or her care such as walking and coughing, and promote an unsafe environment that may lead to the unwanted dislodgment of drains and other supportive devices, with potentially life-threatening consequences. Pain and delirium frequently coexist, and each can contribute to the development of the other. Despite high reported rates of overall patient satisfaction, pain control is frequently inadequate in the perioperative setting<sup>1</sup> with high rates of complications such as drowsiness and unacceptable levels of pain. Therefore, it is mandatory that the surgical plan for every patient include control of postoperative pain and delirium and regular monitoring of the efficacy of pain control.

Pain management, like all surgical planning, begins in the preoperative assessment. In the modern era, a large proportion of surgical patients will require special attention with respect to pain control. Patients with preexisting pain syndromes, such as sciatica or interspinal disc disease, or patients with a history of opioid use may have a high tolerance for opioid analgesics. Every patient’s history should include a thorough investigation for chronic pain syndrome, addiction (active or in recovery), and adverse reactions to opioid, nonsteroidal, or epidural analgesia. The pain control strategy

may include consultation with a pain control anesthesiology specialist, but it is the responsibility of the operating surgeon to identify complicated patients and construct an effective pain control plan.

## Opioid Analgesia

Postoperative pain control using opioid medication has been in use for thousands of years. Hippocrates advocated the use of opium for pain control. The benefits of postoperative pain control are salutary, and include improved mobility and respiratory function, and earlier return to normal activities. The most effective strategy for pain control using opioid analgesia is patient-controlled analgesia (PCA), wherein the patient is instructed in the use of a preprogrammed intravenous pump that delivers measured doses of opioid (usually morphine or meperidine). In randomized trials, PCA has been shown to provide superior pain control and patient satisfaction compared to interval dosing,<sup>2</sup> but PCA has not been shown to improve rates of pulmonary and cardiac complications<sup>3</sup> or length of hospital stay,<sup>4</sup> and there is evidence that PCA may contribute to postoperative ileus.<sup>5</sup> In addition, PCA may be unsuitable for patients with a history of substance abuse, high opioid tolerance, or those with atypical reactions to opioids.

## Epidural Analgesia

Due to the limitations of PCA, pain control clinicians have turned to epidural analgesia as an effective strategy for the management of postoperative pain. Postoperative epidural analgesia involves the insertion of a catheter into the epidural space of the lumbar or thoracic spine, enabling the delivery of local anesthetics or opioids directly to the nerve roots. The insertion procedure is generally safe, with complication rates of motor block and numbness between 0.5% and 7%,<sup>6</sup> and an epidural abscess rate of 0.5 per thousand.<sup>7</sup> Potential advantages of epidural analgesia include elimination of systemic



opioids, and thus less respiratory depression, and improvement in pulmonary complications and perioperative ileus. There have been several large trials,<sup>8-10</sup> a meta-analysis,<sup>6</sup> and a systematic review<sup>11</sup> comparing PCA with epidural analgesia in the setting of abdominal surgery. These studies indicate that epidural analgesia provides more complete analgesia than PCA throughout the postoperative course. Furthermore, in randomized prospective series of abdominal procedures, epidural analgesia has been associated with decreased rates of pulmonary complications<sup>12,13</sup> and postoperative ileus.<sup>14,15</sup> Epidural analgesia requires a skilled anesthesia clinician to insert and monitor the catheter and adjust the dosage of neuraxial medication. Some clinicians may prefer correction of coagulopathy before inserting or removing the catheter, although the American Society of Anesthesiologists (ASA) has not issued official guidelines on this issue.

## Analgesia With Nonsteroidal Anti-Inflammatory Drugs

Oral nonsteroidal anti-inflammatory drugs (NSAIDs) have long been used for postoperative analgesia in the outpatient setting, and with the development of parenteral preparations, have come into use in the inpatient population. This class of medication has no respiratory side effects and is not associated with addiction potential, altered mental status, or ileus. In addition, these medications provide effective pain relief in the surgical population. However, use of NSAIDs has not been universally adopted in abdominal surgery due to concerns regarding the platelet dysfunction and erosive gastritis associated with heavy NSAID use. In prospective trials, NSAIDs were found to provide effective pain control without bleeding or gastritis symptoms following laparoscopic cholecystectomy,<sup>16</sup> abdominal hysterectomy,<sup>17</sup> and inguinal hernia repair.<sup>18,19</sup> NSAIDs have also been shown to improve pain control and decrease morphine dosage when used in combination following appendectomy.<sup>20</sup>

The sensation of pain is very subjective and personal. Accordingly, the surgeon must individualize the pain control plan to fit the needs of each patient. The pain control modalities discussed above can be used in any combination, and the surgeon should not hesitate to use all resources at his or her command to provide adequate relief of postoperative pain.

## Postoperative Delirium

Delirium, defined as acute cognitive dysfunction marked by fluctuating disorientation, sensory disturbance, and decreased attention, is an all too common complication of surgical procedures, with reported rates of 11–25%, with the highest rates reported in the elderly population.<sup>21,22</sup> The postoperative phase of abdominal surgery exposes patients, some of whom may be quite vulnerable to delirium, to a



**TABLE 2-1: CAUSES OF PERIOPERATIVE DELIRIUM**

Pain
Narcotic analgesics
Sleep deprivation
Hypoxemia
Hyperglycemia
Acidosis
Withdrawal (alcohol, narcotics, benzodiazepines)
Anemia
Dehydration
Electrolyte imbalance (sodium, potassium, magnesium, calcium, phosphate)
Fever
Hypotension
Infection (pneumonia, incision site infection, urinary tract infection)
Medication (antiemetics, antihistamines, sedatives, anesthetics)
Postoperative myocardial infarction (MI)

large number of factors that may precipitate or exacerbate delirium (Table 2-1). These factors can augment each other: postoperative pain can lead to decreased mobility, causing respiratory compromise, atelectasis, and hypoxemia. Escalating doses of narcotics to treat pain can cause respiratory depression and respiratory acidosis. Hypoxemia and delirium can cause agitation, prompting treatment with benzodiazepines, further worsening respiratory function and delirium. This vicious cycle can play out right before the physician's eyes, and if not interrupted, can result in serious complications or death. Preoperative recognition of high-risk patients and meticulous monitoring of every patient's mental status are the most effective ways to prevent postoperative delirium; treatment can be remarkably difficult once the vicious cycle has begun.

Patient factors that are associated with high risk of perioperative delirium include age greater than 70 years, preexisting cognitive impairment or prior episode of delirium, history of alcohol or narcotic abuse, and malnutrition.<sup>21,23</sup> Procedural factors associated with high delirium risk include operative time greater than 2 hours, prolonged use of restraints, presence of a urinary catheter, addition of more than three new medications, and reoperation.<sup>22</sup>

Once the patient's risk for postoperative delirium is identified, perioperative care should be planned carefully to decrease other controllable factors. Epidural analgesia has been associated with less delirium than PCA after abdominal surgery.<sup>24</sup> Sedation or "sleepers" should be used judiciously, if at all, with high-risk patients. If the patient requires sedation, neuroleptics such as haloperidol and the atypical neuroleptics such as olanzapine are tolerated much better than benzodiazepines.<sup>25</sup> The patient's mental status, including orientation and attention, should be assessed

with every visit, and care should be taken to avoid anemia, electrolyte imbalances, dehydration, and other contributing factors.

Once the diagnosis of postoperative delirium is established, it is important to recognize that some of the causes of delirium are potentially life-threatening, and immediate action is necessary. Evaluation begins with a thorough history and physical examination at the bedside by the surgeon. The history should focus on precipitating events such as falls (possible traumatic brain injury), recent procedures, use of opioids and sedatives, changes in existing medications (eg, withholding of thyroid replacement or antidepressants), and consideration of alcohol withdrawal. The vital signs and fluid balance may suggest sepsis, hypovolemia, anemia, or dehydration. The examination should include brief but complete sensory and motor neurological examinations to differentiate delirium from stroke. Pay attention to common sites of infection such as the surgical wound, the lungs, and intravenous catheters. Urinary retention may be present as a result of medication or infection. Deep venous thrombosis may be clinically evident as limb swelling. Postoperative myocardial infarction (MI) may often present as acute cardiogenic shock.

The history and physical examination should then direct the use of laboratory tests. Most useful are the electrolytes, blood glucose, and complete blood cell count. Pulse oximetry and arterial blood gases may disclose hypercapnia or hypoxemia. Chest x-ray may disclose atelectasis, pneumonia, acute pulmonary edema, or pneumothorax. Cultures may be indicated in the setting of fever or leukocytosis, but will not help immediately. Electrocardiogram (ECG) and cardiac troponin may be used to diagnose postoperative MI.

Resuscitative measures may be required if life-threatening causes of delirium are suspected. Airway control, supplemental oxygen, and fluid volume expansion should be considered in patients with unstable vital signs. The patient should not be sent out of the monitored environment for further tests, such as head computed tomography (CT), until the vital signs are stable and the agitation is controlled. Treatment of postoperative delirium depends on treatment of the underlying causes. Once the underlying cause has been treated, delirium may persist, especially in elderly or critically ill patients, who regain orientation and sleep cycles slowly. In these patients, it is important to provide orienting communication and mental stimulation during the day, and to promote sleep during the night. The simplest ways are the most effective: contact with family members and friends, use of hearing aids, engagement in activities of daily living, and regular mealtimes. Sleep can be promoted by keeping the room dark and quiet throughout the evening, and preventing unnecessary interruptions. If nighttime sedation is required, atypical neuroleptics or low-dose serotonin reuptake inhibitors such as trazodone are better tolerated than benzodiazepines. If agitation persists, escalating doses of neuroleptics (or benzodiazepines in the setting of alcohol withdrawal) can be used to control behavior, but hidden causes of delirium must be considered.

## CARDIAC EVALUATION

### Risk Assessment

It has been estimated that 1 million patients have a perioperative MI each year, and the contribution to medical costs is \$20 billion annually.<sup>26</sup> Thoracic, upper abdominal, neurological, and major orthopedic procedures are associated with increased cardiac risk. Diabetes, prior MI, unstable angina, and decompensated congestive heart failure (CHF) are most predictive of perioperative cardiac morbidity and mortality, and patients with these conditions undergoing major surgery warrant further evaluation<sup>27</sup> (Table 2-2). Patient factors conferring intermediate risk include mild angina and chronic renal insufficiency with baseline creatinine  $\geq 2$  mg/dL.<sup>28</sup> It is worth noting that women were underrepresented in the studies on which the American College of Cardiology and the American Heart Association (ACC/AHA) guidelines are based.<sup>29</sup> A retrospective study in gynecological patients found that hypertension and previous MI were major predictors of postoperative cardiac events, as opposed to the ACC/AHA guidelines, which indicate that they are minor and intermediate criteria, respectively.<sup>30</sup> Therefore, vascular surgical patients are at highest risk because of the prevalence of underlying coronary disease in this population.<sup>27,31</sup> Other high-risk procedural factors include emergency surgery, long operative time, and high fluid replacement volume; these are associated with a more than 5% risk of perioperative cardiac



**TABLE 2-2: CLINICAL PREDICTORS OF INCREASED RISK FOR PERIOPERATIVE CARDIAC COMPLICATIONS**

#### Major

- Recent MI (within 30 days)
- Unstable or severe angina
- Decompensated CHF
- Significant arrhythmias (high-grade atrioventricular block, symptomatic ventricular arrhythmias with underlying heart disease, supraventricular arrhythmias with uncontrolled rate)
- Severe valvular disease

#### Intermediate

- Mild angina
- Any prior MI by history or ECG
- Compensated or prior CHF
- Diabetes mellitus
- Renal insufficiency

#### Minor

- Advanced age
- Abnormal ECG
- Rhythm other than sinus (eg, atrial fibrillation)
- Poor functional capacity
- History of stroke
- Uncontrolled hypertension (eg, diastolic blood pressure  $>10$  mm Hg)

morbidity and mortality. Intraoperative procedures, carotid endarterectomy, thoracic surgery, head and neck procedures, and orthopedic procedures carry an intermediate risk, and are associated with a 1–5% risk of a perioperative cardiac event.<sup>28</sup>

Perioperative evaluation to identify patients at risk for cardiac complications is essential in minimizing morbidity and mortality. Workup should start with history, physical examination, and ECG to determine the existence of cardiac pathology. Screening with chest radiographs and ECG is required for men over 40 and women over 55. According to the ACC/AHA guidelines, indications for preoperative cardiac testing should mirror those in the nonoperative setting.<sup>32</sup> The preoperative evaluation should include the surgeon, anesthesiologist, primary care physician, and possibly a cardiologist. Cardiology consultations are recommended for patients with major clinical predictors, those with intermediate clinical predictors and poor functional status undergoing intermediate-risk procedures, or those undergoing high-risk procedures with poor functional status or intermediate clinical predictors (Table 2-3). Overall functional ability is the best measure of cardiac health. Patients who can exercise without limitations can generally tolerate the stress of major surgery.<sup>33</sup> Limited exercise capacity may indicate poor cardiopulmonary reserve and the inability to withstand the stress of surgery. Poor functional status is the inability to perform activities such as driving, cooking, or walking less than 5 km/h.

Intraoperative risk factors include operative site, inappropriate use of vasopressors, and unintended hypotension. Intra-abdominal pressure exceeding 20 mm Hg during laparoscopy can decrease venous return from the lower extremities and thus contribute to decreased cardiac output,<sup>34</sup> and Trendelenburg positioning can result in increased pressure on the diaphragm from the abdominal viscera, subsequently reducing vital capacity. Intraoperative hypertension has not been isolated as a risk factor for cardiac morbidity, but it is often associated with wide fluctuations in pressure, and has been more closely associated with cardiac morbidity than intraoperative hypotension. Preoperative anxiety can contribute to hypertension even in normotensive patients. Those patients with a history of hypertension, even medically controlled hypertension, are more likely to be hypertensive preoperatively. Those with poorly controlled hypertension are at greater risk of developing intraoperative ischemia, arrhythmias, and blood

pressure derangements, particularly at induction and intubation. Twenty-five percent of patients will exhibit hypertension during laryngoscopy. Patients with chronic hypertension may not necessarily benefit from lower blood pressure during the preoperative period because they may depend on higher pressures for cerebral perfusion. Those receiving antihypertensive medications should continue them up until the time of surgery. Patients taking beta-blockers are at risk of withdrawal and rebound ischemia. Key findings on physical examination include retinal vascular changes and an  $S_4$  gallop consistent with left ventricular (LV) hypertrophy. Chest radiography may show an enlarged heart, also suggesting LV hypertrophy.

Noninvasive cardiac testing is used to define risk in patients known to be at high or intermediate risk, and detect those with CHF or dyspnea. It is most useful in intermediate-risk patients. No special laboratory tests are necessary unless there is evidence of active ischemia. A baseline ECG is necessary to identify any new ECG findings, to rule out active ischemia, and as a baseline for comparison during the postoperative period. The baseline ECG will be normal in 25–50% of patients with coronary disease, but no history of MI. A 12-lead ECG should be obtained in patients with chest pain, diabetes, prior revascularization, prior hospitalization for cardiac causes, all men age 45 or older, and all women aged 55 with two or more risk factors. High- or intermediate-risk patients should also have a screening ECG. A lower-than-normal ejection fraction demonstrated on echocardiography is associated with the greatest perioperative cardiac risk, and should be obtained in all patients with symptoms suggesting heart failure or valvular disease. Tricuspid regurgitation indicates pulmonary hypertension and is often associated with sleep apnea. The chest x-ray is used to screen for cardiomegaly and pulmonary congestion, which may signify ventricular impairment.

Exercise testing demonstrates a propensity for ischemia and arrhythmias under conditions that increase myocardial oxygen consumption. Numerous studies have shown that performance during exercise testing is predictive of perioperative mortality in noncardiac surgery. ST-segment changes during exercise including horizontal depression greater than 2 mm, changes with low workload, and persistent changes after 5 minutes of exercise are seen in severe multivessel disease. Other findings include dysrhythmias at a low heart rate, an inability to raise the heart rate to 70% of predicted, and sustained decrease in systolic pressure during exercise.

Unfortunately, many patients are unable to achieve adequate workload in standard exercise testing because of osteoarthritis, low back pain, and pulmonary disease. In this case, pharmacological testing is indicated with a dobutamine echocardiogram. Dobutamine is a beta-agonist that increases myocardial oxygen demand and reveals impaired oxygen delivery in those with coronary disease. Echocardiography concurrently visualizes wall motion abnormalities due to ischemia. Transesophageal echocardiography may be preferable to transthoracic echocardiography in obese patients because of their body habitus, and has been shown to have high negative predictive value in this group.<sup>35</sup> Nuclear perfusion imaging with vasodilators such as adenosine or dipyridamole can identify coronary artery disease



**TABLE 2-3: FACTORS THAT INCREASE THE RISK OF PERIOPERATIVE CARDIAC COMPLICATIONS**

Risk Variable	Odds Ratio (95% Confidence Interval)
Poor functional status	1.8 (0.9–3.5)
Ischemic heart disease	2.4 (1.3–4.2)
Heart failure	1.9 (1.1–3.5)
Diabetes	3.0 (1.3–7.1)
Renal insufficiency	3.0 (1.4–6.8)
High-risk surgery	2.8 (1.6–4.9)

and demand ischemia. Heterogeneous perfusion after vasodilator administration demonstrates an inadequate response to stress. Wall motion abnormalities indicate ischemia and an ejection fraction lower than 50% increases the risk of perioperative mortality. Angiography should only be performed if the patient may be a candidate for revascularization.

## Coronary Disease

Most perioperative MIs are caused by plaque rupture in lesions that do not produce ischemia during preoperative testing.<sup>36</sup> This presents an obvious challenge for detecting

patients at risk. Stress testing has a low positive predictive value in patients with no cardiac risk factors, and has been associated with an unacceptably high rate of false-positives.<sup>37</sup>

Preoperative optimization may include medical management, percutaneous coronary interventions (PCI), or coronary artery bypass grafting (CABG).<sup>38</sup> The ACC/AHA guidelines (Fig. 2-1) recommend coronary revascularization prior to noncardiac surgery in the following situations:

1. The combined risk of the two procedures does not exceed the risk of the surgical procedure alone.

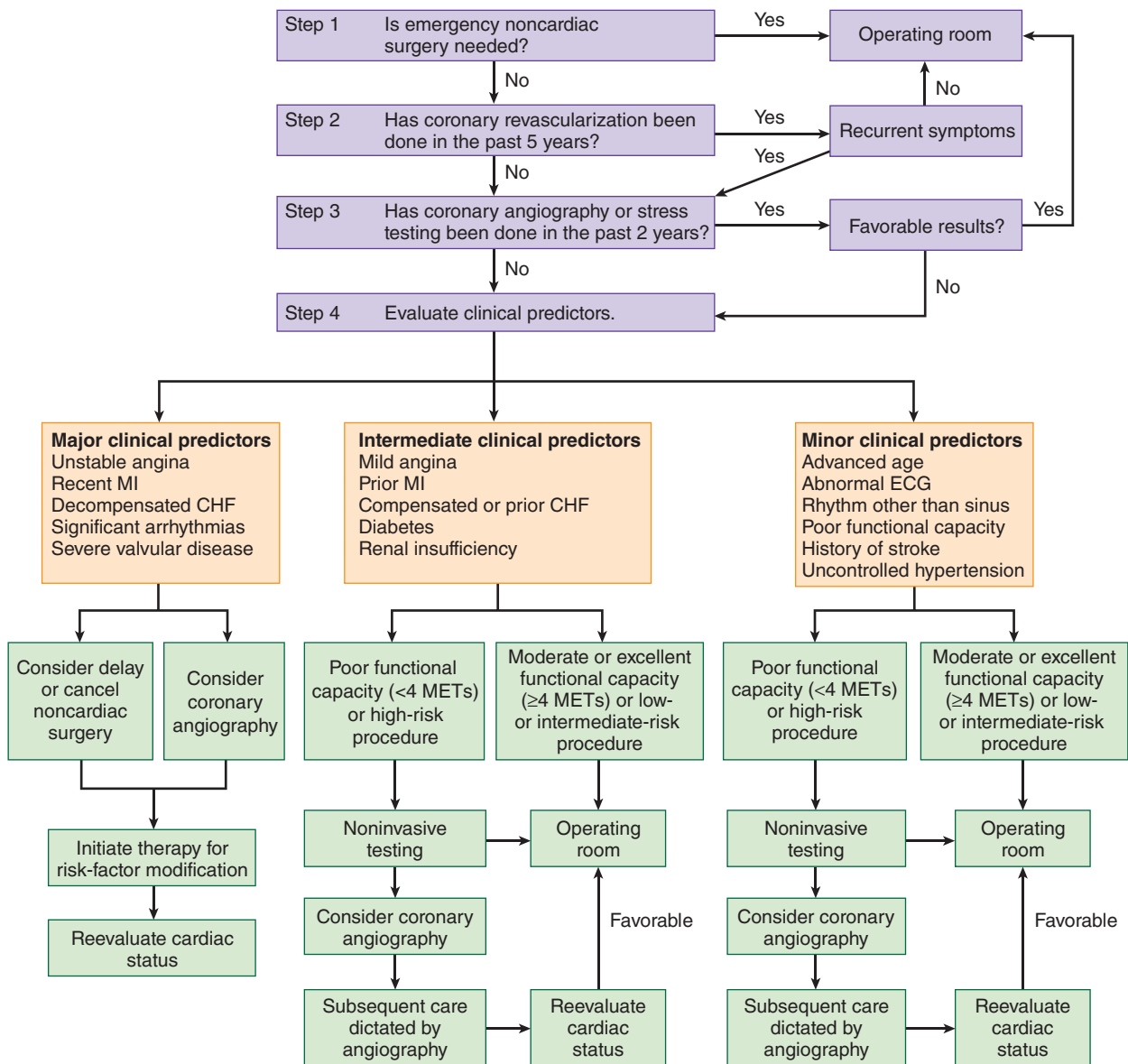


FIGURE 2-1 Preoperative cardiac risk assessment algorithm suggested by the ACC/AHA. (Adapted with permission from Eagle KA, Brundage BH, Chaitman BR, et al. Guidelines for perioperative cardiovascular evaluation for noncardiac surgery. Report of the American College of Cardiology/American Heart Association Task Force on Practice Guidelines [Committee on Perioperative Cardiovascular Evaluation for Noncardiac Surgery]. *J Am Coll Cardiol.* 1996;27:921.) MI, myocardial infarction; CHF, congestive heart failure; ECG, electrocardiography; METs, metabolic equivalents.



2. Revascularization should reduce the risk of the noncardiac surgery more than the risk of the revascularization procedure itself.
3. Revascularization should not unduly delay the noncardiac surgery, especially if it is urgent.

Patients warranting emergent CABG will be at greatest risk for that procedure. A recent study from the Veterans Administration Hospitals recommends against revascularization in patients with stable cardiac symptoms.<sup>39</sup> Preoperative PCI does not decrease the risk of future MI or mortality in patients with stable coronary disease, and only targets stenotic lesions, rather than those most likely to rupture. One retrospective study found no reduction in morbidity or perioperative MI after percutaneous transluminal coronary angioplasty, and the authors proposed that surgery within 90 days of balloon angioplasty increased the risk of thrombosis.<sup>40</sup> However, PCI done more than 90 days before surgery did provide benefit when compared to those who had no intervention at all. Another retrospective study found that patients who have surgery within 2 weeks of stenting had a high incidence of perioperative MI, major bleeding, or death.<sup>41</sup> Although a retrospective review from the Coronary Artery Surgery Study registry showed a lower mortality rate in patients with coronary artery disease who were post-CABG than those without CABG (0.09 vs 2.4%), this benefit did not include the morbidity associated with CABG itself. Unfortunately, the benefit was overwhelmed by the 2.3% morbidity rate seen with CABG in this cohort.<sup>42</sup> Survival benefit of CABG over medical management is realized for 2 years after surgery<sup>43</sup> so that preoperative mortality may decrease overall short-term survival. Revascularization and bypass grafting should be restricted to patients who would benefit from the procedure independent of their need for noncardiac surgery. One of the disadvantages of PCI in the preoperative setting is the need for anticoagulation to prevent early stent occlusion. The use of platelet inhibitors to prevent stent occlusion must be included in the overall risk assessment, especially for surgery of the central nervous system.

Catecholamine surges can cause tachycardia, which may alter the tensile strength of coronary plaques and incite plaque rupture.<sup>44,45</sup> Catecholamine surges can also increase blood pressure and contractility, contributing to platelet aggregation and thrombosis after plaque rupture and increasing the possibility of complete occlusion of the arterial lumen.<sup>46</sup> Perioperative beta-blockade mitigates these effects and has been shown to reduce MI and mortality from MI by over 30% in vascular surgical patients with reversible ischemia.<sup>44</sup> Patients at highest risk still have a cardiac event rate of 10%, even with adequate perioperative beta-blockade.<sup>37</sup>

In 1998, a landmark study<sup>47</sup> demonstrated a 55% reduction in mortality in non-cardiac surgical patients with known coronary disease who were given atenolol perioperatively. This was followed by the DECREASE trial<sup>48</sup>, which showed a 10-fold reduction in perioperative MI and death compared to placebo. Thereafter, perioperative beta-blockade was widely adopted as a quality measure. However, more

recent investigations have shown that while perioperative beta-blockers benefit patients with known ischemia, low-risk patients may in fact be harmed.<sup>49</sup> Tight rate control has been associated with increased risk of hypotension and bradycardia requiring intervention, and stroke without any significant decrease in mortality.<sup>50–53</sup> Furthermore, critical analysis of the literature shows that studies have been inconsistent in the type of medication administered, the duration and timing of administration, or the target for heart rate control.<sup>54</sup> Consequently, results are difficult to interpret. Thus, prophylactic perioperative beta-blockade should be restricted to patients with cardiac ischemia and has a limited role in patients with low or moderate risk of postoperative cardiac events.

## Congestive Heart Failure and Arrhythmia

Congestive heart failure (CHF) is associated with coronary disease, valvular disease, ventricular dysfunction, and all types of cardiomyopathy. These are all independent risk factors that should be identified prior to surgery. Even compensated heart failure may be aggravated by fluid shifts associated with anesthesia and abdominal surgery and deserves serious consideration. Perioperative mortality increases with higher New York Heart Association class and preoperative pulmonary congestion. CHF should be treated to lower filling pressures and improve cardiac output before elective surgery. Beta-blockers, angiotensin-converting enzyme inhibitors, and diuretics can be employed to this end. The patient should be stable for 1 week before surgery.<sup>55</sup>

Arrhythmias and conduction abnormalities elicited in the history, on examination, or on ECG, should prompt investigation into metabolic derangements, drug toxicities, or coronary disease. In the presence of symptoms or hemodynamic changes, the underlying condition should be reversed and then medication given to treat the arrhythmia. Indications for anti-arrhythmic medication and cardiac pacemakers are the same as in the nonoperative setting. Nonsustained ventricular tachycardia and premature ventricular contractions have not been associated with increased perioperative risk and do not require further intervention.<sup>56,57</sup>

## Valvular Disease

Valvular disease should be considered in patients with symptoms of CHF, syncope, and a history of rheumatic heart disease (RHD). Aortic stenosis (AS) is a fixed obstruction to the LV outflow tract, limiting cardiac reserve and an appropriate response to stress. History should elicit symptoms of dyspnea, angina, and syncope; examination may reveal a soft S<sub>2</sub>, a late peaking murmur, or a right-sided crescendo-decrescendo murmur radiating to the carotids. AS is usually caused by progressive calcification or congenital bicuspid valve. Critical stenosis exists when the valve area is less than 0.7 cm<sup>2</sup> or

transvalvular gradients are greater than 50 mm Hg, and is associated with an inability to increase cardiac output with demand. If uncorrected, AS is associated with a 13% risk of perioperative death. Valve replacement is indicated prior to elective surgery in patients with symptomatic stenosis.<sup>58</sup> Myocardial ischemia may occur in the absence of significant coronary artery occlusion in the presence of aortic valve disease. Perioperative management should include optimizing the heart rate to between 60 and 90 beats per minute and avoiding atrial fibrillation if possible. Because of the outflow obstruction, stroke volume may be fixed and bradycardia will lower cardiac output. Similarly, hypotension is also poorly tolerated.

Aortic regurgitation (AR) is associated with backward flow into the left ventricle during diastole and reduced forward stroke volume. Bradycardia facilitates regurgitation by increased diastolic time. Chronic AR causes massive LV dilatation (cor bovinum) and hypertrophy, which is associated with decreased LV function at later stages. AR is most often caused by rheumatic disease or congenital bicuspid valve. Medical treatment includes rate control and afterload reduction. Without valve replacement, survival is approximately 5 years once patients become symptomatic. This is an obvious consideration when planning any other surgical procedures.

Tricuspid regurgitation is usually caused by pulmonary hypertension secondary to severe left-sided failure. Other causes include endocarditis, carcinoid syndrome, and primary pulmonary hypertension. Hypovolemia, hypoxia, and acidosis can increase right ventricular afterload and should be avoided in the perioperative period.

Mitral stenosis is an inflow obstruction that prevents adequate LV filling. The transvalvular pressure gradient depends on atrial kick, heart rate, and diastolic filling time. Tachycardia decreases filling time and contributes to pulmonary congestion. Mitral regurgitation is also associated with pulmonary hypertension with congestion, as the pathologic valve prevents forward flow, causing left atrial dilatation, and subsequent atrial arrhythmias. History and physical examination should focus on signs of CHF such as orthopnea, pedal edema, dyspnea, reduced exercise tolerance, and auscultatory findings such as murmurs and an  $S_3$  gallop. Neurological deficits may signify embolic sequelae of valve disease. Perioperative rate control is essential for maintaining adequate cardiac output. ECG findings will reflect related arrhythmias and medications, but will not be specific for valve disease. Laboratory studies should identify secondary hepatic dysfunction or pulmonary compromise. Left ventricular hypertrophy is an adaptive response, which may cause subsequent pulmonary hypertension and diastolic dysfunction.

Prosthetics in the mitral position pose the greatest risk for thromboembolism, and the risk increases with valve area and low flow. Mechanical valves pose a higher risk than tissue valves in patients with a history of valve replacement. Diuretics and afterload-reducing agents will enhance forward flow and minimize cardiopulmonary congestion. Patients with mitral valve prolapse (MVP) should receive antibiotics.

Mitral regurgitation may also impair LV function and lead to pulmonary hypertension. Stroke volume is reduced by backward flow into the atrium during systole. The left ventricle dilates to handle increasing end-systolic volume, eventually causing concentric hypertrophy and decreased contractility. The end result may be decreased ejection fraction and CHF. A decrease in systemic vascular resistance and an increase in atrial contribution to the ejection fraction can both improve forward flow and reduce the amount of regurgitation. Echocardiography can clarify the degree of valvular impairment. Medical treatment centers on afterload reduction with vasodilators and diuretics. MVP is present in up to 15% of women, and is usually associated with a midsystolic click and late systolic murmur on physical examination. Murmur is indicative of prolapse. Although MVP is associated with connective tissue disorders, it usually occurs in otherwise healthy, asymptomatic patients. Echocardiography is used to confirm the diagnosis and evaluate the degree of prolapse. Chronically, MVP may be associated with mitral regurgitation, emboli, and increased risk of endocarditis. Prolapse may be aggravated by decreased preload, which should be minimized in the perioperative period. Patients with MVP are at risk of ventricular arrhythmias with sympathetic stimulation and endocarditis, which can be addressed with pain control and antibiotic prophylaxis, respectively.

Individuals with underlying structural cardiac defects are at increased risk for developing endocarditis after invasive procedures. Surgical procedures involving mucosal surfaces or infected tissues may cause transient bacteremia that is usually short-lived. Certain procedures are associated with a greater risk of endocarditis and warrant prophylaxis (Table 2-4). Abnormal valves, endocardium, or endothelium can harbor the blood-borne bacteria for a longer period of time, and infection and inflammation can ensue. While there



**TABLE 2-4: AHA ENDOCARDITIS  
PROPHYLAXIS RECOMMENDATIONS**

**Antibiotic Coverage Recommended:**

Respiratory: tonsillectomy/adenoidectomy; rigid bronchoscopy; procedures involving respiratory mucosa  
Gastrointestinal tract: sclerotherapy for esophageal varices; esophageal dilation; ERCP; biliary tract surgery; procedures involving intestinal mucosa  
Genitourinary tract: prostatic surgery; cystoscopy; urethral dilation

**Antibiotic Coverage Not Recommended:**

Respiratory: endotracheal intubation; flexible bronchoscopy; tympanostomy tube insertion  
Gastrointestinal tract: transesophageal echocardiography; endoscopy without biopsy  
In uninfected tissue: urethral catheterization; uterine dilation and curettage; therapeutic abortion; manipulation of intrauterine devices  
Other: cardiac catheterization; pacemaker placement; circumcision; incision or biopsy on prepped skin

are no randomized trials regarding endocarditis prophylaxis, the American Heart Association recommends prophylaxis for those<sup>59</sup> at high and moderate risk for developing the condition. Highest-risk patients have prosthetic heart valves, cyanotic congenital heart disease, or a history of endocarditis (even without structural abnormality).<sup>60</sup> Conditions associated with moderate risk include congenital septal defects, patent ductus arteriosus, coarctation of the aorta, and bicuspid aortic valve. Hypertrophic cardiomyopathy and acquired valvular disease also fall into this category. Mitral valve prolapse is a prevalent and often situational condition. Normal valves may prolapse in the event of tachycardia or hypovolemia, and may reflect normal growth patterns in young people. Prolapse without leak or regurgitation seen on Doppler studies is not associated with risk greater than that of the general population and no antibiotic prophylaxis is necessary.<sup>61,62</sup> However, the jet caused by the prolapsed valve increases the risk of bacteria sticking to the valve and subsequent endocarditis. Leaky valves detected by physical examination or Doppler warrant prophylactic antibiotics.<sup>62</sup> Those with significant regurgitation are more likely to be older and men, and other studies have shown that older men are more likely to develop endocarditis.<sup>63–65</sup> Some advocate prophylaxis for men older than 45 years with MVP even in the absence of audible regurgitation.<sup>65</sup> Prolapse secondary to myxomatous valve degeneration also warrants prophylactic antibiotics.<sup>66,67</sup> Prophylaxis is indicated in cases in whom mitral regurgitation cannot be determined.<sup>68</sup>

For patients at risk the goal should be administration of antibiotics in time to attain adequate serum levels during and after the procedure. For most operations, a single intravenous dose given 1 hour prior to incision will achieve this goal. Antibiotics should generally not be continued for more than 6–8 hours after the procedure to minimize the chance of bacterial resistance. In the case of oral, upper respiratory, and esophageal procedures, alpha-hemolytic streptococcus is the most common cause of endocarditis, and antibiotics should be targeted accordingly. Oral amoxicillin, parenteral ampicillin, and clindamycin for penicillin-allergic patients are suitable medications. Erythromycin is no longer recommended for penicillin-allergic patients because of gastrointestinal side effects and variable absorption.<sup>69</sup> Antibiotics given to those having genitourinary and nonesophageal gastrointestinal procedures should target enterococci.<sup>69</sup> While gram-negative bacteremia can occur, it rarely causes endocarditis. Parenteral ampicillin and gentamicin are recommended for highest-risk patients. Moderate-risk patients may receive amoxicillin or ampicillin. Vancomycin may be substituted in patients allergic to penicillin.

## PERIOPERATIVE MANAGEMENT OF ANTITHROMBOTIC MEDICATION

Estimates suggest that 250,000 patients receiving chronic anticoagulation require surgery in the United States each year. Operative bleeding risk must be balanced against thromboembolic risk for the patient off of anticoagulation, and

requires careful judgment. Factors that influence the risk of thromboembolism include the condition requiring chronic anticoagulation, the duration of the procedure, time expected off of anticoagulation, and the duration of perioperative immobility. Thromboembolic risk increases with the amount of time that the patient's anticoagulation is subtherapeutic.

Primary indications for chronic anticoagulation include arterial embolism associated with mechanical valves and atrial fibrillation and venous thromboembolism (VTE). Arterial events precipitate stroke, and valvular and atrial clot and systemic emboli are higher risk for morbidity and mortality than venous events. According to the American College of Chest Physicians Practice Guidelines for the Perioperative Management of Antithrombotic Therapy,<sup>70</sup> patients at highest risk for perioperative embolism have mechanical mitral valves, aortic caged-ball and tilted valves, RHD, or history of stroke or transient ischemic attacks (TIA) in the past 3 months. The risk of thromboembolism without anticoagulation is higher than 10% per year in high-risk patients.

Patients at moderate risk of thromboembolism without anticoagulation, 4–10% per year, have atrial fibrillation, a bileaflet valve, or history of stroke or TIA. The congestive heart failure-hypertension-age-diabetes-stroke score (CHADS<sub>2</sub>) further stratifies embolic risk for patients with atrial fibrillation based on comorbidities. One point is assigned for hypertension, diabetes, congestive heart failure, and age >75 years; two points are assigned for history of stroke or TIA. Patients with a cumulative score of 5–6 are highest risk; 3–4 are moderate risk, and 0–2 without history of stroke or TIA are low risk.

Chronic anticoagulation is indicated for VTE. Patients with VTE within 3 months of surgery and severe thrombophilia are at highest risk for perioperative events and should receive bridging anticoagulation with therapeutic doses of low-molecular weight heparin (LMWH) or intravenous unfractionated heparin (IV UFH). Patients at moderate risk include those with thromboembolic event 3–12 months before surgery and less severe thrombophilias. They can receive therapeutic or subtherapeutic doses of anticoagulation depending on the risk of bleeding associated with the procedure. Patients with a remote event are at lowest risk, and do not require bridging anticoagulation. It is generally recommended to stop Warfarin 5 days prior to surgery if a normal International Normalized Ratio (INR) is desired. Vitamin K may be administered in days leading up to the event if the INR is not coming down quickly enough.

LMWH should be held 24 hours before surgery, and IV UFH should be held 4 hours before surgery. Oral anticoagulants may be started 12–24 hours postoperatively because they take at least 48 hours to effect coagulation. The timing of resuming IV and SC anticoagulants should be determined on a case-by-case basis.

Low-risk patients receiving Clopidogrel or aspirin should have it held 5–10 days before surgery. Patients with coronary stents are chronically treated with Clopidogrel and aspirin to mitigate the risk of stent thrombosis. Interruptions in therapy are associated with high risk of thrombosis and infarct.

Patients with bare metal stents placed within 6 weeks of surgery, and drug-eluting stents within 12 months of surgery, should continue Clopiogrel and aspirin in the perioperative period.

## PULMONARY EVALUATION

Pulmonary complications are common after surgery, and can prolong hospital stays for 1–2 weeks.<sup>71</sup> Complications include atelectasis, pneumonia, exacerbations of chronic pulmonary disorders, and respiratory failure requiring mechanical ventilation. Smoking, underlying chronic obstructive pulmonary disease (COPD), and poor exercise tolerance are the greatest risk factors for postoperative pulmonary complications. Physicians should ask about a history of smoking, decreased exercise capacity, dyspnea, and chronic cough. Examination should note pursed lip breathing, clubbing, and chest wall anatomy that could impair pulmonary function. Pulmonary testing is unnecessary in patients without a clear history of smoking or pulmonary disease. The predictive value of screening spirometry is unclear, and no threshold value has been identified to guide surgical decision making. Forced expiratory volume in 1 second less than 50% of predicted is indicative of exertional dyspnea and may herald the need for further testing. Preoperative chest x-ray abnormalities are associated with postoperative pulmonary complications,<sup>71</sup> but to this point there are no recommendations for screening radiographs in patients without pulmonary disease. Any preoperative chest x-ray must be examined for signs of hyperinflation consistent with COPD. While compensated hypercapnia has not been shown to be an independent predictor for postoperative ventilatory insufficiency in patients undergoing lung resection, preoperative arterial blood gas analysis provides useful baseline information for perioperative management of patients with chronic CO<sub>2</sub> retention. Transverse and upper abdominal incisions are associated with a higher rate of postoperative pulmonary complications than longitudinal midline incisions and lower abdominal incisions.<sup>72</sup> Surgery longer than 3 hours is also associated with higher risk.<sup>73</sup> General anesthesia is also associated with a higher risk of pulmonary complications than spinal, epidural, or regional anesthesia.<sup>74</sup>

Physiologic changes can be seen in the postoperative period, especially after thoracic and upper abdominal procedures. Vital capacity may decrease by 50–60%, and is accompanied by an increased respiratory rate to maintain tidal volumes. Normally, functional residual capacity usually exceeds the closing capacity of the alveoli, so they remain open throughout the respiratory cycle. Prolonged effects of anesthetics and narcotics reduce functional reserve capacity postoperatively, causing alveolar collapse. These changes can last for weeks to months. A distended abdomen can impair diaphragmatic excursion; painful incisions around the diaphragm and other respiratory muscles contribute to splinting and inadequate pulmonary toilet. Narcotics can inhibit sighing and coughing reflexes, which normally prevent alveolar

collapse during periods of sleep and recumbency. Analgesics must be titrated carefully to permit deep breathing and avoid impairing respiratory effort.

Inspired nonhumidified oxygen and halogenated anesthetics are cytotoxic and interfere with surfactant production and mucociliary clearance. Depressed respiratory reflexes, diaphragm dysfunction, and decreased functional reserve capacity all contribute to alveolar collapse and pooling of secretions. Aspiration risk is also increased. Excess secretions cause further alveolar collapse and create a milieu ripe for bacterial infection and pneumonia. Intubated patients should receive antacid prophylaxis and gastric drainage to minimize the risk of aspiration.

Multiple analyses have found that poor exercise tolerance is the greatest predictor of postoperative pulmonary impairment. The ASA risk classification is a gauge of general status, and is highly predictive of both cardiac and pulmonary complications.<sup>75,76</sup> Although advanced age is associated with increased incidence of chronic pulmonary disease and underlying impairment, it is not an independent risk factor for pulmonary complications.

Clearly, all smokers should be urged to stop before surgery. Even in the absence of coexisting pulmonary disease, smoking increases the risk of perioperative complications. Smoking confers a relative risk of 1.4–4.3, but a reduced risk of pulmonary complications has been shown in patients who stop smoking at least 8 weeks before cardiac surgery.<sup>77</sup> Even 48 hours of abstinence can improve mucociliary clearance, decrease carboxyhemoglobin levels to those of nonsmokers, and reduce the cardiovascular effects of nicotine. A nicotine patch may help some patients with postoperative nicotine withdrawal, but may not be advisable in patients at risk for poor wound healing.

COPD confers a relative risk of 2.7–4.7 in various studies. Symptoms of bronchospasm and obstruction should be addressed before surgery and elective procedures should be deferred in patients having an acute exacerbation. Preoperative treatment may include bronchodilators, antibiotics, steroids, and physical therapy to increase exercise capacity. Patients with active pulmonary infections should have surgery delayed if possible. Asthmatics should have peak flow equivalent to their personal best or 80% of predicted, and should be medically optimized to achieve this goal. Pulse corticosteroids may be used without an increased risk of postoperative infection or other complication.<sup>78,79</sup>

Malnourished patients may not be able to meet the demands of the increased work of breathing, increasing their risk for respiratory failure. Obese patients have higher rates of oxygen consumption and carbon dioxide production, which increases their work of breathing. They may also exhibit restrictive physiology due to a large, stiff chest wall. A complete history should inquire about sleeping difficulty and snoring. Obesity increases the amount of soft tissue in the oropharynx, which can cause upper airway obstruction during sleep. Fifty-five percent of morbidly obese patients may have sleep-related breathing disorders such as obstructive sleep apnea and obesity-hypoventilation syndrome.<sup>80</sup>



Symptoms include snoring and daytime sleepiness, and formal sleep studies are employed for definitive diagnosis. Sleep-disordered breathing is associated with hypoxia, hypercapnia, changes in blood pressure, nocturnal angina, and increased cardiac morbidity and mortality including stroke and sudden death.<sup>81</sup> Arterial blood gas with partial arterial oxygen pressure less than 55 mm Hg or partial arterial carbon dioxide pressure greater than 47 mm Hg confirms the diagnosis. An increased incidence of pulmonary hypertension and right-sided heart failure is seen in patients with obesity hypoventilation syndrome and these patients should have an echocardiogram before surgery. In severe cases, intraoperative monitoring with a pulmonary artery catheter may be prudent.

In the patient who is awake, postoperative care should include coughing and deep breathing exercises, and in non-ambulatory patients, early mobilization should include turning every 2 hours. Early ambulation prevents atelectasis and pooling of secretions, and increases the ventilatory drive. Upright position distributes blood flow and minimizes shunting. Preoperative medications should be resumed expeditiously. Incentive spirometry and pulmonary toilet are pulmonary expansion maneuvers, which reduce the relative risk of pulmonary complications by 50%.<sup>82</sup> Patients should receive preoperative education about these techniques. Inhaled ipratropium and beta-agonists, used together, may prevent postoperative wheezing and bronchospasm, and should be prescribed in patients at risk. Intermittent positive pressure ventilation and nasal bi-level positive airway pressure may be enlisted for secondary prevention. Epidural analgesia is superior to parenteral narcotics in abdominal and thoracic procedures for preventing pulmonary complications.

## GASTROINTESTINAL EVALUATION

Stress ulceration has been a well-recognized complication of surgery and trauma since 1932, when Cushing reported gastric bleeding accompanying head injury. With later research in gastric physiology and shock, it has been recognized that the appearance of gastric erosion results from failure of the protective function of gastric mucosa and back diffusion of hydrogen ion, enabling gastric acid to injure the mucosa. Once the mucosa is injured, the defenses are further weakened, leading to further injury in a vicious cycle. The protective functions of the mucosa rely on the stomach's rich blood flow to maintain high oxygen saturation. The most critical factor in the development of erosive ulceration now appears to be mucosal ischemia. Once the rich blood supply of the mucosa is compromised, the protective mechanisms are impaired, and gastric acid causes erosion, bleeding, and perforation.

In the late 1970s, the incidence of gastric bleeding in critically ill patients was 15%. Recognition of the importance of organ perfusion has resulted in decreased rates of erosive stress gastritis. Factors often cited for this observation are: improvement in resuscitation and monitoring technology, nutritional support, and effective agents for

medical prophylaxis. The prophylactic medicines are targeted to reduce gastric acidity. Antacids have been shown to provide effective protection against erosive ulceration; however, there is some risk of aspiration pneumonia. Antagonists of the histamine-2 ( $H_2$ ) receptors of the parietal cells impair gastric acid secretion and also are effective prophylaxis for erosive ulceration. Due to ease of use,  $H_2$ -blockers have become the mainstay of stress ulcer prophylaxis in abdominal surgery.<sup>83</sup>

In the setting of elective operations when the patients are not critically ill, the incidence of stress ulceration is now very low and routine use of ulcer prophylaxis medication has been questioned. In addition, the routine use of  $H_2$ -antagonists in this setting may lead to increased risk of pneumonia because of failure of the gastric juices to kill bacteria.

## Postoperative Ileus

Ileus is a condition of generalized bowel dysmotility that frequently impairs feeding in the postoperative setting. Ileus typically occurs after abdominal surgery, even if the bowel itself is not altered. It has been shown that laparotomy alone, without intestinal manipulation, leads to impaired gastrointestinal motility. The small bowel is typically affected the least, and can maintain organized peristaltic contractions throughout the perioperative period. The stomach usually regains a normal pattern of emptying in 24 hours, and the colon is last to regain motility, usually in 48–72 hours.

The exact mechanism that causes postoperative ileus is not known; however, physiologic studies have demonstrated the significant contribution of both inhibitory neural reflexes and local mediators within the intestinal wall. Inhibitory neural reflexes have been shown to be present within the neural plexuses of the intestinal wall itself, and in the reflex arcs traveling back and forth from the intestine to the spinal cord. These neural pathways may account for the development of ileus during laparotomy without bowel manipulation. In addition, inflammatory mediators such as nitric oxide are present in manipulated bowel and in peritonitis and may play a role in the development of ileus.

Ileus can be recognized from clinical signs, such as abdominal distension, nausea, and the absence of bowel sounds and flatus, which should prompt the diagnosis. Abdominal x-ray imaging typically shows dilated loops of small bowel and colon. Bowel obstruction must also be considered with these clinical findings, however, and CT or other contrast imaging may be required to rule out obstruction.

Ileus can also appear following nonabdominal surgery, and can result from the effects of medications (most often narcotics), electrolyte abnormalities (especially hypokalemia), and a wide variety of other factors.

Occasionally, the patient sustains a prolonged period of postoperative ileus. This can be due to a large number of contributing factors, such as intra-abdominal infection, hematoma, effects of narcotics and other medications, electrolyte abnormalities, and pain. In addition, there can be prolonged

dysmotility from certain bowel operations, such as intestinal bypass.

The role of laparoscopic surgery in prevention of ileus is controversial. In theory, with less handling of the bowel laparoscopically and with smaller incisions, there should be less stimulation of the local mediators and neural reflexes. Animal studies comparing open and laparoscopic colon surgery indicate earlier resumption of normal motility studies and bowel movements with the laparoscopic approach. Human trials have not been conclusive. Several series demonstrate earlier tolerance of postoperative feeding with the laparoscopic approach to colon resection; however, these have been criticized for selection bias, and such studies are impossible to conduct in a blind fashion.

Early mobilization has long been held to be useful in prevention of postoperative ileus. While standing and walking in the early postoperative period have been proven to have major benefits in pulmonary function and prevention of pneumonia, mobilization has no demonstrable effect on postoperative ileus.

In the expected course of uncomplicated abdominal surgery, the stomach is frequently drained by a nasogastric tube for the first 24 hours after surgery, and the patient is not allowed oral intake until there is evidence that colonic motility has returned, usually best evidenced by the passage of flatus. Earlier feeding and no gastric drainage after bowel surgery can be attempted for healthy patients undergoing elective abdominal surgery, and has a high rate of success provided clinical symptoms of ileus are not present. In such patients, the use of effective preventive strategies is highly effective. These include maintenance of normal serum electrolytes, use of epidural analgesia, and avoidance of complications such as infection and bleeding. The routine use of nasogastric tubes for drainage in the postoperative period after abdominal surgery has come into question since the mid-1990s.

The most effective strategy for management of postoperative ileus following abdominal surgery has been the development of epidural analgesia. Randomized trials have shown that the use of nonnarcotic (local anesthetic-based) epidural analgesia at the thoracic level in the postoperative period results in a decreased period of postoperative ileus in elective abdominal surgery. Ileus reduction is not seen in lumbar level epidural analgesia, suggesting that inhibitory reflex arcs involving the thoracic spinal cord may play a major role in postoperative ileus.

Narcotic analgesia, while effective for postoperative pain, has been shown to lengthen the duration of postoperative ileus, especially when used as a continuous infusion or as PCA. Patients report better control of postoperative pain with continuous infusion or PCA as compared to intermittent parenteral dosing. Many studies have been done comparing various types of opioid analgesics, in attempts to find a type that does not prolong ileus. There has been no clearly superior drug identified; all currently available opioids cause ileus. Opioid antagonists such as naloxone have been used in trials to decrease ileus in chronic narcotic use, and there is evidence that antagonists are effective in that setting; however, in

postoperative ileus, the antagonists have not been shown to be clinically useful, again suggesting that other mechanisms are contributing to postoperative ileus.

## Early Postoperative Bowel Obstruction

Early postoperative bowel obstruction refers to mechanical bowel obstruction, primarily involving the small bowel, which occurs in the first 30 days following abdominal surgery. The clinical picture may frequently be mistaken for ileus, and these conditions can overlap. The clinical presentation of early postoperative bowel obstruction is similar to that of bowel obstruction arising *de novo*: crampy abdominal pain, vomiting, abdominal distention, and obstipation. The incidence of early postoperative bowel obstruction has been variable in published series, due to difficulty in differentiating ileus from early postoperative bowel obstruction, but the reported range is from 0.7% to 9.5% of abdominal operations.

Retrospective large series show that about 90% of early postoperative bowel obstruction is caused by inflammatory adhesions. These occur as a result of injury to the surfaces of the bowel and peritoneum during surgical manipulation. The injury prompts the release of inflammatory mediators that lead to formation of fibrinous adhesions between the serosal and peritoneal surfaces. As the inflammatory mediators are cleared and the injury subsides, these adhesions eventually mature into fibrous, firm, and bandlike structures. In the early postoperative period, the adhesions are in their inflammatory, fibrinous form, and as such do not usually cause complete mechanical obstruction.

Internal hernia is the next most common cause of early postoperative bowel obstruction, and can be difficult to diagnose short of repeat laparotomy. Internal hernia occurs when gaps or defects are left in the mesentery or omentum, or blind gutters or sacs are left in place during abdominal surgery. The typical scenario is colon resection involving extensive resection of the mesentery for lymph node clearance. If the resulting gap in the mesentery is not securely closed, small bowel loops may go through the opening and not be able to slide back out. A blind gutter may be constructed inadvertently during the creation of a colostomy. When the colostomy is brought up to the anterior abdominal wall, there is a space between the colon and the lateral abdominal wall, which may also trap the mobile loops of small bowel. Defects in the closure of the fascia during open or laparoscopic surgery can cause obstruction from incarcerated early postoperative abdominal wall hernia. Fortunately, internal hernia is a rare occurrence in the early postoperative period; however, it must be suspected in cases where bowel anastomoses or colostomies have been constructed. Unlike adhesive obstruction, internal hernia requires operative intervention due to the high potential for complete obstruction and strangulation of the bowel.

Intussusception is a rare cause of early postoperative bowel obstruction in adults, but occurs more frequently in children. Intussusception occurs when peristalsis carries a segment of the bowel (called the lead point) up inside the distal bowel

like a rolled up stocking. The lead point is usually abnormal in some way, and typically has some intraluminal mass, such as a tumor or the stump of an appendix after appendectomy. Other rare causes for early postoperative bowel obstruction include missed causes of primary obstruction at the index laparotomy, peritoneal carcinomatosis, obstructing hematoma, and ischemic stricture.

Management of early postoperative bowel obstruction depends on differentiation of adhesive bowel obstruction (the majority) from internal hernia and the other causes, and from ileus. Clinicians generally rely on radiographic imaging to discern ileus from obstruction. For many years, plain x-ray of the abdomen was used: if the abdominal plain film showed air-distended loops of bowel and air-fluid levels on upright views, the diagnosis of obstruction was favored. However, plain radiographs can be misleading in the postoperative setting, and the overlap of ileus and obstruction can be confusing. Upper GI contrast studies using a water-soluble agent has better accuracy, and abdominal CT using oral contrast has been shown to have 100% sensitivity and specificity in differentiating early postoperative bowel obstruction from postoperative ileus.

Once the diagnosis is made, management is tailored to the specific needs of the patient. Decompression via nasogastric tube is usually indicated, and ileus can be treated as discussed. Adhesive bowel obstruction warrants a period of expectant management and supportive care, as the majority of these problems will resolve spontaneously. Most surgical texts recommend that the waiting period can be extended to 14 days. If the early bowel obstruction lasts longer than 14 days, less than 10% resolve spontaneously, and exploratory laparotomy is indicated. The uncommon causes of early postoperative bowel obstruction, such as internal hernia, require more early surgical correction, and should be suspected in the setting of complete obstipation, or when abdominal CT suggests internal hernia or complete bowel obstruction.

## Renal Evaluation

Patients without a clinical history suggesting renal disease have a low incidence of significant electrolyte disturbances on routine preoperative screening.<sup>84</sup> However, those patients with renal or cardiac disease who are taking digitalis or diuretics, or those with ongoing fluid losses (ie, diarrhea, vomiting, fistula, and bleeding) do have an increased risk of significant abnormalities and should have electrolytes measured and replaced preoperatively.

Preoperative urinalysis can be a useful screen for renal disease. Proteinuria marks intrinsic renal disease or congestive heart failure. Urinary glucose and ketones are suggestive of diabetes and starvation in the ketotic state, respectively. In the absence of recent genitourinary instrumentation, microscopic hematuria suggests calculi, vascular disease, or infection. A few leukocytes may be normal in female patients, but an increased number signifies infection. Epithelial cells are present in poorly collected specimens.

Patients with renal insufficiency or end-stage renal disease often have comorbidities that increase their overall risk in the perioperative period. Hypertension and diabetes correlate with increased risk of coronary artery disease and postoperative MI, impaired wound healing, wound infection, platelet dysfunction, and bleeding. Preoperative history should note the etiology of renal impairment, preoperative weight as a marker of volume status, and timing of last dialysis and the amount of fluid removed routinely. Evaluation should include a cardiac risk assessment. Physical examination should focus on signs of volume overload such as jugular venous distention and pulmonary crackles. In patients with clinically evident renal insufficiency, a full electrolyte panel (calcium, phosphorus, magnesium, sodium, and potassium) should be checked preoperatively, along with blood urea nitrogen and creatinine levels. Progressive renal failure is associated with catabolism and anorexia. Such patients need aggressive nutritional support during the perioperative periods to minimize the risk of infection and poor healing.

Dialysis-dependent patients should have dialysis within 24 hours before surgery, and may benefit from monitoring of intravascular volume status during surgery. Blood samples obtained immediately after dialysis, before equilibration occurs, should only be used in comparison to predialysis values to determine the efficacy of dialysis.<sup>85</sup>

Postoperatively, patients with chronic renal insufficiency or end-stage renal disease will need to have surgical volume losses replaced, but care should be taken to avoid excess. Replacement fluids should not contain potassium, and early dialysis should be employed to address volume overload and electrolyte derangements. Patients with impaired creatinine clearance should have their medications adjusted accordingly. For example, meperidine should be avoided because its metabolites accumulate in renal impairment and can lead to seizures.

The choice of postoperative fluid therapy depends on the patient's comorbidities, the type of surgery, and conditions that affect the patient's fluid balance. There is no evidence that colloid is better than crystalloid in the postoperative period, and it is considerably more expensive.<sup>86</sup> Sepsis and bowel obstruction will require ongoing volume replacement rather than maintenance. Ringer's solution provides six times the intravascular volume as an equivalent amount of hypotonic solution. In patients with normal renal function, clinical signs such as urine output, heart rate, and blood pressure should guide fluid management. Once the stress response subsides, fluid retention subsides and fluid is mobilized from the periphery, and fluid supplementation is unnecessary. This fluid mobilization is evident by decreased peripheral edema and increased urine output. Diuretics given in the period of fluid sequestration may cause intravascular volume depletion and symptomatic hypovolemia.

Postoperative management includes close monitoring of urine output and electrolytes, daily weight, elimination of nephrotoxic medications, and adjustment of all medications that are cleared by the kidney. Hyperkalemia, hyperphosphatemia, and metabolic acidosis may be seen and should


**TABLE 2-5: GUIDELINES FOR PERIOPERATIVE MANAGEMENT OF ANTITHROMBOTIC MEDICATIONS**

	Standard Anticoagulation	Antiplatelet Therapy	Should Warfarin or Antiplatelet Be Stopped Preoperatively?	Is Bridging Anticoagulation Indicated?	When Should Anticoagulant or Antithrombotic Be Restarted Postoperatively?
<b>Low-risk atrial fibrillation</b>	Warfarin goal INR 2.0	None	Yes, 5 days	No	When taking orals
<b>Moderate/High-risk atrial fibrillation</b>	Warfarin goal INR 2.0	None	Yes, 5 days	No	When taking orals
<b>Mechanical mitral valve</b>	Warfarin goal INR 2.5–3.0	None	Yes, 5 days	Yes	Low bleeding risk: 24 hours High bleeding risk: 48–72 hours
<b>Mechanical aortic valve</b>	Warfarin goal INR 2.0	None	Yes, 5 days	Yes	Low bleeding risk: 24 hours High bleeding risk: 48–72 hours
<b>Coronary stent</b>	None	Clopidogrel Aspirin	Yes, 5–10 days	No	Low bleeding risk: 24 hours High bleeding risk: 48–72 hours
<b>Bare metal coronary stent within 6 weeks</b>	None	Aspirin and Clopidogrel	No	No	Low bleeding risk: 24 hours High bleeding risk: 48–72 hours
<b>Drug-eluting stent within 12 months</b>	None	Aspirin and Clopidogrel	No	No	Low bleeding risk: 24 hours High bleeding risk: 48–72 hours
<b>History of VTE</b>	Warfarin goal INR 2.0 for at least 3 months	No	Yes, 5–7 days	Low risk: No Moderate/high risk: yes	

Low risk: VTE >12 months ago; CHADS<sub>2</sub> score 0–2 without prior stroke or TIA

Moderate risk: VTE in last 3–12 months, moderate thrombophilia, recurrent thrombophilia, cancer; CHADS<sub>2</sub> score 3–4

High risk: VTE in last 3 months, prior postoperative VTE, severe thrombophilia; CHADS<sub>2</sub> score 5–6, RHD, or stroke or TIA within 3 months

Data from Douketis, JD, Berger, PB, Dunn, AS, et al. The perioperative management of antithrombotic therapy: American College of Chest Physicians Evidence-Based Clinical Practice Guidelines (8th Edition). *Chest*. 2008;133:299S–339S.

be addressed accordingly. Indications for renal replacement therapy include severe intravascular overload, symptomatic hyperkalemia, metabolic acidosis, and complicated uremia (pericarditis and encephalopathy) (Table 2-5).

Postoperative renal failure increases perioperative mortality. Risk factors for postoperative renal failure include intraoperative hypotension, advanced age, congestive heart failure, aortic cross-clamping, administration of nephrotoxic drugs or radiocontrast, and preoperative elevation in renal insufficiency. Up to 10% of patients may experience acute renal failure after aortic cross-clamping. Postoperative renal failure rates are higher in hypovolemic patients, so preoperative dehydration should be avoided. Contrast nephropathy is a common cause of hospital-acquired renal failure, and manifests as a 25% increase in serum creatinine within 48 hours of contrast administration.

Nephropathy is caused by ischemia and direct toxicity to the renal tubules. Diabetes and chronic renal insufficiency are the greatest risk factors for dye nephropathy. Recent trials<sup>87</sup> have shown that patients receiving contrast have a lower incidence of contrast-induced nephropathy when treated with a sodium bicarbonate infusion. *N*-acetylcysteine given orally on the day prior to contrast exposure also decreases the incidence of radiocontrast nephropathy.<sup>88</sup>

Rising blood urea nitrogen and creatinine and postoperative oliguria (<500 mL/d) herald the onset of postoperative renal failure. Management is determined by the cause of renal insufficiency. Acute renal failure is classified into three categories: prerenal, intrarenal, and postrenal. Prerenal azotemia is common in the postoperative period. It is caused by decreased renal perfusion seen with hypotension and intravascular volume contraction. Intrarenal causes of oliguric renal failure include acute tubular necrosis (from aortic cross-clamping, shock, or renal ischemia), and less commonly, acute interstitial nephritis from nephrotoxic medication. Postrenal causes include obstruction in the collecting system (from bilateral ureteral injury, Foley catheter occlusion, or urethral obstruction). Workup should include urinalysis, serum chemistries, and measurement of the fractional excretion of sodium. Invasive monitoring and cardiac echocardiogram may be employed to evaluate volume status. Ultrasound is indicated if obstruction is suspected.

Initial management of oliguria in adults includes placement of a bladder catheter, and a challenge with isotonic fluids (500 mL of normal saline or Ringer's lactate). If a bladder catheter is already present, it should be checked to ensure that it is draining properly. A urinalysis should be obtained with special attention to specific gravity, casts, and evidence of





TABLE 2-6: OLIGURIA IN THE PERIOPERATIVE PATIENT

	Prerenal	Intrarenal	Postrenal
Causes	Bleeding Hypovolemia Cardiac failure Dehydration	Drugs Contrast medium Sepsis Myoglobinuria	Obstruction
UOsm	>500 mOsm/L	Equal to plasma	Variable
U <sub>Na</sub>	<20 mOsm/L	>50 mOsm/L	>50 mOsm/L
Fe <sub>Na</sub>	<1%	>3%	Indeterminate

Fe<sub>Na</sub>, fractional excretion of sodium; U<sub>Na</sub>, urinary sodium concentration; UOsm, urinary osmolality.

infection. Hematocrit should be evaluated to exclude bleeding and blood pressure measured to rule out hypotension as causes. The fractional excretion of sodium can help determine the etiology of the renal failure (Table 2-6). Serum creatinine is used to follow the course of acute renal failure. Patients who have been adequately resuscitated or who are in CHF require evaluation to rule out cardiogenic shock. Urinary retention can be treated with a Foley catheter, and ureteral obstruction can be addressed with percutaneous nephrostomy.

Intravascular volume depletion adversely affects cardiac output, tissue perfusion, and oxygen delivery. Monitoring includes total body weight, urine output, vital signs, and mental status. However, body weight should not be used alone because total volume overload can be seen in the setting of intravascular volume depletion. Most cases of postoperative renal failure are associated with an episode of hemodynamic instability,<sup>47</sup> and perioperative hemodynamic optimization has been shown to decrease acute kidney injury and mortality.<sup>89</sup> Invasive monitoring to measure cardiac filling pressures may be utilized when clinical assessment is unreliable.

Fluid overload may be seen in patients with renal, hepatic, and cardiac disease, and is associated with increased morbidity.<sup>90</sup> Critically ill patients may develop anasarca. It is difficult to determine volume status by observation alone, and invasive monitoring may be required.

Electrolyte abnormalities are common in the perioperative period. Serum sodium reflects intravascular volume status. Hyponatremia signifies excess free water in the intravascular space, and is caused by excess antidiuretic hormone in the postoperative period. It occurs in the setting of normo-, hypo-, or hypervolemia. It may be avoided by judicious use of isotonic fluids. Conversely, hypernatremia suggests a relative deficit of intravascular free water. Patients who are unable to drink, or those with large insensible losses, are most at risk. Treatment includes free water replacement.

Diuretics, malnutrition, and gastrointestinal losses may cause postoperative hypokalemia. Metabolic alkalosis shifts potassium into the intracellular compartment. Serum potassium levels less than 3 mEq/L warrant ECG monitoring and replacement in patients who are not anuric. Replacement in patients with renal insufficiency may be complex. Hyperkalemia is more commonly seen in renal patients. It may also be seen in myonecrosis, hemolysis,

and acidosis. Cardiac arrhythmias are seen at levels above 6.5 mEq/L and death is associated with levels greater than 8 mEq/L. These patients should have cardiac monitoring until their levels normalize. ECG will show widened QRS interval, peaked T waves, and absent P waves. Hyperkalemia should be treated with sodium bicarbonate to stimulate acidosis, as well as intravenous calcium and insulin with glucose to drive potassium into the intracellular compartment. Cation exchange resins can be administered orally or per rectum to bind ions in the gastrointestinal tract, but care should be taken for the patient who is post-GI surgery or has underlying gastrointestinal problems. Dialysis can be employed if other measures fail.

## GLYCEMIC CONTROL

Hyperglycemia is a risk factor for postoperative infection and perioperative mortality. Intensive insulin therapy (IIT) has been associated with improved outcomes for intensive care unit patients, and after cardiac surgery, in brain injury and after acute MI. However, early enthusiasm for IIT has waned as more recent studies have shown that it is not as beneficial in medical patients as it is in surgical patients, and has been associated with severe hypoglycemia.<sup>91</sup> More recently, a meta-analysis of 29 randomized trials of IIT in adult ICU patients showed no difference in mortality in patients receiving IIT versus conventional insulin therapy with goal blood sugar <200 mg/dL.<sup>92</sup>

Although there does appear to be consensus that controlling glucose is a worthwhile therapeutic goal in surgical patients in particular, appropriate targets for control remain controversial. While hyperglycemia is associated with increased infection and mortality,<sup>93</sup> IIT is associated with hypoglycemia and increased mortality. Results from a recent international, randomized controlled trial in ICU patients demonstrated a 2.6% increase in absolute risk of death in ICU patients with blood glucose target of 81–108 mg/dL versus 180 mg/dL.<sup>94</sup> Others suggest that the variability in glucose level may affect morbidity and mortality more than blood glucose levels alone.<sup>95</sup> More investigation is needed to determine the optimal way to manage blood glucose levels in the postoperative patient.

Our current recommendations for glucose control in non-cardiac surgery patients is to maintain blood glucose less than 180 mg/dL.

## HEMATOLOGICAL EVALUATION

A complete preoperative evaluation should include assessment of hematological disorders, which can increase the risk for postoperative bleeding or thromboembolism. Patients should be asked about a family history of bleeding disorders and personal history of bleeding problems, especially after procedures. Excessive bleeding after dental procedures and menorrhagia in women can alert the physician to undiagnosed hematologic disease. Risk factors for postoperative hemorrhage include known coagulopathy, trauma, hemorrhage, or potential factor deficiency.<sup>96</sup> Factor deficiencies can be seen with a history of liver disease, malabsorption, malnutrition, or chronic antibiotic use. Even high-risk patients have only a 1.7% risk of postoperative hemorrhage and a 0.21% risk of death related to postoperative hemorrhage.<sup>96,97</sup>

Routine tests may include a complete blood count, prothrombin time (PT), activated partial thromboplastin time (PTT), and INR, but are not required in the asymptomatic patient with no associated history. The complete blood count will reveal leukocytosis, anemia, and thrombocytopenia or thrombocytosis. A baseline hematocrit is useful for postoperative management when anemia is suspected. Platelet count also provides a useful baseline, but does not provide information about platelet function. A bleeding time may be required to provide more information in select patients. However, bleeding time results are operator dependent and highly variable, making it a poor screening tool for identifying high-risk patients.<sup>98,99</sup> An abnormal bleeding time is not associated with increased postoperative bleeding,<sup>100</sup> nor has it proven useful in identifying patients taking nonsteroidal anti-inflammatory medication or aspirin.<sup>98</sup> None of the aforementioned tests can be used to diagnose hereditary bleeding disorders. However, an elevated PTT may be seen in factor XI deficiency, and should be obtained in patients at risk for this deficiency. Low-risk patients are very unlikely to have bleeding complications even if the PTT is abnormal,<sup>99</sup> and have an increased risk of false-positives that can lead to unnecessary testing. PTT is not a reliable predictor of postoperative bleeding,<sup>101</sup> and should not be used to screen for bleeding abnormalities in patients without symptoms or risk factors.<sup>102,103</sup>

A platelet count of 20,000 or more is usually adequate for normal clotting. Aspirin causes irreversible impairment of platelet aggregation, and is commonly prescribed in patients at risk of cardiovascular and cerebrovascular disease. The clinical effect of aspirin lasts 10 days, and it is for this reason that patients are asked to stop taking aspirin 1 week before elective surgery. Desmopressin can be used to partially reverse platelet dysfunction caused by aspirin and uremia. Other NSAIDs cause reversible platelet dysfunction and should also be held before surgery. Glycoprotein IIb-IIIa inhibitors prevent platelet-fibrin binding and platelet aggregation, and are

used for 2–4 weeks after coronary angioplasty. Elective surgery should be avoided during these 2–4 weeks, as stopping treatment increases the risk of thrombosis. Patients who do not receive 4 weeks of antiplatelet therapy are at risk of stent thrombosis.<sup>104</sup>

Indications for red blood cell transfusion remain somewhat controversial and are often empirical in practice. Transfusing one unit of red blood cells or whole blood can increase the hematocrit by approximately 3% or hemoglobin by 1 g/dL. Multiple studies have demonstrated that overutilizing transfusion may adversely affect patient outcome and increase risk of infection. ASA guidelines<sup>105</sup> suggest that transfusion should be based on risks of inadequate oxygenation, rather than a threshold hemoglobin level. Generally, transfusion is rarely indicated when the hemoglobin level exceeds 10 g/dL, but is almost always indicated when it is less than 6 g/dL, especially in the setting of acute anemia. Healthy individuals can usually tolerate up to 40% of blood loss without requiring blood cell transfusion, and blood products should not be used solely to expand volume or to improve wound healing. The decision to transfuse red cells or whole blood should be based on the patient's risk of complications associated with impaired oxygen delivery, including hemodynamic indices, history of cardiopulmonary disease, rate of blood loss, and preexisting anemia.

Conditions associated with abnormal platelets and low platelet counts can be treated with platelet transfusions. The usual dose, one unit of platelet concentrate per 10 kg body weight, can be expected to increase the platelet count by approximately 5,000–10,000 in an average adult. In patients without increased risk of bleeding, prophylactic platelet administration is not indicated until counts fall below 20,000. Higher thresholds may be indicated for patients at increased risk of bleeding, known platelet dysfunction, and microvascular bleeding. Desmopressin can augment platelet function in uremia and incite release of Von Willebrand's factor (VWF) from the endothelium, which can improve platelet function. The decision to transfuse platelets should be based on the amount of bleeding expected, the ability to control bleeding, and the presence of platelet dysfunction or destruction.

Transfusion of fresh frozen plasma (FFP) is indicated to reverse warfarin before procedures or in the presence of active bleeding, for inherited or acquired coagulopathy that can be treated with FFP, and for massive transfusion of more than one whole blood volume. Microvascular bleeding can be seen if the PT/PTT is greater than 1.5 times normal, and FFP can be used to reverse bleeding in this setting. Warfarin reversal can be achieved with doses of 5–8 mL/kg, and 30% factor concentration can be achieved with 10–15 mL/kg. FFP should not be used to address volume depletion alone. Cryoprecipitate contains factors VIII, VWF, XIII, fibrinogen, and fibronectin, and can be used preventively in patients with these factor deficiencies and uremia.

Endothelial injury and venous stasis are the greatest risk factors for VTE. The patient with hereditary thrombophilia, or a personal history of VTE, cancer, or recent surgery (within

4 weeks) has an increased risk of VTE.<sup>106</sup> Preventive measures include external pneumatic leg compression, early mobilization after surgery, and anticoagulation. Compression devices are contraindicated in patients with severe peripheral vascular disease, venous stasis, or risk of tissue necrosis. Inferior vena cava (IVC) filters are indicated in patients who cannot take anticoagulation or who have failed anticoagulation therapy. Patients with a history of VTE benefit from IVC filter placement in the short term, but IVC filter placement is accompanied by an increased incidence of deep venous thrombosis over the long term.<sup>107</sup> Systemic anticoagulation is the preferred long-term option. LMWH and UFH are equally effective for prevention of pulmonary embolism in patients with deep venous thrombosis.<sup>107</sup> Recent VTE, atrial fibrillation, and mechanical heart valves are common indications for warfarin treatment.

Clinically, UFH activity is measured by PTT and the therapeutic goal is usually 2.0–2.5 times normal. LMWH is a relatively stronger inhibitor of factor Xa and does not have the same effect on the PTT. The anticoagulant effect of LMWH is measured by factor Xa activity. Protamine can reverse the effects of heparin, but may cause allergic reactions and induce hypercoagulability, and should be used cautiously. FFP will not reverse heparin, and can actually increase heparin activity because it contains antithrombin III. Direct thrombin inhibitors can also prolong the PTT. Direct thrombin inhibitors are not reversible with protamine and may require large amounts of FFP for reversal.

Heparin can be used for the prevention and treatment of VTE. Surgical patients over age 40 or those at increased risk for VTE should receive 5,000 U SC every 8–12 hours, depending on their weight. High-risk patients with a history of VTE, cancer, morbid obesity, or those having orthopedic procedures should either receive SC heparin with a goal of high range of normal or LMWH. In the event of acute VTE intravenous heparin should be started promptly with a therapeutic goal of PTT 1.5–2.0 times normal. Oral anticoagulation should be started within 24 hours and continued for 3–6 months.<sup>106</sup>

Heparin-induced thrombocytopenia (HIT) is a potentially lethal complication of heparin therapy. HIT is caused by an IgG mediated hypersensitivity reaction between the heparin moiety and platelet factor 4 (PF4). Patients with previous heparin exposure, such as orthopedic and cardiac surgical patients, are at greatest risk. The incidence of HIT is 0.5–5.0% in patients receiving UFH. HIT occurs with UFH or low molecular weight heparin; the risk is highest with UFH.

Platelet counts usually drop 40–50% from baseline. Thrombosis can be venous or arterial leading to deep vein thrombosis, extremity ischemia, and mesenteric ischemia of stroke. Digital ischemia and skin necrosis can also be seen. HIT remains a clinical syndrome which can be diagnosed by a decrease in platelet count <405 of baseline in 4–14 days of heparin administration once other causes of thrombocytopenia have been ruled out. The diagnosis can be supported by the ELISA assay for antiplatelet antibodies.

Because HIT can be life-threatening, heparin should be stopped as soon as HIT is suspected, and treatment with an

alternative anticoagulant, such as the thrombin inhibitor bivalirudin, should be started immediately. Platelets should return to baseline after therapy is initiated. If thrombosis is present, patients should be anticoagulated for 6 months with Coumadin. Coumadin should not be started until platelet counts have recovered.

Warfarin inhibits synthesis of vitamin K–dependent clotting factors (II, VII, IX, X, and proteins C and S). Poor diet, prolonged antibiotic use, and fat malabsorption can also cause vitamin K deficiency and cause abnormal coagulation. Liver disease can lead to multiple coagulation abnormalities including factor deficiencies, vitamin K deficiency, fibrinolysis, and elevated levels of fibrin degradation products. All patients with known or suspected liver disease should be tested for coagulopathy. Vitamin K can be administered subcutaneously or intravenously in deficient patients. The initiation of warfarin therapy is associated with a transient thrombotic state because plasma concentrations of protein C fall approximately 24 hours before concentrations of other clotting factors.

Heparin is the drug of choice for VTE during pregnancy because it does not cross the placenta. Adverse effects of heparin therapy may include hemorrhage, thrombocytopenia, and osteoporosis. HIT is an immune disorder seen in patients with prior exposure to heparin, which may cause thrombosis. Treatment includes cessation of heparin and utilization of alternative anticoagulants such as lepirudin, danaparoid, or argatroban. These should be given until platelet counts recover.

For patients on long-term anticoagulation therapy, the INR should be 1.5 or lower before elective surgery. After warfarin is discontinued, it takes about 4 days for an INR in the range of 2.0–3.0 to spontaneously reach 1.5, and about 3 days for the INR to reach 2.0 after it is restarted. If therapy is withheld preoperatively, most patients will have a window of 2–4 days when they are not anticoagulated and at risk for venous thrombosis. This risk is compounded by the increased risk of thromboembolism associated with surgery.<sup>108,109</sup> It has been estimated that surgery increases the risk of VTE by 100-fold in patients with recurrent disease.<sup>110</sup> Without anticoagulation, there is a 50% chance of recurrence within the 3 months after the first episode of venous thrombosis. Warfarin therapy reduces the risk to 10% after 1 month and 5% after 3 months. It is not advisable to interrupt anticoagulation within 1 month after an event of VTE, and if possible, surgery should be deferred until the patient has completed 3 months of therapy.<sup>110</sup> Chronic anticoagulation lowers the risk of thromboembolism in patients with atrial fibrillation and mechanical heart valves by 66% and 75%, respectively.<sup>110</sup>

Patients with prior embolic episodes are at increased risk for recurrence. Six percent of episodes of VTE and 20% of arterial thromboembolism may be fatal,<sup>110</sup> and a significant percentage cause disability. Alternatively, the risk of death after postoperative hemorrhage is less than 1%,<sup>111</sup> so the judicious use of postoperative anticoagulation can be relatively protective. Preoperative heparinization is not required during the second and third months of warfarin treatment for

deep vein thrombosis (DVT) because the risk is sufficiently low. Such patients have increased VTE risk after surgery and should receive postoperative anticoagulation. Patients who are at risk for recurrent DVT, and are within 2 weeks of the first episode, or who cannot tolerate anticoagulation are candidates for an IVC filter.<sup>107</sup>

Elective surgery should be deferred for the first month after arterial embolism because of the high risk of recurrence during this period. If necessary, patients should receive perioperative heparin while oral anticoagulation is held. Patients on long-term anticoagulation to prevent arterial thromboembolism do not need perioperative heparin because the risk of bleeding outweighs the risk of arterial embolism during this period.

Heparin should be titrated to a goal PTT of 1.5–2.0 times normal and given as a continuous intravenous infusion. It should be stopped 6 hours prior to a procedure, and can be restarted 12 hours after surgery if there was no evidence of bleeding at the end of the case. Heparin can be restarted without a bolus at the anticipated maintenance infusion rate.<sup>110,111</sup>

## INFECTIOUS COMPLICATIONS

Infectious complications can be most unwelcome and difficult to control after major abdominal surgery, yet they are surprisingly frequent despite all modern prophylactic measures. Reported surgical wound infection rates in elective operations vary from 2% for inguinal hernia repair<sup>112</sup> to 26% for colectomy,<sup>113</sup> and are even higher for emergency surgery.<sup>114</sup> Surgical site infections (SSIs) increase overall mortality and morbidity, and increase hospital length of stay and overall costs. Therefore prevention and treatment of infectious complications should be included in surgical decision making for all abdominal procedures.

Prevention of SSIs begins with preoperative evaluation and identification of patients at high risk for SSI. Patient factors implicated in risk of SSI include age, diabetes mellitus, smoking, steroid use, malnutrition, obesity, active distant infection, prolonged hospital stay, and nasal colonization with *Staphylococcus aureus*.<sup>115–118</sup>

Standard basic surgical rules should be followed with every patient. These were codified as formal guidelines by the Centers for Disease Control and Prevention (CDC) in 1999<sup>119</sup> and include recommendations for skin preparation with alcohol or iodophor, surgical barriers such as drapes and gowns, careful hand scrubbing, and appropriate selection of prophylactic antibiotics. Preoperative hair removal and antiseptic shower have not been shown to decrease SSI rates, and shaving and clipping of hair can increase SSIs. The CDC recommendations are summarized in Table 2-7. (See Table 2-3 for extended recommendations.)

Antibiotic prophylaxis may be indicated for patients at high risk, or in contaminated surgical procedures, but antibiotics should not be used indiscriminately. Overuse of antibiotics is associated with emergence of multidrug-resistant bacteria and increased rates of hospital-acquired infections. Selection of patients for antimicrobial prophylaxis requires stratification of



**TABLE 2-7: CDC CATEGORY 1 RECOMMENDATIONS FOR REDUCTION OF SURGICAL SITE INFECTIONS**

*These are strongly recommended based on best clinical evidence:*

- Identify and treat distant infections prior to surgery
- Do not remove hair routinely; if hair must be removed, use electric clippers immediately prior to surgery
- Control hyperglycemia in the perioperative period
- Cease tobacco smoking 30 days prior to surgery
- Antiseptic shower the night prior to surgery
- Antiseptic skin preparation
- Surgery team should practice hand scrubs
- Administer appropriate antimicrobial prophylaxis
- Surgical barriers (gown, gloves, hat, mask)
- Do not close contaminated skin incisions

patient risk factors as discussed above and procedure-specific risk factors. The degree of contamination in the surgical site has long been recognized as an independent risk factor for SSI,<sup>120</sup> leading to the wound classification system (Table 2-8) in use since 1983.

Patients undergoing class I (clean) procedures have a very low infection rate and generally do not benefit from prophylactic antibiotics, unless there is some suspicion at the start of the procedure that some contamination may occur, such as unplanned enterotomy in a patient with many previous abdominal procedures. In addition, many surgeons prefer to use antibiotic prophylaxis in class I procedures when a prosthesis is implanted; examples include hernia repair and vascular bypass. In this setting, the risk of SSI is low, but the morbidity and mortality of an infected prosthesis are great, and prophylaxis may decrease the risk. To date, large prospective trials have not shown benefit of antibiotic prophylaxis in preventing prosthetic infections,<sup>121,122</sup> but smaller trials have suggested a decrease in site infection without



**TABLE 2-8: SURGICAL WOUND CLASSIFICATION**

### **Class I. Clean**

Uninfected wounds without contamination

### **Class II. Clean/contaminated**

Uninfected wounds in procedures where the respiratory, gastrointestinal, or genitourinary tracts are entered in a controlled fashion without gross spillage

### **Class III. Contaminated**

An operation with major breaks in sterile technique, gross spillage, or incisions into inflamed but not suppurating infections; fresh accidental wounds

### **Class IV. Dirty/infected**

Wounds with necrotic or devitalized infected tissue



change in implant infection rate.<sup>123,124</sup> Therefore, there is no strict guideline for the use of systemic antibiotics for implant surgery, and the surgeon must tailor the use of antibiotics to the individual patient's risk.

Patients with class II (clean/contaminated) surgical wounds do benefit from systemic antibiotic prophylaxis. The most studied example of this class of wound is elective colon resection. Most current guidelines recommend systemic broad-spectrum antibiotic coverage using a second-generation cephalosporin plus metronidazole if the parenteral route is used, and neomycin plus metronidazole or erythromycin base (both as nonabsorbable antibiotics), if the oral route is used.<sup>125</sup> Published evidence supports administration of antibiotics preoperatively in order to achieve maximum therapeutic levels at the time of incision, and repeat dosing to maintain therapeutic levels during a long procedure. There is no documented study showing benefit to additional doses of antibiotics after the procedure is over and the skin is closed, and prolonged use of prophylactic antibiotics contributes to emergence of resistant bacteria.<sup>126,127</sup>

Patients with class III (contaminated) wounds are a mixed population. Some of these wounds are the result of inadvertent entry into a contaminated field, some result from traumatic injury, and some are planned operations for débridement of infected tissue. In the latter case, antibiotic therapy is indicated for specific therapy rather than prophylaxis. In the case of penetrating traumatic injury to the colon, there is strong evidence to support single-dose antibiotic prophylaxis at the time of laparotomy, similar to elective colon resection.<sup>128,129</sup> Surgical judgment must be individualized in these cases as to whether the risk of skin closure can be justified due to the high rate of wound infection despite antibiotic prophylaxis.

Patients with class IV (dirty) wounds are generally undergoing débridement of already infected and necrotic tissue, and should be receiving antibiotic therapy targeted to the relevant organisms. Skin wound closure is generally not advised in these patients.

The wound classification system does not take into account patient risk factors or site-specific risk factors. Various physiologic scoring systems including the Acute Physiology Score and the Acute Physiology, Age, and Chronic Health Evaluation index have been used to predict perioperative infection risk with some success. In an effort to provide more accurate risk stratification, the CDC's National Nosocomial Infection Surveillance project has developed a risk index that accounts for patient risk factors such as malnutrition and chronic medical conditions, and operative factors including duration and site of procedure.<sup>130</sup> Enlightened risk assessment of perioperative infections should be included in the discussion for informed surgical consent.

## NUTRITIONAL EVALUATION

The importance of proper nutritional assessment and management cannot be overstressed. In surgical patients, malnutrition increases risk for major morbidity,<sup>131,132</sup> including wound

infection, sepsis, pneumonia, delayed wound healing, and anastomotic complications. Careful preoperative clinical assessment can identify those patients at increased nutritional risk. The assessment should include a thorough history and physical examination with attention paid to usual weight, recent weight loss, changes in eating and bowel habits, changes in abdominal girth, loss of muscle bulk, and the presence of diseases that carry a risk of malnutrition such as COPD, diabetes mellitus, inflammatory bowel disease, and psychiatric conditions such as bulimia and anorexia nervosa. The history and physical examination should identify those patients with nutritional risk; that risk can be stratified by calculation of the Nutritional Risk Index (NRI). The NRI is a simple calculation ( $15.19 \times$  serum albumin (g/dL) +  $41.7 \times$  present weight/usual weight), which has been shown in prospective studies to correlate with increased rates of mortality and complications from major abdominal surgery.<sup>133,134</sup> NRI less than 83 indicates a significantly increased rate of mortality and complications, especially wound dehiscence and infection. Severely malnourished patients have been shown to benefit from preoperative nutritional support.<sup>135,136</sup>

Malnutrition can be classified into protein deficiency (kwashiorkor), calorie deficiency (marasmus), or mixed protein calorie deficiency. In order to complete the nutritional assessment and to guide nutritional support, it is useful to classify the patient's specific nutritional state (Table 2-9). Malnutrition states are much more common than is generally acknowledged, with 30–55% of hospital inpatients meeting criteria for one of the diagnoses.<sup>137</sup>

Some interval of deficient nutritional intake is expected after an abdominal operation. In uncomplicated cases, this is usually the result of postoperative adynamic ileus and resolves promptly, in less than 7 days. Traditional surgical management includes provision of dextrose-containing intravenous fluids. The goal of this therapy is not to provide sufficient calories for complete nutritional support, but simply to provide enough carbohydrate to prevent breakdown of lean body mass. Certain organs, including the heart and brain, have an obligate requirement for carbohydrate as a primary energy source, and do not store energy in the form of fat or glycogen. If intake is insufficient to meet this requirement, the body breaks down hepatic glycogen to provide glucose to the circulation, and ultimately the brain and heart. Once hepatic glycogen stores have been depleted (after about 1 day of no intake), lean muscle mass is converted to glucose via gluconeogenesis to produce carbohydrate. Provision of only 100 g of exogenous glucose per day is sufficient to prevent breakdown of lean muscle mass in otherwise healthy subjects.

In already malnourished patients, or in patients who do not return to normal bowel function promptly, nutritional support is indicated. As in the preoperative setting, a thorough evaluation of the patient's nutritional status is necessary, as is the identification of the cause of bowel dysfunction. In the postoperative setting, there are many potential causes of bowel dysfunction (Table 2-10), and nutritional support should be individualized for each patient's needs. Some patients may respond to enteral support and some may require parenteral support. Whenever available, the enteral

**TABLE 2-9: ASSESSMENT OF NUTRITIONAL STATUS**

**Protein Deficiency Criteria**

- Albumin <2.2 g/dL
- Total lymphocyte count 800/mm<sup>3</sup> or less
- Weight maintained
- Peripheral edema
- Inadequate protein intake (<50% of goal for 3 days or <75% for 7 days)
- Four criteria out of these five establish the diagnosis of protein deficiency

**Calorie Deficiency Criteria**

- Weight loss: 5% over 1 month or 7.5% over 3 months or 10% over 6 months
- Underweight: less than 94% ideal body weight (IBW)
- Clinically measurable muscle wasting
- Serum protein maintained
- Inadequate calorie intake (50% for 3 days or <75% for 7 days)
- Three criteria out of these five establish diagnosis of calorie deficiency

**Mixed Protein Calorie Malnutrition Criteria**

	Mild	Moderate	Severe
Weight loss	5–9%	10–15%	10–15% over 6 months
Underweight	94–85%	84–70%	<70% ideal weight
Albumin	2.8–3.4 g/dL	2.1–2.7 g/dL	<2.1 g/dL
Total lymphocytes	1499–1200/mm <sup>3</sup>	1199–800/mm <sup>3</sup>	<800/mm <sup>3</sup>
Transferrin	199–150 mg/dL	149–100 mg/dL	<100 mg/dL
			Muscle wasting Deficient intake (at least 3 days)

route is the preferred route of support, as it has been shown to cause less morbidity and mortality.<sup>138</sup>

Enteral nutritional support is effective in patients that have functional small bowel; examples include esophageal or gastric resection, patients with postoperative delirium or dysphagia, and patients who have gastroparesis. In the short term, if the dysfunction is expected to respond to treatment, nasogastric tubes can be used effectively to deliver full support. Patients that need long-term enteral support are best served with gastrostomy or jejunostomy tubes, which may be placed operatively or percutaneously. With good preoperative nutritional assessment and sound surgical judgment, these patients' needs for long-term postoperative support can often be anticipated, and long-term feeding access can be included in the operative plan. Enteral support may not be suitable for some patients; examples include early postoperative bowel obstruction,

fistula, or intestinal insufficiency (short-gut syndrome). In such patients, parenteral support is indicated, and should be initiated without delay, and futile attempts to use the enteral route should be avoided.

To establish the diagnoses of mild or moderate protein calorie malnutrition, two of the five criteria shown must be met; to establish the diagnosis of severe protein calorie malnutrition, three of the seven criteria must be met.

Irrespective of the route of support, every patient on nutritional support should have his or her nutritional needs assessed and provided. The assessment begins with the calorie requirement. There are several formulas and nomograms that estimate basal energy expenditure, taking into account height, weight, age, gender, stress factors, and activity factors.<sup>139</sup> All of these methods are estimations, and may underfeed or overfeed certain subgroups, especially the obese. The method in most common clinical use bases basal energy expenditure on adjusted body weight (ABW). Using this method, ABW is defined as the patient's ideal body weight (IBW) plus the difference between actual body weight (BW) and the IBW divided by two:

$$ABW = IBW + 0.5(BW - IBW)$$

The baseline caloric requirement for weight maintenance based on ABW is 25 kcal/kg/d. This target may be adjusted upward in patients with extreme metabolic demands, as is the case in burns or head injury.<sup>126</sup> Furthermore, the ABW can be used to establish the protein requirement. In unstressed normal subjects, the minimum daily protein requirement is 0.8 g protein/kg/d. In postoperative patients with healing wounds, this target is adjusted to 1.0–1.5 g/kg/d, and in severely ill patients to 2.0 g/kg/d. The highest requirements are seen in severe burn and bone marrow transplant patients.

Essential nutritional components must be provided, again irrespective of the route of support. These include water- and lipid-soluble vitamins, trace elements such as zinc and selenium, essential fatty acids such as linoleic and linolenic acids, and the eight essential amino acids. These trace elements are provided in abundance in all enteral feeds, and are part of the standard additives in parenteral formula.

Once nutritional support has been initiated, the patient's response to support must be followed closely, especially in parenteral support and in patients with preexisting metabolic conditions such as diabetes. Blood glucose should be

**TABLE 2-10: POSTOPERATIVE CAUSES OF DEFICIENT NUTRITIONAL INTAKE**

- Ileus
- Bowel obstruction
- Colitis (ischemic, infectious)
- Fistula
- Dysphagia
- Gastric dysmotility
- Intestinal insufficiency (short-gut syndrome)

monitored regularly during the first few days of support. Recent evidence has linked hyperglycemia in the postoperative setting, especially in critically ill patients, with increased risk of death and infection.<sup>140,141</sup> In addition, electrolyte abnormalities (especially those of potassium, magnesium, and phosphate) are often seen in the early period of nutritional support, and should be corrected.

It is also important to follow the markers of nutrition repletion to ensure that the calories and protein provided (based on the initial estimate) are sufficient, and the patient is not mobilizing lean body mass due to inadequate support. Serum markers such as prealbumin, retinol binding protein, and transferrin can be useful in this regard. They are serum proteins with short (2–7 days) turnover times that reflect the body's ability to synthesize new protein.<sup>139</sup> Unfortunately, the serum concentrations of these proteins are also affected by acute disease states and renal and hepatic failure, and can be difficult to interpret in postoperative patients. Nitrogen balance can also be used to monitor nutritional support and reflects the ability to synthesize new protein. Nitrogen balance is calculated by subtracting nitrogen excretion from nitrogen intake. Nitrogen intake is calculated from the protein intake, where each gram of protein divided by 6.25 is equal to the number of grams of nitrogen. Nitrogen excretion has two components: urinary urea nitrogen (UUN) and insensible loss. UUN can be measured in a 24-hour urine collection; insensible loss is generally accepted to be 4 g/d, unless there is another source of loss, such as abdominal drainage of proteinaceous ascites, enterocutaneous fistula, or nephrotic syndrome. Thus, in most cases, nitrogen balance can be simplified to:

$$\text{Nitrogen balance} = \text{protein intake}/6.25 - 24 \text{ hour UUN} \\ - 4\text{g (insensible loss)}$$

A patient that takes in more nitrogen than he or she excretes in the urine and feces is in positive nitrogen balance and is synthesizing new protein. On the other hand, a patient that is excreting more nitrogen than he or she is receiving in nutritional support is in negative nitrogen balance, and is therefore losing lean body mass, becoming more malnourished. These patients should be reevaluated for nutritional needs and for sources of nutritional depletion, such as uncontrolled diabetes mellitus, sepsis, and organ failure.

By itself, uncontrolled diabetes mellitus can be viewed as a perioperative nutritional complication, as it results in nutritional depletion, interferes with delivery of parenteral and enteral nutrition, and is associated with increased infectious morbidity.<sup>140,141</sup>

## REFERENCES

1. Bauer M, Böhler H, Aichele G, et al. Measuring patient satisfaction with anaesthesia: perioperative questionnaire versus standardised face-to-face interview. *Acta Anaesthesiol Scand.* 2001;45:65–72.
2. Ballantyne JC, Carr DB, Chalmers TC, et al. Postoperative patient-controlled analgesia: meta-analyses of initial randomized control trials. *J Clin Anesth.* 1993;5:182–193.
3. Nitschke LF, Schlösser CT, Berg RL, et al. Does patient-controlled analgesia achieve better control of pain and fewer adverse effects than intramuscular analgesia? A prospective randomized trial. *Arch Surg.* 1996;131:417–423.
4. Kenady DE, Wilson JF, Schwartz RW, et al. A randomized comparison of patient-controlled versus standard analgesic requirements in patients undergoing cholecystectomy. *Surg Gynecol Obstet.* 1992;174:216–220.
5. de Leon-Casasola OA, Karabella D, Lema MJ. Bowel function recovery after radical hysterectomies: thoracic epidural bupivacaine-morphine versus intravenous patient-controlled analgesia with morphine: a pilot study. *J Clin Anesth.* 1996;8:87–92.
6. Block BM, Liu SS, Rowlingson AJ, et al. Efficacy of postoperative epidural analgesia: a meta-analysis. *JAMA.* 2003;290:2455–2463.
7. Wang LP, Hauerberg J, Schmidt JF. Incidence of spinal epidural abscess after epidural analgesia: a national 1-year survey. *Anesthesiology.* 1999;91:1928–1936.
8. Boylan, JF, Katz J, Kavanagh BP, et al. Epidural bupivacaine-morphine analgesia versus patient-controlled analgesia following abdominal aortic surgery: analgesic, respiratory, and myocardial effects. *Anesthesiology.* 1998;89:585–593.
9. Bois S, Couture P, Boudreault D, et al. Epidural analgesia and intravenous patient-controlled analgesia result in similar rates of postoperative myocardial ischemia after aortic surgery. *Anesth Analg.* 1997;85:1233–1239.
10. Wu CL, Naqibuddin M, Fleisher LA. Measurement of patient satisfaction as an outcome of regional anesthesia and analgesia: a systematic review. *Reg Anesth Pain Med.* 2001;26:196–208.
11. Werawatganon T, Charuluxanun S. Patient controlled intravenous opioid analgesia versus continuous epidural analgesia for pain after intra-abdominal surgery. *Cochrane Database Syst Rev.* 2005;(1):CD004088.
12. Hendolin H, Lahtinen J, Lansimies E, et al. The effect of thoracic epidural analgesia on respiratory function after cholecystectomy. *Acta Anaesthesiol Scand.* 1987;31:645–651.
13. Cuschieri RJ, Morran CG, Howie JC, McArdle CS. Postoperative pain and pulmonary complications: comparison of three analgesic regimens. *Br J Surg.* 1985;72:495–498.
14. Scheinin B, Asantila R, Orko R. The effect of bupivacaine and morphine on pain and bowel function after colonic surgery. *Acta Anaesthesiol Scand.* 1987;31:161–164.
15. Bredtmann RD, Herden HN, Teichmann W, et al. Epidural analgesia in colonic surgery: results of a randomized prospective study. *Br J Surg.* 1990;77:638–642.
16. Horattas MC, Evans S, Sloan-Stakleff KD, et al. Does pre-operative rofecoxib (Vioxx) decrease postoperative pain with laparoscopic cholecystectomy? *Am J Surg.* 2004;188:271–276.
17. Bikhazi GB, Snabes MC, Bajwa ZH, et al. A clinical trial demonstrates the analgesic activity of intravenous parecoxib sodium compared with ketorolac or morphine after gynecologic surgery with laparotomy. *Am J Obstet Gynecol.* 2004;191:1183–1191.
18. Lau H, Wong C, Goh LC, et al. Prospective randomized trial of preemptive analgesics following ambulatory inguinal hernia repair: intravenous ketorolac versus diclofenac suppository. *ANZ J Surg.* 2002;72:704–707.
19. Mixer CG 3rd, Meeker LD, Gavin TJ. Preemptive pain control in patients having laparoscopic hernia repair: a comparison of ketorolac and ibuprofen. *Arch Surg.* 1998;133:432–437.
20. Morton NS, O'Brien K. Analgesic efficacy of paracetamol and diclofenac in children receiving PCA morphine. *Br J Anaesth.* 1999;82:715–717.
21. Litaker D, Locala J, Franco K, et al. Preoperative risk factors for postoperative delirium. *Gen Hosp Psychiatry.* 2001;23:84–89.
22. Moller JT, Cluitmans P, Rasmussen LS, et al. Long-term postoperative cognitive dysfunction in the elderly ISPOCD1 study. ISPOCD investigators. International Study of Post-Operative Cognitive Dysfunction. *Lancet.* 1998;351:857–861.
23. Inouye SK, Charpentier PA. Precipitating factors for delirium in hospitalized elderly persons. Predictive model and interrelationship with baseline vulnerability. *JAMA.* 1996;275:852–857.
24. Mann C, Pouzeratte Y, Boccarda G, et al. Comparison of intravenous or epidural patient-controlled analgesia in the elderly after major abdominal surgery. *Anesthesiology.* 2000;92:433–441.
25. Skrobik YK, Bergeron N, Dumont M, Gottfried SB. Olanzapine vs haloperidol: treating delirium in a critical care setting. *Intensive Care Med.* 2004;30:444–449.



26. Mangano DT, Goldman L. Preoperative assessment of patients with known or suspected coronary disease. *N Engl J Med.* 1995;333:1750–1756.
27. Eagle KA, Brundage BH, Chaitman BR, et al. Guidelines for perioperative cardiovascular evaluation for noncardiac surgery: Report of the ACC/AHA Task Force on Practice Guidelines. *J Am Coll Cardiol.* 1996;27:910–948.
28. Park KW. Preoperative cardiology consultation. *Anesthesiology.* 2003; 98:754–762.
29. Liu LI, Wiener-Kronish JP. Preoperative cardiac evaluation of women for noncardiac surgery. *Cardiol Clin.* 1998;16:59–66.
30. Shackelford DP, Hoffman MK, Kramer PR Jr, et al. Evaluation of preoperative cardiac risk index values in patients undergoing vaginal surgery. *Am J Obstet Gynecol.* 1995;173:80–84.
31. Mangano DT, Hollenberg M, Fegert G, et al. Perioperative myocardial ischemia in patients undergoing non-cardiac surgery—I: Incidence and severity during the 4 day perioperative period. The study of perioperative ischemia (SPI) research group. *J Am Coll Cardiol.* 1991;4:843–850.
32. ACC/AHA task force report: Special report: guidelines for perioperative cardiovascular evaluation for non-cardiac surgery. *Circulation.* 1996;93:1278–1317.
33. Mukherjee D, Eagle KA. Perioperative cardiac assessment for noncardiac surgery, eight steps to the best possible outcome. *Circulation.* 2003;107:2771–2774.
34. Chui PT, Gin T, Oh TE. Anaesthesia for laparoscopic surgery. *Anaesth Intensive Care.* 1993;21:163–171.
35. Madu EC. Transesophageal dobutamine stress echocardiography in the evaluation of myocardial ischemia in morbidly obese subjects. *Chest.* 2000;117:657–661.
36. Dawood MM, Gupta DK, Southern J, et al. Pathology of fatal perioperative myocardial infarction: implications regarding pathophysiology and prevention. *Int J Cardiol.* 1996;57:37–44.
37. Boersma E, Poldermans D, Bax JJ, et al. Predictors of cardiac events after major vascular surgery: role of clinical characteristics, dobutamine echocardiography, and beta-blocker therapy. *JAMA.* 2001;285:1865–1873.
38. Gersh BJ, Braunwald E, Bonow RO. Chronic coronary artery disease. In: Braunwald E, Zipes DP, Libby P, eds. *Heart Disease.* Philadelphia, PA: WB Saunders; 2001:1272–1363.
39. McFalls EO, Ward HB, Moritz TE, et al. Coronary artery revascularization before elective major vascular surgery. *N Engl J Med.* 2004;352:2795–2804.
40. Posner KL, Van Norman GA, Chan V. Adverse cardiac outcomes after noncardiac surgery in patients with prior percutaneous transluminal coronary angioplasty. *Anesth Analg.* 1999;89:553–560.
41. Kaluza GL, Joseph J, Lee JR, et al. Catastrophic outcomes of noncardiac surgery soon after coronary stenting. *J Am Coll Cardiol.* 2000;35: 1288–1294.
42. Foster ED, Davis KB, Carpenter JA, et al. Risk of noncardiac operation in patients with defined coronary disease: the Coronary Artery Surgery Study (CASS) registry experience. *Ann Thorac Surg.* 1986;14:42–50.
43. Yusuf S, Zucker D, Peduzzi P, et al. Effect of coronary artery bypass graft surgery on survival: overview of 10-year results from randomised trials by the Coronary Artery Bypass Graft Surgery Trialists Collaboration. *Lancet.* 1994;344:563–570.
44. Selzman CH, Miller SA, Zimmerman MA, Harkin AH. The case for beta-adrenergic blockade as prophylaxis against perioperative cardiovascular morbidity and mortality. *Arch Surg.* 2001;136:286–290.
45. Lee RT, Grodinsky AJ, Frank EH, et al. Structure dependent dynamic mechanical behavior of fibrous caps from human atherosclerotic plaques. *Circulation.* 1991;83:1764–1770.
46. Rabbani R, Topol EJ. Strategies to achieve coronary arterial plaque stabilization. *Cardiovasc Res.* 1999;4:402–417.
47. Mangano DT, Layug EL, Wallace A, et al; Multicenter Study of Perioperative Ischemia Research Group. Effect of atenolol on mortality and cardiovascular morbidity after noncardiac surgery. *N Engl J Med.* 1996;335:1713–1720.
48. Poldermans D, Boersma E, Bax JJ, et al; Dutch Echocardiographic Cardiac Risk Evaluation Applying Stress Echocardiography Study Group. The effect of bisoprolol on perioperative mortality and myocardial infarction in high-risk patients undergoing vascular surgery. *N Engl J Med.* 1999;341:1789–1794.
49. Lindenauer PK, Pekow P, Wang K, et al. Perioperative beta-blocker therapy and mortality after major noncardiac surgery. *N Engl J Med.* 2005;353:349–361.
50. Brady AR, Gibbs JS, Greenhalgh RM, et al. Perioperative beta-blockade (POBBLE) for patients undergoing infrarenal vascular surgery: results of a randomized double-blind controlled trial. *J Vasc Surg.* 2005;41:602–609.
51. Yang H, Raymer K, Butler R, et al. The effects of perioperative beta-blockade: results of the Metoprolol after Vascular Surgery (MaVS) study, a randomized controlled trial. *Am Heart J.* 2006;152:983–990.
52. Juul AB, Wetterslev J, Gluud C, et al. Effect of perioperative beta blockade in patients with diabetes undergoing major non-cardiac surgery: randomised placebo controlled, blinded multicentre trial. *BMJ.* 2006;332:1482.
53. Devereaux PJ, Yang H, Yusuf S, et al. Effects of extended-release metoprolol succinate in patients undergoing non-cardiac surgery (POISE trial): a randomised controlled trial. *Lancet.* 2008;371:1839–1847.
54. Devereaux PJ, Beattie WS, Choi PT, et al. How strong is the evidence for the use of perioperative beta blockers in non-cardiac surgery? Systematic review and meta-analysis of randomised controlled trials. *BMJ.* 2005;331:313–321.
55. Detsky AS, Abrams HB, McLaughlin JR, et al. Predicting cardiac complications in patients undergoing non-cardiac surgery. *J Gen Intern Med.* 1986;1:211–219.
56. O’Kelly B, Browner WS, Massie B, et al. Ventricular arrhythmias in patients undergoing noncardiac surgery: The Study of Perioperative Ischemia Research group. *JAMA.* 1992;268:217–221.
57. Mahla E, Rotman B, Rehak P, et al. Perioperative ventricular dysrhythmias in patients with structural heart disease undergoing noncardiac surgery. *Anesth Analg.* 1998;86:16–21.
58. Eagle KA, Berger PB, Calkins H, et al. ACC/AHA guideline update for perioperative cardiac evaluation for noncardiac surgery—executive summary: a report of the American College of Cardiology/American Heart Association Task Force on Practice Guidelines (Committee to Update the 1996 Guidelines on Perioperative Cardiac Evaluation for Noncardiac Surgery). *J Am Coll Cardiol.* 2002;39:542–553.
59. Dajani AS, Taubert KA, Wilson W, et al. Prevention of bacterial endocarditis: recommendations by the American Heart Association. *JAMA.* 1997;277:1794–1801.
60. Steckelberg JM, Wilson WR. Risk factors for infective endocarditis. *Infect Dis Clin North Am.* 1993;7:9–19.
61. Boudoulais H, Wooley CF. Mitral valve prolapse. In: Emmanouilides GC, Riemenschneider TA, Allen HD, Gutgesell HP, eds. *Moss and Adams Heart Disease in Infants, Children and Adolescents including the Fetus and Young Adult.* 5th ed. Baltimore, MD: Williams & Wilkins; 1995:1063–1086.
62. Carabello BA. Mitral valve disease. *Curr Probl Cardiol.* 1993;7:423–478.
63. Devereux RB, Hawkins I, Kramer-Fox R, et al. Complications of mitral valve prolapse. Disproportionate occurrence in men and older patients. *Am J Med.* 1986;81:751–758.
64. MacMahon SW, Roberts JK, Kramer-Fox R, et al. Mitral valve prolapse and infective endocarditis. *Am Heart J.* 1987;113:1291–1298.
65. Devereux RB, Kramer-Fox R, Kligfield P. Mitral valve prolapse: causes, manifestations, and management. *Ann Intern Med.* 1989;111:305–317.
66. Marks AR, Choong CY, Sanfillipo AJ, et al. Identification of high-risk and low-risk subgroups of patients with mitral-valve prolapse. *N Engl J Med.* 1989;320:1031–1036.
67. Nishimura RA, McGoon MD, Shub C, et al. Echocardiographically documented mitral-valve prolapse. Long-term follow up of 237 patients. *N Engl J Med.* 1985;313:1305–1309.
68. Cheitlin MD, Alpert JS, Armstrong WF, et al. ACC/AHA guidelines for the clinical application of echocardiography: a report of the American College of Cardiology/ American Heart Association Task Force Guidelines (Committee on Clinical Application of Echocardiography). *Circulation.* 1997;95:1686–1744.
69. Durak DT. Prevention of infective endocarditis. *N Engl J Med.* 1995; 332:38–44.
70. Douketis JD, Berger PB, Dunn AS, et al. The perioperative management of antithrombotic therapy: American College of Chest Physicians Evidence-based Clinical Practice Guidelines (8th Edition). *Chest.* 2008;133:299S–339S.
71. Lawrence VA, Dhanda R, Hilsenbeck SG, Page CP. Risk of pulmonary complications after elective abdominal surgery. *Chest.* 1996;110: 744–750.
72. Becquemin JP, Piquet J, Becquemin MH, et al. Pulmonary function after transverse or midline incision in patients with obstructive pulmonary disease. *Intensive Care Med.* 1985;11:247–251.

73. Celli BR, Rodriguez KS, Snider GL. A controlled trial of intermittent positive pressure breathing, incentive spirometry, and deep breathing exercises in preventing pulmonary complications after abdominal surgery. *Am Rev Respir Dis*. 1984;130:12–15.
74. Tarhan S, Moffitt EA, Sessler AD, et al. Risk of anesthesia and surgery in patients with chronic bronchitis and chronic obstructive pulmonary disease. *Surgery*. 1973;74:720–726.
75. Gerson MC, Hurst JM, Hertzberg VS, et al. Prediction of cardiac and pulmonary complications related to elective abdominal and noncardiac thoracic surgery in geriatric patients. *Am J Med*. 1990;88:101–107.
76. Williams-Russo P, Charlson ME, Mackenzie CR, et al. Predicting postoperative pulmonary complications. Is it a real problem? *Arch Intern Med*. 1992;152:1209–1213.
77. Warner MA, Offord KP, Warner MA, et al. Role of pre-operative cessation of smoking and other factors in postoperative pulmonary complications: a blinded prospective study of coronary artery bypass patients. *Mayo Clin Proc*. 1989;64:609–616.
78. Pien LC, Grammer LC, Patterson R. Minimal complications in a surgical population with severe asthma receiving prophylactic corticosteroids. *J Allergy Clin Immunol*. 1988;82:696–700.
79. Kabalin CS, Yarnld PR, Grammer LC. Low complication rate of corticosteroid-treated asthmatics undergoing surgical procedures. *Arch Intern Med*. 1995;155:1379–1384.
80. Flancbaum L, Choban PS. Surgical implications of obesity. *Annu Rev Med*. 1998;49:215–234.
81. Shepherd JW. Hypertension, cardiac arrhythmias, myocardial infarction and stroke in relation to obstructive sleep apnea. *Clin Chest Med*. 1992;13:459–479.
82. Brooks-Brunn JA. Postoperative atelectasis and pneumonia. *Heart Lung*. 1995;24:94–115.
83. Zinner MJ, Zuidema GD, Smith PA, et al. The prevention of upper gastrointestinal tract bleeding in patients in an intensive care unit. *Surg Gynecol Obstet*. 1981;153:215–220.
84. Kaplan EB, Sheiner LB, Boeckmann AJ, et al. The usefulness of preoperative laboratory screening. *JAMA*. 1985;253:3576–3581.
85. Ifudu O. Care of patients undergoing hemodialysis. *N Engl J Med*. 1998;339:1054–1062.
86. Cochrane Injuries Group Albumin Reviewers. Human albumin administration in critically ill patients: systematic review of randomized controlled trials. *BMJ*. 1998;317:235.
87. Merten GJ, Burgess WP, Gray LV, et al. Prevention of contrast-induced nephropathy with sodium bicarbonate. A randomized controlled trial. *JAMA*. 2004;291:2328–2334.
88. Tepel M, van der Giet M, Schwarzfeld C, et al. Prevention of radiographic-contrast-agent-induced reductions in renal function by acetylcysteine. *N Engl J Med*. 2000;343:180–184.
89. Brienza N, Giglio MT, Marucci M, et al. Does perioperative hemodynamic optimization protect renal function in surgical patients? A meta-analytic study. *Crit Care Med*. 2009;37:2079–2090.
90. Lobo DN, Bostock KA, Neal KR, et al. Effect of salt and water balance on recovery of gastrointestinal function after elective colonic resection: a randomised controlled trial. *Lancet*. 2002;359:1812–1818.
91. van den Berghe G, Wouters P, Weekers F, et al. Intensive insulin therapy in the critically ill patients. *N Engl J Med*. 2001;345:1359–1367.
92. Marik PE, Preiser J. Toward understanding tight glycemic control in the ICU: a systematic review and metaanalysis. *Chest*. 2010;137:544–551.
93. Krinsley JS. Association between hyperglycemia and increased hospital mortality in a heterogeneous population of critically ill patients. *Mayo Clin Proc*. 2003;78:1471–1478.
94. NICE-SUGAR Study Investigators. Intensive versus conventional glucose control in critically ill patients. *N Engl J Med*. 2009;360:1283–1297.
95. Egi M, Bellomo R, Stachowski E, et al. Variability of blood glucose concentration and short-term mortality in critically ill patients. *Anesthesiol*. 2006;105:244–252.
96. Suchman AL, Mushlin AI. How well does the activated partial thromboplastin time predict postoperative hemorrhage? *JAMA*. 1986;256:750–753.
97. Houry S, Georgeac C, Hay JM, et al; The French Associations for Surgical Research. A prospective multi-center evaluation of preoperative hemostatic screening tests. *Am J Surg*. 1995;170:19–23.
98. Burns ER, Lawrence C. Bleeding time. A guide to its diagnostic and clinical utility. *Arch Pathol Lab Med*. 1989;113:1219–1224.
99. Peterson P, Hayes TE, Arkin CF, et al. The preoperative bleeding time lacks clinical benefit: College of American Pathologists and American Society of Clinical Pathologists' position article. *Arch Surg*. 1998;133:134–139.
100. Gewirtz AS, Miller ML, Keys TF. The clinical usefulness of the preoperative bleeding time. *Arch Pathol Lab Med*. 1996;120:353–356.
101. Robbins JA, Rose SD. Partial thromboplastin time as screening test. *Ann Intern Med*. 1979;90:796–797.
102. Eisenberg JM, Goldfarb S. Clinical usefulness of measuring prothrombin time as a routine admission test. *Clin Chem*. 1976;22:1644–1647.
103. Robbins JA, Mushlin AI. Preoperative evaluation of the healthy patient. *Med Clin North Am*. 1979;63:1145–1156.
104. Kaluza GL, Joseph J, Lee JR, et al. Catastrophic outcomes of noncardiac surgery soon after coronary stenting. *J Am Coll Cardiol*. 2000;35:1288–1294.
105. American Society of Anesthesiologists Task Force on Blood Component Therapy. Practice guidelines for blood component therapy: a report by the American Society of Anesthesiologists Task Force on Blood Component Therapy. *Anesthesiology*. 1996;84:732–747.
106. Ginsburg SJ. Management of venous thromboembolism. *N Engl J Med*. 1996;335:1816–1828.
107. Decousus H, Leizorovicz A, Parent F, et al. Prevention du Risque d'Embolie Pulmonaire par Interruption Cave Study Group. A clinical trial of vena caval filters in the prevention of pulmonary embolism in patients with proximal deep-vein thrombosis. *N Engl J Med*. 1998;338:409–415.
108. Flanc C, Kakkar VV, Clarke MB. The detection of venous thrombosis of the legs using 125 I-labelled fibrinogen. *Br J Surg*. 1968;55:742–747.
109. Carter CJ. The pathophysiology of venous thrombosis. *Prog Cardiovasc Dis*. 1994;36:439–446.
110. Kearon C, Hirsch J. Management of anticoagulation before and after elective surgery. *N Engl J Med*. 1997;336:1506–1512.
111. Hirsch J, Rasche R, Warkentin TE, et al. Heparin: mechanism of action, pharmacokinetics, dosing considerations, monitoring, efficacy, and safety. *Chest*. 1995;108(Suppl):258S–275S.
112. Sanchez-Manuel FJ, Seco-Gil JL. Antibiotic prophylaxis for hernia repair. *Cochrane Database Syst Rev*. 2004;(4):CD003769.
113. Smith RL, Bohl JK, McElearney ST, et al. Wound infection after elective colorectal resection. *Ann Surg*. 2004;239:599–605.
114. O'Neill PA, Kirton OC, Dresner LS, et al. Analysis of 162 colon injuries in patients with penetrating abdominal trauma: concomitant stomach injury results in a higher rate of infection. *J Trauma*. 2004;56:304–312.
115. Christou NV, Nohr CW, Meakins JL. Assessing operative site infection in surgical patients. *Arch Surg*. 1987;122:165–169.
116. Perl TM, Cullen JJ, Wenzel RP, et al. Mupirocin and the Risk of *Staphylococcus aureus* Study Team. Intranasal mupirocin to prevent postoperative *Staphylococcus aureus* infections. *N Engl J Med*. 2002;346:1871–1877.
117. Gil-Egea MJ, Pi-Sunyer MT, Verdaguer A, et al. Surgical wound infections: a prospective study of 4,486 clean wounds. *Infect Control*. 1987;8:277–280.
118. Forse RA, Karam B, MacLean LD, Christou NV. Antibiotic prophylaxis for surgery in morbidly obese patients. *Surgery*. 1989;106:750–756.
119. Mangram AJ, Horan TC, Pearson ML, Silver LC, Jarvis WR. Guidelines for prevention of surgical site infection. *Infect Control Hosp Epidemiol*. 1999;20:247–278.
120. Polk HC Jr, Simpson CJ, Simmons BP, Alexander JW. Guidelines for prevention of surgical wound infection. *Arch Surg*. 1983;118:1213–1217.
121. Perez AR, Roxas MF, Hilvano SS. A randomized, double-blind, placebo-controlled trial to determine effectiveness of antibiotic prophylaxis for tension-free mesh herniorrhaphy. *J Am Coll Surg*. 2005;200:393–397.
122. Darouiche RO. Antimicrobial approaches for preventing infections associated with surgical implants. *Clin Infect Dis*. 2003;36:1284–1289.
123. Yerdel MA, Akin EB, Dolalan S, et al. Effect of single-dose prophylactic ampicillin and sulbactam on wound infection after tension-free inguinal hernia repair with polypropylene mesh: the randomized, double-blind, prospective trial. *Ann Surg*. 2001;233:26–33.
124. Bratzler DW, Houck PM. Antimicrobial prophylaxis for surgery: an advisory statement from the National Surgical Infection Prevention Project. *Clin Infect Dis*. 2004;38:1706–1715.
125. Hecker MT, Aron DC, Patel NP, et al. Unnecessary use of antimicrobials in hospitalized patients: current patterns of misuse with an

- emphasis on antianaerobic spectrum of activity. *Arch Intern Med.* 2003;163:972–978.
126. Eggiman P, Pittet D. Infection control in the ICU. *Chest.* 2001;120:2059–2093.
127. Fullen WD, Hunt J, Altemeier WA. Prophylactic antibiotics in penetrating wounds of the abdomen. *J Trauma.* 1972;12:282–289.
128. Thadepelli H, Gorbach SL, Broido PW, et al. Abdominal trauma, anaerobes, and antibiotics. *Surg Gynecol Obstet.* 1973;137:270–276.
129. Dellinger EP. Antibiotic prophylaxis in trauma: penetrating abdominal injuries and open fractures. *Rev Infect Dis.* 1991;13:S847–S857.
130. Gaynes RP, Culver DH, Horan TC, et al. Surgical site infection (SSI) rates in the United States, 1992–1998: the National Nosocomial Infections Surveillance System basic SSI risk index. *Clin Infect Dis.* 2001;33(Suppl 2):S69–S77.
131. Sungurtekin H, Sungurtekin U, Balci C, et al. The influence of nutritional status on complications after major intraabdominal surgery. *J Am Coll Nutr.* 2004;23:227–232.
132. Rey-Ferro M, Castano R, Orozco O, et al. Nutritional and immunologic evaluation of patients with gastric cancer before and after surgery. *Nutrition.* 1997;13:878–881.
133. Bozzetti F, Gavazzi C, Miceli R, et al. Perioperative total parenteral nutrition in malnourished, gastrointestinal cancer patients: a randomized, clinical trial. *JPEN J Parenter Enteral Nutr.* 2000;24:7–14.
134. The Veterans Affairs Total Parenteral Nutrition Cooperative Study Group. Perioperative total parenteral nutrition in surgical patients. *N Engl J Med.* 1991;325:525–532.
135. Reilly JJ Jr, Hull SF, Albert N, et al. Economic impact of malnutrition: a model system for hospitalized patients. *JPEN J Parenter Enteral Nutr.* 1988;12:371–376.
136. Moore FA, Moore EE, Jones TN, et al. TEN versus TPN following major abdominal trauma—reduced septic morbidity. *J Trauma.* 1989;29:916–922.
137. Kudsk KA, Croce MA, Fabian TC, et al. Enteral versus parenteral feeding. Effects on septic morbidity after blunt and penetrating abdominal trauma. *Ann Surg.* 1992;215:503–511.
138. Demling RH, Seigne P. Metabolic management of patients with severe burns. *World J Surg.* 2000;24:673–680.
139. Haider M, Haider SQ. Assessment of protein-calorie malnutrition. *Clin Chem.* 1984;30:1286–1299.
140. Pomposelli JJ, Baxter JK 3rd, Babineau TJ, et al. Early postoperative glucose control predicts nosocomial infection rate in diabetic patients. *JPEN J Parenter Enteral Nutr.* 1998;22:77–81.
141. Furnary AP, Zerr KJ, Grunkemeier GL, Starr A. Continuous intravenous insulin infusion reduces the incidence of deep sternal wound infection in diabetic patients after cardiac surgical procedures. *Ann Thorac Surg.* 1999;67:352–360.

*This page intentionally left blank*

# ENDOSCOPY AND ENDOSCOPIC INTERVENTION

Jeffrey M. Marks • Jeffrey L. Ponsky

Over the past several decades, flexible endoscopy has shifted the management of numerous gastrointestinal diseases from the surgeon to the endoscopist. What had started as a diagnostic discipline has now become one of advanced therapeutic potential. The concept of performing endoscopic surgery has become a reality with the advancement of endoluminal therapies for neoplasia, gastroesophageal reflux, and obesity. In addition, with the significant investigation into natural orifice transluminal endoscopic surgery (NOTES) and the development of advanced endoscopic tools, the ability to perform intraperitoneal therapies without abdominal scars continues to become more possible. This chapter will address the indications and techniques for upper and lower flexible endoscopy as well as the recent advances in imaging and interventional endoscopy.

## THE FLEXIBLE ENDOSCOPE

### Imaging

The flexible endoscope was initially developed in 1957 as an imaging device dependent on the delivery of light and transmission of the image along multiple bundles of chemically treated glass fibers. The fiberoptic bundle is 2–3 mm wide and is composed of 20,000–40,000 individual fine glass fibers, each approximately 10  $\mu\text{m}$  in diameter.<sup>1</sup> The image undergoes a series of internal reflections within each fiber, which are coated with low optical density glass to prevent escape of light, as it is transmitted up the bundle. Due to formation of the fibers and surrounding material, a characteristic meshed image is seen in fiberoptic endoscopes, which inherently results in a lower resolution than that seen with rigid lens systems. In addition, if the fibers become cracked, the image is not generated at this site of the bundle and multiple black spots are seen.

When utilizing a fiberoptic endoscope, the endoscopist views the image through the eyepiece at the instrument head,

or alternatively, a video camera can be affixed to the eyepiece to transmit the image to a video monitor. The progression from fiberoptic scopes to the videoendoscopes, we use today, has allowed for advancements in our ability to perform more involved therapies, educate physicians and endoscopic assistants, and obtain static and dynamic recorded data images for improved clinical management.

The majority of endoscopes in use today are videoscopic, although in many parts of the world, fiberoptic systems are still the standard. In these videoscopic systems, the visualized image is created from reflections onto a charge coupled device (CCD), which is a chip mounted at the end of the endoscope rather than via the fiberoptic bundles. The CCD chip has thousands of pixels (light-sensitive points), which directly increase image resolution.<sup>2</sup>

### Imaging Advances

There have been many recent advances in endoscopic imaging techniques. The purpose of most of these techniques is early detection of dysplasia, which might elude standard endoscopic visualization. Clinical use of new imaging is limited principally to specialized centers, but future widespread application of an imaging method for early dysplasia detection is a certainty.

## CHROMOENDOSCOPY

The aim of chromoendoscopy is to detect subtle mucosal abnormalities. Commonly used agents include Lugol's solution, methylene blue, indigo carmine, and Congo red. A 2–3% solution of potassium iodide (Lugol's solution) reacts with glycogen in keratinized squamous epithelium. Normal squamous epithelium stains a deep brown, but inflammation, dysplasia, and carcinoma do not stain because of a lack of glycogen. Lugol's solution has been shown to be effective in detecting Barrett's esophagus as well as screening for squamous cell carcinoma of the esophagus.<sup>3</sup>



## MAGNIFICATION ENDOSCOPY

In magnification endoscopy, a cap with a magnifying lens is fitted to the tip of an endoscope. The mucosa in contact with the lens is magnified without impairing the maneuverability of the scope. Degrees of magnification range from 1.5 $\times$  to 115 $\times$  and can be changed on the scope by turning a dial at the hand controls. The technique of magnification endoscopy is frequently used in conjunction with chromoendoscopy. Chromoendoscopy is used for broad surveillance of the mucosa followed by focused examination of suspicious lesions in magnification mode. This combined examination has been reported in case series to enhance detection of Barrett's esophagus, chronic gastritis, *Helicobacter pylori* infection, gastric dysplasia, and early gastric cancer.<sup>4-6</sup>

## CONFOCAL FLUORESCENCE MICROENDOSCOPY

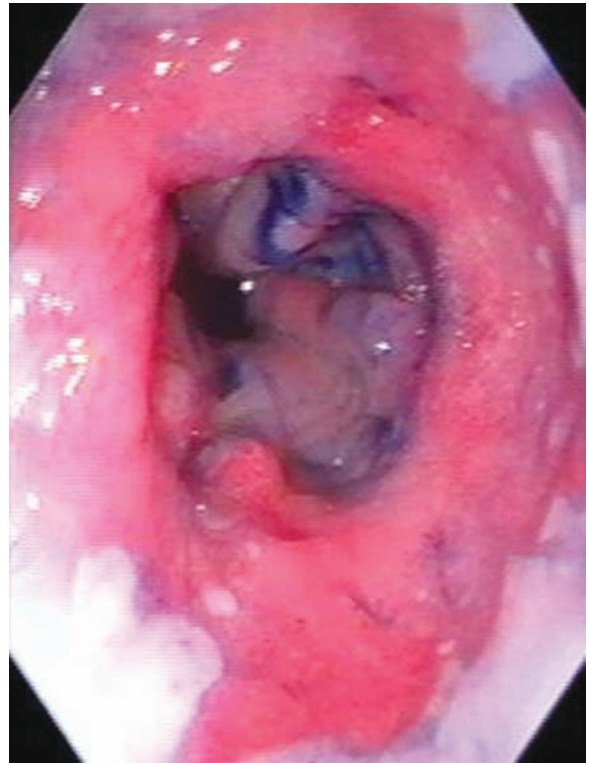
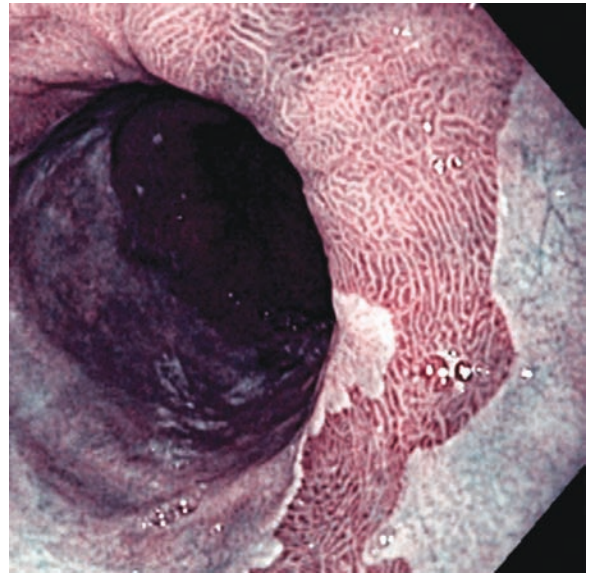
Standard endoscopy uses white light to visualize a large surface area with relatively low resolution. In contrast, confocal endoscopy aims to visualize the mucosa and submucosa with subcellular resolution, a technique deemed optical biopsy. The process of confocal magnification reduces out-of-focus light from above and below the focal plane at a magnification of 1000 $\times$ . The system is designed to measure tissue fluorescence; therefore, an exogenous fluorophore (a molecule that causes another molecule to be fluorescent) is usually administered. Varying depths of tissue are examined by altering the focal plane, and images from different depths are stacked together to create an optical slice of tissue, thus the term optical biopsy.<sup>4</sup>

## NARROW BAND IMAGING

Most endoscopes now have the ability to switch from standard to narrow band imaging (NBI) with the push of a button. In narrow band endoscopy, filtered light is used to preferentially enhance the mucosal surface, especially the network of superficial capillaries. Narrow band imaging is often combined with magnification endoscopy. Both adenomas and carcinomas have a rich network of underlying capillaries and enhance on NBI, thereby appearing dark brown against a blue-green mucosal background.<sup>5</sup> The use of white light as well as NBI has enabled endoscopists to provide an immediate assessment of small colonic lesions without histopathologic evaluation.<sup>7</sup> Gastric mucosal abnormalities are also differentiated by NBI with and without magnification endoscopy.<sup>8</sup> NBI can also differentiate squamous from non-squamous epithelium to help identify Barrett's esophagus (Figs. 3-1 and 3-2).

## AUTOFLUORESCENCE

Autofluorescence endoscopy has been shown in pilot studies to improve the detection of dysplasia in Barrett's esophagus and chronic ulcerative colitis. Autofluorescence endoscopy relies on several principles: tissue architecture changes, such as



**FIGURES 3-1 AND 3-2** Standard white light versus NBI imaging of the distal esophagus in patients with Barrett's esophagus (top). Differentiation of the squamous and columnar mucosa is easily seen in the NBI image (bottom).

mucosal thickening, dampen submucosal autofluorescence; neovascularization alters the light-emitting and scattering properties of surrounding tissue; the biochemical microenvironment, such as high oxidation-reduction activity, alters

autofluorescence; and different tissue types have unique distribution of fluorophores.<sup>4,9</sup>

### OPTICAL COHERENCE TOMOGRAPHY

Endoscopic optical coherence tomography (OCT) is an emerging technology analogous to endoscopic ultrasound (EUS). OCT utilizes a probe passed via the endoscope, although it does not require tissue contact. The technique uses reflection of near-infrared light to produce real-time two-dimensional cross-sectional images of the gastrointestinal tract. These true anatomic images correspond to the histologic layers (mucosa, submucosa, and muscularis propria). The images obtained have a resolution 10-fold greater than EUS (Fig. 3-3). Preliminary studies have looked at the utility of OCT in the evaluation of Barrett's esophagus.<sup>10</sup> Endoscopic optical coherence tomography is not yet in widespread use.

### LIGHT SCATTERING SPECTROSCOPY

Light scattering spectroscopy mathematically analyzes the intensity and wavelength of reflected light to estimate the size and degree of crowding of surface epithelial nuclei. The technique relies on absorption and scattering of white light. Light scattering spectroscopy has shown limited efficacy in detecting Barrett's esophagus and early colonic dysplasia. The technique relies on graphing mathematical computations rather than an optical biopsy as is done in other emerging

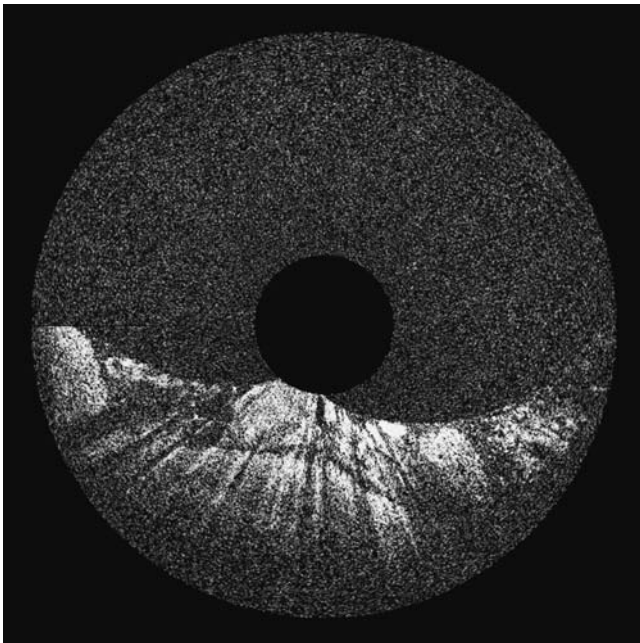


FIGURE 3-3 OCT image of the esophagus.

imaging techniques. Light scattering spectroscopy might be used in combination with optical biopsy for detection of early dysplasia.<sup>4</sup>

### Image Documentation

Many gastrointestinal diseases require surveillance evaluation, and the progression or regression of identified disease state is vital to appropriate patient care. Video endoscopes produce digital signals that can be recorded on a variety of media, including film, hardcopy printout, disk, or a secure data file. During the procedure, it is imperative to visually document important findings and their location for comparison with previous or follow-up studies. This practice also allows other members of the health care team to understand and interpret the findings and plan for appropriate treatment. Additional documentation on anatomic diagrams will also facilitate interpretation. Pertinent negative findings should also be documented.

### Endoscope Anatomy

Flexible endoscopes are being created in a wide variety of lengths and diameters, with an assortment of channel numbers and sizes, adjunct imaging modalities, and intrinsic and extrinsic scope mechanics for reducing scope looping and providing improved scope advancement. A basic understanding of the scope anatomy is vital to the performance of safe and effective flexible endoscopy.

Uniformly, the knobs for controlling manipulation of the scope tip are located on the right side of the headpiece, with an internal larger knob for upward and downward deflections and an external smaller knob, which manipulates the tip to the left and right. Locks accompany each knob to hold the deflection in position when needed. The ability for greater degree of deflection of the endoscope occurs with upward rather than downward manipulations. There is no variability in deflection provided by the right-left knob. In addition to manipulation of the deflecting knobs, significant scope rotation can be achieved by torquing the endoscope, altering the endoscopist's stance, or by rotating the headpiece while inserting or withdrawing the shaft of the endoscope.

There are two buttons on the front of the scope headpiece responsible for tip cleaning, air insufflation, and suction. The suction channel also functions as the biopsy channel so that any endoscopic tools placed into the biopsy channel will limit the ability to suction fluids through the endoscope. A small button on the front of the handpiece above the suction button allows for freezing of the image and digital recording by pressing the image capture button on the back of the handpiece. The endoscope is held in the left hand regardless of the individual physician's hand dominance. The internal up and downward deflection knob is controlled by the left thumb while the air, water, and suction by the left index and middle

fingers. The smaller left-right knob then is usually manipulated by the right hand.

One of the challenges in modern endoscopy, especially colonoscopy, is the formation of undesired loops in the shaft of a flexible scope. Loop formation impedes expeditious and safe passage to the cecum by transmitting the force of insertion to the colon wall or mesentery rather than to forward progression. Two technical advances aim to prevent loop formation: variable stiffness endoscopes and shape-locking overtubes.

### VARIABLE STIFFNESS ENDOSCOPES

Conventional colonoscopes have a static level of column strength throughout the length of the insertion tube. The column strength determines the amount of buckling of the instrument that occurs during insertion and the level of elasticity that remains during reduction of loops. Variable stiffness endoscopes permit alteration of the column strength through an adjustable tensioning coil (Fig. 3-4). The data from studies comparing variable stiffness colonoscopes to conventional scopes are inconclusive. Some studies report faster cecal intubation using variable stiffness endoscopes with less need for adjunct maneuvers, while other similar studies report no significant differences.<sup>11,12</sup>

### SHAPE-LOCKING DEVICE

The ShapeLock Endoscopic Guide (ShapeLock, USGI Medical, San Clemente, CA) consists of a reusable skeleton of multiple titanium links, a disposable inner plastic lining, an atraumatic foam tip, and a disposable smooth external skin. A squeeze handle at the base of the device converts it from a flexible mode



**FIGURE 3-4** The variable stiffness control is seen at the base of the head piece of the colonoscope.

to a rigid mode. The shape-locking device is made in 40 cm and 60 cm lengths with an inner diameter of 20 mm. A small clinical study has been reported using the shape-locking device. No device-related complications were noted, but the optimal strategy for employing the device was uncertain.<sup>13</sup>

## New Scope Technology

While the construction of standard endoscopes has remained largely unchanged over many decades, novel scope designs are being developed to either simplify colonoscopic examinations or enhance mucosal visualization. Other than double balloon enteroscopy, these technologies are chiefly limited to small clinical trials, but their application could gain momentum in the coming years.

### SELF-PROPELLED COLONOSCOPES

In an effort to simplify the process of colonoscopic screening, self-propelled endoscopes are in development. The Aer-O-Scope (GI View, Ltd, Ramat Gan, Israel) is a user-independent, self-propelled, self-navigating colonoscope. The device consists of a disposable rectal introducer, supply cable, and a scope embedded within a scanning balloon. The device contains no working channel for therapeutic interventions; therefore, it is intended for screening purposes only. A small pilot study examined the proof of concept of the Aer-O-Scope. There were no device-related complications.<sup>4</sup>

Another self-propelled colonoscope, the ColonoSight (Stryker Corp, Kalamazoo, MI) employs air-assisted propulsion in a disposable system. A pneumatic mechanism generates the pressure to create the forward force, while an operator directs the scope using handles. The system uses light-emitting diode optics, rather than video or fiber optics, and has disposable working channels. A pilot study for ColonoSight reported intubation of the cecum in 88% of cases at a mean time of 12 minutes without any device-related complications.<sup>4</sup>

## Endoscopic Education

Recent mandates from the American Board of Surgery now require surgical residents to graduate with an increased number of flexible endoscopy cases (50 colonoscopies, 35 esophagogastroduodenoscopies [EGDs]). To provide this experience and to improve the overall endoscopic education of surgery residents, a cohesive curriculum is needed.<sup>14</sup> An iteration of such a curriculum might include periodic simulation training for first-year residents, formal endoscopy rotations for junior residents, and intraoperative and advanced endoscopy for senior and chief residents.<sup>15</sup>

Efforts to improve endoscopic training have led to the development of computer simulators for teaching endoscopic skills. Currently, simulators are available for training in flexible sigmoidoscopy, gastroscopy, endoscopic retrograde cholangiopancreatography (ERCP), EUS, and colonoscopy.<sup>16</sup>



## PATIENT ASSESSMENT, SEDATION, AND MONITORING

### Patient Assessment

Although both upper and lower endoscopy can be performed unsedated, the majority of patients undergoing endoscopic procedures receive agents to provide conscious sedation. Preprocedural patient risk assessment, intraprocedural cardiopulmonary monitoring, and postprocedural recovery are vital to the performance of safe and effective endoscopic interventions. Preprocedural evaluation for ASA risk classification and Mallampati score have become standard guidelines for most endoscopy units.<sup>17</sup> Elderly patients or those with preexisting cardiopulmonary conditions are at increased risk for these complications, as are those undergoing more extensive endoscopic interventions. Patients with diseases associated with the oropharynx or trachea, and those with morbid obesity, sleep apnea, or neuromuscular degenerative diseases require extra vigilance during endoscopic procedures.<sup>18</sup>

### Monitoring

Monitoring should be performed before, during, and after the procedure by a dedicated endoscopy assistant. Signs that are routinely monitored include the patient's level of consciousness, degree of pain, vital signs, and respiratory status.<sup>19</sup> Supplemental nasal oxygen is required to decrease the frequency of desaturation during endoscopic procedures. The patient's oxygenation status and cardiac electrical activity are also monitored by equipment throughout the procedure. It must be understood that pulse oximetry levels can rule out hypoxia and hypoventilation, and resultant hypercarbia can still go undetected. At this time, measurement of end tidal CO<sub>2</sub> monitoring, however, is just beginning to be utilized at the time of endoscopic interventions. In addition, external suction for clearing oropharyngeal secretions must be immediately available and within reach of the endoscopic assistant.

### Sedation

The combination of narcotics (analgesia) and benzodiazepines (sedation and amnesia) is commonly used to provide sedation during endoscopic procedures.<sup>20</sup> Although propofol has a more rapid onset and shorter half-life, its routine use during endoscopic procedures has been widely reserved for those performed in an operating room with an anesthesiologist.<sup>21</sup> Reversal agents (antagonists) for both class of drugs are now available and should be immediately ready for delivery in patients who show signs of oversedation. Titration of medications delivered in small increments allows for the safe performance of sedated endoscopy, especially in older patients with slower circulatory distribution.

Cardiopulmonary issues are the most commonly reported complications with endoscopic procedures. These complications include aspiration, oversedation, hypotension, hypoventilation, arrhythmia, bradycardia (vasovagal), and airway obstruction. Many of the latter are associated with use of intravenous moderate (formerly "conscious") sedation, defined as decreased consciousness associated with preservation of protective reflexes.

## UPPER GASTROINTESTINAL ENDOSCOPY

### Indications

The indications for upper gastrointestinal endoscopy (EGD) can be divided between those for diagnosis and those to provide for potential therapy. Diagnostic EGD is used for the evaluation or surveillance of patients who present with "alarm symptoms" (Table 3-1) as do those with abnormal or inconclusive radiographic studies. Follow-up evaluations for ulcers or surveillance for patients with Barrett's esophagus are also indications. Therapeutic upper endoscopic interventions include the management of bleeding, removal or ablation of premalignant or malignant lesions, management of upper gastrointestinal obstructions, leaks or fistulae, and the creation of enteral access for supplemental feeding or decompression.

### Contraindications

The contraindications to EGD are related to the patient's associated comorbidities, underlying gastrointestinal disorders, or patient's inability to tolerate conscious sedation. Recent myocardial infarction, pneumonia, and recent foregut surgical procedure are relative contraindications for EGD, and the risks and benefits need to be weighed on an independent basis for each patient to determine appropriateness. A recent surgical anastomosis is most likely safe at any time during the postoperative period to be evaluated endoscopically, remembering

**TABLE 3-1: INDICATIONS FOR EGD ("ALARM" SYMPTOMS)**

1. Abdominal complaints not responsive to appropriate empiric therapy
2. Weight loss
3. Early satiety
4. Odynophagia
5. Dysphagia
6. Persistent nausea and vomiting
7. Hematemesis/melena
8. Foreign body impaction
9. Iron deficiency or unexplained chronic anemia

that tissue strength will be weakest on postoperative days five to seven.

Coagulopathy secondary to thrombocytopenia, liver failure, renal failure, or exogenous use of anticoagulants and platelet-inhibiting agents is a relative contraindication for a diagnostic EGD, but an absolute contraindication for a therapeutic intervention. Patient noncooperation and inability for a patient to be safely sedated due to high cardiopulmonary risk are also contraindications to EGD. Respiratory depression secondary to medications as well as inability to maintain an airway can occur in these high-risk patients. Preassessment with ASA classification and Malampatti scores will help predict this high-risk group. Patients with suspected perforation or caustic ingestion injury should not undergo EGD unless there are plans to provide palliative therapy such as endoscopic closure or stent placement.

## Patient Preparation

Upper gastrointestinal endoscopy requires very little preparation other than fasting of solid food for 6–8 hours and liquids for 2–4 hours. Removable dentures and dental implants must be taken out to avoid dislodgement and aspiration during the procedure. The role of lavage in patients with bleeding is debatable, and if large volume lavage is to be used, care must be taken to avoid aspiration including the judicious use of endotracheal intubation. If intervention is anticipated, a recent coagulation profile and platelet count should be within safe ranges. The use of topical pharyngeal anesthetic spray is necessary in unsedated procedures in order to suppress the gag reflex, and is used based on physician preference for sedated cases.

The use of prophylactic antibiotics is rarely indicated for EGD, except in the scenario of esophageal sclerotherapy, dilation, and percutaneous endoscopic gastrostomy (PEG) tube placement. Discussion with the cardiologist as to the role of antibiotics is recommended for patients with prosthetic heart valves, previous endocarditis, systemic pulmonary shunts, or recent vascular prostheses.

## Basic Endoscopic Techniques—EGD

The forward-viewing endoscope is preferred for routine diagnostic endoscopy. It should be noted that the medial duodenal wall, at the site of the ampulla, is preferentially seen with a side-viewing endoscope. More recently, the use of small diameter 5 mm transnasal endoscopes has allowed for the safe performance of unsedated endoscopy.

After appropriate preprocedural patient assessment and informed consent, the patient is routinely placed in a left side down lateral decubitus position. Patients undergoing PEG procedure or other therapies requiring access to the abdominal wall are left supine. Prior to delivery of sedation, a baseline set of vitals is taken and it is confirmed that the equipment is in proper working order and potentially necessary endoscopic

tools are readily available. Following the slow delivery of medications, titrating the doses as needed based on the individual patient needs, the distal several centimeters of the endoscope are lubricated avoiding the actual tip of the endoscope as this will obscure the image and, even with irrigation, will make visualization difficult.

Intubation of the esophagus is best accomplished under direct vision by advancing the endoscope over the tongue, past the uvula and epiglottis, and then posterior to the arytenoid cartilages. This maneuver will impact the endoscope tip at the cricopharyngeal sphincter and allow entry into the cervical esophagus with gentle forward pressure once the patient swallows. Blind insertion with the endoscopist's hand in the patient's pharynx is not recommended as this is more dangerous for both the patient and the endoscopist.

Once in the cervical esophagus, the instrument is advanced under direct vision taking care to survey the mucosa during both insertion and withdrawal. The distance to the squamocolumnar junction, the “Z-line,” where the white squamous esophageal mucosa meets the red columnar gastric epithelium, is recorded in the procedure report. The site of the diaphragmatic crura (hiatus) should also be recorded and is seen as impression into the esophageal or gastric lumen. This point can be accentuated by asking the patient to sniff while the area is visualized. The endoscope is then advanced into the gastric lumen under direct visualization. Unlike colonoscopy where there is a requirement for significant torquing or twisting of the scope, due to fixation of the esophagus in the mediastinum, EGD manipulations can be more directly achieved with deflection of the wheels and movement of the handpiece (“dancing with the scope”).

After aspirating any gastric contents, the four gastric walls are surveyed using combinations of tip deflection and shaft rotation, insertion, or withdrawal. During upper endoscopy, the endoscope will naturally follow the greater curvature as it advances toward the antrum and this is called the “long position.” This affords an end-on view of the pylorus, which is approached directly. Passage through the pylorus can usually be facilitated by gentle pressure and air insufflation. Entry into the duodenal bulb is recognized by the typical granular, pale mucosa without the folds of the valvulae conniventes. Finally, the second portion of the duodenum is entered with the associated folds, by deflecting the tip up and to the right. In addition, rotating the handpiece to the right will help facilitate this maneuver. Withdrawal of the endoscope at this point while keeping the tip deflected leads to paradoxical advancement of the endoscope down the duodenum. Withdrawal of the endoscope places the shaft along the lesser curvature of the stomach and allows for this paradoxical forward advancement of the tip. This is referred to the “short position.” All areas should be carefully surveyed again as the endoscope is withdrawn.

The final component of a diagnostic EGD is evaluation of the cardia, fundus, and incisura along the lesser curvature. With a forward-viewing endoscope, these sites are visualized by a retroflexion maneuver with full upward tip deflection (Figs. 3-5 and 3-6).

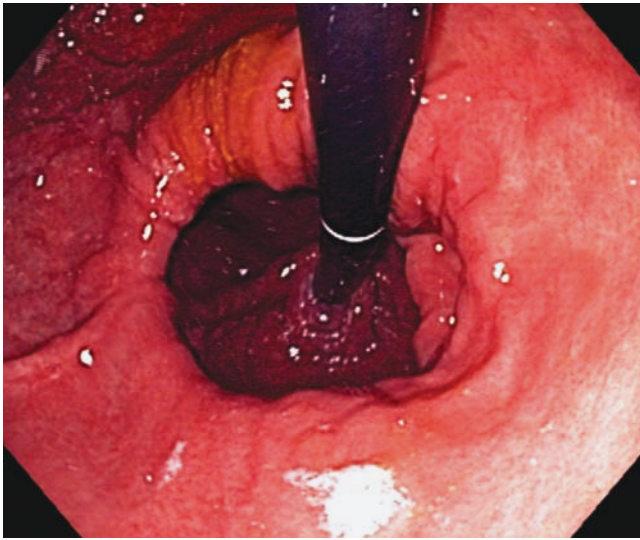


FIGURE 3-5 Retroflex view in the stomach, here revealing a large type III paraesophageal hernia.

## Techniques of Endoscopic Tissue Sampling

Sampling of tissue is most frequently obtained by passage of a spiked forceps via the endoscope's biopsy channel. Multiple biopsies should usually be obtained. For ulcers, one should biopsy the edge of the lesion in at least four quadrants. Standard biopsy techniques are quite superficial; however, if deeper biopsies are desired, these can be obtained by using either a jumbo forceps or the practice of repetitive biopsies at the same site, which will lead to a deeper sampling.

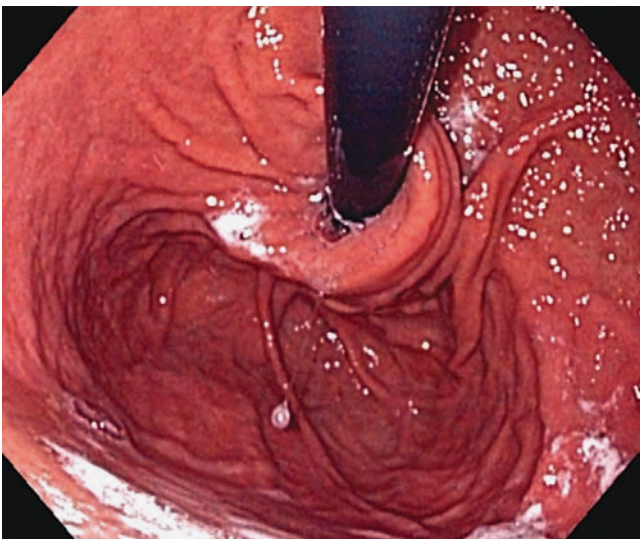


FIGURE 3-6 In another retroflex view, an intact surgical fundoplication is seen.

Surveillance in diseases such as ulcerative colitis and Barrett's esophagus require a standardized sampling technique. Ulcerative colitis protocols recommend biopsies every 10 cm throughout the entire colon, and Barrett's sampling per the Seattle protocol requires at minimum 4-quadrant biopsies every 1 cm using a jumbo forceps. The goal of these sampling techniques is to identify the presence of dysplastic tissue necessitating further intervention.

Tissue and lesions can also be sampled by the use of brush cytology. In this technique, a sleeved brush is passed through the biopsy channel of the scope and rubbed forcefully over the desired site. The brush head is extended, stirred in a fixative solution to be spun down for cell evaluation, and then transected and dropped into fixative for direct cytologic analysis. The sensitivity and specificity of this technique are dependent on direct approximation to the diseased mucosa, and should not replace a directed biopsy if attainable.

## THERAPEUTIC ENDOSCOPIC INTERVENTIONS

### Management of Bleeding

Endoscopy plays a critical role in evaluation and treatment of upper GI (UGI) bleeding. The degree of rapidity of UGI bleeding varies from severe with gross hematemesis to mild, presenting as either heme-positive stools or iron deficiency anemia. The timing for EGD should be based on each individual clinical scenario, understanding that endoscopy is both a diagnostic and a therapeutic tool. In all patients, hemodynamic stabilization and correction of any sources for ongoing coagulopathy are a priority.

Endoscopic hemostatic therapies can be divided into thermal and nonthermal categories. In addition, these hemostatic options can be further delineated based on specific ideal applications. There are associated risks with each of these techniques, which must be understood to allow for appropriate tool selection. It is also possible to treat bleeding with combined modalities such as coagulation and injection, or clipping and injection. When comparing individual therapeutic techniques, there is very little difference between them in terms of providing successful hemostasis. In fact, there are numerous studies to demonstrate the superiority of combined over single hemostatic therapy. Given the relatively high success rates of controlling UGI bleeding by endoscopic modalities, it is appropriate to pursue endoscopic means whenever available before seeking surgical or interventional radiology options.<sup>22</sup>

### THERMAL TECHNIQUES

Thermal therapies control hemorrhage by inducing tissue coagulation, collagen contraction, and vessel shrinkage. Thermal energy is delivered via a contact or a noncontact device. Thermal therapies are successful in 80–95% of cases, with a



rebleed rate of 10–20%. These techniques are easy to use and safe, with a perforation rate of 0.5%, although this is dependent on the site of the gastrointestinal tract, with the cecum more likely to result in perforation than a thicker organ such as the stomach.<sup>23</sup>

**Contact Thermal Techniques.** Contact or coaptive techniques involve the use of probes passed via the biopsy channel, which allow for pressure tamponade of the bleeding point with simultaneous application of thermal energy for coagulation. The firmer one applies the device to the tissue, the greater the depth of energy penetration. In addition, the tamponade not only improves visualization, but also reduces the “heat sink” effect of active bleeding, and thereby improves the efficiency of the coagulation process. Multi-polar (bipolar) cautery (Fig. 3-7) and heater probe devices are used most commonly, although monopolar cautery via a biopsy forceps or snare may also be employed, albeit with a potentially higher risk of injury. The heat generated, which can reach several thousand degrees, is sufficient to cause full-thickness tissue damage, so care is required when using this modality.

Both cautery and heater probe units allow pulse irrigation to be performed for visualization and clot clearance via foot pedal control. Variables important in achieving hemostasis include probe size, force of application, power setting, and duration of energy delivery.<sup>23,24</sup> Vessels of up to 2 mm in diameter appear to be able to be well controlled by these techniques although the overall surface area treated by these devices is limited by the size of the probes.

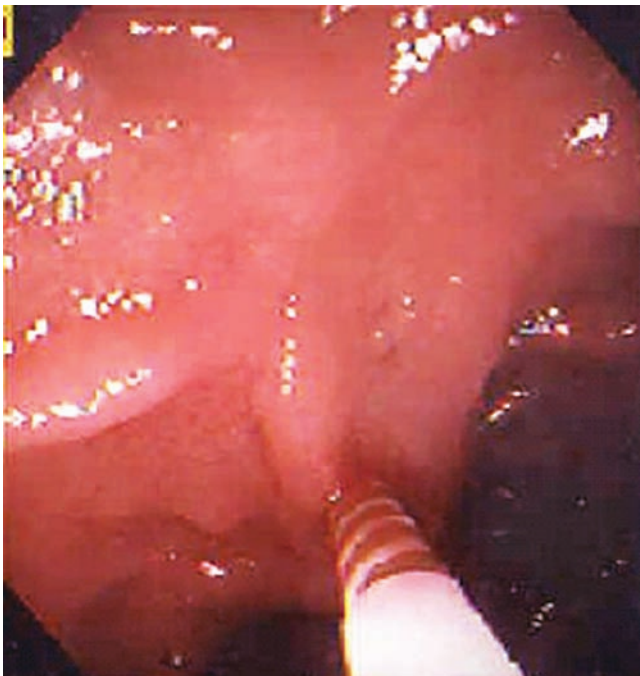


FIGURE 3-7 The bipolar endoscopic cautery device.

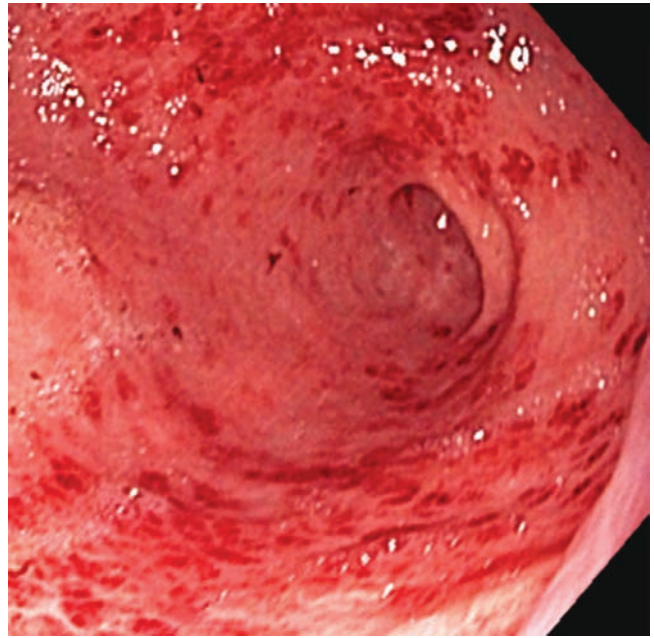


FIGURE 3-8 Endoscopic image of gastric antral vascular ectasia (GAVE) representing a diffuse disease best treated with argon plasma coagulation.

**Noncontact Thermal Techniques.** Argon plasma coagulation (APC) is a technique in which thermal energy is applied to tissue via ionized argon gas. This technique has the disadvantage of not allowing a tamponade effect, but conversely is not prone to adherence of the probe to the hemostatic coagulum. The gas has an effect of clearing luminal liquid from the point of application; however, due to the high pressure of gas delivery, one must be careful to avoid overdistention of the lumen by using frequent suctioning during APC usage. It is more widely utilized in most centers than laser, and in limited studies appears to have similar efficacy to contact probes.<sup>24</sup>

APC is particularly well-suited for settings where large mucosal areas require treatment such as gastric antral vascular ectasia (GAVE) (Fig. 3-8), or where the risk of deeper thermal injury leading to perforation is of heightened concern, for example, cecal angiodyplasia.

## NONTHERMAL TECHNIQUES

**Injection Sclerotherapy.** Injection therapy is performed by passage of a catheter system through the biopsy channel of the endoscope. There is an internal 5-mm needle, which can be advanced and withdrawn as needed. The sclerosant is injected submucosally. Injection therapy at three or four sites surrounding a bleeding site prior to contact thermal techniques may prove more effective, as the created eschar is occasionally removed inadvertently affixed to the treating probe. If tamponade is provided first with injection

therapy, bleeding following initial thermal therapies can be reduced. The amount injected varies with different agents, and it must be remembered that systemic absorption will occur. Dilute 1:10,000 epinephrine solution is the most commonly used agent, and should be limited to less than 10 cc total volume. Other agents available include absolute alcohol, thrombin in normal saline, sodium tetradecyl sulfate, and polidocanol.<sup>22,23</sup> For esophageal varices, injections are begun just above the gastroesophageal junction. Sclerosants can be injected either directly into the varix or along side it, intravariceal or paravariceal. Variceal banding with endoscopic band ligators, although associated with a slightly higher rate of rebleeding, has predominantly supplanted injection sclerotherapy due to lower complication rates. In the absence of active bleeding or stigmata of bleeding, prophylactic endoscopic variceal eradication should not be performed because of the high risks of complications associated with the procedures. In patients with severe variceal bleeding or recurrent bleeding following endoscopic therapies, other options such as transjugular intrahepatic portosystemic shunt (TIPS) or surgical portosystemic shunting should be considered (see Chap. 47).

### Endoscopic Ligation Techniques

**Endoscopic Band Placement.** Endoscopic band ligating systems are readily available and provide an alternative for management of variceal and nonvariceal bleeding, and are also routinely used in conjunction with endoscopic mucosal resection (EMR) techniques. This technique is based on the ability to suction tissue into a cap placed at the tip of the endoscope, and then with the turning of a control knob, fire a small tightly constricting rubber band. Single band devices were initially developed for the treatment of esophageal varices, but there are now numerous multiband ligating systems. This innovation provided an alternative to injection sclerotherapy, and although it proved to be slightly less effective in preventing recurrent bleeding, complications such as stricture formation have been dramatically reduced. Applications for endoscopic banding include treatment of internal hemorrhoids, dieulafoy ulcers, esophageal and gastric varices, and mucosal neoplasia in conjunction with EMR.<sup>25</sup>

**Endoscopic Suture Placement.** Pretied endoscopic loops can also be applied through a standard endoscope biopsy channel, and can be used for ligation of pedunculated structures before or after endoscopic resection. These single application devices are similar to laparoscopic endoloops, although they are nylon sutures, and instead of an actual slip knot, a plastic cinching device holds the loop in place once deployed. Use of a double channel endoscope, allowing for a two-handed technique to grasp the desired tissue and deliver it through the opened loop, is preferred. Similar to clips, these sutures will routinely slough off the tissue in 1–2 weeks.

**Endoscopic Clipping.** Endoscopic clip placement is an effective method to control bleeding and can be used safely

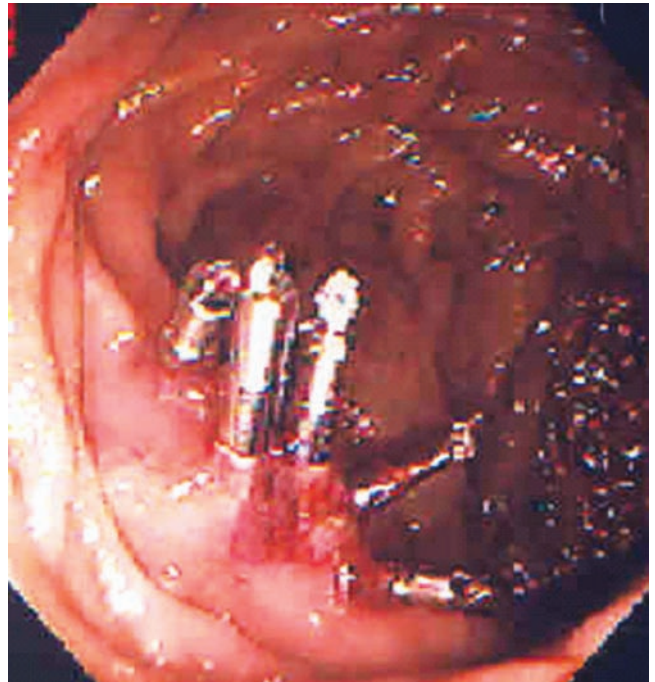


FIGURE 3-9 Endoscopic image of multiple clips placed to provide hemostasis.

at multiple sites throughout the gastrointestinal tract.<sup>26–28</sup> Frequently, more than one clip is necessary at the site of bleeding (Fig. 3-9). The depth of tissue obtained by endoscopic clip placement is quite superficial, with only the mucosa routinely being captured. Clips are placed via the biopsy channel of the scope and come with varied application and shape qualities. Rotatable clips as well as clips that can be opened and closed prior to final positioning are available. In addition, clips with both two arms and three arms, as well as those that have single use and multiple use deployment systems are manufactured. These clips can effectively control bleeding, and usually fall off in 1–2 weeks. Cases of clips remaining at the site with and without mucosal overgrowth months after placement have been reported.

### Endoscopic Mucosal Resection

The treatment of premalignant as well as superficial cancers can now be managed by endoscopic resective techniques. EMR has been employed for adenomas, dysplastic lesions, and early-stage carcinomas, including lateral spreading tumors.<sup>29</sup> Carcinomas without submucosal invasion or nodal spread might be amenable to EMR. Although these diseases are less commonly seen in Western societies, the use of these techniques is routine throughout Asian populations for treatment of esophageal and gastric lesions. Conversely, colonic lesions in Western countries are routinely managed with these modalities. CT scan and EUS are recommended to assess for



nodal disease prior to EMR. Multiple technical variations of EMR for the upper and lower tract have been developed, including submucosal injection, “suck-and-cut,” “suck-and-ligate,” and strip biopsy.

### SALINE LIFT EMR

The most commonly performed EMR technique employs submucosal injection of a fluid followed by electro-surgical polypectomy. Initially the margins of the lesion are clearly delineated, and the periphery is marked using short burst of electrocautery. A standard sclerotherapy needle is then used to perform a submucosal injection. The most commonly used fluid is saline with or without epinephrine, although hyaluronic acid, glycerol, and dextrose have all been described. A bleb is created with the submucosal injection creating space between the line of resection and the muscularis propria of the organ, and the lesion is resected (Figs. 3-10 to 3-12). Repeat injection of agent is commonly needed due to absorption as well as diffusion of the fluid. Injection beyond the lesion first allows for better imaging of the tissues. Intralesional injection can also be used prior to resection. One caveat to this technique is that if the submucosal injection does not result in elevation, one must consider that this mass is an invasive lesion and should not be resected endoscopically. Multiple biopsies as well as EUS should be performed.

### “SUCK-AND-CUT” EMR

The “suck-and-cut” technique uses a specially designed cap attached to the tip of the endoscope. A submucosal injection may be created a priori and the lesion is sucked into the cap. A snare affixed to the cap is used to encircle the lesion, which is then resected by application of electrocautery. Similar to

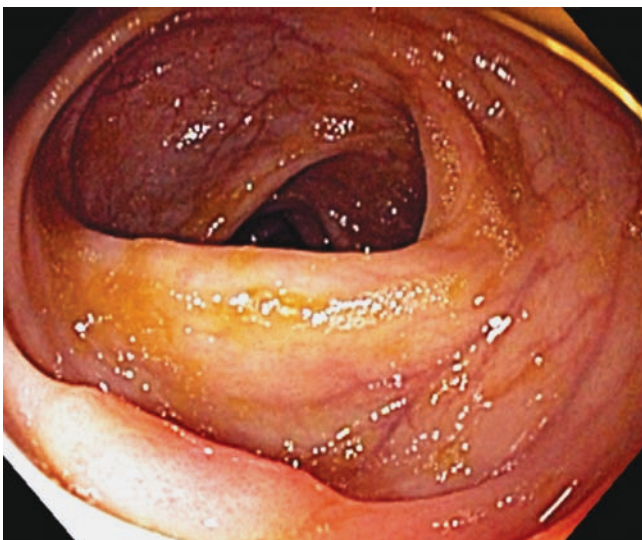


FIGURE 3-10 Sessile colon polyp prior to saline lift EMR polypectomy.

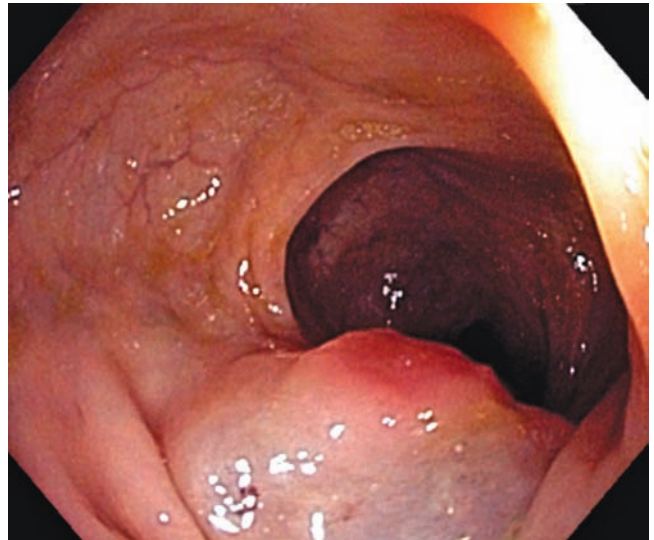


FIGURE 3-11 Sessile colon polyp following saline submucosal injection.

any thermal technique, risk of perforation exists. In addition, the depth of tissue acquisition is not well controlled, and care should be taken to avoid inadvertent perforation, especially in thinner walled organs such as the cecum.

### “SUCK-AND-LIGATE” EMR

The “suck-and-ligate” technique transforms a sessile or nodular lesion into an artificial pedunculated polyp, which can then be resected with standard polypectomy techniques. A band ligating device is attached to the tip of the endoscope

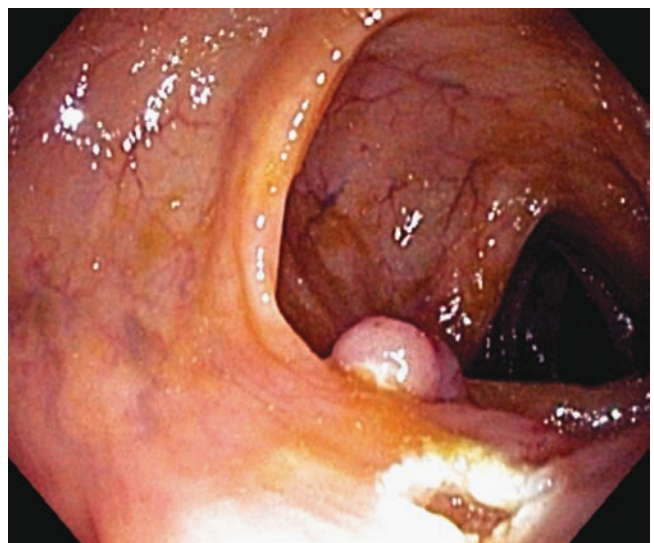


FIGURE 3-12 Saline lift EMR polypectomy of sessile colon polyp. Resected polyp is seen in the distance and the polypectomy site in the foreground.

and the tissue is sucked into the cap and a band is placed at the base of the lesion. This is done with or without saline lift injections prior to banding. This serves to separate the mucosal lesion from the submucosa, permitting safe resection using a standard polypectomy snare.

The most frequent complications of EMR are bleeding and perforation. Immediate bleeding can be controlled with endoscopically placed clips or injection of dilute epinephrine. Electrocautery should be used judiciously after EMR because the thin submucosa and serosa are susceptible to full-thickness injury with cautery. Delayed bleeding often requires repeat endoscopy with injection therapy or clip application, although angiography and embolization may be an alternative. Perforations can also be managed endoscopically with endoscopic clips as well as temporary enteral stent placement to cover the site of perforation.

### ENDOSCOPIC SUBMUCOSAL DISSECTION

An extension of EMR that has been recently reported for endoscopic resection of more extensive lesions is endoscopic submucosal dissection (ESD). Utilizing a combination of needle cautery and blunt endoscope cap dissection, large segments of tissue can be resected. Two-handed techniques utilizing a double channel scope is vital. Circumferential segments of tissue can be removed, although these are lengthy and very challenging procedures. The advantage of ESD is that it represents a more classic oncologic maneuver, as compared to the piece meal resection that occurs with other EMR techniques, in that margins as well as lesion depth can be more accurately pathologically evaluated. Complications are higher than for the other EMR techniques, including bleeding, perforation, and stricture formation which can occur in almost 20% of cases.<sup>29</sup>

### ENDOSCOPIC MUCOSAL ABLATION

Endoluminal therapies for ablation of mucosal-based diseases such as Barrett's esophagus have recently seen great advances. Previously, photodynamic therapy was the principal technique used, but the associated complications and the side effects related to the delivery of the sensitizing agent were high. Endoscopic radiofrequency ablation (RFA) is a relatively new technology that has recently gained acceptance for treatment of intestinal metaplasia as seen in Barrett's esophagus.<sup>30</sup> Its unique design incorporates bipolar radiofrequency energy and applies it directly to the esophageal epithelium for ablation. A balloon-based system, as well as a directed planar electrode device implementing this technology, has been used in this form of therapy. The balloon-based model has proved to be safe for Barrett's esophagus.<sup>29</sup> The HALO<sup>90</sup> system (BARRX Medical, Sunnyvale, CA) is an endoscopic RFA device composed of an ablation electrode that is mounted to the end of a flexible endoscope.

There is a 13 mm (width) × 20 mm (length) planar electrode on the face of the probe that delivers the designated energy. The electrode has a 4-mm diameter catheter that runs

from the device along the endoscope and is connected to an RFA generator. The generator can be altered to vary energy density [joules/centimeter<sup>2</sup> (J/cm<sup>2</sup>)] and power density (watts/cm<sup>2</sup>). This endoscopic RFA technology also delivers a controlled amount of energy to the tissue that is predetermined prior to firing, whereby limiting unintentional transmural and potentially extraluminal injury.

Several studies have proven feasibility and safety for this novel therapy, with very few documented cases of postprocedural structuring as had been seen with photodynamic therapy (PDT).<sup>31–33</sup> Further studies documenting long-term effects of this therapy, as well as the absence of buried submucosal metastatic glands or cancer, are still necessary.

## Endoscopic Enteral Access

Endoscopic access to the gastrointestinal tract has become one of the most common endoscopic procedures now performed. What had previously required surgical intervention is routinely managed endoscopically. Gastric access (PEG), jejunal access (direct percutaneous endoscopic jejunostomy [PEJJ]), or a combination of both (PEG with jejunostomy tube extension [PEG-JJ]) can be provided. Indications for access include supplemental feeding, decompression, fixation of structures, and access for meds. There are only a few absolute contraindications to endoscopic enteral access including esophageal obstruction and limited life expectancy. Patients with expected survival of less than 4 weeks should not undergo these procedures. Relative contraindications requiring individual patient selection include severe malnutrition, ascites, prior abdominal surgery, prior gastric resection, peritoneal dialysis, coagulopathy, and gastric malignancy.

### PERCUTANEOUS ENDOSCOPIC GASTROSTOMY

PEG is now the preferred method for long-term feeding in patients who are unable to swallow or who require supplemental nutrition or chronic gastric decompression. PEG may be preferable to surgical gastrostomy since it is safe, less expensive, and less invasive. A variety of PEG techniques are available including "pull," "push," and "introducer." "Pull" and "push" techniques require passage of the tube via the oropharynx and it is proposed that infectious risks and seeding of oropharyngeal cancers might be increased as compared to "introducer" technique, where the tube is placed percutaneously through the abdominal wall under endoscopic guidance. This theory has yet to be proven in randomized prospective trials.

Prior to any PEG procedure, a single dose of prophylactic cephalosporin (or equivalent) should be given intravenously. The patient is placed in the supine or semi-Fowler position with the head elevated and the arms held with soft restraints, after which the abdomen is prepared and draped using sterile technique. The endoscope is then passed into the stomach, which is distended with air insufflation. It is

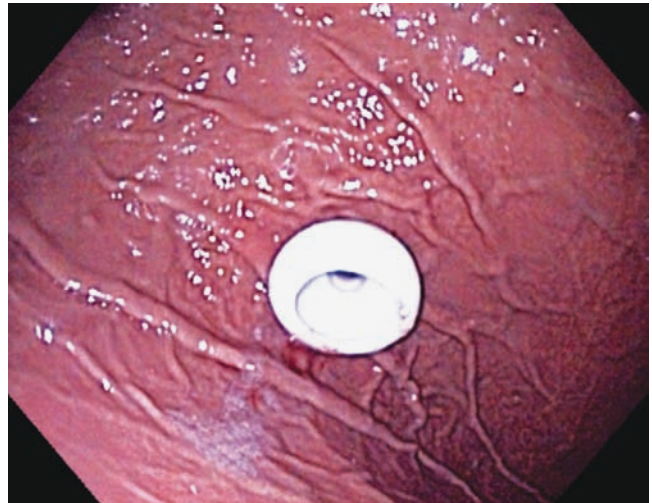
recommended to perform a brief but complete endoscopic evaluation of the esophagus, stomach, and duodenum to rule out any coexistent disease, which might require treatment or complicate the PEG procedure. The assistant then presses on the abdomen with a single finger and the impact against the anterior gastric wall should be noted. Ideally, this point should be 2–3 cm below the costal margin and the maximal point of impression may be on either side of the abdominal wall or subxyphoid. Light transillumination from within the stomach to the skin surface may aid in identifying a safe landmark. Finally, it is imperative to perform a “safe tract” technique to assure that there is no intervening hollow viscus between the stomach and anterior abdominal wall. After anesthetizing the skin, a syringe with saline or local anesthetic is passed through the abdominal wall at the selected site while aspirating. As soon as air is appreciated in the syringe, the tip of the needle should be simultaneously visualized by the endoscopist in the gastric lumen. If not, an alternative site needs to be selected.

The endoscopist now passes a polypectomy snare through the endoscope channel at the selected intragastric site. A small transverse incision (approximately 7–9 mm) in the skin is created and the assistant then inserts a 14-gauge intravenous cannula through the incision into the gastric lumen. The snare is then tightened around the cannula and the inner stylet is removed.

**“Pull” PEG.** In the “pull technique,” a long looped suture is placed through the cannula, after which the snare is released. The suture is then firmly grasped with the polypectomy snare. The endoscope and the tightened snare are removed together, bringing the suture out of the patient’s mouth. The suture is secured to a well-lubricated gastrostomy tube at its tapered external end. The assistant then pulls on the suture until the attached tube exits the abdominal wall. The endoscope is then reinserted and used to view the tube’s inner bolster (Fig. 3-13) as the stomach is loosely seated against the abdominal wall and the tube is properly positioned. This second intubation of the endoscope can be aided by grasping the PEG bumper with the snare passed through the endoscope. With withdrawal of the PEG through the mouth and out the abdominal wall, the endoscope is reintroduced into the esophagus. The snare is opened after esophageal intubation. The external bumper is placed loosely so that there is no tension at the PEG site and the endoscope is then removed.

**“Push” PeG.** In the “push technique,” a guide wire rather than a looped suture is inserted through the cannula and pulled out the patient’s mouth. The gastrostomy tube, called a Sachs-Vine tube, has a long tapered tip, which can be pushed over the wire until it exits the abdominal wall. A second endoscopic intubation is recommended similar to the “pull” technique.

**“Introducer” PeG.** In the “introducer technique,” a guide wire is passed through the cannula placed into the stomach



**FIGURE 3-13** Second intubation is recommended after PEG placement to confirm the position of the internal bumper and to exclude any postprocedural bleeding.

under endoscopic guidance. An introducer with a peel-away sheath is then passed over this wire, allowing removal of the wire and introducer. A Foley catheter or other similar gastrostomy tube is then placed through the sheath, its balloon is inflated, and the sheath is removed. The catheter is then secured to the abdominal wall. The placement of T-tags prior to performance of the introducer PEG can help to secure the stomach to the abdominal wall.

**Laparoscopic-Assisted PEG.** In patients with morbid obesity, prior surgery, or intrathoracic gastric positioning, where safe access cannot be adequately determined by routine endoscopic techniques, simultaneous laparoscopy and endoscopy can be performed to complete the PEG safely. In this way, a long spinal needle can be passed under direct laparoscopic view from the abdominal wall into the gastric lumen and the PEG can be completed as described above.

**Interventional Radiology–Assisted PEG.** In patients with a “hostile” abdomen secondary to malignancy, multiple prior surgeries, or obesity where safe access cannot be endoscopically determined and laparoscopy would be challenging, a percutaneous intragastric pigtail catheter can be placed by interventional radiology under CT or ultrasound guidance. Utilizing a rendezvous technique, a guide wire is then advanced through the pigtail during upper endoscopy, and the PEG is completed.

**PEG with Jejunostomy Tube Extension.** In patients who fail to tolerate gastric feedings due to severe gastroesophageal reflux or gastroparesis, transpyloric feeding can be provided via a jejunostomy tube passed through the existing PEG. There are no prospective randomized trials, however, showing a difference between intragastric and transpyloric feeding, in terms of incidence of aspiration pneumonia. The majority of cases of



aspiration pneumonia are related to aspirated oropharyngeal secretions in a patient unable to protect their own airway.

PEG-J placement is achieved by passing a jejunal feeding tube through the PEG lumen (a 24 Fr PEG tube accommodates up to a 12.5 Fr J-tube; a standard 20 Fr PEG tube accommodates an 8.5 Fr J-tube). Endoscopically, the jejunal tube is guided into the duodenum under direct vision. A loop suture on the tip of the jejunostomy tube can be grasped by an endoscopic clip and once in the distal duodenum, the clip is deployed onto the small bowel mucosa to secure the tube in place. These clips routinely fall off in 1–2 weeks, but this technique allows for easier removal of the endoscope from the duodenum without simultaneous inadvertent withdrawal of the J-tube at the end of the procedure.

### DIRECT PERCUTANEOUS ENDOSCOPIC JEJUNOSTOMY TUBE

In patients with confirmed aspiration secondary to gastroesophageal reflux of intragastric feedings, direct PEJ rather than PEG-J is of benefit. Feedings beyond the ligament of Treitz are associated with a lower incidence of gastroesophageal-induced aspiration as compared to simple postpyloric feeding.<sup>34</sup> Direct PEJ, however, is associated with increased procedural risks including bleeding, inadvertent viscus injury, and leakage.<sup>35–38</sup> Performance of direct PEJ requires both endoscopic and fluoroscopic guidance. Utilizing a pediatric colonoscope, the proximal jejunum is intubated and the tip of the endoscope is fluoroscopically visualized. Abdominal wall depression with a haemostat is performed at this site to try to identify a loop of small bowel adjacent to the abdominal wall. Safe tract techniques are then used to access the identified bowel and a “pull” PEJ is performed with either a 16 Fr or 20 Fr tube. Second intubation with the endoscope to the PEJ site is mandatory to assure intraluminal positioning of the jejunostomy tube bumper.

**Foreign Body Extraction.** Foreign bodies are ingested predominantly by two groups of patients: children (ages 1–5 years) who accidentally swallow an object, and adults, who are obtunded or inebriated, have a psychiatric disorder, or are prisoners.<sup>39,40</sup> Food impaction may occur in patients who have an underlying benign or malignant esophageal stricture, or in patients with esophageal motility disorders.<sup>41</sup> Also, patients who are edentulous or have poor fitting dental prostheses are at risk for food impaction of poorly chewed meat boluses. Evidence of respiratory compromise or an inability to handle one’s own secretions indicates an immediate need for endoscopic evaluation and extraction of the object.

When performing endoscopic extraction, protection of the airway is of vital importance. Endotracheal intubation is required in patients who are unable to handle their own secretions. An endoscopic overtube should be considered when there is concern for dropping pieces into the airway such as when removing sharp objects or multiple fragments. In addition, practicing with a similar foreign body prior to an

attempted removal will allow for selection of the most appropriate endoscopic tool.

Coins represent the most object swallowed by children, and if seen to be in the esophagus should be removed promptly due to the risk of pressure necrosis and fistula formation.<sup>39</sup> The coin is localized and grasped with a polypectomy snare, net, or rat-tooth or tenaculum forceps. A Foley catheter is not recommended since it does not control the object well during removal and could become dislodged into the airway.

In the adult population, meat impaction represents the most common foreign body and should be removed if they remain for longer than 12 hours due to the risk of pressure necrosis.<sup>41</sup> Gentle scope advancement at the level of the obstruction can many times assist in passage of the food bolus. Piecemeal removal with baskets, nets, and snares may be needed, with care being taken to avoid passage of the foreign body into the airway. If the bolus should pass, EGD is still indicated to rule out an associated esophageal lesion.<sup>41</sup>

Use of an overtube or protective endoscopic hood may greatly facilitate removal of sharp objects such as toothpicks, fish or chicken bones, needles, and razor blades. When removing sharp objects it is important to follow the tenet of always having the sharp end trailing. If necessary, sharp objects can be carefully pushed into the stomach, rotated, and then brought out with the pointed end trailing.

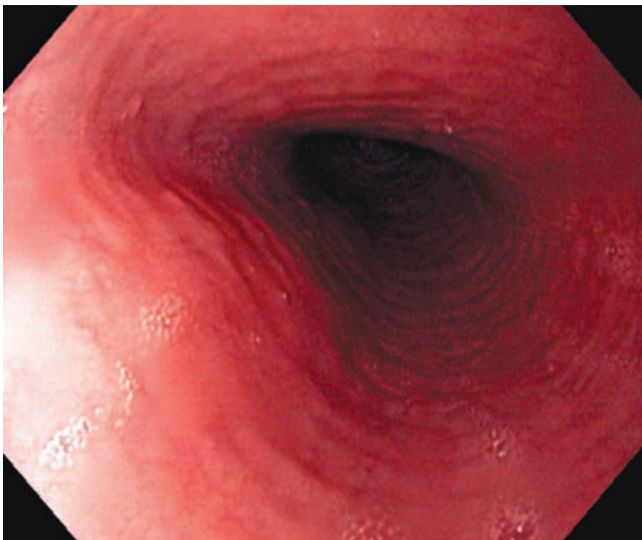
Ingested button batteries must be removed immediately to prevent viscus injury secondary to a corrosive burn. These batteries usually pass readily in other parts of the gastrointestinal tract without causing harm, although all mucosal surfaces must be examined endoscopically to identify any resultant injury.

When encountered, cocaine-filled packets should never be removed endoscopically because of the risk of breakage. Close observation and expectant management is more appropriate, with expedient surgical intervention for any signs of bag rupture or bowel obstruction.

Following any foreign body removal, the endoscopist must exclude any associated underlying disease such as stricture, neoplasm, or motility disorder (Fig. 3-14). In addition, one must be aware of the possibility of delayed viscus injury secondary to pressure necrosis resulting in partial or full thickness injury. Emergent contrast study or CT should be used as needed to evaluate for these complications. Repeat endoscopy, motility study, or elective contrast studies may also be required based on patient’s history or continued symptoms.

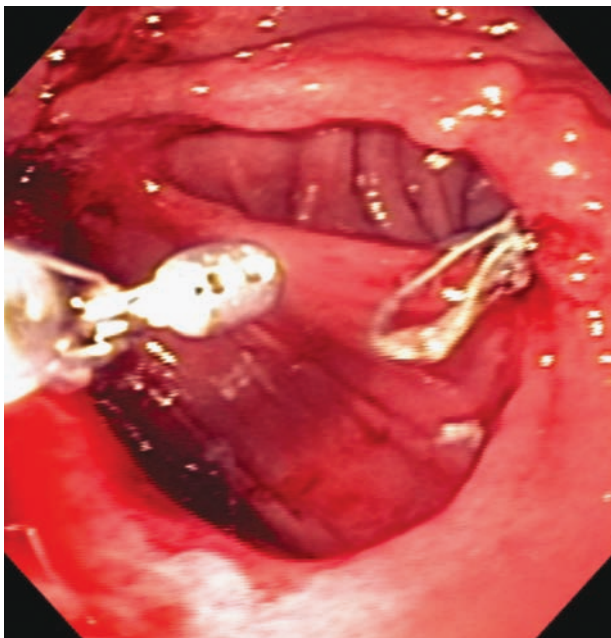
Other nonobstructing foreign bodies may be identified in postsurgical patients. Intraluminal suture migration may lead to symptoms of pain or dysphagia. (Fig. 3-15). Removal with endoscopic scissors may relieve the patient’s symptoms of pain or dysphagia.

**Endoscopic Dilation.** Endoscopic dilation can be performed for any enteral stricture that can be accessed by endoscopic means. The endoscopic component of dilation may include identification, passage of a guide wire, or delivery of a dilating balloon via the endoscope channel. Strictures secondary to ischemia, inflammation, radiation, neoplasm, and



**FIGURE 3-14** Classic eosinophilic esophagitis seen in a patient with history of dysphagia and prior food bolus. Endoscopic biopsies with identification of increased eosinophils confirms the diagnosis.

postsurgery are all amenable to endoscopic dilation. The use of fluoroscopy as an adjunct to endoscopic dilation is believed to decrease the risk of perforation, although this has not been fully proven in randomized prospective trials.<sup>42</sup> In addition, the type of sedation utilized is dependent on the clinical status of each individual patient, as those with tight esophageal strictures may be best served with elective airway protection.



**FIGURE 3-15** Sutures can be seen at the site of a prior gastrojejunostomy.

Although several types of dilators have been used, the two most common dilators used are the guide wire–driven type, which applies both axial and radial forces, and the balloon type, which applies only radial forces. Treatment is safer when performed by incremental dilations over successive sessions. A general approach is to limit the number of dilations to three successive balloon or dilator sizes in one session. Injection of steroid solutions (kenalog) into the stricture may reduce the severity of postdilation inflammation, scarring, and restructure. The frequency of dilation will depend on the severity of the stricture and the patient's symptoms.

Balloon dilators are used for short strictures, stenotic stomas, and achalasia. These dilators can be passed over a previously placed guide wire, and are delivered through the endoscope's therapeutic channel. Fluoroscopic guidance for balloon dilation allows the endoscopist to gauge several components of the procedure. First, it assures the positioning of the balloon in the viscus lumen. Second, if contrast is injected in the balloon as the dilating fluid, expansion of the balloon fully can be appreciated. This is termed "waist ablation" and refers to the full dilation of the balloon at the site of the stricture. The balloon changes from an hour glass appearance to a full elliptical-shaped figure.

Long, complex strictures may be less responsive to endoscopic dilation, and may also require repeat treatments. Aggressive biopsing of the mucosa after dilation is necessary in cases of unclear etiology. Complications secondary to endoscopic dilation include bleeding, perforation, mucosal tears, and recurrent structuring.

**Enteral Stent Placement.** Over the past several years, endoscopic stent technology has made impressive strides in providing tools for increasingly complex clinical scenarios. Both the delivery systems and the stents themselves have gone through significant changes and allowances for treatment of a multitude of benign and malignant disease processes. Strictures, leaks, fistulae, and obstructing neoplasms have all been approached with enteral stents.<sup>43-50</sup>

**Stent Delivery Systems.** Based on the location of the gastrointestinal tract that is to be treated, as well as the characteristics of the stent desired, endoscopic stent deployment is either through-the-scope (TTS), or wire guided. TTS stents are delivered through the endoscope channel and are routinely a 10 Fr system and require a therapeutic scope. Only uncovered self-expanding metal stents (SEMS) have a TTS characteristic. The remainder of stents all utilize wire guided systems and are placed under fluoroscopic guidance. Stent delivery systems are further categorized as proximal or distal deploying based on which end of the stent is opened first. In patients undergoing stent placement in the proximal esophagus, proximal deploying stents are preferred. Otherwise, most stent systems utilize a distal deployment pattern. Non-TTS stents are limited to the esophagus including the esophago-gastric junction. In patients following gastric resection, these systems can also traverse a gastrojejunal anastomosis. TTS systems, conversely, can reach any site in the gastrointestinal tract that can be accessed by a therapeutic endoscope.<sup>43</sup>



**Stent Characteristics.** Covered endoscopic stents have been created for the sole purpose of temporarily bridging esophageal and proximal anastomotic leaks and fistulae.<sup>45</sup> The fully covered nature of the stent impedes tissue ingrowth as would occur with an uncovered enteral stent, and thereby allows removal after 2–3 months once the fistula has been cured. With the increased frequency of bariatric procedures, anastomotic complications secondary to Roux-en-Y bypass are routinely managed with placement of endoscopic stents.

Removable stents are subdivided into plastic or hybrid based on the underlying structural platform. As stated above, fully covered silicone stents which are self-expandable but require the use of a large deployment system, can reach as far as the proximal stomach. Similarly, covered SEMT (hybrid) are also placed outside of the endoscope under fluoroscopic guidance, and can reach the proximal stomach as well. The greatest problem with these stents is the high risk of migration.<sup>45</sup> If placed across a gastrojejunostomy, this can result in small bowel impaction of a migrated stent, resulting in the need for surgical extirpation. Bleeding, perforation, and obstruction are far less common complications.

Uncovered enteral stents, utilizing TTS deployment systems, are not intended for removal and can be placed for temporary relief of benign and malignant strictures throughout the gastrointestinal tract.<sup>43,44,46–48</sup> They are associated with increased tissue ingrowth and occlusion as compared to covered stents, but have a lower rate of migration. In unresectable disease states, palliation of obstruction with enteral stents can provide an alternative to surgical bypass procedures. In addition, endoscopic stent placement in patients with obstructing colon lesions can allow for immediate decompression followed by semielective resection and primary anastomosis, rather than an initial diverting stoma.<sup>49,50</sup>

## Endoluminal Treatment of GERD

Numerous endoluminal treatments for gastroesophageal reflux disease (GERD) have been introduced over the past 10 years and have had varied clinical success. These technologies were based on either suturing, tissue bolstering, or energy delivery. Unfortunately, due to many factors including marginal patient improvement, limited physician acceptance, severe complications, and corporate financial difficulties, most of these treatments are not presently available in the United States. Examples of each of these modalities are described below.

### ENDOCINCH (BARD, BILLERICA, MA)

The EndoCinch plication device (CR Bard, Inc, Murray Hill, NY) creates an internal mucosa-to-mucosa plication of the stomach. Using a standard endoscope outfitted with the device at its tip, the tissue is drawn into the suturing chamber by suction, and two sutures are placed. The knots are formed extracorporally and advanced to the gastric mucosa. While

some of the short-term results were promising, the long-term results were bleak, confirming the lack of durability of a mucosa-to-mucosa apposition. This product is not presently being marketed for GERD treatment. Most authorities agree that technical refinements would be necessary before the EndoCinch can be effectively used for gastroplication.<sup>51,52</sup>

### STRETTA (CURON MEDICAL, SUNNYVALE CA)

This is the only device that involves delivery of radio frequency energy to the lower esophageal sphincter (LES) muscles. Multiple applications at several levels are required to complete the treatment. The procedure is performed blindly after endoscopically confirming the location of the LES. The intention is to induce collagen deposition to the LES, thereby adding more bulk and reducing the compliance of the LES. The effects are generally not immediate, but are realized over time. Despite modest success with this device, the company declared bankruptcy in 2007.<sup>53–57</sup>

### PLICATOR (NDO SURGICAL, MANSFIELD MA)

The NDO endoscopic plication system (NDO Surgical, Inc, Mansfield, MA) performed serosa-to-serosa apposition of the stomach just distal to the esophagogastric junction. The reusable device included a suturing mechanism at its tip and a channel for passage of a small bore endoscope for visualization. The single-use suturing implant used pretied polypropylene sutures with polytetrafluoroethylene bolsters. A proprietary retraction device selected the tissue for plication before deploying the sutures with a turn of the handle. Similar to Curon, this company also had significant financial difficulties and declared bankruptcy in 2008.<sup>58–61</sup>

### ENTERYX (BOSTON SCIENTIFIC CORP, NATICK, MA)

For augmentation of the LES, the Enteryx system used a bio-compatible, nonbiodegradable polymer. The solution contained a liquid polymer and radiopaque material to gauge the depth of injection. A circumferential injection of the polymer is performed, and its subsequent solidification tightens the esophagogastric junction. Multiple recent studies employing the Enteryx system have been published. Of note, Deviere and colleagues described the first sham-controlled trial with Enteryx in 2005.<sup>62</sup> Of the 64 patients, 83% reduced proton pump inhibitor (PPI) use by 50%, and 68% had discontinued PPIs. However, in the sham arm, 53% had halved their PPI use, and 40% discontinued PPIs. There was no objective improvement in pH values. Due to severe adverse events related to intra-aortic injections and subsequent fatal fistulization, the product was voluntarily discontinued by the company.<sup>62–68</sup>

### GATEKEEPER (MEDTRONIC, INC, MINNEAPOLIS, MN)

The Gatekeeper reflux repair system alters esophagogastric junction anatomy in order to restrict the aperture for reflux.

A saline lift is performed above the squamocolumnar junction, and a biocompatible cylindrical prosthetic composed of polyacrylonitrile hydrogel is placed in the submucosa. The prosthetic subsequently enlarges with hydration, thereby impeding gastroesophageal reflux. There were two significant complications and the manufacturer has since withdrawn the Gatekeeper system from the market.<sup>69,70</sup>

### ESOPHYX (ENDOGASTRIC SOLUTIONS, REDWOOD CITY, CA)

EsophyX is a novel endoluminal fundoplication technique using a trans-oral fastener-deploying device, attempting to mimic a Nissen fundoplication. In a feasibility study from Belgium, the results at 2 years supported long-term safety and durability with a sustained effect on the elimination of heartburn, esophagitis, hiatal hernia, and daily dependence on PPIs. At 2 years, no adverse events were reported, and a 50% or greater improvement in GERD-HRQL scores as compared with baseline on PPIs was sustained by 64% of patients. EsophyX was effective in eliminating heartburn in 93% of patients and daily PPI therapy in 71% of patients. Further clinical trials directly comparing this procedure to medical or surgical therapy are still necessary.<sup>53</sup>

## ENDOSCOPIC RETROGRADE CHOLANGIOPANCREATOGRAPHY

### History

William McKune, a surgeon, along with Paul Shorb, a gastroenterologist, were the first physicians to perform ERCP. In 1968, they reported on four cases of endoscopic identification and catheter placement into the ampulla of Vater. For the first time, imaging of the pancreatic ductal system could be seen and utilized for diagnostic purposes. Several years later in the mid-1970s, German and Japanese physicians described their experience in endoscopic sphincterotomy, the first therapeutic extension of ERCP. Other endoscopic adjuncts including stone lithotriptors, plastic and expandable metal stents, and intraductal imaging tools have fully changed ERCP from a diagnostic tool into one that is predominantly therapeutic.

### Indications

There are numerous indications for ERCP as listed in Table 3-2. ERCP, however, is preferentially used as a therapeutic tool due to the high risk of serious complications.<sup>71</sup> In patients where a diagnostic imaging of the pancreaticobiliary tree is desired, magnetic resonance cholangiopancreatography (MRCP) should be utilized.<sup>72</sup> Prior to cholecystectomy for symptomatic cholelithiasis, the presence of persistent jaundice or cholangitis is the indication for preoperative ERCP. Finally, as the number of



**TABLE 3-2: INDICATIONS FOR ENDOSCOPIC RETROGRADE CHOLANGIOPANCREATOGRAPHY**

1. Suspected choledocholithiasis
2. Identification and management of malignant or benign strictures
3. Investigation of abnormal radiographic imaging of the biliary tree
4. Persistent jaundice
5. Evaluation and treatment of sphincter of Oddi dysfunction (SOD)
6. Evaluation and treatment of pancreatic or biliary ductal injury/trauma or leaks
7. Treatment for identified ampullary adenoma
8. Recurrent or idiopathic pancreatitis
9. Treatment of complications of chronic pancreatitis including stones and/or strictures
10. Treatment for pancreatic fluid/cyst or pancreatic necrosis
11. Cytology of suspected pancreatic cancer and other pancreatic malignancies

patients undergoing bariatric procedures (Roux–en-Y gastric bypass) increases, access to the ampulla has become more challenging. Identification and access to the remnant stomach routinely require surgical or radiologic intervention for performance of ERCP.

### Patient Preparation

Patient preparation, sedation, and monitoring for ERCP are similar to those for other upper endoscopic procedures, although the patient is routinely placed in the prone position. Patients may require general anesthesia for airway protection, inability to tolerate conscious sedation, for expected lengthy or more complicated ERCP interventions, or in the presence of multiple comorbid diseases. ERCP can be performed in a supine position although this can make the procedure more challenging, as in patients undergoing ERCP at the time of laparoscopic cholecystectomy.

### Techniques of ERCP

ERCP is performed using a side-viewing scope and requires both endoscopic and fluoroscopic skills for interpretation and intervention. As stated above, ERCP is predominantly a therapeutic technique. The scope is initially passed into the esophagus blindly to a position beyond the upper esophageal sphincter and then rapidly advanced into the proximal stomach where any residual secretions should be aspirated. Unlike a forward-viewing endoscope, the pylorus cannot be visualized during intubation with a side-viewing scope.

Upward deflection of the side-viewing endoscope with continued advancement will allow easy passage into the duodenal bulb.

To manipulate around the superior duodenal angle, the endoscope is turned to the right, and the tip is deflected upward to reach the second portion of the duodenum. The endoscope is then withdrawn during this maneuver, leaving the scope in the ideal “short-scope” position.

With the “short-scope” position, the endoscopist views the papilla directly along the medial duodenal wall. Very minute movements of the tip and further withdrawal of the scope will bring the papilla into view. Intermittent doses of glucagon can be given to minimize duodenal peristaltic contractions. Dosing with glucagon, however, can lead to increased postprocedure nausea and vomiting. Fluoroscopy can also be used to determine appropriate scope position and to help identify the site of the major papilla. After the papilla is visualized, it is then cannulated using one of the various types of catheters available. As the majority of ERCP cases are potentially of a therapeutic nature, most endoscopists will start with a pull wire sphincterotome. Guide wire–assisted cannulation has also become a popular practice for several reasons. First, it may minimize the overall volume of contrast required, thereby hopefully decreasing the rates of pancreatitis and cholangitis. Second, it may increase the efficiency of selectively cannulating the desired duct. Finally, it can help maintain access into the duct during catheter exchanges.

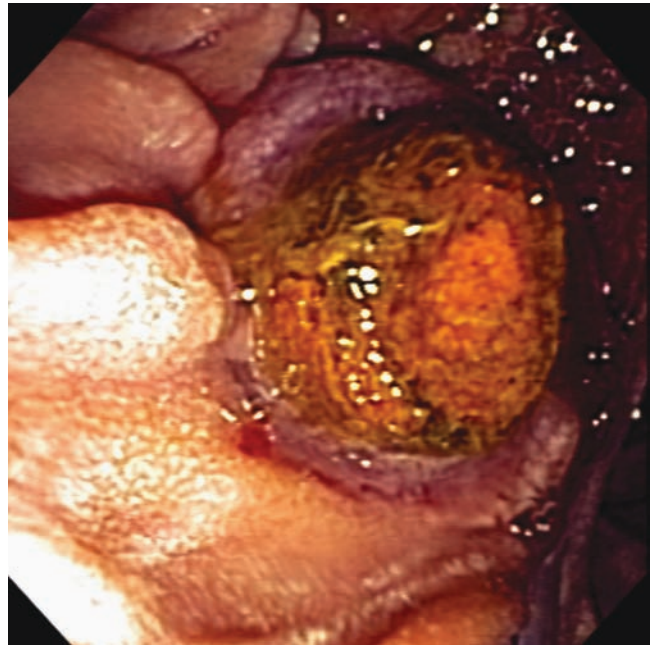Selective cannulation of the biliary and pancreatic ducts depends on the angle of the catheter and the position of the scope tip. The pancreatic duct tends to enter the papilla in a relatively perpendicular fashion at the 1-o’clock position. In contrast, the bile duct runs toward 11 o’clock below the “lip” of the papilla.

ERCP represents an endoscopic and radiographic intervention, and proper radiologic technique is critical to obtaining interpretable radiographs. Artifacts such as air bubbles, streaming and layering of contrast, and contrast spillage into the duodenum should be recognized and avoided.

## ERCP Therapeutic Interventions

### SPHINCTEROTOMY

There are two types of sphincterotomy that can be performed, needle knife sphincterotomy (precut sphincterotomy) or pull wire sphincterotomy. Needle knife sphincterotomy is performed when deep selective cannulation is unable to be obtained, and can be done over a previously placed stent or guide wire, or when an impacted common bile duct (CBD) stone is protruding through the ampulla (Fig. 3-16). This technique is more technically challenging and also has a higher risk of bleeding, pancreatitis, and perforation. Pull wire sphincterotomy, conversely, requires deep selective cannulation with or without previous wire placement.



**FIGURE 3-16** An impacted common bile duct stone seen extruding through the ampulla. This is best treated by needle knife sphincterotomy to allow release of the stone.

Once proper selective ductal cannulation is verified, the sphincterotome is withdrawn until approximately half of the wire is visible outside of the papilla (Figs. 3-17 and 3-18). Biliary or pancreatic sphincterotomy can be done as needed. Indications for sphincterotomy include treatment of sphincter of Oddi dysfunction (SOD), improved access for stone removal or stent placement, and recurrent pancreatitis. To perform sphincterotomy, the pull-wire is tightened, bowing it against the papillary roof. Current is then applied while maintaining gentle upward force on the wire and gently lifting the sphincterotome, making the incision in small increments.

### MANAGEMENT OF CHOLEDOCHOLITHIASIS

Retained or recurrent CBD stones represent the most common indication for endoscopic sphincterotomy, and ERCP with sphincterotomy successfully treats 95% of these cases.<sup>73</sup> In expert hands, over 90% of bile ducts can be successfully cleared of calculi with balloon catheters or Dormia baskets, resulting in an overall ductal clearance rate approximating 85% (Figs. 3-19 and 3-20). Stone size is often a limiting factor, as stones greater than 2 cm in diameter often require fragmentation prior to removal. The other reasons for unsuccessful ERCP include patient intolerance, inability to identify or access the papilla, and inability to selectively cannulate the desired duct.

Routine preoperative ERCP and sphincterotomy are not warranted in patients undergoing biliary operations for



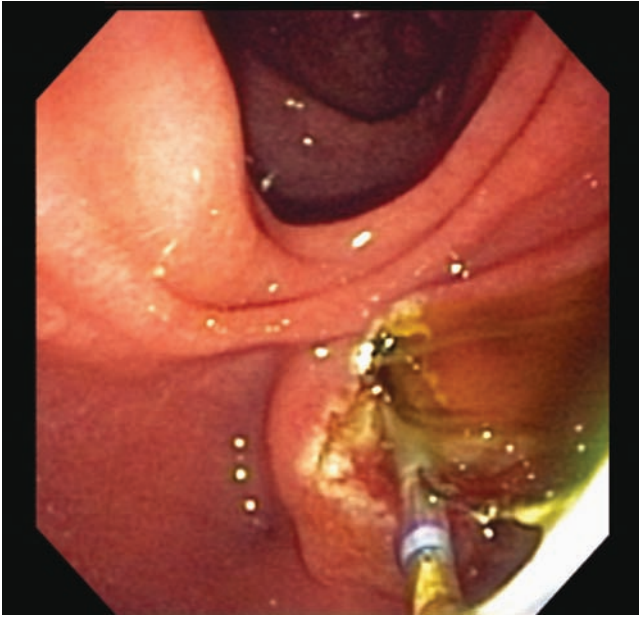

FIGURE 3-17 Following deep selective cannulation of the bile duct, a sphincterotomy is performed with a pull-wire sphincterotome.

symptomatic cholelithiasis.<sup>73</sup> Unfortunately, determining the presence of CBD stones is challenging, as ultrasound findings of biliary dilation, elevation of liver function tests (LFTs), and clinical factors such as pancreatitis are not always predictive of CBD stones. Only the actual radiographic finding of choledocholithiasis is statistically associated with the actual presence of CBD stones. As stated above, ERCP should rarely be utilized as a diagnostic procedure.<sup>74</sup>

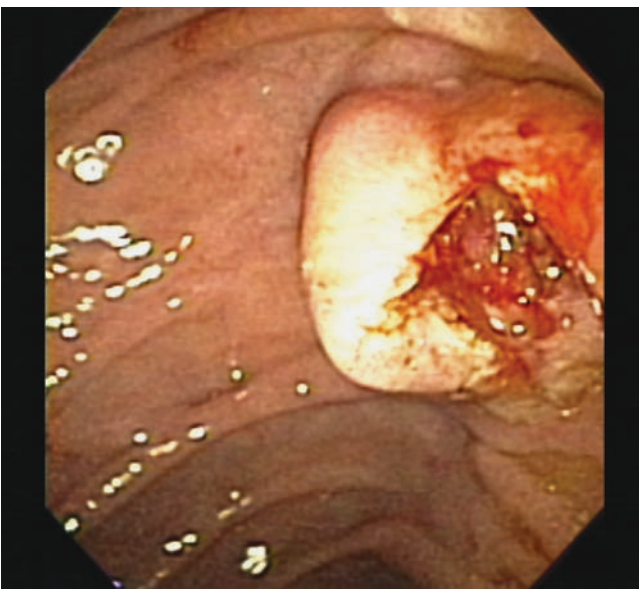

FIGURE 3-18 Postsphincterotomy image of the major papilla.

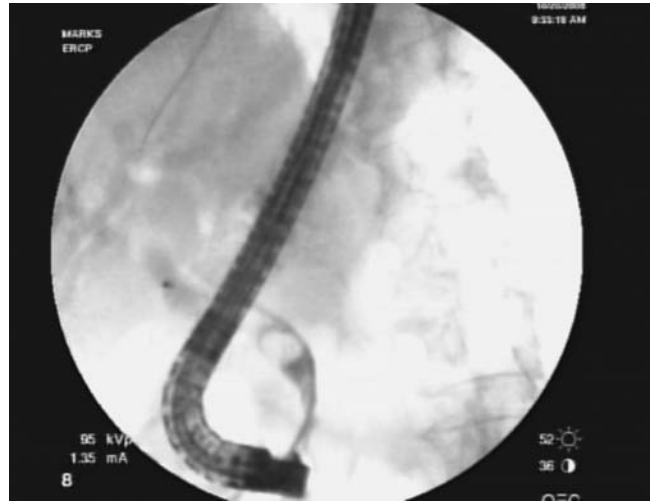

FIGURE 3-19 ERCP radiographic image of a distal common bile duct stone.

#### MANAGEMENT OF SOD

SOD represents a broad range of symptoms including pain, biliary colic, altered liver function tests, ductal dilation with delayed drainage, and elevated sphincteric pressures. Based on the number of associated symptoms, the response to endoscopic sphincterotomy can be predicted. This disease also has a close association with gallbladder dyskinesia, and may represent a parallel process in that many patients

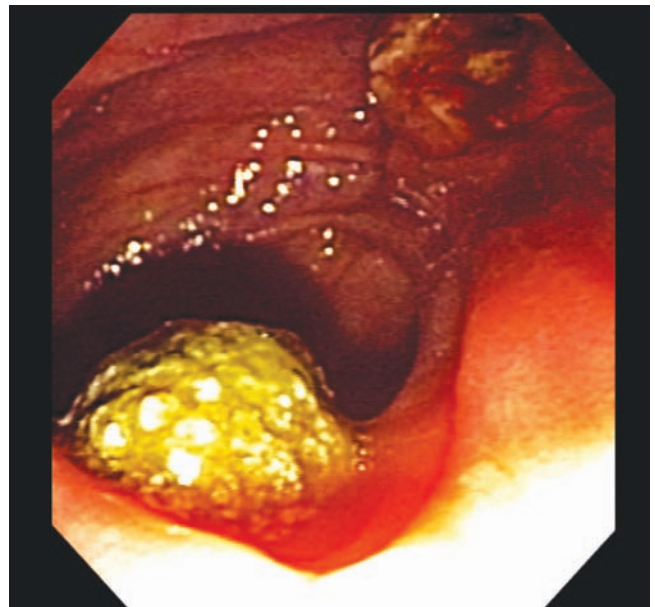


FIGURE 3-20 Following sphincterotomy (seen in the upper right-hand portion of the image) and balloon sweeping, the extracted common bile duct stone is seen in the duodenum.

following cholecystectomy for gallbladder dyskinesia will eventually be suspected of also having SOD. While multiple noninvasive tests have been evaluated in this disorder (eg, ultrasonography and scintigraphy), they all appear to lack adequate sensitivity or specificity. The development of endoscopic manometric techniques now allows direct measurement of motility and intraluminal pressures within both the biliary and pancreatic segments of the sphincter of Oddi.<sup>75,76</sup>

The common thread in patients with this disorder is elevated basal sphincter pressure. Criteria for abnormal manometry include basal pressure >40 mm Hg, peak sphincter pressure >240 mm Hg, >50% retrograde contractions, no relaxation with cholecystokinin administration, and contraction waves >8 per minute. Sphincter of Oddi manometry is technically challenging to perform and carries a high rate of post-ERCP pancreatitis. In addition, any ERCP intervention on patients with suspected SOD is associated with higher rates of postprocedural pancreatitis.<sup>75</sup>

### MANAGEMENT OF ACUTE CHOLANGITIS

Endoscopic biliary drainage has now been clearly shown to be the procedure of choice for patients with acute suppurative cholangitis. In critically ill patients, simple endoscopic stenting or nasobiliary drainage, with or without sphincterotomy, should be performed. Complete clearance of the duct is not necessary as long as drainage had been achieved. Stone extraction can be performed after the patient has stabilized, at the time of stent removal 4–6 weeks later.

### MANAGEMENT OF ACUTE GALLSTONE PANCREATITIS

Patients with biliary pancreatitis can typically be managed conservatively, saving ERCP for those patients with worsening pancreatitis or concomitant evidence of biliary obstruction secondary to choledocholithiasis.<sup>77</sup> In these cases, early ERCP and sphincterotomy can significantly reduce morbidity and mortality.<sup>77,78</sup> The majority of patients who develop gallstone pancreatitis will have spontaneous passage of the CBD stone without intervention. Laparoscopic cholecystectomy should then be performed in the near future to prevent recurrence. Conversely, patients who are not an operative candidate, ERCP and sphincterotomy are effective in minimizing the risks of pancreatitis, but obviously will have no effect on the development of gallbladder complications related to the cholecystolithiasis.

### ENDOPROSTHESIS INSERTION

Currently available endoprostheses or stents vary in their composition, shape, size, length, deployment system, and method of anchorage. The indications for stent insertion include cholangitis, benign/malignant biliary or pancreatic duct stricture, biliary or pancreatic duct leak, retained/unremovable CBD stones, and prophylactic pancreatic duct

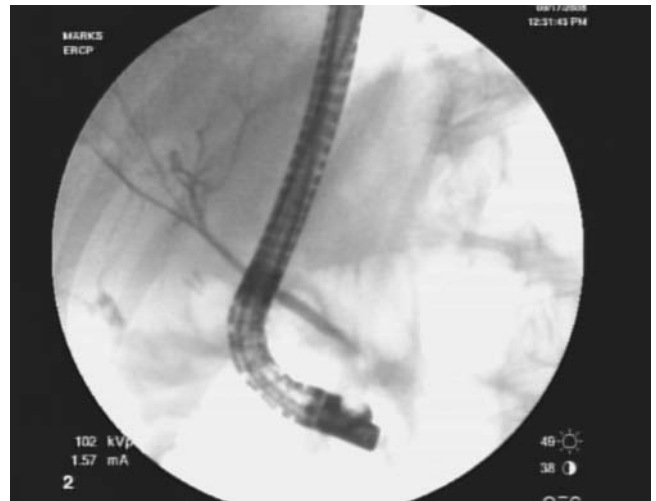

FIGURE 3-21 ERCP revealing extravasation of contrast from an accessory duct leak.

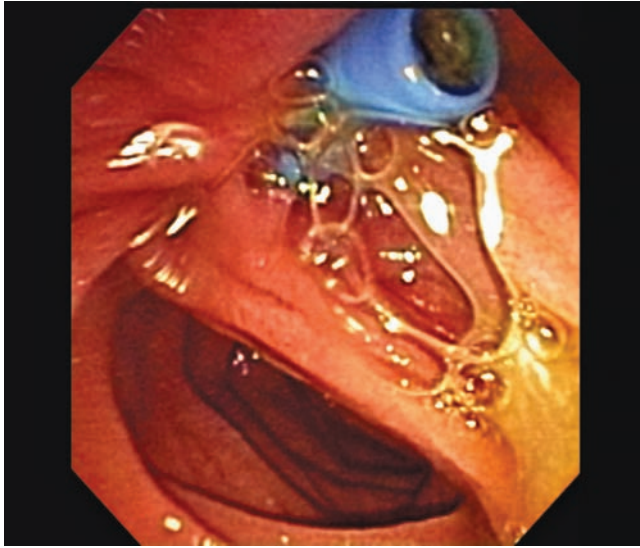
stent placement for pancreatitis protection.<sup>79–82</sup> In patients with biliary fistulae, the goal of the stent is to equilibrate the biliary and duodenal pressures to facilitate closure of the leak (Figs. 3-21 to 3-23).

Initially, a diagnostic cholangiogram or pancreatogram is obtained to identify the lesion's extent and to determine the length of endoprosthesis required, and a guide wire is maintained. If desired, a sphincterotomy can then be performed to facilitate subsequent manipulations, although stent placement can be performed without this maneuver. Ideally, the endoprosthesis will be located with its upper flap above the stricture and its lower flap just outside the papilla, although suprapapillary placement of metal stents is routinely

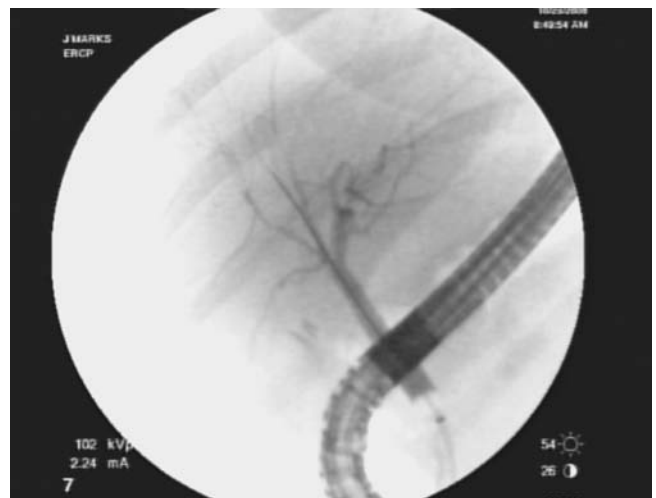

FIGURE 3-22 Following a 6-week course of biliary stenting, the leak has resolved.





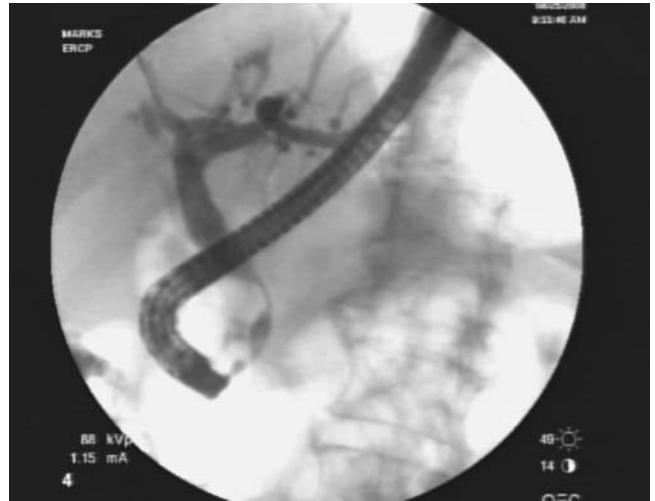**FIGURE 3-23** Transpapillary biliary stent placement for treatment of the biliary leak.

performed for more proximal malignant strictures. Transpapillary position of plastic stents serves a function to ease removal as well as equilibrating biliary and duodenal pressures in cases of bile duct leaks.

All biliary and pancreatic stents are placed using TTS deployment systems. The diameters of these delivery systems vary based on the type of stent and the actual diameter of the stent. Straight biliary and pancreatic plastic stents come in 3, 4, 5, 7, 10, and 11.5 Fr diameters. For SEMT, a special delivery system is used to insert the stent in a collapsed state (10 Fr diameter). After release, there is shortening of the SEMS as the stent expands to its full diameter (8–10 mm).<sup>80,81</sup>

Straight plastic biliary stents are temporary and must be changed every 3–6 months.<sup>79</sup> Obstructive jaundice and cholangitis are common sequelae of occluded stents. Placing multiple stents may increase the length of overall patency, as bile can traverse around and between the stents even if the stent lumen becomes obstructed. SEMS carry a longer patency rate of 9–12 months as compared to plastic stents.<sup>80,81</sup> Uncovered metal stents are less likely to migrate as compared to covered ones, but have a shorter patency rate due to the allowance for ingrowth of tissue or tumor. Newer fully covered self-expanding metal biliary stents also allow for delayed removal, and can therefore be used in the management of chronic benign strictures.

Patients undergoing endoscopic palliation for obstructive jaundice secondary to malignancy who are not operative candidates may be better served with SEMS rather than plastic stents due to the decreased need for repeat endoscopic intervention in patients with a limited life expectancy.<sup>80</sup> If patients have both a biliary and duodenal obstruction secondary to malignancy, it is important to place the biliary SEMS prior to the duodenal stent as access to the papilla becomes very



**FIGURE 3-24** Distal common bile duct stricture secondary to a pancreatic head malignancy.

challenging.<sup>44</sup> Palliation of unresectable malignant biliary obstruction in elderly high-risk patients appears to be one of the most significant indications for biliary endoprostheses (Fig. 3-24).

In addition to biliary disorders, ERCP has been employed in the management of benign and malignant pancreatic disorders. Pancreatic duct stenting can be used successfully to decompress the ductal system, to bypass ductal leaks and strictures, and to treat pancreatic fistulas. Patients with pancreatic divisum may be treated with minor papilla stenting or sphincterotomy. Pancreatic stents are smaller than biliary stents and they contain side holes for drainage. Pancreatic duct stents also can be placed in patients with high risk for post-ERCP pancreatitis including SOD, idiopathic/autoimmune pancreatitis, and those having had a complex ERCP with extensive pancreatic or bile duct manipulations (Figs. 3-25 and 3-26).<sup>75</sup> Pancreatic duct stents should be endoscopically removed within 2–3 weeks due to the risk of ductal inflammatory changes, whereas biliary stents can be used indefinitely and changed when there is evidence of obstruction. On many occasions, the pancreatic stents will pass spontaneously.

## PANCREATIC DUCT STONES

ERCP for pancreatic ductal stone extraction is technically more challenging and is associated with a higher risk of complications such as pancreatitis. Some clinicians have reported success with the use of mechanical lithotripsy, contact lithotripsy, and/or extracorporeal shock wave lithotripsy to manage pancreaticolithiasis.<sup>83</sup> Pancreatic duct stones routinely are harder than biliary cholesterol-based stones and these patients may eventually require surgical intervention.

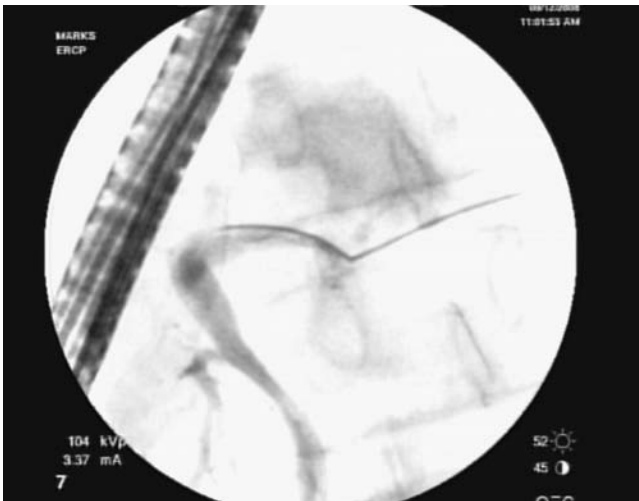


FIGURE 3-25 Radiographic image of a pancreatic duct wire prior to stent placement.

### ENDOSCOPIC PSEUDOCYST DRAINAGE/ NECROSECTOMY

The management of pancreatic pseudocysts and necrotic debris is one of the more recent advances in the therapeutic armamentarium of the endoscopist. Pancreatic pseudocysts can be approached in a transpapillary or a transvisceral fashion based on the location and nature of the pseudocyst. Many pseudocysts have direct connection to the main pancreatic duct, and are referred to as “communicating” pseudocysts.

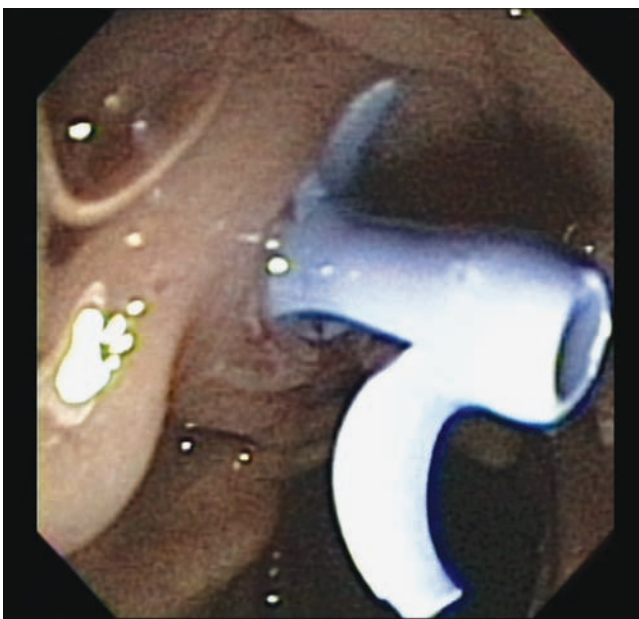


FIGURE 3-26 Temporary plastic 5 Fr pancreatic stent in place.

If wire access can be obtained via the pancreatic duct into the cyst cavity, a pancreatic stent can be placed to allow for drainage of the cystic cavity. Although this may result in initial resolution of the cyst, a high recurrence rate exists due to the continued communication to the ductal system. After drainage, subsequent stenting of the pancreatic duct across the site of leakage may be required.

Pancreatic pseudocysts directly adjacent to an endoscopically approachable lumen (ie, stomach, duodenum) may be amenable to a transvisceral approach.<sup>84–87</sup> Assuring maturity of the cyst, absence of concern for neoplasm, and no evidence of actual infection are important factors to determine prior to endoscopic drainage. The use of EUS is an invaluable adjunct to this procedure for several reasons.<sup>85,87</sup> It can rule out intervening organs or vasculature, determine if there is extensive debris rather than simple fluid collections, and assure proximity of the cyst to the selected viscus. EUS aspiration followed by guide wire placement is followed by tract dilation and eventual pigtail stent placement. Stents are removed in 6–12 weeks after confirming resolution of the pseudocyst.

Patients with pancreatic necrosis rather than simple pseudocyst formation have also been approached endoscopically.<sup>88–92</sup> Similar to transvisceral cyst drainage, EUS guidance is used to confirm the presence of a collection of debris, and following tract dilation, the endoscope is advanced directly into the adjacent cavity. Tissue is then removed using a combination of irrigation/suction and snare/basket tissue debridement. Stents are placed to maintain the tract to allow for serial debridement of the necrotic tissue.

## Complications of ERCP

### POST-ERCP PANCREATITIS

The occurrence of ERCP-induced pancreatitis is associated with both procedural factors and patient factors. Although the precise factor leading to postprocedural pancreatitis has yet to be elucidated, many factors including complex interventions including manometry, multiple pancreatic cannulations or injections, excess delivery of thermal energy, and placement of covered SEMs have all been implicated. Prophylaxes with antibiotics, steroids, somatostatin, xanthine oxidase inhibitors, and immunologic agents such as IL-1 have been investigated in multiple prospective comparative trials without success in reduction of pancreatitis.<sup>74,93</sup> Patient factors associated with pancreatitis include SOD, idiopathic pancreatitis, and the prior history of acute or chronic pancreatitis.<sup>93</sup> The use of short-term prophylactic pancreatic stent placement may eventually be proven beneficial in patients following higher risk procedures, or who have comorbid disease states increasing their risk for post-ERCP pancreatitis.<sup>75</sup>

Bacteremia or sepsis following ERCP, similar to pancreatitis, is secondary to procedural factors as well as underlying patient factors.<sup>93</sup> Patients undergoing ERCP for obstructive

jaundice or cholangitis have a high risk of sepsis if adequate drainage is not obtained. In addition, despite the use of sterile contrast agents, ERCP is a contaminated procedure related to the introduction of duodenal contents and bacteria into the biliary tree during cannulation. If contrast is injected above a stricture that cannot be adequately drained, the development of cholangitis uniformly occurs. One method for preventing this is to attempt wire advancement across a stricture first before performing a cholangiogram. In complex strictures, this can be challenging, but it avoids contamination in cases where the stricture cannot be traversed. The performance of biliary dilation also carries a very high risk of bacteremia and prophylactic antibiotics are recommended. Finally, high pressure or high volume injections can also lead to cholangiovenous translocation of bacteria.

Bleeding following endoscopic sphincterotomy occurs in approximately 1% of all cases, and can occur immediately or up to 2 weeks postprocedure. Hemorrhage should be initially managed by repeat endoscopic intervention. Injection sclerotherapy, balloon tamponade, and endoscopic clip placement are the most common and effective ways to manage this complication.<sup>94</sup> If unsuccessful, angiographic embolization should be utilized before proceeding to surgical intervention.

Perforation is the least common complication and may occur secondary to the ERCP intervention (wire placement, cannulation, sphincterotomy) or the actual advancement of the endoscope. Endoscope-induced perforations can occur at the level of the cervical esophagus due to the blind nature of the initial passage of the side-viewing endoscope, or in the duodenum, usually on the lateral aspect opposite the papilla. Proximal esophageal perforations usually can be managed with antibiotics, NPO status, and cervical drainage as needed. Duodenal perforations secondary to the endoscope may result in a large rent of the lateral wall and may require more aggressive therapy including surgical drainage, or in more serious situations, duodenal diversion techniques.

Perforations secondary to ERCP manipulations may occur in the periampullary duodenum or in the biliary tree. Perforations of the bile duct secondary to guide wires or catheter systems are rare but can result in bile peritonitis. Small perforations and leaks in patients without clinical deterioration can usually be managed with transpapillary stent placement and image-guided peritoneal drain placement as needed. CT scans are vital in the management of these patients.<sup>95</sup> Microperforation of the duodenum can lead to extensive retroperitoneal, intraperitoneal, mediastinal, and subcutaneous air, which appears very concerning, but as long as the patients are clinically stable, this situation can routinely be managed conservatively with antibiotics, NPO status, and close observation. Conversely, patients identified to have retroperitoneal or intraperitoneal fluid collections will most likely require aggressive drainage via either surgical or image-guided techniques. Emergent resective therapy (pancreaticoduodenectomy) should be avoided in these situations.

## SMALL BOWEL ENTEROSCOPY

The small bowel up until recently had been an elusive part of the gastrointestinal tract in terms of diagnostic and therapeutic endoscopic intervention. The advent of capsule endoscopy has permitted the endoscopist to obtain recorded images of the lumen of the small bowel for identification of obscure sites of bleeding, inflammatory changes, and neoplasia. Unlike contrast studies such as enteroclysis, capsule endoscopy simulated the visual advantages of flexible endoscopy, and with the time recording and navigation system, was able to approximate the actual site of the identified disease. Unfortunately, there was no potential for tissue sampling or providing therapy. This deficiency has now been addressed with the progression of deep bowel enteroscopy.

Previous endoscopic approaches to evaluate the small bowel included Sonde enteroscopy and push enteroscopy. Both of these were very challenging, time consuming, often unsuccessful, and provided limited alternatives for therapy. Intraoperative enteroscopy, either transoral or transanal, allowed for the manual pleating of the small bowel on the enteroscope, but was also very challenging.<sup>96</sup> Therapy would be provided surgically after the offending site was identified endoscopically. Intraoperative endoscopic evaluation of the small bowel can also be performed via an enterotomy in the midportion of the bowel allowing the endoscope to be advanced both proximally and distally. One of the undesired consequences of intraoperative endoscopy is massive bowel distention. The use of CO<sub>2</sub> insufflation rather than air insufflation has been shown to minimize the overall distention and length of time for resolution of this problem. Many endoscopists are looking to use CO<sub>2</sub> for all endoscopic interventions, especially those that are expected to be of longer duration.

Over the past 10 years, several new endoscopic systems have been developed and utilized for the evaluation and treatment of small bowel disease. Double balloon endoscopy (DBE) and single balloon endoscopy (SBE) have allowed the endoscopist to fully evaluate the small bowel, obtain tissue samples, and provide therapy for processes such as bleeding, obstruction, and occult neoplasia.<sup>97–105</sup> In addition, patients following surgical resection and reconstruction (ie, Roux-en-Y bypass, long afferent limb), balloon enteroscopy can allow access into the desired segment of the small bowel.<sup>102</sup>

Both systems utilize the principle of scope fixation with a soft balloon that is serially inflated and deflated as the scope is advanced. This permits the endoscopist to pleat the bowel over the endoscope. This is performed both antegrade and retrograde to visualize the entire mucosal surface of the small bowel, and can also be used for evaluation of the entire colon following unsuccessful standard colonoscopy.<sup>104</sup> Unique overtubes are also available for deep bowel enteroscopy, and are used in conjunction with the endoscopes.<sup>101,103</sup> As these techniques can be somewhat time consuming (1–4 hours), it is not uncommon to perform these under general anesthesia. The use of fluoroscopy is also helpful in guiding the endoscopist through the small bowel.



## LOWER GASTROINTESTINAL ENDOSCOPY

The field of therapeutic lower endoscopy originated in 1975 when Shinya and Wolff reported the first series of colonoscopic polypectomies.<sup>106</sup> This groundbreaking report transformed colonoscopy from a purely diagnostic tool into an interventional modality. Since then, therapeutic colonoscopy has expanded to include resection of large neoplastic lesions, stenting for management of leaks, strictures, fistulae and obstructions, and bleeding. Advances in instrumentation and technique will continue to broaden the applications of interventional colonoscopy, possibly even using the colon as a portal to the peritoneal cavity.

### Indications

Screening colonoscopy has become the standard of care for evaluation of average risk patients over the age of 50.<sup>107–110</sup> Prior screening tools such as fecal occult blood testing, sigmoidoscopy, and digital rectal exams no longer are considered as effective screening tools.<sup>111</sup> CT colonography, however, has gained some support due to improved abilities to identify colonic neoplasia; however, smaller lesions are still somewhat a challenge for this imaging tool. The indications for colonoscopy are listed in Table 3-3.

### Contraindications

The contraindications for colonoscopy are in part similar to those for EGD, and are related to the patient's associated

comorbidities, underlying gastrointestinal disorders, or patient's inability to tolerate conscious sedation. As with EGD, recent myocardial infarction, pneumonia, and recent foregut surgical procedure are relative contraindications for colonoscopy, and the risks and benefits need to be weighed on an independent basis for each patient to determine appropriateness. A recent surgical anastomosis is most likely safe at any time during the postoperative period to be evaluated endoscopically, remembering that tissue strength will be weakest on postoperative day's five to seven.

Coagulopathy secondary to thrombocytopenia, liver failure, renal failure, or exogenous use of anticoagulants and platelet-inhibiting agents is a relative contraindication for a diagnostic colonoscopy, but an absolute contraindication for a therapeutic intervention. Patient noncooperation or an inability for a patient to be safely sedated due to high cardiopulmonary risk is also contraindication to colonoscopy. Respiratory depression secondary to medications as well as inability to maintain an airway can occur in these high-risk patients even though there is no transorally placed scope. Preassessment with ASA classification and Malampatti scores will help predict this high-risk group.<sup>16</sup> Patients with suspected perforation, ischemic colitis, acute diverticulitis, or toxic megacolon should not undergo colonoscopy unless there are plans to provide immediate therapy such as endoscopic closure or stent placement, or surgical intervention.

### Patient Preparation

Most endoscopic evaluations of the lower gastrointestinal tract can be done under conscious sedation on an outpatient basis. Unsedated colonoscopy can be performed safely but requires a compliant, nonanxious patient, who understands that prior abdominal surgery as well as female gender increases the need for conversion to sedated endoscopy.

The day before the examination the patient should begin a light diet with only clear liquids at lunch. The most common bowel preparation for colonoscopy utilizes a sodium sulfate–based electrolyte solution containing polyethylene glycol as an osmotic agent (eg, GoLYTELY). Alternative regimens including magnesium citrate and multiple enema solutions have also been described. In addition to different agents for prep, endoscopists have also utilized varied timing for preps with the use of split doses, with the final dose being given four hours before the scheduled procedure. Fleet Phospho-soda, a small volume prep, is no longer an alternative due to the rare occurrence of cardiac complications.

Prophylactic antibiotics are usually not required for colonoscopy. Although diagnostic procedures can be performed in patients on anticoagulative therapy, these medications should be withdrawn if polypectomy or other therapeutic procedures are expected to be performed. Aspirin therapy, unlike other anticoagulative medications, probably does not alter the risk of postpolypectomy bleeding.

 **TABLE 3-3: INDICATIONS FOR COLONOSCOPY**

#### Diagnostic

1. Evaluate and confirm radiographic findings
2. Identify suspected polyps
3. Unexplained GI bleeding or iron deficiency anemia
4. Colon cancer screening and surveillance
5. Follow-up after intervention for polyp or cancer
6. Surveillance of inflammatory bowel disease
7. Significant unexplained diarrhea
8. Preoperative/intraoperative localization of lesions

#### Therapeutic

1. Control bleeding
2. Polypectomy
3. Remove foreign body
4. Reduce sigmoid volvulus
5. Decompress pseudo-obstruction (Ogilvie's)
6. Dilate or stent strictures/stenoses (malignant and benign)

Adapted, with permission, from the Society of American Gastrointestinal and Endoscopic Surgeons guidelines, [www.colonoscopy.info](http://www.colonoscopy.info), 2002; and the American Society of Colon and Rectal Surgeons parameters, 2004.

## Basic Endoscopic Techniques— Colonoscopy

When performing colonoscopy, there are several universal principles to the technique similar to upper endoscopy, but there are also several specific caveats to assure performance of a safe procedure. Due to the tortuosity of the colon and the lack of fixation, manipulations such as scope torquing, loop reduction, patient position changes, and abdominal wall manual pressure are vital to the performance of colonoscopy. One other difference from upper endoscopy is the lack of reliability of correlation of shaft length inserted and actual anatomic position in the colon. Therefore, understanding specific colonoscopic landmarks is very important to interpreting actual lower gastrointestinal anatomy. In addition, surgical alterations to the anatomy must be recognizable (Fig. 3-27).

A digital rectal examination should always be performed prior to initiating the colonoscopic exam. This provides lubrication of the anal canal, relaxes the anal sphincters, provides evaluation of the prostate and lower rectal vault, and assesses the patient's level of sedation. The endoscope is introduced either by direct straight insertion or by rubbing the tip of the endoscope along the perineal body with the right index finger. Once reaching the anal verge, the tip of the endoscope is directed into the anal canal.

Once in the rectal vault, insufflation is initiated to allow view of the lumen. Although mucosal inspection occurs during advancement, principal evaluation for pathology occurs on scope withdrawal after the cecum is reached. Gentle advancement of the colonoscope is now performed. If the lumen is lost to view, termed a "red out," the scope is slightly pulled back and the wheels deflected in combination with scope torque to reestablish the lumen. Passage of the scope

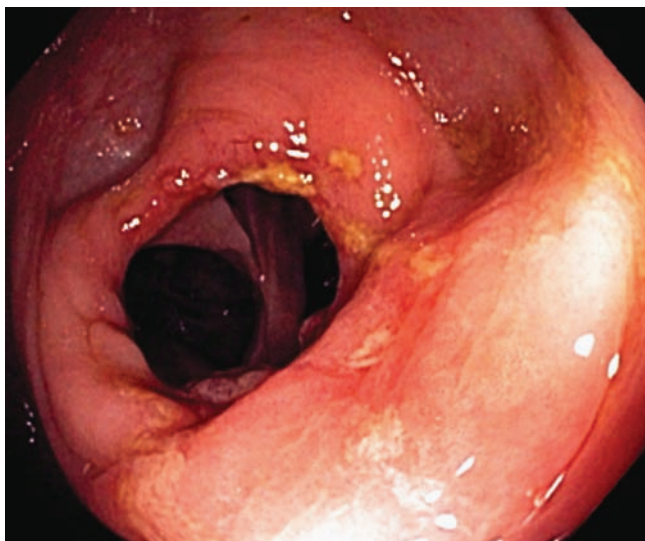


FIGURE 3-27 An EEA stapled anastomosis at the rectosigmoid level is seen in this image.

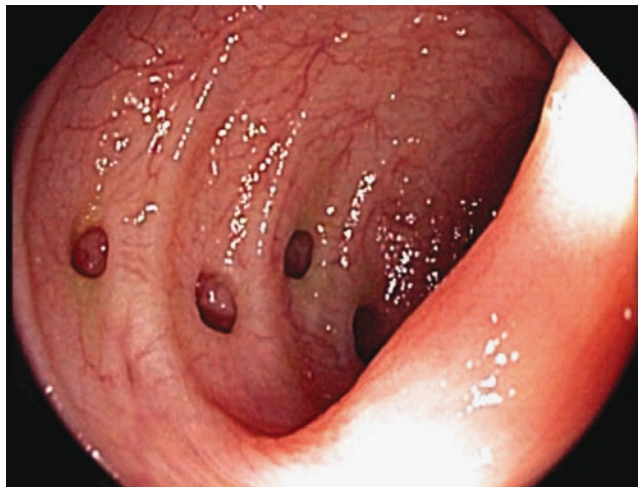

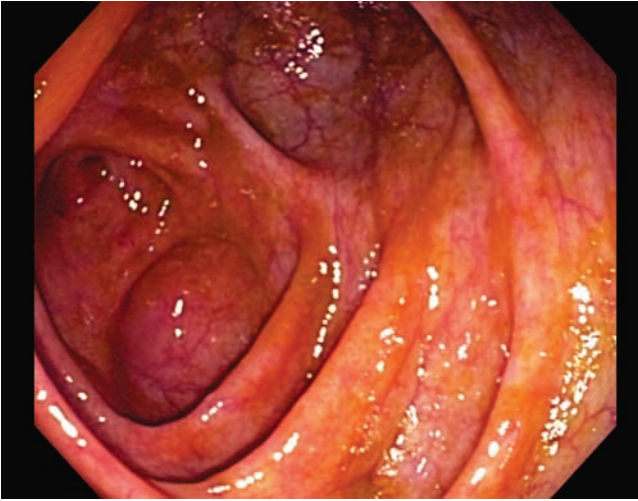FIGURE 3-28 Multiple diverticuli seen in the sigmoid colon.

into the sigmoid colon can be challenging in patients with prior abdominal surgery, morbid obesity and a large pannus, or multiple diverticuli (Fig. 3-28). Abdominal compression and patient position change to supine may assist in this maneuver. Rarely, a "slide-by" maneuver is required to overcome the tight angulation in and out of the sigmoid colon. This technique entails careful insertion without complete luminal view but with appearance of the mucosa sliding by the scope. During all portions of the colonoscopy, however, increased patient discomfort, "redded out view," and excessive scope resistance with advancement are markers to the endoscopist to pull back one's colonoscope.

Exiting the sigmoid colon may require building up a "loop." This may lead to increased patient discomfort and may require additional medication. Once access into the descending colon is achieved, the loop is reduced by gentle withdrawal and slight torquing of the scope. Adding variable stiffness to the scope, if available, will now allow advancement in a one-to-one fashion, to the splenic flexure. "One-to-one" refers to equal scope tip advancement with scope insertion. The descending colon is usually quite straight, and the splenic flexure is identified by the extraluminal blue hue as well as the tight turn encountered as one enters into the distal transverse colon. Suctioning and scope withdrawal will assist in maintaining positioning beyond the splenic flexure.

Introduction of the scope, again with the addition of variable stiffness, should allow one-to-one progress through the transverse colon, which is easily identified by the triangular configuration. As one proceeds toward the hepatic flexure, the blue hue of the liver becomes apparent. At this time, paradoxical motion routinely will occur with scope introduction. Access into the ascending colon usually requires the endoscopist to make a sharp deflection at the hepatic flexure followed by withdrawal of the scope and simultaneous suctioning. The ascending colon may have a yellow discoloration due to the continued passage of succus entericus despite a complete bowel preparation. Asking the patient to take a deep breath

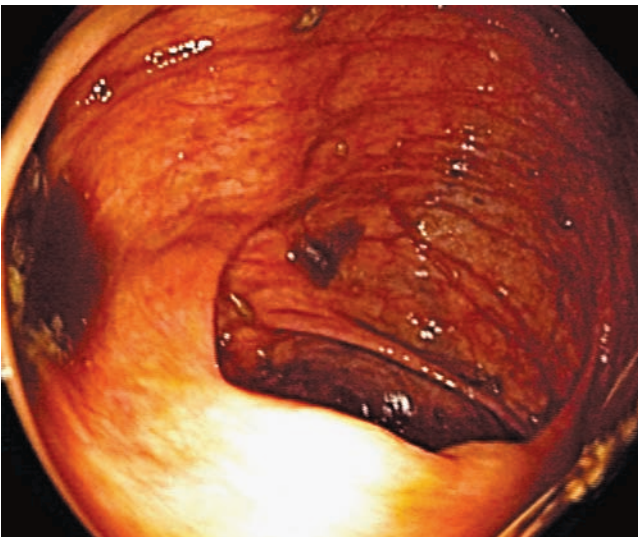




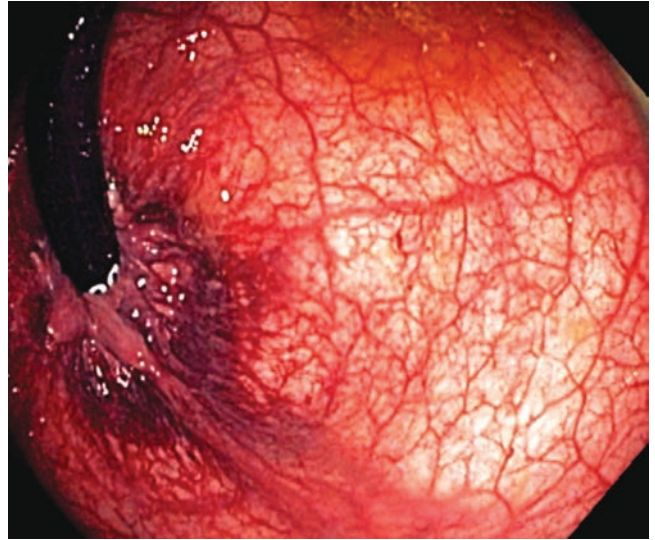
**FIGURE 3-29** The cecum is seen here, identified by the ileocecal valve, appendiceal orifice, and classic cecal strap.

as well as placing them in supine position may assist in this maneuver. Eventually, the cecum is identified by the ileocecal valve, appendiceal orifice, cecal strap, abdominal wall translumination, and right lower quadrant palpation (Figs. 3-29 and 3-30). Intubation of the ileum, however, is the only way to confirm 100% that you have actually reached the cecum. The terminal ileum can be intubated by deflecting the tip toward the ileocecal valve, gently withdrawing the scope, and prying open the upper lip of the valve. Throughout this maneuver, air insufflation is used. The scope is then slowly advanced into the terminal ileum.

The goal of the endoscopist is to reliably and safely gain access into the cecum, confirming one's position, and then



**FIGURE 3-30** Classic lipomatous appearance of the ileocecal valve helps differentiate it from other colonic folds.



**FIGURE 3-31** Retroflexed view in the rectal vault identifying the dentate line and excluding any anorectal disease not able to be seen on anteflex view.

performing a slow careful withdrawal evaluating the entire mucosal surface. Areas of excess stool must be flushed clear and extra care must be taken at the flexures and around larger folds to investigate for underlying disease. Retroflexion of the endoscope, which had been utilized for evaluation of the rectal vault, is now being performed with some regularity, in the cecum and flexures, as well as to see behind larger folds. Manipulation by patient position change, as with upper endoscopy, may aid in visualization of areas with excess stool. Retroflexion in the rectum can be done at the beginning or at the end of the procedure (Fig. 3-31). The colonoscope is withdrawn into the anal canal and then carefully advanced for several centimeters. Full upward deflection along with clockwise torquing and gentle advancement will result in the scope looking back toward the distal rectum and dentate line.

## Complications

Complications specifically related to colonoscopy include hemorrhage and perforation. The former is most unusual following diagnostic colonoscopy, occurring in 0–0.07% of cases. Hemorrhage in this setting is usually intra-abdominal such as following injury to the colon mesentery or to the capsule of the spleen, resulting from the use of excessive force during manipulation. Hemorrhage is seen more often following polypectomy (1–3%).<sup>112</sup> Postpolypectomy bleeding can be immediate or delayed, and can occur up to 2 weeks after the procedure. Repeat colonoscopy is recommended for hemodynamic instability, transfusion requirement, and continued or recurrent episodes of bleeding.

Perforation is the most common complication of colonoscopy, occurring in <1% of cases.<sup>111</sup> These injuries are caused by mechanical or pneumatic pressure and are most common at the rectosigmoid or sigmoid–descending colon junctions along the antimesenteric border at the site of scope looping. Alternatively, cecal perforation can occur if the colon is excessively insufflated across a more distal nontraversable obstruction. In patients with a competent ileocecal valve, there is a resultant trapping of air between the distal obstruction and the valve, which prevents release of the insufflated air into the small bowel.

Therapeutic colonoscopy can also be complicated by perforation, at the site of therapy, as well as the other previously reported sites. Reported incidences are rare (<1%), with the greatest risks occurring with the removal of sessile polyps. Following polypectomy, patients occasionally develop localized pain secondary to peritoneal irritation, along with fever, tachycardia, and leukocytosis. There is usually no evidence of diffuse peritonitis or overt perforation (ie, no “free air”). This syndrome has been labeled postpolypectomy syndrome, and is probably attributable to a transmural electrocoagulation injury with microperforation. Patients usually can be managed conservatively with antibiotics, analgesics, and close observation with serial exams. Symptoms usually resolve within 48–72 hours and rarely are surgical interventions needed.

In patients with a suspected perforation, CT studies are recommended to evaluate for abscess formation or intra-abdominal fluid collections. Intra-abdominal fluid collection is a more concerning finding and these patients require close observation with a low tolerance for surgical intervention. It is important to base therapy on individual patient status, however, rather than just radiographic studies. The presence of intraperitoneal or retroperitoneal air in the absence of clinical peritonitis or hemodynamic instability does not warrant surgical exploration.

## Polypectomy

By far, the most commonly performed colonoscopic intervention is polypectomy. When performed at regular intervals, removing adenomatous polyps has been shown to significantly reduce the incidence of colon cancer.<sup>107</sup> Small sessile lesions are amenable to hot or cold biopsy polypectomy. For hot polypectomy, standard biopsy forceps without spike are attached to an electrocautery unit set at 10 to 20 watts. The polyp is grasped and lifted from the surrounding mucosa, and monopolar cautery is applied in short bursts until the base of the polyp whitens. The biopsy forceps is sharply withdrawn and the polyp is then removed through the working channel of the colonoscope. Polypectomy serves to biopsy the polyp and ablate any residual tissue, thereby diminishing the risk of progression to carcinoma. Due to the concern for delayed bleeding following sloughing of the eschar as well as the risk of perforation, many endoscopists are now adopting cold polypectomy techniques. Several series have shown no difference in the rates of bleeding, and

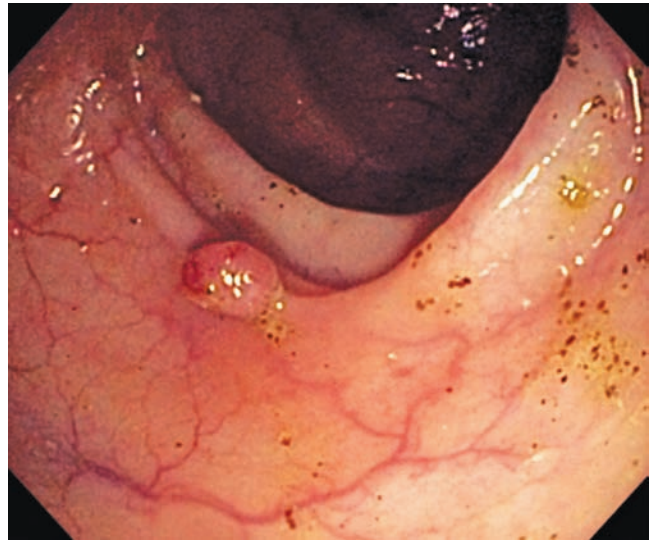

FIGURE 3-32 Small pedunculated polyp amenable to snare polypectomy technique.

it presents a more easily evaluable specimen to the pathologist without cautery artifact.

Pedunculated polyps are suitable for snare polypectomy (Fig. 3-32). The base of the polyp is encircled with the snare several millimeters below the head-stalk junction. This allows removal of a portion of the stalk for pathologic evaluation to rule out invasion of the lamina or muscular layers, identifying a more advanced neoplasm. Cautery is applied as the snare is gradually closed, thus severing the polyp and cauterizing the base. Broader-based pedunculated polyps may be managed with placement of an endoscopic pretied endoloop proximal to the site of resection to help minimize bleeding. These loops usually will slough off within several weeks and pass spontaneously.

Sessile polyps are frequently more difficult to manage than pedunculated polyps. Small sessile lesions may be captured in a single application of a snare and resected, with (hot) or without (cold) cautery, while larger lesions might require resection in a piecemeal fashion. Piecemeal resection provides for removal of a larger lesion along with ablation of residual tissue, but may make pathologic interpretation more challenging.<sup>113</sup>

Resection of sessile polyps poses a higher risk of colonic perforation than pedunculated polyps. Given that, endoscopic mucosal resection has been developed to minimize the risk of perforation and ensure complete resection of the lesion. This is provided by submucosal injection of saline to create a cushion between the mucosa and muscularis, to help minimize the risk for perforation.<sup>113–116</sup> Lesions that do not easily elevate may have a component of invasive carcinoma and these tumors should be biopsied and tattooed, rather than attempted to be endoscopically resected. Following removal of large sessile lesions, APC ablation of the site has been proposed to minimize adenoma recurrence.



## POLYP RETRIEVAL

Small polyps may be retrieved through the suction channel of the endoscope and captured in a trap. Larger polyps may be recovered in a net placed through the working channel of the endoscope or apposed to the tip of the endoscope by constant application of suction and then withdrawn with the scope. Marking the site of resection with a carbon particle–based tattoo via a sclerotherapy needle will allow for more accurate surveillance, as well as to guide surgery if the polyp proves to be malignant. Injections should be placed at multiple sites circumferentially to allow for the most reliable visualization at the time of surgery or during subsequent surveillance endoscopy.

## POLYP SURVEILLANCE

Over the past 15 years, much has been learned about the nature of the adenoma carcinoma sequence, leading to ongoing changes in the recommendations for polyp surveillance. Average risk patients with satisfactory bowel preps require repeat surveillance in 10 years, while patients with those with poorer preps might be recommended to have a shorter interval of 5 to 7 years.<sup>107,109–111</sup> Hyperplastic polyps carry an undetermined risk/association with advanced neoplasia, although there has been some suggestion that left-side hyperplastic lesions have a more aggressive nature than those in the rectosigmoid. Similar to fundic gland polyps of the stomach, these lesions may be sampled but do not need to be fully removed. Tubular adenomas, tubulovillous adenomas, and villous adenomas warrant a surveillance colonoscopy at 5, 3, and 1 year, respectively.<sup>107</sup>

## Lower Gastrointestinal Bleeding

Sources of lower gastrointestinal bleeding include UGI bleeding, infection, ischemia, neoplasia, diverticulosis, angiodysplasia, and anorectal disease. A detailed history of the nature of bleeding is vital to the management of patients with lower gastrointestinal bleeding identifying underlying coagulopathy, recent surgical or colonoscopic interventions (polypectomy), and associated comorbid diseases. These factors are important in patient management and guiding surgical and nonsurgical interventions.

The role of bowel preparation prior to colonoscopy in the face of lower gastrointestinal bleeding is dependent on the rapidity of the bleeding. As blood is a very active cathartic, colonoscopy can be performed in the unprepped colon with extensive bleeding.<sup>117–119</sup> Otherwise, a rapid prep over 3 to 4 hours can be utilized in patients with less aggressive bleeding prior to endoscopic evaluation. The endoscopist must compare the need for a more urgent intervention versus the necessity of a more adequately cleared mucosal surface. In addition, newer irrigation devices are now available that can be affixed to the colonoscope to provide for high pressure and volume irrigation and cleaning.

Colonoscopic therapy for lower gastrointestinal hemorrhage within 6 to 24 hours of admission has been shown to diminish rates of rebleeding and reduce the necessity for urgent surgical intervention.<sup>117</sup> Various methods are available for hemostasis including thermal and nonthermal devices, and are described in the preceding sections of this chapter. One must always remember, however, that the colon wall is thinner, especially on the right side, as compared to the stomach. Depth of penetration of the varied thermal endoscopic devices must be closely considered to avoid full thickness perforations.

Diverticular disease is the most frequent cause of lower gastrointestinal hemorrhage. Up to 75% of diverticular bleeds are self-limited, but in those patients with transfusion requirements, massive hematochezia, or hemodynamic instability, colonoscopy may aid in confirming diagnosis, identifying the site, achieving hemostasis and limiting patient morbidity.<sup>117–121</sup> Locating the precise site of bleeding may be difficult in the face of multiple diverticula and a blood-stained colon. The bleeding diverticular vessel is frequently at the lip of the diverticulum, although bleeding vessels in the dome of the diverticulum may also occur. The use of endoscopic clips and ligation bands for treatment of bleeding diverticuli has also been reported.<sup>120,121</sup>

Vascular ectasia or angiodysplasia, commonly in the right colon but also routinely multicentric, is another common cause of lower gastrointestinal hemorrhage. Argon plasma coagulation is invaluable in this situation, but care should be taken to avoid excessive distension of the bowel, as the argon gas accumulates and could lead to perforation.<sup>122</sup> Other thermal endoscopic contact probes, as described in previous sections of this chapter, can also be utilized.

## Colonoscopic Decompression

Mechanical or nonmechanical obstructions with unrelieved distention of the colon, in addition to leading to patient discomfort, can result in bowel ischemia, perforation, and death. In patients with colonic distention secondary to acute pseudo-obstruction, Ogilvie's syndrome, colonoscopy provides both a diagnostic and therapeutic potential. Underlying etiologies including ischemia, infectious colitis, or an unsuspected obstructing lesion must be excluded.

Conservative treatment is initially indicated in patients with benign abdominal exams, clinical stability, and cecal diameters less than 12 cm. Patients should be maintained NPO, electrolyte imbalances corrected, narcotics withdrawn, and one should consider possible placement of nasogastric and rectal tubes.

Colonoscopic decompression is done without a routine bowel preparation, thus limiting the overall mucosal evaluation. The endoscope is advanced, with limited air insufflation, as far proximally as can be achieved without excessive bowel wall tension, minimizing any risk for perforation. Decompression is then performed upon withdrawal of the colonoscope, suctioning both fluid and intraluminal air. Although the cecum

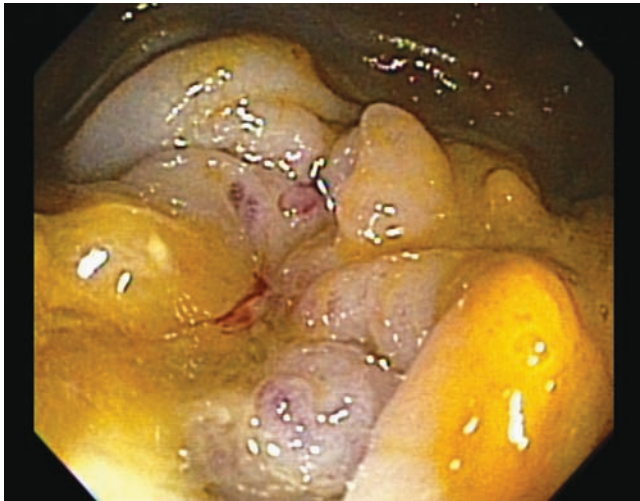

FIGURE 3-33 An obstructing sigmoid colon cancer prior to stent placement.

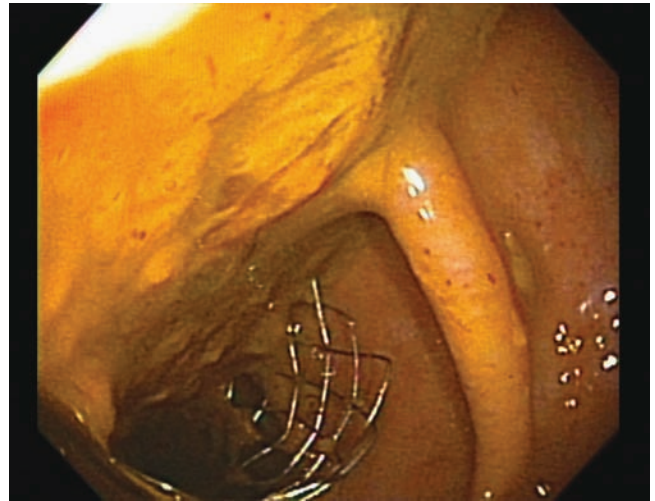


FIGURE 3-35 Following stent deployment, obstruction is relieved as seen by the large volume of liquid stool.

is the optimal endpoint, successful decompression can also be achieved with a less complete colonoscopy. Evaluation of visualized segments of the colon for ischemia and/or mechanical obstruction, possibly requiring stent placement or dilation, is crucial. It must be understood that repeat colonoscopic decompression is routinely required in patients with pseudo-obstruction, and they should be watched closely for several days.

## Enteral Stents

Colonic stenting can provide relief of malignant colon obstruction or benign stricture and serve either as palliation or as a bridge to operation.<sup>123-127</sup> Permanent SEMT are

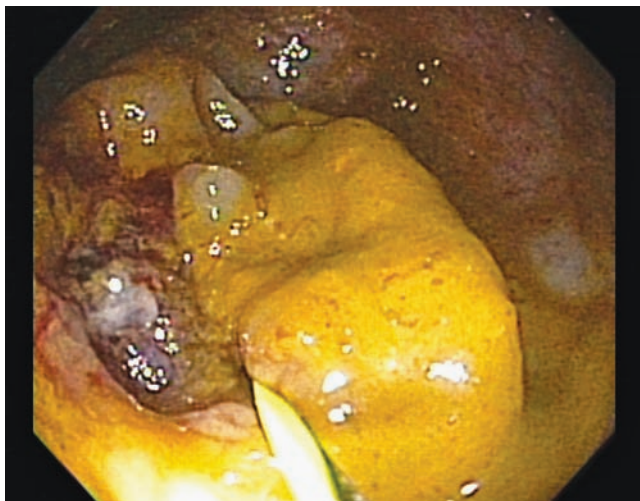

FIGURE 3-34 Guide wire placement across the obstructing lesion.

commonly employed in large bowel obstruction. Through-the-scope stents are placed under endoscopic and fluoroscopic guidance. The malignant stricture is located endoscopically and a guide wire is passed through the narrowed lumen (Figs. 3-33 and 3-34). Contrast is injected into the bowel lumen, typically through an ERCP catheter, to define the borders of the stricture. If possible, the proximal and distal extents of the stricture are marked by injecting submucosal contrast. The stent is then placed over the wire, positioned properly, and deployed (Fig. 3-35). Self-expanding metal stents have shown efficacy in reducing the need for emergency operation in acute large bowel obstruction.<sup>123,124,126</sup> In patients who are not candidates for operation, metal stents may serve a palliative purpose.<sup>125</sup> Stenting is generally safe, although perforation has been reported in up to 10% of cases. Migration of stents can also occur, although is less likely due to tissue in-growth, which can also lead to subsequent stent occlusion.

## ENDOSCOPIC ULTRASOUND

Endoscopic ultrasound has become a mainstay in the diagnostic and therapeutic armamentarium of endoscopy (Table 3-4). The staging of neoplastic processes throughout the gastrointestinal tract, and those structures adjacent to the hollow viscera, can now be more accurately accomplished, with the addition of tissue sampling for confirmation of disease.<sup>128-130</sup> The use of neoadjuvant therapy has become closely tied to the results of endoscopic ultrasonographic findings, providing for more appropriate patient care. Finally, directed therapy for endoscopic removal, drainage, and palliation of gastrointestinal and extragastric diseases is now readily being performed with the assistance of EUS.<sup>131</sup>




**TABLE 3-4: INDICATIONS FOR ENDOSCOPIC ULTRASOUND**
**Pancreatic**

1. Fine-needle aspiration and cytology of cystic or solid lesions
2. Drainage of fluid collections
3. Lymph node sampling (to determine resectability)
4. Assess portal venous system
5. Intraductal ultrasound
6. Ampullary mass

**Hepatobiliary**

1. Detect stones (in conjunction with or in lieu of ERCP)
2. Intraductal ultrasound
3. Periportal lymph node sampling
4. Biopsy of liver mass

**Mediastinal**

1. Aortopulmonary window lymph node sampling (in lieu of mediastinoscopy)
2. Bronchial and carinal tissue sampling/cytology
3. Lung cancer staging

**Esophageal**

1. Esophageal cancer staging
2. Follow-up of hiatal hernia repair and antireflux surgery (under investigation)

**Gastric**

1. Gastric cancer staging
2. Evaluation of submucosal masses

**Retroperitoneal**

1. Lymph node cytology
2. Celiac axis nerve blocks
3. Retroperitoneal biopsies
4. Renal/adrenal biopsies

**Colorectal**

1. Anorectal cancer staging
2. Anorectal lymph node evaluation
3. Anal sphincter evaluation
4. Perirectal abscess detection and management

The echoscope endoscopically visualizes similar to a side-viewing duodenoscope. After providing appropriate sedation, endoscopic visualization is used initially to achieve appropriate scope position. Once the endoscope is in the desired position, a balloon on the endoscope tip is filled with deaerated water. The lumen of the GI tract is suctioned to affix the scope adjacent to the mucosal surface as excess air limits ultrasound views. Miniature probes as well as Doppler capabilities are also available. When a lesion is found, the working port of the scope allows for passage of a 19 or 20 gauge needle to obtain fine-needle aspiration biopsies. Immediate cytologic evaluation is recommended as repeat passes for further samples is commonly required.

**FUTURE DEVELOPMENTS**

The future developments in endoscopy will be based on advancements of both the tools and the applications available to endoluminal therapy. As surgery becomes less invasive with the advancement of laparoscopy, endoscopy is taking on an increasingly more invasive and therapeutic role. Intraluminal and transluminal procedures are being developed with the goal of further supplanting surgery. Recent interest in NOTES united surgeons and gastroenterologists with the desire to access the abdominal cavity via naturally existing orifices including the stomach, colon, bladder, and vagina. Using existing endoscopic technology, investigators have attempted numerous intra-abdominal procedures in porcine models, and eventually human cases under laparoscopic guidance have also been reported.<sup>132,133</sup> An appropriate application for this approach is still yet to be elucidated. It is theorized that NOTES may have distinct advantages over laparoscopy in that it may not necessarily require a sterile working environment to perform, and it possibly could also be completed under conscious sedation similar to other endoscopic procedures.<sup>134,135</sup>

The obvious limitations to NOTES were based on the lack of adequate and appropriate endoscopic equipment. The accessories were too flimsy to perform intra-abdominal manipulation of tissue, and the endoscopes were too flexible, inhibiting access and stable positioning once in the abdominal cavity. It was apparent early on that stable platforms would be necessary as well as endoscopic tools for cutting, hemostasis, and tissue manipulation. Transoral and transvaginal multichannel platforms with internal capability for manipulation and fixation are now becoming available. Scissors, suturing devices, bipolar forceps, and grasping devices are a few of the novel instruments soon to be added to the endoscopist's armamentarium.

These tools, however, will have a more likely impact on intraluminal endoscopic surgery.<sup>136</sup> The ability to perform full thickness resection, intraluminal anastomoses, and closure of perforations are all likely procedures to be seen in the very near future, and it is imperative that surgeons stay abreast of the numerous advancements in these technologies.

**REFERENCES**

1. Sivak MV. Gastrointestinal endoscopy: past and future. *Gut*. 2006;55(8):1061–1064.
2. Ponsky JL. Endoluminal surgery: past, present and future. *Surg Endosc*. 2006;20(Suppl 2):S500–S502.
3. Chiu HM, Chang CY, Chen CC, et al. A prospective comparative study of narrowband imaging, chromoendoscopy, and conventional colonoscopy in the diagnosis of colorectal neoplasia. *Gut*. 2007;56(3):373–379.
4. Pearl JB, Marks JM. New technology in endoscopy. In: Soper NJ, ed. *Mastery of Endoscopic and Laparoscopic Surgery*. 2nd ed. Lippincott Williams & Wilkins: Philadelphia, PA; 2009:17–23.
5. Tischendorf JJ, Schirin-Sokhan R, Streetz K, et al. Value of magnifying endoscopy in classifying colorectal polyps based on vascular pattern. *Endoscopy*. 2009 Nov 6. [Epub ahead of print].
6. Kawahara Y, Takenaka R, Okada H, et al. Novel chromoendoscopic method using an acetic acid-indigocarmine mixture for diagnostic

- accuracy in delineating the margin of early gastric cancers. *Dig Endosc*. 2009 Jan;21(1):14–19.
7. Ignjatovic A, East JE, Suzuki N, et al. Optical diagnosis of small colorectal polyps at routine colonoscopy (Detect InSpect ChAracterise Resect and Discard; DISCARD trial): a prospective cohort study. *Lancet Oncol*. 2009 Nov 10. [Epub ahead of print].
  8. Mannath J, Raguath K. Dig Narrow band imaging and high resolution endoscopy with magnification could be useful in identifying gastric atrophy. *Dis Sci*. 2009 Oct 3. [Epub ahead of print].
  9. Kato M, Kaise M, Yonezawa J, et al. Trimodal imaging endoscopy may improve diagnostic accuracy of early gastric neoplasia: a feasibility study. *Gastrointest Endosc*. 2009 Nov;70(5):899–906.
  10. Isenberg G, Sivak MV Jr, Chak A, et al. Accuracy of endoscopic optical coherence tomography in the detection of dysplasia in Barrett's esophagus: a prospective, doubleblinded study. *Gastrointest Endosc*. 2005;62(6):825–831.
  11. Othman MO, Bradley AG, Choudhary A, et al. Variable stiffness colonoscope versus regular adult colonoscope: meta-analysis of randomized controlled trials. *Endoscopy*. 2009 Jan;41(1):17–24.
  12. Lee DW, Li AC, Ko CW, et al. Use of a variable-stiffness colonoscope decreases the dose of patient-controlled sedation during colonoscopy: a randomized comparison of 3 colonoscopes. *Gastrointest Endosc*. 2007 Mar;65(3):424–429.
  13. Hawari R, Pasricha PJ. Going for the loop: a unique overtube for the difficult colonoscopy. *J Clin Gastroenterol*. 2007 Feb;41(2):138–140.
  14. Bittner JG, Marks JM, Dunkin BJ, et al. Resident training in flexible gastrointestinal endoscopy: a review of current issues and options. *J Surg Edu*. 2007;10:399–403.
  15. Pearl J, Marks J. The future of teaching surgical endoscopy. *Surg Innov*. 2006;13(4):280–282.
  16. Dunkin BJ. Flexible endoscopy simulators. *Semin Laparosc Surg*. 2003;10:29–35.
  17. Qadeer MA, Rocio Lopez A, Dumot JA, et al. Risk factors for hypoxemia during ambulatory gastrointestinal endoscopy in ASA I-II patients. *Dig Dis Sci*. 2009 May;54(5):1035–1040.
  18. Khiani VS, Salah W, Maimone S, et al. Sedation during endoscopy for patients at risk of obstructive sleep apnea. *Gastrointest Endosc*. 2009 Aug 4. [Epub ahead of print].
  19. Waring JP, Baron TH, Hirota WK, et al; the American Society for Gastrointestinal Endoscopy, Standards of Practice Committee. Guidelines for conscious sedation and monitoring during gastrointestinal endoscopy. *Gastrointest Endosc*. 2003;58:317–322.
  20. Faigel DO, Baron TH, Goldstein JL et al; the Standards of Practice Committee, American Society for Gastrointestinal Endoscopy. Guidelines for the use of deep sedation and anesthesia for GI endoscopy. *Gastrointest Endosc*. 2002;56:613–617.
  21. VanNatta ME, Rex DK. Propofol alone titrated to deep sedation versus propofol in combination with opioids and/or benzodiazepines and titrated to moderate sedation for colonoscopy. *Am J Gastroenterol*. 2006 Oct;101(10):2209–2217.
  22. Adler DG, Leighton JA, Davila RE et al; the American Society for Gastrointestinal Endoscopy. ASGE guideline: the role of endoscopy in acute non-variceal upper-GI hemorrhage. *Gastrointest Endosc*. 2004;60:497–504.
  23. Cappell MS, Friedel D. Acute nonvariceal upper gastrointestinal bleeding: endoscopic diagnosis and therapy. *Med Clin North Am*. 2008 May;92(3):511–550.
  24. Tang SJ, Lee SY, Hynan LS, et al. Endoscopic hemostasis in nonvariceal upper gastrointestinal bleeding: comparison of physician practice in the east and the west. *Dig Dis Sci*. 2009 Nov;54(11):2418–2426.
  25. Zepeda-Gómez S, Marcon NE. Endoscopic band ligation for nonvariceal bleeding: a review. *Can J Gastroenterol*. 2008 Sep;22(9):748–752.
  26. Guo SB, Gong AX, Leng J, et al. Application of endoscopic hemoclips for nonvariceal bleeding in the upper gastrointestinal tract. *World J Gastroenterol*. 2009 Sep 14;15(34):4322–4326.
  27. Kapetanios D, Beltsis A, Chatzimavroudis G, et al. The use of endoclips in the treatment of nonvariceal gastrointestinal bleeding. *Surg Laparosc Endosc Percutan Tech*. 2009 Feb;19(1):2–10.
  28. Yuan Y, Wang C, Hunt RH. Endoscopic clipping for acute nonvariceal upper-GI bleeding: a meta-analysis and critical appraisal of randomized controlled trials. *Gastrointest Endosc*. 2008 Aug;68(2):339–351.
  29. Chennat J, Konda VJ, Ross AS, et al. Complete Barrett's eradication endoscopic mucosal resection: an effective treatment modality for high-grade dysplasia and intramucosal carcinoma—an American single-center experience. *Am J Gastroenterol*. 2009 Nov;104(11):2684–2692.
  30. Avilés A, Reymunde A, Santiago N. Balloon-based electrode for the ablation of non-dysplastic Barrett's esophagus: ablation of intestinal metaplasia (AIM II Trial). *Bol Asoc Med P R*. 2006 Oct–Dec;98(4):270–275.
  31. Ganz RA, Overholt BF, Sharma VK, et al. Circumferential ablation of Barrett's esophagus that contains high-grade dysplasia: a U.S. Multicenter Registry. *Gastrointest Endosc*. 2008 Jul;68(1):35–40.
  32. Fleischer DE, Overholt BF, Sharma VK, et al. Endoscopic ablation of Barrett's esophagus: a multicenter study with 2.5-year follow-up. *Gastrointest Endosc*. 2008 Nov;68(5):867–876.
  33. Sharma VK, Kim HJ, Das A, et al. A prospective pilot trial of ablation of Barrett's esophagus with low-grade dysplasia using stepwise circumferential and focal ablation (HALO system). *Endoscopy*. 2008 May;40(5):380–387.
  34. Panagiotakis PH, DiSario JA, Hilden K, et al. DPEJ tube placement prevents aspiration pneumonia in high-risk patients. *Nutr Clin Pract*. 2008 Apr–May;23(2):172–175.
  35. Freeman C, Delege MH. Small bowel endoscopic enteral access. *Curr Opin Gastroenterol*. 2009 Mar;25(2):155–159.
  36. Virnig DJ, Frech EJ, Delege MH, et al. Direct percutaneous endoscopic jejunostomy: a case series in pediatric patients. *Gastrointest Endosc*. 2008 May;67(6):984–987.
  37. Del Piano M, Ballarè M, Carmagnola S, et al. DPEJ placement in cases of PEG insertion failure. *Dig Liver Dis*. 2008 Feb;40(2):140–143.
  38. DeLegge MH. Small bowel endoscopic enteral access. *Gastrointest Endosc Clin N Am*. 2007 Oct;17(4):663–686.
  39. American Society for Gastrointestinal Endoscopy. Guideline for the management of ingested foreign bodies. *Gastrointest Endosc*. 1995; 42:622–625.
  40. Palta R, Sahota A, Bemarki A, et al. Foreign-body ingestion: characteristics and outcomes in a lower socioeconomic population with predominantly intentional ingestion. *Gastrointest Endosc*. 2009 Mar;69(3 Pt 1): 426–433.
  41. Prasad GA, Reddy JG, Boyd-Enders FT, et al. Predictors of recurrent esophageal food impaction: a case-control study. *J Clin Gastroenterol*. 2008 Aug;42(7):771–775.
  42. American Society for Gastrointestinal Endoscopy Guideline. Esophageal dilation. *Gastrointest Endosc*. 1998;48:702–704.
  43. Keränen I, Udd M, Lepistö A, et al. Outcome for self-expandable metal stents in malignant gastroduodenal obstruction: single-center experience with 104 patients. *Surg Endosc*. 2009 Sep 3. [Epub ahead of print].
  44. Moon JH, Choi HJ, Ko BM, et al. Combined endoscopic stent-in-stent placement for malignant biliary and duodenal obstruction by using a new duodenal metal stent (with videos). *Gastrointest Endosc*. 2009 Oct; 70(4):772–777.
  45. Babor R, Talbot M, Tyndal A. Treatment of upper gastrointestinal leaks with a removable, covered, self-expanding metallic stent. *Surg Laparosc Endosc Percutan Tech*. 2009 Feb;19(1):e1–e4.
  46. van Hooft JE, Uitdehaag MJ, Bruno MJ, et al. Efficacy and safety of the new WallFlex enteral stent in palliative treatment of malignant gastric outlet obstruction (DUOFLEX study): a prospective multicenter study. *Gastrointest Endosc*. 2009 May;69(6):1059–1066.
  47. Phillips MS, Gosain S, Bonatti H, et al. Enteral stents for malignancy: a report of 46 consecutive cases over 10 years, with critical review of complications. *J Gastrointest Surg*. 2008 Nov;12(11):2045–2050.
  48. Huang Q, Dai DK, Qian XJ, et al. Treatment of gastric outlet and duodenal obstructions with uncovered expandable metal stents. *World J Gastroenterol*. 2007 Oct 28;13(40):5376–5379.
  49. Gupta K, Freeman ML. Enteral and colonic self-expanding metallic stents. *Rev Gastroenterol Disord*. 2008 Spring;8(2):83–97.
  50. Small AJ, Young-Fadok TM, Baron TH. Expandable metal stent placement for benign colorectal obstruction: outcomes for 23 cases. *Surg Endosc*. 2008 Feb;22(2):454–462.
  51. Schiefke I, Zabel-Langhennig A, Neumann S, et al. Long term failure of endoscopic gastroplication (EndoCinch). *Gut*. 2005 Jun;54(6):752–758.
  52. Abou-Rebyeh H, Hoepffner N, Rosch T, et al. Long-term failure of endoscopic suturing in the treatment of gastroesophageal reflux: a prospective follow-up study. *Endoscopy*. 2005 Mar;37(3):213–216.
  53. Pearl J, Marks J. Endoluminal therapies for gastroesophageal reflux disease: are they dead? *Surg Endosc*. 2007;21(1):1–4.
  54. Lutfi RE, Torquati A, Richards WO. Endoscopic treatment modalities for gastroesophageal reflux disease. *Surg Endosc*. 2004;18:1299–1315.

55. Lutfi RE, Torquati A, Kaiser J, et al. Three year's experience with the Stretta procedure: did it really make a difference? *Surg Endosc.* 2005 Feb;19(2):289–295.
56. Wolfsen HC, Richards WO. The Stretta procedure for the treatment of GERD: a registry of 558 patients. *J Laparoendosc Adv Surg Tech A.* 2002 Dec;12(6):395–402.
57. Triadafilopoulos G, DiBaise JK, Nostrant TT, et al. The Stretta procedure for the treatment of GERD: 6 and 12 month follow-up of the U.S. open label trial. *Gastrointest Endosc.* 2002 Feb;55(2):149–156.
58. Chuttani R, Sud R, Sachdev G, et al. A novel endoscopic full-thickness plicator for the treatment of GERD: a pilot study. *Gastrointest Endosc.* 2003 Nov;58(5):770–776.
59. Haber G, Sakai P, Moura E, Maluf-Filho F, Pleskow D, Lembo A. The Plicator procedure for the treatment of GERD: 12-month multicenter results. *Gastrointest Endosc.* 2005;61:5.
60. Lin E, Smith CD, Sedghi S. Objective improvements following full thickness gastric cardia plication for complicated GERD. *SAGES.* 2005.
61. Pleskow D, Rothstein R, Lo S, et al. Endoscopic full-thickness plication for the treatment of GERD: 12-month follow-up for the North American open-label trial. *Gastrointest Endosc.* 2005;61:6,643–649.
62. Deviere J, Costamagna G, Neuhaus H, et al. Nonresorbable copolymer implantation for gastroesophageal reflux disease: a randomized sham-controlled multicenter trial. *Gastroenterology.* 2005 Mar;128(3):532–540.
63. Schumacher B, Neuhaus H, Ortner M, et al. Reduced medication dependency and improved symptoms and quality of life 12 months after enteryx implantation for gastroesophageal reflux. *J Clin Gastroenterol.* 2005 Mar;39(3):212–219.
64. Cohen LB, Johnson DA, Ganz RA, et al. Enteryx implantation for GERD: expanded multicenter trial results and interim postapproval follow-up to 24 months. *Gastrointest Endosc.* 2005 May;61(6):650–658.
65. Noh KW, Loeb DS, Stockland A, et al. Pneumomediastinum following Enteryx injection for the treatment of gastroesophageal reflux disease. *Am J Gastroenterol.* 2005 Mar;100(3):723–726.
66. Tintillier M, Chaput A, Kirch L, et al. Esophageal abscess complicating endoscopic treatment of refractory gastroesophageal reflux disease by Enteryx injection: a first case report. *Am J Gastroenterol.* 2004 Sep;99(9):1856–1858.
67. Wong RF, Davis TV, Peterson KA. Complications involving the mediastinum after injection of Enteryx for GERD. *Gastrointest Endosc.* 2005 May;61(6):753–756.
68. FDA preliminary public health notification: recall of Boston Scientific Enteryx procedure kits and Enteryx injector single packs for treatment of gastroesophageal reflux disease (GERD). <http://www.fda.gov/cdrh/safety/101405-enteryx.html>. Accessed November 15, 2009.
69. Cicala M, Gabbrielli A, Emerenziani S, et al. Effect of endoscopic augmentation of the lower esophageal sphincter (Gatekeeper reflux repair system) on intraesophageal dynamic characteristics of acid reflux. *Gut.* 2005 Feb;54(2):183–186.
70. Fockens P, Bruno MJ, Gabbrielli A, et al. Endoscopic augmentation of the lower esophageal sphincter for the treatment of gastroesophageal reflux disease: multicenter study of the Gatekeeper Reflux Repair System. *Endoscopy.* 2004 Aug;36(8):682–689.
71. Adler DG, Baron TH, Davila RE et al; the Standards of Practice Committee of the American Society for Gastrointestinal Endoscopy. ASGE guideline: the role of ERCP in diseases of the biliary tract and the pancreas. *Gastrointest Endosc.* 2005;62:1–8.
72. Scaffidi MG, Luigiano C, Consolo P, et al. Magnetic resonance cholangio-pancreatography versus endoscopic retrograde cholangiopancreatography in the diagnosis of common bile duct stones: a prospective comparative study. *Minerva Med.* 2009 Oct;100(5):341–348.
73. Parra-Membrives P, Díaz-Gómez D, Vilegas-Portero R, et al. Appropriate management of common bile duct stones: a RAND Corporation/UCLA Appropriateness Method statistical analysis. *Surg Endosc.* 2009 Nov 14. [Epub ahead of print].
74. Folkers MT, Disario JA, Adler DG. Long-term complications of endoscopic biliary sphincterotomy for choledocholithiasis: a North-American perspective. *Am J Gastroenterol.* 2009 Nov;104(11):2868–2869.
75. Madácsy L, Kurucaş G, Fejes R, et al. Prophylactic pancreas stenting followed by needle-knife fistulotomy in patients with sphincter of Oddi dysfunction and difficult cannulation: new method to prevent post-ERCP pancreatitis. *Dig Endosc.* 2009 Jan;21(1):8–13.
76. Sherman S. What is the role of ERCP in the setting of abdominal pain of pancreatic or biliary origin (suspected sphincter of Oddi dysfunction)? *Gastrointest Endosc.* 2002 Dec;56(6 Suppl):S258–S266.
77. Horakova M, Vadovicova I, Katuscak I, et al. Consideration of endoscopic retrograde cholangiopancreatography in cases of acute biliary pancreatitis. *Bratisl Lek Listy.* 2009;110(9):553–558.
78. Uy MC, Daez ML, Sy PP, et al. Early ERCP in acute gallstone pancreatitis without cholangitis: a meta-analysis. *JOP.* 2009 May 18;10(3):299–305.
79. Nguyen-Tang T, Frossard JL, Dumonceau JM. Endoscopic management of benign biliary strictures. *Rev Med Suisse.* 2009 Sep 2;5(215):1714–1716, 1718–1719.
80. Perdue DG, Freeman ML, DiSario JA, et al. Plastic versus self-expanding metallic stents for malignant hilar biliary obstruction: a prospective multicenter observational cohort study. *J Clin Gastroenterol.* 2008 Oct;42(9):1040–1046.
81. Wasan SM, Ross WA, Staerckel GA, et al. Use of expandable metallic biliary stents in resectable pancreatic cancer. *Am J Gastroenterol.* 2005 Sep;100(9):2056–2061.
82. Piñol V, Castells A, Bordas JM, et al. Percutaneous self-expanding metal stents versus endoscopic polyethylene endoprosthesis for treating malignant biliary obstruction: randomized clinical trial. *Radiology.* 2002 Oct;225(1):27–34.
83. Baillie J. Endoscopic therapy in acute recurrent pancreatitis. *World J Gastroenterol.* 2008 Feb 21;14(7):1034–1037.
84. Lerch MM, Stier A, Wahnschaffe U, et al. Pancreatic pseudocysts: observation, endoscopic drainage, or resection? *Dtsch Arztebl Int.* 2009 Sep;106(38):614–621.
85. Park DH, Lee SS, Moon SH, et al. Endoscopic ultrasound-guided versus conventional transmural drainage for pancreatic pseudocysts: a prospective randomized trial. *Endoscopy.* 2009 Oct;41(10):842–848.
86. Bhasin DK, Rana SS, Nanda M, et al. Endoscopic management of pancreatic pseudocysts at atypical locations. *Surg Endosc.* 2009 Nov 14. [Epub ahead of print].
87. Yasuda I, Iwata K, Mukai T, et al. Eus-guided pancreatic pseudocyst drainage. *Dig Endosc.* 2009 Jul;21(Suppl 1):S82–S86.
88. Ang TL, Teo EK, Fock KM. Endoscopic drainage and endoscopic necrosectomy in the management of symptomatic pancreatic collections. *J Dig Dis.* 2009 Aug;10(3):213–224.
89. Babu BI, Siriwardena AK. Current status of minimally invasive necrosectomy for post-inflammatory pancreatic necrosis. *HPB.* 2009;11(2):96–102.
90. Talreja JP, Kahaleh M. Endotherapy for pancreatic necrosis and abscess: endoscopic drainage and necrosectomy. *J Hepatobiliary Pancreat Surg.* 2009;16(5):605–612.
91. Friedland S, Kaltenbach T, Sugimoto M, et al. Endoscopic necrosectomy of organized pancreatic necrosis: a currently practiced NOTES procedure. *J Hepatobiliary Pancreat Surg.* 2009;16(3):266–269.
92. Seifert H, Biermer M, Schmitt W, et al. Transluminal endoscopic necrosectomy after acute pancreatitis: a multicentre study with long-term follow-up (the GEPARD Study). *Gut.* 2009 Sep;58(9):1260–1266.
93. Cotton PB, Garrow DA, Gallagher J, et al. Risk factors for complications after ERCP: a multivariate analysis of 11,497 procedures over 12 years. *Gastrointest Endosc.* 2009 Jul;70(1):80–88.
94. Tsou YK, Lin CH, Liu NJ, et al. Treating delayed endoscopic sphincterotomy-induced bleeding: epinephrine injection with or without thermotherapy. *World J Gastroenterol.* 2009 Oct 14;15(38):4823–4828.
95. Morgan KA, Fontenot BB, Ruddy JM, et al. Endoscopic retrograde cholangiopancreatography gut perforations: when to wait! When to operate! *Am Surg.* 2009 Jun;75(6):477–483; discussion 483–484.
96. Moreels TG. History of endoscopic devices for the exploration of the small bowel. *Acta Gastroenterol Belg.* 2009 Jul–Sep;72(3):335–337.
97. Monkemuller K, Weigt J, Treiber G, et al. Diagnostic and therapeutic impact of double balloon enteroscopy. *Endoscopy.* 2006;38(1):67–72.
98. Lahat A, Nadler M, Simon C, et al. Double balloon enteroscopy: a 2 year experience. *Isr Med Assoc J.* 2009 Aug;11(8):456–459.
99. Moreels TG, Hubens GJ, Ysebaert DK, et al. Diagnostic and therapeutic double-balloon enteroscopy after small bowel Roux-en-Y reconstructive surgery. *Digestion.* 2009;80(3):141–147.
100. Rondonotti E, Villa F, Saladino V, et al. Enteroscopy in the diagnosis and management of celiac disease. *Gastrointest Endosc Clin N Am.* 2009 Jul;19(3):445–4460.



101. Akerman PA, Cantero D. Spiral enteroscopy and push enteroscopy. *Gastrointest Endosc Clin N Am*. 2009 Jul;19(3):357–369.
102. Pohl J, May A, Aschmoneit I, et al. Double-balloon endoscopy for retrograde cholangiography in patients with choledochojejunostomy and Roux-en-Y reconstruction. *Z Gastroenterol*. 2009 Feb;47(2):215–219.
103. Lennon AM, Chandrasekhara V, Shin EJ, et al. Spiral-enteroscopy-assisted enteral stent placement for palliation of malignant small-bowel obstruction (with video). *Gastrointest Endosc*. 2010;71(2):422–425. Epub 2009 Nov 6.
104. Moreels TG, Macken EJ, Roth B, et al. Cecal intubation rate with the double-balloon endoscope after incomplete conventional colonoscopy: a study in 45 patients. *J Gastroenterol Hepatol*. 2009 Aug 3. [Epub ahead of print].
105. Chowdhury M, Endo M, Chiba T, et al. Characterization of follicular lymphoma in the small intestine using double-balloon endoscopy. *Gastroenterol Res Pract*. 2009;2009:835258. Epub 2009 Nov 5.
106. Wolff WL, Shinya H. Definitive treatment of “malignant” polyps of the colon. *Ann Surg*. 1975;182(4):516–525.
107. Winawer SJ, Zauber AG, Ho MN, et al. Prevention of colorectal cancer by colonoscopic polypectomy. The National Polyp Study Workgroup. *N Engl J Med*. 1993;329(27):1977–1981.
108. Winawer S, Fletcher R, Rex D, et al. Colorectal cancer screening and surveillance: Clinical guidelines and rationale—Update based on new evidence. *Gastroenterology*. 2003;124:544–560.
109. Davila RE, Rajan E, Adler D, et al. American Society for Gastrointestinal Endoscopy guideline: the role of endoscopy in the diagnosis, staging, and management of colorectal cancer. *Gastrointest Endosc*. 2005;61:1–7.
110. Anthony T, Simmang C, Hyman N, et al. Practice parameters for the surveillance and follow-up of patients with colon and rectal cancer. *Dis Colon Rectum*. 2004;47:807–817.
111. Winawer SJ, Stewart ET, Zauber AG, et al. A comparison of colonoscopy and double-contrast barium enema for surveillance after polypectomy. National Polyp Study Work Group. *N Engl J Med*. 2000;342:1766–1772.
112. Dominitz JA, Eisen GM, Baron TH, et al. Complications of colonoscopy. *Gastrointest Endosc*. 2003;57:441–445.
113. Conio M, Repici A, Demarquay JF, et al. EMR of large sessile colorectal polyps. *Gastrointest Endosc*. 2004;60(2):234–241.
114. Conio M, Ponchon T, Blanchi S, et al. Endoscopic mucosal resection. *Am J Gastroenterol*. 2006;101(3):653–663.
115. Uraoka T, Fujii T, Saito Y, et al. Effectiveness of glycerol as a submucosal injection for EMR. *Gastrointest Endosc*. 2005;61(6):736–40.
116. Fujishiro M, Yahagi N, Kashimura K, et al. Comparison of various submucosal injection solutions for maintaining mucosal elevation during endoscopic mucosal resection. *Endoscopy*. 2004;36(7):579–583.
117. Green BT, Rockey DC, Portwood G, et al. Urgent colonoscopy for evaluation and management of acute lower gastrointestinal hemorrhage: a randomized controlled trial. *Am J Gastroenterol*. 2005;100(11):2395–2402.
118. Jensen DM, Machicado GA, Jutabha R, et al. Urgent colonoscopy for the diagnosis and treatment of severe diverticular hemorrhage. *N Engl J Med*. 2000;342(2):78–82.
119. Green BT, Rockey DC. Lower gastrointestinal bleeding—management. *Gastroenterol Clin North Am*. 2005;34(4):665–678.
120. Simpson PW, Nguyen MH, Lim JK, et al. Use of endoclips in the treatment of massive colonic diverticular bleeding. *Gastrointest Endosc*. 2004;59(3):433–437.
121. Farrell JJ, Graeme-Cook F, Kelsey PB. Treatment of bleeding colonic diverticula by endoscopic band ligation: an in-vivo and ex-vivo pilot study. *Endoscopy*. 2003;35(10):823–829.
122. Ben Soussan E, Mathieu N, Roque I, et al. Bowel explosion with colonic perforation during argon plasma coagulation for hemorrhagic radiation-induced proctitis. *Gastrointest Endosc*. 2003;57(3):412–413.
123. Ely CA, Arregui ME. The use of enteral stents in colonic and gastric outlet obstruction. *Surg Endosc*. 2003;17(1):89–94.
124. Meisner S, Hensler M, Knop FK, et al. Self-expanding metal stents for colonic obstruction: experiences from 104 procedures in a single center. *Dis Colon Rectum*. 2004;47(4):444–450.
125. Xinopoulos D, Dimitroulopoulos D, Theodosopoulos T, et al. Stenting or stoma creation for patients with inoperable malignant colonic obstruction? Results of a study and cost-effectiveness analysis. *Surg Endosc*. 2004;18(3):421–426.
126. Baik SH, Kim NK, Cho HW, et al. Clinical outcomes of metallic stent insertion for obstructive colorectal cancer. *Hepatogastroenterol*. 2006;53(68):183–187.
127. Ng KC, Law WL, Lee YM, et al. Self-expanding metallic stent as a bridge to surgery versus emergency resection for obstructing left-sided colorectal cancer: a case-matched study. *J Gastrointest Surg*. 2006;10(6):798–803.
128. Preston SR, Clark GW, Martin IG, et al. Effect of endoscopic ultrasonography on the management of 100 consecutive patients with oesophageal and junction carcinoma. *Br J Surg*. 2003;90:1220–1224.
129. Hunt GC, Faigel DO. Assessment of EUS for diagnosing, staging, and determining respectability of pancreatic cancer: a review. *Gastrointest Endosc*. 2002;55:232–237.
130. Siemsen M, Svendsen LB, Knigge U et al. A prospective randomized comparison of curved array and radial echoendoscopy in patients with esophageal cancer. *Gastrointest Endosc*. 2003;58:671–676.
131. Gress F, Schmitt C, Sherman S, et al. A prospective randomized comparison of endoscopic ultrasound- and computed tomography-guided celiac plexus block for managing chronic pancreatitis pain. *Am J Gastroenterol*. 1999;94:900–905.
132. McGee MF; Marks JM; Onders RP; et al. Complete endoscopic closure of gastrotomy following natural orifice transluminal endoscopic surgery (NOTES) using the NDO plicator. *Surg Endosc*. 2008; 22(1):214–220.
133. Pearl JB, Marks JM, Ponsky JL. Hybrid surgery: combined laparoscopy and natural orifice surgery. *Gastrointestinal Endoscopy Clinics of North Am*. 2008;18(2):325–332.
134. Onders R; McGee MF; Marks J, et al. Diaphragm pacing with natural orifice transluminal endoscopic surgery (notes): potential for difficult to wean intensive care unit (ICU). *Surg Endosc*. 2007;21(3):475–479.
135. Marks J; Ponsky J; Pearl J; et al. PEG “rescue”: a practical NOTES technique. *Surg Endosc*. 2007;21(5):816–819.
136. Elmunzer BJ, Trunzo JA, Marks JM, et al. Endoscopic full thickness resection of gastric tumors using a novel grasp-and-snare technique: feasibility in ex vivo and in vivo porcine models. *Endoscopy*. 2008;10:1055.



# FUNDAMENTALS OF LAPAROSCOPIC SURGERY

Ashley H. Vernon • John G. Hunter

Tremendous growth in the use of minimally invasive techniques has occurred over the past decade. This was made possible by developments in technology and was fueled by patient demands for less painful operations and quicker postoperative recovery.

Almost all general surgical procedures can be performed using minimally invasive techniques. The greatest benefit is achieved in operations where the trauma of access exceeds that of the procedure. Procedures in the chest, upper abdomen, and pelvis, especially those not requiring tissue removal, are ideally suited for minimally invasive techniques. Conversely, other procedures may have less obvious benefits when performed with minimally invasive techniques, especially if a large specimen is to be removed. To be a proficient *laparoscopist*, one must become familiar with a new set of techniques and instruments, as well as knowing when to apply them and when to convert to an open operation.

## PATIENT CONSIDERATIONS

### Patient Selection

As in all surgery, choosing the right operation for the patient is the first step. Since all laparoscopic surgery of the abdomen requires the use of general anesthesia, the ability to tolerate anesthesia is an absolute requirement. Patients with impaired exercise tolerance or a history of shortness of breath will need a preoperative consultation with a cardiologist or pulmonologist. Patients with severe carbon dioxide (CO<sub>2</sub>) retention can be difficult to manage intraoperatively because the use of carbon dioxide for pneumoperitoneum exacerbates the condition. By increasing the minute ventilation and decreasing the CO<sub>2</sub> pneumoperitoneum from 15 to 8–10 mm Hg, one can control metabolic acidosis. Rarely, when these measures are ineffective at controlling hypercarbia, we have resorted to using nitrous oxide (N<sub>2</sub>O) for peritoneal insufflation. While not suppressing combustion (as does CO<sub>2</sub>), N<sub>2</sub>O supports combustion no more than air and has been proven safe for laparoscopic use.

A single blind randomized trial has demonstrated that N<sub>2</sub>O pneumoperitoneum is associated with decreased postoperative pain compared with CO<sub>2</sub>.<sup>1</sup>

When deciding if a patient is a suitable candidate for a laparoscopic procedure, it is important to assess patient or procedure characteristics that will lengthen the operative time sufficiently to nullify the benefits of laparoscopy. If the laparoscopic operation takes substantially longer than the open equivalent or is more risky, then it is not prudent to proceed laparoscopically. A history of a prior open procedure or multiple open procedures can make access to the abdomen difficult and will be discussed in detail later in this chapter. Adhesions and scarring in the surgical field from prior surgery can make laparoscopic surgery very difficult and may require use of many novel dissecting and coagulating tools. Operating on patients with severe obesity is challenging specifically because torque on transabdominal ports leads to surgeon fatigue and diminishes surgical dexterity. In addition, the long distance from the insufflated abdominal wall to the abdominal organs can make laparoscopic surgery a “far reach.” Special long ports and instruments are available to overcome this difficulty.

Inability to obtain an adequate working space makes laparoscopic surgery impossible. This is encountered most commonly in patients with dilation of the intestine from bowel obstruction. Often, laparoscopic lysis of adhesions for distal bowel obstruction is not technically feasible.<sup>2</sup> Some patients with appendicitis will have sufficient small bowel dilation that laparoscopic access to the right iliac fossa is not possible.

### Patient Positioning

We rely on gravity for retraction of the abdominal contents to provide exposure. Sometimes this requires steep positional changes, and care must be taken to prevent nerve complications or neuropathies after laparoscopic surgery as in open surgery. Patients must be positioned properly at the beginning of the procedure, making certain that all pressure points are padded. Perineal nerve injury is caused by lateral pressure at the knee and may occur when the table is “airplaned” to the

side with a retractor holding the patient in place. Femoral and sciatic neuropathies are similar in that they are due to compression. Padding the retractor arms and securing the patient to the table can prevent these neuropathies.

It is best if the arms can be tucked for most laparoscopic procedures so that the surgeon may move freely up and down the table in order to line up instruments and the target tissue. This is most important for procedures in the pelvis, where the surgeon will want to stand adjacent to the contralateral thorax. However, even with upper abdominal laparoscopy, tucked arms allow more optimal positioning of instrument columns and monitors. If there is a need to extend the arms on arm boards, one must be very careful to avoid a brachial plexus injury that occurs when the arm is extended greater than 90 degrees at the shoulder. Usually, at the start of a procedure, the arm positioning is safe but may change as the patient slides down on the table. For this reason, when reverse Trendelenburg is expected, we place footplates at the feet. This prevents sliding on the table and does not cause any discomfort to the patient because it is much like standing. We secure the ankles as well to be sure they do not “twist” during the procedure. There are footplates available for split-leg tables that can be used when operating on the upper abdomen and steep reverse Trendelenburg is needed.

## Patient Preparation

There may be an increased incidence of deep venous thrombosis after laparoscopic surgery that is due to pooling of blood in the venous system of the lower extremities. Venous return is impaired by compression of the iliac veins from the elevated intraabdominal pressure exerted by the pneumoperitoneum. Additionally, the positional effects of placing the patient in a steep reverse Trendelenburg position lead to further distension of the venous system. All patients undergoing laparoscopic procedures in reverse Trendelenburg, even short procedures such as laparoscopic cholecystectomy, should have sequential compression devices placed before the procedure begins, although this does not improve femoral blood flow entirely.<sup>3</sup> Patients at high risk for developing deep venous thrombosis should be treated with subcutaneous anticoagulants as either fractionated or unfractionated heparin.<sup>4</sup> This includes patients undergoing lengthy procedures, obese patients, patients with a prior history of deep venous thrombosis or pulmonary embolism, and patients in whom ambulation after surgery will be delayed. Some authors recommend placement of vena caval filters in patients with a prior history of deep venous thrombosis who are undergoing lengthy laparoscopic procedures.<sup>5</sup>

Laparoscopic surgery is associated with a high incidence of postoperative nausea and vomiting. A recent review asserts that serotonin receptor antagonists such as ondansetron (Zofran, GlaxoSmithKline) appear to be the most effective and should be considered for routine prophylaxis.<sup>6</sup> Another prospective, blinded, randomized trial shows a decrease in the postoperative nausea and vomiting when low-dose steroids are given to all patients.<sup>7</sup> There was no increased infection rate in

the group that received steroids. Other preventive measures include ensuring adequate hydration<sup>8,9</sup> and decompression of the stomach with an orogastric tube before the end of the procedure. Intravenous nonsteroidal anti-inflammatory drugs (NSAIDs) such as ketorolac provide superb pain relief and diminish the need for postoperative narcotics, which may help to prevent nausea and vomiting.

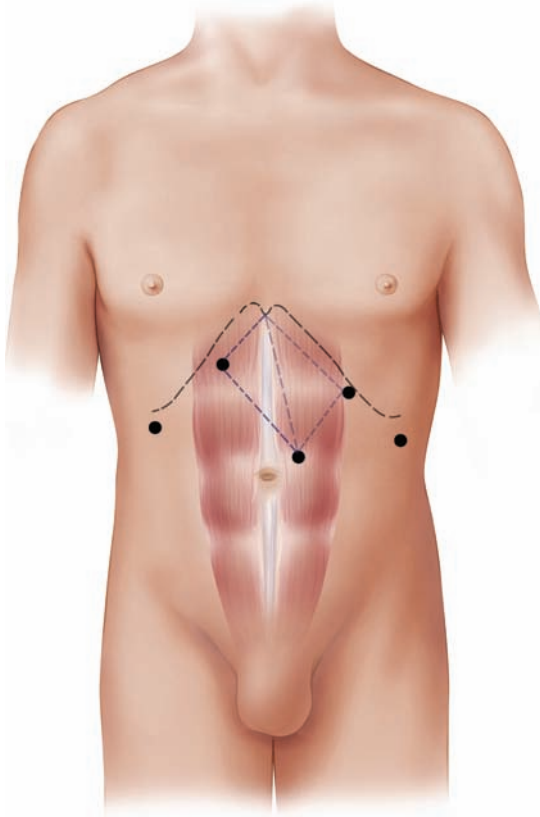
## PORT PLACEMENT

### Site Selection

Proper placement of ports is important to facilitate completion of the laparoscopic procedure. The location of port sites depends on the type of procedure; the primary port should be placed with this in mind. We do not always place the primary port at the umbilicus but rather judge which site is best for the camera or which is the safest site for the primary puncture in a previously operated abdomen. The first laparoscopic port can be positioned anywhere in the abdomen after pneumoperitoneum has been created. The additional or secondary ports should not be placed too close to each other. The optimal pattern of port placement should form an equilateral triangle or a diamond array around the operative field. This “diamond of success” takes into account the optimal working distance from the operative target for each instrument and the telescope (Fig. 4-1). In laparoscopy, the standard instrument length is 30 cm. To produce a 1:1 translation and movement from the surgeon’s hands to the operative field, the fulcrum of the instrument should be 15 cm from the target. A similar separation of the two working ports (surgeon’s left and right hands) ensures that these two instruments will not be involved in “sword fighting” and that the angle between the two instruments at the target will be optimal (between 60 and 90 degrees). The secondary port site is chosen, and the abdominal wall is transilluminated to avoid large abdominal wall vessels.<sup>10,11</sup> The trocar is watched laparoscopically as it enters into the abdomen, and care is taken to avoid injuring the abdominal contents. During the procedure, the area beneath the primary trocar site is inspected for unexpected injuries.

### Port Characteristics

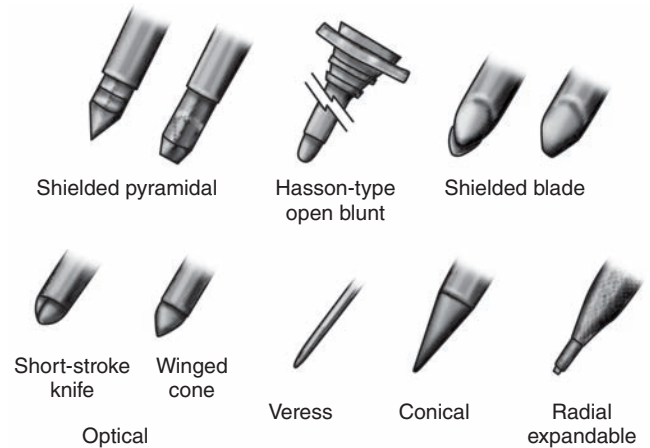
There is a wide variety of ports, each with different characteristics, available on the market. The bladed trocars cut the abdominal wall fascia during entry. Because the nonbladed trocars do not cut the abdominal wall as much, they make smaller defects in the abdominal wall and may be less prone to hernia formation in the future. The most commonly used bladed ports have a shield that retracts as the blade is pushed through the fascia of the abdominal wall, and then it engages once inside the abdomen. When first introduced to the market, the shields were called safety shields, but they have lost



**FIGURE 4-1** The “diamond of success” for optimal placement of laparoscopic ports. (Redrawn from Hunter JG, Trus TL, Branum GD, Waring JP. Laparoscopic Heller myotomy and fundoplication for achalasia. *Ann Surg.* 1997;225:655–665.)

that designation because the shield provides little protection. The nonbladed trocars come in many forms. One nonbladed trocar is used in the Step system (Covidien, Mansfield, MA), a modified Veress needle that locks inside an expandable sheath. Once inside the abdomen, the Veress needle is removed, and a blunt port is passed into the sheath that guides the port by dilating radially.<sup>12</sup> The Ethicon nonbladed trocar has a rough edge of plastic that is twisted and pushed through the layers of the abdominal wall. None of these technologies have proven safer than the more economical reusable nonshielded bladed trocar systems made by most instrument companies (Fig. 4-2).

Important characteristics of a port need to be considered when choosing which port to use. The advantage of a port introduced with a nonbladed trocar is that the abdominal wall defect is smaller, which does not allow gas to leak from the abdomen during the procedure. Because the fascia is not cut, there is a lower risk of port-site hernia, and the fascia of most 10-mm incisions does not have to be closed. Additionally, these ports tend not to slip out of the abdominal wall during manipulation. Other considerations when choosing a port are the size of the external component, the smoothness of entry and exit of the instruments and specimens, and whether an external reducer cap is needed.



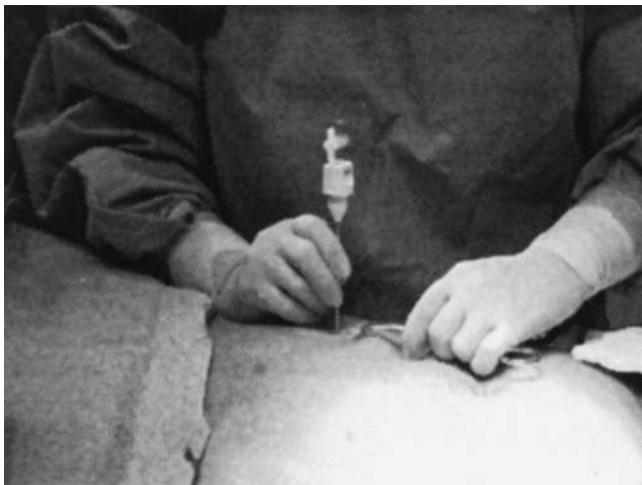
**FIGURE 4-2** Various trocars for the introduction of laparoscopic ports through the abdominal wall. There are bladed and nonbladed types. Of the bladed trocars, there are shielded and nonshielded types. The Veress needle with a radially dilating sheath used in the Step system is an example of a nonbladed trocar. (Reprinted with permission from Chandler JG, Corson SL, Way LW. Three spectra of laparoscopic entry access injuries. *J Am Coll Surg.* 2001;192:478–490; discussion 490–471.)

## Access or Placement of the First Port

No single access technique has emerged as the safest and best technique.<sup>13,14</sup> The techniques for abdominal access include direct-puncture and an open-access technique.<sup>15</sup> The direct-puncture technique can be performed either by direct trocar insertion without pneumoperitoneum or by first obtaining pneumoperitoneum using a Veress needle and then inserting the first trocar directly. The latter technique is performed most commonly in the United States. Each technique has a specific pattern of complications that must be considered when choosing among them.

The Veress needle access was first described in 1938.<sup>16</sup> This technique involves direct insertion of a needle into the peritoneum after lifting the abdominal wall with towel clips or a firm grip. The optimal site for insertion of the Veress needle is through the central scar at the umbilicus. One can make either a vertical skin incision through the umbilicus, hiding the incision in the base, or a curvilinear incision in an infraumbilical or supraumbilical position. Nevertheless, insertion of the Veress needle should be aimed at the central scar, where the layers of the abdominal wall are fused. This does not mean, though, that the first port inserted must be at the umbilicus. Advocates state that the benefits of this technique are the ability to place the initial port anywhere on the abdomen, that it is relatively quick, and that the skin and fascial openings are smaller, which prevents CO<sub>2</sub> leakage during the procedure.

For safe Veress needle insertion, first one must be certain to check the stylet and needle patency, especially when reinserting it after an unsuccessful initial pass. The Veress needle is available either as a reusable or disposable product and comes in two sizes, both long and short. The spring



**FIGURE 4-3** Proper Veress technique in the left upper quadrant using the dominant hand with the wrist stabilized on the patient. The nondominant hand is used to stabilize the abdominal wall.

mechanism that pushes the stylet out, thus protecting bowel from the needle, must be tested when using the reusable Veress needle.

The safest technique requires stabilizing the abdominal wall (we prefer penetrating towel clips in nonobese patients). It is important to have control over the force and depth of insertion of the needle. This is aided by either placing your wrist against the patient's abdomen or using the nondominant hand to support the hand wielding the needle. It is sometimes necessary to raise the operating table to achieve the proper control. One must be mindful of the fact that the most common catastrophic complication from Veress needle insertion is injury to major vessels. The trajectory of the needle should not be angled toward the aorta or iliac vessels (Fig. 4-3).

After placement of the Veress needle, one should perform an aspiration test by connecting a syringe filled with saline to the top of the Veress needle and aspirate. Aspiration of air, blood, or bile signifies incorrect placement and should prompt serious concern for an unexpected injury. If there is no aspirate, saline should be injected and should flow easily. The saline should flow down the Veress needle into the peritoneal cavity without pressure, a qualitative measure. Removing the plunger from the syringe and watching the saline level drop briskly may achieve a quantitative assessment of patency. If the saline flows slowly or not at all, the needle is likely in the wrong position, that is, up against an intra-abdominal organ, or it is in the preperitoneal space. Alternatively, the tip may be occluded with fat, or the system may have an "air lock." To test this, inject a little bit of fluid again gently, and retest by removing the plunger and allowing the saline to drop into the abdomen.

The Veress needle then is connected to the insufflation tubing. The expected initial insufflation pressure, assuming proper placement, should be less than 5–6 mm Hg. Abnormally high insufflation pressure is an indication that something

is not right.<sup>17</sup> Because the insufflator is usually set to allow a maximum pressure of 15 mm Hg, a value greater than this suggests that the patient is not anesthetized adequately and is contracting his or her abdominal muscles. If the insufflator records a pressure of 15 mm Hg, there are a few explanations. The most ominous cause would be incorrect placement into an intra-abdominal organ. More likely, the Veress needle tip may be against omentum or is in the preperitoneal space. The insufflation line may be occluded at the stopcock, or there may be a kink in the tubing.

Direct trocar insertion without first establishing pneumoperitoneum is not used as frequently because many surgeons think that it is dangerous given that the bladed trocar must be pushed into the abdomen with significant force to penetrate the abdominal wall. Surgeons unfamiliar with the technique worry about injury to bowel and vessels when using excessive force. There are, however, many surgeons who perform this technique with no increased complication rate, confirming its safety.<sup>18–22</sup> Still other surgeons believe that the open-access technique that involves a "minilaparotomy" is the safest.<sup>15,23–25</sup>

The open, or Hasson, technique was first described in 1974.<sup>15</sup> A 1- to 2-cm skin incision is made at the umbilicus, and the soft tissue is divided to identify the abdominal wall. The fascia and muscles are opened with a knife, and the peritoneum is identified and grasped with Kocher or Allis clamps. A 0-0 absorbable suture is placed through the fascia, and the Hasson port is secured to the fascial sutures. Later, these sutures can be used to close the abdominal wall. The insufflation tubing is attached to the sideport of the trocar, and the abdomen is insufflated rapidly to 15 mm Hg.

Newer trocars, called *optical trocars*, allow visualization of the tip of the trocar as it passes through the layers of the abdominal wall (Fig. 4-4). A straight-viewing 0-degree scope is placed inside a clear trocar that is available with and without a bladed tip. Safe introduction of an optical trocar is a skill that requires judgment and experience and can best be learned in patients with no prior surgery after insufflation is established. Success depends on the operator's ability to see each of the layers of tissue, although visualization does not imply safety.<sup>26</sup> It is useful for the surgeon to have command of several access techniques because there is no single technique that is best for all circumstances.<sup>27</sup>

## Difficult Access

Access can be the most challenging aspect of the procedure in some patients no matter which technique is used. This is especially true in obese patients. First, the site of the central scar is often judged inaccurately because the umbilicus is in a caudad position owing to the loose panniculus. Additionally, there is an increased distance between the skin and the abdominal wall fascia. The Veress needle may not penetrate the abdominal wall. If an open-access technique is chosen, it may be difficult to expose the abdominal wall through a small incision. Degenerated fascia in obese patients will make the abdominal wall bounce against the needle or finger,



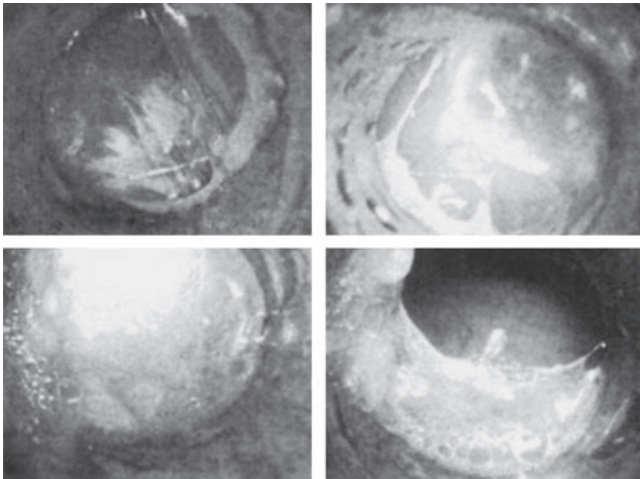



FIGURE 4-4 Optical trocar. (Used with permission of Ethicon.)

making its identification difficult. Raising the skin with penetrating towel clips does not facilitate this exposure and, in fact, distorts the anatomy, making it more difficult to identify the fascia. Sometimes a modified technique described by Vakili and Knight can be helpful.<sup>28</sup> This is a combination of open and Veress techniques in which a small skin incision is made in obese patients. Kochers are used to hold the abdominal wall fascia up, and a Veress needle is passed through the abdominal wall.

Access is also difficult in patients who have had prior surgery through a midline incision. In these patients, it is unsafe to perform the Hasson technique through the midline site because of the potential for adhesions of bowel to the posterior surface of the abdominal wall. Injury can occur when dividing the fascia or when sweeping adhesions away with a finger. It is difficult to perform the open technique at sites other than the umbilicus because of the multiple layers of the abdominal wall. In these patients, we prefer to place the Veress needle in the next safest location, which is the left upper quadrant along the

costal margin. One must be certain that the table is flat because the spleen and liver are injured more easily in patients in the reverse Trendelenburg position. One must be certain that the stomach is decompressed with an orogastric tube before inserting the Veress needle in the left upper quadrant. Once insufflation is obtained, a port can be placed into the abdomen away from the previously operated field. We prefer entering with a 5-mm step port followed by a 30-degree 5-mm scope. Other surgeons recommend use of optical trocars in this situation.

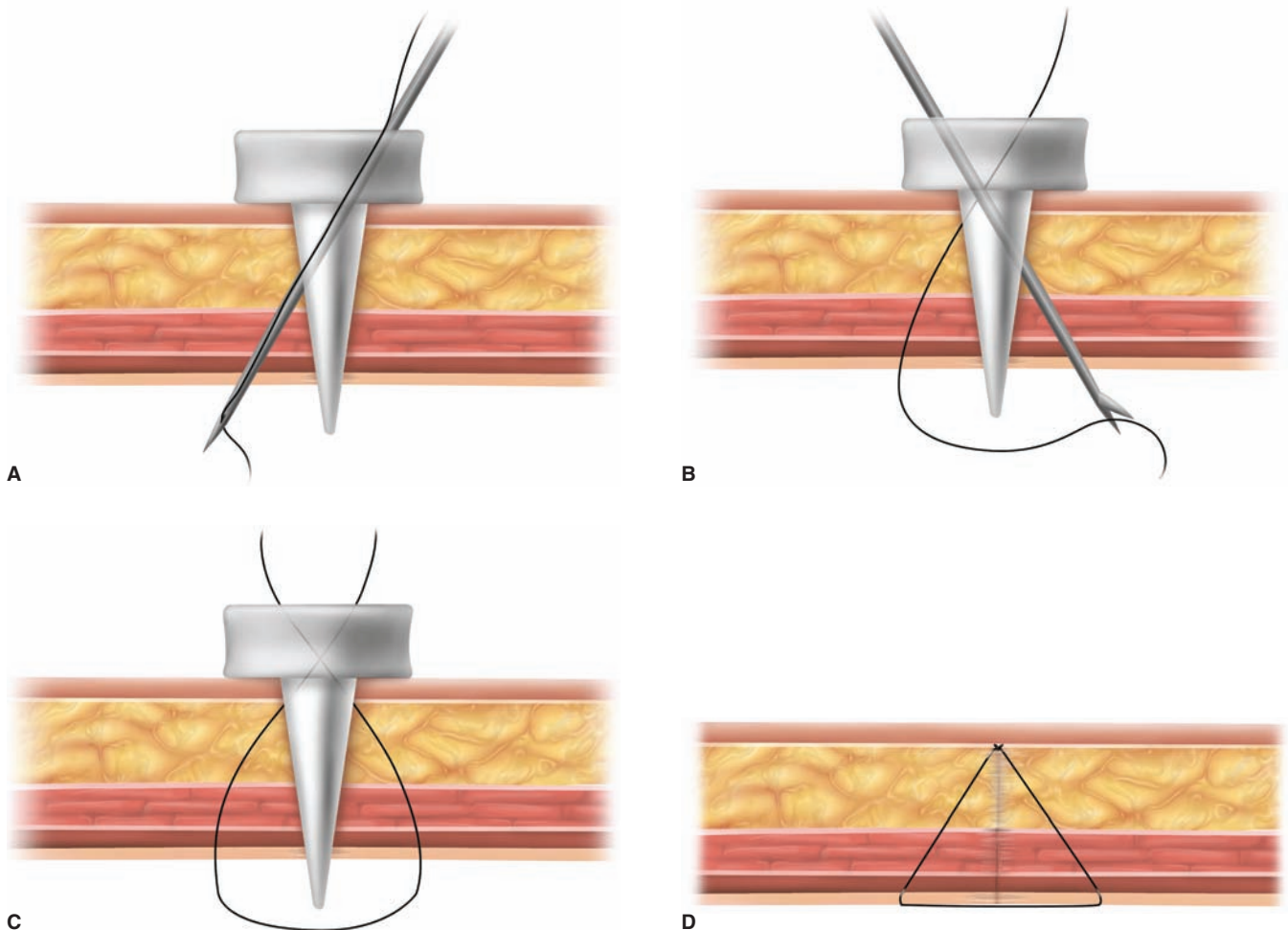
## Fascial Closure

Care should be taken to prevent port-site hernias, which occur in 0.65–2.80% of laparoscopic gastrointestinal operations,<sup>29</sup> because they can lead to bowel obstruction, incarceration, and/or Richter's hernias. All defects created with a 10-mm or greater bladed trocar should be closed, although this is not necessary when using some of the newer nonbladed trocars that create smaller fascial defects.<sup>30,31</sup> Most 5-mm defects do not require fascial closure in adults, although there are reported cases of hernias at these sites.<sup>9,32,33</sup> Because there is always a possibility of formation of a port-site hernia, the smallest possible port always should be used. When a port is manipulated excessively or has to be replaced multiple times, there may be a larger than expected fascial defect that may require closure. Additional recommendations are to place ports lateral to the rectus muscles when possible.<sup>34</sup> At the conclusion of the procedure, removal of ports from the abdomen should be observed to be certain that omentum or abdominal contents are not brought up through the abdominal wall.

Fascial closure can prevent trocar-site hernia.<sup>35</sup> A number of port-site closure devices have been developed<sup>36</sup> because small laparoscopic incisions make it difficult to close the abdominal wall with round needles. The closure devices function like crochet needles, passing a suture through the abdominal wall on one side of the fascial incision. The suture end is released intra-abdominally under laparoscopic visualization, and the needle is removed. The needle is replaced (without suture) on the other side of the incision, and the free end is secured and pulled back out through the abdominal wall. A knot is then tied that closes the trocar site, as viewed laparoscopically (Fig. 4-5).

## Trocar Injury

The overall risk of a trocar injury to intra-abdominal structures is estimated to be between 5 in 10,000 and 3 in 1,000.<sup>14</sup> Almost all injuries occur during primary trocar insertion. According to Chandler and colleagues,<sup>13</sup> the most commonly injured organ is the small bowel (25.4%), followed by the iliac artery (18.5%), colon (12.2%), iliac vein (8.9%), mesenteric vessels (7.3%), and aorta (6.4%). All other organs were injured less than 5% of the time. The mortality from trocar injury is 13%, with 44% owing to major vessel injury, 26% to bowel injury with delayed diagnosis, and 20% to small



**FIGURE 4-5** Using the Inlet device, the suture is passed through the abdominal wall on one side of the fascial incision. The suture end is released intra-abdominally under laparoscopic visualization, the suture then is pulled out on the other side of the incision using the device, and a knot is tied.

bowel injury. Major vascular injuries are noticed immediately and require rapid conversion to laparotomy. They are managed by applying pressure when possible to allow the anesthesia team to maintain and correct volume and prepare for rapid blood loss. Then the surgeon gets control of inflow and outflow to permit repair of the injury. Unfortunately, many bowel injuries are not recognized at the time of the procedure, and nearly half are not noticed until more than 24 hours postoperatively. This obviously leads to severe sequelae and may be prevented by careful dissection and inspection at the conclusion of the procedure.


## EQUIPMENT

### Telescope

Laparoscopic and thoracoscopic telescopes come in a variety of shapes and sizes, offering several different angles of view. The standard laparoscope consists of a metal shaft

24 cm in length containing a series of quartz-rod lenses that carry the image through the length of the scope to the eyepiece. The telescope also contains parallel optical fibers that transmit light into the abdomen from the light source via a cable attached to the side of the telescope. Telescopes offer either a straight-on view with the 0 degree or can be angled at 25–30 or 45–50 degrees. The 30-degree telescope provides a total field of view of 152 degrees compared with the 0-degree telescope, which only provides a field of view of 76 degrees (Fig. 4-6).

The most commonly used telescope has a diameter of 10 mm and provides the greatest light and visual acuity. The next most commonly used telescope is the 5-mm laparoscope, which can be placed through one of the working ports for an alternative view. Smaller-diameter laparoscopes, down to a 1.1-mm scope, are available and are used mostly in children. They are not used commonly in adult patients because of an inability to direct enough light into the larger abdominal cavity. The camera is attached to the eyepiece of the laparoscope for processing.



**FIGURE 4-6** The 30-degree telescope (top) provides a total field of view of 152 degrees compared with the 0-degree telescope (bottom), which provides a field of view of only 76 degrees. (Used with permission of Storz.)

## Video Camera

A high-resolution video camera is attached to the eyepiece of the telescope and acquires the image for projection on the monitor. The video image is transmitted via a cable to a video unit, where it is processed into either an analog or a digital form. Analog is an electrical signal with a continuously varying wave or shift of intensity or frequency of voltage. Digital is a data signal with information represented by ones and zeros and is interpreted by a computer. These are the methods by which the picture is transmitted to the video monitor. The camera and cable are designed so that they can be sterilized in glutaraldehyde.

The camera iris directly controls the amount of light processed by opening the aperture of the camera. The gain controls the brightness of the image under conditions of low light by recruiting pixels to increase signal strength. Clearly, this step results in some loss of image resolution. This increases light but results in a grainy picture with poorer resolution. It also may create a loss of color accuracy owing to amplification of the noise-to-signal ratio.

## Light Sources

High-intensity light is created with bulbs of mercury, halogen vapor, or xenon. The bulbs are available in different wattages—150 and 300 W—and should be chosen based

on the type of procedure being performed. Because light is absorbed by blood, any procedure in which bleeding is encountered may require more light. We use the stronger light sources for all advanced laparoscopy. Availability of light is a challenge in many bariatric procedures where the abdominal cavity is large. The light is carried to the fiberoptic bundles of the laparoscope via a fiberoptic cable. The current systems create even brightness across the field.

## Insufflators

An insufflator delivers gas from a high-pressure cylinder to the patient at a high rate with low and accurately controlled pressure. Some insufflators have an internal filter that prevents contamination of the insufflator with the gas from the patient's abdomen and similarly filters any particulate matter that may be freed from the inside of an aging gas cylinder. Others require use with disposable insufflator tubing that has a filter on it. Some insufflators provide heated or humidified gas, but clinical benefit to these theoretically desirable features has not yet to be proven.

## Video Monitors

High-resolution video monitors are used to display the image. Optimal monitor size varies but ranges from 19 to 21 in. Smaller monitors may be used if placed close to the operative field. Larger monitors provide little advantage outside of a display setting. Cathode-ray monitors (analog) are being replaced rapidly by flat-panel (digital) displays with excellent color and spatial resolution. These monitors may be positioned optimally when hung from the ceiling on light booms.

## INSTRUMENTATION

The instruments used in laparoscopic surgery are similar to those of open surgery at the tips but are different in that they are attached to a long rod that can be placed through laparoscopic ports. Standard-length instruments possess a 30-cm-long shaft, but longer instruments (up to 45 cm in length) have been developed for bariatric surgery. The handles come in many varieties and must be chosen based on comfort and ergonomics, as well as the need for a locking or nonlocking mechanism. The shaft of most hand instruments is 5-mm wide; however, some specialized dissectors are available only in a 10-mm width. Pediatric laparoscopy instrumentation is generally 2–3 mm in diameter (Fig. 4-7). Bowel graspers come in a wide variety with different types of teeth (Fig. 4-8). The most atraumatic grasper has small, smooth teeth like a Debakey forceps. This has the advantage of not tearing the tissues and can be used on almost all organs. We use the Hunter



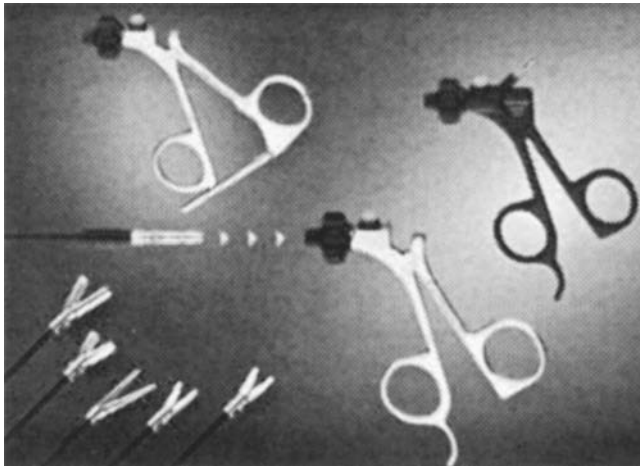


FIGURE 4-7 Instrument handles and tips. (Used with permission of Storz.)

grasper (Jarit), which, like a Debakey, can be used to grasp bowel and also can be used to grasp a needle. An additional benefit is that the tip is blunt and not prone to causing tissue trauma. Another commonly used bowel grasper is the Glassman (Storz), which is atraumatic and is slightly longer than the standard-sized Hunter grasper. It is fenestrated and cannot be used to grasp a needle. For some tissues, these instruments do not “grip” well enough, and bigger teeth or a different tip, such as those of Allis and Babcock clamps, is preferred. We reserve these larger-toothed instruments only for organs that are being removed, such as the gallbladder, or for thicker tissue, such as the stomach. The rule is to be gentle because small injuries can take a relatively long time to fix laparoscopically.

The most commonly used dissector is the Maryland dissector (Fig. 44-9). It is useful for dissecting small ductal structures such as the cystic duct and can be used when dissecting vessels. Another use for the Maryland dissector is that it can be attached to monopolar cautery and used to grasp and cauterize a bleeding vessel (this should not be done with bowel graspers). The Maryland dissector should not be used to grasp delicate tissue because too much pressure is applied over a very small area, much like erroneously using a Kelly clamp for grasping tissue. Very delicate right-angle dissectors can be used for renal, adrenal, and splenic vessels and are less traumatic than the Maryland dissector because there are no ridges.



FIGURE 4-8 Atraumatic bowel graspers.



FIGURE 4-9 Maryland dissector.

## Hemostasis

Hemostasis can be achieved using current from a monopolar electro-surgical generator applied to common instruments and controlled with a foot pedal. One of the most useful instruments for dissection is a disposable hook attached to the hand-held Bovie device for dissection (Valley Labs/Conmed and others). If a vessel has been transected and is bleeding but is too large to control with monopolar electro-surgery, a pretied lassolike suture (Endo-loop, Ethicon Endosurgery) can be helpful. Laparoscopic clips are handy for small identifiable vessels but should not be used when a vessel is not identified. The clip is only 7 mm in length and is not useful for vessels larger than this. When the vessel is not clearly identified but the bleeding site is, ultrasonic shears and some bipolar instruments such as the LigaSure device (Covidien, Mansfield, MA) can be helpful. These instruments have the advantage of facilitating dissection while providing hemostasis for larger bleeding vessels.

## Monopolar Electro-surgery

Although hemostasis is obtained using the same electro-surgical generator that is used in open surgery, there are hazards that are unique to minimally invasive surgery. The most frequently used method of delivering electro-surgery is monopolar. The desired surgical effect is hemostasis, and this is obtained by production of heat. Alternating current at 50,000 Hz (household current is 60 Hz) is generated and travels through an active electrode. The active electrode can be a Bovie tip in open surgery or, in laparoscopy, an instrument that is connected to the generator by the monopolar cord. The current passes into the target tissue at sufficiently high current density to cause a great deal of heat. Depending on tissue heating, coagulation, fulguration, or vaporization of the tissue occurs. The circuit is completed by the return of the electrons broadly spread through the tissue (insufficiently dense to cause any adverse effect) back to the generator via the return electrode (grounding pad).



In open surgery, monopolar current sometimes is passed from the active electrode (Bovie tip) to the patient via another conductive instrument, the forceps. This is called *direct coupling*. In laparoscopy, it is not prudent to touch the active electrode (an activated instrument) on or near other conductive instruments within the abdominal cavity, that is, the laparoscope or other working instruments. Direct coupling in minimally invasive surgery always should be avoided because injury may occur out of the surgeon's field of view. It is also not prudent to activate the generator in "midair" because the current may travel out of the surgeon's field of view to a crack in the insulation of a laparoscopic instrument. This results in transfer of current to a small area that generates heat and can produce an injury. All laparoscopic instruments should be checked for cracks in the insulation before being used.

## Ultrasonic Shears

Before the introduction of ultrasonic shears, larger vessels had to be tied off individually. This was very tedious laparoscopically, especially with the division of short gastric vessels during fundoplication. The development of the ultrasonic shears was revolutionary, allowing surgeons to divide larger vessels quickly and dissect simultaneously. Ultrasonic energy or sound waves are used to ablate, cauterize, and cut tissues. A generator produces a 55.5-kHz (55,500 Hz) electrical signal that travels via a cable to a piezoelectric crystal stack mounted in the transducer. The crystal stack converts the electrical signal to mechanical vibration at the same frequency. The ultrasonic vibration is amplified as it traverses the length of the titanium probe that is the active blade of the scalpel. Shearing forces separate tissue and heat the surrounding tissue, thereby coagulating and sealing blood vessels without burning. Damage to adjacent tissues is low, although the active blade can become quite hot, and burn injuries can occur.

## Bipolar Electrosurgery

Bipolar electrosurgery coagulates tissue by passing a high-frequency, low-voltage electric current between two directly apposed electrodes. Laparoscopic general surgeons use it much less frequently because an additional maneuver must be made to divide the tissue. The LigaSure, a newer bipolar device, coagulates larger vessels (up to 7 mm in diameter) and seals tissue and has a knife available for subsequent division of the tissue between the jaws of the forceps. The instrument makes a sound when the tissue within the jaw has been coagulated safely. The advantage is that division of larger vessels can be performed safely. Unfortunately, it is relatively slow to use as a dissecting instrument, and the tip is not very useful for dissection because it is straight and wide.<sup>37</sup> It does not produce a large amount of heat, and damage to surrounding tissues is low.

## SUTURING

Intracorporeal suturing may be out of the realm of the fundamentals of a laparoscopic surgery chapter. However, obtaining this skill is critical for successful performance of many laparoscopic procedures. A fundamental skill of laparoscopic surgery is the ability to place a suture accurately and tie a knot with a needle holder and a standard surgical suture. This skill can be mastered easily with a training box. Various suture aids have been developed, such as the EndoStitch (USSC), and can be used as a substitute. However, these devices are expensive, and the range of suture and needle sizes and types is limited. Many surgeons believe that an extracorporeal knot is acceptable because it is easier to create a knot outside the patient and slide it down with a knot pusher. In most settings, this is not true because securing an extracorporeal knot creates "sawing" of the tissue as the suture is pulled through or around it. This often results in tissue tearing. For interrupted suturing, the sliding square knot is the simplest most secure knot to master (Fig. 4-10).

## THE PHYSIOLOGIC EFFECTS OF PNEUMOPERITONEUM

The pneumoperitoneum has many effects that are only partially known despite years of study in humans and in animal models. There are effects resulting from the pressure within the abdomen and effects resulting from the composition of the gas used, generally CO<sub>2</sub>.

The pressure within the abdomen from pneumoperitoneum decreases venous return by collapsing the intra-abdominal veins, especially in volume-depleted patients. This decrease in venous return may lead to decreased cardiac output. To compensate, there is an elevation in the heart rate, which increases myocardial oxygen demand. High-risk cardiopulmonary patients cannot always meet the demand and may not tolerate a laparoscopic procedure.<sup>38</sup> In volume-expanded healthy patients with full intra-abdominal capacitance vessels (veins), the increased intra-abdominal pressure actually may serve as a pump that increases right atrial filling pressure.<sup>39</sup>

Through a different mechanism associated with catecholamine release triggered by CO<sub>2</sub> pneumoperitoneum, heart rate rises along with systemic vascular resistance. This may lead to hypertension and impair visceral blood flow. It is not uncommon after the induction of pneumoperitoneum for the heart rate to rise along with the mean arterial pressure. This leads to a minimal effect in a young, healthy patient<sup>40</sup>; however, in elderly, compromised patient, the strain on the heart can lead to hypotension, end-organ hypoperfusion, and ST-segment changes.

To minimize the cardiovascular effects of pneumoperitoneum, it is important that patients have adequate preoperative hydration. By insufflating the abdomen slowly, the vagal response to peritoneal stretching may be diminished and vagally mediated bradycardia avoided. Additionally, if cardiovascular effects are noted during insufflation or during the

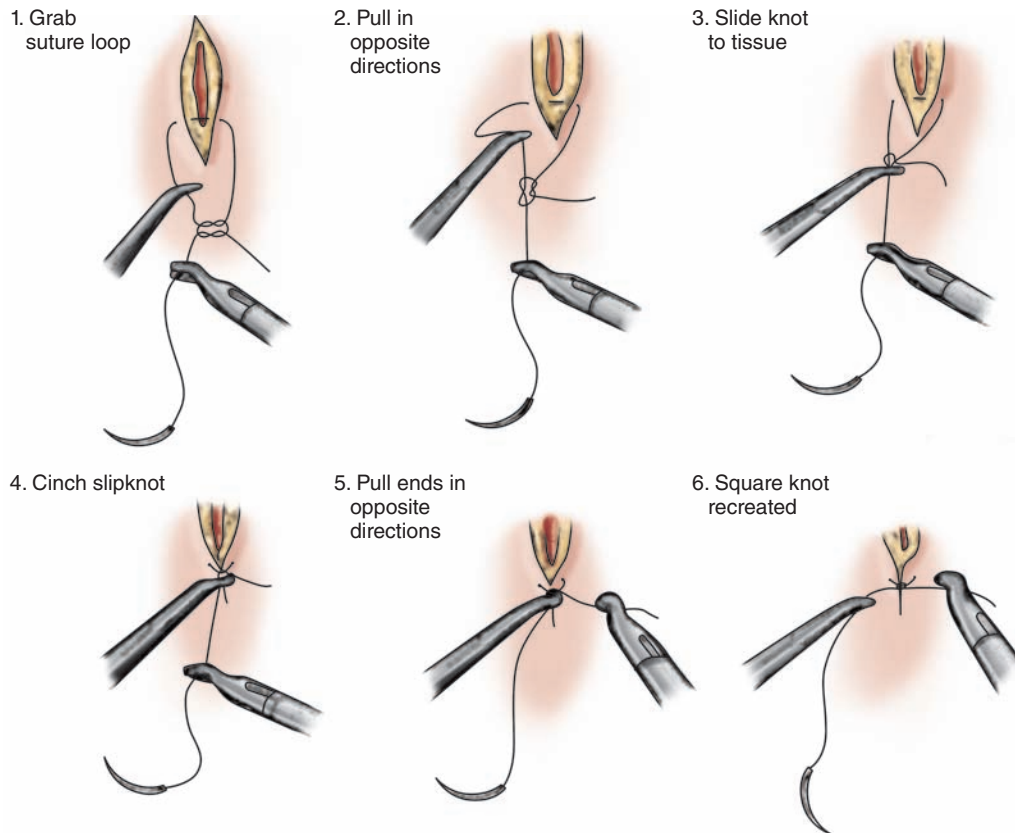


FIGURE 4-10 Suturing. (Reprinted with permission from Hunter JG, Terry. *Minimally invasive surgery: fundamentals*. In: Cameron JL, ed. *Current Surgical Therapies*. St. Louis: Mosby.)

maintenance of pneumoperitoneum, the insufflation pressures should be lowered from the usual 15 to 12 mm Hg, or pneumoperitoneum should be evacuated while the anesthesiologist sorts out the cardiovascular changes. Taking patients out of the steep reverse Trendelenburg position can help to increase venous return. Sometimes these effects can last for hours after desufflation.

The elevated intra-abdominal pressures restrict movement of the diaphragm, which reduces diaphragmatic excursion. This is represented as a decrease in functional residual capacity and pulmonary compliance and an increase in inspiratory pressure. Overall, there is no significant change in the physiologic dead space or shunt in patients without cardiovascular compromise. Bardoczky and colleagues studied seven healthy patients undergoing laparoscopy with CO<sub>2</sub> pneumoperitoneum.<sup>41</sup> After the induction of pneumoperitoneum, peak airway and plateau airway pressures increased by 50% and 81%, respectively. Bronchopulmonary compliance decreased by 47% during the period of increased intra-abdominal pressure. After desufflation, peak and plateau pressures remained elevated by 36% and 27%, respectively, for 2–6 hours. Compliance remained at 86% of the preinsufflation value.

Urine output often is diminished during laparoscopic procedures and usually is the result of diminished renal

blood flow owing to the cardiovascular effects of pneumoperitoneum and direct pressure on the renal veins.<sup>42</sup> In addition to direct effects, elevated intra-abdominal pressure results in release of antidiuretic hormone (ADH) by the pituitary, resulting in oliguria that may last 30–60 minutes after the pneumoperitoneum is released. Aggressive fluid hydration during pneumoperitoneum increases urine output.<sup>43</sup> Positional changes can affect the collection of urine in the Foley catheter and must be taken into consideration if anuria is noted.

## Carbon Dioxide–Related Effects

### HYPERCAPNIA

Hypercapnia and acidosis are seen with pneumoperitoneum and are likely due to the absorption of CO<sub>2</sub> from the peritoneal cavity. In the ventilated patient, increasing respiratory rate or vital capacity must compensate for these changes. At extremes, increases in tidal volume may risk barotraumas, and increases in respiratory rates diminish time for gas mixing, increasing dead-space ventilation. A first steady state in PaCO<sub>2</sub> is reached around 15–30 minutes after introduction of

the pneumoperitoneum. After this period, increases in PaCO<sub>2</sub> suggest that existing body buffers (>90% exist in bone) have been exhausted. Sudden increases may be related to port slippage and extraperitoneal or subcutaneous diffusion of CO<sub>2</sub>. This will resolve spontaneously once the port is repositioned.

Hypercapnia and acidosis that are difficult to control may follow, especially in elderly patients, those undergoing long operations, and patients with pulmonary insufficiency. Our response to this is to desufflate the abdomen for 10–15 minutes. If reinsufflation results in recurrent hypercapnia, then we change insufflation gases (see above) or convert to an open operation. Acidosis can persist for hours after desufflation. Other complications of pneumoperitoneum that are less frequent but may be life threatening include CO<sub>2</sub> embolism and capnothorax.

### CARBON DIOXIDE EMBOLUS

The incidence of clinically significant CO<sub>2</sub> embolism is very low, although recent reports using more sensitive tests suggest that tiny bubbles of gas are present commonly in the right side of the heart during laparoscopic procedures. Clinically important CO<sub>2</sub> embolism may be noted by unexplained hypotension and hypoxia during the operation. There is a characteristic millwheel murmur that can be detected with auscultation of the chest. This is produced by contraction of the right ventricle against the blood–gas interface. Usually the anesthesiologist notes an exponential decrease in the end-tidal CO<sub>2</sub>, which is consistent with complete right ventricular outflow obstruction. The mainstays of treatment are immediate evacuation of the pneumoperitoneum and placement of the patient in the left lateral decubitus, head down (Durant) position. This allows the CO<sub>2</sub> bubble to “float” to the apex of the right ventricle, where it is less likely to cause right ventricular outflow tract obstruction. It is important to administer 100% oxygen and hyperventilate the patient during this period. Additionally, aspiration of gas through a central venous line may be performed.

### CAPNOTHORAX/PNEUMOTHORAX

Capnothorax can be caused by CO<sub>2</sub> escaping into the chest through a defect in the diaphragm or tracking through fascial planes during dissection of the esophageal hiatus. It also can be due to opening of pleuroperitoneal ducts most commonly seen on the right side. Pleural tears during fundoplication can lead to pneumothorax, and additionally, the usual causes of pneumothorax, such as ruptured bullae, may be the etiology. The effects of CO<sub>2</sub> gas in the chest usually are noted as decreased O<sub>2</sub> saturation (a result of shunting induced by lung collapse), increased airway pressure, decreased pulmonary compliance, and increases in CO<sub>2</sub> and end-tidal CO<sub>2</sub>. The treatment is to desufflate the abdomen, stop CO<sub>2</sub> administration, correct the hypoxemia by adjusting the ventilator, apply positive end-expiratory pressure (PEEP), if possible, and decrease the intra-abdominal pressure as much as possible. The recommendation is to avoid thoracentesis because this usually resolves with anesthetic management. We generally evacuate the capnothorax directly at the end of the procedure with a red rubber catheter

placed across the diaphragm (through the pleural defect) and brought out a trocar site. The external end of the catheter is placed under water as the lung is inflated and then removed from the water when the bubbles stop. We do not obtain chest radiographs in the recovery room after these maneuvers if there is no evidence of hypoxia on 2 L/min of O<sub>2</sub> flow. Patients should be maintained on supplemental oxygen to help facilitate absorption of the CO<sub>2</sub> from the pleural space.

## CONCLUSIONS

Although minimally invasive surgery is firmly established in modern surgery, its safe performance can be ensured only with mastery of the basics. Basic skills used in laparoscopy include evaluation of a patient based on a new set of considerations, safe use of devices for abdominal access and instrumentation, and mastery of complex manual skills and intraoperative assessment of novel physiologic parameters. Laparoscopic surgery will only be employed more in the future as technical innovations allow us to care for our patients in new and better ways.

## REFERENCES

1. Tsereteli Z, Terry ML, Bowers SP, et al. Prospective, randomized clinical trial comparing nitrous oxide and carbon dioxide pneumoperitoneum for laparoscopic surgery. *J Am Coll Surg*. 2002;195:173–179; discussion 179–180.
2. Chopra R, McVay C, Phillips E, Khalili TM. Laparoscopic lysis of adhesions. *Am Surg*. 2003;69:966–968.
3. Marshall NJ, Bessell JR, Maddern GJ. Study of venous blood flow changes during laparoscopic surgery using a thermodilution technique. *ANZ J Surg*. 2000;70:639–643.
4. Okuda Y, Kitajima T, Egawa H, et al. A combination of heparin and an intermittent pneumatic compression device may be more effective to prevent deep-vein thrombosis in the lower extremities after laparoscopic cholecystectomy. *Surg Endosc*. 2002;16:781–784.
5. Prystowsky JB, Morasch MD, Eskandari MK, et al. Prospective analysis of the incidence of deep venous thrombosis in bariatric surgery patients. *Surgery*. 2005;138:759–763; discussion 763–755.
6. Goldfaden A, Birkmeyer JD. Evidence-based practice in laparoscopic surgery: perioperative care. *Surg Innov*. 2005;12:51–61.
7. Bisgaard T, Klarskov B, Kehlet H, Rosenberg J. Preoperative dexamethasone improves surgical outcome after laparoscopic cholecystectomy: a randomized, double-blind, placebo-controlled trial. *Ann Surg*. 2003;238:651–660.
8. Magner JJ, McCaul C, Carton E, et al. Effect of intraoperative intravenous crystalloid infusion on postoperative nausea and vomiting after gynaecological laparoscopy: comparison of 30 and 10 mL kg<sup>-1</sup>. *Br J Anaesth*. 2004;93:381–385.
9. Maharaj CH, Kallam SR, Malik A, et al. Preoperative intravenous fluid therapy decreases postoperative nausea and pain in high risk patients. *Anesth Analg*. 2005;100:675–682.
10. Epstein J, Arora A, Ellis H. Surface anatomy of the inferior epigastric artery in relation to laparoscopic injury. *Clin Anat*. 2004;17:400–408.
11. Hurd WW, Amesse LS, Gruber JS, et al. Visualization of the epigastric vessels and bladder before laparoscopic trocar placement. *Fertil Steril*. 2003;80:209–212.
12. Yim SF, Yuen PM. Randomized, double-masked comparison of radially expanding access device and conventional cutting tip trocar in laparoscopy. *Obstet Gynecol*. 2001;97:435–438.
13. Dabirashrafi H, Mohammad K, Tabrizi NM, et al. The use of Veress needle and 10-mm trocar (VN) versus direct trocar insertion (DTI) in the beginning of laparoscopy. *J Am Assoc Gynecol Laparosc*. 1994;1:59.

14. Chandler JG, Corson SL, Way LW. Three spectra of laparoscopic entry access injuries. *J Am Coll Surg*. 2001;192:478–490; discussion 490–471.
15. Hasson H. Open laparoscopy: a report of 150 cases. *J Reprod Med*. 1974;12:234–238.
16. Veress J. Neues Instrument Zur Ausführung von Brustoder Bauchpunktionen und Pneumothoraxbehund-lung. *Deutsch Med Wocheser*. 1938;64:1480–1481.
17. Vilos GA, Vilos AG. Safe laparoscopic entry guided by Veress needle CO<sub>2</sub> insufflation pressure. *J Am Assoc Gynecol Laparosc*. 2003;10:415–420.
18. Dingfelder JR. Direct laparoscope trocar insertion without prior pneumoperitoneum. *J Reprod Med*. 1978;21:45–47.
19. Clayman RV. The safety and efficacy of direct trocar insertion with elevation of the rectus sheath instead of the skin for pneumoperitoneum. *J Urol*. 2005;174:1847–1848.
20. Gunenc MZ, Yesildaglar N, Bingol B, et al. The safety and efficacy of direct trocar insertion with elevation of the rectus sheath instead of the skin for pneumoperitoneum. *Surg Laparosc Endosc Percutan Tech*. 2005;15:80–81.
21. Agresta F, De Simone P, Ciardo LF, Bedin N. Direct trocar insertion vs Veress needle in nonobese patients undergoing laparoscopic procedures: a randomized, prospective single-center study. *Surg Endosc*. 2004;18:1778–1781.
22. Jacobson MT, Osias J, Bizhang R, et al. The direct trocar technique: an alternative approach to abdominal entry for laparoscopy. *JLS*. 2002;6:169–174.
23. Rumstadt B, Sturm J, Jentschura D, et al. Trocar incision and closure: daily problems in laparoscopic procedures—a new technical aspect. *Surg Laparosc Endosc*. 1997;7:345–348.
24. Champault G, Cazacu F, Taffinder N. Serious trocar accidents in laparoscopic surgery: a French survey of 103,852 operations. *Surg Laparosc Endosc*. 1996;6:367–370.
25. Saville LE, Woods MS. Laparoscopy and major retroperitoneal vascular injuries (MRVI). *Surg Endosc*. 1995;9:1096–1100.
26. Sharp HT, Dodson MK, Draper ML, et al. Complications associated with optical-access laparoscopic trocars. *Obstet Gynecol*. 2002; 99:553–555.
27. Corson SL, Chandler JG, Way LW. Survey of laparoscopic entry injuries provoking litigation. *J Am Assoc Gynecol Laparosc*. 2001;8:341–347.
28. Vakili C, Knight R. A technique for needle insufflation in obese patients. *Surg Laparosc Endosc*. 1993;3:489–491.
29. Tonouchi H, Ohmori Y, Kobayashi M, Kusunoki M. Trocar site hernia. *Arch Surg*. 2004;139:1248–1256.
30. Liu CD, McFadden DW. Laparoscopic port sites do not require fascial closure when nonbladed trocars are used. *Am Surg*. 2000;66:853–854.
31. Bhojru S, Payne J, Steffes B, et al. A randomized, prospective study of radially expanding trocars in laparoscopic surgery. *J Gastrointest Surg*. 2000;4:392–397.
32. Kwok A, Lam A, Ford R. Incisional hernia in a 5-mm laparoscopic port-site incision. *Aust NZ J Obstet Gynaecol*. 2000;40:104–105.
33. Reardon PR, Preciado A, Scarborough T, et al. Hernia at 5-mm laparoscopic port site presenting as early postoperative small bowel obstruction. *J Laparoendosc Adv Surg Tech A*. 1999;9:523–525.
34. Montz FJ, Holschneider CH, Munro M. Incisional hernia following laparoscopy: a survey of the American Association of Gynecologic Laparoscopists. *J Am Assoc Gynecol Laparosc*. 1994;1:S23–S24.
35. Lowry PS, Moon TD, D'Alessandro A, Nakada SY. Symptomatic port-site hernia associated with a non-bladed trocar after laparoscopic live-donor nephrectomy. *J Endourol*. 2003;17:493–494.
36. Di Lorenzo N, Coscarella G, Liroi F, Gaspari A. Port-site closure: a new problem, an old device. *JLS*. 2002;6:181–183.
37. Carbonell AM, Joels CS, Kercher KW, et al. A comparison of laparoscopic bipolar vessel sealing devices in the hemostasis of small-, medium-, and large-sized arteries. *J Laparoendosc Adv Surg Tech A*. 2003;13:377–380.
38. Gebhardt H, Bautz A, Ross M, et al. Pathophysiological and clinical aspects of the CO<sub>2</sub> pneumoperitoneum (CO<sub>2</sub>-PP). *Surg Endosc*. 1997;11:864–867.
39. Kashtan J, Green JF, Parsons EQ, Holcroft JW. Hemodynamic effect of increased abdominal pressure. *J Surg Res*. 1981;30:249–255.
40. Larsen JF, Svendsen FM, Pedersen V. Randomized clinical trial of the effect of pneumoperitoneum on cardiac function and haemodynamics during laparoscopic cholecystectomy. *Br J Surg*. 2004;91:848–854.
41. Bardoczky GI, Engelman E, Levarlet M, Simon P. Ventilatory effects of pneumoperitoneum monitored with continuous spirometry. *Anaesthesia*. 1993;48:309–311.
42. Ninomiya K, Kitano S, Yoshida T, et al. Comparison of pneumoperitoneum and abdominal wall lifting as to hemodynamics and surgical stress response during laparoscopic cholecystectomy. *Surg Endosc*. 1998;12:124–128.
43. Demyttenaere SV, Feldman LS, Bergman S, et al. Does aggressive hydration reverse the effects of pneumoperitoneum on renal perfusion? *Surg Endosc*. 2006;20:274–280.



# LAPAROSCOPIC STAGING AND APPROACHES TO CANCER

Kevin C. Conlon • Tom K. Gallagher

## INTRODUCTION

The role of laparoscopy in the staging of gastrointestinal malignancy has continued to evolve over the last decade. Improvements in noninvasive diagnostic modalities have led to a more selective approach being adopted. Nonetheless, minimally invasive surgical techniques for staging and palliative bypass continue to play an important role in the staging and management of patients with upper gastrointestinal malignancies.

## RATIONALE FOR LAPAROSCOPIC STAGING

As the multidisciplinary management of gastrointestinal cancer has evolved over the last decade, an accurate extent of disease workup has become essential to treatment planning. Staging procedures should accurately define the extent of disease, direct appropriate therapy, facilitate the use of adjuvant therapies and avoid unnecessary interventions in a safe and cost-efficient fashion.

Recent advances in radiology have provided many noninvasive tools, such as multidetector computed tomographic (CT) scanning, magnetic resonance imaging (MRI) and combined CT with positron-emission tomographic (CT/PET) scanning, that have had a considerable impact on the extent of disease workup. Unfortunately, these modalities may underestimate the extent of disease, with small-volume metastatic disease being appreciated only at open surgical exploration. For over 100 years, laparoscopy has been suggested as a means for identifying such small-volume disease. Recently, a significant amount of data has been produced to suggest that the use of laparoscopy and laparoscopic ultrasound (LUS) in the staging of gastrointestinal malignancies has an impact on overall management.<sup>1-7</sup> The aim of laparoscopic staging (LS) is to mimic staging at open exploration while minimizing morbidity, enhancing recovery, and thus allowing for

quicker administration of adjuvant therapies if indicated. Proponents believe that LS should be viewed as complementary and not as a replacement for other staging modalities such as CT scanning, MRI, or PET scanning. In simplistic terms, the advantages of laparoscopy are that it allows the surgeon to visualize the primary tumor, determine vascular involvement, identify regional nodal metastases, detect small-volume peritoneal/liver metastases, and obtain tissue for histologic diagnosis.

## SURGICAL TECHNIQUE FOR LAPAROSCOPIC STAGING

Laparoscopic staging can be performed immediately before a planned open procedure or at a separate occasion. We have moved to the latter approach in the main because of logistical concerns around the availability and utilization of operating time. Generally the procedure is performed as an ambulatory/outpatient procedure with excellent patient satisfaction.

Laparoscopic staging usually is performed under general anesthesia with the patient positioned supine on the operating table. A warming blanket is placed underneath the patient, who is secured appropriately to the table with padding over the pressure points.

The following operative equipment is considered necessary for the procedure:

1. A 30-degree angled laparoscope either 5 or 10 mm in diameter
2. Five-millimeter laparoscopic instruments, including a Maryland dissector, a blunt-tip dissecting forceps, a cup/biopsy forceps, atraumatic grasping forceps, a liver retractor, and scissors
3. A 5- or 10-mm suction/irrigation device
4. An LUS probe (optional)

In general, we prefer a multiport technique. Access is gained into the peritoneal cavity using a blunt port placed

subumbilically by direct cutdown. By using forceps to grasp the fascial layers, retractors can be avoided and the wound size minimized. An alternative approach, particularly in patients with previous midline incisions, is to place the initial port in either the right or the left upper quadrant of the abdomen. Many surgeons prefer to use a Veress needle to achieve pneumoperitoneum prior to placing the surgical ports. In this case, care should be exercised to avoid visceral or vascular injury. Laparoscopic access using an optical trocar, which combines the advantages of the Hasson and Veress techniques, is a safe and feasible primary insertion method, which may alleviate this risk and is becoming an increasingly accepted technique.<sup>8</sup>

Pneumoperitoneum is achieved with CO<sub>2</sub> gas. Insufflation commences at a low flow rate until peritoneal entry is confirmed. An intraperitoneal pressure of 10–12 mm Hg is considered optimal. However, in patients with cardiopulmonary compromise, a lower maximum pressure may be chosen. A 5- to 10-mm 30-degree angled telescope is preferred, and systematic examination of the peritoneal cavity is performed. Additional trocars then are inserted under direct vision. Placement depends on the site of the primary tumor (ie, colonic, gastric, pancreatic, etc) and the findings at initial inspection (ie, whether obvious metastatic disease is present). In general, ports are placed along the planned open incision line (Fig. 5-1).

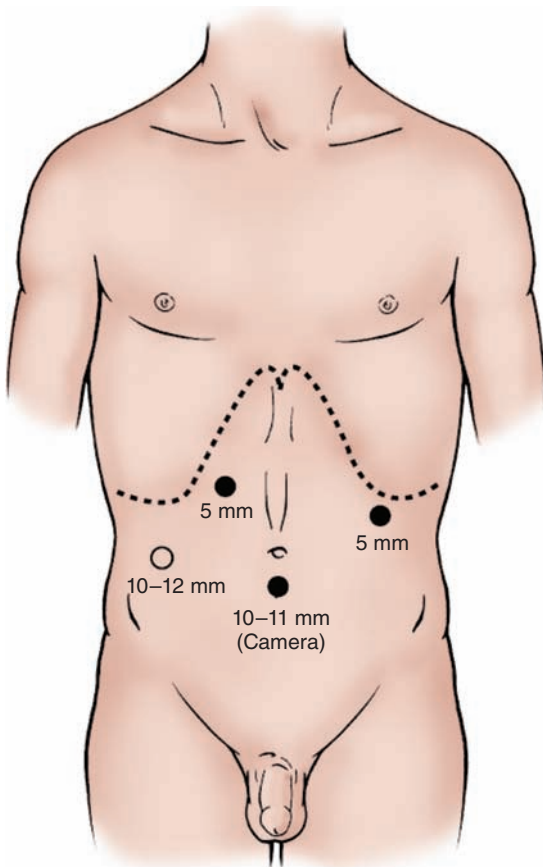


FIGURE 5-1 Port placement.

Following port placement, a detailed examination of the peritoneal cavity is performed in a similar fashion to an open exploration. The primary tumor is assessed. Any extension into contiguous organs can be identified. Following an initial survey, a systematic examination of the intra-abdominal viscera is performed commencing with the liver. To facilitate hepatic examination, the patient is placed in a 20-degree reverse Trendelenberg position with 10 degrees of left lateral tilt. The anterior and posterior surfaces of the left lateral segment of the liver are examined, followed by examination of the anterior and inferior surfaces of the right lobe. Despite the absence of tactile sensation, indirect palpation of the liver surface can be achieved by using two instruments (Fig. 5-2). A blunt suction device is particularly useful in compressing the liver tissue in order to detect small metastases. Improved visualization of diaphragmatic and posterior surfaces may be achieved by placing the camera in the right upper quadrant port. Any suspicious areas can be biopsied at this point. A cup biopsy forceps is the preferred instrument for obtaining adequate biopsies for diagnostic purposes. For this, we use a 5-mm biopsy forceps with a 2-mm cup as standard. Multiple samples may be taken to increase diagnostic yield. The cup is used to breach the liver capsule and a bite is taken out of the lesion. Further scoops can then be taken from the lesion and liver parenchyma as needed. Thorough hemostasis can easily be obtained with electrocautery or use of argon beam diathermy. If electrocautery is used, it is important to avoid direct coupling or capacitance coupling, which can lead to visceral injury. Direct coupling, when current flows directly from one instrument to the other, may occur when the instruments are too close together, especially if one is just outside of the field of view. Capacitance coupling occurs when two conductors have an insulator sandwiched between them. The high frequency AC current in the active conductor generates a magnetic field, which then induces current in the second conductor. Mixing of metal and plastic instruments and ports can lead to capacitance coupling and, at least in theory, severe burns. The incidence of complications is reduced by limiting

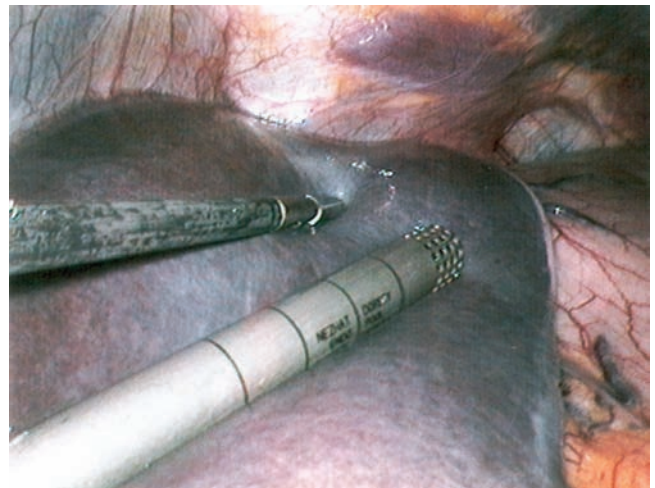


FIGURE 5-2 Examination of the liver.

the gain of electrocautery to 30 W and possibly by using plastic rather than metallic ports.

The hilus of the liver, hepatoduodenal ligament, and foramen of Winslow then are examined. Any abnormal lymphadenopathy can be identified. The suspicious node can be either excised or biopsied using the cup forceps. As in open surgery, care must be taken not to crush the node and possibly disseminate tumor cells during this procedure. In general, the duodenum is not mobilized. However, for patients with pancreatic or common bile duct tumors, close attention is paid to the presence or absence of tumor infiltration in the angle between the duodenum and the lateral aspect of the common bile duct because this may indicate significant vascular involvement.

The patient then is repositioned into a 10-degree Trendelenberg position without lateral tilt to facilitate examination of the transverse mesocolon and retroperitoneum. The omentum is retracted toward the left upper quadrant, elevating and enabling inspection of the transverse mesocolon and the ligament of Treitz. The mesocolon is inspected carefully with particular attention to the middle colic vein, which usually is visible. Any abnormal adenopathy or infiltration (Fig. 5-3) around the middle colic vein is noted and may be biopsied. For patients with an upper gastrointestinal primary tumor, the lesser sac is examined. To facilitate this maneuver, the patient then is returned to a supine position, the left lobe of the liver is elevated, and the gastrohepatic omentum is incised (Fig. 5-4). This exposes the caudate lobe of the liver, the inferior vena cava, and the celiac axis. If present, an aberrant left hepatic artery should be identified and preserved. Often, adhesions between the stomach and the pancreas require division to allow entry into the lesser sac. By elevating the stomach, the “gastric pillar” can be clearly identified (Fig. 5-5). This “pillar” contains the left gastric artery and vein. This structure followed down leads us to the celiac axis, and any suspicious nodal tissue can be biopsied. The hepatic artery also is identified and followed to the hepatoduodenal ligament. The anterior

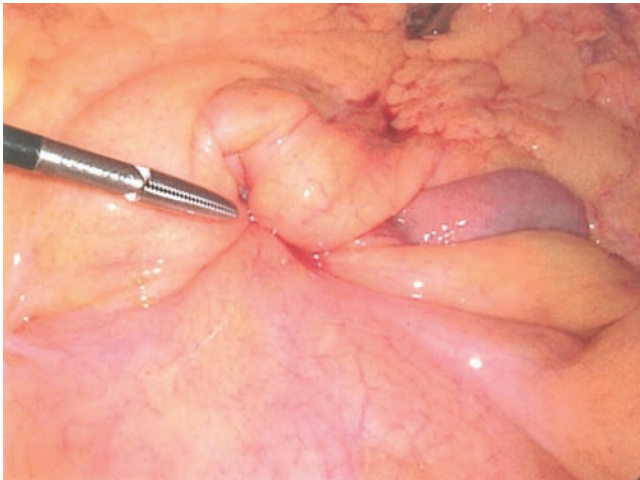


FIGURE 5-3 Infiltration of the colonic mesocolon.

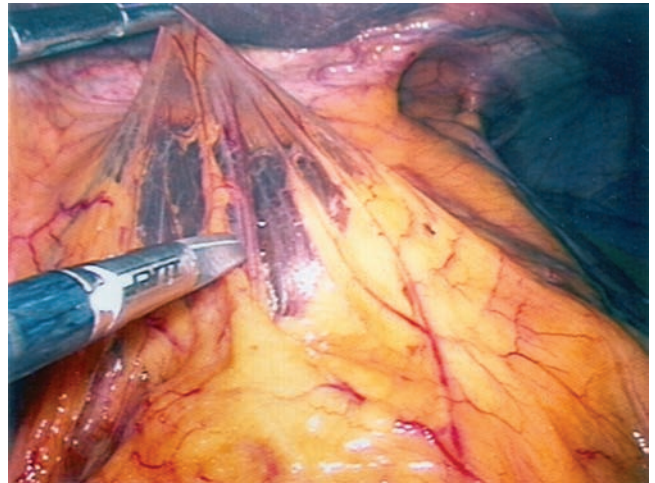


FIGURE 5-4 Incision of the gastrocolic omentum to gain access to the lesser sac.

aspect of pancreas, hepatic artery, and left gastric artery is also seen. Any suspicious periportal, hepatic, or celiac nodes can be biopsied.

The diagnostic yield for LS may be increased by performing peritoneal lavage cytology. In general, the specimens are taken at the start of the laparoscopy to avoid potential contamination following tumor manipulation or dissection. Between 200 and 400 mL of normal saline is instilled into the peritoneal cavity. The abdomen is agitated gently before aspiration. In pancreatic cases, samples are taken from the right and left upper quadrants. An additional sample is taken from the pelvis in patients with gastric cancer. Informing the pathologist/cytologist of the procedure timing and clinical question often leads to better clinical yields and is advisable prior to undertaking the laparoscopy.

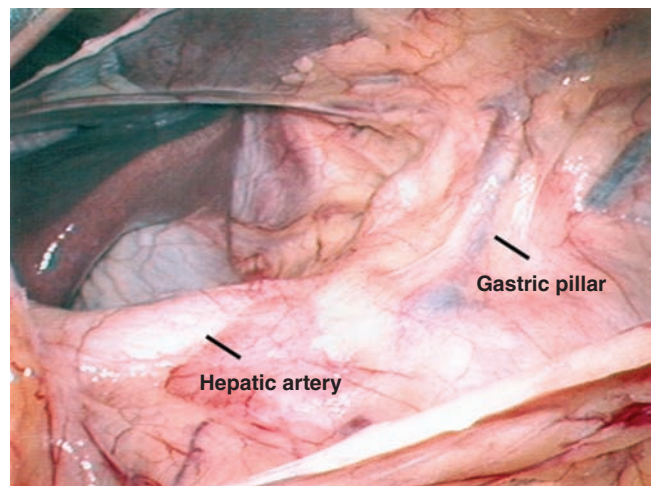


FIGURE 5-5 Lesser sac exposed. Solid arrow points to hepatic artery. Dashed arrow points to “gastric pillar.”



If available, LUS can be performed at this stage. Laparoscopy by its nature is a two-dimensional modality, with the result that appreciation of deep or subsurface lesions in solid organs is often suboptimal. LUS can partially overcome this deficiency. Transducers in clinical use employ either curved or linear-array technology and have a high-frequency performance with a range in the region of 6–10 MHz, allowing for high-resolution images to be obtained that can detect lesions from 0.2 cm in size. In addition, Doppler flow capability, if present, allows for accurate vessel identification and facilitates assessment of the tumor-vessel interface. The LUS probe is inserted via a 10- to 12-mm port, usually in the right upper quadrant.

The LUS is an invaluable tool for examination of the liver. Initially, the transducer is placed over the left lateral segment (Fig. 5-6), allowing assessment of segments I, II, and III. It is important that the probe is placed in direct contact with the liver surface to maximize acoustic coupling. Examination of the right lobe commences with the probe on the dome of the liver. The vena cava is visualized at the back and as the probe is moved forward slowly to identify the hepatic and portal veins. Within the liver, these can be identified by virtue of their surrounding fibrous sheath. The remaining hepatic segments (IV, V, VI, VII, and VIII) are examined by rotating the probe over the rest of the liver. Suspicious lesions can be biopsied either by fine-needle aspiration (FNA) or by percutaneously inserting core biopsy needles under LUS guidance. With the probe over segment V, the gallbladder is assessed, and with transverse placement of the probe over the hepatoduodenal ligament, the common hepatic duct, common bile duct, and hepatic arteries along with the portal vein can be identified (Fig. 5-7). The portal vein can be followed to its confluence with the splenic and superior mesenteric vein. The superior mesenteric artery also can be seen and its relationship to a pancreatic tumor, if present, determined. The pancreas can be examined, and any lesion can be identified.

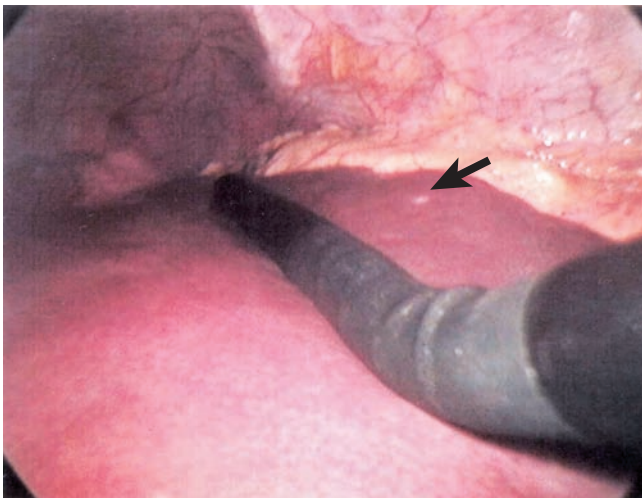


FIGURE 5-6 LUS examination of the liver. Note the superficial metastasis (solid arrow).

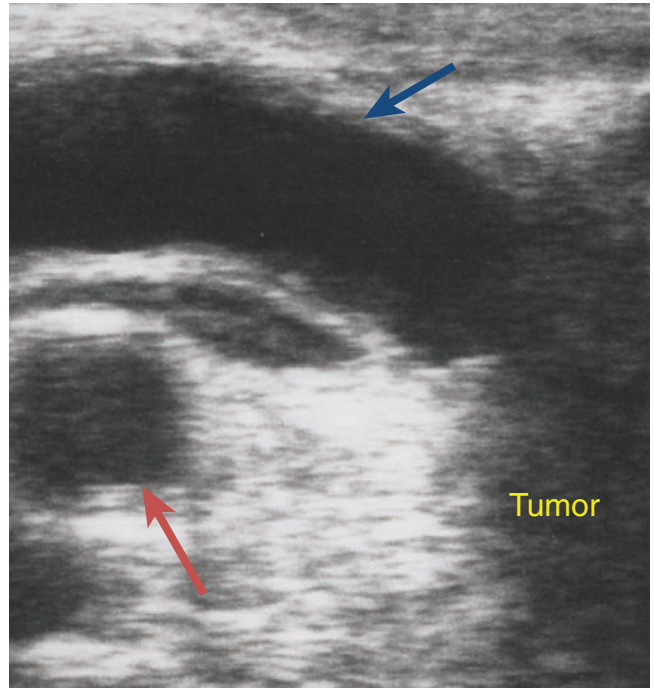


FIGURE 5-7 LUS examination of the retropancreatic structures. Red arrow points to superior mesenteric artery and blue arrow points to obstructed pancreatic duct secondary to a lesion in the head of the gland.

## ESOPHAGEAL CARCINOMA

Esophageal cancer is the eighth most common cancer and is the sixth leading cause of cancer death worldwide.<sup>9</sup> Esophageal cancer was diagnosed in 16,470 new patients in the United States in 2008, with an overall annual incidence of approximately 5.4 cases per 100,000 population.<sup>10</sup> It is estimated that more than 14,000 patients will die of this disease each year. Unfortunately, the prognosis remains poor; with an overall survival rate of approximately 5–10% in spite of the availability of new chemotherapeutic and biologic agents in both neoadjuvant and adjuvant settings. Surgical resection remains the treatment of choice for patients with localized disease. In addition, in the last few years, there has been a significant progress in palliative nonsurgical treatment options. Therefore, accurate staging for esophageal cancer is of paramount importance.<sup>7,11–14</sup>

Common diagnostic modalities are listed in Table 5-1. The results of a meta-analysis in 2008 suggest that endoscopic ultrasonography (EUS), CT, and fluorine-18-fluorodeoxyglucose (FDG)-PET each play a distinctive role in the detection of metastases in esophageal cancer patients. For the detection of regional lymph node metastases, EUS is most sensitive, whereas CT and FDG-PET are more specific tests. For the evaluation of distant metastases, FDG-PET has probably a higher sensitivity than CT.<sup>15</sup> These have been discussed in detail elsewhere in this book. Endoscopy remains the diagnostic gold standard. Biopsies can be



**TABLE 5-1: DIAGNOSTIC MODALITIES FOR STAGING ESOPHAGOGASTRIC CANCERS**

History and clinical examination
Ultrasonography
Endoscopic ultrasonography
MDR-computed tomography
Magnetic resonance imaging
Computed tomography/Positron emission tomography (CT/PET)
Laparoscopy
Laparoscopic ultrasonography

obtained and an assessment of local disease extent made. In patients considered unsuitable for surgical resection, a number of palliative options such as endoscopic dilation, laser ablation, or placement of luminal stents exist.

Multislice CT scanning of the thorax and abdomen is the radiologic staging modality of choice. The primary tumor can be visualized and metastatic disease detected. However, while data suggest that current-generation high-resolution multislice CT scanning is of significant value, its capacity to accurately T stage the disease and predict lymphatic and peritoneal spread remains between 65% and 80%.<sup>16</sup>

EUS enables detailed imaging of the esophageal wall, local lymph nodes, and contiguous structures, making it the ideal tool for tumor node metastasis (TNM) staging.<sup>11,12,17</sup> The shape, pattern, and demarcated borders of nodes are examined to assess metastatic potential.<sup>18,19</sup> EUS appears superior to CT scanning for locoregional staging.<sup>13,20</sup> Harewood and Wiersema from the Mayo Clinic compared the cost of EUS-FNA with CT-FNA and a surgical approach in staging patients with nonmetastatic esophageal cancer. They suggested that by avoiding unnecessary surgery, primarily by detecting celiac node involvement, EUS-FNA was the least costly strategy.<sup>21</sup>

It appears that combined CT scan and EUS is a better prediction of tumor resectability than CT scan alone (81% vs 65% with  $p < 0.05$ ) reported by de Graaf et al.<sup>22</sup> In a study of the impact of EUS-FNA in the management of patients with esophageal cancer, Morris et al found that EUS-FNA altered management in 28 (67%) patients and appeared to help direct patients toward appropriate treatment strategies including palliative and neoadjuvant therapies.<sup>23</sup> In a meta-analysis and systematic review of studies that included over 2500 patients, Puli et al<sup>24</sup> concluded that EUS performs better with advanced (T4) than early (T1) disease and that FNA substantially improves the sensitivity and specificity of EUS in evaluating N stage disease (from 84.7% [95% CI: 82.9–86.4] to 96.7% [95% CI: 92.4–98.9]). However, while most thoracic surgeons have embraced EUS-FNA as the most accurate locoregional staging modality in esophageal cancer, this attitude is not fully reflected in utilization patterns due to a lack of quality EUS services in some centers.<sup>25</sup>

Several studies have investigated the detection of the primary tumor by FDG-PET. Increased uptake of FDG was seen in 68–100% of the esophageal tumors.<sup>26–28</sup> Undetected

tumors are mostly stages T1 and T2. T1a tumors, remaining within the submucosa, are especially difficult to detect by FDG-PET.<sup>29–30</sup> Kato et al<sup>31</sup> found a significant relationship between the intensity of the primary tumor FDG-uptake, expressed as SUV, and the depth of the tumor invasion. However, Flamen et al<sup>32</sup> found no correlation between SUV and pT-stage.

To determine whether FDG-PET could delineate patients with esophageal cancer who may not benefit from esophagectomy after chemoradiotherapy, Monjazebe et al reviewed 163 patients with histologically confirmed stage I to IVA esophageal cancer receiving chemoradiotherapy with or without resection with curative intent and found that patients who achieved a complete response on FDG-PET imaging may not benefit from added resection given their excellent outcomes without resection.<sup>33</sup> These results should be validated in a prospective trial of FDG-PET-directed therapy for esophageal cancer.

It has been suggested that FDG-PET scanning has a role for the detection of metastatic disease and for restaging after neoadjuvant therapy or evaluation of recurrence. In the study by Flamen and colleagues, FDG-PET scanning had a significantly higher rate of detection of stage IV disease compared with the combination of CT scanning and EUS. It upstaged disease in 15% and downstaged disease in 7% of patients.<sup>32</sup> Other studies have reported similar results.<sup>34–36</sup>

In relation to the role of FDG-PET/CT in tumor delineation for radiotherapy, only three studies have reported a significant positive correlation between FDG-PET-based tumor lengths and pathological findings and so the authors of a systematic review on the role of FDG-PET/CT in tumor delineation and radiotherapy planning in patients with esophageal cancer concluded that standard implementation of FDG-PET/CT into the tumor delineation process for radiation treatment seems unjustified and needs further clinical validation first.<sup>37</sup>

Despite this increasingly sophisticated diagnostic armamentarium, between 15% and 20% of patients will continue to have radiologically occult peritoneal, nodal, or liver metastases detected at surgical exploration. Laparoscopy has been suggested as a means to detect such disease and thus exclude this cohort of patients from potentially ineffective treatment regimens.

The value of LS in esophageal cancer is accurate abdominal nodal staging and detection of occult distant metastases. The procedure also allows for more detailed assessment of the tumor looking for serosal involvement, local invasion, or peritoneal cavity, liver, and omental disease. In a comparison of LS and EUS for esophageal cancer, Kaushik et al found an overall staging accuracy of EUS compared with LS of 72%.<sup>38</sup> Staging differences were mostly reflected in distant metastases detected at LS (17%). The yield of LS appears to be determined at least in part by the site of disease, histologic cell type, and noninvasive stage. There are several observational studies reporting the usefulness of LS in both gastric and oesophageal cancers, the largest and most recent of which includes 416 consecutive patients undergoing staging laparoscopy.<sup>39</sup> The

authors report an 88% sensitivity of laparoscopy for resectability, with avoidance of unnecessary laparotomy in 20.2% of all patients. Staging laparoscopy was most useful in patients with adenocarcinoma, distal oesophageal, and gastroesophageal cancer, with percentage change in treatment decision of 21.9%, 17.1%, and 17.2%, respectively. No patients in this study with upper two-third lesions had their treatment decision changed by staging laparoscopy. This would be in accordance with the general trend in the literature that the more distal the tumor in the esophagus, the greater the risk and likelihood of intra-abdominal metastases<sup>40,41</sup> and this is likely related to lymphatic anatomy.

In a well-designed study, Samee et al report that the addition of LUS in the staging of esophagogastric cancers increases the detection rate of metastasis by 8% but that there is little impact on the false-negative rate.<sup>42</sup> In their retrospective case series of 320 patients, LUS proved most useful in detecting metastatic lymphadenopathy beyond the limits of curative resection and liver metastasis. The main benefit appears to be in the assessment of nodal disease, particularly in the celiac axis, hepatoduodenal ligament, and para-aortic area as disease in these sites accounts for more than 40% of the positive findings at laparoscopy.

The combination of endoscopic and laparoscopic ultrasonography (EUS-LUS) is accurate for resectability assessment of patients with esophageal cancer. In a series of 256 consecutive esophageal cancer patients, Mortenson et al demonstrated a statistically significant survival difference ( $p < 0.01$ ) between the different TNM stages and resectability groups predicted by a EUS-LUS combination.<sup>43</sup> The poor prognosis for the patients with irresectable or disseminated disease was accurately predicted by EUS and LUS.

The yield of LS appears to be determined at least in part by the site of disease, histologic cell type, and noninvasive stage. In an earlier review of 369 patients with carcinoma of the distal esophagus or gastric antrum, Dagnini and colleagues demonstrated occult disease in 33% at laparoscopy in patients with adenocarcinoma of either the distal esophagus or gastric cardia.<sup>44</sup> However, LS had a minimal impact for patients with squamous cell cancers in the upper third of the esophagus, changing management in only 3.5% of cases. Stein and colleagues reported similar results. At laparoscopy following radiologic staging, they found that 25% of patients with locally advanced (T3/T4) adenocarcinoma of the distal esophagus or gastric cardia had peritoneal or liver metastases.<sup>45</sup> Thus, for patients with squamous cell carcinoma of the esophagus, we believe that LS is not indicated in the absence of suspicious intra-abdominal imaging findings.

## GASTRIC CANCER

The overall incidence of gastric cancers is declining; however, there has been a relative increase in the incidence of tumors of the esophagogastric junction (OGJ) and gastric cardia. The peak incidence is in the seventh decade, and the disease is approximately twice as common in men as in women.<sup>46</sup>

Despite its apparent falling prevalence in the Western world, gastric cancer remains a significant public health problem and one of the leading causes of cancer death worldwide. The prognosis remains poor, with a current overall 5-year survival of 20%<sup>47</sup> and 50–90% of patients dying of the disease within 2 years of diagnosis, even in those who have undergone a potentially “curative” resection.<sup>48–50</sup> The poor outcome may be related in part to late presentation and inadequate staging and subsequent poor patient selection for surgery. Historically, following diagnosis and if medically fit, patients were subjected to open exploration for either resection or palliation. In a significant series of 916 patients in the mid-1990s, Pye and colleagues<sup>51</sup> reported that 23% of the operations were exploratory alone in nature. However, with the recent development of multidisciplinary approaches to the disease, improved staging, and the establishment of less invasive palliative algorithms, the need for operative intervention has been questioned.<sup>52–54</sup>

Accurate staging is essential for patient selection. A sophisticated and complex diagnostic armamentarium exists. While upper gastrointestinal endoscopy and biopsy remain the primary diagnostic tools, with multislice contrast-enhanced CT scanning, EUS, MRI, and CT/PET scanning being used increasingly for preoperative staging, laparoscopy and LUS continue to have an important role in the staging algorithm for selected patients with gastric cancer (Fig. 5-8).

While the literature would suggest that despite currently available imaging modalities, LS will continue to detect small-volume metastatic disease in 20–30% of cases, the identification of occult nodal disease remains problematic. EUS appears somewhat better than CT in this regard. Wakelin and colleagues have reported an overall accuracy of EUS in nodal staging for proximal or orogastric junction tumors of 72%.<sup>55</sup> If tumors that are nontraversable by endoscope are excluded, its accuracy increases by approximately 10%. Reported accuracy rates for laparoscopy and LUS vary from 60% to 90%. With LUS, direct biopsy of suspicious nodes can be obtained, which improves the utility of the modality. In distal gastric cancer, Finch and colleagues demonstrated an accuracy of 82% in T staging with the use of LUS.<sup>56</sup> This compares favorably with other studies looking at the use of EUS (83%) or CT scanning (66%) for T staging distal tumors.<sup>57</sup> In addition, the authors noted an accuracy rate of 89% for LUS in assessing lymph node status. In contrast, Wakelin noted that 38% of nodes were understaged. It would appear, therefore, that as with other ultrasound data, results are operator-dependent and reflect willingness or not to aggressively biopsy suspicious nodes.

While level I evidence does not exist for the use of LS in gastric cancer, a number of large single-institution studies have been carried out that allow us to make a number of conclusions regarding its role in the staging algorithm. As in esophageal cancer, laparoscopy will detect radiologically occult metastatic disease in a significant number of patients (Fig. 5-9). Muntean et al reported overall staging laparoscopy sensitivity for distant metastases of 89%, specificity 100%, and diagnostic accuracy 95.5%. The sensitivity for lymph node

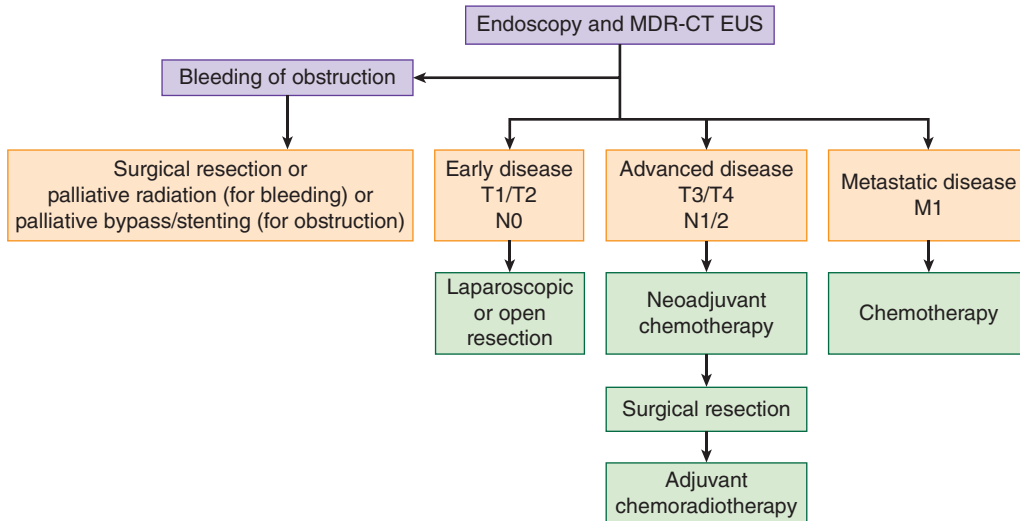


FIGURE 5-8 Treatment algorithm for gastric cancer.

metastases was 54.5%, with a specificity 100% and a diagnostic accuracy 64.3%. The positive predictive value for resectability was 96% and the negative predictive value was 50%.<sup>58</sup> Sotiropoulos et al reported that staging laparoscopy resulted in up staging 51.1% of patients, most commonly in the form of peritoneal seeding.<sup>59</sup> As a consequence, the therapy planning was changed and laparotomy was avoided in 14 of these patients as the first operative procedure. Sensitivity of clinical staging was especially poor for stage IV tumors

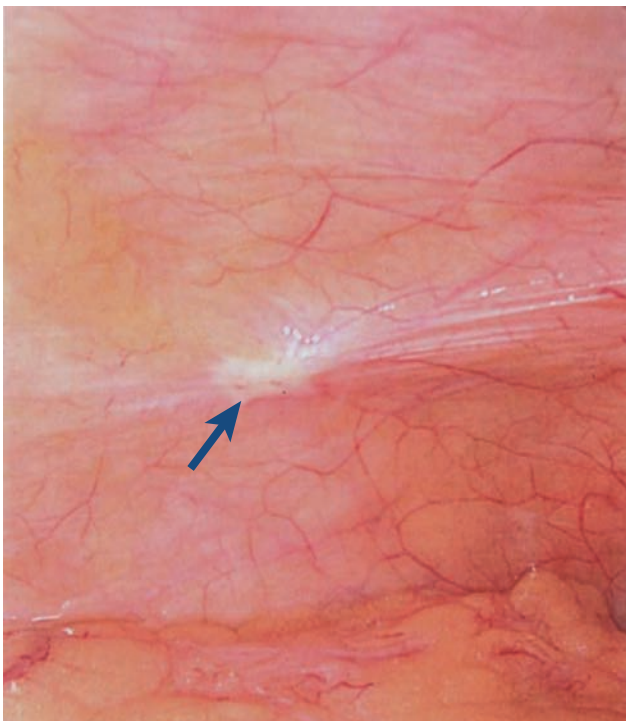

FIGURE 5-9 Peritoneal metastasis in gastric cancer.

(5.3%) and for the majority of stage IIIB tumors (42.9%) in this particular study.

It has been suggested that, with more advanced radiological imaging, the value of staging laparoscopy will somehow diminish; however, the literature has not borne this out. Kim et al retrospectively measured the diagnostic performance of prospective computed tomographic (CT) results obtained by using 16- or 64-detector row scanners in the detection of peritoneal metastases (PMs) in patients with advanced gastric cancer.<sup>60</sup> In 498 patients with T2 disease and above in a retrospective comparison of CT images with operative and pathological findings, a sensitivity and a specificity of 28.3% and 98.9%, respectively, were reported in scans demonstrating definite peritoneal deposits and 50.9% and 96.2% respectively in scans reported as equivocal. The authors concluded that even with modern CT techniques, the sensitivity for PM detection is limited. Similarly when evaluating preoperative local staging with 3D multidetector row CT, Chen et al reported that reconstructions yield significantly better overall accuracy than transverse images for tumor staging but not for lymph node staging.<sup>61</sup> This highlights the need for a multimodality staging process, including EUS, LS, and LUS.

As mentioned earlier, we routinely take peritoneal washings for cytologic examination at the time of LS. Positive cytology obtained during peritoneal lavage at staging laparoscopy is information potentially available preoperatively that identifies a patient population at very high risk for early recurrence and death after curative resection of gastric cancer. Mehzir and colleagues recently reviewed a prospectively maintained database of 1241 patients with gastric cancer who underwent laparoscopy with peritoneal washings.<sup>62</sup> Two hundred and ninety-one (23%) patients had positive cytology. A total of 48 of the 291 cytology-positive patients had repeat staging laparoscopy after chemotherapy. Compared with patients who had persistently positive cytology ( $n = 21$ ), those who converted to negative



cytology ( $n = 27$ ) had a significant improvement in disease-specific survival (2.5 years vs 1.4 years,  $p = 0.0003$ ). In an earlier publication by the same group on a lesser number of patients in this database, multivariate analysis identified preoperative T stage, preoperative N stage, site, and cytology as significant predictors of outcome. Positive cytology was the preoperative factor most predictive of death from gastric cancer (RR 2.7,  $p < 0.001$ ).<sup>63</sup> Although evaluated at laparotomy, La Torre et al reported similar results in their cohort of 64 patients.<sup>64</sup> Eighty-six percent of patients with positive peritoneal lavage cytology had a pT3/pT4 tumor and 100% of those positive had an N-positive tumor ( $p < 0.001$ ). The median survival of patients presenting with positive cytology was significantly lower than that of patients with negative peritoneal cytology (19 and 38 months respectively,  $p = 0.0001$ ). Multivariate analysis of this group of patients also identified cytology as a significant predictor of outcome ( $p = 0.018$ ). Looking at the value of staging laparoscopy in advanced gastric cancer, Shimizu et al stratified 34 patients into groups according to the presence of peritoneal deposits and/or positive peritoneal lavage cytology.<sup>65</sup> Those who were positive for both did not receive any operative intervention and were shown to do significantly worse over all, thus validating the argument for LS.

Taking the concept of intraperitoneal disease and its consequences even further, novel methods are being evaluated to increase the sensitivity of peritoneal lavage cytology. Wong et al have recently described a novel and very interesting method of detecting free peritoneal cancer cells in gastric cancer using cancer-specific Newcastle disease virus (NDV).<sup>66</sup> The green fluorescent protein of NDV appears to specifically infect and detect peritoneal gastric cancer cells and offers a more sensitive method compared with conventional cytology. Results were particularly impressive in advanced disease. Of patients with M1 disease discovered during laparoscopy, only 50% were cytology positive. All, however, were NDV-GFP positive. Cytology was positive in 9% of patients with T3 disease, 8% with N1 disease, and 50% with N2 disease. In contrast, NDV-GFP was positive in 95% of T3 patients and 100% of patients with N1 or N2 disease. This novel modality may offer enhanced detection of intraperitoneal cancer spread and provide important prognostic information. The same group has also looked at reverse transcriptase polymer chain reaction to detect micrometastases in peritoneal washings with promising results<sup>67</sup> and this reflects a growing area of research in gastric cancer staging today.

In this chapter, we have concentrated on the role of LS in determining unresectability. However, the advent of minimally invasive techniques applied to early gastric cancer has raised the possibility that LS may have an increasing role in treating that spectrum of the disease. It has been argued that gastric cancer is one of the most suitable targets for minimally invasive surgery (MIS) based on sentinel node status. Staging laparoscopy combined with sentinel node mapping may become a very important adjunct to laparoscopic local resection for curative treatment of sentinel-node-negative early gastric cancer.<sup>68</sup> More work is required before the true utility of this approach is understood.

## LIVER AND GALLBLADDER CANCER

At present, surgical resection remains the most effective therapy for primary and metastatic disease of the liver. While there are no definitive criteria that define what constitutes resectable disease in part owing to differing therapeutic philosophies and surgical experience, most surgeons would consider extrahepatic disease, extensive bilobar disease, or the presence of extensive cirrhosis as the major factors that would preclude a potentially curative resection.

As with the other gastrointestinal malignancies, imaging modalities such as multidetector CT scanning, MRI, and CT/PET scanning are available for preoperative staging. Despite the use of these modalities, a significant number of patients continue to have exploration without resection.<sup>48–50,69–71</sup> Laparoscopy, therefore, can serve to improve curative resection rates and decrease unnecessary laparotomy with its associated morbidity and quality-of-life issues.

Laparoscopic staging detects subradiologic disease in 10–60% of cases.<sup>72,73</sup> As with other anatomical sites, variability in part relates to the completeness and quality of preoperative imaging. Jarnagin and colleagues from Memorial Sloan-Kettering Cancer Center (MSKCC) reviewed their experience with 186 patients who had either primary or secondary hepatic malignancies who underwent surgery at their institution.<sup>70</sup> Laparoscopy was attempted in 104 patients and completed successfully in 85%. Overall, 26 (25%) of these patients were noted to have unresectable disease at the time of LS, and although nine patients had subsequent laparotomy for palliation, 17 patients were spared a laparotomy. More extensive hepatic disease, peritoneal disease, and extensive cirrhosis were the main laparoscopic findings that precluded resection. Difficulties were encountered determining the true extent of tumor vascular invasion or extensive biliary involvement. In addition, findings at laparoscopy had an impact on the type of resection performed in a further 10%. The authors also compared the patients undergoing LS with a similar nonrandomized cohort of 82 patients who did not receive LS but went directly to operation during the same time period. At open laparotomy, 28 (34%) of this group were noted to have unresectable disease. Although nine patients had a palliative procedure, 19 patients had only an exploratory procedure, which the authors suggested potentially could have been avoided with laparoscopy. Comparing the two groups, LS was associated with increased resectability rates (83% vs 63%), shorter hospital stay (8.6 vs 11.9 days), and reduced hospital charges. A subsequent study from the same institution analyzed experience with 401 patients.<sup>74</sup> Prior surgery did not preclude staging because a complete laparoscopic examination was performed in 291 (73%) cases. Despite a false-negative rate of 22%, LS improved the overall resectability rate from 62% to 78%.

In an attempt to define the patients who would benefit from LS, the same group created a clinical risk score (CRS) based on five factors related to the primary tumor and the hepatic disease.<sup>75,76</sup> (Table 5-2). Each criterion was assigned one point. Thus, 42% of patients with a CRS score of greater than 2 had unre-



**TABLE 5-2: CLINICAL RISK SCORE FOR THE DETERMINATION OF RESPECTABILITY IN HEPATIC COLORECTAL DISEASE**

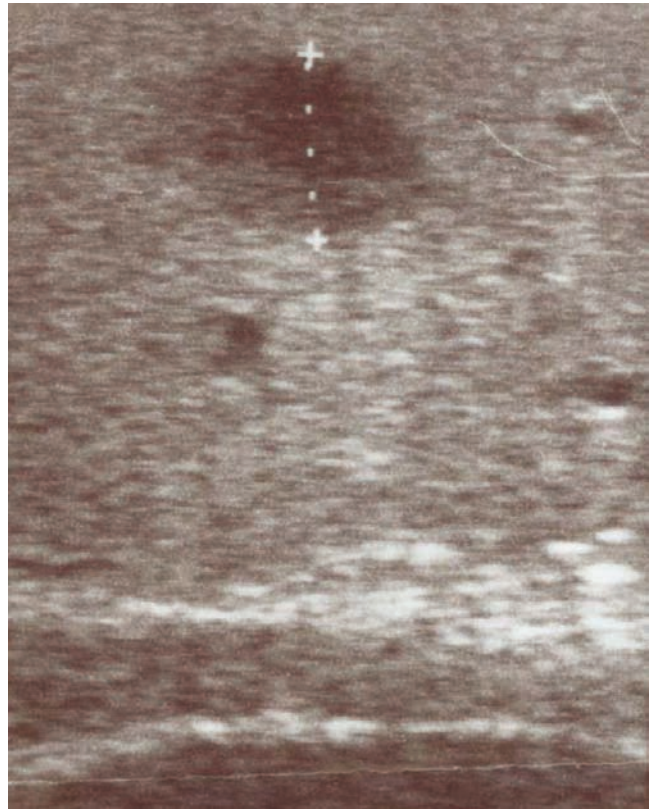
Lymph node–positive tumor
Disease-free interval between primary colonic surgery and detection of metastatic disease <12 months
Number of hepatic tumors greater than one (based on pre-operative staging)
CEA greater than 200ng/mL within one month of surgery
Size of the largest hepatic tumor greater than 5 cm

sectable disease detected at laparoscopy versus 0% of patients with CRS scores of 0–1. Therefore, targeting laparoscopy to high-risk patients should avoid unnecessary LS in low-risk patients, whereas performing it in the high-risk group should prevent needless staging laparotomies and overall improve the yield from laparoscopy. This scoring scheme has recently been validated by a number of groups. Mann and coworkers noted that an increasing CRS correlated with the likelihood of detecting incurable disease. Management was altered in 0%, 14%, and 53% of cases if the CRS was 0–1, 2–3, or 4–5, respectively.<sup>77</sup> Shah and colleagues reported that in patients with a CRS  $\leq 2$  laparoscopy and LUS prevented an operation in only 7% compared to 24% in those with a CRS  $> 2$ .<sup>78</sup> This data suggests that a focused use of LS is warranted.

Others have argued that improved imaging, particularly the increased availability of preoperative CT/PET, coupled with a more aggressive surgical approach have reduced the potential yield of LS in patients with colorectal metastases to the liver. However, data to support this hypothesis is lacking and in the main relies on review of the findings at open exploration, which were noted to preclude resection and potentially would have been detected by laparoscopy if it had been performed.

The history of a prior colectomy does not preclude accurate LS. Rahusen and colleagues performed laparoscopy in 50 patients with colorectal metastases, laparoscopy completing the examination in 94% and demonstrating unresectable disease in 38%.<sup>79</sup> Similar results have been reported by others.<sup>80,81</sup> Failure to accurately stage patients may occur due to adhesions from the prior open surgery in up to 20% of patients.<sup>80,81</sup>

Thaler and colleagues have suggested that the addition of intraoperative ultrasonography (IUS) improves the yield of LS (Fig. 5-10). In a review of 136 patients, LS/IUS changed the treatment plan in 48% of patients. Surgically untreatable disease was noted in 25% owing to PMs, nodal involvement, or diffuse hepatic disease.<sup>82</sup> Others have also noted the added value of LUS to LS.<sup>73,79,83,84</sup> Foroutani and colleagues reported their experience with LUS and biopsy in 310 patients with 1080 primary and metastatic liver lesions.<sup>85</sup> Using a linear side-viewing transducer, core needle biopsies were taken using an 18-gauge spring-loaded biopsy gun. Histologic confirmation was obtained in all patients, with no



**FIGURE 5-10** Isolated metastasis in a patient with gallbladder cancer as demonstrated by LUS.

bleeding complications or visceral injuries. A recent report has suggested that the combined use of laparoscopic and LUS-guided biopsies changed patient management in 27% of patients with upper gastrointestinal cancers (including primary and secondary liver tumors). LUS-guided biopsies were supplementary to laparoscopic biopsies and accounted for 44% of the clinical impact, suggesting that LUS should be an integral component of the staging procedure.<sup>86</sup> Hartley and colleagues reported that LUS was equivalent to MRI in determining resectability, particularly for primary hepatic tumors.<sup>87</sup> However, they and others also have noted that determining the extent of vascular and biliary involvement was problematic.<sup>83</sup>

For primary hepatocellular disease, experience is similar.<sup>88,89</sup> Lo and colleagues performed staging laparoscopy with LUS in 91 patients with primary hepatocellular carcinoma (HCC), identifying unresectable disease in 16%, two-thirds of whom avoided any further surgical intervention and commenced nonoperative treatment earlier.<sup>71</sup> As the use of laparoscopic resection and radiofrequency ablation for HCC has increased, it has been suggested that the role of LS has also expanded to not only identify unresectable disease but also aid selection of the optimal therapy. Lai and coworkers described a cohort of 122 patients with potentially resectable HCC who underwent LS prior to planned open laparotomy. Laparoscopic staging was performed in 119 patients, 44 of

whom were noted to have unresectable disease. Overall 25% of patients had their therapy delivered laparoscopically (22 curative resection, 8 palliative ablation/resection) with a significant reduction in median hospital stay compared to those who underwent open surgery.<sup>90</sup> In an interesting publication, Casaccia et al noted that, while laparoscopic ultrasonography accurately staged HCC in patients with advanced cirrhosis, it also allowed for laparoscopic radiofrequency ablation to be safely performed.<sup>91</sup>

The role of LS in the evaluation of noncolorectal nonneuroendocrine tumors was studied by D'Angelica and colleagues from MSKCC.<sup>92</sup> Following preoperative staging, 30 patients considered to have resectable disease underwent laparoscopy. Staging was completed in 80% and correctly identified six patients of the nine finally found to have unresectable disease.

There has been little work specifically directed to determining the utility of LS for gallbladder cancer. Agrawal and colleagues reported on a cohort of 91 patients with apparent resectable disease who underwent staging laparoscopy. Laparoscopic findings of either locally advanced or disseminated disease avoided open exploration in 35 cases.<sup>93</sup> Similar results were reported by Goere and coworkers from France who noted that LS detected unresectable disease in 36% of patients with potentially resectable biliary cholangiocarcinoma or gallbladder cancers. Peritoneal and liver metastases were detected but vascular and lymphatic extension was not diagnosed leading the authors to suggest that laparoscopy was more useful in extrahepatic cholangiocarcinomas and gallbladder cancer and should only be considered in selected cases with hilar cholangiocarcinomas.<sup>94</sup>

## PANCREAS CANCER

Adenocarcinoma of the pancreas remains a lethal disease.<sup>95</sup> Despite increased awareness and improved diagnostic modalities, most patients continue to present with advanced disease at the time of diagnosis. Actual 5-year survival is between 3% and 5%, with surgical resection offering the only chance of cure. However, resection is only appropriate for a minority of patients. For the majority, the need for surgical intervention is controversial. In common with esophagogastric cancers, the notion that all patients require an operative procedure for accurate staging or palliation no longer is true. Our increased understanding of the natural history of the disease, coupled with the improvements in nonoperative palliative techniques, suggests that effective palliation does not require an open surgical procedure. Proponents of LS argue that the combination of dynamic contrast-enhanced CT scanning and/or MRI with laparoscopy remains the most effective means of staging, preventing needless open surgery for those who would not benefit, while not precluding resection for those who would benefit. Avoidance of unnecessary open procedures potentially will result in reduced perioperative morbidity and mortality, decreased hospital stay, shorter time to appropriate therapy, improved quality of life, and overall reduced treatment costs.

Laparoscopic staging for pancreatic cancer is not a new concept. In fact, the first published case in the United States of a minimally invasive approach to cancer staging was in a patient with pancreatic cancer. Bernheim in 1911 staged a patient of W. S. Halstead with presumed pancreatic cancer prior to laparotomy.<sup>96</sup> He stated that the procedure he termed *organoscopy* “may reveal general metastases or a secondary nodule in the liver, thus rendering further procedures unnecessary and saving the patient a rather prolonged convalescence.” The use of laparoscopy was sporadic and not widespread until the seminal works of Alfred Cuschieri from Scotland and Andrew Warshaw from the United States.<sup>97–100</sup> Both used the technique before the laparoscopic revolution and began to define the role it would have in the staging algorithm.

The yield of positive laparoscopy that avoids unnecessary laparotomy is highly dependent on the quality of the preoperative radiologic studies. The yield of laparoscopy cannot be assessed from studies that have not included state-of-the-art CT scans.<sup>101</sup> Currently, the standard protocol should include a contrast-enhanced thin-cut dynamic CT scan of the pancreas. Initial reports from MSKCC concerning LS of peripancreatic malignancy reported an improvement in resectability from 50% based on standard CT scanning alone to 92% when staging laparoscopy was performed.<sup>73,102</sup> Compared with previous reports, improvements in technology and better patient selection have reduced the benefit of laparoscopy. However, laparoscopy continues to consistently upstage approximately 15–20% of patients with radiologically resectable disease.<sup>73,97,102–107</sup>

An early study at MSKCC examined 577 patients who following contrast-enhanced CT scans were considered to have potentially resectable disease and underwent staging laparoscopy.<sup>108</sup> Unresectability was determined at laparoscopy if histologic proof was obtained of:

1. Metastasis (hepatic, serosal, and/or peritoneal) (Fig. 5-11)
2. Extrapancreatic extension of the tumor (ie, mesocolic involvement)

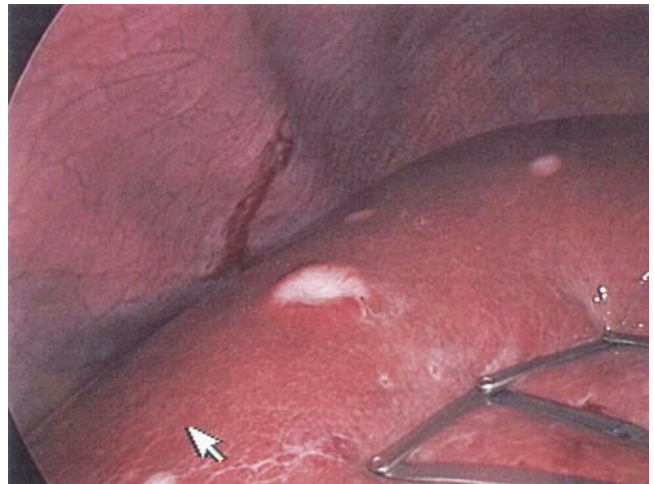

FIGURE 5-11 Hepatic metastases in pancreas cancer.

3. Celiac or high portal node involvement
4. Invasion or encasement of the celiac or hepatic artery
5. Involvement by tumor of the superior mesenteric artery

Portal or superior mesenteric venous involvement was considered a relative contraindication to resection depending on the degree and extent of involvement.

In the MSKCC series, 366 patients were considered to have resectable disease after LS and subsequently underwent open exploration, with 92% (338 patients) being resected. The predominant sites for metastases were the liver and the peritoneal cavity. The resectability rate was compared with results from the decade before the introduction of LS, during which 1135 patients at MSKCC were explored but only 35% were resected. In a recent update from the same group examining 1045 patients with radiographically resectable disease who underwent LS between 1995 and 2005, it was reported that the yield of LS had decreased to 14% for patients with pancreatic adenocarcinoma. The predominant reason for unresectability at laparoscopy was metastatic liver disease. Only seven patients were noted to have locoregional disease highlighting the improvements in CT imaging. Of the patients considered resectable at laparoscopy 99% were subsequently resected.<sup>109</sup> A similar yield was reported by Doran and colleagues; 239 patients with suspected periampullary cancer underwent staging laparoscopy following dual-phase helical CT scanning.<sup>110</sup> CT “resectable” disease was noted in 190 patients, of whom laparoscopy correctly identified unresectable disease in 28 patients. Overall, owing to findings at laparoscopy, 15% of patients were spared a further procedure, leading the authors to conclude that when added to CT scanning, LS provides valuable information that improves the selection of patients for surgical or nonsurgical treatment significantly. Many other authors have reported similar results (Table 5-3).

## Carbohydrate Antigen 19-9

The use of tumor markers such as the carbohydrate antigen 19-9 (CA-19-9) to further select patients for staging laparoscopy has been proposed. Halloran and colleagues used a cut off value for CA-19-9 of 150 kU/L improving resectability levels and reducing nontherapeutic laparotomies.<sup>111</sup> Using a receiver operating characteristics (ROC) curve for preoperative CA-19-9 values and tumor resectability, Maithel and coworkers demonstrated a statistically optimal cutoff of 130 U/mL. Unresectable disease was identified in 38 of 144 patients (26%) with a preoperative level  $\geq 130$  U/mL compared to 13 of 118 patients (11%) with a value  $< 130$  U/mL.<sup>112</sup> We believe that this added information does allow for better selection of patients. Figure 5-12 details a recommended clinical algorithm. The use of such a strategy is supported by the analyses of population-based administrative databases. Mayo and colleagues reviewed the experience in Oregon and noted that the majority of patients did not undergo LS.<sup>113</sup> However, in the subset that did undergo LS metastatic disease, which precluded resection, was noted in 27.6%. These patients were spared an unnecessary laparotomy.

## Laparoscopic Ultrasonography

To further increase the added value, we use LUS. LUS has been used by a number of groups in an attempt to increase the yield of LS.<sup>114,115</sup> John and colleagues showed that laparoscopy demonstrated unsuspected metastatic disease in 14 of 40 patients considered to have resectable disease.<sup>103</sup> However, laparoscopy had only 50% sensitivity in predicting tumor resectability. The accuracy in predicting resectability increased to 89% with the addition of LUS. Several other studies have demonstrated that the added value of LUS to standard laparoscopy is on the order of 14–25%.<sup>73,116–119</sup> Callery and colleagues analyzed the effect of routine implementation of laparoscopy with LUS, determining that the addition of LUS improved staging by identifying an additional 22% of patients with unresectable disease.<sup>73</sup> Minnard and colleagues reported the benefit of LUS over laparoscopy alone in evaluating the primary tumor and the presence of vascular involvement.<sup>117</sup> LUS findings resulted in a change in surgical treatment in 14% of patients in whom standard laparoscopic examination was equivocal. A further study by Schachter and colleagues demonstrated a change in surgical intervention in 36% of patients, with avoidance of unnecessary laparotomy in 31%.<sup>120</sup> Catheline and colleagues reported that LUS altered therapy in 41% of cases, avoiding open exploration in 46%.<sup>121</sup> This group reported a 90% sensitivity for assessing positive nodal disease and 100% for hepatic and peritoneal disease. Vollmer and colleagues similarly reported an improvement in resection rates using LUS (84% with LS vs 58% without)<sup>122</sup>. Merchant and colleagues concluded that the addition of LUS during LS enhances the ability of laparoscopy to determine resectability and approaches the accuracy of open exploration without increasing morbidity or mortality

**TABLE 5-3: DETECTION OF INTRA-ABDOMINAL METASTASES AT LAPAROSCOPY**

Author	Year	Number of patients	Yield (%)
John Fernandez-del Castello	1995	40	14 (35%)
Conlon	1996	108	27 (24%)
Holzman	1997	28	28 (26%)
Jiminez	1997	28	14 (50%)
White	2000	125	30 (24%)
Vollmer	2001	45	8 (18%)
Doran	2002	72	16 (22%)
Karachristos	2004	45	8 (18%)
Ahmed	2005	63	63 (19%)
Ferrone	2006	37	9 (24%)
		297	68 (23%)



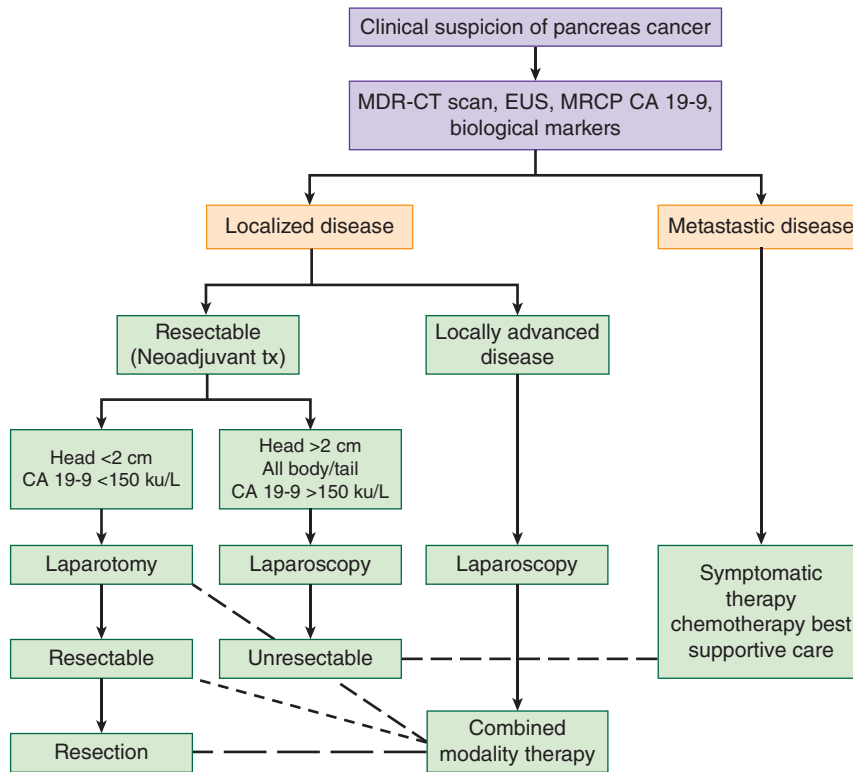


FIGURE 5-12 Treatment algorithm for pancreas cancer.

significantly.<sup>123</sup> As clinical experience has developed it appears that the main utility remains in assessment of the liver or vascular involvement (Fig. 5-13). In patients with portal/superior mesenteric vein involvement, determining (i) resectability and/or if resectable (ii) the amount of venous resection required to obtain clear margins. This approach is supported by Thomson and colleagues using the widely accepted CT classification of vascular involvement, which examined the relationship between the tumor and the major vasculature and grades the involvement between A and F.<sup>124</sup> Tumors graded A to D were generally resectable while those graded E and F were invariably unresectable.<sup>125</sup> The authors suggest that, using these criteria, the selective use of LUS in LS is indicated. A meta-analysis examining the role of laparoscopy and LUS was performed by Hariharan and coworkers.<sup>126</sup> They identified 29 studies in which 3305 patients underwent LS. The true yield was 25% (95% CI 24–27). The authors suggested that this represents a significant benefit to patients with potentially resectable adenocarcinoma of the pancreas in avoiding nontherapeutic laparotomy.

## Peritoneal Cytology

Cytologic examination of peritoneal washing obtained at the time of laparoscopy has also been suggested to enhance the sensitivity of staging laparoscopy.<sup>127</sup> Laparoscopy combined with peritoneal cytology is reported to upstage approximately 10% of patients.<sup>123,128</sup> Peritoneal recurrence is a significant

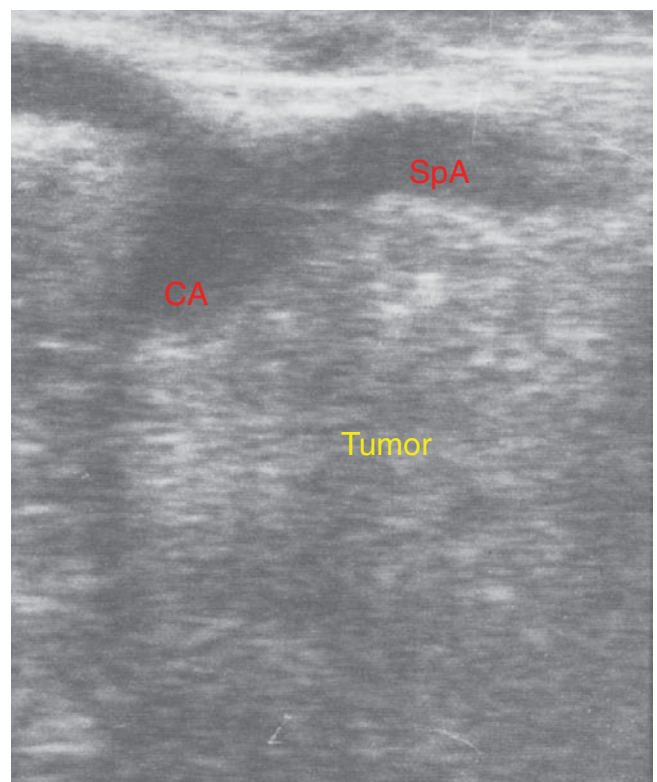


FIGURE 5-13 LUS examination demonstrating infiltration of the celiac axis (CA) and splenic artery (SpA).



site of failure following a potentially curative pancreaticoduodenectomy. Leach and colleagues studied a consecutive series of patients with suspected or biopsy-proven radiologically resectable adenocarcinoma of the pancreatic head.<sup>129</sup> Peritoneal washings were obtained at the time of staging laparoscopy and/or at subsequent laparotomy. Positive peritoneal cytology (PPC) was noted in 7% of patients, all of whom had overt metastatic disease at a median of 4.8 months. Merchant and colleagues examined 228 patients with radiographically resectable pancreatic adenocarcinoma who underwent LS.<sup>123</sup> Peritoneal washings were taken from both upper quadrants at the beginning of laparoscopy. Overall survival was significantly higher in patients with negative peritoneal cytology. The authors determined that PPC had a positive predictive value of 94.1%, a specificity of 98.1%, and a sensitivity of 25.6% for determining unresectability. Quantitative real time-polymerase chain reaction (RT-PCR) assay was used by Dalal and coworkers to detect tumor cells in a cohort of 35 patients undergoing staging laparoscopy.<sup>130</sup> Positive cytology was noted in eight cases and appeared to be stage-related. However, 25 patients were RT-PCR positive suggesting that this methodology could represent a more sensitive method for the detection of subclinical disease and enable improved selection for operative therapies and clinical trials. This intriguing pilot study requires further confirmation.

Despite the above, there is no consensus around the value of LS. Critics argue that confining laparoscopy to the setting of determination of resectability overestimates the usefulness of laparoscopy because it fails to account for patients who require open procedures for palliation of unresectable disease.<sup>101</sup>

Pisters and colleagues from the MD Anderson Cancer Center reported resectability rates of 80% using high-quality CT scanning alone.<sup>101</sup> Based on these data, the authors proposed that the maximum positive yield of routine staging laparoscopy in patients with potentially resectable disease on high-quality CT scanning would be 20%, assuming a false-negative result of zero. This group did not perform routine staging laparoscopy but rather used selective laparoscopy at the time of planned laparotomy for tumor resection in patients with localized disease on CT scan and patients at high risk for occult M1 disease.<sup>131,132</sup> This is a strategy that has been advocated by others.<sup>133</sup> Gouma and colleagues from Amsterdam assessed the role of LS in patients with periampullary tumors compared with standard radiologic staging with helical CT scanning.<sup>134</sup> Laparoscopic staging identified biopsy-proven unresectable disease in only 13% of 297 patients, with a detection rate of 35%. Based on the findings, the authors proposed that LS should be performed selectively. Since their practice is to recommend a surgical bypass as palliation for patients with locally advanced unresectable disease, they believe that LS only adds value in the presence of metastatic disease.

## Locally Advanced Disease

Recent reports have focused on the role of LS in patients with locally advanced unresectable disease who were considered for

adjuvant chemoradiotherapy. Shoup and colleagues reviewed 100 consecutive patients with locally advanced disease who underwent LS.<sup>135</sup> Contemporary imaging studies failed to detect metastatic disease in 37% of cases. Peritoneal disease was noted in 12 cases, liver metastases in 18, and 7 patients had both. Similar results were reported by Liu and Traverso, who described their experience with 74 patients, all of whom had undergone high-quality pancreas protocol CT examination prior to LS.<sup>136</sup> Occult tumor was found in 34% of patients. The authors reported that tumors situated in the body and tail of the gland were more likely than head lesions to have unsuspected metastases (53% vs 28%). Morak and coworkers in a prospective cohort study reported that 24 of 68 (35%) patients with locally advanced disease on CT had metastatic disease at laparoscopy.<sup>137</sup> These studies emphasize that despite the improvements in imaging modalities, LS should be performed in patients considered to have locally advanced disease prior to the start of combined modality therapy.

The studies cited earlier focus on invasive ductal adenocarcinoma of the pancreas. For other cell types, including neuroendocrine tumors, intraductal papillary mucinous neoplasms, and cystadenocarcinomas, the data are sparse. A review of the MSKCC experience with laparoscopy in non-functioning islet cell tumors by Hochwald and colleagues found a high incidence of occult metastases at laparoscopy.<sup>138</sup> CT scan followed by laparoscopy was significantly more sensitive than CT scan alone in predicting resectability (93% vs 50%;  $p = 0.03$ ). This resulted from a high false-negative rate on CT scan for small-volume metastatic disease, hepatic disease being the most common site. The predictive value for tumor resectability also was much higher for CT scan followed by laparoscopy than for CT scan alone (95% vs 74%). Brooks and colleagues examined the role of LS in 144 patients with ampullary, duodenal, and distal bile duct tumors.<sup>139</sup> Patients with distal bile duct tumors also appeared to benefit from LS in terms of both determining resectability and avoiding unnecessary surgery. In contrast, patients with known duodenal or ampullary tumors gained little added value from LS.

## COMPLICATIONS OF STAGING LAPAROSCOPY

In experienced hands, the procedure is safe and well tolerated as a day case procedure. Complications are low with few specific reports in the literature. Of those, only one identifies a series of complications directly attributable to the LS procedure.<sup>140</sup> In their series published in 2003, Rodgers et al report a complication rate of 2.8% (3/106 patients), one of which was unrecognized at laparoscopy and which eventually contributed directly to the patients' death. In general, major morbidity such as hemorrhage, visceral perforation, and intra-abdominal infection may occur in 1–2% of cases.

As the use of laparoscopy in malignant disease increased, concern was expressed regarding the potential risk of disseminating disease at the time of pneumoperitoneum. An initial case report in 1978 by Dobronite and colleagues described a “port site” tumor implant in a patient with malignant ascites 2 weeks following laparoscopy.<sup>141</sup> A number of similar reports followed, again involving patients who had disseminated disease at the time of their laparoscopic examination. Nieveen van Dijkum and colleagues from Amsterdam demonstrated an overall 2% port-site recurrence, with all cases having advanced peritoneal disease.<sup>142</sup>

Clinical experience over the last two decades appears to support the hypothesis that LS is safe from the oncologic standpoint. Pearlstone and colleagues from the MD Anderson Cancer Center described their experience with laparoscopy in 533 patients with nongynecologic intra-abdominal cancer, 339 of whom had laparoscopic procedures for upper gastrointestinal malignancies.<sup>143</sup> They reported port-site recurrences in four patients (0.88%), three of whom had advanced disease at the time of initial laparoscopy. Similar results were noted in a report from MSKCC, which reviewed a prospective database of 1650 diagnostic laparoscopic procedures performed in 1548 patients with upper gastrointestinal malignancies, in which a total of 4299 trocars were inserted.<sup>144</sup> The most frequent diagnosis was pancreatic cancer (51.2%). At a median follow-up of 18 months, a port-site recurrence was noted in 13 patients (0.8%). An open operation was performed in 1040 patients, of whom 9 (0.9%) developed a wound recurrence. This latter figure is similar to the 0.8% incisional recurrence rate noted by Hughes and colleagues in a review of 1600 open laparotomies for colon cancer.<sup>145</sup> Median time for the development of the port-site recurrence in the MSKCC study was 8.2 months. Eight occurred in patients with documented metastatic disease at the time of laparoscopy, and the remaining five had local or distant disease at the time of diagnosis of the port-site implant, and therefore, the recurrence did not appear to be an isolated event but rather a marker for more advanced disease. The authors concluded that LS appeared safe from an oncologic standpoint. This is further supported by a retrospective review of 235 patients who had laparoscopy to stage pancreatic cancer. This study demonstrated a port-site recurrence rate of 3% versus a 3.9% incisional recurrence rate in those patients who had an exploratory laparotomy alone.<sup>146</sup>

A number of hypotheses have been suggested to explain port-site implantation. Tumor seeding has been associated with carbon dioxide pneumoperitoneum in animal studies; however, reports that tumor growth is established more easily after open laparotomy would appear to refute this theory.<sup>147-149</sup> Other mechanisms, such as tissue manipulation, direct wound contamination, poor surgical technique, or immunologic effects such as changes in host immune responses, also have been suggested.<sup>150</sup> It appears so far, however, in most studies that port-site implantation is uncommon, differs little from open surgical incision recurrence, and is more likely to reflect the underlying biologic behavior of the disease rather than the type of surgery.

## LAPAROSCOPIC BILIARY AND GASTRIC BYPASS

Since the majority of patients with pancreatic cancer have unresectable disease at the time of presentation, palliation to minimize symptoms and maximize quality of life has a major role in the care of these patients. Palliation most commonly is required for one of three problems: biliary obstruction, gastric outlet obstruction (GOO), and relief of pain.

While both cholecystoenteric and choledochoenteric bypasses have been performed laparoscopically, the latter is much more difficult technically, requiring a high level of laparoscopic skills. A sufficient length of common duct needs to be exposed, and a difficult intracorporeal anastomosis between the small bowel and the common duct must be performed. Cholecystojejunostomy is the more commonly performed laparoscopic procedure (Fig. 5-14). Patient selection is critical. A low insertion of the cystic duct into the common bile duct or tumor impingement within 1 cm of the duct is a predictor of early technical failure. The anastomosis can be performed with either a stapled or hand-sewn technique. In patients who have experienced a prior cholecystectomy or who have a diseased gallbladder, blocked cystic duct, low insertion of the cystic duct, or tumor encroachment on the cystic duct or gallbladder, a cholecystojejunostomy is not possible; therefore, either a laparoscopic choledochojejunostomy is performed, or the procedure is converted to open and a standard surgical bypass is performed.

Rhodes and colleagues presented in 1995 one of the first series of patients who underwent laparoscopic palliation for advanced pancreatic carcinoma. From the 16 patients, 7 underwent laparoscopic cholecystojejunostomy, 5 had laparoscopic gastroenterostomy, 3 had both procedures, and in 1 patient laparoscopic palliation failed. The median operating time was 75 minutes, the hospital stay was 4 days, the morbidity was 13%, and the median survival in 10 patients was 201 days, with the rest of the patients remaining alive at the

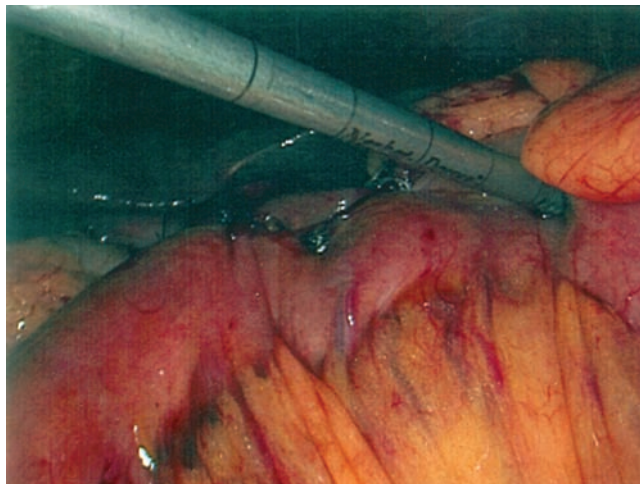


FIGURE 5-14 Laparoscopic cholecystojejunostomy.

time of the publication.<sup>151</sup> In 1999, Rothlin and colleagues published a case-controlled study of 28 patients with pancreatic cancer divided in two groups; in one group, laparoscopic palliation was performed, and the other group underwent conventional surgical palliation.<sup>152</sup> Of the 14 patients in the laparoscopic group, 7 had laparoscopic gastroenterostomy, 3 had gastroenterostomy and hepaticojejunostomy, and 4 had staging laparoscopy only.

Postoperative morbidity was 7% for the laparoscopic group compared with 43% for the open palliation group. There were no deaths in the laparoscopic group versus 29% mortality in the open group. Average postoperative hospital stay was 9 days for the laparoscopic group versus 21 days for the open group. Finally, the laparoscopic group required significantly less analgesia postoperatively. Choi presented a series of 78 gastrojejunostomies, 45 open and 33 laparoscopic, performed for palliation of gastric outflow obstruction caused by advanced gastric, duodenal, ampullary, and pancreatic cancers.<sup>153</sup> In the laparoscopic group, there was less suppression of immune function, lower morbidity, and earlier recovery of bowel function. A randomized trial reported by Navarra and colleagues demonstrated that patients undergoing a laparoscopic gastrojejunostomy had significantly less intraoperative blood loss and resumed oral intake sooner than those patients undergoing an open palliative antecolic gastrojejunostomy.<sup>154</sup>

The technique for a transumbilical single-incision laparoscopic gastrojejunostomy has recently been reported.<sup>155</sup> While this is technically feasible, the benefits compared to the conventional laparoscopic approach remain to be determined.

The true incidence of symptomatic GOO in pancreatic cancer remains unclear. Historically, it was considered that more than 25% of patients would develop GOO during the course of their illness, and therefore, prophylactic gastric bypass was recommended at the time of exploratory laparotomy. However, as the need for open exploration for staging purposes has decreased, the need for prophylactic bypass for the majority of patients has been questioned. GOO is a late complication of advanced pancreatic cancer affecting 10–20% of patients who survive more than 15 months.<sup>156–158</sup> However, fewer than 3% of the patients who develop GOO require surgical bypass.<sup>156,159,160</sup> Most important, 60% of patients with advanced pancreatic cancer have delayed gastric emptying with no evidence of gastric or duodenal invasion. This may be explained by tumor infiltration of the celiac plexus causing gastric stasis, nausea, and vomiting.<sup>161</sup>

Espat and colleagues examined in a prospective but non-random study of 155 patients undergoing LS.<sup>156</sup> Following laparoscopy, 40 patients had locally advanced unresectable disease, and the remainder had metastatic disease. In follow-up, only 3% of patients required a subsequent open operation for biliary drainage or GOO. A subsequent update of this experience has confirmed the results, with over 90% of patients dead of disease. This low incidence of patients requiring operation for symptomatic GOO is consistent with the data seen from

the nonoperative control groups in randomized trials of endoscopic biliary drainage versus surgery.

A laparoscopic gastroenterostomy is a relatively straightforward procedure. Nagy and colleagues reported a series of laparoscopic gastrojejunostomies.<sup>162</sup> Nine of 10 patients in this series had GOO from pancreatic malignancy. The laparoscopic method was successful in 90%. There was no postoperative morbidity or mortality associated with the surgical technique.

## Surgical Technique for Biliary and Gastric Bypass

The patient is placed supine on the operating table in 10 degrees of reverse Trendelenberg position with 10 degrees of left lateral tilt. The placement of trocars is similar to that for a standard staging procedure. However, in order to accommodate a linear stapler, the right upper quadrant 10-mm trocar is converted into a 12- to 15-mm size. Following exploration, the ligament of Trietz is identified, and a loop of jejunum approximately 30 cm distal to the ligament of Treitz is brought in an antecolic position to the gallbladder (Fig. 5-15). Using an intracorporeal suturing technique, the jejunum is approximated to the gallbladder by two 3-0 coated, braided lactomer sutures (Polysorb, US Surgical, Norwalk, CT). The distended gallbladder may be decompressed using a Veress needle attached to a suction device. There is usually minimal biliary spillage owing to the raised intra-abdominal pressure consequent on the pneumoperitoneum. Small enterotomy incisions (10 mm) are made in the gallbladder and jejunum using either scissors or a device such as the ultrasonic shears (Fig. 5-16). Hemostasis is achieved with electrocautery. Any spillage can be dealt with by suction device placed through the left upper quadrant port. An endoscopic 30-mm linear stapler using 3.5-mm staples is introduced through the right upper quadrant port, and the “jaws” are manipulated into the gallbladder and jejunum in a standard fashion. Often, this is difficult because of the proximity of the port site to the gallbladder. A reticulating stapler facilitates this maneuver. The stapler heads are approximated, and the instrument is fired (Fig. 5-17). After removing the stapler, the anastomosis is inspected, hemostasis is confirmed, and the gallbladder interior is aspirated and irrigated with saline.

The resulting enterotomy can be closed by using either a completely intracorporeal or laparoscopically assisted approach. Using an intracorporeal technique, the defect is closed with a continuous seromuscular 3-0 coated, braided lactomer suture, with knots tied using an intracorporeal technique (Fig. 5-18).

An alternative method is to create a completely hand-sewn anastomosis using 3-0 coated, braided lactomer suture. If a running suture is used, the assistant should maintain tension on the suture with an atraumatic grasping forceps following placement of each stitch. Knots can be tied either using an intracorporeal or extracorporeal technique.



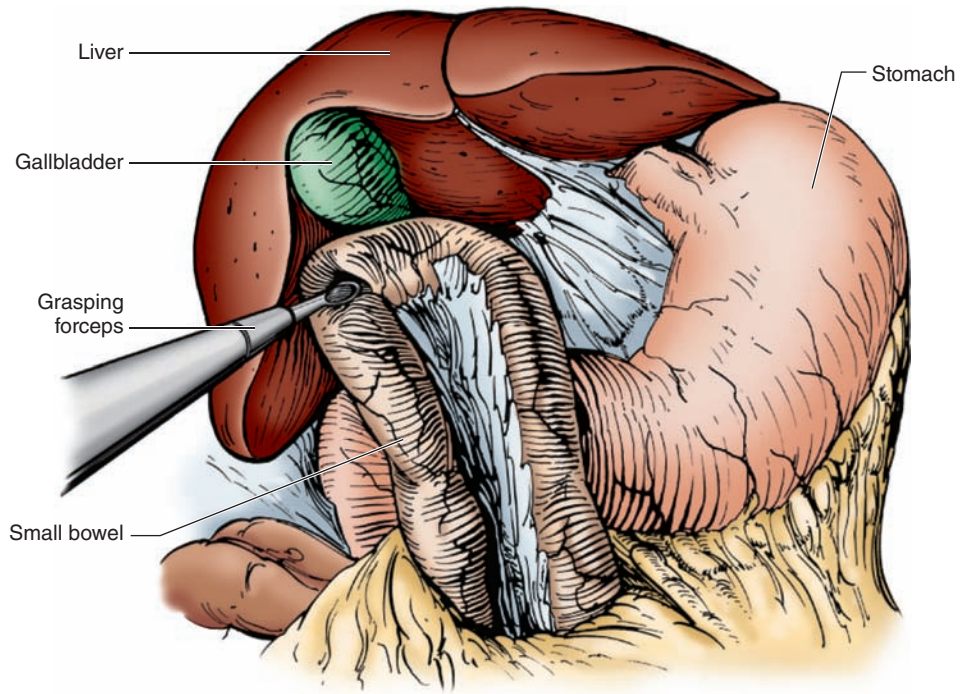


FIGURE 5-15 Laparoscopic cholecystojejunostomy.

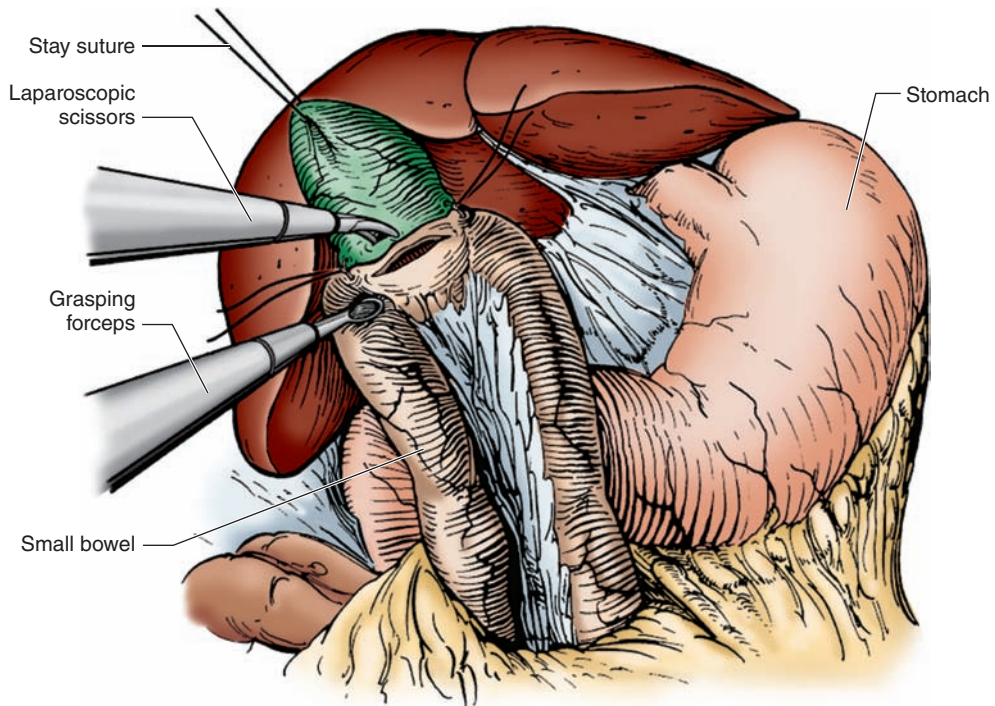


FIGURE 5-16 Approximation of small bowel to gallbladder, creation of enterostomy.



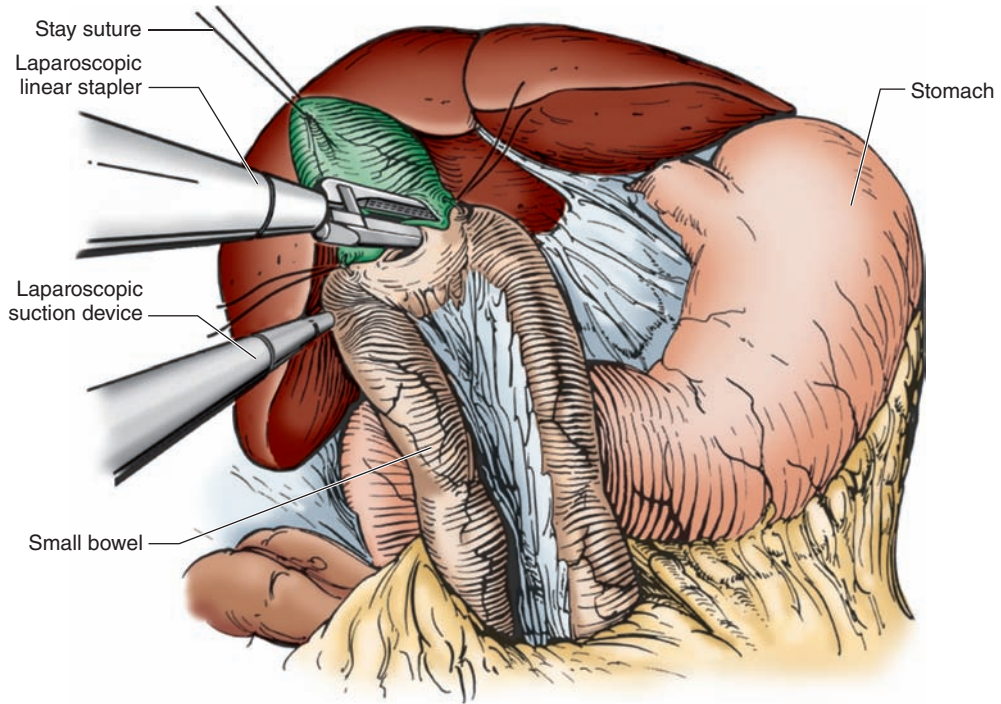


FIGURE 5-17 Stapled anastomosis.

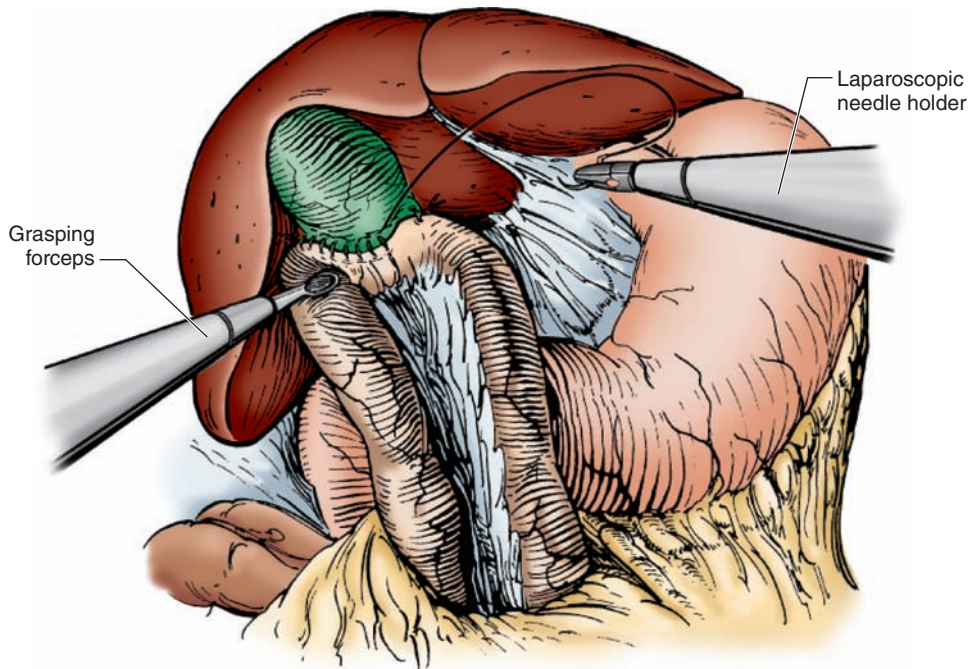


FIGURE 5-18 Closure of enterotomy.

A laparoscopically assisted method is suitable in thin patients. Two stay sutures are placed on either side of the anastomotic defect. These sutures are cut long. The 12-mm trocar is removed, and the incision is enlarged to 20 mm. Using retraction on the stay sutures, the newly created biliary-enteric anastomosis can be exteriorized and the enterotomy closed in a standard fashion. When this is completed, the bowel is returned to the abdominal cavity, and the wound is closed. The abdomen is reinsufflated and the anastomosis inspected. This technique allows for the construction of a 2.5-cm cholecystojejunal anastomosis without any bowel narrowing. No intra-abdominal drains are used.

The technique for fashioning a gastrojejunostomy is similar. In this case, a proximal loop of jejunum is brought in an antecolic position to the stomach. The left upper quadrant 5-mm laparoscopic trocar is converted to a 12-mm trocar. Two 3-0 coated, braided lactomer sutures (Polysorb, US Surgical) are used to approximate the jejunum to the stomach. Enterotomies are made in both stomach and jejunum. In cases in which there has been a significant period of gastric obstruction, the gastric wall may be hypertrophied, making creation of the gastrotomy difficult. Confirmation that one is inside the stomach is required before placement of the stapler. When this is achieved, a 30-mm linear stapler is inserted through the 12-mm left upper quadrant port and manipulated into both enterotomies. The instrument is positioned and fired. The stapler is removed and reloaded, returned into the anastomosis, and refired. This creates an anastomosis approximately 5 cm in length. The anterior defect can be closed in a fashion similar to the cholecystojejunostomy (Fig. 5-19). Any defects in the anastomosis can be repaired with individual 3-0 sutures.

The ideal palliative procedure for biliary or gastric obstruction should be effective in relieving jaundice or GOO, have minimal morbidity, be associated with a short hospital stay, have a low symptomatic recurrence, and maintain quality of life. Laparoscopic procedures have the potential to achieve

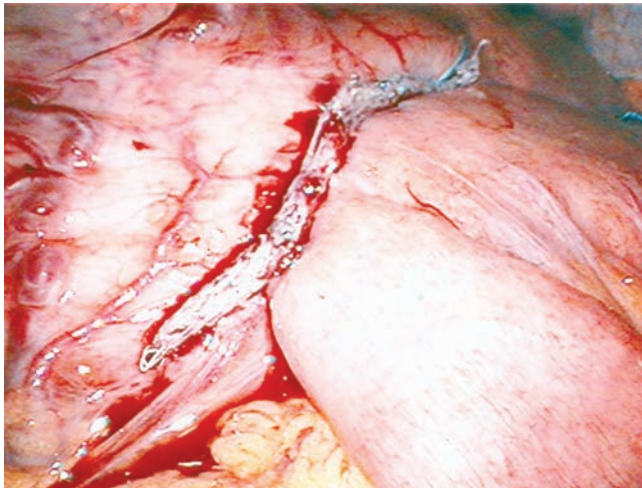


FIGURE 5-19 Laparoscopic gastrojejunostomy.

these goals, although data do not support prophylactic bypass procedures in patients who do not otherwise require surgery.

## SUMMARY

Laparoscopy is no longer a tool of limited use and now has widespread indications within surgical oncologic practice. Despite improvements in noninvasive imaging, there is still an added value to use LS in selected patients with upper gastrointestinal cancers. In the future, the combination of NOTES technology and MIS techniques offers further exciting potential to enhance staging of these patients.

## REFERENCES

1. Samee A, Moorthy K, Jaipresad T, et al. Evaluation of the role of laparoscopic ultrasonography in the staging of oesophagogastric cancers. *Surg Endosc.* 2009;23(9):2061–2065.
2. Muntean V, Mihailov A, Iancu C, et al. Staging laparoscopy in gastric cancer. Accuracy and impact on therapy. *J Gastrointest Liver Dis.* 2009;18(2):189–195.
3. De Graff GW, Ayantunde AA, Parsons SL, Duffy JP, Welch NT. The role of staging laparoscopy in oesophagogastric cancers. *Eur J Surg Oncol.* 2007;33(8):988–992.
4. Hemming AW, Nagy AG, Scudmore CH, et al. Laparoscopic staging of intra-abdominal malignancy. *Surg Endosc.* 1995;9:325–328.
5. Van Delden OM, De Wit LT, Bemelman WA, et al. Laparoscopic ultrasonography for abdominal tumor staging: technical aspects and imaging findings. *Abdom Imaging.* 1997;22:125–131.
6. Buyske J. Role of videoscopic-assisted techniques in staging malignant diseases. *Surg Clin North Am.* 2000;80:495–503.
7. Pratt BL, Greene FL. Role of laparoscopy in the staging of malignant disease. *Surg Clin North Am.* 2000;80:1111–1126.
8. Schoonderwoerd L, Swank DJ. The role of optical access trocars in laparoscopic surgery. *Surg Technol Int.* 2005;14:61–67.
9. Kamangar F, Dores GM, Anderson WF. Patterns of cancer incidence, mortality, and prevalence across five continents: defining priorities to reduce cancer disparities in different geographic regions of the world. *J Clin Oncol.* 2006;24(14):2137–2150.
10. Jemal A, Siegel R, Ward E, et al. Cancer statistics. *CA Cancer J Clin.* 2008;58(2):71–96.
11. Aibe T, Fuji T, Okita K, et al. A fundamental study of normal layer structure of the gastrointestinal wall visualised by endoscopic ultrasonography. *Scand J Gastroenterol.* 1986;21:6–15.
12. Tio TL, Tytgat GNJ. Endoscopic ultrasonography of normal and pathologic upper gastrointestinal wall structure: comparison of studies in vivo and in vitro with histology. *Scand J Gastroenterol.* 1986;21:27–33.
13. Dittler HJ, Siewert JR. Role of endoscopic ultrasonography in esophageal carcinoma. *Endoscopy.* 1993;25:156–161.
14. Lea JW 4th, Prager RL, Bender HW Jr. The questionable role of computed tomography in preoperative staging of esophageal cancer. *Ann Thorac Surg.* 1984;38:479–481.
15. van Vliet EPM, Heijnenbroek-Kal MH, Hunink MGM, Kuipers EJ, Siersema PD. Staging investigations for oesophageal cancer: a meta-analysis. *BJC.* 2008;98:547–557.
16. van Vliet EPM, Hermans JJ, De Wever W, et al. Radiologist experience and CT examination quality determine metastasis detection in patients with esophageal or gastric cardia cancer. *European Radiology.* 2008;18(11):2475–2484.
17. Kimmey MB, Martin RW, Haggitt RC, et al. Histologic correlates of gastrointestinal ultrasound images. *Gastroenterology.* 1989;96:433–441.
18. Aibe T, Ito T, Yoshida T. Endoscopic ultrasonography of lymph nodes surrounding the upper GI tract. *Scand J Gastroenterol.* 1986;21:164–169.




19. Tio TL, Cohen P, Coene PP, et al. Endosonography and computed tomography of esophageal carcinoma: pre-operative classification compared to the new TNM system. *Gastroenterology*. 1989;96:1478–1486.
20. Rosch T, Lorenz R, Zenker K, et al. Local staging and assessment of resectability in carcinoma of esophagus, stomach, and duodenum by endoscopic ultrasonography. *Gastrointest Endosc*. 1992;38:460–467.
21. Harewood GC, Wiersma MJ. A cost analysis of endoscopic ultrasound in the evaluation of esophageal cancer. *Am J Gastroenterol*. 2002;97:452–458.
22. de Graaf GW, Ayantunde AA, Parsons SL, Duffy JP, Welch NT. The role of staging laparoscopy in oesophagogastric cancers. *Euro J Surg Oncol*. 2007;33(8):988–992.
23. Morris JM, Suzuki H, McKernan M, Stephen M, Stuart RC, Stanley AJ. Impact of EUS-FNA in the management of patients with oesophageal cancer. *Scottish Med J*. 2009;54(2):30–33.
24. Puli SR, Reddy JBK, Bechtold ML, Antillon D, Ibdah JA, Antillon MR. Staging accuracy of esophageal cancer by endoscopic ultrasound: a meta-analysis and systematic review. *World J Gastroenterol*. 2008;14(10):1479–1490.
25. Maple JT, Peifer KJ, Edmondowicz SA, et al. The impact of endoscopic ultrasonography with fine needle aspiration (EUS-FNA) on esophageal cancer staging: a survey of thoracic surgeons and gastroenterologists. *Dis Esoph*. 2008;21(6):480–487.
26. Pfau PR, Perlman SB, Stanko P. The role and clinical value of EUS in a multimodality esophageal carcinoma staging program with CT and positron emission tomography. *Gastrointest Endosc*. 2007;65:377–384.
27. Salahudeen HM, Balan A, Naik K. Impact of the introduction of integrated PET-CT into the preoperative staging pathway of patients with potentially operable oesophageal carcinoma. *Clin Radiol*. 2008;63:765–773.
28. Kato H, Kimura H, Nakajima M. The additional value of integrated PET/CT over PET in initial lymph node staging of esophageal cancer. *Oncol Rep*. 2008;20:857–862.
29. Block MI, Patterson GA, Sundaresan RS. Improvement in staging of esophageal cancer with the addition of positron emission tomography. *Ann Thorac Surg*. 1997;64:770–776.
30. Kato H, Miyazaki T, Nakajima M. The incremental effect of positron emission tomography on diagnostic accuracy in the initial staging of esophageal carcinoma. *Cancer*. 2005;103:148–156.
31. Kato H, Kuwano H, Nakajima M. Comparison between positron emission tomography and computed tomography in the use of the assessment of esophageal carcinoma. *Cancer*. 2002;94:921–928.
32. Flamen P, Lerut A, Van Cutsem E. Utility of positron emission tomography for the staging of patients with potentially operable esophageal carcinoma. *J Clin Oncol*. 2000;18:3202–3210.
33. Monjabez AM, Riedlinger G, Aklilu M, et al. Outcomes of patients with esophageal cancer staged with [1F]fluorodeoxyglucose positron emission tomography (FDG-PET): can postchemoradiotherapy FDG-PET predict the utility of resection? *J Clin Oncol*. 2010;28(31):4714–4721.
34. Flanagan FL, Dehdashti F, Siegal BA, et al. Staging of esophageal cancer with <sup>18</sup>F-fluorodeoxyglucose positron emission tomography. *AJR*. 1997;168:417–424.
35. Block MI, Patterson GA, Sundaresan RS, et al. Improvement in staging of esophageal cancer with addition of positron emission tomography. *Ann Thorac Surg*. 1997;64:770–776.
36. Weber WA, Ott K, Becker K, et al. Prediction of response to preoperative chemotherapy in adenocarcinoma of the esophagogastric junction by metabolic imaging. *J Clin Oncol*. 2001;19:3058–3065.
37. Christina TM, Jannet CB, Jan P, et al. A systematic review on the role of FDG-PET/CT in tumour delineation and radiotherapy planning in patients with esophageal cancer. *Radiotherapy and Oncology*. 2010;97(2):165–171.
38. Neeraj K, Asif K, Debra B, James L, Kevin M. Endoscopic ultrasound compared with laparoscopy for staging esophageal cancer. *Ann Thorac Surg*. 2007;83(6):2000–2002.
39. De Graaf GW, Ayantunde AA, Parsons SL, Duffy JP, Welch NT. The role of staging laparoscopy in oesophagogastric cancers. *Euro J Surg Oncol (EJSO)*. 2007;33(8):988–992.
40. Watt I, Stewart I, Anderson D, Bell G, Anderson JR. Laparoscopy, ultrasound and computed tomography in cancer of the oesophagus and gastric cardia: a prospective comparison for detecting intra-abdominal metastases. *Br J Surg*. 1989;76:1036–1039.
41. O'Brien MG, Fitzgerald FF, Lee G, Crowley M, Shanahan F, O'Sullivan GC. A prospective comparison of laparoscopy and imaging in the staging of oesophageal cancer before surgery. *Am J Gastroenterol*. 1995;90:2191–2194.
42. Samee A, Moorthy K, Jaipersad T, et al. Evaluation of the role of laparoscopic ultrasonography in the staging of oesophagogastric cancers. *Surg Endosc Other Interven Tech*. 2009;23(9):2061–2065.
43. Mortensen MB, Fristrup C, Ainsworth A, Nielsen HO, Pless T, Hovendal C. Combined pretherapeutic endoscopic and laparoscopic ultrasonography may predict survival of patients with upper gastrointestinal tract cancer. *Surg Endoscopy*. 2011;43:596–603.
44. Dagnini G, Caldironi MW, Marian G, et al. Laparoscopy in abdominal staging of esophageal carcinoma: report of 369 cases. *Gastrointest Endosc*. 1986;32:400–402.
45. Stein HJ, Kraemer SJ, Freussner H, et al. Clinical value of diagnostic laparoscopy with laparoscopic ultrasound in patients with cancer of the esophagus or cardia. *J Gastrointest Surg*. 1997;1:167–173.
46. Ferlay J, Autier P, Boniol M, et al. Estimates of the cancer incidence and mortality in Europe in 2006. *Ann Oncol*. 2007;18:581–592.
47. Crew KD, Neugut AI. Epidemiology of gastric cancer. *World J Gastroenterol*. 2006;12(3):354–362.
48. Hartgrink HH, Jansen EP, van Grieken NC, van de Velde CJ. Gastric cancer. *Lancet*. 2009;374(9688):477–490.
49. Karpeh MS Jr, Brennan MF. Gastric carcinoma. *Ann Surg Oncol*. 1998;5:650–656.
50. Brennan MF, Karpeh MS Jr. Surgery for gastric cancer: the American view. *Ann Surg Oncol*. 1996;23:352–359.
51. Pye JK, Crumplin MK, Charles J, et al. Hospital clinicians in Wales: one-year survey of carcinoma of the oesophagus and stomach in Wales. *Br J Surg*. 2001;88:278–285.
52. Lordick F, Siewert JR. Recent advances in multimodal treatment for gastric cancer: a review. *Gastric Ca*. 2005;8(2):78–85.
53. Davies AR, Deans DAC, Penman I, et al. The multidisciplinary team meeting improves staging accuracy and treatment selection for gastroesophageal cancer. *Diseases of the Esophagus*. 2006;19(6):496–503.
54. Burke EC, Karpeh MS Jr, Conlon KC, et al. Laparoscopy in the management of gastric adenocarcinoma. *Ann Surg*. 1997;225:262–267.
55. Wakelin SJ, Deans C, Crofts PL, et al. A comparison of computerised tomography, laparoscopic ultrasound and endoscopic ultrasound in the preoperative staging of oesophago-gastric carcinoma. *Eur J Radiol*. 2002;41:161–167.
56. Finch M, John T, Garden OJ, et al. Laparoscopic ultra-sonography for staging gastroesophageal cancer. *Surgery*. 1997;121:10–17.
57. Stell DA, Carter Cr, Stewart I, Anderson JR. Prospective comparison of laparoscopy, ultrasonography and computed tomography in the staging of gastric cancer. *Br J Surg*. 1996;83:1260–1262.
58. Muntean V, Mihailov A, Iancu C, et al. Staging laparoscopy in gastric cancer: accuracy and impact on therapy. *J Gastrointest Liver Dis*. 2009;18(2):189–195.
59. Sotiropoulos GC, Kaiser GM, Lang H, et al. Staging laparoscopy in gastric cancer. *Eur J Medical Res*. 2005;10(2):88–91.
60. Kim SJ, Kim HH, Kim YH, et al. Peritoneal metastasis: detection with 16- or 64-detector row CT in patients undergoing surgery for gastric cancer. *Radiology*. 2009;253(2):407–415.
61. Chen CY, Hsu JS, Wu DC, et al. Gastric cancer: preoperative local staging with 3D multi-detector row CT: correlation with surgical and histopathologic results. *Radiology*. 2007;242(2):472–482.
62. Mezhir JJ, Shah MA, Jacks LM, Brennan MF, Coit DG, Strong VE. Positive peritoneal cytology in patients with gastric cancer: natural history and outcome of 291 patients. *Ann Surg Oncol*. 2010 Jun 29. [Epub ahead of print].
63. Bentrem D, Wilton A, Mazumdar M, Brennan M, Coit D. The value of peritoneal cytology as a preoperative predictor in patients with gastric carcinoma undergoing a curative resection. *Ann Surg Oncol*. 2005;12(5):1–7.
64. La Torre M, Ferri M, Giovagnoli MR, et al. Peritoneal wash cytology in gastric carcinoma: prognostic significance and therapeutic consequences. *Eur J Surg Oncol*. 2010;36(10):982–986.
65. Hiroki S, Hiroshi I, Katsuya O, et al. Usefulness of staging laparoscopy for advanced gastric cancer. *Surg Today*. 2010;40(2):119–124.
66. Wong J, Schulman A, Kelly K, Zamarin D, Palese P, Fong Y. Detection of free peritoneal cancer cells in gastric cancer using cancer-specific Newcastle disease virus. *J Gastrointest Surg*. 2010;14(1):7–14.

67. Dalal KM, Woo Y, Kelly K, et al. Detection of micrometastases in peritoneal washings of gastric cancer patients by the reverse transcriptase polymerase chain reaction. *Gastric Ca*. 2008;11(4):206–213.
68. Kitagawa Y, Fujii H, Mukai M, et al. Current status and future prospects of sentinel node navigational surgery for gastrointestinal cancers. *Ann Surg Oncol*. 2004;11:242S–244S.
69. Fortner JG, Silva JS, Cox EB, et al. Multivariate analysis of a personal series of 247 patients with liver metastases from colorectal cancer: treatment by intrahepatic chemotherapy. *Ann Surg*. 1984;199:317–324.
70. Jarnagin WR, Bodniewicz J, Dougherty E, et al. A prospective analysis of staging laparoscopy in patients with primary and secondary hepatobiliary malignancies. *J Gastrointest Surg*. 2000;4:24–43.
71. Lo CM, Lai E, Liu CL, et al. Laparoscopy and laparoscopic ultrasonography avoid exploratory laparotomy in patients with hepatocellular carcinoma. *Ann Surg*. 1998;227:527–532.
72. John TG, Greig JD, Crosbie JL, et al. Superior staging of liver tumors with laparoscopy and laparoscopic ultrasound. *Ann Surg*. 1994;220:711–719.
73. Callery MP, Strasberg SM, Doherty GM, et al. Staging laparoscopy with laparoscopic ultrasonography: optimizing resectability in hepatobiliary and pancreatic malignancy. *J Am Coll Surg*. 1997;185:33–39.
74. D'Angelica M, Fong Y, Weber S, et al. The role of laparoscopy in hepatobiliary malignancy: prospective analysis of 401 cases. *Ann Surg Oncol*. 2003;10:183–189.
75. Jarnagin WR, Conlon K, Bodniewicz J, et al. A clinical scoring system predicts the yield of diagnostic laparoscopy in patients with potentially resectable hepatic colorectal metastases. *Cancer*. 2001;91:1121–1128.
76. Grobmyer SR, Fong Y, D'Angelica M, et al. Diagnostic laparoscopy prior to planned hepatic resection for colorectal metastases. *Arch Surg*. 2004;139:1326–1330.
77. Mann CD, Neal CP, Metcalfe MS, Pattenden CJ, Dennison AR, Berry DP. *Br J Surg*. 2007;94:855–859.
78. Shah AJ, Phull J, Finch-Jones MD. Clinical risk score can be used to select patients for staging laparoscopy and laparoscopic ultrasound for colorectal metastases. *World J Surg*. 2010;34:2141–2145.
79. Rahusen FD, Cuesta MA, Borgstein PJ, et al. Selection of patients for resection of colorectal metastases to the liver using diagnostic laparoscopy and laparoscopic ultrasonography. *Ann Surg*. 1999;230:31–37.
80. de Castro SM, Tilleman EH, Busch OR, et al. Diagnostic laparoscopy for primary and secondary liver malignancies: impact of improved imaging and changed criteria for resection. *Ann Surg Oncol*. 2004;11:522–529.
81. Koea J, Rodgers M, Thompson P, et al. Laparoscopy in the management of colorectal cancer metastatic to the liver. *ANZ J Surg*. 2004;74:1056–1059.
82. Thaler K, Kanneganti S, Khajanchee Y, et al. The evolving role of staging laparoscopy in the treatment of colorectal hepatic metastases. *Arch Surg*. 2005;140:727–734.
83. Foroutani A, Garland AM, Berber E. Laparoscopic ultrasound versus triphasic computed tomography for detecting liver tumors. *Arch Surg*. 2000;135:953–958.
84. Metcalfe MS, Close JS, Iswariah H, et al. The value of laparoscopic staging for patients with colorectal metastases. *Arch Surg*. 2003;138:770–772.
85. Berber E, Garland AM, Engle KL, et al. Laparoscopic ultrasonography and biopsy of hepatic tumors in 310 patients. *Am J Surg*. 2004;187:213–218.
86. Mortensen MB, Frstrup C, Ainsworth A, et al. Laparoscopic ultrasound-guided biopsy in upper gastrointestinal tract cancer patients. *Surg Endosc*. 2009;23:2738–2742.
87. Hartley JE, Kumar H, Drew PJ, et al. Laparoscopic ultrasound for the detection of hepatic metastases during laparoscopic colorectal cancer surgery. *Dis Colon Rectum*. 2000;43:320–324.
88. Lightdale CJ. Laparoscopy and biopsy in malignant liver disease. *Cancer*. 1982;50:2672–2675.
89. Jeffers L, Spiegelman G, Reddy R, et al. Laparoscopically directed fine needle aspiration for the diagnosis of hepatocellular carcinoma: a safe and accurate technique. *Gastrointest Endosc*. 1988;34:235–237.
90. Lai EC, Tang CN, Ha JB, Tsui DK, Li MK. The evolving influence of laparoscopy and laparoscopic ultrasonography on patients with hepatocellular carcinoma. *Am J Surg*. 2008;196:736–740.
91. Casaccia M, Andorno E, Nardi I, et al. Laparoscopic staging and radiofrequency of hepatocellular carcinoma in liver cirrhosis: a “bridge” treatment to liver transplantation. *Hepatogastroenterology*. 2009;56:793–797.
92. D'Angelica MD, Jarnagin WR, Dematteo RP, et al. Staging laparoscopy for potentially resectable non-colorectal nonendocrine liver metastases. *Ann Surg Oncol*. 2003;9:204–209.
93. Agrawal S, Sonawane RN, Behari A, et al. *Dig Surgery*. 2005;22:440–445.
94. Goere D, Wagholikar GD, Pessaux P, et al. Utility of staging laparoscopy in subsets of biliary cancers. *Surg Endosc*. 2006;20:721–725.
95. Jemal A, Tiwari RC, Murray T, et al. Cancer statistics. *CA Cancer J Clin*. 2004;54:8–29.
96. Bernheim BM. Organoscopy. *Ann Surg*. 1911;53:764–767.
97. Warshaw AL, Gu ZY, Wittenberg J, et al. Preoperative staging and assessment of resectability of pancreatic cancer. *Arch Surg*. 1990;125:230–233.
98. Warshaw AL, Tepper JE, Shipley WU. Laparoscopy in the staging and planning therapy for pancreatic cancer. *Am J Surg*. 1986;151:76–80.
99. Cuschieri A, Hall AW, Clark J. Value of laparoscopy in the diagnosis and management of pancreatic carcinoma. *Gut*. 1978;19:672–677.
100. Cuschieri A. Laparoscopy for pancreatic cancer: does it benefit the patient? *Eur J Surg Oncol*. 1988;14:41–44.
101. Pisters PW, Lee JE, Vauthey JN, et al. Laparoscopy in the staging of pancreatic cancer. *Br J Surg*. 2001;88:325–337.
102. Conlon KC, Dougherty E, Klimstra DS, et al. The value of minimal access surgery in the staging of patients with potentially resectable peripancreatic malignancy. *Ann Surg*. 1996;223:134–140.
103. John TG, Greig JD, Carter DC, et al. Carcinoma of the pancreatic head and periampullary region: tumor staging with laparoscopy and laparoscopic ultrasonography. *Ann Surg*. 1995;221:156–164.
104. Bemelman WA, de Wit LT, van Delden OM, et al. Diagnostic laparoscopy combined with laparoscopic ultrasonography in staging of cancer of the pancreatic head region. *Br J Surg*. 1995;82:820–824.
105. Fernandez-del Castillo C, Rattner DW, Warshaw AL. Further experience with laparoscopy and peritoneal cytology in the staging of pancreatic cancer. *Br J Surg*. 1995;82:1127–1129.
106. Reddy KR, Levi J, Livingstone A, et al. Experience with staging laparoscopy in pancreatic malignancy. *Gastrointest Endosc*. 1999;49:498–503.
107. Yoshida T, Matsumoto T, Morii Y, et al. Staging with helical computed tomography and laparoscopy in pancreatic head cancer. *Hepatogastroenterology*. 2002;49:1428–1431.
108. Conlon KC, Brennan MF. Laparoscopy for staging abdominal malignancies. *Adv Surg*. 2000;34:331–350.
109. White R, Winston C, Gonen M, et al. Current utility of staging laparoscopy for pancreatic and peripancreatic neoplasms. *J Am Coll Surg*. 2008;206:445–450.
110. Doran HE, Bosonnet L, Connor S, et al. Laparoscopy and laparoscopic ultrasound in the evaluation of pancreatic and periampullary tumors. *Dig Surg*. 2004;21:305–313.
111. Halloran C, Ghaneh P, Connor S, Sutton R, Neoptolemos J, Raraty MGT. Carbohydrate antigen 19-9 accurately selects patients for laparoscopic assessment to determine resectability of pancreatic malignancy. *Br J Surg*. 2008;95:453–459.
112. Maithel SK, Maloney S, Winston C, et al. Preoperative Ca 19-9 and the yield of staging laparoscopy in patients with radiographically resectable pancreatic adenocarcinoma. *Ann Surg Oncol*. 2008;15:3512–3520.
113. Mayo SC, Austin DF, Sheppard Bc, Mori M, Shipley DK, Billingsley KG. Evolving preoperative evaluation of patients with pancreatic cancer: does laparoscopy have a role in the current era? *J Am Coll Surg*. 2009;208:87–95.
114. Cuesta MA, Meijer S, Borgstein PJ, et al. Laparoscopic ultrasonography for hepatobiliary and pancreatic malignancy. *Br J Surg*. 1993;80:1571–1574.
115. Ascher SM, Evans SR, Zeman RK. Laparoscopic cholecystectomy: intraoperative ultrasound of the extrahepatic biliary tree and the natural history of postoperative transabdominal ultrasound findings. *Semin Ultrasound CT MR*. 1993;14:331–337.
116. John TG, Wright A, Allan PL, et al. Laparoscopy with laparoscopic ultrasonography in the TNM staging of pancreatic carcinoma. *World J Surg*. 1999;23:870–881.
117. Minnard EA, Conlon KC, Hoos A, et al. Laparoscopic ultrasound enhances standard laparoscopy in the staging of pancreatic cancer. *Ann Surg*. 1998;228:182–187.
118. Pietrabissa A, Caramella D, Di Candio G, et al. Laparoscopy and laparoscopic ultrasonography for staging pancreatic cancer: critical appraisal. *World J Surg*. 1999;23:998–1002.
119. Murugiah M, Paterson-Brown S, Windsor JA, et al. Early experience of laparoscopic ultrasonography in the management of pancreatic carcinoma. *Surg Endosc*. 1993;7:177–181.



120. Schachter PP, Avni Y, Shimonov M, Gvirtz G, Rosen A, Czerniak A. The impact of laparoscopy and laparoscopic ultrasonography on the management of pancreatic cancer. *Arch Surg.* 2000;135:1303–1307.
121. Catheline J, Turner R, Rizk N. The use of diagnostic laparoscopy supported by laparoscopic ultrasonography in the assessment of pancreatic cancer. *Surg Endoscopy.* 1999;13:239–245.
122. Vollmer CM, Drebin JA, Middleton WD, et al. Utility of staging laparoscopy in subsets of peripancreatic and biliary malignancies. *Ann Surg.* 2002;235:1–7.
123. Merchant NB, Conlon KC, Saigo P, et al. Positive peritoneal cytology predicts unresectability of pancreatic adenocarcinoma. *J Am Coll Surg.* 1999;188:421–426.
124. Loyer EM, David CL, Dubrow RA, Evans DB, Charnsangavej C. Vascular involvement in pancreatic adenocarcinoma: reassessment by thin-section CT. *Abdom Imaging.* 1996;21:202–206.
125. Thomson BNJ, Parks RW, Redhead DN, et al. Refining the role of laparoscopy and laparoscopic ultrasound in the staging of presumed pancreatic head and ampullary tumours. *Br J Cancer.* 2006;94:213–217.
126. Hariharan D, Constantinides VA, Froeling FEM, Tekkis PP, Kocher HM. *EJSO.* 2010;36:941–948.
127. Jimenez RE, Warsaw AL, Fernandez-del Castillo C. Laparoscopy and peritoneal cytology in the staging of pancreatic cancer. *J Hepatobil Pancreat Surg.* 2000;7:15–20.
128. Fernandez-del Castillo CL, Warsaw AL. Pancreatic cancer: laparoscopic staging and peritoneal cytology. *Surg Oncol Clin North Am.* 1998;7:135–142.
129. Leach SD, Rose JA, Lowy AM, et al. Significance of peritoneal cytology in patients with potentially resectable adenocarcinoma of the pancreatic head. *Surgery.* 1995;118:472–478.
130. Dalal KM, Woo Y, Galanis C, et al. Detection of micrometastases in peritoneal washings of pancreatic cancer patients by the reverse transcriptase polymerase chain reaction. *J Gastrointest Surg.* 2007;11:1598–1601.
131. Abdalla EK, Barnett CC, Pisters PW, et al. Subaqueatic laparoscopy for staging of intraabdominal malignancy. *J Am Coll Surg.* 2003;196:155–158.
132. Spitz FR, Abbruzzese JL, Lee JE, et al. Preoperative and postoperative chemoradiation strategies in patients treated with pancreaticoduodenectomy for adenocarcinoma of the pancreas. *J Clin Oncol.* 1997;15:928–937.
133. Obertop H, Gouma DJ. Essentials in biliopancreatic staging: a decision analysis. *Ann Oncol.* 1999;10:150–152.
134. Nieveen van Dijkum EJ, Romijn MG, Terwee CB, et al. Laparoscopic staging and subsequent palliation in patients with peripancreatic carcinoma. *Ann Surg.* 2003;237:66–73.
135. Shoup M, Winston C, Brennan MF, et al. Is there a role for staging laparoscopy in patients with locally advanced unresectable pancreatic adenocarcinoma? *J Gastrointest Surg.* 2004;8:1068–1071.
136. Liu RC, Traverso W. Diagnostic laparoscopy improves staging of pancreatic cancer deemed locally unresectable by computed tomography. *Surg Endosc.* 2005;19:638–642.
137. Morak MJM, Hermans JJ, Smeenk Hg, et al. Staging for locally advanced pancreatic cancer. *EJSO.* 2009;35:963–968.
138. Hochwald SN, Weiser MR, Colleoni R, et al. Laparoscopy predicts metastatic disease and spares laparotomy in selected patients with pancreatic non-functioning islet cell tumors. *Ann Surg Oncol.* 2001;8:249–253.
139. Brooks AD, Mallis MJ, Brennan MF, et al. The value of laparoscopy in the management of ampullary, duodenal, and distal bile duct tumors. *J Gastrointest Surg.* 2002;6:139–145.
140. Rodgers MS, Windsor JA, Koea JB, McCall JL. Laparoscopic staging of upper gastrointestinal malignancy. *ANZ J Surg.* 2003;73(10):806–810.
141. Dobronze Z, Wittmann T, Karacsony G. Rapid development of malignant metastases in the abdominal wall after laparoscopy. *Endoscopy.* 1978;10:127–130.
142. Nieveen van Dijkum EJ, de Wit LT, van Delden OM, et al. Staging laparoscopy and laparoscopic ultrasonography in more than 400 patients with upper gastrointestinal carcinoma. *J Am Coll Surg.* 1999;189:459–465.
143. Pearlstone DB, Mansfield PF, Curley SA, et al. Laparoscopy in 533 patients with abdominal malignancy. *Surgery.* 1999;125:67–72.
144. Shoup M, Brennan MF, Karpeh MS, et al. Port site metastasis after diagnostic laparoscopy for upper gastrointestinal tract malignancies: an uncommon entity. *Ann Surg Oncol.* 2002;9:632–636.
145. Hughes ES, McDermott FT, Polglase AL, et al. Tumor recurrence in the abdominal wall scar tissue after large-bowel cancer surgery. *Dis Colon Rectum.* 1983;26:571–572.
146. Velanovich V. The effects of staging laparoscopy on trocar site and peritoneal recurrence of pancreatic cancer. *Surg Endosc.* 2004;18:310–313.
147. Bouvy ND, Marquet RL, Jeekel H, et al. Impact of gas(less) laparoscopy and laparotomy on peritoneal tumor growth and abdominal wall metastases. *Ann Surg.* 1996;224:694–700; discussion 700–701.
148. Jones DB, Guo LW, Reinhard MK, et al. Impact of pneumoperitoneum on trocar site implantation of colon cancer in hamster model. *Dis Colon Rectum.* 1995;38:1182–1188.
149. Yamaguchi K, Hirabayashi Y, Shiromizu A, et al. Enhancement of port site metastasis by hyaluronic acid under CO<sub>2</sub> pneumoperitoneum in a murine model. *Surg Endosc.* 2001;15:504–507.
150. Curet MJ. Port site metastases. *Am J Surg.* 2004;187:705–712.
151. Rhodes M, Nathanson L, Fielding G. Laparoscopic biliary and gastric bypass: a useful adjunct in the treatment of carcinoma of the pancreas. *Gut.* 1995;36:778–780.
152. Rothlin MA, Schob O, Weber M. Laparoscopic gastroand hepaticojejunostomy for palliation of pancreatic cancer: a case-controlled study. *Surg Endosc.* 1999;13:1065–1069.
153. Choi YB. Laparoscopic gastrojejunostomy for palliation of gastric outlet obstruction in unresectable gastric cancer. *Surg Endosc.* 2002;16:1620–1626.
154. Navarra G, Musolino C, Venneri A, deMarco ML, Bartolotta M. Palliative antecolic isoperistaltic gastrojejunostomy: a randomized controlled trial comparing open and laparoscopic approaches. *Surg Endosc.* 2006;20:1831–1834.
155. Bucher P, Pugin F, Morel P. Transumbilical single-incision laparoscopic intracorporeal anastomosis for gastrojejunostomy: a case report. *Surg Endosc.* 2009;1667–1670.
156. Espat NJ, Brennan MF, Conlon KC. Patients with laparoscopically staged unresectable pancreatic adenocarcinoma do not require subsequent surgical biliary or gastric bypass. *J Am Coll Surg.* 1999;188:649–657.
157. Sohn TA, Lillemoie KD, Cameron JL, et al. Surgical palliation of unresectable periampullary adenocarcinoma in the 1990s. *J Am Coll Surg.* 1999;188:658–669.
158. Molinari M, Helton WS, Espat NJ. Palliative strategies for locally advanced unresectable and metastatic pancreatic cancer. *Surg Clin North Am.* 2002;81:651–666.
159. Casaccia M, Diviacco P, Molinello P, et al. Laparoscopic palliation of unresectable pancreatic cancers: preliminary results. *Eur J Surg.* 1999;165:556–559.
160. Yim HB, Jacobson BC, Saltzman JR, et al. Clinical outcome of the use of enteral stents for palliation of patients with malignant upper GI obstruction. *Gastrointest Endosc.* 2001;53:329–332.
161. DiMango EP, Reber HA, Tempero MA. AGA technical review on the epidemiology, diagnosis, and treatment of pancreatic ductal adenocarcinoma. *Gastroenterology.* 1999;117:1464–1484.
162. Nagy A, Brosseuk D, Hemming A, et al. Laparoscopic gastroenterostomy for duodenal obstruction. *Am J Surg.* 1995;165:539–542.

*This page intentionally left blank*



# ABDOMINAL WALL

*This page intentionally left blank*



# INCISIONS, CLOSURES, AND MANAGEMENT OF THE ABDOMINAL WOUND

Robert E. Roses • Jon B. Morris

## INCISIONS

The impact that the planning, execution, and closure of an incision has on the outcome of an abdominal operation should not be underestimated. The high combined incidence of surgical site infection (SSI), wound dehiscence, and hernia formation suggests a dominant contribution of wound complications to surgical morbidity. Moreover, the quality of exposure provided by an incision influences the ease and safety with which an operation can be undertaken and the outcome in ways which defy easy quantification.

An incision must provide access to the site of abdominal pathology and allow easy extension if greater exposure than originally anticipated is required. Indeed, the adequacy of an incision is determined above all else by the safety with which an operation can be undertaken. Nothing should compromise this and a larger incision or even, on occasion, a second incision should be created without hesitation if exposure is inadequate. Notwithstanding this, the incision should be executed in a fashion that anticipates a secure wound closure and interferes as little as possible with the function and cosmesis of the abdominal wall. These principles apply to both open and laparoscopic incisions. While the vertical midline incision remains most popular, and is, perhaps the most flexible, a variety of other incisions may have distinct advantages in specific settings.

### Choice of Incision

Abdominal incisions can be vertically, transversely, or obliquely oriented. The avascular linea alba affords the vertical midline its superior flexibility. Indeed, when optimal exposure of the abdominal cavity is necessary (eg, exploration for abdominal trauma), the vertical midline incision is preferred and can be extended superiorly to the xiphoid process and inferiorly to the symphysis pubis. Alternatively, vertical incisions may be placed in a paramedian position, an approach that was

previously more popular than it is today but continues to have its proponents. Transverse and oblique incisions can be placed in any of the four quadrants of the abdomen depending on the site of pathology. Common examples include the Kocher subcostal incision for biliary surgery, the Pfannenstiel infraumbilical incision for gynecologic surgery, and the McBurney and Rockey-Davis incisions for appendectomy. A bilateral subcostal incision affords excellent exposure of the upper abdomen. Alternatively, when superior exposure of upper abdominal organs (eg, the esophagogastric junction) is required, thoracoabdominal incisions may be used.

The relative merit of vertical versus transverse incisions remains a topic of active debate. Proponents of transverse incisions argue that they anticipate a more secure closure than do vertical incisions, a hypothesis supported by anatomic and surgical principle. The fascial fibers of the anterior abdominal wall are oriented transversely or obliquely. Therefore, transverse incisions parallel the direction of the fascial fibers and allow for ready reapproximation with sutures placed perpendicular to these fibers. In contrast, vertical incisions disrupt fascial fibers and must be reapproximated with sutures placed between fibers.<sup>1</sup> In the latter case, the absence of an anatomic barrier may predispose such sutures to pull through tissue resulting in dehiscence or hernia formation. Despite these concerns, little evidence supports a substantial benefit of transverse incisions. A number of retrospective clinical studies and a meta-analysis do suggest that transverse incisions are superior to vertical incisions with regard to long-term and short-term outcomes (eg, postoperative pain, pulmonary complications, and frequencies of incisional hernia and dehiscence).<sup>1</sup> Prospective data has been less definitive, however. One randomized controlled trial compared vertical and transverse incisions with regards to the frequency of evisceration; no significant difference in outcome was observed with either technique.<sup>2</sup> In a more recent prospective randomized trial, no significant differences in 30-day mortality, pulmonary complications, median length of hospital stay, median time to tolerate

solid food, and incisional hernia formation at 1 year were observed. More wound infections were seen with transverse incisions.<sup>3</sup>

Likewise, some controversy persists regarding the relative advantages of midline versus paramedian incisions. The theoretical advantage of a paramedian over a midline incision is a diminished risk of wound dehiscence and incisional hernia owing to the presence of rectus muscle interposed between layers of divided fascia. In practice, when these incisions are reopened, the medial edge of the rectus muscle is frequently found to be adherent to the posterior sheath incision and does not effectively buttress the wound. The potential advantages of the paramedian incision have also been investigated in prospective randomized trials which fail to demonstrate any advantage with regards to wound failure rates when compared to midline or transverse incisions.<sup>4</sup> A “lateral paramedian incision” refers to a vertical incision created several centimeters lateral to the location of the traditional paramedian incision.<sup>5</sup> One randomized prospective study suggested a statistically significant decrease in the incidence of incisional hernia following closure of lateral paramedian incisions (0%) compared to medial paramedian incisions (14.9%)<sup>6</sup> and midline incisions (6.9%).<sup>7</sup> A disadvantage of the paramedian incision is the greater length of time needed to create the wound, which increases with the distance from the midline.

In the patient who has had prior abdominal surgery, the cosmetic advantages of re-entering the abdomen through a preexisting scar must be balanced against the challenges associated with dissection in a reoperative field. Close proximity of a new incision to an old one should be avoided in order to minimize the risk of ischemic necrosis of intervening skin and fascial bridges.

## Preparation of the Surgical Site

Prior to incision, the surgical field is prepared with antiseptic solution and draped in order to reduce skin bacterial counts and the likelihood of subsequent wound infection. Shaving prior to operation has been associated with an increased rate of SSI and should, therefore, be avoided. If hair at the surgical site will interfere with accurate wound closure or precludes thorough application of the sterile preparation, the use of clippers is preferred to a razor.<sup>8</sup> A variety of antiseptic solutions are commonly used to prepare the skin, including povidone-iodine, alcohol, and chlorhexidine. The efficacy of povidone-iodine depends on the release of the active iodine from a carrier molecule. The solution should, therefore, be applied several minutes prior to incision to maximize its efficacy. The use of chlorhexidine gluconate has been associated with greater reductions in skin bacterial counts and lower rates of SSI when compared to povidone-iodine in a number of studies<sup>6,9,10</sup> and is emerging as the preferred skin antiseptic.

## Incisions: Technical Considerations

### VERTICAL INCISIONS

**Midline Incision.** The midline incision allows rapid access to, and adequate exposure of, almost every region of the abdominal cavity and retroperitoneum. It is typically associated with little blood loss and does not require transection of muscle fibers or nerves. The upper midline incision (ie, above the umbilicus) may be used to expose the esophageal hiatus, abdominal esophagus and vagus nerves, stomach, duodenum, gallbladder, pancreas, and spleen (Fig. 6-1). The lower midline incision (ie, below the umbilicus) provides exposure of lower abdominal and pelvic organs. When broad exposure is required, as in an exploration for trauma, the midline incision can be extended to the xiphoid process superiorly and to the pubic symphysis inferiorly.

In creating a midline incision, the operating surgeon and assistant apply opposing traction to the skin on both sides of the abdomen. The skin is then incised with a scalpel. Gauze pads are applied to the skin edges to tamponade bleeding cutaneous vessels and lateral traction is placed on the subcutaneous fat on both sides of the incision. The incision is then carried down to the linea alba using either electrocautery or a scalpel; the decussation of fascial fibers in the upper abdomen serves as an important landmark for the midline. The linea alba, extraperitoneal fat, and peritoneum are then divided sequentially. If exposure of both the upper and lower peritoneal cavities is required, the incision is carried around the umbilicus in a curvilinear fashion. The peritoneum itself is best divided with scissors or scalpel to avoid coagulation injury to underlying intraabdominal organs. Additionally, safe entry may be facilitated by picking up a fold of peritoneum, palpating it to ensure that no bowel has been drawn up, and sharply incising the raised fold. The falciform ligament is best avoided by entering the peritoneum to the left or right of the midline in the upper abdomen.

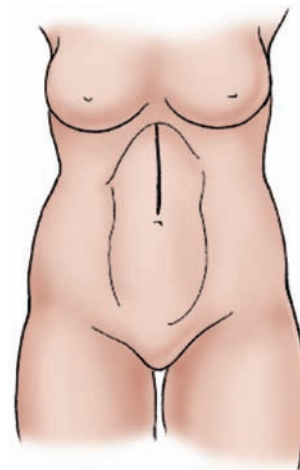
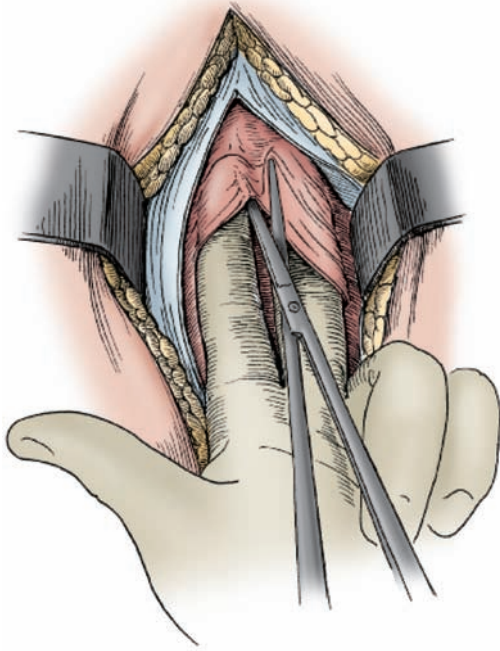


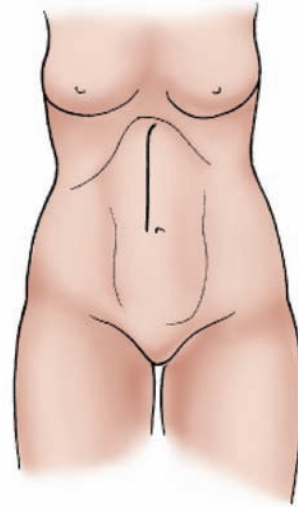
FIGURE 6-1 Epigastric midline incision: surface markings.



**FIGURE 6-2** Vertical midline incision: the linea alba and peritoneum are divided.

To avoid injuries to the bladder, the peritoneum is entered in the upper portion of the incision. After a small opening is created in the midline, it is enlarged to accommodate two fingers that are then used to protect the underlying viscera as the peritoneum is further divided along the length of the wound (Fig. 6-2).

**Paramedian Incision.** Paramedian incisions are vertical incisions placed either to the right or the left of the midline on the abdominal wall. Like midline incisions, paramedian incisions obviate division of nerves and the rectus muscle and may be made in the upper or lower abdomen. Superiorly, additional access can be obtained by curving the upper portion of the incision along the costal margin toward the xiphoid process (Fig. 6-3). The anterior border of the rectus sheath is exposed and incised across the entire length of the wound. The medial aspect of the anterior rectus sheath is then dissected away from the rectus muscle to its medial edge (Fig. 6-4). Particular care must be taken during this dissection in the upper abdomen where tendinous inscriptions that attach the rectus muscle to the anterior fascia are associated with segmental vessels. These vessels should be clipped or ligated when encountered to avoid significant bleeding. Once free, the rectus muscle is retracted laterally. The posterior sheath (above the arcuate line) and peritoneum are then incised to gain entry into the abdomen. During creation of a paramedian incision in the lower abdomen, the inferior epigastric vessels may be encountered and must be ligated prior to division (Fig. 6-5).



**FIGURE 6-3** Upper paramedian incision: surface markings. Additional exposure can be obtained by sloping the upper portion of the incision upward toward the xiphoid process.

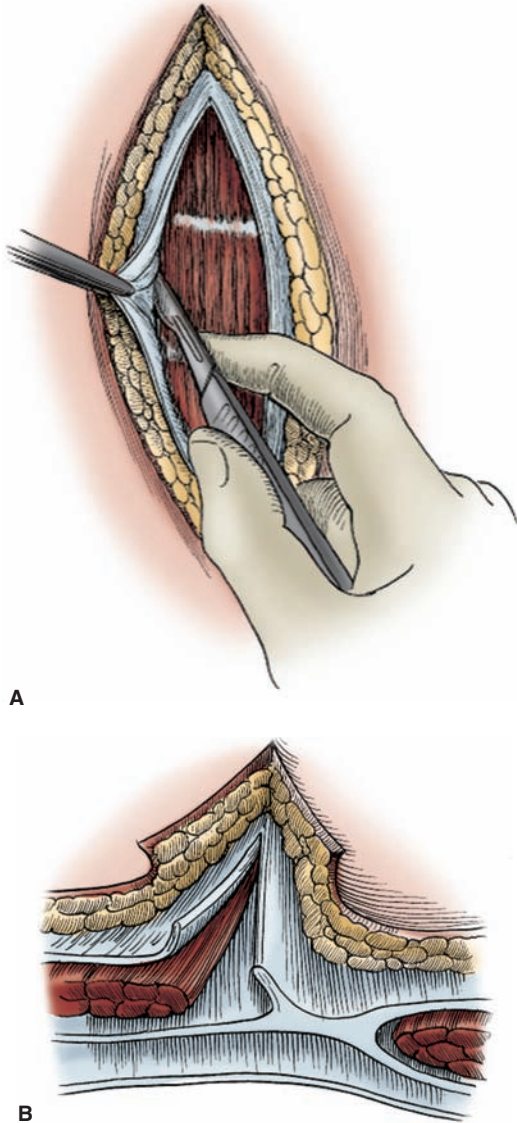
**Vertical Muscle-Splitting Incision.** The vertical muscle-splitting incision is made in much the same way as the traditional paramedian incision except that the rectus muscle is split, rather than retracted laterally. This wound can be opened and closed quickly and is of particular value in reopening a previous paramedian incision where dissection of the rectus muscle away from the rectus sheath can be difficult. Longer incisions should be avoided, however, because they result in significantly more bleeding and sacrifice of nerves that may lead to weakening of the corresponding area of the abdominal wall.

## TRANSVERSE AND OBLIQUE INCISIONS

Transverse and oblique incisions generally follow Langer's lines of tension and usually allow a more cosmetic closure than do vertical incisions. Importantly, the rectus muscle has a segmental nerve supply derived from intercostal nerves, which enter the rectus sheath laterally. Transverse or slightly oblique incisions through the rectus most often spare these nerves. Provided that the anterior and posterior sheaths are closed, the rectus muscle can therefore be divided transversely without significantly compromising the integrity of the abdominal wall. Although properly placed transverse incisions can provide exposure of specific organs, they may be limiting when pathology is located in both the upper and lower abdomen.

**Kocher Subcostal Incision.** A right subcostal incision is used commonly for operations in which exposure of the gallbladder and biliary tree is necessary. The left-sided subcostal incision is used less often, mainly for splenectomy. A bilateral subcostal incision provides excellent exposure of the upper abdomen and can be employed for hepatic resections, liver transplantation, total gastrectomy, and for anterior access to both adrenal glands.





**FIGURE 6-4** **A.** Paramedian incision: dissection of the rectus muscle from the anterior rectus sheath. **B.** Paramedian incision in transverse section.

The standard subcostal incision begins at the midline, two fingerbreadths below the xiphoid process and is extended laterally and inferiorly, parallel to the costal margin (Fig. 6-6). The incision should not be placed too far superiorly as sufficient fascia must be preserved to allow a secure abdominal closure. Following incision of the rectus sheath along the plane of the skin incision, the rectus muscle is divided using electrocautery or ligatures to control branches of the superior epigastric artery. The peritoneum is then divided in the plane of the skin incision. The incision can be extended beyond the lateral aspect of the rectus muscle if necessary to facilitate exposure.

**McBurney and Rockey-Davis Incisions.** Originally described by Charles McBurney in 1894,<sup>11</sup> the muscle-splitting

right iliac fossa incision known as the *McBurney* incision is well suited for appendectomy. This incision is oriented obliquely. The McBurney incision has largely been supplanted by the Rockey-Davis incision, which is oriented transversely as opposed to obliquely, allowing for better cosmesis (Fig. 6-7).

The suspected position of the appendix and the thickness of the abdominal wall influence the placement of the incision as well as its length. Examination of the anesthetized patient's abdomen will often reveal a mass, guiding placement of the incision directly over the appendix. If no mass is palpable, the incision is centered over McBurney's point at the junction of the middle and outer thirds of the line between the umbilicus and the anterior superior iliac spine. If the patient is obese, or if extension of the incision is anticipated, the incision should be placed obliquely, allowing ready lateral extension.

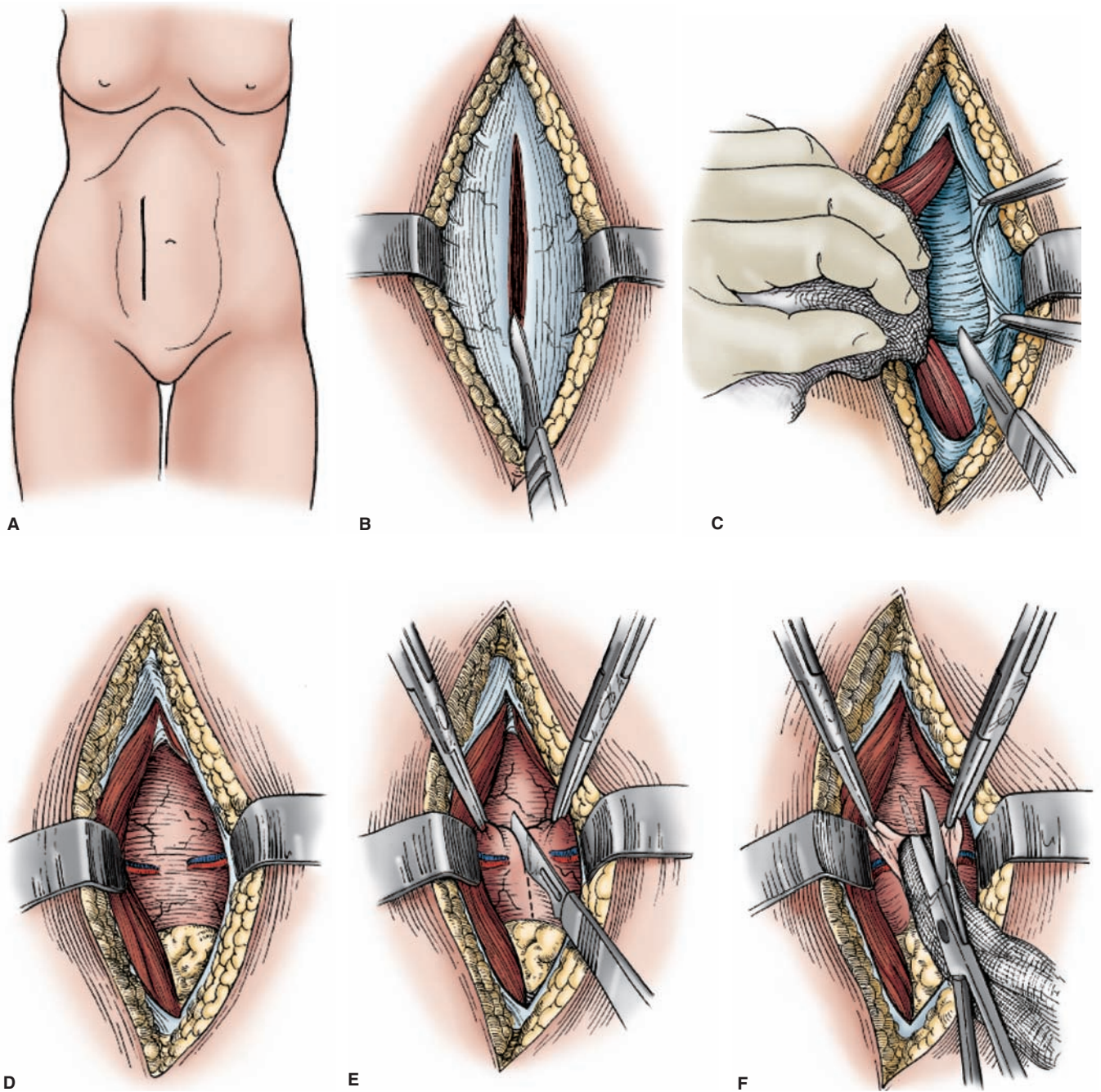
After skin and subcutaneous tissues are incised, the external oblique aponeurosis is exposed and divided parallel to the direction of its fibers to reveal the underlying internal oblique muscle. At a point adjacent to the lateral border of the rectus sheath, a small incision is made in the internal oblique muscle, which is similarly opened in the direction of its fibers. Once the underlying transversalis muscle is exposed, it is split to reveal the transversalis fascia and peritoneum. These are sharply divided and the appendix and cecum are exposed (Fig. 6-8). If further exposure is necessary, the wound can be enlarged by dividing the rectus sheath, retracting the rectus muscle medially, and extending the peritoneal defect. If the operation requires extension of the wound laterally, this can be accomplished through division of the oblique muscles.

**Pfannenstiel Incision.** The Pfannenstiel incision is used frequently for gynecologic operations and for access to the retroperic space (eg, for extraperitoneal retroperic prostatectomy). The skin incision is placed in the interspinous crease above the symphysis pubis. The anterior rectus sheath is exposed and divided transversely. The superior and inferior leaflets of the divided sheath are dissected from the underlying rectus muscles superiorly to the umbilicus and inferiorly to the pubic symphysis. The recti are retracted laterally and the peritoneum is opened vertically in the midline. At the inferior aspect of the wound, the bladder is protected to avoid injury (Fig. 6-9). An advantage of this incision is that it affords a cosmetic closure because it is placed in a skin crease at the level of the belt line; however, exposure may be somewhat limited.

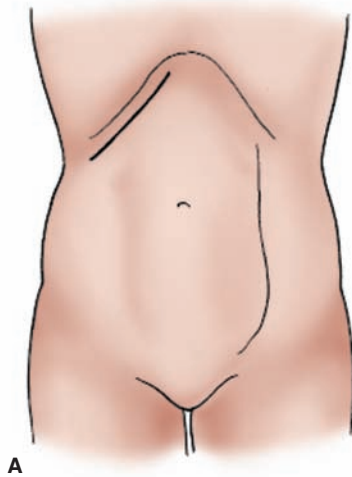
## ABDOMINOTHORACIC INCISIONS

The thoracoabdominal incision provides enhanced exposure of upper abdominal organs. A left thoracoabdominal incision is useful for access to the left hemidiaphragm, gastroesophageal junction, gastric cardia and stomach, distal pancreas and spleen, left kidney and adrenal gland, and aorta. A right thoracoabdominal incision can be used to expose the right hemidiaphragm, esophagus, liver, portal triad, inferior vena cava, right kidney, right adrenal gland, and proximal pancreas.

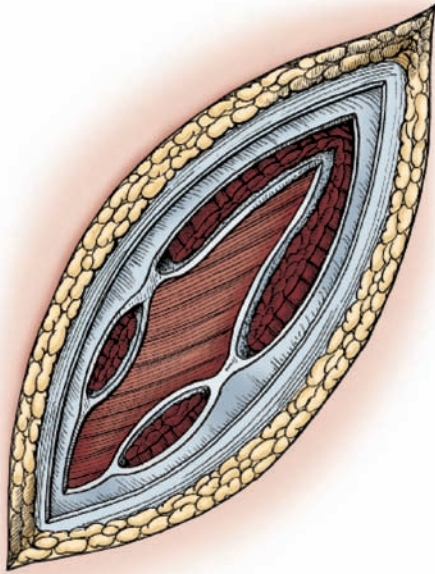




**FIGURE 6-5** Lower paramedian incision. **A.** Surface markings. **B.** Incision of the rectus sheath. **C.** Retraction of the rectus abdominis muscle. **D.** Location of the branches of the inferior epigastric vessels that run across the lower portion of the incision. **E.** Peritoneum opened. **F.** The peritoneum is incised for the full length of the wound.



A

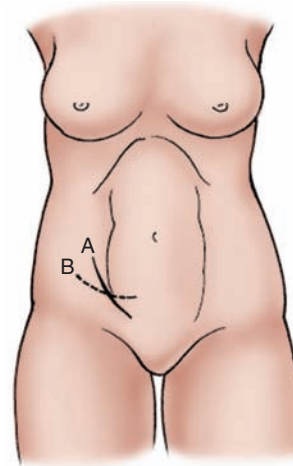


B

**FIGURE 6-6** Kocher incision. **A.** Surface markings. **B.** Division of the rectus and medial portions of the lateral abdominal muscles.

These incisions are reserved for circumstances in which an operation cannot safely be performed through an abdominal incision, as they are theoretically associated with increased morbidity relating to a more difficult pulmonary recovery and risk of phrenic nerve injury.

The patient is placed in the “corkscrew” position on the operating room table to enhance access to both the abdominal and thoracic cavities. The abdomen is tilted approximately 45 degrees from the horizontal plane and the thorax is oriented in full lateral position (Fig. 6-10A). Positioning is aided by the use of a bean bag. The abdominal part of the incision may consist of a midline or upper paramedian incision, which allows exploration of the abdomen. The incision is extended obliquely along the line of the eighth interspace



**FIGURE 6-7** Surface markings of the right iliac fossa appendectomy incisions. **A.** The classic McBurney incision is obliquely placed. **B.** The Rocky-Davis incision is transversely placed in a skin crease.

just beneath the inferior pole of the scapula (Fig. 6-10B). Alternatively, an oblique upper abdominal incision can be used and extended directly into the thoracic portion of the incision.

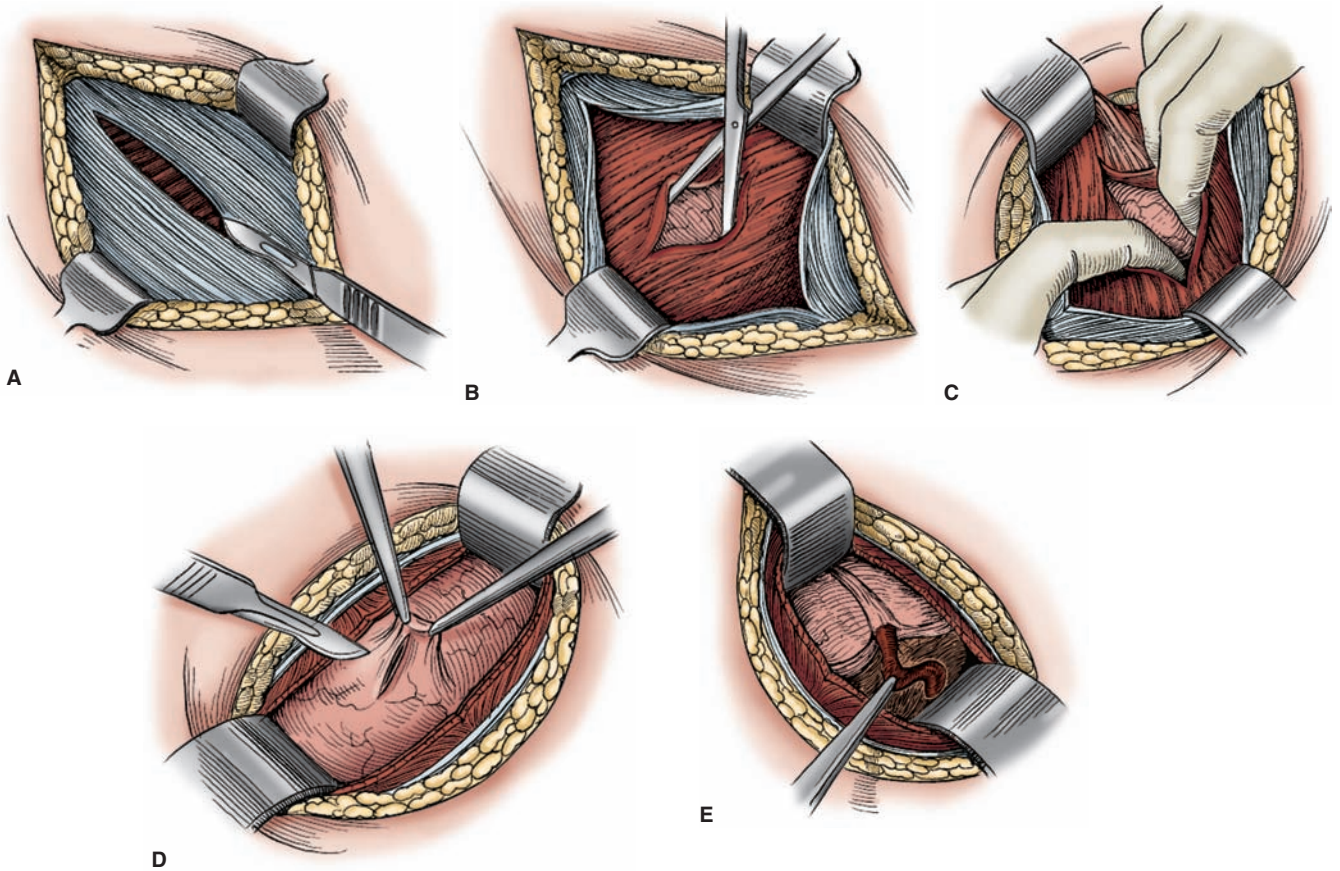
After entry into the peritoneal cavity through the abdominal portion of the incision, the incision is extended onto the chest wall and the latissimus dorsi and serratus anterior muscles, and then the external oblique muscle and aponeurosis are divided. The intercostal muscles of the eighth interspace are divided to allow entry into the chest cavity and the incision is extended across the costal margin, which is divided with a scalpel. It is often useful to resect a short segment of costal cartilage to facilitate closure of the chest wall. A self-retaining rib retractor is inserted and the intercostal space is gently spread. The diaphragm is either incised radially toward the esophageal or aortic hiatus, or in a curvilinear fashion if less exposure is required. This incision also preserves phrenic nerve function and is useful for patients with pulmonary compromise.<sup>12</sup>

At the completion of the operation, chest tubes placed in the pleural cavity are brought out through the chest or upper abdominal wall through separate incisions. The diaphragm is repaired in two layers using nonresorbable sutures. Pericostal sutures are placed to reapproximate the ribs. The chest muscles and abdominal wall are then closed in layers.

## RETROPERITONEAL AND EXTRAPERITONEAL INCISIONS

Retroperitoneal and extraperitoneal approaches to the abdomen have several advantages over transperitoneal exposures. Manipulation and retraction of intraabdominal viscera are limited and postoperative ileus is reduced. Hemorrhage is more likely to be tamponaded in the retroperitoneum than when it occurs in the peritoneal cavity. Retroperitoneal and





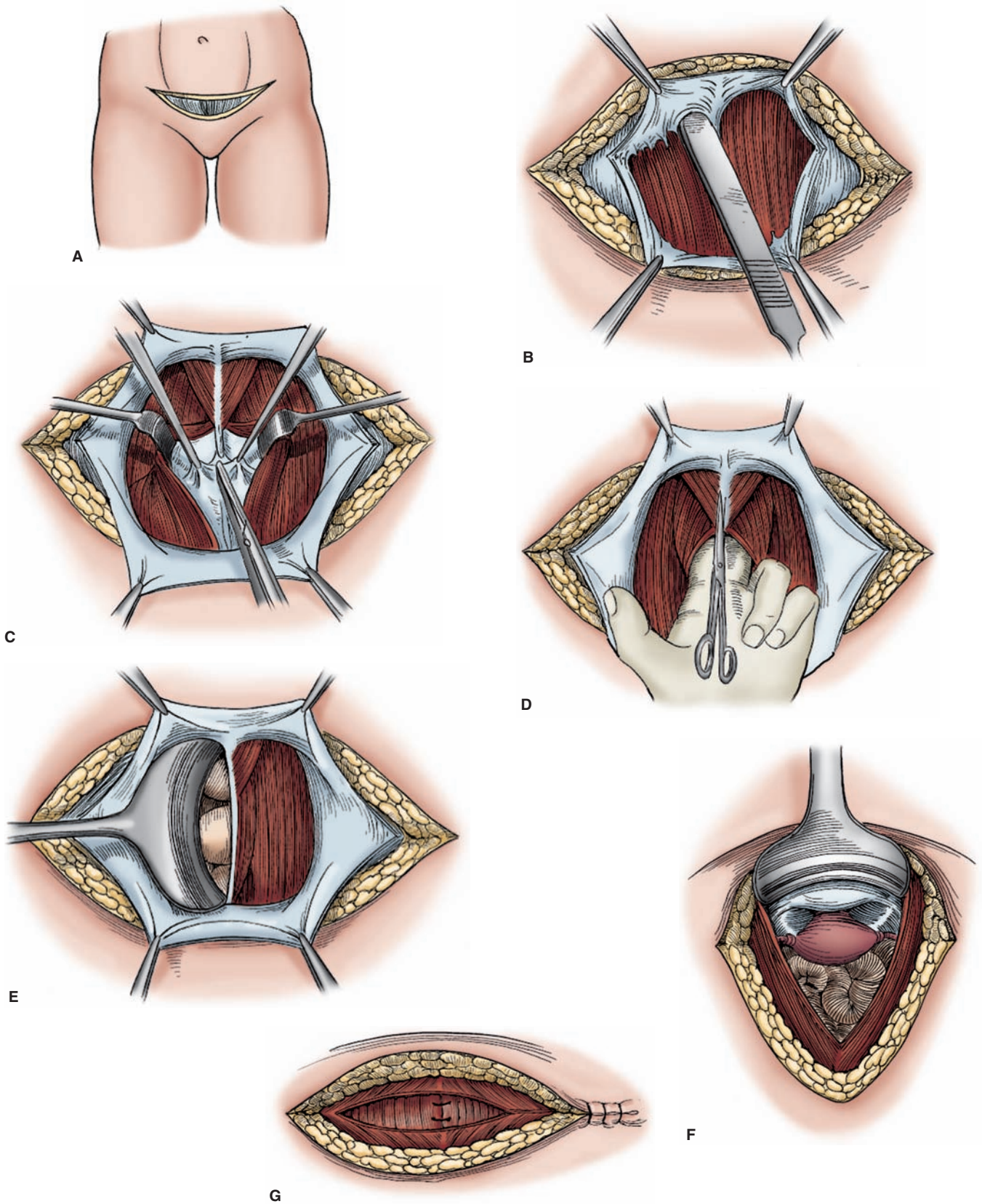
**FIGURE 6-8** McBurney muscle-splitting incision. **A.** Division of the external oblique aponeurosis. **B.** The internal oblique and transversus abdominis muscles are split. **C.** The index fingers of each hand enlarge the opening. **D.** Incision of the peritoneum. **E.** Exposure of the appendix.

extraperitoneal approaches can be used for operations on the kidney, ureter, adrenal gland, bladder, splenic artery and vein, vena cava, lumbar sympathetic chain, abdominal aorta, iliac vessels, and on groin hernias.

**Retroperitoneal Approach to the Lumbar Area.** The retroperitoneal approach to the lumbar area is frequently used for aortic surgery, nephrectomy, lumbar sympathectomy, and ureterolithomy. The patient is positioned with the operative side elevated 30–45 degrees with the knees and hips flexed. The incision extends from the lateral margin of the rectus sheath at the level of the umbilicus toward the twelfth rib for approximately 12–14 cm (Fig. 6-11). A portion of the twelfth rib is resected if necessary. The external oblique, internal oblique, and transversalis muscles are exposed, and divided in the direction of their fibers. The retroperitoneum is entered and the peritoneum and retroperitoneal fat are swept anteriorly. The lower pole of the kidney, ureter, and sympathetic chain are easily identified. The vena cava is exposed on the right and the aorta is exposed on the left. If the peritoneum is unintentionally entered, it is closed immediately with continuous absorbable suture. At the conclusion of the procedure, the retroperitoneal fat and viscera fall back into

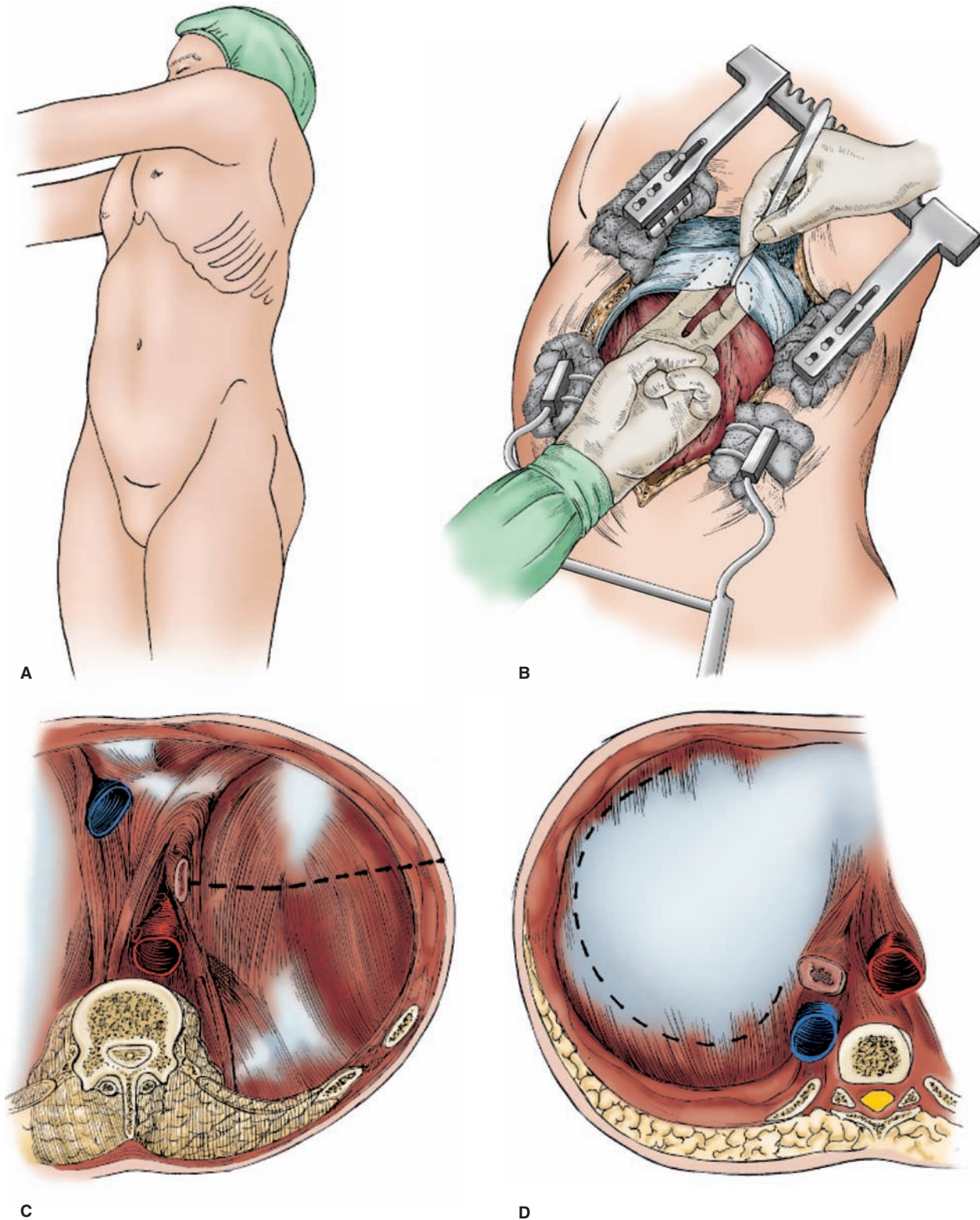
place and the muscles of the abdominal wall are reapproximated in layers.

**Posterior Approach to the Adrenal Glands.** With the posterior approach, dissection is performed entirely in the retroperitoneal space. The patient is placed in the prone jackknife position. A curvilinear incision is made beginning on the tenth rib approximately three fingerbreadths lateral to the midline and carried inferiorly and laterally toward the iliac crest, ending approximately four fingerbreadths lateral to the midline (Fig. 6-12). The subcutaneous tissues are divided to expose the posterior layer of the lumbodorsal fascia. This fascia and the fibers of the latissimus dorsi muscle, which originate from it, are divided. The erector spinae muscle is exposed and retracted medially to uncover the twelfth rib and the middle layer of the lumbodorsal fascia. The attachments of the erector spinae to the twelfth rib are divided with electrocautery; the vessels and nerves that penetrate the fascia are secured with clamps and ligated. The twelfth rib is then resected. Gerota's fascia is exposed by incising the lumbodorsal fascia along the lateral margin of the quadratus lumborum muscle. The intercostal neurovascular bundle should now become visible directly below the bed of the resected twelfth rib.

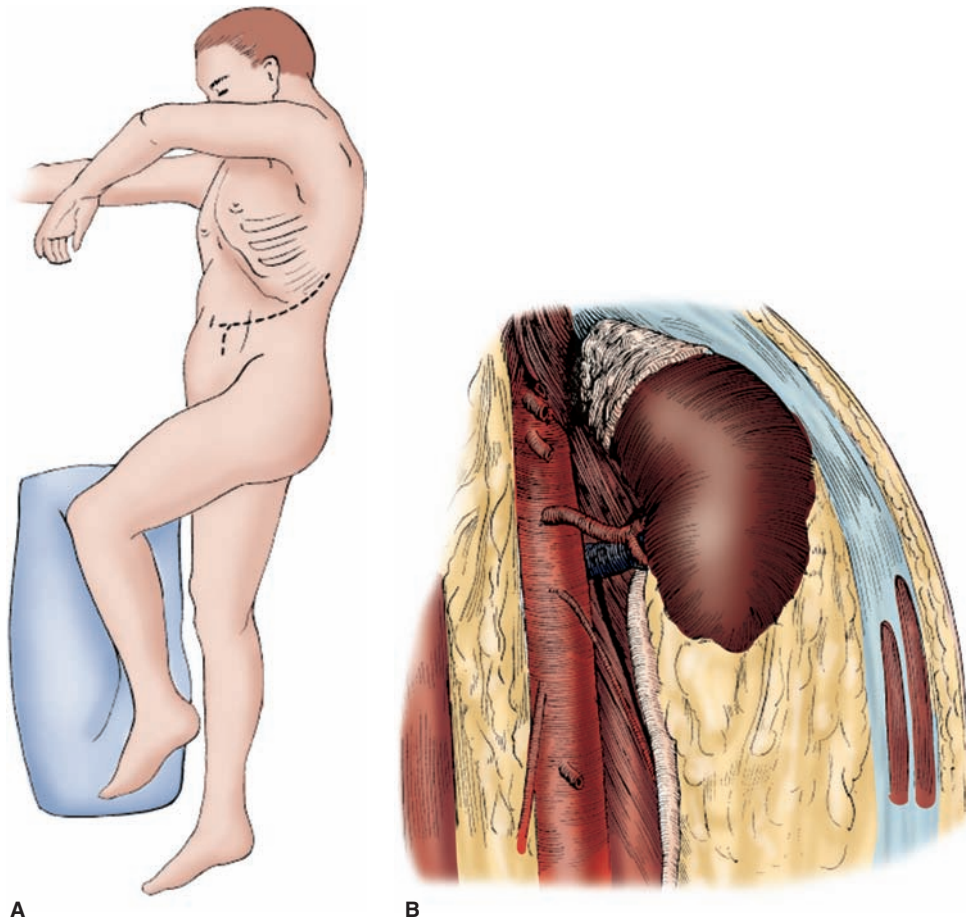


**FIGURE 6-9** Pfannenstiel incision. **A.** Skin incision. **B.** Horizontal division of the anterior rectus sheath and developing fascial flap. **C.** Dividing in the midline and entering the peritoneal cavity. **D.** Opening midline. **E.** Lateral retractors are placed for exposure. **F.** Inferior retractors placed for exposure. **G.** Closure midline and inferior rectus.





**FIGURE 6-10** Anterolateral thoracoabdominal incision. **A.** The “corkscrew” position, with the thorax in the lateral position and the abdomen at 45 degrees from the horizontal plane. Appropriate positioning on the operating table is essential to prevent injury to the brachial plexus and minimize pressure on peripheral nerves. **B.** The abdominal incision is made first; usually a vertical midline incision that is extended into the chest through the eighth intercostal space. The pleural space is then entered. **C.** The diaphragm is usually opened in a radial fashion with an incision directed toward the esophageal or aortic hiatus. **D.** The diaphragm can alternatively be opened with a hemieliptical incision 2–3 cm from the lateral chest wall; this incision preserves phrenic nerve function, of particular importance in patients with impaired pulmonary function. (Reproduced, with permission, from Penn I, Baker RJ. Abdominal wall incisions and repair. In: Baker RJ, Fischer JE, eds. *Mastery of Surgery*. 4th ed. Philadelphia, PA: Lippincott Williams & Wilkins; 2001:197.)



**FIGURE 6-11** **A.** Left lumbar approach to the retroperitoneum. **B.** The peritoneum has been bluntly dissected from the retroperitoneal structures with the preperitoneal fat and soft tissue. Origins of the celiac, superior mesenteric, left renal, and inferior mesenteric arteries are shown. (Reproduced, with permission, from Penn I, Baker RJ. Abdominal wall incisions and repair. In: Baker RJ, Fischer JE, eds. *Mastery of Surgery*. 4th ed. Philadelphia, PA: Lippincott Williams & Wilkins; 2001:194.)

The intercostal vessels are clamped, divided, and ligated and the intercostal nerve is retracted downward. The posterior fibers of the diaphragm are identified and divided where they insert on the periosteum of the twelfth rib. The lower margin of the lung will enter the field with hyperinflation. If the pleura are inadvertently injured, the resulting pneumothorax is handled at closure by insertion of a large-bore rubber catheter into the pleural cavity, which is brought out through the wound. After closure of the fascial fibers around the catheter, the lung is hyperinflated evacuating all air from the pleural space, and the catheter is briskly removed.

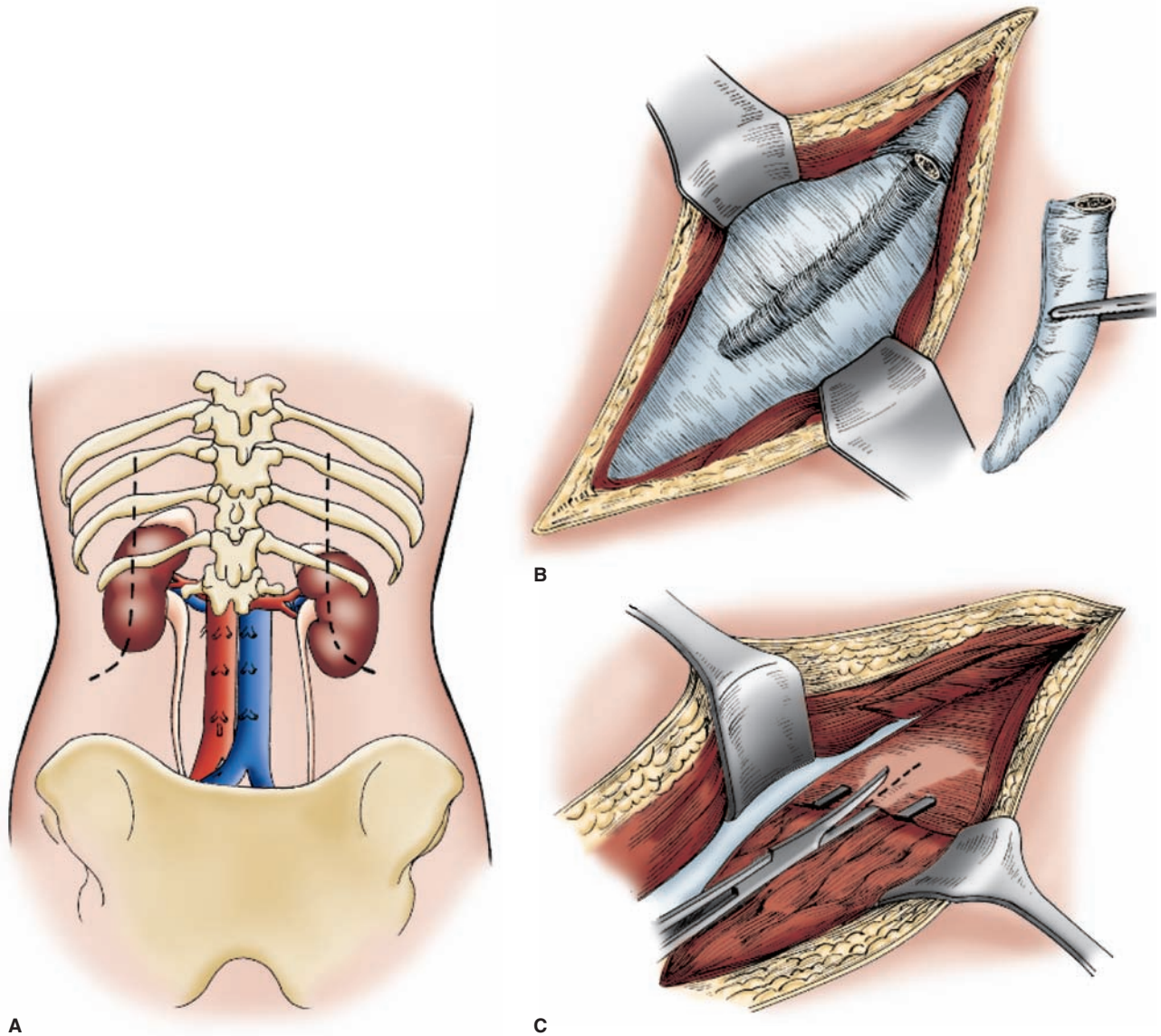
**Retroperitoneal Approach to the Iliac Fossa.** The retroperitoneal approach to the iliac fossa provides access to the bladder, distal ureter, and common, internal, and external iliac vessels. It is often employed for surgery on the iliac arteries and for kidney transplantation. It may also be used to drain psoas or retrocecal abscesses and to resect retroperitoneal tumors. The skin incision is oriented obliquely and extends from approximately 2 cm above the anterosuperior iliac spine

to a point just lateral to the pubic symphysis (Fig. 6-13). The incision can also be extended superiorly as far as the costal margin, if necessary. The external oblique, internal oblique, and transversus abdominis muscles are divided in line with the skin incision. The retroperitoneum is entered and the retroperitoneal fat and peritoneum are swept superomedially. If the peritoneum is inadvertently entered, it is closed immediately. At the conclusion of the procedure, the retroperitoneal fat and viscera fall back into place and the muscles of the abdominal wall are reapproximated in layers.

#### LAPAROSCOPIC INCISIONS

As with open abdominal incisions, laparoscopic access must allow optimal exposure without unnecessarily compromising abdominal wall function or cosmesis. Laparoscopic incisions may be placed anywhere on the abdominal wall. When appropriate, laparoscopic incisions should allow for ready extension should conversion to open operation become necessary. Additionally, laparoscopic access may be combined with small





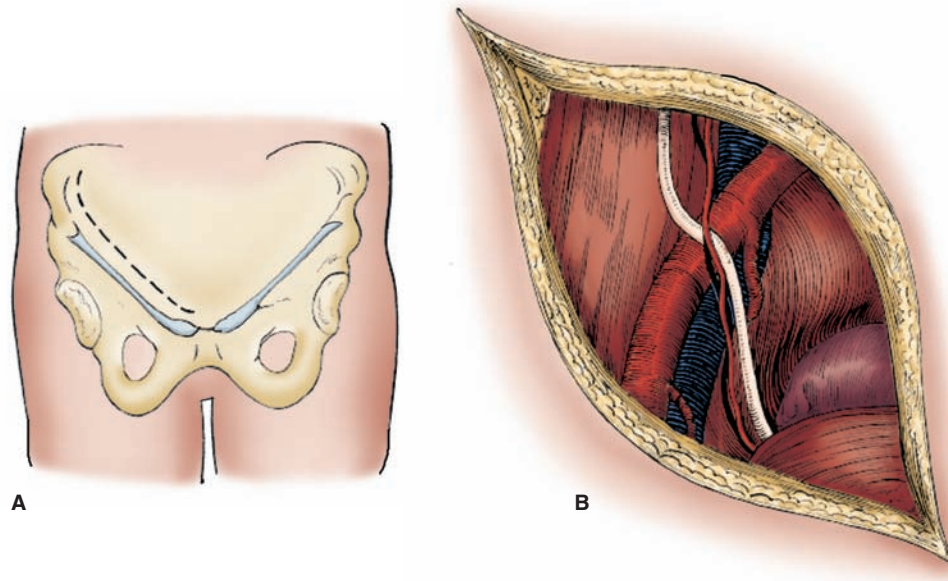
**FIGURE 6-12** The posterior approach to the kidney and adrenal. **A.** J-shaped incision over the tenth to twelfth ribs, extending inferiorly 6–10 cm below the twelfth rib. **B.** Resection of the twelfth rib facilitates exposure. **C.** The diaphragmatic attachment to the twelfth rib is taken down, with care taken not to enter the pleura. If the pleura are opened, the wound closure is performed over a pleural suction catheter, which is removed with simultaneous positive airway pressure by the anesthetist as the skin is being closed. (Reproduced, with permission, from Penn I, Baker RJ. Abdominal wall incisions and repair. In: Baker RJ, Fischer JE, eds. *Mastery of Surgery*. 4th ed. Philadelphia, PA: Lippincott Williams & Wilkins; 2001:195.)

open incisions that accommodate appliances through which a hand can be inserted into the peritoneal cavity without the loss of pneumoperitoneum. Such *hand-assisted laparoscopic* approaches are frequently associated with shorter operative times than are purely laparoscopic approaches and may have particular advantages for operation in which a larger incision is necessary to remove the surgical specimen (eg, laparoscopic colectomy) and more complex procedures.<sup>13</sup> The initial step of any laparoscopic procedure is the establishment of pneumoperitoneum. This can be achieved using an open or closed technique. Access is most often obtained at a site just above or below the umbilicus; the thinnest portion of the abdominal

wall and a central location from which all quadrants of the abdominal cavity can be visualized. Other sites are preferable in specific circumstances (eg, left upper quadrant access in a patient with a previous midline incision).

#### INITIAL ACCESS

The open approach involves the creation of a small incision, generally 1.5 cm, through which the abdominal fascia is grasped with straight clamps and elevated toward the wound. Exposure of the fascia is often enhanced with the use of S-shaped retractors. The fascia and then peritoneum are



**FIGURE 6-13** Right lower quadrant extraperitoneal approach to the iliac vessels, ureter, and bladder. **A.** The skin incision may be shorter than depicted in thinner patients or if an abscess is to be drained. **B.** Peritoneum is retracted medially by blunt dissection, which exposes the psoas muscle and gonadal artery and vein, shown anterior to the ureter. (Reproduced, with permission, from Penn I, Baker RJ. Abdominal wall incisions and repair. In: Baker RJ, Fischer JE, eds. *Mastery of Surgery*. 4th ed. Philadelphia, PA: Lippincott Williams & Wilkins; 2001:196.)

divided under direct vision. Abdominal entry is confirmed by digital palpation. Heavy stay sutures are then placed in each fascial edge and are lifted up while a blunt-tipped (Hasson) obturator and cannula are inserted through the opening in the abdominal wall. The stay sutures are then wrapped around the struts on the cannula to secure it in position. Insufflation tubing is then attached to the cannula and the obturator is withdrawn. Carbon dioxide is insufflated into the abdomen to a pressure of 12–15 mm Hg.

The closed technique involves the passage of a sharp needle (*Veress needle*) through the abdominal wall into the abdominal cavity. A small skin incision is made in the skin through which the needle is inserted, generally at an angle of 45 degrees to the abdominal wall; an angle of 90 degrees is sometimes necessary in the obese patient. As the needle passes through the fascia and then the peritoneum, a sensation of overcoming resistance is appreciated, often reinforced by an audible *click* as the blunt tip of the needle springs forward. A 10 cc syringe containing 5 cc of saline is attached to the end of the needle and is aspirated. If enteric contents, blood or urine, are not aspirated, the saline is instilled through the needle. If the needle is appropriately placed in the peritoneal cavity, saline should pass through the needle without resistance and the meniscus should descend down the hub of the needle when the syringe is detached (the so-called *drop test*); free descent of the meniscus sometimes requires manual elevation of the abdominal wall. The presence of significant resistance in the syringe or failure of the meniscus to descend usually indicates extraperitoneal placement or apposition of the needle against the underlying omentum and usually mandates replacement. Insufflation tubing is then attached

to the needle. An initial pressure reading of less than 10 mm Hg further suggests appropriate placement, whereas higher pressures generally indicate extraperitoneal placement. Once satisfactory placement of the needle has been achieved, CO<sub>2</sub> is insufflated through the needle to a pressure of 12–15 mm Hg. The needle is then removed and a cannula and sharp trocar are inserted through an appropriately sized skin incision.

A variety of instrumentation has been developed to facilitate the closed approach. This includes expandable sheaths, which are introduced over the needle and can accommodate larger ports which dilate open the fascial opening (or *radially expanding trocars*), and devices that dilate the fascial opening under direct vision (or *optical access trocars*). Such instrumentation may also obviate formal fascial closure because the resulting fascial defect is small after removal of the port.

The open approach holds the theoretical advantage of minimizing the potential for injury to intra-abdominal visceral and vascular structures. Disadvantages include the generally longer-associated operative time and the occasional need for larger skin incisions, particularly in obese patients. In contrast, the closed approach is generally faster and may allow better cosmesis. Contraindications to the closed approach include the suspected or known presence of extensive intra-abdominal adhesions and pregnancy. However, in patients who have had limited prior surgery, the closed approach may be used to gain access at a site remote from the previous surgical site. The safety of open and closed approaches has been compared in several studies. A large retrospective review of closed laparoscopy in 489,335 patients and open laparoscopy in 12,444



suggested higher rates of visceral and vascular injury in closed laparoscopy. Rates of visceral and vascular injury were 0.083% and 0.075% after closed laparoscopy, and 0.048% and 0% open laparoscopy, respectively ( $p = 0.002$ ). Mortality rates after closed and open laparoscopy were not statistically different.<sup>14</sup> Notably, this small difference was not evident in several other meta-analyses.<sup>15,16</sup>

### PLACEMENT OF ADDITIONAL PORTS

The approach to the placement of secondary cannulas is highly surgeon and operation specific. Some basic principles, however, should always be adhered to. These include: (1) all cannulas should be inserted with the aid of laparoscopic visualization; (2) cannulas must be placed far apart from one another to avoid frequent crossing of instruments (generally 10 cm or more apart); and (3) the cannulas should be placed at a distance from the operative site, which maximizes range of motion at the cannula site and minimizes operator discomfort (approximately 15 cm). Additionally, skin incisions, while often small, should never compromise easy passage of trocars through the abdominal fascia. Undue resistance at the level of the skin can undermine the surgeon's control of the trocar as it passes through the peritoneum and lead to injury of underlying viscera or vascular structures.

### CLOSURE OF ABDOMINAL INCISIONS

As noted above, wound complications make a dominant contribution to surgical morbidity. Indeed, wound infection is the most common early complication and incisional hernia is the most common long-term complication of open abdominal surgery. Multiple factors contribute to the incidence of wound failure, including diabetes mellitus, malnutrition, obesity, and corticosteroid use. Surgical technique also appears to influence rates of wound failure; however, there has been little consensus regarding the optimal approach to closure. An evolving literature focuses on the relative merits of multiple-layered versus single-layer closure, closure with different suture materials, and interrupted versus continuous closures.

#### Closure of the Fascia

The abdomen can be closed in multiple layers or en mass. The former technique reconstructs the anterior and posterior aponeurotic sheaths separately with the posterior layer generally incorporating the peritoneum. Mass closure involves a single-layer closure of all layers and may or may not include the peritoneum. Numerous clinical trials have compared multiple-layered closure to mass abdominal closure. Some studies have shown an increased incidence of dehiscence and incisional hernia formation with multiple-layered closure,<sup>17,18</sup> while other studies show no difference in the incidences of these complications.<sup>19</sup> Given the shorter

**TABLE 6-1: RATE OF RESORPTION OF DIFFERENT SUTURE MATERIALS**

Suture Material	Time Until Total Resorption (days)
Rapidly resorbable	
Catgut	15
Chromic catgut	90
Polyglycolic acid (Dexon)	20
Polyglactin 910 (Vicryl)	60–90
Slowly resorbable	
Polydioxanone (PDS)	180
Polyglyconate (Maxon)	180
Nonresorbable	
Nylon (Nurulon)	–
Polypropylene (Prolene)	–
Polyethylene (Ethibond)	–
Polyamide (Ethilon)	–

Dexon (Davis and Geck, Wayne, NJ, USA), Vicryl (Ethicon, Somerville, NJ, USA), PDS (Ethicon), Maxon (Davis and Geck), Nurulon (Ethicon), Prolene (Ethicon), Ethibond (Ethicon), Ethilon (Ethicon). Modified from van't Riet, et al.<sup>32</sup>

time required to close the fascial layers en mass, this method is generally preferred.

The relative advantages of resorbable versus nonresorbable suture for use in closing the fascia have long been debated. Opponents of closure with nonresorbable suture invoke higher rates of suture sinus formation and increased postoperative pain; the incidences of these complications have been estimated at 8% and 17%, respectively. In contrast, it has been suggested that closure with resorbable suture may lead to increased incidences of dehiscence and hernia formation owing to an intrinsic loss of tensile strength during the postoperative period. While these complications are certainly seen with increased frequency when absorbable catgut suture is used,<sup>19</sup> the literature has not consistently borne out an association between wound failure and the use of resorbable sutures such as polyglycolic acid (Dexon), polyglactin acid (Vicryl), polydioxanone (PDS), and polyglyconate (Maxon).<sup>20–25</sup> In particular, several studies comparing permanent (Prolene, Ethicon, or Nylon) and slowly absorbable suture (PDS and Maxon) have failed to demonstrate any advantage to the use of nonresorbable suture. There may be some advantage to the use of slowly resorbable compared to rapidly resorbable suture; one study demonstrated a significant decrease in the rate of hernia formation when slowly resorbable suture (PDS and Maxon) were used compared to more rapidly resorbable sutures (catgut, Dexon, and Vicryl) ( $p = 0.009$ ).<sup>25,26</sup> Nonresorbable suture does appear to be associated with a higher incidence of suture sinus formation. This association may be greatest with multifilament permanent suture, which may abet bacterial ingrowth and infection.<sup>21,24</sup> Table 6-1 shows the rates of resorption for different suture materials.

It has been suggested that a continuous, running closure will result in a more durable wound than an interrupted closure. The former may allow the more even distribution of tension across the suture line with less resultant tissue strangulation and wound disruption. The obvious disadvantage of a continuous closure is its dependence on a single suture. The majority of studies comparing interrupted and continuous closure, however, demonstrate similar incidences of wound dehiscence, incisional hernia, wound infection, wound pain, and suture sinus formation.<sup>25,27-30</sup> One recent randomized trial compared interrupted and continuous closure with resorbable suture. No significant difference in the rates of incisional hernia, dehiscence, or wound infection was observed.<sup>31</sup>

In summary, an evidence-based approach to laparotomy closure narrowly favors the use of nonresorbable or slowly resorbable suture in order to minimize the risk of hernia formation. The latter is preferred because of the lower-associated risk of suture sinus formation and decreased postoperative pain. A running closure is associated with either an equivalent or lower risk of hernia formation and, given the ease and speed with which it can be performed, is to be preferred. Importantly, undue tension should not be placed on the running closure to avoid strangulation of the fascia.

## Technique of Mass Closure of the Abdomen

When closing a midline laparotomy incision, two size #0 looped or size #1 nonlooped slowly resorbable monofilament sutures are generally used. One suture is anchored at the upper extent and one at the lower extent of the wound. A malleable retractor can be used to protect the underlying viscera while the fascia is closed. The suture is run in a continuous manner, taking full-thickness bites of the linea alba fascia incorporating both the anterior and posterior rectus aponeuroses (Fig. 6-14). Sutures are passed through the fascia a minimum of 1 cm from the wound edge at 1 cm intervals. An assistant holds steady tensions on the suture while the closure progresses. Repetitive relaxation and application of tension of the suture is avoided to limit injury to the fascia. Likewise, it is unnecessary and probably counterproductive to overly tighten the suture as closure progresses, as this may lead to fascial necrosis. This point has been illustrated in a study associating evisceration and hernia formation with a lower suture length to wound length ratio.<sup>33</sup> The two sutures are run toward one another and then tied together in the center of the wound.

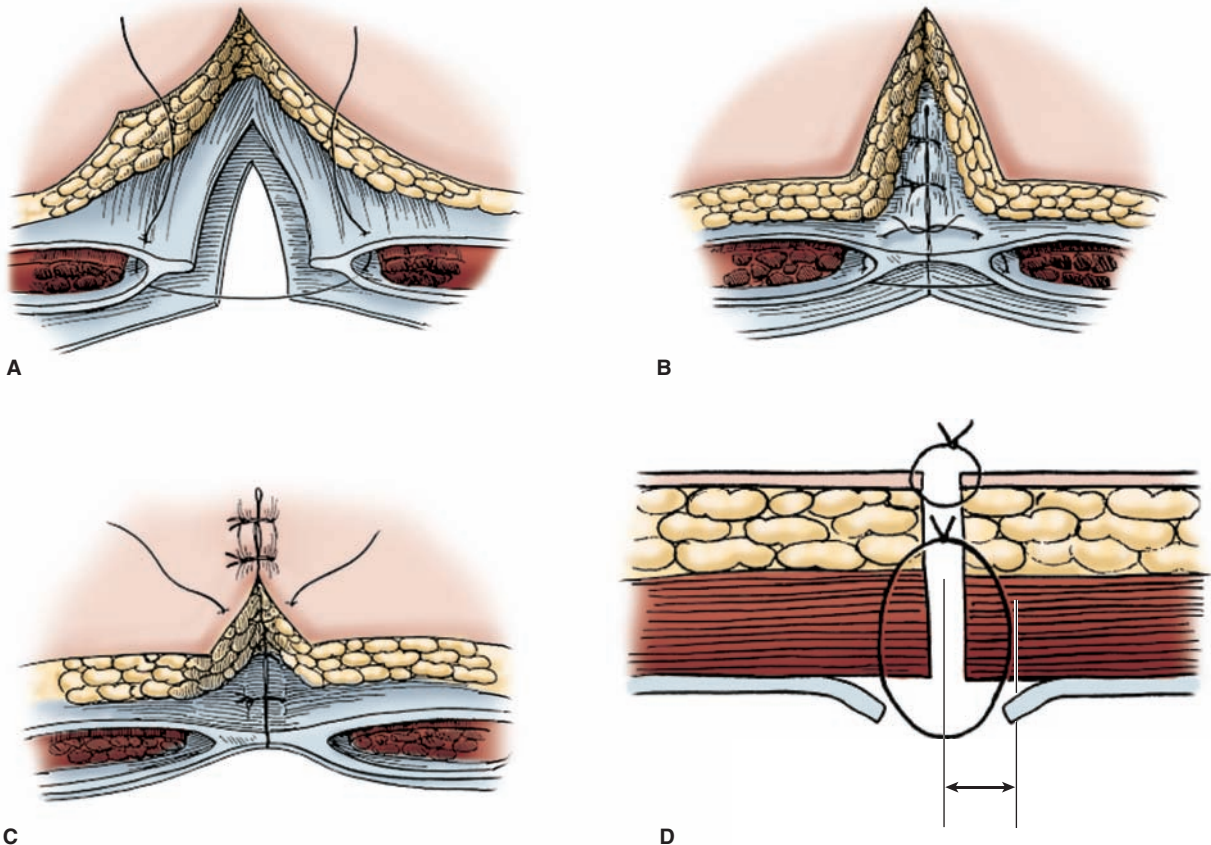


FIGURE 6-14 Mass closure of the midline abdominal incision.

## Skin Closure

A number of skin closure techniques can be used following clean (class I) or clean-contaminated (class II) operations; these include interrupted suture, subcuticular suture, stapled, and adhesive glue. Three randomized-controlled studies have compared stapled to subcuticular suture closures. Both techniques are associated with equivalent rates of wound infection.<sup>34–36</sup> Two of the studies suggested that subcuticular suture closure is associated with less postoperative pain than is stapled closure.<sup>34,36</sup> Two studies also demonstrated a superior cosmetic result early following suture closure; however, this difference was insignificant by 6 months after operation.<sup>35,36</sup>

Glues are used with increasing frequency for skin closure. Advantages of glues include ease and rapidity of application and simplification of wound care; generally, no additional dressing is required. Closure with glues has been compared to traditional skin closure methods in several clinical trials. Wound durability appears to be comparable,<sup>37,38</sup> although there are conflicting data on cosmesis, and postoperative pain.<sup>38,39</sup> If the surgical site is contaminated (class III or class IV wound), the skin should be left open to heal by secondary intention or by delayed primary skin closure.<sup>40</sup>

## Retention Sutures

The incidence of fascial dehiscence after major abdominal operations is 1–3% and is associated with a mortality rate of 15–20%.<sup>41</sup> Several patient-related factors are associated with an increased risk of fascial dehiscence, including advanced age, male gender, malnutrition, anemia, and steroids use; however, local mechanical factors and closure technique appear to have a greater influence on the rate of dehiscence.<sup>41</sup> Placement of drains or ostomies through the main incision compromises fascial integrity and should be avoided. Wound sepsis and increased intra-abdominal pressure, whether from ileus, bowel obstruction, atelectasis, or after hernia repair, also compromise the integrity of a fascial closure. Indications for prophylactic placement of retention sutures at initial operation remain controversial. The purpose of retention sutures in this setting is to relieve tension along the suture line in order to prevent significant wound disruption and evisceration in the patient at high risk.

There has been only one randomized trial comparing closure with and without retention suture placement. Hubbard and associates could not identify a benefit of retention suture closure over standard mass closure of the abdominal wall.<sup>42</sup> The potential disadvantages of retention sutures, however, are well known and include entrapment of underlying viscera, increased postoperative pain, poor cosmesis, and leakage of intraperitoneal fluid through the wound.<sup>43</sup> Some surgeons advocate primary closure with retention sutures in selected circumstances. In a retrospective study of midline abdominal wound dehiscence, Makela and colleagues identified preoperative variables that are significantly associated

with fascial disruption, including hypoalbuminemia, anemia, malnutrition, chronic pulmonary disease, and emergent operation. For patients with three or more of these preoperative risk factors, this group recommended internal retention suture closure.<sup>44</sup>

When employed, retention sutures are placed across the wound prior to formal fascial closure. Interrupted permanent monofilament sutures are passed through skin and fascia approximately 2 cm from the wound margin at intervals of several centimeters. Placement is facilitated by the use of a long cutting needle. It may be advantageous to omit the peritoneum from the retention closure in order to protect underlying viscera from injury or entrapment. After conventional closure of the fascia, the sutures are threaded through rubber tubing bolsters or commercially available plastic bolster devices and tied at the skin level.

## Mesh and Biologic Implant Placement

Placement of a mesh underlay represents an alternative approach to the prophylactic placement of retention sutures for the *at risk* abdominal closure.<sup>45,46</sup> Additionally, the occasional operation that requires resection of a significant portion of the abdominal wall, as well as transection of bowel, sometimes necessitates the placement of a prosthesis in a potentially contaminated field. Interposition placement of resorbable mesh accepts a hernia that will require complex abdominal wall reconstruction to repair. Moreover, high rates of fistula formation and mesh infection have been described with resorbable as well as nonresorbable mesh in this setting.<sup>46</sup> Biologic implants, such as human and porcine acellular dermal allograft, are an attractive alternative to meshes when faced with a difficult-to-close abdominal wall, particularly in the setting of contamination. As with resorbable meshes, underlay rather than interposition placement likely yields a much more durable result. While the use of these products in acute clinical settings has been described,<sup>47</sup> there is little definitive data to guide selective application of such techniques. More complex abdominal reconstructions utilizing component separation techniques, releasing incisions or rectus mobilization in conjunction with mesh or biologic implants, may be undertaken in appropriately selected patients when primary closure is not possible. More often, such approaches are utilized in a delayed fashion after development of an abdominal wall hernia.<sup>48</sup>

## Closure of Laparoscopic Incisions

The closure of laparoscopic incisions poses particular challenges. Reapproximation of the fascia is made more challenging in the presence of small skin incisions, which limit visualization. While small fascial defects may be left open, any fascial defect 10 mm or greater in the midline or below the arcuate line should generally be closed to reduce the risk of port-site hernia formation.<sup>49</sup> The use of radially expanding



trocars obviates the need for formal closure in many cases, although larger midline defects still generally require suture reapproximation.<sup>50–52</sup>

While sometimes challenging, particularly in obese patients, secure reapproximation of the fascia, usually with several interrupted sutures, can be achieved under direct visualization. Alternatively, a variety of instrumentation may be used to facilitate closure, usually in combination with laparoscopic visualization and maintenance of pneumoperitoneum. The Endoclose device (Tyco Healthcare, Mansfield, Massachusetts) has a sharp tip, which also functions as a grasper. The tip of a suture is grasped with the device and driven through the fascia adjacent to the cannula (and fascial defect) under laparoscopic visualization. The end of the suture is left free inside the abdomen. The grasper is then placed through the fascia a second time on the opposite side of the defect, and the free end of the suture is grasped inside the abdominal cavity and pulled out through the fascia. The suture is then tied to close the defect. The Carter-Thomason System (Inlet Medical, Eden Prairie, Minnesota) additionally includes a needle director, which is inserted through the fascia instead of the cannula, which ensures that adequate fascia is obtained by directing the needle at an appropriate angle, and may expedite closure.<sup>53</sup>

## Temporary Closure of the Abdomen

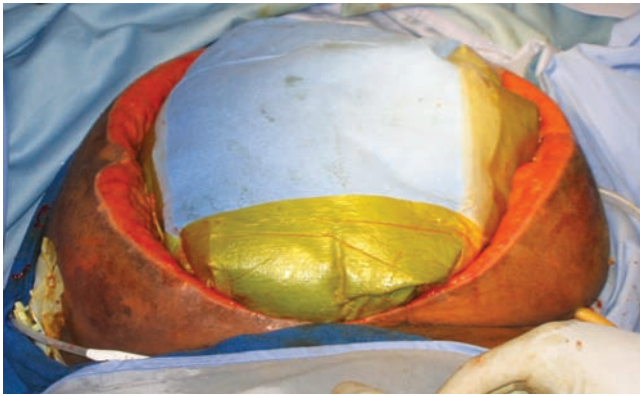Despite the frequent misconception that temporary abdominal closure techniques are a recent innovation, such approaches have long been utilized. Pringle reported his experience with temporary packing of hepatic injuries in 1908.<sup>54</sup> In 1913, Halsted recommended interposition of a nonadherent layer between the injured liver and packs.<sup>55</sup> Such an approach did fall out of favor in the period following the World War II owing to the very highly observed incidences of late hemorrhage and sepsis. However, beginning in 1973 with a report by Lucas and Ledgerwood, a number of investigators suggested the feasibility of utility and temporary abdominal closure, particularly in the setting of massive traumatic injury.<sup>56–58</sup> In 1993, Rotondo and Schwab introduced the term “damage control” and outlined a three-phase approach to the management of major abdominal injuries. The first phase consists of rapid control of hemorrhage and contamination followed by temporary abdominal closure; the second phase focuses on the restoration of normal body temperature, correction of coagulopathy, and optimization of ventilation; and the third phase involves removal of abdominal packs, definitive operation, and abdominal closure. In their initial series, Rotondo and Schwab demonstrated a marked survival advantage in patients with major vascular injury and two or more visceral injuries treated using the damage control approach (10 of 13, 77%) compared to those definitively closed at the time of initial operation (1 of 9, 11%) ( $p < 0.02$ ).<sup>59</sup> The applications of this approach have broadened with greater experience. Patients who may benefit from this damage control approach include those at risk of developing abdominal hypertension

(eg, hypothermia, coagulopathy, acidosis, large transfusion requirement) and those who require a *second-look laparotomy* (eg, intestinal ischemia).

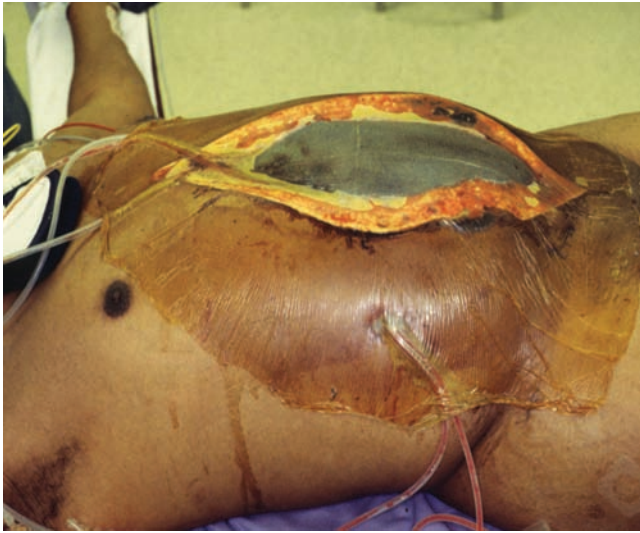
This approach has necessitated the evolution of temporary closure techniques. These range from the very simple and inexpensive (eg, towel clip closure, running nylon suture close) to more sophisticated vacuum-assisted closure (VAC) systems. No single approach is clearly superior and multiple techniques may have advantages in specific clinical settings. The Bogota bag utilizes a large IV bag, secured to the skin or fascia. Impermeable plastic drapes may be used alternatively in a similar fashion. This approach is fast, inexpensive, minimizes fluid losses, and is easily removed. It may be less durable than other closures; tearing of sutures through the periphery of the bag can result in evisceration. Absorbable meshes such as polyglactin 910 (Vicryl; Ethicon, Somerville, NJ) and polyglycolic acid (Dexon; Davis & Geck, Danbury, CT) can be sutured to the skin or fascia. This approach allows for a degree of flexibility as definitive closure can subsequently be undertaken without removal of the mesh. Alternatively, the mesh can serve as a bed for the elaboration of granulation tissue. If reapproximation of the fascia is not feasible or needs to be substantially delayed, a skin graft can be placed over the granulation bed. A variation on mesh closure utilizes the *Wittman patch*, a device made of two adherent sheets of biocompatible polymeric material. The edges of the patch are sewn to the surrounding abdominal fascia. As edema resolves, the fascial edges are gradually reapproximated by drawing the two sheets closer together and cutting away excess material.

An increasingly popular alternative to these temporary closures has been termed the “open abdomen technique.”<sup>60</sup> Generally, a nonadherent barrier (eg, a towel covered with an adhesive plastic drape) is placed on top of the intra-abdominal contents, below the fascia. Jackson-Pratt drains are placed above this barrier to control drainage and maintain the integrity of an adhesive dressing placed over the entire wound and skin (Fig. 6-15). This dressing is readily applied, inexpensive, and facilitates multiple re-explorations. Loss of abdominal domain can be limited with the additional placement of *lacing* across the wound; generally, vessel loops laced through skin staples are placed along the edges of the wound, which can be progressively tightened as intra-abdominal hypertension resolves. Maintenance of the open abdomen may be facilitated with the use of the commercially available abdominal VAC. The abdominal VAC comprises a barrier enveloped in nonadherent plastic, which is placed over the intra-abdominal contents below the fascial edges. A polyurethane sponge is cut to the size of the wound and placed over the barrier. The sponge is then covered with an adherent dressing. A small defect is created in the dressing and suction tubing with an adherent appliance is applied over this defect and attached to a vacuum device. Drainage is drawn out through the sponge through the vacuum tubing and into a vacuum canister. This system is particularly useful when multiple re-explorations are anticipated. Additionally, loss of abdominal domain is minimized by the negative pressure exerted on the dressing. While the use of the abdominal VAC may facilitate a more delayed definitive closure, the risk of





A



B

**FIGURE 6-15** Open abdominal dressing. *Top.* A towel wrapped in adhesive plastic is placed between the abdominal contents and the fascia. *Bottom.* Jackson Pratt drains and an impermeable dressing are applied over the barrier. (Images used with permission from Benjamin Braslow, MD.)

injury to underlying viscera and fistula formation does increase with additional dressing changes.<sup>61</sup> In the patient who cannot undergo definitive closure after approximately 1 week, transition to a Vicryl mesh closure may be advantageous.

## MANAGEMENT OF THE POSTOPERATIVE WOUND

### Dressing the Wound

At the conclusion of a procedure, a sterile dressing is typically applied to the wound before removal of the sterile drapes. Theoretically, this dressing prevents bacterial colonization of the wound during the initial 24–48 hours of healing, allowing for epithelialization and the formation of coagulum. Before application of the dressing, excess antiseptic solution should

be washed off with sterile saline. In general, the dressing should be secured without the use of excessive tape, which may be irritating to the skin. In most cases, the dressing can be removed within 48 hours of application. This practice is supported by studies from the 1960s documenting that exposure of clean, closed wounds to the atmosphere on postoperative day two, is not associated with an increased incidence of infection.<sup>62</sup> In many cases, after closure of a clean wound, no dressing is necessary. Indeed, in a randomized study of patients undergoing either inguinal hernia repair or high saphenous ligation, there was no significant difference in the rate of wound infection whether wounds were immediately exposed, covered with a dry gauze dressing, or covered with an occlusive film dressing.<sup>63</sup>

A variety of dressing types are used in the management of surgical wounds and may have advantages in some specific clinical settings. A simple dry dressing composed of gauze secured with sparing use of tape is generally sufficient. Wet-to-dry dressings are commonly used to dress open and contaminated wounds; mechanical debridement of the wound results from removal of dried packing material with adherent devitalized tissue. Enzymatic agents (eg, papain/urea [Accuzyme]) may be used in conjunction with wet-to-dry dressings to gently debride fibrinous exudate. In addition, application of broad-spectrum antibacterials (eg, silver sulfadiazine) may limit bacterial colonization and promote wound healing.

Recently, VAC dressings have gained great popularity for the management of open wounds. The VAC dressing has three components: (1) the VAC sponge, which is applied directly to the wound bed; (2) an occlusive dressing, which is applied over the sponge to seal it to the surrounding skin; and (3) a suction pump, which provides regulated negative pressure through the sponge. The VAC dressing has been used extensively in a variety of clinical settings and appears to promote granulation tissue formation and wound contraction. A major advantage of the VAC is the need for fewer dressing changes compared with conventional wet-to-dry dressings. As discussed above, the VAC has become a prominent part of the armamentarium for treating abdominal wounds that cannot be definitively closed at the time of initial operation.

### Surgical Site Infections

Surgical site infections (SSIs) are the most common nosocomial infections in surgical patients. It has been estimated that each SSI results in 7.3 additional inpatient days and adds over \$3000 to the hospital charges.<sup>40</sup> The bacterial colony count at the surgical site makes a dominant contribution to the risk of wound infection; colony counts per gram of tissue of  $10^5$  or greater are associated with a marked-increased risk. In the presence of a foreign body, however, a much lower count may lead to infection. Other risk factors for the development of wound infections include advanced age, obesity, diabetes mellitus, smoking, malnutrition, altered immune response, preoperative hospitalization, presence of infection at a remote body site, length of operation, and use of surgical drains.<sup>40</sup>


**TABLE 6-2: CRITERIA FOR DEFINING SURGICAL SITE INFECTIONS**

Incisional SSI		
Superficial Incisional	Deep Incisional	Organ/Space SSI
<p>Infection occurring within 30 days of surgery, <b>and</b> Infection involves only skin and subcutaneous tissue; <b>and</b> At least one of the following:</p> <ol style="list-style-type: none"> <li>1. Purulent discharge</li> <li>2. Organisms isolated from aseptically cultured fluid or tissue</li> <li>3. At least one sign of infection: pain or tenderness, localized swelling, redness, or heat</li> </ol> <p><b>and</b> the incision is deliberately opened by the surgeon unless the incision is culture negative</p> <ol style="list-style-type: none"> <li>4. Diagnosis of SSI by the surgeon or attending physician</li> </ol>	<p>Infection occurring within 30 days of surgery; or within 1 year of operation if implants are in place; <b>and</b> Infection involves deep soft tissue; <b>and</b> At least one of the following:</p> <ol style="list-style-type: none"> <li>1. Purulent discharge</li> <li>2. Deep incision spontaneously dehiscences or is deliberately opened by a surgeon when the patient has at least one of the following symptoms: fever (<math>&gt;38^{\circ}\text{C}</math>), localized pain or tenderness unless the site is culture negative</li> <li>3. Evidence of deep infection on direct examination, during reoperation, or on radiological examinations</li> <li>4. Diagnosis of SSI by the surgeon or attending physician</li> </ol>	<p>Infection occurs within 30 days of surgery, or within 1 year of operation if implants are in place; <b>and</b> Infection involves any part of anatomy that was manipulated during an operation, other than the incision; <b>and</b> At least one of the following</p> <ol style="list-style-type: none"> <li>1. Purulent drainage that is placed through a stab wound into the organ space</li> <li>2. Organism isolated from and aseptically cultured fluid or tissue</li> <li>3. Evidence of deep infection on the direct examination, during reoperation, or on radiological examinations</li> <li>4. Diagnosis of SSI by the surgeon or attending physician</li> </ol>

SSIs are subdivided into two categories: incisional and organ/space (Table 6-2). Incisional SSIs are limited to the surgical site. They are further divided into superficial SSIs, which involve the skin and subcutaneous tissue and deep SSIs, which involve the fascial and muscle layers. Organ/space SSIs can involve any part of the anatomy that was manipulated during the surgery excepting the incision.

Wounds can be classified by degree of contamination (Table 6-3). The risk of a postoperative SSI reflects, in part, the wound classification; however, infection rates vary widely within each classification group.<sup>64,65</sup> Other risk-scoring systems have, therefore, been developed to better anticipate the risk of wound infections. Examples of such scoring systems are the SENIC (Study of the Efficacy of Nosocomial Infection Control) and NNIS (National Nosocomial Infection Surveillance) risk indexes. The SENIC system predicts risk associated with abdominal surgery, operations lasting longer than 2 hours, contaminated or dirty wound classifications, and operation on patients with three or more discharge diagnoses.<sup>64</sup> The NNIS system predicts risk associated with American Society of Anesthesiologists preoperative assessment scores of greater than 2, wound classifications of contaminated or dirty, and increased duration of the operation.<sup>65</sup>

The organisms most commonly responsible for SSIs are *Staphylococcus aureus* and coagulase-negative staphylococci. After abdominal surgery, infection with enteric organisms (*Escherichia coli* and *Enterobacter* species) is also prevalent. The Centers for Disease Control and Prevention recommendations for the prevention of SSIs are summarized

in Table 6-4.<sup>40</sup> The use of preoperative prophylactic antibiotics in all clean-contaminated and clean cases with associated risk factors is recommended. The antibiotic of choice for most upper gastrointestinal procedures is cefazolin or a comparable first-generation cephalosporin. For colorectal surgery, metronidazole is added to this regimen. The administration of a mechanical and oral antibiotic bowel preparation has been recommended prior to colorectal surgery, although this practice has been challenged by recent meta-analyses suggesting no benefit.<sup>66,67</sup> Preoperative intravenous antibiotics should be administered 30–60 minutes before the incision is made to allow the agent to reach maximal tissue concentration. In obese patients, the antibiotic should be adjusted appropriately. For long procedures, the antibiotic should be readministered after every two half-lives to maintain an effective serum concentration.

The treatment for incisional SSIs includes removal of skin stitches or staples to allow drainage of any underlying collection. Antibiotics are indicated in the presence of cellulitis. The effective use of antibiotics depends on (1) appropriate coverage of the offending organisms and (2) maintenance of an adequate tissue concentration of the drug. Cefazolin or an equivalent first- or second-generation cephalosporin is appropriate for uncomplicated incisional SSI. Wound cultures are obtained in the presence of purulence and are used to guide antibiotic selection. Following abscess drainage, wounds are left open and allowed to close by secondary intention.

Deep space SSIs also require drainage. Increasingly, this is achieved by percutaneous placement of a drain under CT or ultrasound guidance. Deep space infections that are not


**TABLE 6-3: CLASSIFICATION OF SURGICAL WOUNDS**

Type of Wound	Definition	Risk of SSI
Class I: Clean	An uninfected operative wound in which no inflammation is encountered and respiratory, alimentary, genital, or uninfected urinary is not entered. They are primarily closed, and if necessary, drained with close drainage.	1–5%
Class II: Clean-contaminated	An operative wound in which the respiratory, alimentary, genital, or urinary tracts are entered under controlled conditions and without unusual contamination. In particular, surgeries involving the biliary tract, appendix, vagina, and oropharynx are included in this category provided no evidence of infection or a major break in technique is encountered.	2–9%
Class III: Contaminated	Open fresh accidental wounds. In addition, surgeries with major breaks in sterile technique (eg, open cardiac massage) or gross spillage from the gastrointestinal tract, and incisions in which acute, nonpurulent inflammation is encountered are included in this category.	3–13%
Class IV: Dirty-infected	Old traumatic wounds with retained devitalized tissue and those that involve existing clinical infection or perforated viscera.	3–13%

amenable to percutaneous drainage require operative drainage. Broad-spectrum antibiotics are indicated until culture data is obtained at which point the spectrum should be narrowed to target the offending organism.

### NECROTIZING WOUND INFECTIONS

Necrotizing soft tissue infections are a heterogeneous group of clinical entities<sup>68</sup>; however, several fundamental concepts govern the treatment of all. Paramount is early identification followed by operative debridement and initiation of antibiotic therapy. Patients often present early in the postoperative period (ie, within 48 hours) with incisional pain followed by the rapid onset of signs and symptoms of sepsis. While the incision may initially appear benign, more often serous drainage is noted. Patients may also present with bulla or blebs, crepitus, cutaneous anesthesia, and cellulitis that are refractory to antibiotic therapy.<sup>69</sup> Tenderness that extends beyond the borders of the apparent cellulitis suggests progression of the infection to the deeper cutaneous layers and should raise suspicion for an early necrotizing process. Importantly, fewer than 40% of patients exhibit the classic symptoms and signs described and a high degree of suspicion should be maintained in the postoperative patient with early signs of sepsis.<sup>70,71</sup>

In the absence of characteristic clinical features, diagnosis can be challenging. An elevated white blood cell (WBC) count ( $\leq 15,400/\text{mm}^3$ ) and hyponatremia (serum sodium level lower than 135 mmol/L) are sensitive markers for the presence of a necrotizing soft tissue infection; however, they are fairly nonspecific.<sup>72</sup> Imaging studies, including plain x-ray and CT,

may reveal the presence of soft tissue gas, though this finding is present in a minority of cases.<sup>69,73</sup> The reported sensitivity of MRI for diagnosis of necrotizing soft tissue infection ranges from 89% to 100%, and its specificity ranges from 46% to 86%.<sup>74,75</sup> However, the frequent presence of subcutaneous air in an early postoperative wound precludes reliable imaging in most cases and, more importantly, imaging may delay appropriate treatment.

In suspected cases, immediate surgical exploration and debridement is recommended and constitutes the most important single therapy. *Clostridium perfringens* or group A beta-hemolytic streptococci are the most frequently implicated organisms, but necrotizing infections are often polymicrobial. A sample of debrided tissue should be sent for gram stain and culture, and initial therapy should have a broad spectrum of coverage (eg, penicillin, clindamycin, and an aminoglycoside). Following initial debridement, the wound should be reexamined frequently. Any evidence of extension of the necrotizing process should prompt further debridement. Although the initial management of all necrotizing infections is essentially the same, there are several specific clinical entities that deserve special mention, as they may require unique therapies.

**Gas Gangrene.** Gas gangrene infection following abdominal surgery results from contamination with clostridia, typically from the alimentary tract or biliary system. Patients usually present with severe wound pain often associated with fever and tachycardia. Such wounds often appear edematous and erythematous; they later become dusky and necrotic.


**TABLE 6-4: CDC RECOMMENDATIONS TO PREVENT SURGICAL SITE INFECTIONS**
**Preoperative Factors**

Preparation of the patient:

1. Identify and treat all infections remote from the surgical site and postpone elective surgery until infection has resolved.
2. Do not remove hair unless it interferes with surgery.
3. If hair is to be removed, remove immediately preoperatively using clippers.
4. Ensure good blood glucose control in diabetic patients and avoid hyperglycemia.
5. Encourage cessation of tobacco use (at least for 30 days before surgery, if possible).
6. Do not withhold blood products, as transfusion does not affect rates of SSI.
7. Require the patient to shower or bathe with an antiseptic solution the night before surgery.
8. Remove gross contamination from the surgical site before performing antiseptic skin preparation.
9. Use an appropriate antiseptic solution for skin preparation.
10. Apply preoperative antiseptic solution for skin preparation in concentric circles moving outward toward the periphery.
11. Keep the preoperative hospital stay as short as possible.

Hand/forearm antisepsis for surgical team:

1. Keep nails short and do not wear artificial nails.
2. Perform a preoperative scrub for at least 2–5 minutes up to the elbows.
3. After performing the surgical scrub, keep the hands up and away from the body (elbows flexed) so that the water runs from the tips of fingers toward the elbows. Dry hands with a sterile towel and don a sterile gown and gloves.
4. Clean underneath each fingernail.
5. Do not wear hand or arm jewelry.

Management of infected or colonized surgical personnel:

1. Educate and encourage surgical personnel who have signs and symptoms of a transmissible infectious illness to report promptly to their supervisor and occupational health personnel.
2. Develop well-defined policies concerning patient care responsibilities when personnel have potentially transmissible infectious conditions. These policies should govern: (1) responsibility of personnel in using health services and reporting illness, (2) work restrictions, and (3) clearance to resume work after an illness that required work restriction. The policies should also identify staff members that have the authority to remove personnel from duty.
3. Obtain appropriate cultures and exclude from duty surgical personnel who have draining skin lesions until infection has been ruled out, or until these personnel have received adequate therapy and infection has been resolved.
4. Do not routinely exclude surgical personnel who are colonized with organisms such as *Staphylococcus aureus* or group A streptococci, unless they have been linked epidemiologically to dissemination of the organism.

**Antibiotic prophylaxis:**

1. Administer a prophylactic antimicrobial agent only when indicated, and select it based on its efficacy against the most

common pathogens causing SSIs for a specific operation, and in accordance with published recommendations.

2. Administer by the IV route the initial dose of prophylactic antimicrobial agent, timed such that bactericidal concentration of the drug is established in serum and tissue when the incision is made. Maintain therapeutic levels of the agent in serum and tissues throughout the operation, and for a few hours after the incision has been closed.
3. Before elective colorectal operations, in addition to the above measures, mechanically prepare the bowel by using enemas and cathartic agents. Give nonabsorbable oral antimicrobial agents in divided doses on the day before the operation.
4. For high-risk cesarean sections, administer the prophylactic antimicrobial agent immediately after the umbilical cord is clamped.
5. Do not routinely use vancomycin for prophylaxis.

**Intraoperative**

Ventilation:

1. Maintain positive pressure ventilation in the operating room with respect to the corridors and adjacent area.
2. Maintain a minimum of 15 air changes per hour, of which at least 3 should be fresh air.
3. Filter all air, recirculated and fresh, through the appropriate filters per the American Institute of Architects' recommendations.
4. Introduce all air at the ceiling, and exhaust air near the floor.
5. Do not use ultraviolet radiation in the operating room.
6. Keep operating suite doors closed except as need for passage of equipment, personnel, or patients.
7. Consider performing orthopedic implant operations in an operating suite supplied with ultraclean air.
8. Limit the number of personnel entering the operating room.

Cleaning and disinfection of environmental surfaces:

1. When visible soiling or contamination of surfaces or equipment with blood or other body fluids occurs during an operation, use an Environmental Protection Agency (EPA)-approved hospital disinfectant to clean the affected areas before the next operation.
2. Do not perform special cleaning (in addition to cleaning with routine EPA-approved hospital disinfectant) or closing of operating rooms after contaminated or dirty operations.
3. Do not use tacky mats at the entrance to the operating room suite or individual operating rooms for infection control.
4. Wet vacuum the operating floor with an EPA-approved disinfectant after the last operation of the day or night.

Microbiological sampling:

1. Do not perform routine environmental sampling of the operating room.

Sterilization of surgical instruments:

1. Sterilize all surgical instruments according to published guidelines.
2. Perform flash sterilization only for patient care items that will be used immediately. Do not flash sterilize for reasons of convenience or to save time.

Surgical attire and drapes:

1. Wear a surgical mask that fully covers the mouth and nose when entering the operating room if an operation is about to begin or is underway, or if sterilized instruments are exposed. Wear the mask throughout the operation.

(continued)




**TABLE 6-4: CDC RECOMMENDATIONS TO PREVENT SURGICAL SITE INFECTIONS (Continued)**

2. Wear a cap or hood to fully cover hair on the head and face.
3. Do not wear shoe covers for prevention of SSIs.
4. Wear sterile gloves if scrubbed as a surgical team member. Put on gloves after donning the sterile gown.
5. Use surgical gowns and drapes that are effective barriers when wet.
6. Change scrub suits that are visibly soiled, contaminated, and/or penetrated by blood or other potentially infectious material.

#### Asepsis and surgical technique:

1. Adhere to principles of asepsis when placing intravascular devices, spinal or epidural anesthesia catheters, or when dispensing or administering IV drugs.
2. Assemble sterile equipment and solutions immediately prior to use.
3. Handle tissue gently, maintain effective hemostasis, minimize devitalized tissue and foreign bodies, and eradicate dead space at the surgical site.
4. Use delayed primary skin closure or leave an incision open if the surgeon considers the surgical site to be heavily contaminated.
5. If drain is necessary, use closed suction drain, and place it through a separate incision distant from the operating incision. Remove the drain as soon as possible.

#### Postoperative Incision Care

1. Protect an incision that has been closed primarily with a sterile dressing for 24–48 hours postoperatively.
2. Wash hands before and after dressing changes and before and after any contact with surgical site.

3. When an incision dressing must be changed, use a sterile technique.
4. Educate the patient and family regarding proper incision care, symptoms of SSI, and the need to report such symptoms.

#### Surveillance

1. Use CDC definitions of SSI without modification for identifying SSIs among surgical inpatients and outpatients.
2. For inpatient cases, use direct prospective observation, indirect prospective detection, or a combination of both for the duration of the patient's hospitalization.
3. When postdischarge surveillance is performed for detecting SSIs following certain operations, use a method that accommodates available resources and data needs.
4. For outpatient cases, use a method that accommodates available resources and data needs.
5. Assign a surgical wound classification upon completion of an operation. A surgical team member should make the assignment.
6. For a patient undergoing an operation chosen for surveillance, record those variables shown to be associated with increased risk of SSI.
7. Periodically calculate operation-specific SSI rates stratified by variables shown to be associated with increased risk of SSI.
8. Report appropriately stratified operation-specific SSI rates to surgical team members. The optimum frequency and format of such rate computations will be determined by stratified case-load sizes and the objectives of local, continuous quality improvement initiatives.

Wound crepitus and foul smelling watery discharge, so-called “dishwater drainage,” are characteristics. Early surgical intervention with debridement of all infected and nonviable tissue is recommended in suspected cases. Although there have been no controlled clinical trials, there is some evidence that hyperbaric oxygen is of considerable value in treating clostridial infection, and reduces the mortality rate by some reports from 66% to 23%.<sup>76</sup> The potential benefits of hyperbaric oxygen include improved leukocyte function and increased tissue oxygen levels; it is bactericidal for *C. perfringens* and bacteriostatic for other anaerobic bacteria.<sup>77</sup>

**Necrotizing Fasciitis.** This syndrome has been divided into two subcategories depending on the implicated organisms. Type I necrotizing fasciitis is a polymicrobial process; Type II necrotizing fasciitis is caused by group A streptococci.<sup>68,78</sup> Polymicrobial necrotizing infections are generally slowly progressive and affect the total thickness of the skin, but do not involve the deep fascia. Purulence may or may not be present. Most often, such infections are heralded by a nonspecific cellulitis around the wound that slowly extends over days. Later, the central area of the cellulitis becomes purple and then develops typical features of gangrene. These infections are referred to as Fournier's gangrene when they affect the perineum. The causative organisms are usually a mixture of

anaerobes, gram-negative rods, and enterococcus species. Broad-spectrum antibiotics should be initiated early and then tailored pending the result of microbial cultures.

Necrotizing infections caused by group A streptococci are more rapidly progressive and can involve the subcutaneous fat, the superficial fascia, and the deep fascia. Early in the process, the overlying skin is often intact, but later may become compromised following interruption of the deep blood supply. The condition is clinically distinguished from gas gangrene by the absence of crepitus and muscle involvement. Early operative exploration is recommended in suspected cases. Group A streptococcus is highly sensitive to penicillin; however, the addition of clindamycin appears to have clinical benefit.<sup>78</sup> Treatment must include early surgical exploration with debridement of involved tissues.

## Seroma and Hematoma

Superficial seroma formation is exceedingly common but rarely has significant clinical consequence. Most seromas can be observed; the rare large seroma that causes troubling symptoms (eg, discomfort) or is cosmetically unacceptable to the patient can usually be managed with a single aspiration, or serial aspirations in the office. Refractory large seromas can

be treated with percutaneous placement of a drain, which is maintained until the output is low (usually less than 30 cc per day) or, rarely, excision (ie, capsulectomy).

The more liberal use of aspirin, plavix, and heparins in the perioperative period has likely resulted in an increased incidence of wound hematoma following abdominal surgery; now in the range of 4–8%.<sup>79,80</sup> Small wound hematomas are of little consequence and usually resolve without intervention. If larger, hematomas may lead to compromise of the overlying skin or predispose to infection. Such hematomas can be aspirated with a large-bore needle, or evacuated by opening the wound. If the overlying skin is under tension or ongoing extravasation of blood is noted, hematomas are often better managed in the operating room where active bleeding can be controlled, if encountered.

## Stitch Abscess

Stitch abscesses or suture sinuses are most often seen at approximately the 10th postoperative day, but may occur earlier or weeks after operation. Stitch abscesses may be superficial or deep. When superficial, they typically present as brown or mauve-colored circumscribed blisters in the line of the incision. The associated pain can be resolved by incising the overlying skin, evacuating the contents, and, if possible, excising residual suture material. Antibiotic treatment is rarely necessary. Deeper stitch abscesses typically present with an indurated mass. As noted above, the use of nonabsorbable suture, such as polypropylene, has been associated with an increased incidence of deep stitch abscesses when compared to closure with a slowly absorbing suture such as polydioxanone.<sup>32,81</sup> When permanent suture has been used, treatment requires removal of the residual suture material.

## Wound Dehiscence and Evisceration

Separation of abdominal wounds (ie, dehiscence) with or without protrusion of intraabdominal contents (ie, evisceration) causes considerable morbidity and mortality. Historically, wound dehiscence rates of up to 10% were reported; contemporary series estimate an incidence between 1% and 3%.<sup>82,83</sup> Mortality associated with dehiscence has been estimated at 16%.<sup>84</sup> The mean time to wound dehiscence is 8–10 days after operation.<sup>32,84</sup> Classically, dehiscence is heralded by a sudden rush of pink serosanguinous discharge from the wound. Sometimes, the acute evolution of a large subcutaneous hematoma or tympanic swelling that distends the wound reflecting herniation of bowel through the abdominal fascia is also noted.

As mentioned above, the literature on abdominal closure appears to favor a running mass closure with slowly resorbable or nonresorbable suture. Notwithstanding such technical considerations, a variety of patient-associated risk factors for

dehiscence must be recognized and include advanced age (>65 years), hypoalbuminemia, wound infection, ascites, obesity, steroid use, chronic obstructive pulmonary disease, pneumonia, cerebrovascular accident with residual deficit, anemia (ie, hematocrit <30), prolonged ileus, coughing, emergency operation, and operative time greater than 2.5 hours.<sup>44,83,85</sup> Although some surgeons advocate prophylactic placement of retention sutures in those at high risk for dehiscence, there is little data to support this practice.

Fundamentally, the treatment for a disrupted wound is reclosure of the wound; this is particularly true when dehiscence occurs early in the postoperative period. If evisceration is present, the wound and protruding viscera should be bathed with warm normal saline solution and covered with a large sterile dressing prior to prompt transport to the operating room. In the operating room, the prolapsed bowel is replaced below the level of the fascial edges. Residual suture material is extracted, and necrotic wound edges are debrided. Reclosure of the fascia is then performed, typically using a monofilament nonabsorbable suture such as polypropylene. Although some surgeons advocate interrupted closure of the fascia following dehiscence, two retrospective analyses have failed to demonstrate a reduction in the incidence of late ventral hernia formation with this technique compared to a running closure.<sup>32,84</sup> The advantage of retention suture placement in this setting is similarly unproven. Retrospective analyses fail to demonstrate any benefit, although a reduction in recurrent evisceration is frequently invoked. Retention sutures are associated with increased discomfort for the patient.<sup>45</sup> Placement of resorbable mesh as an underlay may serve to reinforce the abdominal closure.

On occasion, if the dehiscence is small, the patient is critically ill, or there is no evisceration, nonoperative management is appropriate. In such cases, the wound is packed with a moist sterile dressing. An abdominal binder can be used for further support. The dressing should be changed at regular intervals until the wound fills in with granulation tissue. In some cases, delayed reclosure of the skin can be carried out at this stage. Alternatively, the use of a VAC dressing has been described in this setting.<sup>86</sup>

## Incisional Hernia

Incisional hernia formation is the most common long-term complication of abdominal surgery and is discussed extensively in Chapter 7.

## Acknowledgements

We would like to thank Bryan M. Burt, Ali Tavakkolizadeh, and Stephen J. Ferzoco for their contribution to the previous edition of this text, which served as the foundation for this revised chapter. We would also like to thank Benjamin Braslow and Bilal Shafi for their valuable suggestions.

## REFERENCES

- Grantcharov TP, Rosenberg J. Vertical compared with transverse incisions in abdominal surgery. *Eur J Surg.* 2001;167:260–267.
- Greenall MJ, Evans M, Pollock AV. Midline or transverse laparotomy? A random controlled clinical trial. Part II: Influence on postoperative pulmonary complications. *Br J Surg.* 1980;67:191–194.
- Seiler CM, Deckert A, Diener MK, et al. Midline versus transverse incision in major abdominal surgery: a randomized, double-blind equivalence trial (POVATI: ISRCTN60734227). *Ann Surg.* 2009;249:913–920.
- Ellis H, Coleridge-Smith PD, Joyce AD. Abdominal incisions—vertical or transverse? *Postgrad Med J.* 1984;60:407–410.
- Guillou PJ, Hall TJ, Donaldson DR, Broughton AC, Brennan TG. Vertical abdominal incisions—a choice? *Br J Surg.* 1980;67:395–399.
- Paocharoen V, Mingmalairak C, Apisarnthanarak A. Comparison of surgical wound infection after preoperative skin preparation with 4% chlorhexidine [correction of chlohexidine] and povidone iodine: a prospective randomized trial. *J Med Assoc Thai.* 2009;92:898–902.
- Cox PJ, Ausobsky JR, Ellis H, Pollock AV. Towards no incisional hernias: lateral paramedian versus midline incisions. *J R Soc Med.* 1986;79:711–712.
- Olson M, O'Connor M, Schwartz ML. Surgical wound infections. A 5-year prospective study of 20,193 wounds at the Minneapolis VA Medical Center. *Ann Surg.* 1984;199:253–259.
- Ishizuka M, Nagata H, Takagi K, Kubota K. Comparison of 0.05% chlorhexidine and 10% povidone-iodine as cutaneous disinfectant for prevention of central venous catheter-related bloodstream infection: a comparative study. *Eur Surg Res.* 2009;43:286–290.
- Saltzman MD, Nuber GW, Gryzlo SM, Marecek GS, Koh JL. Efficacy of surgical preparation solutions in shoulder surgery. *J Bone Joint Surg Am.* 2009;91:1949–1953.
- McBurney C, IV. The incision made in the abdominal wall in cases of appendicitis, with a description of a new method of operating. *Ann Surg.* 1894;20:38–43.
- Lumsden AB, Colborn GL, Sreeram S, Skandalakis LJ. The surgical anatomy and technique of the thoracoabdominal incision. *Surg Clin North Am.* 1993;73:633–644.
- Cima RR, Pattana-arun J, Larson DW, Dozois EJ, Wolff BG, Pemberton JH. Experience with 969 minimal access colectomies: the role of hand-assisted laparoscopy in expanding minimally invasive surgery for complex colectomies. *J Am Coll Surg.* 2008;206:946–950; discussion 50–52.
- Bonjer HJ, Hazebroek EJ, Kazemier G, Giuffrida MC, Meijer WS, Lange JF. Open versus closed establishment of pneumoperitoneum in laparoscopic surgery. *Br J Surg.* 1997;84:599–602.
- Merlin TL, Hiller JE, Maddern GJ, Jamieson GG, Brown AR, Kolbe A. Systematic review of the safety and effectiveness of methods used to establish pneumoperitoneum in laparoscopic surgery. *Br J Surg.* 2003;90:668–679.
- Ahmad G, Duffy JM, Phillips K, Watson A. Laparoscopic entry techniques. *Cochrane Database Syst Rev.* 2008:CD006583.
- Goligher JC, Irvin TT, Johnston D, De Dombal FT, Hill GL, Horrocks JC. A controlled clinical trial of three methods of closure of laparotomy wounds. *Br J Surg.* 1975;62:823–829.
- Bucknall TE, Ellis H. Abdominal wound closure: a comparison of monofilament nylon and polyglycolic acid. *Surgery.* 1981;89:672–677.
- Leaper DJ, Pollock AV, Evans M. Abdominal wound closure: a trial of nylon, polyglycolic acid and steel sutures. *Br J Surg.* 1977;64:603–606.
- Carlson MA, Condon RE. Polyglyconate (Maxon) versus nylon suture in midline abdominal incision closure: a prospective randomized trial. *Am Surg.* 1995;61:980–983.
- Irvin TT, Koffman CG, Duthie HL. Layer closure of laparotomy wounds with absorbable and non-absorbable suture materials. *Br J Surg.* 1976;63:793–796.
- Corman ML, Veidenheimer MC, Collier JA. Controlled clinical trial of three suture materials for abdominal wall closure after bowel operations. *Am J Surg.* 1981;141:510–513.
- Cameron AE, Parker CJ, Field ES, Gray RC, Wyatt AP. A randomised comparison of polydioxanone (PDS) and polypropylene (Prolene) for abdominal wound closure. *Ann R Coll Surg Engl.* 1987;69:113–115.
- Bucknall TE. Abdominal wound closure: choice of suture. *J R Soc Med.* 1981;74:580–585.
- Wissing J, van Vroonhoven TJ, Schattenkerk ME, Veen HF, Ponsen RJ, Jeekel J. Fascia closure after midline laparotomy: results of a randomized trial. *Br J Surg.* 1987;74:738–741.
- Gilbert JM, Ellis H, Foweraker S. Peritoneal closure after lateral paramedian incision. *Br J Surg.* 1987;74:113–115.
- Trimbos JB, Smit IB, Holm JP, Hermans J. A randomized clinical trial comparing two methods of fascia closure following midline laparotomy. *Arch Surg.* 1992;127:1232–1234.
- Richards PC, Balch CM, Aldrete JS. Abdominal wound closure. A randomized prospective study of 571 patients comparing continuous vs. interrupted suture techniques. *Ann Surg.* 1983;197:238–243.
- Larsen PN, Nielsen K, Schultz A, Mejdahl S, Larsen T, Moesgaard F. Closure of the abdominal fascia after clean and clean-contaminated laparotomy. *Acta Chir Scand.* 1989;155:461–464.
- Fagniez PL, Hay JM, Lacaine F, Thomsen C. Abdominal midline incision closure. A multicentric randomized prospective trial of 3,135 patients, comparing continuous vs interrupted polyglycolic acid sutures. *Arch Surg.* 1985;120:1351–1353.
- Seiler CM, Bruckner T, Diener MK, et al. Interrupted or continuous slowly absorbable sutures for closure of primary elective midline abdominal incisions: a multicenter randomized trial (INSECT: ISRCTN24023541). *Ann Surg.* 2009;249:576–582.
- van't Riet M, Steyerberg EW, Nellensteyn J, Bonjer HJ, Jeekel J. Meta-analysis of techniques for closure of midline abdominal incisions. *Br J Surg.* 2002;89:1350–1356.
- Jenkins TP. The burst abdominal wound: a mechanical approach. *Br J Surg.* 1976;63:873–876.
- Ranaboldo CJ, Rowe-Jones DC. Closure of laparotomy wounds: skin staples versus sutures. *Br J Surg.* 1992;79:1172–1173.
- Frishman GN, Schwartz T, Hogan JW. Closure of Pfannenstiel skin incisions. Staples vs. subcuticular suture. *J Reprod Med.* 1997;42:627–730.
- Zwart HJ, de Ruiter P. Subcuticular, continuous and mechanical skin closure: cosmetic results of a prospective randomized trial. *Neth J Surg.* 1989;41:57–60.
- Singer AJ, Quinn JV, Clark RE, Hollander JE. Closure of lacerations and incisions with octylcyanoacrylate: a multicenter randomized controlled trial. *Surgery.* 2002;131:270–276.
- Blondeel PN, Murphy JW, Debrosse D, et al. Closure of long surgical incisions with a new formulation of 2-octylcyanoacrylate tissue adhesive versus commercially available methods. *Am J Surg.* 2004;188:307–313.
- Harold KL, Goldstein SL, Nelms CD, et al. Optimal closure method of five-millimeter trocar sites. *Am J Surg.* 2004;187:24–27.
- Mangram AJ, Horan TC, Pearson ML, Silver LC, Jarvis WR. Guideline for Prevention of Surgical Site Infection, 1999. Centers for Disease Control and Prevention (CDC) Hospital Infection Control Practices Advisory Committee. *Am J Infect Control.* 1999;27:97–132; quiz 3–4; discussion 96.
- Poole GV, Jr. Mechanical factors in abdominal wound closure: the prevention of fascial dehiscence. *Surgery.* 1985;97:631–640.
- Hubbard TB, Jr., Rever WB, Jr. Retention sutures in the closure of abdominal incisions. *Am J Surg.* 1972;124:378–380.
- Rink AD, Goldschmidt D, Dietrich J, Nagelschmidt M, Vestweber KH. Negative side-effects of retention sutures for abdominal wound closure. A prospective randomised study. *Eur J Surg.* 2000;166:932–937.
- Makela JT, Kiviniemi H, Juvonen T, Laitinen S. Factors influencing wound dehiscence after midline laparotomy. *Am J Surg.* 1995;170:387–390.
- McNeeley SG, Jr., Hendrix SL, Bennett SM, et al. Synthetic graft placement in the treatment of fascial dehiscence with necrosis and infection. *Am J Obstet Gynecol.* 1998;179:1430–1434; discussion 4–5.
- van't RM, Vrijland WW, Lange JF, Hop WC, Jeekel J, Bonjer HJ. Mesh repair of incisional hernia: comparison of laparoscopic and open repair. *Eur J Surg.* 2002;168:684–689.
- Shaiikh FM, Giri SK, Durrani S, Waldron D, Grace PA. Experience with porcine acellular dermal collagen implant in one-stage tension-free reconstruction of acute and chronic abdominal wall defects. *World J Surg.* 2007;31:1966–1972; discussion 73–75.
- Kolker AR, Brown DJ, Redstone JS, Scarpinato VM, Wallack MK. Multi-layer reconstruction of abdominal wall defects with acellular dermal allograft (AlloDerm) and component separation. *Ann Plast Surg.* 2005;55:36–41; discussion 42.
- Tonouchi H, Ohmori Y, Kobayashi M, Kusunoki M. Trocar site hernia. *Arch Surg.* 2004;139:1248–1256.
- Johnson WH, Fecher AM, McMahon RL, Grant JP, Pryor AD. VersaStep trocar hernia rate in unclosed fascial defects in bariatric patients. *Surg Endosc.* 2006;20:1584–1586.

51. Kouba EJ, Hubbard JS, Wallen E, Pruthi RS. Incisional hernia in a 12-mm nonbladed trocar site following laparoscopic nephrectomy. *ScientificWorld-Journal*. 2006;6:2399–2402.
52. Bhojru S, Payne J, Steffes B, Swanstrom L, Way LW. A randomized prospective study of radially expanding trocars in laparoscopic surgery. *J Gastrointest Surg*. 2000;4:392–397.
53. Elashry OM, Nakada SY, Wolf JS, Jr., Figenshau RS, McDougall EM, Clayman RV. Comparative clinical study of port-closure techniques following laparoscopic surgery. *J Am Coll Surg*. 1996;183:335–344.
54. Pringle JH, V. Notes on the arrest of hepatic hemorrhage due to trauma. *Ann Surg*. 1908;48:541–549.
55. Halstead WS. Ligature and suture material: the employment of fine silk in preference to catgut and the advantages of transfixing tissue and vessels in controlling hemorrhage—also an account of the introduction of gloves, gutta percha tissue and silver foil. *JAMA*. 1913;1119–1126.
56. Lucas CE, Ledgerwood AM. Prospective evaluation of hemostatic techniques for liver injuries. *J Trauma*. 1976;16:442–451.
57. Calne RY, McMaster P, Pentlow BD. The treatment of major liver trauma by primary packing with transfer of the patient for definitive treatment. *Br J Surg*. 1979;66:338–339.
58. Svoboda JA, Peter ET, Dang CV, Parks SN, Ellyson JH. Severe liver trauma in the face of coagulopathy. A case for temporary packing and early reexploration. *Am J Surg*. 1982;144:717–721.
59. Rotondo MF, Schwab CW, McGonigal MD, et al. 'Damage control': an approach for improved survival in exsanguinating penetrating abdominal injury. *J Trauma*. 1993;35:375–382; discussion 82–83.
60. Gracias VH, Braslow B, Johnson J, et al. Abdominal compartment syndrome in the open abdomen. *Arch Surg*. 2002;137:1298–1300.
61. Bee TK, Croce MA, Magnotti LJ, et al. Temporary abdominal closure techniques: a prospective randomized trial comparing polyglactin 910 mesh and vacuum-assisted closure. *J Trauma*. 2008;65:337–342; discussion 42–44.
62. Hermann RE, Flowers RS, Wasylenki EW. Early exposure in the management of the postoperative wound. *Surg Gynecol Obstet*. 1965;120:503–506.
63. Law NW, Ellis H. Exposure of the wound—a safe economy in the NHS. *Postgrad Med J*. 1987;63:27–28.
64. Haley RW, Morgan WM, Culver DH, et al. Update from the SENIC project. Hospital infection control: recent progress and opportunities under prospective payment. *Am J Infect Control*. 1985;13:97–108.
65. Culver DH, Horan TC, Gaynes RP, et al. Surgical wound infection rates by wound class, operative procedure, and patient risk index. National Nosocomial Infections Surveillance System. *Am J Med*. 1991;91:152S–157S.
66. Guenaga KK, Matos D, Wille-Jorgensen P. Mechanical bowel preparation for elective colorectal surgery. *Cochrane Database Syst Rev*. 2009;CD001544.
67. Bucher P, Mermillod B, Gervaz P, Morel P. Mechanical bowel preparation for elective colorectal surgery: a meta-analysis. *Arch Surg*. 2004;139:1359–1364; discussion 65.
68. Urschel JD. Necrotizing soft tissue infections. *Postgrad Med J*. 1999;75:645–649.
69. McHenry CRC, C.N. Soft tissue infection. In: Malangoni MHS, N.J., ed. *Problems in General Surgery*. Philadelphia, PA: Lippincott Williams & Wilkins; 2002:7.
70. Anaya DA, Dellinger EP. Necrotizing soft-tissue infection: diagnosis and management. *Clin Infect Dis*. 2007;44:705–710.
71. McHenry CR, Piotrowski JJ, Petrinic D, Malangoni MA. Determinants of mortality for necrotizing soft-tissue infections. *Ann Surg*. 1995;221:558–563; discussion 63–65.
72. Wall DB, Klein SR, Black S, de Virgilio C. A simple model to help distinguish necrotizing fasciitis from nonnecrotizing soft tissue infection. *J Am Coll Surg*. 2000;191:227–231.
73. Struk DW, Munk PL, Lee MJ, Ho SG, Worsley DF. Imaging of soft tissue infections. *Radiol Clin North Am*. 2001;39:277–303.
74. Brothers TE, Tagge DU, Stutley JE, Conway WF, Del Schutte H, Jr., Byrne TK. Magnetic resonance imaging differentiates between necrotizing and non-necrotizing fasciitis of the lower extremity. *J Am Coll Surg*. 1998;187:416–421.
75. Hopkins KL, Li KC, Bergman G. Gadolinium-DTPA-enhanced magnetic resonance imaging of musculoskeletal infectious processes. *Skeletal Radiol*. 1995;24:325–330.
76. Riseman JA, Zamboni WA, Curtis A, Graham DR, Konrad HR, Ross DS. Hyperbaric oxygen therapy for necrotizing fasciitis reduces mortality and the need for debridements. *Surgery*. 1990;108:847–850.
77. Clark LA, Moon RE. Hyperbaric oxygen in the treatment of life-threatening soft-tissue infections. *Respir Care Clin N Am*. 1999;5:203–219.
78. Bisno AL, Stevens DL. Streptococcal infections of skin and soft tissues. *N Engl J Med*. 1996;334:240–245.
79. Nurmohamed MT, Verhaeghe R, Haas S, et al. A comparative trial of a low molecular weight heparin (enoxaparin) versus standard heparin for the prophylaxis of postoperative deep vein thrombosis in general surgery. *Am J Surg*. 1995;169:567–571.
80. Kakkar VV, Boeckl O, Boneu B, et al. Efficacy and safety of a low-molecular-weight heparin and standard unfractionated heparin for prophylaxis of postoperative venous thromboembolism: European multicenter trial. *World J Surg*. 1997;21:2–8; discussion 9.
81. Hodgson NC, Malthaner RA, Ostbye T. The search for an ideal method of abdominal fascial closure: a meta-analysis. *Ann Surg*. 2000;231:436–442.
82. Bucknell TE, Cox PJ, Ellis H. Burst abdomen and incisional hernia: a prospective study of 1129 major laparotomies. *Br Med J*. 1982;89:1350.
83. Webster C, Neumayer L, Smout R, et al. Prognostic models of abdominal wound dehiscence after laparotomy. *J Surg Res*. 2003;109:130–137.
84. Gislason H, Viste A. Closure of burst abdomen after major gastrointestinal operations—comparison of different surgical techniques and later development of incisional hernia. *Eur J Surg*. 1999;165:958–961.
85. Pavlidis TE, Galatianos IN, Papaziogas BT, et al. Complete dehiscence of the abdominal wound and incriminating factors. *Eur J Surg*. 2001;167:351–354; discussion 5.
86. Schimp VL, Worley C, Brunello S, et al. Vacuum-assisted closure in the treatment of gynecologic oncology wound failures. *Gynecol Oncol*. 2004;92:586–591.



# HERNIAS

Patrick J. Javid • Jacob A. Greenberg  
• David C. Brooks

A hernia is defined as an area of weakness or complete disruption of the fibromuscular tissues of the body wall. Structures arising from the cavity contained by the body wall can pass through, or herniate, through such a defect. While the definition is straightforward, the terminology is often misrepresented. It should be clear that *hernia* refers to the actual anatomic weakness or defect, and *hernia contents* describe those structures that pass through the defect.

Hernias are among the oldest known afflictions of humankind, and surgical repair of the inguinal hernia is the most common general surgery procedure performed today.<sup>1</sup> Despite the high incidence, the technical aspects of hernia repair continue to evolve.

## INGUINAL HERNIA

### History

The word “hernia” is derived from a Latin term meaning “a rupture.” The earliest reports of abdominal wall hernias date back to 1500 BC. During this early era, abdominal wall hernias were treated with trusses or bandage dressings. The first evidence of operative repair of a groin hernia dates back to the first century AD. The original hernia repairs involved wide operative exposures through scrotal incisions requiring orchiectomy on the involved side. Centuries later, around 700 AD, principles of operative hernia repair evolved to emphasize mass ligation and en bloc excision of the hernia sac, cord, and testis distal to the external ring. The first report of groin hernia classification based on the anatomy of the defect (ie, inguinal versus femoral) dates back to the 14th century, and the anatomical descriptions of direct and indirect types of inguinal hernia were first reported in 1559.

Bassini revolutionized the surgical repair of the groin hernia with his novel anatomical dissection and low recurrence rates. He first performed his operation in 1884, and published his initial outcomes in 1889.<sup>2</sup> Bassini reported 100% follow-up of patients over a 5-year period, with just five recurrences in over 250 patients. This rate of recurrence was unheard of at the time and marked a distinct turning point

in the evolution of herniorraphy. Bassini’s repair emphasizes both the high ligation of the hernia sac in the internal ring, as well as suture reinforcement of the posterior inguinal canal. The operation utilizes a deep and superficial closure of the inguinal canal. In the deep portion of the repair, the canal is repaired by interrupted sutures affixing the transversalis fascia medially to the inguinal ligament laterally. This requires an incision through the transversalis fascia. The superficial closure is provided by the external oblique fascia.

In addition to Bassini’s contributions, the first true Cooper’s ligament repair, which affixes the pectineal ligament to Poupart’s ligament and thereby repairs both inguinal and femoral hernia defects, was introduced by Lotheissen in 1898. McVay further popularized the Cooper’s ligament repair with the addition of a relaxing incision to reduce the increased wound tension.

The advances in groin hernia repair in the century following Bassini have shared the primary goal of reducing long-term hernia recurrence rates. To this end, efforts have been directed at developing a repair that imparts the least tension on the tissues that are brought together to repair the hernia defect. Darn repairs were first introduced in the early 20th century to reduce wound tension by using either autologous tissue or synthetic suture to bridge the gap between fascial tissues. Muscle and fascial flaps were attempted without consistent success. In 1918, Handley introduced the first use of silk as a prosthetic darn and nylon followed several years later. However, it was found that heavy prosthetic material increased the risk of wound infection, and the silk suture ultimately lost its strength over time. The use of autologous or synthetic patches was also attempted in order to reduce wound tension and improve rates of recurrence. The first patches, beginning in the early 20th century, consisted of silver wire filigree sheets that were placed along the inguinal canal. Over time, the sheets suffered from metal fatigue leading to hernia recurrence. Reports of the wire patches eroding into adjacent inguinal structures and even the peritoneal cavity itself caused even more concern with this technique. The modern synthetic patch, made of a plastic monofilament polymer (polyethylene), was introduced by Usher in 1958. Lichtenstein, who developed a sutureless hernia repair using a plastic

mesh patch placed across the inguinal floor, further popularized this technique.

In the search for a technical means to reduce recurrence, emphasis was also placed on a meticulous dissection that would avoid placement of a prosthetic mesh. The most popular version was the Shouldice technique, initially introduced in 1958, and in essence a modification of the Bassini operation. This technique involves meticulous dissection of the entire inguinal floor and closure of the inguinal canal in four layers. The transversalis fascial layer itself is closed in two layers, as opposed to the single layer of interrupted suture advocated by Bassini. While the operation can be technically challenging to the beginner, it has been associated with excellent long-term outcomes and low recurrence rates.

Today, laparoscopic techniques have been validated as safe and effective in the treatment of groin hernias and have become commonplace. The laparoscopic approaches were initially developed in the early 1990s as laparoscopic techniques diffused throughout other specialties of general surgery.

## Epidemiology

Seventy-five percent of all abdominal wall hernias are found in the groin, making it the most common location for an abdominal wall hernia. Of all groin hernias, 95% are hernias of the inguinal canal with the remainder being femoral hernia defects. Inguinal hernias are nine times more common in men than in women. Although femoral hernias are found more often in women, the inguinal hernia is still the most common hernia in women.<sup>3</sup> The overall lifetime risk of developing a groin hernia is approximately 15% in males and less than 5% in females. There is clearly an association between age and hernia diagnosis. After an initial peak in the infant, groin hernias become more prevalent with advancing age. In the same way, the complications of hernias (incarceration, strangulation, and bowel obstruction) are found more commonly at the extremes of age.

Currently in this country, approximately 700,000 operations for inguinal hernia repair are performed annually.<sup>4</sup>

## Anatomic Classification

A thorough classification system has been developed to assist in the proper diagnosis and management of the inguinal hernia. All hernias can be broadly classified as congenital or acquired, and it is thought that the vast majority of inguinal hernias are congenital in nature. Acquired groin hernias develop after surgical incision and manipulation of the involved abdominal wall tissues. Given the paucity of primary groin incisions utilized in modern general surgery, acquired hernias of the inguinal or femoral region are rare.

Inguinal hernias are further divided by anatomical location into direct and indirect types. This differentiation is based on the location of the actual hernia defect in relation to the inferior epigastric vessels. The inferior epigastric vessels are

continuous with the superior epigastric vessels that originate from the internal mammary artery cephalad and ultimately course caudally into the common femoral artery and vein. These vascular structures make up the lateral axis of Hesselbach's triangle, which includes the lateral border of the rectus sheath as its medial border and the inguinal (Poupart's) ligament itself as the inferior border. Hernias that develop lateral to the inferior epigastric vessels are termed *indirect* inguinal hernias, and those that develop medial to the vessels are *direct* inguinal hernias. In this way, direct hernia defects are found *within* Hesselbach's triangle. Hernias of the femoral type are located caudal or inferior to the inguinal ligament in a medial position.

The indirect inguinal hernia develops at the site of the internal ring, or the location where the spermatic cord in men and the round ligament in women enters the abdomen. While they may present at any age, indirect inguinal hernias are thought to be congenital in etiology. The accepted hypothesis is that these hernias arise from the incomplete or defective obliteration of the processus vaginalis during the fetal period. The processus is the peritoneal layer that covers the testicle or ovary as it passes through the inguinal canal and into the scrotum in men or the broad ligament in women. The internal ring closes, and the processus vaginalis becomes obliterated following the migration of the testicle into the inguinal canal. The failure of this closure provides an environment for the indirect inguinal hernia to develop. In this way, the remnant layer of peritoneum forms a sac at the internal ring through which intra-abdominal contents may herniate, thereby resulting in a clinically detectable inguinal hernia. Anatomically, the internal ring is lateral to the external ring and the remainder of the inguinal canal, and this explains the lateral relationship of the indirect inguinal hernia to the inferior epigastric vessels. It is noteworthy that indirect inguinal hernia develops more frequently on the right, where descent of the gonads occurs later during fetal development.

Direct inguinal hernias, in contrast, are found medial to the inferior epigastric artery and vein, and within Hesselbach's triangle. These hernias are acquired and only rarely found in the youngest age groups. They are thought to develop from an acquired weakness in the fibromuscular structures of the inguinal floor, so that the abdominal wall in this region can no longer adequately contain the intra-abdominal contents. The exact relationship between direct inguinal hernias and heavy lifting or straining remains unclear, and some studies suggest that the incidence of direct hernia is no greater in people in professions that routinely involve heavy manual labor.<sup>5</sup>

While femoral hernias account for less than 10% of all groin hernias, their presentation can be more acute in nature. In fact, it is estimated that up to 40% of femoral hernias present as emergencies with hernia incarceration or strangulation.<sup>3</sup> In this way, femoral hernias may also present with bowel obstruction. The empty space through which a femoral hernia forms is medial to the femoral vessels and nerve in the femoral canal and adjacent to the major femoral lymphatics. The inguinal ligament forms

the cephalad border of the empty space. However, while the empty space is inferior to the ligament, the herniated contents may present superior to the ligament, thereby making an accurate diagnosis difficult.

Femoral hernias are much more common in females than in males, although inguinal hernias are still the most common hernia in women. The predilection for femoral hernias in women may be secondary to less bulky groin musculature or weakness in the pelvic floor tissues from previous childbirth. It has been shown that previous inguinal hernia repair may be a risk factor for the subsequent development of a femoral hernia.<sup>3</sup>

## Anatomy of the Groin

The boundaries of the inguinal canal must be understood to comprehend the principles of hernia repair. In the inguinal canal, the anterior boundary is the external oblique aponeurosis; the posterior boundary is composed of the transversalis fascia with some contribution from the aponeurosis of the transversus abdominis muscle; the inferior border is imparted by the inguinal and lacunar ligaments; and the superior boundary is formed by the arching fibers of the internal oblique musculature.

The internal (or deep) inguinal ring is formed by a normal defect in the transversalis fascia through which the spermatic cord in men and the round ligament in women pass into the abdomen from the extraperitoneal plane. The external (or superficial) ring is inferior and medial to the internal ring and represents an opening of the aponeurosis of the external oblique. The spermatic cord passes from the peritoneum through the internal ring and then caudally into the external ring before entering the scrotum in males.

From superficial to deep, the surgeon first encounters Scarpa's fascia after incising the skin and subcutaneous tissue. Deep to Scarpa's layer is the external oblique aponeurosis, which must be incised and spread to identify the cord structures. The inguinal ligament represents the inferior extension of the external oblique aponeurosis, and extends from the anterior superior iliac spine to the pubic tubercle. The medial extension of the external oblique aponeurosis forms the anterior rectus sheath. The iliohypogastric and ilioinguinal nerves, which provide sensation to the skin, penis, and the upper medial thigh, lie deep to the external oblique aponeurosis in the groin region. The internal oblique aponeurosis is more prominent cephalad in the inguinal canal, and its fibers form the superior border of the canal itself. The cremaster muscle, which envelops the cord structures, originates from the internal oblique musculature. The transversus abdominis muscle and its fascia represent the true floor of the inguinal canal. Deep to the floor is the preperitoneal space, which houses the inferior epigastric artery and vein, the genitofemoral and lateral femoral cutaneous nerves, and the vas deferens, which traverses this space to join the remaining cord structures at the internal inguinal ring.

## Etiology

The indirect inguinal hernia, the most common form of groin hernia across all ages and both genders, is thought to be congenital in etiology. The processus vaginalis is the pocket of peritoneum that forms around the testicle as it descends through the internal ring and along the inguinal canal into the scrotum during the 28th week of gestation. The primary etiology behind the indirect inguinal hernia is believed to be a patent processus vaginalis, which in essence represents a hernia sac. In this way, the hernia defect is the internal ring itself, and the sac is preformed but never closes at the end of gestation. Once intra-abdominal contents find their way into the sac, an indirect inguinal hernia is formed.

It is likely, however, that every person with a patent processus vaginalis does not develop an inguinal hernia during his or her lifetime. Thus, other predisposing factors must aid in indirect inguinal hernia formation. It is commonly thought that repeated increases in intra-abdominal pressure contribute to hernia formation; hence, inguinal hernias are commonly associated with pregnancy, chronic obstructive pulmonary disease, abdominal ascites, patients who undergo peritoneal dialysis, laborers who repeatedly flex the abdominal wall musculature, and individuals who strain from constipation. It is also thought that collagen formation and structure deteriorates with age, and thus hernia formation is more common in the older individual.

Several inborn errors of metabolism can lead to hernia formation. Specifically, conditions such as Ehlers–Danlos syndrome, Marfan's syndrome, Hunter's syndrome, and Hurler's syndrome can predispose to defects in collagen formation. There is evidence that cigarette smoking is associated with connective tissue disruption, and hernia formation is more common in the chronic smoker.

## Clinical Manifestations

The groin hernia can present in a variety of ways, from the asymptomatic hernia to frank peritonitis in a strangulated hernia. Many hernias are found on routine physical examination or on a focused examination for an unrelated complaint. These groin hernias are usually fully reducible and chronic in nature. Such hernias are still referred for repair since they invariably develop symptoms, and asymptomatic hernias still have an inherent risk of incarceration and strangulation.

The most common presenting symptomatology for a groin hernia is a dull feeling of discomfort or heaviness in the groin region that is exacerbated by straining the abdominal musculature, lifting heavy objects, or defecating. These maneuvers worsen the feeling of discomfort by increasing the intra-abdominal pressure and forcing the hernia contents through the hernia defect. Pain develops as a tight ring of fascia outlining the hernia defect compresses intra-abdominal structures with a visceral neuronal supply. With a reducible hernia, the feeling of discomfort resolves as the pressure is released when the patient stops straining the abdominal muscles. The pain is often worse

at the end of the day, and patients in physically active professions may experience the pain more often than those who lead a sedentary lifestyle.

Overwhelming or focal pain from a groin hernia is unusual and should raise the suspicion of hernia incarceration or strangulation. An incarcerated hernia occurs when the hernia contents are trapped in the hernia defect so that the contents cannot be reduced back into the abdominal cavity. The tight circumferential pressure applied by the hernia defect serves to impede the venous outflow from the hernia contents, resulting in congestion, edema, and tissue ischemia. Ultimately, the arterial inflow to the hernia contents is compromised as well, resulting in tissue loss and necrosis, termed strangulation of the hernia.

All types of groin hernias are at risk for incarceration and strangulation, although the femoral hernia seems to be predisposed to this complication. Incarceration and strangulation of a groin hernia may present as a bowel obstruction when the tight hernia defect constricts the lumen of the viscus. Hence, all patients presenting with bowel obstruction require a thorough physical examination of the groin region for inguinal and femoral hernias. If there is no bowel in the hernia sac, an incarcerated groin hernia may alternatively present as a hard, painful mass that is tender to palpation.

The physical examination differs between an incarcerated hernia and a strangulated hernia. The incarcerated hernia may be mildly tender due to venous congestion from the tight defect. The strangulated hernia will be tender and warm and may have surrounding skin erythema secondary to the inflammatory reaction from the ischemic bowel. The patient with the strangulated hernia may have a fever, hypotension from early bacteremia, and a leukocytosis. The incarcerated hernia requires operation on an urgent basis within 6–12 hours of presentation. If the operation is delayed for any reason, serial physical examinations are mandated to follow any change in the hernia site indicating the onset of tissue loss. The strangulated hernia clearly requires emergent operation immediately following diagnosis.

It may also be difficult to differentiate fat from bowel contents in the hernia sac. It is important to recognize that incarcerated omental fat alone can produce significant pain and tenderness on physical examination.

## Pregnancy and Groin Hernia

Not surprisingly, groin hernias during pregnancy may become symptomatic. This is related to the increased intra-abdominal pressure from the growing fetus and enlarging uterus. The symptomatic groin discomfort may become positional later in pregnancy as the uterus shifts location with movement. While the risk of complications of groin hernias still exists during pregnancy, the enlarging uterus may in theory protect against incarceration by physically blocking the intra-abdominal contents from the inlet of the defect.

In general, elective repair of groin hernias during pregnancy is not recommended, even if they become increasingly

symptomatic. Emergent repair of the incarcerated or strangulated hernia is undertaken as needed.

## Physical Examination

As with any hernia, the groin hernia should be properly examined with the patient in the standing position. This allows the hernia contents to fill the hernia sac and make the hernia obvious on physical examination. Some hernias, however, may be easily identifiable in the supine position. It should be noted that the exact anatomical classification of the inguinal hernia (ie, indirect vs direct) is impossible to accurately predict based on physical examination alone.

In the male patient, using the second or third finger, the examiner should invaginate the scrotum near the external ring and direct the finger medial toward the pubic tubercle. The examiner's finger will thus lie on the spermatic cord with the tip of the finger within the external ring. The patient is then asked to cough or perform a Valsalva maneuver. A true inguinal hernia will be felt as a silklike sensation against the gloved finger of the examiner. This is the infamous “silk glove” sign.

The female patient does not have the long and stretched spermatic cord to follow with the examiner's finger during the physical examination. Instead, two fingers can be placed along the inguinal canal, and the patient is asked to cough or strain. If present, the examiner should feel the sensation of the hernia sac against the gloved finger. Particular attention in the female patient should be paid to the location of the sensation; femoral hernia sacs will present medial and just inferior to the lower border of the inguinal ligament.

While the physical examination does not differ in the infant, it can be more challenging to elicit the hernia impulse given the compressed groin anatomy of the young child. It is well known that a groin hernia can be more readily diagnosed in the infant who is actively crying and hence increasing the intra-abdominal pressure through flexion of the abdominal wall musculature.

The examination for the femoral hernia in both genders involves palpation of the femoral canal just below the inguinal ligament in the upper thigh. In this way, the most easily palpable landmark is the femoral artery, which is located lateral in the canal. Medial to the femoral artery is the femoral vein, and the femoral empty space is just medial to the vein. This area can be located easily, palpated with two fingers, and then examined closely while the patient coughs or strains. In general, a focused groin hernia examination should involve the investigation for both inguinal and femoral hernias in both genders.

## Treatment

The treatment of all hernias, regardless of their location or type, is surgical repair. Elective repair is performed to alleviate symptoms and to prevent the significant complications



of hernias, such as incarceration or strangulation. While the limited data available on the natural history of groin hernias show that these complications are rare, the complications are associated with a high rate of morbidity and mortality when they occur. At the same time, the risks of elective groin hernia repair, even in the patient with a complicated medical history, are exceedingly low. Outcomes of surgical repair are generally excellent with minimal morbidity and relatively rapid return to baseline health.

The major risk with delayed surgical repair is the risk of incarceration and/or strangulation. It is not possible to reliably identify those hernias that are at an increased risk for these complications. It is known that the risk of incarceration of a hernia is greatest soon after the hernia manifests itself. This is likely due to the fact that at the early stage of the hernia, the defect is small and fits tightly around the hernia sac; therefore, any contents that fill the sac may quickly become trapped within the hernia. Over time, the hernia defect stretches due to the tissue that enters and leaves the sac with changes in intra-abdominal pressure. After 6 months, the risk of hernia incarceration decreases from 5% per year to 1–2% per year. In general, the larger the palpable defect on physical examination, the lower the risk of incarceration. Clearly, all risks of tissue loss aside, elective hernia repair is still preferred to emergent repair.

## Anesthesia

Groin hernia repair can be performed using a variety of anesthesia options, including general, regional (such as spinal or epidural), and local anesthesia.<sup>6</sup> Laparoscopic repairs usually require general anesthesia in order to provide the complete muscle relaxation needed to achieve insufflation of the preperitoneal or peritoneal space.

Open groin hernia repairs are most often performed using either regional or local anesthesia. Local anesthesia with controlled intravenous sedation, referred to as monitored anesthesia care, is often preferred in the repair of the reducible inguinal hernia. Its advantages include the ease of induction and awakening, the short postanesthesia recovery period, and the fact that its intensity can easily be titrated up or down based on patient comfort levels intraoperatively. The only major disadvantage to this approach is in patients who experience considerable pain during repairs of large groin hernias.

In groin hernia repair, local anesthesia can be administered as a direct infiltration of the tissues to be incised or as a local nerve block of the ilioinguinal and iliohypogastric nerves. The latter is associated with improved local pain control, but may be difficult to achieve. The local nerve block also spares the soft tissue of edema from diffuse infiltration of local anesthesia.

Spinal or continuous epidural anesthesia allows the surgeon greater freedom to maneuver within the operative field since the anesthetized region is larger than in local anesthesia. However, these modes of anesthesia carry their own

infrequent risks such as urinary retention, prolonged anesthetic effect, hypotension, and spinal headache. They may also be associated with longer in-hospital recovery times on the day of surgery.

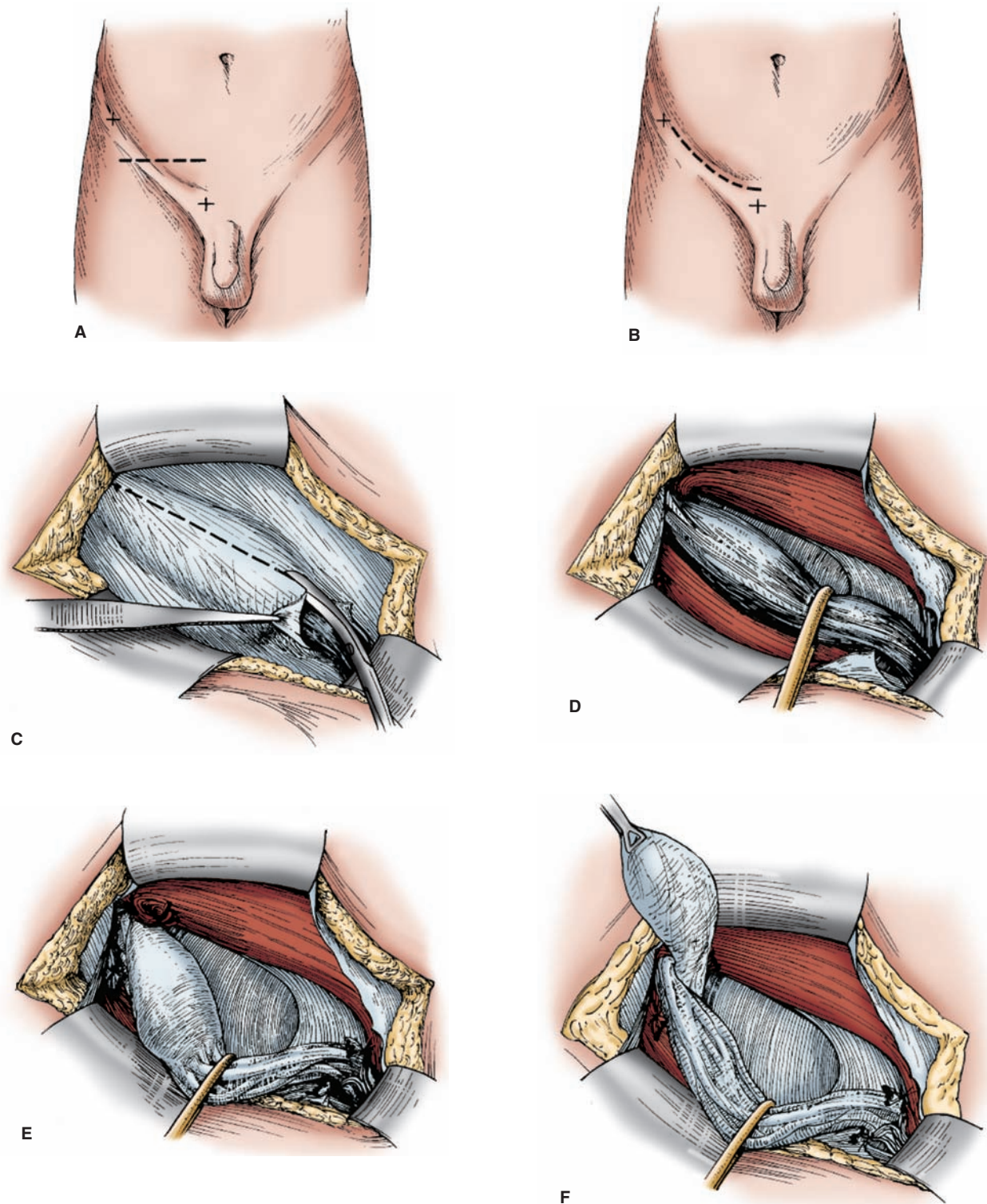
A randomized trial of local, regional, and general anesthesia in 616 adult patients undergoing open inguinal hernia repair in 10 hospitals found that local anesthesia was superior in the early postoperative period.<sup>7</sup> Compared to those who received regional or general anesthesia, patients who received local anesthesia had less postoperative pain and nausea, shorter time spent in the hospital, and fewer unplanned overnight admissions (3% vs 14% and 22%, respectively).

## Operative Techniques

Successful surgical repair of a hernia depends on a tension-free closure of the hernia defect to attain the lowest possible recurrence rate. Previous efforts to simply identify the defect and suture it closed resulted in unacceptably high recurrence rates of up to 15%. Modern techniques have improved upon this recurrence rate by placement of mesh over the hernia defect, or in the case of laparoscopic repair, behind the hernia defect. One exception to this rule is the classic Shouldice repair, which uses meticulous dissection and closure without mesh placement to obtain a consistently low recurrence rate. Another benefit of the tension-free closure is that it has been shown to cause the patient significantly less pain and discomfort in the short-term postoperative period.

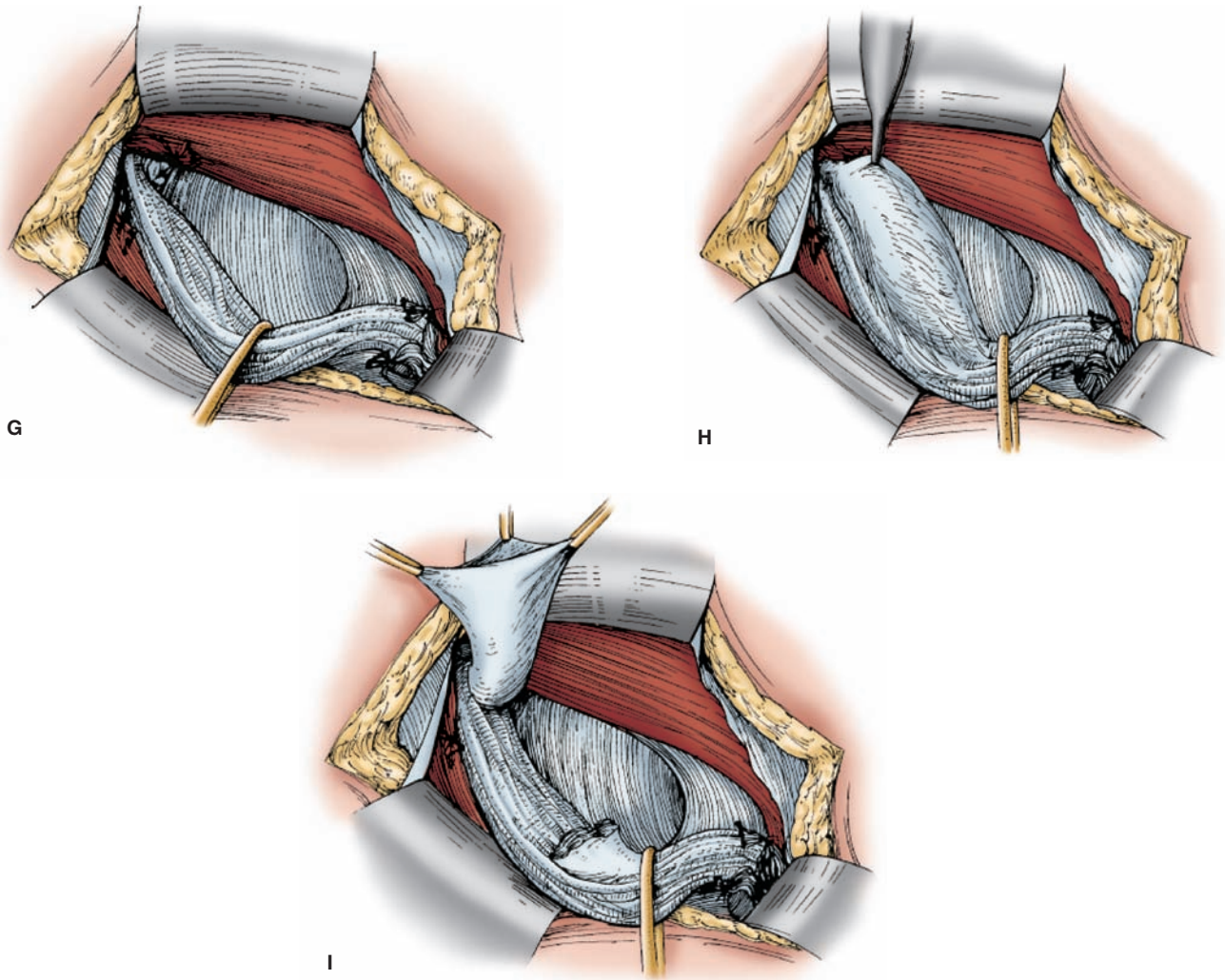
Figure 7-1 illustrates the essential steps to the modern open inguinal hernia repair. All of the open anterior hernioplasty techniques begin with a transversely oriented, slightly curvilinear skin incision of approximately 6–8 cm positioned one to two fingerbreadths above the inguinal ligament. Dissection is carried down through the subcutaneous and Scarpa's layers. The external oblique aponeurosis is identified and cleaned so that the external ring is identified inferomedially. Being careful to avoid injury to the iliohypogastric and ilioinguinal nerves, the aponeurosis is incised sharply and opened along its length through the external ring with fine scissors. The nerves underlying the external oblique fascia are then identified and isolated for protection. The soft tissue is cleared off the posterior surface of the external oblique aponeurosis on both sides and the spermatic cord is mobilized. Using a combination of blunt and sharp dissection, the cremaster muscle fibers enveloping the cord are separated from the cord structures and the cord itself is isolated. At this point, it is possible to accurately define the anatomy of the hernia. An indirect hernia will present with a sac attached to the cord in an anteromedial position extending superiorly through the internal ring. A direct inguinal hernia will present as a weakness in the floor of the canal posterior to the cord. A pantaloon defect will present as both a direct and an indirect defect in the same inguinal canal.

The specifics of the common modern techniques for hernia repair will be discussed further.



**FIGURE 7-1** Adult hernia incision and dissection. **A.** Transverse incision. **B.** Curved skin crease incision. **C.** The aponeurosis of the external oblique is incised along the direction of its fibers. **D.** The inguinal canal is exposed and the spermatic cord mobilized. **E.** The spermatic cord has been skeletonized, and the internal ring and posterior wall of the canal (the transversalis fascia) have been defined. **F.** A medium-sized sac has been dissected free of the cord elements.





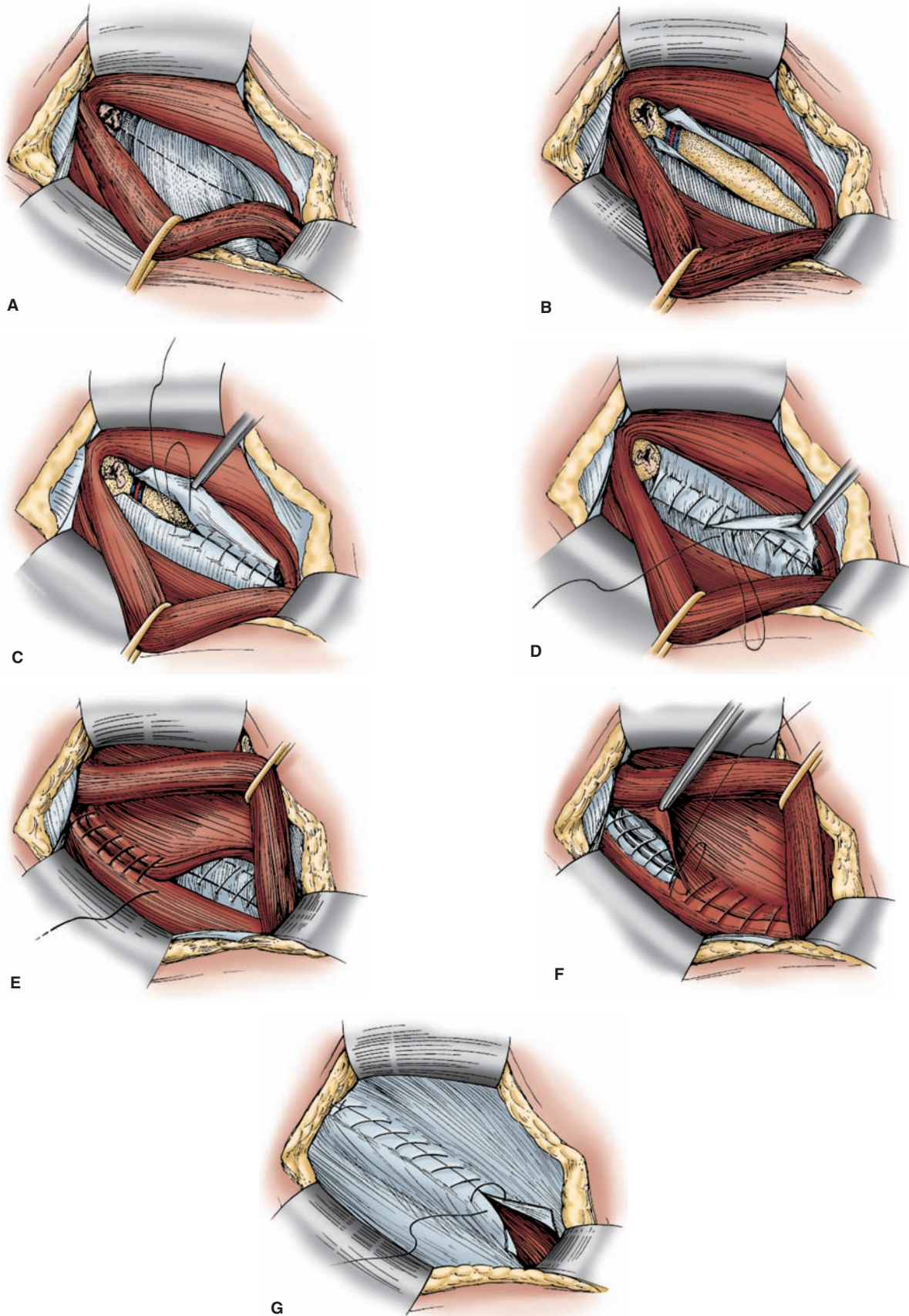
**FIGURE 7-1** *Continued*—**G.** The sac has been invaginated. **H.** A long or complete sac is being dissected free close to the internal ring. **I.** The sac has been transected.

## THE SHOULDICE TECHNIQUE

The Shouldice technique is commonly used for open repair of inguinal hernias and is the most popular pure tissue hernia repair. It is in essence the modern evolution of the Bassini repair performed in a multilayered fashion. Both operations use a tightening of the internal ring and closure of the transversalis fascia to the inguinal ligament as their primary tenets of hernia repair.<sup>8</sup>

Figure 7-2 illustrates the basic steps in the Shouldice repair. After suitable exposure and isolation of the cord, a pair of scissors is passed posterior to the transversalis fascia beginning at the medial pillar of the internal ring and extending inferomedially to the pubic tubercle. In this way, the transversalis fascia is separated from the preperitoneal fat plane. Care must be taken at this stage to preserve the inferior epigastric vessels that reside in the preperitoneal space. The transversalis fascia is then opened with scissors along the entire inguinal floor

from internal ring to pubic tubercle, and the posterior surface of the transversalis is cleaned of its preperitoneal attachments. As the first layer of the repair, the free edge of the lower transversalis flap is sutured in a continuous, imbricated fashion behind the upper flap to the posterior surface of the upper transversalis fascia and the lateral component of the posterior rectus sheath. This running suture layer is started medially at the pubic tubercle and carried up to and through the internal ring, thereby tightening the transversalis fascia around the cord at its entrance to the inguinal canal. The first layer is not tied but continued in a running fashion from lateral to medial as a second layer closing the upper transversalis flap to the base of the lower edge as well as the inguinal ligament. This second layer progresses medially to the pubic tubercle where it is tied to the original tail that started the first layer. The third layer of continuous suture starts at the tightened internal ring and brings together the conjoined tendon (the internal oblique and transversus abdominis aponeuroses)



**FIGURE 7-2** The Shouldice operation. **A.** The transversalis fascia is being incised. **B.** The upper and lower flaps of the transversalis fascia have been dissected free and elevated to expose the extraperitoneal fat and the inferior epigastric vessels. **C.** The first layer of the Shouldice operation. **D.** The second layer. **E.** The third layer. **F.** The fourth layer. **G.** The external oblique aponeurosis has been repaired anterior to the spermatic cord.



medially with the inguinal ligament laterally. This layer is run down to the pubic tubercle, and returns to the internal ring as the fourth layer including the anterior rectus sheath medially with the posterior aspect of the external oblique aponeurosis laterally. The cord can now be relaxed gently on the new inguinal floor, and the external oblique aponeurosis is closed in one to two additional continuous layers extending down to the external ring to reapproximate this structure. The original descriptions of the operation by Shouldice used continuous stainless steel wire suture for all four layers of repair, although surgeons commonly use permanent synthetic suture today.

The Shouldice Hospital reports excellent long-term outcomes from their operation with recurrence rates less than 1% in selected patients.<sup>9,10</sup> These results have not been achieved with any other pure tissue technique. The operation is well tolerated by most patients using local anesthesia only. From the multiple, overlapping, continuous suture lines, Shouldice proponents argue that any tension brought about in this type of closure is dispersed throughout the entire inguinal canal. The dissection is complicated, however, and requires excellent surgical technique and anatomic awareness. Moreover, other surgeons utilizing the Shouldice method have not achieved recurrence rates this low. Thus, the low rate of recurrence associated with the Shouldice technique likely depends on the level of surgical expertise and the patient selection. In one report of 183 inguinal hernia repairs using the Shouldice technique under local anesthesia, the recurrence rates for beginners versus more experienced surgeons were 9.4% versus 2.5%, respectively.<sup>11</sup>

A recent meta-analysis conducted by the Cochrane Collaboration compared the Shouldice technique with other open techniques for inguinal hernia repair.<sup>12</sup> The analysis incorporated results from 16 different randomized or quasi-randomized studies and compared 2566 hernias repaired via the Shouldice technique with 1121 hernias repaired with mesh and 1608 hernias repaired with other nonmesh techniques. The recurrence rate for the Shouldice repair was significantly higher than mesh repair (odds ratio 3.8), but significantly lower than nonmesh repair (Odds Ratio 0.62). There were no significant differences between the groups with respect to complications, length of stay, or chronic pain following herniorrhaphy.<sup>12</sup> Thus, the Shouldice technique is associated with a higher recurrence rate than mesh repairs, but appears to be the repair of choice in situations where mesh cannot be implanted.

## THE COOPER LIGAMENT REPAIR

The Cooper ligament repair is the only technique that definitively repairs both the inguinal and femoral hernia defects in the groin. The operation is often named after Chester McVay, who popularized the operation in the 1940s and introduced the concept of the relaxing incision to decrease the tension from the repair. The repair is also a primary tissue repair in that no mesh is utilized.

The Cooper ligament repair begins similar to the Shouldice procedure, and exposure and isolation of the cord is performed.

The transversalis fascia is then opened and cleaned posteriorly. At this time, Cooper's ligament is identified and dissected free of its fibrous and fatty attachments. The defects are repaired by using interrupted suture to affix the upper border of the transversalis fascia to Cooper's ligament beginning medially at the pubic tubercle and continuing until the femoral sheath is reached. At this point, the femoral canal is closed by carefully suturing Cooper's ligament to the femoral sheath. The repair is continued with interrupted sutures between the transversalis fascia and the iliopubic tract laterally until the entrance point of the cord is reached. In this way, the closure creates a new, and tighter, internal inguinal ring around the cord.

The Cooper ligament repair requires a relaxing incision because this pure tissue repair is associated with significant tension in closing all three groin hernia defects. After the transversalis fascia has been mobilized, and prior to the closure of the fascia to Cooper's ligament, a 2–4 cm vertical incision is made at the lateral border of the anterior rectus sheath beginning at the pubic tubercle and extending superiorly. The relaxing incision can be left open since the rectus muscle should protect against any herniation; alternatively, some surgeons argue for placement of a mesh over the relaxing incision since hernia formation can occur at this site.

The Cooper ligament repair is an outstanding technique for a femoral hernia and is associated with excellent long-term results in experienced hands. Disadvantages of the repair include a longer operating time, a more extensive dissection, the potential for vascular injury and thromboembolic complications from the femoral vessels, and a longer postoperative recovery phase.

## Prosthetic Repairs

Polypropylene mesh is the most common prosthetic used today in mesh repairs of the inguinal hernia. The two most common prosthetic repairs are the Lichtenstein<sup>13</sup> and the “plug and patch” repair as described by Gilbert<sup>14</sup> and popularized by Rutkow and Robbins.<sup>15</sup>

The type of mesh to be used during prosthetic inguinal hernia repairs deserves a brief discussion. The most common and preferred mesh for groin hernia repair is a polypropylene woven mesh marketed under a variety of names. Polypropylene is preferred because it allows for a fibrotic reaction to occur between the inguinal floor and the posterior surface of the mesh, thereby forming scar and strengthening the closure of the hernia defect. This fibrotic reaction is not seen to the same extent with other varieties of prosthetic, namely expanded polytetrafluoroethylene (PTFE) mesh. PTFE is often used for repair of ventral or incision hernias in which the fibrotic reaction with the underlying serosal surface of the bowel is best avoided.

There are limited prospective, randomized data comparing the recurrence rate of open prosthetic repairs versus open nonprosthetic repairs. An attempted meta-analysis concluded that mesh repair was associated with fewer overall recurrences, although the authors report that formal analysis was limited

by the lack of available study data.<sup>16</sup> A review of 26,000 inguinal hernia repairs from Denmark found that mesh repairs had a lower reoperation rate than conventional open repairs.<sup>17</sup> The majority of groin hernia repairs performed in the United States in the modern era utilize mesh placement.

## THE LICHTENSTEIN TECHNIQUE

The Lichtenstein inguinal hernia repair was the first pure prosthetic, tension-free repair to achieve consistently low recurrence rates in long-term outcomes analysis. This operation begins with the incision of the external oblique aponeurosis, and the isolation of the cord structures. Any indirect hernia sac is mobilized off the cord to the level of the internal ring. At this point, a large mesh tailored to fit along the inguinal canal floor is placed so that the curved end lies directly on top of the pubic tubercle. The mesh patch extends underneath the cord until the spermatic cord and the tails of the mesh patch meet laterally. Here, an incision is made in the mesh, and the cord is inserted between the tails of the mesh, thereby creating a new, tighter, and more medial internal ring. The tails are sutured together with one nonabsorbable stitch just proximal to the attachment of the cord. The mesh is then sutured in a continuous or interrupted fashion to the pubic tubercle inferiorly, the conjoined tendon medially, and the inguinal ligament laterally.

Rutkow and Robbins have reported interesting and effective advances in the Lichtenstein technique. The “plug and patch” repair, as illustrated in Fig. 7-3, represents a tension-free herniorrhaphy and can even be performed without sutures. In this technique, the patch is placed in a similar fashion to the modern Lichtenstein repair as it lies along the inguinal canal from the pubic tubercle medially to beyond the cord laterally. In addition, a mesh plug in the form of an umbrella or cone is snugly fit up and into the internal ring. In this way, the repair goes beyond just a tightening of the internal ring, but serves to close the ring around the spermatic cord. Modifications of this operation exist and are practiced commonly by general surgeons. The patch and plug can be sutured to the surrounding inguinal canal tissue in an interrupted or continuous fashion. Alternatively, both prostheses can be placed in appropriate position with no suture affixment. In this way, the body’s natural scarring mechanism will hold both pieces of mesh in place over time. Wide internal ring defects, often caused by large or chronic indirect sacs, may require one or two sutures to tack the plug in place to avoid slippage into the canal anteriorly or the retroperitoneal space posteriorly.

## THE PREPERITONEAL APPROACH

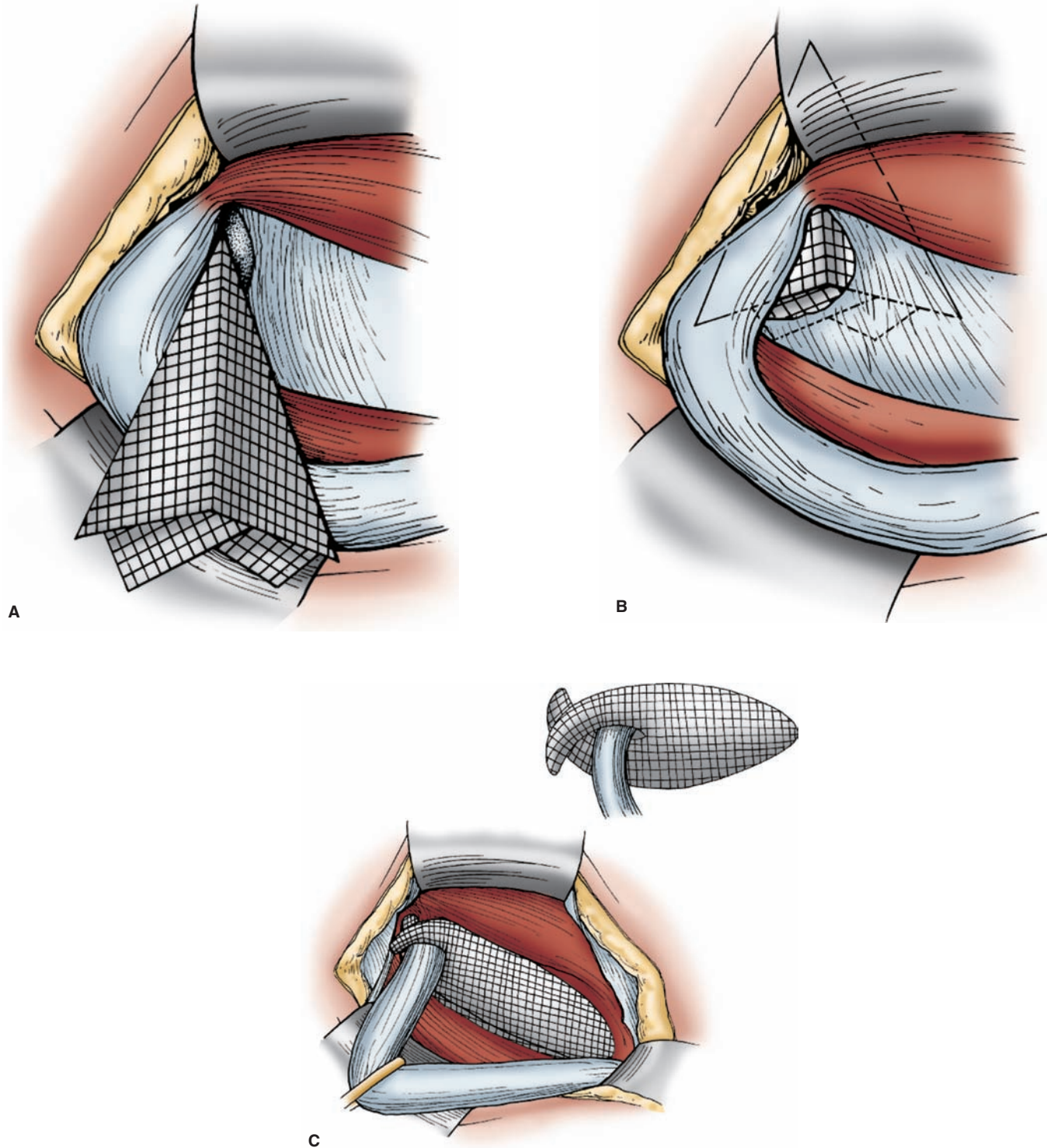
The preperitoneal space is found between the transversalis fascia and the peritoneum itself. The actual groin hernia defect is located anterior to this space, whether the defect exists in the internal ring (indirect inguinal hernia) or through the transversalis floor of the inguinal canal (direct inguinal hernia). Several authors, including Rives, Nyhus,

Stoppa, and Kugel, advocate the use of a preperitoneal or posterior approach to repair the inguinal hernia. They argue that this approach is more effective than the traditional anterior herniorrhaphy because a repair in the preperitoneal plane fixes the hernia defect in the space between the hernia contents and the hernia defect. In contrast, the anterior approach does not keep the hernia contents from contact with the defect, but rather fixes the hernia defect anterior to the defective anatomy. The operation is also advocated for difficult inguinal hernia recurrences, since the posterior approach will usually remain open and without scar following a previous anterior hernia repair. The original operation as described by Nyhus repairs the hernia primarily with suture, although more recent modifications incorporate a mesh patch posterior to the floor of the inguinal canal. As described later in this chapter, the standard laparoscopic technique for inguinal hernia repair is based entirely on the preperitoneal hernia repair.

Figures 7-4 and 7-5 illustrate the preperitoneal repair as described by Rives.<sup>18</sup> In the preperitoneal hernia repair, the incision is usually made transversely in the lower quadrant 2–3 cm cephalad to the inguinal ligament. The incision is made slightly more medial than the anterior approach so that the lateral border of the rectus muscle can be exposed after incising the anterior rectus sheath. Once the muscle is exposed, retraction of the rectus muscle medially allows for careful opening of the posterior rectus sheath and entry into the preperitoneal space. The inferior epigastric vessels and the cord can be visualized in this space. The cord usually does not require extensive manipulation or dissection since the usual cord attachments (lipoma and cremaster fibers) are found in the anterior layers of the inguinal canal. In this way, the approach also avoids exposure to the sensory nerves of the inguinal canal.

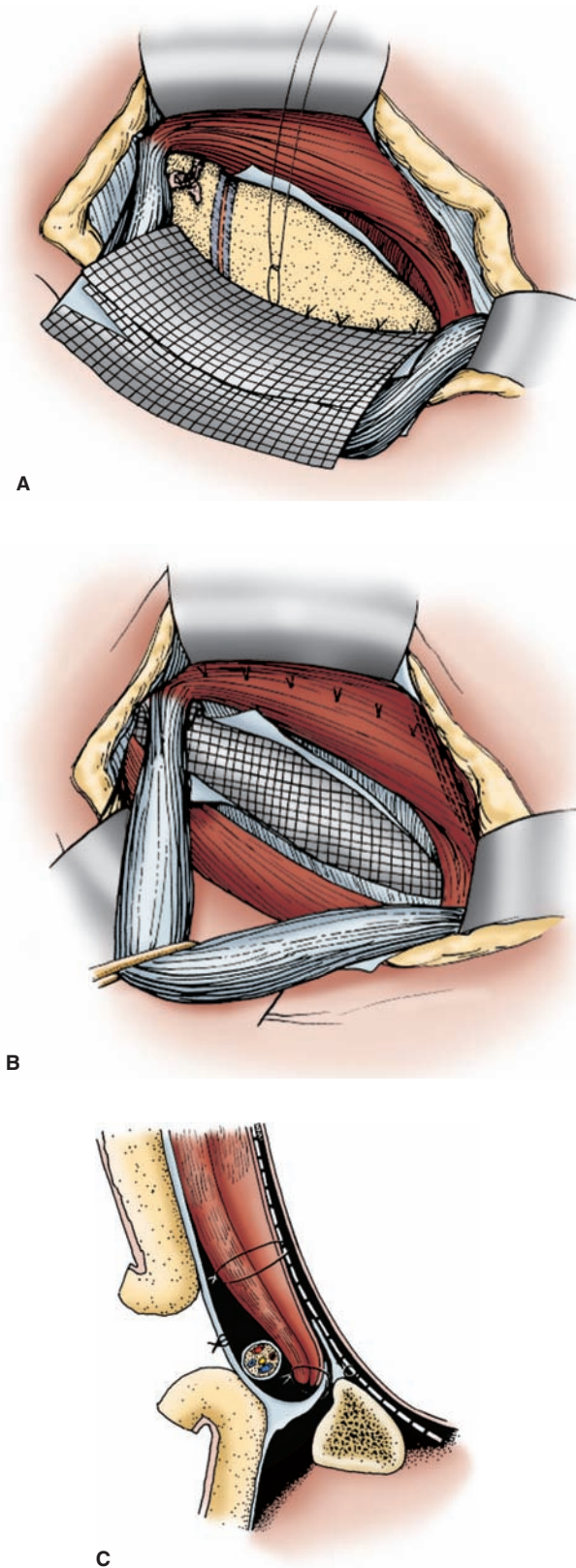
Once the preperitoneal space has been entered and exposed, the specific repair to be performed depends on hernia anatomy. For direct defects, the sac is inverted back into the peritoneal cavity but does not need to be excised. The transversalis fascia is then reapproximated over the inverted sac using interrupted sutures; in this way, the upper border of the transversalis fascia is affixed to the lower border composed of the iliopubic tract. For indirect defects, the sac is reduced off of the cord and a high ligation of the sac is performed at the sac neck; ironically, with this approach, the “high ligation” is actually a “posterior” ligation, since the surgeon ideally should transect the sac just above the preperitoneal fat, which is situated along the inferior border of the exposed field. Once the sac has been ligated, the defect in the internal ring is repaired from the posterior plane using interrupted suture to affix the ring leaflets of the transversalis fascia to the iliopubic tract, thereby tightening the ring itself.

Modifications of this approach using the prosthetic mesh patch are relatively straightforward. The mesh patch is placed underneath the transversalis fascia and directly on the preperitoneal fat. This patch, if placed completely over the inguinal region, covers any peritoneum that could potentially form a hernia sac through a direct or indirect fascial defect.

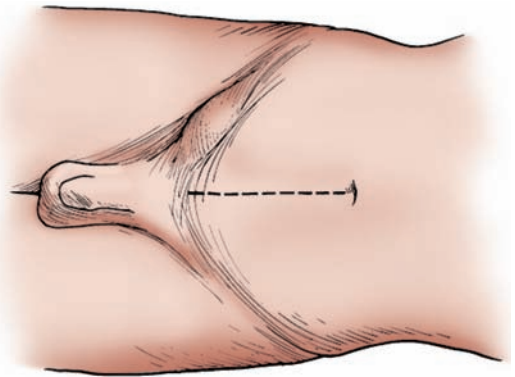


**FIGURE 7-3** The sutureless “patch and plug” tension-free inguinal hernia repair. **A.** The polypropylene mesh “umbrella plug” being passed through the internal ring. **B.** The “umbrella plug” has opened behind the transversalis fascia. **C.** The polypropylene mesh laid down onto the posterior wall of the inguinal canal (the transversalis fascia). Note the end tails of the mesh patch embracing the cord.

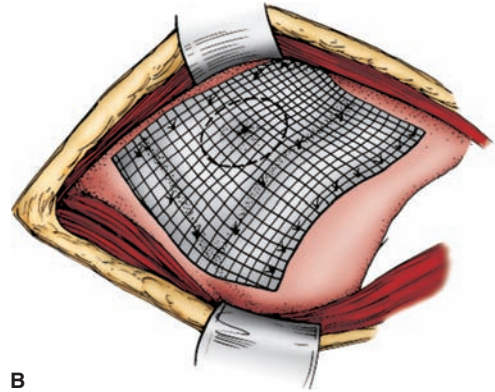




**FIGURE 7-4** Rives prosthetic mesh repair. **A.** Lower line of fixation of the mesh. **B.** Lateral and upper points of fixation of the mesh. **C.** Preperitoneal placement of the mesh and the Bassini-type repair of the posterior wall of the inguinal canal anterior to the mesh.



**A**



**B**

**FIGURE 7-5** **A.** The lower midline incision used for the preperitoneal approach to inguinal hernia repair. **B.** Another view of the points of attachment of the mesh in the preperitoneal plane.

## Laparoscopic Repair

Laparoscopic groin hernia repair was first performed by Ger in 1979, although it was only within the past decade and a half that laparoscopic hernia repair became more accepted. The laparoscopic approach to hernia repair has since evolved into a common and effective procedure. Today, the laparoscopic approach comprises approximately 20–25% of groin hernia operations and 80,000–100,000 laparoscopic hernia repairs are performed annually in the United States. The most important difference between the laparoscopic and open approaches for inguinal hernia repair is anatomical: the laparoscopic approach uses mesh to repair the hernia defect in a plane posterior to the defect (either in the preperitoneal space or from within the peritoneal cavity), whereas the open approaches repair the hernia anterior to the defect.

Three different techniques exist for laparoscopic repair of groin hernias. The transabdominal preperitoneal (TAP) repair involves standard laparoscopy with access into the peritoneal cavity and placement of a large mesh along the anterior abdominal wall, thereby repairing the hernia posterior to the defect. This technique was the first laparoscopic hernia repair to be performed. Ports are generally placed



through the umbilicus and then laterally on either side of the rectus muscle. The hernia defect is usually well visualized from within the peritoneal cavity. After both inguinal regions have been inspected and laparoscopic adhesiolysis performed if necessary, the median umbilical ligament (the urachal remnant), the medial umbilical ligament (the remnant of the umbilical artery), and the lateral umbilical fold (the reflection of peritoneum over the inferior epigastric vessels) are identified. The parietal layer of peritoneum is then incised superior to the hernia defect and reflected inferiorly, thereby exposing the hernia defect, the epigastric vessels, Cooper's ligament, the pubic tubercle, and the iliopubic tract. The cord structures are then dissected free of their peritoneal attachments. In a direct hernia, the peritoneal sac is pulled back within the peritoneal cavity with gentle traction to separate the thin peritoneal layer from the equally thin layer of transversalis fascia anterior to it. In an indirect hernia, the peritoneal sac is retracted off of the cord structures and pulled back within the peritoneal cavity. Alternatively, in the setting of a large chronic indirect hernia, the sac can be divided distal to the internal ring so that only the proximal portion of the sac needs to be mobilized for the repair. A large polypropylene mesh patch is then placed between the peritoneum and the transversalis fascia that covers the inguinal floor, internal ring, and the femoral canal. The mesh is stapled or tacked to the pubic tubercle medially, Cooper's ligament inferiorly, and the anterior superior iliac spine laterally. The incised peritoneal flap is then closed over the mesh.

While the TAP repair has been shown to be effective, there is a risk that the prosthetic mesh will be in direct contact with the bowel, and significant concern has been raised about the potential for intra-abdominal adhesions postoperatively.<sup>19</sup> Enthusiasm for this technique has waned in recent years with the advent of extraperitoneal laparoscopic approaches to inguinal hernia repair.

The total extraperitoneal (TEP) approach to laparoscopic inguinal hernia repair is currently the most popular laparoscopic technique. This repair is performed entirely within the preperitoneal space and does not involve the peritoneal cavity when performed correctly. In this technique, the surgeon carefully develops a plane between the peritoneum posteriorly and the abdominal wall tissues anteriorly, and thus insufflates the preperitoneal space. An incision is made inferior to the umbilicus, and the anterior rectus sheath on the ipsilateral side is incised. The rectus muscle is retracted laterally, and the preperitoneal space is bluntly dissected to allow placement of a balloon port to facilitate insufflation. Once the space has been insufflated, two additional ports are placed in the midline between the umbilicus and the pubic symphysis. In experienced hands, this approach provides for excellent visualization of the groin anatomy, and the dissection proceeds in a similar fashion to the TAP. The TEP repair allows a large prosthetic mesh to be placed through a laparoscopic port into the preperitoneal space, and it is then positioned deep to the hernia defect to repair the hernia from a posterior approach.<sup>20</sup>

The intraperitoneal onlay mesh technique (IPOM) was developed as a simplified version of the TAP repair. In this technique, laparoscopic exposure is obtained directly into the peritoneal cavity as in the TAP. However, this technique does not require an extensive mobilization of the peritoneal flap and dissection of the preperitoneal space. Rather, a large mesh is simply stapled or sutured directly posterior to the peritoneum to repair the hernia. In theory, once the peritoneum scars to the mesh after allowing for connective tissue in-growth, the peritoneum will not be mobile enough to herniate through the actual defect and intra-abdominal pressure will keep the abdominal contents posterior to the mesh patch. The disadvantage of this procedure is that there is direct exposure of mesh to the intra-abdominal contents and therefore a high risk of adhesion formation and possible erosion of the mesh into bowel contents. Another potential disadvantage of the IPOM is the fact that in large inguinal hernias, the mesh and peritoneum may herniate through the defect together, thereby negating any protective effect imparted by the mesh patch. Therefore, at the present time, this procedure is thought to be experimental only.

There are few prospective, randomized data available to adequately judge short- and long-term results of the different laparoscopic inguinal hernia techniques. A systematic review by the Cochrane Collaboration in 2005 found that among the several nonrandomized trials, TAP was associated with an increased rate of port site herniation and visceral organ injury. This review concluded that there are insufficient data from prospective, randomized trials to make firm conclusions about the relative effectiveness of the TEP and TAP procedures.<sup>21</sup>

There are emerging data comparing laparoscopic techniques to open inguinal hernia repair, although the evidence is far from definitive. While there are multiple meta-analyses in the literature, only two truly compare the laparoscopic hernia technique with a tension-free open repair. A meta-analysis of 29 randomized trials in 2003 found that laparoscopic hernia repair was associated with earlier discharge from the hospital, quicker return to normal activity and work, and fewer postoperative complications than open repair.<sup>22</sup> However, in these data there was a trend toward an increase in the risk of recurrence after laparoscopic repair. A separate meta-analysis reviewing 41 published randomized trials found no significant difference in risk of recurrence between the two approaches.<sup>23</sup> Laparoscopic repair was associated with a quicker return to function and less postoperative pain, but also was found to have a higher risk of visceral and vascular injuries. A more recent multicenter, randomized trial that analyzed long-term hernia results in over 2000 patients in 14 Veterans Affairs hospitals found that laparoscopic hernia repair was associated with a higher recurrence rate among primary hernias, but was equivalent to open repair in recurrent hernias.<sup>24</sup> In all of these studies, the laparoscopic repair was noted to take more time in the operating room. Proper laparoscopic technique also appears to play a significant role in recurrence rates. In a randomized, multicenter trial comparing 665 TEP versus 705 Lichtenstein repairs with 5-year

follow-up, authors initially found that the recurrence rate following TEP (3.5%) was significantly higher ( $p = 0.008$ ) than that following Lichtenstein (1.2%).<sup>25</sup> However, when they removed a single surgeon who was responsible for 33% of all the recurrences in the TEP group, the cumulative recurrence rate for TEP was lowered to 2.4% and was not statistically different from the Lichtenstein group. Finally, a recent study has reported a significant learning curve inherent in the laparoscopic approach.<sup>26</sup> Clearly, more definitive multicenter data from surgeons experienced in both procedures are needed to reach formal conclusions about the utility of both hernia approaches.

A separate issue that deserves further study in laparoscopic hernia repair is the anatomical disturbance of the space of Retzius. This area, first described by Retzius in the 19th century, is the prevesical space located anterior and lateral to the bladder. Suprapubic prostatectomy is performed with dissection through this space, and this operation may be made more difficult following laparoscopic hernia repair.

## SURGICAL COMPLICATIONS OF GROIN HERNIA

Although groin hernia repair is associated with excellent short- and long-term outcomes, complications of the procedure exist and must be recognized.

### Recurrence

Recurrence of the hernia in the early postoperative setting is rare. When this does occur, it is often secondary to deep infection, undue tension on the repair, or tissue ischemia. Clearly, all of these etiologies raise the concern for a technical complication on the part of the surgeon, either in the handling of the groin tissues or the placement of mesh or suture. The patient who is overactive in the immediate postoperative setting may also be at risk for early hernia recurrence. In this way, it is thought that early exercise is performed before the suture or mesh in the repair has had an opportunity to hold tissue in place and promote scar tissue formation. In the initial postoperative setting, patients may also develop seromas along the planes of dissection as well as fluid in the obliterated hernia sac. These benign consequences of surgery must be differentiated from the more worrisome early recurrence.

Tension is an important, if not the primary, etiology of hernia recurrence. Tissues repaired under undue tension will tend to pull apart, even if sutures or mesh has been affixed to them. In addition, tension at the site of suture may lead to ischemia at the point where the suture pulls against the tissue, thereby further weakening the hernia repair. Sutures can also cut out or fall apart, especially if placed in a continuous fashion, when tensile force predominates. The role of excessive tissue tension in promotion of hernia recurrence is the basic rationale behind

the modern, tension-free, and increasingly suture-free hernia repairs advocated by hernia experts such as Lichtenstein and Rutkow.

The size of the hernia defect is proportional to the risk of hernia recurrence. Larger hernias have an increased rate of recurrence postoperatively. This is most likely due to the nature of the surrounding fascial tissues that are critical to the strength and reliability of the repair. As large hernias stretch and attenuate the surrounding fascial planes, these tissues are correspondingly weaker when repaired with suture or mesh. The weakened tissue may also be relatively ischemic at the time of hernia repair, although this has not been adequately studied.

An emergency operation for strangulated or incarcerated hernia may increase the risk of postoperative recurrence. It is likely that the strangulated hernia, with its inherent inflammation, tissue ischemia, and fascial edema, provides an environment in which the hernia repair is placed either at increased tension or through unhealthy tissue.

A hernia that is overlooked in the operating room represents a potential etiology of hernia recurrence, although this should not be a major concern for the modern hernia surgeon. Most of the repairs in the current era emphasize the repair of both an indirect and a direct defect through strengthening of the internal ring and inguinal canal floor, respectively.

A final etiology of hernia recurrence pertains to tobacco use and smoking. The relationship between smoking and hernia formation as well as recurrence was first reported in 1981 and further research has identified proteolytic enzymes that may degrade the connective tissue components.<sup>27</sup>

### Infection

Infection of the hernia wound or mesh is an uncommon postoperative complication but represents another etiology of hernia recurrence. In specialized hernia practices, the incidence of wound infection following inguinal hernia operation is 1% or less. When an infection does occur, skin flora is the most likely etiology, and appropriate gram-positive antibiotics should be initiated. Patients who undergo mesh placement during groin herniorrhaphy are at a slightly higher risk of postoperative wound infection. It is often difficult to determine whether the mesh itself is infected or if just the skin or soft tissue anterior to the layer of mesh is infected. However, even if mesh is present, most postoperative groin hernia infections can be treated with aggressive use of antibiotics after the incision is opened and drained expeditiously.<sup>28</sup> Mesh removal in this setting is rarely indicated; when this is mandated, primary closure or redo herniorrhaphy with a synthetic tissue substitute may be warranted and a preperitoneal approach may be necessary.

Seromas and hematomas are frequent complications in the postoperative setting. Seromas form in the dead space remaining from a wide dissection during the hernia repair or when fluid fills the distal remnant of the hernia sac.

While the sac is often ligated or excised during open herniorrhaphy, it remains in place following laparoscopic repair, and the filling of the remnant sac with seroma-type fluid has been termed a pseudohernia. This must be differentiated from the more concerning complication of the early recurrent hernia. Defined fluid collections infrequently require drainage or aspiration, as most will reabsorb or drain through the incision on their own.

Hematoma formation must be assiduously avoided during groin hernia repair. This is especially true in the anticoagulated patient, and therefore it is recommended that patients temporarily stop taking aspirin and clopidogrel at least 1 week prior to their operation. Hematoma formation may be minor and lead only to ecchymoses and wound drainage. The ecchymosis often spreads inferiorly into the scrotal plane in a dependent fashion. The hematoma usually resolves in days to weeks following repair and supportive management for pain control including scrotal elevation and warm packs is all that is required. A large volume of hematoma is concerning, as it may serve as a nidus for infection deep in the hernia wound and may risk secondary infection of the prosthetic mesh. Therefore, hemostasis at the end of a groin hernia repair is paramount to achieve effective wound healing.

## Neuralgia

Postoperative groin pain, or neuralgia, is common to varying degrees following groin herniorrhaphy.<sup>29</sup> Often, the neuralgia will follow the known distribution of the regional nerves, including the ilioinguinal, iliohypogastric, genital branch of the genitofemoral nerve, and the lateral femorocutaneous nerves. During open hernia repair, the ilioinguinal, iliohypogastric, and the genitofemoral nerves are most commonly injured, while the lateral femorocutaneous nerve is more commonly injured during laparoscopic herniorrhaphy. Nerve injury is usually due to entrapment of a portion of the nerve in the mesh or suture line placed in one of the soft tissue layers.

Neuralgias can be prevented by meticulously avoiding overt manipulation of the nerves during operative dissection. The ilioinguinal and iliohypogastric nerves are generally injured during elevation of the external oblique fascial flaps, while the genitofemoral nerve is most likely to be injured during the isolation of the cord and stripping of the cremaster muscle fibers. Often, once the nerve branches are identified, they are encircled with a vessel loop and retracted out of the operative field to avoid injury. The nerves can also be intentionally sacrificed at time of surgery. The result of this maneuver is a region of sensory deprivation in the distributions of these nerve structures, namely on the inner upper thigh and the hemiscrotum. However, the sensory deprivation is thought to be better tolerated by the patient than the chronic and persistent pain attributed to nerve entrapment in scar or mesh. In laparoscopic repair, nerve injury can be prevented

by avoiding tack or staple placement below the iliopubic tract.

Neuralgia should first be managed conservatively, with attempts at local anesthetic injection in the affected groin. When local anesthesia is injected along the known course of a nerve, this modality may serve as both a diagnostic and a therapeutic maneuver. In some cases, temporary control of the chronic pain with local anesthesia may reduce or altogether eliminate the sequelae of chronic groin pain. When this conservative approach does not succeed, groin re-exploration can be performed to ligate or excise affected nerve branches. This is clearly not the preferred first option, since the groin wound has abundant scar and previously undamaged nerve structures may be placed at additional risk. Occasionally, patients will present with postoperative neuralgia that does not match the distribution of any known inguinal nerve. Groin re-exploration should be avoided in this case since it is unlikely to ameliorate the pain and may damage additional structures.

Nerve injury during laparoscopic repair can occur during the tacking of the mesh to the anterior abdominal wall. Tacks should be avoided in the known areas of nerve structures. Some surgeons prefer to not place any tacking staples at all when performing laparoscopic herniorrhaphy to avoid this complication altogether.

## Bladder Injury

The urinary bladder may be inadvertently injured during dissection of a direct inguinal hernia sac, but only rarely during repair of an indirect defect. The bladder can also participate in a sliding hernia so that a portion of the bladder wall is adherent to the sac in a direct defect. Because of the potential for this complication, direct sacs should be inverted into the peritoneal cavity so that excessive dissection can be avoided. If bladder injury takes place, the sac should be opened, and the bladder injury repaired in two layers of an absorbable suture. In general, a urethral catheter is placed for a minimum of 7–14 days.

## Testicular Injury

Testicular swelling and atrophy is seen after inguinal hernia repair. Edema of the scrotum or testis may be secondary to edema or hematoma of the inguinal canal that tracks inferomedially to the scrotum in a dependent fashion. Alternatively, a tender testicle or an atrophic testicle may be secondary to injury to the blood supply to the genitals during dissection and isolation of the cord. In most cases, this is not an emergency in the adult patient, and the testes will atrophy without significant infectious complications so that orchietomy is rarely necessary. A testicle that is tender on examination may require ultrasonographic imaging to rule out testicular torsion or a corresponding abscess. Necrosis of the

testes, a very rare complication of groin hernia repair, usually requires orchiectomy to avoid infectious complications.

In the pediatric patient, traction on the cord in the cephalad direction can cause the testes to migrate into the inguinal canal and out of the scrotum. For this reason, the scrotum is often prepped sterilely in the pediatric inguinal hernia operation, and the testes are confirmed to be in appropriate position by palpation at the end of the hernia repair. If the testes remain in the inguinal canal following herniorrhaphy, this may require manipulation of the testes further down the canal and into the scrotum using a long atraumatic forceps or a choker instrument.

## Vas Deferens Injury

Injury to the vas deferens is a rare complication of groin hernia surgery in the male patient. Transection of the vas is the most serious form of this injury; this requires urologic consultation and likely immediate reanastomosis in the child or young adult, but may only require ligation of both ends in the older adult patient. Minor injuries to the vas can be avoided by using gentle, atraumatic traction only and by avoiding complete grasping or squeezing of the vas. The most worrisome sequela of vas deferens obstruction or transection is formation of antisperm antibodies in the serum, leading to infertility.

## THE STRANGULATED GROIN HERNIA

The strangulation of a groin hernia is a complication of the hernia itself rather than of a hernia repair. This pathophysiologic process is associated with a high rate of mortality and morbidity, especially in the elderly population with multiple comorbidities. The risk of strangulation is highest in the first months to years after the initial presentation of a reducible hernia. Gallegos and associates estimated the probability of inguinal hernia strangulation over time to be 2.8% over 3 months and 4.5% at 2 years.<sup>30</sup> It is likely that with time, the hernia contents weaken the hernia defect and widen the hernia neck so that the sac is no longer compressed as tightly, thereby decreasing the opportunity for incarceration and strangulation to take place.

The mortality from a strangulated hernia is related to the duration of the strangulation and the age of the patient. A longer duration of strangulation leads to a greater degree of tissue edema, ischemia, and risk of outright necrosis. Therefore, a strangulated hernia clearly represents a surgical emergency. The incarcerated hernia without overt signs of strangulation on examination and laboratory analysis should undergo attempts at reduction, often requiring conscious sedation to minimize discomfort. After the hernia is reduced, the repair can take place 1–2 days later, usually during the same inpatient hospitalization, to minimize risk of recurrent incarceration leading to strangulation.

Surgery for an incarcerated inguinal hernia is most often performed under general anesthesia given the high likelihood that bowel resection will need to be performed. Epidural or spinal anesthesia may suffice in select cases, but local anesthesia should not be employed. The location of the incision depends on the diagnosis and clinical assessment. In those patients who are unlikely to have ischemic bowel present within the hernia sac, an inguinal incision will likely be successful in both reducing the hernia contents and repairing the hernia defect. If nonviable bowel is found on exploration of the inguinal canal, the resection and anastomosis can take place deep to the transversalis fascia in the preperitoneal space or a midline incision can be made. If the initial physical examination yields signs of ischemic bowel that may necessitate resection, a midline laparotomy can be performed and the hernia repaired in the inguinal canal using a tissue repair after the laparotomy is closed. A helpful alternative is the preperitoneal hernia repair, which can be used to evaluate the bowel and repair the hernia defect; yet it can also be easily converted to an intraperitoneal exposure if extensive bowel resection and anastomosis is required. Placement of prosthetic mesh should be avoided when possible in strangulated hernia repair given the increased risk of bacterial translocation and wound infection.

## FEMORAL HERNIA

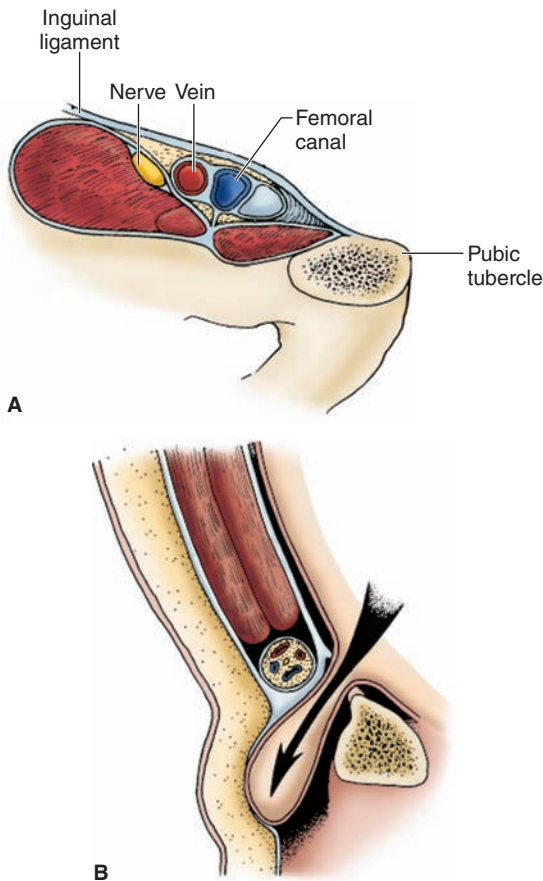
The femoral hernia is the second most common abdominal wall hernia, although it makes up only 5–10% of all hernias. The femoral hernia is more common in females than in males, by a ratio of approximately 4:1.

## Anatomy and Etiology

Figure 7-6 illustrates the anatomy of the femoral hernia. The defect through which a femoral hernia occurs is in the medial femoral canal. The anterior boundary of this defect is the inguinal ligament, the lateral boundary the femoral vein, the posterior boundary the pubic ramus and Cooper's ligament, and the medial boundary the lacunar portion of the inguinal ligament. This space is obviously tight and does not have room to expand when hernia contents fill the sac since the boundaries are either ligamentous, bony, or the fibrous femoral sheath and its vessels. Therefore, femoral hernias have a high propensity for incarceration and strangulation. Gallegos and associates reported the cumulative probability of femoral hernia strangulation to be 22% in the first 3 months following diagnosis and 45% at nearly 2 years.<sup>30</sup> Therefore, repair of a known femoral hernia is mandatory to avoid this highly morbid complication.

In contrast to the inguinal hernia, the femoral hernia is unlikely to be of congenital etiology. The incidence of femoral hernia in infancy and childhood is exceedingly low, in the range of 0.5%. In addition, there is no embryologic mechanism for a preexisting sac of peritoneum in the femoral canal. The hernia defect most often presents in middle-aged





**FIGURE 7-6** The anatomy of the femoral hernia. **A.** The structures posterior to the inguinal ligament. **B.** The femoral hernia passing through the femoral canal and bulging in the groin below the inguinal ligament.

to older women, suggesting that the natural loss of tissue strength and elasticity is a primary etiology.

## Clinical Presentation

The femoral hernia often presents as a small bulge just below the medial groin crease. It is often difficult to reduce on initial presentation.<sup>31</sup> The hernia usually extends caudad as the sac increases in size with abdominal contents but may extend up and over the inguinal ligament anteriorly. Not uncommonly, the femoral hernia presents acutely with strangulation given its anatomic limitations. The differential diagnosis for a femoral hernia includes femoral lymphadenopathy, groin lipoma, or a soft tissue mass of benign or rarely malignant nature.

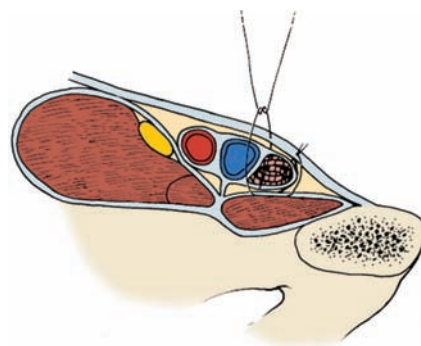
## Treatment

The operative approach to repairing the reducible femoral hernia differs from inguinal hernia repair in several ways.

The incision is usually centered transversely just below the inguinal ligament, although a standard groin hernia incision may still afford exposure to the defect. The simplest approach is anterior to the inguinal ligament. Here, the sac can often be found, dissected, and reduced into the peritoneal cavity. Repair of the defect can be performed using a Cooper ligament repair as described above, by affixing the transversalis fascia to the Cooper's ligament medially and the iliopubic tract laterally up to the internal ring. Alternatively, a simple suture repair can be performed by tacking the inguinal ligament anteriorly to Cooper's ligament posteromedially to close the defect. A third option is a purse-string suture placed first anteriorly into the inguinal ligament, then through the lacunar ligament medially, the pectineal ligament posteriorly, and finally through the fascia medial to the femoral vein and back to the inguinal ligament. All of these techniques can successfully close the femoral hernia defect.

However, a unique complication from suture repair of the femoral hernia defect is bleeding from an aberrant obturator artery. This vessel originates from the inferior epigastric rather than the internal iliac artery and traverses a space medial to the femoral hernia defect adjacent to the pubic ramus. The medial suture placed in femoral hernia repair can injure an aberrant obturator artery if present. A simple and possibly safer way to repair the femoral defect is a mesh plug placed from cephalad to caudad to obstruct the defect and promote scar tissue formation. This technique, shown in Fig. 7-7, has been reported by Lichtenstein with excellent results and low rates of recurrence.<sup>32</sup>

If the femoral hernia sac is large and filled with voluminous intra-abdominal contents, a preperitoneal repair should be considered. In this way, the transversalis fascia is opened and the preperitoneal plane is entered. This approach is particularly useful during repair of a strangulated hernia since there is more space to allow for inspection of the bowel to ensure viability. Bowel resection, if needed, can also take place in the preperitoneal space prior to full reduction of the hernia contents.



**FIGURE 7-7** The Lichtenstein polypropylene plug for repair of a femoral hernia.

## UMBILICAL HERNIA

The umbilicus represents a midline opening in the linea alba. Umbilical hernia occurs when the umbilical scar closes incompletely in the child or fails and stretches in later years in the adult patient. The hernia becomes readily apparent once the abdominal contents move through the umbilical opening given the relative lack of soft tissue in the anterior body wall at the site of the umbilicus.

### History

Umbilical hernias have been documented throughout history with the first references dating back to the ancient Egyptians with the first known record of a surgical repair by Celsus in the first century AD. Mayo in 1901 reported the first series of patients to undergo the classic overlapping fascia operation through a transverse umbilical incision using nonabsorbable suture.<sup>35</sup>

### Incidence

Estimates of umbilical hernia present at birth have a wide range. In Caucasian babies, the incidence has been reported at 10–30%, although for unknown reasons it may be several times greater in African-American children. Umbilical hernia is even more common in premature infants of all races and there is a tendency for familial inheritance.

The majority of congenital pediatric umbilical hernias are known to close over time, as the infant becomes a child. In this way, by school age, only 10% of umbilical hernias remain open on physical examination. Umbilical hernia repair in the child is therefore rarely performed electively before the age of 2 years, and incarceration in the child is rare. Current recommendations in the pediatric surgical literature advise the delay of umbilical hernia repair until at least 2–3 years of age given the likelihood that most umbilical hernias will spontaneously close in the young child.

The incidence of umbilical hernia in the adult is largely unknown but most cases are thought to be acquired rather than congenital. It is known to occur more commonly in adult females with a female:male ratio of 3:1. Umbilical hernia is also more commonly found in association with processes that increase intra-abdominal pressure, such as pregnancy, obesity, ascites, persistent or repetitive abdominal distention in bowel obstruction, or peritoneal dialysis. The etiology of umbilical hernia in the adult may be multifactorial, with increased intra-abdominal pressure working against a weak or incomplete umbilical scar.

### Embryology and Anatomy

The fascial margins that make up the umbilical defect are formed by the third week of gestation, and the umbilical

cord takes shape in the fifth week of gestation. In the sixth week, the intestinal tract migrates through the umbilicus and outside the coelom as intestinal growth outpaces the size of the abdominal cavity. The intestinal tract returns to the abdominal cavity through the umbilical defect as the midgut undergoes rotation at the tenth week of gestation, and subsequent to this, the four folds of the somatopleure begin to fuse inward. This, in turn, forms the tight umbilical defect, which allows only the passage of the umbilical vessels. At birth, when the umbilical cord is manually ligated, the umbilical arteries and vein thrombose and the umbilical aperture close. Any defect in the process of umbilical closure will result in an umbilical hernia through which omentum or bowel can herniate.

### Clinical Manifestations

The diagnosis of umbilical hernia is not difficult to make. The condition presents with a soft bulge located anterior or adjacent to the umbilicus. In most cases, the bulge will be readily reducible so that the actual fascial defect can be easily defined by palpation. The patient may provide a history of vague abdominal pain associated with herniation and reduction. The list of differential diagnoses is short and includes abdominal wall varices associated with advanced cirrhosis, umbilical granulomas, and metastatic tumor implants in the umbilical soft tissue (Sister Joseph's node). In clinical practice, there is usually little doubt as to the diagnosis of umbilical hernia on physical examination.

While the majority of umbilical hernias will close spontaneously in the infant, the clinical spectrum varies widely in the adult. The hernia in the adult is often symptomatic and does not show a tendency to close without intervention. As the hernia contents increase in size, the overlying umbilical skin may become thin and ultimately ulcerated by pressure necrosis. The umbilical hernia with incarcerated omentum may present with significant tenderness on examination, despite the fact that bowel integrity is not at risk. Alternatively, an umbilical hernia may be found incidentally in the adult on physical examination. This hernia is usually small and any hernia contents are usually readily reducible. The small, asymptomatic, reducible hernia in the adult can be observed without the need for immediate intervention.

Patients with umbilical hernia secondary to chronic, massive ascites require special consideration. The repair of such hernias is associated with significantly increased morbidity and mortality. Fluid shifts leading to hemodynamic instability, infection, electrolyte imbalance, and blood loss are all considerable risks for the patient in this clinical scenario. Umbilical hernia recurrence is also common in this setting given the persistently increased intra-abdominal pressure. Thus, hernia repair in this population should be reserved for those with progressively symptomatic or incarcerated umbilical hernias.

## Treatment

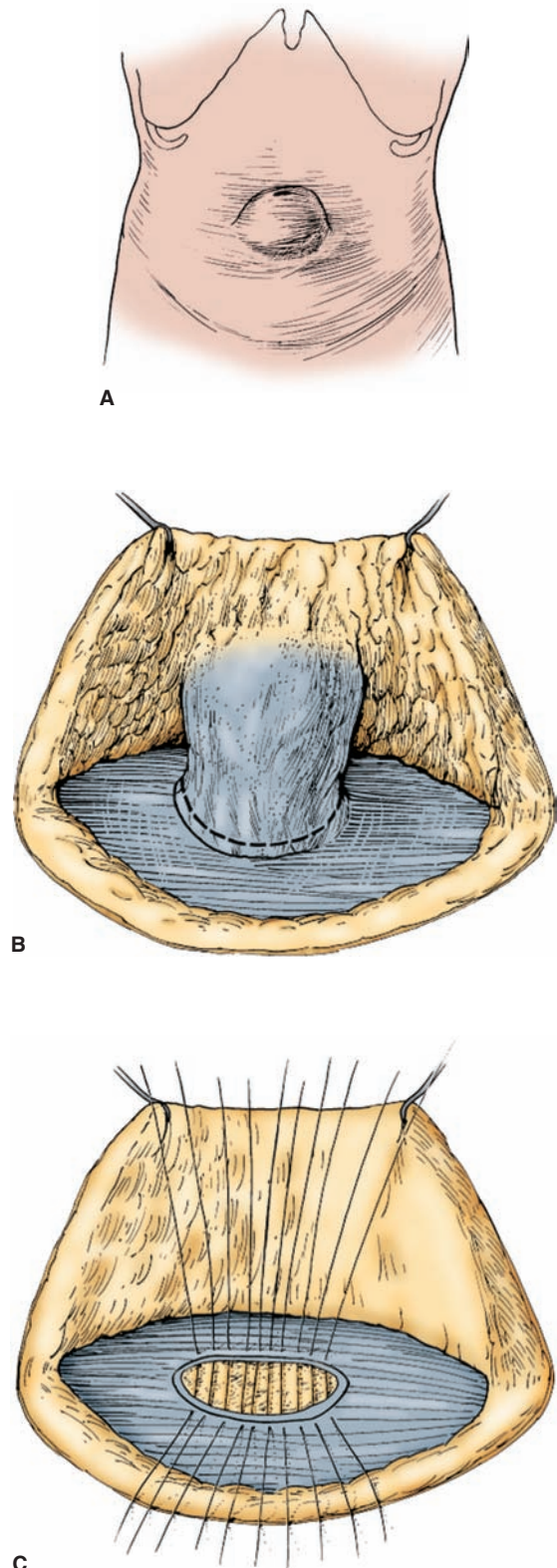
In the pediatric patient with a small umbilical hernia, a short curvilinear (smile) incision is made just inferior to the umbilicus in the typical skin crease. A skin flap is then raised cephalad using blunt dissection and low-level electrocautery. Dissection is carried through the subcutaneous tissues and down to the fascial level. The neck of the sac is then encircled with a hemostat. After the sac is dissected free of its umbilical attachments, it can be reduced or inverted completely into the peritoneal cavity or incised to explore the contents of the hernia sac. In this way, the redundant portion of the sac can be excised using electrocautery. The fascial defect is then closed transversely with interrupted sutures in a horizontal mattress fashion, and the skin of the umbilicus is tacked to the fascia layer using a single suture. This operation is usually performed under general anesthesia as a day-surgery procedure.

In the adult patient, most small umbilical hernia repairs are performed using local anesthesia with the possible addition of intravenous sedation. The approach is also through a curvilinear incision, placed transversely on the inferior border of the umbilicus or vertically on one curved edge of the umbilicus (Fig. 7-8). A skin flap is raised to elevate the umbilicus off the hernia sac. The sac is again dissected free of its fascial attachments to isolate the sac for complete reduction and to allow for an adequate width of fascia for suture closure. The sac contents are then reduced into the abdominal cavity and any excess sac can be excised. The defect is then closed with a strong, nonabsorbable suture (such as 0 polypropylene or nylon), usually in an interrupted fashion. The fascial edges are approximated through this technique. The traditional “vest-over-pants” technique originated by Mayo is less commonly utilized since overlapping fascial closures have been shown to weaken the overall wound strength in hernia repair.

In large defects that may close only with a significant degree of tension, a cone of polypropylene mesh can be fitted to fill the umbilical defect in place of a tissue repair. The mesh is then sutured circumferentially to the surrounding umbilical fascia to prevent migration. Newer mesh products contain polypropylene mesh or polyester mesh in combination with a bioabsorbable layer so that they can be placed in contact with the bowel without the formation of significant adhesions. These products can be very useful in the treatment of umbilical and other ventral hernias where mesh adherence to bowel is a concern.

## EPIGASTRIC HERNIA

An epigastric hernia is a defect in the abdominal wall in the midline junction of the aponeuroses of the abdominal wall musculature from the xiphoid process superiorly to the umbilicus inferiorly. The region of this midline raphe is termed the linea alba, and the rectus muscles are situated just lateral to the linea alba. In this area, there is no muscle layer to protect



**FIGURE 7-8** Repair of the small umbilical hernia. **A.** The “smile” curvilinear incision that allows for a skin flap to be raised. **B.** The incising of the hernia sac. **C.** The sutures in place. Mattress type sutures can also be used to alleviate undue tension in larger hernias.



against herniation of intra-abdominal contents through defects in the midline fascia. A paraumbilical hernia is an epigastric hernia that borders on the umbilicus.

## History

The epigastric hernia was first described by Villeneuve in 1285, but the term “epigastric hernia” was only first used to describe this condition in 1812 by Leville. The first successful repair of an epigastric hernia was reported in 1802 by Maunior.

## Incidence

Estimates of the frequency of epigastric hernia in the general population range from 3% to 5%. It is most commonly diagnosed in middle age, and congenital epigastric hernias are uncommon. The condition is more common in males by a ratio of 3:1. Twenty percent of epigastric hernias may be multiple, although most are associated with one dominant defect.

## Anatomy and Etiology

The cause of epigastric hernia is largely unknown. Since the condition does not predominate in children, it is unlikely that the defect is entirely congenital in origin. Rather, the hernia is likely the result of multiple factors, such as a congenitally weakened linea alba from a lack of decussating midline fibers and subsequent increase in intra-abdominal pressure, surrounding muscle weakness, or chronic abdominal wall strain.

The midline defect is usually elliptical in nature, with the long axis oriented transversely. The width of the defect is generally a few millimeters to several centimeters, and larger defects are rare. In most cases, the hernia is filled by a small amount of preperitoneal fat only and no peritoneal sac is present. The hernia will often not be seen on laparoscopy owing to the lack of peritoneal involvement through the hernia defect. Epigastric hernias that involve a peritoneal sac usually contain only omentum and rarely small intestine.

## Clinical Manifestations

Epigastric hernia is often asymptomatic and represents a chance finding on physical examination. Patients with symptomatic hernias complain of vague abdominal pain above the umbilicus that is exacerbated with standing or coughing and relieved in the supine position. Severe pain may be secondary to incarceration or strangulation of preperitoneal fat or omentum. Bowel strangulation in epigastric hernias is a rare finding.

On examination, the hernia is diagnosed by palpating a small, soft, reducible mass in the midline superior to the umbilicus. The mass may protrude with a Valsalva maneuver or with standing. Palpation can be especially difficult in the obese patient. Rarely, imaging is needed to confirm the diagnosis, and computed tomography of the abdomen is the preferred technique.

## Treatment

As illustrated in Fig. 7-9, operative repair of the epigastric hernia can most often be performed as a day-surgery procedure under local anesthesia. General anesthesia should be reserved for the complicated patient, a very large hernia, or the pediatric population. The herniated contents are exposed through a small midline vertical or transverse incision. The defect in the linea alba and the surrounding fascia are cleared of subcutaneous fat. Effort is made to identify a peritoneal sac protruding through the defect. If identified, a small sac can be simply inverted back within the abdominal cavity. Alternatively, a larger sac can be opened, its contents reduced, and any excess peritoneum excised. It is usually not necessary to perform formal closure of the peritoneal sac. The defect is then closed transversely with a few interrupted sutures of polypropylene or nylon, taking generous bites of surrounding fascia.

This repair usually suffices with minimal recurrence. In general, it is not necessary to reconstruct the linea alba for a single epigastric hernia. Most patients will not develop a subsequent epigastric hernia at a separate site, and repair of an epigastric hernia is a minor ambulatory procedure that can be repeated easily if necessary.

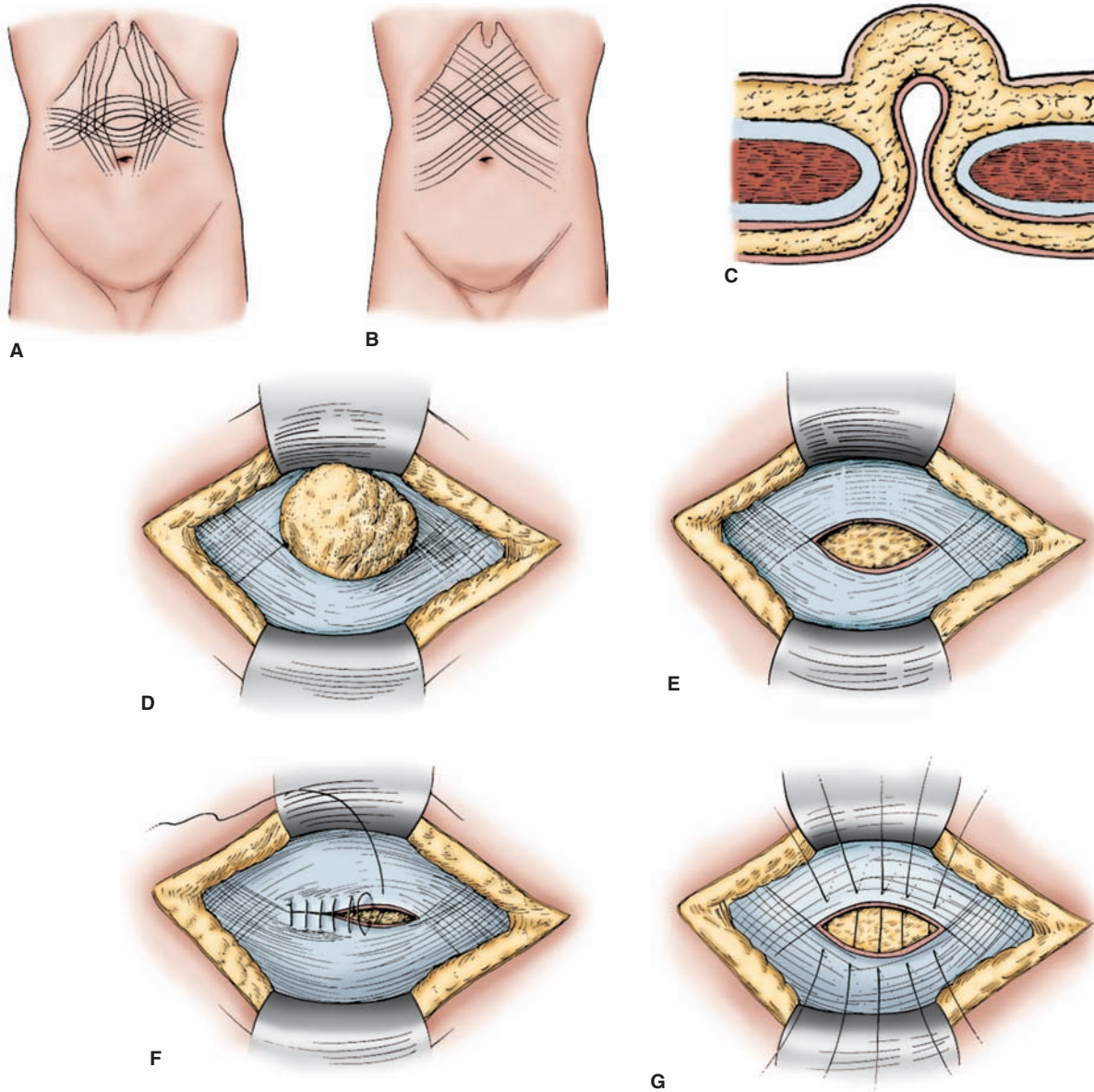
## OBTURATOR HERNIA

An obturator hernia is one of the rarest forms of hernia, and most surgeons will see few in an entire career. An obturator hernia occurs when there is protrusion of intra-abdominal contents through the obturator foramen in the pelvis.

## Incidence

The true incidence of obturator hernia is unknown. The largest reported series includes only 43 patients diagnosed with obturator hernia over a 30-year period.<sup>34</sup> It is thought that less than 1% of mechanical bowel obstructions arise from strangulated obturator hernias. The hernia is much more common in females, with a female:male ratio of 6:1. The gender discrepancy is often explained by differences in female pelvic anatomy, including a broader pelvis, a wide obturator canal, and the increase in pelvic diameter brought about by pregnancy. Most cases of obturator hernia present in the seventh and eighth decades, and this condition is clearly





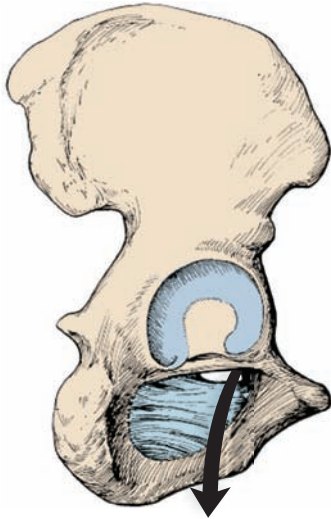
**FIGURE 7-9** Repair of the epigastric hernia. **A.** The elliptical opening. **B.** The diamond-shaped opening. **C.** The small empty sac. **D.** Herniated fat exposed during dissection. **E.** Herniated fat and the sac have been excised. **F.** Repair of continuous suture technique. **G.** Repair using interrupted sutures.

associated with advanced age. Bilateral obturator hernias have been reported in 6% of cases.

## Anatomy

The obturator foramen is formed by the ischial and pubic rami (Fig. 7-10). The obturator membrane covers the majority of the foramen space, except for a small portion through which the obturator vessels and nerve pass. These vessels traverse the canal to leave the abdominal cavity and enter the medial aspect of the thigh. The boundaries of the

obturator canal are the obturator groove on the superior pubic ramus superiorly and the upper edge of the obturator membrane inferiorly. The canal is approximately 3 cm in length, and the obturator vessels and nerve lie posterolateral to the hernia sac in the canal. The hernia sac usually takes the shape of the canal so that it is long and narrow before ballooning in the upper thigh. The hernia lies deep to the pectineus muscle and therefore is difficult to palpate on examination. Small bowel is the most likely intra-abdominal organ to be found in an obturator hernia, although rare cases have been reported of the appendix, Meckel's diverticulum, omentum, bladder, and ovary incarcerated in the hernia.



**FIGURE 7-10** The direction of the obturator hernia through the obturator canal.

## Clinical Manifestations

Obturator hernia is associated with four cardinal findings that assist in the difficult diagnosis. Rarely do all four physical findings occur together. The most common clinical manifestation is intestinal obstruction, which occurs in over 80% of patients. This is often in the form of acute obstruction secondary to hernia strangulation.<sup>35</sup> The second most common finding is the Howship–Romberg sign, seen in about one-half of patients with obturator hernia. With this sign, patients characteristically complain of pain along the medial surface of the thigh that may radiate to the knee and hip joints. The finding is likely associated with compression of the obturator nerve between the canal and the hernia sac. The adductor reflex in the thigh may also be weakened or lost secondary to motor dysfunction from an entrapped obturator nerve. The third finding, observed in 30% of patients, is a history of repeated episodes of bowel obstruction that pass quickly and without intervention. This is likely due to periodic incarceration of the hernia sac in the obturator canal. Finally, a fourth finding is a palpable mass in the proximal medial aspect of the thigh at the origin of the adductor muscles. The palpable mass is only found in an estimated 20% of patients with obturator hernia. The mass is best palpated with the thigh flexed, abducted, and rotated outward.

In rare cases, ecchymoses may be noted in the upper medial thigh due to effusion from the strangulated hernia contents. The obturator hernia mass may also be palpated laterally on a vaginal examination.

## Treatment

The only treatment for obturator hernia is surgical repair. All obturator hernias should be operated on soon after diagnosis given the high risk for bowel incarceration and strangulation.

There is no role for conservative management given the location of the hernia and the fact that the strangulated obturator hernia is difficult to diagnose. A preoperative diagnosis of obturator hernia is rare indeed, and a diagnosis prior to presentation with bowel obstruction is even more uncommon. The typical case of obturator hernia presents as an acute small bowel obstruction with evidence of ischemic bowel on examination, laboratory analyses, or imaging. Therefore, obturator hernia repair is often performed as a surgical emergency via a midline laparotomy.

There are three general operative approaches for obturator hernia repair: the lower midline transperitoneal approach, the lower midline extraperitoneal approach, and the anterior thigh exposure.

The lower midline transperitoneal approach is the most common method for repair of obturator hernias since most cases are encountered unexpectedly during exploratory laparotomy for small bowel obstruction of unknown etiology. Following laparotomy, the dilated small bowel is run deep into the pelvis where it is found to enter the obturator canal alongside the obturator vessels and nerve. A careful attempt should be made to reduce the incarcerated bowel with gentle traction. This maneuver may be augmented by palpation on the medial inner thigh to push the hernia sac into the abdominal cavity from the outside. This is difficult to perform without assistance since the thigh is rarely sterilely prepared for the exploratory laparotomy unless a preoperative diagnosis of obturator hernia has been made. The pelvic side of the obturator canal has a rigid opening that cannot be digitally dilated, making reduction of the hernia sac more difficult. If traction alone does not allow reduction of the bowel, the obturator membrane can be carefully incised from anterior to posterior to facilitate exposure. Care should be taken to avoid injury to both the incarcerated bowel and the obturator vessels. If these maneuvers are unsuccessful, a counter incision can be made in the medial groin to facilitate reduction from both sides of the canal. Once the hernia has been reduced, the intestine is assessed for viability and resected as needed. The hernia opening is then closed around the obturator vessels with a running layer of polypropylene or nylon suture applied in the thin layer of fascia that encircles the inner circumference of the canal. Alternatively, in a clean case without bowel contamination, a piece of mesh can be placed over the obturator foramen. Some hernia surgeons suture the mesh to Cooper's ligament to avoid migration.

The midline extraperitoneal approach is used when the diagnosis of obturator hernia has been made preoperatively. It allows complete exposure of the opening of the obturator canal. The incision is made in the midline from the umbilicus to the pubis. The preperitoneal plane is entered deep to the rectus muscle, and the bladder is peeled from the peritoneum. The space is opened so that the superior pubic ramus and the obturator internus muscle are exposed. The hernia sac is seen as a projection of peritoneum passing inferiorly into the obturator canal. The sac is incised at the base, the contents are reduced, and the neck of the sac is transected. Any remaining distal sac in the canal is extracted by traction or

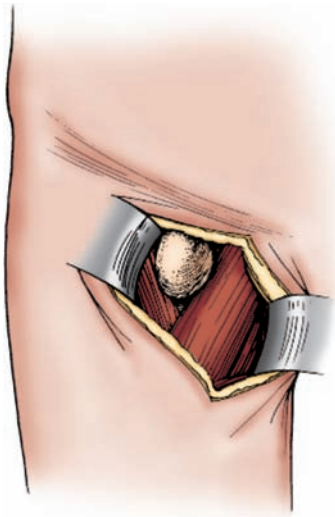


FIGURE 7-11 The thigh approach for repair of the obturator hernia.

with long forceps. The internal opening to the obturator canal is closed with a continuous suture as described above. The bites of tissue should include the periosteum of the superior pubic ramus and the fascia on the internal obturator muscle. Care must be exercised at all times to avoid injury to the obturator vessels and nerve that run alongside the hernia defect. In addition to or in place of the suture closure of the obturator defect, preperitoneal mesh placement has been described to cover the defect.

The thigh approach begins with a vertical incision in the upper medial thigh placed along the adductor longus muscle (Fig. 7-11). The muscle is retracted medially to expose the pectineus muscle, which is cut across its width to expose the sac. The sac is carefully incised, the contents inspected and reduced if viable, and the sac is excised. The hernial opening is closed with a continuous suture layer. If the bowel contents within the hernia sac do not appear viable, it is difficult to perform an adequate small bowel resection through the thigh incision and therefore midline laparotomy is usually performed.

Laparoscopic transperitoneal and extraperitoneal approaches have been recently described for obturator hernia repair with placement of prosthetic mesh to close the obturator opening.<sup>36</sup>

## Results

Mortality after obturator hernia repair has been much higher than with other hernias because it is associated with acute bowel obstruction in an elderly population with multiple comorbidities. Recent data show a mortality of less than 5% and a 25% incidence of small bowel resection during obturator hernia repair.<sup>34</sup> These reports emphasize the benefit in accuracy in the modern era afforded by computed

tomographic imaging techniques. Recurrence rates are low in published series, although long-term follow-up has proved difficult in this patient population.

## PERINEAL HERNIAS

Hernias of the perineum are rare and composed of protrusions of the intra-abdominal contents through a weakened pelvic floor. They may also be termed pelvic hernias, ischio-rectal hernias, pudendal hernias, subpubic hernias, or hernias of the pouch of Douglas. Perineal hernias should be differentiated from the more common rectocele or cystocele, which are related to pelvic floor relaxation, most often from childbirth, and do not represent true hernias.

Primary perineal hernias are extremely rare. The first reported case was by Scarpa in 1821. Secondary, or postoperative, perineal hernias are more commonly seen and occur in patients status postabdominoperineal resection in which the pelvic musculature is dissected to resect the distal rectum.

## Etiology

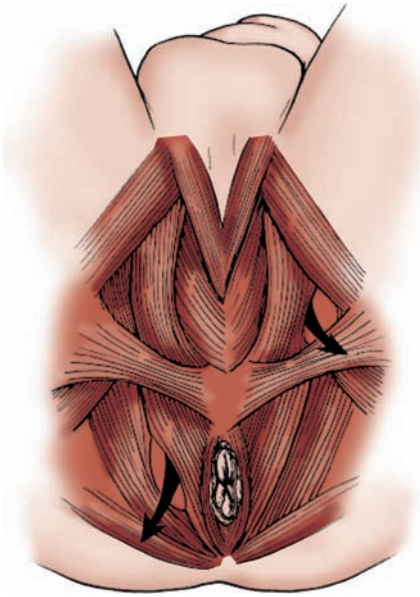
Primary perineal hernias occur in the older population, usually between the fifth and seventh decades of life. They are at least five times more common in women than in men, and this is thought to be associated with the broader pelvic floor in the female and long-term effects of pregnancy and childbirth. Factors that may predispose to a primary perineal hernia include a deep or elongated pouch of Douglas, obesity, chronic ascites, history of pelvic infection, and obstetric trauma.

Postoperative perineal hernia may occur in patients who have undergone abdominoperineal resection or pelvic exenteration. It is thought to form as a result of excision of the levator ani musculature and its surrounding fascia with incomplete repair of the pelvic floor. An excision of the coccyx is thought to be an additional aggravating factor in hernia formation. As in primary perineal hernias, women are affected more often than men. The condition, while more common than the primary perineal hernia, remains rare.

## Anatomy

The pelvic floor is formed by the levator ani and iliococcygeus muscles and their fascia. The pelvic outlet is bounded by the pubic symphysis and the subpubic ligament anteriorly, the pubic rami and ischial tuberosities laterally, and the coccyx and sacrotuberous ligaments posteriorly. The outlet is divided into anterior and posterior divisions by the superficial transversus perinei muscles. The anterior space is termed the urogenital triangle, and the posterior space is termed the ischio-rectal fossa. Anterior and posterior perineal hernias are named according to the location of the hernia defect and subsequent sac protrusion, as shown in Fig. 7-12.





**FIGURE 7-12** The anatomy of the perineal hernia showing the location of both anterior and posterior defects.

The anterior perineal hernia occurs almost exclusively in women. The sac enters in front of the broad ligament and lateral to the bladder, emerging anterior to the transversus perinei musculature. The sac may pass between the ischio-pubic bone and the vagina, thereby producing a swelling in the posterior portion of the labia majus. Posterior perineal hernias are found in both genders but remain more common in women. In men, the hernia sac emerges between the bladder and the rectum to present as a bulge in the perineum. In women, the hernia enters between the rectum and the uterus to pass posteriorly to the broad ligament. In this space, the hernia can push forward to present as a bulge in the posterior vagina or emerge posteriorly into the rectum. The hernia can pass through the levator ani muscle or between it and the iliococcygeus muscle. A lateral pelvic hernia may occur through the hiatus of Schwalbe when the levator ani muscle is not firmly attached to the internal obturator fascia. This type of perineal hernia can present anteriorly in the labium majus or posteriorly in the ischiorectal fossa.

## Clinical Manifestations

The patient with a perineal hernia most often complains of a soft protuberance that is reduced in the recumbent position. In cases of anterior perineal hernia, minor urinary retention or discomfort may be reported. A soft bulge may be noted in the posterior vagina or the labia, thereby interfering with labor or intercourse. In posterior perineal hernias, the patient may describe a mass protruding between the gluteus muscles, thereby making sitting difficult after the hernia has emerged in a standing position. The patient may rarely

complain of constipation or the feeling of incomplete defecation.

In general, symptoms from a perineal hernia are mild, and strangulation is rare since the hernia defect in the pelvic floor is large and surrounded by soft tissue and atrophied musculature. Rectal prolapse may be confused with a posterior perineal hernia, although the two can exist concomitantly. The perineal hernia, even when the defect involves the posterior pelvic floor, will present as a bulge anterior to the prolapsed rectum.

## Treatment

Three options for repair of the perineal hernia exist including the transperitoneal, perineal, and the combined approaches. The transperitoneal approach is the preferred method for complete repair. In this technique, a lower midline abdominal incision is performed and the bowel retracted out of the pelvis with the patient in the Trendelenburg position. A defect in the muscular lining of the pelvic floor will be noted, and any remaining bowel in the defect can usually be easily reduced. The sac is everted and excess sac tissue can be excised. While small defects in the pelvic floor can be closed with interrupted sutures of nylon or polypropylene, this is usually not an adequate repair given the poor strength of the atrophied tissue that often surrounds the hernia defect. Therefore, a repair with a large piece of nonabsorbable mesh is preferred and is usually tacked down to the pelvic floor tissues with interrupted nonabsorbable monofilament sutures.

The perineal approach to hernia repair is more direct and avoids a laparotomy but suffers from inadequate exposure of the actual hernia defect. In this technique, a transverse or longitudinal incision is made directly over the site of the hernia bulge. The sac is identified and dissected free of its attachments to the surrounding pelvic musculature and fascia. The sac is then excised and its contents are reduced within the abdominal cavity. The defect is repaired with interrupted nonabsorbable suture, as the exposure is usually not wide enough for proper placement of mesh. While this approach may be suitable for a small hernia defect in an unhealthy patient, the risk of recurrence is high.

In extraordinary cases in which the hernia contents cannot be reduced during a transperitoneal repair, a combined approach with dissection from the perineum can be considered. The actual repair of the hernia defect should take place from within the abdomen to obtain optimal exposure and facilitate placement of mesh to reinforce the closure.

Postoperative perineal hernia repairs may also be repaired by either a transperitoneal or perineal approach. However, the transperitoneal approach is preferred in this scenario, as the hernia contents may be difficult to completely reduce secondary to postoperative adhesion formation. In addition, given the previous operative dissection, the pelvic floor is already weakened and mesh placement is often necessary to achieve an adequate, tension-free closure of the defect.



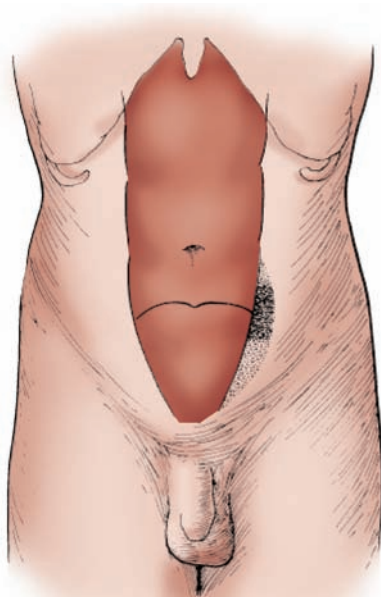
## SPIGELIAN HERNIA

A spigelian hernia occurs along the semilunar line, which traverses a vertical space along the lateral rectus border from the costal margin to the pubic symphysis. Adriaan van der Spieghel (1578–1625), a pupil of Fabricius of Padua and a professor of anatomy and surgery, was the first to accurately describe the semilunar line. He described the spigelian fascia as the aponeurotic structure between the transversus abdominis muscle laterally and the posterior rectus sheath medially. This fascia is what makes up the semilunar line, and it is through this fascial layer that a spigelian hernia forms.

Spigelian hernia is well described, and almost 1000 cases have been reported in the medical literature. It is likely that more of these hernias will be diagnosed, as the spigelian hernia is readily seen on computed tomography scans as well as laparoscopic views of the anterior abdominal wall.

### Anatomy

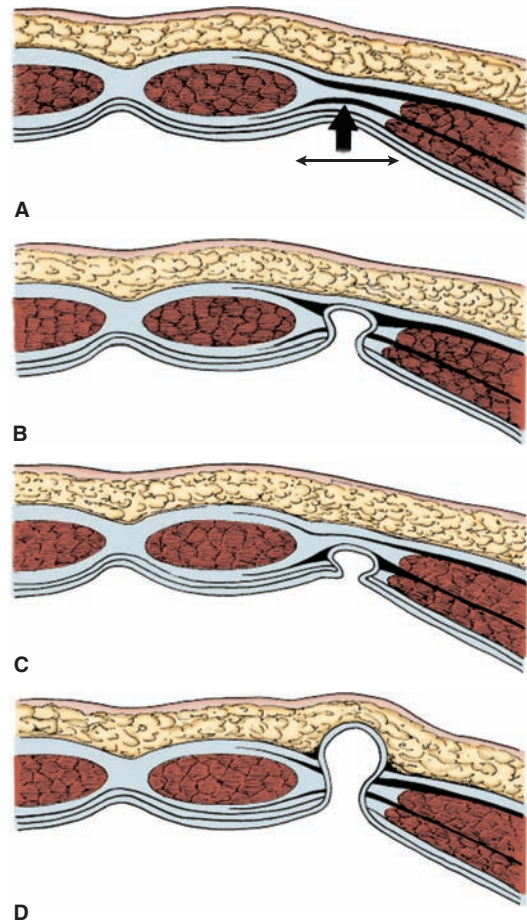
In practice, the semilunar line is taken as the lateral border of the rectus sheath. Spieghel originally intended this structure to represent the line of transition from the muscular fibers of the transversus abdominis muscle to the posterior aponeurosis of the rectus. The semilunar line runs from the ninth rib cartilage superiorly to the pubic tubercle inferiorly. The spigelian fascia varies in width along the semilunar line, and it gets wider as it approaches the umbilicus. The widest portion of the spigelian fascia is the area where the semilunar line intersects the arcuate line of Douglas (the linea semicircularis; Fig. 7-13). It is in this



**FIGURE 7-13** Anatomy of the spigelian hernia and the sites of most common occurrence.

region, between the umbilicus and the arcuate line, where more than 90% of spigelian hernias are found.<sup>37</sup> It is thought that since the spigelian fascia is widest at this point, it is also weakest in this region. Below the arcuate line, all of the transversus abdominis aponeurotic fibers pass anterior to the rectus muscle to contribute to the anterior rectus sheath, and there is no posterior component of the rectus sheath. The rearrangement of muscle and fascial fibers at the intersection of the arcuate and semilunar lines is thought to cause an area of functional weakness that is predisposed to hernia formation. Hernias at the upper extremes of the semilunar line are rare and usually not true spigelian hernias since there is little spigelian fascia in these regions.

As the hernia develops, preperitoneal fat emerges through the defect in the spigelian fascia bringing an extension of the peritoneum with it (Fig. 7-14). The hernia usually meets resistance from the external oblique aponeurosis, which is intact and does not undergo rearrangement of



**FIGURE 7-14** The spigelian hernia. **A.** Breaching the spigelian fascia. **B.** The most common type has passed through the transversus abdominis and the internal oblique aponeuroses and is spreading out in the interstitial layer posterior to the external oblique aponeurosis. **C.** The less common type in the interstitial layer between the transversus abdominis aponeurosis and the internal oblique muscle. **D.** The least common subcutaneous type.

its aponeurotic fibers at the arcuate line. For this reason, almost all spigelian hernias are interparietal in nature, and only rarely will the hernia sac lie in the subcutaneous tissues anterior to the external oblique fascia. This fact makes the accurate diagnosis of spigelian hernias more challenging. The hernia also cannot develop medially due to resistance from the intact rectus muscle and sheath. Therefore, a large spigelian hernia is most often found lateral and inferior to its defect in the space directly posterior to the external oblique muscle.

## Clinical Manifestations

The patient most often presents with a swelling in the middle to lower abdomen just lateral to the rectus muscle. The patient may complain of a sharp pain or tenderness at this site. The hernia is usually reducible in the supine position. However, up to 20% of spigelian hernias will present incarcerated, and for this reason operative repair is mandatory once the hernia is confirmed on diagnosis. The reducible mass may be palpable, even if it sits below the external oblique musculature.

When the diagnosis is unclear, radiologic imaging may be necessary. Ultrasound examination has been shown to be the most reliable and easiest method to assist in the diagnostic workup. Testa and colleagues found that abdominal wall ultrasonography was accurate in 86% of cases of spigelian hernia.<sup>38</sup> If the hernia is fully reduced during examination and no mass is palpable, ultrasound evaluation can show a break in the echogenic shadow of the semilunar line associated with the fascial defect. Ultrasound can also identify the nonreduced hernia sac passing through the defect in the spigelian fascia. Computed tomographic scanning of the abdomen will also confirm the presence of a spigelian hernia. As described above, the anatomy of the spigelian hernia should make it readily apparent on laparoscopic evaluation of the anterior abdominal wall.

## Treatment

The treatment for spigelian hernia is operative repair once the diagnosis has been confirmed, given the risk for incarceration. This is usually performed under general anesthesia given the need for splitting of the external oblique muscle. A transverse incision is made directly over the palpable mass or fascial defect. A hernia in the subcutaneous space will reveal itself immediately, and an interparietal hernia will require further dissection. In this way, the external oblique fascia is incised and the external oblique muscle is split to identify the sac posterior to the muscle. The sac is freed from its surrounding attachments until the neck is isolated. The sac is opened, the intra-abdominal contents reduced, and the sac is either excised if sizable or simply inverted into the intra-abdominal cavity. Suturing the medial and lateral edges of the internal oblique and transversus

abdominis aponeuroses closes the fascial defect. Essentially, this approximates the internal oblique and transversus fascia laterally to the rectus sheath medially. Prosthetic mesh is not required for this repair, although the use of mesh plugs to close the hernia defect has been described.<sup>38</sup> Recurrence is uncommon and the operation is usually well tolerated.

## LUMBAR HERNIA

The lumbar region is bordered by the twelfth rib superiorly, the iliac crest inferiorly, the erector spinae muscles of the back posteriorly, and a vertical line between the anterior tip of the twelfth rib and the iliac crest anteriorly. The region contains two anatomic triangles, through which the rare lumbar hernia can form. The inferior lumbar triangle of Petit is the more common of the two. Its anterior border is the posterior edge of the external oblique muscle, the posterior border is the anterior extent of the latissimus dorsi muscle, and the inferior border is the iliac crest (Fig. 7-15). The anterior floor of the canal formed by this triangle is the lumbar fascia. Occasionally, the lower border of the latissimus dorsi muscle overlaps the external oblique muscle, and in this setting the triangle is absent. The superior lumbar triangle of Grynfeltt (see Fig. 7-15) is deeper and is bounded by the twelfth rib and the serratus posterior inferior muscle, the posterior border of the internal oblique muscle, and by the quadratus lumborum and erector spinae muscles posteriorly. The floor of the superior triangle is composed of transversalis fascia and the entire triangular space is covered posteriorly by the latissimus dorsi muscle.

Congenital lumbar hernias are rare, but case reports can be found in the literature. Lumbar hernias most commonly present in adults older than 50 years of age. Two-thirds of the cases are reported in males, and left-sided hernias are thought to be more common. Bilateral lumbar hernias have been reported. Acquired lumbar hernias have been associated with

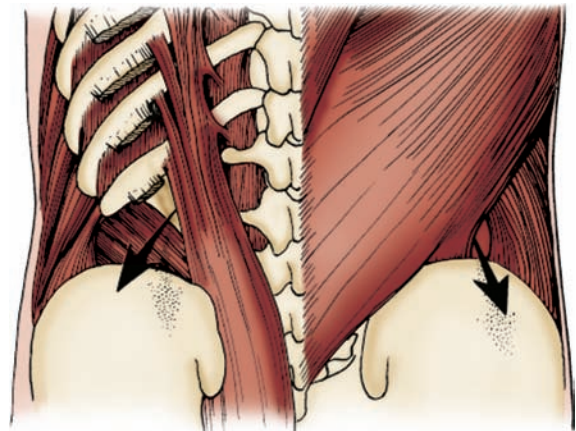

FIGURE 7-15 The anatomy of the lumbar hernia illustrating the superior and inferior lumbar triangles.

back or flank trauma, poliomyelitis, back surgery, and the use of the iliac crest as a donor site for bone grafts.

Strangulation is rare in lumbar hernias since at least two of the three boundaries for the hernia defect are soft and muscular in origin. The hernia tends to increase in size over time and may assume large proportions and overhang the iliac crest. Symptoms range from a vague dullness in the flank or lower back to focal pain associated with movement over the site of the defect. On physical examination, a soft swelling in the lower posterior abdomen will be found that is usually reducible without difficulty. The hernia will increase in size with straining or a standard Valsalva maneuver. Ultrasonographic or computed tomographic imaging is usually obtained in the patient with a suspected lumbar hernia to confirm the diagnosis.

Operative repair of the lumbar hernia is performed with the patient under general anesthesia and in a modified lateral decubitus position. A kidney rest can be used to widen the lumbar space between the twelfth rib and iliac crest. An oblique skin incision is made in the region of the hernia and the sac is identified. The dissection may require takedown of the latissimus dorsi muscle to reach the deeper superior lumbar triangle. Once the sac is identified, it is opened and the contents are carefully reduced. The empty sac can then be inverted or simply excised. While complicated procedures for lumbar hernia closure utilizing muscle flaps and grafts have been described, a small defect surrounded by healthy tissue can usually be closed primarily with an interrupted or continuous layer of nylon or polypropylene suture. If a large defect is found or the tissues appear weak, the hernia may be repaired with a large sheet of prosthetic nonabsorbable mesh placed between the peritoneal layer and the abdominal wall musculature. To prevent migration, the mesh is usually fixed to the peripheral tissues by a series of interrupted nonabsorbable sutures.

Recently, minimally invasive approaches to repair of lumbar hernias have been reported. These involve either intraperitoneal laparoscopy necessitating takedown of the lateral peritoneal reflection of the colon to facilitate exposure of the hernia defect,<sup>39</sup> or retroperitoneoscopy in which the lateral retroperitoneal space is entered and insufflated.<sup>40</sup> Initial results with the minimally invasive approaches are encouraging, although these case series contain small numbers of subjects.

## SCIATIC HERNIA

A sciatic hernia is defined as a protrusion of peritoneum and intra-abdominal contents through the greater or lesser sciatic notch (Fig. 7-16). The greater sciatic notch is traversed by the piriformis muscle, and hernia sacs can protrude either superior or inferior to this muscle. There are classically three variants of the sciatic hernia that are defined by their anatomic site of exit from the pelvis. The suprapiriform defect is by far the most common and is thought to represent 60% of cases of sciatic hernia. Infrapiriform hernias are found in approximately 30% of cases, and subspinous hernias (through the lesser sciatic foramen) occur in 10% of cases.

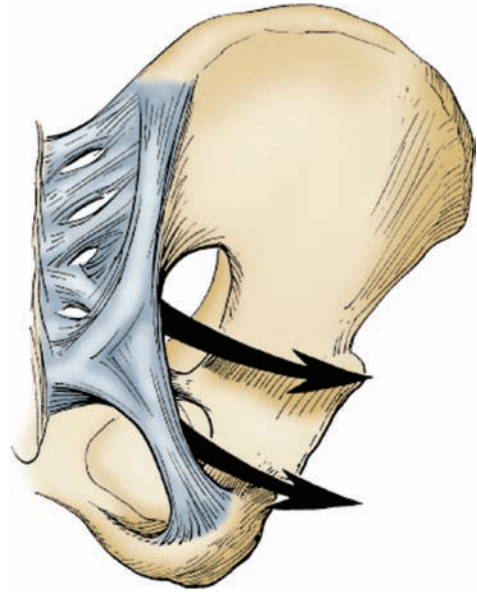


FIGURE 7-16 The superior and inferior sciatic foramina and the direction of sciatic hernias.

The hernia sac passes laterally, inferiorly, and ultimately posteriorly to lie deep to the gluteus maximus muscle. While case reports of this rare hernia exist in the pediatric age group, the majority of sciatic hernias are found in the adult population. The patient complains of pain deep in the buttock that may radiate down the leg in the sciatic nerve distribution. Alternatively, the patient may report a lump in the buttock or infragluteal area that is painful and tender. Rarely, ureteral obstruction occurs because the ipsilateral ureter is contained within the hernia contents. Physical examination often reveals a reducible mass deep to the gluteus maximus, although the actual hernia defect is rarely palpable given the anatomic depth and the thickness of the buttock musculature. Incarceration of the hernia can occur, and sciatic hernia has been known to present with bowel obstruction.

The treatment of a sciatic hernia is surgical. Both transperitoneal and transgluteal approaches have been described in depth, and the transperitoneal technique is preferred in the setting of bowel obstruction or incarceration. Rarely, a combined approach will be necessary to fully reduce the hernia contents. Even in the setting of incarceration, the bowel can usually be reduced from within the hernia with gentle traction. When necessary with the transperitoneal approach, the defect can be dilated with manual manipulation or the piriformis muscle may be partially incised. Full visualization of the structures is necessary and great care must be taken to avoid injury to the many nerves and vessels found in this region. After the sac has been excised, the defect is repaired using interrupted nonabsorbable suture or a prosthetic mesh plug or patch for larger hernia defects.

The posterior or transgluteal technique can be utilized for uncomplicated, reducible sciatic hernias diagnosed preoperatively. With this method the patient is placed in the prone position.



The gluteus maximus muscle is approached through a gluteal incision starting at the posterior edge of the greater trochanter and is detached at its origin to expose the hernia defect. This exposure allows visualization of the piriformis muscle, the gluteal vessels and nerve, and the sciatic nerve. The sac is then isolated and opened. Following reduction of the hernia contents, the defect can be sutured closed using large nonabsorbable suture or repaired with a prosthetic mesh.

## POSTOPERATIVE VENTRAL WALL (INCISIONAL) HERNIA

A postoperative ventral abdominal wall hernia, more commonly termed incisional hernia, is the result of a failure of fascial tissues to heal and close following laparotomy. Such hernias can occur after any type of abdominal wall incision, although the highest incidence is seen with midline and transverse incisions.<sup>41</sup> Postoperative ventral hernias following paramedian, subcostal, McBurney, Pfannenstiel, and flank incisions have also been described in the literature. Laparoscopic port sites may also develop hernia defects in the abdominal wall fascia.

As the approximated fascial tissue separates, the bowel and omentum herniate through the opening, covered by a peritoneal sac. These hernias can increase in size to enormous proportions, and giant ventral hernias can contain a significant amount of small or large bowel. At the extreme end of the ventral hernia spectrum is the giant incisional hernia that leads to loss of the abdominal domain, which occurs when the intra-abdominal contents can no longer lie within the abdominal cavity.

### Incidence and Etiology

Incisional hernias have been reported in up to 20% of patients undergoing laparotomy. Modern rates of incisional hernia range from 2% to 11%.<sup>42–44</sup> It is estimated that approximately 100,000 ventral incisional hernia repairs are performed each year in the United States alone. The incidence seems to be lower in smaller incisions so that laparoscopic port site hernias are much less common than hernias following large midline abdominal incisions. While it was once believed that the majority of incisional hernias presented within the first 12 months following laparotomy, longer-term data indicate that at least one-third of these hernias will present 5–10 years postoperatively.

Multiple risk factors exist for the development of an incisional hernia. Some of these risks are under the control of the surgeon at the initial operation, while many others are patient specific or related to postoperative complications. Patient-specific risks for postoperative ventral hernia include advanced age, malnutrition, presence of ascites, corticosteroid use, diabetes mellitus, cigarette smoking, and obesity.<sup>41,45–47</sup> Emergency surgery is known to increase the risk of incisional

hernia formation. Wound infection is believed to be one of the most significant prognostic risk factors for development of an incisional hernia.<sup>41,48</sup> It is for this reason that many surgeons advocate aggressive and early opening of the skin closure to drain any potential infection at the fascial level. Postoperative sepsis has also been identified as a risk for subsequent incisional hernia.

Technical aspects of wound closure likely contribute to incisional hernia formation. Wounds closed under excessive tension are prone to fascial closure disturbance. Therefore, a continuous closure is advocated to disperse the tension throughout the length of the wound. In this way, 1 cm bites of fascia on either side of the incision are taken with each pass of the suture and the suture is advanced 1 cm at a time along the length of the incision. The type of incision may affect hernia formation. Studies have shown that transverse incisions are associated with a reduced incidence of incisional hernia compared to midline vertical laparotomies, although the data are far from conclusive.<sup>46,49</sup>

### Clinical Manifestations

The patient with an incisional hernia will complain of a bulge in the abdominal wall originating deep to the skin scar. The bulge may cause varying degrees of discomfort or may present as a cosmetic concern. Symptoms will usually be aggravated by coughing or straining as the hernia contents protrude through the abdominal wall defect. In large ventral hernias, the skin may present with ischemic or pressure necrosis leading to frank ulceration. Presentation of the incisional hernia with incarceration causing bowel obstruction is not uncommon. This may be associated with a history of repeated mild attacks of colicky dull abdominal pain and nausea consistent with incomplete bowel obstruction.

On examination the hernia is usually easy to identify and the edges of the fascial defect can often be defined by palpation. The entire abdominal wall along the length of the incision should be inspected and palpated carefully, as multiple hernias are often present in the setting of an incisional hernia. In the obese patient with a suspected incisional hernia that cannot be confirmed on examination, computed tomography of the abdomen is the best way to visualize intra-abdominal contents within the hernia sac. In extreme instances, laparoscopy may be required to diagnose a hernia defect that only intermittently contains intra-abdominal contents.

### Treatment

The treatment of ventral incisional hernia is operative repair, and three general classes of operative repair have emerged in the modern era. These techniques include primary suture repair of the hernia, open repair of the hernia with prosthetic mesh, and laparoscopic incisional hernia repair. The major sequela from operative repair of the incisional hernia is hernia



recurrence, and there are convincing data that placement of mesh to repair the hernia defect has decreased the high recurrence rate historically associated with primary suture repair to less than 25%.<sup>50,51</sup> Many advocates of the operation believe that laparoscopic incisional hernia repair will have the lowest rate of hernia recurrence and definitive studies are underway to assess this question.

In general, primary repair of incisional hernias can be performed for hernia defects less than 4 cm in diameter with strong, viable surrounding tissue. For larger hernias or hernias associated with multiple small defects, mesh repair is indicated. Even with mesh repair, hernia recurrence remains a significant complication. In one multicenter trial, for example, 200 patients were randomly assigned to suture or mesh repair of a primary hernia or a first recurrence of hernia at the site of a vertical midline incision.<sup>52</sup> The 3-year cumulative rates of recurrence among patients who had suture or mesh for repair of a primary hernia were 43% and 24%, respectively. The rates of second recurrence were 58% and 20%, respectively.

### PRIMARY SUTURE REPAIR

The operation is best performed with the patient under general anesthesia to achieve full relaxation of the abdominal wall musculature. The skin is opened through the previous incision and dissection is performed through the subcutaneous tissues. Care should be taken as the level of the anterior rectus sheath is approached since portions of the sac and its contents may lie at this level. The sac is identified and cleared of its attachments to the fascia using electrocautery. In this way, any peritoneal attachments to the anterior abdominal wall in the vicinity of the hernia are taken down and the sac is fully reduced into the abdominal cavity. The fascia is then cleared of soft tissue both anteriorly and posteriorly for at least a 3–4 cm margin. This allows for a margin of healthy fascia to bring together in the midline with suture closure.

The fascia is then closed using an interrupted layer of nonabsorbable suture by taking large bites of the clean fascia on both sides of the defect. The sutures are usually placed sequentially and then tied after the entire layer of suture has been placed. The fascia is then inspected to confirm that no additional defects are present and that the repair sutures are not pulling through the tissue due to excessive tension. The skin is closed over the fascia using either staples or a running subcuticular layer. If the hernia contents have created a large pocket in the soft tissue above the anterior fascia, placement of a closed suction drain for evacuation of early seroma fluid can be considered.

If there is tension upon attempted closure of the abdominal wall, a separation of components can be performed in order to mobilize the fascia toward the midline (Fig. 7-17). This technique begins with the mobilization of the skin and soft tissue off of the underlying fascia. The fascia of the external oblique is then incised lateral to the rectus abdominis and the external oblique is dissected free from the internal oblique in a relatively avascular plane. This alone allows for significant mobilization of the abdominal wall toward

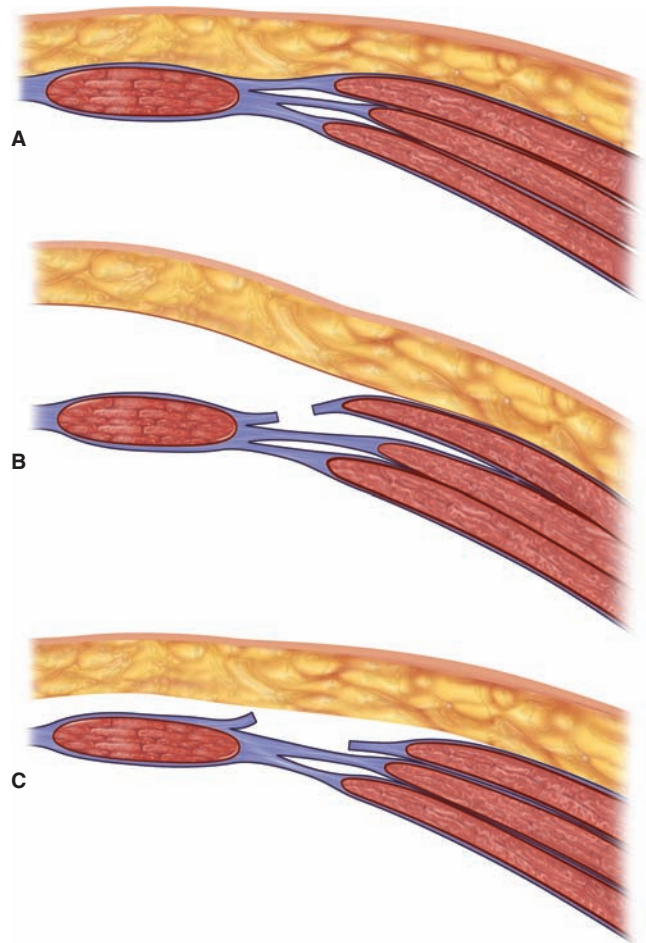


FIGURE 7-17 Separation of components of the abdominal wall to mobilize the fascia toward the midline.

the midline. Should additional mobilization be required, the posterior rectus sheath can be incised in a longitudinal fashion to allow the overlying rectus abdominis and anterior rectus sheath to slide even further toward the midline.<sup>53</sup> This technique allows for closure of complex or infected abdominal wounds without the need for implantation of any foreign material.

Over the last 10–15 years, the introduction of component separation as a method for repairing ventral hernias has gained increasing popularity due to its conceptual purity and its overwhelming success. Recent series including those by Ko<sup>54</sup> has reported his experience in 200 patients who underwent this procedure over the course of slightly over 1 decade. The overall recurrence rate was 21%. Supportive polypropylene mesh was employed to cover the defect. In the process of performing this procedure, bilateral releases of the external oblique muscle are performed and the fascia is mobilized, thereby allowing medial movement of the rectus muscle. This brings the rectus muscle closer to the midline and achieves a muscular closure of the midline which can be reinforced or strengthened by the placement of either biologic or

manufactured mesh. Mesh is not a necessary portion of the component separation technique although it is frequently used. The variety of different types of mesh includes polypropylene, polyester, and other both biologic and nonbiologic materials. Primary repair using no mesh but using the component separation technique had a 22.5% recurrence rate, while recurrence rates using cadaveric biomesh were 33.3%. Those in whom low-weight polypropylene was used had a 0% recurrence rate. Part of the study looked at demographic factors and noted that elevated body mass had a significant risk of recurrence. This was true at less than a  $p$  value of 0.005 and also notable most commonly in patients with a BMI of greater than 25.

## MESH REPAIR

The use of sheets of nonabsorbable prosthetic mesh placed across the incisional hernia defect and sutured to the abdominal wall is routinely employed in the modern era. It is associated with a low incidence of perioperative complications and lower rates of recurrence than open, nonmesh repairs.

Many variations of mesh repair for the incisional hernia have been described (Fig. 7-18). The mesh is cut to the shape of the hernia defect with a margin added circumferentially around the mesh to suture to healthy surrounding fascia. The mesh is sutured to the fascial layer either deep to the peritoneum or between the peritoneum and the abdominal wall. Alternative techniques have been described that suture pieces of mesh to fascia from both intra- and extraperitoneal planes.

The operation is performed under general anesthesia. The old scar is incised and the soft tissue dissected down to the level of the anterior rectus sheath. Here the defect is identified and the fascia is cleared of surrounding soft tissue attachments to allow a 3–4 cm rim of healthy fascia circumferentially. The sac is then freed from the fascia in order to reduce the hernia contents and prevent recurrence. This portion of the operation is often technically challenging, as significant adhesion formation may have occurred following the initial operation. It is often impossible to stay in an extraperitoneal plane in this situation, and dissection within the abdominal cavity may be necessary to fully excise the sac and reduce its contents. The mesh can now be placed either anterior to the fascia or posterior from within the intra-abdominal cavity. Effort should be made to protect the bowel from direct contact with the mesh patch, and a layer of omentum can often be placed between them. The mesh is sutured in an interrupted fashion in multiple sites throughout the entire circumference of the patch to ensure that any tension is distributed throughout the entire area of the repair. Large, nonabsorbable suture is used to affix the mesh to the fascia layer.

There are currently a variety of mesh products readily available for use in the repair of ventral incisional hernias. In general, these products can be grouped into those that are composed of synthetic materials and those that are composed of biologic materials. The synthetic meshes frequently incorporate either polypropylene or expanded polyfluorotetraethylene

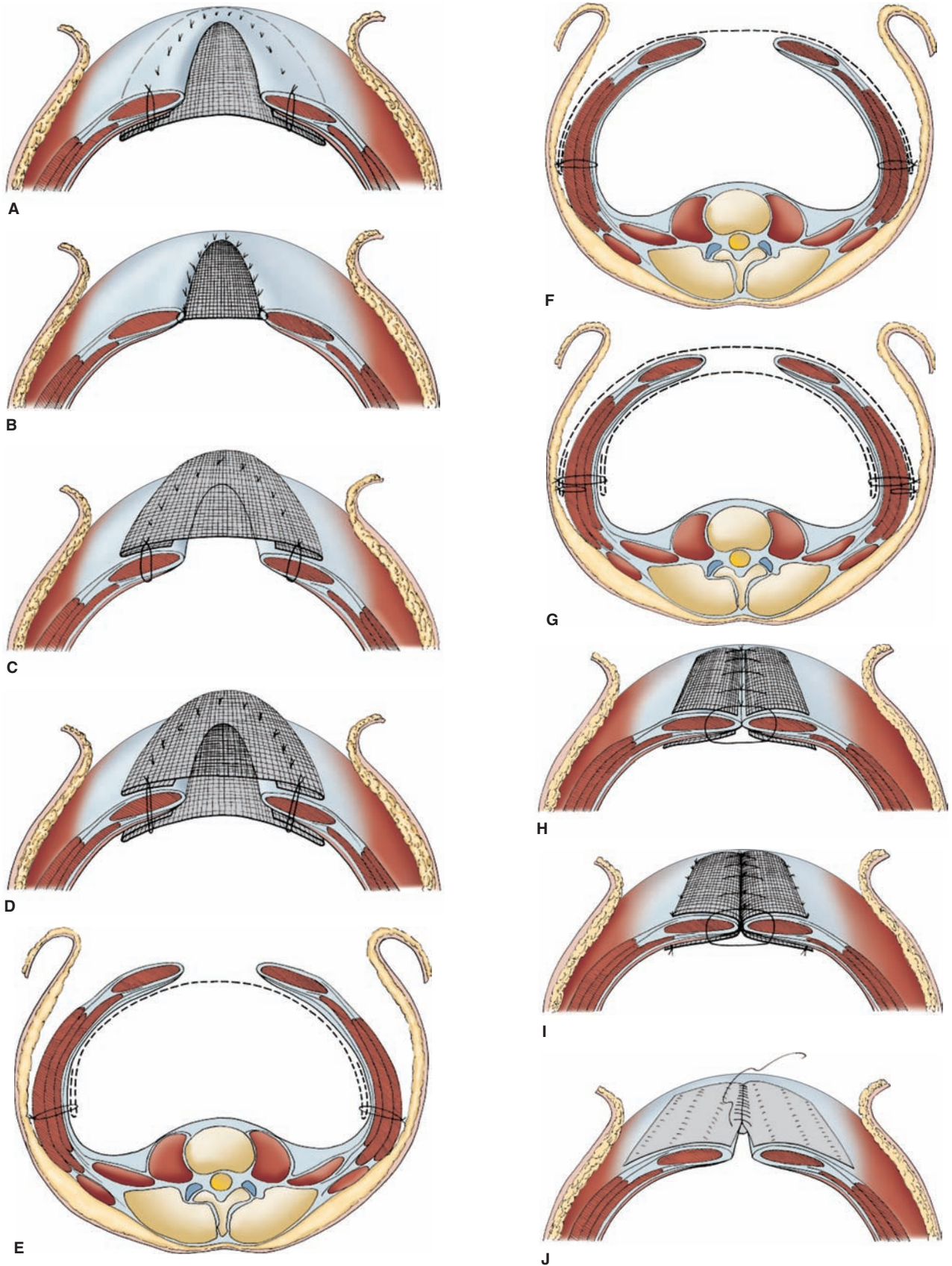
(ePTFE) in combination with some form of barrier to prevent adhesions to the bowel. While both polypropylene and ePTFE are used in the treatment of ventral hernias, they have significantly different properties. Polypropylene meshes are macroporous and allow for ingrowth of native tissue into the mesh, leading to incorporation. Conversely, ePTFE meshes are more microporous and do not promote as much ingrowth. This leads to less adhesions to ePTFE meshes, but also requires that there is adequate fixation in order to prevent disruption and thus recurrence. Biologic meshes are based on acellular dermal matrices from human, porcine, and fetal bovine sources. While the long-term outcomes for these meshes are currently being studied, the biologic meshes have been shown to be more resistant to infection than their synthetic predecessors and are more appropriate for use in infected or contaminated fields.<sup>55</sup>

Biologic grafts derive from two basic materials. The first is human tissue and the second is animal tissue. Their use in hernias is confined primarily to dirty or contaminated fields in which placement of a prosthetic mesh might increase the chance of infection. It is well recognized that primary closure of incisional hernias carries a high recurrence rate and that removal of prosthetic mesh in an infected field and attempts to primarily close these defects will invariably lead to recurrence. As a result, enthusiasm has recently grown for the use of biologic grafts that may enhance the repair, decrease the chances of infection, and provide a bridge to a clean wound. If recurrence subsequently develops, it can be managed with a prosthetic material. The biologic grafts have different characteristics depending on the tissue of origin. Grafts can be based on dermis, either human or porcine, or on submucosa. The dermis-based grafts are prepared in such a way as to allow collagen and elastin to remain within the matrix. Although these materials have excellent resistance to infection, they do have the distinct disadvantage of weakening over time because of elastin breakdown. This can lead to evisceration, recurrence, or the possibility of pseudorecurrence, which can occur as a result of the weakening of the elastin, increased compliance, and softening of the graft. Methods that are utilized to improve the durability of these grafts are the use of glutaraldehyde and hexamethylene diisocyanate, cross-linking agents which make the material, whether it is human or porcine, more resistant to breakdown by enzymatic degradation. This leads not only to greater durability but also to increasing the susceptibility of these grafts to microbiologic attack. Cross-linking limits the ability of the host to incorporate the graft and make it essentially a part of the native tissue.

## LAPAROSCOPIC REPAIR

The evolution of ventral hernia repair has advanced from open mesh repair to the application of mesh repair to the laparoscopic approach. In this technique, the defect is repaired posteriorly and no dissection within the scarred layer of anterior fascia is required. The laparoscopic approach may also allow for identification of additional hernia defects in the anterior abdominal wall during the repair.





**FIGURE 7-18** Variations of prosthetic mesh repair for incisional hernia. **A.** Underlay graft. **B.** Inlay graft. **C.** Overlay graft. **D.** Combined overlay and underlay grafts. **E.** Large underlay graft. **F.** Large overlay graft. **G.** Combined large overlay and underlay grafts. **H.** Reinforcing onlay and underlay strips of mesh. **I.** Wrap-around mesh reinforcement of wound edges. **J.** Two sheets of mesh sutured to abdominal wall, then sutured to each other to draw together the edges of the wound.

One of the challenging aspects of laparoscopic repair is port access into a peritoneal cavity that has been previously operated upon. In general, access can be obtained for needle insufflation via the left upper quadrant, placing the port along the anterior axillary line to avoid injury to the more laterally positioned spleen. Once insufflation has been achieved and instruments have been inserted, the next challenge is the extensive laparoscopic lysis of adhesions that is often necessary to gain exposure to the entire hernia defect. The goal of the adhesiolysis is to provide a 3–4 cm circumferential area of overlap for the mesh patch beyond the edge of the ventral hernia defect.

After the appropriate adhesions have been taken down and the fascial edges of the defect confirmed, the sac is retracted and excised from within the hernia. The outline of the defect is then drawn on the anterior abdominal wall. Edges of the defect at the skin level can be confirmed from within the abdominal cavity using the laparoscope. The mesh is then cut to fit this defect with a margin of 3–4 cm on each side to provide adequate coverage and to minimize tension. Nonabsorbable sutures are placed around the circumference of the mesh and tied, but not cut. The mesh is rolled so that the anterior surface lies inside the roll, and the mesh is inserted into the abdomen through a large 10- or 12-mm port.

Once inside the abdominal cavity, the mesh is unrolled and positioned. A transfascial suture passer can be introduced through small stab incisions placed around the marked border of the defect. The suture passer retrieves the long ends of the suture that has been previously placed in the mesh, and the ends are tied at the skin level at 4–6 points around the repair and buried with the subcutaneous tissue in the stab incision. This affixes the mesh patch to the fascia layers around the circumference of the patch. After all sutures have been tied and cut, laparoscopically placed tacks or staples can be used to further fasten the mesh to the anterior abdominal wall. Whether the strength of the repair is imparted by the transfascial sutures or the tacks or both remains controversial.

## Complications

The major complication from open, nonmesh incisional hernia repair is recurrence. Rates of recurrence in this type of repair have approached 30–50% in some series. The risk of recurrence is likely related to the tension placed on the repair in large hernias, and for this reason, incisional hernias with a diameter greater than 4 cm should be repaired with mesh.

Open incisional hernia repairs using mesh can also suffer from hernia recurrence, although the risk is far less than that of the nonmesh technique. Several studies have shown that the risk of recurrence in incisional hernia repair with mesh is approximately 10%. Recurrence in this setting is usually secondary to the appearance of an additional, unrecognized hernia site or an improperly placed prosthesis that pulls away from the fascia edge of the repair. Hematoma or seroma formation may occur in the cavity left behind following a hernia repair. For this reason, closed suction drains may be placed if a

large amount of dead space remains following the repair. The drains should be managed judiciously, however, since they may be placed in proximity to the prosthetic mesh, thereby increasing the chance of secondary infection. Wound infection and infection of the mesh can be grave complications, often necessitating removal of the mesh and application of an allogenic tissue graft. Wound infection in open mesh repairs is thought to approximate 5%.

The laparoscopic approach to incisional hernia repair shares the general complications of laparoscopy, including the potential for port-site herniation, vascular injury from trocar placement, and inadvertent bowel injury during laparoscopic adhesiolysis. The mesh placed during laparoscopic repair can also be prone to infection, although the incidence of mesh infection appears to be lower in laparoscopic than open mesh techniques. This may be related to the extensive tissue dissection required to place the mesh in the open procedure. Several nonrandomized studies have shown that the laparoscopic approach is associated with a low incidence of hernia recurrence, in the range of 0–11%.<sup>56</sup> Seroma formation in the retained sac above the mesh may occur but usually resolves spontaneously.

There are numerous prospective studies that provide data for the individual techniques, but data are scarce in the comparison between open and laparoscopic mesh repairs for incisional hernia. Nonrandomized, retrospective studies have provided ample evidence that the laparoscopic approach is associated with fewer postoperative complications, a lower incidence of wound and mesh infections, a lower rate of recurrence in long-term follow-up, and shorter in-hospital stays.<sup>57</sup> A recent meta-analysis pooled results from five separate randomized controlled trials comparing laparoscopic and open incisional hernia repairs.<sup>58</sup> The authors found no significant differences in recurrence rates between the two groups, but the open repair was associated with significantly longer length of stay and postoperative complications compared to the laparoscopic group. Clearly, more studies are required to definitively determine which procedure is optimal; however, at this time both open and laparoscopic techniques appear to be safe and effective in the treatment of incisional hernias.

## REFERENCES

1. Rutkow IM, Robbins AW. Demographic, classificatory, and socioeconomic aspects of hernia repair in the United States. *Surg Clin North Am.* 1993;73:413.
2. Bassini E. *Nouvo Metodo per la Cura Radicale dell'Ernia Inguinale*. Padua, Italy: Prosperini; 1889.
3. McIntosh A, Hutchinson A, Roberts A, et al. Evidence-based management of groin hernia in primary care—a systematic review. *Fam Pract.* 2000;17:442.
4. Schumpelick V, Treutner KH, Arlt G. Inguinal hernia repair in adults. *Lancet.* 1994;344:375.
5. Kang SK, Burnett CA, Freund E, et al. Hernia: is it a work-related condition? *Am J Ind Med.* 1999;36:638.
6. Young DV. Comparison of local, spinal, and general anesthesia for inguinal herniorrhaphy. *Am J Surg.* 1987;153:560.
7. Nordin P, Zetterstrom H, Gunnarsson U, et al. Local, regional, or general anaesthesia in groin hernia repair: multicentre randomised trial. *Lancet.* 2003;362:853.



8. Shouldice EE. The treatment of hernia. *Ontario Med Rev.* 1953;20:670.
9. Simons MP, Kleijnen J, van Geldere D, et al. Role of the Shouldice technique in inguinal hernia repair: a systematic review of controlled trials and a meta-analysis. *Br J Surg.* 1996;83:734.
10. Shouldice EB. The Shouldice repair for groin hernias. *Surg Clin North Am.* 2003;83:1163.
11. Klingsworth AN, Britton BJ, Morris PJ. Recurrent inguinal hernia after local anesthetic repair. *Br J Surg.* 1982;68:273.
12. Amato B, Moja L, Panico S, et al. Shouldice technique versus other open techniques for inguinal hernia repair. *Cochrane Database of Syst Rev.* 2009;(4):CD001543.
13. Lichtenstein IL, Shulman AG, Amid PK. The cause, prevention, and treatment of recurrent groin hernia. *Surg Clin North Am.* 1993;73:529.
14. Gilbert AI. An anatomic and functional classification for the diagnosis and treatment of inguinal hernia. *Am J Surg.* 1989;157:331.
15. Rutkow IM, Robbins AW. "Tension-free" inguinal herniorrhaphy: a preliminary report on the mesh plug technique. *Surgery.* 1993;114:3.
16. Scott NW, Webb K, Go PM, et al. Open mesh versus non-mesh repair of inguinal hernia. *Cochrane Database Syst Rev.* 2001;(4):CD002197.
17. Bay-Nielsen M, Kehlet H, Strand L, et al. Quality assessment of 26,304 hernioplasties in Denmark: a prospective nationwide study. *Lancet.* 2001;358:1124.
18. Rives J. Major incisional hernias. In: Chevrel JR, ed. *Surgery of the Abdominal Wall.* New York, NY: Springer-Verlag; 1987:116.
19. Vader VL, Vogt DM, Zucker KA, et al. Adhesion formation in laparoscopic inguinal hernia repair. *Surg Endosc.* 1997;11:825.
20. Ferzli G, Sayad P, Huie F, et al. Endoscopic extraperitoneal herniorrhaphy: a 5-year experience. *Surg Endosc.* 1998;12:1311.
21. Wake B, McCormack K, Fraser C, et al. Transabdominal pre-peritoneal (TAPP) versus totally extraperitoneal (TEP) laparoscopic techniques for inguinal hernia repair. *Cochrane Database Syst Rev.* 2005;(1):CD004703.
22. Memon MA, Cooper NJ, Memon B, et al. Meta-analysis of randomized clinical trials comparing open and laparoscopic inguinal hernia repair. *Br J Surg.* 2003;90:1479.
23. Collaboration EH. Laparoscopic compared with open methods of groin hernia repair: systematic review of randomized controlled trials. *Br J Surg.* 2000;87:860.
24. Neumayer L, Giobbie-Hurder A, Jonasson O, et al. Open mesh versus laparoscopic mesh repair of inguinal hernia. *N Engl J Med.* 2004;350:1819.
25. Eklund AS, Montgomery AK, Rasmussen IC, et al. Low recurrence rate after laparoscopic (TEP) and open (Lichtenstein) inguinal hernia repair. *Ann Surg.* 2009;249:33.
26. Neumayer LA, Gawande AA, Wang J, et al. Proficiency of surgeons in inguinal hernia repair: effect of experience and age. *Ann Surg.* 2005;242:344.
27. Read RC. A review: the role of protease-antiprotease imbalance in the pathogenesis of herniation and abdominal aortic aneurysm in certain smokers. *Postgrad Gen Surg.* 1992;4:161.
28. Gilbert AI, Felton LL. Infection in inguinal hernia repair considering biomaterials and antibiotics. *Surg Gynecol Obstet.* 1993;177:126.
29. Tverskoy M, Cozacov C, Ayache M, et al. Postoperative pain after inguinal herniorrhaphy with different types of anesthesia. *Anesth Analg.* 1990;70:29.
30. Gallegos NC, Dawson J, Jarvis M, Hobsley M. Risk of strangulation in groin hernias. *Br J Surg.* 1991;78:1171.
31. Corder AP. The diagnosis of femoral hernia. *Postgrad Med J.* 1992;68:26.
32. Lichtenstein IL, Shore JM. Simplified repair of femoral and recurrent inguinal hernia by a "plug" technique. *Am J Surg.* 1974;128:439.
33. Mayo WJ. An operation for the radical cure of umbilical hernia. *Ann Surg.* 1901;31:276.
34. Kammori M, Mafune K, Kirashima T, et al. Forty-three cases of obturator hernia. *Am J Surg.* 2004;187:549.
35. Skandalakis JE. Obturator hernia. In: Skandalakis JE, Gray SW, Mansberger AR, et al, eds. *Hernia Surgical Anatomy and Technique.* New York, NY: McGraw-Hill; 1989:174.
36. Tucker JG, Wilson RA, Ramshaw BJ, et al. Laparoscopic herniorrhaphy: technical concerns in prevention of complications and early recurrence. *Am Surg.* 1995;61:36.
37. Montes IS, Deysine M. Spigelian and other uncommon hernia repairs. *Surg Clin North Am.* 2003;83:1235.
38. Testa T, Fallo E, Celoria G, et al. Spigelian hernia: its echotomographic diagnosis and surgical treatment. *G Chir.* 1992;13:29.
39. Sakarya A, Ayded H, Erhan MY, et al. Laparoscopic repair of acquired lumbar hernia. *Surg Endosc.* 2003;17:1494.
40. Habib E. Retroperitoneoscopic tension-free repair of lumbar hernia. *Hernia.* 2003;7:150.
41. Bucknall TE, Cox PJ, Ellis H. Burst abdomen and incisional hernia: a prospective study of 1129 major laparotomies. *Br Med J.* 1982;284:931.
42. Santora TA, Rosalyn JJ. Incisional hernia. *Surg Clin North Am.* 1993;73:557.
43. Mudge M, Hughes LE. Incisional hernia: a 10 year prospective study of incidence and attitudes. *Br J Surg.* 1985;72:70.
44. Regnard JF, Hay JM, Rea S. Ventral incisional hernias: incidence, date of recurrence, localization, and risk factors. *Ital J Surg Sci.* 1988;3:259.
45. Read RC, Yoder G. Recent trends in the management of incisional herniation. *Arch Surg.* 1989;124:485.
46. Greenall MJ, Evans M, Pollack AV. Midline or transverse laparotomy? A random controlled clinical trial. Part I: influence on healing. *Br J Surg.* 1980;67:188.
47. Makela JT, Kiviniemi H, Juvonen T, et al. Factors influencing wound dehiscence after midline laparotomy. *Am J Surg.* 1995;170:387.
48. Gys T, Hubens A. A prospective comparative clinical study between monofilament absorbable and non-absorbable sutures for abdominal wall closure. *Acta Chir Belg.* 1989;89:265.
49. Carlson MA, Ludwig KA, Condon RE. Ventral hernia and other complications of 1,000 midline incisions. *South Med J.* 1995;88:450.
50. Millikan KW, Baptista M, Amin B, et al. Intraperitoneal underlay ventral hernia repair utilizing bilayer ePTFE and polypropylene mesh. *Am Surg.* 2003;69:258.
51. McLanahan D, King LT, Weems C, et al. Retrorectus prosthetic mesh repair of midline abdominal hernia. *Am J Surg.* 1997;173:445.
52. Luijendijk RW, Hop WC, van den Tol MP, et al. A comparison of suture repair with mesh repair for incisional hernia. *N Engl J Med.* 2000;343:292.
53. Ramirez OM, Ruas E, Dellon AL. "Components separation" method for closure of abdominal-wall defects: an anatomic and clinical study. *Plast Reconstr Surg.* 1990;86:519.
54. Ko JH, Wang EC, Salvay DM, Paul BC, Dumanian GA. *Arch Surg.* 2009;144:1047-1055.
55. Bachman S, Ramshaw, B. Prosthetic material in ventral hernia repair: how do I choose? *Surg Clin N Am.* 2008;88:101.
56. Thoman DS, Phillips ES. Current status of laparoscopic ventral hernia repair. *Surg Endosc.* 2002;16:939.
57. Cobb WS, Kercher KW, Heniford BT. Laparoscopic repair of incisional hernias. *Surg Clin North Am.* 2005;85:91.
58. Muhammad SS, Bokhari SA, Mallick AS, et al. Laparoscopic versus open repair of incisional/ventral hernia: a meta-analysis. *Am Jour Surg.* 2009;197:64.

*This page intentionally left blank*

# PERSPECTIVE ON HERNIAS: LAPAROSCOPIC INCISIONAL HERNIA

Alex Escalona • David W. Rattner

## INTRODUCTION

Incisional hernias are an all too frequent complication of laparotomies and surgeons spend a significant part of their practice repairing such defects. Leblanc and Booth published the first report of laparoscopic incisional hernia repair in 1993.<sup>1</sup> Over the course of time, this approach has gained popularity with patients who seek a “minimally invasive” solution to their hernia problem and with surgeons who believe that the laparoscopic approach offers advantages over traditional repairs.

After nearly two decades of experience with laparoscopic incisional hernia repair, there is a surprising paucity of good data clearly proving the benefits of this technique over standard open surgery. In this chapter, we will review the published experience, technical factors needed for successful laparoscopic repairs, the costs, and long-term results of laparoscopic ventral hernia repair (LVH). Since most ventral hernias are small and easy to repair primarily, we will focus on incisional hernias and use the term LVH to cover both types of defect.

## RATIONALE FOR LAPAROSCOPIC VENTRAL HERNIA REPAIR

Although the pioneers of LVH felt that this approach would be less invasive and therefore less painful than traditional surgery, many other advantages became apparent as the procedure was developed. Traditional incisional hernia repairs—even when performed with mesh—have a relatively high failure rate. Some of the failures are due to patient-related factors such as obesity, steroid use, tobacco abuse, or abdominal stressors such as chronic cough. However, one of the most common technical causes of failure is failure to identify all fascial defects. Many incisional hernias have multiple components, some of which are not apparent on physical examination. If a surgeon fails to

repair all the defects, failure (occasionally described as a new hernia defect in proximity to the prior repair) is almost certain to occur. LVH offers a superior view of the fascial defect and hence reduces the likelihood that a surgeon will fail to identify the extent of the problem that needs to be fixed. This is particularly helpful when the fascia is attenuated. An additional advantage is gained in patients who have undergone surgery for abdominal neoplasms in that peritoneoscopy may occasionally discover signs of recurrent disease. Finally, in patients whose incisions are deeply scarred, approaching the defect transperitoneally can avoid a tedious dissection of the subcutaneous layers. Likewise, if a patient has had a prior wound infection, the transperitoneal approach delivers the mesh prosthesis through a clean field and may reduce the risk of recurrent infection.

There are disadvantages of LVH that need to be considered when recommending treatment to a patient. Since very little is done to the subcutaneous tissue, LVH often leaves a large dead space that can result in a seroma. Even if seroma formation is prevented, excess skin and fat can lead to a poor cosmetic outcome following repair of large defects. Some patients in whom LVH is attempted may have severe adhesions necessitating a tedious and occasionally hazardous adhesiolysis. Inadvertent bowel injury is probably the leading cause of mesh infection in LVH and can be a devastating complication if it is not recognized and repaired promptly. Lastly, some locations in the abdomen preclude transfascial fixation of the mesh and hence may be more prone to failure of the repair than when the defect is centrally located (Table 8A-1).

## TECHNIQUE

It is well established that the use of prosthetic mesh reduces the rate of long-term recurrence in open incisional hernia repairs compared with suture repair alone.<sup>2,3</sup> Although suture hernioplasty has been described in laparoscopic surgery, it is technically more difficult than mesh hernia repair and violates


**TABLE 8A-1: PROS AND CONS OF LAPAROSCOPIC VENTRAL HERNIA REPAIR**
**Pros**

Accurately identifies all fascial defects  
 May identify unsuspected intraperitoneal pathology  
 Approaches fascia through a “clean field”

**Cons**

Not possible to revise contour of abdominal wall  
 Adhesiolysis may be difficult with increase potential for enterotomy  
 Hard to get good fixation for defects at margins of abdominal cavity

the principle of a tension-free technique.<sup>4</sup> Therefore, laparoscopic hernia repair is almost uniformly performed with a mesh prosthesis.

In LVH, the mesh is placed in direct contact with the viscera. As in open inlay repairs, this carries the risk of development of chronic inflammation, fistula, infection, and mesh migration.<sup>5</sup> To minimize these risks, dual-sided mesh prostheses have been developed and should be utilized in LVH. These implants are coated with materials designed to prevent adhesion formation on the side exposed to the viscera. Animal studies have demonstrated good short-term results; nevertheless, there are few human studies evaluating long-term results that compare different types of mesh.<sup>6,7</sup>

Both open repair and LVH require clear identification of the hernia defect to place and fix the mesh properly. LVH replaces a large incision and an extensive dissection of the subcutaneous tissue with adhesiolysis, peritoneal dissection, and intra-abdominal reduction of the contents of the hernia sac. Paradoxically this minimally invasive approach may be more invasive than an open repair because of the extent of peritoneal and visceral trauma. This paradox may explain in part the limited advantage (if any) of LVH in reducing postoperative pain.<sup>8,9</sup> Indeed, in most of the randomized controlled trials (RCTs) and meta-analyses where postoperative pain and/or quality of life were evaluated, no significant differences between open repair and LVH were identified.<sup>10,11</sup> Different techniques of laparoscopic mesh fixation have also been evaluated with no significant differences in postoperative pain or quality of life.<sup>12</sup>

When extensive intra-abdominal dissection is required in the laparoscopic approach to access and/or identify the defect and place the mesh, it almost certainly accounts for the higher number of bowel injuries observed in laparoscopic technique compared with open surgery.<sup>8,10,13,14</sup> In LeBlanc's 2007 review article, the overall incidence of enterotomy secondary to incisional and ventral hernia repairs was 1.78% (72 out of 3925 patients). Patients who sustained this complication had an increase in mortality rate compared with those who did not have an enterotomy from 0.05% to 2.8%.<sup>15</sup>

As with any new procedure, the learning curve needs to be surmounted. A common mistake a novice surgeon is apt to make is failure to get adequate overlap of the mesh with normal tissue in covering the defect. While adhesiolysis can be performed at typical pneumoperitoneum pressures of 15 mm Hg, sizing the mesh should be done with the abdomen nearly deflated. If the mesh is measured with the abdomen fully distended, it will be lax once the pneumoperitoneum is released and patients may feel as if their hernia was never fixed! As Brooks et al point out in their chapter, transfascial fixation sutures are a vital component for good mesh fixation. The larger the mesh, the more sutures are needed in our opinion. Tacks should be placed between the fixation sutures to prevent herniation of viscera between sutures. Postoperatively, patients should be instructed to wear abdominal binders—particularly if a large defect has been repaired—in an effort to obliterate dead space and prevent seroma formation.

## POSTOPERATIVE RESULTS

In contrast to many other laparoscopic procedures, LVH may not always reduce postoperative pain. As was previously discussed, immediate postoperative pain and quality of life appear to be similar after laparoscopic and open ventral hernia repair. Nevertheless, there are other postoperative outcomes where LVH offers advantages.

Most of the RCTs, meta-analyses, and comparative studies show a significantly lower rate of short-term postoperative complications after LVH compared with open surgery.<sup>9,11,13,16,17</sup> Detailed analysis of postoperative complications shows that this reduction is primarily due to fewer wound-related complications. In the article published by Itani and colleagues, postoperative complications were observed in 31.5% of a laparoscopic group and 47.9% of an open group of patients with an incidence of wound infection of 2.8% and 21.9% in laparoscopic and open hernia repair, respectively.<sup>13</sup> This is an important outcome because surgical site infection may require mesh removal. In the meta-analysis published by Forbes et al, the rate of mesh removal secondary to infection was 0.7% in LVH and 3.5% in open surgery.<sup>17</sup>

It is interesting that although postoperative pain is similar, hospital stay is shorter for patients undergoing LVH in most, but not all, the randomized controlled studies.<sup>17</sup> Some studies, such as the one published by Itani and colleagues that did not find a reduction in hospital stay (4.0 vs 3.9 in laparoscopic vs open surgery, respectively), did however find that LVH patients returned to work more rapidly than those undergoing open repairs (23 vs 28 days).

In summary, the overall incidence of postoperative complications is reduced after laparoscopic hernia repair mainly due to a lower incidence of wound-related complications. While short-term pain and quality of life appear to be similar, hospital stay and return to work appear to be shorter in LVH compared with open surgery.



## LONG-TERM FOLLOW-UP

The most important outcome in hernia repair surgery is recurrence. The introduction of mesh in open hernia repair was a major advance that substantially reduced the recurrence rate.<sup>2,3</sup> Burger et al reported a 10-year cumulative rate of recurrence of 63% and 32% for suture and mesh hernia repair, respectively. Based on the data currently available, the rate of hernia recurrence after open and laparoscopic hernia repair is at least similar.<sup>9,10,13,18</sup> Unfortunately, most of the trials comparing LVH and traditional repairs were designed to evaluate postoperative complications, not long-term recurrence. Hence, there is little, if any, published follow-up beyond 3 years. A meta-analysis published in 2009 that analyzed eight RCTs found no significant difference in the risk of hernia recurrence between both techniques at short term of follow-up (3.4% and 3.6% in laparoscopic and open repair, respectively).<sup>17</sup> Similar findings were recently published by Itani and colleagues.<sup>13</sup> In this RCT, the recurrence rate at 2 years of follow-up was 12.5% for the laparoscopic repair group and 8.2% for the open technique group ( $p = 0.44$ ). In open hernia repairs, the recurrence rate is lower when the procedure is performed by experienced surgeons.<sup>19</sup> It is logical to expect that the same relationship exists between LVH and surgeon volume.

## COST-BENEFIT

The laparoscopic technique of hernia repair involves the use of laparoscopic instruments and potentially new, expensive mesh prostheses that must be added to the standard cost of operating room use and hospital stay. In open hernia repair, the use of mesh has been shown to be a cost-effective alternative to suture repair when one accounts for postoperative complications, recurrence rate, and long-term follow-up.<sup>20</sup> There is little data available for LVH. This is an issue that should be incorporated in future trials. It is impossible to compare the cost/benefit ratio of LVH to standard repairs without this information.

## CONCLUSION

LVH is a well-established technique for treating abdominal wall hernias. It is hard to make a blanket statement that LVH is a superior approach to traditional mesh repairs. However, understanding the unique features of the approach allows well-trained surgeons to utilize it where it is most likely to be beneficial and likewise opt for a traditional mesh repair when LVH is unlikely to offer any advantage. The modern surgeon treating abdominal wall hernias should be facile with both techniques.

## REFERENCES

1. LeBlanc KA, Booth WV. Laparoscopic repair of incisional abdominal hernias using expanded polytetrafluoroethylene: preliminary findings. *Surg Laparosc Endosc*. 1993 Feb;3(1):39–41.
2. Luijendijk RW, Hop WC, van den Tol MP, et al. A comparison of suture repair with mesh repair for incisional hernia. *N Engl J Med*. 2000 Aug 10;343(6):392–398.
3. Burger JW, Luijendijk RW, Hop WC, Halm JA, Verdaasdonk EG, Jeekel J. Long-term follow-up of a randomized controlled trial of suture versus mesh repair of incisional hernia. *Ann Surg*. 2004 Oct;240(4):578–583; discussion 583–575.
4. Ballester P, Ammori BJ. Laparoscopic suture repair of selected incisional hernias: a simple technique. *J Laparoendosc Adv Surg Tech A*. 2007 Jun;17(3):326–328.
5. Horzic M, Vergles D, Cupurdija K, Kopljar M, Zidak M, Lackovic Z. Spontaneous mesh evacuation per rectum after incisional ventral hernia repair. *Hernia*. 2011;15:351–352.
6. LeBlanc KA. Incisional hernia repair: laparoscopic techniques. *World J Surg*. 2005 Aug;29(8):1073–1079.
7. Champault G, Polliand C, Dufour F, Zioli M, Behr L. A “self adhering” prosthesis for hernia repair: experimental study. *Hernia*. 2009 Feb; 13(1):49–52.
8. Barbaros U, Asoglu O, Seven R, et al. The comparison of laparoscopic and open ventral hernia repairs: a prospective randomized study. *Hernia*. 2007 Feb;11(1):51–56.
9. Misra MC, Bansal VK, Kulkarni MP, Pawar DK. Comparison of laparoscopic and open repair of incisional and primary ventral hernia: results of a prospective randomized study. *Surg Endosc*. 2006 Dec;20(12):1839–1845.
10. Asencio F, Aguilo J, Peiro S, et al. Open randomized clinical trial of laparoscopic versus open incisional hernia repair. *Surg Endosc*. 2009 Jul;23(7):1441–1448.
11. Sajid MS, Bokhari SA, Mallick AS, Cheek E, Baig MK. Laparoscopic versus open repair of incisional/ventral hernia: a meta-analysis. *Am J Surg*. 2009 Jan;197(1):64–72.
12. Wassenaar E, Schoenmaeckers E, Raymakers J, van der Palen J, Rakic S. Mesh-fixation method and pain and quality of life after laparoscopic ventral or incisional hernia repair: a randomized trial of three fixation techniques. *Surg Endosc*. 2010 Jun;24(6):1296–1302.
13. Itani KM, Hur K, Kim LT, et al. Comparison of laparoscopic and open repair with mesh for the treatment of ventral incisional hernia: a randomized trial. *Arch Surg*. 2010 Apr;145(4):322–328; discussion 328.
14. Perrone JM, Soper NJ, Eagon JC, et al. Perioperative outcomes and complications of laparoscopic ventral hernia repair. *Surgery*. 2005 Oct;138(4):708–715; discussion 705–706.
15. LeBlanc KA, Elieson MJ, Corder JM, 3rd. Enterotomy and mortality rates of laparoscopic incisional and ventral hernia repair: a review of the literature. *JSLs*. 2007 Oct–Dec;11(4):408–414.
16. Olmi S, Scaini A, Cesana GC, Erba L, Croce E. Laparoscopic versus open incisional hernia repair: an open randomized controlled study. *Surg Endosc*. 2007 Apr;21(4):555–559.
17. Forbes SS, Eskicioglu C, McLeod RS, Okrainec A. Meta-analysis of randomized controlled trials comparing open and laparoscopic ventral and incisional hernia repair with mesh. *Br J Surg*. 2009 Aug;96(8): 851–858.
18. Bingener J, Buck L, Richards M, Michalek J, Schwesinger W, Sirinek K. Long-term outcomes in laparoscopic vs open ventral hernia repair. *Arch Surg*. 2007 Jun;142(6):562–567.
19. Langer C, Schaper A, Liersch T, et al. Prognosis factors in incisional hernia surgery: 25 years of experience. *Hernia*. 2005 Mar;9(1):16–21.
20. Finan KR, Kilgore ML, Hawn MT. Open suture versus mesh repair of primary incisional hernias: a cost-utility analysis. *Hernia*. 2009 Apr;13(2):173–182.

# PERSPECTIVE ON HERNIAS: LAPAROSCOPIC INGUINAL HERNIA REPAIR

Lokesh Bathla • Robert J. Fitzgibbons, Jr

The transabdominal preperitoneal (TAPP) and the totally extraperitoneal repair (TEP) are the two most commonly performed types of laparoscopic inguinal hernia repairs. The intraperitoneal onlay mesh (IPOM) repair, the only truly minimally invasive laparoscopic hernia repair (because a radical dissection of the preperitoneal space is avoided), is rarely performed. Over the last decade, surgeons have become proficient in these procedures and an increasing number of laparoscopic repairs are being performed. Long-term follow-up data is now available, which shows that laparoscopic hernia repair has similar success rate as the conventional repair, with early return to work and possibly decreased overall cost.

Laparoscopic inguinal hernia repair requires that the surgeon appreciate the anatomy of the myopectineal orifice from a perspective opposite to that of the conventional anterior repair. Consequently, a detailed understanding of the anatomy of the deep inguinal region and the posterior aspect of the anterior abdominal wall is necessary to perform a laparoscopic inguinal hernia repair. The major nerves (five in number) in the region of the myopectineal orifice are all located lateral to the deep inguinal ring. The nerves, from lateral to medial, include the lateral femoral cutaneous nerve, anterior femoral cutaneous nerve, femoral nerve, femoral branch of the genitofemoral nerve, and the genital branch of the genitofemoral nerve. These nerve branches may be quite variable in their course and lie in the so-called *triangle of pain*, bordered medially by the gonadal vessels, anteriorly and inferiorly by the iliopubic tract, and laterally by the iliac crest.

On the other hand, the important vascular structures are located infero-medial to the deep ring. In some individuals, a vessel or vessels, which are usually referred to as “aberrant,” arise from the inferior epigastric system, arching over Cooper’s ligament to join the normal obturator vessels, thereby completing a vascular ring. This is referred to as the *corona mortis*. Bleeding can be quite significant from it if attention is not paid during the dissection in this region. The internal spermatic vessels and the ductus deferens approach the deep inguinal ring from different directions, forming the

apex of the *triangle of doom*, so called because the external iliac vessels, deep circumflex iliac vein, genital branch of the genitofemoral nerve, and the femoral nerve lie in this region.<sup>1</sup>

A tension-free open mesh repair is still the gold standard for the treatment of inguinal hernia and is usually performed under local anesthesia with sedation. Compared with this, the laparoscopic approach requires general anesthesia, is associated with higher in-hospital costs, and has a long learning curve. More importantly, the laparoscopic approach has the remote potential for a fatal complication such as major vascular or bowel injury.

Certain hernia types are better served by the laparoscopic approach. These include, bilateral hernias because both sides can be repaired from the same access ports, thereby pushing the risk/benefit ratio in favor of laparoscopy; recurrent hernias assuming the preperitoneal space has not been previously dissected and hernias in women because of higher incidence of femoral recurrence with the usual anterior prosthetic repairs.<sup>2</sup> Many laparoscopic surgeons believe that sliding hernias especially when reducible are more effectively approached laparoscopically than conventionally. Previous surgery in the retropubic space, intra-abdominal adhesions, scrotal hernia, incarcerated inguino-scrotal hernia, and the presence of ascites constitute relative contraindications.

Brooks and his colleagues have nicely described the basics of the surgical technique in the previous section. We would like to emphasize a few additional points. For the TAPP operation, it is important to dissect the entire symphysis pubis to the contralateral pubic tubercle for adequate coverage of the myopectineal orifice to prevent the all too common pubic tubercle recurrence. Additionally, it is very important to adequately mobilize the inferior peritoneal flap because the prosthesis tends to roll up in the limited space and may be a cause for recurrence. A large inguinal scrotal sac does not need to be removed in its entirety and can be divided at a convenient point along the cord structures with the proximal side ligated and the distal side left widely opened. This avoids an excessive incidence of hydrocele and the vascular disruption

in the distal cord, which can lead to various testicular complications. Slitting the mesh to wrap around the spermatic cord is optional, and if done, care should be taken to adequately repair the mesh around the spermatic cord. Prosthesis fixation methods continue to be controversial with some authors in fact questioning the need to do so. Several methods of prosthetic fixation, including absorbable tacks and biologic tissue adhesives, have been evaluated in recent studies.<sup>3,4</sup> Additionally, it has been hypothesized that if there is enough overlap of the myopectineal orifice, fixation should not be required. Nevertheless, we continue to fix the mesh and avoid placing tacks inferior to the iliopubic tract and lateral to the internal spermatic vessels as they have been implicated in posthernia repair groin pain, which can be debilitating.

The choice between TEP and TAPP repair is largely determined by the surgeon's training, experience, and personal preference. The literature generally favors TEP over TAP because of the avoidance of complications associated with entering the peritoneal cavity including visceral injury, vascular injury, adhesion formation, and trocar site hernias. In addition, peritoneal closure does not have to be performed since the dissection is extraperitoneal. However, these advantages are not universally embraced and in fact the largest series of laparoscopic inguinal hernia repairs in the world were largely TAPP repair.<sup>5</sup>

A large number of randomized control trials and meta-analyses have shown that patients who undergo laparoscopic hernia repair experience less pain in the early postoperative period, and have lower analgesic and narcotic requirements, better cosmesis, and early return to normal activities. Most comparative studies have shown equivalent complication rates between the tension-free repair and the laparoscopic approach. It is important to note here that most of these outcomes have been reported from specialized centers and may not be truly reflective of outcomes in the community. This was suggested by the often-quoted Veterans Administration (VA) cooperative trial comparing a laparoscopic preperitoneal inguinal herniorrhaphy (mostly TEP) with a standardized Lichtenstein approach.<sup>6</sup> Recurrences were more common in the laparoscopic group (87 of 862 patients or 10.1%) than in the open group (41 of 834 patients or 4.9%) and this was statistically significant. The surgeons participating in this trial were well trained but did not have a specialty interest in hernia surgery. Thus, the selection of open versus laparoscopic has to be based on the expertise of the surgeon. Both the patient and the surgeon should weigh the risks and benefits of this approach before pursuing laparoscopic inguinal hernia repair. Although several studies in the past have tried to define the learning curve for laparoscopic hernia repair, the number of procedures recommended to gain proficiency continues to be variable.

The overall incidence of morbidity after laparoscopic inguinal hernia repair has been quite variable. Fortunately, serious complications are rare. These complications may be related to laparoscopy per se, the patient, the hernia, or the prosthesis. Over three quarters of the major vascular injuries occur during the insertion of the Veress needle or trocars. The risk of major vascular injury requiring operative repair is relatively

low, around 0.8%.<sup>7</sup> Despite the low prevalence, these injuries are associated with mortality up to 17%.<sup>8</sup> Prompt repair of such injuries with formal laparotomy should be considered, as the true magnitude of the injury may not be truly appreciated laparoscopically. Occasionally, bowel or bladder injury occurs during the access phase of laparoscopy. Such injuries should be promptly repaired either laparoscopically or with laparotomy, depending on the experience and skills of the surgeon.

With improvement in laparoscopic skills and increased surgeon experience, the recurrence rates of laparoscopic hernia repair have become almost equivalent to those reported for conventional hernia repair. Chronic pain after hernia repair is an important adverse outcome and has been extensively discussed in the literature. Unfortunately, there is poor understanding of the pre-, intra-, and postoperative factors that cause the various pain syndromes. These pain syndromes could be somatic or visceral in nature (depending on the underlying cause) and can be difficult to treat. Initial treatment of all these pain syndromes is initially conservative with reassurance, anti-inflammatory medication, cryotherapy, and local nerve blocks. In case conservative measures fail to relieve patient's symptoms and other underlying causes have been excluded, groin exploration may be required. When exploring the groin in this situation, the surgeon must be prepared for possible mesh removal, which may be difficult because of the dense adhesions. Neurectomy, neurolysis, or neuroma excision should be reserved as a last resort. Occasionally, patients may develop infertility or the dysejaculation syndrome. These could be due to underlying injury to the vas deferens or extensive cicatrization around the vas deferens due to mesh-induced inflammation. These conditions, although rare, can be difficult to treat and usually have less than satisfactory outcomes.

The hospital cost for laparoscopic hernia repair is significantly higher than that for conventional hernia repair. However, when both direct and indirect costs are assessed in follow-up, there does not appear to be a significant cost difference. The direct operative costs appear to be compensated by the higher productivity attributable to earlier return to work.

In conclusion, laparoscopic inguinal hernia repair is an excellent alternative to conventional repair for the properly trained surgeon. Although appropriate for uncomplicated unilateral hernias, one must consider the risk/benefit ratio carefully because of the need for general anesthesia and the slight possibility of a disastrous laparoscopic accident that can be avoided with the conventional procedure. There is wide agreement that the risk/benefit ratio favors laparoscopy for patients with bilateral or recurrent inguinal hernias where the conventional space has been violated.

## REFERENCES

1. Spaw AT, Ennis BW, Spaw LP. Laparoscopic hernia repair: the anatomic basis. *J Laparoendosc Surg.* 1991;1(5):269-277.
2. Koch A, Edwards A, Haapaniemi S, Nordin P, Kald A. Prospective evaluation of 6895 groin hernia repairs in women. *Br J Surg.* 2005;92(12):1553-1558.

3. Olmi S, Scaini A, Erba L, Guaglio M, Croce E. Quantification of pain in laparoscopic transabdominal preperitoneal (TEP) inguinal hernioplasty identifies marked differences between prosthesis fixation systems. *Surgery*. 2007;142(1):40–46.
4. Lovisetto F, Zonta S, Rota E, et al. Use of human fibrin glue (Tissucol) versus staples for mesh fixation in laparoscopic transabdominal preperitoneal hernioplasty: a prospective randomized study. *Surg Endosc*. 2007 Apr;21(4):646–652. Epub 2006 Nov 14.
5. Wauschkuhn CA, Schwarz J, Boekeler U, Bittner R. Laparoscopic inguinal hernia repair: gold standard in bilateral hernia repair? Results of more than 2800 patients in comparison to literature. *Surg Endosc*. 2010;24(12):3026–3030.
6. Neumayer L, Giobbie-Hurder A, Jonasson O, et al. Open mesh versus laparoscopic mesh repair of inguinal hernia. *N Engl J Med*. 2004;350(18):1819–1827.
7. Schafer M, Lauper M, Krahenbuhl L. A nation's experience of bleeding complications during laparoscopy. *Am J Surg*. 2000;180:73.
8. Olsen DO. Laparoscopic cholecystectomy. *Am J Surg*. 1991;161:339.



# INTESTINAL STOMAS

Ira J. Kodner • Thomas E. Read • Donna L. Loehner

An intestinal stoma is an opening of the intestinal or urinary tract onto the abdominal wall, constructed surgically or appearing inadvertently. A colostomy is a connection of the colon to the skin of the abdominal wall. An ileostomy involves exteriorization of the ileum on the abdominal skin. In rare instances, the proximal small bowel may be exteriorized as a jejunostomy. A urinary conduit involves a stoma on the abdominal wall that serves to convey urine to an appliance placed on the skin. The conduit may consist of an intestinal segment, or in some cases a direct implantation of the ureter, or even the bladder, on the abdominal wall.

Information about the types and numbers of stomas constructed, complications of stomas, and resultant impairment of an individual's life has been limited because the diseases for which stomas are constructed are not mandated as reportable in the United States. Therefore, the United Ostomy Association of America (UOAA, [www.uoaa.org](http://www.uoaa.org)), formerly the United Ostomy Association, a voluntary group of 40,000 members with stomas of various types, undertook the mission of collecting data from patients in the United States and Canada who have an intestinal stoma. A review of 15,000 such entries shows the peak incidence for ileostomy construction owing to ulcerative colitis to occur in persons between 20 and 40 years of age, with a lower peak but in the same age range for patients with Crohn's disease. The second largest peak represents colostomies constructed because of colorectal cancer, and this peak is in patients 60–80 years of age. When complications were analyzed according to original indication for surgery, we found that many patients knew that they had complications but were not aware of the exact nature of the complication. Postoperative intestinal obstruction occurred in all categories of disease, as did retraction of the stoma and abscess formation. There was a preponderance of hernia formation in patients who had surgery for colorectal cancer, whereas abscess, fistula, and stricture formation were the major complications in the patients with Crohn's disease. As new surgical procedures are devised, a justification for their utilization is often the reduction of the level of handicap that exists among patients who have had construction of a conventional ostomy. The UOA survey revealed that patients resumed household activities 90% of the time, vocational activities 73% of the time, social activities 92% of

the time, and sexual activities 70% of the time. It is taken into account that patients who have proctectomy for cancer frequently lose their sexual function because of autonomic denervation and not because of the presence of a stoma.

Changes that have improved the quality of life of the patient with a stoma include the development and availability of improved stoma equipment. Specialized surgical techniques, some of which are described in this chapter, have been developed that facilitate the subsequent maintenance of an ostomy. In addition, specialized nursing techniques applied both preoperatively and postoperatively have enhanced the care of the patient with a stoma. The involvement of a Certified Wound Ostomy Continence Nurse (CWOCN) in the care of patients with stomas is critical.

The overall incidence of stoma construction appears to be decreasing and will probably continue to do so. There are now fewer abdominoperineal resections for cancer because of the advent of new surgical techniques, especially the use of stapling devices, as well as an increased use of local treatment for selected rectal tumors. The incidence of permanent ileostomies is decreasing because of the popularization of sphincter-saving procedures for patients with ulcerative colitis and familial polyposis. The surgical procedures that eliminate permanent stomas, however, have resulted in an increasing use of temporary loop ileostomies.

Each type of stoma is associated with a particular spectrum of complications, but some problems are common to all intestinal stomas. The specific ones are dealt with under each category of stoma. A common complication, regardless of the stoma type, is destruction of the peristomal skin, which is usually caused by poor location or construction of the stoma. In addition to the acute maceration and inflammation of the skin, pseudoepitheliomatous hyperplasia may arise at the mucocutaneous border of stomas subjected to chronic ill-fitting appliances. Appearance of a fistula adjacent to a stoma usually indicates recurrence of Crohn's disease. One of the difficult complications to handle, especially in an obese patient, is improper location of the stoma, which prohibits maintenance of the seal of an appliance. A stoma buried in a skin fold, or a flush stoma, can create devastating peristomal skin problems. A special problem arises in the patient who

has portal hypertension because the construction of a stoma results in the creation of a portosystemic shunt, and varices can form in the peristomal skin.

Other common problems include the need for precautions with medications, especially time-released enteric medications, which may pass through a shortened intestinal tract unabsorbed. Laxatives also can be devastating to patients with no colon or with a proximal colostomy. In some cases, the ostomy patient has chronic difficulty maintaining proper fluid and electrolyte balance, and diuretics in these patients can be especially difficult to manage. The usual intestinal preparations prior to diagnostic testing should be altered for the patient with an intestinal stoma.

Many potential stoma complications can be avoided by proper preoperative marking and counseling. The stoma location should be chosen and marked preoperatively, even if there is only a remote possibility of the need for an intestinal stoma during the operative procedure. Surgeons who perform intestinal stomas should be well versed in stoma care and management of stoma complications. The value of collaboration with an enterostomal therapist (CWOCN) cannot be overstated. Patients should meet with the CWOCN preoperatively, and the surgeon and CWOCN should discuss the selection of potential stoma sites together prior to operation.

## COLOSTOMY

The most common indication for fashioning a colostomy is cancer of the rectum. Since a colostomy is an opening of the large intestine with no sphincteric control, its location would obviously be better on the abdominal wall than in the perineum, where an appliance cannot be maintained. A distal colorectal anastomosis in an elderly patient with a poorly functioning anal sphincter may result in what is essentially a “perineal colostomy.” In these cases, it often behooves the surgeon to construct a good colostomy rather than to restore intestinal continuity to an incontinent anus. Colostomies are also constructed as treatment for obstructing lesions of the distal large intestine and for actual or potential perforations.

### Type by Anatomic Location

Traditionally, the type of colostomy has been categorized by the part of the colon used in its construction. The most common type has been called an “end-sigmoid” colostomy. However, if the origin of the inferior mesenteric artery is transected during an operation for cancer of the rectum, the blood supply to the sigmoid colon is no longer dependable, and it should not be used for stoma construction. Therefore, an “end-descending” colostomy is usually preferable to an end-sigmoid colostomy. Other types of colonic stomas include the transverse colostomy and cecostomy. The physiology of the colon should be taken into account when considering stoma construction. The right side of the colon absorbs water and has irregular peristaltic contractions. Stomas made from the proximal half of the colon

usually expel a liquid content. The left colon serves as a conduit and reservoir and has a few mass peristaltic motions per day. The content is more solid, and in many cases the stoma output can be regulated by irrigation. Proximal colostomies should be avoided, as they will combine the worst features of both a colostomy and an ileostomy: liquid, high-volume, foul-smelling effluent. The left colon should be used for a colostomy if possible; the distal transverse colon is also a reasonable choice.

### Determination of Colostomy Location

The location of the colostomy must be carefully selected preoperatively. It should avoid any deep folds of fat, scars, and bony prominences of the abdominal wall. The site is chosen by evaluating the patient in the standing, sitting, and supine positions. Often abdominal skin and fat folds are only noted with the patient in the sitting position. A stoma faceplate is applied to the abdominal wall with its medial margin at the midline; care is taken to not overlay any fold, scar, or prominence; and the stoma site is marked. The inguinal fold and waistline fold should be avoided. If a sigmoid or descending colostomy is contemplated, the most desirable position is usually in the left lower quadrant of the abdomen. However, if the patient is obese, it may be preferable to site the colostomy in the left upper quadrant so that it is visible to the patient and not trapped on the undersurface of a panniculus. If a distal transverse colostomy is planned, the left upper quadrant is usually the preferable site. Please refer to the section on determination of the ileostomy location for more details regarding stoma site selection.

### Type by Function

More important than the anatomy of the colon is the function that the colostomy is intended to perform. There are two considerations: (1) to provide decompression of the large intestine, and (2) to provide diversion of the feces.

### DECOMPRESSING COLOSTOMY

A decompressing colostomy is most often constructed for distal obstructing lesions causing dilation of the proximal colon without ischemic necrosis, severe sigmoid diverticulitis with phlegmon, and for select patients with toxic megacolon. Alternative treatments exist for these conditions: total abdominal colectomy with ileostomy or ileorectal anastomosis; segmental colectomy with construction of end colostomy; segmental colectomy with primary anastomosis; and segmental colectomy with intraoperative colonic lavage and primary anastomosis with temporary diverting loop ileostomy. However, temporary decompressing stomas are still useful and safe. The procedure acts as a bridge to definitive operation for toxic patients with benign disease and those with malignant distal obstruction. The disadvantages of a decompressing stoma is that it does not provide definitive management of the disease process and thus the patient often requires subsequent operation, and it does not necessarily

provide complete fecal diversion and thus carries the risk of potentially fatal sepsis if there is distal perforation.

**Types of Decompressing Stomas.** There are three types of decompressing colostomies: (1) the so-called “blow-hole” decompressing colostomy constructed in the cecum or transverse colon, (2) tube cecostomy, and (3) loop colostomy.

**Cecostomy and “Blow-Hole” Colostomy.** A cecostomy should be constructed only rarely because it is difficult to manage postoperatively. It should be reserved for the severely, acutely ill patient with massive distention and impending perforation of the colon. This is seen most often with distal obstructing cancer or in some of the pseudo-obstruction syndromes seen in elderly or immuno-compromised patients. Because these operations are done on an urgent basis and the abdomen is usually distorted by intestinal dilation, the choice of site for an incision is over the dilated cecum. The location of this incision or of an intended decompressing transverse colostomy can be selected by placing a marker on the umbilicus when an abdominal film is obtained.

The construction of a blow-hole cecostomy or transverse colostomy (Fig. 9-1) is carried out by making a 4–6 cm transverse incision over the most dilated part of intestine and then placing a series of interrupted, seromuscular, absorbable sutures between the peritoneum and the seromuscular layer of the bowel to be decompressed. This should be done through an incision sufficient to allow subsequent incision of the intestine and suturing of the intestine to the skin. The bowel wall will be very thin, and it is not unusual to have leakage of gas as the sutures are being placed. A disadvantage of a cecostomy or loop colostomy done through a small incision is that one cannot evaluate other parts of the colon for potential ischemic necrosis due to massive dilation.

Once the first layer of sutures has been placed and the intestine is sealed from the remainder of the abdominal cavity, needle decompression of the gas-distended viscus is performed to reduce the tension on the intestinal wall. When this procedure is completed, a second layer of absorbable sutures is placed between the seromuscular layer of the intestine and the fascia of the abdominal wall. Subsequently, the colon is incised, usually with release of a large amount of liquid and gas. The full thickness of intestine then is sutured to the full thickness of skin, again with absorbable sutures, and an appliance is placed over the stoma. Postoperatively, it is not unusual for there to be significant inflammation in the abdominal wall around such a stoma, and after a period of weeks, significant prolapse may occur. Therefore, these stomas should be used for short periods of time, with definitive resection performed as soon as possible.

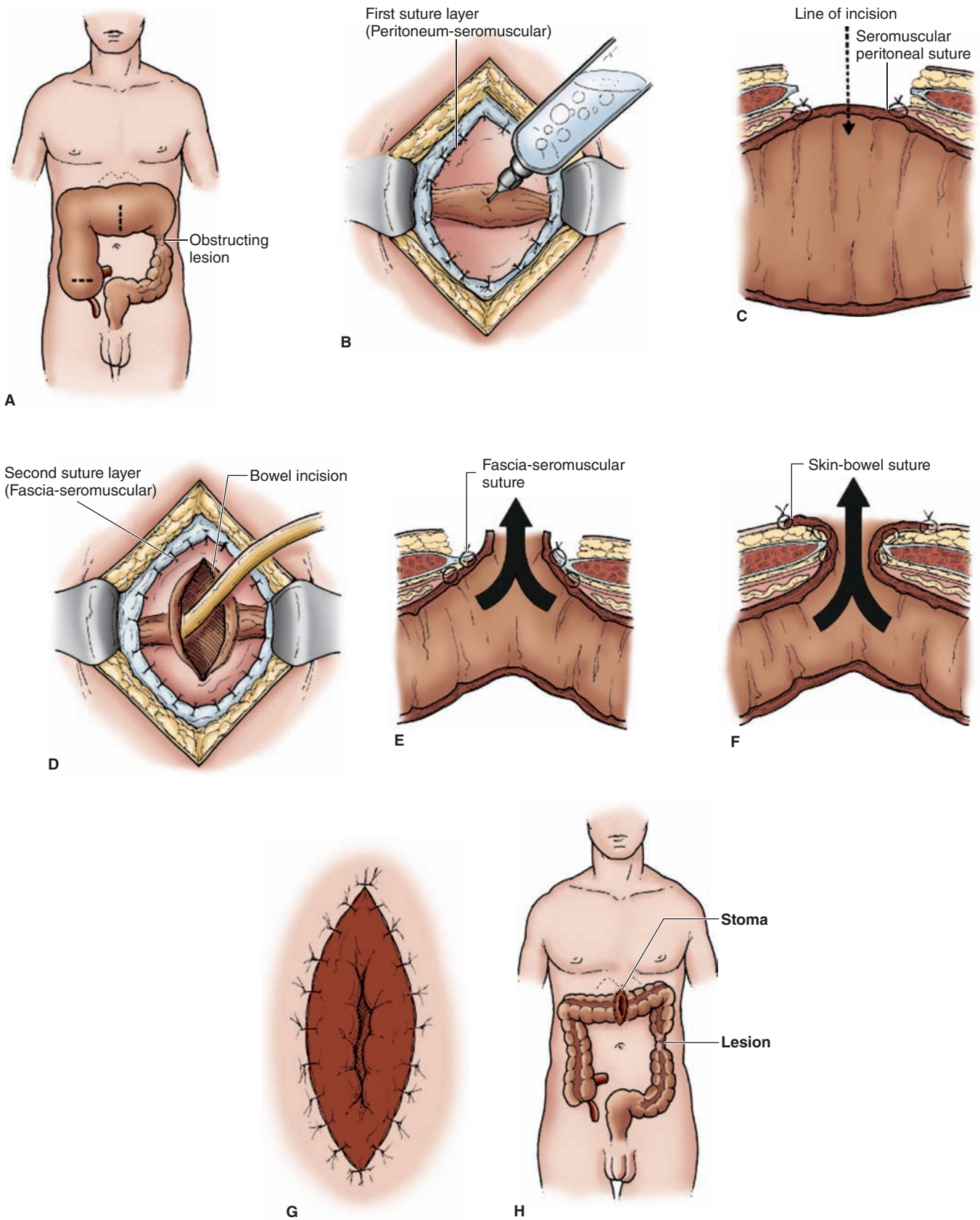
A tube cecostomy (Fig. 9-2) is constructed by making an incision similar to that used for a “blow hole” colostomy, by formal laparotomy, or by laparoscopy. A purse-string suture is placed in the cecal wall, and a large mushroom-tipped or Malecot catheter is placed in the cecum. The purse-string suture secures the catheter. Usually a second purse-string suture is placed, and the tube is brought through a right lower

quadrant incision. The cecum then is sutured to the peritoneum of the abdominal wall. The advantage of this stoma is that there is less chance of prolapse. The major disadvantage is that the tubes usually become blocked with feces, drain poorly, and sometimes leak stool adjacent to the drain. Because of all their disadvantages, tube cecostomy and blow-hole colostomies are rarely performed at present.

**Loop-Transverse Colostomy.** A loop colostomy using the transverse colon (Fig. 9-3) or left colon can be used as a decompressive stoma, although it will usually completely divert the flow of stool away from the distal colon and can thus be considered a diverting stoma. Occasionally, the posterior wall of the stoma recesses far enough below the wall of the abdomen so that stool can enter the distal loop, although this is uncommon. These stomas are constructed for reasons similar to those described for the blow-hole type stoma and to provide temporary diversion for protection of complicated distal anastomoses. The other advantage is that when properly constructed, a loop colostomy can serve as a long-term stoma. The incidence of prolapse is not prohibitive. Parastomal hernias can occur if the fascia is not closed tightly enough, and these stomas usually cannot be regulated by irrigation techniques.

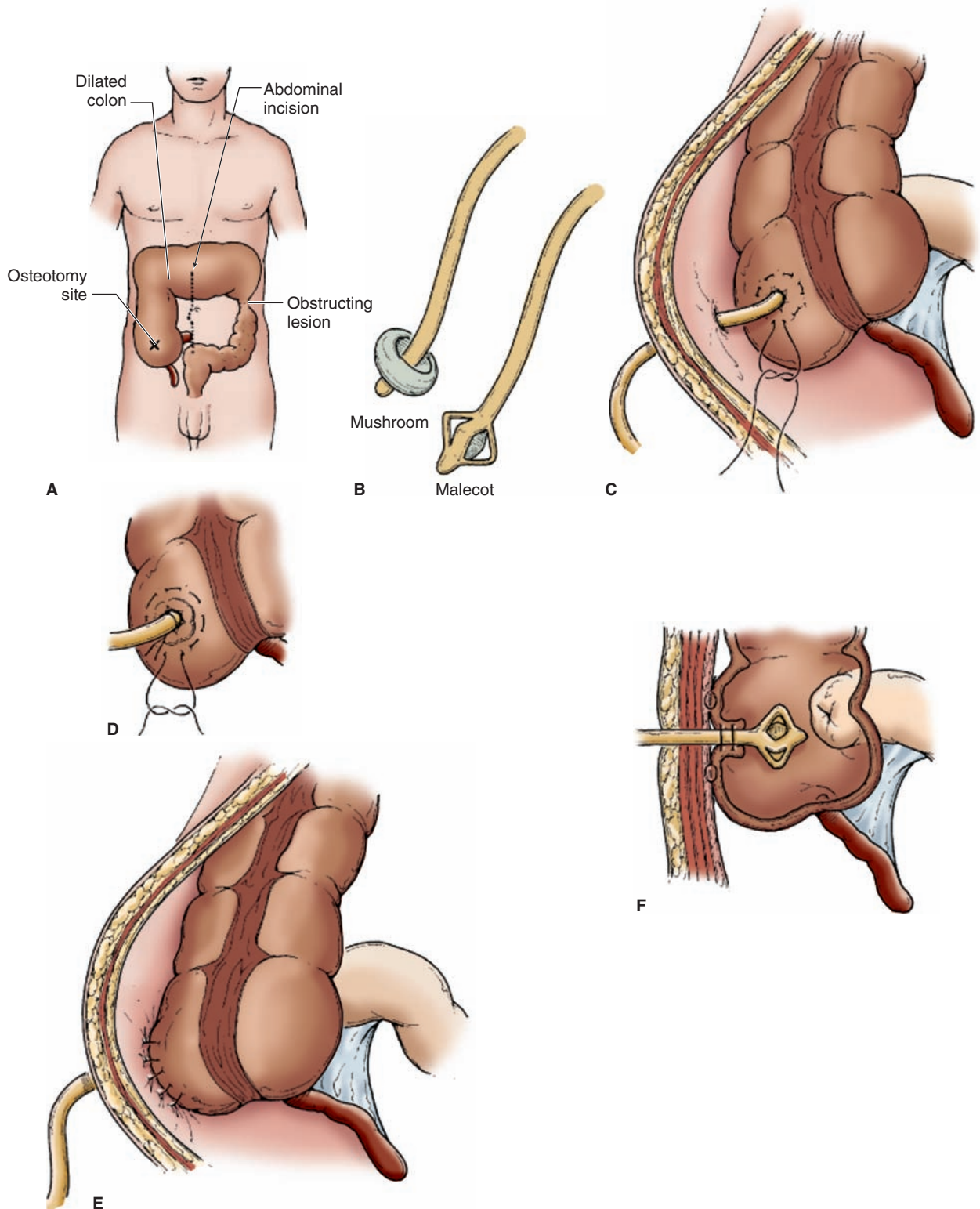
The site can be chosen for this stoma in an emergency situation as previously described, but it should be marked electively on the abdominal wall in preparation for potential construction in patients who are to have low colorectal anastomoses or in those in whom it is anticipated that an inflammatory reaction will be encountered and will require temporary diversion of intestinal contents as a safeguard against contamination from a leaking anastomosis. This occurs occasionally in patients with severe diverticulitis. In an elective situation, the stoma can be placed through the rectus muscle either on the right or left side, depending on later intentions of closing or resecting the colostomy site in continuity with a cancer operation, or it can be brought through the midline (Fig. 9-3A). If performed in conjunction with a midline incision, a midline colostomy site may be suboptimal because of difficulty with placing the ostomy appliance over the fresh incision.

Construction of loop colostomy requires the colon to be mobile enough to be brought to the level of the abdominal wall (Fig. 9-3B). If this cannot be done or if the colon is so massively dilated that loop colostomy is not safe, one should resort to the use of a blow-hole colostomy as previously described, in which only one wall of the intestine is utilized and tension on the mesentery is avoided. A transverse loop colostomy can be constructed by placing a tracheostomy tape or soft latex drain around the colon at the site chosen for the colostomy. The transverse colon at this site is usually dissected free of the overlying omentum in the embryonic peritoneal fusion planes. The tracheostomy tape and colon are brought through an avascular window in the omentum to allow better sealing between the colon and the abdominal wall (Figs. 9-3B and 9-3C). The fascia is then closed on either side of the loop of colon tightly enough to allow snug passage of one fingertip (Fig. 9-3D).

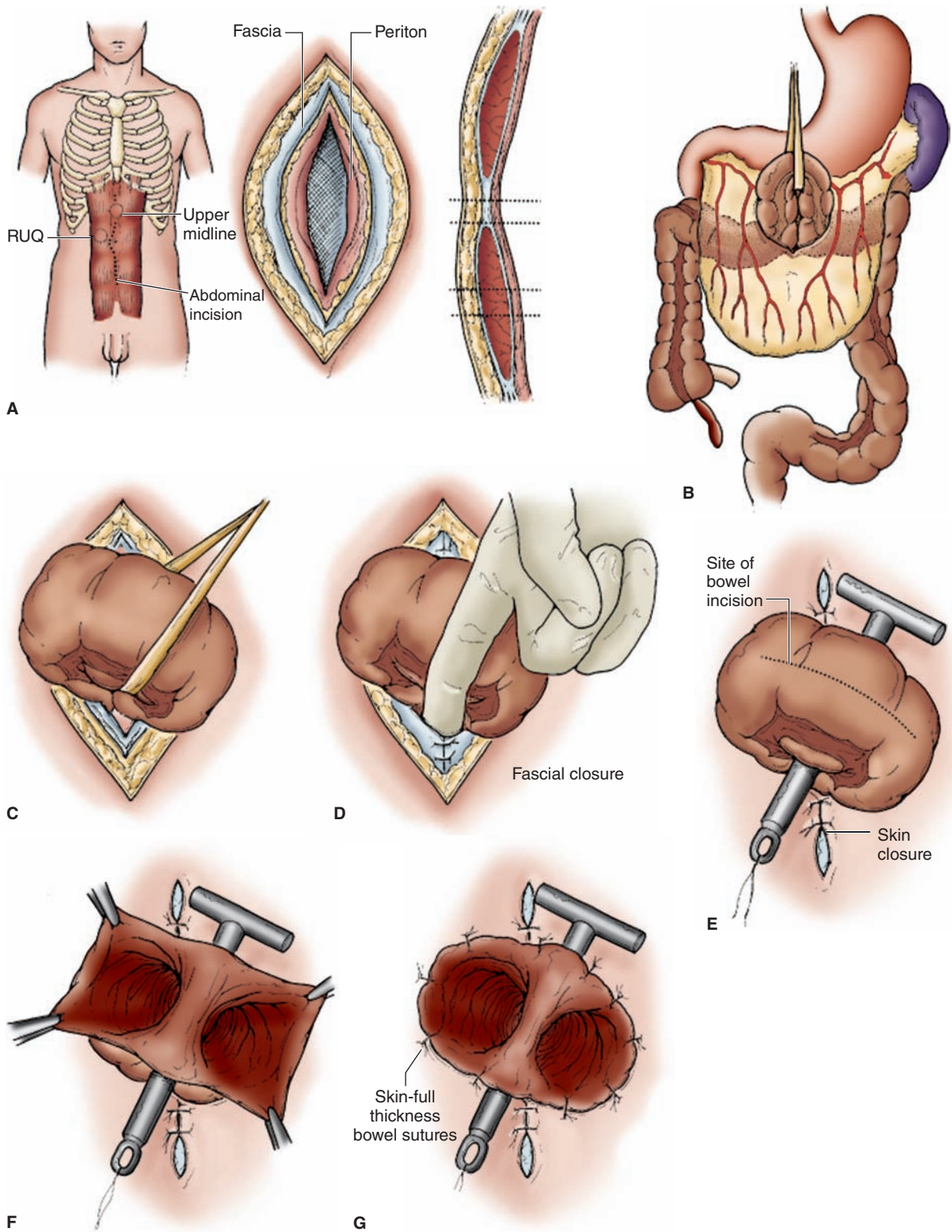


**FIGURE 9-1** Construction of blow-hole cecostomy or colostomy. **A.** The incision is located over the most dilated aspect of the intestine. **B.** After the peritoneum is quarantined, gas is allowed to escape, decompressing the bowel. **C.** Placement of the quarantine sutures. **D.** The colon is opened, and more adequate aspiration is effected. **E.** Details of the second level of quarantine sutures between the fascia and seromuscular layer of the colonic wall (this should be completed before the bowel is opened). **F, G.** The stoma is completed by placement of sutures between skin and colonic wall. **H.** Completed blow-hole stoma.





**FIGURE 9-2** Construction of a tube cecostomy. **A.** The cecostomy is constructed over the most dilated aspect of the cecum. **B.** A very large Malecot or mushroom-tipped catheter is used. **C, D.** The catheter is secured within the cecum by two purse-string sutures. **E.** The cecum is sutured to the abdominal wall at the entry site of the catheter. **F.** Cross section of the completed tube cecostomy.



**FIGURE 9-3** Construction of a loop-transverse colostomy. **A**, Choice of stomal location. **B**, **C**, Tracheostomy tape is used to pull the loop of colon through the incision. **D**, The fascia is closed tightly around the loop of intestine. **E**, **F**, **G**, The loop of colon is opened over a supporting rod and is sutured to the skin of the abdominal wall.

The skin is then snugly closed, on either side of the loop of colon. The tracheostomy tape is replaced by a plastic rod that frequently has a suture through each end so that it can be easily repositioned should it be displaced (Fig. 9-3E). The wound is protected, and attention is directed to the protruding loop of colon, which is incised either longitudinally or transversely to allow the best separation of the edges of the colon (Fig. 9-3F). Full thickness of intestine is then sutured to full thickness of skin with absorbable suture material (Fig. 9-3G). If this stoma is properly constructed, the posterior wall will bulge upward, providing the desired diversion as well as decompression. An appliance is applied either over the rod or beneath the rod, depending on the tension of the stoma.

If there is a possibility that the colostomy may become permanent, it may be advantageous to divide the colon with a stapler and create a “divided end-loop” stoma in the manner of Prasad and Abcarian. The proximal colon is matured as an end colostomy, and a corner of the distal limb opened and matured as a mucus fistula in the same stoma incision to vent the distal colon (see Fig. 9-9, construction of separated [divided end-loop] ileostomy). The stoma size is typically smaller than a loop colostomy and the tendencies to prolapse or retract may be lessened.

In the postoperative period, the appliance is emptied or changed as necessary, and the wound is kept clean. The rod is usually left in place for several days and then is easily removed. The colostomy appliance is fashioned as necessary as the contour of the stoma and skin opening change. Patients with this type of stoma usually are not taught to irrigate, because irrigation is infrequently successful. After the immediate postoperative period, the patient usually is instructed to empty the appliance as necessary and to change the entire appliance every 3 to 4 days, depending on the condition of the skin and the ability to maintain an adequate seal of the appliance to the skin.

**Closure of a Temporary Colostomy.** The most important consideration in dealing with closure of a temporary colostomy is deciding when it is safe to restore intestinal continuity. Distal integrity and adequacy of sphincter muscle function must be carefully evaluated before closure of the stoma is undertaken. The reason for constructing the stoma initially must be taken into account, and contrast studies and endoscopy should demonstrate clearly that the original reason for fecal diversion no longer exists.

Adequate function of the anal sphincter must be demonstrated before the temporary colostomy is closed. This can be done by formal manometric and electromyographic studies or by giving the patient a 500-mL enema and asking him or her to hold it until he or she can comfortably walk to a toilet and expel the enema. If the sphincter does not work and cannot be repaired, the patient will be better off with a properly constructed end colostomy than with attempts to preserve a nonfunctional sphincter. Once it is decided that it is safe to close the colostomy, the procedure should be undertaken with the same skill and precaution as

that required for a colon anastomosis (Fig. 9-4). The complication rate following colostomy closure is not insignificant, and is cited by some authors as a reason to avoid diverting colostomy construction at all costs. However, as with all issues in medicine, careful consideration of the potential risks and benefits of the procedure in the individual patient should be made prior to deciding on whether or not fecal diversion is indicated.

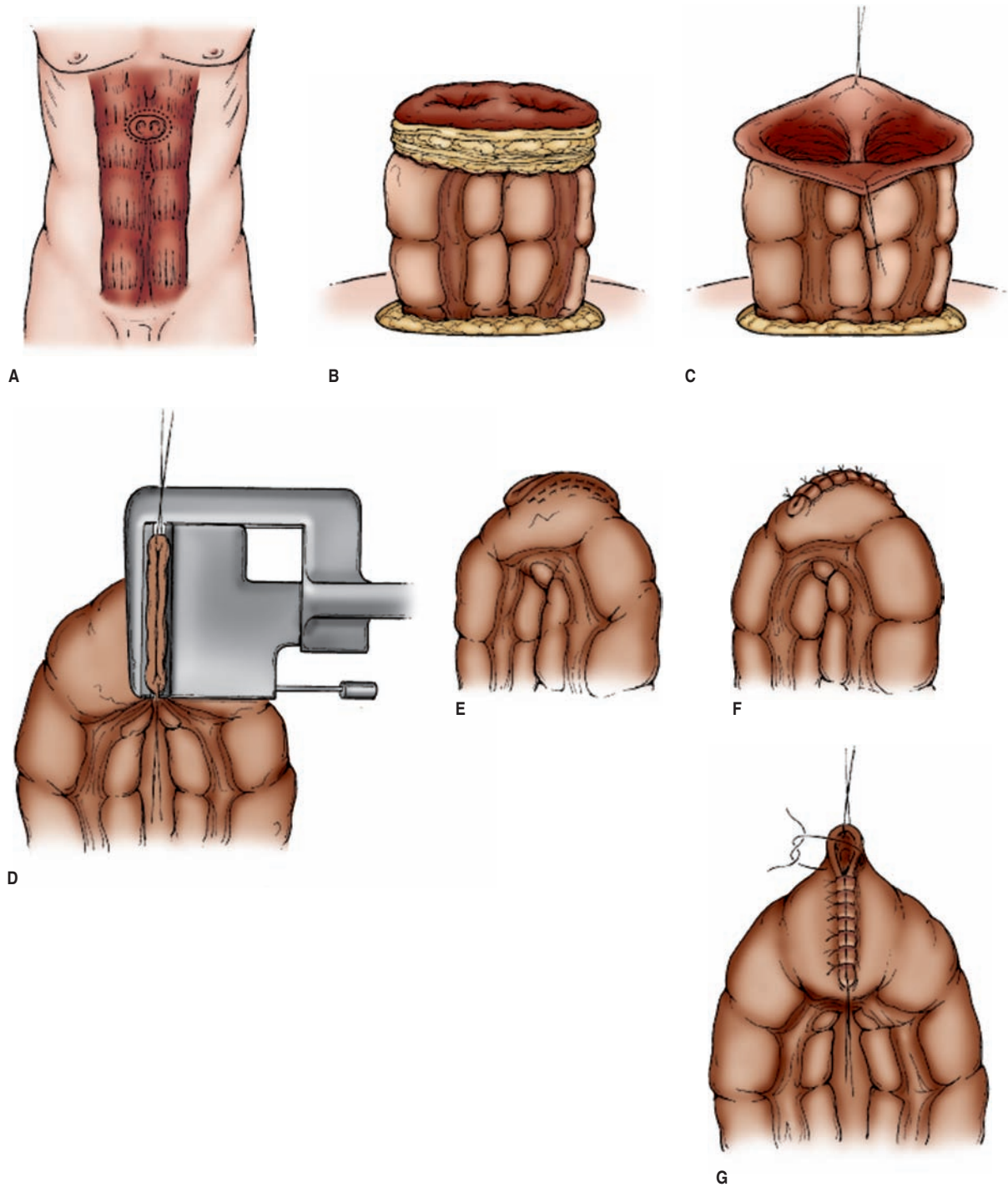
The closure is begun by making a circumferential incision around the stoma, including a small rim of skin (Fig. 9-4A). If the stoma has been placed in the midline, the midline incision may be opened on either side of it to allow adequate mobilization. The circumferential incision is deepened until the peritoneal cavity is entered and the colon and surrounding omentum can be separated from the abdominal wall. The colon is then brought through the incision, and the serosal surface is clearly defined circumferentially (Figs. 9-4B and 9-4C). This involves resecting omentum and fibrofatty tissue from the serosal surface. Once this step is completed, the stoma is ready for closure, which can be accomplished by a linear stapling device (Figs. 9-4D and 9-4E), by a hand-sutured closure (Figs. 9-4F and 9-4G), or if the bowel has been compromised in any way, by complete transection of the colon and construction of a formal end-to-end anastomosis. Caution must be taken to ensure that no small intestine has been injured and that no significant bleeding has been left unattended. Once this has been accomplished, the colon is returned to the abdominal cavity and the abdomen is closed. Usually the skin itself is left open for delayed primary closure.

## DIVERTING COLOSTOMY

A diverting colostomy is constructed to provide diversion of intestinal content. It is performed because the distal segment of bowel has been completely resected (as during abdominoperineal resection), because of known or suspected perforation or obstruction of the distal bowel (eg, obstructing carcinoma, diverticulitis, leaking anastomosis, or trauma), or because of destruction or infection of the distal colon, rectum, or anus (eg, Crohn's disease or failed anal sphincter reconstruction).

**Choices for Construction.** Although a completely diverting colostomy can be made only by complete transection of the colon, a well-constructed loop-transverse or sigmoid colostomy may provide near complete fecal diversion. Stool and flatus will move preferentially toward the low-pressure side of any pressure gradient, and this usually means that it will flow into the stoma appliance, which is at atmospheric pressure, rather than into the distal bowel. However, patients who have loop stomas must be counseled that if the stoma appliance becomes full, stool and flatus can be forced distally because the pressure gradient now favors passage of intestinal contents into the distal limb of intestine. This discussion should take place prior to discharge from the hospital, as this phenomenon usually occurs late





**FIGURE 9-4** Closure of a loop-transverse colostomy. **A**, A circumferential incision is made around the stoma, with reopening of the midline incision if needed. **B, C**, The colon is mobilized adequately. **D, E**, Staple closure of the colostomy. **F, G**, Suture closure of the colostomy.

at night after the patient has slept and not emptied their appliance. The first passage of flatus or stool per anus in a patient who was under the impression that their fecal stream was completely diverted can be sufficiently alarming as to prompt an emergent call to the surgeon, usually in the wee hours of the morning.

There are some situations in which the diverting loop colostomy fails to divert the flow of stool because the stoma retracts into the abdomen and stool flows into the distal colon. Patients who are profoundly malnourished may be at increased risk of this complication. In addition, stomas that are constructed under tension may also be prone to retraction.



If a colostomy is being performed proximal to an obstructing lesion, to decompress the colon and divert the flow of stool, it is critical that the distal limb of the colostomy be vented to the atmosphere and not closed. If the distal limb is closed and there is a complete obstruction distal to the colostomy, this will create a closed loop obstruction, and there is a substantial risk of distention and perforation.

If the rectum and anus have been completely resected, an end colostomy is created. If a partial colectomy/proctectomy has been performed, and an anastomosis is not constructed, an end colostomy is created and the distal bowel is closed (as in a Hartmann resection) or brought to the skin as a mucus fistula. The decision about whether to create a mucus fistula or to close the distal segment will hinge on whether there is concern regarding distal obstruction, the length of the distal segment, and the integrity of the distal segment. For example, in a patient undergoing sigmoid colectomy and colostomy for complicated diverticulitis, it is reasonable to close the rectal stump providing that proctoscopy reveals a normal rectum. Conversely, in a patient undergoing abdominal colectomy and ileostomy for toxic colitis, it may be preferable to bring the distal sigmoid to the skin level as a mucus fistula to avoid rectal stump blowout. A mucus fistula may be constructed as a separate stoma, opening just a corner of the closed end as a small vent. Alternatively, the mucus fistula can be constructed so that the small vent is matured ("mature" means that the colonic wall is sutured primarily to the skin) in a corner of the abdominal wall opening used to create the proximal stoma in the manner of Prasad and Abcarian (the "divided end-loop" stoma). This facilitates care in that the patient has only one stoma appliance, and facilitates stoma closure because both limbs of the bowel are located adjacent to one another. The old operation of the so-called Divine double-barreled colostomy should be abandoned because the adjacent full-diameter stomas make application of an appliance very difficult.

**Construction of an End Colostomy (Fig. 9-5).** An end, completely diverting, colostomy usually is located in the left lower quadrant, where the site is chosen preoperatively by placing a vertical line through the umbilicus and another line transversely through the inferior margin of the umbilicus and by affixing a disk, the size of a stoma faceplate to designate the stoma opening through the rectus muscle and on the summit of the infraumbilical fan fold (Fig. 9-5A).

Once a site is chosen, the patient should be evaluated in multiple body configurations to verify the adequacy of the stoma site. A common mistake is to choose the site with the patient supine and then find when the patient rises to a standing or sitting position that the chosen site is completely obscured by fat folds, scar tissue, or a protruding skeletal structure. The location should be adjusted up or down, even considering the use of upper quadrants of the abdomen if necessary, to allow proper fixation of an appliance and easy access by the patient. The site usually is marked with ink in the patient's room and then is scratched into the skin with a needle in the operating room

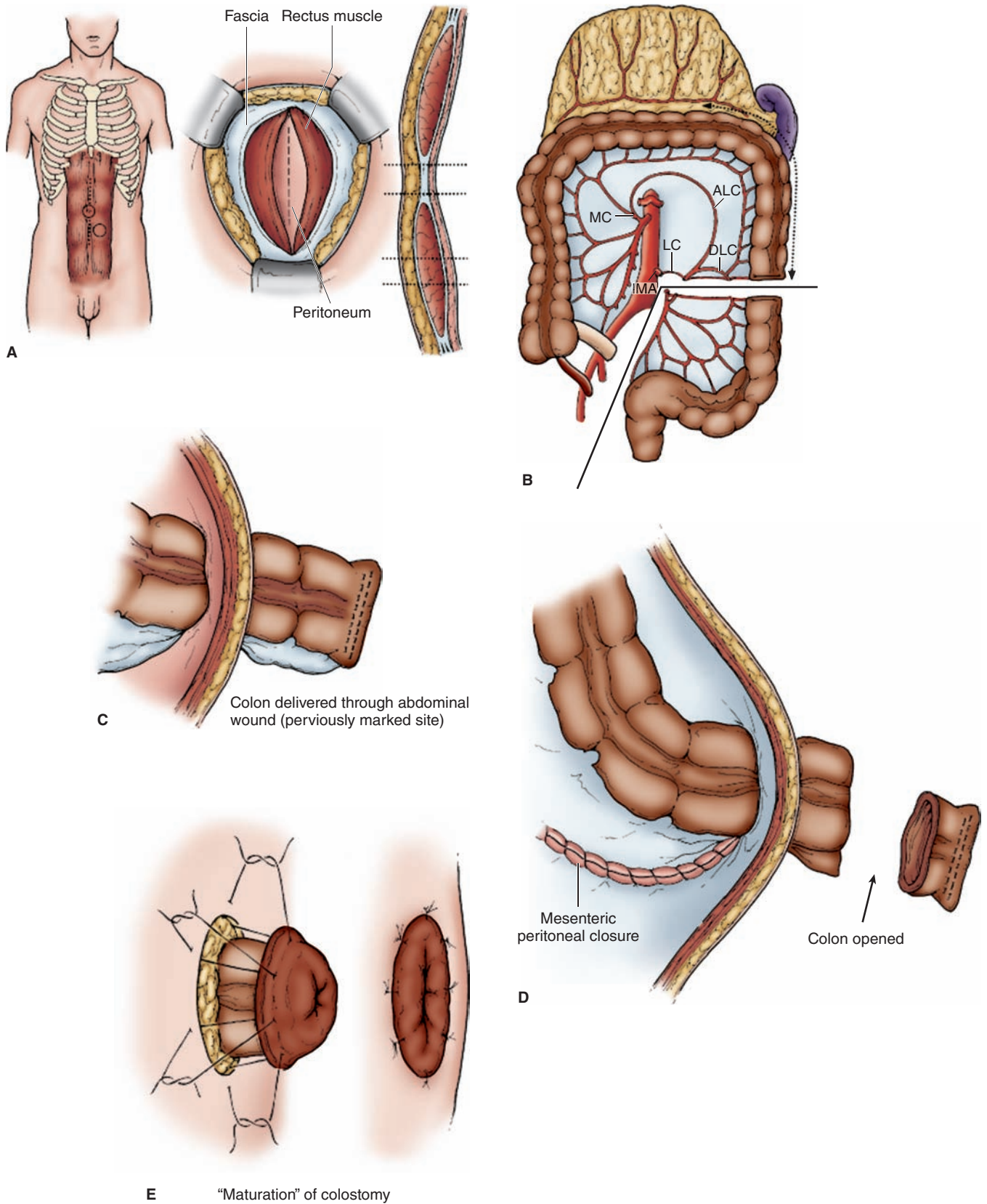
after induction of anesthesia. This is totally painless for the patient and does not leave a permanent tattoo should colostomy not be needed.

An end colostomy most often is constructed after removal of the rectum for low-lying malignancy (see Chap. 40). The entire left colon is mobilized on its mesentery, and depending on mobility of the colon and thickness of the abdominal wall, may require mobilization of the splenic flexure (Fig. 9-5B). If the patient has received neoadjuvant pelvic radiotherapy and/or the inferior mesenteric artery is transected at its origin at the aorta, the entire sigmoid colon should be removed because of concerns regarding ischemia and a descending colostomy created.

If the colostomy is to be brought through the left lower quadrant, an opening in the abdominal wall is made at the previously marked site by excising a 3 cm disk of skin. The undesirable oval configuration of a stoma is avoided by placing traction clamps in the dermis, the fascia, and the peritoneum. These clamps are held in alignment when the opening is made through the abdominal wall. This duplicates the configuration of the abdominal wall when the abdomen is closed and should allow construction of a desirable circular stoma.

The fat, fascia, muscle, and posterior peritoneum are incised longitudinally (Fig. 9-5A). The opening is then dilated, and the closed end of the colon is pulled through the abdominal wall (Fig. 9-5C). The mesentery of the colon can be sutured to the lateral abdominal wall with a running suture, although the complication of small bowel obstruction due to torsion of the small bowel mesentery around the colon mesentery has not been proven to be reduced by this maneuver. After the wound is closed and protected, attention is directed to completing the colostomy (Figs. 9-5C, 9-5D, and 9-5E). The stoma is completed by excising the staple or suture line and by placing chromic catgut sutures between the full thickness of colon and skin. If the stoma is constructed because of inflammatory bowel disease or radiated bowel, a spigot configuration is utilized by applying principles similar to those for ileostomy construction. This facilitates a good appliance seal for anticipated high-volume, liquid effluents.

Once the stoma construction is complete, an appliance is applied in the operating room. The simplest is a one-piece appliance with a skin barrier that can be cut to the appropriate size of the stoma. This same appliance can be used for colostomy and ileostomy. The appliance, which need not be sterile, is held in place with the skin adhesive of the appliance. Tincture of benzoin or other similar adhesives should never be used to maintain adhesion of an appliance to the skin because it has a high risk of initiating contact dermatitis. If colostomy function does not begin within 4 or 5 days, the stoma can be irrigated with small volumes (250 mL) of normal saline to initiate stoma function. The stoma nurses are involved early in the care of the stoma and in teaching the patient and family to provide long-term care of the colostomy. In some cases, the patient is taught the technique of stoma irrigation, and then each individual decides in the



**FIGURE 9-5** Construction of an end (diverting) colostomy. **A.** Selection of stoma location and technique of incision of the abdominal wall at the colostomy site. **B.** Technique of colonic mobilization and provision of adequate blood supply for the colostomy. **C, D, E.** Final stages of constructing a "mature" end colostomy. (LC, left colic artery; MC, middle colic artery; ALC, ascending left colic artery; DLC, descending left colic artery.)

more distant postoperative course if she or he wishes to irrigate the stoma or not.

## Long-Term Colostomy Management

The patient with a properly constructed, well-functioning colostomy may elect to irrigate once a day or every other day and to wear only minimal appliance over the stoma or simply cover it with a gauze in the intervening period, although the patient should be instructed to always carry an appliance should episodes of diarrhea occur. Simple appliances exist to allow absorption of mucus and deodorized passage of gas during the period between irrigations, if the patient elects to irrigate.

### IRRIGATION

The advantages of irrigating the colostomy include the absence of need for wearing an appliance at all times, the provision of a more regulated lifestyle, the reduced passage of uncontrolled gas, less leakage of stool between irrigations, and the general feeling of comfort that some people experience after irrigating the colostomy. The disadvantages are that it is a time-consuming ritual and that some people feel discomfort when the bowel is distended during irrigation. Irrigation carries a minimal risk of perforation. Absorption of water during the irrigation process can be significant, and the patient with an irritable bowel syndrome will usually not achieve adequate control by irrigation and may be frustrated by attempting to do so. The principle of irrigation is based on the fact that the distal colon displays a few mass peristaltic motions each day and that these can be stimulated by distention of the intestine. It has been shown that 80% of people who irrigate daily can depend on the discharge from the colostomy being one or two movements per day. Poor results from irrigation can be anticipated if the patient has irritable bowel syndrome, a peristomal hernia, irradiated bowel, inflammatory bowel disease, poor eyesight, reduced manual dexterity, or simply fear of dealing with the intestine at the abdominal wall. A preoperative history of irritable bowel syndrome is most important because these patients must never be promised regular function of their colostomies.

The technique of irrigation, usually performed in the morning, uses a cone tip that fits into the stoma only enough to provide a seal and to allow the instillation of 500–1000 mL of water. It is not necessary to dilate the stoma, and a finger is inserted only periodically to determine the direction for placement of the cone tip. Once the water has been instilled, a drainage bag is applied, and the individual can proceed with morning chores while the colostomy empties in response to the stimulation. Between irrigations the patient usually wears a security pouch, which permits passage of gas through a charcoal filter and provides a small pad to absorb any mucus normally secreted by the colonic mucosa.

Ischemia or infection causing partial loss of the intestinal wall or separation of the stoma from the skin can result in

stricture of the colostomy. A tight stricture makes irrigation impossible and frequently causes the patient significant discomfort because of the resulting partial obstruction. Because the stricture is always at skin level, its correction is simple and no patient should suffer because of a colostomy stricture.

## Colostomy Complications

### GENERAL CONSIDERATIONS

A common problem experienced by the patient with a colostomy is irregularity of function, which most often is related to irritable bowel syndrome or irradiation of the intestine. Many problems are related to improper location of the stoma, which allows seepage of mucus and maceration of the skin because an appliance seal cannot be adequately maintained. Parastomal hernia formation is common, and prolapse less so. Patients experience episodes of diarrhea and constipation depending on their underlying disease, dietary habits, and episodic infections. Patients with colostomies can be troubled with gas and odor problems because there is no sphincter around the stoma and gas can be passed uncontrollably. However, most appliances today are odor-proof, making odor only an issue during changing or emptying the appliance. This problem is usually regulated by diet, and in some cases by administering mild antidiarrheal agents when social activity dictates. Minimal bleeding around a stoma is common because the mucosa is exposed to environmental trauma. Of course, prolonged bleeding should be evaluated to be sure that there is not a recurrence of the primary disease process. The same is true of cramps and diarrhea. These can be acceptable occasionally, but anything of a prolonged or severe nature must be evaluated.

Evaluation of the UOA data registry shows that hernia formation is the most common complication of end colostomy, with obstruction, abscess, and fistula presenting less frequently. Of all the complications that occur, few require surgical correction. Fecal impaction can occur with a colostomy and can be managed by irrigation and laxatives. Digital disimpaction is rarely required.

### STOMA STRICTURE

In the past, it was believed unsafe to open the colon and suture the edges to the skin at the time of initial operation and stomas were thus opened in a delayed fashion. Serositis developed because the serosal surface of the exposed colon was irritated by exposure to air. After the exposed end of the colon was opened, it would take some time for the mucosa to eventually aneal to the epidermis. This process was called “maturation” of the colostomy. Strictures were common because the inflammation associated with serositis often led to fibrosis. Surgeons eventually learned to open stomas immediately at the time of initial operation and suture the intestinal wall to the skin. For historical reasons,



this maneuver is still referred to as immediate “maturation” of the stoma.

Another cause of colostomy stricture is ischemia, usually as a result of resection of too much mesentery during construction of the stoma, or from inadequate mobilization and tension. Repair may require a simple local procedure if the stricture is focal at the skin level, or revision of the stoma via a transabdominal approach if the stricture involves a longer segment.

### COLOSTOMY NECROSIS

Ischemia or necrosis of the colostomy results from excessive resection of colonic mesentery, excessive tension on the mesentery leading to the stoma, creation of a fascial opening too small to accommodate the bowel and its mesentery, or poor perfusion due to low-flow states. The blood supply to an end colostomy is unidirectional, without collaterals; therefore, it will be most sensitive to changes in visceral perfusion. If the necrosis is limited to the area of the stoma anterior to the fascia, it may be observed carefully, and stoma revision performed electively at a later date, if necessary. If the necrosis extends into the peritoneal cavity, the abdomen should be explored and the stoma recreated. In some cases it is difficult to ascertain the extent of necrosis. Gentle flexible endoscopy via the stoma is an accurate method to determine the level of necrosis. Occasionally it may be possible to use a glass test tube and light to make this determination, but endoscopy is more reliable.

### PARACOLOSTOMY HERNIA

Paracolostomy hernia is a frequent complication of colostomy creation, even when all is done according to acceptable surgical principles. The creation of an abnormal opening in the abdominal wall that is then subjected on a daily basis to the pressures of Valsalva maneuvers may predispose the patient to suffer a gradual enlargement of the fascial opening. The relative weakness of the posterior rectus sheath in the inferior abdominal wall, with the potential space that exists alongside the rectus muscle, may also predispose the patient to develop a peritonealized sac in the rectus sheath without a large fascial defect. Although it is surgical dogma to create stomas in the rectus sheath to lessen the development of parastomal hernias, there are no definitive data to support this contention.

Asymptomatic parastomal hernias should be observed because the rate of recurrence after repair or relocation of the stoma is high. Patients should be counseled to seek immediate medical attention if they develop symptoms or signs of intestinal incarceration in the hernia. Symptomatic hernias may be relocated or repaired, although no technique has proven to be reliably successful. Local suture repair often fails, and although broad fascial mesh repair appears to be a more rigorous method of repair, there is still a substantial risk of recurrence and the added concern of mesh infection. Laparoscopic repair with intraperitoneal mesh is being used more

frequently, although it would appear to offer no advantage over open mesh repair other than a potential reduction in wound complications and short-term postoperative recovery. Some surgeons are placing mesh in the abdominal wall at the time of permanent stoma creation as prophylaxis against hernia formation, but the experience is too preliminary to make definitive assessments of the safety and efficacy of this technique.

### COLOSTOMY PROLAPSE

Prolapse of the colostomy is seen most often with the transverse loop colostomy. This is probably the result of several factors, most prominent being the lack of fixation of the transverse mesocolon to the retroperitoneum, and the size of the fascial opening necessary to bring both limbs of the colon and the mesocolon to the skin level. If the transverse loop colostomy is constructed to decompress a dilated colon, the fascial opening may need to be large initially, and then be excessive once the colon decompresses and thus predispose the colostomy to prolapse later. The surgical treatment of transverse loop colostomy prolapse is difficult, and the best treatment is to rid the patient of the primary disease and restore intestinal continuity. If this is not possible, the loop colostomy should be converted to an end colostomy with mucous fistula, or a divided end-loop colostomy, with concurrent tightening of the fascial defect.

Prolapse of an end colostomy can be managed by a local procedure in which the mucocutaneous junction is disconnected, the redundant colon resected, and the mucocutaneous junction recreated. Concurrent hernia repair can be performed as indicated.

### COLOSTOMY PERFORATION

Perforation of the colon just proximal to the stoma most often occurs during careless irrigation with a catheter or during contrast x-ray studies when a catheter is placed in the colostomy and a balloon is inflated. This occurrence represents a surgical emergency and must be dealt with by laparotomy and reconstruction of the colostomy with adequate drainage, if there is significant fecal or barium contamination. Cases of mild inflammation with extravasation of air can only be managed with antibiotics and localized drainage, and surgery can be avoided.

### ILEOSTOMY

An ileostomy is an opening constructed between the small intestine and the abdominal wall, usually by using distal ileum, but sometimes more proximal small intestine. The stoma is constructed on a permanent basis for patients who require removal of the entire colon, and usually the rectum, for inflammatory bowel disease, either Crohn's disease or ulcerative colitis. The use of a loop ileostomy is becoming more frequent because of the complex sphincter-preserving operations being



performed for ulcerative colitis, familial polyposis, and rectal cancer. For these operations, it is necessary to have complete diversion of intestinal flow while the distal anastomosis and neorectum are allowed to heal and adapt. The loop ileostomy is also useful in cases where multiple or complex anastomoses must be performed distally, usually for Crohn's disease or diverticulitis. As sphincter-preserving operations are used more often, diminishing numbers of permanent ileostomies will be constructed, but similar principles and techniques will be utilized in constructing the temporary loop ileostomies. The same principles used in constructing an ileostomy can be applied to the construction of a urinary conduit.

The surgical construction of an ileostomy must be more precise than that for a colostomy because the content is liquid, high volume, and corrosive to the peristomal skin. Therefore, the stoma must be accurately located preoperatively, and it must have a spigot configuration to allow an appliance to seal effectively and precisely around the stoma.

Various types of ileostomies can be constructed. The most common has been the end ileostomy, using a technique popularized by Brooke and Turnbull. The loop ileostomy is used, as described, to divert stool away from diseased areas or surgical anastomoses distally. The loop-end ileostomy is a stoma that uses the principles of a loop ileostomy but is constructed as a permanent stoma when the mesentery and its blood supply need special protection. The continent ileostomy, a technique devised by the Swedish surgeon, Nils Kock, is an internal pouch that does not require the wearing of an external appliance. The urinary conduit is a stoma constructed of small intestine to provide a conduit to the outside for the urinary tract.

## Determination of Ileostomy Location

The location of the ileostomy must be carefully chosen before surgery (Fig. 9-6). It should avoid any deep folds of fat, scars, bony prominences of the abdominal wall, the inguinal folds, and the waistline crease. The site is chosen by drawing a vertical line through the umbilicus and a transverse line through the inferior margin of the umbilicus and applying a disk the size of a stoma faceplate (approximately 8 cm in diameter) to determine the location. The disk is allowed to abut on both of the lines in the right lower quadrant, and the site is marked with ink. The patient is then brought to an exaggerated sitting position and allowed to turn in various directions to be sure the site is adequate in all positions, and there are no creases or skin folds created by changes of position. If so, the location should be adjusted to bring the stoma to the summit of the infraumbilical fat fold to be sure that there is clearance for fitting of an appliance. When the patient is in the operating room and anesthesia has been administered, the chosen site is scratched with a fine needle before preparation of the abdominal skin is carried out. The majority of complications arising from ileostomies can be avoided by taking these precautions in marking the site for the stoma preoperatively. Even in cases in which the use of a stoma seems remote, the precaution of marking the site

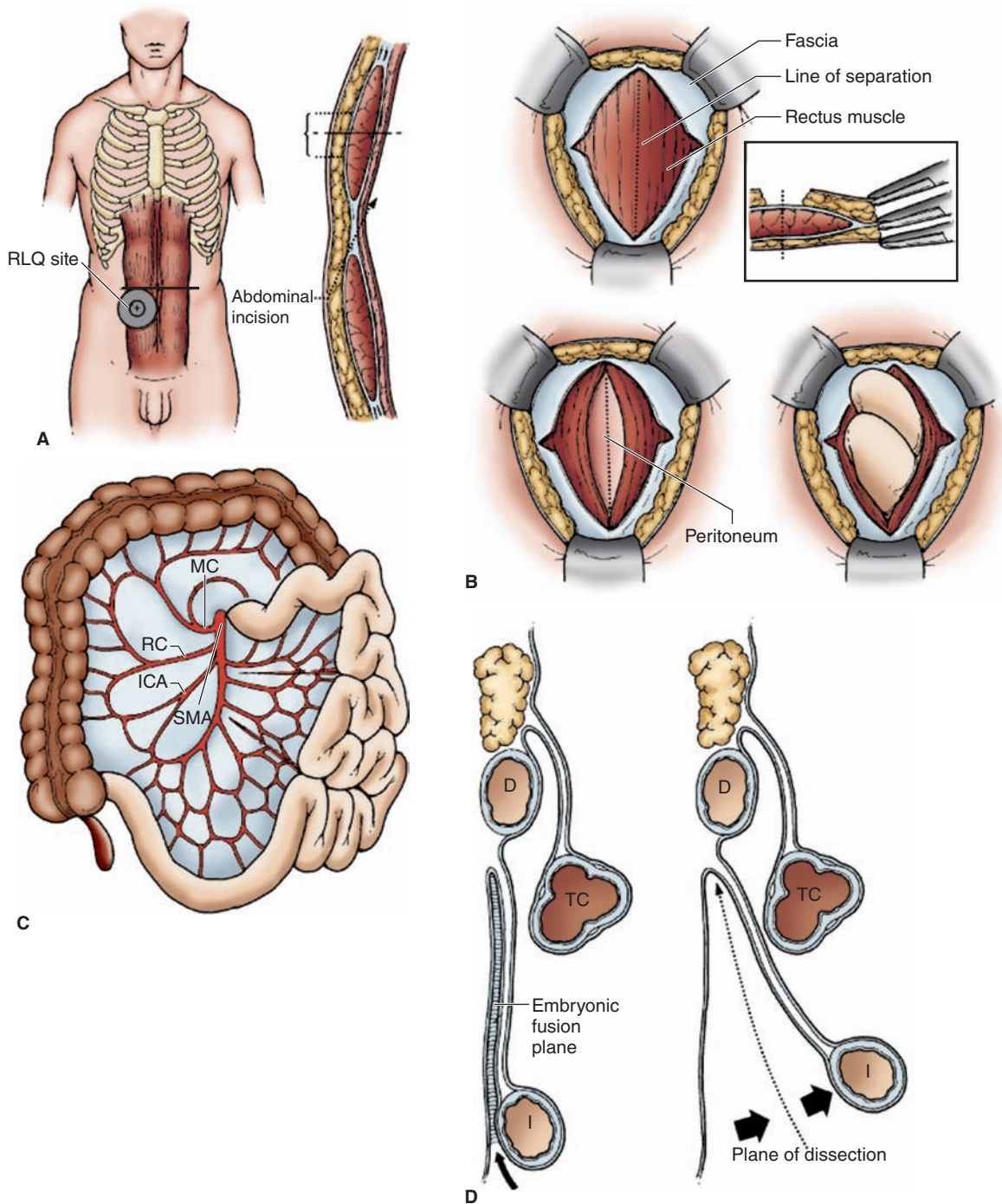
preoperatively should be taken. In addition, whenever possible, patients should be seen by a CWOCN and an ostomy visitor so that they can be given information about the stoma and its care. The visit from an ostomate (someone who has done well with a similar stoma) is helpful because it allows the patient to know that the surgery can be survived and that life can be continued productively and normally with the presence of a stoma. The discussion should avoid excessive details about types of equipment and types of stoma problems during the postoperative period, as this information can be overwhelming to a patient facing complex surgery, often life-threatening disease processes, and the concept of having a stoma.

When an ileostomy is anticipated, the choice of abdominal incision is a left paramedian skin incision, slanting the incision to the midline fascia (Fig. 9-6A). This gives the advantage of opening the fascia through the midline to provide a simple, effective closure and at the same time preserve all the right lower quadrant peristomal skin for maintenance of the appliance seal.

## End Ileostomy

The construction of the ileostomy begins early in the operative procedure. When the colon is mobilized for colectomy, as is the usual case when an ileostomy is to be constructed, full mobilization of the mesentery of the distal ileum should be carried out (Fig. 9-6D). This is an important and often neglected part of the procedure. There is an embryonic fusion plane of the mesentery of the small intestine to the right posterior abdominal wall. The ileum can be elevated on this mesentery up to the duodenum, allowing extreme mobility of the terminal ileum. The ileocolic artery is then transected as part of the colectomy, and the remaining blood supply to the small intestine is preserved (Fig. 9-6C). It is important to preserve the most distal arcade of vessels and mesenteric tissue on the ileum at the segment of the intended ileostomy. This blood supply is prepared early in the operative procedure so that if there is any question about the vascularity of the distal ileum, it will be known long before the abdomen is closed. The preservation of this distal bit of mesentery and fat on the ileum sometimes appears to cause excess bulk around the ileostomy, but this fat soon atrophies, allowing a well-vascularized stoma of appropriate size. The intestine is transected with a linear-cutting type of stapling instrument so that the end of the ileum can be easily pulled through the abdominal wall without increased risk of contamination. This can, of course, also be accomplished by suturing the end of the ileum.

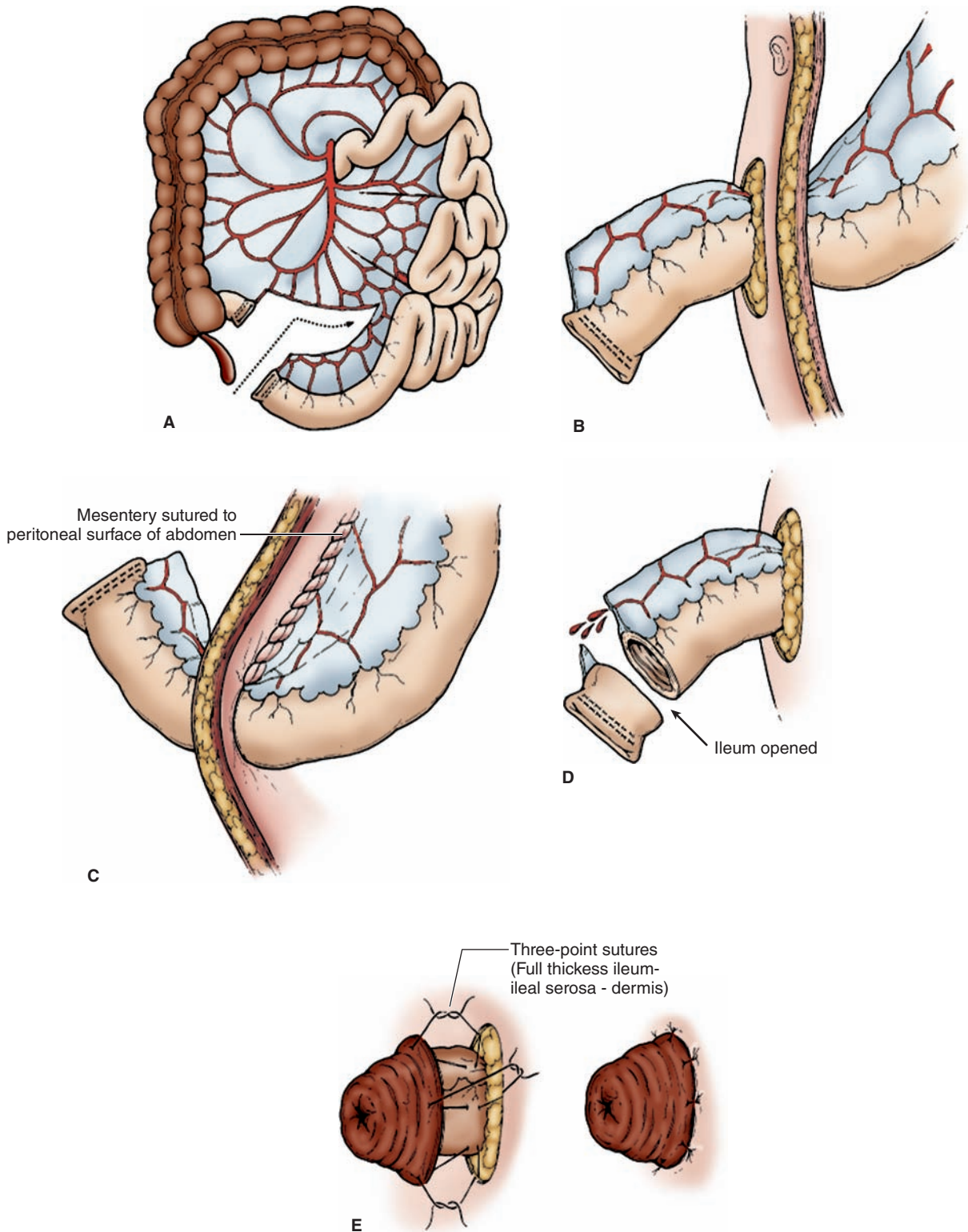
When the intestinal resection has been completed, an opening is prepared in the right lower quadrant of the abdominal wall at the previously marked site (Fig. 9-6B). It is important to return the abdominal fascia to its natural position prior to making the stoma opening so that the fascia does not impinge upon the stoma when closed. This is of significant concern during situations when a Pfannenstiel incision is used to accomplish the colectomy, as is common with hand-assisted laparoscopic colectomy. The round configuration of the stoma



**FIGURE 9-6** General considerations in construction of an ileostomy. **A.** Locating the ileostomy site and the use of a paramedian skin incision that slants to the midline fascia, allowing preservation of the peristomal skin. **B.** Technique for making the abdominal wall opening. **C.** Vascular supply of the distal ileum, which must be used to maintain viability of the ileostomy. (MC, middle colic artery; RC, right colic artery; ICA, ileocolic artery; SMA, superior mesenteric artery.) **D.** Plane of mobilization of the distal ileum to allow construction of an ileostomy without tension. (P, pancreas; D, duodenum; TC, transverse colon; I, ileum.)

is maintained by placing traction clamps on the dermis, fascia, and peritoneum. A 3 cm disk of skin is excised, and a longitudinal incision approximately 3–4 cm long is made through all layers, with each layer being retracted with small retractors as the incision is deepened. If the patient is obese, some fat

can be excised, although this is not mandatory. The fascia is incised longitudinally as well, and frequently a small lateral notch is placed on each side. The muscle is separated, and any vessels are coagulated. The posterior fascia and peritoneum are then incised.



**FIGURE 9-7** Construction of an end ileostomy. **A.** The distal arcade of vessels and some mesentery are preserved on the segment to be used for ileostomy construction. **B.** The closed ileum is pulled through the abdominal wall to a length of 6 cm. **C.** The mesentery of the ileum is fixed to the abdominal wall. **D.** The adequacy of the blood supply is verified. **E.** The spigot configuration is achieved by placing sutures to include full thickness of intestine, the seromuscular layer at the base of the stoma, and the dermis.



The size of the stoma opening should be approximated based on estimates of the diameter of the intestine and mesentery to be brought through, and the thickness of the abdominal wall. The geometric shape of the stoma opening should also be determined by these factors. If the abdominal wall is thin, the opening in the abdominal wall can be cylindrical. If the abdominal wall is thick, the shape of the incision should be pyramidal, with the fascial opening larger than the skin opening to accommodate the amount of mesentery that will be brought through at the fascial level. The oft-used “two finger” rule to gauge the size of the stoma opening is usually not adequate to account for all of the above considerations.

The ileum is brought through the abdominal wall to the intended length, usually about 6 cm (Fig. 9-7B). If the abdominal wall is thick, this maneuver may be difficult to accomplish. It may be helpful to use a small plastic wound protector/retractor through the stoma to facilitate passage of the intestine through the abdominal wall. Alternatively, the fat and skin can be raised off of the fascia as a flap, the intestine brought through the muscle and fascia first, and then subsequently brought through the fat to skin level. The mesentery of the distal ileum may be sutured to the right lateral abdominal wall, although there are no data to prove that this maneuver reduces the incidence of intestinal obstruction, stoma prolapse, or stoma retraction.

The abdomen is then closed. The incision is protected, and attention is directed to the ileostomy where the staple line or suture line is excised, verifying the adequacy of blood supply. If the blood supply of the stoma is questioned, more of the ileum should be resected.

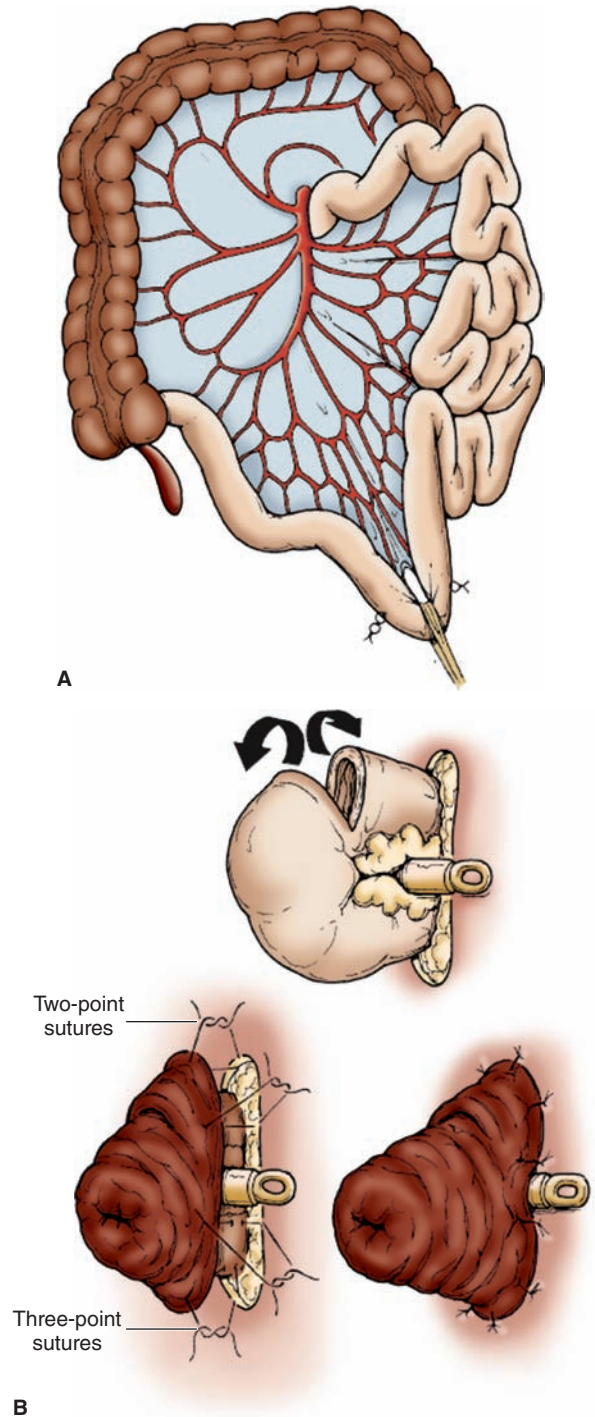
The next objective is to make a protruding, everting stoma. This is accomplished by placing 3-0 chromic catgut sutures through the full thickness of intestine, the seromuscular area of the ileum at the base of the stoma, and the dermis (Fig. 9-7E). Sutures through the skin should be avoided, because any stellate scarring will prevent the maintenance of the required seal of the appliance. Eight of these sutures should be placed, one in and one between each quadrant; and as traction is applied after they are all placed, the stoma should evert nicely.

After the stoma is completed, an ileostomy appliance is applied. A simple appliance in which the skin barrier can be cut to the size of the stoma is best. In the immediate postoperative period, if there is any question about leakage around the appliance or malfitting of the appliance, it should be changed and the skin cleaned immediately. It is important to preserve the integrity of the peristomal skin, and all the nursing staff should be aware of the importance of this. The leaking appliance should not be left for changing by the next shift or for the CWOCN the next morning, because the skin can be damaged during this waiting period.

## Loop Ileostomy

The loop ileostomy stoma is constructed when both diversion of the intestinal flow and decompression of the distal intestine are required. The location is chosen exactly as one would choose the site for an end ileostomy. The construction can

then follow one of two techniques. The technique popularized by Turnbull at the Cleveland Clinic involves choosing the site in the intestine for the intended loop ileostomy and then placing orienting sutures proximally and distally (Fig. 9-8A). A loose suture with one knot can be placed proximally and



**FIGURE 9-8** Construction of a loop ileostomy. **A.** A tracheostomy tape is placed at the segment for the intended ileostomy with sutures to identify proximal and distal limbs. **B.** The loop is pulled through the abdominal wall while its proper orientation is maintained. The tape is replaced by a plastic rod, and the spigot configuration is completed.



one with two groups of knots distally. It is important to maintain this orientation as the stoma is constructed.

The opening in the abdominal wall is made the same as for an end ileostomy (Fig. 9-6B), but the loop of intestine is drawn through this abdominal opening by a tape placed through the mesentery and around the intestine (Fig. 9-8A). Some surgeons recommend orienting the proximal functioning loop in the inferior position, placing a partial twist on the loop of intestine. Although this may help configure the spout of the ileostomy so that ileal effluent is less likely to undermine the appliance, this maneuver may be associated with a higher rate of intestinal obstruction. In massively obese patients with a shortened mesentery, it is necessary to make a pyramidal configuration of the opening in the abdominal wall, with the internal opening being much larger than the external opening at the skin. If this maneuver is used, it is best to place a row of tacking sutures between the peritoneum and the loop of intestine to maintain position and orientation. Once the loop is drawn through the abdominal wall, the abdomen is closed, maintaining the orientation of the loop. It is usually not necessary to fix the mesentery of the ileum to the abdominal wall when constructing a loop ileostomy. The wound is then protected, and attention is directed to the stoma.

The tape is replaced by a small plastic rod, which is commercially available (Fig. 9-8B). It is not sutured to the peristomal skin, but it often has a heavy suture tied around each side so that should the rod dislodge, it can be drawn back through the mesentery rather than being pushed through, with risk of injuring the mesentery. The loop of intestine is opened by making a four-fifths circumferential incision at the distal aspect of the loop, allowing 1 cm of ileum above the skin level in the superior aspect (Fig. 9-8B). The recessive limb thus is formed distally, and sutures are placed between the full thickness of ileum and dermis at this level. As the proximal aspect of the stoma is constructed, sutures are placed as previously described between the full thickness of ileum, the seromuscular area at the base of the stoma, and the dermis. As these sutures are tied, the stoma should assume a spigot configuration supported by the rod. The ileostomy appliance may be placed beneath the rod or over the rod, depending on the tension of the mesentery. The rod is left in place for 1 week, and the same ileostomy care is provided as previously described.

Another technique for constructing a completely diverting ileostomy is to use the divided end-loop method popularized by Abcarian and Prasad (Fig. 9-9). This technique involves transecting the ileum with a linear-cutting stapling instrument. No compromise of the mesentery is involved. The opening in the abdominal wall is made in identical fashion to that previously described, but when the intestine is pulled through, the proximal component is excised, and the stoma is constructed as previously described for an end ileostomy. The recessive limb at the base of the stoma has one corner of the staple line excised, and the full thickness of ileum is sutured to the dermis at the superior aspect of the stoma.

This allows a small recessive limb that serves to decompress the distal intestine.

If a loop ileostomy cannot be brought to skin level because of obesity and/or tension on the mesentery (a situation most often encountered following restorative proctocolectomy), it may be helpful to create a divided end ileostomy to achieve more length. The ileum at the site chosen for ileostomy is divided and the proximal end brought out as an end stoma. The distal end is left closed in the peritoneal cavity or abdominal wall. This maneuver will sometimes result in formal laparotomy being required to close the stoma, but is a better alternative than a flush ileostomy.

### CLOSURE OF LOOP ILEOSTOMY

When endoscopic procedures and contrast studies have shown that the pouch is intact or that the distal anastomoses have healed securely, consideration can be given to closing the loop ileostomy. If the primary procedure has involved the anal sphincter mechanism, careful physical examination and manometric studies should verify the adequacy of sphincter function before intestinal continuity is restored.

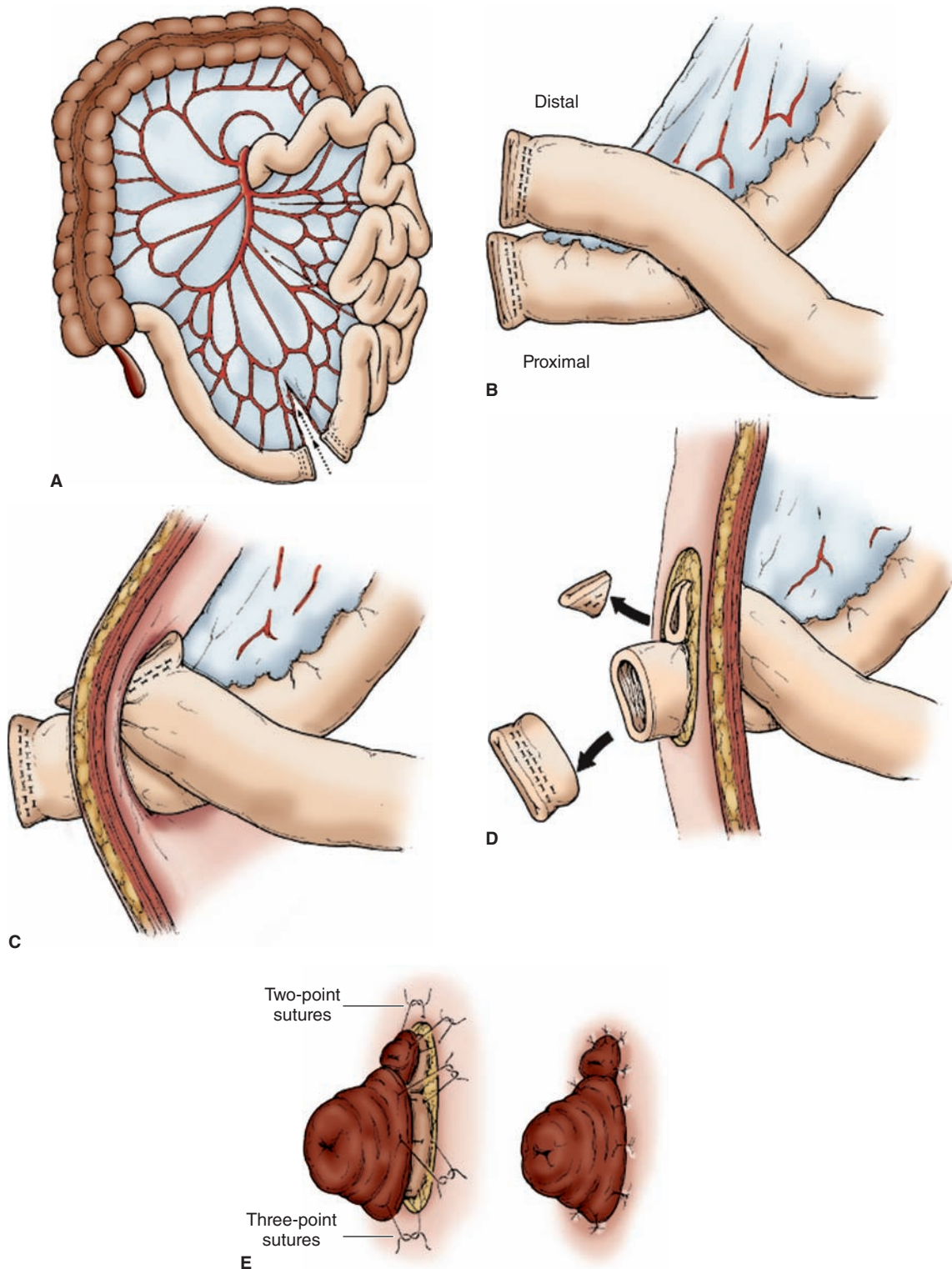
For closure of the loop ileostomy (Fig. 9-10), a circumferential dissection is carried out, with a minimal rim of skin included, until the peritoneal cavity is entered and clean peritoneal surface of abdominal wall can be palpated circumferentially. Once this is accomplished, the loop of intestine can usually be brought easily through the circular incision in the abdominal wall. Closure is completed by excising the rim of fibrous tissue, with care being taken to preserve as much of the viable intestinal wall as possible (Figs. 9-10B and 9-10C). The choice of closure then varies between hand-sutured transverse closure (Figs. 9-10D and 9-10E), stapled transverse closure (Figs. 9-10F and 9-10G), or formal construction of an anastomosis.

For closure of the separated (divided end-loop) ileostomy (Fig. 9-11), the mobilization is carried out in similar fashion, and a functional end-to-end closure is performed. A linear-cutting stapler is applied and removed, and the enterotomy is closed transversely. The intestine should be rotated so that antimesenteric surfaces are used for the staple line.

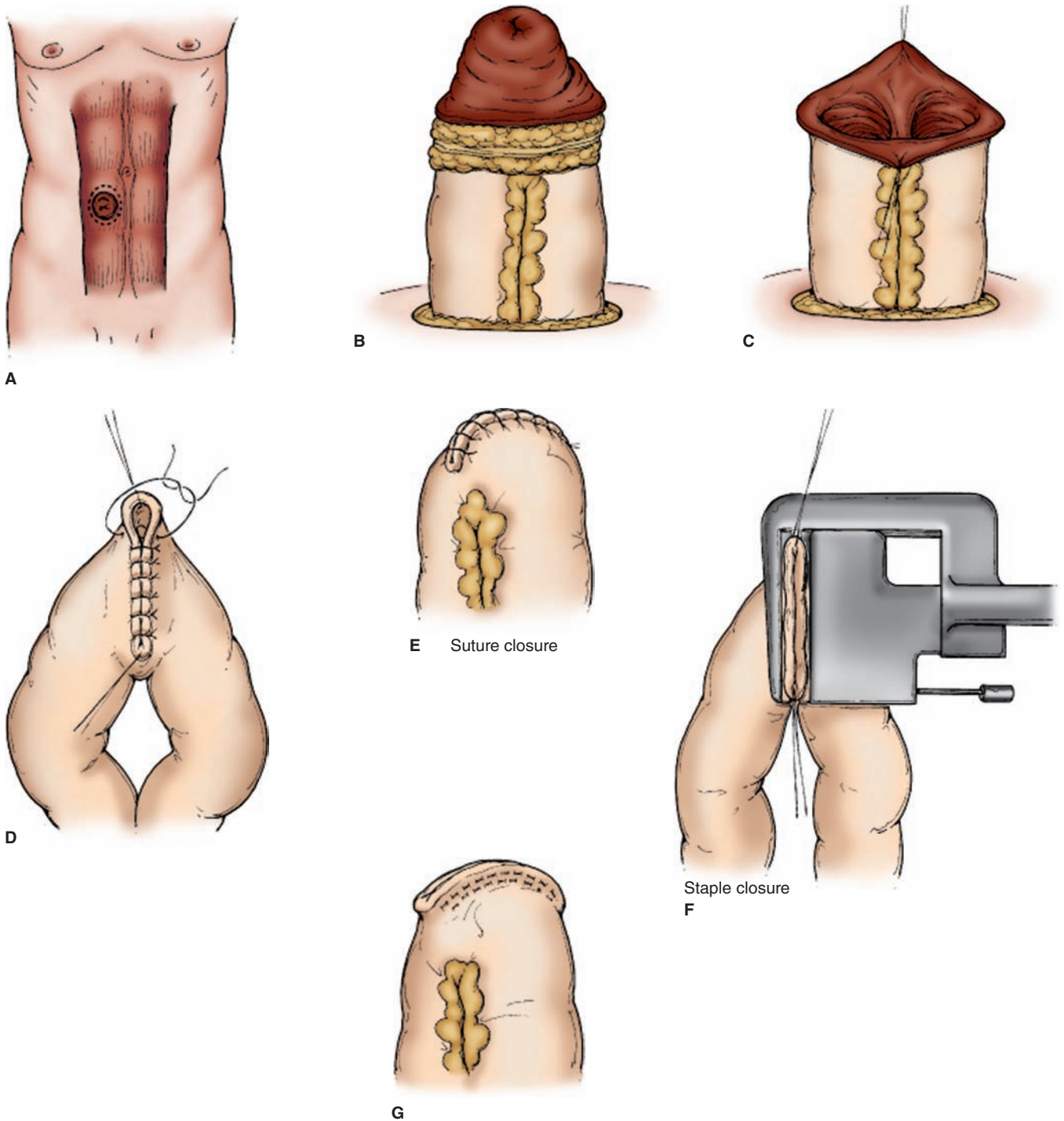
After intestinal continuity is restored, the abdominal wall is closed. Because of the risk of skin infection, many surgeons are reluctant to close the skin primarily. Rather, the skin defect can be handled by a number of alternative methods: closure over a drain; partial closure in linear fashion; or partial purse-string closure.

### LOOP-END ILEOSTOMY

A loop-end ileostomy should be constructed in the rare circumstances in which it is unsafe to resect the mesentery of the distal ileum or when there is tension created on the mesentery as the ileum is brought to the abdominal wall for construction of the ileostomy. This occurs in the patient with a thickened mesentery or a very obese abdominal wall, or in a patient who has had multiple surgical procedures that altered the mesentery. These conditions preclude dealing with the usually

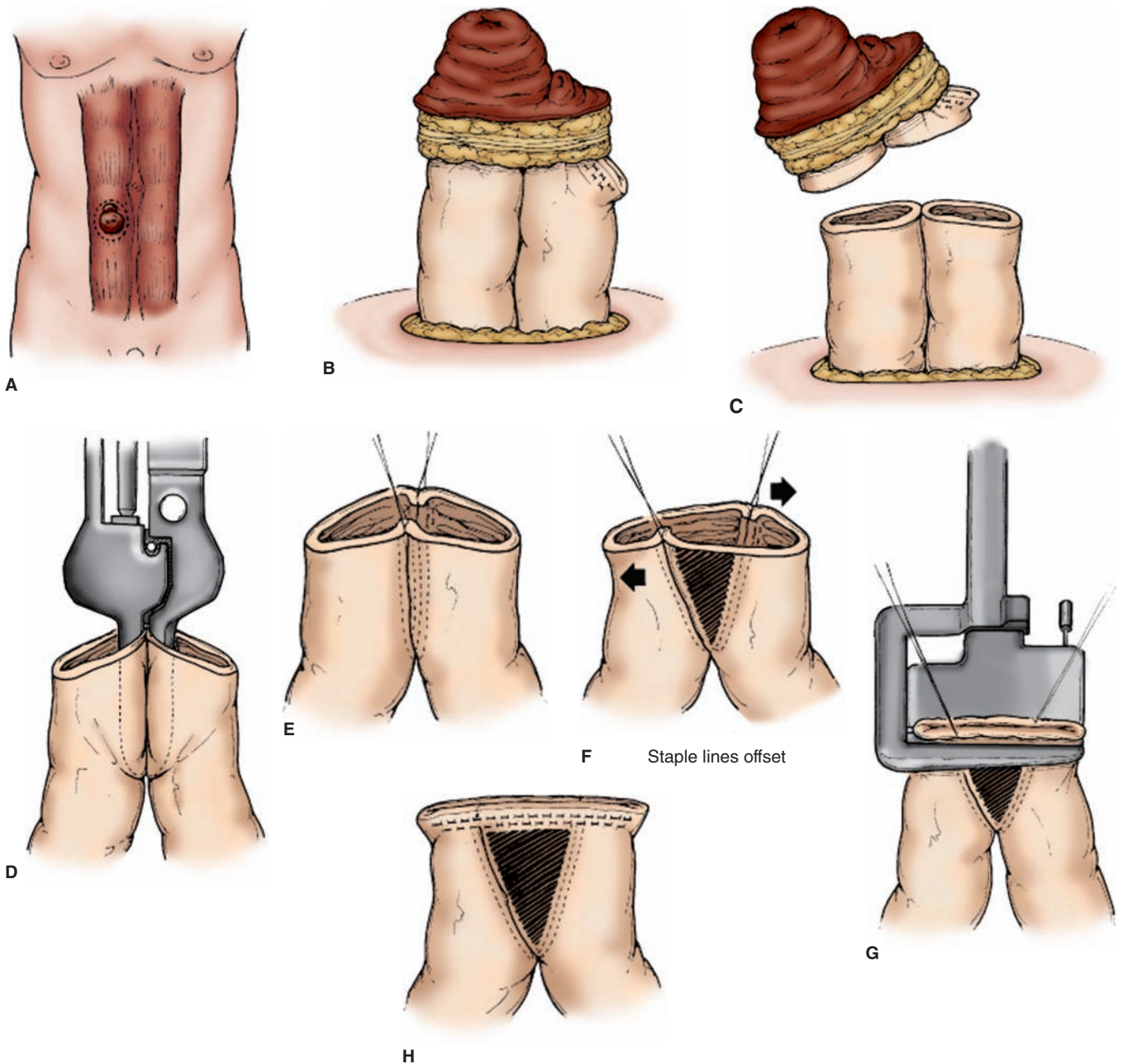


**FIGURE 9-9** Construction of a separated (divided end-loop) ileostomy. **A.** The distal ileum, but very little of the mesentery, is transected, using a linear-cutting stapler device, in preparation for constructing the ileostomy. **B, C.** The proximal, functioning component is brought through for spigot construction, whereas only the corner of the distal component is brought through. **D.** The entire staple line of the proximal component and a corner of the distal component are excised. **E.** The functioning spigot and nonfunctioning recessive opening are completed.



**FIGURE 9-10** Closure of a loop ileostomy. **A.** A circumferential incision is made and carried into the peritoneal cavity. **B.** The loop of intestine is completely mobilized. **C.** The fibrofatty tissue is completely excised, preserving all the intestine. **D, E.** A suture closure can be performed, or a transverse stapled closure (**F, G**) can be performed.





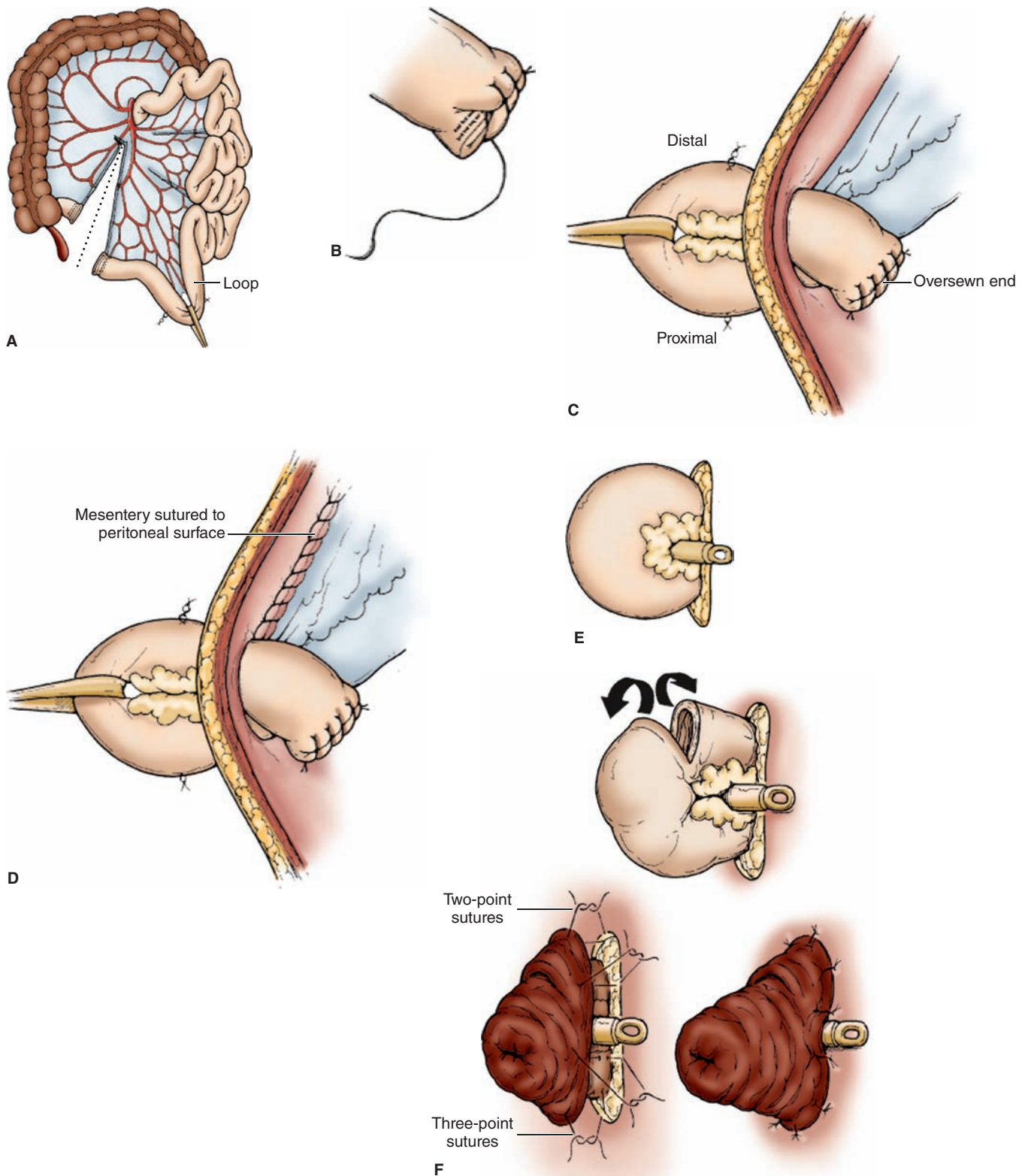
**FIGURE 9-11** Closure of a separated (divided end-loop) ileostomy. **A**, A circumferential incision is made and carried into the peritoneal cavity. **B**, **C**, The stoma site and residual staples are excised. **D**, A linear-cutting stapler is applied to the antimesenteric side of the intestine. **E**, **F**, The components of the staple line are offset. **G**, **H**, The functional end-to-end closure is completed with a linear stapling instrument.

pliable mobile tissue. This technique is especially useful in the obese patient who requires construction of a urinary conduit after cystectomy and radiation. The technique is especially helpful because a supporting rod can be placed beneath the stoma for 1 week to help avoid retraction through a thick abdominal wall (Fig. 9-12).

Constructing a loop-end ileostomy involves transecting the ileum as previously described, but the closed end will remain closed (Fig. 9-12A). The staple line is inverted with

seromuscular sutures, or if it is to be used for a urinary conduit, only absorbable sutures are used to close the end of the ileum, because stone formation has been reported around staples (Fig. 9-12B). The orienting sutures are then placed as described for construction of a loop ileostomy, and a tracheostomy tape is placed so that when the loop of ileum is pulled through the abdominal wall, the closed recessive end will be superior and just within the abdominal cavity (Fig. 9-12C). The construction of the loop-end stoma then proceeds exactly





**FIGURE 9-12** Construction of a loop-end ileostomy. **A.** A tracheostomy tape is placed around the loop of intestine, with the mesentery mobilized but completely preserved. **B.** The end of the ileum is inverted. **C.** The intestine is pulled through the abdominal wall so that the functional limb will be in the inferior position, and the closed end is allowed to reside just within the abdominal cavity. **D.** The mesentery of the ileum is fixed to the abdominal wall because this is meant to be a permanent stoma. **E.** The tracheostomy tape is replaced with a small plastic rod. **F.** The stoma construction is completed exactly the same as described for a loop ileostomy.

as that described for the loop ileostomy (Figs. 9-12D, 9-12E, and 9-12F). However, in the case in which the stoma will be permanent, the mesentery of the distal ileum is fixed to the abdominal wall (Fig. 9-12D). If the stoma will be used as a urinary conduit, the loop of the conduit should be brought through the abdominal wall before the ureteral anastomoses have been carried out. It is a disconcerting problem to have the ureters fixed and then find there is an inadequate length of ileum to bring through the abdominal wall. It is also easier to place the ureteral stents when the construction is done in this fashion.

A special problem has been found in patients with a loop-end ileostomy in that there continues to be mucus secretion from the recessive limb, and after a period of several months, this secretion may interfere with the perfect seal of the ileostomy appliance. If interference does occur, it may be necessary to resect the distal limb and convert the stoma to a proper end ileostomy. This is a small price to pay, however, because it is an easy operation to remove the recessive limb, and it can be done without opening the abdominal cavity. Of more importance is the fact that the loop configuration during the initial procedure has allowed maintenance of blood supply and a protruding configuration under circumstances in which this otherwise may have been impossible, and that would have resulted in major complications.

## POSTOPERATIVE CARE OF ILEOSTOMIES

The components of an ileostomy appliance are a skin barrier with a faceplate, and a drainable pouch. Most ileostomy appliances are now commercially available as one-piece or semi-disposable two-piece units. The one in common use has a skin barrier with a fixed plastic flange (ring) so that the stoma opening can be cut precisely, the skin barrier applied, and the pouch snapped directly onto the plastic flange, thus allowing easy drainage and disposal of the pouch part of the appliance. The skin barrier component should need changing only every 4–5 days in a patient with a properly protruding and located stoma. A well-constructed ileostomy should allow the patient to display normal physical vigor, to eat a well-balanced palatable diet, and to engage in normal recreational and sexual activity. There should be no prolapse or retraction, the skin should remain normal, and the appliance should not leak. When first constructed, ileostomy output typically averages 1500 mL per day of liquid effluent, but after adaptation occurs, between 500 mL and 800 mL of thick liquid content should be passed per day.

## ILEOSTOMY COMPLICATIONS

Before the concept of stoma eversion was conceived, in approximately 1960, the majority of patients who underwent construction of an ileostomy had serious postoperative complications, usually related to serositis, which caused a partial obstruction at the stoma itself. These patients suffered massive fluid and electrolyte imbalance and often death, which were related to the enormous sequestration of

fluid secondary to the small bowel obstruction. This condition was called “ileostomy dysfunction” and was anticipated after the construction of each stoma. This devastating problem essentially has been eliminated, since stomas have been opened and everted immediately at the time of construction. The output of an ileostomy should thus not be excessive, even in the immediate postoperative period.

Patients with ileostomies do have problems, most often related to maintenance of the seal of the appliance because of poor location or defective configuration of the stoma. In some cases, it is necessary either to revise the stoma locally to bring it into a spigot configuration, or to relocate it so an appliance can be securely applied. The most common problem experienced by ileostomy patients is chemical dermatitis. This can be prevented by proper stoma construction techniques, and by obtaining a pouching system that is properly sized and adherent. If the patient has a poorly constructed stoma, or a poorly fitting appliance, destruction of the peristomal skin can be so severe as to require split-thickness skin graft for definitive management. In these cases and in others in which the skin is injured around the stoma, a special ileostomy appliance may be utilized. It is based on maintenance of the seal to the mucosa of the ileum rather than to the peristomal skin. This appliance is used infrequently, when it is the only solution to complicated peristomal skin problems. Its use requires wearing supportive belts to maintain the appliance in place, but the skin can be treated with medicated pads during this period.

Another potential complication of ileostomy is dehydration. In patients with newly constructed ileostomies, the output of intestinal contents is frequently high enough that patients will require intravenous fluid administration until the stoma output decreases and the patient can compensate with adequate oral intake of fluids and electrolytes. One of the early symptoms associated with dehydration is nausea, which further exacerbates the problem as patients are loath to drink fluids. This problem not infrequently results in readmission to the hospital following major intestinal surgery accompanied by ileostomy formation. Patients should be counseled prior to discharge regarding the signs and symptoms of dehydration, and to intervene early with increased oral intake of fluids. Patients with long-term ileostomies are also at risk of becoming dehydrated, which occurs in hot weather and during strenuous physical activity. The individuals should be instructed to maintain adequate intake of fluids and electrolytes. They should routinely have medications on hand for simple diarrhea so that control can be achieved before dehydration occurs.

Some patients with ileostomies will present with acute blockage of the stoma, which is usually related to food indiscretion creating a “food bolus obstruction” just proximal to the level where the intestine exits the abdominal wall. This complication is most common in patients with newly constructed stomas, as there is some residual edema in the tissues which creates a relative narrowing of the ileum as it crosses the abdominal wall. Typically, patients will have ingested some fibrous food with a high residual component and will present with crampy abdominal pain, reduced stoma output,

dehydration, and vomiting. These patients should be admitted to the hospital and started on intravenous fluid replacement. The stoma can then be irrigated in an attempt to release the presumed food bolus blockage. A Foley or similar catheter is placed into the stoma, and the stoma is then irrigated gently with warm saline. If food particles are returned from the initial irrigation, the irrigation can be continued until stoma function returns and the blockage is eliminated. If the return is clear, it suggests a more proximal obstruction or an adhesive obstruction, and a water-soluble contrast study should be done for evaluation. If the problem is food blockage, the instillation of the hyperosmolar contrast medium often will prove therapeutic. If there is no evidence of food blockage, it should be dealt with as an adhesive small intestinal obstruction. Figure 9-13 is an algorithm for the alleviation of ileostomy blockage.

Some patients develop a high ileostomy output because of dietary indiscretion, infectious disease, short bowel syndrome, or recurrence of inflammatory bowel disease. The cause must be determined and each problem dealt with individually. It is important to maintain fluid and electrolyte balance as these problems are being resolved. Special care must be provided for the patient with short bowel syndrome to maintain electrolyte balance and to compensate for the vitamin B<sub>12</sub>, calcium, and fat malabsorption that occurs with absence of the distal ileum.

Another special problem that may occur with an ileostomy is the formation of a paraileostomy fistula. This usually represents recurrence of Crohn's disease and should be dealt with based on the extent of the Crohn's disease. While evaluation and treatment are being carried out, the appliance should be modified so that the fistula is allowed to drain into the appliance, and no attempt should be made to cover the fistula opening. This is usually achieved by modification of the configuration of the skin barrier component of the appliance.

Patients and those individuals aiding in the care of the ileostomy should be in the habit of observing the ileostomy

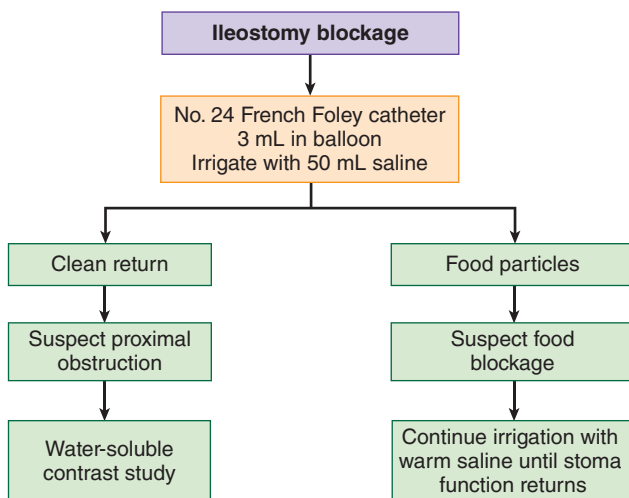
for injury. There are no pain fibers in the ileum, and it is not unusual for a patient to lacerate the stoma with a malfitting appliance without noticing the injury, especially on the inferior aspect of the stoma.

Review of the UOA data registry overall shows a low incidence of complications from ileostomy and an even lower incidence of need for corrective surgery. The vast majority of patients with conventional ileostomies lead normal lives and rarely have a restricted lifestyle because of the stoma. Most patients spend less than 1 hour a day dealing with their stomas.

## CONTINENT ILEOSTOMY

The continent ileostomy, or Kock pouch, has been used as an alternative to a conventional ileostomy for selected patients with ulcerative colitis or familial polyposis. It involves construction of an internal pouch with a continent nipple valve. The continent ileostomy allows placement of the stoma in an inconspicuous location and avoids the need for wearing an appliance permanently. It does require multiple intubations of the pouch daily to allow emptying. The complication rate for construction of this continent ileostomy has been high because of the difficulty in maintaining continence of the nipple valve and position of the pouch so that intubation can be easily accomplished. This operation should probably be done only in centers where it is performed frequently and where the complications are managed by an experienced team. The continent ileostomy can be constructed as a primary procedure for patients with ulcerative colitis. It may also be considered for patients who have an existing ileostomy that malfunctions, is poorly located, or causes severe injury to the peristomal skin because of allergic reaction to the ostomy equipment. However, the Kock pouch has been used infrequently as primary treatment for patients with familial polyposis and ulcerative colitis since the advent of the restorative proctocolectomy with ileal pouch-anal anastomosis. Most surgeons agree that the continent ileostomy is contraindicated for patients with Crohn's disease because of the significant risk of recurrent disease and the potential for loss of substantial length of intestine should the patient require pouch excision. It is also not to be recommended for patients who have a well-functioning end ileostomy.

The advantages of continent ileostomy are that a patient need not wear an appliance, the patient is continent between intubations, and she or he may experience a better quality of life than if they had a conventional ileostomy. The disadvantages are that not all patients are continent, it does require multiple intubations during the day, there can be difficulty in intubation, and the surgery is prolonged and carries a substantial risk of complications. If the procedure fails, the individual will lose a significant amount of small intestine. Also, psychological factors may have been involved in the original motivation for choosing the internal ileostomy that are not alleviated by the more complicated surgical procedure.



**FIGURE 9-13** Ileostomy blockage algorithm. (Reproduced, with permission, from Kodner IJ. Stoma complications. In: Fazio VW, ed. *Current Therapy in Colon and Rectal Surgery*. Philadelphia, PA: BC Decker; 1990:420–425.)



## Construction of Continent Ileostomy

The construction of an intestinal reservoir for feces was first described in 1967 by Nils Kock. His original description of a U-shaped pouch was based on the theory that interruption of coordinated peristalsis would enhance capacity. Since then, J- and S-shaped pouches have been used with similar results. An S-shaped pouch is described here.

The construction of a continent ileostomy, or Kock pouch, can be broken into four components: (1) the creation of a pouch, (2) the creation of a nipple valve, which provides continence, (3) the suspension of the pouch from the abdominal wall in such a way as to prevent slippage of the nipple valve, and (4) the creation of a stoma.

The terminal ileum should be transected as close to the cecum as possible (Fig. 9-14A). The S-shaped reservoir is fashioned from a 30 to 45 cm segment of distal ileum, starting 15 cm from the cut end (Fig. 9-14B). The last 15 cm is used for the outlet (5 cm) and nipple valve (10 cm). The intestine is tacked in place in the shape of an S, using interrupted seromuscular sutures of 2-0 polyglycolic acid placed at the edge of the mesentery. Each limb of the S should be 10–15 cm long. The intestine is opened along the entire portion of the S, with the surgeon taking care to incise close to the mesenteric border on the outer limbs of the S and exactly at the antimesenteric surface of the central limb. A single-layer continuous suture line of 2-0 synthetic absorbable suture is first placed between the two walls of the central limb and the inner walls of the two outer limbs (Fig. 9-14C). The sutures that begin on the posterior wall continue onto the anterior wall as the suture line reaches the outer wall of each of the two outer limbs of the S. The anterior wall is completed by continuing the suture from each direction, using an inverting full-thickness technique (either “baseball” or Connell) until the sutures meet in the middle. Before the pouch is closed, the nipple valve must be constructed.

The 15 cm of ileum distal to the pouch will become the nipple valve and stoma. Prior to the completion of the anterior wall suture, with the pouch mostly open, the nipple valve is made by intussuscepting the ileum into the pouch (Figs. 9-14D and 9-14E). A Babcock clamp is passed into the distal ileum from within the pouch and is closed onto the full thickness of the bowel at a point 5 cm from the pouch. The clamp is drawn into the pouch, intussuscepting the bowel on itself to form the nipple valve. The valve is maintained in this position by placing a line of staples on either side of the mesentery and a third row of staples on the antimesenteric aspect (Fig. 9-14F). Occasionally it is possible to place four staple lines equidistant around the circumference of the nipple valve (Fig. 9-14G). A linear-cutting stapling instrument with the cutting blade removed is used to place the staple lines. One arm of the instrument is inserted into the lumen of the nipple from within the pouch before closing and firing the instrument. These staple lines make a serosa-to-serosa fixation of the nipple valve and prevent its unfolding. The anterior wall of the pouch is then completed as previously described (Fig. 9-15A). A 5 cm outlet of distal ileum remains that will pass through the abdominal wall and allow construction of a flush stoma.

The right lower quadrant stoma site is created as described earlier in this chapter, with the opening placed below the belt line and within the rectus muscle. Before the outlet is passed through the abdominal wall opening, a sling of soft synthetic mesh (1 × 10 cm) is passed through a window made in the mesentery of both the pouch and nipple valve under the major vessels as they fold into the nipple valve mesentery (Figs. 9-15B and 9-15C). The strip of mesh maintains the nipple configuration and helps secure the pouch to the abdominal wall. Seromuscular absorbable sutures are used to fix the mesh to the base of the outlet (Fig. 9-15D). The two ends of the sling are left long because they are sutured together at the antimesenteric surface of the outlet. This facilitates delivery of the outlet through the stoma site and allows a securing suture of nonabsorbable material to be placed through the sling into the anterior fascia. As the outlet is readied to be drawn through the abdominal wall, a row of three untied seromuscular sutures is placed on the shoulders of the pouch medial and lateral to the outlet (Fig. 9-15E). These sutures, incorporating the posterior fascia and peritoneum, are used to fix the pouch to the anterior abdominal wall. The outlet is delivered through the stoma site and the pouch is drawn toward the abdominal wall. The sutures are then tied, first laterally and then medially (Fig. 9-15F). A permanent securing suture is placed through the tails of the sling and the anterior fascia, and the ends of the mesh are trimmed.

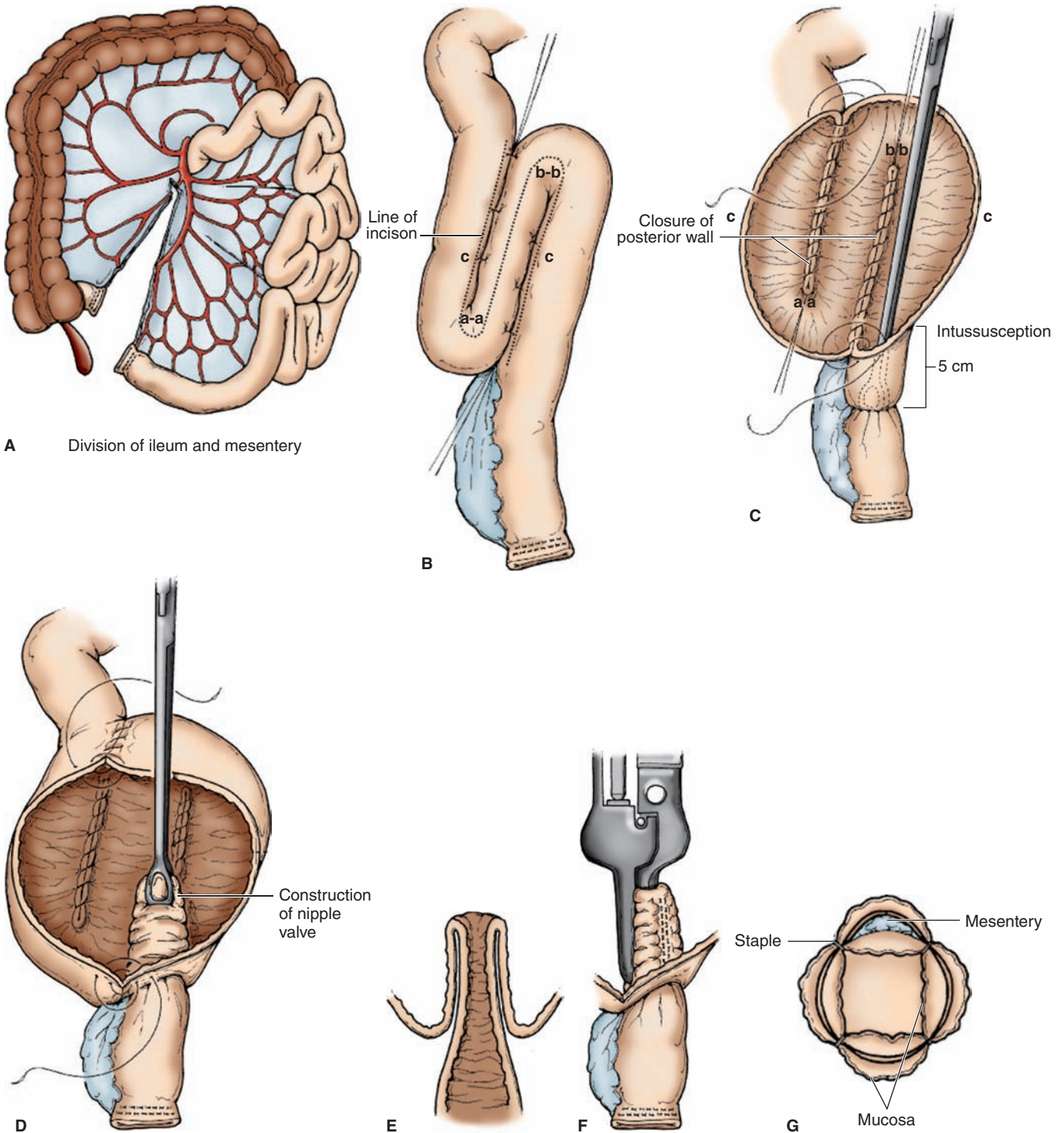
If possible, the cut edge of the small intestine’s mesentery is sutured to the anterior abdominal wall (Fig. 9-15F). A continuous suture is placed from the outlet of the pouch to the falciform ligament. The pouch in its final position should rest at the right pelvic brim, with the antimesenteric surface (anterior wall) of the pouch directed inferiorly.

The terminal ileum at the outlet should be excised at skin level (Fig. 9-15G). The stoma is finally completed by absorbable sutures between the subcuticular layer of the skin and the full thickness of the intestinal wall (Fig. 9-15H). A Medina catheter is passed through the stoma into the pouch and is secured to the skin to prevent slippage of the tube into or out of the pouch (Fig. 9-15I). There should be minimal resistance and no deviation from a straight passage. The pouch should be drained in this manner for 2 weeks before intermittent clamping is begun during the third week. Finally, the pouch should be extubated and reintubated every 4 hours until the intervals gradually increase to 6 or 8 hours.

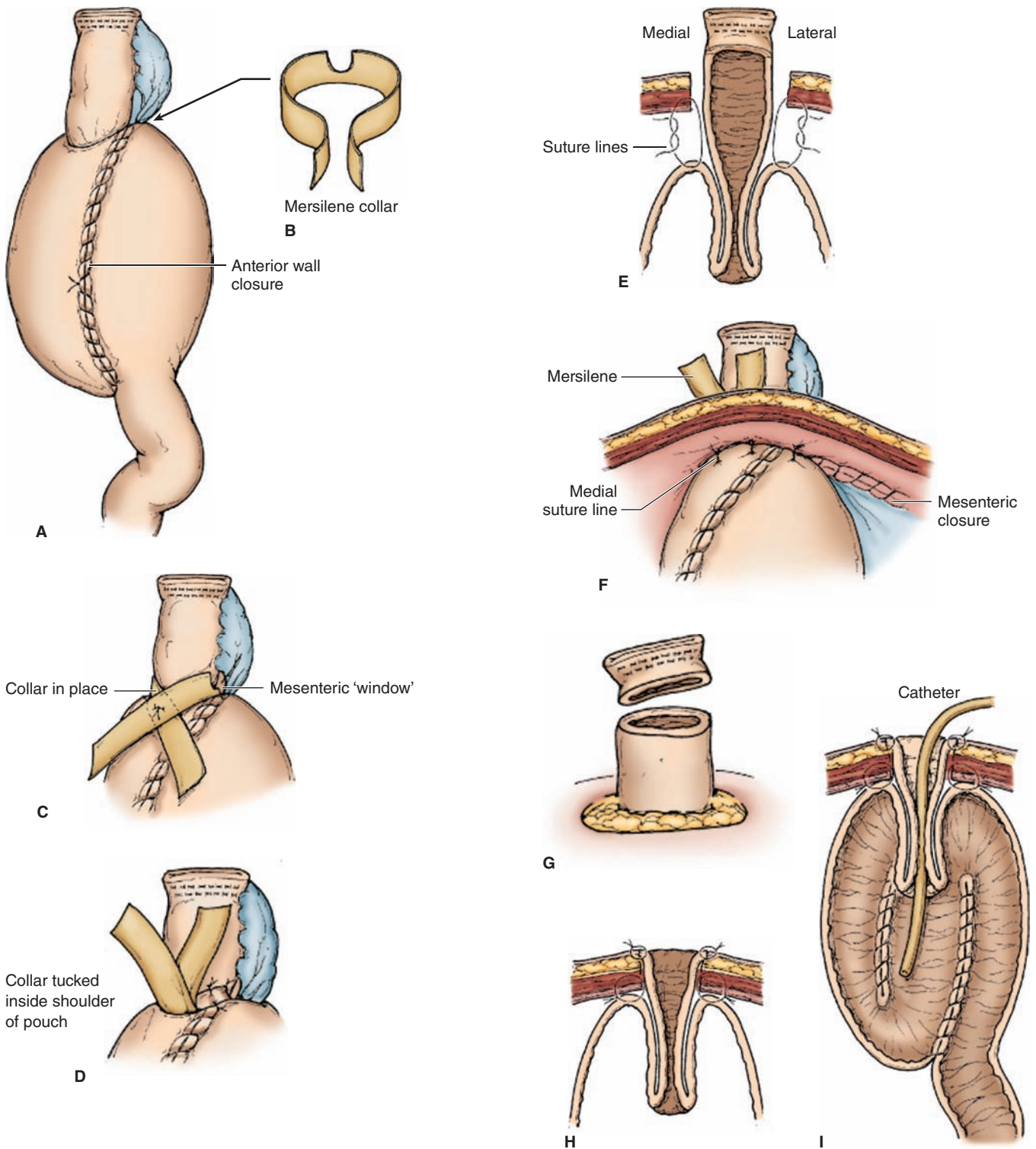
The nipple valve provides increasing continence as pressure rises in the pouch. Should the nipple valve lose its configuration and prolapse or should it slip through the mesenteric aspect of the pouch (the weakest point), either incontinence or obstruction will result. These two problems, along with “pouchitis,” are the most common complications following the continent ileostomy procedure. As a result, many variations of pouch construction have been used in attempts to prevent or correct these problems.

If a fistula should form from the nipple valve or if the nipple valve should slip, it may be possible to preserve the pouch and construct a new nipple valve (Fig. 9-16). The technique involves resecting the pouch outlet, including the nipple valve, after fully mobilizing the pouch from the

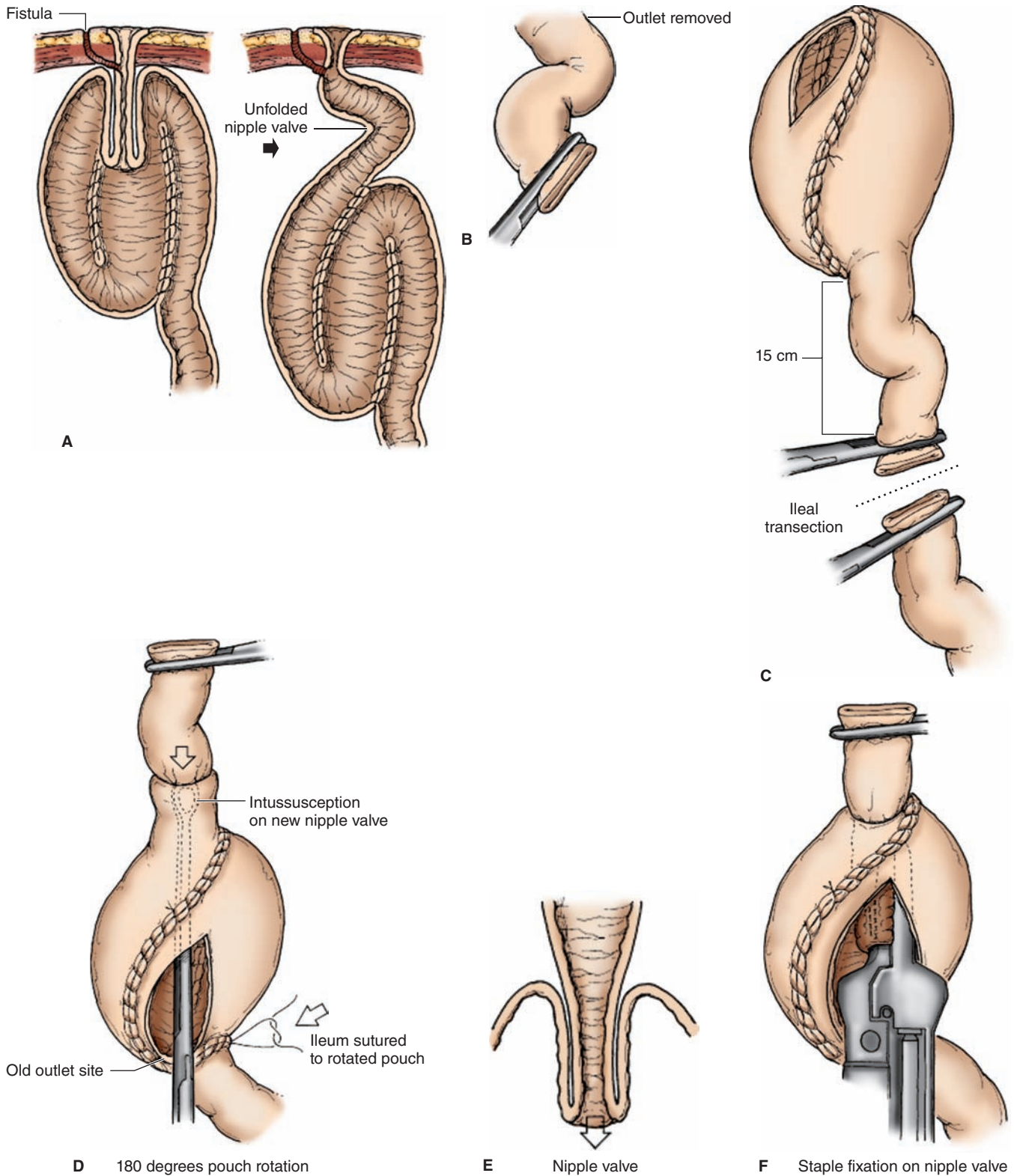




**FIGURE 9-14** Construction of a continent ileostomy. **A.** The colectomy should be completed with as much distal ileum preserved as possible. **B.** Alignment of the components of the S-shaped pouch and nipple valve and the line of incision to open the pouch. **C.** The pouch construction is begun with continuous 2-0 synthetic absorbable suture material. **D.** The anterior wall of the pouch is formed by continuous suture from each corner, and the nipple valve is constructed before complete closure of the pouch. **E.** The ileum is intussuscepted to form the 5 cm long nipple valve. **F, G.** The intussusception is maintained by placement of multiple lines of staples adjacent to the mesentery and on the antimesenteric borders.

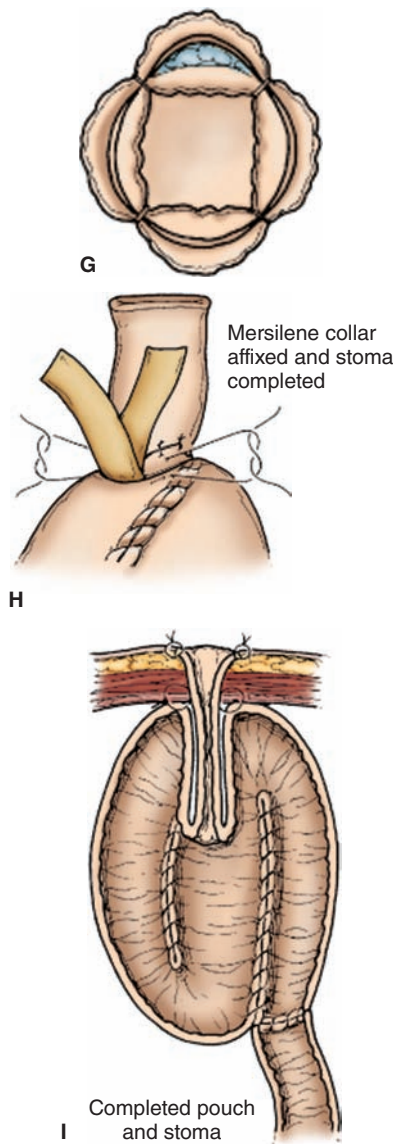


**FIGURE 9-15** Completion of the continent ileostomy. **A.** The anterior wall of the pouch is completed. **B.** A band of soft synthetic mesh (1 × 10 cm). **C.** The mesh collar is placed through the mesentery of the pouch and nipple valve around the valve. **D.** The mesh collar is sutured to the nipple valve and to the shoulders of the pouch. **E.** Fixation sutures are placed between the shoulders of the pouch and the abdominal wall. **F.** The pouch is secured to the abdominal wall. **G.** The terminal ileum of the outlet is excised at skin level. **H.** The stoma is completed by placing sutures between full thickness of intestine and dermis. **I.** The Medina catheter is replaced in the completed pouch and is secured to the skin.



**FIGURE 9-16** Preservation of the continent ileostomy after fistula formation or loss of the nipple configuration. **A.** Fistula between skin and nipple valve (*left*) and slipped nipple valve (*right*). **B.** The faulty nipple valve and outlet are excised. **C.** The distal ileum is transected 15 cm proximal to pouch, leaving enough intestine to reconstruct the valve and stoma. **D.** The pouch is rotated 180 degrees, and the intestine is anastomosed to the pouch through a second enterostomy. **E, F, G.** The nipple valve is reconstructed as before, through the enterotomy made by resecting the old valve.





**FIGURE 9-16** *Continued—H, I.* The pouch is fixed to the abdominal wall, and the stoma is completed.

abdominal wall and pelvis (Fig. 9-16B). The terminal ileum is transected 15 cm proximal to the pouch (Fig. 9-16C). The pouch is then rotated 180 degrees on its mesentery (Fig. 9-16D). A new nipple valve is created as previously described by intussuscepting the new outlet on itself and placing staple lines along the valve to secure the fold (Figs. 9-16E, 9-16F, and 9-16G). The opening in the pouch wall created when the old outlet was resected serves as the entry to the pouch to perform this maneuver. The proximal ileum's cut edge is then anastomosed to the pouch through a second enterotomy in a position that allows the pouch to lie comfortably in the right lower quadrant as before (Fig. 9-16D). If at all possible, the existing stoma site should be preserved and reused. The pouch then is resuspended by using a mesh sling as described

above, and the stoma is constructed (Figs. 9-16H and 9-16I). The pouch should be protected by constant drainage through an indwelling Medina catheter for at least 1 week. Because the pouch will not require expansion and the patient will not need education, the prolonged period of progressive clamping should not be necessary.

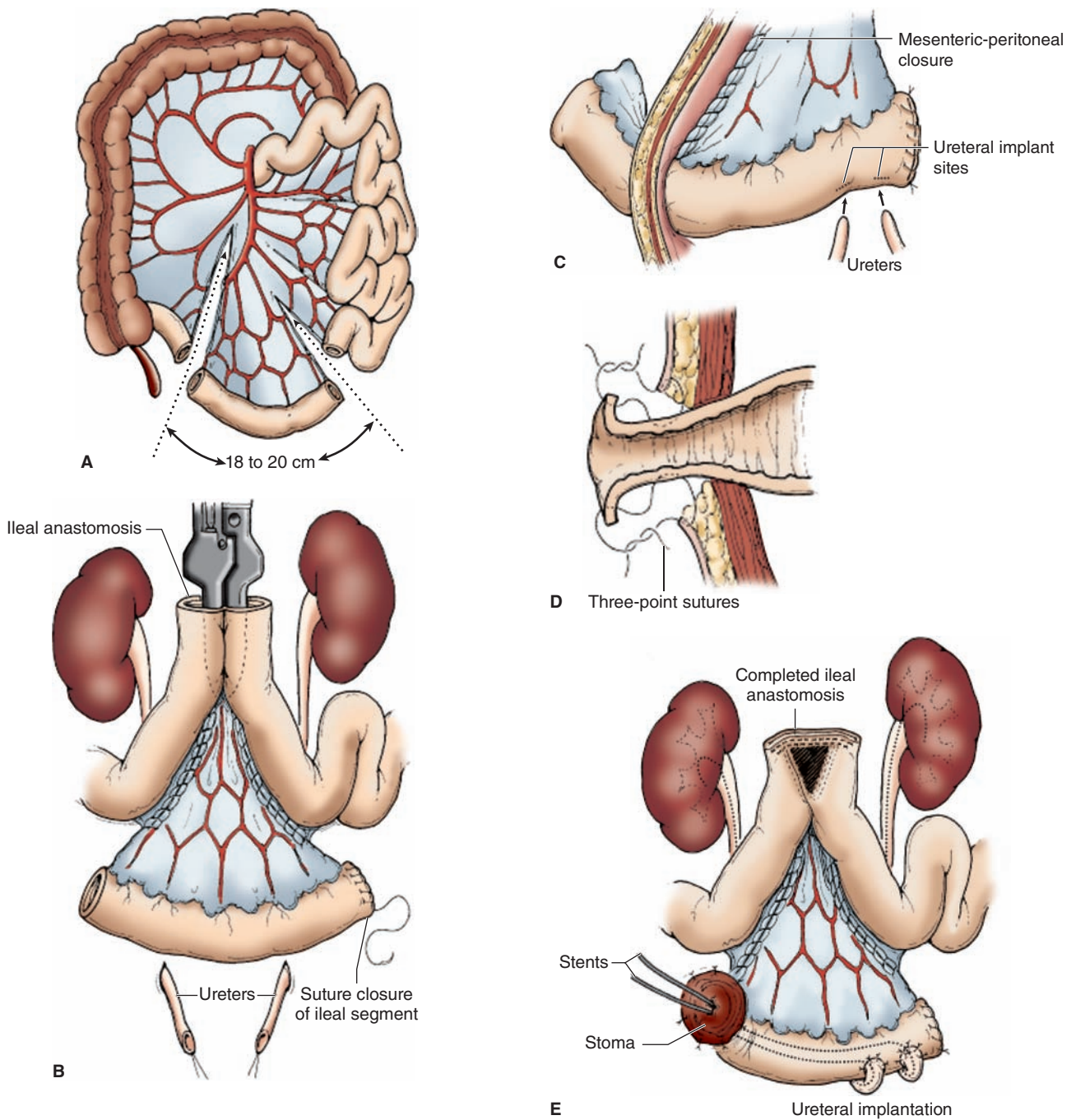
## URINARY CONDUIT

The urinary conduit is constructed of a segment of intestine with well-maintained vascularity so that it can be connected to the urinary tract to allow egress of urine through the abdominal wall via a stoma constructed exactly like an ileostomy. It is not intended to have any type of reservoir capacity but merely to provide an open conduit. This urinary conduit is constructed most often after removal of the urinary bladder for invasive cancer. It is also used for management of severe obstructive uropathy, the congenital abnormalities of spina bifida, meningomyelocele, or bladder exstrophy, and for trauma to the spinal cord resulting in a severely neurogenic bladder. The incidence of this surgery for congenital and traumatic disorders is decreasing as other means of emptying the bladder are devised. The cystectomy, construction of the urinary conduit, and ureterointestinal anastomosis are most often carried out by urologists, but the construction of the stoma, as well as restoration of intestinal continuity, may be done by a surgeon more experienced in intestinal and stoma surgery.

The basic principles of construction of the conduit and stoma involve isolation of a segment of intestine, with maintenance of the mesenteric blood supply and enough mobility to allow the distal end to be used as a stoma and the proximal end to serve as the site for ureteral implantation. It is most important to maintain the isoperistaltic direction of the intestine, especially if the conduit is constructed of sigmoid colon. The conduit must not be made of irradiated bowel, even if this requires using either colonic or proximal small intestinal conduits. If the stoma is improperly constructed, there may be a stasis of urine, resulting in reflux and damage to the proximal tract.

The surgical technique consists of choosing a long enough segment of small intestine to allow the stoma to be constructed at the level of the abdominal wall and still allow the proximal end to reach close enough to the retroperitoneum to preclude tension on the ureterointestinal anastomoses (Fig. 9-17). Usually, 18–20 cm of intestine is enough, but this must be modified if there is a shortened mesentery or a massively obese abdominal wall. It is in these latter situations that the loop-end stoma, supported over a small rod, can be advantageous. After the segment of intestine is chosen, the mesentery at the distal point is incised to allow enough mobility for reaching the abdominal wall. The mesentery at the proximal site of transection is incised only in a limited fashion, and care must be taken to preserve a generous blood supply (Fig. 9-17A). Intestinal continuity is restored, with the intended conduit positioned posterior to the restored intestine





**FIGURE 9-17** Construction of a urinary conduit. **A.** An 18 to 20 cm segment of distal ileum is taken out of continuity, and the blood supply is carefully preserved. **B.** Intestinal continuity is restored, and the intended conduit located posterior to the restored intestine. **C.** The ureteral conduit anastomoses are completed. **D.** The stoma is constructed with a spigot configuration. **E.** Stents are placed through the completed ureteral anastomoses.

(Fig. 9-17B). The ileoileal anastomosis may be completed in any fashion that uses sutures or staples. The conduit is then cleaned of intestinal content, and the proximal end is closed. Closure must be done with absorbable sutures, because staples can lead to stone formation. It is then preferable to make the

opening in the abdominal wall to construct the stoma as previously described for an ileostomy (Figs. 9-17C and 9-17D). This procedure ensures that the ureteral anastomosis will be completed with the conduit in its final position and without the need for applying tension to bring the intestine through

the abdominal wall. The ureteral anastomoses are performed, and stents are placed (Fig. 9-17E). All aspects of the stoma construction are the same as those for an ileostomy except that the appliance must contain a valve to allow emptying since the volume of urine is high and its weight may tend to pull the appliance off. This problem is avoided by the patient emptying the appliance frequently and by sleeping attached to a night drainage system.

## Complications of the Urinary Conduit

The most common complication of a urinary conduit is a leaking appliance because of improper placement or construction of a flush rather than a protruding stoma. Although some urologists believe that a flush stoma is less susceptible to injury, most surgeons disagree with this concept and believe that a spigot configuration is best. Sometimes sutures are placed in the skin rather than in the dermis during stoma construction. This leads to a circumferential series of radial scars that preclude maintenance of the seal of the appliance. Because the stoma effluent is thin liquid, the appliance seal must be precise to avoid injury to the peristomal skin. If there is stasis in the conduit, an odor will develop and become the cause of great concern to the patient. Odor, increased mucus production, flank pain, and fever can indicate a urinary tract infection. In order to obtain an accurate urine sample for culture, it is necessary to intubate the stoma rather than sending urine collected from the appliance. It is not unusual to have to revise and sometimes relocate flush urinary conduit stomas. If this is done, care must be taken to ensure that the length of the conduit is adequate. If it is not, it is possible to add a segment of small intestine so that a proper stoma can be constructed without having to revise the ureterointestinal anastomoses.

The patient who does not maintain adequate personal hygiene and acidification of the urine may develop stone formation, with crystal formation around the stoma itself. This development can be alleviated by acidifying the urine or by cleaning and soaking the pouch with white vinegar. The use of Collyseal (Torbot Co.) can also be used to maintain an acidic environment and thus minimize crystal formation at the stoma. If the stoma has been constructed within the field of radiation, the radiation can break down the skin around the stoma. This requires relocation of the stoma to a nonirradiated location on the abdominal wall. Relocation should be done even if the upper quadrants need to be used. Recent advances have employed the principles of Kock pouch construction, previously described, to allow construction of a continent urinary diversion.

## INTESTINAL FISTULA

The formation of an intestinal fistula is not planned by the surgeon. Therefore, it must be dealt with as it occurs. Applying modern principles of stoma care to maintain the integrity of the peristomal skin until definitive treatment of the fistula can be carried out should prevent damage to the skin from

primitive means of preventing severe destruction of the skin and abdominal wall. These stomal care techniques, coupled with intravenous nutritional supplementation, should alleviate uncontrolled intestinal drainage from abdominal wounds.

## LAPAROSCOPIC CREATION OF INTESTINAL STOMAS

The most appealing operation early on in the laparoscopic colorectal surgery experience was creation of a diverting intestinal stoma. Laparoscopic loop stoma creation does not require division of the bowel or anastomosis, and the only incision larger than 5 mm required is at the stoma site. Thus, the full benefits of the totally laparoscopic approach can be realized. Surgeons inexperienced in laparoscopic approaches to colorectal disease may find that creation of intestinal stomas is a relatively straightforward and rewarding method to begin their laparoscopic colorectal experience.

Laparoscopic creation of intestinal stomas was reported in the early 1990s and the technique was quickly adopted by many surgeons. Several case series demonstrating the safety and efficacy of the procedure have been reported in the literature. Although there has not been a prospective, randomized trial of laparoscopic versus open stoma creation, case-controlled series have demonstrated reduced duration of postoperative ileus and reduced length of hospital stay with the laparoscopic approach. The benefits of the laparoscopic approach to stoma creation became immediately obvious to surgeons, and thus, it is unlikely that a prospective, randomized trial will ever be performed comparing outcomes of stomas created using laparoscopy versus laparotomy.

Laparoscopic ileostomy and colostomy creation have been performed for a plethora of indications, including obstructing rectal adenocarcinoma, rectal obstruction from extrarectal malignancies, fecal incontinence, penetrating rectal trauma, sacral pressure ulceration, obstructed defecation, perineal Crohn's disease, pelvic fracture, and lumbosacral burns. Virtually any disease process that is an indication for fecal diversion is an indication for consideration of the laparoscopic approach. Laparoscopic creation of diverting loop colostomy is particularly appropriate for patients suffering from symptomatic near-obstructing rectal carcinoma. The technique allows the surgeon to evaluate the liver and peritoneum for the presence of metastases that may be undetected on preoperative imaging studies, and institute fecal diversion without creating adhesions in the abdomen and pelvis that may increase toxicity of neoadjuvant radiotherapy and make future proctectomy more difficult. The absence of a laparotomy incision allows patients to recover rapidly, and allows them to begin neoadjuvant radiotherapy treatments almost immediately.

Some authors have argued that trephine stoma creation is an easier, quicker, and less expensive method of stoma creation than the laparoscopic technique. For the thin patient

with a virgin abdomen who will not benefit from abdominal exploration, the trephine method does offer those advantages. However, for patients who are obese, those who have had multiple prior laparotomies, those who would benefit from abdominal exploration, or those who require mobilization of the intestine from its retroperitoneal attachments, the laparoscopic approach offers significant advantages.

In order to save time and expense in the operating room, we have developed an approach to the patient requiring fecal diversion that combines the advantages of both trephine and laparoscopic stoma creation. If the patient is thin and would not necessarily benefit from laparoscopic exploration of the peritoneal cavity, the patient is approached initially with the intention of creating a trephine stoma, with the laparoscopic approach held in reserve. The patient is positioned for a laparoscopic procedure, but the laparoscopic equipment is kept unopened in the operating room. The stoma incision is made, and if the bowel can be delivered in correct orientation to the skin level, the stoma is created and the laparoscopic equipment remains unopened. However, if trephine creation of the stoma is impossible, a Hasson trocar is placed through the stoma incision and the procedure proceeds laparoscopically.

## Technique of Laparoscopic Stoma Creation

Patients undergoing diverting colostomy should be placed in the dorsal lithotomy or split leg position in order to have access to the anorectum; patients undergoing ileostomy may be placed in the supine position. The preselected stoma site is opened, a purse-string suture is placed in the posterior rectus sheath, and a Hasson trocar is placed. A 5 mm trocar is placed in the contralateral abdomen and the peritoneal cavity explored. If the bowel to be used for the stoma is sufficiently mobile, no other trocars need to be placed. If mobilization is required, additional 5 mm trocars can be placed to facilitate the dissection. Mobility is usually adequate when the bowel will reach to the peritoneal surface at the stoma site, as the distance to the skin level will decrease when pneumoperitoneum is released. A 5 mm camera is then placed through one of the 5 mm port sites, and the bowel grasped in the correct orientation using an instrument placed through the Hasson trocar at the stoma site. It is occasionally useful to mark the bowel for orientation of the proximal and distal limbs with sutures or clips prior to delivery through the stoma site—this is especially true when creating an ileostomy. The pneumoperitoneum is then released and the posterior rectus sheath opened over the trocar, allowing the bowel to be delivered through the stoma opening.

If the bowel is to be divided and an end stoma fashioned, it is critical that orientation be confirmed. Left-sided colostomy orientation can be confirmed by insufflation of air through a proctoscope, instillation of povidone iodine or dye through a small opening in the distal limb of the stoma with confirmation of dye passage to the rectum via a proctoscope,

or passage of a flexible sigmoidoscope to the stoma site. Alternatively, the colon can be divided with a linear-cutting stapler, the distal end is allowed to retract into the peritoneal cavity, and direct visualization with a 5 mm laparoscope is performed to ensure that the distal bowel can be traced in continuity to the rectum.

The rapidity with which postoperative ileus resolves following laparoscopic creation of intestinal stomas may allow patients to return home within 1–2 days. This may create a problem for the patient and the CWOCN, who has little time to perform in-hospital stoma care training. Therefore, it is imperative that the patient meet with the CWOCN preoperatively, not only for stoma site marking, but for stoma care teaching as well.

## Laparoscopic Stoma Closure

Laparoscopic techniques are most applicable to patients who have undergone colectomy with construction of a proximal colostomy. Although laparoscopic adhesiolysis is occasionally a beneficial adjunct to loop stoma closure, this is rarely required, as most loop stomas can be closed via a peristomal incision. The most common indication for a laparoscopic approach to the restoration of intestinal continuity is colostomy take-down and construction of coloproctostomy following sigmoid colectomy for complicated diverticular disease (“Hartmann reversal”). This procedure can either be straightforward or complicated, depending on the number and severity of intra-peritoneal adhesions and the degree of pelvic fibrosis.

Several methods can be used to perform laparoscopic Hartmann reversal. Some surgeons establish laparoscopic access initially, perform adhesiolysis, mobilize the colon and rectum, take down the colostomy and insert the anvil of the end-to-end stapling device, re-establish pneumoperitoneum, and perform the anastomosis. A more cost-effective method is to take down the colostomy initially, perform as much of the procedure as possible through the colostomy opening, and then decide whether a laparoscopic technique is feasible. A substantial amount of adhesiolysis and mobilization can often be performed through the stoma incision, especially if there is a parastomal hernia present that has enlarged the fascial opening. The proximal colon can be prepared for anastomosis and the anvil of a circular stapling device inserted. If a determination of laparoscopic feasibility can be made prior to establishing pneumoperitoneum, it avoids the need to open any laparoscopic instruments or struggle with fruitless attempts at laparoscopic dissection prior to conversion. However, if it appears that laparoscopic techniques are likely to be successful, pneumoperitoneum is then established, either by closure of the fascia around a port or by insertion of a hand-assist device. The size of the fascial defect will determine which method is more advantageous for the patient and surgeon. The operation is then completed laparoscopically.

Prior to embarking on a laparoscopic reversal of a Hartmann procedure performed for diverticular disease, the surgeon should consider that it may be necessary to resect retained



sigmoid colon and mobilize the splenic flexure to allow soft descending colon to reach easily into the pelvis for a colorectal anastomosis. Preoperative evaluation of the proximal colon and distal rectal stump with endoscopy and/or contrast enema will help the surgeon plan the operative procedure and exclude alternative diagnoses.

It is also possible to perform laparoscopic restoration of intestinal continuity following total abdominal or subtotal colectomy and ileostomy. The ileostomy can be taken down, and an end-to-end anastomosis performed laparoscopically using a surgical stapling device.

## SELECTED READINGS

- Arumugam PJ, Bevan L, MacDonald L, et al. A prospective audit of stomas—analysis of risk factors and complications and their management. *Colorectal Dis.* 2003;5:49–52.
- Bricker EM. Bladder substitution after pelvic evisceration. *Surg Clin North Am.* 1950;30:1511.
- Burch J. The pre- and postoperative nursing care for patients with a stoma. *Br J Nurs.* 2005;14(6):310–318.
- Butcher HR Jr, Sugg WL, McAfee CA, et al. Ileal conduit method of ureteral urinary diversion. *Ann Surg.* 1962;156:682.
- Byers JM, Steinberg JB, Postier RG. Repair of parastomal hernias using polypropylene mesh. *Arch Surg.* 1992;127:1246.
- Chechile G, Klein EA, Bauer L, Novick AC, Montie JE. Functional equivalence of end and loop ileal conduit stomas. *J Urol.* 1992;147:582.
- Cheung MT. Complications of an abdominal stoma: an analysis of 322 stomas. *Aust N Z J Surg.* 1995;65:808–811.
- Colwell J, Goldberg MT, Carmel JE. *Fecal and Urinary Diversions: Management Principles.* Mosby Publishing; St. Louis, MO. 2009.
- Corman JM, Odenheimer DB. Securing the loop—historic review of the methods used for creating a loop colostomy. *Dis Colon Rectum.* 1991;34:1014.
- Crile G Jr, Turnbull RB Jr. Mechanism and prevention of ileostomy dysfunction. *Ann Surg.* 1954;140:459.
- Deol ZK, Shayani V. Laparoscopic parastomal hernia repair. *Arch Surg.* 2003;138:203–205.
- Dinnick T. The origins and evolution of colostomy. *Br J Surg.* 1934;22:142.
- Doughty D. Role of the enterostomal therapy nurse in ostomy patient rehabilitation. *Cancer.* 1992;70(Suppl):1390.
- Edwards DP, Leppington-Clarke A, et al. Stoma-related complications are more frequent after transverse colostomy than loop ileostomy: a prospective randomized clinical trial. *Br J Surg.* 2001;88:360–363.
- Feinberg SM, McLeod RS, Cohen Z. Complications of loop ileostomy. *Am J Surg.* 1987;153:102.
- Fleshman JW, Cohen Z, McLeod RS, Stern H, Blair J. The ileal reservoir and ileoanal anastomosis procedure: factors affecting technical and functional outcome. *Dis Colon Rectum.* 1988;31:10.
- Fleshman JW. Loop ileostomy. *Surg Rounds.* 1992;Feb:129.
- Fucini C, Wolff BG, Dozois RR. Bleeding from peristomal varices: perspectives on prevention and treatment. *Dis Colon Rectum.* 1991;34:1073.
- Gottlieb LM, Handelsman JC. Treatment of outflow tract problems associated with continent ileostomy (Kock pouch): report of six cases. *Dis Colon Rectum.* 1991;34:936.
- Grundfest-Broniatowski S, Fazio V. Conservative treatment of bleeding stomal varices. *Arch Surg.* 1983;118:981.
- Guenaga KF, Lustosa SA, Saad SS, Saconato H, Matos D. Ileostomy or colostomy for temporary decompression of colorectal anastomosis. *Cochrane Database Syst Rev.* 2007;(1):CD004647.
- Hasegawa H, Radley S, Morton DG, Keighley MR. Stapled versus sutured closure of loop ileostomy: a randomized controlled trial. *Ann Surg.* 2000;231:202–204.
- Hampton B. *Ostomies and Continent Diversions: Nursing Management.* Mosby Publishing; St. Louis, MO. 1992.
- Huser N, Michalski CW, Erkan M. Systematic review and meta-analysis of the role of defunctioning stoma in low rectal cancer surgery. *Ann Surg.* 2008;248(1):52–60.
- Janes A, Cengiz Y, Israelsson LA. Preventing parastomal hernia with a prosthetic mesh. *Arch Surg.* 2004;139:1356–1358.
- Jayaprakash A, Creed T, Stewart L. Should we monitor vitamin B<sub>12</sub> levels in patients who have had end-ileostomy for inflammatory bowel disease? *Int J Colorectal Dis.* 2004;19:316–318.
- Jeter KF. Perioperative teaching and counseling. *Cancer.* 1992; 70 (Suppl):1346.
- Jeter KF. *These Special Children. A Book for Parents of Children with Colostomies, Ileostomies, & Urostomies.* Palo Alto, CA: Bull; 1982.
- Kalady MF, Fields RC, Klein S, Nielsen KC, Mantyh, CR, Ludwig, KA. Loop ileostomy closure at an ambulatory surgery facility: a safe and cost-effective alternative to routine hospitalization. *Dis Colon Rectum.* 2003;46:486–490.
- Kaveggia FF, Thompson JS, Taylor RJ. Placement of an ileal loop urinary diversion back in continuity with the intestinal tract. *Surgery.* 1991;110:557.
- Khoo RE, Cohen MM. Laparoscopic ileostomy and colostomy. *Ann Surg.* 1995;221:207–208.
- Kodner IJ. Colostomy and ileostomy. *Clin Symp.* 1978;30:1.
- Kodner IJ. Colostomy. Indications, techniques for construction, and management of complications. *Semin Colon Rectal Surg.* 1991;2:73.
- Kodner IJ, Fry RD. Intestinal stomas: their management. In: Veidenheimer MC, ed. *Seminars in Colon & Rectal Surgery.* Philadelphia, PA: WB Saunders; 1991:65.
- Kodner IJ. Stoma complications. In: Fazio VW, ed. *Current Therapy in Colon and Rectal Surgery.* Hamilton, Ontario: BC Decker; 1989:420.
- Köhler LW, Pemberton JH, Zinsmeister AR, Kelly KA. Quality of life after proctocolectomy: a comparison of Brooke ileostomy, Kock pouch, and ileal pouch-anal anastomosis. *Gastroenterology.* 1991;101:679.
- Leblanc KA, Bellanger DE, Whitaker JM, Hausmann MG. Laparoscopic parastomal hernia repair. *Hernia.* 2005;9:140–144.
- Leung TT, MacLean AR, Buie WD, Dixon E. Comparison of stapled versus hand-sewn loop ileostomy closure: a meta-analysis. *J Gastrointest Surg.* 2008;12(5):939–944.
- Ludwig KA, Milsom JW, Garcia-Ruiz A, Fazio VW. Laparoscopic techniques for fecal diversion. *Dis Colon Rectum.* 1996;39:285–288.
- MacKeigan JM, Cataldo PA. *Intestinal Stomas: Principles, Techniques, and Management.* St. Louis, MO: Quality Medical; 2004.
- MacLeod JH. Colostomy irrigation—a transatlantic controversy. *Dis Colon Rectum.* 1972;15:357.
- Marcello PW, Roberts PL, Schoetz DJ Jr, Coller JA, Murray JJ, Veidenheimer MC. Obstruction after ileal pouchanal anastomosis: a preventable complication? *Dis Colon Rectum.* 1993;36:1105–1111.
- McLeod RS, Fazio VW. Quality of life with the continent ileostomy. *World J Surg.* 1984;8:90.
- McLeod RS, Lavery IC, Leatherman JR. Patient evaluation of the conventional ileostomy. *Dis Colon Rectum.* 1985;28:152.
- Nightingale JMD, Lennard-Jones JE, Walker ER, Farthing MJ. Oral salt supplement to compensate for jejunostomy losses: comparison of sodium chloride capsules, glucose electrolyte solution, and glucose polymer electrolyte solution. *Gut.* 1992;33:759.
- Oliveira L, Reissman P, Noguera J, Wexner SD. Laparoscopic creation of stomas. *Surg Endosc.* 1997;11:19–23.
- Ortiz H, Sara MJ, Armendariz P, de Miguel M, Marti J, Chocarro C. Does the frequency of paracolostomy hernias depend on the position of the colostomy in the abdominal wall? *Int J Colorectal Dis.* 1994;9:65–67.
- Pachler J, Wille-Jorgensen P. Quality of life after rectal resection for cancer, with or without permanent colostomy. *Cochrane Database Syst Rev.* 2004;3:CD004323
- Parks SE, Hastings PR. Complications of colostomy closure. *Am J Surg.* 1985;149:672.
- Pata G, D'Hoore A, Fieus S, Penninckx F. Mortality risk analysis following routine vs selective defunctioning stoma formation after total mesorectal excision for rectal cancer. *Colorectal Dis.* 2009;11(8):797–805.
- Pearl RK, Prasad ML, Orsay CP, Abcarian H, Tan AB, Melzl MT. Early local complications from intestinal stomas. *Arch Surg.* 1985;120:1145.
- Pearl RK, Prasad ML. End-loop stomas: the new generation of intestinal stomas. *Contemp Surg.* 1985;27:270.
- Pemberton JH, Phillips SF, Ready RR, Zinsmeister AR, Beahrs OH. Quality of life after Brooke ileostomy and ileal pouch-anal anastomosis: comparison of performance status. *Ann Surg.* 1989;209:620.
- Prasad ML, Abcarian H, Pearl RK. End-loop colostomy. *Surg Gynecol Obstet.* 1984; 158:380
- Prasad ML, Pearl RK, Orsay CP, Abcarian H. Rodless ileostomy. A modified loop ileostomy. *Dis Colon Rectum.* 1984;27:270.



- Price AL, Rubio PA. Laparoscopic colorectal surgery: a challenge for ET nurses. *J Wound Ostomy Continence Nurs.* 1994; 21:179–182.
- Read TE, Salgado J, Ferraro D, Fortunato R, Caushaj PF. “Peek port”: a novel approach to avoid conversion in laparoscopic colectomy. *Surgical Endoscopy.* 2009;23(3):477–481.
- Remzi FH, Oncel M, Hull TL, Strong SA, Lavery IC, Fazio VW. Current indications for blow-hole colostomy: ileostomy procedure. A single center experience. *Int J Colorectal Dis.* 2003;18:361–364.
- Rieger N, Moore J, Hewett P, Lee S, Stephens J. Parastomal hernia repair. *Colorectal Dis.* 2004;6:203–205.
- Rolstad BS, Wilson G, Rothenberger DA. Sexual concerns in the patient with an ileostomy. *Dis Colon Rectum.* 1983;26:170.
- Rombeau JL, Wilk PJ, Turnbull RB Jr, Fazio VW. Total fecal diversion by the temporary skin-level loop transverse colostomy. *Dis Colon Rectum.* 1978;21:223.
- Rondelli F, Reboldi P, Rulli A, Matthews JB. Loop ileostomy versus loop colostomy for fecal diversion after colorectal or coloanal anastomosis: a meta-analysis. *Int J Colorectal Dis.* 2009;24(5):479–488.
- Rubin MS, Schoetz DJ Jr, Matthews B. Parastomal hernia. Is stoma relocation superior to fascial repair? *Arch Surg.* 1994;129:413–418.
- Saha AK, Tapping CR, Foley GT, et al. Morbidity and mortality after closure of loop ileostomy. *Colorectal Dis.* 2009;11(8):866–871.
- Sakai Y, Nelson H, Larson D, Maird L, Young-Fadok T, Ilstrup D. Temporary transverse colostomy vs loop ileostomy in diversion: a case-matched study. *Arch Surg.* 2001;136:338–342.
- Salvadalena, G. Incidence of complications of the stoma and peristomal skin among individuals with colostomy, ileostomy, and urostomy: a systematic review. *J Wound Ostomy Continence Nurs.* 2008;35(6):596–607.
- Shabbir J, Britton DC. Stoma complications: a literature overview. *Colorectal Dis.* 2010;12:958.
- Shemesh EI, Kodner IJ. Statistics from the ostomy registry. *Ostomy Quart.* 1987;24:70.
- Shirley F, Kodner IJ, Fry RD. Loop ileostomy: techniques and indications. *Dis Colon Rectum.* 1984;27:382.
- Soliani P, Carbognani P, Piccolo P, Sabbagh R, Cudazzo E. Colostomy plug devices: a possible new approach to the problem of incontinence. *Dis Colon Rectum.* 1992;35:969.
- Stephenson ER Jr, Ilahi O, Koltun WA. Stoma creation through the stoma site: a rapid, safe technique. *Dis Colon Rectum.* 1997;40:112–115.
- Svaninger G, Nordgren S, Palselius IR, Fasth S, Hulten L. Sodium and potassium excretion in patients with ileostomies. *Eur J Surg.* 1991;157:601.
- Swain BT, Ellis CN Jr. Laparoscopy-assisted loop ileostomy: an acceptable option for temporary fecal diversion after anorectal surgery. *Dis Colon Rectum.* 2002;45:705–707.
- Thompson JS, Williams SM. Technique for revision of continent ileostomy. *Dis Colon Rectum.* 1992;35:87.
- Turnbull RB Jr, Weakley F, eds. *Atlas of Intestinal Stomas.* St. Louis, MO: CV Mosby; 1967.
- Unti JA, Abcarian H, Pearl RK, et al. Rodless end-loop stomas: seven-year experience. *Dis Colon Rectum.* 1991;34:999.
- Wexner SD, Taranow DA, Johansen OB, et al. Loop ileostomy is a safe option for fecal diversion. *Dis Colon Rectum.* 1993;36:349.
- Wiesner RH, LaRusso NF, Dozois RR, Beaver SJ. Peristomal varices after proctocolectomy in patients with primary sclerosing cholangitis. *Gastroenterology.* 1986;90:316.
- Winslet MC, Drole Z, Allan A, Keighley MR. Assessment of the defunctioning efficiency of the loop ileostomy. *Dis Colon Rectum.* 1991;34:699.
- Winslet MC, Poxon V, Youngs DJ, Thompson H, Keighley MR. A pathophysiologic study of diversion proctitis. *Surg Gynecol Obstet.* 1993;177:57.
- Young CJ, Evers AA, Solomon MJ. Defunctioning of the anorectum: historical controlled study of laparoscopic vs. open procedures. *Dis Colon Rectum.* 1998;41: 190–194.

*This page intentionally left blank*

# ABDOMINAL ABSCESS AND ENTERIC FISTULAE

Patrick S. Tawadros • Jory Simpson • Josef E. Fischer

• Ori D. Rotstein

## ABDOMINAL ABSCESS

### Definition and Etiology

Abscesses are well-defined collections of infected purulent material that are walled off from the rest of the peritoneal cavity by inflammatory adhesions, loops of intestine and their mesentery, the greater omentum, or other abdominal viscera. Abscesses may occur in the peritoneal cavity, either within or outside of abdominal viscera (extravisceral), as well as in the retroperitoneum.<sup>1</sup> Most relevant to the surgeon are extravisceral abscesses that usually arise in one of two situations: (1) after resolution of diffuse peritonitis in which a loculated area of infection persists and evolves into an abscess and (2) after perforation of a viscus or an anastomotic breakdown that is successfully walled off by peritoneal defense mechanisms. More than 80% of intra-abdominal abscesses occur in the postoperative period, the majority of which occur after pancreaticobiliary or colorectal surgery and are usually related to anastomotic dehiscence.<sup>2,3</sup> Occasionally, postsurgical abscesses result from infection of an intraperitoneal hematoma that develops following surgery. Less frequently, intra-abdominal abscesses are unassociated with previous surgery and are usually attributable to spontaneous inflammatory processes associated with a small, localized perforation, such as in appendicitis, diverticulitis, and Crohn's disease.<sup>3,4</sup> Visceral abscesses are most commonly caused by hematogenous or lymphatic spread of bacteria to the organ. Retroperitoneal abscesses may be caused by several mechanisms, including perforation of the gastrointestinal (GI) tract into the retroperitoneum and hematogenous or lymphatic spread of bacteria to retroperitoneal organs, particularly the inflamed pancreas.

### Pathophysiology of Abscess Formation

After bacterial contamination of the peritoneal cavity, a complex series of events is initiated that, under ideal circumstances, effects complete eradication of invading bacteria.

The three major defense mechanisms in the peritoneal cavity are (1) mechanical clearance of bacteria via the diaphragmatic lymphatics, (2) phagocytosis and destruction of suspended or adherent bacteria by phagocytic cells, and (3) sequestration and walling off of bacteria coupled with delayed clearance by phagocytic cells.<sup>5</sup> The first two mechanisms act rapidly, usually within hours. Egress of bacteria from the peritoneal cavity via the lymphatics is responsible for the early septic response due to bacteremia and initiation of the innate immune response to infection.

The initial peritoneal response to bacterial contamination is characterized by hyperemia, exudation of protein-rich fluid into the peritoneal cavity, and a marked influx of phagocytic cells. Resident peritoneal macrophages predominate early in the infection, but the rapid influx of neutrophils after a 2- to 4-hour delay makes them the predominant phagocytic cell in the peritoneal cavity for the first 48–72 hours.<sup>6</sup> The combination of resident peritoneal cells plus the influx into the peritoneum serves to propagate the initiation of the innate immune response, including the elaboration of inflammatory cytokines and the procoagulant response. In humans with severe intra-abdominal infection, peritoneal levels of tumor necrosis factor- $\alpha$  (TNF- $\alpha$ ), interleukin (IL)-1, and IL-6 are higher than levels measured simultaneously in plasma.<sup>7,8</sup> Haecker and colleagues reported that TNF- $\alpha$  and IL-10 levels are increased and reach 100- to 1000-fold that is observed in the plasma following appendiceal perforation. In adult patients, a correlation between the magnitude of the cytokine response and outcome in infected patients has been demonstrated in several clinical studies.<sup>9</sup> Higher levels of circulating TNF- $\alpha$  and IL-6 have been recorded in patients who later die with intra-abdominal infection.<sup>7</sup> Interestingly, elevated peritoneal levels persist even after systemic inflammatory response has abated. This suggests that during resolving peritonitis, there is compartmentalization of the response with local cytokine elaboration, thereby promoting local resolution of infection. Other cell types are likely important in the initiation of the local peritoneal response. Peritoneal mast cells and

mesothelial lining cells have also been shown to be potent producers of a range of cytokines and procoagulants. Fibrin deposition appears to play an important role in this compartmentalization of infection, not only by incorporating large numbers of bacteria within its interstices<sup>10</sup> but also by causing loops of intestine to adhere to each other and the omentum, thereby creating a physical barrier against dissemination. Fibrin deposition is initiated after the exudation of protein-rich fluid containing fibrinogen into the peritoneal cavity. The conversion of fibrinogen to fibrin is promoted by the elaboration of tissue factor by both mesothelial cells and stimulated peritoneal macrophages.<sup>11</sup> In addition, generation of other inflammatory mediator molecules and components of the complement cascade (eg, C3a and C5a) further promotes the development of local inflammation. The net effect of these responses is the localization of the bacterial infection in the peritoneal cavity, wherein ultimate resolution can occur. However, a number of local factors thwart complete resolution and presumably establish the local environment for persistent infection and hence abscess formation. These include regional fibrin deposition that impedes phagocytic cell migration, factors that inhibit phagocytic cell function such as hemoglobin, particulate stool, low pH, and hypoxia. On the microbial side, polymicrobial flora of these infections as well as the near ubiquitous presence of *Bacteroides fragilis* and its unique capsular polysaccharide have been implicated in persistence of infection and abscess formation. Considered together, while the process of abscess formation represents a successful outcome of the peritoneal response to bacterial contamination of the peritoneal cavity, one is left with a residual infection that carries with it morbidity and potential mortality and must be actively managed.

## Clinical Presentation and Diagnosis

### CLINICAL PRESENTATION

Diagnosis of an intra-abdominal abscess is based on clinical suspicion complemented by radiologic confirmation of the presence of the abscess. High spiking fevers, chills, tachycardia, tachypnea, and leukocytosis, associated with localized abdominal pain, anorexia, and delay in return of bowel function in the postoperative patient are the classic signs and symptoms associated with the presence of an intra-abdominal abscess. The presence of a well-localized tender mass on clinical examination is consistent with the presence of an abscess. However, there may be considerable variability in the clinical appearance of the patient with this infection, ranging from a relatively mild picture where the patient appears generally well but is “slow to recover” from his surgical procedure to those who manifest evidence of profound systemic inflammation. There may be no mass palpable on clinical examination. A number of factors may contribute to this variability, including patient factors such as age, immunocompetence, and concurrent use of antimicrobials,

as well as abscess factors such location and size of the abscess and how well walled off the abscess is. For example, subphrenic abscesses can present with vague upper quadrant abdominal pain, referred shoulder pain, and occasionally hiccoughs but with no localized abdominal tenderness or palpable mass. By contrast, paracolic abscesses present with localized tenderness and may manifest as a palpable mass on abdominal examination. Pelvic abscesses may also cause local irritation of the urinary bladder causing frequency, or of the rectum resulting in diarrhea and tenesmus. Retroperitoneal collections, particularly psoas abscesses, can manifest as leg and back pain with muscular spasm and flexion deformity of the hip. In reality, with the ready availability of computed tomography (CT) scanning in most institutions, almost any deviation from the normal recovery trajectory in the postoperative period will prompt a CT scan and possible early detection of the abscess.

### DIAGNOSTIC TESTS

Imaging provides the definitive evidence of the presence of an intra-abdominal abscess. Abdominal plain films can be helpful in identifying air-fluid levels in the upright or decubitus positions, extraluminal gas, or a soft tissue mass displacing the bowel. In the postoperative patient, however, extraluminal gas may be present for up to 7 days. Overall, plain radiography may suggest the presence of an abscess, but other imaging modalities have essentially replaced plain films in the evaluation of intra-abdominal abscesses.

CT scanning has emerged as the radiological investigation of choice in the diagnosis of intra-abdominal abscess.<sup>12</sup> With its ready availability, it has essentially supplanted abdominal ultrasound (US) as the main diagnostic tool in this setting, mainly because of its accuracy, but also because its functionality is not impaired in the setting of ileus, wound dressings, stomas, and the open abdomen. The accuracy of the scan is improved if contrast is used. IV contrast increases the accuracy of defining the presence of an abscess, while GI tract contrast helps to distinguish fluid-filled bowel loops from an abscess and in addition may detect the presence of an anastomotic leak. In a retrospective study that compared US and CT in diagnosing intra-abdominal abscesses, the sensitivity of US in 123 patients was 82% compared to 97% in 74 patients by CT, and the overall accuracy of US was found to be 90% versus 96% for CT.<sup>13</sup> Criteria for identification of an abscess by CT have been well described and include identification of an area of low CT attenuation in an extraluminal location or within the parenchyma of solid abdominal organs. The density of abscesses usually falls between that of water and solid tissue.<sup>14</sup> Other radiological signs of an abscess are mass effect that replaces or displaces normal anatomic structures, a lucent center that is not enhanced after the intravenous administration of a contrast medium, enhancing rim around the lucent center after IV contrast administration, and gas in the fluid collection. One of the major advantages of CT over US is the ability to detect abscesses in the retroperitoneum and pancreatic area. There are also some disadvantages



to CT scanning. In the absence of contrast rim enhancement, gas or visible septations, CT cannot distinguish between sterile and infected fluid collections. Occasionally, there may be a solid-appearing collection that is really an abscess with a high leukocyte and protein content. Septations and other signs of loculated abscesses can often be better visualized with US than CT. Finally, CT scanning is sometimes unable to differentiate between subphrenic and pulmonic fluid, a relatively common situation in abdominal surgery.<sup>15</sup> In these limited circumstances, US may be considered as a complement to CT imaging.

Other modalities include magnetic resonance imaging (MRI). While MRI can sometimes better delineate the extent of an abscess, particularly in relation to adjacent soft tissue structures such as muscles and major blood vessels, it does not clearly have advantages over CT scanning and its practicality may be limited in the sick surgical patient.<sup>16</sup> One area where US and MRI may be relevant is in the investigation of the pregnant patient with abdominal pain.<sup>17</sup> US is particularly useful when appendicitis/appendiceal abscess is suspected, and MRI may be useful when localization is less clear. The roles of radiolabelled compounds in the diagnosis of abdominal abscesses are limited at present.<sup>18</sup>

## Management

The basic principles underlying the successful treatment of intra-abdominal abscesses are threefold:

1. Adequate resuscitation and support
2. Antimicrobial therapy
3. Source control/abscess drainage

### RESUSCITATION AND SUPPORT

In keeping with the variable presentation of patients with intra-abdominal abscesses, the initial approach to resuscitation and support will vary considerably. Attention to the ABCs (airway, breathing, circulation) while individualizing the intervention for each patient according to his/her deviation from normal physiology is appropriate. Particularly in the postsurgical patient, nutritional support should be considered. When feasible, oral nutrition should be given in preference to total parenteral nutrition. Some patients are able to ingest food and/or supplements by mouth, while others might require an enteral feeding tube, due to anorexia, precluding adequate ingestion of nutrients. Systematic review of the literature suggests that infectious complications and cost are reduced in critically ill patients receiving enteral nutrition compared to parenteral nutrition.<sup>19</sup> One can presumably extrapolate to patients with intra-abdominal infection. When abscess formation occurs due to an anastomotic leak, there is a sense that this might preclude use of enteral nutrition. This concern is likely unfounded, unless there is profound ileus associated with the infection.

### ANTIMICROBIAL THERAPY

Considerations regarding antimicrobial use are based on the microbial flora recovered from the infections. Over the past decade, there has been increasing appreciation that there is an evolution of the flora with increasing severity of abdominal infection.<sup>20</sup> For example, Table 10-1 shows the bacteriology of peritonitis in patients with community-acquired peritonitis and those with postoperative peritonitis. The major pathogens in community-acquired intra-abdominal infections are coliforms (esp. *Escherichia coli*) and anaerobes (esp. *B. fragilis*). As illustrated, while both are polymicrobial, postoperative peritonitis has a higher incidence of more resistant microbes. Aside from patients with postoperative peritonitis, other factors predict this shift in microbiology, including advanced age, severe physiologic derangement, immunosuppression, previous use of antibiotics, and residence in a health care institution in hospitals and nursing homes, etc. Guidelines have been developed recently by the Surgical Infection Society and the Infectious Diseases Society of America regarding the use of antimicrobial therapy in intra-abdominal infection.<sup>21</sup> These authors have risk-stratified patients into three categories and provided recommendations for empiric antimicrobial regimens according to category. The three categories are (1) community-acquired infections of mild to moderate severity; (2) high-risk or severe community-acquired infections; and (3) health care-associated infections. Factors that dictate conversion from mild-to-moderate severity to high severity include severe physiologic derangement (eg, high Acute Physiology and Chronic Health Evaluation II [APACHE II] score), advanced

**TABLE 10-1: MICROBIOLOGY OF COMMUNITY-ACQUIRED PERITONITIS COMPARED TO HEALTH CARE-ASSOCIATED PERITONITIS**

Strain	Percent of Isolates of	
	Community-Acquired	Postoperative (Health Care-Associated)
Enterococci	5	21
<i>Escherichia coli</i>	36	19
<i>Enterobacter</i> sp	3	12
<i>Bacteroides</i> sp	10	7
<i>Klebsiella</i> sp	7	7
<i>Staphylococcus aureus</i>	1	6
Coagulase-negative staph	1	5
<i>Candida</i>	7	4
<i>Pseudomonas</i> sp	2	6
Streptococci	14	4
Hemolytic strep	3	0
Other	11	9

From Roehrborn A, Thomas L, Potreck O, et al. The microbiology of postoperative peritonitis. *Clin Infect Dis*. 2001;33:1513.


**TABLE 10-2: RECOMMENDATIONS FOR ANTIMICROBIAL THERAPY IN THE COMMUNITY-ACQUIRED SETTING**

Regimen	Community-Acquired Infection in Pediatric Patients	Community-Acquired Infection in Adults	
		Mild-to-Moderate Severity: Perforated or Abscessed Appendicitis and Other Infections of Mild-to-Moderate Severity	High Risk or Severity: Severe Physiologic Disturbance, Advanced Age, or Immunocompromised State
Single agent	Ertapenem, meropenem, imipenem-cilastatin, ticarcillin-clavulanate, and piperacillin-tazobactam	Cefoxitin, ertapenem, moxifloxacin, tigecycline, and ticarcillin-clavulanic acid	Imipenem-cilastatin, meropenem, doripenem, and piperacillin-tazobactam
Combination	Ceftriaxone, cefotaxime, cefepime, or ceftazidime, each in combination with metronidazole; gentamicin or tobramycin, each in combination with metronidazole or clindamycin, and with or without ampicillin	Cefazolin, cefuroxime, ceftriaxone, cefotaxime, ciprofloxacin, or levofloxacin, each in combination with metronidazole <sup>a</sup>	Cefepime, ceftazidime, ciprofloxacin, or levofloxacin, each in combination with metronidazole <sup>a</sup>

<sup>a</sup> Because of increasing resistance of *Escherichia coli* to fluoroquinolones, local population susceptibility profiles and, if available, isolate susceptibility should be reviewed. From Solomkin JS, Mazuski JE, Bradley JS, et al. Diagnosis and management of complicated intra-abdominal infection in adults and children: guidelines by the Surgical Infection Society and the Infectious Diseases Society of America. *Clin Infect Dis*. 2010;50:133, with permission.

age, or immunocompromised state. Table 10-2 shows the recommended agents according to this stratification. These guidelines are therefore readily applicable to decision making regarding patients coming into the hospital with abscesses, including processes such as appendiceal abscess or peridiverticular abscess. It is noteworthy that while enterococcus is frequently recovered in isolates in these infections, the evidence demonstrates no additional benefit to treating this microbe as part of empiric therapy. When possible, switchover to oral agents is appropriate. The duration of antibiotics should be 4–7 days, anticipating resolution of the clinical signs and symptoms during this period. Should there be no resolution by this time, reevaluation of the patient for the presence of persistent infection in the abdomen and elsewhere is appropriate.

Patients who present in the postsurgical period fall into the category of patients with health care–associated infection. In these patients, empiric therapy should include agents with expanded spectra against gram-negative aerobic and facultative bacilli, including meropenem, imipenem-cilastatin, doripenem, piperacillin-tazobactam, or ceftazidime or cefepime in combination with metronidazole. Table 10-3 shows the considerations regarding selection depending on local institutional microbial isolates. Empiric anti-enterococcal treatment should be given. Treatment of *Candida* with fluconazole when recovered from cultures and treatment of methicillin-resistant *Staphylococcus aureus* with vancomycin should be followed if the patient is colonized with the microbe.

## SOURCE CONTROL

*Source control* is a term used to include all physical measures taken to control a focus of infection. Here we focus our

discussion to abscess drainage, but adequate source control may also include debridement of necrotic tissue, surgical repair, resection, and/or exteriorization of the anatomic defect causing peritoneal contamination.<sup>22</sup>

Over the past two decades, percutaneous drainage of abscesses has become an established technique and a safe alternative to surgery. This evolution of care has not been based on a series of strong randomized trials showing equivalence or superiority of this approach. Rather, observational studies from a number of centers have shown it to be a safe effective alternative to surgical intervention, with equivalent success rates, comparable mortality (10–20%) and morbidity (~25%).<sup>23–25</sup> Combined with other advantages of percutaneous approaches including avoidance of general anesthesia, lower costs, and the potential for fewer complications, it has now become the default approach to abscess management. Prerequisites for catheter drainage include an anatomically safe route to the abscess, a well-defined unilocular abscess cavity, concurring surgical and radiologic evaluation, and surgical backup for technical failure. Multiple abscesses, abscesses with enteric connections as seen with enterocutaneous fistulas, and the need to traverse solid viscera are not contraindications. Indeed, as the technique has evolved over several decades, the barriers to accessing unusually positioned collections have disappeared with the use of unconventional routes (transgluteal, transvaginal, transrectal) and the advent of new technologies including endoscopic US.<sup>26,27</sup> Even the presence of septations and loculations has not precluded at least an attempt to use percutaneous drainage.<sup>28</sup>

Percutaneous drainage can be performed with US or CT guidance. CT provides for more precise identification of organs and bowel loops and is more accurate for planning of drainage route.<sup>15</sup>

**TABLE 10-3: RECOMMENDATIONS FOR ALTERATIONS IN ANTIMICROBIAL THERAPY IN THE HEALTH CARE–ASSOCIATED SETTING**

Organisms Seen in Health Care–associated Infection at the Local Institution	Regimen				
	Carbapenem <sup>a</sup>	Piperacillin-Tazobactam	Ceftazidime or Cefepime, Each With Metronidazole	Aminoglycoside	Vancomycin
<20% Resistant <i>Pseudomonas aeruginosa</i> , ESBL-producing Enterobacteriaceae, <i>Acneobacter</i> , or other MDR GNB	Recommended	Recommended	Recommended	Not recommended	Not recommended
ESBL-producing Enterobacteriaceae	Recommended	Recommended	Not recommended	Recommended	Not recommended
<i>P. aeruginosa</i> >20% resistant to ceftazidime	Recommended	Recommended	Not recommended	Recommended	Not recommended
MRSA	Not recommended	Not recommended	Not recommended	Not recommended	Recommended

ESBL, extended-spectrum  $\beta$ -lactamase; GNB, gram-negative bacilli; MDR, multidrug resistant; MRSA, methicillin-resistant *Staphylococcus aureus*.

NOTE. "Recommended" indicates that the listed agent or class is recommended for empiric use, before culture and susceptibility data are available, at institutions that encounter these isolates from other health care–associated infections. These may be unit- or hospital-specific.

<sup>a</sup> Imipenem-cilastatin, meropenem, or doripenem

Reproduced from Solomkin JS, Mazuski JE, Bradley JS, et al. Diagnosis and management of complicated intra-abdominal infection in adults and children: guidelines by the Surgical Infection Society and the Infectious Diseases Society of America. *Clin Infect Dis*. 2010;50:133, with permission.

Once the abscess is identified, initial diagnostic aspiration should be sent for Gram's stain and microbiological culture. The catheter used for drainage should be as small as possible for safety, yet large enough so that the tubing does not become obstructed. Most commonly used catheters range in size from 8 to 12F. With appropriate catheter placement, the abscess cavity typically decompresses and collapses. Irrigation of the catheter should be done once daily to ensure tube patency. As catheter drainage decreases, repeat CT scanning can be performed to evaluate for residual contents. If drainage increases over time or continues at a steady rate, the development of an enteric fistula must be suspected. This may not have been unexpected when the catheter was initially placed near a perianastomotic abscess or an abscess adjacent to some underlying pathological process. Potential complications of catheter placement include bacteremia, sepsis, vascular injury, enteric puncture, cutaneous fistula, or transpleural catheter placement.

Catheters should be maintained on closed drainage systems. There does not appear to be benefit to the use of suction or irrigation of these catheters, although flushing once per day with saline ensures patency. Patients should respond with defervescence of symptoms within 48 hours of catheter insertion. If they do so, a repeat CT scan is done at approximately 5–7 days to ensure shrinkage of the abscess. Criteria for removal of the drain include (1) clinical resolution of septic parameters, including patient well-being, normal temperature, and leukocyte count; (2) minimal drainage from the catheter; and (3) CT evidence of the resolution of the abscess.

As noted previously, studies comparing outcomes of surgical and percutaneous drainage of intra-abdominal abscesses

demonstrate comparable efficacy. In one study, patients were matched for age, abscess location, and etiology, and had similar APACHE II scores. There were no differences between percutaneous and surgical drainage in patient morbidity, mortality, or duration of hospital stay.<sup>24</sup> Furthermore, initial percutaneous drainage of abscesses in the context of diverticular disease allowed for subsequent definitive operative resection and primary anastomosis in one rather than two operations. Another group retrospectively examined postoperative intra-abdominal abscesses after laparotomy. This study similarly demonstrated that use of either form of drainage resulted in similar cure rates for postoperative intra-abdominal abscesses.<sup>25</sup>

With clear demonstration of its efficacy when compared to surgical drainage, percutaneous drainage should be considered the preferred approach in source control of abscesses. Table 10-4 shows outcome of percutaneous drainage according to underlying pathological processes. In general, one should predict a successful outcome in patients with a single, well-defined abscess with no enteric communication. The presence of enteric communication per se does not reduce the likelihood of success as it is defined by the resolution of the infection. In a postoperative abscess, following drainage of the infection, the underlying anastomotic defect will usually close. In other settings, there may be a requirement for subsequent surgery to manage the underlying disease process such as diverticular disease or Crohn's disease. For example, in one study, approximately 75% of patients with large peridiverticular abscesses were drained percutaneously and then they went on to a single-stage sigmoid colectomy.<sup>28</sup> Other circumstances such as fungal abscesses, infected


**TABLE 10-4: DETERMINANTS OF OUTCOME FOLLOWING PERCUTANEOUS DRAINAGE OF ABSCESES**

Clinical Condition	Successfully Treats Abscess	Comment
Single, well-defined bacterial abscess with no enteric communication	Yes	
Abscess with enteric communication (eg, diverticular abscess or Crohn's disease abscess)		May require subsequent surgery to treat pathological process or residual fistula
Interloop abscess or other difficult-to-access abscesses (eg, deep pelvic)	Usually	Requires alternative approaches to access successfully, eg, transrectal, transvaginal, transluteal, etc
Early postoperative diffuse peritonitis (eg, caused by anastomotic dehiscence or bile peritonitis)	Low	Inappropriate—needs surgery
Infected tumor mass	Low	Inadequate drainage
Fungal abscess		
Infected hematoma		
Pancreatic necrosis		
Small abscess (<4 cm in diameter)	Low	Difficult to drain; antibiotics alone may be suitable

hematomas, peripancreatic necrosis, or necrotic-infected tumor have a lower success rate for percutaneous drainage and early consideration for surgical intervention.<sup>29</sup> CT features such as the presence of a “rind,” a sharp exterior margin, air-fluid levels, and septations do not predict outcome and therefore should not be determinants as to whether or not initial percutaneous drainage should be used.<sup>30</sup> Finally, one should use clinical judgment as to the need for percutaneous drainage for small abscess (<5 cm diameter) such as those that might occur associated with acute diverticulitis, Crohn's disease, and interloop collections. These may well respond to antibiotics alone, and the use of percutaneous drainage may be meddlesome and potentially morbid.<sup>31</sup>

There are circumstances where percutaneous drainage should be considered contraindicated. Most important among these is the circumstance where peritoneal infection is not localized, such as in the early postsurgical period where an anastomotic leak leads to diffuse peritonitis. Abdominal CT scans performed in this scenario may demonstrate one or more discrete fluid collections. When there is diffuse peritoneal irritation on clinical examination, fluid collections distant from the anastomosis, or the presence of massive intraperitoneal air, surgical intervention is clearly indicated. Attempts to manage such situations with percutaneous interventions invariably lead to delayed definitive surgical management and adverse outcome.

## SURGICAL DRAINAGE

As stated previously, percutaneous drainage is the procedure of choice for the majority of intra-abdominal abscesses, with the

caveats being those indicated. Specifically, when the infection is diffuse rather than localized, surgical intervention is clearly indicated. Second, when the content of the abscess is too thick for percutaneous drainage, an initial percutaneous attempt may be reasonable, but conversion to surgery early in the course is reasonable. Finally, when access is impossible, surgery is indicated. This last circumstance is increasingly rare.

The transperitoneal approach allows for examination of the entire abdominal cavity and allows for the drainage of multiple abscesses. Subphrenic abscesses and right subhepatic abscesses may also be approached by lateral abdominal incisions. Once abscess cavities are identified, they are entered and drained quickly to minimize spillage and contamination of the rest of the peritoneal cavity. The abscess cavity should then be widely opened. Specimens should be sent for Gram's stain and culture. Copious warm irrigation must be used at the end of the operation to properly cleanse the abdominal cavity. Closed-suction drains should be placed in dependent positions to reduce the risk of reaccumulation. In extremely contaminated cases, the incision may be left open and packed to prevent wound infection.

## ENTERIC FISTULAS

### Introduction

A *fistula* is defined as an abnormal communication between two epithelial surfaces. Enteric fistulas may arise in a number of settings: (1) diseased bowel extending to



surrounding epithelialized structures; (2) extraintestinal disease eroding into otherwise normal bowel; (3) surgical trauma to normal bowel including inadvertent or missed enterotomies; or (4) anastomotic disruption following surgery for a variety of conditions. The first two generally occur spontaneously, while the latter two occur following surgical procedures. For the surgeon, the latter two are generally more problematic, in part because they are iatrogenic complications of surgery, but also because their early management often requires treatment of the critically ill patient with sepsis.

While this chapter overviews general considerations regarding the pathophysiology and management of enteric fistulas, it focuses on postsurgical enteric fistulas, particularly fistulas to the skin, that is, enterocutaneous fistulas. In this particular patient population, the mortality rate remains high, between 3 and 22% in series dating back six decades, largely due to the frequent complications of sepsis and malnutrition (Table 10-5). Successful outcome requires a multidisciplinary team of health care workers, including surgeons, infectious disease specialists, intensivists, radiologists, nurses, enterostomal therapists, and nutrition specialists. Management of these patients must also take into account the psychosocial and emotional needs of the patient and his/her family through a prolonged and often complex treatment course.

One of the challenges in attempting to discern optimal management of these patients relates to the quality of the medical literature. Most reports are retrospective reviews of large case series emanating from referral institutions. Notwithstanding this shortcoming, these series provide general approaches to therapy, which help to guide treatment.

## Classification

Fistulas involving the alimentary tract have traditionally been classified in three distinct ways: by the *etiology* responsible for their formation, that is, spontaneous versus postoperative, by the *anatomy* of the structures involved, and finally by the *amount and composition of drainage from the fistula*. Such distinctions may provide important prognostic information about the physiologic impact of fistulas and the likelihood that they will close without surgical intervention.

### SPONTANEOUS VERSUS POSTOPERATIVE

Enterocutaneous fistulas may be classified as either spontaneous or postoperative. Approximately three-quarters of fistulas occur in the postoperative setting, most commonly subsequent to procedures performed for malignancy, inflammatory bowel disease (IBD), or adhesive bowel obstruction.<sup>32</sup> These fistulas become evident to the surgeon in a number of different ways: (1) They may occur in the early postoperative period as a septic complication of surgery, sometimes with catastrophic physiological deterioration. This is usually a result of uncontrolled diffuse intra-abdominal infection caused by anastomotic leakage, breakdown of enterotomy closure, or a missed enterotomy. (2) They may occur in a more delayed manner, following treatment of a postsurgical infection with percutaneous drainage of a deep abscess or opening of a superficial wound infection may reveal that an underlying connection to the GI tract as a cause. (3) They may occur very late after the surgery due to unanticipated injury to the GI tract. The development of a wound infection following use of mesh for hernia repair would fall into this category either through erosion of mesh into bowel or due



**TABLE 10-5: COLLECTED SERIES OF OUTCOMES IN PATIENTS WITH OPERATIVE REPAIR OF ENTEROCUTANEOUS FISTULAS**

Source	Period	No. (%)		
		Definitive Operation	Recurrence	Death
Edmunds et al, <sup>32</sup> 1960	1946–1959	67	8 (12)	10 (15)
Soeters et al, <sup>33</sup> 1979	1960–1970	76	13 (17)	11 (14)
Reber et al, <sup>34</sup> 1978	1968–1977	108	22 (20)	22 (20)
Aquirre et al, <sup>35</sup> 1974	1970–1973	38	8 (30)	6 (22)
Soeters et al, <sup>33</sup> 1979	1970–1975	88	19 (22)	18 (20)
Conter et al, <sup>36</sup> 1988	1978–1986	46	5 (11)	4 (9)
Hollington et al, <sup>37</sup> 2004	1992–2002	167	55 (33)	5 (3) <sup>a</sup>
Lynch et al, <sup>38</sup> 2004	1994–2001	203	42 (21)	6 (3)
Draus et al, <sup>39</sup> 2006	1997–2005	77	8 (11)	<sup>b</sup>
Vijschers et al, <sup>40</sup> 2008	1990–2005	107	10 (9)	13 (12)
Brenner et al, <sup>41</sup> 2009	1989–2005	135	23 (17)	11 (8)

<sup>a</sup> These deaths were “fistula related within 30 days of surgery.”

<sup>b</sup> The number of deaths in patients who were operated on could not be determined in this study.

Adapted from Brenner M, Clayter JL, Tillou A, et al. Risk factors for recurrence after repair of enterocutaneous fistula. *Arch Surg*. 2009;144:500–505, with permission.

to iatrogenic injury to the bowel as one attempts to debride infected mesh. Overly aggressive management of an open abdominal wound can also lead to intestinal injury and fistula formation. This complication has been reported to occur in up to 25% of patients during treatment with an open abdomen for abdominal sepsis.<sup>42</sup>

The remaining 25% of fistulas occur spontaneously, that is, without an antecedent surgical intervention. These fistulas often develop in the setting of cancer or inflammatory conditions. Fistulas occurring in the setting of malignancy or irradiation are unlikely to close without operative intervention. Inflammatory conditions such as IBD, diverticular disease, perforated ulcer disease, or ischemic bowel can result in fistula development.<sup>43</sup> Of these, fistulas in patients with IBD are most common; these fistulas may close following a prolonged period of parenteral nutrition, only to reopen when enteral nutrition resumes.<sup>33</sup>

## ANATOMIC CLASSIFICATION

Fistulas may communicate with the skin (external fistulas: entero- or colocutaneous fistulas) or other intra-abdominal or intrathoracic organs (internal fistulas). Internal fistulas that bypass only short segments of bowel may not be symptomatic; however, internal fistulas of bowel that bypass significant length of bowel or that communicate with either the bladder or vagina typically cause symptoms and become clinically evident. Identification of the anatomic site of origin of external fistulas may provide further information on the etiology and management of the fistula.

**Oral, Pharyngeal, and Esophageal Fistulas.** Radical resections and reconstructions for head and neck malignancy may be complicated by postoperative fistulas in 5–25% of cases.<sup>44</sup> Alcohol and tobacco use, poor nutrition, and preoperative chemoradiation therapy all contribute to poor wound healing and increase the risk of fistula formation. Failure of closure of the pharyngeal defect at the base of the tongue most commonly leads to fistula formation, and free microvascular flaps are the preferred method for closure. Brown and colleagues reported a significantly decreased postoperative fistula rate in patients who underwent free flap closure versus those with pedicled pectoralis flap closure, 4.5 versus 21%, respectively.<sup>45</sup> Most esophagocutaneous fistulas result from either breakdown of the cervical anastomosis following resection of esophageal malignancy or following esophageal trauma. Less common causes of oropharyngeocutaneous or esophagocutaneous fistula include tuberculosis, laryngeal or thoracic surgery, trauma, congenital neck cysts, anterior cervical spine fusion, and foreign body perforations.<sup>46–48</sup>

**Gastric Fistulas.** The most commonly reported procedure associated with gastrocutaneous fistula formation is the removal of a gastrostomy feeding tube, particularly in children. The duration of gastrostomy tube placement appears to be related to the likelihood of development of a fistula after tube removal, with nearly 90% of children developing a fistula

when the tube had been in situ for more than 9 months.<sup>49</sup> The rate of gastrocutaneous fistula following operations for non-malignant processes such as ulcer disease, reflux disease, and obesity is between 0.5 and 3.9%.<sup>50</sup> The recent rapid increase in the number of bariatric surgical procedures was anticipated to lead to an increase in the incidence of gastrocutaneous fistula following surgery for benign disease, as the rate of anastomotic leakage after gastric bypass surgery is 2–5%. One study has reported that approximately 10% of patients with staple line leaks go on to form chronic fistulas, making the overall rate less than 0.5%.<sup>51</sup> Fistula formation following resection for gastric cancer remains a dreaded complication with significant mortality rates. Spontaneous gastrocutaneous fistulas are uncommon but can result from inflammation, ischemia, cancer, and radiation.

**Duodenal Fistulas.** The majority of duodenocutaneous fistulas develop after distal or total gastric resections or surgery involving the duodenum or pancreas. Inadvertent injury to or intentional excision of a portion of the duodenum during surgery of the colon, aorta, kidney, or biliary tract may also result in fistula formation. Spontaneous cases resulting from trauma, malignancy, Crohn's disease, and ulcer disease account for the remaining duodenal fistulas.<sup>52,53</sup> Prognostically, duodenal fistulas segregate into two groups: lateral duodenal fistulas and duodenal stump fistulas. Some authors have reported a decreased spontaneous closure rate with lateral duodenal fistulas when compared to that with duodenal stump fistulas.<sup>32,54</sup>

**Small Bowel Fistulas.** Fistulas arising in the small bowel account for the majority of gastrointestinal-cutaneous fistulas, the majority of which (70–90%) occur in the postoperative period.<sup>33,34,55</sup> Postoperative small bowel fistulas result from either disruption of anastomoses (either small bowel anastomoses or small bowel to colon anastomoses) or inadvertent and unrecognized injury to the bowel during dissection or closure of the abdomen. Operations for cancer, IBD, and adhesiolysis for bowel obstruction are the most common procedures antecedent to small bowel fistula formation. As noted previously, spontaneous small bowel fistulas arise from IBD, cancer, peptic ulcer disease, or pancreatitis. Crohn's disease is the most common cause of spontaneous small bowel fistula. The transmural inflammation underlying Crohn's disease may lead to adhesion of the small bowel to the abdominal wall or other abdominal structures. Microperforation may then cause abscess formation and erosion into adjacent structures or the skin. Approximately half of Crohn's fistulas are internal and half are external.<sup>56–58</sup> Crohn's fistulas typically follow one of two courses. The first type represents fistulas that present in the early postoperative period following resection of a segment of diseased bowel. These fistulas arise in otherwise healthy bowel and follow a course similar to non-Crohn's fistulas with a significant likelihood of spontaneous closure. The other group of Crohn's fistulas arises in diseased bowel and has a low rate of spontaneous closure.

**Appendiceal Fistulas.** Fistulas of appendiceal origin may result from drainage of an appendiceal abscess or post-appendectomy in a patient either without or with Crohn's disease.<sup>59,60</sup> In the latter case, the fistula often originates from the terminal ileum, not the cecum. The inflamed ileum adheres to the abdominal wall closure and subsequently results in fistula formation.

**Colonic Fistulas.** While spontaneous fistulas of the colon may result from inflammatory conditions such as diverticulitis, appendicitis and IBD, or from advanced malignancy, the majority of colocutaneous fistulas are postsurgical, usually secondary to anastomotic breakdown following colonic resection for one of these conditions. Preoperative radiation therapy reduces the risk of local recurrence and death from advanced rectal cancer and is an accepted practice.<sup>61</sup> However, radiation therapy contributes to both spontaneous and post-operative colocutaneous fistulas. Russell and Welch authors reported a 31% incidence of breakdown of primary anastomoses performed in irradiated tissues with resulting sepsis or fistula formation.<sup>62</sup>

### PHYSIOLOGIC CLASSIFICATION

Traditionally, fistulas have been classified into high-output (>500 mL/d), moderate-output (200–500 mL/d), and low-output (<200 mL/d) groups. Enterocutaneous fistulas cause the loss of fluid, minerals, trace elements, and protein, and, when improperly managed, they can result in profound irritation of the skin and subcutaneous tissues. Depending on the origin of the fistula and its anatomy, the amount of output and nature of the effluent may be estimated (Table 10-6). However, direct measurement of these parameters for an individual fistula allows for accurate replacement and an understanding of the physiologic and metabolic challenges to the patient. Classification of enterocutaneous fistulas by the volume of daily output provides information regarding mortality and has been used to predict spontaneous closure and patient outcome.<sup>32,63–65</sup> In the classic series of Edmunds and associates, patients with high-output fistulas had a mortality rate of 54%, compared to a 16% mortality rate in the low-output group.<sup>32</sup> More recently, Levy and colleagues reported a 50% mortality rate in patients with high-output fistulas, while those with low-output fistulas had a 26% mortality.<sup>63</sup> Soeters and coworkers reported no association between fistula output and rate of spontaneous closure,<sup>33</sup> while multivariate analysis by Campos and associates suggested that patients with low-output fistulas were three times more likely to achieve closure without operative intervention.<sup>65</sup> The reason for these different closure rates most likely relates to the nature of the particular fistula, rather than the volume of output per se. If the fistula totally diverts flow, for example a pouting small bowel opening in the center of an open abdomen, it will be both high output and unlikely to close, without these two factors being causally related. By contrast, a defect at a small bowel anastomotic site with a long fistula tract and no local infection will likely be walled off by surrounding tissues and

**TABLE 10-6: PREDICTED OUTPUT AND ELECTROLYTE COMPOSITION OF FISTULAS ACCORDING TO LOCATION**

Source	Volume (mL/d)	pH	Na	K	HCO <sub>3</sub> <sup>-</sup>	Cl
Gastric	2000–2500	<4	60	10	—	90
		>4	100	10	—	100
Pancreatic	1000		140	5	90–110	30–45
Bile	1500		140	5	35	100
Small bowel	3500		100–130	15	25–35	100–140

All values for sodium, potassium, bicarbonate, and chloride given in milliequivalents per liter.

Adapted from Evenson AR, Fischer JE. Current management of enterocutaneous fistula. *J Gastrointest Surg.* 2006;10:455.

close spontaneously. These fistulas, while initially high output, will often close because of favorable local conditions. In essence, prediction of closure should be based on the local conditions, and particularly the nature of the fistula rather than the output. To the extent that the output often reflects the nature of the fistula, it will then be predictive.

### Predicting Closure of Enterocutaneous Fistulas

Spontaneous closure of enterocutaneous fistulas without the need for major surgical intervention is clearly a desirable outcome for these patients. The precise probability of spontaneous closure is somewhat difficult to assess since the large series reporting management of fistulas are usually derived from specialty centers for fistula management and thus not only represent a biased sample but also reflect differences in referral practice. Thus, spontaneous closure has been reported to occur in 10–75% of patients.<sup>36,39,40,66,67</sup> Nevertheless, a number of factors have been suggested to be predictive of failure of spontaneous closure of fistulas (Table 10-7). Some of these factors are modifiable, for example nutritional status, presence of local infection, and foreign bodies, while many do not include location, presence of an open wound, and the presence of distal obstruction. Knowledge of these factors should prove to be helpful in discussion of outcome with the patient and family members, as well as with the multidisciplinary team.

### Risk Factors and Prevention of Enterocutaneous Fistulas

The majority of enterocutaneous fistulas arise in the post-operative period, often related to leakage of small bowel/colonic anastomoses or enterotomy closure. A number of factors have been associated with postsurgical enteric leaks. These can be divided into patient factors such as old age,



**TABLE 10-7: FACTORS THAT PREDICT FAILURE OF SPONTANEOUS FISTULA CLOSURE**

- Distal obstruction
- Local infection
- Foreign body
- Open abdomen
- Epithelialized tract
- Fistula characteristics:
  - Multiple fistula openings
  - Defect >1 cm
  - Short fistula tract
- Abnormal bowel at origin of fistula (radiation, inflammatory bowel disease)
- Profound malnutrition
- High-output fistula
- Jejunal origin of fistula

Adapted from Evenson AR, Fischer JE. Current management of enterocutaneous fistula. *J Gastrointest Surg.* 2006;10:455.

immunosuppression, malnutrition, emergency surgery, and peritoneal contamination, and surgical factors such as emergency surgery, level of anastomosis, preoperative radiation, duration of surgery, blood loss, tension on anastomosis, inadequate blood supply to anastomosis, and technical error in suturing or stapling. Use of mechanical bowel preparation, anastomotic technique (stapled vs hand-sewn; single vs double layer), and omentoplasty has not been shown to influence anastomotic integrity. A recent meta-analysis in 2008 of 13 trials and 4601 patients showed no difference in the anastomotic leak rate when a mechanical bowel preparation was used compared to when it was not used in elective colon resection.<sup>68</sup>

Clearly, optimization of modifiable factors will serve to reduce anastomotic leak. In the elective setting, operations may be delayed to allow for normalization of nutritional parameters, thus optimizing wound healing and immune function. In emergency operations, the luxury of optimizing nutritional status preoperatively is not possible. Instead, emphasis should be on adequate resuscitation and restoration of circulating volume, normalization of hemodynamics, and use of appropriate antibiotic therapy.

Once a patient has been optimized preoperatively, attention is then turned to operative techniques to minimize the development of a fistula. Performance of anastomoses in healthy, well-perfused bowel without tension provides the best chance for healing. Testing of the rectal and sigmoid anastomoses with intraoperative air insufflations has been shown to reduce “radiologic” leak rate through guiding placement of additional sutures as needed.<sup>69</sup> Careful hemostasis to avoid postoperative hematoma formation will decrease the risk of abscess, while inadvertent enterotomies and serosal injuries should be identified and repaired. A recent meta-analysis based on three randomized trials showed that omentoplasty

to buttress a colonic anastomosis did not reduce the rate of postoperative radiological leaks, alter mortality or change the need for reoperation.<sup>70</sup> However, while omentoplasty per se does not reduce the probability of anastomotic leakage, interposition of an omental flap to separate the anastomosis from the abdominal incision may lessen the probability of injuring the bowel during closure or of an enterocutaneous fistula should anastomotic leakage occur. A recent study pooling the data from five European randomized clinical trials studying rectal cancer care demonstrated that diverting stomas reduced the rate of symptomatic anastomotic leaks and improved overall survival but had no effect on cancer-specific survival.<sup>71</sup> The differential survival was primarily attributable to early postoperative mortality. Proximal diverting colostomy or ileostomy may allow sufficient anastomotic healing prior to suture-line challenge by luminal contents.

## Approach to Management

An organized treatment approach is of paramount importance to ensuring the optimal patient outcome. Table 10-4 lists overall mortality of patients presenting with enterocutaneous fistulas from a number of reports dating back six decades. Overall, the more recent studies appear to be associated with a lesser mortality rate, presumably a result of improvements in imaging, fluid resuscitation, antibiotic management, and intensive care support. However, the ultimate goals in treating patients with enterocutaneous fistulas are closure of the fistula with abdominal wall closure and return to baseline functioning level. Evenson and Fischer<sup>72</sup> outlined five distinct phases of management that can be used to guide care of this patient population. These phases are discussed in detail and also summarized in Table 10-8.

### PHASE 1: RECOGNITION AND STABILIZATION

**Identification and Resuscitation.** As noted in the Introduction, the clinical presentation of patients with enterocutaneous fistulas depends on the underlying pathophysiological process. Invariably, the patient who develops a postoperative enterocutaneous fistula will do well clinically for the first few days after operation. Within the first week, however, the patient may suffer delayed return of bowel function, as well as fever and leukocytosis, together suggestive of intra-abdominal infection. This setting will usually prompt a request for an abdominal CT scan that demonstrates a perianastomotic abscess. Percutaneous drainage for therapeutic management of the abscess will serve to confirm anastomotic disruption, either immediately or a few days later when there is evidence of enteric content. Occasionally, erythema of the wound develops and opening the wound reveals purulent drainage that is soon followed by enteric contents. In both these circumstances, the peritoneal host defenses have successfully walled off and contained infection. By contrast, in some patients, diffuse peritoneal contamination arising from a leaking anastomosis or enterotomy causes profound and





TABLE 10-8: APPROACH TO MANAGEMENT OF ENTEROCUTANEOUS FISTULAS

Phase	Goals	Time Course
Recognition/stabilization	Resuscitation with crystalloid, colloid, or blood Control of sepsis with percutaneous or open drainage and antibiotics Electrolyte repletion Provision of nutrition Control of fistula drainage Commencement of local skin care and protection	24–48 h
Investigation	Fistulogram to define anatomy and characteristics of fistula Other GI studies CT scan to define pathology Operative notes from prior surgery	7–10 d
Decision	Evaluate the likelihood of spontaneous closure Decide duration of trial of nonoperative management	10 d–6 wk When closure, unlikely or after 4–6 wk
Definitive management	Plan operative approach Refunctionalization of entire bowel Resection of fistula with end-to-end anastomosis Secure abdominal closure Gastrostomy and jejunostomy	Surgical intervention at 3–6 mo after patient stabilized
Postsurgical	Usual postoperative protocol Psychological and emotional support	Ensure access to ICU for management of potential complication Team approach to management facilitates recovery

CT, computed tomography; GI, gastrointestinal; ICU, intensive care unit.

Adapted from Evenson AR, Fischer JE. Current management of enterocutaneous fistula. *J Gastrointest Surg.* 2006;10:455.

rapid deterioration of the patient with diffuse abdominal tenderness, evidence of organ dysfunction, and hemodynamic instability. Usually, these patients exhibit signs of organ dysfunction in the days prior to their catastrophic deterioration, including reduced level of consciousness, tachycardia, and mild renal impairment. The diagnosis then becomes clear and management shifts from routine postoperative care to the management of a potentially critically ill patient. As with all critically ill patients, attention should turn to management of the ABCs. The patient with a localized collection or one that has necessitated into the wound can usually be managed on the ward, while the patient with a more significant septic response may require transfer to an intensive care unit (ICU) setting. In both scenarios, restoration of intravascular volume usually crystalloid is appropriate with or without inotropic support as determined by physiologic monitoring. A recent *Cochrane Database Systematic Review* showed no difference in outcome in critically ill patients managed with crystalloid versus colloid and therefore recommended crystalloid as the preferable resuscitation fluid.<sup>73</sup> The initiation of broad-spectrum antibiotic therapy should occur early and be directed toward the most likely pathogens involved. Patients with postoperative peritonitis have increased probability of having multiresistant microorganisms and should receive broader-spectrum antibiotics. The consensus guidelines published by the Surgical Infection Society/Infectious Diseases Society of America address antimicrobial options for these severe health care-associated infections<sup>21</sup> (see Tables 10-2 and 10-3).

**Control of Sepsis.** Uncontrolled infection with the development of a septic response and the concomitant fluid imbalance and malnutrition are the leading causes of mortality in modern series of enterocutaneous fistulas. The leakage of enteric contents outside of the bowel lumen may lead to a localized abscess or to generalized peritonitis. Percutaneous management of localized abscesses accompanied by appropriate antibiotic therapy and supportive measure is usually sufficient to resolve infection in this subgroup. Diffuse peritoneal infection represents a much greater management challenge. In general, the generalized nature of the infection precludes successful therapy with percutaneous drainage and therefore an operative approach is indicated. Particularly in the early postoperative period, the surgeon should be wary of attempting to treat multiple intra-abdominal fluid collections observed on CT scan with percutaneous drains, when surgical intervention is required for definitive management.

**Surgical Approach.** The goals of operative management of peritonitis are to eliminate the source of contamination, reduce the bacterial inoculum, and prevent recurrent or persistent infection. The operative technique used to control contamination depends on the location and the nature of the pathological condition in the GI tract.<sup>43</sup> For patients progressing to diffuse peritonitis in the early postoperative period, the abdomen is usually reentered through the previous incision with the discovery of pus and enteric content. After aspiration of the fluid, an exploration to find the source

of contamination is warranted. Anastomotic dehiscence/enterotomy should generally be managed by exteriorization of the affected bowel. Whether this is performed via a single stoma site or with separate stomas (ie, end stoma plus mucous fistula) depends on the specific scenario. Obviously, if one is able to exteriorize the intestinal defect, the likelihood of a postoperative enteric fistula is markedly reduced. It is attractive to hope that a surgically repaired enterotomy or leaking enterotomy might heal primarily, given the obvious simplicity of the procedure. However, this is rarely successful in the setting of diffuse peritoneal infection, and therefore this approach is not recommended. Reoperation after this misjudgment is fraught with potential difficulty, in that the surgeon is faced with the need to reoperate on the patient in the early postoperative period. This laparotomy is invariably more difficult, often associated with bleeding, further enterotomies, and a bowel that is extremely difficult to exteriorize. Under these circumstances, there should be consideration of a proximal defunctioning stoma if technically feasible. These cases are frequently the ones associated with inability to close the abdominal wall.

A number of anatomical circumstances may also preclude exteriorization of a leaking anastomosis. The principle of “defunction and drain” is appropriately applied in this setting. Most important among these is the rectal or sigmoid anastomosis where the distal end can be neither exteriorized nor closed. Unless the anastomosis is greater than 50% disrupted, it is reasonable to defunction with an ileostomy or a colostomy upstream and drain the site of the hookup. This approach is preferred as it increases the probability of future restoration of the GI tract. This is particularly true of leaks below the peritoneal reflection.<sup>74</sup> If the anastomosis is almost completely disrupted, the surgeon is obliged to perform an end stoma and drain the pelvis, as the preserved anastomosis would stricture and preclude later stoma closure.

**Control of Fistula Drainage and Skin Care.** Concurrent with drainage of sepsis, a plan to control fistula drainage and provide local skin care will prevent continued irritation of the surrounding skin and abdominal wall structures. Obviously, fistulas created following percutaneous drainage of abscesses are usually well managed by the drain itself. Indeed, the drainage of a local infection is frequently sufficient to permit closure of the fistula. For small low-output fistulas, dry dressing may suffice. In less controlled circumstances, particularly in the setting of the open abdomen, control of the effluent is not straightforward and must be managed aggressively. A skilled enterostomal therapist can often provide useful insight into these issues and should work in concert with a dedicated nursing team.<sup>75</sup> The goals of therapy are to protect the skin, accurately monitor output, and minimize patient anxiety over effluent control. Use of a drainable wound pouch that is tailored to the size of the open wound is effective. This is often combined with some of colloid paste to protect skin and have an improved base on which to secure the stoma. Vacuum-assisted closure devices have been reported to aid in the care of these complicated wounds, including the

promotion of closure. For example, Wainstein and coauthors reported promising results after reviewing their 10-year experience with it. In this study, fistula output was profoundly suppressed soon after commencing use of the device and spontaneous closure was achieved in 46% of patients. The use of a vacuum-assisted device was also found to reduce the frequency of wound dressing changes and improve dermatitis in all cases.<sup>76</sup> These findings are consistent with most surgeons' anecdotal experience with vacuum treatment. Some authors have reported a small number of patients developing new enteric fistulas with the vacuum device. Therefore, some judgment is required in patient selection; presumably stabilized patients with some granulation overlying the exposed bowel may be appropriate.<sup>77,78</sup>

**Reduction in Fistula Output.** While fistula output does not correlate with the rate of spontaneous closure, reduction in fistula drainage may facilitate wound management and decrease the time to closure. Further, reduced output enhances the ease of fluid and electrolyte management and may make local wound care easier. In the absence of obstruction, prolonged nasogastric drainage is not indicated and may even contribute to morbidity in the form of patient discomfort, impaired pulmonary toilet, alar necrosis, sinusitis or otitis media, and late esophageal stricture. Measures to decrease the volume of enteric secretions include administration of histamine antagonists or proton pump inhibitors. Reduction in acid secretion will also aid in the prevention of gastric and duodenal ulceration as well as decrease the stimulation of pancreatic secretion. Antimotility agents such as loperamide and codeine may also be effective.

As inhibitors of the secretion of many GI hormones, somatostatin, and octreotide were postulated to promote nonoperative closure of enterocutaneous fistulas. As recently reviewed, these agents did not accomplish this, although the data suggest that fistula output is reduced and time to spontaneous closure is lessened.<sup>79</sup> This effect is more pronounced with somatostatin infusion than with its longer-acting analogue, octreotide. Infliximab, a monoclonal antibody to TNF- $\alpha$ , has been shown to be beneficial in inflammatory and fistulizing IBD.<sup>80</sup> In a randomized trial of patients with chronic fistulas (duration >3 months), administration of infliximab resulted in a significantly increased rate of closure of all fistulas when compared to placebo.<sup>80</sup> Some evidence suggests a role for infliximab in treatment of fistulas complicating IBD and its use has been reported to promote healing of persistent fistulae even in non-IBD patients.<sup>81</sup> A number of other approaches to managing fistula output and promoting closure have been reported. These include endoscopic injection of fibrin glue into identified fistula openings,<sup>82</sup> radiologically guided percutaneous Gelfoam embolization of the enteric opening,<sup>83</sup> and the insertion of an absorbable fistula plug using a combination of percutaneous and endoscopic approaches.<sup>84</sup> All three involve the “plugging” of the opening with a biological material, presumably with the expectation of tipping the local conditions toward healing. These low-morbidity techniques may therefore be considered as adjuvant considerations for fistula management.

One would speculate that their greatest efficacy would be in the setting of a long tract, without epithelialization and with low output. Recently, endoscopic insertion of a silicone-covered stent across the fistula opening related to gastrojejunal leak following gastric bypass surgery has been described as a means of allowing early feeding and promoting fistula closure.<sup>51</sup> One well-documented and potentially morbid complication of the stent use is its downstream migration with obstruction and erosion of the intestine. Clearly, no consensus regarding use of this approach has been achieved, given the small patient numbers described.

**Nutritional Support.** Provision of nutritional support and time may be all that are necessary for spontaneous healing of enterocutaneous fistulas. Alternatively, should operative intervention be required, normalization of nutritional parameters will optimize patients in preparation for their surgery. Malnutrition, identified by Edmunds in 1960 as a major contributor to mortality in these patients, may be present in 55–90% of patients with enterocutaneous fistulas.<sup>33</sup> Patients with postoperative enterocutaneous fistulas are often malnourished due to a combination of poor enteral intake, the hypercatabolic septic state, and the loss of protein-rich enteral contents through the fistula and via the open abdominal wall. The optimal route of nutrition in the management of enterocutaneous fistulas has not been critically studied. Parenteral nutrition has long been the cornerstone of support for patients with enterocutaneous fistulas.<sup>33,85–87</sup> This, in part, is related to the fear that early enteral feeds will exacerbate the fistula through increasing output and also that enteral feeds may not be an adequate form of nutritional support. Parenteral nutrition can be commenced once sepsis has been controlled and appropriate intravenous access has been established. Transition to partial or total enteral nutrition has been advocated in recent reports to prevent atrophy of GI mucosa as well as support the immunologic and hormonal functions of the gut and liver. Additionally, parenteral nutrition is expensive and requires dedicated nursing care to prevent undue morbidity and mortality from line insertion, catheter sepsis, and metabolic complications. Thus, attempting enteral feeding is appropriate in most fistula patients. As achieving goal rates of enteral feeding may take several days, patients are often maintained on parenteral nutrition as tube feedings are advanced. Enteral feeding may occur per os or via feeding tubes placed nasogastrically or nasoenterically. Enteral support typically requires 4 ft of small intestine and is contraindicated in the presence of distal obstruction. Drainage from the fistula may be expected to increase with the commencement of enteral feeding, although this does not uniformly occur and is often dependent on fistula location and size of the fistula defect; however, spontaneous closure may still occur, often preceded by a decrease in fistula output. When parenteral and enteral nutrition are both options, the latter is preferred. It is far less expensive, safer, and is easier to administer (particularly if the intent is to manage the patient as an outpatient). A meta-analysis by Gramlich et al<sup>19</sup> indicated that ICU patients receiving enteral feeds have a lesser infection rate than those receiving parenteral feeds.

In patients with high-output proximal fistulas, it has been suggested to provide enteral nutrition by a technique called *fistuloclysis*. In fistuloclysis, an enteral feeding tube is placed directly into the matured high-output fistula.<sup>88</sup> Teubner et al reported on their experience using fistuloclysis in 12 patients before reconstructive surgery.<sup>89</sup> Eleven of twelve patients were able to discontinue parenteral support and nutritional status was maintained until surgery in nine patients (19–422 days) and for at least 9 months in the two patients who did not undergo operative intervention.<sup>89</sup> Of note, surgeons in this study also reported improved bowel caliber, thickness, and ability to hold sutures in patients who had received enteral nutrition.<sup>89</sup> Other measures such as the use of recombinant human growth hormone (rGH) on fistula patients have been examined. While able to promote intestinal mucosal epithelial cell proliferation; increase levels of total proteins, albumin, fibronectin, and prealbumin; and transfer and reduce nitrogen excretion, its clinical role has not been clearly defined.<sup>90</sup>

**Psychological Support.** Patients who develop postoperative enterocutaneous fistulas require considerable psychological support. They have sustained a major complication of surgery and are frequently faced with prolonged postoperative stay, excessive abdominal discomfort, and potentially one or more additional surgical interventions. In aggregate, all of these factors lead to psychological distress for patient and their families and should be addressed once the acute disease is dealt with.

## PHASE 2: INVESTIGATION

Once the patient has been stabilized with control of sepsis and commencement of nutritional support, early radiological investigation may be of value. Abdominal CT scanning with GI contrast with help to discern whether there is residual local infection that requires drainage, to localize the level of the fistula and the amount of contrast flowing beyond the defect, and occasionally whether there is distal obstruction. Fistulograms down drainage tracts will elucidate the length, course, and relationships of the fistula tract. If the fistula is spontaneous, the nature of the local pathological process from which the fistula arises may be determined. In the setting where the mucosal bud of the fistula is readily observed in the center of an open abdomen, aside from a CT scan to rule out distant infection, little further early imaging is required. Because patients with enterocutaneous fistulas are frequently referred to larger centers for management, it is essential that all notes, particularly operative notes, be obtained from the referring hospital. Personal communication with the surgeon may further elucidate other factors in the patient's disease that are not readily evident from the notes.

## PHASE 3: DECISION

Spontaneous closure of fistulas restores intestinal continuity and allows resumption of oral nutrition. As noted previously, the rate of spontaneous closure varies considerably from series to series, with an average of approximately one-third

of patients. This wide range likely represents patient selection in the various series, and in particular whether the series emanates from a referral center where the patient population tends to be more complex. A number of factors predict spontaneous closure. These are listed in Table 10-7. One might consider two case scenarios to illustrate these points. A long, narrow fistula tract originating from a small leak in a colonic anastomosis with no evidence of distal obstruction and a well-drained perianastomotic abscess is almost certain to close spontaneously. By contrast, a small bowel defect revealing itself as a mucosal bud in the middle of an open abdomen is unlikely to heal as the tract is short and epithelialized, in essence mimicking a stoma. Fistulas associated with IBD often close with nonoperative management only to reopen upon resumption of enteral nutrition. These fistulas should be formally resected once closed to prevent recurrence. Fistulas in the setting of malignancy or irradiated bowel are particularly resistant to closure and would suggest the need for earlier operative intervention.

Most authors agree that once resuscitation, wound care, and nutritional support are established, 90–95% of fistulas that will spontaneously close typically do so within 4–8 weeks of the original operation.<sup>25,85</sup> In the absence of closure, there should be consideration of surgical closure. Like any surgical procedure, weighing of the risk and benefits of surgical intervention is critical prior to proceeding to operation. This is particularly relevant in this patient population where the surgical procedure is a major one and has a finite risk of recurrence. Some patients are perfectly well, are tolerating a regular diet, and have fistula effluent that is trivial in volume and requires only coverage with dry gauze. The potential risks of a major operation in this type of patient might outweigh the ultimate benefit. The timing of elective operative intervention for fistulas that are unlikely to or fail to close is extremely important. Early operation is only indicated to control sepsis not amenable to percutaneous intervention. These early procedures are typically limited to drainage of infected fluid collections and drainage, defunctioning, or exteriorization of the defect.

There is some controversy in the literature as to how long one should wait before attempting definitive elective closure of enterocutaneous fistulae. Very early closure appears to be contraindicated because the patient condition is generally not optimized. Further, from a technical standpoint, adhesions tend to be dense and vascular, therefore rendering the procedure difficult. In one retrospective study, Keck et al observed that operative difficulty and denser adhesions leading to inadvertent enteromies were more common when patients were taken to surgery for reversal of a Hartmann's procedure before 15 weeks compared to after.<sup>91</sup> Poor outcome when surgery is performed in the 2-week to 3-month window has been reported by several groups.<sup>38,92</sup> At least two reports suggest that a very long delay before definitive surgery (>36 weeks) might adversely affect outcome.<sup>41,93</sup> It is generally recommended that definitive surgery be considered in the window of 3–6 months after the patient is stabilized from the initial recovery from the procedure that lead to the fistula formation. Various factors

will influence where, in this interval, surgery is performed. Patient factors such as nutritional status, ease of managing the fistula, and family support may influence decision making. Some authors talk about the “soft” abdomen and prolapse of the fistula as being a valuable clinical signs that peritoneal conditions are reasonable to proceed with surgery.<sup>37</sup> On occasion, there is intense pressure from the patient and family to reoperate and “fix” the fistula during this early period. This approach should be resisted.

#### PHASE 4: DEFINITIVE MANAGEMENT

Operations repairing enterocutaneous fistulas may be complex and often lengthy. In addition to repairing the fistula, many of these patients require complex abdominal wall closures. Before definitive management, the patient should have achieved optimal nutritional parameters and be free of all signs of sepsis. Through careful management of fistula drainage, a well-healed abdominal wall without inflammation should be present.

**Consent.** As for all operations, the patient should be fully apprised of the nature of the procedure and its potential for complications. Connolly and colleagues reported a very high incidence of complications following intestinal reconstructive surgery (82.5% of procedures) when one considered postoperative nosocomial infections including surgical site infections, respiratory infections, and central line sepsis together with postsurgical myocardial dysfunction, GI bleeding, and deep vein thrombosis.<sup>94</sup> In discussions with patients and their families, the unique difficulty of these procedures should be raised, pointing out the potential for adhesions and therefore inadvertent injury and excessive bleeding. The fistula recurrence rate is also significant with reported rates up to 33% (see Table 10-5), depending on the individual circumstance. The patient and relevant family members should know that the procedure may be prolonged and may require an ICU stay in the postoperative period. Some of the anxiety of the patient may be related to mistrust of physicians in general following a previously complicated operation. Clearly, the sensitive nature of reoperation for prior complications requires a strong physician-patient relationship to minimize patient anxiety prior to the planned procedure.

**Patient Preparation.** It is critically important for the operating surgeon to fully understand the nature of the prior surgeries. Reviewing the previous operative notes as well as speaking with the original surgeon will consolidate one's knowledge of the initial pathological process and the precise anatomy to be corrected in the reoperative setting. One should also be very liberal about using preoperative contrast imaging or endoscopy to completely define the anatomy. In the hypothetical case of reoperation after a colonic anastomotic dehiscence, the need for definition of the anatomy varies according to the initial source control procedure. A prior operation consisting of exteriorization of an end colostomy with nearby mucus fistula or exteriorization of the disrupted anastomosis



is a circumstance where investigation is probably unnecessary. In preparation for closure of a Hartmann's procedure, the rectal stump should be routinely investigated by endoscopy. This may help with planning of the operation as well as locating the stump at surgery. Closure of a defunctioning ileostomy or colostomy should also be preceded by investigation of the downstream anastomosis. This is intended to rule out the presence of a stricture or persistent defect at that site, both of which would alter surgical approach. Finally, contrast studies are essential when complex fistulas exist and are to be treated by reoperative surgery.

The general principles related to preparation for any surgery should be applied to reoperation. These would include optimization of the general medical status of the patient, administration of subcutaneous heparin and/or other antithrombotic strategies, and initiation of measures aimed at reducing postoperative infectious complications. Orthograde intestinal lavage by mouth as well as distally via the defunctioned limb has been recommended for mechanical preparation of the bowel. However, the evidence underlying this recommendation is limited and, in fact, recent studies show that mechanical bowel preparation for elective colon surgeon does not improve outcome and may have some deleterious effects.<sup>69</sup> Our practice is to forego the use of mechanical prep unless reconstruction involves passage of stapling device transanally. Clearance of inspissated mucus in the rectal stump with an enema may facilitate advancement of the stapler proximally. Finally, prophylactic intravenous antibiotics with broad-spectrum coverage of both facultative gram-negative enterics as well as anaerobic bacteria are indicated. Consideration of coverage of resistant microbes should be made.<sup>21</sup>

**Operative Intervention.** Patients should be positioned to permit optimal exposure to the field of surgery, to take into account potential requirements for extension of the operative field, and to facilitate optimal reconstruction of the GI tract and/or drainage of the operative field. In the majority of situations, the supine position is adequate. Concomitant lithotomy positioning is often helpful, particularly when reconstruction involves the left colon or rectum, where transanal access for endoscopy or stapling may be useful. When reoperation involves the upper GI tract, left lateral decubitus positioning will allow an initial thoracoabdominal incision or extension of an abdominal incision into the chest.

Careful planning of the location and type of incision are mandatory prior to making the initial incision. It is preferable to enter the peritoneal cavity through a previously unoperated area of the abdominal wall, thereby avoiding the areas where the most intense adhesions would be expected, that is, beneath the previous abdominal wall incision and in the region of the abdomen where the inflammation might have been the most severe. Inadvertent enterotomy is relatively common during reoperation, occurring in approximately 20% of patients, and is associated with a higher rate of postoperative complication and a longer postoperative hospital stay.<sup>95</sup> In addition, it is a frustrating beginning to an often long and tedious operation.

The use of the midline incision, beginning with entry either cephalad or caudad to this initial incision through an unoperated field is the most common approach to reentering the abdomen. This approach provides broad access to the peritoneal cavity with opportunity for extension and is also readily closed. Other approaches may include unilateral or bilateral subcostal incisions, transverse incisions, flank incisions, or thoracoabdominal incisions. In general, these should be considered when a specific area of the abdomen is operated on, because they generally afford less access to the overall peritoneal cavity. When placing new incisions, care should be taken not to render intervening tissue bridges ischemic. This might occur when a midline incision is placed adjacent to a previous paramedian incision. It is preferable to use the previous paramedian incision with extension into the midline above or below. When the fistula opening is in the center of a reepithelialized section of the abdomen with no underlying fascia/muscle, one should preferably enter the abdomen as described above, either cephalad and caudad to the previously operated area. When this is not possible, one should consider placing the initial incision along the line of the fascial edge, rather than through the reepithelialized portion. In the latter operative field, the skin may be very adherent to the underlying bowel, therefore increasing the chance of bowel injury. This is particularly true when there is retained mesh, which may have contributed to fistula formation in the first place.

Upon entering the peritoneal cavity, adhesions between the anterior abdominal wall and the underlying omentum and bowel must be released. By 3–6 months following the initial surgery, adhesions are generally relatively filmy and readily divided using scissor or cautery dissection. Gentle traction on the bowel with countertraction on the abdominal wall will facilitate exposure of the appropriate tissue plane for division. A similar approach is appropriate for dense adhesions, with some surgeons preferring knife dissection. During this dissection, it may be necessary to leave patches of abdominal wall (peritoneum with or without fascia) or even mesh adherent to bowel to avoid enterotomy. It is also noteworthy that enterotomies may be caused by traction on the bowel due to retraction on the abdominal wall. Clearance of the fascial edges along both sides of the entire incision is necessary to achieve adequate and safe closure of the abdominal wall.

Having successfully entered the abdominal cavity, one faces varying degrees of interloop adhesions. The degree to which these must be lysed depends on the particular operation to be performed. When one is operating on the colon for the purpose of stoma closure or reestablishment of colonic continuity, there is generally little need to exhaustively take down small bowel adhesions. The fact that the patient has been tolerating a normal diet preoperatively provides ample evidence that the small bowel adhesions are not of physiological significance. While not having to lyse all adhesions, it is necessary, however, to free small bowel loops from their attachments to the colon so that the latter might be adequately mobilized to permit easy closure or anastomosis. When operating to close a small bowel stoma or to correct an enterocutaneous fistula, when possible, one should consider more comprehensive lysis of adhesions,

along the entire length of the small bowel, but in particular the distal small bowel. The presence of a stoma or fistula may serve to defunction a distal small bowel adhesive obstruction prior to surgery and may therefore preclude its recognition. The presence of a distal obstruction following upstream anastomosis could prove catastrophic in the postoperative period.

Adhesiolysis varies considerably in its degree of difficulty. Even when the reoperation is appropriately delayed from the initial operative procedure and vascularized adhesions are no longer present, the number and density of residual fibrous adhesions may still be significant and represent a significant technical challenge. As described for opening the peritoneal cavity, good lighting of the operative field, excellent surgical assistance, and a dose of patience are absolute requirements for this part of the operation. Two experienced surgeons working together facilitates adhesiolysis. During lysis of adhesions, one should also be wary of encountering previous anastomoses. Adhesions may be particularly tenacious in these areas, particularly when the prior anastomosis was performed using a stapled technique. For side-to-side functional end-to-end stapled anastomoses, the crotch of the anastomosis may be mistaken for intense adhesions. Failure to recognize this may result in inadvertent enterotomy and the attendant increased morbidity.

When surgery has been timed appropriately, one usually finds that the dissection distant from the fistula to be reasonably straightforward. As one approaches the fistula site, it becomes increasingly tedious with multiple adherent loops of bowel. We recommend that the fistula be addressed relatively late in the dissection, after most of the small bowel has been mobilized. This minimizes inadvertent injury to loops of bowel uninvolved in the fistula.

Several of the large case reviews address surgical technique and risk of recurrence.<sup>37,38,40,41</sup> In general, it appears to be preferable to locally resect the segment of small bowel bearing the fistula rather than simply closing the intestinal opening. This may represent a biased finding since the instances where simple closure was used correlated with the finding of an abdomen with impossibly dense adhesions, therefore precluding mobilization and resection. Under these latter circumstances, one might consider the addition of a temporary proximal defunctioning stoma.

In the elective surgical setting, stapled anastomoses have been shown to be equivalent to hand-sewn anastomoses in terms of anastomotic dehiscence.<sup>96</sup> By contrast, for closure of enterocutaneous fistulas, hand-sewn appears to be the preferred approach to performing the anastomosis following resection. Whether single layer versus two layers of sutures or running versus interrupted stitching should be used has not been systematically addressed. Frequently, the chronically defunctioned bowel is atrophic, line-walled, and stiff. Under these circumstances, the stapling devices are unable to accommodate the pathological nature of this bowel, where hand sewing can better accommodate differences in size, thickness, and compliance of the intestine.

Wrapping of the anastomosis with omentum has been examined as a means of preventing anastomotic leakage but has not proven to be effective.<sup>71</sup> However, placement of

a flap of omentum between the fresh anastomosis and the abdominal wall closure may minimize recurrence of fistulization. Some have advocated the placement of a decompressive gastrostomy and/or the placement of a feeding jejunostomy, both of which may aid in the postoperative care of patients undergoing procedures of this scale.

As the cumulative experience with complex laparoscopic procedures has increased, several groups have reported laparoscopic approaches to enteric and enterocutaneous fistulas.<sup>97-102</sup> The largest of these series reported 73 procedures in 72 patients, 20% of which were enterocutaneous fistulas.<sup>101</sup> The authors reported a mean operative time of 199 minutes with a 4.1% conversion rate.<sup>101</sup> Because surgical procedures for the management of enteric fistulas are generally complex ones, a laparoscopic approach would seem appropriate only in the hands of a skilled and experienced laparoscopic surgeon and only in selected circumstances.

**Abdominal Wall Closure.** After the fistula has been appropriately managed, one is left with closure of the abdominal wall. The complexity of this aspect of the operation varies depending on the preoperative state of the abdominal wall. Closure may be straightforward when the enterocutaneous fistula is along a previous drain tract or through necessitation of an abscess through an abdominal wound. By contrast, when the prior patient management involved an open abdomen approach with the fistula draining from the center of the wound, patients may present with large ventral hernias that are not amenable to simple fascial closure. In advance of surgery, it is essential that the surgeon consider management of abdominal wall a significant part of the procedure and reflect upon the various surgical options. Included in these preoperative deliberations should be the proactive involvement of a plastic surgeon to aid in the assessment of options and to potentially prepare him/her for involvement in the operation. Table 10-9 outlines the various approaches. Prior to beginning abdominal wall closure,



**TABLE 10-9: MANAGEMENT OF ABDOMINAL WALL FOLLOWING ELECTIVE CLOSURE OF GASTROINTESTINAL FISTULA**

#### **No Preoperative Fascial Defect**

- Primary closure with or without some fascial relaxation

#### **Preoperative Fascial Defect**

- Small defect (<5 cm)
  - Primary fascial closure with or without some fascial relaxation
- Large defect
  - Primary fascial closure using component separation technique
    - If very large, may be combined with prosthetic material
  - Coverage with vascularized flap
  - Use of prosthetic material
    - Nonabsorbable
    - Absorbable
      - Nonbiological
      - Biological

it is desirable to debride/remove any residual infected foci, including chronically infected suture material and previously placed infected mesh. One should also attempt to position the intestinal anastomosis away from the closure and, if possible, to interpose omentum between the anastomosis and the abdominal wall. Finally, it is generally considered that, in the setting of GI surgery where there is contamination of the surgical field, the use of nonabsorbable permanent mesh is contraindicated as it is associated with an increased risk of infection and refistulization.<sup>103</sup>

When no defect or a small defect in the fascia exists, primary closure is usually achievable although there may be some mild tension on the closure. This is, in part, related to the stiffness of the abdominal wall attendant with repeated abdominal surgery. In these circumstances, relaxing incisions placed in the aponeurosis of the external oblique muscle approximately 2 cm lateral to the edge of the rectus muscle may minimize any tension. Polydioxanone, a slowly absorbable monofilament suture material, appears preferable as it is equivalent to nonabsorbable monofilament suture in terms of recurrent hernias but has less wound pain and sinus formation.<sup>104</sup> Various closure techniques have been proposed when primary fascial closure is not possible.<sup>103,105–107</sup> There has been increasing enthusiasm regarding the use of the component separation technique as a means of achieving abdominal wall closure without prosthetic material.<sup>105–107</sup> In brief, this approach involves the separation of the external oblique and internal oblique muscles bilaterally plus division of the posterior rectus fascia. Together, these accomplish approximately 12-, 22-, and 10-cm advancement of the upper, middle, and lower thirds of the abdomen, respectively.<sup>105</sup> This approach has been reported for abdominal wall closure after trauma surgery, in patients with sepsis managed with the open abdomen and in patients with enterocutaneous fistulas.

Wind and colleagues examined the application of this technique in the presence of a contaminated abdominal wall defect, including during closure of an enterocutaneous fistula and/or stoma.<sup>106</sup> This study reported the feasibility of this approach in terms of achieving abdominal wall closure but noted considerable morbidity, including wound seromas, wound infections, and hematomas as well as recurrent abdominal wall hernias in approximately 22% of patients. Recurrence of the enterocutaneous fistula occurred in 25% of patients. In a small percentage of patients, the use of absorbable mesh was combined with the component separation technique, because the advancement of the abdominal wall alone was not sufficient to cover the defect.

Finally, absorbable prosthetics may be considered for management of the defect. Synthetic meshes such as polyglactin effect good initial coverage but have the anticipated long-term consequence of incisional hernia formation.<sup>94</sup> As an alternative, biological prostheses including porcine collagen mesh and acellular dermal matrix have been suggested with the potential advantage of increased resistance to infection and reduced late incisional hernias. These outcomes have not been uniformly achieved when used in the

treatment of fascial defects following repair of enterocutaneous fistulas.<sup>94,108</sup>

In summary, management of the abdominal wall following reoperative surgery in these patients may be a considerable challenge. The major objective is to prevent recurrent fistula formation and minimize postoperative infection. Prevention of late ventral hernia formation is a secondary goal. Involvement of a surgical team with expertise in the options, including the use of the component separation technique, would appear to broaden the clinical options for the patient.

## PHASE 5: POSTSURGICAL PHASE

The postoperative period can be divided into two parts: the early postoperative recovery period and the later rehabilitation and convalescence phase. The former of these periods can be somewhat complex as postoperative complications are frequent, with up to 80% of patients having one or more complications.<sup>94</sup> In particular, these patients have a significant incidence of postoperative infection, both at the surgical site and at distant sites including lung and central venous lines. As shown in Table 10-5, the incidence of recurrent fistulization following surgery is considerable and is associated with prolonged hospital stays and repeat admissions to the ICU as well as repeat interventions. Brenner et al reported that recurrence of the enterocutaneous fistula in the postoperative period was the strongest predictor of mortality, invariably due to the development of overwhelming sepsis and organ failure.<sup>41</sup> Mortality is related to the presence of preoperative comorbidities.<sup>109</sup> Short of death, the recurrence of enterocutaneous fistula following surgery represents a major complication. Among those who survive this recurrence, only 50–66% go on to further surgery and successful closure, while the remainder live with a chronic fistula.<sup>38,41</sup> A number of factors predict recurrence (Table 10-10).

By the time their fistulas have been surgically closed, these patients have often been undergoing medical care, usually both as inpatients and outpatients for several



**TABLE 10-10: FACTORS PREDICTING RECURRENCE AFTER ELECTIVE REPAIR OF ENTEROCUTANEOUS FISTULA**

### Patient Factors

- Open abdomen
- Origin of fistula (small bowel > large bowel)
- Underlying inflammatory bowel disease
- “Frozen abdomen” or residual intra-abdominal infection

### Surgical Factors

- Timing of surgery (<4 weeks, >36 weeks)
- Multiple inadvertent enterotomies at reoperation
- Oversewing of enteric defect, rather than resection and anastomosis
- Use of stapled anastomosis, compared to hand-sewn anastomosis
- Need to perform mesh closure of abdominal wall

months following the initial development of their enterocutaneous fistulas. By the end of this period, which may have included prolonged in-hospital stays, multiple surgical and radiological interventions, frequent visits to health care facilities as outpatients, and an overriding focus on their medical disability, patients are invariably physically deconditioned and emotionally fatigued. The impact on the long-term quality of life, as measured by objective questionnaires, even in those treated, continues to be lower than matched controls especially if there is a concurrent medical illness.<sup>110</sup> Physical and occupational therapists play a role throughout each patient's hospitalization, but their efforts become even more important during the healing phase as the focus shifts to reintroducing the patient to normal activities of daily living. Involvement of case management staff early in the patient's course will identify obstacles to the patient's successful reintroduction to an active lifestyle, while use of psychiatric consultation-liaison services will identify and address issues of depression and adaptive disorders. Finally, active involvement by the senior surgeon responsible for the patient's care to ensure clear communication to the patient and the family during what is invariably a prolonged convalescence and rehabilitation period is essential. Optimally, this physician-patient relationship would have begun early in the patient's illness and would continue through till complete recovery occurs.

## Conclusion

Enteric fistulas, occurring spontaneously or in the postsurgical period, represent a significant management challenge. This chapter has focused predominantly on the postsurgical enterocutaneous fistulas, which may result in both morbidity and occasionally mortality for the patient. The care in these patients may be complex and has led to the establishment of specialized intestinal failure units, aimed at optimizing outcome. General principles of care include (1) early recognition and stabilization of patients with fistulas combined with control of sepsis and provision of nutritional support; (2) investigation of the anatomic and etiological characteristics of each fistula, thus providing information about the likelihood of spontaneous closure or need for operative management; (3) decision making regarding the approach to management, including the involvement of a multidisciplinary team, will provide the best possibility of resolution of the fistula; (4) definitive surgical therapy in a controlled setting; and (5) postoperative care including physical rehabilitation and emotional support, which together help the patient return to their premorbid condition.

## REFERENCES

- Altemeier WA, Culbertson WR, Shook CD. Intra-abdominal abscesses. *Am J Surg.* 1973;125:70.
- Lambiase RE, Deyoe L, Cronan JJ, et al. Percutaneous drainage of 335 consecutive abscesses: results of primary drainage with 1-year follow-up. *Radiology.* 1992;184:167.
- Levison MA, Zeigler D. Correlation of APACHE II score, drainage technique and outcome in postoperative intra-abdominal abscess. *Surg Gynecol Obstet.* 1991 Feb;172:89-94.
- Field TC, Pickleman J. Intra-abdominal abscess unassociated with prior operation. *Arch Surg.* 1985;120:821.
- Nathens AB, Ahrenholz DH, Simmons RL, Rotstein OD. Peritonitis and other intra-abdominal infections. In: Howard RJ, Simmons RL, eds. *Surgical Infectious Diseases.* Norwalk, CT: Appleton & Lange; 1995: 959-1010.
- Hau T, Hoffman R, Simmons RL. Mechanisms of the adjuvant effect of hemoglobin in experimental peritonitis: I. *In vivo* inhibition of peritoneal leukocytosis. *Surgery.* 1978;83:223.
- Holzheimer RE, Schein M, Wittmann DH. Inflammatory response in peritoneal exudate and plasma of patients undergoing planned relaparotomy for severe secondary peritonitis. *Arch Surg.* 1995;130:1314.
- Schein M, Wittmann DH, Holzheimer R, et al. Hypothesis: compartmentalization of cytokines in intra-abdominal infection. *Surgery.* 1996;119:694.
- Haecker FM, Fasler-Kan E, Manasse C, et al: Peritonitis in childhood: clinical relevance of cytokines in the peritoneal exudate. *Eur J Pediatr Surg.* 2006 Apr;16(2):94.
- Rotstein OD. Role of fibrin deposition in the pathogenesis of intra-abdominal infection. *Eur J Clin Microbiol Infect Dis.* 1992;11:1064.
- Khadaroo RG, Nathens AB, Rotstein OD. Intraabdominal abscesses. In: Gorbach SL, Bartlett JG, Blacklow NR, eds. *Infectious diseases.* 3rd ed. Chapter 82, 731.
- Fry DE. Noninvasive imaging tests in the diagnosis and treatment of intra-abdominal abscesses in the postoperative patient. *Surg Clin North Am.* 1994 Jun;74(3):693.
- Knochel JQ, Koehler PR, Lee TG, et al. Diagnosis of abdominal abscesses with computed tomography, ultrasound, and 111In leukocyte scans. *Radiology.* 1980;137:425.
- Mueller PR, Simeone JF. Intraabdominal abscesses: diagnosis by sonography and computed tomography. *Radiol Clin North Am.* 1983;21:425.
- Clark RA, Towbin R. Abscess drainage with CT and ultrasound guidance. *Radiol Clin North Am.* 1983;21:445.
- Wall SD, Fisher MR, Ampara EG, et al. Magnetic resonance imaging in the evaluation of abscesses. *Am J Roentgenol.* 1985;144:1217.
- Oto A, Ernst RD, Ghulmiyyah LM, et al. MR imaging in the triage of pregnant patients with acute abdominal and pelvic pain. *Abdom Imaging.* 2009 Mar-Apr;34(2):243.
- Bleeker-Rovers CP, Boerman OC, Rennen HJ, et al. Radiolabeled compounds in diagnosis of infectious and inflammatory disease. *Curr Pharm Des.* 2004;10:2935.
- Gramlich L, Kichian K, Pinilla J, et al. Does enteral nutrition compared to parenteral nutrition result in better outcomes in critically ill adult patients? A systematic review of the literature. *Nutrition.* 2004;20:843.
- Roehrborn A, Thomas L, Potreck O, et al. The microbiology of postoperative peritonitis. *Clin Infect Dis.* 2001;33:1513.
- Solomkin JS, Mazuski JE, Bradley JS, et al. Diagnosis and management of complicated intra-abdominal infection in adults and children: guidelines by the Surgical Infection Society and the Infectious Diseases Society of America. *Clin Infect Dis.* 2010;50:133.
- Marshall JC, al Naqbi A. Principles of source control in the management of sepsis. *Crit Care Clin.* 2009;25:753.
- Olak J, Christou NV, Stein LA, et al. Operative vs percutaneous drainage of intra-abdominal abscesses. Comparison of morbidity and mortality. *Arch Surg.* 1986;121:141.
- Hemming A, Davis NL, Robins RE. Surgical versus percutaneous drainage of intra-abdominal abscesses. *Am J Surg.* 1991;161:593.
- Bufalari A, Giustozzi G, Moggi L. Postoperative intraabdominal abscesses: percutaneous versus surgical treatment. *Acta Chir Belg.* 1996;96:197.
- Maher MM, Gervais DA, Kalra MK, et al. The inaccessible or undrainable abscess: how to drain it. *Radiographics.* 2004;24:717.
- Piraka C, Shah RJ, Fukami N, et al. EUS-guided transesophageal, transgastric, and transcolonic drainage of intra-abdominal fluid collections and abscesses. *Gastrointest Endosc.* 2009;70:786.
- Stabile BE, Puccio E, vanSonnenberg E, et al. Preoperative percutaneous drainage of diverticular abscess. *Am J Surg.* 1990;159:99.
- Cinat ME, Wilson SE, Din AM. Determinants for successful percutaneous image-guided drainage of intra-abdominal abscess. *Arch Surg.* 2002;137:845.



30. Jaques P, Mauro M, Safrit H, et al. CT features of intraabdominal abscesses: prediction of successful percutaneous drainage. *AJR Am J Roentgenol.* 1986;146:1041.
31. Benoist S, Panis Y, Pannegeon V, et al. Can failure of percutaneous drainage of postoperative abdominal abscesses be predicted? *Am J Surg.* 2002;184:148.
32. Edmunds LH, Williams GM, Welch CE. External fistulas arising from the gastro-intestinal tract. *Ann Surg.* 1960;152:445.
33. Soeters PB, Ebeid AM, Fischer JE. Review of 404 patients with gastrointestinal fistulas: impact of parenteral nutrition. *Ann Surg.* 1979;190:189.
34. Reber HA, Robert C, Way LW, et al. Management of external gastrointestinal fistulas. *Ann Surg.* 1978;188:460.
35. Aguirre A, Fischer JE, Welch CE. The role of surgery and hyperalimentation in therapy of gastrointestinal-cutaneous fistulae. *Ann Surg.* 1974;180:393.
36. Conter RL, Roof L, Roslyn JJ. Delayed reconstructive surgery for enterocutaneous fistulas. *Am Surg.* 1988;54:589.
37. Hollington P, Mawdsley J, Lim W, et al. An 11-year experience of enterocutaneous fistula. *Br J Surg.* 2004;91:1646.
38. Lynch AC, Delaney CP, Senagore AJ, et al. Clinical outcome and factors predictive of recurrence after enterocutaneous fistula surgery. *Ann Surg.* 2004;240:825.
39. Draus JM Jr, Huss SA, Hartly NJ, et al. Enterocutaneous fistula: are treatments improving? *Surgery.* 2006;140:570.
40. Visschers RGJ, Olde Damink SWM, Van Bekkum M, et al. Treatment strategies in 135 consecutive patients with enterocutaneous fistulas. *World J Surg.* 2008;32:445.
41. Brenner M, Clayter JL, Tillou A, et al. Risk factors for recurrence after repair of enterocutaneous fistula. *Arch Surg.* 2009;144:500.
42. Bosscha K, Hulstaert PF, Visser MR, et al. Open management of the abdomen and planned reoperations in severe bacterial peritonitis. *Eur J Surg.* 2000;166:44.
43. Berry SM, Fischer JE. Classification and pathophysiology of enterocutaneous fistulas. *Surg Clin North Am.* 1996;76:1009.
44. Myssiorek D, Becker GD. Extended single transverse neck incision for composite resections: does it work? *J Surg Oncol.* 1991;48:101.
45. Brown MR, McCulloch TM, Funk GF, et al. Resource utilization and patient morbidity in head and neck reconstruction. *Laryngoscope.* 1997;107:1028.
46. Xavier S, Kochhar R, Nagi B, et al. Tuberculous esophagocutaneous fistula. *J Clin Gastroenterol.* 1996;23:118.
47. Janssen DA, Thimsen DA. The extended submental island lip flap: an alternative for esophageal repair. *Plast Reconstr Surg.* 1998;102:835.
48. Eng J, Sabanathan S, Mearns AJ. Late esophageal fistula after pneumonectomy. *Ann Thorac Surg.* 1994;57:1337.
49. Gordon JM, Langer JC. Gastrocutaneous fistula in children after removal of gastrostomy tube: incidence and predictive factors. *J Pediatr Surg.* 1999;34:1345.
50. Papavramidis ST, Eleftheriadis EE, Papavramidis TS, et al. Endoscopic management of gastrocutaneous fistula after bariatric surgery by using a fibrin sealant. *Gastrointest Endosc.* 2004;59:296.
51. Eubanks S, Edwards CA, Fearing NM, et al. Use of endoscopic stents to treat anastomotic complications after bariatric surgery. *J Am Coll Surg.* 2008;206:935.
52. Shorr RM, Greaney GC, Donovan AJ. Injuries of the duodenum. *Am J Surg.* 1987;154:93.
53. Pokorny WJ, Brandt ML, Harberg FJ. Major duodenal injuries in children: diagnosis, operative management, and outcome. *J Pediatr Surg.* 1986;21:613.
54. Malangoni MA, Madura JA, Jesseph JE. Management of lateral duodenal fistulas: a study of fourteen cases. *Surgery.* 1981;90:645.
55. Kuvshinoff BW, Brodish RJ, McFadden DW, et al. Serum transferrin as a prognostic indicator of spontaneous closure and mortality in gastrointestinal cutaneous fistulas. *Ann Surg.* 1993;217:615.
56. Hill GL, Bourchier RG, Witney GB. Surgical and metabolic management of patients with external fistulas of the small intestine associated with Crohn's disease. *World J Surg.* 1988;12:191.
57. Harper PH, Fazio VW, Lavery IC, et al. The long term outcome in Crohn's disease. *Dis Colon Rectum.* 1987;30:174.
58. Pettit SH, Irving MH. The operative management of fistulous Crohn's disease. *Surg Gynecol Obstet.* 1988;167:223.
59. Nanni G, Bergamini C, Bertocini M, et al. Spontaneous appendicocutaneous fistula: case report and literature review. *Dis Colon Rectum.* 1981;24:187.
60. Hyett A. Appendicocutaneous fistula: a hazard of incomplete appendectomy. *Aust N Z J Surg.* 1995;65:144.
61. Colorectal cancer collaborative group. Adjuvant radiotherapy for rectal cancer: a systematic overview of 8507 patients from 22 randomized trials. *Lancet.* 2001;358:1291.
62. Russell JC, Welch JP. Operative management of radiation injuries of the intestinal tract. *Am J Surg.* 1979;137:433.
63. Levy E, Frileux P, Cugnenc PH, et al. High-output external fistulae of the small bowel: management with continuous enteral nutrition. *Br J Surg.* 1989;76:676.
64. Campos ACL, Meguid MM, Coelho JCU. Surgical management of gastrointestinal fistulas. *Surg Clin North Am.* 1996;76:1191.
65. Campos ACL, Andrade DF, Campos GMR, et al. A multivariate model to determine prognostic factors in gastrointestinal fistulas. *J Am Coll Surg.* 1999;188:483.
66. Martinez JL, Luque-de-Leon E, Mier J, Blanco-Benavides R, Robledo F. Systemic management of postoperative enterocutaneous fistulas: factors related to outcomes. *World J Surg.* 2008;32:426.
67. Haffeeje AA. Surgical management of high output enterocutaneous fistulae: a 24-year experience. *Curr Opin Clin Nutr Metab Care.* 2004;7(3):309.
68. Guenaga KK, Matos D, Wille-Jorgenson P. Mechanical bowel preparation for elective colorectal surgery. *Cochrane Database Syst Rev.* 2009;21:CD001544.
69. Beard JD, Nicholson ML, Sayers RD, et al. Intraoperative air testing of colorectal anastomoses: a prospective, randomized trial. *Br J Surg.* 1990;77:1095.
70. Hao XY, Yang KH, Guo TK, et al. Omentoplasty in the prevention of anastomotic leakage after colorectal resection: a meta-analysis. *Int J Colorectal Dis.* 2008;23:1159.
71. den Dulk M, Marijnen CAM, Collette L, et al. Multicentre analysis of oncology and survival outcomes following anastomotic leakage after rectal cancer surgery. *Br J Surg.* 2009;96:1066.
72. Evenson AR, Fischer JE. Current management of enterocutaneous fistula. *J Gastrointest Surg.* 2006;10:455.
73. Perel P, Roberts I. Colloids versus crystalloids for fluid resuscitation in critically ill patients. *Cochrane Database Syst Rev.* 2004;(4):CD000567.
74. Parc Y, Frileux P, Schmitt G, et al. Management of postoperative peritonitis after anterior resection: experience from a referral intensive care unit. *Dis Colon Rectum.* 2000;43:579.
75. Brindle CT, Blankenship J. Management of complex abdominal wounds with small bowel fistulae: isolation techniques and exudates control to improve outcomes. *J Wound Ostomy Continence Nurs.* 2009;36:396.
76. Wainstein DE, Fernandez E, Gonzalez D, et al. Treatment of high-output enterocutaneous fistulas with a vacuum-compaction device. A ten-year experience. *World J Surg.* 2008;32:430.
77. Erdmann D, Drye C, Heller L, et al. Abdominal wall defect and enterocutaneous fistula treatment with the vacuum-assisted closure (VAC) system. *Plast Reconstr Surg.* 2001;108:2066.
78. Alvarez AA, Maxwell GL, Rodriguez GC. Vacuum-assisted closure for cutaneous gastrointestinal fistula management. *Gynecol Oncol.* 2001;80:413.
79. Sancho JJ, di Costanzo J, Nubiola P, et al. A Randomized double-blind placebo-controlled trial of early octreotide in patients with postoperative enterocutaneous fistula. *Br J Surg.* 1995;82:638.
80. Present DH, Rutgeerts P, Targan S, et al. Infliximab for the treatment of fistulas in patients with Crohn's disease. *N Engl J Med.* 1999;340:1398.
81. Date RS, Panesar KJ, Neilly P. Infliximab as a therapy for non-Crohn's enterocutaneous fistulae. *Int J Colorectal Dis.* 2004;19:603.
82. Ragabo LR, Ventosa N, Castro JL, Marco J, Gerra N, Gea F. Endoscopic treatment of postoperative fistulas resistant to conservative management using biological fibrin glue. *Endoscopy.* 2002;34:632.
83. Lisle DA, Hunter JC, Pollard CW, Borrowdale RC. Percutaneous Gelfoam embolization of chronic enterocutaneous fistulas: report of three cases. *Dis Colon Rectum.* 2006;50:251.
84. Toussaint E, Eisendrath P, Kwan V, et al. Endoscopic treatment of postoperative enterocutaneous fistulas after bariatric surgery with the use of a fistula plug: report of five cases. *Endoscopy.* 2009;41:560.
85. Rose D, Yarborough MF, Canizaro PC, et al. One hundred and fourteen fistulas of the gastrointestinal tract treated with total parenteral nutrition. *Surg Gynecol Obstet.* 1986;163:345.

86. MacFadyen BV, Dudrick SJ, Ruberg RL. Management of gastrointestinal fistulas with parenteral hyperalimentation. *Surgery*. 1973;74:100.
87. Berry SM, Fischer JE. Enterocutaneous fistulas. *Curr Probl Surg*. 1994;31:474.
88. Ham M, Horton K, Kauntiz J. Fistuloclysis: case report and literature review. *Nutr Clin Pract*. 2007;22:553.
89. Teubner A, Morrison K, Ravishankar HR, et al. Fistuloclysis can successfully replace parenteral feeding in the nutritional support of patients with enterocutaneous fistula. *Br J Surg*. 2004;91:625.
90. Gu GS, Ren JA, Li N, Li JS. Effects of recombinant human growth hormone on enterocutaneous fistula patients. *World J Gastroenterol*. 2008;14:6858.
91. Keck JO, Collopy BT, Ryan PJ, et al. Reversal of Hartmann's procedure: effect of timing and technique on ease and safety. *Dis Colon Rectum*. 1994;37:243.
92. Fazio VW, Coutsoftides T, Steiger E. Factors influencing the outcome of treatment of small bowel cutaneous fistula. *World J Surg*. 1983;7:481.
93. Fleming FJ, Gillen P. Reversal of Hartmann's procedure following acute diverticulitis: is timing everything? *Int J Colorectal Dis*. 2009;24:1219.
94. Connolly PT, Teubner A, Lees NP, et al. Outcome of reconstructive surgery for intestinal fistula in the open abdomen. *Ann Surg*. 2008;247:440.
95. Van Der Krabben AA, Dijkstra FR, Nieuwenhuijzen M, Reijnen MM, Schaapveld M, Van Goor H. Morbidity and mortality of inadvertent enterotomy during adhesiotomy. *Br J Surg*. 2000;87:467.
96. Hull TL, Kobe I, Fazio VW. Comparison of handsewn with stapled loop ileostomy closures. *Dis Colon Rectum*. 1996;39:1086.
97. Hewett PJ, Stitz R. The treatment of internal fistulae that complicate diverticular disease of the sigmoid colon by laparoscopically assisted colectomy. *Surg Endosc*. 1995;9:411.
98. Joo JS, Agachan F, Wexner SD. Laparoscopic surgery for lower gastrointestinal fistulas. *Surg Endosc*. 1997;11:116.
99. Poulin EC, Schlachta CM, Mamazza J, et al. Should enteric fistulas from Crohn's disease or diverticulitis be treated laparoscopically or by open surgery? A matched cohort study. *Dis Colon Rectum*. 2000;43:621.
100. Watanabe M, Hasegawa H, Yamamoto S, et al. Successful application of laparoscopic surgery to the treatment of Crohn's disease with fistulas. *Dis Colon Rectum*. 2002;45:1057.
101. Regan JP, Salky BA. Laparoscopic treatment of enteric fistulas. *Surg Endosc*. 2004;18:252.
102. Garcia GD, Freeman IGH, Zagorski SM, et al. A laparoscopic approach to the surgical management of enterocutaneous fistula in a wound healing by secondary intention. *Surg Endosc*. 2004;18:554.
103. Fischer JE. The importance of reconstruction of the abdominal wall after gastrointestinal fistula closure. *Am J Surg*. 2009 Jan;197(1):131.
104. van't Riet M, Steyerberg EW, Nellensteyn J, et al. Meta-analysis of techniques for closure of midline abdominal incisions. *Br J Surg*. 2002;89:1350.
105. Lowe JB. Updated algorithm for abdominal wall reconstruction. *Clin Plast Surg*. 2006;33:225.
106. Wind J, van Koperen PJ, Slors JFM, Bemelman WA. Single-stage closure of enterocutaneous fistula and stomas in the presence of large abdominal wall defects using the components separation technique. *Am J Surg*. 2009;197:24.
107. de Vries Reilingh TS, van Goor H, Charbon JA, et al. Repair of giant midline abdominal wall hernias: "components separation technique" versus prosthetic repair. *World J Surg*. 2007;31:756.
108. Lee EI, Chike-Obi CJ, Gonzalez P, et al. Abdominal wall repair using human acellular dermal matrix: a follow-up study. *Am J Surg*. 2009;198:650.
109. Mawdsley JE, Hollington P, Bassett P, et al. An analysis of predictive factors for healing and mortality in patients with enterocutaneous fistulas. *Aliment Pharmacol Ther*. 2008; 28:1111.
110. Visschers RGJ, Olde Damink SWM, Van Bekkum M, et al. Health-related quality of life in patients treated for enterocutaneous fistula. *Br J Surg*. 2008;95:1280.

# GASTROINTESTINAL BLEEDING

Anita Balakrishnan • Ali Tavakkoli  
• Stanley W. Ashley

## OVERVIEW

Acute gastrointestinal (GI) hemorrhage is a significant cause of morbidity and mortality in the emergency setting. The source of GI bleeding can range from the esophagus through to the colon and is classified into upper or lower GI bleeding depending on the site of bleeding relative to the ligament of Treitz. Upper GI hemorrhage occurs from sites proximal to the ligament of Treitz frequently due to peptic ulcer disease and variceal hemorrhage and accounts for more than 80% of acute bleeding.<sup>1</sup> The majority of lower GI bleeding originates from the colon from pathologies such as diverticular disease and angiodysplasias. The small intestine is the site of hemorrhage in fewer than 5% of patients.<sup>1</sup> Hemorrhage persisting or recurring after negative endoscopy is termed *obscure bleeding*. Occasionally patients present with *occult bleeding*, where there are no signs of overt bleeding, but the presenting symptoms are due to chronic blood loss and anemia. In all cases, thorough investigation to localize the source of bleeding allows rapid and often definitive management.

## Incidence of Acute GI Hemorrhage

The annual incidence of acute upper GI hemorrhage is estimated at 170 cases per 100,000 adults, with an increasing incidence with age. The majority of cases are due to upper GI bleeding, with lower GI bleeding having an annual incidence of only 20.5 per 100,000 adults.<sup>2,3</sup> There are geographical variations in the incidence, with reported rates varying from 45 per 100,000 in the Netherlands to 172 per 100,000 in Scotland. This difference is likely related to differences in population demographics and prevalence of various etiological factors between the countries.<sup>4-10</sup>

## Morbidity and Mortality

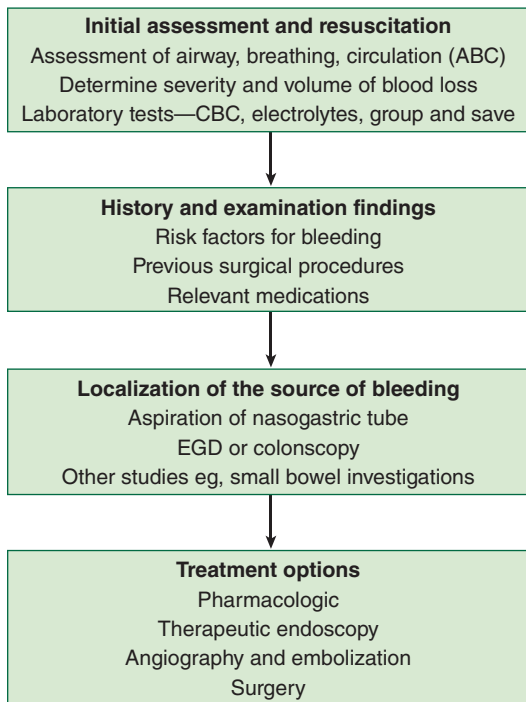
Despite advances in medical and endoscopic therapies, the mortality from upper GI bleeding remains unchanged at 5–14%,<sup>4,5,7-11</sup> and is particularly high in the elderly and hospitalized.<sup>12</sup> In fact, recent reports from the United Kingdom highlight an increase in the mortality rates of patients with upper GI bleeding, in part due to the aging population.

## Economic Effects

Acute GI bleeding exerts a massive drain on health care resources. Rectal bleeding was the 6th most common symptom and melena the 11th most common symptom requiring an outpatient clinic appointment in 2002,<sup>13</sup> while colonic diverticular disease with hemorrhage was the 11th most common cause of inpatient admissions in 2002.<sup>13</sup> Approximately 5% of surgery for diverticular disease was necessitated by massive bleeding.<sup>14</sup> Diverticular bleeding has been estimated to cost over US \$1.3 billion<sup>15</sup> while upper GI bleeding exerts an even higher burden on health care systems, costing an estimated US \$2.5 billion annually in the United States.<sup>16</sup> Variceal bleeding incurred particularly high costs, with an estimated cost of \$23,207 per admission for complicated variceal bleeding compared to \$5632 for complicated non-variceal upper GI bleeding. Uncomplicated cases cost \$3402 per admission (nonvariceal upper GI bleeding) and \$6612 per admission (variceal upper GI bleeding).<sup>17</sup>

## INITIAL ASSESSMENT AND RESUSCITATION

A structured approach is recommended in the initial evaluation and management of the patient with acute GI bleeding



**FIGURE 11-1** A brief overview of the management of gastrointestinal bleeding. ABC, airway, breathing, and circulation; CBC, complete blood count; EDG, esophagogastroduodenoscopy. (Adapted from Fig. 46-1, *Sabiston Textbook of Surgery*, 18th ed, Townsend, Beauchamp, Evers, and Mattox, Elsevier.)

(Fig. 11-1). Early resuscitation with the aim of restoring hemodynamic stability is of paramount importance, followed by a careful history and physical examination to identify the etiology and source of bleeding. Particular attention should be paid to comorbidities and the drug history as this may further complicate management. Diagnostic tests are subsequently performed to confirm the site of bleeding, and therapeutic interventions commenced to control active bleeding and prevent future recurrent hemorrhage.

## Initial Assessment

Management of resuscitation should follow the principles of the ABCs (airway, breathing, and circulation). Once airway and breathing have been managed, adequate hemodynamic

resuscitation is of the highest priority. In particular, the clinician needs to assess the amount of blood lost and the extent of ongoing hemorrhage. Initial evaluation should focus on rapid assessment of the magnitude of both the preexisting deficits and of ongoing hemorrhage. This can be determined by history and examination of the presenting symptoms, which may range from occult bleeding to life-threatening hematemesis and melena. In the majority of cases, a wealth of information can be obtained from simple clinical parameters such as conscious level, blood pressure, and heart rate (Table 11-1), and further facilitated by measurement of urine output as a marker of end-organ perfusion. Depending on the hemodynamic status of the patient and existing comorbidities, more invasive forms of monitoring such as central venous pressure measurements may be of use. Measurement of postural changes (drop in systolic blood pressure >10 mm Hg or increased pulse by >20 beats/min after sitting the patient up for approximately 5 minutes) will identify otherwise undetectable changes in circulating volume in patients with less than 20% circulating volume loss. Tachycardia (>100 beats/min) and a reduced pulse pressure suggest loss of 20–30% of circulating volume. Loss of greater than 40% of circulating volume produces impairment of conscious level (obtundation/agitation), cool, clammy peripheries, and drops the systolic blood pressure to less than 90 mm Hg. Note however that not all patients will demonstrate a tachycardic response to bleeding—occasionally severe blood loss may cause vagal-mediated bradycardia. Similarly, signs of hypotension are less reliable in the elderly and in those on beta-blockers.

While initial blood tests including full blood count and a group and save are essential, a normal hematocrit in the early stages of bleeding may be falsely reassuring, as the hematocrit will only decrease following dilution of the blood volume after resuscitation is commenced.

## Resuscitation

The importance of adequate resuscitation cannot be over-emphasized. The most important contributor to morbidity and mortality in acute GI bleeding is fulminant multiorgan failure resulting from insufficient resuscitation. The extent of resuscitation necessary will depend on the amount of blood lost and severity of ongoing bleeding. The critical care team

**TABLE 11-1: LEVELS OF SHOCK**

Class	Blood Loss (mL)	Blood Loss (%)	Heart Rate (beats/min)	Blood Pressure	CNS Symptoms
I	<750	<15	<100	Normal	Normal
II	750–1500	15–30	>100	Orthostatic	Anxious
III	1500–2000	30–40	>120	Hypotension	Confused
IV	>2000	>40	>140	Severe hypotension	Obtunded

CNS, central nervous system.



should be involved early in the resuscitation process, as early intubation and ventilation will reduce the complications of any respiratory compromise. Large-bore venous access is crucial in the hemodynamically unstable, particularly in those still actively bleeding. Fluid resuscitation in unstable patients should be commenced with a 2-L bolus of crystalloid solution of similar electrolyte composition to whole blood, such as lactated Ringer's. Success of fluid resuscitation should be monitored using simple clinical parameters such as heart rate, blood pressure, and urine output. Urine output is an excellent marker of end-organ perfusion and all hemodynamically unstable patients should be catheterized to allow hourly urine output measurement. A central venous catheter will allow accurate measurement of the preload in those with cardiac, pulmonary, or renal comorbidities, thereby facilitating more sensitive assessment of fluid balance and staving off fluid overload. Supplemental oxygen will maximize oxygen delivery to tissues. The basic blood tests of complete blood count, routine chemistries, and liver function tests should be performed. In addition, in this group of patients a coagulation profile and type and cross-match are essential.

## Transfusion

Several factors need to be considered when deciding whether a blood transfusion is required. Of these, the most important are the presence and extent of ongoing bleeding and the response of the patient to fluid resuscitation. Other factors include the age of the patient (young patients are more able to tolerate blood loss than the elderly) and the presence of cardiopulmonary comorbidities that might produce preexisting compromise of tissue perfusion. The hematocrit (which can take 12–24 hours to equilibrate) is not a reliable first indicator of acute blood loss, but a hematocrit below 30% in the elderly and 20% in the young can be used as an index for the requirement for transfusion. The suspected likelihood of rebleeding should also be taken into account; for instance, in cases of upper GI bleeding, a transfusion is more likely to be required for pathology such as esophageal varices that have a high propensity for profuse rebleeding. While whole blood may be used in cases of massive blood loss, packed red cells are the optimal form of transfusion but are defective in clotting factors, calcium, and platelets. Patients requiring massive transfusion (>10 units of blood) must therefore also receive fresh frozen plasma, platelets, and calcium.

## Risk Stratification

The development of risk stratification scores has greatly facilitated prediction of mortality and rebleeding as well as decision making regarding the need for hospital admission, intensive care unit (ICU) admission, or urgent investigation in patients with GI bleeding. This allows consistent differentiation of patients requiring only outpatient investigation (eg, in patients with transient rectal bleeding) from urgent

therapeutic endoscopy in patients with ongoing upper GI bleeding. The BLEED study identified ongoing bleeding, low blood pressure (systolic blood pressure <100 mm Hg), elevated prothrombin time (>1.2 times control), erratic mental status, and unstable comorbid disease as risk factors for significantly higher rates of surgery, and increased recurrent bleeding and mortality in patients with GI bleeding.<sup>18</sup> Other studies have identified hepatic cirrhosis, high Acute Physiologic and Chronic Health Evaluation II (APACHE II) scores, active GI bleeding, hypotension, and end-organ dysfunction as independent predictors for the aforementioned outcomes.<sup>19</sup> These studies highlight the importance of comorbidities in determining outcome of GI bleeding. A further study confirmed this by identifying a mortality rate of nearly 30% in patients with significant renal disease and of 65% in patients with acute renal failure.<sup>20</sup> At present most of these scoring systems are predominantly used in research studies. There is little consensus on a uniform scoring system for use in the clinical domain, and these scoring systems should be applied with appropriate clinical judgment.

## HISTORY AND EXAMINATION

A thorough history and examination will not only assist in diagnosing the cause of the bleeding but will also identify any comorbidity likely to influence outcome.

## Important Characteristics of GI Bleeding

Time of onset, volume, and frequency of bleeding are key aspects of the history in determining amount of blood loss. The character of bleeding is also extremely important. *Hematemesis* is defined as the vomiting of blood, and it usually represents upper GI bleeding (rarely bleeding from the nasopharynx or oropharynx). Hematemesis may be bright red when fresh, but older blood will resemble coffee grounds. *Melena* is defined as the passage of offensive, black, tarry stool, again usually due to upper GI bleeding. The appearance of the stool is a result of gastric acid degradation (which converts hemoglobin to hemeatin), as well as the effects of intestinal enzymes and bacteria. Rarely, in cases of slow intestinal transit, blood loss from distal small bowel or the right colon may also present as melena. A guaiac test will allow differentiation of the tarry black stool of melena from the dark green stool of patients on iron supplementation (melena will test positive). Rectal bleeding is called hematochezia—this may represent blood on the tissue paper, blood around the stool, or blood mixed in with the stool, all important features to elicit on history taking. Hematochezia usually results from bleeding from the left side of the colon, usually sigmoid colon or rectum, but may manifest in massive upper GI bleeds with rapid transit through the intestine. Occasionally blood loss is occult, resulting in patients presenting with anemia. In these cases, history taking will identify end-organ symptoms suggestive of reduced oxygen delivery such as syncope, angina, or myocardial infarction.

## Other Essential Features in the History

Other useful features to elicit in the history include antecedent vomiting (suggesting a Mallory-Weiss tear), recent weight loss or loss of appetite (suggesting malignancy), recent epigastric pain (possibility of peptic ulceration), and alcohol intake or liver disease (likelihood of variceal bleeding). Demographic data such as age will also assist in narrowing down the cause of bleeding—diverticulitis, angiodysplasias, malignancy, and ischemic colitis are likely culprits in the elderly. In contrast, younger patients are more likely to bleed from peptic ulceration, Meckel's diverticula, hemorrhoids, or esophageal varices. Previous abdominal surgery may be of relevance—previous aortic surgery in particular raises suspicion of aortoenteric fistula. Drug history is especially relevant in upper GI bleeding. Nonsteroidal anti-inflammatory drugs (NSAIDs) are a common cause of peptic ulceration, and similarly salicylates and selective serotonin reuptake inhibitors (SSRIs) are also associated with upper GI bleeding.<sup>21,22</sup> Use of anticoagulants may require administration of fresh frozen plasma to correct the clotting but is not in itself a predisposing factor for GI bleeding.<sup>23</sup>

## PHYSICAL EXAMINATION

Although bleeding is likely to occur from the esophagus or more distal sites, bleeding from the nasopharynx and oropharynx may occasionally present as GI bleeding and so these sites should be routinely examined. Pigmented lesions in the oral mucosa suggest Peutz-Jeghers disease—a rare cause of GI bleeding. The abdomen should be examined to identify any masses or hepatosplenomegaly. A tender epigastrium is a non-specific indication of possible peptic ulceration. The neck and groins should be examined for lymphadenopathy suggestive of malignancy. The examination should include inspection for stigmata of liver disease. The jaundiced patient with ascites, caput medusae, and palmar erythema may present with GI bleeding secondary to varices. Rectal examination and anoscopy are essential aspects of the examination to exclude rectal cancer or, more frequently, hemorrhoids.

## IDENTIFYING THE SOURCE OF BLEEDING

Insertion of a nasogastric (NG) tube and aspiration may assist in identifying the source of the bleeding. An aspirate positive for blood (either fresh blood or coffee grounds) confirms upper GI bleeding, assesses the rate of bleeding, and allows removal of blood from the stomach to ensure good views of the gastric mucosa during esophagogastroduodenoscopy (EGD).

A negative aspiration of the stomach, however, does not rule out bleeding from the duodenum, as a competent pylorus will prevent reflux of bile, or blood from a bleeding

duodenal ulcer, into the stomach. A blood-free bilious aspirate strongly suggests a lower GI source for the bleeding; however, a recent study showed that 20% of patients had a blood-free aspirate from the duodenum despite a diagnosis of upper GI bleeding.<sup>24</sup>

## The Use of Endoscopy in the Management of Upper GI Bleeding

EGD remains the gold standard investigation for the diagnosis and management of upper GI bleeding, as it facilitates identification of the source of bleeding, determining the underlying etiology, achieving hemostasis, and providing prognostic information for risk stratification.<sup>25</sup> The timing of the endoscopic assessment in patients with GI bleeding remains controversial. Although there is little doubt that early endoscopy in hemodynamically unstable patients is necessary, the ideal timing for endoscopic intervention in stable patients remains less clear. A recent review of the studies examining the utility of early endoscopic intervention in upper GI bleeding concluded that while endoscopy within 24 hours of presentation was of benefit in terms of aiding risk assessment and reduced length of hospital stay, earlier endoscopies (within 12 hours) offered no additional benefit. Indeed, endoscopy within 12 hours of presentation was associated with unnecessarily increased use of therapeutic endoscopy without any benefit in terms of rate of rebleeding or survival. Overall, these studies suggested that endoscopy should be performed within 24 hours of presentation, and in hospitals without a 24-hour endoscopy service this should be offered to patients the following day.<sup>26</sup> Several issues need to be considered regarding the use of EGD in acute GI bleeding—first, the sensitivity of EGD may be reduced in the presence of active bleeding as mucosal visibility is impaired, and second, the rate of complications from EGD (perforation and aspiration) increases in the emergency setting. Airway protection and early intubation in the event of aspiration is therefore essential. Similarly, endoscopy in a patient with a low blood count can exacerbate the effects of sedative medications, causing hypotension and hypoxemia; hence resuscitative measures should not be delayed or paused for the endoscopic procedure. All patients undergoing urgent endoscopy should be continuously monitored using electrocardiogram (ECG) and noninvasive measurement of oxygen saturations.

## The Use of Endoscopy in the Management of Lower GI Bleeding

### FLEXIBLE SIGMOIDOSCOPY VERSUS COLONOSCOPY

Colonoscopy is recommended over flexible sigmoidoscopy in most cases of lower GI bleeding with few exceptions. Colonoscopy has been deemed the most appropriate investigation in patients older than 50 years with hematochezia

or iron deficiency anemia. In younger patients colonoscopy is unnecessary if a convincing benign source of bleeding has been demonstrated with flexible sigmoidoscopy but is necessary in the presence of repeated episodes of bleeding.<sup>27</sup>

### EFFECTIVENESS IN IDENTIFYING THE SOURCE OF ACUTE LOWER GI BLEEDING

Colonoscopy has a diagnostic yield of 89–97% in the setting of acute GI bleeding.<sup>28,29</sup> Bowel preparation using polyethylene glycol with a prokinetic such as metoclopramide has been recommended to improve endoscopic visualization and thus diagnostic yield.<sup>27,30</sup> This step may have to be omitted in patients with severe ongoing GI bleeding, where there is insufficient time for a formal bowel preparation routine.

### Capsule Enteroscopy and Deep Enteroscopy

Lesions of the small bowel causing bleeding are rare and account for only 5% of all GI bleeding. In the United States and Europe, angiodysplastic lesions account for 30–40% of such bleeding; the remaining sources are ulceration, Dieulafoy's lesions, and small bowel neoplasms in 1–3% of patients. Several factors make endoscopic access to the small bowel difficult, including the length of the small bowel, the intraperitoneal location, contractility, and overlying loops. Capsule enteroscopy has emerged as a suitable new option for small bowel imaging and is now the third diagnostic test in patients with obscure bleeding following EGD and colonoscopy.<sup>31</sup> The capsules measure 11 × 26 mm and contain a lens, white light-emitting diodes for illumination, silver oxide batteries, and an ultra high frequency (UHF) band radio telemetry transmitter. A capsule delivery device is available for patients with dysphagia, dysmotility disorders, and pediatric patients to deliver the capsule directly to the duodenum. Capsule enteroscopy has a much better yield than push enteroscopy or small bowel series, and an equivalent yield to intraoperative enteroscopy without the attendant morbidity and mortality of the operative procedure.<sup>32,33</sup> It must, however, be noted that capsule enteroscopy is unsuitable for imaging of the proximal duodenum because it provides poor visualization of the periampullary region, and the success of capsule enteroscopy is dependent on the experience of the reader.<sup>34,35</sup>

More recently, newer techniques for imaging of the small bowel ("deep enteroscopy") have been developed, specifically double-balloon enteroscopy, single-balloon enteroscopy, and spiral enteroscopy. The first two techniques use a balloon to grip the intestinal wall, allowing advancement of the endoscope forward through the intestine. Spiral enteroscopy uses a special overtube with helices at the distal end to pleat the small bowel onto the overtube, again allowing advancement of the endoscope through the intestine. Comparative trials are required to determine the advantages of each system in terms of insertion depth and procedure times. The advantage of these enteroscopic systems over capsule enteroscopy

is their ability to perform biopsies of lesions, treat bleeding, and execute therapeutic measures such as stent insertion or stricture dilation.<sup>36</sup> The most significant disadvantage of deep enteroscopy over capsule enteroscopy is the relatively high rates of perforation (0.3–3.4%), particularly in patients with inflammatory bowel disease, malignancy, and bowel anastomosis.<sup>35,37–40</sup>

### Angiography

Visceral angiography is a relatively insensitive investigation and able to detect bleeding only at a rate of 0.5–1 mL/min.<sup>41,42</sup> Although the specificity is 100%, the sensitivity varies from 47% with acute lower GI bleeding to 30% with recurrent bleeding.<sup>43</sup> Angiography has a role in patients with massive lower GI bleeding precluding colonoscopies or in patients with negative endoscopies.

### Red Cell Labeling (Nuclear Scintigraphy)

Red cell labeling has been found to play a limited role in the diagnosis of GI bleeding and may be useful after other methods have failed. While sensitive (this method can detect GI bleeding at a rate of 0.1 mL/min), the site of bleeding is only localized to an area of the abdomen, and intestinal motility shifts intraluminal blood away from the site of bleeding, resulting in a relatively nonspecific investigation. Specificity is improved when scans are positive within 2 hours after injection of labeled erythrocytes as less motility will have occurred, resulting in correct localization in 95–100% of cases. This decreases to 57–67% when scans are positive more than 2 hours after injection.<sup>44</sup> Red cell scans are therefore more often used to identify a potential role for angiography—in red cell scans only positive after 2 hours, angiography is unlikely to be sufficiently sensitive to detect bleeding.

## THERAPEUTIC OPTIONS

### Pharmacologic Management

Pharmacologic management is unlikely to halt active bleeding but instead is aimed at preventing recurrence of bleeding by management of the underlying etiology, such as triple therapy for *Helicobacter pylori* infection or proton pump inhibitors (PPIs) to prevent recurrence of gastric ulceration and bleeding.

### Endoscopic Treatment

Endoscopy remains the mainstay of investigation and often therapy for most causes of upper and lower GI bleeding. Techniques used for control of hemorrhage include thermal coagulation, injection therapy, and the use of mechanical

devices such as metallic clips and band ligation. Thermal coagulation probes include bipolar, monopolar, and heat probes, with an overall perforation rate of up to 2.5%, particularly frequent in the thin-walled right hemicolon.<sup>45</sup> Argon plasma coagulation (APC) is a means of noncontact coagulation with an almost nonexistent risk of perforation in the colon.<sup>46</sup> Laser-mediated coagulation (such as with the Nd:YAG laser) uses high-energy laser light to vaporize the tissue, producing deeper penetration than APC but with a higher perforation rate.

Injection of a 1:10,000 dilution of epinephrine is an effective and inexpensive method of endoscopic treatment, causing vasoconstriction and physical compression of the vessel. Metallic clips, both in reusable and disposable forms, are also suitable for arrest of hemorrhage endoscopically. Rubber band ligation is frequently employed in lower GI bleeding due to hemorrhoids or rectal varices.

## Interventional Angiography

While initial attempts of embolization led to high rates of bowel infarction due to the use of large-bore catheters for cannulation, the more recent approach using microcatheters has circumvented this and produces success rates of 70–90% without significant complications and recurrent hemorrhage rates of only 15%.<sup>47</sup> Embolization material includes microcoils, Gelfoam (gelatin sponge), and polyvinyl alcohol particles. Selective angiographic embolization has been shown to arrest life-threatening bleeding from gastroduodenal ulcers, with a low rate of early rebleeding and no late rebleeding, obviating the need for emergency surgery in high-operative-risk patients.<sup>48</sup>

Early bleeding recurrence is associated with coagulation disorders, longer time to angiography, higher preprocedural blood transfusion volume, two or more comorbidities, and the use of coils as the only embolic agent.<sup>49</sup> Embolization has also been shown to be of value in patients with diverticular lower GI bleeding, with an 85% success rate, and particularly successful in the left colon compared to the right colon and caecum. Less success was noted in nondiverticular lower GI bleeding, such as from arteriovenous dysplastic lesions, with a greater than 40% rate of rebleeding.<sup>50</sup>

Angiography may also be coupled with selective infusion of a vasoconstrictor such as vasopressin or the longer-acting analogue terlipressin; however, this is associated with a 50% rate of rebleeding after cessation of the infusion.<sup>51</sup> The side effects of vasopressin and terlipressin, including abdominal pain and cardiac complications, have meant that this technique is now only rarely used.

## Surgery

Surgery is rarely used as a means of controlling hemorrhage except when a clear bleeding point has been identified, but all other modalities of hemorrhage control have failed. However,

surgery remains the treatment of choice in patients with neoplasia and may be used as a last resort in patients with recurrent bleeding without a defined bleeding point or in fulminant hemorrhage. Blind segmental colectomy is associated with unacceptably high rates of rebleeding (up to 75%) and mortality (up to 50%); hence intraoperative endoscopy should be used to aid in determination of the source of bleeding, resulting in a more conservative directed segmental colectomy (6% rebleeding and 4% mortality).<sup>52,53</sup>

## UPPER GI HEMORRHAGE

### Causes of Upper GI Hemorrhage

Causes of upper GI hemorrhage can be divided into variceal and nonvariceal bleeding (Table 11-2), of which the latter is more common. Nonvariceal bleeding is also more common than variceal bleeding in patients with portal hypertension; however, the higher morbidity and mortality of variceal bleeding means that this should be excluded before bleeding is attributed to any other source.

### NONVARICEAL BLEEDING

**Peptic Ulcer Disease and Bleeding.** Numerous studies demonstrated a worldwide reduction in the incidence of peptic ulcers between 1958 and 1999, attributable to the introduction of *H. pylori* eradication therapy and PPIs. A reduction was also noted in the rate of operation and mortality from peptic ulcer disease; however, the overall incidence of peptic ulcer bleeding

**TABLE 11-2: CAUSES OF UPPER GI BLEEDING**

	Causes	Frequency (%)
<b>Nonvariceal upper GI bleeding (80%)</b>	Peptic ulcer disease	40
	Mallory-Weiss tears	15–20
	Gastritis/duodenitis	10–15
	Esophagitis	5–10
	Dieulafoy's lesions	1.5
	GAVE	4
	Malignancy	2
	Others:	7.5
	Aortoenteric fistula	
	Hemobilia	
Hemosuccus pancreaticus		
Iatrogenic bleeding		
<b>Portal hypertensive upper GI bleeding (20%)</b>	Gastroesophageal varices	>90
	Gastric varices	Rare
	Portal hypertensive gastropathy	Rare

GAVE, gastric antral vascular ectasia; GI, gastrointestinal.



did not show a significant decrease over the same period.<sup>12</sup> Peptic ulcer bleeding still carries a mortality rate of 5–10%,<sup>11,54</sup> and in-hospital care costs more than \$2 billion annually in the United States.<sup>55</sup>

Nonvariceal bleeding accounts for 80–90% of acute upper GI bleeding, the majority of which is due to gastroduodenal peptic ulceration,<sup>11</sup> which accounts for 40% of all nonvariceal upper GI bleeding.<sup>24</sup> A large proportion of this is associated with use of aspirin and NSAIDs, and the majority of cases occur in the elderly (68% of patients are >60 years of age and 27% >80 years of age).<sup>56</sup> At some point during the course of the disease, 10–15% of ulcers will bleed. Patients with bleeding ulcers commonly present with hematemesis and/or melena, and require early and aggressive fluid resuscitation to replace any existing losses. History, examination, and investigations should proceed as outlined previously (Fig. 11-2). Both duodenal and gastric ulcers can bleed profusely; however, this predilection is higher in gastric compared to the more common duodenal ulcers. Bleeding is most significant when involving an artery such as branches of the gastroduodenal or left gastric arteries.

Several risk stratification scores have been developed to assist in identification of patients who require close monitoring and are at risk of rebleeding. The two most commonly used tools are the Rockall score and the lesser used Blatchford score (Table 11-3). The Rockall score utilizes clinical as well as endoscopic findings to risk-stratify patients. The score ranges from 0 to 11; a higher score is associated with greater risk of rebleeding or death.<sup>57</sup> The Blatchford score uses hemoglobin, blood urea nitrogen, systolic blood pressure, pulse, melena, syncope, hepatic disease, or cardiac failure to produce a maximum score of 23; again higher scores indicate higher likelihood of rebleeding or death.<sup>58</sup>

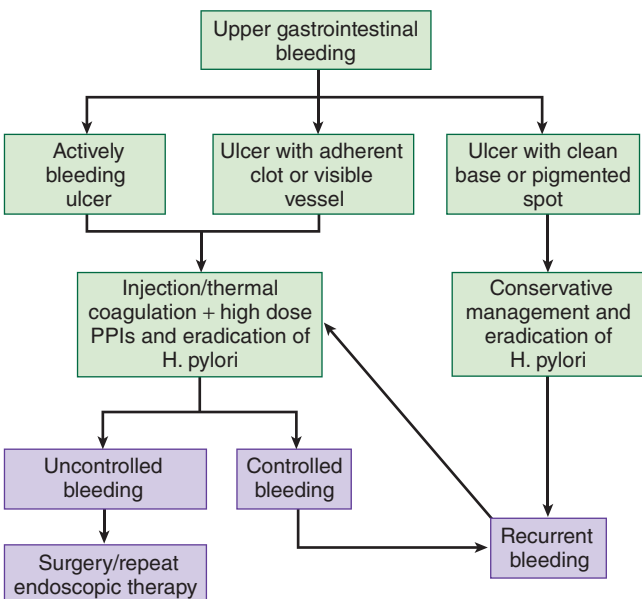


FIGURE 11-2 An algorithm for the management of peptic ulcer bleeding.

**TABLE 11-3: COMPARISON OF THE BLATCHFORD AND ROCKALL SCORES**

Criteria of the Blatchford Score	Criteria of the Rockall Score
Systolic blood pressure	Age
Blood urea nitrogen	Shock
Hemoglobin	Coexisting illness
Pulse	Endoscopic diagnosis
Melena	Endoscopic stigmata of recent hemorrhage
Syncope	
Hepatic disease	
Cardiac failure	

The endoscopic appearance of a bleeding ulcer alone can also be used to stratify the risk of rebleeding using the Forrest criteria (Table 11-4).<sup>59</sup> High-grade lesions are those that are actively spurting or oozing blood, or have a nonbleeding visible vessel or adherent clot.

**Medical Management**

**STOP ANY CAUSES (EG, DRUGS).** All ulcerogenic medication such as salicylates, NSAIDs, and SSRIs should be stopped and nonulcerogenic alternatives prescribed. Cyclooxygenase-2 (COX-2) inhibitors, which initially showed promise as a gastroprotective alternative to NSAIDs have recently been shown to demonstrate cardiotoxicity without significant benefit on gastric mucosal protection and are therefore infrequently used.<sup>60</sup>

**ERADICATION OF H. PYLORI AND LONG-TERM ACID SUPPRESSION.** The association of bleeding with *H. pylori* infection is not as strong as the association reported for perforated ulcers, with *H. pylori* infection reported in only 60–70% of bleeding ulcers. However, recent data show that treating patients positive for *H. pylori* with eradication therapy reduces the risk of rebleeding and obviates the need for long-term acid suppression<sup>61</sup>; hence *H. pylori* eradication is recommended in all bleeders infected with *H. pylori*.

**TABLE 11-4: FORREST CLASSIFICATION FOR ENDOSCOPIC FINDINGS AND RISK OF REBLEEDING IN PEPTIC ULCER DISEASE**

Classification (Grade)	Endoscopic Finding	Risk of Rebleeding
Ia	Active, pulsatile bleeding	High
Ib	Active, nonpulsatile bleeding	High
IIa	Nonbleeding visible vessel	High
IIb	Adherent clot	Intermediate
IIc	Ulcer with flat, pigmented spot	Low
III	Clean, nonbleeding ulcer bed	Low

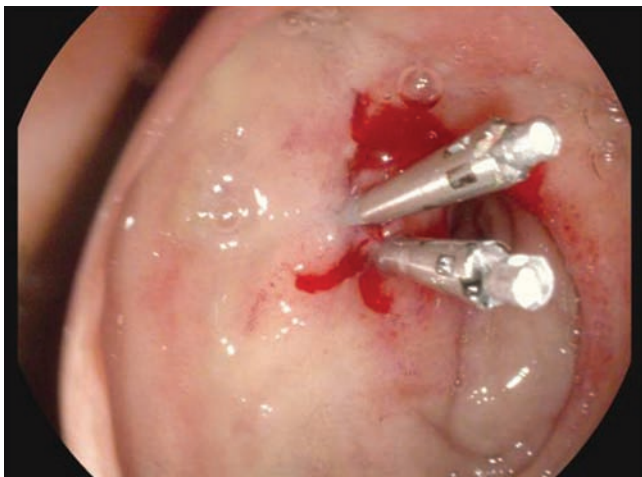Gastric acid has been shown to impair clot formation, promote platelet disaggregation, and increase fibrinolysis. In keeping with this, PPIs have been shown to significantly reduce the risk of ulcer rebleeding, the need for urgent surgery, and, in patients with high-risk stigmata who have undergone endoscopic therapy, mortality.<sup>62,63</sup>

**Endoscopic Management.** Patients with high-risk stigmata on endoscopy (active bleeding or nonbleeding visible vessel) require haemostatic intervention, such as injection, and thermal or mechanical therapy such as clips (Fig. 11-3). Addition of any one of these to adrenaline injection further reduces rebleeding rates, the need for surgery, and mortality.<sup>64-66</sup>

Several factors are predictors of failure of endoscopic therapy for peptic ulcer bleeding, including previous ulcer bleeding, shock and presentation, active bleeding during endoscopy, ulcers greater than 2 cm in diameter, a large underlying bleeding vessel greater than 2 mm in diameter, and ulcers on the lesser curve of the stomach or the posterior or superior duodenal bulb.<sup>67</sup> Recent studies suggest that second-look endoscopy (within 24 hours of the initial endoscopic therapy) provides only a small reduction in the rate of rebleeding, is not cost-effective in the presence of acid-suppressing medication, and is overall not recommended.<sup>25,68,69</sup> Repeat endoscopy should only be considered in cases of recurrent hemorrhage or unsuccessful first treatment.

**Surgical Management.** Meta-analysis and surgical registry data show the rate of surgical intervention for bleeding peptic ulcers has decreased to 6.5–7.5%. An improved understanding of peptic ulcer disease as well as the development of newer pharmacologic and endoscopic treatments has meant that surgery is now employed not as first-line or curative treatment, but instead only when other modalities have failed.

There are no consensus guidelines on the appropriate indications for surgery; however in general, persistent blood



**FIGURE 11-3** Metallic clips to arrest bleeding from a duodenal ulcer. (Used with permission from Dr Nicola Simmonds, Luton and Dunstable Hospital, UK.)



**TABLE 11-5: POSSIBLE INDICATIONS FOR SURGICAL INTERVENTION FOR PEPTIC ULCER BLEEDING**

**Possible Indications for Surgery in Peptic Ulcer Bleeding**

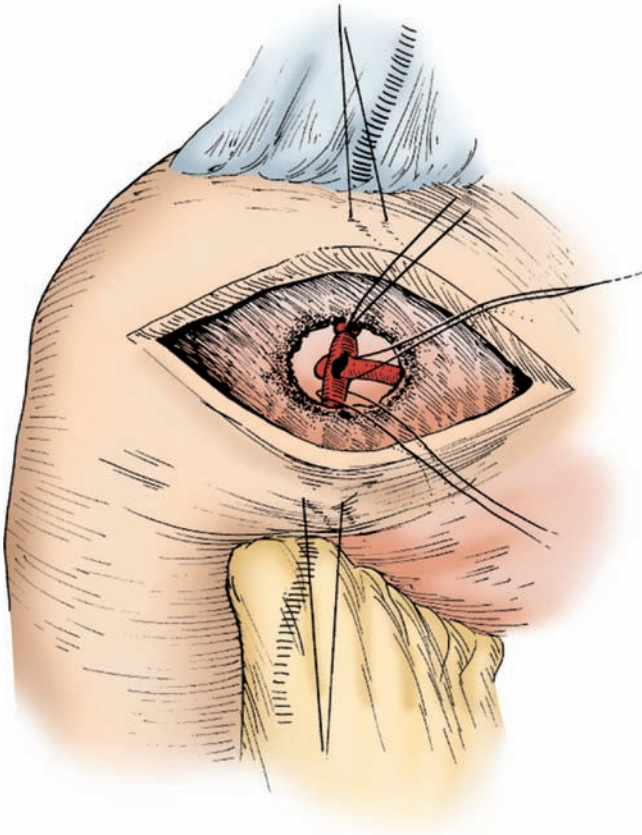
Absolute indications	Persistent blood loss refractory to endoscopic therapy Shock with recurrent hemorrhage Slow blood loss requiring >3 units blood
Relative indications	Shock on admission Transfusion in excess of 6 units Elderly patient Severe comorbidity Rare blood type/refusal of transfusion Suspicion of malignancy in a gastric ulcer

loss with failure of endoscopic therapy and a blood transfusion requirement in excess of 6 units are often considered an indication for surgical intervention (Table 11-5). Similarly, hypovolemic shock associated with recurrent hemorrhage or a slow continuous blood loss requiring transfusion of more than 3 units per day is also considered indicative. Shock on admission, an elderly patient, severe comorbidity, a rare blood type, refusal of transfusion, and bleeding chronic gastric ulcer with a suspicion of malignancy are considered relative indications for surgery.

In stable patients with evidence of rebleeding, a second attempt at endoscopic hemostasis is often as effective as surgery with fewer complications and is the recommended management.<sup>70</sup> The aim of surgery in both gastric and duodenal ulcers is to arrest hemorrhage and perform an acid-reducing procedure if deemed necessary.

**OPERATIVE PROCEDURE FOR DUODENAL ULCERS.** A longitudinal duodenotomy or duodenopyloromyotomy provides good exposure of bleeding sites in the duodenal bulb, the most common site of duodenal ulcers. Direct pressure provides temporary arrest of the bleeding, and it should be followed by suture ligation with a nonabsorbable suture such as Prolene. Four-quadrant suture ligation will achieve hemostasis in anterior ulcers. Posterior ulcers, particularly if involving the pancreaticoduodenal or gastroduodenal artery, will require suture ligation of the artery both proximal and distal to the ulcer for adequate control of hemorrhage, as well as placement of a U-stitch underneath the ulcer to control the pancreatic branches (Fig. 11-4).

The use of an acid-reducing procedure in duodenal ulcers remains a topic of debate, as theoretically arrest of hemorrhage and *H. pylori* eradication is likely to be sufficient management. In the absence of trials and convincing data, however, it is hard to make any firm recommendations, and the decision is best left to the surgeon taking into account each patient's condition and their experience with such operations. Surgical



**FIGURE 11-4** Suture control of bleeding duodenal ulcers. A longitudinal pyloric incision is made and figure-of-eight sutures are placed at the cephalad and caudad aspects of the ulcer to occlude the gastroduodenal artery.

options for acid reduction in bleeding duodenal ulcer management include pyloroplasty with truncal vagotomy, parietal cell vagotomy, or antrectomy with truncal vagotomy. The former is the most frequently used as it is facilitated by the longitudinal approach to the pylorus for arrest of hemorrhage. Parietal cell vagotomy is limited by surgeon inexperience. Antrectomy with truncal vagotomy may be suitable in patients refractory to conservative surgery but is a complex procedure that is unsuitable in the shocked patient. Ulcer surgery is covered in greater detail in Chap. 26.

**OPERATIVE PROCEDURE FOR GASTRIC ULCERS.** Management of the bleeding gastric ulcer also prioritizes arrest of the bleeding. However, because of the risk of rebleeding and the 10% risk of malignancy in gastric ulcers, gastrotomy and suture ligation are insufficient in these patients. Resection of the ulcer alone is associated with a 20% rebleeding rate; hence a distal gastrectomy is recommended for ulcers in the antrum and distal stomach. In patients who may be unfit for a distal gastrectomy, resection of the ulcer itself combined with an acid-reducing procedure in the form of a vagotomy and pyloroplasty may

be an option. Management of bleeding ulcers at the cardioesophageal junction and the proximal stomach is more challenging. While optimal resection would involve a proximal or near-total gastrectomy, this results in increased morbidity and mortality in patients acutely bleeding. More conservative options may suffice, such as distal gastrectomy with resection of a tongue of proximal stomach to ensure excision of the ulcer, or a wedge resection of the ulcer or simple oversewing with a vagotomy and pyloroplasty.

**Mallory-Weiss Tears.** The sensation of nausea is accompanied by closure of the pylorus, gastric distension, and retrograde propulsion of gastric contents toward the cardia. When this is followed by vomiting, the diaphragm moves abruptly upward, associated with rapid increase in intra-abdominal pressure that pushes the gastric cardia into the thorax through the diaphragmatic hiatus. With sufficient force, a longitudinal laceration of the esophagus or stomach can result.<sup>71</sup> Hiatus hernias coexist in more than 75% of patients with Mallory-Weiss tears, and the amount of herniated stomach determines the point of maximal dilation (law of Laplace) and therefore the position of the tear.<sup>72,73</sup> Large hiatus hernias are associated with more distal tears, while in patients with small or absent hiatus hernias, tears occur at or below the gastroesophageal junction. The majority of tears are situated within 2 cm of the gastroesophageal junction on the lesser curvature.

The highest incidence of Mallory-Weiss tears occurs in patients between 30 and 50 years of age and in men more than women. Some 40–75% of patients have a history of alcohol use<sup>74</sup> and 30% a history of aspirin use.<sup>75</sup> Patients typically present with a history of several episodes of vomiting or retching followed by hematemesis with fresh red blood. Ten percent of patients may present with only melena.

EGD usually identifies a single tear on the lesser curve of the cardia, or occasionally on the greater curvature of the cardia. Retroflexion during the endoscopic examination is an important maneuver in these patients to ensure the distal gastroesophageal junction and cardia are visualized. The majority of lesions heal spontaneously; hence management is largely supportive, with emphasis on antiemesis and acid suppression. Patients with persistent bleeding may require endoscopic injection or thermocoagulation, or angiographic embolization. Surgery may be required should these options prove unsuccessful, and hemorrhage can be arrested operatively by a high gastrotomy and suture of the mucosal laceration.

**Stress-Related Mucosal Bleeding.** Critically ill patients are at risk for the development of diffuse mucosal injury of the stomach, resulting in upper GI bleeding with significant morbidity and mortality. This phenomenon, termed “stress-related mucosal bleeding” or occasionally “stress gastritis,” is a result of a combination of mucosal ischemia and reperfusion injury and impairment of host cytoprotective defenses, and ultimately results in a prolonged ICU stay in a vulnerable population of patients.<sup>65</sup> While this phenomenon was previously common, the incidence of clinically significant



bleeding in the critically ill population has now decreased to less than 3.5% with the use of prophylaxis.<sup>76</sup>

The most important risk factors for stress-related mucosal bleeding are prolonged mechanical ventilation (>48 hours) and coagulopathy. Other factors include shock, severe sepsis, neurologic injury/neurosurgery, greater than 30% burns, and multiorgan failure. Patients with these risk factors require prophylaxis with antacids, H<sub>2</sub>-receptor blockers, PPIs, or Carafate.

Acid suppression is often sufficient to control hemorrhage in stress-related mucosal bleeding. For persistent bleeding, options include selective infusion of octreotide or vasopressin via the left gastric artery, endoscopic measures, or angiographic embolization. Surgery is now rarely performed but, if necessary, involves vagotomy and pyloroplasty with oversewing of discrete regions of hemorrhage or subtotal gastrectomy.

**Esophagitis.** In rare cases bleeding may originate in the esophagus and is then often due to esophagitis. Gastroesophageal reflux disease (GERD) repeatedly exposes the mucosa to irritant acidic gastric content, causing chronic inflammation and blood loss (Fig. 11-5). Occasionally ulceration may follow, presenting as occult bleeding with anemia or guaiac-positive stool. While GERD is the most common cause, other causes include Crohn's disease, certain drugs, and radiotherapy. Immunocompromised patients may have esophagitis of an infective etiology; causes most commonly include herpes simplex, *Candida*, and cytomegalovirus (CMV), but esophagitis can occasionally be due to ulceration directly induced by human immunodeficiency virus (HIV) or Epstein-Barr virus, or secondary involvement of the esophagus in mycobacterial infection of adjacent lymph

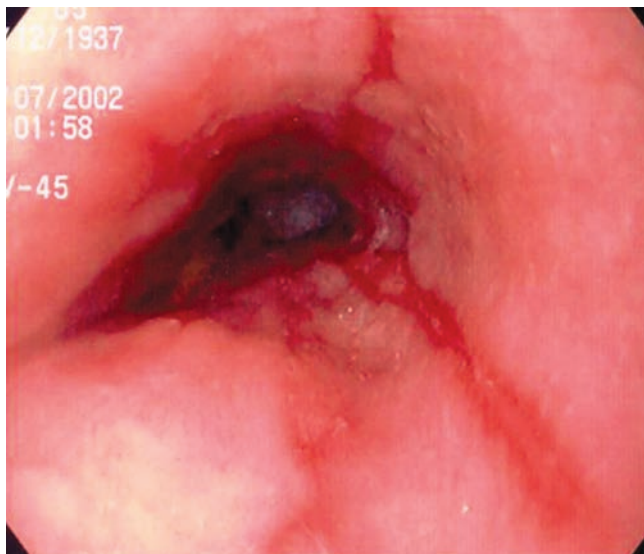


FIGURE 11-5 Gastroesophageal reflux disease (GERD) viewed on endoscopy.

nodes.<sup>77</sup> Infective esophagitis is uncommon but may lead to torrential hemorrhage.

Management, particularly of GERD-induced esophagitis, hinges on acid-suppressive therapy, occasionally requiring therapeutic endoscopy to arrest the bleeding. Treatment of the infective cause is often successful at managing the bleeding in immunocompromised infected patients.

**Dieulafoy's Lesion.** Dieulafoy's lesions are an arterial vascular anomaly featuring abnormally large ("caliber persistent") submucosal end arteries, likely congenital in origin, and with the potential for massive, potentially life-threatening hemorrhage upon erosion of the overlying gastric mucosa. These lesions are most commonly located in the stomach within 5–7 cm of the cardia but may present in small bowel, duodenum, and colon. These account for 1.5% of upper GI bleeding and are more commonly encountered in men.<sup>78</sup>

Dieulafoy's lesions appear as reddish-brown protrusions on endoscopy with no ulceration. Endoscopic therapy is often successful provided good visualization of the lesion is obtained; mechanical methods such as clipping or banding have been shown to work better than injections for control of hemorrhage.<sup>79,80</sup> Angiographic embolization or surgery may be employed for endoscopic failures. Surgical intervention may require prior endoscopic tattooing to facilitate identification of the site, followed by wedge resection of the lesion.<sup>78</sup>

**Gastric Antral Vascular Ectasia (GAVE).** GAVE, or "watermelon stomach," is so named for the dilated, tortuous mucosal capillaries and veins present in the antrum, converging onto the pylorus, and resembling the surface of a watermelon (Fig. 11-6). This condition is more common in women than in men and often presents with occult blood loss and iron

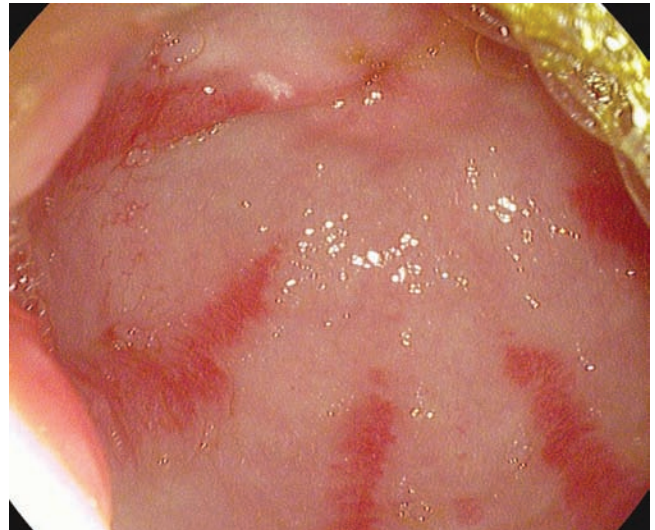
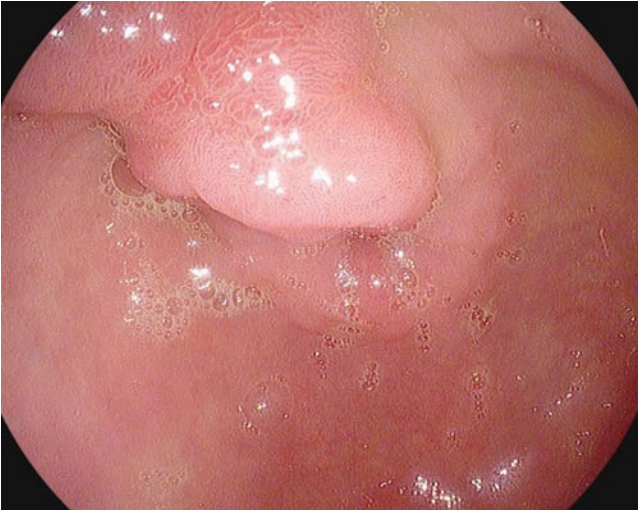

FIGURE 11-6 Gastric antral vascular ectasia (GAVE) can be seen in the gastric antrum, giving the stomach a watermelon appearance. (Used with permission from Dr Nicola Simmonds, Luton and Dunstable Hospital, UK.)





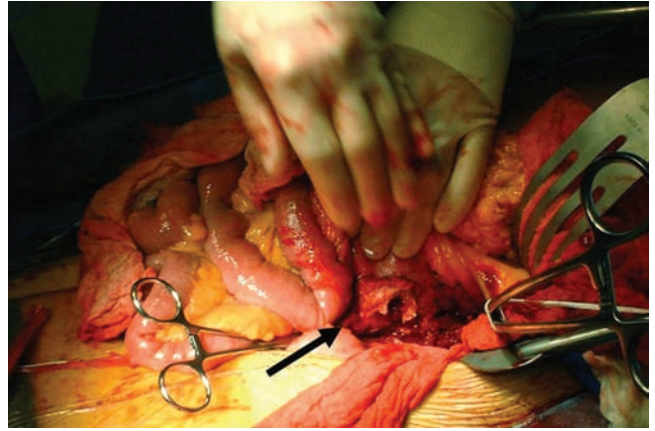
**FIGURE 11-7** A gastrointestinal stromal tumor (GIST) of the stomach on endoscopy. (Used with permission from Dr Nicola Simmonds, Luton and Dunstable Hospital, UK.)

deficiency anemia. APC is the treatment of choice for GAVE; treatment may need to be repeated for recurrences, and PPI cover is recommended for 1 month following treatment.<sup>78,81</sup> Patients refractory to APC should be considered for surgical intervention in the form of an antrectomy.

**Malignancy.** Malignant upper GI lesions rarely present with overt significant hemorrhage and instead are more likely to present with hemocult-positive stool or iron deficiency anemia. Endoscopy occasionally reveals a recurrent bleeding ulcer, a common feature of GI stromal tumors, which characteristically appear as a submucosal tumor with central umbilication and ulceration (discussed further in Chap. 24), and on occasion leiomyomas and lymphomas (Fig. 11-7). Surgery is necessary as the rate of rebleeding in these malignant lesions is high, and may involve full curative resections or in unfit patients, palliative wedge resections for hemorrhage control.

**Aortoenteric Fistula.** Aortoenteric fistula is an important clinical condition, often presenting with torrential GI hemorrhage. Primary fistulae are rare; most commonly fistulation occurs following a previous abdominal aortic aneurysm (AAA) repair and is seen in approximately 1% of these cases. The pathophysiology behind this is likely to be infective in origin, leading to the development of a pseudoaneurysm at the proximal suture line, resulting in fistulization into the duodenum (Fig. 11-8).

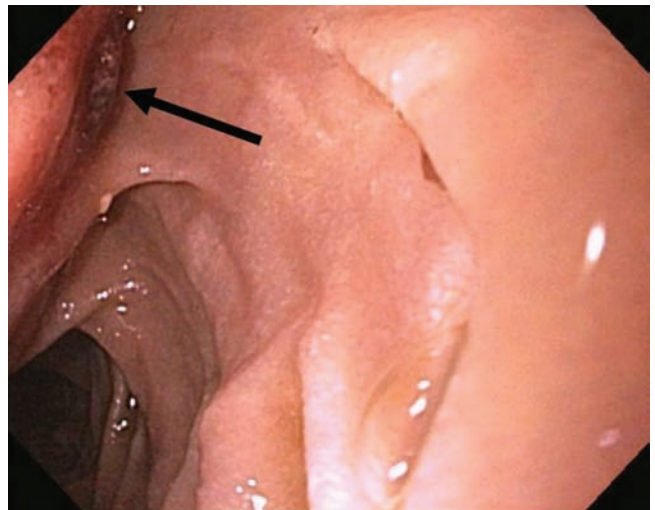
Early diagnosis of this problem is critical but can be difficult. A high index of suspicion is required in all patients presenting with GI hemorrhage with known aortic aneurysms or a history of previous aortic aneurysm repair. Often, patients present with several smaller, self-limiting episodes of GI hemorrhage (“sentinel bleeds”). Urgent endoscopy at this stage is essential to preempt a subsequent torrential, often



**FIGURE 11-8** Intraoperative appearance of an aortoenteric fistula. The photograph demonstrates a large hole (*black arrow*) in the posterior aspect of the third part of the duodenum after it was medialized and peeled off of the graft. The photograph has been taken from left side of the table with the patient in supine position. (Used with permission from Neal Barshes, MD, MPH, Brigham and Women’s Hospital, Boston, MA.)

fatal bleed, and usually reveals bleeding at the third or fourth part of the duodenum (Fig. 11-9). CT with IV contrast is a useful adjunct in these patients, often demonstrating air within the aortic thrombus or around the graft (particularly in the context of an infected graft), and rarely a pseudoaneurysm or contrast within the duodenal lumen.

Surgical repair involves extra-anatomic bypass grafting and aortic ligation for primary aortoenteric fistula. For secondary aortoenteric fistula, surgery involves excision of the graft with extra-anatomic bypass or in situ aortic reconstruction. By necessity these procedures are often performed in critically ill,



**FIGURE 11-9** Endoscopic view of the aortoenteric fistula on EGD showing the fistulous track (*black arrow*) into the aneurysmal sac from the third part of the duodenum. (Used with permission from Neal Barshes, MD, MPH, Brigham and Women’s Hospital, Boston, MA.)

severely exsanguinated, and septic patients and hence associated with high morbidity and mortality.

With the advent of endovascular stenting for primary AAA repair, various studies have been performed to determine the effectiveness of endovascular stenting for aortoenteric fistula. This has been associated with a high incidence of recurrent bleeding and infection, particularly in the presence of preprocedural infection.<sup>82</sup>

**Hemobilia.** Hemobilia is a rare cause of GI bleeding. Causes include trauma, hepatic neoplasms, instrumentation of the biliary tree, percutaneous radiofrequency liver ablation, and following liver transplant. A high index of suspicion is required in patients with these risk factors, as the classic presentation of hemorrhage, right upper quadrant pain, and jaundice is only seen in a minority of patients. Endoscopy may reveal blood at the ampulla, but angiography and embolization remain the diagnostic and therapeutic modality of choice.

**Hemosuccus Pancreaticus.** Bleeding from the pancreatic duct (hemosuccus pancreaticus) is another rare cause of upper GI bleeding, due to fistulation of a pancreatic pseudocyst into the splenic or other peripancreatic artery.<sup>83</sup> A presentation of abdominal pain, hematemesis, and melena in patients with a previous history of pancreatitis should raise suspicion of hemosuccus pancreaticus. Angiography is again both diagnostic and therapeutic, although in some cases distal pancreatectomy may be employed.

**Iatrogenic Bleeding.** Upper GI endoscopy or surgery is another cause of bleeding. Percutaneous gastrostomy is often necessary as a means of nutritional support in certain conditions but is accompanied by a 3% rate of GI hemorrhage. Bleeding may have tracked into the stomach from the incision site but may also be from the stomach mucosa; both causes can be managed endoscopically.

Endoscopic sphincterotomy is increasingly common as a means of accessing the biliary tree during an endoscopic retrograde cholangiopancreatography and facilitates endoscopic clearance of the common bile duct, but it is associated with a 2% risk of bleeding. Bleeding may occur after 48 hours but can often be arrested by local injection of epinephrine, rarely requiring surgical intervention. Bleeding following upper GI surgery may occur from suture or staple lines. This can occasionally be treated endoscopically, with minimal insufflation to avoid disruption of the anastomosis.

## VARICEAL BLEEDING AND PORTAL HYPERTENSION

Portal hypertension is a serious cause of upper GI bleeding, often the result of cirrhosis that is the end stage of chronic liver disease. The pathophysiology of portal hypertension is discussed further in Chap. 47 and hence is not covered here. Approximately 50% of patients with cirrhosis will develop gastroesophageal varices as a result of portal hypertension.<sup>84</sup> Variceal bleeding occurs in 30% of patients

and is one of the most important complications of hepatic cirrhosis. Variceal bleeding is associated with increased risk of rebleeding and transfusion requirement, greater length of hospital stay, and higher morbidity and mortality compared with nonvariceal bleeding.<sup>17,84</sup>

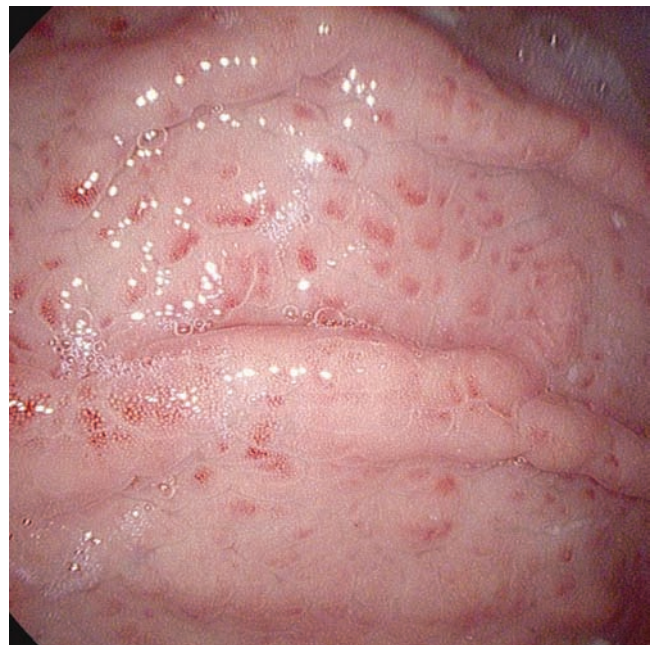
Gastroesophageal varices represent one site of portosystemic anastomosis, which is dilated as the portal circulation tries to decompress to the systemic circulation. Other sites of portosystemic collaterals are the stomach, the umbilical region (collateral formation leads to formation of caput medusae), and the distal rectum.

Factors that determine variceal bleeding include high variceal wall tension (determined by vessel diameter) and variceal pressure, in turn related to hepatic venous pressure gradient (HPVG). Patients with a HPVG of less than 12 mm Hg are unlikely to develop variceal bleeding.<sup>85</sup>

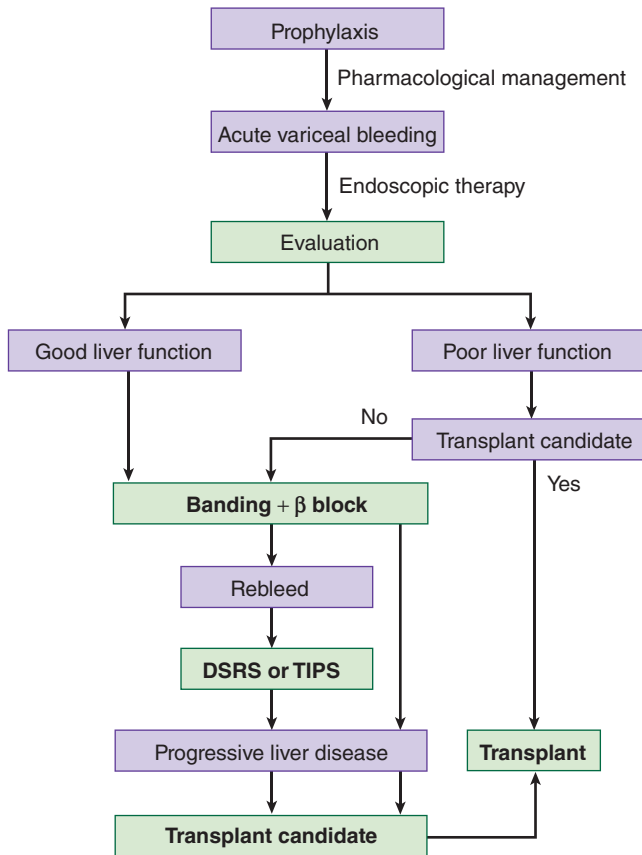
Isolated gastric varices (IGV) can occur in the absence of esophageal varices and are located along the gastric fundus (IGV1), or along the body, antrum, or pylorus (IGV2).<sup>84</sup> Risk factors for gastric variceal bleeding include variceal size and the presence of a cherry-red spot (localized reddish mucosal area or spots on the mucosal surface of a varix).<sup>86</sup>

In addition to varices, portal hypertension can also cause the development of portal hypertensive gastropathy, diffuse dilation of the mucosal, and submucosal venous plexus of the stomach with overlying gastritis. The stomach develops a snake-skin appearance with cherry-red spots on endoscopy, and rarely may be the site of major hemorrhage (Fig. 11-10).

The management of variceal upper GI bleeding follows the same principles as those of nonvariceal upper GI bleeding, with



**FIGURE 11-10** Endoscopic view of portal hypertensive gastropathy. Note the snake-skin appearance of the stomach and the associated cherry-red spots. (Used with permission from Dr Nicola Simmonds, Luton and Dunstable Hospital, UK.)



**FIGURE 11-11** An algorithm for the management of variceal bleeding. DSRS, distal splenorenal shunt; TIPS, transjugular intrahepatic portosystemic shunt.

emphasis on urgent resuscitation and therapeutic endoscopy because of the higher morbidity and mortality associated with variceal bleeds (Fig. 11-11).

EGD remains the gold standard for diagnosing variceal bleeding. The diagnosis of variceal hemorrhage is based on meeting one of the following criteria: active bleeding from a varix, a “white nipple” overlying a varix, clots overlying a varix, or varices with no other potential source of bleeding.<sup>87</sup>

**Management.** Treatment of variceal bleeding requires a combination of medical and endoscopic management.

**Medical.** Somatostatin or its analogues octreotide or terlipressin should be administered as a bolus immediately in cases where there is a high index of suspicion, and continued for 3–5 days after endoscopic confirmation of diagnosis.<sup>84</sup> Fluids and blood products should be administered judiciously to maintain a hemoglobin level of greater than 8 g/dL. Current recommendations are that any patients with cirrhosis and GI bleeding should be given up to 7 days of antibiotic prophylaxis, specifically a fluoroquinolone such as norfloxacin or ciprofloxacin.

**Endoscopic.** Variceal bleeding should be diagnosed and treated by EGD, either with variceal ligation or

sclerotherapy.<sup>84</sup> In patients with variceal bleeding, endoscopy should be performed as soon as possible (within 12 hours of admission).<sup>88,89</sup> This is of particular importance in patients with hemodynamic instability or features of cirrhosis. Early endoscopy also excludes nonvariceal causes of bleeding, which occur in 15% of patients with varices.<sup>90</sup> Variceal ligation is the endoscopic treatment of choice as it has been shown to have lower rates of complications compared to sclerotherapy, which can cause perforation, mediastinitis, and stricture formation. Variceal ligation involves the placement of rubber bands on the varices to completely interrupt blood flow into the ligated varix and arrest hemorrhage acutely. The mucosa and submucosa develop ischemic necrosis and granulation and sloughing of the rubber rings, and necrotic tissue results in replacement of varices by scar tissue. Sequential treatments may be required, as many as three treatments over 24 hours, but will achieve control of hemorrhage in up to 90% of patients.

Mechanical tamponade devices may be useful in temporarily controlling bleeding from esophageal varices where endoscopy and medical management have failed. One example is the Sengstaken-Blakemore tube, which consists of a gastric tube with gastric and esophageal balloons. Inflation of the gastric and esophageal balloons compresses the esophagogastric venous plexus, arresting bleeding, but at the risk of ischemic necrosis and perforation. Deflation of the tube can be associated with recurrent bleeding in 50% of patients; hence this technique is reserved as a temporizing measure in massive hemorrhage before more definitive intervention is commenced.

Gastric varices should be managed initially by pharmacotherapy. Endoscopic therapy is not as successful in gastric varices because of the diffuse nature of portal hypertensive gastropathy. Patients with refractory bleeding should be referred early for decompressive therapy such as TIPS (transjugular intrahepatic portosystemic shunt) or shunting.

IGVs, without associated portal hypertension, can occur in the setting of splenic vein thrombosis, often associated with pancreatitis. Varices occur in the presence of normal central portal pressures due to left-sided hypertension, rerouted from the spleen to the short gastric vessels. Splenectomy may relieve the hypertension, but the risk of variceal bleeding in these patients is low and hence splenectomy should not be routinely undertaken.<sup>91</sup>

**PREVENTION OF REBLEEDING.** Prevention of rebleeding is of the utmost importance in this patient population. Rebleeding may occur in up to 70% of patients within 2 months without further definitive therapy.<sup>92</sup> The highest risk of rebleeding is in the first few days following the initial episode. A combination of nonselective beta-blockers with isosorbide mononitrate has been shown to be more effective than beta-blockers alone in preventing rebleeding.<sup>93</sup> The addition of prophylactic endoscopic band ligation to combination pharmacotherapy did not reduce the risk of rebleeding but instead was associated with more adverse events in a recent randomized controlled trial.<sup>94</sup>



**Radiologic or Surgical Portal Decompression.** In approximately 10% of cases of variceal bleeding, endoscopic management is unsuccessful, necessitating urgent decompression of the portal system. A TIPS procedure involves the creation of an artificial anastomosis between the hepatic and portal veins under fluoroscopic guidance with the use of a covered stent, shunting blood away from the hepatic sinusoids and relieving portal pressure.<sup>95</sup> TIPS is, however, associated with a 30-day mortality of up to 30% in the emergency setting, usually a result of hepatic encephalopathy from diversion of blood away from the liver parenchyma.<sup>96</sup> Rebleeding may occur in 20% of patients and is often due to occlusion of the anastomosis. Surgery is another therapeutic option for decompression of the portal system. Surgical shunts, such as the selective distal splenorenal shunt (DSRS), have lower rates of rebleeding compared to endoscopic therapy but do not demonstrate any difference in survival.<sup>97</sup> DSRS patients have an in-hospital mortality of approximately 5%, a 5–8% rate of rebleeding, and a 75–80% 3-year survival.<sup>97</sup> A recent randomized controlled trial comparing TIPS with DSRS in patients with failed medical or endoscopic therapy showed no significant difference in the rate of rebleeding, hepatic encephalopathy, or overall survival, but identified a need for close follow-up and a greater need for reintervention in patients subjected to TIPS, suggesting that in patients with relatively limited access to health care facilities, DSRS may be a more suitable therapeutic option.<sup>98</sup> Further details on surgical decompression for portal hypertension are covered in Chap. 47.

## LOWER GI HEMORRHAGE

Lower GI bleeding can occur from any site distal to the ligament of Treitz, most commonly from the colon. Occasionally bleeding can also occur from the small bowel. Difficulty in diagnosis of lower GI bleeding stems from the large surface area of colon and small intestine, intermittent bleeding, occasional lack of visible mucosal lesions, and difficulties in endoscopic visualization as lesions are obscured by forward movement of blood. The majority of patients with lower GI bleeding experience self-limiting episodes; only 10–20% of patients present with massive unremitting lower GI bleeding. Patients with self-limited bleeding can usually be managed with initial resuscitation, exclusion of an upper GI source, and further investigation using colonoscopy and, if necessary, angiography or nuclear scintigraphy. Younger patients with suspected hemorrhoidal bleeding should be followed up and the hemorrhoids managed appropriately, while older patients should be investigated for malignancy before bleeding is attributed to a benign pathology. Bleeding from the anus or rectum can be identified by digital rectal examination (DRE) and proctoscopy and may on occasion require sigmoidoscopy. Upper GI bleeding can be effectively excluded in the presence of a blood-free bilious NG aspirate; however, an EGD is required for definitive exclusion.

## Management of Lower GI Hemorrhage

Lower GI bleeding is often less severe than upper GI bleeding; however, the same principles for resuscitation should be followed (Fig. 11-12), guided by the hemodynamic stability of the patient. Accurate identification of the source of bleeding can be difficult in patients with lower GI bleeding—more than one source for bleeding is found in 40% of patients and in up to 25% of patients no source is identified. A management algorithm is outlined in Fig. 11-13. Patients with hematochezia who are hemodynamically stable should undergo colonoscopy in the first instance to identify a cause for the bleeding. If a bleeding site is identified, endoscopic therapy should be attempted to control the bleeding. If no bleeding site is identified, an EGD should be performed, followed by capsule or deep enteroscopy if this is unsuccessful. Hemodynamically unstable patients should undergo EGD in the first instance as severe upper GI bleeding may often present as hematochezia.

Patients with bleeding refractory to endoscopic management or those with significant hemodynamic instability may require urgent operative intervention. In these patients an exploratory laparotomy is required, and attempts made to determine the location of blood within the GI tract. Although this is relatively nonspecific, it may assist in broadly localizing the origin of bleeding; for instance if blood is only present beyond the ileocecal valve, bleeding is likely to be colonic in origin. The GI tract should be thoroughly examined to exclude bleeding from small bowel tumors or Meckel's diverticulum. A segmental bowel resection is appropriate in localized bleeding, and in relatively fit patients this may be combined with a primary anastomosis. In unfit patients with preexisting hemodynamic instability or severe malnutrition, a mucous fistula and end stoma is a more appropriate option. Segmental colectomies should not be performed as “blind” procedures without localization of the bleeding source, as these have been associated with unacceptably high mortality rates and rebleeding rates between 20 and 50%.<sup>99</sup> A better alternative in patients without localization of the bleeding source is a “blind” subtotal colectomy, with a primary ileorectal anastomosis, associated with a less than 10% mortality rate and less than 10% rebleeding rate with the benefit of normal postoperative bowel control. This procedure further allows irrigation of the rectal segment with repeat proctoscopy to rule out rectal bleeding.

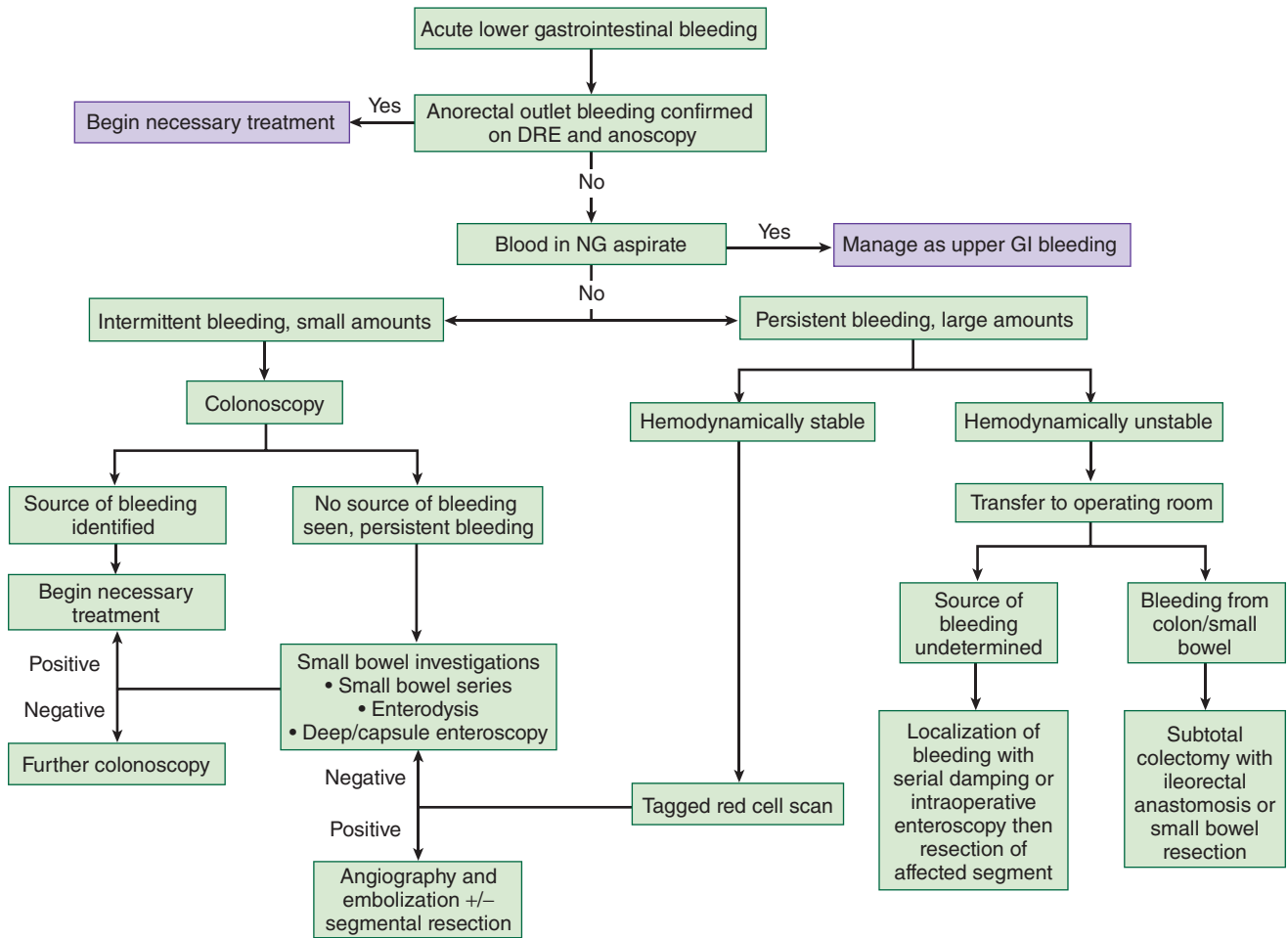
On-table lavage may allow identification of a bleeding source, facilitating segmental colectomy, but is best attempted in stable patients who may not retain acceptable bowel function after a total or subtotal colectomy and not advised in the unstable patient.

## Causes of Lower GI Hemorrhage

### OVERT LOWER GI BLEEDING

The majority of lower GI bleeding originates from the colon as a result of common pathologies such as diverticular disease

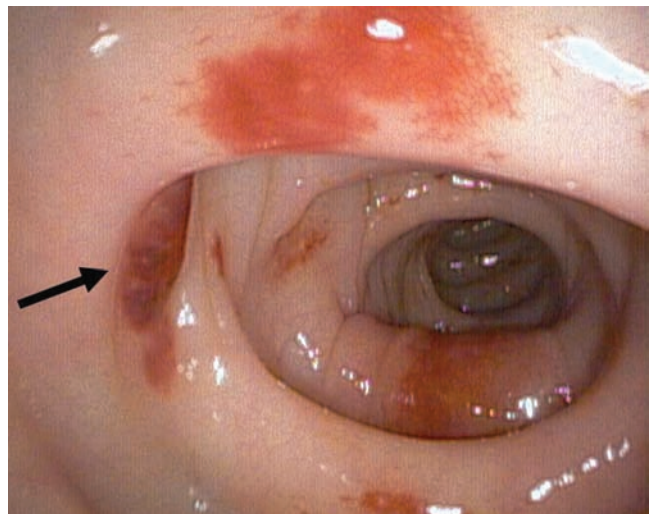




**FIGURE 11-12** An algorithm for the management of lower gastrointestinal bleeding. DRE, digital rectal examination; GI, gastrointestinal; NG, nasogastric. (Adapted from Fig. 46-12, *Sabiston Textbook of Surgery*, 18th ed. Townsend, Beauchamp, Evers, and Mattox, Elsevier.)

and neoplasia (Table 11-6). Early identification of the cause of bleeding is essential to initiate appropriate management, in particular for cases of malignancy.

**Diverticular Disease.** Diverticular disease is an extremely prevalent and often asymptomatic disease of Western countries. The incidence increases with age; up to 60% of patients older than 80 years have diverticulae.<sup>100</sup> In Western countries, 95% of diverticula are in the sigmoid and left colon; however, in Asian countries 70% of cases are in the right colon.<sup>101,102</sup> Colonic diverticular are usually pulsion-type pseudodiverticula—outpouchings of the mucosa and submucosa through the muscular layer of the bowel at the sites of penetration of the vasa recta—resulting from high intraluminal pressure and bowel segmentation. Only 4–17% of patients with diverticular disease develop symptoms of bleeding<sup>103</sup>; however, the frequency of diverticular disease means that diverticular bleeding accounts for 30–40% of lower GI bleeding.<sup>104</sup> Eighty percent of diverticular bleeds stop spontaneously, but a small minority will require hemostatic intervention. Ten percent of patients will rebleed within a year and 50% within 10 years.<sup>104</sup>



**FIGURE 11-13** An inflamed diverticulum with associated bleeding (black arrow) seen on colonoscopy. (Used with permission from Dr Nicola Simmonds, Luton and Dunstable Hospital, UK.)

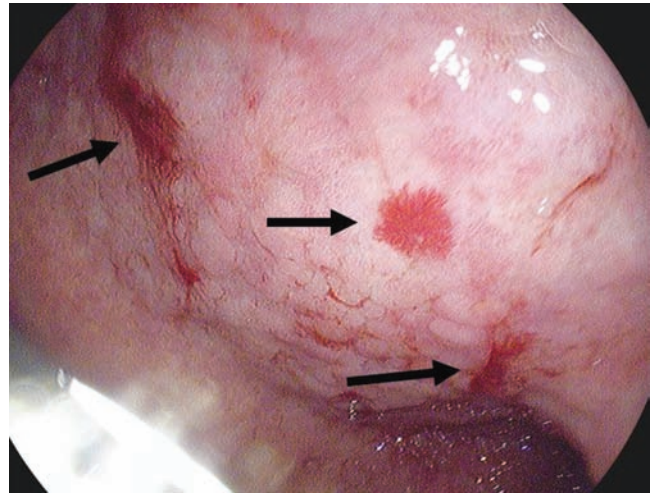
**TABLE 11-6: CAUSES OF LOWER GI BLEEDING**

Causes		Frequency (%)
Colonic bleeding (95%)	Diverticular disease	30–40
	Angiodysplasia	40
	Ischemia	6–18
	Anorectal disease	6–16
	Neoplasia	3–11
	Infectious colitis	3–29
	Polyps	5–13
	Inflammatory bowel disease	2–4
	Radiation proctitis	1–3
	Other	1–9
Unknown	6–23	
Small intestinal bleeding (5%)	Angiodysplasias	
	Neoplasia	
	Meckel's diverticulum	
	Erosions/ulcers	
	Crohn's disease	
	Radiation	

Colonoscopy remains the most useful diagnostic and therapeutic investigation for diverticular bleeding (Fig. 11-13), and can be combined with adrenaline injection, mechanical clipping, or thermal or electrical coagulation to achieve hemostasis. A recent meta-analysis showed embolization to be successful at arresting diverticular bleeding in 85% of patients.<sup>50</sup> Surgery is indicated in refractory bleeding, and a limited resection may also be considered as a management option in patients with multiple episodes of self-limiting bleeding.

**Angiodysplasia.** Angiodysplastic lesions in the intestine are degenerative vascular lesions that develop as a result of progressive dilation of submucosal vessels. Bleeding from these lesions can account for up to 40% of lower GI bleeds.<sup>104</sup> Angiodysplastic lesions are frequently found in the elderly and associated with aortic stenosis and renal failure. The majority of cases present with anemia and cease bleeding spontaneously; however, 50% will rebleed in 5 years. Massive bleeding may occur in up to 15% of cases.

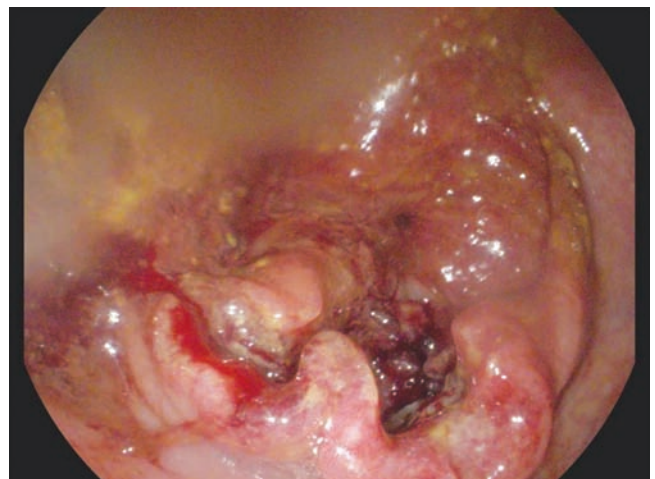In the colon, angiodysplastic lesions are predominantly located in the cecum and ascending colon, particularly in elderly patients. Colonoscopy reveals red stellate lesions with a rim of pale mucosa, while angiographic criteria include early prolonged filling of the draining vein, clusters of small arteries, and a visible vascular tuft (Fig. 11-14). First-line treatment options include injection with intra-arterial vasopressin, selective Gelfoam embolization, endoscopic electrocoagulation, or injection with sclerosing agents. Bleeding refractory to these treatments requires a segmental colectomy, usually in the form of a right hemicolectomy.



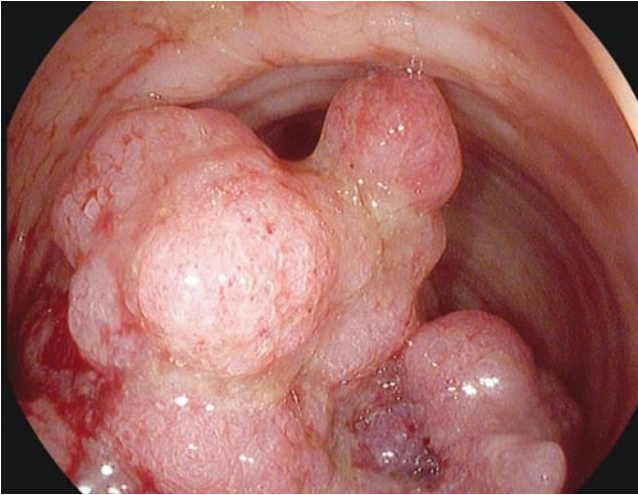
**FIGURE 11-14** Telangiectatic lesions (*black arrows*) characteristic of colonic angiodysplasia, seen on colonoscopy. (Used with permission from Dr Nicola Simmonds, Luton and Dunstable Hospital, UK.)

**Neoplasia.** Neoplasia is a rare cause of lower GI bleeding, accounting for only 2–9% of all hematochezia, but is significant due to the relatively high incidence of colorectal cancer in developed countries.<sup>53</sup> Neoplasia-induced hemorrhage presents as chronic painless bleeding, usually associated with iron deficiency anemia.<sup>53</sup> This is particularly frequent in tumors of the right side of the colon, while tumors of the left side often present with obstructive symptoms and occasionally ulcerate to produce bright red bleeding (Fig. 11-15). Colonic polyps are the cause of bleeding in 5–11% of patients and of anemia in 3–7% of patients; however, this is most often the case in polyps exceeding 1 cm in diameter (Fig. 11-16).<sup>105</sup>

A common cause of lower GI bleeding is postpolypectomy bleeding, where the site may bleed for up to 14 days



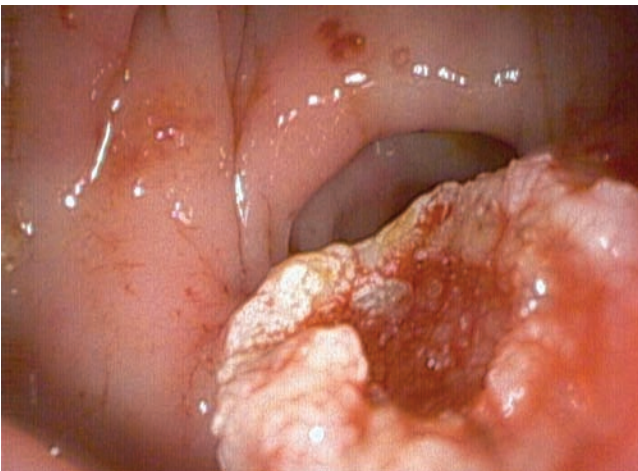
**FIGURE 11-15** Colonoscopic views of a large ulcerated neoplastic lesion. (Used with permission from Dr Nicola Simmonds, Luton and Dunstable Hospital, UK.)



**FIGURE 11-16** Colonoscopic view of a large pedunculated polyp with associated bleeding. (Used with permission from Dr Nicola Simmonds, Luton and Dunstable Hospital, UK.)

following polypectomy (Fig. 11-17). Several factors influence the risk of postpolypectomy bleeding, including size of polyp, inadequate electrocautery, comorbidity, bowel preparation, and experience of the endoscopist.<sup>106</sup> Delayed postpolypectomy bleeding in particular was more likely in large polyps and in polyps in the right side of the colon, and in patients in whom anticoagulant therapy had been resumed within 1 week of polypectomy.<sup>107</sup> Colonic polyps and neoplasia are covered in more detail in Chap. 36.

**Anorectal Disease.** Anorectal pathology that can cause lower GI bleeding includes anal fissures, hemorrhoids, and colorectal neoplasia. Fissures are associated with significant pain on defecation and examination but rarely cause



**FIGURE 11-17** Colonoscopic views of bleeding from the base of a polyp postpolypectomy. (Used with permission from Dr Nicola Simmonds, Luton and Dunstable Hospital, UK.)

large amounts of blood loss. Inspection of the anal margin is usually diagnostic and can be made painless following injection of local anesthetic. Bleeding from fissures usually ceases spontaneously. Conservative management includes the use of stool bulking agents, stool softeners, increased fluid intake, and topical nitroglycerin or diltiazem, which facilitate healing of the fissure by reducing sphincter spasm.

Hemorrhoids account for lower GI bleeding in 2–9% of patients.<sup>105</sup> Fresh red blood is seen on the tissue paper, in the bowl, and around the stool, and is usually painless in nature. Bleeding usually derives from painless internal hemorrhoids and is associated with prolapse of these hemorrhoids, often requiring manual reduction. Management includes stool-bulking agents and increased consumption of fibre and water. Rubber band ligation, injection sclerotherapy, and infrared coagulation may also be employed, and in refractory cases surgical hemorrhoidectomy can be performed.

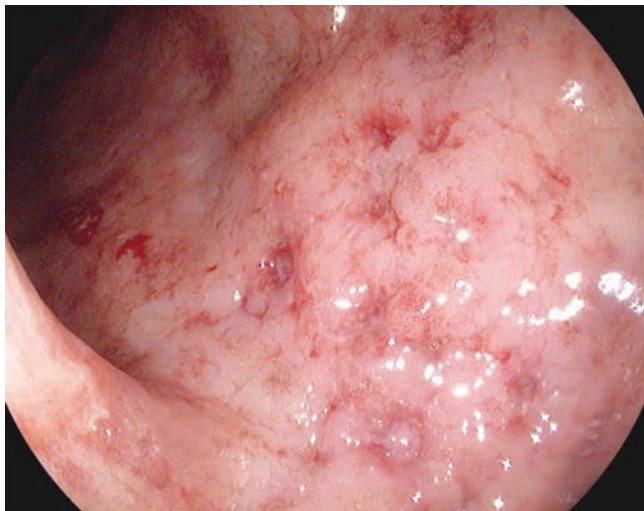
Other rarer anorectal causes of lower GI bleeding include solitary rectal ulcers and anorectal varices. Solitary rectal ulcers are postulated to arise as a result of local ischemia, due to internal rectal prolapse or lack of inhibition of the puborectalis muscle on straining. Bleeding is rare with solitary rectal ulcers but in contrast can be severe with anorectal varices. These arise in patients with portal hypertension and can bleed in 18% of those patients.<sup>108</sup>

An important point to note is that anorectal causes of bleeding such as fissures and hemorrhoids are relatively common incidental findings and should not be considered the only source of bleeding until more proximal colonic neoplasia has been excluded, particularly in the elderly. Benign anorectal conditions are discussed further in Chap. 39.

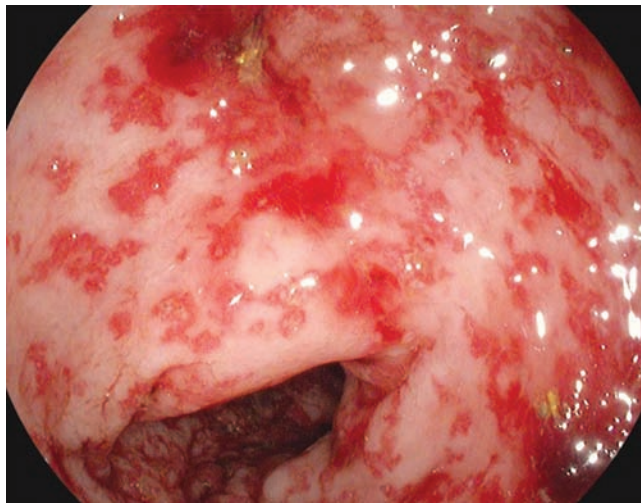**Colitis.** Bleeding associated with colitis may be multifactorial in origin.

**Bleeding From Inflammatory Bowel Disease.** Bleeding from colonic inflammation may be a feature of inflammatory bowel disease. Lower GI hemorrhage has been reported in the majority of patients with ulcerative colitis and in up to a third of patients with Crohn's disease.<sup>109</sup> Most bleeding stops spontaneously, but 35% of patients experience rebleeding.<sup>110</sup> Both ulcerative colitis and Crohn's disease are associated with abdominal pain and increased bowel movements. While ulcerative colitis predominantly involves the mucosal layer and begins at the rectum then spreads proximally, Crohn's disease is associated with transmural thickening of the bowel wall, skip lesions, and strictures, and classically involves the terminal ileum (Fig. 11-18). Both Crohn's disease and ulcerative colitis are diagnosed on endoscopy and managed with 5-aminosalicylic acid (5-ASA) compounds, immunomodulatory agents, steroids, and antibiotics as needed. Surgical therapy for ulcerative colitis is needed if the rare complication of toxic megacolon develops or in the event of refractory life-threatening hemorrhage. Surgery is avoided as much as possible in Crohn's disease because of the natural relapsing and remitting nature of the disease and the tendency of the lesions to affect any region of the GI tract.





**FIGURE 11-18** Colonoscopic view of Crohn's colitis. Note the cobblestone appearance of the mucosa and the associated edema and erythema. (Used with permission from Dr Nicola Simmonds, Luton and Dunstable Hospital, UK.)



**FIGURE 11-19** Colonoscopic view of radiation-induced proctitis, with the characteristic appearance of multiple telangiectasia on a background of otherwise pale mucosa. (Used with permission from Dr Nicola Simmonds, Luton and Dunstable Hospital, UK.)

Crohn's disease and ulcerative colitis are discussed further in Chaps. 33 and 34.

**Infectious Colitis.** Causes of infectious colitis that may cause bloody diarrhea include CMV colitis, *Escherichia coli*, *Shigella*, *Salmonella*, and *Campylobacter*. Patients with infectious colitis typically present with bloody diarrhea with positive stool cultures. CMV colitis typically affects the immunocompromised.

Patients with HIV are particularly at risk of GI bleeding and, because of the immune deficiency, are particularly at risk from opportunistic organisms. Causes of GI bleeding in the colon of HIV-positive patients include CMV colitis, lymphoma, colonic histoplasmosis, Kaposi's sarcoma of the colon, and bacterial colitis, with an overall average mortality of 14%.<sup>111</sup> Colonoscopy and biopsy confirms the diagnosis, and treatment should be commenced as appropriate.

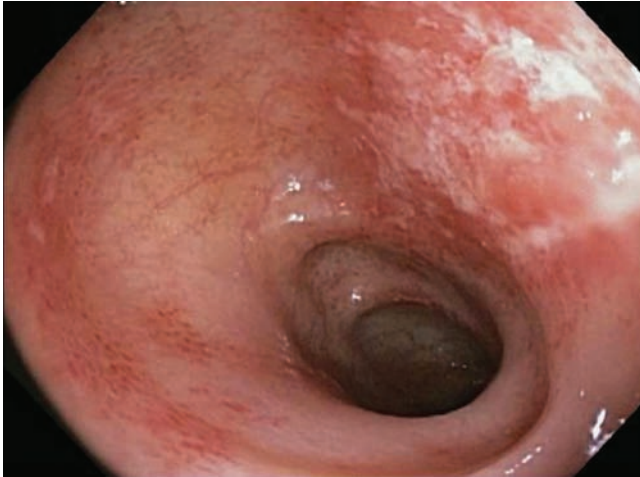
**NSAID-Associated Lower GI Bleeding.** NSAIDs are also able to induce and exacerbate lower GI bleeding. NSAIDs can themselves induce mucosa damage and colonic inflammation, erosions, and ulcers. In addition, they can exacerbate existing colitis and increase the tendency of preexisting lesions such as polyps or angiodysplasia to bleed. NSAID-induced lesions appear as flat, irregularly shaped erosions and ulcerations with otherwise normal mucosa.<sup>53</sup>

**Radiation Proctitis.** Radiation therapy in the pelvic region is another cause of lower GI bleeding, producing a chronic radiation proctopathy due to the neovascularization resulting from radiation-induced endarteritis obliterans. Bleeding occurs in 4–13% of patients receiving radiation therapy for prostatic carcinoma.<sup>112</sup> Patients typically present with bloody diarrhea, cramping pelvic pain, and tenesmus. Endoscopy reveals multiple

telangiectasias on an otherwise pale mucosa and can be coupled with argon plasma coagulation for treatment (Fig. 11-19). Other treatment options include antidiarrheals and hydrocortisone enemas. Ablation with 4% formalin solution may be considered for refractory bleeding.<sup>113</sup>

**Mesenteric Ischemia.** Mesenteric ischemia, or ischemic colitis, results from a sudden reduction in blood flow to the intestine due to either reduced blood pressure or vasoconstriction. This is particularly frequent in elderly patients with a background of cardiovascular disease; other risk factors include recent abdominal vascular surgery, hypercoagulable states, and vasculitis. Patients on inotropes and vasoconstrictors are particularly prone to mesenteric ischemia due to splanchnic vasoconstriction. The splenic flexure of the colon and the rectosigmoid junction are vascular watershed areas and are especially susceptible to ischemia. Patients present with abdominal pain and bloody diarrhoea. The diagnosis is suspected with the identification of a thickened bowel wall on CT and is confirmed on endoscopy showing bleeding, edematous mucosa with a demarcation between ischemic, and normal bowel (Fig. 11-20). Ulcerations may appear on endoscopy in the later stages of disease progression. Despite the self-limiting nature of the disease in most patients, mesenteric ischemia is associated with a high morbidity and mortality.<sup>114</sup> Conservative management is usually employed, with bowel rest, intravenous antibiotics, and cardiovascular support and normalization of the hemodynamic state. In 15% of patients, ischemia is followed by gangrene and perforation, the patient develops sepsis, acidosis, and peritonitis, and requires urgent laparotomy with resection of ischemic bowel and the creation of an end colostomy.<sup>115</sup>





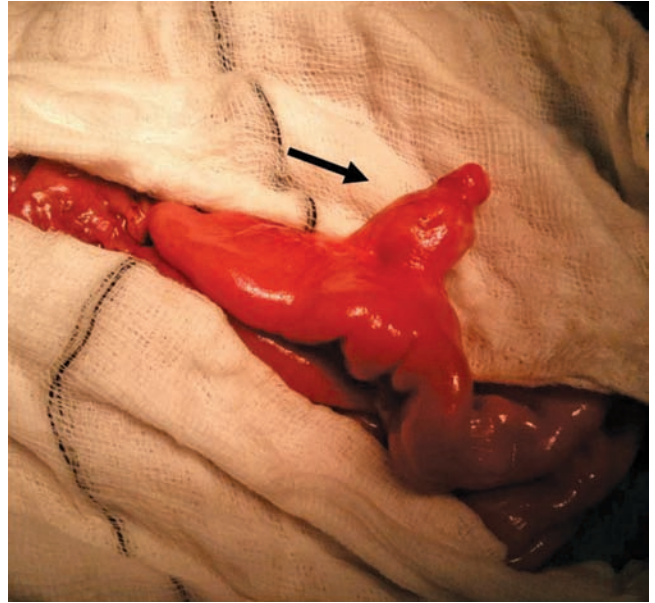
**FIGURE 11-20** Ischemic colitis as viewed on colonoscopy, with evidence of ulceration and submucosal hemorrhage. (Used with permission from Dr Frederick Makrauer MD, Brigham and Women's Hospital, Boston, MA.)

### OBSCURE LOWER GI BLEEDING

Bleeding persisting or recurring after negative esophagogastros-copy and colonoscopy occurs in approximately 5% of cases is termed *obscure bleeding*, often the result of angiodysplastic lesions, Meckel's diverticula, Dieulafoy's lesions, and small bowel neoplasms.<sup>116</sup> Bleeding in these cases may be visible (termed obscure-overt bleeding) or only detected by the presence of guaiac-positive stools (obscure-occult bleeding). Further investigation in the form of capsule enteroscopy, deep enteroscopy, angiography, or red cell labeling is often necessary in these cases.

**Angiodysplasia.** Angiodysplasia is the most common cause of small bowel hemorrhage, accounting for up to 40% of cases in elderly patients and 10% of cases in younger patients. The jejunum is the most common site for these lesions. While angiodysplasias of the small intestine often present with obscure bleeding, patients with bleeding angiodysplastic lesions may also present with occult bleeding and iron deficiency anemia. Unlike colonic angiodysplasia, angiography is rarely helpful in small intestinal angiodysplasia, and deep enteroscopy or capsule enteroscopy are the investigative modalities of choice. Optimal management involves on-table endoscopy with segmental resection of the affected length of small bowel; however, it is important to note that a significant number of patients may spontaneously cease bleeding.<sup>117</sup>

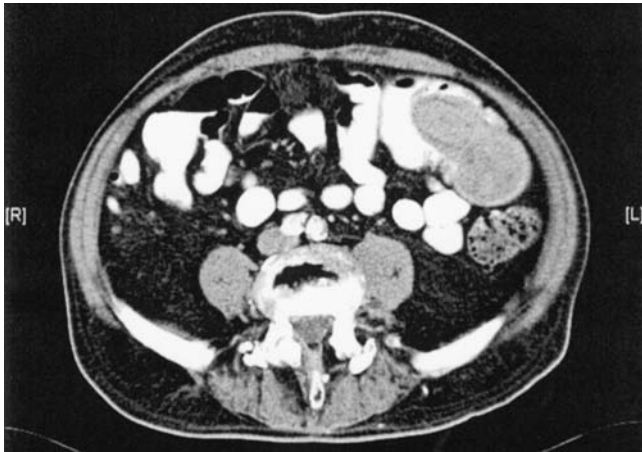
**Meckel's and Other Small Intestinal Diverticula.** A Meckel's diverticulum is the incomplete obliteration of the remnant of the embryonic vitelline duct, the communication between the yolk sac and the fetal gut, and occurs in approximately 2% of the population. Meckel's diverticulum is usually found within 100 cm of the ileocecal valve and usually ranges from 1 to 10 cm in length (Fig. 11-21).<sup>118</sup> Up to 60% of Meckel's diverticula contain heterotopic mucosa,



**FIGURE 11-21** Meckel's diverticulum seen intraoperatively. Meckel's diverticulum (*black arrow*) can be seen on the antimesenteric border of the ileum.

usually of gastric or pancreatic origin. Hemorrhage is a common complication of a Meckel's diverticulum in both adults and children, occurring in 38% of adults and 31% of children, and results from ulceration of the normal mucosa adjacent to the acid-producing heterotopic mucosa.<sup>119</sup> Radionuclide scans may assist in the diagnosis of Meckel's diverticulum but is much less accurate in the adult population compared to the pediatric population. The use of cimetidine, which decreases peptic acid secretion without affecting radionuclide uptake, slows the release of the pertechnetate into the lumen and increases the sensitivity of the scan to 95%.<sup>120</sup> Laparoscopy may be used for the diagnosis as well as the treatment of Meckel's diverticulum. Operative management hinges on removal of the Meckel's diverticulum and associated bands as well as resection of the adjacent affected bowel.

The incidence of nonmeckelian intestinal diverticulosis is low, ranging from 0.06 to 4.6% on autopsy studies.<sup>121</sup> These are particularly common in the elderly but may present in any age group. The pathophysiology of small bowel diverticula is similar to that of colonic diverticula—these are pseudodiverticula involving only mucosa and submucosa, unlike a Meckel's diverticulum that is a true diverticulum. The majority of small intestinal diverticula occur in the jejunum, corresponding with the greatest frequency of vasa rectae in the small intestine. Upper GI contrast series or CT scans may reveal diverticula as contrast-filled sacculations; however, these lack sensitivity. Enteroclysis is a double-contrast radiographic modality involving the use of duodenojejunal intubation and intraluminal distension, allowing even small diverticula to be filled. The lack of cost-effectiveness, however, makes this modality



**FIGURE 11-22** CT image of an ileal adenocarcinoma, obvious as a mass in the left midabdomen.

only appropriate if standard radiographic modalities have proved unsuccessful. The incidence of bleeding from jejunal diverticulosis ranges from 5 to 33%.<sup>121</sup> Enteroscopy (particularly deep enteroscopy) is suitable for diagnosis of diverticula complicated by bleeding, inflammation, or obstruction, but laparotomy remains the gold standard for diagnosis and management, particularly in the unstable patient. Operative management involves resection of the affected segment of small bowel with a primary end-to-end anastomosis. Rarely a large proportion of the bowel is involved (panjejunoileal diverticulosis), and conservative management may be tried to avoid massive small bowel resection and resultant short bowel syndrome. Selective mesenteric angiography and embolization may assist in the control of hemorrhage in these cases.

**Neoplasia.** Although small bowel tumors account for only 5% of all GI tumors, they are the second most common cause of small intestinal bleeding.<sup>122</sup> Patients may present either with melena or with fecal occult blood. Leiomyomas and leiomyosarcomas are the most common tumors to bleed and may bleed briskly due to tumor necrosis and mucosal ulceration. These are highly vascular tumors, and hence angiography has an 86% rate of detection for these lesions. Other tumors in the small intestine include adenocarcinoma, carcinoid, and lymphoma. Tumors can be diagnosed on enteroscopy, small bowel contrast series, or CT (Fig. 11-22), and treatment involves surgical resection of the tumor.

## REFERENCES

1. Peura DA, Lanza FL, Gostout CJ, et al. The American College of Gastroenterology Bleeding Registry: preliminary findings. *Am J Gastroenterol.* 1997;92:924-928.
2. Gralnek IM, Barkun AN, Bardou M. Management of acute bleeding from a peptic ulcer. *New Engl J Med.* 2008;359:928-937.
3. Longstreth GF. Epidemiology and outcome of patients hospitalized with acute lower gastrointestinal hemorrhage: a population-based study. *Am J Gastroenterol.* 1997;92:419-424.
4. Longstreth GF. Epidemiology of hospitalization for acute upper gastrointestinal hemorrhage: a population-based study. *Am J Gastroenterol.* 1995;90:206-210.
5. Yavorski RT, Wong RK, Maydonovitch C, et al. Analysis of 3,294 cases of upper gastrointestinal bleeding in military medical facilities. *Am J Gastroenterol.* 1995;90:568-573.
6. Blatchford O, Davidson LA, Murray WR, et al. Acute upper gastrointestinal haemorrhage in west of Scotland: case ascertainment study. *BMJ.* 1997;315:510-514.
7. Rockall TA, Logan RF, Devlin HB, et al. Incidence of and mortality from acute upper gastrointestinal haemorrhage in the United Kingdom. Steering Committee and members of the National Audit of Acute Upper Gastrointestinal Haemorrhage. *BMJ.* 1995;311:222-226.
8. Vreeburg EM, Snel P, de Bruijne JW, et al. Acute upper gastrointestinal bleeding in the Amsterdam area: incidence, diagnosis, and clinical outcome. *Am J Gastroenterol.* 1997;92:236-243.
9. Paspatis GA, Matrella E, Kapsoritakis A, et al. An epidemiological study of acute upper gastrointestinal bleeding in Crete, Greece. *Eur J Gastroenterol Hepatol.* 2000;12:1215-1220.
10. van Leerdam ME, Vreeburg EM, Rauws EA, et al. Acute upper GI bleeding: did anything change? Time trend analysis of incidence and outcome of acute upper GI bleeding between 1993/1994 and 2000. *Am J Gastroenterol.* 2003;98:1494-1499.
11. Barkun A, Sabbah S, Enns R, et al. The Canadian Registry on Non-variceal Upper Gastrointestinal Bleeding and Endoscopy (RUGBE): endoscopic hemostasis and proton pump inhibition are associated with improved outcomes in a real-life setting. *Am J Gastroenterol.* 2004;99:1238-1246.
12. van Leerdam ME. Epidemiology of acute upper gastrointestinal bleeding. *Best Pract Res.* 2008;22:209-224.
13. Shaheen NJ, Hansen RA, Morgan DR, et al. The burden of gastrointestinal and liver diseases, 2006. *Am J Gastroenterol.* 2006;101:2128-2138.
14. McConnell EJ, Tessier DJ, Wolff BG. Population-based incidence of complicated diverticular disease of the sigmoid colon based on gender and age. *Dis Colon Rectum.* 2003;46:1110-1114.
15. Strate LL, Saltzman JR, Ookubo R, et al. Validation of a clinical prediction rule for severe acute lower intestinal bleeding. *Am J Gastroenterol.* 2005;100:1821-1827.
16. Gilbert DA. Epidemiology of upper gastrointestinal bleeding. *Gastrointest Endosc.* 1990;36:S8-S13.
17. Adam V, Barkun, NA. Estimates of costs of hospital stay for variceal and nonvariceal upper gastrointestinal bleeding in the United States. *Value Health.* 2007;11:1-3.
18. Kollef MH, O'Brien JD, Zuckerman GR, et al. BLEED: a classification tool to predict outcomes in patients with acute upper and lower gastrointestinal hemorrhage. *Crit Care Med.* 1997;25:1125-1132.
19. Afessa B. Triage of patients with acute gastrointestinal bleeding for intensive care unit admission based on risk factors for poor outcome. *J Clin Gastroenterol.* 2000;30:281-285.
20. Lieberman D. Gastrointestinal bleeding: initial management. *Gastroenterol Clin North Am.* 1993;22:723-736.
21. Dall M, Schaffalitzky de Muckadell OB, Lassen AT, et al. An association between selective serotonin reuptake inhibitor use and serious upper gastrointestinal bleeding. *Clin Gastroenterol Hepatol.* 2009;7:1314-1321.
22. Tata LJ, Fortun PJ, Hubbard RB, et al. Does concurrent prescription of selective serotonin reuptake inhibitors and non-steroidal anti-inflammatory drugs substantially increase the risk of upper gastrointestinal bleeding? *Aliment Pharmacol Ther.* 2005;22:175-181.
23. Rubin TA, Murdoch M, Nelson DB. Acute GI bleeding in the setting of supratherapeutic international normalized ratio in patients taking warfarin: endoscopic diagnosis, clinical management, and outcomes. *Gastrointest Endosc.* 2003;58:369-373.
24. Rockey DC. Gastrointestinal bleeding. *Gastroenterol Clin North Am.* 2005;34:581-588.
25. Barkun A, Bardou M, Marshall JK. Consensus recommendations for managing patients with nonvariceal upper gastrointestinal bleeding. *Ann Intern Med.* 2003;139:843-857.
26. Tsoi KK, Ma TK, Sung JJ. Endoscopy for upper gastrointestinal bleeding: how urgent is it? *Nat Rev Gastroenterol Hepatol.* 2009;6:463-469.

27. Davila RE, Rajan E, Adler DG, et al. ASGE Guideline: the role of endoscopy in the patient with lower-GI bleeding. *Gastrointest Endosc.* 2005;62:656–660.
28. Chaudhry V, Hyser MJ, Gracias VH, et al. Colonoscopy: the initial test for acute lower gastrointestinal bleeding. *Am Surg.* 1998;64:723–728.
29. Ohyama T, Sakurai Y, Ito M, et al. Analysis of urgent colonoscopy for lower gastrointestinal tract bleeding. *Digestion.* 2000;61:189–192.
30. Elta GH. Urgent colonoscopy for acute lower-GI bleeding. *Gastrointest Endosc.* 2004;59:402–408.
31. Pennazio M. Capsule endoscopy. *Endoscopy.* 2005;37:1073–1078.
32. Triester SL, Leighton JA, Leontiadis GI, et al. A meta-analysis of the yield of capsule endoscopy compared to other diagnostic modalities in patients with non-stricturing small bowel Crohn's disease. *Am J Gastroenterol.* 2006;101:954–964.
33. Hartmann D, Schmidt H, Bolz G, et al. A prospective two-center study comparing wireless capsule endoscopy with intraoperative enteroscopy in patients with obscure GI bleeding. *Gastrointest Endosc.* 2005;61:826–832.
34. Clarke JO, Giday SA, Magno P, et al. How good is capsule endoscopy for detection of periampullary lesions? Results of a tertiary-referral center. *Gastrointest Endosc.* 2008;68:267–272.
35. Mehdizadeh S, Ross A, Gerson L, et al. What is the learning curve associated with double-balloon enteroscopy? Technical details and early experience in 6 U.S. tertiary care centers. *Gastrointest Endosc.* 2006;64:740–750.
36. Gerson LB. Capsule endoscopy and deep enteroscopy: indications for the practicing clinician. *Gastroenterology.* 2009;137:1197–1201.
37. Mensink PB, Haringsma J, Kucharzik T, et al. Complications of double balloon enteroscopy: a multicenter survey. *Endoscopy.* 2007;39:613–615.
38. May A, Nachbar L, Pohl J, et al. Endoscopic interventions in the small bowel using double balloon enteroscopy: feasibility and limitations. *Am J Gastroenterol.* 2007;102:527–535.
39. Yamamoto H, Kita H, Sunada K, et al. Clinical outcomes of double-balloon endoscopy for the diagnosis and treatment of small-intestinal diseases. *Clin Gastroenterol Hepatol.* 2004;2:1010–1016.
40. Tomimaga K, Iida T, Nakamura Y, et al. Small intestinal perforation of endoscopically unrecognized lesions during peroral single-balloon enteroscopy. *Endoscopy.* 2008;40(suppl 2):E213–E214.
41. Zuckerman DA, Bocchini TP, Birnbaum EH. Massive hemorrhage in the lower gastrointestinal tract in adults: diagnostic imaging and intervention. *AJR Am J Roentgenol.* 1993;161:703–711.
42. Nusbaum M, Baum S. Radiographic demonstration of unknown sites of gastrointestinal bleeding. *Surg Forum.* 1963;14:374–375.
43. Fiorito JJ, Brandt LJ, Kozicky O, et al. The diagnostic yield of superior mesenteric angiography: correlation with the pattern of gastrointestinal bleeding. *Am J Gastroenterol.* 1989;84:878–881.
44. Zuckerman GR, Prakash C. Acute lower intestinal bleeding: part I: clinical presentation and diagnosis. *Gastrointest Endosc.* 1998;48:606–617.
45. Foutch PG. Angiodysplasia of the gastrointestinal tract. *Am J Gastroenterol.* 1993;88:807–818.
46. Kwan V, Bourke MJ, Williams SJ, et al. Argon plasma coagulation in the management of symptomatic gastrointestinal vascular lesions: experience in 100 consecutive patients with long-term follow-up. *Am J Gastroenterol.* 2006;101:58–63.
47. Farrell JJ, Friedman LS. Review article: the management of lower gastrointestinal bleeding. *Aliment Pharmacol Ther.* 2005;21:1281–1298.
48. Loffroy R, Guiu B, Cercueil JP, et al. Refractory bleeding from gastroduodenal ulcers: arterial embolization in high-operative-risk patients. *J Clin Gastroenterol.* 2008;42:361–367.
49. Loffroy R, Guiu B, D'Athis P, et al. Arterial embolotherapy for endoscopically unmanageable acute gastroduodenal hemorrhage: predictors of early rebleeding. *Clin Gastroenterol Hepatol.* 2009;7:515–523.
50. Khanna A, Ognibene SJ, Koniaris LG. Embolization as first-line therapy for diverticulosis-related massive lower gastrointestinal bleeding: evidence from a meta-analysis. *J Gastrointest Surg.* 2005;9:343–352.
51. Browder W, Cerise EJ, Litwin MS. Impact of emergency angiography in massive lower gastrointestinal bleeding. *Ann Surg.* 1986;204:530–536.
52. Vernava AM, 3rd, Moore BA, Longo WE, et al. Lower gastrointestinal bleeding. *Dis Colon Rectum.* 1997;40:846–858.
53. Barnert J, Messmann H. Diagnosis and management of lower gastrointestinal bleeding. *Nat Rev Gastroenterol Hepatol.* 2009;6:637–646.
54. Lim CH, Vani D, Shah SG, et al. The outcome of suspected upper gastrointestinal bleeding with 24-hour access to upper gastrointestinal endoscopy: a prospective cohort study. *Endoscopy.* 2006;38:581–585.
55. Viviane A, Alan BN. Estimates of costs of hospital stay for variceal and nonvariceal upper gastrointestinal bleeding in the United States. *Value Health.* 2008;11:1–3.
56. Ohmann C, Imhof M, Ruppert C, et al. Time-trends in the epidemiology of peptic ulcer bleeding. *Scand J Gastroenterol.* 2005;40:914–920.
57. Rockall TA, Logan RF, Devlin HB, et al. Risk assessment after acute upper gastrointestinal haemorrhage. *Gut.* 1996;38:316–321.
58. Blatchford O, Murray WR, Blatchford M. A risk score to predict need for treatment for upper-gastrointestinal haemorrhage. *Lancet.* 2000;356:1318–1321.
59. Forrest JA, Finlayson ND, Shearman DJ. Endoscopy in gastrointestinal bleeding. *Lancet.* 1974;2:394–397.
60. Hippisley-Cox J, Coupland C. Risk of myocardial infarction in patients taking cyclo-oxygenase-2 inhibitors or conventional non-steroidal anti-inflammatory drugs: population-based nested case-control analysis. *BMJ.* 2005;330:1366.
61. Gisbert JP, Khorrani S, Carballo F, et al. *H. pylori* eradication therapy vs. antisecretory non-eradication therapy (with or without long-term maintenance antisecretory therapy) for the prevention of recurrent bleeding from peptic ulcer. *Cochrane Database Syst Rev.* 2003:CD004062.
62. Bardou M, Toubouti Y, Benhaberou-Brun D, et al. Meta-analysis: proton-pump inhibition in high-risk patients with acute peptic ulcer bleeding. *Aliment Pharmacol Ther.* 2005;21:677–686.
63. Dorward S, Sreedharan A, Leontiadis GI, et al. Proton pump inhibitor treatment initiated prior to endoscopic diagnosis in upper gastrointestinal bleeding. *Cochrane Database Syst Rev.* 2006:CD005415.
64. Adler DG, Leighton JA, Davila RE, et al. ASGE guideline: The role of endoscopy in acute non-variceal upper-GI hemorrhage. *Gastrointest Endosc.* 2004;60:497–504.
65. Cook DJ, Guyatt GH, Salena BJ, et al. Endoscopic therapy for acute nonvariceal upper gastrointestinal hemorrhage: a meta-analysis. *Gastroenterology.* 1992;102:139–148.
66. Calver X, Vergara M, Brullet E, et al. Addition of a second endoscopic treatment following epinephrine injection improves outcome in high-risk bleeding ulcers. *Gastroenterology.* 2004;126:441–450.
67. Chung IK, Kim EJ, Lee MS, et al. Endoscopic factors predisposing to rebleeding following endoscopic hemostasis in bleeding peptic ulcers. *Endoscopy.* 2001;33:969–975.
68. Adler DG, Adler AL, Nolte T, et al. Complications of urgent and emergency endoscopy in patients with GI bleeding as a function of time. *Am J Gastroenterol.* 2001;96:3452–3424.
69. Spiegel BM, Ofman JJ, Woods K, et al. Minimizing recurrent peptic ulcer hemorrhage after endoscopic hemostasis: the cost-effectiveness of competing strategies. *Am J Gastroenterol.* 2003;98:86–97.
70. Lau JY, Sung JJ, Lam YH, et al. Endoscopic retreatment compared with surgery in patients with recurrent bleeding after initial endoscopic control of bleeding ulcers. *Am J Gastroenterol.* 1999;340:751–756.
71. Mallory G, Weiss S. Hemorrhages from lacerations of the cardiac orifice of the stomach due to vomiting. *Am J Med Sci.* 1929;178:506–515.
72. Michel L, Serrano A, Malt RA. Mallory-Weiss syndrome. Evolution of diagnostic and therapeutic patterns over two decades. *Ann Surg.* 1980;192:716–721.
73. Watts HD. Lesions brought on by vomiting: the effect of hiatus hernia of the site of injury. *Gastroenterology.* 1976;71:683–688.
74. Sugawa C, Benishek D, Walt AJ. Mallory-Weiss syndrome. A study of 224 patients. *Am J Surg.* 1983;145:30–33.
75. Knauer CM. Mallory-Weiss syndrome. Characterization of 75 Mallory-Weiss lacerations in 528 patients with upper gastrointestinal hemorrhage. *Gastroenterology.* 1976;71:5–8.
76. Cook DJ, Griffith LE, Walter SD, et al. The attributable mortality and length of intensive care unit stay of clinically important gastrointestinal bleeding in critically ill patients. *Crit Care.* 2001;5:368–375.
77. Wilcox CM. Esophageal disease in the acquired immunodeficiency syndrome: etiology, diagnosis, and management. *Am J Gastroenterol.* 1992;92:412–4121.
78. Regula J, Wronska E, Pachlewski J. Vascular lesions of the gastrointestinal tract. *West Pract Res.* 2008;22:313–328.
79. Chung IK, Kim EJ, Lee MS, et al. Bleeding Dieulafoy's lesions and the choice of endoscopic method: comparing the hemostatic efficacy of mechanical and injection methods. *Gastrointest Endosc.* 2000;52:721–724.



80. Park CH, Joo YE, Kim HS, et al. A prospective, randomized trial of endoscopic band ligation versus endoscopic hemoclip placement for bleeding gastric Dieulafoy's lesions. *Endoscopy*. 2004;36:677-681.
81. Roman S, Saurin JC, Dumortier J, et al. Tolerance and efficacy of argon plasma coagulation for controlling bleeding in patients with typical and atypical manifestations of watermelon stomach. *Endoscopy*. 2003;35:1024-1028.
82. Antoniou GA, Koutsias S, Antoniou SA, et al. Outcome after endovascular stent graft repair of aortoenteric fistula: a systematic review. *J Vasc Surg*. 2009;49:782-789.
83. Risti B, Marincek B, Jost R, et al. Hemosuccus pancreaticus as a source of obscure upper gastrointestinal bleeding: three cases and literature review. *Am J Gastroenterol*. 1995;90:1878-1880.
84. Garcia-Tsao G, Sanyal AJ, Grace ND, et al. Prevention and management of gastroesophageal varices and variceal hemorrhage in cirrhosis. *Am J Gastroenterol*. 2007;102:2086-2102.
85. Casado M, Bosch J, Garcia-Pagan JC, et al. Clinical events after transjugular intrahepatic portosystemic shunt: correlation with hemodynamic findings. *Gastroenterology*. 1998;114:1296-1303.
86. Kim T, Shijo H, Kokawa H, et al. Risk factors for hemorrhage from gastric fundal varices. *Hepatology*. 1997;25:307-312.
87. de Franchis R, Pascal JP, Ancona E, et al. Definitions, methodology and therapeutic strategies in portal hypertension. A Consensus Development Workshop, Baveno, Lake Maggiore, Italy, April 5 and 6, 1990. *J Hepatol*. 1992;15:256-261.
88. de Franchis R. Evolving consensus in portal hypertension. Report of the Baveno IV consensus workshop on methodology of diagnosis and therapy in portal hypertension. *J Hepatol*. 2005;43:167-176.
89. Villanueva C, Colomo A, Aracil C, et al. Current endoscopic therapy of variceal bleeding. *Best Pract Res*. 2008;22:261-278.
90. Garcia-Tsao G, Sanyal AJ, Grace ND, et al. Prevention and management of gastroesophageal varices and variceal hemorrhage in cirrhosis. *Hepatology*. 2007;46:922-938.
91. Heider TR, Azeem S, Galanko JA, et al. The natural history of pancreatitis-induced splenic vein thrombosis. *Ann Surg*. 2004;239:876-880; discussion 80-82.
92. Prediction of the first variceal hemorrhage in patients with cirrhosis of the liver and esophageal varices. A prospective multicenter study. *New Engl J Med*. 1988;319:983-989.
93. Garcia-Pagan JC, Feu F, Bosch J, et al. Propranolol compared with propranolol plus isosorbide-5-mononitrate for portal hypertension in cirrhosis. A randomized controlled study. *Ann Intern Med*. 1991;114:869-873.
94. Garcia-Pagan JC, Villanueva C, Albillos A, et al. Nadolol plus isosorbide mononitrate alone or associated with band ligation in the prevention of recurrent bleeding: a multicentre randomised controlled trial. *Gut*. 2009;58:1144-1150.
95. Owen AR, Stanley AJ, Vijayanathan A, et al. The transjugular intrahepatic portosystemic shunt (TIPS). *Clin Radiol*. 2009;64:664-674.
96. Azoulay D, Castaing D, Majno P, et al. Salvage transjugular intrahepatic portosystemic shunt for uncontrolled variceal bleeding in patients with decompensated cirrhosis. *J Hepatol*. 2001;35:590-597.
97. Spina GP, Henderson JM, Rikkers LF, et al. Distal spleno-renal shunt versus endoscopic sclerotherapy in the prevention of variceal rebleeding. A meta-analysis of 4 randomized clinical trials. *J Hepatol*. 1992;16:338-345.
98. Henderson JM, Boyer TD, Kutner MH, et al. Distal spleno-renal shunt versus transjugular intrahepatic portal systematic shunt for variceal bleeding: a randomized trial. *Gastroenterology*. 2006;130:1643-1651.
99. Finne CI. The aggressive management of serious lower gastrointestinal bleeding. *Probl Gen Surg*. 1992;9:597.
100. Parks TG. Natural history of diverticular disease of the colon. A review of 521 cases. *Br Med J*. 1969;4:639-642.
101. Hughes LE. Postmortem survey of diverticular disease of the colon. I. Diverticulosis and diverticulitis. *Gut*. 1969;10:336-344.
102. Nakada I, Ubukata H, Goto Y, et al. Diverticular disease of the colon at a regional general hospital in Japan. *Dis Colon Rectum*. 1995;38:755-759.
103. Ure T, Vernava, AM, Longo, WE. Diverticular bleeding. *Semin Col Rect Surg*. 1994;5:32.
104. Strate LL. Lower GI bleeding: epidemiology and diagnosis. *Gastroenterol Clin North Am*. 2005;34:643-664.
105. Zuckerman GR, Prakash C. Acute lower intestinal bleeding. Part II: etiology, therapy, and outcomes. *Gastrointest Endosc*. 1999;49:228-238.
106. Kim HS, Kim TL, Kim WH, et al. Risk factors for immediate postpolypectomy bleeding of the colon: a multicenter study. *Am J Gastroenterol*. 2006;101:1333-1341.
107. Sawhney MS, Salfiti N, Nelson DB, et al. Risk factors for severe delayed postpolypectomy bleeding. *Endoscopy*. 2008;40:115-119.
108. Ganguly S, Sarin SK, Bhatia V, et al. The prevalence and spectrum of colonic lesions in patients with cirrhotic and noncirrhotic portal hypertension. *Hepatology*. 1995;21:1226-1231.
109. Pardi DS, Loftus EV, Jr, Tremaine WJ, et al. Acute major gastrointestinal hemorrhage in inflammatory bowel disease. *Gastrointest Endosc*. 1999;49:153-157.
110. Robert JR, Sachar DB, Greenstein AJ. Severe gastrointestinal hemorrhage in Crohn's disease. *Ann Surg*. 1991;213:207-211.
111. Bini EJ, Weinschel EH, Falkenstein DB. Risk factors for recurrent bleeding and mortality in human immunodeficiency virus infected patients with acute lower GI hemorrhage. *Gastrointest Endosc*. 1999;49:748-753.
112. Teshima T, Hanks GE, Hanlon AL, et al. Rectal bleeding after conformal 3D treatment of prostate cancer: time to occurrence, response to treatment and duration of morbidity. *Int J Radiat Oncol Biol Phys*. 1997;39:77-83.
113. Saclarides TJ, King DG, Franklin JL, et al. Formalin instillation for refractory radiation-induced hemorrhagic proctitis. Report of 16 patients. *Dis Colon Rectum*. 1996;39:196-199.
114. Strate LL, Ayanian JZ, Kotler G, et al. Risk factors for mortality in lower intestinal bleeding. *Clin Gastroenterol Hepatol*. 2008;6:1004-1010; quiz 955.
115. Walker AM, Bohn RL, Cali C, et al. Risk factors for colon ischemia. *Am J Gastroenterol*. 2004;99:1333-1337.
116. Singh V, Alexander JA. The evaluation and management of obscure and occult gastrointestinal bleeding. *Abdom Imaging*. 2009;34:311-319.
117. Lewis BS, Salomon P, Rivera-MacMurray S, et al. Does hormonal therapy have any benefit for bleeding angiodysplasia? *J Clin Gastroenterol*. 1992;15:99-103.
118. Mackey WC, Dineen P. A fifty year experience with Meckel's diverticulum. *Surg Gynecol Obstet*. 1983;156:56-64.
119. Park JJ, Wolff BG, Tollefson MK, et al. Meckel diverticulum: the Mayo Clinic experience with 1476 patients (1950-2002). *Ann Surg*. 2005;241:529-533.
120. Rossi P, Gourtsoyiannis N, Bezzi M, et al. Meckel's diverticulum: imaging diagnosis. *AJR Am J Roentgenol*. 1996;166:567-573.
121. Makris K, Tsiotos GG, Stafyla V, et al. Small intestinal nonmeckelian diverticulosis. *J Clin Gastroenterol*. 2009;43:201-207.
122. Rossini FP, Risio M, Pennazio M. Small bowel tumors and polyposis syndromes. *Gastroenterol Clin North Am*. 1999;9:93-114.



# MANAGEMENT OF ABDOMINAL TRAUMA

L. D. Britt • Robert A. Maxwell

## MANAGEMENT OF PENETRATING ABDOMINAL TRAUMA

### Introduction

The management of penetrating abdominal trauma parallels the evolution of diagnostic modalities. In the 19th century, expectant (observation) management was the approach of choice worldwide. In 1880, Paule Recluse, a French surgeon, advocated supportive care only for penetrating abdominal injuries. Sir William McCormick, chief Army Surgeon during this same period, coined the McCormick aphorism regarding the management of gunshot wounds to the abdomen that stated “if a man undergoes surgery after being shot he dies and lives if left in peace.” Even with a mortality rate that was exceedingly high, such dogma was the standard of care during this era for any penetrating abdominal trauma. This management approach was, unfortunately, applied when President James A. Garfield sustained a gunshot wound to the abdomen. The observational management, called the “Garfield Death Watch,” by the President’s medical team resulted in the demise of President Garfield. There were very few voices that challenged this surgical dogma of nonoperative management, with Dr Marion Simms, a prominent Southern surgeon who became president of the American Medical Association, being the most vocal.<sup>1</sup> With predictably overwhelming morbidity/mortality associated with these injuries, it became apparent that a more aggressive, interventional approach was needed for penetrating injuries to the abdomen, and, as a result, mandatory exploration, or celiotomy, became the prevailing management option of choice and essentially the standard of care.

Shafton and Nance’s landmark articles, which emphasized surgical judgment in the management of penetrating wounds of the abdomen, changed the approach to penetrating abdominal injuries from mandatory celiotomy to a more

selective management.<sup>2,3</sup> Enhanced diagnostic imaging has greatly assisted in making the nonoperative/selective management a more reliable and acceptable treatment option in penetrating abdominal trauma.

### Initial Trauma Management

Before focusing on the specific anatomical region where there is an obvious traumatic injury, an initial assessment of the entire patient is imperative. The concept of initial assessment includes the following components: (1) rapid primary survey, (2) resuscitation, (3) detailed secondary survey (evaluation), and (4) reevaluation. Such an assessment is the cornerstone of the Advanced Trauma Life Support (ATLS) program.<sup>4</sup> Integrated into primary and secondary surveys are specific adjuncts. Such adjuncts include the application of electrocardiographic monitoring and the utilization of other monitoring modalities such as arterial blood gas determination, pulse oximetry, the measurement of ventilatory rate and blood pressure, insertion of urinary and/or gastric catheters, and incorporating necessary x-rays and other diagnostic studies, when applicable, such as focused abdominal sonography for trauma (FAST) examination, other diagnostic studies (plain radiography of the spine/chest/pelvis and computed tomography [CT]), and diagnostic peritoneal lavage (DPL). Determining the right diagnostic study depends on the mechanism of injury and the hemodynamic status of the patient.

The focus of the primary survey is to both identify and expeditiously address immediate life-threatening injuries. Only after the primary survey is completed (including the initiation of resuscitation) and hemodynamic stability is addressed, should the secondary survey be conducted, which entails a head-to-toe (and back-to-front) physical examination, along with a more detailed history.

## PRIMARY SURVEY

Only the emergency care disciplines of medicine have a two-tier approach to their initial assessment of the patient, with primary and secondary surveys being integral components. As highlighted previously, the primary survey is designed to quickly detect life-threatening injuries.

Therefore, a universal approach has been established with the following prioritization:

- Airway maintenance (with protection of the cervical spine)
- Breathing (ventilation)
- Circulation (including hemorrhage control)
- Disability (neurologic status)
- Exposure/environmental control

Such a systematic and methodical approach (better known as the ABCDEs of the initial assessment) greatly assists the surgical/medical team in the timely management of those injuries that could result in a poor outcome.

**A. Airway assessment management (along with cervical spine protection):** Because loss of a secure airway could be lethal within 4 minutes, airway assessment/management always has the highest priority during the primary survey of the initial assessment of any injured patient, irrespective of the mechanism of injury or the anatomical wound. The chin lift and jaw thrust maneuvers are occasionally helpful in attempting to secure a patient airway. However, in the trauma setting, the airway management of choice is often translaryngeal, endotracheal intubation. If this cannot be achieved due to an upper airway obstruction or some technical difficulty, a surgical airway (needle or surgical cricothyroidectomy) should be the alternative approach. No other management can take precedence over obtaining an appropriate airway control. Until adequate and sustained oxygenation can be documented, administration of 100% oxygen is required.

**B. Breathing (ventilation assessment):** An airway can be adequately established and optimal ventilation still not be achieved. For example, such is the case when there is an associated tension pneumothorax (other examples include a tension hemothorax, open pneumothorax, or a large flail chest wall segment). Worsening oxygenation and an adverse outcome would ensue unless such problems are expeditiously addressed. Therefore, assessment of breathing is imperative, even when there is an established and secure airway. A patent airway but poor gas exchange will still result in a poor outcome. Tachypnea, absent breath sounds, percussion hyperresonance, distended neck veins, and/or tracheal deviation are all consistent with inadequate gas exchange. Decompression of the pleural space with a needle/chest tube insertion should be the initial intervention for a pneumo-/hemothorax. A large flail chest, with underlying pulmonary contusion, will likely require endotracheal intubation and the administration of positive-pressure ventilation.

**C. Circulation assessment (adequacy of perfusion management):** The most important initial step in

determining adequacy of circulatory perfusion is to quickly identify and control any active source of bleeding, along with restoration of the patient's blood volume with crystalloid fluid resuscitation and blood products, if required. Decreased levels of consciousness, pale skin color, slow (or nonexistent) capillary refill, cool body temperature, tachycardia, or diminished urinary output are all suggestive of inadequate tissue perfusion. Optimal resuscitation requires the insertion of two large-bore intravenous lines and infusion of crystalloid fluids (warmed). Adult patients who are severely compromised will require a fluid bolus (2 L of Ringer's lactate or saline solution). Children should receive a 20 mL/kg fluid bolus. Blood and blood products are administered as required. Along with the initiation of fluid resuscitation, emphasis needs to remain on identifying the source of active bleeding and stopping the hemorrhage. For a patient in hemorrhagic shock, the source of blood loss will be an open wound with profuse bleeding, or within the thoracic or abdominal cavity, or from an associated pelvic fracture with venous or arterial injuries. Disposition (operating room, angiography suite, etc) of the patient depends on the site of bleeding. For example, a FAST assessment that documents substantial blood loss in the abdominal cavity in a patient who is hemodynamically labile dictates an emergency celiotomy. However, if the quick diagnostic workup of a hemodynamically unstable patient who has sustained blunt trauma demonstrates no blood loss in the abdomen or chest, the source of hemorrhage could be from a pelvic injury that would likely necessitate angiography/embolization if external stabilization (eg, a commercial wrap or binder) of the pelvic fracture fails to stop the bleeding. Profuse bleeding from open wounds can usually be addressed by application of direct pressure or occasionally ligating torn arterial vessels that can easily be identified and isolated.

**D. Disability assessment/management:** Only a baseline neurologic examination is required when performing the primary survey in order to determine neurologic function deterioration that might necessitate surgical intervention. It is inappropriate to attempt a detailed neurologic examination initially. Such a comprehensive examination should be done during the secondary survey or evaluation. This baseline neurologic assessment could be the determination of the Glasgow coma scale (GCS), with an emphasis on the best motor or verbal response, and eye opening. An alternative approach for a rapid neurologic evaluation would be the assessment of the pupillary size and reaction, along with establishing the patient's level of consciousness (alert, responds to visual stimuli, responds only to painful stimuli or unresponsive to all stimuli). The caveat that must be highlighted is the fact that neurologic deterioration can occur rapidly and that a patient with a devastating injury can have a lucid interval (eg, epidural hematoma). Because the leading causes of secondary brain injury are hypoxia and hypotension, adequate cerebral oxygenation and perfusion are essential in the management of a patient with neurologic injury.

**E. Exposure/environmental control:** In order to perform a thorough examination of a patient, he/she must be completely undressed. This often requires cutting off the garments to safely expedite such exposure. However, care must be taken to keep the patient from becoming hypothermic. Adjusting the room temperature and infusing warmed intravenous fluids can help establish an optimal environment for the patient.

## SECONDARY SURVEY

The secondary survey should not be done until the primary survey has been completed and resuscitation initiated, with some evidence of normalization of vital signs. It is imperative that this head-to-toe evaluation be performed in a detailed manner in order to detect less obvious or occult injuries. This is particularly important in the unevaluable (eg, head injury or severely intoxicated) patient. The physical examination should include a detailed assessment of every anatomical region, including the following:

- Head
- Maxillofacial
- Neck (including cervical spine)
- Chest
- Abdomen
- Perineum (including the rectum and genital organs)
- Back (including the remaining spinal column)
- Extremities (musculoskeletal)

A full neurologic examination needs to be performed, along with an estimate of the GCS score if one was not done during the primary survey. The secondary survey and the utilization (when applicable) of the armamentarium of diagnostic adjuncts, previously mentioned, will allow detection of more occult or subtle injuries that could, if not found, account for significant morbidity and mortality. When possible, the secondary survey should include a history of the mechanism of injury, along with vital information regarding allergies, medications, past illnesses, recent food intake, and pertinent events related to the injury.

It cannot be overemphasized that frequent reevaluation of the injured patient is necessary in order to detect any deterioration in the patient status. This sometimes requires repeating both the primary and secondary surveys.

## Topography and Clinical Anatomy

The *abdomen* is often defined as a component of the torso that has for its superior boundary the left and right hemidiaphragm, which can ascend to the level of the nipples (fourth intercostal space) on the frontal aspect and to the tip of the scapula in the back. The inferior boundary of the abdomen is the pelvic floor. For clinical purposes, it is helpful to further divide the abdomen into four areas: (1) anterior abdomen (below the anterior costal margins to above the inguinal ligaments

and anterior to the anterior axillary lines), (2) intrathoracic abdomen (from the nipple or the tips of the scapula to the inferior costal margins), (3) flank (inferior scapular tip to the iliac crest and between the posterior and anterior axillary lines), and (4) back (below the tips of the scapula to the iliac crest and between the posterior axillary lines). The majority of the digestive system and urinary tract, along with a substantial network of vasculature and nerves, are contained within the abdominal cavity. A viscera-rich region, the abdomen can often be the harbinger for occult injuries as a result of penetrating wounds, particularly in the unevaluable abdomen as the result of a patient's compromised sensorium.

## Mechanism of Injury

In addition to the hemodynamic status of the patient, important variables in the decision making regarding management of penetrating abdominal injuries are both the mechanism and location of injury (see Physical Examination). The kinetic energy generated by hand-driven weapons, such as knives and sharp objects, is substantially less than what is caused by firearms. Although not always evident, it is important to know the length and width of the wound along with the depth of penetration of the weapon or device that caused the stab injury. For example, a stab injury usually results in a long, more shallow wound that does not penetrate the peritoneum. Local wound management is the primary focus for these injuries with no concern for any potential intra-abdominal injury.<sup>5</sup> Although there are some stab wounds that do not penetrate the peritoneal cavity, such cannot be assumed without some formal determination or serial abdominal examinations to assess for worsening abdominal tenderness or the development of peritoneal signs.

There is notable variability among the full spectrum of firearms in the civilian setting, with this arsenal, including mostly handguns, rifles, shotguns, and air guns. The kinetic energy, which correlates with the wounding potential, is dependant on mass and velocity ( $KE = 1/2 mv^2$ ). Therefore, the higher the velocity, the greater the wounding potential.<sup>6</sup> Because the barrel is longer in a rifle than a handgun, the bullet has more time to accelerate—generating a much higher velocity. A high-velocity missile is propelled at 2500 ft/s or greater. Air guns usually fire pellets (eg, BBs) and are associated with a lower velocity and wounding potential. Shotguns fire a cluster of metal pellets, called a shot. The pellets separate after leaving the barrel, with a rapidly decreasing velocity. At a distance, the wounding potential is diminished. However, at close range (<15 ft), because of the increase in aggregate mass, the tissue destruction is similar to a high-velocity missile injury.

Although each injury should be handled on an individual basis, there are general principles that will provide some guidance in the management of penetrating injuries based on mechanism of injury. Regarding stab wounds, approximately one-third of the wounds do not penetrate the peritoneum and only half of those that do penetrate require

operative intervention. The number of organs injured and the intra-abdominal sepsis complication rate are significantly less than wounds caused by gunshots.<sup>7,8</sup>

## Physical Examination

A complete and thorough physical examination of the entire body is essential in the management of penetrating abdominal injury. There are some findings (Table 12-1) on physical examination that are absolute indications for operative intervention. The components of the physical examination should include careful inspection, palpation, and auscultation.

In addition to being able to determine the location, extent, and the number of wounds, inspection can sometimes determine the trajectory of the missile or other wounding agent and, consequently, guide management decisions. For example, a patient with a documented, superficial tangential gunshot wound (low-velocity), with no other remarkable physical findings, would likely be managed expectantly (observation). However, if a penetrating abdominal injury results in a patient presenting with an evisceration, exploratory laparotomy would be the management option of choice. Palpation will enable the examiner to elicit abdominal tenderness or frank peritoneal signs, along with being able to detect abdominal distention and rigidity. On occasion, missiles can be palpated lodged in the soft tissue. Unless in a controlled and sterile setting such as the operative theatre, probing of a wound should be avoided. Auscultation is also an important component of the physical examination. It can help determine diminished or absent bowel sounds that could be suggestive of evolving peritonitis. Also, auscultation could detect a trauma-induced bruit, suggestive of a vascular injury.

The examiner has to be keenly aware of the fact that there are situations in which the abdominal examination will be unreliable due to possible spinal cord injury or a patient's altered mental state.

## Diagnostic Studies

Even with penetrating injuries, the abdomen is notorious for hiding its secrets—occult injuries. Access to an extensive

diagnostic armamentarium is imperative in the optimal management of these injuries. Strongly advocated by some for abdominal stab wounds, local wound exploration has the advantage of allowing the patient to be discharged from the trauma bay or emergency department, if surgical exploration of the wound fails to demonstrate penetration of the posterior fascia and peritoneum. However, if the patient has to go to the operating room for other injuries, the local wound exploration should be done in the surgical suite that will have better lighting and a more sterile environment. A positive finding during local wound exploration dictates a formal laparotomy or laparoscopy. However, even with local wound exploration as a guide, the nontherapeutic laparotomy rate can be high, given that only a third of the patients with stab wounds to the anterior abdomen require therapeutic laparotomies.<sup>9,10</sup> In the patient who has an evaluable abdomen, serial abdominal examinations would be an acceptable alternative to local wound exploration, in order to determine the need for operative intervention. Local wound exploration should only be done for stab wounds to the anterior abdomen. Such an approach is potentially too hazardous for thoracoabdominal penetrating injuries and back/flank wounds. Plain radiography (abdomen/pelvis/chest) can be pivotal in documenting the presence of missiles and other foreign bodies and determining the trajectory of the injury tract, particularly for wounds from firearms. Also, the presence of free air might be confirmed by plain radiography. Unless there is concern about a retained broken blade, there is little utility for plain radiography for stab injuries.<sup>11</sup> The DPL developed by David Root in 1965, was a major advance in the care of the hemodynamically labile patient who sustained blunt trauma.<sup>12</sup> With the advent of FAST and rapid CT, DPL has very limited utility. DPL has never had a broad appeal in the diagnostic evaluation of penetrating abdominal wounds. Although some have advocated its use with tangential wounds of the abdominal wall, the technique has failed to receive widespread support.<sup>13</sup> Its reliability in detecting clinically significant injuries sustained as a result of penetrating abdominal injuries has been a prevailing concern.<sup>14-16</sup> The reported sensitivity and specificity of DPL for abdominal stab wounds are 59–96% and 78–98%, respectively.<sup>17</sup> Also, DPL is a poor diagnostic modality for detecting diaphragmatic and retroperitoneal injuries.

Diagnostic imaging has had the greatest impact in changing the face of trauma management with CT taking the lead in this area. Its ubiquitous presence in the management of blunt abdominal trauma is well established. However, it is becoming an important diagnostic study in the evaluation of penetrating abdominal injuries. In addition to its excellent sensitivity in detecting a pneumoperitoneum, free fluid, and abdominal wall/peritoneal penetration, CT is helpful in identifying the tract of the penetrating agent. Hauser et al recommended the use of “triple contrast” CT in the assessment of penetrating back and flank injuries.<sup>18</sup> CT scan evaluation is an essential diagnostic tool in the increasing advocacy for selective management of abdominal gunshot wounds obviating the need for mandatory surgical exploration.<sup>19</sup> However, there still remain two major limitations of



**TABLE 12-1: ABSOLUTE INDICATIONS FOR EXPLORATORY LAPAROTOMY IN PENETRATING ABDOMINAL INJURIES**

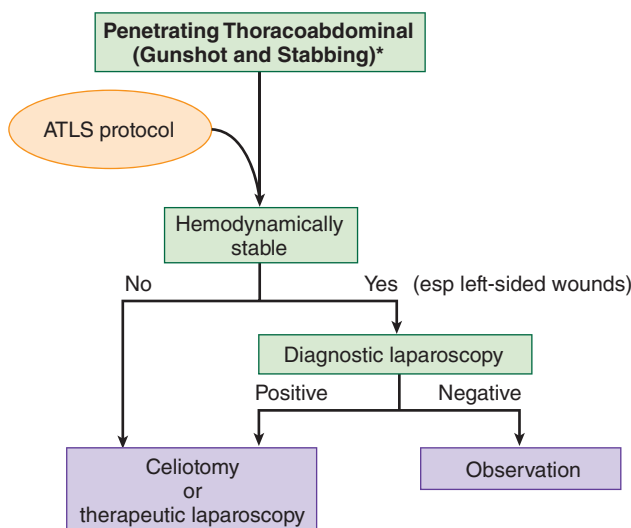
- A. Peritonitis
- B. Evisceration
- C. Impaled object
- D. Hemodynamic instability
- E. Associated bleeding from natural orifice
- F. Documented pneumoperitoneum



CT: detection of an intestinal perforation and a diaphragmatic injury.

Unless the injury is confined to the solid organ of the abdomen, such as the liver or spleen, the matrix of intestinal gas patterns makes detection of penetrating injuries difficult. Kristensen et al were one of the first teams to introduce the role of ultrasonic scanning as part of the diagnostic armamentarium in trauma management.<sup>20</sup> Kimura and Otsuka endorsed using ultrasonography in the emergency room for evaluation of hemoperitoneum.<sup>21</sup> FAST does not have the same broad application in the evaluation of penetrating trauma as it does in blunt trauma assessment. Rozycki et al reported on the expanded role of ultrasonography as the “primary adjuvant modality” for the injured patient assessment.<sup>22</sup> Rozycki et al also reported that FAST examination was the most accurate for detecting fluid within the pericardial sac. Such a finding would be confirmatory for a cardiac injury and possible cardiac tamponade, given a mechanism of injury that could result in an injury to the heart.

As a diagnostic modality, laparoscopy is not a new innovation. Other specialists have been utilizing this operative intervention for several decades. However, it was formally introduced as a possible diagnostic procedure of choice for specific torso wounds when Ivatury et al did a critical evaluation of laparoscopy on penetrating abdominal trauma.<sup>23</sup> Fabian et al also reported on the efficacy of diagnostic laparoscopy in a prospective analysis.<sup>24</sup> With there being no conventional diagnostic tool that can conclusively rule out a diaphragmatic laceration or rent, diagnostic laparoscopy becomes the study of choice for penetrating thoracoabdominal injuries, particular left thoracoabdominal wounds (Fig. 12-1). Laparoscopy can also be used to determine peritoneal entry from a tangential penetrating injury.



\*Operative intervention is mandatory for all high-velocity injuries, irrespective of left or right.

FIGURE 12-1 Management algorithm for penetrating thoracoabdominal injuries.

## Penetrating Abdominal Injuries and the Hemodynamically Stable and Unstable Patient

As highlighted previously, the management principles in patients who sustain penetrating abdominal injuries and remain hemodynamically stable depend on the mechanism and location of injury, along with the hemodynamic status of the patient. Irrespective of the patient’s hemodynamic parameters, the ATLS protocol should be strictly followed upon arrival of the patient to the trauma bay.<sup>25</sup> Figures 12-2 through 12-5 are management algorithms for the patient with penetrating thoracoabdominal, penetrating anterior abdominal, penetrating abdominal, or penetrating back or flank injuries.

## Trauma Laparotomy

The operative theater should be large enough to accommodate more than one surgical team, in the event the patient might require simultaneous procedures to be performed. In addition, the room should have the capability of maintaining room temperatures in order to avoid having a hypothermic patient. Also, there should be a rapid transfusion device in the room in order to facilitate the delivery of large fluid volume and ensure that the fluid administration is appropriately warm.

Abdominal exploration for trauma has basically four imperatives: (1) hemorrhage control, (2) contamination control, (3) identification of the specific injury(ies), and (4) repair/reconstruction. The abdomen is prepared with a topical

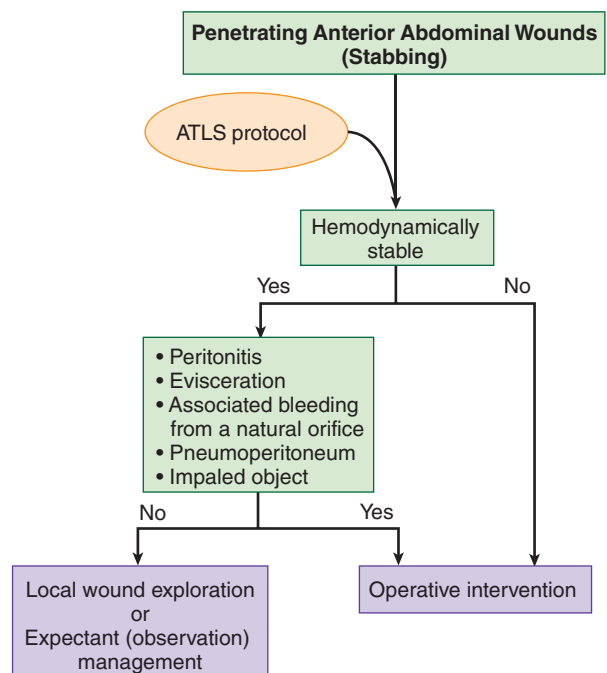
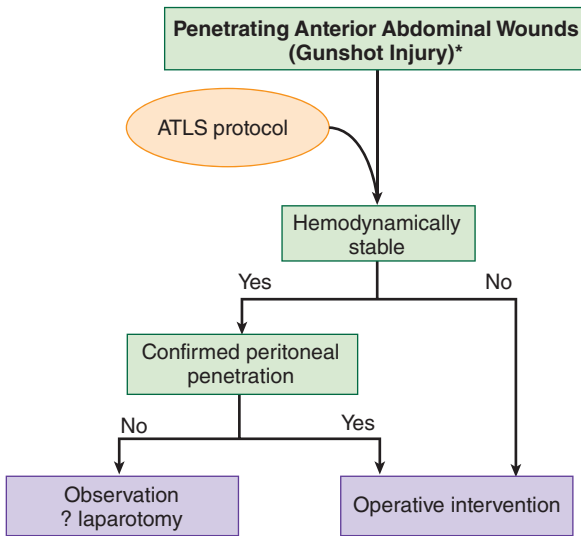


FIGURE 12-2 Management algorithm for penetrating anterior abdominal injuries.



\*Operative intervention is mandatory for all high-velocity injuries.

FIGURE 12-3 Management algorithm for penetrating abdominal injuries.

antimicrobial from sternal notch to bilateral midhighs and extending the prep laterally to the side of the operating room table, followed by widely draping the patient. Such preparation allows for expeditious entry into the thorax if needed and possible vascular access or harvesting. Exploration is initiated with a midline vertical incision that should extend from the xyphoid to the symphysis pubis in order to achieve optimal exposure.

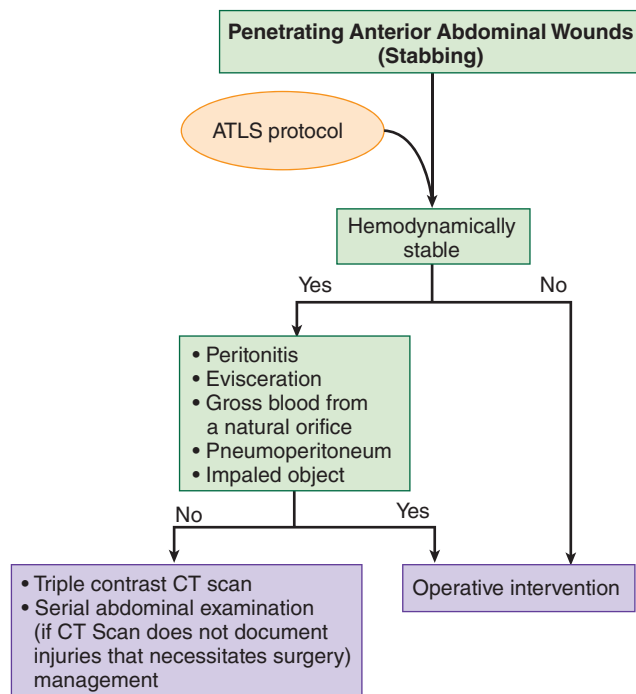
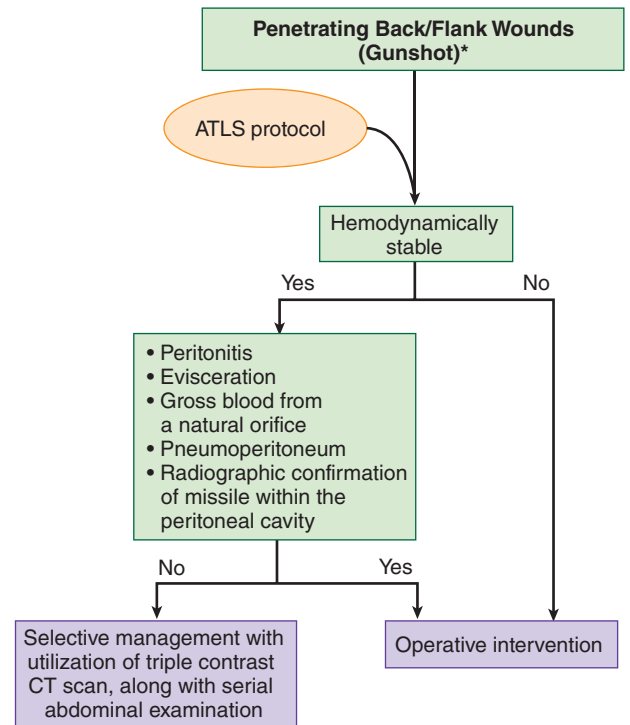


FIGURE 12-4 Management algorithm for penetrating abdominal injuries.



\*Operative intervention is mandatory for all high-velocity injuries.

FIGURE 12-5 Management algorithm for penetrating back/flank injuries.

The first priority upon entering the abdomen is control of exsanguinating hemorrhage. Such control can usually be achieved by direct control of the lacerated site or obtaining proximal vascular control. After major hemorrhage is controlled, blood and blood clots are removed. Abdominal packs (radiologically labeled) are used to tamponade any bleeding and allow for identification of any injury bleeding. The preferred approach to packing is to divide the falciform ligament and retract the anterior abdominal wall. This will allow manual placement of the packs above the liver. Abdominal packs should also be placed below the liver. This arrangement of the packs on the liver creates a compressive tamponade effect. After manually eviscerating the small bowel out of the cavity, packs should be placed on the remaining three quadrants, with care taken to avoid an iatrogenic injury to the spleen. During the packing phase after ongoing hemorrhage has been controlled, the surgeon should communicate with the anesthesia team that major hemorrhage has been controlled and that this would be an optimal time to establish a resuscitative advantage with fluid/blood product administration.

The next priority should be control or containment of gross contamination. This begins with the removal of the packs from each quadrant—one quadrant at a time. Packs should be removed from the quadrants that you least suspect to be the source for blood loss, followed by removal of the packs from the final quadrant—the one that you believe is the area of concern.

After control of major hemorrhage has been achieved, any evidence of gross contamination must be addressed immediately. Obvious leakage from intestinal injury can be initially controlled with clamps (eg, Babcock clamp), staples, or sutures. The entire abdominal gastrointestinal tract needs to be inspected, including the mesenteric and antimesenteric border of the small and large bowel, along with the entire mesentery. Rents in the diaphragm should also be closed to prevent contamination of the thoracic cavity.

Further identification of any and all intra-abdominal injuries should be initiated. Depending on the mechanism of injury and the estimated trajectory of the wounding agent, a thorough and meticulous abdominal exploration should be performed, including entering the lesser sac to better inspect the pancreas and the associated vasculature. In addition, mobilization of the C-loop of the duodenum (Kocher maneuver) might be required, along with medial rotation of the left and/or right colon for exposure of vital retroperitoneal structures.

The final component of a trauma laparotomy is definitive repair, if possible, of specific injuries. As will be highlighted later in the chapter, the status of the patient dictates whether each of the components of a trauma laparotomy can be achieved at the index operation. A staged celiotomy (“damage-control” laparotomy) might be necessary if the patient becomes acidotic, hypothermic, coagulopathic, or hemodynamically compromised.

## Definitive Management of Specific Injuries

### SMALL INTESTINES

Isolated small bowel enterotomies can be closed primarily with nonabsorbable sutures for a one-layer closure. If the edges of the enterotomy appear nonviable, they should be gently debrided prior to primary closure. However, multiple contiguous small bowel holes or an intestinal injury on the mesenteric border with associated mesenteric hematoma will likely necessitate segmental resection and anastomosis of the remaining viable segments of the small bowel. The operative goal is always the reestablishment of intestinal continuity without substantial narrowing of the intestinal lumen, along with closure of any associated mesenteric defect. Application of noncrushing bowel clasps can contain ongoing contamination while the repair is being performed. Although a hand-sewn or stapler-assisted anastomosis is operator dependant, trauma laparotomies are time-sensitive interventions and expeditious management is imperative.

### COLON

The segment of injured bowel should be thoroughly inspected, particularly missile injuries that are most common, for through-and-through enterotomies. This requires adequate mobilization of the colon in order to visualize the entire circumference of the bowel wall. Initially controversial, an enterotomy (right- or left-sided injuries) of the colon can be closed primarily, irrespective

of contamination or transient shock state.<sup>26</sup> If the colon injury is so extensive that primary repair is not possible or would severely compromise the lumen, a segmental resection should be performed. Depending on the setting, the remaining proximal segment can be anastomosed to the distal segment or a proximal ostomy and Hartmann’s procedure can be performed. If the distal segment is long enough, a mucous fistula should be established. Documented rectal injuries, below the peritoneal reflection should necessitate a diverting colostomy and presacral drainage (exiting from the perineum). Such drainage is, however, not universally endorsed.

### STOMACH/DUODENUM

With respect to penetrating wounds of the stomach, the anterior and posterior aspects of the stomach need to be meticulously inspected for accompanying through-and-through injuries. Penetrating injuries of the stomach should be repaired primarily after debridement of nonviable edges. The primary repair can either be performed in a single layer with nonabsorbable suture or as a double layer closure with an absorbable suture (eg, Vicryl) for the first layer and the second layer being closed with unabsorbable sutures (eg, silk). There are very few penetrating injuries of the stomach that would compromise the gastric lumen. Also, it is unlikely that primary repair of a through-and-through stomach injury would compromise the gastric lumen. Duodenal injuries can be repaired primarily in a one- or two-layered fashion if the penetration is less than half the circumference of the duodenum. However, for more complex duodenal injuries, an operative procedure is needed to divert gastric contents away from the site (where closure of the wound has been attempted). Performing a pyloric exclusion with the establishment of a gastrojejunostomy is such a procedure.<sup>27–29</sup>

### PANCREAS

Superficial or tangential penetrating wounds of the pancreas, in which there is not an injury to the main pancreatic duct, can be externally drained. However, a penetrating injury that transects the pancreas, including the main pancreatic duct, requires extirpation of the distal pancreas (distal pancreatectomy), particularly if the transection site is to the left of the superior mesenteric vessels. A more proximal penetrating injury that involves the main pancreatic duct, with associated complex duodenal injury (eg, injury to the ampulla), would likely necessitate a pancreatoduodenectomy. Unfortunately, because of the rich vascular network surrounding the pancreas, penetrating pancreatic wounds can be lethal injuries.

### SPLEEN

Most penetrating splenic injuries, particularly gunshot wounds, require a splenectomy. In order to visualize the entire spleen, it should be mobilized to the midline by dividing its ligamentous attachments. Superficial penetrating injuries of the spleen can sometimes be managed by either splenorrhaphy or application of a topical hemostatic agent. Splenorrhaphy can be

done by a pledgeted repair or an omental buttress. However, complex repair of the spleen is not a prudent approach in the always time-sensitive trauma setting.

## GALLBLADDER AND LIVER

Penetrating injuries to the gallbladder dictate the need for extirpation. There is no role for primary repair of a penetrating wound to the gallbladder.

Liver injuries are common in both blunt and penetrating trauma. The majority of injuries are superficial or minor and require no surgical repair. Simple application of pressure and/or a hemostatic agent or fibrin glue will constitute definitive management of the majority of these injuries. The argon beam coagulator, also a helpful adjunct in superficial hepatic injuries with persistent oozing, generates ionizing energy through an argon gas stream that causes rapid coagulation. The operative armamentarium for complex penetrating hepatic injuries is highlighted in Table 12-2.

## GENITOURINARY SYSTEM

Fewer than 10% of patients with penetrating abdominal wounds sustain genitourinary tract injuries. The majority of the injuries are renal. Penetrating injuries that result in a grade IV (cortical/calycal injury and associated vascular injury with contained hemorrhage) or grade V (shattered kidney and vascular avulsion) invariably necessitate a nephrectomy, particularly if there is a viable contralateral kidney. Lacerations or more superficial wounds of the kidney might require renorrhaphy, with approximation of the disrupted capsule with pledgeted sutures or a prosthetic (mesh) wrap. Absorbable interrupted suture should be used and all repairs should be drained. The injury pattern might dictate the need for a partial nephrectomy. Ureteral injuries can be extremely difficult to identify in penetrating wounds with an accompanying retroperitoneal hematoma. When possible, the ureter should be repaired primarily with interrupted absorbable suture over a double J-stent. A complete transection of the ureter requires debridement of the nonviable edges and the ends being spatulated, with and primary repair over a stent. All repair sites should be adequately drained. If the anastomosis cannot be performed in a tension-free fashion, a bladder flap

(Boari) could be surgically constructed, with implantation of the proximal segment of the transected ureter into the flap. A psoas “hitch” might be required if there is any tension on the flap and the tunneled ureter.

Penetrating injury to the intraperitoneal bladder requires surgical repair. After no involvement of the trigone is confirmed, the bladder should be closed with a two-layer closure with absorbable suture (the second layer incorporates Lembert sutures to imbricate the first layer). Suprapubic drainage should only be done selectively; however, a Foley catheter should be left in place.

## Retroperitoneal Hematomas

The retroperitoneum, an organ-rich region, has several vital structures that can be injured when its boundaries are penetrated. It can be a major potential site for hemorrhage in patients sustaining either penetrating or blunt trauma due to the substantial vascularity along with bleeding that can occur from an associated solid organ wound (eg, kidney). In the central region (zone 1) of the retroperitoneum reside the abdominal aorta; celiac axis; and the superior mesenteric artery, vena cava, and proximal renal vasculature. The lateral retroperitoneum (zone 2) encompasses the proximal genitourinary system and its vasculature. The pelvic retroperitoneum (zone 3) contains the iliac arteries, veins, and tributaries of veins. In addition to the vasculature and the kidneys (plus ureters) highlighted above, the retroperitoneum contains the second, third, and fourth portions of the duodenum, along with the pancreas, the adrenals, and the intrapelvic portion of the colon and rectum. Table 12-3 underscores the management principles of trauma-related retroperitoneal hematomas. Ideally, proximal (and when applicable, distal) control need to be achieved before exploring any retroperitoneal hematoma. For retroperitoneal hematomas in zone 1, mandatory exploration is required irrespective of a penetrating or blunt mechanism. Also, retroperitoneal hematoma in any of the three zones requires exploration for all penetrating injuries. For zone 2 retroperitoneal hematomas resulting from blunt trauma, all pulsatile or expanding hematomas should undergo exploration. Gross extravasation of urine also necessitates exploration. Zone 3 (pelvic retroperitoneum) hematomas should be explored only for penetrating injuries to determine if there is a specific intrapelvic colorectal, ureteral, or vascular injury. However, such an approach should not be taken for blunt trauma, for the injury would likely be venous and application of an external compression device would be the



**TABLE 12-2: CONSIDERATIONS FOR HEPATIC INJURY**

- Portal triad occlusion (Pringle maneuver)
- Hepatic artery ligation
- Hepatotomy (sharp or finger fracture with distal vein isolation)
- Resectional debridement
- Omental buttress
- Intrahepatic balloon tamponade
- Atrial caval shunt (to the superior vena cava)
- Abdominal packing



**TABLE 12-3: RETROPERITONEAL HEMATOMAS**

	Zone 1	Zone 2	Zone 3
Penetrating	Explore	Explore	Explore
Blunt	(Not mandatory)	Explore	(Not mandatory)



preferred intervention. An arterial injury could be addressed by arteriography/embolization.

## Intra-abdominal Packing and “Damage-Control” Strategy

“Damage-control” strategy, popularized by Rotondo et al, is a staged celiotomy strategy that was initially made operational by Mattox and Feliciano and was labeled the “Bogota bag” approach. Although Mattox and Feliciano did not actually develop this approach, they certainly popularized the technique and made it acceptable for use in the United States.<sup>30–34</sup> Irrespective of the name given to this strategy of surgically managing only immediate life-threatening injuries (along with intra-abdominal packing and rapid temporary closure of the abdominal cavity), the goal is the same—avoiding the potential irreversibility of sustained acidosis, hypothermia, coagulopathy, and hemodynamic lability by delaying definitive operative management until the patient can be stabilized in the intensive care unit. Although “damage control” is most frequently used in association with severe hepatic wounds, other organ injuries, including vascular wounds, can necessitate this staged celiotomy approach with hepatic packing and a rapid, creative abdominal closure.

## MANAGEMENT OF BLUNT ABDOMINAL TRAUMA

### Introduction

Management of blunt abdominal trauma has undergone significant change over the past two decades, evolving from a primary operative scheme to more nonoperative management. The workup has shifted largely from the use of physical examination, plain x-ray, laboratory findings, and DPL to the extensive use of CT and ultrasonography. Treatment for visceral injury has traditionally been surgical, but many forms of solid-organ injury can now be managed nonoperatively or with minimally invasive and interventional radiology techniques. Management of the multiply injured trauma patient at level I trauma centers with state-of-the-art techniques has now conclusively shown significantly improved patient outcomes and survival.<sup>35</sup>

## Diagnostic and Imaging Techniques

### DIAGNOSTIC PERITONEAL LAVAGE

Originally described by Root in 1965, diagnostic peritoneal lavage (DPL) has been a mainstay in the management of blunt abdominal trauma for over four decades.<sup>36</sup> Before the era of routine CT scanning, it was used as a screening tool to evaluate patients having blunt or penetrating abdominal trauma with

**TABLE 12-4: DIAGNOSTIC CRITERIA FOR A POSITIVE DPL**

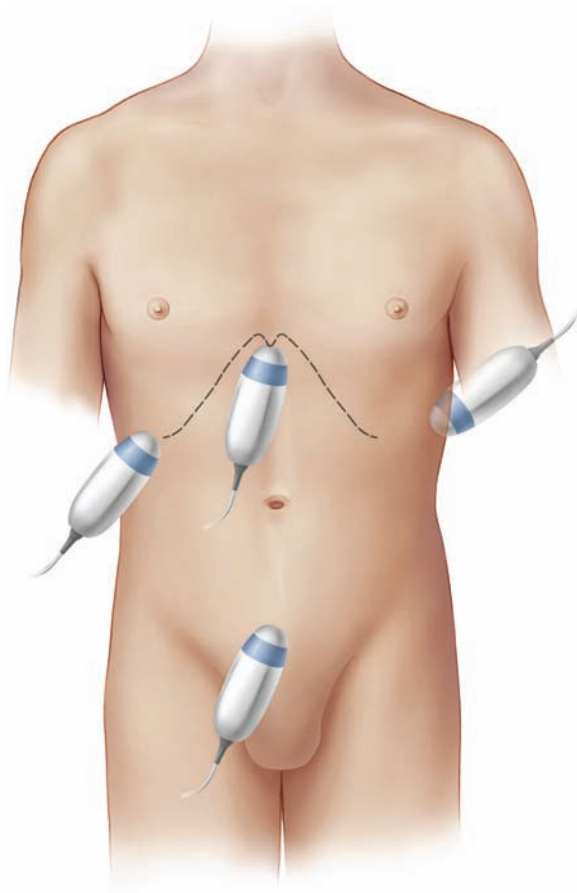
Any Viscus	Bowel
10 mL gross blood	Bacteria
>100,000 red blood cell/mm <sup>3</sup>	Bile
>500 white blood cell/mm <sup>3</sup>	Food particles
>75 IU/L amylase	

an accuracy rate reported between 92 and 98%.<sup>37–42</sup> Because of its invasive nature, DPL has largely been supplanted by CT scans and FAST. However, it remains an excellent tool for further workup of occult bowel injury or in unstable patients when FAST is not available or has questionable findings. In the workup for occult bowel injury, traditional parameters (Table 12-4) should be used to guide therapy. In unstable patients, a diagnostic tap is usually all that is necessary, and exploration indicated for greater than 10 mL of gross blood.

The pitfalls of DPL are a relatively high false-positive rate, risk of creating visceral injury, and poor sensitivity for detecting injury to retroperitoneal structures such as the pancreas and duodenum.<sup>43–45</sup> Iatrogenic events are minimized if a Foley catheter and nasogastric tube are placed prior to the procedure. Patients with pelvic fractures and suspected retroperitoneal hematoma or pregnant females should undergo a supraumbilical approach. Visceral injury is less likely with an open approach but more time consuming and invasive.<sup>46–49</sup> Checking amylase or lipase in lavage, concomitant use of CT scan, and a high index of suspicion are necessary to avoid missed retroperitoneal injury.

### FOCUSED ABDOMINAL SONOGRAPHY FOR TRAUMA

One of the most recent advances in the workup of the acutely injured patient is the use of bedside ultrasonography for detection of cardiac and intra-abdominal injury. Known as focused abdominal sonography for trauma (FAST), this technique’s noninvasive nature allows the operator to perform an examination simultaneously during the initial resuscitation and stabilization of a multiply injured trauma patient. The technique may thereby provide evidence of significant hemorrhage early in the course of an evaluation. An ultrasound probe is used to examine four key windows for fluid: the subxyphoid area permits visualization of the pericardium, the left subcostal area visualization of the splenorenal recess, right subcostal area visualization of Morison’s pouch, and the suprapubic area visualization of the pelvic cul-de-sac (Fig. 12-6). The presence of fluid may indicate then presence of cardiac tamponade, intra-abdominal hemorrhage, hollow viscus perforation, hemoperitoneum, or ascites. False-positive results secondary to preexisting ascites or false negatives due to operator error and/or body habitus are the main limitations. Scanning the supra pubic area with distension of the



**FIGURE 12-6** Schematic showing sonographic windows for (1) subxyphoid, (2) left subcostal, (3) right subcostal and suprapubic areas. Distension of the urinary bladder either prior to Foley catheter placement or by installation of 150–200 mL normal saline will enhance sensitivity. (Redrawn from Rozycki GS, Ochsner MG, Schmidt JA, et al. A prospective study of surgeon-performed ultrasound as the primary adjunct modality for injured patient assessment. *J Trauma*. 1995;39:492–498; discussion 498–500.)

urinary bladder will enhance the sensitivity of the examination for the detection of pelvic fluid. A threshold of at least 200 mL of fluid in the abdominal cavity is necessary for detection, and intra-abdominal injuries must be associated with the presence of this much free fluid for a positive finding.<sup>50</sup> Reported sensitivities range between 73 and 88% and specificity between 98 and 100%.<sup>51</sup> Accuracy rates range from 96 to 98%. FAST is an inexpensive, rapid, portable, noninvasive technique that can be performed in serial fashion if there is a change in patient stability.<sup>52–54</sup> Additionally, it obviates the risk of exposing pregnant females to radiation. Positive findings in stable patients can be further evaluated with CT or DPL while unstable patients with a positive finding may be taken to the operating room for emergent exploration. Workup of a patient with a reliable abdominal examination may be complete with a negative FAST in the absence of abdominal signs or symptoms.

## COMPUTED TOMOGRAPHY

Technological advances in CT have revolutionized the initial management of trauma patients over the past two decades. Multidetector scanners have dramatically improved resolution and accuracy of these imaging studies. Negative predictive values as high as 99.63% have been reported for patients sustaining significant mechanisms of blunt trauma allowing the use of CT as a reliable and noninvasive tool for screening patients with blunt abdominal trauma.<sup>55</sup> In light of modern-day CT capabilities, prospective data have demonstrated that patients with a significant mechanism and a benign abdomen can be released from the emergency department if a CT scan of the abdomen shows no evidence of visceral injury provided that there are no other reasons for hospitalization.<sup>55</sup>

CT reliably identifies injuries in solid organs such as the spleen, liver, and kidney because of their vascular nature demonstrating disruption of normal architecture, associated free fluid, and the so-called vascular blush.<sup>56</sup> Grading scales have been developed to allow for accurate classification and determination of management plan (Tables 12-5 through 12-7).<sup>56,57</sup>



**TABLE 12-5: SPLEEN INJURY SCALE OF THE AMERICAN ASSOCIATION FOR THE SURGERY OF TRAUMA, 1994 REVISION**

	Grade <sup>a</sup>	Injury Description	ICD-9 <sup>b</sup>	AIS-90 <sup>c</sup>
I	Hematoma	Subcapsular, <10% surface area	865.01 865.11	2
	Laceration	Capsular tear, <1 cm parenchymal depth	865.02 865.12	2
II	Hematoma	Subcapsular, 10–50% surface area; intraparenchymal, <5 cm in diameter	865.01 865.11	2
	Laceration	1–3 cm parenchymal depth that does not involve a trabecular vessel	865.02 865.12	2
III	Hematoma	Subcapsular, >50% surface area or expanding; ruptured subcapsular or parenchymal hematoma		3
	Laceration	Intraparenchymal hematoma >5 cm or expanding >3 cm parenchymal depth or involving trabecular vessels	865.03 865.13	3
IV	Laceration	Laceration involving segmental or hilar vessels producing major devascularization (>25% of spleen)		4
V	Laceration	Completely shattered spleen	865.04	5
	Vascular	Hilar vascular injury that devascularizes spleen	865.14	5

<sup>a</sup> Advance one grade for multiple injuries, up to grade III.

<sup>b</sup> ICD, International Classification of Diseases, 9th Revision.

<sup>c</sup> AIS, abbreviated injury score.

**TABLE 12-6: LIVER INJURY SCALE OF THE AMERICAN ASSOCIATION FOR THE SURGERY OF TRAUMA, 1994 REVISION**

Grade <sup>a</sup>	Injury Description	ICD-9 <sup>b</sup>	AIS-90 <sup>c</sup>
I	Hematoma Subcapsular, <10% surface area	864.01 864.11	2
	Laceration Capsular tear, > 1 cm parenchymal depth	864.02 864.12	2
II	Hematoma Subcapsular, 10–50% surface area; intraparenchymal, <10 cm in diameter	864.01 864.11	2
	Laceration 1–3 cm parenchymal depth, <10 cm in length	864.03 864.13	2
III	Hematoma Subcapsular, >50% surface area or expanding; ruptured subcapsular or parenchymal hematoma Intraparenchymal hematoma >10 cm or expanding >3 cm parenchymal depth		3
	Laceration	864.04 864.14	3
IV	Laceration Parenchymal disruption involving 25–75% of hepatic lobe or 1–3 Couinaud's segments within a single lobe	864.04 864.14	4
V	Laceration Parenchymal disruption involving >75% of hepatic lobe or >3 Couinaud's segments within a single lobe		5
	Vascular Juxtahepatic venous injuries; ie, retrohepatic vena cava/central major hepatic veins		5
VI	Vascular Hepatic avulsion		6

<sup>a</sup> Advance one grade for multiple injuries, up to grade III.

<sup>b</sup> ICD, International Classification of Diseases, 9th Revision

<sup>c</sup> AIS, Abbreviated injury score.

Detection of bowel injury via CT scan in patients who are intoxicated, intubated, or have associated closed-head injury or other distracting injuries can present a diagnostic challenge in the absence of a reliable abdominal exam. The incidence of blunt bowel injury varies from series to series but is generally reported in the 1–5% range in all blunt trauma patients admitted to level I trauma centers.<sup>58,59</sup> A high index of suspicion is predicated on mechanism of injury and physical examination findings such as abdominal wall tattooing and/or the seat belt sign. CT findings may be direct such as extravasation of oral contrast or pneumoperitoneum or more commonly indirect such as bowel wall thickening, stranding of the mesentery, or

**TABLE 12-7: KIDNEY INJURY SCALE OF THE AMERICAN ASSOCIATION FOR THE SURGERY OF TRAUMA**

Grade <sup>a</sup>	Injury Description	ICD-9 <sup>b</sup>	AIS-90 <sup>c</sup>
I	Contusion Microscopic or gross hematuria, urologic studies normal	866.00 866.02	2
	Hematoma Subcapsular, nonexpanding without parenchymal laceration	866.11	2
II	Hematoma Nonexpanding perirenal hematoma confined to renal retroperitoneum	866.01	2
	Laceration Parenchymal depth of renal cortex (>1.0 cm) without urinary extravasation	866.11	2
III	Laceration Parenchymal depth of renal cortex (>1.0 cm) without collecting system rupture or urinary extravasation	866.02 866.12	3
	IV	Laceration Parenchymal laceration extending through the renal cortex, medulla, and collecting system	866.02 866.12
Vascular Main renal artery or vein injury with contained hemorrhage			4
V	Laceration Completely shattered kidney	866.03	5
	Vascular Avulsion of renal hilum which devascularizes kidney	866.13	5

<sup>a</sup> Advance one grade for bilateral injuries up to grad III.

<sup>b</sup> ICD, International Classification of Diseases, 9th Revision.

<sup>c</sup> AIS, Abbreviated Injury Score.

Adapted from Moore EE, Shackford SR, Pachter HL, et al. Organ injury scaling: spleen, liver, and kidney. *J Trauma*. 1989;Dec;29(12):1664–1666.

free fluid in the absence of solid organ injury. Indirect findings may be fairly nonspecific and secondary to bowel edema from resuscitation or preexisting ascites. Reproductive age females may have a small amount of normal or “physiologic” pelvic fluid present sometimes adding to the complexity of the evaluation. Patients on positive pressure ventilation or with significant barotrauma may develop mediastinal or subcutaneous emphysema that can tract through the peritoneum or retroperitoneum and give the appearance of free air. Great care in the radiologic interpretation and close clinical correlation are necessary in such cases. The liberal use of DPL may prevent nontherapeutic laparotomy. Obviously, when significant doubt remains, abdominal exploration may be necessary to confirm an injury.

The role of oral contrast in the evaluation of the acutely injured patient has recently come under question. Little time

is usually available in the emergent setting to permit adequate opacification of the small bowel. Patients are further at risk for aspiration of the contrast media, and administration often requires placement of a nasogastric tube. A number of reports now have shown that elimination of oral contrast media does not lead to an increased incident of missed bowel injury.<sup>58–60</sup> Many centers have now safely eliminated the use of oral contrast media from their routine trauma protocols expediting management and ease of patient care. Resuscitation edema may cause a hazy appearance around the head of the pancreas and duodenal c-loop raising the question of a pancreas or duodenal injury. Further clarification in this situation can be obtained, when it occasionally occurs, via repeat CT scan with the administration of oral contrast and the injection of 300- to 500-cc bolus of air down the nasogastric tube and may make the pneumoperitoneum obvious.

CT may also be of great importance in identifying patients with arterial hemorrhage related to pelvic fracture. CT imaging may demonstrate an arterial blush or large hematoma in the vicinity of a pelvic fracture indicating the need for pelvic arteriography or pelvic external fixation. A “CT cystogram” may also be helpful and eliminate redundancy of x-ray evaluation. The Foley catheter is clamped after placement in the trauma bay. Real-time interpretation, as the CT scan is performed by the evaluating physician, may dictate further delayed images or a formal three-view (anterior/posterior, lateral, and postvoid views) cystogram.

## Specific Organ Injury

### THE SPLEEN

The spleen is the most commonly injured intra-abdominal organ followed by the liver and small bowel in blunt trauma patients. The spleen's location in the left upper quadrant lends susceptibility to injury from broken ribs, deceleration, and blunt percussion forces. Clinically, patients with splenic injury may present with hypotension, left upper quadrant pain, or tenderness to palpation or diffuse peritonitis from extravasated blood. Referred pain to the left shoulder on deep inspiration, in face of splenic hematoma, is known as *Kehr's sign*.

**Nonoperative Management.** Most series indicate that approximately 60–80% of patients presenting with blunt splenic injury can be managed nonoperatively at level I or II trauma centers.<sup>61–65</sup> Facilities without the resources and experience of a bona fide trauma team may not safely meet the demands of nonoperative management and should consider patient transfer.<sup>66</sup> Patients selected for nonoperative management must have stable vital signs, be free of peritoneal signs or other concern for hollow viscus injury, and have no evidence of free extravasation of IV contrast from the splenic parenchyma.

Considerable debate remains regarding risk factors for failure of nonoperative management. Higher splenic injury

grade, age greater than 55 years, moderate to large hemoperitoneum, subcapsular hematoma, and portal hypertension have all been suggested to increase the risk of failure. Early reports in the evolution of nonoperative management regarding ASST grade did not demonstrate higher failure rates for higher-grade injury. More recent reports using high-resolution multidetector CT scanners allow better assessment of injury grade. The data from these studies show patients with injury grades III–V to be at increased risk for nonoperative failure.<sup>61,63</sup> Age continues to be controversial subject matter in the literature with numerous reports claiming that age greater than 55 years *is* or *is not* a risk factor for failure.<sup>61,63,67</sup> Documentation of a moderate or large hemoperitoneum is suggestive of a major injury and should be considered a significant factor in individual patient assessment.

Patients with splenic subcapsular hematoma or history of portal hypertension are specific subgroups of patients who deserve special consideration. Patients with subcapsular hematoma in our experience tend to ooze from the raw parenchymal surface and further disrupt the capsule leading to more raw surface area to bleed. These patients are at increased risk for delayed rupture 6 to 8 days following injury and may already be discharged from the hospital if they have isolated injury. Furthermore, splenic embolization is not a very effective treatment of this condition because it usually necessitates coiling of the main splenic artery that can lead to significant pain and abscess formation. A history of portal hypertension or cirrhosis, while not absolute contraindications to nonoperative management, certainly should raise concerns. The general risks of laparotomy in a Childs B or C cirrhotic need to be carefully weighed against the risk of ensuing and worsening coagulopathy. This scenario may, indeed, call for main splenic artery embolization. None of these risk factors alone should dictate the decision to proceed immediately to operative intervention. Nonoperative management does reduce hospital length of stay and transfusion requirement; however, the morbidity of splenectomy should remain low in any surgeon's hands. Overall, the patient's condition, including comorbidities, coagulopathy, and other problems (such as traumatic brain injury, aortic injury and suspicion for concomitant hollow viscus injury) factor into the decision making process. No one should ever succumb to splenic hemorrhage that was undergoing nonoperative management.

**Management of Blunt Splenic Injury.** Approximately 20% of patients initially undergoing nonoperative management of blunt splenic injury require further intervention. Failure has been associated with the presence of a contrast blush in up to two-thirds of these patients.<sup>68</sup> The presence of a contained contrast blush within the parenchyma of the spleen represents pseudoaneurysm formation of a branch of the splenic artery. Angioembolization is now commonly used to selectively occlude the arterial branches containing these injuries.<sup>61,62,65,69,70</sup> Implementation of this salvage technique at centers that routinely screen for the presence of pseudoaneurysm has increased the success of nonoperative management to 90% or greater.



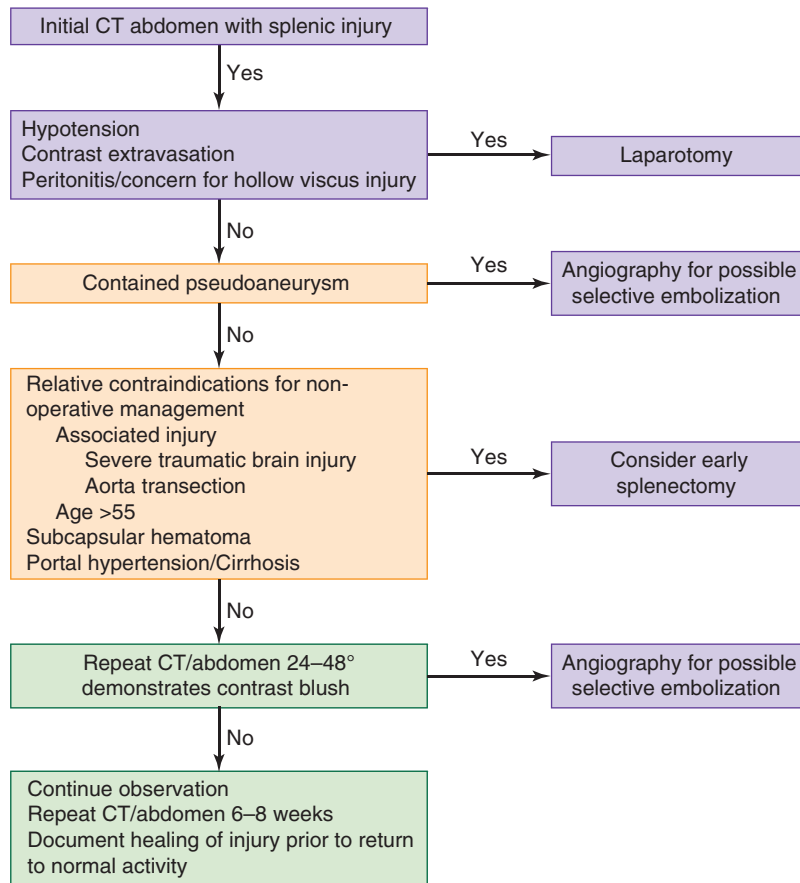


FIGURE 12-7 Management algorithm for blunt splenic injury.

Pseudoaneurysm formation has been observed in even grades I and II injuries and may not be present on the initial imaging.<sup>61,64,70</sup> Therefore, follow-up CT scan is recommended on all patients with splenic trauma within 24–48 hours after injury. If these images show stable injuries without pseudoaneurysm formation, expectant management may ensue. Figure 12-7 is a management algorithm for the patient with blunt splenic injury.

Long-term data are unavailable concerning the risk of outpatient or delayed rupture, but the incidence is low and has been reported to be about 1.4%.<sup>71</sup> The average date to readmission for delayed splenectomy after discharge was 8 days in this study. Lower-grade (I, II) injuries tend to heal more quickly and most all injuries are healed by 5–6 weeks.<sup>72</sup> However, approximately 20% of blunt splenic injuries will not show complete healing and may be at risk for pseudocyst formation. A CT scan should be repeated in 6 weeks for grades I and II injuries and 10–12 weeks in grades III–V before reinstating normal activity.

**Splenectomy.** Patients requiring urgent or emergent intervention for splenic hemorrhage may develop hypothermia, coagulopathy, and visceral edema. The most expeditious and safest course of action under these conditions is removal of the spleen. The general assumption of

abdominal exploration for trauma is that there are known and, possibly, unknown injuries. The operative approach is via a midline vertical incision that allows the best exposure and facilitates temporary abdominal closure should visceral edema or damage-control measures be necessary. Standard operating procedure is similar to that previously highlighted in the section, Management of Penetrating Abdominal Trauma.

With respect to performing a splenectomy, a Buckwalter retractor is used to expose the left upper quadrant. The spleen is retracted medially with some downward compression, and the posterior attachments can be taken with the cautery. Once these attachments are freed, the spleen can be mobilized medially for optimal exposure. The assistant stands on the left side of the table and supports the spleen while the surgeon ligates short gastric and hilar vessels. Being careful to avoid the tail of the pancreas, a large clip, placed on the specimen side of the splenic hilum, will reduce back-bleeding and expedite the procedure. Once the spleen has been removed, the splenic fossa is inspected for further bleeding with a rolled laparotomy pad.

**Splenorrhaphy.** Hemodynamically stable patients found to have small to moderate amounts of parenchymal hemorrhage at laparotomy may be candidates for splenic preservation.

The spleen is mobilized into the wound using the same technique as for splenectomy. The injury to the spleen is assessed and decision is made whether to resect a portion if the parenchymal injury extends into the hilum or if arterial bleeding is coming from within the splenic laceration itself. If the decision is made to resect the upper or lower pole, the parenchyma is divided with the cautery, and the associated hilar vessels are taken with clamps and ties. Any arterial bleeding from the parenchyma is controlled with suture ligation and the cautery is used to control oozing from the parenchyma. A tongue of omentum is then sutured into the laceration or to the raw surface of the remaining spleen in the case of resection. Approximately 50% of the spleen is required to preserve adequate phagocytic and immunologic function. If this cannot be achieved, a splenectomy is probably the best option.

**Overwhelming Postsplenectomy Infection.** The incidence of overwhelming postsplenectomy infection (OPSI) following trauma is not well understood because it may not be appreciated when it occurs and it is not routinely reported. However, the reported incidence of OPSI in adult patients undergoing splenectomy for all causes is 0.9% with a mortality of 0.8%.<sup>73</sup> The risk of OPSI in adults following trauma is felt to be lower than the incidence seen after splenectomy for hematological disorders such as idiopathic thrombocytopenic purpura (ITP), lymphoma, and thalassemia. Children are at greater risk for OPSI and should receive prophylactic penicillin V 125 mg twice daily until age 3 and then 250 mg twice daily until age 5. Currently, anyone older than 2 years should receive the 23 valent pneumococcal vaccine and a one-time dose of the *Haemophilus influenzae* and meningococcal vaccine. A one-time booster dose of the pneumococcal vaccine is recommended 5 years after the original vaccine.<sup>74</sup>

## The Liver

The liver is susceptible to the same blunt force mechanisms as the spleen making it the second most frequently injured

intra-abdominal organ. Similar to the spleen, nonoperative management of blunt liver injury has greatly reduced transfusion requirements, hospital length of stay, and mortality.<sup>75–78</sup> Angiographic embolization of arterial injury has also greatly reduced the morbidity and mortality of liver trauma. Complications of nonoperative management such as biloma and liver abscess can usually be managed with minimally invasive techniques as well. What is imperative in the management scheme is the knowledge of when to take the patient immediately to the operating room for active hemorrhage versus attempting nonoperative management with angioembolization. The liver is obviously not as expendable an organ as the spleen, and there is no substitute for an in-depth knowledge and experience handling hepatic injuries.

## NONOPERATIVE MANAGEMENT

Similar to the experience with blunt splenic trauma, routine use of CT scans has revolutionized the management of blunt hepatic trauma. The most recent data show that 70–85% of all patients presenting with blunt liver trauma can be managed nonoperatively.<sup>75,76,79,80</sup> Patients must be hemodynamically stable, free of peritoneal signs or other evidence of bowel injury, and have absence of contrast extravasation. Worsening grade of injury makes nonoperative management less likely, but injury grade alone should *not* dictate the decision to intervene.<sup>78,81</sup> Patients should have a stable systolic blood pressure greater than 90 mm Hg with a heart rate less than 100 beats/min after controlling other possible sources of extra-abdominal blood loss, such as orthopedic and soft tissue injuries. Failure from subsequent liver hemorrhage occurs in 0.4–5% of patients and failure due to missed injury of other intra-abdominal organs, such as the kidney, spleen, pancreas, and bowel, occurs in 0.5–15% of patients.<sup>75,76,79,81,82</sup> These data are summarized in Table 12-8. It is difficult to tell the specific cause of immediate surgery in the earlier reports because laparotomies for *all* causes, such as associated splenic hemorrhage, were included. Christmas et al and Velmahos et al



**TABLE 12-8: FAILURE RATES FOR NONOPERATIVE MANAGEMENT OF LIVER TRAUMA**

Study (year)	Number of Patients	Immediate Surgery (%)	Overall Failure Rate (%)	Liver Failure Rate (%)	Other Failure Rate (%)
Meredith et al <sup>81</sup> (1994)	116	48	3	3	0
Croce <sup>75</sup> (1995)	136	18	11	5	6
Pachter et al <sup>82</sup> (1996)	404	53	1.2	0.7	0.5
Malhotra <sup>76</sup> (2000)	661	15	7	3	4
Velmahos et al <sup>79</sup> (2003)	78	29 <sup>a</sup>	15	0	15
Christmas et al <sup>78</sup> (2005)	561	32 <sup>b</sup>	1.8	0.4	1.4

Other failure refers to failure due to injuries from other intra-abdominal organs such as the spleen, kidney, pancreas, or bowel.

<sup>a</sup> 15% for liver bleeding.

<sup>b</sup> 13% for liver bleeding.

report that rates of immediate operative intervention for liver hemorrhage are 15 and 13%, respectively.<sup>78,79</sup>

Angiographic embolization is a useful adjunct in the management of blunt hepatic trauma both in nonoperative patients and those who have undergone damage-control laparotomy in a number of small series.<sup>78,79,83–89</sup> Intravenous contrast extravasating from the liver parenchyma into the peritoneal cavity and contrast contained within the parenchyma of the liver associated with a large amount of intraperitoneal blood on initial CT scan are emergent situations mandating angiographic embolization or surgery.<sup>90</sup> If bleeding appears to originate from the retrohepatic vena cava or hepatic veins and is ongoing, emergent exploration is the only choice because arterial embolization is ineffective in these scenarios. Patients with labile blood pressure and parenchymal injury may be better served with emergent exploration depending on the time necessary to assemble the angiography team. However, if angiography is readily available, favorable results have been obtained transporting patients to the angiography suite with ongoing resuscitation for arterial bleeding.<sup>86,91</sup> Patients requiring significant resuscitation during a successful embolization procedure may still be at risk for abdominal compartment syndrome and should have bladder pressures monitored if they receive greater than 10 units of blood products.<sup>79,92</sup>

Patients with contrast extravasation contained within the liver parenchyma without significant associated hemoperitoneum are less worrisome but should probably undergo arteriogram for further assessment.<sup>90</sup> A perceived contrast blush on CT scan is associated with bleeding identified at angiography in approximately 60% of patients.<sup>87</sup> Arteriography in the absence of contrast extravasation will likely be a low-yield study. Patients requiring operative exploration of their liver wounds that have arterial bleeding from deep within the liver parenchyma may benefit from hepatic packing with radiolucent laparotomy pads and direct transportation to the angiography suite.<sup>83,84,88</sup>

Several complications can occur in the management of liver trauma, including biloma, hepatic necrosis, liver abscess, and gallbladder necrosis.<sup>85</sup> Minimally invasive techniques can be successfully used to handle the majority of these complications. Biloma can occur after significant damage to the biliary tree. Patients may present with an ileus, abdominal pain, distention, or an abscess often with some degree of hyperbilirubinemia. Percutaneous drainage for localized collections will often control the leak and immediate symptomatology.<sup>87,88</sup> Persistent bile leak will usually require an endoscopic retrograde cholangiopancreatography (ERCP) with biliary stent placement. Patients with hepatic duct or common bile duct injury may require hepatectomy or hepaticojejunostomy. Patients with generalized ascites may benefit from laparoscopic washout and placement of perihepatic drains followed by ERCP for persistent leak.<sup>78,88</sup>

Simple abscess can usually be managed with percutaneous drainage, unless significant hepatic necrosis simultaneously exists.<sup>88</sup> Sterile liver necrosis may eventually resolve with expectant management but usually requires hepatic debridement when associated with infection. Patients who undergo embolization without surgery have approximately a 20%

chance of developing infected necrosis, while patients who undergo laparotomy followed by hepatic artery embolization have an incidence of hepatic necrosis of over 80% in one series.<sup>85</sup> Gallbladder necrosis occurs in approximately 20% of grades IV and V injury following nonselective embolization of the right hepatic artery.<sup>87</sup> These patients usually present several days after injury with leukocytosis, hyperbilirubinemia, and abdominal pain. HIDA (hepatobiliary iminodiacetic acid) scan and a high index of suspicion may be necessary to differentiate this diagnosis from the others listed.

## OPERATIVE MANAGEMENT

Bleeding from minor liver injuries (grades I and II) usually stops spontaneously, and surgical intervention is rarely required.<sup>75,81,93</sup> Occasionally, patients may require exploration for other injuries after abdominal trauma in the presence of minor liver trauma. Nonbleeding liver injuries should be left alone. In the face of coagulopathy or hypothermia, minor hepatic injuries may present with persistent oozing. In such cases, topical hemostatic agents, with or without perihepatic packing, may be all that is necessary to stop the bleeding if the patient is being adequately resuscitated.

Major liver injuries (grades III–V) are more likely to bleed and require surgical intervention. Because grades IV and V liver injuries can present formidable technical challenges even in the hands of the most capable individuals, a variety of surgical techniques have been developed for their management.

Large liver wounds should be quickly inspected to get some idea about the degree of hemorrhage and then packed off initially. Anesthesia should be notified about anticipated blood loss and blood availability checked. Vital signs and resuscitation status should be reviewed. Bleeding should be contained with packing and direct pressure until anesthesia has had time to “catch up.” Remaining focused and well organized, as well as replenishing intravascular volume, is invaluable in the management of any trauma patient.

The most direct approach at this point is to remove the packing and visually inspect for bleeding vessels which can be individually ligated. Debridement of devitalized tissue using finger fracture technique will expose additional bleeding vessels which may have retracted into the surrounding parenchyma. If bleeding prevents adequate visualization of the surgical field, the next step should be vascular control of the portal triad (ie, the Pringle maneuver).<sup>93</sup> This maneuver is easiest to perform for the person standing on the left of the patient. This individual places the fingers of the left hand into the foramen of Winslow and uses the thumb to palpate for the cord of tissue running into the caudal surface of the liver. Once this structure is suspected, its identity can generally be confirmed by appreciating the pulse in the hepatic artery. A hole is then created in the hepatoduodenal ligament using blunt finger dissection. A noncrushing vascular clamp can be applied or a ½-in. Penrose drain can be doubled, looped around the porta and cinched down with a Kelly clamp. We prefer the latter technique because it seems to be less obtrusive

to further manipulation of the liver and may be less traumatic to the structures of the porta.

If a Pringle maneuver does not adequately decrease liver bleeding, concern for hepatic vein or retrohepatic caval injury should be entertained. Obtaining adequate exposure in deep liver wounds or in juxtahepatic caval injuries is of utmost importance. The falciform ligament is taken off the diaphragm posteriorly to the bare area. The right and left triangular ligaments are dissected with the cautery extension to the corresponding coronary ligaments. Further dissection of the coronary ligaments to the bare area will allow vigorous mobilization of the liver into the surgical field. Careful dissection of the bare area will allow access to the suprahepatic inferior vena cava. If the plane in the bare area is difficult to develop, a transverse incision in the diaphragm here will gain access to the pericardium and intrapericardial control of the inferior vena cava can be achieved.<sup>94</sup> Total hepatic isolation can be achieved with a Pringle maneuver and vascular control of the infrahepatic, suprarenal inferior vena cava, and the suprahepatic intra-abdominal or intrapericardial inferior vena cava. The final step in this procedure is occluding inflow to the intra-abdominal aorta at the diaphragm while cardiac return from the lower body is eliminated. The physiologic stress of this technique may not be well tolerated in patients with severe shock and clamp times less than 20–30 minutes should be maintained.

Vascular shunts of the liver, otherwise known as atriocaval shunts, have been devised to circumvent impeding cardiac return when vascular isolation of the liver is desired.<sup>95</sup> In this procedure, early recognition of juxtahepatic venous injury is essential and liver bleeding is temporarily contained with packing and direct pressure.<sup>96</sup> A two-team approach is best; a median sternotomy is performed simultaneously while gaining vascular control of the infrahepatic suprarenal vena cava with a Rumel tourniquet. A Rumel tourniquet is also necessary around the intrapericardial inferior vena cava. A purse-string suture is placed in the right atrial appendage, and an opening is created in this structure. A 32F chest tube can then be directed from the atrium into the inferior vena cava. The Rumel tourniquets are applied. Before inserting the chest tube, an additional fenestration should be created approximately 3 in from the tapered proximal end. This opening will allow egress of the blood from the chest tube returning from the lower half of the body back into the heart. The proximal end of the chest tube protrudes from the right atrial appendage that is secured with the purse-string suture. The end of the chest tube is clamped or can be accessed with a Christmas tree adapter and used as a large-bore resuscitation line. Exploration of the retrohepatic cava is now possible. A number of institution-specific variations of this technique have been described, but we are unaware of any technique that has demonstrated improved results over Schrock's original description.<sup>97–99</sup>

The alternative to shunting grade V injuries is termed "direct exposure" popularized by Pachter and others.<sup>100–102</sup> This technique consists of four basic principles: (1) manual compression and packing of the liver with vigorous resuscitation, (2) portal triad occlusion, (3) wide mobilization of the hepatic

ligaments allowing for medial rotation of the liver and exposure of the retro hepatic cava, and (4) extensive finger fracture including normal liver parenchyma for direct vascular control of the injury.<sup>102</sup> In one analysis of over 142 patients sustaining juxtahepatic venous injuries, 35 (24.6%) were managed without a shunt, resulting in a survival rate of 49%. The patients managed with a shunt had a survival rate of 19%.<sup>102</sup> Suffice it to say, unless there is a significant institutional experience with the shunt, direct exposure or total hepatic isolation alone may provide the best chance for patient survival for the occasional patient presenting with a grade V injury.

Lobar hepatic resection offers exposure of the involved hepatic veins and retrohepatic vena cava in grade V injuries but has largely fallen out of favor because of high associated mortality rates.<sup>96,103–106</sup> The only current recommendation for this procedure is when the majority of the lobectomy occurred at the time of injury and the disrupted portion or lobe of liver has questionable viability. Selective hepatic artery ligation is another technique that has been employed to control arterial bleeding deep within the liver that cannot be easily identified or controlled through the liver wound.<sup>107–110</sup> In this situation, if a Pringle maneuver greatly reduces the arterial bleeding, the artery to the respective lobe should be dissected out and occluded. If this maneuver maintains hemostasis, the vessel may be taken. A more recent option is to pack the patient with radiolucent laparotomy pads and take him/her for an arteriogram and possible embolization.<sup>83,84,88</sup>

Once patients with operative liver trauma sustain surgical hemostasis, they may become hypothermic and coagulopathic with bleeding occurring from nonsurgical sources, in particular the raw liver parenchyma. At this point, the liver and other sources of nonsurgical bleeding may be packed with laparotomy pads and a temporary abdominal closure performed.<sup>106,111–116</sup> Patients can then be transported to the intensive care unit where they may be further resuscitated and warmed. Take back for removal of the packing, and debridement of devitalized liver may generally be undertaken safely in 24–48 hours. Omental packing of the liver defect originally described by Stone may reduce the incidence of bile leak and abscess formation.<sup>117</sup>

## The Bowel

There is yet no place for nonoperative management of hollow viscus injury, and the nemesis of nonoperative management of blunt abdominal trauma is therefore the missed bowel injury and all its catastrophic consequences. Otherwise, most management is straightforward—debridement and primary repair for nondestructive injuries and resection with primary repair versus stomal formation for destructive injuries.

### RADIOGRAPHIC FINDINGS OF BLUNT BOWEL INJURY

There are two basic types of findings of bowel injury on CT scan: direct and indirect. Direct findings are usually




**TABLE 12-9: CT SCAN FINDINGS OF BLUNT BOWEL INJURY**

Direct	Indirect
Oral contrast extravasation	Mesenteric hematoma
Free air	Mesenteric blush
	Bowel wall edema
	Unexplained ascites
	Fat streaking
	Unopacified (vascular contrast media) bowel loops

straightforward *if* present and amount to extravasation of oral contrast (if administered) and free air, which have been reported to occur in 4 and 28% of the time, respectively. Little else can explain the first of these two entities, while free air from other sources such as extensive subcutaneous emphysema tracking through a diaphragmatic hiatus is unusual.<sup>118–120</sup> Indirect findings may be subtle and can vary in presentation depending on the quality of the scan. Indirect findings include mesenteric hematoma or contrast blush, bowel wall edema, unexplained free fluid, “fat streaking” and bowel loops that don’t opacify with intravenous contrast (Table 12-9).

Mesenteric hematoma is nonspecific and can occur from associated injuries, such as pelvic fractures or renal injuries with hematomas from these structures tracking into the bowel mesentery. However, a vascular blush in the leaves of the mesentery is indicative of active hemorrhage until proven otherwise and, generally, a determinant for immediate operative exploration. Bowel wall edema and ascites are common in blunt trauma patients, can occur from resuscitation of other injuries, and don’t necessarily connote bowel injury. Free fluid in the absence of solid organ injury can be further evaluated with DPL if the abdominal examination is unreliable. Fat streaking can occur with mesenteric contusion and does not necessarily portend an operative indication. Unopacified bowel loops can indicate vascular disruption of the mesentery or simply be due to poor contrast timing in an under-resuscitated patient. In review of 8112 CT scans, Malhotra showed that at least one of these findings was present in 88.3% of patients with blunt bowel or mesenteric injury and that the likelihood of finding an injury at exploration increased when there was an increasing number of these findings.

## OPERATIVE MANAGEMENT

Appreciation of the AAST organ injury grading scale is helpful in describing wounds of the bowel.<sup>121</sup> Grade I injuries are contusions and partial-thickness lacerations of the bowel wall without perforation. Grade II injuries are full-thickness wounds involving less than 50% of the bowel wall circumference. Grade III are lacerations comprising greater than 50% of the bowel wall circumference without complete transection. Grades IV and V injuries represent complete transection of

the bowel wall and transection with segmental tissue loss and/or devascularization of the mesentery respectively. The terms destructive and nondestructive simplify the terminology; nondestructive wounds are those injuries that can be managed with debridement and primary suture enterorrhaphy and comprise grades I–III.<sup>122</sup> Destructive wounds require resection of an entire segment of the bowel due to loss of colonic integrity or devascularization of the mesentery and encompass grades IV and V (Tables 12-10 and 12-11).

The distinction between destructive and nondestructive wounds is important in terms of the prescribed management. Nondestructive wounds of the large or small bowel can generally be repaired without further consideration. Most small bowel destructive injuries should be resected and reconstituted unless damage-control conditions prevail.

In contrast to the small bowel, the management of colon injuries has received great scrutiny. Ushering in the dawn of modern-day trauma surgery, the WWII military experience dictated that *all* colon wounds, destructive or not, be managed by colostomy. This philosophy remained surgical dogma until the 1980s.<sup>123,124</sup> In a comprehensive review of the literature since 1979, primary repair of the colon for nondestructive wounds had been shown to have a leak rate of 1.6%.<sup>122</sup> Compared to patients receiving colostomy for similar types of wounds, the incidence of intra-abdominal abscess was 4.9% for primary repair and 12% for colostomy, and overall complication rate was 14% for primary repair and 30% for colostomy. Mortality rates were similar at 0.11% for primary


**TABLE 12-10: AAST SMALL BOWEL INJURY SCALE**

Grade <sup>a</sup>	Type of Injury	Description of Injury	ICD-9 <sup>b</sup>	AIS-90 <sup>c</sup>
I	Hematoma	Contusion or hematoma without devascularization	863.20–863.31	2
	Laceration	Partial thickness, no perforation		2
II	Laceration	Laceration <50% of circumference	863.20–863.31	3
III	Laceration	Laceration ≥50% of circumference without transection		3
IV	Laceration	Transection of the small bowel	863.20–863.31	4
V	Laceration	Transection of the small bowel with segmental tissue loss	863.20–863.31	4
	Vascular	Devascularized segment		4

<sup>a</sup> Advance one grade for multiple injuries, up to grade III.

<sup>b</sup> ICD, International Classification of Diseases, 9th Revision.

<sup>c</sup> AIS, abbreviated injury score.


**TABLE 12-11: AAST COLON INJURY SCALE**

Grade <sup>a</sup>	Type of Injury	Description of Injury	ICD-9 <sup>b</sup>	AIS-90 <sup>c</sup>
I	Hematoma	Contusion or hematoma without devascularization	863.40 863.44	2
	Laceration	Partial thickness, no perforation	863.40 863.44	2
II	Laceration	Laceration ≤50% of circumference	863.50 863.54	3
III	Laceration	Laceration >50% of circumference	863.50 863.54	
IV	Laceration	Transection of the colon	863.50 863.54	4
V	Laceration	Transection of the colon with segmental tissue loss	863.50 863.54	4

ICD-9:4, .51 = ascending; 42, .52 = transverse; 43, .53 = descending; .44, .54 = rectum.

<sup>a</sup> Advance one grade for multiple injuries, up to grade III.

<sup>b</sup> ICD, International Classification of Diseases.

<sup>c</sup> AIS, abbreviated injury score.

repair and 0.14% for colostomy. These findings clearly show the superiority of primary repair for nondestructive wounds of the colon.

Several risk factors for anastomotic failure pertaining to destructive colon injury have been addressed in the literature: hypotension, shock, interval from injury to operation, amount of fecal contamination, associated organ injury, transfusion requirement, and comorbid disease.<sup>125</sup> No data have conclusively shown that any of these risk factors increase the likelihood of anastomotic failure with certain caveats. Patients with massive blood loss or shock may be better served by undergoing a damage-control procedure, with definitive repair delayed.<sup>126</sup> Interval from injury to repair greater than 12 hours can be a relative contraindication, if there is wide-spread (greater than one quadrant) fecal contamination. Greater than one- or two-organ system injury has been a concern, but this may just be a marker for degree of shock and overall physiologic derangement. Comorbidities such as AIDS and cirrhosis deserve special consideration, and these patients may be better off with diversion.<sup>127,128</sup> Aside from suture line failure, patients with any of these risk factors have a higher incidence of intra-abdominal abscess and overall complications rates.<sup>122</sup>

Notwithstanding the risk factors for colon trauma, most series regard resection and primary anastomosis for destructive colon wounds in a favorable light. In a collective review of 207 patients reported in the literature, management of destructive bowel injury with resection and primary anastomosis had a reported leak rate of 7.2% with a mortality of 1.7% attributable to the colon wound.<sup>122</sup> In the largest single institution experience, Murray showed a leak rate of 11% in 112 patients undergoing resection and primary anastomosis

for destructive colon wounds with two deaths related to leaks.<sup>129</sup>

In a multi-institutional trial, Demetriades reported 297 patients with destructive colon wounds in which 197 underwent resection and anastomosis and 100 underwent diversion.<sup>127</sup> The choice of operation was left to the discretion of the attending surgeon at the time of exploration. Not surprisingly, the patients with diversion were significantly more injured and ill than those being reconstituted. The anastomotic leak rate was 6.6%, with one leak from the stump of a Hartmann's pouch in the diverted group and four deaths related to anastomotic failure. Multivariate analysis showed no significant difference in mortality or abdominal complications between diversion and primary anastomosis groups. The authors concluded that "patients can be managed by primary repair regardless of risk factors." This study certainly demonstrates a liberal use of resection and primary anastomosis in a relatively sick and injured cohort of patients. However, the ultimate decision for the choice of operation was up to the discretion of the surgeon at the time of operation, for which there is no substitute.

At laparotomy, the bowel should be examined in its entirety after all other sources of major bleeding are controlled. Small injuries should be noted and tagged with an identifiable suture for easy reference. Larger wounds contributing to ongoing soiling can be temporarily controlled with a "whip stitch" (quick running suture) or Babcock clamps. Mesenteric injuries are identified and active bleeding controlled appropriately. Attention should be directed to the location of the superior mesenteric artery for injuries encroaching on the root of the mesentery. Mesenteric hematomas should be explored with ligation of injured vessels and mesenteric defects closed by careful reapproximation of the peritoneal edges so as not to compromise any feeding vessels. Bowel viability should be noted in relation to any mesenteric injury. Clusters of grade I through III injuries may be resected or individually repaired depending on the particular injury pattern. In blunt trauma, there is usually only one or two grade II or III wounds that can be repaired primarily or one or more devitalized segments that require resection.

Small, superficial grade I injuries can be left alone while deeper, longer grade I injuries can be closed with a simple running suture or interrupted Lembert sutures. Grades II and III wounds should be debrided back to healthy, viable bowel and closed transversely preventing narrowing of the lumen of the bowel. Single layer running or interrupted closure is generally sufficient for repair of the small bowel. When there is significant bowel wall edema, peritonitis or soiling, a two-layer closure with a running inner layer and interrupted Lembert outer layer may be preferential. Grades I and II colon wounds may be managed with single layer closure, but we usually close grade III colon wounds in two layers for added protection.

The leak rate associated with stapled versus hand-sewn anastomosis for destructive wounds of the bowel has been an area of controversy. In two retrospective studies totaling 284 patients undergoing stapled versus hand-sewn anastomosis, Brundage et al showed that hand-sewn procedures

had lower leak rates.<sup>130,131</sup> Two other retrospective studies totaling 484 patients showed no difference in the leak rate of stapled versus hand-sewn procedures.<sup>132,133</sup> Brundage's two studies included 78 colon wounds while the other studies were confined only to the small bowel. Stapled procedures may be a little quicker, particularly if there is more than one anastomosis. In general, the technique chosen according to the literature can be a matter of personal preference. With edematous bowel, the hand-sewn technique is a more prudent approach.

## SUMMARY

In addition to the management of abdominal trauma that has been underscored throughout the chapter for both penetrating and blunt trauma, there are several proposed treatment paradigms for many of the injuries sustained in trauma. However, the standard-of-care management for an individual is heavily dependent on the resources and personnel available, along with transport options, if any. There are resource-rich trauma systems throughout the country, with highly qualified personnel. However, these systems are not uniform throughout the nation, and the concept of regionalization has not been perfected for all the regions in the country. The overarching goal remains the same: optimal management for everyone, irrespective of where the patient receives trauma care.

## REFERENCES

- Loria FL. Historical aspects of penetrating wounds of the abdomen. *Int Abstrc Surg*. 1948;87:521–549.
- Shafton GW. Indications for operations in abdominal trauma. *Am J Surg*. 1960;99:657–662.
- Nance FC, Cohn I. Surgical judgment in the management of stab wounds of the abdomen: a retrospective and prospective analysis based on a study of 600 stabbed patients. *Ann Surg*. 1969;170:569–590.
- American College of Surgeons Committee on Trauma. *Advanced Trauma Life Support*<sup>®</sup>. 6th ed. Chicago, IL: American College of Surgeons; 1997.
- Rouse DA. Patterns of stab wounds: a six-year study. *Med Sch Law*. 1994;34:67–71.
- Dimaio VJM. *Gunshot Wounds: Practical Aspects of Firearms, Ballistics, and Forensic Techniques*. Boca Raton, FL: CRC Press; 1985:163–226, 257–265.
- Moore EE, Dunn EL, Moore JB, Thompson JS. Penetrating abdominal index. *J Trauma*. 1981;21:439–442.
- Croce MA, et al. Correlation of abdominal trauma index and injury severity score with abdominal septic complications in penetrating and blunt trauma. *J Trauma*. 1992;32:380–392.
- Demernada D, Rabinowitz B. Indications for operation in abdominal stab wounds. *Ann Surg*. 1987;205:129–132.
- Shore RM, et al. Selective management of abdominal stab wounds. *Arch Surg*. 1988;123:1141–1145.
- Kester DE, Andrassy RJ, Aust JB. The value and cost effectiveness of abdominal roentgenograms in the evaluation of stab wounds to the abdomen. *Surg Gynecol Obstet*. 1986;162:337.
- Root HD, et al. Diagnostic peritoneal lavage. *Surgery*. 1965;57:633.
- Merlotti GJ et al. Use of peritoneal lavage to evaluate abdominal penetration. *J Trauma*. 1985;25:228.
- Thal ER. Peritoneal lavage: reliability of RBC count in patients with stab wounds to the chest. *Arch Surg*. 1984;119:579.
- Oreskovich MR, Crrico CJ. Stab wounds of the anterior abdomen: analysis of management plan using local wound exploration and quantitative peritoneal lavage. *Ann Surg*. 1983;198:411.
- Alyono D, Morrwo CE, Perry JF, Jr. Reappraisal of diagnostic peritoneal lavage criteria for operation in penetrating and blunt trauma. *Surgery*. 1982;92:751.
- Feliciano DV, et al. Five hundred open taps or lavages in patients with abdominal stab wounds. *Am J Surg*. 1984;148:772.
- Hauser CJ, et al. Triple contrast computed tomography in the evaluation of penetrating posterior abdominal injuries. *Arch Surg*. 1987;122:1112.
- Demetriades D, Cahralambides D, Lakhoo M, Pantonowitz D. Gunshot wounds of the abdomen: the role of selective conservative management. *Br J Surg*. 1996;78:220.
- Kristensen JK, Bueman B, Kuhl E. Ultrasonic scanning in the diagnostic splenic hematoma. *Acta Chir Scand*. 1971;137:653–657.
- Kimura A, Otsuka T. Emergency center ultrasonography in the evaluation of hemoperitoneum: a prospective study. *J Trauma*. 1991;31:20.
- Rozychi GS, et al. A prospective study of surgeon-performed ultrasound as the primary adjuvant modality for injured patient assessment. *J Trauma*. 1995;39:492–498.
- Ivatury RR, Simon RJ, Stahl WM. A critical evaluation of laparoscopy in penetrating abdominal trauma. *J Trauma*. 1993;34:822.
- Fabian TC, et al. A prospective analysis of diagnostic laparoscopy in trauma. *Ann Surg*. 1993;217:557.
- George SM, Fabian TC, Voeller GR, Kudsk KA, Mangiante EC, Britt LG. Primary repair of colon wounds. *Ann Surg*. 1989;209:728–734.
- George SM, Fabian TC, Voeller GR, Kudsk KA, Mangiante EC, Britt LG. Primary repair of colon wounds. *Ann Surg*. 1989;209:728–734.
- Vaughan G, et al. The use of pyloric exclusion in the management of severe duodenal injuries. *Am J Surg*. 1977;134:785.
- Cogbill T, et al. Conservative management of duodenal traumas: a multi-center perspective. *J Trauma*. 1990;30:1461.
- Asensio J, Feliciano DV, Britt LD, Kerskin MD. Management of complex duodenal injuries. *Curr Probl Surg*. 1993;30:1023–1093.
- Rotondo MF, et al. "Damage control": an approach for improved survival in exsanguinating penetrating abdominal injury. *J Trauma*. 1993;35:375–381.
- Shapiro MB, Jenkins DH, Schwab CW, Rotondo MF. Damage control: collective review. *J Trauma*. 2000;49:969–978.
- Feliciano DV, Mattox KL, Jordan GL. Intraabdominal packing for control of hepatic hemorrhage: a reappraisal. *J Trauma*. 1981;21:285–291.
- Burch JM, Ortiz VB, Richardson RJ, Martin RR, Mattox KL, Jordan GL. Abbreviated laparotomy and planned reoperation for critically injured patients. *Ann Surg*. 1992;215:476–483.
- Hirschberg A, Mattox KL. Planned reoperation for severe trauma. *Ann Surg*. 1995;222:3–8.
- MacKenzie EJ, et al. A national evaluation of the effect of trauma-center care on mortality. *N Engl J Med*. 2006;354(4):366–378.
- Root HD, et al. Diagnostic Peritoneal Lavage. *Surgery*. 1965;57:633–637.
- Fischer RP, et al. Diagnostic peritoneal lavage: fourteen years and 2,586 patients later. *Am J Surg*. 1978;136(6):701–704.
- Smith SB, Andersen CA. Abdominal trauma: the limited role of peritoneal lavage. *Am Surg*. 1982;48(10):514–517.
- Henneman PL, et al. Diagnostic peritoneal lavage: accuracy in predicting necessary laparotomy following blunt and penetrating trauma. *J Trauma*. 1990;30(11):1345–1355.
- Krausz MM, et al. Peritoneal lavage in blunt abdominal trauma. *Surg Gynecol Obstet*. 1981;152(3):327–330.
- Moore JB, et al. Diagnostic peritoneal lavage for abdominal trauma: superiority of the open technique at the infraumbilical ring. *J Trauma*. 1981;21(7):570–572.
- Jacob ET, Cantor E. Discriminate diagnostic peritoneal lavage in blunt abdominal injuries: accuracy and hazards. *Am Surg*. 1979;45(1):11–14.
- Bilge A, Sahin M. Diagnostic peritoneal lavage in blunt abdominal trauma. *Eur J Surg*. 1991;157(8):449–451.
- DeMaria EJ. Management of patients with indeterminate diagnostic peritoneal lavage results following blunt trauma. *J Trauma*. 1991;31(12):1627–1631.
- van Dongen LM, de Boer HH. Peritoneal lavage in closed abdominal injury. *Injury*. 1985;16(4):227–229.



46. Felice PR, Morgan AS, Becker DR. A prospective randomized study evaluating periumbilical versus infraumbilical peritoneal lavage: a preliminary report. A combined hospital study. *Am Surg.* 1987;53(9):518–520.
47. Cue JI, et al. A prospective, randomized comparison between open and closed peritoneal lavage techniques. *J Trauma.* 1990;30(7):880–883.
48. Wilson WR, Schwarcz TH, Pilcher DB. A prospective randomized trial of the Lazarus-Nelson vs. the standard peritoneal dialysis catheter for peritoneal lavage in blunt abdominal trauma. *J Trauma.* 1987;27(10):1177–1180.
49. Lopez-Viego MA, Mickel TJ, Weigelt JA. Open versus closed diagnostic peritoneal lavage in the evaluation of abdominal trauma. *Am J Surg.* 1990;160(6):594–596; discussion 596–597.
50. Branney SW, et al. Quantitative sensitivity of ultrasound in detecting free intraperitoneal fluid. *J Trauma.* 1995;39(2):375–380.
51. Hoff WS, et al. Practice management guidelines for the evaluation of blunt abdominal trauma: the East practice management guidelines work group. *J Trauma.* 2002;53(3):602–615.
52. Rozycki GS, et al. A prospective study of surgeon-performed ultrasound as the primary adjuvant modality for injured patient assessment. *J Trauma.* 1995;39(3):492–498; discussion 498–500.
53. Boulanger BR, et al. Emergent abdominal sonography as a screening test in a new diagnostic algorithm for blunt trauma. *J Trauma.* 1996;40(6):867–874.
54. Branney SW, et al. Ultrasound based key clinical pathway reduces the use of hospital resources for the evaluation of blunt abdominal trauma. *J Trauma.* 1997;42(6):1086–1090.
55. Livingston DH, et al. Admission or observation is not necessary after a negative abdominal computed tomographic scan in patients with suspected blunt abdominal trauma: results of a prospective, multi-institutional trial. *J Trauma.* 1998;44(2):273–280; discussion 280–282.
56. Moore EE, et al. Organ injury scaling: spleen and liver (1994 revision). *J Trauma.* 1995;38(3):323–324.
57. Moore EE, et al. Organ injury scaling: spleen, liver, and kidney. *J Trauma.* 1989;29(12):1664–1666.
58. Holmes JF, et al. Performance of helical computed tomography without oral contrast for the detection of gastrointestinal injuries. *Ann Emerg Med.* 2004;43(1):120–128.
59. Allen TL, et al. Computed tomographic scanning without oral contrast solution for blunt bowel and mesenteric injuries in abdominal trauma. *J Trauma.* 2004;56(2):314–322.
60. Stafford RE, et al. Oral contrast solution and computed tomography for blunt abdominal trauma: a randomized study. *Arch Surg.* 1999;134(6):622–626; discussion 626–627.
61. Bee TK, et al. Failures of splenic nonoperative management: is the glass half empty or half full? *J Trauma.* 2001;50(2):230–236.
62. Haan JM, et al. Splenic embolization revisited: a multicenter review. *J Trauma.* 2004;56(3):542–547.
63. Peitzman AB, et al. Blunt splenic injury in adults: Multi-institutional Study of the Eastern Association for the Surgery of Trauma. *J Trauma.* 2000;49(2):177–187; discussion 187–189.
64. Weinberg JA, et al. The utility of serial computed tomography imaging of blunt splenic injury: still worth a second look? *J Trauma.* 2007;62(5): p. 1143–1147; discussion 1147–1148.
65. Gaarder C, et al. Nonoperative management of splenic injuries: improved results with angioembolization. *J Trauma.* 2006;61(1):192–198.
66. Myers JG, et al. Blunt splenic injuries: dedicated trauma surgeons can achieve a high rate of nonoperative success in patients of all ages. *J Trauma.* 2000;48(5):801–805; discussion 805–806.
67. Cocanour CS, et al. Age should not be a consideration for nonoperative management of blunt splenic injury. *J Trauma.* 2000. 48(4):606–610; discussion 610–612.
68. Schurr MJ, et al. Management of blunt splenic trauma: computed tomographic contrast blush predicts failure of nonoperative management. *J Trauma.* 1995;39(3):507–512; discussion 512–513.
69. Raikhlin A, et al. Imaging and transcatheter arterial embolization for traumatic splenic injuries: review of the literature. *Can J Surg.* 2008; 51(6):464–472.
70. Davis KA, et al. Improved success in nonoperative management of blunt splenic injuries: embolization of splenic artery pseudoaneurysms. *J Trauma.* 1998;44(6):1008–1013; discussion 1013–1015.
71. Zarzur BL, et al. The real risk of splenectomy after discharge home following nonoperative management of blunt splenic injury. *J Trauma.* 2009;66(6):1531–1536; discussion 1536–1538.
72. Savage, S.A., et al., The evolution of blunt splenic injury: resolution and progression. *J Trauma.* 2008;64(4): p. 1085–1091; discussion 1091–1092.
73. Holdsworth RJ, Irving AD, Cuschieri A. Postsplenectomy sepsis and its mortality rate: actual versus perceived risks. *Br J Surg.* 1991;78(9): 1031–1038.
74. American Academy of Pediatrics. Committee on Infectious Diseases. Policy statement: recommendations for the prevention of pneumococcal infections, including the use of pneumococcal conjugate vaccine (Pnevnar), pneumococcal polysaccharide vaccine, and antibiotic prophylaxis. *Pediatrics.* 2000;106(2 Pt 1):362–366.
75. Croce MA, et al. Nonoperative management of blunt hepatic trauma is the treatment of choice for hemodynamically stable patients. Results of a prospective trial. *Ann Surg.* 1995;221(6):744–753; discussion 753–755.
76. Malhotra AK, et al. Blunt hepatic injury: a paradigm shift from operative to nonoperative management in the 1990s. *Ann Surg.* 2000; 231(6):804–813.
77. Delius RE, Frankel RE, Coran AG. A comparison between operative and nonoperative management of blunt injuries to the liver and spleen in adult and pediatric patients. *Surgery.* 1989;106(4):788–792; discussion 792–793.
78. Christmas AB, et al. Selective management of blunt hepatic injuries including nonoperative management is a safe and effective strategy. *Surgery.* 2005;138(4):606–610; discussion 610–611.
79. Velmahos GC, et al. High success with nonoperative management of blunt hepatic trauma: the liver is a sturdy organ. *Arch Surg.* 2003;138(5): 475–480; discussion 480–481.
80. David Richardson J, et al. Evolution in the management of hepatic trauma: a 25-year perspective. *Ann Surg.* 2000;232(3):324–330.
81. Meredith JW, et al. Nonoperative management of blunt hepatic trauma: the exception or the rule? *J Trauma.* 1994;36(4):529–534; discussion 534–535.
82. Pachter HL, et al. Status of nonoperative management of blunt hepatic injuries in 1995: a multicenter experience with 404 patients. *J Trauma.* 1996;40(1):31–38.
83. Wahl WL, et al. The need for early angiographic embolization in blunt liver injuries. *J Trauma.* 2002;52(6):1097–1101.
84. Johnson JW, et al. Hepatic angiography in patients undergoing damage control laparotomy. *J Trauma.* 2002;52(6):1102–1106.
85. Mohr AM, et al. Angiographic embolization for liver injuries: low mortality, high morbidity. *J Trauma.* 2003;55(6):1077–1081; discussion 1081–1082.
86. Hagiwara A, et al. The usefulness of transcatheter arterial embolization for patients with blunt polytrauma showing transient response to fluid resuscitation. *J Trauma.* 2004;57(2):271–276; discussion 276–277.
87. Misselbeck TS, et al. Hepatic angioembolization in trauma patients: indications and complications. *J Trauma.* 2009;67(4):769–773.
88. Asensio JA, et al. Approach to the management of complex hepatic injuries. *J Trauma.* 2000;48(1):66–69.
89. Buckman RF, Jr, Miraliakbari R, Badellino MM. Juxtahepatic venous injuries: a critical review of reported management strategies. *J Trauma.* 2000;48(5):978–984.
90. Fang JF, et al. Classification and treatment of pooling of contrast material on computed tomographic scan of blunt hepatic trauma. *J Trauma.* 2000;49(6):1083–1088.
91. Ciraulo DL, et al. Selective hepatic arterial embolization of grade IV and V blunt hepatic injuries: an extension of resuscitation in the nonoperative management of traumatic hepatic injuries. *J Trauma.* 1998;45(2): 353–358; discussion 358–359.
92. Maxwell RA, et al. Secondary abdominal compartment syndrome: an underappreciated manifestation of severe hemorrhagic shock. *J Trauma.* 1999;47(6):995–999.
93. Pringle JH. V. Notes on the arrest of hepatic hemorrhage due to trauma. *Ann Surg.* 1908;48(4):541–549.
94. Heaney JP, et al. An improved technic for vascular isolation of the liver: experimental study and case reports. *Ann Surg.* 1966;163(2):237–241.
95. Schrock T, Blaisdell FW, Mathewson C, Jr. Management of blunt trauma to the liver and hepatic veins. *Arch Surg.* 1968;96(5):698–704.
96. Burch JM, Feliciano DV, Mattox KL. The atriocaval shunt. Facts and fiction. *Ann Surg.* 1988;207(5):555–568.
97. Pilcher DB, Harman PK, Moore EE, Jr. Retrohepatic vena cava balloon shunt introduced via the sapheno-femoral junction. *J Trauma.* 1977;17(11):837–841.
98. Poggetti RS, et al. Balloon tamponade for bilobar transfixing hepatic gunshot wounds. *J Trauma.* 1992;33(5):694–697.



99. Baumgartner F, et al. Venovenous bypass for major hepatic and caval trauma. *J Trauma*. 1995;39(4):671–673.
100. Buechter KJ, et al. Retrohepatic vein injuries: experience with 20 cases. *J Trauma*. 1989;29(12):1698–1704.
101. Pachter HL, et al. The management of juxtahepatic venous injuries without an atriocaval shunt: preliminary clinical observations. *Surgery*. 1986;99(5):569–575.
102. Pachter HL, et al. Significant trends in the treatment of hepatic trauma. Experience with 411 injuries. *Ann Surg*. 1992;215(5):492–500; discussion 500–502.
103. Trunkey DD, Shires GT, Mc Clelland R. Management of liver trauma in 811 consecutive patients. *Ann Surg*. 1974;179(5):722–728.
104. Levin A, Gover P, Nance FC. Nance, Surgical restraint in the management of hepatic injury: a review of Charity Hospital Experience. *J Trauma*. 1978;18(6):399–404.
105. Defore WW, Jr, et al. Management of 1,590 consecutive cases of liver trauma. *Arch Surg*. 1976;111(4):493–497.
106. Reed RL, 2nd, et al. Continuing evolution in the approach to severe liver trauma. *Ann Surg*. 1992;216(5):524–538.
107. Mays ET. Editorial: The hepatic artery. *Surg Gynecol Obstet*. 1974;139(4):595–596.
108. Mays ET, Whleer CS. Demonstration of collateral arterial flow after interruption of hepatic arteries in man. *N Engl J Med*. 1974;290(18):993–996.
109. Aaron S, Fulton RL, Mays ET. Selective ligation of the hepatic artery for trauma of the liver. *Surg Gynecol Obstet*. 1975;141(2):187–189.
110. Flint LM, et al. Selectivity in the management of hepatic trauma. *Ann Surg*. 1977;185(6):613–618.
111. Feliciano DV, Mattox KL, Jordan GL, Jr. Intra-abdominal packing for control of hepatic hemorrhage: a reappraisal. *J Trauma*. 1981;21(4):285–290.
112. Feliciano DV, et al. Packing for control of hepatic hemorrhage. *J Trauma*. 1986;26(8):738–743.
113. Ivatury RR, et al. Liver packing for uncontrolled hemorrhage: a reappraisal. *J Trauma*. 1986;26(8):744–753.
114. Baracco-Gandolfo V, et al. Prolonged closed liver packing in severe hepatic trauma: experience with 36 patients. *J Trauma*. 1986;26(8):754–756.
115. Carmona RH, Peck DZ, Lim RC, Jr. The role of packing and planned reoperation in severe hepatic trauma. *J Trauma*. 1984;24(9):779–784.
116. Cue JI, et al. Packing and planned reexploration for hepatic and retroperitoneal hemorrhage: critical refinements of a useful technique. *J Trauma*. 1990;30(8):1007–1011; discussion 1011–1013.
117. Stone HH, Lamb JM. Use of pedicled omentum as an autogenous pack for control of hemorrhage in major injuries of the liver. *Surg Gynecol Obstet*. 1975;141(1):92–94.
118. Kane NM, et al. Traumatic pneumoperitoneum. Implications of computed tomography diagnosis. *Invest Radiol*. 1991;26(6):574–578.
119. Malhotra AK, et al. Blunt bowel and mesenteric injuries: the role of screening computed tomography. *J Trauma*. 2000;48(6):991–998; discussion 998–1000.
120. Sherck J, et al. The accuracy of computed tomography in the diagnosis of blunt small-bowel perforation. *Am J Surg*. 1994;168(6):670–675.
121. Moore EE, et al. Organ injury scaling, II: Pancreas, duodenum, small bowel, colon, and rectum. *J Trauma*. 1990;30(11):1427–1429.
122. Maxwell RA, Fabian TC. Current management of colon trauma. *World J Surg*. 2003;27(6):632–639.
123. Ogilvie W. Abdominal wounds in the Western desert. *Surg Gynecol Obstet*. 1944;78:225.
124. General, O.o.t.S. *Circular Letter No. 178*. 1943.
125. Cayten CG, Fabian TC, Garcia VE, Ivatury RR, Morris JA. Patient management guidelines for penetrating colon injury. *J Trauma*. 1998;44(6):941–956.
126. Chavarria-Aguilar M, et al. Management of destructive bowel injury in the open abdomen. *J Trauma*. 2004;56(3):560–564.
127. Demetriades D, et al. Penetrating colon injuries requiring resection: diversion or primary anastomosis? An AAST prospective multicenter study. *J Trauma*. 2001;50(5):765–775.
128. Stewart RM, et al. Is resection with primary anastomosis following destructive colon wounds always safe? *Am J Surg*. 1994;168(4):316–319.
129. Murray JA, et al. Colonic resection in trauma: colostomy versus anastomosis. *J Trauma*. 1999;46(2):250–254.
130. Brundage SI, et al. Stapled versus sutured gastrointestinal anastomoses in the trauma patient. *J Trauma*. 1999;47(3):500–507; discussion 507–508.
131. Brundage SI, et al. Stapled versus sutured gastrointestinal anastomoses in the trauma patient: a multicenter trial. *J Trauma*. 2001;51(6):1054–1061.
132. Witzke JD, et al. Stapled versus hand sewn anastomoses in patients with small bowel injury: a changing perspective. *J Trauma*. 2000;49(4):660–665; discussion 665–666.
133. Kirkpatrick AW, et al. Intra-abdominal complications after surgical repair of small bowel injuries: an international review. *J Trauma*. 2003;55(3):399–406.

*This page intentionally left blank*

# ABDOMINAL VASCULAR EMERGENCIES

John J. Ricotta • Cameron M. Akbari

## INTRODUCTION

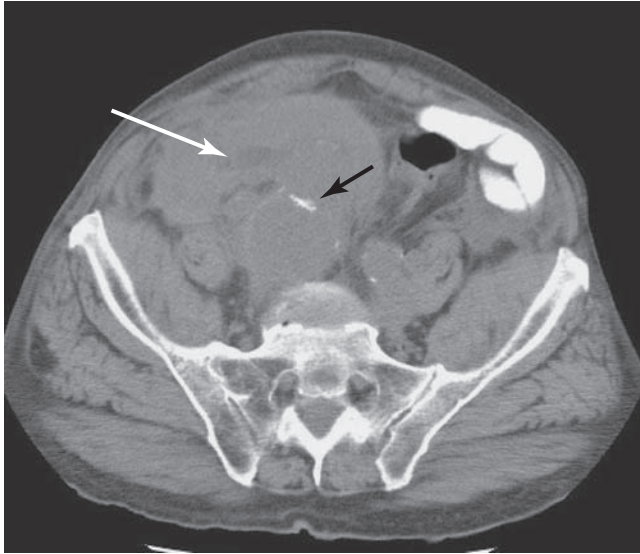
Among the many acute abdominal conditions that confront the general surgeon, disorders involving the vascular system are in the minority. Yet these conditions are often highly lethal if undiagnosed or inappropriately treated. Because operations involving vascular exposure, control, and repair are uncommon in the practice of most abdominal surgeons, a straightforward plan to identify and manage these conditions is required for optimal success. This chapter concerns itself with the general diagnosis of acute vascular abdominal conditions, principles of vascular control and repair, and a discussion of the management of the three most common types of vascular emergency: mesenteric ischemia, ruptured abdominal aneurysm, and abdominal vascular trauma. Whenever possible, emphasis is placed on general principles that can be applied to a variety of conditions. Acute pathology of the gastrointestinal tract that results in hemorrhage (eg, bleeding ulcer, esophageal varices, bleeding diverticula) is not considered within this chapter.

## GENERAL DIAGNOSTIC CONSIDERATIONS

Acute vascular conditions can be divided into those associated with hemorrhage and those accompanied by vascular thrombosis. The presentation within each of these two broad categories is generally distinct. Conditions associated with hemorrhage present with evidence of blood loss including shock. Hemodynamic alterations, for example hypotension and tachycardia, predominate over physical findings. Signs of an “acute abdomen,” specifically peritoneal irritation, are often absent. While abdominal pain is usually present, it is often focal and may be associated with a palpable abdominal mass. Signs of shock in the absence of generalized peritonitis or visceral perforation should prompt the consideration of a vascular emergency. In contrast, vascular thrombosis leads to

intestinal ischemia and perforation. The clinical presentation of vascular thrombosis is often identical to that of other acute nonvascular abdominal conditions that cause an acute abdomen. Stigmata of cardiovascular disease, for example peripheral vascular occlusions, history of cardiac disease, atrial fibrillation, vascular bruits, and advanced age, should all increase the clinical suspicion of a vascular event as the underlying cause of symptoms. Nevertheless, thrombotic vascular complications often remain undiagnosed until the time of laparotomy.

While physical examination may help to identify patients with intra-abdominal or retroperitoneal bleeding (signs of hemorrhagic shock, absence of peritonitis), routine laboratory evaluations are less helpful. Acute hemorrhage may not result in changes in hemoglobin in its early stages. Laboratory studies are generally useful in excluding other acute inflammatory states such as pancreatitis, and acute processes of the biliary tree or intestine. Plain films of the abdomen may reveal vascular calcifications or suggest hemorrhage (loss of psoas shadow) but are often nondiagnostic. Computed tomography (CT) scanning, when available, is the most useful preoperative diagnostic study (Fig. 13-1). With the addition of intravenous contrast, CT angiography (CTA) can identify vascular calcifications, aneurysms, and pseudoaneurysms; localize and quantify blood loss; and often identify thrombosis of major arterial and venous structures. Refinements in CTA, such as three-dimensional (3D) reconstructions, have markedly reduced the need for diagnostic angiography and streamlined the evaluation of all patients with acute abdominal problems. In addition to visualizing vascular structures, nonvascular findings on CT scan may raise the suspicion of an acute vascular emergency.<sup>1,2</sup> Thickening of the bowel wall and pneumatosis intestinalis may be present without an identifiable lesion in the mesenteric arterial or venous system. Evidence of visceral embolization, particularly in the spleen or liver, should suggest a proximal embolic source, most often from endocarditis. Evidence of a shrunken kidney is a sign of visceral atherosclerosis and, while a nonspecific finding, should increase suspicion of disease in other visceral beds.



**FIGURE 13-1** Noncontrast CT scan demonstrating calcium in the wall of the aorta (*dark arrow*) and retroperitoneal hematoma with fresh blood (*white arrow*) diagnostic of ruptured abdominal aortic aneurysm (AAA).

CT scanning cannot identify all acute vascular conditions, particularly when intravenous contrast is not administered, and scans may not be performed before laparotomy in a number of emergent cases. Under these circumstances, the diagnosis of an acute vascular emergency is made at the time of laparotomy. Most often this diagnosis is obvious on clinical grounds, identification of a mesenteric or retroperitoneal hematoma, presence of free blood in the abdomen, or the presence of infarcted bowel without evidence of internal hernia.

## VASCULAR EXPOSURE AND CONTROL

Expedient vascular exposure and control is essential for optimal management of vascular emergencies. The principles of operative vascular control are well established: proximal and distal control in a relatively normal area of the vessel. Proximal control should always be established before the lesion is addressed. When attempts to establish distal control would result in excessive dissection or cause damage to adjacent tissues and organs, the vessel is opened after proximal control is established and distal control established intraluminally by placing balloon catheters to control back bleeding. Increasingly, intraluminal techniques are being used for establishing proximal arterial control from remote access sites. *Antegrade* intravascular balloon control can be established without concern for balloon migration from arterial pulsation. A good example of this is placement of an arterial occlusion balloon in the suprarenal abdominal aorta through the arm vessels.<sup>3</sup> When the balloon catheter is placed from a site distal to the

artery (retrograde control), the balloon must be buttressed to avoid migration as a result of the repetitive force of arterial pressure.<sup>4</sup> This can be done by supporting the catheter and balloon by a rigid sheath on which the balloon can rest. Balloon catheters can be used to tamponade proximal collateral bleeding if the main arterial inflow has otherwise been controlled. The most common example of this is the combination of supraceliac clamping coupled with placement of a Foley catheter to control collateral visceral back bleeding during repair of a ruptured aortic aneurysm.

In cases of active hemorrhage or when dissection is difficult, initial venous control is usually obtained by external pressure. Extensive venous dissection is usually avoided to reduce iatrogenic venous damage. Circumferential venous dissection must be meticulous because of the many venous tributaries and the fragility of the vein wall. Intraluminal balloons can be combined with external compression for both proximal and distal control in cases of venous injury, because this is a low-pressure system and catheter dislodgement is not a problem.

Endovascular techniques have been applied across all aspects of vascular surgery, and management of abdominal vascular emergencies is no exception. However, the application of most of these techniques requires angiographic capabilities in the operating room and significant endovascular experience. In routine practice, the most expeditious way to achieve control remains open exposure. Endovascular techniques remain most useful when they replace extensive or dangerous open dissection. While endovascular options will be discussed within the context of each disease process, these approaches will not be described in detail within this chapter. What follows is a description of the open surgical approach to control of the major abdominal vessels.

## Exposure of the Aorta

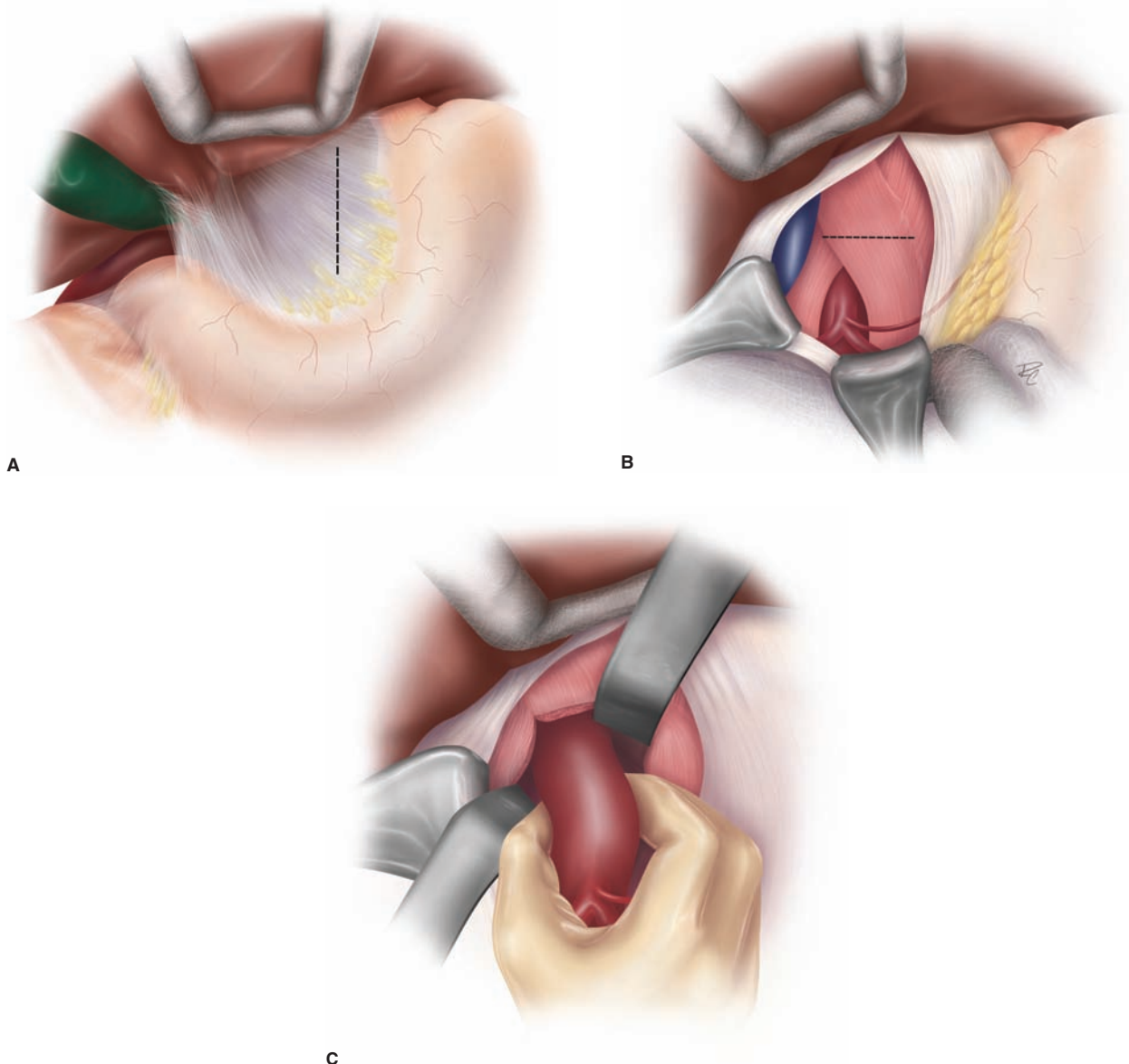
### SUPRACELIAC EXPOSURE

Expedient suprasceliac control of the abdominal aorta is the most important and versatile technique in the management of abdominal vascular emergencies. While suprarenal, intrarenal, and occasionally supramesenteric controls of the aorta are all possible, there is no evidence that these prove superior to suprasceliac aortic control as long as visceral ischemia is limited to 45 minutes or less. Suprasceliac aortic control can be achieved rapidly with very little risk of damage to adjacent organs such as the intestines, pancreas, or vena cava or the visceral vessels. Finally, the suprasceliac aorta is most likely to be free of either aneurysmal or atherosclerotic vascular disease. For this reason, exposure and control of the aorta at that level is easier and safer than control between the visceral vessels.<sup>5</sup> Suprasceliac control of the aorta through a left retroperitoneal approach has been well described<sup>6</sup> but is not germane in this situation, because it precludes evaluation of the abdominal viscera. Therefore, only the transabdominal exposure of the suprasceliac aorta is described.



The supraceliac aorta is approached through the gastrohepatic ligament, which is divided between clamps (Fig. 13-2A). The left lobe of the liver is mobilized by dividing its diaphragmatic attachments if necessary. Division of the gastrohepatic ligament brings one directly down on to the esophagus and aorta as they course through the diaphragmatic hiatus. The aorta lies to the right of the esophagus and should be easily palpable. In the event that the two organs are not easily distinguishable, a nasogastric or orogastric tube may be placed in the esophagus to aid in distinguishing, but this is rarely required in our experience. Once the aorta has been identified, the key to obtaining control is complete division of the fibers of the left crus of the diaphragm as they cross

the anterior aspect of the aorta (Fig. 13-2B). This can be done by placing either the index finger or a large-angled clamp between the aorta and the crural fibers as they cross over its anterior aspect. The fibers are divided, slightly to the left of the midline (“2 o’clock” position) to avoid bleeding, either with scissors or electrocautery. The phrenic arteries are identified and either clipped or, preferentially, spared. One cannot overemphasize the importance of completely dividing these fibers and clearing the anterior, medial, and lateral aspects of the aorta prior to applying the vascular clamp. If this is not done, any aortic clamp will slip anteriorly, resulting in loss of aortic control with disastrous results. Once the crura are divided, the aorta is encircled between the thumb and index

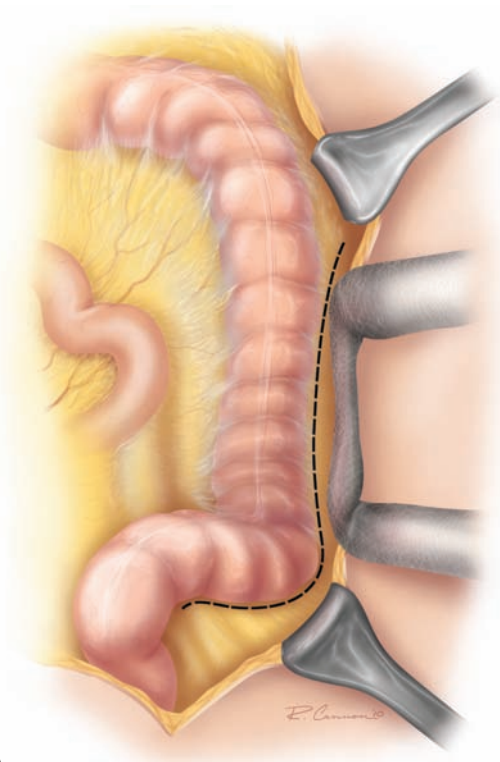


**FIGURE 13-2** Exposure of supraceliac aorta. **A.** Division of gastrohepatic ligament. **B.** Line of incision in left crus of diaphragm to expose aorta. This is facilitated by placing a finger or a clamp between aorta and crural fibers. **C.** The aorta is then encircled bluntly using finger dissection.

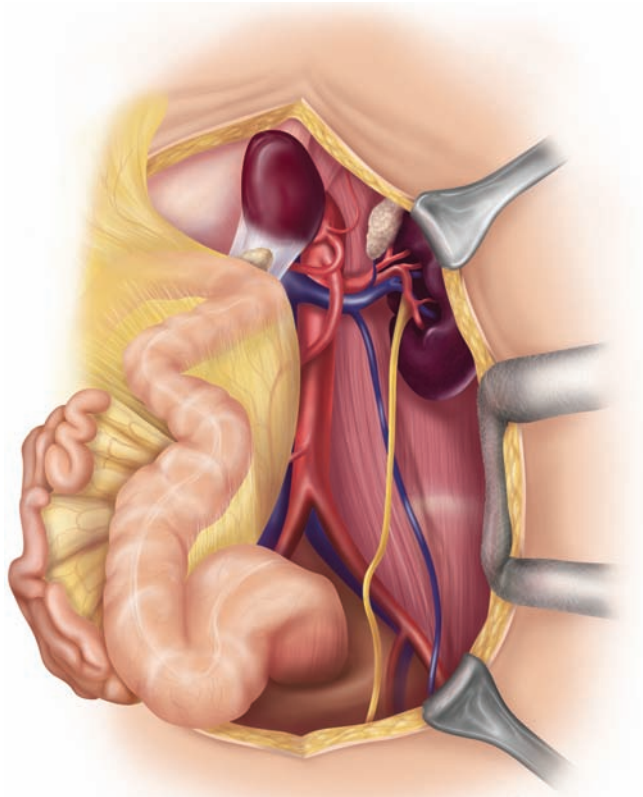
finger of the operating surgeon's right hand (Fig. 13-2C). The aorta is then lifted gently off the spine to be sure that it has been completely mobilized. A clamp can then be reliably placed across the aorta. More extensive dissection of the aorta is not required and we avoid passing angled clamps and loops under the aorta to minimize damage to intercostal vessels. Use of the index finger and a straight aortic clamp are all that is required.

### EXPOSURE OF THE VISCERAL AORTA

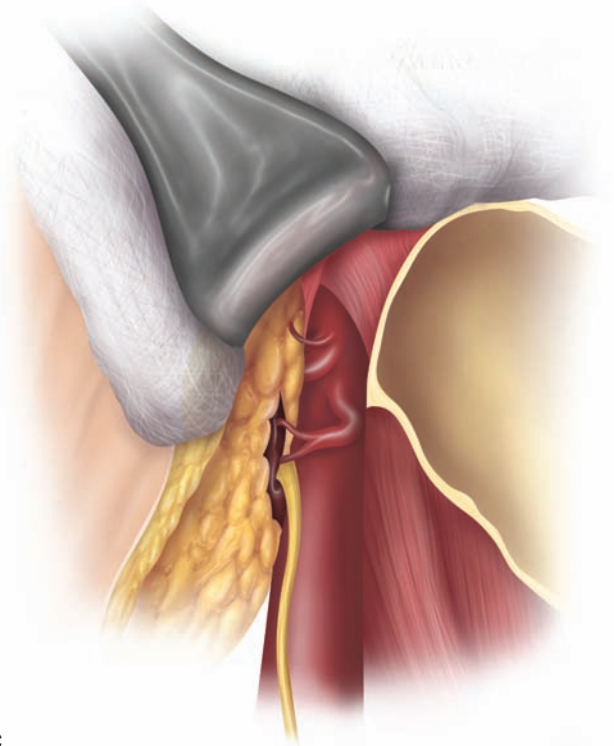
This area of the aorta will rarely need to be exposed for acute vascular emergencies. Transperitoneal control of the visceral aorta requires a left medial visceral rotation.<sup>7</sup> The left colon is mobilized along Toldt's line (Fig. 13-3A), the retroperitoneal and phrenic attachments of the spleen are divided, and the spleen, colon, and tail of the pancreas are reflected medially, leaving the left kidney down (Fig. 13-3B). This results in exposure of the anterior aspect of the aorta, and the origins of the renal, celiac, and superior mesenteric arteries (SMAs). If exposure of the posterior aspect of the aorta is required, the left kidney is elevated with the other viscera (Fig. 13-3C). Exposure of the visceral vessels more distally is described as follows.



A



B



C

**FIGURE 13-3** Left medial visceral rotation. **A.** Mobilization of the left colon along Toldt's line. The spleen and pancreas are also mobilized. **B.** With reflection of the spleen, pancreas, and colon anteriorly toward the midline, the anterior aspect of the aorta is exposed along with the origins of the left renal, superior mesenteric, and celiac arteries. The aortic hiatus may need to be incised to provide additional cephalad exposure. **C.** If access to the posterior aspect of the aorta is required, the left kidney is mobilized outside Gerota's fascia, along with the other viscera.

### INFRARENAL AORTIC EXPOSURE

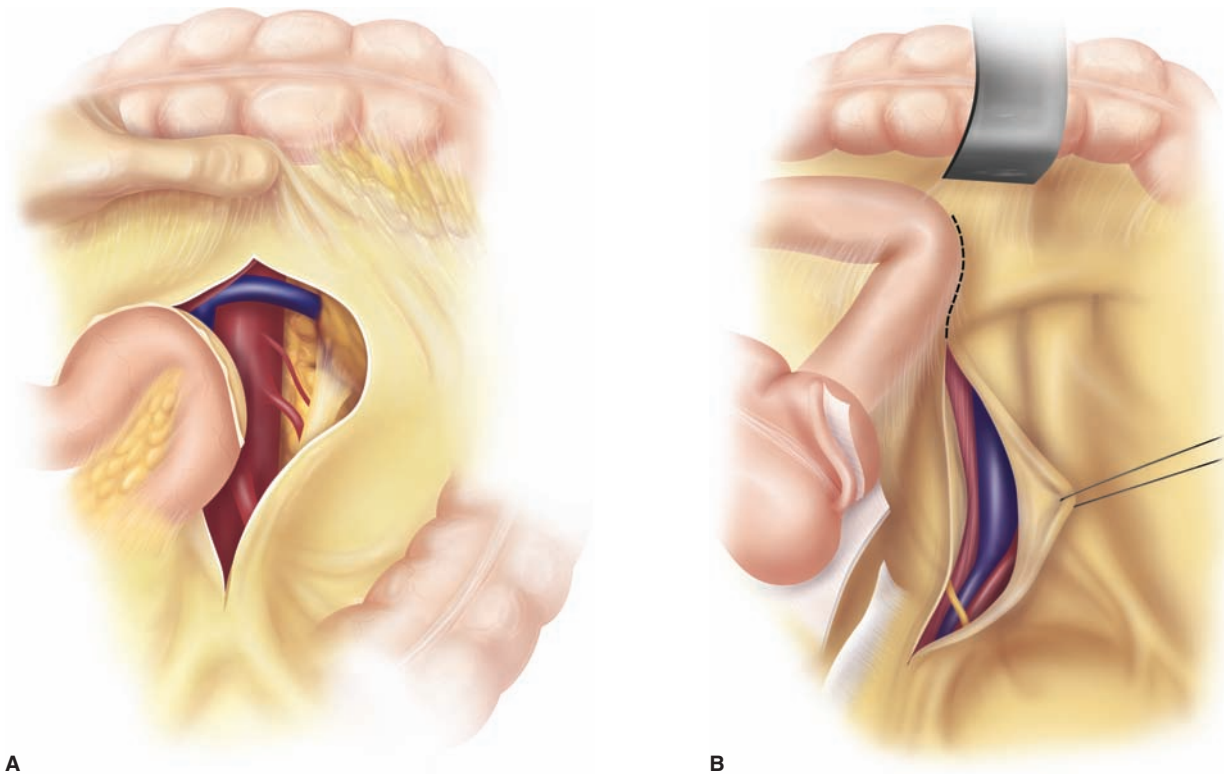
This technique is familiar to most surgeons and involves incision of the ligament of Treitz and mobilization of the fourth portion of the duodenum superiorly and to the right (Fig. 13-4). When encountered, the inferior mesenteric vein may be divided between clamps. This sometimes improves exposure and is preferable to leaving an intact vein under tension with the risk of avulsion. The left renal vein serves as a reference to identify the superior extent of dissection. This vein almost never requires division. Should additional mobilization be required, the gonadal and lumbar veins can be divided for superior mobility and the adrenal vein is divided if the vein is to be retracted inferiorly. If these collaterals are divided and the renal vein is subsequently sacrificed, it must be repaired, either primarily or with an interposition graft. If the left renal vein is *not* encountered during this dissection, one must consider the possibility of an aberrant renal vein coursing posterior to the aorta, which occurs in 1% of patients.<sup>8</sup> In that case, the vein is at risk for damage during aortic cross clamping.

Lymphatic and areolar tissue anterior to the aorta is cauterized or divided and ligated between clamps. It is better to ligate large lymphatics to prevent chyle leak postoperatively. As with the suprarenal aorta, the vessel is encircled using the thumb

and index finger and lumbar vessels usually do not require division. We are more inclined to place a tape around the aorta in the infrarenal location, because visualization is optimal, but this is not required. As described previously, the aorta is circumferentially mobilized digitally, raised off the spine, and an aortic cross clamp is placed under direct vision.

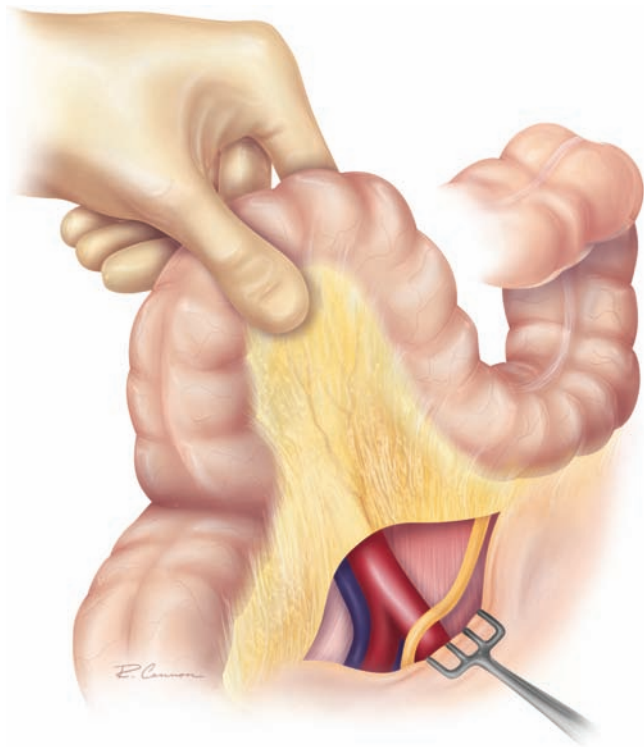
### Exposure of the Iliac Arteries

The common and external iliac arteries are controlled after entering the retroperitoneum. For proximal iliac control, the small bowel mesentery is reflected to the right and the aortic bifurcation is exposed. For more distal control, particularly of the external iliac arteries, the right or left colon is mobilized along Toldt's line and reflected toward the midline (Fig. 13-5). It is important to be mindful of the ureter as it crosses over the iliac bifurcation. Control of the iliac arteries at the aortic bifurcation can be dangerous because of the confluence of the iliac veins behind the right iliac artery. This is one of the most common sites of iatrogenic vascular injury during aortoiliac surgery. The venous structures are gently separated from the arteries by use of blunt dissection



**FIGURE 13-4** **A.** Exposure of the infrarenal aorta. The ligament of Treitz is divided and third and fourth portion of the duodenum are mobilized. The left renal vein is used to identify the superior extent of dissection. The inferior mesenteric vein may be divided. The more distal superior mesenteric artery (SMA) can also be exposed in this manner, although the origin of the vessel will not be reached (see Fig. 13-3). **B.** Exposure of the iliac vessels. The common iliac vessels and much of the right external iliac artery are exposed by continuing the mobilization of the small bowel and cecum medially and superiorly.





**FIGURE 13-5** Exposure of the distal iliac vessels is performed by incising the lateral attachments of the sigmoid or cecum and retracting the bowel medially. Note the ureter as it crosses the iliac bifurcation.

(sponge on stick, kitner dissector or digital dissection). We avoid use of clamps to dissect around the iliac vessels whenever possible. Once the vessels are separated from the adjacent venous structures, they can be encircled with vessel loops and clamped. Relatively blind clamping of the iliac arteries without dissection away from surrounding veins is discouraged as venous injury may result with disastrous consequences.

The hypogastric arteries and distal external iliac arteries can be difficult to expose, particularly in a deep pelvis. The hypogastric artery in particular may present challenges with the risk of injury to deep pelvic veins. This artery can usually be controlled by retrograde balloon tamponade and oversewn. The very distal external iliac artery can be controlled with an intravascular balloon and, if necessary, oversewn. Vascular continuity can be restored by a bypass to the common femoral artery.

### EXPOSURE OF THE CELIAC ARTERY AND ITS BRANCHES

Exposure of the proximal celiac artery can be obtained through the gastrohepatic ligament, as described for the suprarenal aorta, or by left medial visceral rotation. We prefer the former approach whenever possible. The celiac artery is identified as it originates from the aorta at the diaphragmatic hiatus. Division of diaphragmatic fibers facilitates proximal

exposure. More distal control is achieved by careful dissection along the anterior aspect of the vessel with caudal traction on the stomach and superior border of the pancreas. The tissue surrounding the vessel is carefully divided and ligated.

By opening the gastrohepatic ligament along the lesser curvature of the stomach, one can trace and isolate the common hepatic artery superior to the pancreas. The proper hepatic artery courses in the portal triad anterior and medial to the portal vein. The standard techniques for exposure of the porta hepatis will serve to identify and isolate this structure. The splenic artery is exposed by entering the lesser sac and reflecting the pancreas inferiorly and anteriorly. The multiple branches of this vessel that supply the pancreas must be ligated for adequate exposure. The distal splenic artery is best exposed by mobilizing the spleen as for splenectomy.

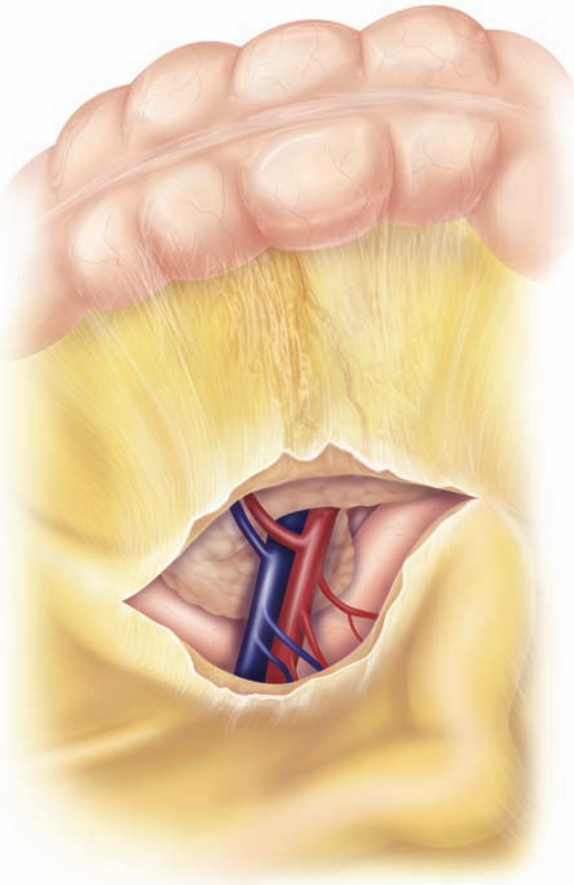
### EXPOSURE OF THE SUPERIOR MESENTERIC ARTERY

Transabdominal control of the superior mesenteric artery (SMA) at its origin requires medial visceral rotation of the left colon, spleen, and tail of the pancreas.<sup>7</sup> Exposure of the more distal SMA can be done through the base of the small bowel mesentery or by approaching the vessel on its posteromedial aspect after reflecting the small bowel mesentery to the right (as in standard aortic exposure). In the former approach, the transverse colon is elevated and the middle colic vessel is traced down to the SMA in the small bowel mesentery (Fig. 13-6). The anterior aspect of the vessel is cleared, taking care not to injure the adjacent vein. In the latter approach, the vessel is palpated in the root of the small bowel mesentery and dissection proceeds on the lateral aspect of the vessel (see Fig. 13-4A). In either case, dissection requires meticulous division and ligation of small venous, arterial and lymphatic branches, and the preservation of as many major arterial and venous branches as possible.

### EXPOSURE OF THE RENAL ARTERIES

Transperitoneal control of the renal arteries can be achieved in a variety of ways, depending on the area of the artery to be controlled. The left renal artery is exposed in the same manner as the infrarenal aorta. The artery is usually superior and posterior to the left renal vein. The renal vein may require mobilization, including division of its lumbar, gonadal, or adrenal tributaries. Occasionally, the retroperitoneal attachments at the inferior border of the pancreas must be incised so the pancreas can be retracted in a cephalad fashion. The renal artery can be traced distally from its origin at the aorta. If the distal renal artery, near the hilum of the kidney, requires exposure, this is most easily done by mobilizing the left colon toward the midline. This may require mobilization of the splenic flexure and occasionally the tail of the pancreas, although this is not always the case. The proximal right renal artery can be exposed for a short segment between the aorta and inferior





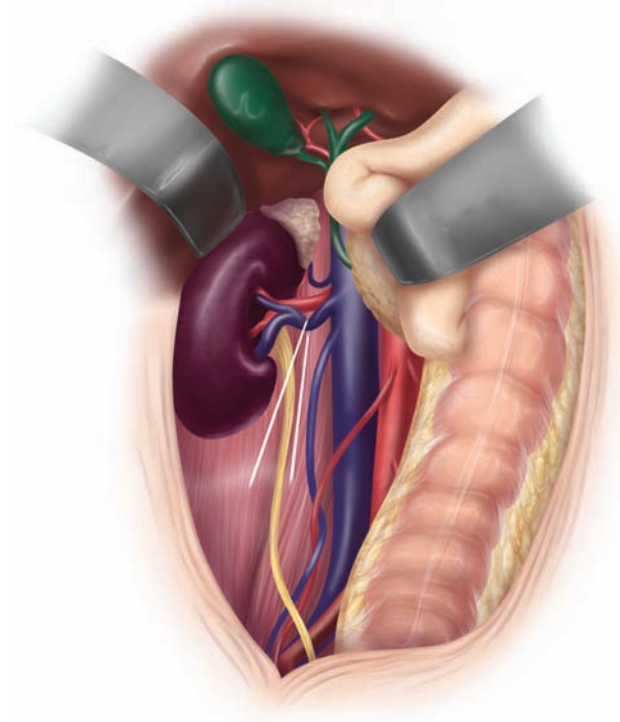
**FIGURE 13-6** Exposure of the superior mesenteric artery (SMA) through the mesocolon. The colon is lifted cephalad and the small bowel mesentery pulled caudally. The middle colic artery is identified and followed down to the SMA. Alternative SMA exposure is shown in Fig. 13-4A.

vena cava (IVC). The first part of the exposure is similar to that for the infrarenal aorta. Because the right renal artery runs *behind* the IVC, significant proximal exposure of this vessel requires mobilization of the vena cava and retracting it to the right. This requires careful division of one and often two sets of lumbar veins. Even with this maneuver, only the most proximal portion of the renal artery is exposed. As a result, the right renal artery is most often exposed by an extended Kocher maneuver; which reflects the duodenum, ascending colon and hepatic flexure toward the midline.<sup>9</sup> The artery again lies posterior and inferior to the renal vein, which often requires mobilization.

#### EXPOSURE OF THE VENOUS STRUCTURES

The visceral veins are exposed by the same approaches as their corresponding arteries. Exposure of the vena cava and iliac veins requires some discussion. In general, these vessels are not involved in acute abdominal vascular emergencies outside the trauma setting. However, the vena cava is the

vascular structure most commonly involved in penetrating abdominal trauma.<sup>10</sup> The IVC and confluence of the iliac veins are generally exposed by a right medial visceral rotation (Fig. 13-7). This involves mobilization of the right colon along with an extended Kocher maneuver rotating the duodenum and head of the pancreas when more proximal venous exposure is required. When exposing venous structures, one must be exceedingly cautious of the fragility of the vessel and, in particular, disrupting small, posterior, lumbar vessels. As a consequence and because the venous system is a “low-pressure” system, compression plays a greater role in control of the vena cava and iliac veins than it does in exposure and control of the corresponding arterial segments. Circumferential mobilization of the veins is avoided if possible, as is the application of clamps. The use of blunt instruments such as sponge sticks can usually provide adequate hemostasis (Fig. 13-8). Fine clamps, such as Allis clamps, can be used to coapt cut ends of vessels and facilitate either suture or control by applying partial occlusion clamps. Whenever possible, only the anterior segments of the vein are exposed to avoid dissection around the lumbar vessels. Exposure of isolated posterior injuries involves significant mobilization and rotation of the vena cava and often requires ligation of multiple tributaries. Ligation is liberally applied in cases of extensive venous injury.



**FIGURE 13-7** Right medial visceral rotation. The right colon, duodenum, and head of the pancreas are mobilized to expose the vena cava, the iliac veins, and the right renal artery and vein. The renal artery is exposed by retracting the vein either cephalad or caudad.

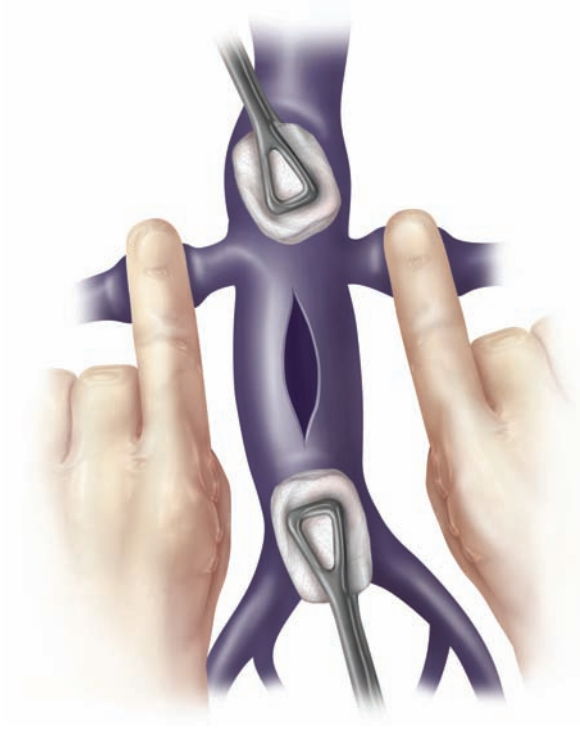


FIGURE 13-8 Control of vena cava. Pressure using digital compression or sponge sticks should be sufficient to control most venous injuries and avoids circumferential dissection.

## PRINCIPLES OF ARTERIAL REPAIR

Several factors dictate the approach to emergency arterial repair, including the extent of contamination, size of the arterial defect, and the adequacy of collateral circulation. The following are principles that should guide the choice of procedure:

1. When possible, primary repair is indicated. While most circumstances do not lend themselves to this approach, lateral repair or primary end-to-end anastomosis, or even arterial reimplantation, is associated with good long-term results and avoids use of a conduit.
2. When adequate collateral circulation exists, ligation without repair is indicated. This is the case with most splenic artery aneurysms and selected aneurysms of the hepatic and superior mesenteric arteries.
3. In the absence of contamination, prosthetic conduits provide the best choice for bypass of major intra-abdominal arteries. The high flow in the aorta and major visceral arteries along with their relatively large diameters is associated with good long-term patency of prosthetic bypass. Prosthetic conduits have the advantage of adequate diameter and ready availability, which makes them preferable to saphenous vein in the absence of any contraindication. Occasionally when reconstruction of a small to medium diameter (<6 mm) vessel is required, saphenous vein may be the preferred conduit.
4. In the presence of anything in excess of minor contamination, autogenous material should be used when vascular reconstruction is required. The risk of prosthetic graft infection with rupture argues against its routine use. For small- to medium-sized vessels (<6 mm), or when a patch closure is feasible, saphenous vein is usually adequate. For larger vessels, deep veins (femoral, popliteal, or jugular) should be considered. Short segment arterial repairs (eg, visceral and renal vessels) can be performed with hypogastric artery. Aortoiliac repair in the face of contamination should be performed with either deep leg veins, or more often arterial ligation and extra-anatomic bypass to restore perfusion.

## MANAGEMENT OF VASCULAR EMERGENCIES

### Acute Mesenteric Insufficiency

#### PRESENTATION

Patients with acute mesenteric insufficiency generally present with abdominal pain out of proportion to their physical findings. However, if undiagnosed, acute ischemia will progress to intestinal infarction with the attendant signs of peritonitis. Laboratory investigations include complete blood count, electrolytes, lactic acid, liver panel, amylase, and lipase. In general, findings are nonspecific early in the course of the disease and consist of a leukocytosis and perhaps some evidence of hemoconcentration. Liver panel, amylase, and lipase are most useful to exclude other acute abdominal conditions. Elevated lactic acid is usually a late sign and associated with a poor prognosis. Plain radiographs are nonspecific. An ileus may be present and occasionally edema of the bowel wall (“thumb printing”) may be present. CT, with intravenous contrast, has emerged as the most useful imaging modality. CT scans can identify abrupt arterial cutoffs, particularly when 3D reconstructions are available. In addition, late-phase CT angiography is the most reliable means to identify mesenteric vein thrombosis. Occasionally, angiography may be required, particularly when nonocclusive mesenteric ischemia (NOMI) is suspected. In these cases, angiography may be both diagnostic and therapeutic.

Mesenteric ischemia results from a variety of conditions; the most common is arterial embolism, followed by arterial thrombosis, low-flow states, and mesenteric venous occlusion.<sup>11–15</sup> Mortality is highest in low-flow (nonocclusive) ischemia and lowest in mesenteric venous thrombosis. Mortality of ischemia resulting from acute arterial occlusion remains 30–40%. Diagnosis is delayed in up to two-thirds of patients with mesenteric ischemia. Outcomes in acute mesenteric ischemia are related to the time to diagnosis,<sup>11,15</sup> and therefore effective treatment relies on prompt diagnosis and initiation of therapy before extensive bowel infarction occurs. This is dependent on a high index of suspicion. Prompt

effective fluid resuscitation is important in all cases of mesenteric ischemia, along with the initiation of broad-spectrum antibiotics. Patients with signs of an acute abdomen should be taken to the operating room as soon as they have been adequately resuscitated. Beyond this, however, the specific management of each type of mesenteric ischemia differs somewhat according to the etiology. Therefore, they are discussed separately.

*Acute mesenteric embolization* presents with the sudden onset of severe abdominal pain in the setting of a relatively normal abdominal examination. Most emboli are of cardiac origin and the patient may have an irregular pulse, cardiac murmur, or a history of prior myocardial infarction. Many patients may have a history of atrial fibrillation and/or prior embolic events. Because of the flow characteristics of the visceral vessels, most emboli preferentially go to the SMA. While some emboli lodge at the origin of this vessel, most end up distal to the first jejunal branches. An abrupt cutoff of flow in the SMA distal to the first jejunal branches on catheter angiography or CT angiogram is diagnostic of this condition (Figs. 13-9 and 13-10). Treatment is generally laparotomy and embolectomy. Characteristically, the most proximal jejunum is viable in the case of SMA embolus, because the occlusion occurs distal to the first jejunal branches. This is a helpful, but not foolproof, way to differentiate mesenteric embolization from mesenteric thrombosis.

As described earlier in this chapter, the SMA is exposed. The artery is usually soft and the site of the embolus is readily apparent. While a transverse arteriotomy with primary repair can be done, we prefer a longitudinal arteriotomy, and patch closure in most circumstances. The longitudinal arteriotomy can be extended if necessary and will allow thorough examination of the vessel and meticulous closure. It also facilitates bypass should this be required. Once the artery is opened, 3F and 4F embolectomy catheters are passed both proximally and distally to reestablish flow. If necessary, papaverine, 1 mg/kg, or 100 µg of nitroglycerine can be instilled in the distal vessels to reduce vasospasm. When there is concern about residual distal thrombus, 250 mg of urokinase or 1–3 mg of tissue plasminogen activator (TPA) in 50-cc saline can be instilled in the distal vascular bed.<sup>16</sup> If there is clinical evidence of atherosclerosis in the artery, a longitudinal arteriotomy and patch closure are mandatory. If bowel resection is required, proximal saphenous vein should be used for arterial reconstruction.

In unusual circumstances catheter-directed thrombolysis can be used as an alternative to open embolectomy.<sup>17</sup> The patient should have no signs of peritonitis and angiography should demonstrate distal emboli (not easily retrieved by an embolectomy catheter) or a partially occluding proximal embolus that permits distal flow to continue during thrombolysis. In these rare circumstances, an infusion of

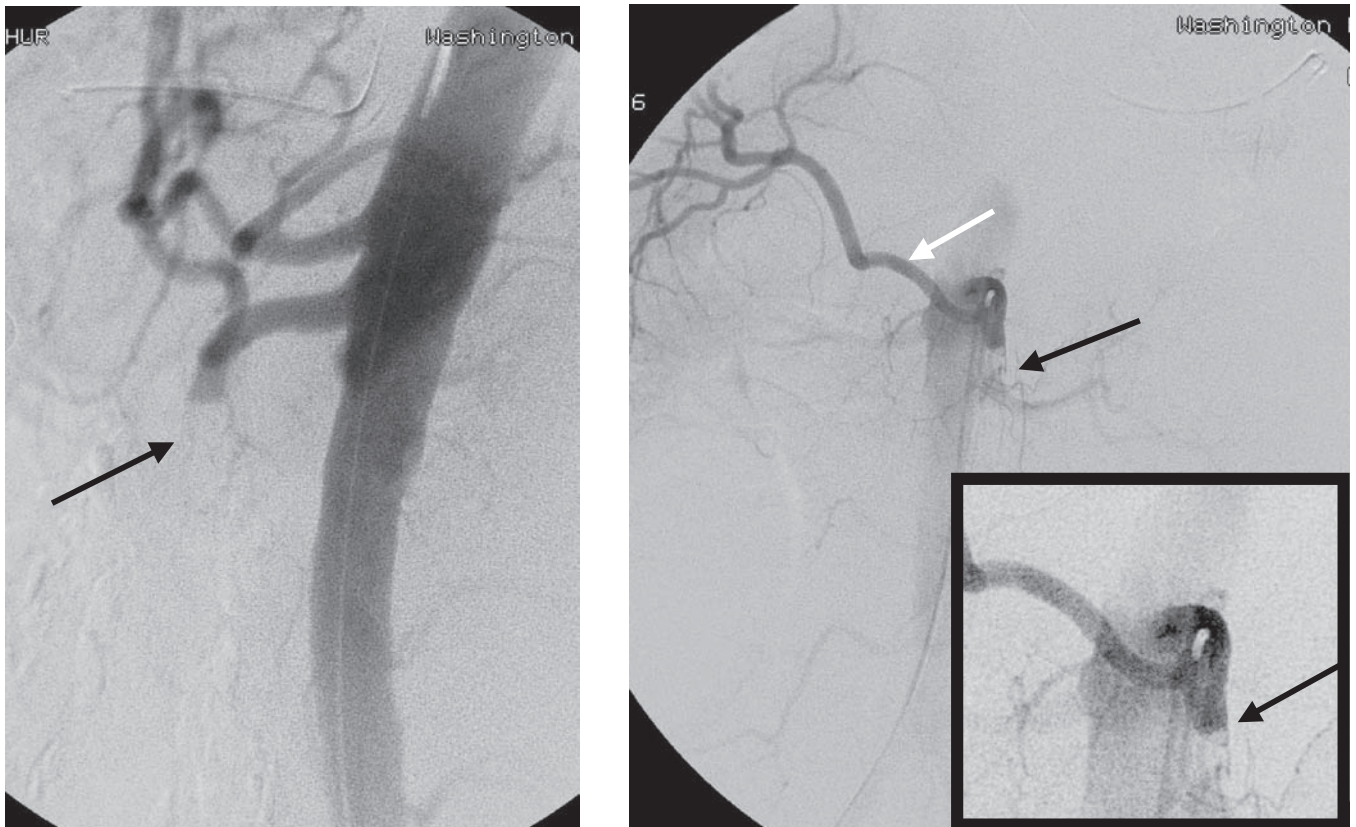


FIGURE 13-9 Angiogram of superior mesenteric artery (SMA) embolus demonstrating an abrupt cutoff distal to a branch point.



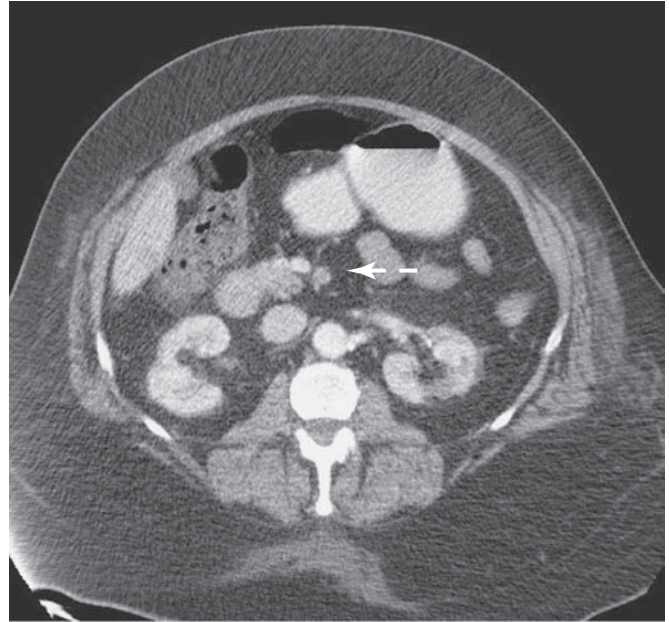
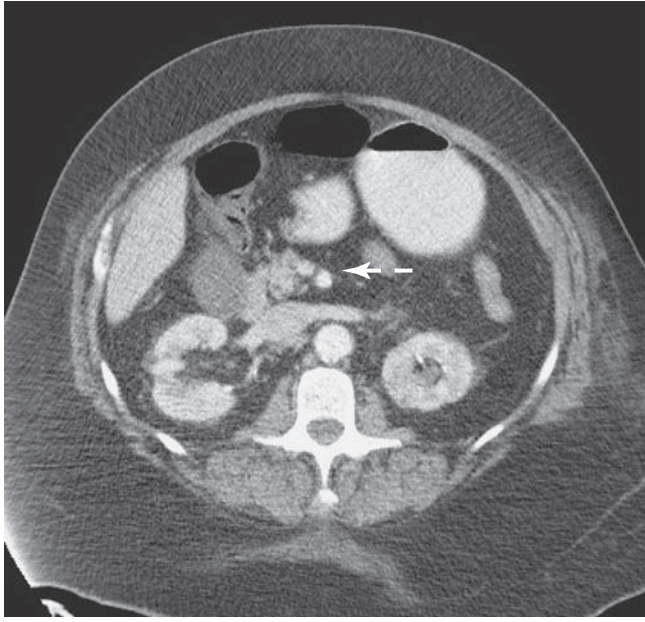


FIGURE 13-10 CT Scan of superior mesenteric artery (SMA) embolus showing patent SMA (*right*) with more distal thrombosis (*left*).

TPA directly into the SMA can be attempted. Mechanical thrombolysis should not be attempted because of the danger of distal embolization. The patient must be observed carefully during lysis for signs of deterioration and any concern over bowel viability will promote laparotomy. Best results are seen when symptoms show some resolution within 1 hour.<sup>18</sup>

The clinical signs of *acute mesenteric thrombosis* are indistinguishable from those of acute embolic occlusion; however, there are often differences in the history and some physical findings. History of arterial occlusive disease (stroke, claudication, myocardial infarction) is common, and atrial fibrillation or prior embolic episodes are unusual. Careful questioning may elicit a history of chronic postprandial pain and weight loss, characteristics of chronic mesenteric ischemia. Physical examination often reveals stigmata of atherosclerosis, for example absent pulses and vascular bruits. Angiographic findings usually reveal diffuse atherosclerosis of the aorta and visceral vessels with multivessel involvement. When vascular occlusion occurs, it is usually at the origin of the mesenteric vessels (Fig. 13-11).<sup>14</sup>

The operative approach to acute mesenteric ischemia from thrombosis differs from that of embolic occlusion. Mesenteric flow cannot be restored by a simple embolectomy and alternatives are required. The most common procedure required is bypass of the SMA usually from the infrarenal aorta or from one of the iliac arteries. While suprarenal bypass is preferred in elective surgery for chronic ischemia, an infrarenal origin of the bypass is more expeditious in

the acutely ischemic patient and avoids the acute hemodynamic consequences of suprarenal clamping in a patient already acutely ill and often hemodynamically compromised. Because bowel resection is usually required, autogenous saphenous vein is the preferred conduit and should

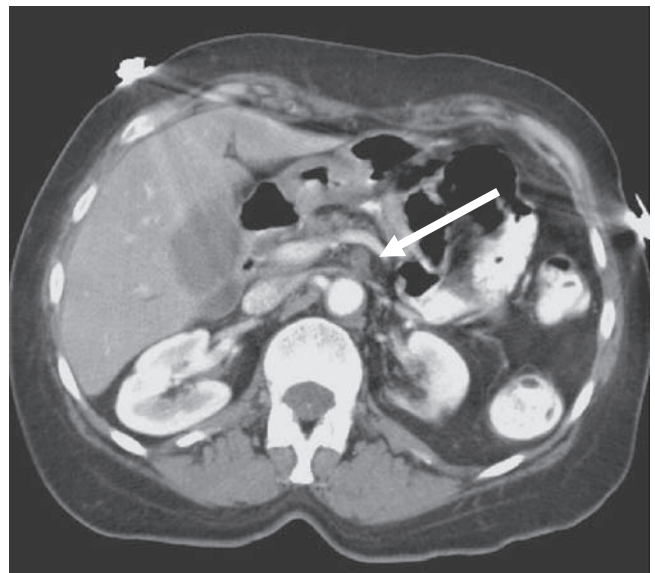
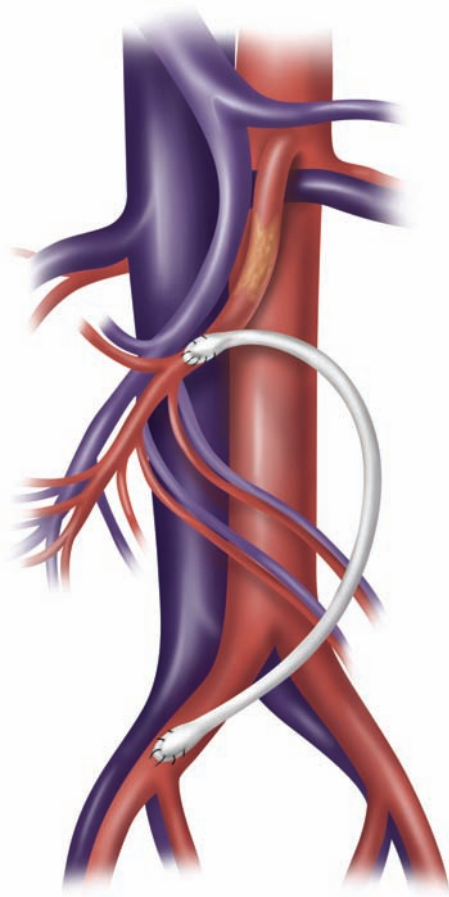


FIGURE 13-11 CT scan of superior mesenteric artery (SMA) thrombosis at the origin of the vessel. This is usually due to underlying atherosclerosis. Emboli lodge at the origin of the SMA in about 30% or fewer of cases.



be harvested from the proximal thigh. When the bypass is performed, there should be sufficient redundancy to allow a “lazy C” loop, traveling from right to left in the abdomen to avoid sharp kinking (Fig. 13-12). The bypass is usually performed on the lateral side of the SMA slightly posterior, so that it can lie without compromise when the viscera are returned to the abdomen. While it is tempting to use very short bypasses, these may be prone to kinking and perioperative thrombosis. In the acute setting, revascularization is usually restricted to the SMA alone.

When there is no suggestion of intestinal necrosis and angiography reveals high-grade stenosis rather than vascular occlusion, an endovascular approach may be attempted.<sup>19,20</sup> Endovascular recanalization is more dangerous when vessels are completely occluded because of the possibility of causing distal embolization. While the target lesion remains the SMA, it is reasonable to perform angioplasty of multiple visceral arteries if the patient remains stable. The visceral vessels may be engaged either transfemorally, or more often via a transbrachial approach. The latter facilitates access to the



**FIGURE 13-12** Retrograde bypass of superior mesenteric artery (SMA) occlusion. This can originate from the aorta or the right iliac artery. The “lazy C” loop reduces the chance of graft kinking. The SMA anastomosis is on the posterolateral aspect of the vessel.

origin of the vessel and passage of angioplasty balloons and stents as required. If there is any indication of intravascular thrombus, lytic infusion should be performed prior to any attempt at angioplasty to avoid the possibility of distal embolization. Once the possibility of thrombus is excluded, angioplasty with the placement of a balloon expandable nitinol stent is then performed. Use of a short (15–20 mm) 5- to 6-mm-diameter balloon-expandable stent allows precise deployment. The stent should completely traverse the area of narrowing and extend a few mms out into the aorta. This is important because the lesion in this case usually has its origin in the aorta. Selecting an endovascular approach does not mean that laparotomy is avoided, because bowel ischemia may be present. Any signs of peritonitis require prompt laparotomy and inspection of the bowel for viability.

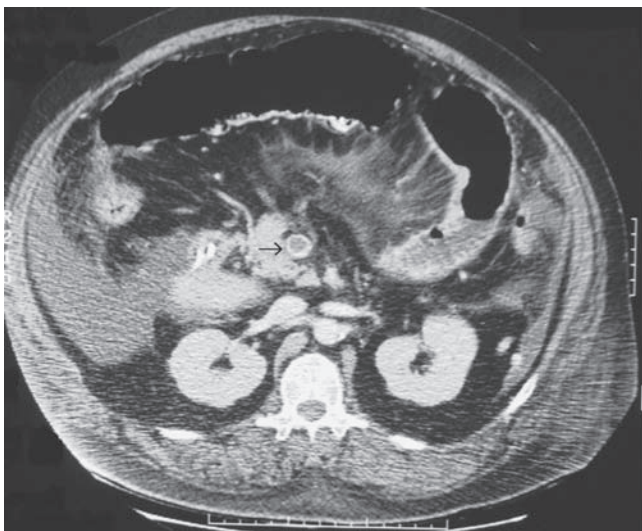
Retrograde endovascular recanalization of a proximal SMA lesion has been reported at the time of celiotomy.<sup>21</sup> This technique involves a longitudinal arteriotomy made in the SMA and a wire is passed retrograde into the aorta under fluoroscopic guidance. Balloon angioplasty of the proximal lesion is performed as an alternative to bypass, and the arteriotomy is closed with a patch. While reports are anecdotal, this procedure is of interest because it avoids the possibility of distal embolization and may be performed more expeditiously than a vein bypass.

*Nonocclusive mesenteric ischemia* (NOMI) may occur as the result of low flow, without evidence of acute arterial thrombosis or embolization. In one form of this condition, the colon, in whole or in part, is involved. The arterial supply of the colon is less robust than that of the small bowel and, in elderly patients particularly, the inferior mesenteric artery (IMA) may be diseased or occluded. Systemic illness with reduced visceral blood flow, or abrupt interruption of the IMA, such as with aortic resection, may precipitate infarction of marginally perfused areas of the colon. This is most common in the sigmoid colon and the splenic flexure. The rectum is often spared in this process, because of its dual supply through the hemorrhoidal vessels. The small bowel is also usually spared. In these situations, resection of the infarcted colon, with exteriorization and diversion as necessary, is all that is required. The SMA and celiac arteries are usually normal, and no attempt at revascularization of the IMA is indicated.

Mesenteric ischemia without an underlying visceral lesion may also involve the SMA and celiac distribution. This has been called “nonocclusive mesenteric ischemia” (NOMI) and is associated with severe systemic illness, hypotension, and spasm of the mesenteric vessels without evidence of an obstructive lesion.<sup>22</sup> Patients with NOMI are often already in an intensive care unit (ICU) and have had a cardiac event requiring vasoactive drug infusions. Some patients may have been on digitalis preparations that themselves are known to reduce visceral blood flow. There have been some recent reports of NOMI following dialysis in patients with end-stage renal disease.<sup>23</sup> Angiography, when performed, shows “pruning” of the mesenteric vessels without discrete

obstruction. Management of these patients is directed at overall cardiovascular support, treatment of the underlying acute condition(s), and broad-spectrum antibiotics. Intra-arterial papaverine may be administered to relieve vascular spasm, although this is not always effective and may be complicated by systemic hypotension. NOMI usually portends a bad outcome in general, which is related as much to the underlying illness as to mesenteric compromise. Laparotomy should be reserved for patients in whom intestinal infarction is suspected and often will not influence the outcome in this disease.

*Mesenteric venous thrombosis* may result in acute intestinal ischemia, although this accounts for only about 5% of all cases. Patients are a distinct subgroup, being younger (30–50 years) and predominantly female.<sup>24–27</sup> Associated hypercoagulable state can be identified in more than three quarters of patients and a history of prior venous thrombosis is not uncommon. Common inherited states include deficiencies of protein C, protein S, and antithrombin III; activated protein C resistance; factor V Leiden mutation; and methylenetetrahydrofolate mutations.<sup>27</sup> Acquired prothrombotic states include profound dehydration, polycythemia, cancer, pelvic or abdominal inflammation, and hormone use. Mesenteric venous occlusion is most readily diagnosed by venous-phase CT angiography, which can demonstrate thrombus in the superior mesenteric vein and portal system (Fig. 13-13). Operative findings suggestive of this condition are edematous beefy red bowel with thrombus in veins of the mesentery. The primary mode of therapy is anticoagulation, operative intervention is rarely indicated. Most patients can be managed supportively, although significant volume resuscitation may be required. There are anecdotal reports of mesenteric and portal vein thrombectomy and



**FIGURE 13-13** CT scan demonstrating thrombus in the superior mesenteric vein. CT scan is the most accurate diagnostic study in this condition.

thrombolysis,<sup>28–30</sup> but these do not reflect the standard of care for most patients.

#### DETERMINING INTESTINAL VIABILITY: THE ROLE OF “SECOND-LOOK” SURGERY

A major challenge in managing patients with intestinal ischemia is assessing the need for, and extent of, intestinal resection. Preoperatively, colonoscopy can be used to assess the viability of the large intestine in questionable situations. Friable red mucosa suggests viability and a grey mucosa that readily sloughs indicates the need for resection. Viability of the large bowel is difficult to judge from external appearance at the time of laparotomy and in general it is preferable to err on the side of resection in questionable circumstances, because maintaining large bowel length is not an absolute requirement for survival. Primary repair should not be undertaken after large bowel resection, as diversion with secondary reconstruction is preferred.

When the small intestine is involved, the problem becomes more complex.<sup>31–33</sup> Every effort should be made to preserve as much small bowel as possible. Clearly necrotic segments of bowel and areas of perforation are resected or excluded immediately to prevent contamination during vascular reconstruction. Evaluation of the remainder of the small bowel is done after blood flow to the intestine is restored. The bowel is usually observed for 15–20 minutes after revascularization and warm lap pads are applied to the intestines to reduce any vasospasm. External inspection, with attention to color and peristalsis, is more helpful than in the large bowel. Doppler interrogation of the antimesenteric border for arterial flow is useful when positive. Use of fluorescein (1 ampule given intravenously) followed by inspection with a Wood’s lamp, is the most sensitive means of determining perfusion. Viable bowel will be fluorescent yellow while nonperfused bowel will appear dark purple. When the extent of resection is minimal and the remaining bowel is clearly viable, anastomosis and abdominal closure is appropriate. When there are large areas of questionable bowel that might mandate extensive resection, an alternative approach is undertaken. Under these conditions, marginal segments of bowel are left in situ and their ends are simply closed over and returned to the abdomen. Plans for a second operation are made. Stomas are not performed at this stage to preserve intestinal length. Fluorescein is not used at this time but reserved for the second procedure. The abdomen is temporarily closed using a “Bogotá bag,” polytetrafluoroethylene (PTFE) patch, or other temporary appliance (to minimize the chance of abdominal compartment syndrome) and the patient is returned to the ICU where resuscitation continues. A subsequent laparotomy is performed at 18–24 hours after the patient has been stabilized. At this point fluorescein is injected and nonviable bowel is resected. Intestinal continuity is restored unless it is unsafe to do so. The abdomen often cannot be closed primarily at this point because of the danger of compartmental hypertension, and an “open abdomen” approach with delayed closure may be needed. Any deterioration in the patient’s subsequent

hospital course should suggest breakdown of an anastomosis and prompt the appropriate therapy.

Despite increased clinical awareness and advances in diagnostic modalities and perioperative care, management of intestinal ischemia remains a significant challenge to the most experienced surgeon with continued high mortality and morbidity.

## Management of Abdominal Vascular Trauma

Vascular injuries occur in 10–15% of cases of blunt and penetrating trauma.<sup>34–38</sup> Associated nonvascular injuries are seen in over 90% of patients with vascular trauma, most commonly small bowel, colon, and liver.<sup>37</sup> Vascular injuries can be highly lethal when they occur and remain the most common cause of death following penetrating abdominal trauma. Arterial and venous injuries occur with equal frequency. The pattern of injury differs between blunt and penetrating injuries. In penetrating injuries, the most commonly injured vessels are the vena cava, followed by the aorta, iliac arteries and veins, and the SMA, and vein and multiple vascular injuries are common.<sup>10</sup> Vessels of the mesentery are the most commonly involved in blunt trauma. This section provides principles for management of injuries to the major arteries and veins of the abdomen and retroperitoneum. The reader is referred to the prior sections on vascular exposure for a description of how to obtain control of these vessels. The discussion here centers on management of specific injuries.

Overall, principles of trauma management including initial resuscitation of the patient, rapid evaluation and triage, and expeditious operation when indicated should prevail. Stable patients, particularly those with blunt trauma, may undergo one or more diagnostic tests, including peritoneal lavage, “FAST” ultrasound examination, and, with increasing frequency, CT scan.<sup>39</sup> Many patients with penetrating trauma are taken directly to the operating room without further diagnostic evaluation. Consequently, in a significant proportion of cases, the extent of vascular trauma is not known preoperatively and must be assessed by the surgeon in the operating room.

Intraoperative hemorrhage is easily recognized and should be expeditiously controlled, by application of external pressure, vascular clamps, or intravascular balloon occlusion catheters. Once active hemorrhage is controlled, any visceral perforation is controlled by exclusion to prevent ongoing peritoneal contamination and any remaining solid-organ injuries (ie, liver, spleen, and pancreas) should be stabilized by packing. Definitive treatment of the vascular injuries should then receive priority over definitive visceral repair. The adaptation of a “damage control” approach to abdominal trauma has improved outcomes in abdominal trauma.<sup>40,41</sup> Vascular “damage control” involves the control of major venous injuries by ligation or packing and placement of temporary shunts to restore arterial continuity when arterial ligation will not be tolerated.<sup>42,43</sup> Shunts are most often used to

temporarily restore flow to the extremities but are used less often in management of visceral injuries. In general, visceral vessels are either repaired or ligated during the initial operation. The end organ will either tolerate ligation because of collateral circulation or be sacrificed. The “damage control” concept combined with endovascular techniques may be of particular use when open vascular repair is exceedingly complex and associated with significant mortality. This is particularly true of contained retroperitoneal or hepatic injuries. Definitive treatment can be deferred at initial laparotomy in these cases and attempted in an imaging suite using endovascular techniques after the patient is stabilized. Examples of this include embolization of intrahepatic arterial injury and treatment of some contained retroperitoneal hematomas. This approach is in evolution and holds significant promise.

There are a number of situations in which the surgeon must make a decision about whether to explore a contained hematoma. In these cases, the risk of missing a major vascular injury is balanced against the morbidity of operative exploration. Classic trauma training requires exploration of all contained hematomas that result from penetrating injury. In the case of blunt trauma, central hematomas (zone 1) are explored because of the risk of injury to the aorta or vena cava, while lateral and pelvic hematomas are explored only if there is active bleeding or expansion under observation.<sup>36</sup> If exploration occurs, it is important to obtain proximal and, whenever possible distal, arterial control outside the area of hematoma before proceeding. Venous control above and below the area of injury is desirable but may not always be obtainable. Approaches to vascular control, including endovascular techniques in various locations, have already been described. Intravascular occlusion catheters should be readily available for additional control as needed. Only after every attempt to control the arterial and venous ingress and egress to the hematoma has been made should it be entered.

The advent of endovascular techniques may be changing the classic paradigm of managing contained hematoma from either blunt or penetrating cause. The rationale for exploring nonexpanding hematomas of any type was based on the concern for occult vascular or visceral injury. The advent of CT angiography and the existence of sophisticated intravascular imaging in the operating room can facilitate evaluation of nonexpanding hematomas from both penetrating and blunt trauma without the need for operative exposure and its attendant blood loss. Furthermore, endovascular techniques such as covered stents or coil embolization will allow treatment of many vascular injuries from remote access with reduced risk of blood loss.<sup>44,45</sup> Such treatments are in fact preferred for trauma to branch vessels in the visceral, renal, or pelvic circulations. This potential change in paradigm suggests that the surgeon consider a form of vascular “damage control” in the case of contained hemorrhage, by considering an “endovascular first” approach for diagnosis and treatment of contained hematomas regardless of location. This area is currently evolving, and there is no consensus on the role endovascular techniques should and will eventually



play. With these general comments in mind, a discussion of specific vascular injuries and their management follows.

### INJURIES TO THE SUPRARENAL AORTA AND VENA CAVA

These injuries as a group are highly lethal and management is difficult. They should be suspected in any patient with a central hematoma from either blunt or penetrating trauma. In the stable patient, CT scan with intravenous contrast can help to identify the area of injury. If CT scan is not possible preoperatively, a clear plan of exposure and management is crucial before commencing any attempt at repair. Because of the advances made in endovascular techniques, patients should be treated in an operating room that has the capability of intraoperative fluoroscopic imaging and angiography whenever possible. If an injury to the aorta or vena cava is suspected and the patient is not exsanguinating, the surgeon should consider intraoperative angiography through the femoral artery or vein as appropriate to evaluate the location and extent of vascular injury and consider intravascular control. Following this, proximal and distal control should be established. Open exposure of the aorta at the diaphragmatic hiatus or endoluminal balloon control,<sup>3,4</sup> both described previously, can be performed. Injuries to the vena cava can initially be controlled by balloon tamponade, although this may reduce venous return to the right side of the heart. Open control of the vena cava is described in the following text.

#### OPEN REPAIR OF THE SUPRARENAL AORTA

The visceral aorta is exposed by a left medial visceral rotation described previously. If access to the posterior aspect of the aorta is required, the left kidney should be elevated along with the other viscera; if access to the anterior aorta is needed, the kidney is left in its bed. Direct suture repair is undertaken whenever possible. Direct repair that does not narrow the lumen of the aorta more than 50% or impinge on a visceral vessel is well tolerated. Larger defects may require patch angioplasty using prosthetic material, arterial autograft, or arterial homograft. In the absence of significant contamination, prosthetic material provides a readily available, strong, and durable material for repair. In the presence of gross fecal contamination, biologic materials should be used if possible. Arterial homograft provides the most expeditious alternative both for size and durability, if available. Saphenous vein is inappropriate in this circumstance due to concerns about strength and durability; deep veins of the leg have proven reliable substitutes for in situ aortic reconstruction in infected fields.<sup>46</sup> If appropriate, the aortic repair can be buttressed by an apron of omentum of some paraspinous muscle, to separate the suture line from any visceral vessels. This should be done in the presence of associated visceral injury, particularly injury to the pancreas. Drainage is established as needed. If the damage involves the origins of one or more of the visceral vessels, these are ligated. Revascularization of these vessels can be performed as described in the following text. Damage

control of the suprarenal aorta is not possible because of the mesenteric ischemia that would attend any such attempt.

#### ENDOVASCULAR REPAIR OF THE AORTA

This emerging alternative should be considered in selected circumstances. In a stable patient with a contained injury, placement of a suitable covered stent can be combined with extra-anatomic debranching of one or two visceral vessels, as has been described for treatment of thoracoabdominal aneurysms.<sup>47</sup> This is most suitable when a single mesenteric vessel is involved, because the bowel will tolerate more prolonged ischemia than the kidney. Modification of the stent graft ("fenestrations"), to allow continued visceral perfusion, is possible.<sup>48</sup> This is most feasible when the aortic defect is posterior and relatively remote from the visceral orifices. More precise fenestrations, as required in suprarenal aortic repair, are currently beyond the capability of most surgeons in an acute setting. If a stent graft is selected, its diameter should be 110–115% of the normal aorta to allow for secure fixation. A variety of off-the-shelf aortic cuffs are available and their successful use has been reported in conjunction with thoracic aortic transection.

#### OPEN REPAIR OF THE SUPRARENAL INFERIOR VENA CAVA

Open repair of injuries to the suprarenal vena cava is one of the most difficult of all abdominal vascular operations. Exposure of the infrahepatic suprarenal IVC is achieved by an extended Kocher maneuver and right medial visceral rotation. One cannot overemphasize the utility of intravascular balloon control in these cases to avoid hemorrhage. Balloon control can be combined with external pressure and the application of partial occlusion clamps to provide hemostasis. Fine Allis clamps are useful in coapting and controlling the cut ends of the IVC and are preferable to more traumatic attempts at control. Wounds of the infrahepatic suprarenal IVC are usually managed by lateral venorrhaphy with running vascular suture. Narrowing the IVC 50–60% is often acceptable. If lateral venorrhaphy is not possible, patch repair using prosthetic or biologic material is acceptable. The use of anticoagulation in these circumstances is unsettled and is likely to remain individualized. Ligation of the suprarenal IVC should be avoided. Injuries to the retrohepatic vena cava, especially those that accompany blunt trauma, usually involve avulsion of the hepatic veins. Such injuries are highly lethal. Exposure of the retrohepatic IVC involves mobilization of the liver and anterior medial rotation of the right lobe.<sup>49–51</sup> Repair of retrohepatic venous injuries may require hepatic isolation (control of the aorta at the hiatus as well as the vena cava above and below the injury and occlusion of the portal triad), placement of an intraluminal shunt between the right atrium and infrarenal IVC or veno venous bypass with hepatic isolation. These techniques are only used in desperate circumstances when bleeding persists despite adequate perihepatic packing. In general, injuries in this area should initially be treated by



packing, nonexpanding hematomas should not be opened, and the extent of injury should be defined and definitive repair planned after the patient has been stabilized.

### ENDOASCULAR TECHNIQUES IN THE SUPRARENAL IVC

At this point, any endovascular approach would be considered experimental. The complexities of and poor results with open surgery in this area make an endovascular approach to suprarenal IVC injuries an attractive potential alternative. Remote access and control, facilitating exposure, along with limited occlusion of the IVC, are all points in favor of an endovascular approach. The size and distensibility of the IVC complicate the selection of an appropriate diameter endovascular graft. Patients with caval injury are often in shock and there may be external pressure on the vessel, both factors that cloud the estimation of caval diameter. No stent grafts have been made for caval use, and it is likely that aortic cuffs or short segment of grafts used for thoracic aortic repair would be most useful. Inadvertent coverage of the renal or hepatic veins represents a further potential complicating factor. There have been no reports of endovascular treatment of hepatic vein injuries. Nonetheless, the potential treatment of these injuries by remote rather than direct access is appealing enough that it will undoubtedly be investigated in the future.

### REPAIR OF THE INFRARENAL AORTA AND ILIAC ARTERIES

Injuries to the infrarenal aorta and iliac arteries can be managed by a combination of open and endovascular techniques. Use of an endovascular balloon to achieve proximal arterial control, described for ruptured aortic aneurysm, should be considered as a part of management. These techniques require access to intraoperative fluoroscopy and familiarity with endovascular techniques. The balloon should be placed in the operating room before celiotomy if possible, either through the femoral artery with a supporting sheath or the left brachial artery, as previously described.<sup>3,4</sup> The balloon does not need to be inflated if the patient remains stable. Because concurrent visceral injury is common, laparotomy is almost universally required. After “damage control” of any gross intestinal spillage, attention is turned to the arterial injuries. Exposure of the aorta and iliac arteries has been described. When there is minimal enteric spillage, irrigation and repair with an in situ prosthetic bypass of appropriate diameter is the most expeditious approach. The repair should be wrapped in omentum if possible to separate it from the viscera. In the presence of significant contamination, the infrarenal aorta and/or iliac vessels should either be repaired primarily, ligated, or a temporary shunt inserted as part of a “damage control” strategy.<sup>42</sup> If ligation is required, extra-anatomic (eg, axillofemoral or femoral) bypass with prosthetic material can be used to restore perfusion to the lower extremities. If the aortic bifurcation is preserved, a

unifemoral bypass is possible. In cases where the aortic bifurcation is not salvageable, primary end-to-end anastomosis of the proximal ends of the common iliac arteries can be performed, followed by axillo-unifemoral bypass. If this is not possible, axillo-bifemoral bypass may be required.

Unilateral common iliac artery injuries may be ligated with subsequent cross femoral reconstruction using a prosthetic graft. Isolated external iliac artery injuries can be repaired in most cases with saphenous vein interposition. Internal iliac artery injuries should be ligated. In the absence of significant contamination, interposition graft replacement of the damaged vessel with a prosthetic graft is preferred. There are advocates of in situ prosthetic bypass, even in the face of more significant contamination.<sup>52</sup> We prefer not to do this unless the situation is life threatening and prefer temporary placement of a shunt.

Endovascular repair of injured aorta and iliac vessels can be performed using techniques applied for repair of endovascular infrarenal aortic aneurysm repair. One must remember, however, that many of these patients are young and the durability of these repairs is unknown. In addition most patients will require laparotomy for associated injuries. These two factors suggest a limited role for stent grafts in the treatment of traumatic lesions of the aortoiliac system. Endovascular repair has been used in treatment of traumatic dissection of the aorta or iliac arteries.<sup>53</sup> As previously noted, endovascular balloon tamponade is a valuable technique and endovascular coil embolization of difficult-to-access hypogastric artery branches can be employed with great success.

### INFRARENAL IVC AND ILIAC VEIN

The principles of controlling venous injuries, including use of balloon tamponade and external pressure, have been previously described. The infrarenal IVC, iliac confluence, and right iliac vein are exposed through a right medial visceral rotation (see Fig. 13-7). The confluence of the iliac veins is obscured by the aortic bifurcation and right common iliac artery. If the aortic bifurcation cannot be sufficiently mobilized to provide exposure, the right common iliac artery should be mobilized or even transected for additional exposure. This is often required in any event because concomitant arterial injury is common. The more distal left iliac vein is approached on either side of the descending/sigmoid colon depending on the location of the injury.

As with the suprarenal IVC, lateral venorrhaphy is the preferred approach, with autogenous vein patch or ligation as alternatives. If needed, the infrarenal IVC and iliac veins can be ligated, due to the rather extensive collateral network that can develop within hours. While this may cause fluid sequestration in the lower legs, it is usually tolerated in the short term and is preferable to an attempt at repair in an unstable patient. In the rare case that ligation results in extreme distal venous hypertension, a bypass graft is indicated. In patients who have been stabilized, we prefer venous repair, either with a vein patch or, when an

interposition graft is required, a ringed prosthetic conduit. Successful venous repair must use a conduit of equal or slightly greater diameter than the native vein and should avoid any tension. Saphenous vein is of insufficient diameter for replacement of the iliac vessels and must be modified to be useful ("panel" grafts). We find such panel grafts excessively time consuming to construct in these critically ill patients and prefer externally supported PTFE of suitable diameter and length. This is usually done in situ but may be performed using an extra anatomic route. When short segments of prosthesis are used in the presence of distal venous hypertension, flow is usually sufficient to maintain patency without the need for anticoagulation or an adjunctive fistula. In our experience, when thrombosis of a prosthetic vein graft does occur, adequate collateral venous flow has been invariably present. The indication for caval filters in patients with venous injury is not clearly established and remains a manner of individual clinical judgment.

#### TREATMENT OF TRAUMATIC ARTERIOVENOUS FISTULA

Fistula between the major arteries and veins can occur at any level, because the vessels are in close proximity throughout their course. It is important to realize that, while this may occur acutely, such a fistula rarely represents a true vascular emergency. Exsanguinating hemorrhage does not occur, because the arterial blood is decompressed into the venous system. Most of these patients present months to years after their initial injury. These patients may present with a continuous bruit, signs of lower extremity edema, and high-output cardiac failure.<sup>54</sup> Management depends on an accurate history of trauma, including prior surgery (particularly lumbar disc surgery) or endovascular manipulation. Detailed vascular imaging is essential. These patients are rarely in extremis, and an effort to delineate the problem and develop a careful plan of correction is time well spent. Repair can usually be delayed until the patient is stabilized and other acute problems are corrected.

Treatment is directed at repair of both the arterial and venous defect.<sup>54,55</sup> This is most often done by primary suture closure, although patch closure is sometimes required. Proximal and distal arterial control is essential and is obtained using open or endovascular techniques as described previously. Proximal and distal venous control should be obtained when possible before opening the fistula. This can be done by external dissection, compression, or an intraluminal balloon. Central venous occlusion is important to prevent air embolization when the vein is opened. We generally avoid extensive venous dissection in close proximity to the fistula. On occasion, venous control can be obtained by placing a balloon catheter *through* the fistula from within the artery and then closing the communication with interrupted or running sutures (Fig. 13-14). In the acute circumstance, the artery and vein may be separated, but this is more difficult in the case of a more chronic fistula and closure of the communication, by

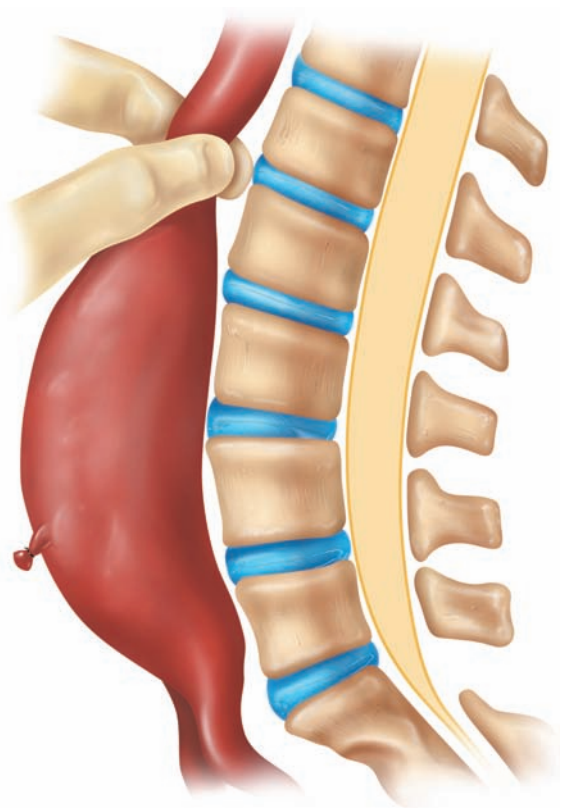


FIGURE 13-14 Control of the aorta by finger dissection. The aortic neck can be elevated off the spine and a clamp applied.

primary suture or patch, can be done from within the vessel. If this approach is chosen, it is important to be sure that the communication has been completely interrupted at the end of the procedure by use of intraoperative ultrasound or angiography. Appropriate flushing of both the arterial and venous sides is important to avoid embolization of debris or air into the central venous circulation.

Arterial-venous communications can also be approached endovascularly using covered stents.<sup>56</sup> The stent can be placed only on the arterial side of the defect if the site of injury is in a main artery and can be accurately identified. However, it is important to remember that the arterial injury may be in a branch of one of the iliac vessels, in which case placement of a stent graft in the main artery will not correct the abnormality. Detailed description of repair of these branch fistulae is complex and beyond the scope of this chapter. Suffice it to say that coil embolization can be particularly dangerous in these cases due to the high flow in the venous system and chance of central venous embolization. A variety of techniques can be employed to reduce this possibility. Endovascular treatment of these lesions should only be undertaken by those with significant experience in endovascular techniques. As with open repair, it is important to be sure that complete interruption of the fistulous communications has occurred using completion angiography.

## TRAUMA TO THE MESENTERIC ARTERIES AND VEINS

The origin of the celiac axis is exposed through the gastrohepatic ligament or by a left medial visceral rotation as described earlier. While a short bypass from the aorta to the bifurcation of the splenic and hepatic arteries can be performed, the origin of the celiac artery can be ligated safely, if necessary, in most cases. This is preferable to attempting repair in a relatively confined space in an unstable patient. Collaterals through the pancreaticoduodenal and gastroduodenal are usually sufficient to preserve foregut flow. If there is any doubt, a bypass can be performed from the aorta to the common hepatic artery. The splenic artery can be ligated, as can the splenic vein. In the case of proximal injuries to these vessels, the short gastric vessels provide adequate collateral flow. When the splenic vessels are injured close to the hilum, a splenectomy is usually the best approach. Injuries to the common hepatic artery may be ligated because of collateral circulation, while injuries to the proper hepatic artery are more likely to require repair. In order of preference, techniques are primary repair, interposition vein graft, and aortomesenteric graft using either saphenous vein or prosthetic. Two-thirds or more of hepatic flow is supplied by the portal vein, and, if this is intact, proper hepatic artery ligation is an acceptable option. Intrahepatic arterial lesions are generally treated with angiographically directed coil embolization unless massive exsanguination requires resection of the damaged area of the liver.

Injuries to the main trunk of the SMA should be repaired because significant loss of small bowel may result from sacrifice of the vessel. Ligation of proximal SMA aneurysms can be performed with acceptable results, due to the presence of collaterals from the celiac and inferior mesenteric arteries. However, in the trauma setting, integrity of collateral pathways from the pancreaticoduodenal and middle colic vessels is not easily ascertained and repair should be performed. Lesions at the origin of the vessel are best exposed by left medial visceral rotation and repaired with a short bypass originating from the aorta. More distal lesions are exposed through the base of the small bowel mesentery and can be repaired by patch angioplasty, interposition graft using saphenous vein, or proximal ligation and distal bypass arising from the aorta. In the trauma setting, the infrarenal aorta is preferred as inflow for the more distal SMA because supraceliac exposure and control is best avoided in patients who may be unstable and have multiple injuries. Saphenous vein is the preferred conduit. The details of SMA bypass have been described, including the need for proper length and orientation to prevent kinking. Trauma to the branches of the SMA is usually treated by vessel ligation and any nonviable bowel is resected. Attempts to repair distal arterial and venous injuries in the mesentery are not rewarding. Mesenteric hematomas that are not expanding and are not associated with compromised bowel should be observed initially with angiography as necessary to identify vascular lesions. Attempts to explore stable mesenteric hematomas can lead to excessive blood loss and vascular compromise, resulting in more bowel ischemia.

Injuries to the splenic vein are treated by ligation, with or without splenectomy. There is often an accompanying injury to the splenic artery. In the rare instance of isolated splenic vein injury, consideration should be given to concomitant splenic artery ligation or splenectomy. Acute ligation of the splenic vein alone may result in sequestration of significant amounts of blood within the spleen and left-sided portal hypertension. This can be ameliorated by ligating the main arterial inflow to the spleen. Injuries to the main trunk of superior mesenteric vein should be repaired to avoid bowel ischemia secondary to mesenteric venous obstruction. If the vein cannot be repaired using a patch angioplasty or short interposition graft, a bypass from the superior mesenteric vein to the portal vein should be performed. This probably will require a large (6- to 8-mm) conduit of either reinforced PTFE or deep vein (jugular or femoral). Injuries to the portal vein should be repaired if possible, by lateral venorrhaphy, patch angioplasty, or interposition grafting, if the patient is stable enough to undergo repair. The retropancreatic portal vein is best exposed by transection of the pancreas (Fig. 13-15). Isolated injuries of the portal vein, with an intact hepatic artery, may be ligated if necessary to save the life of the patient, although significant hepatic dysfunction and acute massive bowel edema can be anticipated. This leads to significant fluid sequestration and may even result in bowel necrosis. Lesions of the hepatic artery

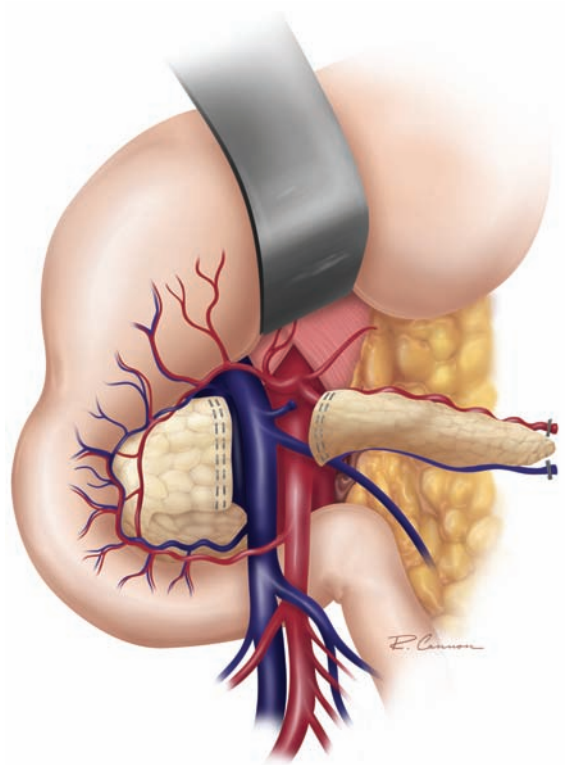


FIGURE 13-15 Exposure of the retropancreatic portal vein by division of the pancreas.



and portal vein that are not immediately lethal should be repaired if possible.

Injuries to the inferior mesenteric artery can usually be ligated, because adequate collaterals will exist from the arc of Riolan, the marginal artery of Drummond, and the hemorrhoidal vessels. If it appears that ligation will not be tolerated, reimplantation or a short bypass with saphenous vein is indicated.

### INJURIES TO THE RENAL ARTERY AND VEIN

Management of renal artery lesions is dictated by the overall status of the patient, duration of ischemia, and presence or absence of a contralateral kidney. It is important to remember that after 60 minutes of warm ischemia time, most of the kidney's excretory function is lost. While some authors advocate renal vascular repair within the first 3–6 hours after injury, preservation of long-term renal function in these cases has been poor.<sup>57,58</sup> Therefore, situations in which there is nonvisualization of one kidney on a preoperative CTA or intravenous pyelogram (IVP) suggests that renal function will not be salvaged by revascularization. In most cases of arterial transection, ligation with nephrectomy is indicated. In cases of blunt trauma observation is usually indicated. In circumstances where the status of the kidney is unknown or when there is not a contralateral kidney, attempts at revascularization should be undertaken. The most expeditious approach is aortorenal bypass for lesions of the main renal artery, using saphenous vein with PTFE as a second choice. Lesions of the more distal renal artery, at or beyond branch points, are best ligated in the acute situation, unless they can be repaired with a simple vein patch, or if the injury is to a solitary functioning kidney. If there is doubt about contralateral renal function, the ipsilateral (damaged kidney) ureter can be clamped and indigo carmine administered intravenously. Appearance of dye in the urine confirms contralateral kidney function. Renal artery thrombosis due to blunt trauma, diagnosed as lack of perfusion on CT scan, can be treated by endovascular placement of a stent<sup>59</sup> if the patient is otherwise stable. However, salvage of a renal vessel in a patient with a contralateral functioning kidney remains a secondary priority in the trauma patient's overall management.

Lesions of the proximal renal veins may be ligated, as long as collateral flow through the gonadal, adrenal, and hypogastric veins is preserved. This works best on the left side. While it is known that some transitory renal dysfunction will occur after renal vein ligation, it is generally well tolerated. If inadequate venous collaterals exist or have been damaged during the course of the injury, a short bypass between the renal vein and the vena cava with 8- to 10-mm PTFE can be performed, although ligation and nephrectomy is appropriate if the patient is unstable. Under rare circumstances of injuries to the renal hilum, for example with a solitary kidney, nephrectomy with ex vivo repair and autotransplantation may be indicated. This extensive reconstructive surgery, however, is unwise in an unstable patient with a contralateral functioning kidney.

## TREATMENT OF RUPTURED ABDOMINAL AND VISCERAL ANEURYSMS

In the patient presenting with abdominal pain, pathology of the abdominal aorta and its branches should always be included within the differential diagnosis. Because of their rapidly catastrophic potential, prompt diagnosis and timely treatment for ruptured abdominal aneurysms are mandatory for patient survival and a successful outcome. While the most common aneurysms of the abdomen involve the abdominal aorta and iliac arteries, aneurysms of the visceral vessels may also rupture and present as abdominal emergencies.

### Ruptured Aneurysms of the Aorta and Iliac Arteries

Although historically called *atherosclerotic* aneurysms, the etiology of abdominal aortic aneurysms (AAAs) has come to be recognized as multifactorial.<sup>60</sup> This complex interplay, which includes elastin degradation, increased proteolytic activity, inflammation, matrix metalloproteinases, and other factors, leads to the ultimate development of aortic expansion and degeneration.<sup>61–63</sup> It is for this reason that the term *degenerative* aneurysm better describes the pathophysiology of AAAs. Familial<sup>64</sup> and sex-linked<sup>65</sup> factors also likely contribute: the incidence is several times higher in men, and the relative risk for development of AAA among first-degree relatives of affected individuals is increased 11-fold. The infrarenal aorta is the most common intra-abdominal location for aneurysmal degeneration; aneurysmal degeneration of the suprarenal aorta is much less common.

Despite advances in treatment and early diagnosis, AAAs continue to be a significant cause of death. In the United States, AAAs are the 15th cause of death overall and the 10th leading cause among men older than 55 years.<sup>66</sup> With improvements in the operative and perioperative management of *elective* AAAs, coupled with the introduction and refinement of endovascular techniques, *ruptured* AAAs overwhelmingly account for most of these deaths. Even among specialized centers, the operative mortality for ruptured AAAs is at least 40%, a number that has remained constant over the past three decades.<sup>67</sup> When one also considers the proportion of patients who die without reaching the hospital, the mortality rate approaches 75%.<sup>68</sup> Accordingly, and because AAAs are notoriously asymptomatic until ruptured, much clinical research has centered on the natural history of the disease, specifically focused toward identifiable risk factors for rupture.

The absolute diameter of the aneurysm is the principal determinant of rupture risk. As the diameter increases, the risk of rupture increases nonlinearly, such that larger aneurysms have a significantly higher rupture rate. For example, AAAs 5–5.5 cm have an annual rupture risk of less than 5%, whereas those 6–7 cm in diameter have a 10–15% annual risk of rupture.<sup>69</sup> These “hinge points,” in which the



rupture risk rises dramatically, are the basis for recommending elective repair for asymptomatic AAAs based on size alone (in general,  $>5.5$  cm in average risk patients).<sup>70</sup> Several other factors also independently predict rupture risk. The strongest risk factors are hypertension, chronic obstructive pulmonary disease (COPD), and family history of AAA.<sup>71,72</sup> Other possible risk factors include rapid expansion ( $>0.4$  cm annually),<sup>73</sup> female gender,<sup>74</sup> and current smoking history.<sup>75</sup>

The classic presentation for ruptured AAA is abdominal or back pain, pulsatile mass, and hypotension; however, this complete triad is present in only a minority of patients. A large pannus or abdominal girth may preclude appreciation for a pulsatile mass; similarly, a blood pressure of 100 mm Hg systolic in an otherwise hypertensive individual may be mistakenly interpreted as “normotensive.” Pain is almost always a presenting symptom, and may include abdominal or back pain, groin pain, testicular pain, or flank pain. Less commonly, a patient with a large ruptured AAA may be obtunded and can present with hypotension only. The diagnosis of ruptured AAA must be included among the differential in every patient older than 50 years presenting with abdominal pain, abdominal pain and hypotension, or hypotension alone. When a pulsatile mass is also appreciated, the diagnosis of ruptured AAA is almost certain.

Much less commonly, an aortocaval fistula may arise from rupture into the adjacent IVC; signs and symptoms may include a bruit, distended veins, and acute heart failure. In general, these patients may be hypotensive but can usually be resuscitated. Because their treatment is different from that of a ruptured aneurysm, careful examination of the abdomen, with an effort to identify a thrill or bruit, will help in diagnosis.

## DIAGNOSTIC IMAGING

Ultimately, the role of imaging should depend on the patient’s hemodynamic stability. In the patient with abdominal pain and hypotension and a pulsatile abdominal mass, immediate transport to the operating room without imaging is indicated. In the more stable patient, in whom the diagnosis is in question, abdominal ultrasound may be performed rapidly in the emergency room to identify AAAs. When performed expeditiously by an experienced ultrasonographer, the diagnosis of ruptured AAA may be rapidly confirmed. However, the technique is operator-dependent and accuracy may be limited by excessive bowel gas and obesity.

CT scanning is the most accurate and useful radiographic method in the evaluation of ruptured AAA (Fig. 13-16). The most common findings are retroperitoneal hematoma, an aneurysmal aorta, and retroperitoneal stranding of blood. With 100% specificity and a very high sensitivity,<sup>76</sup> CT can reliably confirm or rule out the diagnosis of ruptured AAA as well as identify alternative nonvascular causes of the patient’s symptoms. It also yields important anatomical information about adjacent structures (such as a retroaortic left renal vein, horseshoe kidney, or concomitant iliac aneurysms) and about the aneurysm itself (such as an inflammatory AAA). CT scanning is particularly important if endovascular repair

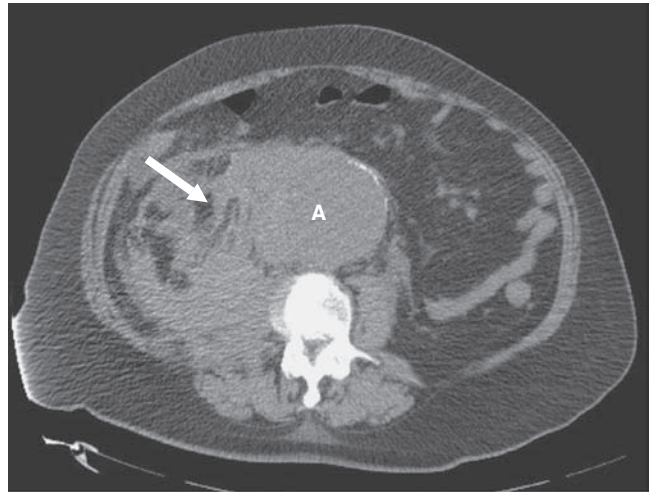


FIGURE 13-16 CT scan of ruptured abdominal aortic aneurysm (AAA) with retroperitoneal hematoma.

is contemplated. The newer-generation multislice scanners allow for complete chest and abdominal imaging to be completed in less than 5 minutes. Although intravenous contrast is very helpful in the planning for elective AAA repair, it is not required for diagnosis in the patient with suspected rupture and may exacerbate postoperative renal dysfunction. Even with an endovascular approach, thin slice (2 mm) non-contrast CT can provide sufficient information for repair.

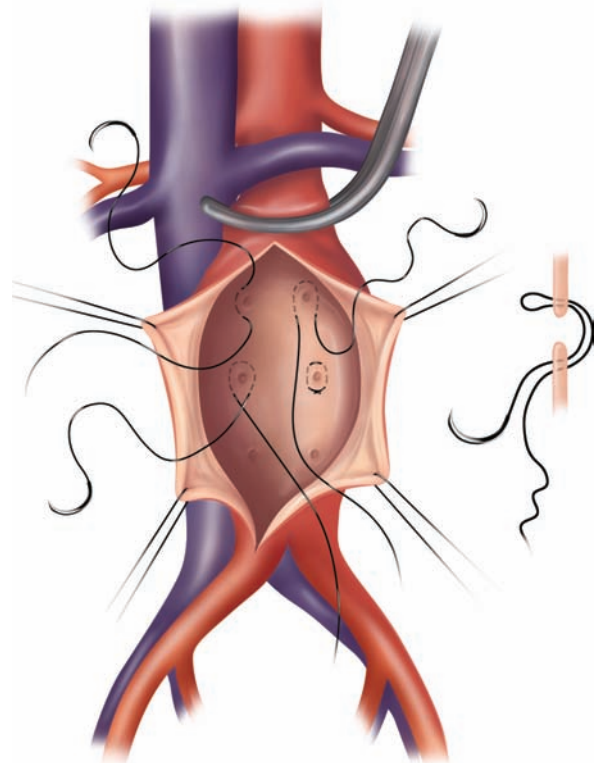


FIGURE 13-17 Control of lumbar vessels from within the aneurysm using mattress sutures to encircle the vessel.

## PREOPERATIVE MANAGEMENT

Once the diagnosis of ruptured AAA is made, either by clinical presentation or radiographically, the patient should be taken immediately to the operating room. Large-bore intravenous access in the upper extremities (or central venous access), indwelling urinary catheter, type and cross-match for at least 6 units of packed cells, and chemistry and coagulation studies should all be performed. Because elevated blood pressure may lead to frank rupture of an otherwise contained leak, a strategy of permissive preoperative hypotension with minimal fluid resuscitation has been recommended. Although no rigid blood pressure parameter exists, most vascular surgeons would favor a minimum systolic pressure to maintain consciousness (usually around 80 mm Hg systolic).

## OPEN REPAIR

Open repair remains the most common and versatile approach to ruptured AAA. Because general anesthesia will lead to both generalized vasodilatation and relaxation of the abdominal musculature, both of which can produce abrupt hypotension; the patient must be prepped and draped (“nipples to knees”) and the surgical team scrubbed prior to induction. A cell saver device should be set up and used when possible. A midline incision is performed for rapid access to the supraceliac aorta. After induction, the abdomen is opened from xiphoid to pubis. The abdomen and retroperitoneum are inspected. If a small or moderate retroperitoneal hematoma is found without intraperitoneal blood, the supraceliac aorta is controlled, as described earlier, but the artery is not clamped. If the juxtarenal aorta is spared of hematoma, this area may be dissected and a clamp applied directly below the renal arteries. Should bleeding develop during the course of this dissection, the supraceliac clamp is applied.

If intraperitoneal blood is present, rapid supraceliac aortic control is obtained, usually by manual compression at the diaphragmatic hiatus while the anesthesiologist rapidly continues resuscitation. The supraceliac aorta is then exposed as previously described and occluded with a vascular clamp. Once the cross clamp is placed, the distal aorta is palpated to confirm obliteration of the pulse and attention is turned to the aneurysm. In patients with massive rupture, bleeding, or hypothermia, in which coagulopathy is almost certainly present, heparin is not given. In such cases, thrombectomy of the distal vessels and vigorous flushing of the graft are necessary prior to restoring flow. In all other cases, we give a small dose of heparin, 40–50 U/kg.

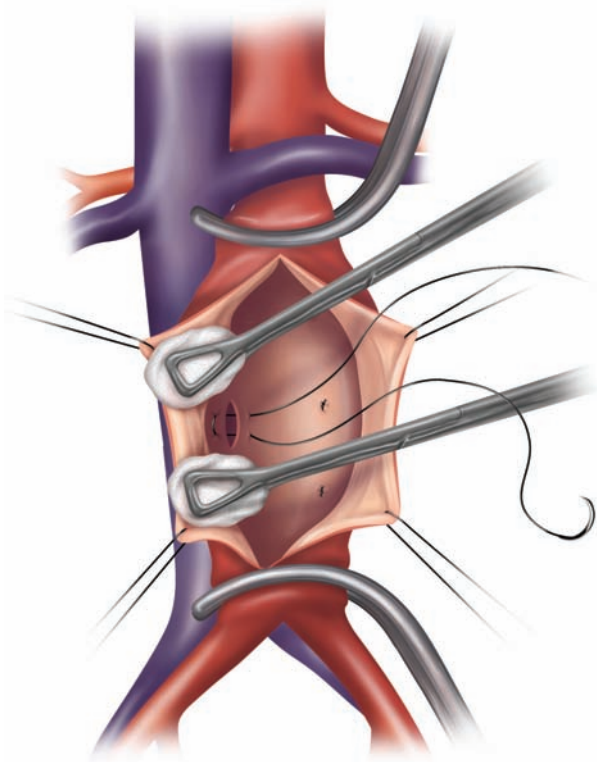
There is an increasing tendency to obtain intravascular supraceliac balloon control of the aorta prior to celiotomy.<sup>77</sup> This is performed by passing a wire and then a balloon into the supraceliac aorta via either a retrograde transfemoral or a prograde transbrachial approach, as described earlier in the chapter, before induction of anesthesia. This requires intraoperative fluoroscopic capabilities and catheter/guidewire skills. This approach provides less invasive and more rapid control

of the supraceliac aorta and can facilitate resuscitation of the patient in circumstances of profound shock.

The aneurysm is approached by evisceration of the transverse colon and omentum cephalad and the small bowel to the right. Care is taken not to injure the IVC or the inferior mesenteric, gonadal, or left renal veins. In most cases, the retroperitoneal hematoma facilitates the dissection. Efforts are made to identify an infrarenal neck of the aneurysm and place a clamp at this level. When there is a free rupture of the aorta, the surgeon can pass the fingers of one hand through the rupture into the aorta (after application of the supraceliac clamp) to help locate the proximal neck of the aneurysm. Bimanual palpation can facilitate the placement of a clamp above the aneurysm without extensive dissection. Once the aortic neck is controlled, the iliac vessels are dissected to allow for clamping and control. Because the iliac veins often adhere to the artery, circumferential dissection around the iliac arteries should be avoided to prevent vein injury. In most cases, the iliac arteries may be readily clamped with minimal dissection. However, if the dissection is difficult, as with a large distal hematoma, endoluminal control may be obtained using a number 5 occlusion balloon, placed in each iliac artery after opening the sac. Once the aneurysm has been isolated proximally and distally, the sac is opened longitudinally and thrombus evacuated. Bleeding from the lumbar vessels is controlled with direct suture ligation using a mattress suture (Fig. 13-17). Venous bleeding encountered inside the sac suggests an aorto caval fistula. In those cases the patient should be placed in mild Trendelenburg's position to reduce the chance of air embolus and the venous bleeding controlled by pressure. The defect is oversewn from within the aneurysm sac, with gentle digital or spongstick compression of the cava proximally and distally (Fig. 13-18). No attempt is made to clamp or mobilize the cava.

Because of the significant risk of colon ischemia following ruptured AAA repair, reimplantation of the IMA should be considered in cases of ruptured AAA.<sup>77</sup> Brisk back bleeding suggests adequate SMA collaterals and implantation is not required. If the IMA is *patent* and back bleeding is absent or sluggish, reimplantation of the IMA should be planned after aortic repair. In these cases, the IMA is controlled just outside the aneurysm sac with a small bulldog clamp, and after the aortic repair the IMA is reimplanted on the aortic graft using a Carrel spatulated patch. An IMA that is obviously occluded at its origin is not reimplanted.

With the aneurysm opened and bleeding controlled, the graft may be sewn in place. When possible, this is done with an infrarenal clamp in place. It is absolutely mandatory that the proximal anastomosis be sewn meticulously into relatively healthy (nonaneurysmal) aorta. Poorly placed sutures in friable aorta will lead to proximal suture line bleeding once clamps are removed. If a secure anastomosis cannot be performed with an infrarenal clamp, the proximal anastomosis should be done with a suprarenal clamp in place. Tamponade of visceral back bleeding may be required while this is performed by placing an inflated balloon catheter through the aneurysm neck into the visceral aorta. Sutures

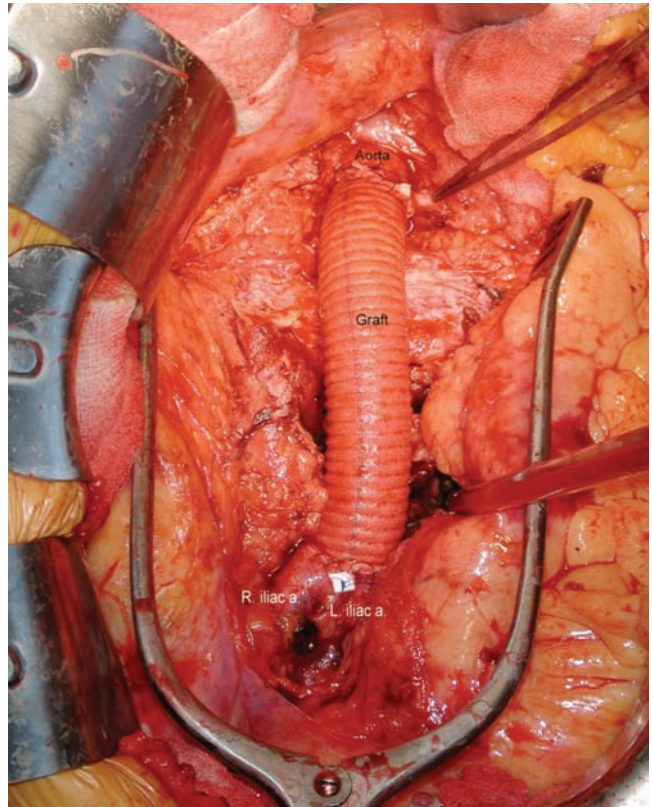


**FIGURE 13-18** Repair of an aortocaval fistula from within the aneurysm. Venous back bleeding is controlled with sponge sticks. This avoids dangerous dissection of the vena cava.

must be placed in the aorta precisely and without tension or torsion of the needle. The proximal anastomosis may be reinforced with a Teflon felt pledget. Once the proximal anastomosis is completed and judged to be satisfactory, heparinized saline (5000 U/1000 mL saline) is flushed into the graft and the graft clamped. The distal anastomosis is then performed in a similar fashion. If heparin had not been given, a number 4 balloon thrombectomy catheter is gently passed down each iliac artery to extract thrombus. The graft should also be flushed to ensure adequate forward flow and the anastomosis is then completed (Fig. 13-19).

The anesthesiologist should be notified before release of the distal clamps. One leg should be perfused gradually, once the pressure has stabilized, the contralateral leg may be perfused. Pulses are checked at the femoral level and should be palpable; if not, thrombus or emboli are likely present and should be treated with thromboembolectomy. With the blood pressure stabilized and following a period of adequate perfusion, both feet should be assessed. Although palpable pulses may not be present, the feet should appear viable with reasonable capillary refill with Doppler flow.

Once adequate perfusion to the lower extremities has been achieved, the colon should be assessed. The colon should appear pink and Doppler flow should be present ideally at the antimesenteric border. If the colon appears ischemic, IMA reimplantation should be performed if not already done.



**FIGURE 13-19** Aortic tube graft in place for treatment of aortic aneurysm.

Hemostasis should be assured as best as possible prior to closure, and this may require infusion of additional clotting factors and protamine if heparin were given. The aneurysm sac is closed snugly around the graft with a running suture to obliterate the dead space and provide some hemostasis. The intestines should be excluded from contact with the graft as best as possible, usually by closing the proximal retroperitoneum or occasionally with a mobilized segment of omentum.

If the abdomen can be closed without tension, the linea alba is approximated and closed with a running suture. However, in many cases, the substantial hematoma precludes closure, and to prevent the development of abdominal compartment syndrome, the abdomen is left open with subsequent delayed closure several days later.

## ENDOVASCULAR REPAIR

The rationale for endovascular repair (EVAR) for ruptured AAAs is extrapolated from data showing less blood loss and improved outcomes in patients undergoing elective endovascular AAA repair<sup>78</sup> and from direct data from specialized centers demonstrating encouraging results with ruptured AAAs.<sup>79,80</sup> EVAR requires accurate assessment of aneurysm geometry using either CT scan or intraoperative calibrated angiography. Accepted anatomic criteria for EVAR include (1) aortic neck diameter between 18 and



32 mm; (2) aortic neck length of 10 mm or greater; (3) proximal aortic neck angulation 60 degrees or less; (4) iliac artery fixation diameter of 8–22 mm; (5) distal iliac artery fixation length of 10 mm or greater (preferably >15 mm); (6) access vessel diameter of 7.5 mm or greater. Other considerations include the degree of iliac tortuosity, circumferential thrombus or calcification, and the aortic length.

Successful application of EVAR technology in treatment of ruptured AAAs requires an experienced surgical team; adequate endovascular imaging capabilities; and an adequate supply of grafts, sheaths, guidewires, and balloons.<sup>80</sup> The single most important consideration is the ability to expeditiously proceed with endovascular aortic control and suitable repair in the patient with a ruptured AAA before irreversible shock occurs. Multiple centers have described their techniques and operative strategy, and some variation exists; however, the fundamental principles are identical to our center's technique. The preoperative management and anesthetic considerations are the same as for open repair. Either local or general anesthesia is utilized; the advantage of the former being that the fall in blood pressure with induction is avoided. This is most advantageous while balloon control is being obtained. In most cases the repair is completed under general anesthesia to facilitate control of the patient's airway and minimize motion.

Access is obtained through both femoral arteries simultaneously. One artery may be accessed percutaneously with placement of a closure device. Once access is obtained by a Seldinger technique, bilateral 6F sheaths are placed over floppy wires and subsequently exchanged for a stiff wire over a guiding catheter to the level of the proximal descending aorta. Contralateral to the side proposed for deploying the main body of the graft, the sheath is exchanged for a large sheath and a compliant 45-mm aortic balloon is introduced to the level of T12. Although a 12F sheath is the minimum size for the compliant aortic balloon, we prefer larger sheaths to allow for simultaneous pigtail catheter placement. If the patient is hemodynamically stable, the procedure can proceed with the balloon in place but not inflated. A marking pigtail catheter is introduced over a second floppy wire, aortogram is performed, and the position of the renal arteries marked. The main body graft is then introduced through the opposite femoral artery over the stiff wire and placed in appropriate position (Fig. 13-20). The deflated aortic balloon and its sheath are pulled back and the graft is deployed as is normally done for an elective EVAR. The contralateral gate of the graft is then cannulated, and the contralateral limb is introduced and deployed. If the patient becomes unstable, the aortic occlusion balloon may be reintroduced through the sheath of the contralateral limb and inflated in the suprarenal aorta.

The ipsilateral limb deployment is then completed and any ipsilateral limb extensions (if needed) are introduced and deployed. Once the endografting has been performed, all fixation sites are molded with the compliant balloon and a completion aortogram performed to document absence of endoleak (Fig. 13-21). A type I (attachment or perigraft leak) or type III endoleak (modular disconnection) warrants further repair before leaving the operating room, whereas a type

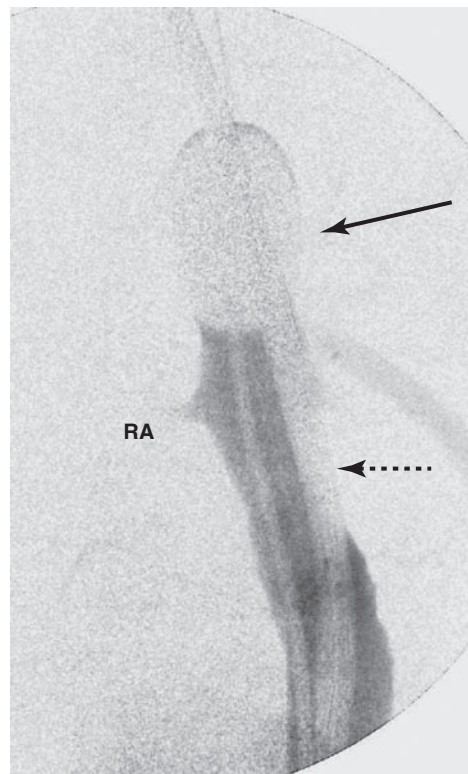


FIGURE 13-20 Intraoperative angiogram showing suprarenal occlusion balloon in place (*arrow*) and sheathed stent graft in position for deployment (*dotted arrow*).

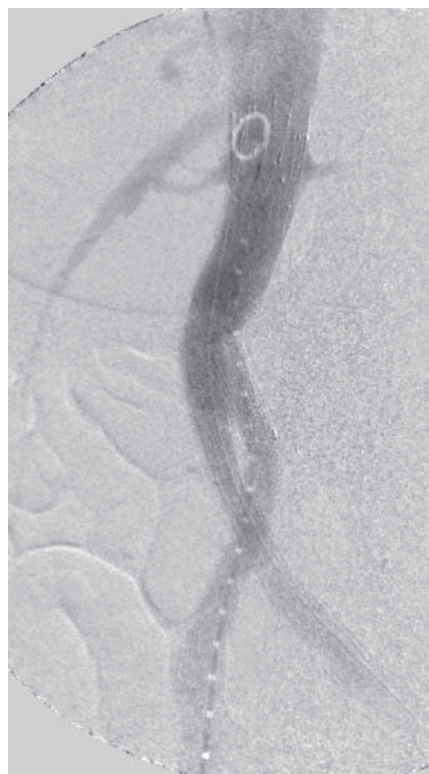


FIGURE 13-21 Completed endograft for ruptured abdominal aortic aneurysm (AAA) showing complete exclusion of the aneurysm.



II (branch endoleak) or type IV (graft porosity) endoleak may be followed conservatively.

The femoral arteries are then closed primarily. If heparin had not been administered, inflow and back bleeding should be assessed prior to closure, and, if judged to be poor, a thrombectomy catheter may be passed gently to retrieve thrombus.

Although the above describes one approach for ruptured EVAR, multiple options exist, and the surgeon should be well acquainted with the options based on anatomic criteria should an endovascular approach be undertaken. These may include conversion to an aortouniliac device with a femoral-femoral crossover graft or a proximal aortic extension in the case of a type I endoleak. It is anticipated that the future generation of endografts, along with greater surgeon experience, will lead to greater use of EVAR for ruptured AAA.

## Results

Although some variation exists among individual series, pooled data suggest an overall perioperative mortality of approximately 50% after open repair for ruptured AAA.<sup>81</sup> Attempts have been made to correlate both pre- and postoperative variables with the probability of survival. Poor prognostic preoperative predictors include hypotension on induction (systolic blood pressure <90); age over 80 years, preoperative cardiac arrest, and low hematocrit.<sup>82</sup> Similar logistic regression analysis has identified postoperative myocardial infarction, respiratory failure, coagulopathy, and renal dysfunction as strong predictors of postoperative mortality; the probability of survival decreases dramatically with two or more complications or with the need for dialysis.<sup>83</sup>

Studies suggest that 40–60% of patients with ruptured AAA may be treated by endovascular means. Encouraging

survival results have been reported following EVAR for ruptured AAA, with perioperative mortality of less than 20% and decreased renal, cardiac, and respiratory complications when compared to historical (open repair) controls.<sup>79</sup> Analyses of institutional algorithms and larger databases suggest that endovascular repair of AAA is increasing and mortality is significantly lower than with open repair.<sup>80,84,85</sup> EVAR for ruptured AAA can be complicated by the development of compartment syndrome requiring decompressive laparotomy in a significant number of patients, and this must remain a consideration when this approach is undertaken.<sup>86</sup> While these admirable results cannot be applied universally, given the small number of specialized centers routinely performing ruptured EVAR, there is hope that increased dissemination of EVAR technology and its application in ruptured AAA will lead to a global decrease in the mortality of ruptured AAA.

## Visceral Artery Aneurysms

Aneurysms of the visceral arteries are uncommon, seen in 0.01–0.02% of autopsy studies.<sup>87</sup> However, the increased utilization of routine body imaging has resulted in greater recognition and discovery of asymptomatic visceral artery aneurysms, and thus their true prevalence is likely higher. The elective treatment of visceral aneurysms is outside the scope of this chapter. The major complications of these aneurysms are rupture or distal embolization and prevention of these complications is the rationale for elective treatment. Table 13-1 summarizes the relative frequency of these aneurysms, their estimated risk of rupture, and recommended treatment. Approximately 25–30% of splanchnic artery aneurysms are ruptured at the time of presentation<sup>88</sup> and about one-third are associated with aneurysms elsewhere in the arterial tree.<sup>89</sup>

**TABLE 13-1: VISCERAL ARTERY ANEURYSMS**

Location	Frequency (%)	Risk of Rupture	Indications for Surgery	Type of Repair
Splenic	60	Low	Symptomatic; pregnant or childbearing age	Ligation; splenectomy; transcatheter embolization
Hepatic	20	High	Symptomatic; asymptomatic >2 cm (or all)	Ligation (common hepatic); endoaneurysmorrhaphy with arterial reconstruction; endovascular stent graft or transcatheter embolization
SMA	6	High	All	Ligation (with revascularization if compromised bowel)
Celiac	4	High	All	Ligation; resection with revascularization; aneurysmorrhaphy
Gastric/Gastroepiploic	4	Very high	All	Ligation
Peripancreatic	Rare	High	All	Transcatheter embolization

This chapter does not concern itself with the elective management of visceral aneurysms, but rather the proper surgical approach once rupture has occurred.

## Splenic Artery Aneurysms

Splenic artery aneurysms are the most frequent visceral aneurysms (60%), are the only aneurysms with a female predominance (3:1), and have the lowest risk of rupture. Splenic artery aneurysms have the lowest risk of rupture, perhaps no more than 10% overall and less than 2% in low-risk patients. However, the risk of rupture rises dramatically among pregnant patients, with maternal and fetal mortality rates of over 70%, and after liver transplantation,<sup>90</sup> which is the rationale for recommending repair of asymptomatic aneurysms in these groups.<sup>91</sup> Both arterial medial dysplasia (more common in females) and the underlying vascular effects of multiple pregnancies (both hormonal and hemodynamic) have been proposed as contributing factors.<sup>92</sup> Other possible etiologies include portal hypertension and splenomegaly, pancreatitis or pseudocyst-associated local inflammation, and trauma. Ruptured splenic artery aneurysm initially presents with abdominal pain referable to hemorrhage in the lesser sac without abdominal distention or shock. These signs may become apparent later after continued hemorrhage spills into the peritoneal cavity through the foramen of Winslow (“double rupture”).

In most cases, ruptured splenic artery aneurysms are treated by laparotomy and ligation. Restoration of arterial continuity is rarely necessary because of the collateral supply to the spleen, and therefore either open or endovascular obliteration of the aneurysmal segment is appropriate. Operative repair of proximal and midsplenic artery aneurysms entails exposure through the lesser sac, proximal and distal control, and simple ligation of the aneurysm without arterial reconstruction. It is important to ligate all feeding vessels; this may require opening the aneurysm and ligation from within the sac. Aneurysms of the splenic hilum require mobilization of the spleen and may be treated by ligation of all branches or splenectomy, if necessary. As in trauma, early control of the proximal splenic artery is important for the treatment of hilar aneurysms. While laparoscopic techniques have been reported for the elective resection of splenic aneurysms,<sup>93</sup> they have no place in the acute setting. Endovascular approaches are generally reserved for patients at high operative risk such as those whose aneurysms are associated with pancreatitis, advanced portal hypertension, or liver transplantation. In these cases, if the patient is stable, vascular access to the splenic artery is obtained through the celiac artery from a femoral or brachial approach. Using guiding sheaths and microcatheters, the splenic artery is engaged and coils are placed distal to the aneurysm, in the aneurysm sac and then proximal to the aneurysm. There is a 10–15% risk of rebleeding<sup>94</sup> using endovascular techniques, as well as a risk of splenic infarction when hilar aneurysms are treated. However, the difficulties of open surgery in patients with pancreatitis or advanced liver disease justify attempts at endovascular treatment as a

first effort. Endovascular stent graft placement has also been described<sup>95</sup> and may be particularly useful in certain subsets, such as patients in whom preservation of splenic blood flow need be maintained (as for portal-systemic shunts) or in high-risk patients with pancreatitis-associated aneurysms and severe inflammation.

## Hepatic Artery Aneurysms

Hepatic artery aneurysms, unlike splenic artery aneurysms, occur more frequently in men. There is some evidence that posttraumatic hepatic artery aneurysms are increasing in frequency. Etiologies include medial degeneration, atherosclerosis, trauma (up to 20% of cases), infection (usually secondary to illicit drug use), vasculitis, and as a consequence of orthotopic liver transplantation.<sup>96</sup> Hepatic artery aneurysms have a rupture risk of no less than 14%<sup>96</sup> and possibly higher.<sup>97</sup> About half the ruptured hepatic artery aneurysms present with signs and symptoms of intraperitoneal hemorrhage, while the other half will rupture into the biliary tract, manifesting as either hemobilia or gastrointestinal hemorrhage.

A variety of treatment options exist for hepatic artery aneurysms, including ligation, excision, repair with arterial grafting and reconstruction, hepatic resection, and endovascular approaches.<sup>87,96–98</sup> Treatment of ruptured hepatic artery aneurysms generally depends on their location and the status of hepatic blood flow. When feasible, preoperative arteriography is helpful in planning the operative approach. Arteriography can provide information on the collateral flow to the liver, demonstrate anomalies such as a replaced right or left hepatic artery, and identify multiple aneurysms, especially in the case of intrahepatic lesions.

Ruptured common hepatic artery aneurysms are treated by simple ligation and exclusion, unless the liver appears ischemic after clamping. Collaterals from the right gastric and gastroduodenal arteries will maintain hepatic artery flow in most cases. Arterial reconstruction is indicated for most aneurysms of the proper hepatic artery and its extra hepatic branches unless the patient is too unstable to tolerate attempts at bypass. In most instances, this requires interposition grafting (preferably with autologous saphenous vein) aneurysmectomy, or endoaneurysmorrhaphy. Because of their proximity to the bile duct and portal vein, dissection of the more distal hepatic or extrahepatic branch arterial aneurysmal segments may be tedious, and proximal and distal control may be easier from within the aneurysm itself. Ruptured aneurysms may require concomitant control at the supraceliac aorta level. If an interposition graft is not possible (as with distal common or proximal proper hepatic artery aneurysms), an aortohepatic bypass can be performed by exposing the right anterolateral border of the aorta through an extended Kocher maneuver and medial visceral rotation. The aortic anastomosis is performed first; the graft is tunneled retroduodenal to the porta hepatis and anastomosed to the hepatic artery after opening the aneurysm. If the patient is unstable, ligation of the hepatic artery, at any level, is acceptable as long as the portal vein is

patent; the risk of hepatic infarction is low and is less than that of an extended procedure in a compromised patient.

Intrahepatic aneurysms are best treated by catheter-based embolization unless they are large. Options for endovascular treatment of hepatic artery aneurysms include both coil embolization and stent graft placement. Embolization has been most useful for small, saccular intrahepatic pseudoaneurysms, as may be seen following trauma or percutaneous biliary procedures with iatrogenic arterial injury. Large intrahepatic aneurysms may require liver resection. Endovascular approaches have also been described for extrahepatic aneurysms, including both coil embolization and the placement of endovascular covered stents.<sup>94</sup>

## Superior Mesenteric Artery Aneurysms

Superior mesenteric artery (SMA) aneurysms have been associated with an infectious etiology, dating back to DeBakey and Cooley's 1953 report of successful resection of a mycotic aneurysm,<sup>99</sup> and systemic infection (usually associated with endocarditis) continues to be a significant factor in their development. Other less common causes of SMA aneurysms include atherosclerosis, connective tissue disorders, vasculitis, and trauma. The risk of rupture of SMA aneurysms is in the range of 40–50%. The majority of SMA aneurysms occur in the proximal 5 cm of the vessel. SMA aneurysms are usually symptomatic, presenting with abdominal pain and sometimes signs of intestinal angina. Treatment of ruptured SMA aneurysms is complicated by their frequent infectious etiology and difficulty with arterial reconstruction. Unlike the situation with trauma to the SMA, resection and reconstruction of aneurysms is often more difficult because the lesion is more extensive. While early teaching mandated proximal SMA reconstruction, larger, contemporary series suggest that ligation without revascularization can be considered in most patients.<sup>100</sup> In these cases, test occlusion of the vessel to assess the extent of intestinal ischemia is critical prior to a decision on the need for reconstruction. When collateral circulation from the celiac and inferior mesenteric arteries, through the pancreaticoduodenal and middle colic vessels, respectively, is sufficient to maintain intestinal viability after test occlusion of the SMA, ligation can be performed. If extensive intestinal ischemia is present after test occlusion, bypass grafting is required. This is usually performed as an interposition graft or a bypass from the infrarenal aorta, using autogenous vein. More distal aneurysms of the SMA can often be treated by ligation with resection of the compromised small bowel as needed. Access to the origin of the SMA is obtained by left medial visceral rotation. The more distal segments of the SMA are exposed by elevating the mesocolon and dissecting through the small bowel mesentery, using the middle colic artery as a guide.

Transcatheter embolization is usually reserved for multiple small bleeding aneurysms in a hemodynamically stable patient. Assessment of bowel viability by angiographic determination of collateral flow and celiotomy is mandatory after the procedure is completed.

## Celiac Artery Aneurysms

Medial degeneration is the most common etiology of celiac artery aneurysms. This is particularly true in those cases associated with anatomic anomalies such as a common celiomesenteric trunk.<sup>101</sup> On occasion, aneurysmal dilation occurs distal to compression by the median arcuate ligament, although the incidence of rupture in these cases is unknown. Atherosclerosis is also associated with celiac aneurysms. Ruptured celiac artery aneurysms are usually treated by ligation, which is generally well tolerated. In saccular or very focal aneurysms, aneurysmectomy, and arterial reconstruction may be considered.<sup>102</sup> In the patient with preexisting liver disease or evidence of portal hypertension, reconstruction is indicated to maximally preserve hepatic nutrient flow. When necessary, arterial continuity may be established using either an aortoceliac bypass, originating from the supraceliac aorta or, less commonly, with an interposition graft. In some cases, the aneurysm may be confined to a portion of arterial wall; aneurysmorrhaphy may be accomplished with excision of that portion of aneurysmal wall provided the remaining wall is healthy. Exposure and control of the celiac artery is best obtained through a transabdominal incision and medial visceral rotation, allowing for visualization and subsequent division of the crura and median arcuate ligament. Alternatively, a direct approach through the lesser sac may be used.

## Gastric, Gastroepiploic, Gastroduodenal, Pancreatic, and Pancreaticoduodenal Aneurysms

Gastric and gastroepiploic aneurysms represent 4% of splanchnic aneurysms, the majority of which are solitary and involve the gastric artery. The etiology is undefined but likely results from either medial degeneration or an associated inflammatory process. These aneurysms have a very high incidence of rupture, either into the peritoneum or the gastrointestinal tract and 70% present with gastrointestinal bleeding. These aneurysms are best treated by ligation, including resection of involved organs as necessary. The excellent collateral supply of the stomach and the urgent nature of the operation make reconstruction inadvisable.

Aneurysms of the gastroduodenal, pancreatic, and pancreaticoduodenal arteries are usually associated with either acute or chronic pancreatitis.<sup>103</sup> Occasionally these aneurysms are seen after liver transplantation or pancreaticoduodenectomy, particularly when complicated by postoperative pancreatic fistula. Most are symptomatic; rupture and gastrointestinal hemorrhage are common occurrences. Because of their association with pancreatic inflammation, gastroduodenal and pancreaticoduodenal aneurysms are best managed with transcatheter embolization and obliteration, especially in the setting of active hemorrhage.

## Aneurysms of Mesenteric Branches and the Inferior Mesenteric Artery

Jejunal, ileal, and colic branch aneurysms are usually small and often solitary.<sup>103</sup> These aneurysms are often identified during angiography to investigate gastrointestinal bleeding or on CT scans for evaluation of abdominal pain. The presence of multiple mesenteric aneurysms suggests a systemic pathology such as polyarteritis nodosa, septic emboli from bacterial endocarditis, or a connective tissue disorder. Rupture is most commonly seen in aneurysms involving colonic branches. Rupture most often occurs into the mesentery, although free intraperitoneal rupture can occur. Management is operative ligation, with resection of involved bowel as necessary. Transcatheter embolization has a very limited role, because laparotomy is required in any case to assess intestinal viability.

Aneurysms of the inferior mesenteric artery are exceedingly rare and little is known about their etiology or natural history. These aneurysms can usually be managed by ligation, with revascularization using autogenous vein if collateral circulation is inadequate.

## COMPLICATIONS AFTER RUPTURED ABDOMINAL ANEURYSMS

Local and systemic complications are frequent after rupture of an abdominal aortic or visceral aneurysm. A high index of suspicion, prompt recognition, with early treatment of complications is mandatory for survival. Mortality rates range from 10–60% for ruptured visceral artery aneurysm and 40–75% ruptured aortoiliac aneurysms. Postoperative bleeding may occur as the result of ongoing coagulopathy (“medical bleeding”) or from a technical defect (“surgical bleeding”). Correction of hypothermia and coagulopathy (using blood component therapy) should be prompt, and abdominal reexploration, if bleeding continues, is mandatory. In the face of extensive blood loss and resuscitation, abdominal compartment syndrome may occur and should be promptly recognized. Abdominal compartment syndrome results in increased peak airway pressures, progressive hypoxemia, renal dysfunction and visceral ischemia from direct compression of mesenteric and hepatic capillary flow and venous compression, reduced cardiac output, and increased intracranial pressure.<sup>104</sup> The diagnosis is suspected on clinical grounds and confirmed by bladder manometry. Bladder pressures that exceed 20 mm Hg should be treated with decompressive celiotomy. Once the edema has resolved (usually within 7 days), the abdomen is closed, either primarily or with mesh.

Residual visceral ischemia may occur after resection of aortic or visceral aneurysms. Patients who have persistent fever, leukocytosis, or ileus after surgery should be evaluated for residual visceral ischemia, pancreatitis, or intra-abdominal abscess. This is particularly true when resection of abdominal organs has been performed. Colon ischemia occurs in up to 30% of patients after ruptured AAA repair, with an associated

mortality of more than 50%.<sup>105</sup> It occurs unpredictably, and can present with a range of signs and symptoms. Diarrhea, which may or may not be bloody, that occurs within 24 hours of AAA resection should raise suspicion of colonic ischemia; flexible sigmoidoscopy should be promptly performed in questionable cases. If the diagnosis of colonic ischemia is confirmed, differentiation between transmural and mucosal ischemia may be difficult, and the decision between nonoperative treatment (with broad spectrum antibiotics, fluids, and bowel rest and repeat colonoscopy) or celiotomy and resection should be based on the patient’s clinical course. In questionable cases, it is better to err on the side of operative intervention and colon resection.

Rupture of the aorta or a major visceral vessel often results in shock and multisystem organ failure. Cardiac (myocardial infarction, heart failure, arrhythmias) and respiratory (respiratory failure, adult respiratory distress syndrome) problems predominate. Renal dysfunction occurs in about one-third of patients undergoing ruptured AAA repair; the need for dialysis portends a poor prognosis, with mortality rates of greater than 75%.<sup>106</sup> Gastrointestinal and infectious complications may also occur, usually in the later stages of protracted convalescence. Finally, the culmination of these manifests as multisystem organ failure, which is the most common cause of death beyond 48 hours in patients with ruptured AAA.

Limb ischemia may be seen in patients after resection of ruptured AAA and is caused by distal embolization of aortic debris. If femoral or popliteal pulses are absent at the conclusion of surgery, prompt vascular exploration, usually by a groin incision, is indicated. In most cases the offending thrombus can be removed with an embolectomy catheter. If femoral and popliteal pulses are present, but pedal Doppler signals are diminished or absent, more distal embolization has occurred. This sometimes manifests as “blue toes” and may be associated with microembolization of atherosclerotic debris to the buttocks, spinal cord, and sometimes abdominal and pelvic viscera. Treatment of this condition is generally supportive, because retrieval of microemboli is not feasible. Outcome depends on the severity and location of embolization and attendant ischemia and may range from full recovery to amputation and death.


## REFERENCES

1. Gore RM, Yaghami V, Vahid T, et al. Imaging in intestinal ischemic disorders. *Radiol Clin North Am.* 1008;46(5):845–875.
2. Levy AD. Mesenteric ischemia. *Radiol Clin North Am.* 2007;45(3):593–599.
3. Veith FJ, Ohki T, Lipsitz EC, Suggs WD, Cynamon J. Endovascular grafts and other catheter directed techniques in the management of ruptured abdominal aortic aneurysms. *Semin Vasc Surg.* 2003;16:326–331.
4. Malina M, Veith FJ, Ivancev K, et al. Balloon Occlusion of the aorta during endovascular repair of ruptured abdominal aortic aneurysm. *J Endovasc Ther.* 2005;12(5):556–559.
5. Green RM, Ricotta JJ, Ouriel K, DeWeese JA. Results of supraceliac aortic clamping in the difficult elective resection of infrarenal abdominal aortic aneurysm. *J Vasc Surg.* 1989;9:124–134.
6. Ricotta JJ, Williams GM. Endarterectomy of the upper abdominal aorta and visceral arteries through an extraperitoneal approach. *Ann Surg.* 1980;192:633.



7. Murray SP, Kuestner LM, Stoney RJ. Transperitoneal medial visceral rotation. *Ann Vasc Surg.* 1995;9:209–216.
8. Ricotta JJ. Venous anomalies encountered during aortic surgery. In: Ernst CB, Stanley JC, eds. *Current Therapy in Vascular Surgery-2*. Toronto, Canada: BC Decker, Inc.; 1990.
9. Dean RH, Hansen KJ. Renal revascularization: how to make a difficult operation easier. In: Veith FJ, ed. *Current Critical Problems in Vascular Surgery*. St. Louis, MO: Quality Medical Publishing; 1989:306–308.
10. Asensio JA, Chahwan S, Hampeter D, et al. Operative management and outcomes of 302 abdominal vascular injuries. *Am J Surg.* 2000;180:528–534.
11. Oldenberg WA, Lau LL, Rodenberg, TJ, Edmonds HJ, Burger CD. Acute mesenteric ischemia: a clinical review. *Arch Intern Med.* 2004;164:1054–1062.
12. Björck M, Acosta S, Lindberg F, Troeng T, Bergqvist D. Revascularization of the superior mesenteric artery after acute thromboembolic occlusion. *Br J Surg.* 2002;89:923–927.
13. Edean ED, Barnes SL, Kwolek CJ, Minton TJ, Schwatz TH, Mentzer RW, Jr. Surgical management of thrombotic acute intestinal ischemia. *Ann Surg.* 2001;233:801–808.
14. Acosta S, Ogren M, Sternby NH, Bergqvist D, Björck M. Clinical implications of acute thromboembolic occlusion of the superior mesenteric artery: autopsy findings in 213 patients. *Ann Surg.* 2005;24:516–522.
15. Bingol H, Zeybeck N, Cingoz F, Yilmaz AT, Tatar H, Sen D. Surgical therapy for acute mesenteric artery embolism. *Am J Surg.* 2004;188:68–70.
16. Comerota AJ, Rao AK, Throm RC, et al. A prospective, randomized, blinded, and placebo-controlled trial of intraoperative intra-arterial urokinase infusion during lower extremity revascularization. Regional and systemic effects. *Ann Surg.* 1993;218(4):534–541.
17. Schoots IG, Levi MM, Reekers JA, et al. Thrombolytic therapy for acute superior mesenteric artery occlusion. *J Vasc Interv Radiol.* 2005;16:317–329.
18. Landis MS, Rajan DK, Simons ME, et al. Percutaneous management of chronic mesenteric ischemia: outcomes after intervention. *J Vasc Interv Radiol.* 2005;16:1319–1325.
19. Kasirajan K, O'Hara PJ, Gray BH, et al. Chronic mesenteric ischemia: open surgery versus percutaneous angioplasty and stenting. *J Vasc Surg.* 2001;33:63–71.
20. Kougiyas P, Panagiotis EF, Zhou W, Lin PH. Management of chronic mesenteric ischemia: the role of endovascular therapy. *J Endovasc Ther.* 2007;14(3):395–405.
21. Wyers M, Powell R, Nolan B, Cronenwett J. Retrograde mesenteric stenting during laparotomy for acute occlusive mesenteric ischemia. *J Vasc Surg.* 2007;45:269–275.
22. Klotz S, Vestring T, Rotker J, et al. Diagnosis and treatment of nonocclusive mesenteric ischemia after open heart surgery. *Ann Thorac Surg.* 2001;72:1583–1586.
23. Trompeter M, Brazda T, Remy CT. Non-occlusive mesenteric ischemia: etiology, diagnosis, and interventional therapy. *Eur Radiol.* 2002;12(5):1179–1187.
24. Rhee RY, Gloviczki P, Mendonca CT, et al. Mesenteric venous thrombosis: still a lethal diseases in the 1990's. *J Vasc Surg.* 1994;20:688–697.
25. Kumar S, Sarr MG, Kamath PS. Mesenteric venous thrombosis. *N Engl J Med.* 2001;345:1683–1688.
26. Abu-Daff S, Abu-Daff N, Al-Shahed M. Mesenteric venous thrombosis and factors associated with mortality: a statistical analysis with five-year follow-up. *J Gastrointest Surg.* 2009;13:1245–1250.
27. Amitrano L, Brancaccio V, Guardascione MA, et al. High prevalence of thrombophilic genotypes in patients with acute mesenteric vein thrombosis. *Am J Gastroenterol.* 2001;96:146–149.
28. Bergentz S, Ericsson B, Hedner U, et al. Thrombosis in the superior mesenteric and portal veins: report of a case treated with thrombectomy. *Surgery.* 1974;76:286–290.
29. Lopera JE, Correa G, Brazzini A, et al. Percutaneous transhepatic treatment of symptomatic mesenteric venous thrombosis. *J Vasc Surg.* 2002;36:1058–1061.
30. Henao EA, Bohannon TW, Silva MB. Treatment of portal venous thrombosis with selective superior mesenteric artery infusion of recombinant tissue plasminogen activator. *J Vasc Surg.* 2003;38:1411–1415.
31. Park WM, Gloviczki P, Cherry KJ, et al. Contemporary management of acute mesenteric ischemia: factors associated with survival. *J Vasc Surg.* 2002;35:445–452.
32. Ballard JL, Stone WM, Hallett JW, et al. A critical analysis of adjuvant techniques used to assess bowel viability in acute mesenteric ischemia. *Am Surg.* 1993;59:309–311.
33. Kaminsky O, Yampolski I, Aranovich D, et al. Does a second look operation improve survival in patients with peritonitis due to acute mesenteric ischemia? A five-year retrospective experience. *World J Surg.* 2005;29:645–648.
34. Demetriades D, Velmahos G, Cornwell EE, et al. Selective non operative gunshot wounds of the anterior abdomen. *Arch Surg.* 1997;132:178–183.
35. Feliciano DV, Burch JM, Grahan JM. Abdominal vascular injury. In: Mattox KL, Feliciano DV, Moore EE, eds. *Trauma*. 4th ed. New York, NY: McGraw-Hill; 2000:783–806.
36. Yasuhara H, Kuroda T, Wada N. Blunt thoracic and abdominal vascular trauma and organ injury caused by road traffic accident. *Eur J Vasc Endovasc Surg.* 2000;20:517–522.
37. Demetriades D, Theodorou D, Murray J, et al. Mortality and prognostic factors in penetrating injury of the abdominal aorta. *J Trauma.* 1996;40:761–763.
38. Asensio JA, Forno W, Roidan W, et al. Visceral vascular injuries. *Surg Clin North Am.* 2002;82(1):1–20.
39. Rozycki GS, Knudson MM, Shackford SR, Dicker R. Surgeon performed bedside organ assessment with sonography after trauma (BOAST): a pilot study from the WTA multicenter group. *J Trauma.* 2005;59:1356–1364.
40. Rotondo MF, Schwab CW, McGonigal MD, et al. "Damage control": an approach for improved survival in exsanguinating penetrating abdominal injury. *J Trauma.* 1993;35:375–383.
41. Fox CJ, Gillespie DL, Cox ED, et al. Damage control resuscitation for vascular surgery in a combat support hospital. *J Trauma.* 2008;65:1–9.
42. Rasmussen TE, Clouse WD, Jenkins DH, Peck MA, Eliason JL, Smith DL. The use of temporary vascular shunts as damage control adjuncts in the management of wartime vascular injury. *J Trauma.* 2006;61:8–12.
43. Lee JT, Bongard FS. Iliac Vessel Injuries. *Surg Clin North Am.* 2002;82(1):21–48.
44. Starnes B, Arthurs ZM. Endovascular management of vascular trauma. *Perspect Vasc Surg Endovasc Ther.* 2006;18:114–129.
45. Yeh MW, Horn JK, Schechter WB, Chuter TA, Lane JS. Endovascular Repair of an actively hemorrhaging gunshot injury to the abdominal aorta. *J Vasc Surg.* 2006;42:1007–1009.
46. Valentine RJ, Clagett GP. Aortic graft infections: replacement with autogenous vein. *Cardiovasc Surg.* 2001;9:419–425.
47. Black SA, Wolfe JH, Clark M, Hamady M, Cheshire NJ, Jenkins MP. Complex thoracoabdominal aortic aneurysms: endovascular exclusions with visceral revascularization. *J Vasc Surg.* 2006;43:1081–1089.
48. Greenberg RK, West K, Pfaff K, Foster J, et al. Beyond the aortic bifurcation: branched endovascular grafts for thoracoabdominal and aortoiliac aneurysms. *J Vasc Surg.* 2006;43:879–886.
49. Marino IR, Francesco F, Doria C, Gruttadauria S, Lauro A, Scott VL. A new technique for successful management of complete suprahepatic caval transection. *J Am Coll Surg.* 2008;206:190–194.
50. Nicoluzzi JE, Von Bahten LC, Laux G. Hepatic vascular isolation in treatment of a complex hepatic vein injury. *J Trauma.* 2007;63:684–686.
51. Buckman RF, Pathak AS, Badelino MM, Bradley KM. Injuries of the inferior vena cava. *Surg Clin North Am.* 2001;81:1431–1447.
52. Carrillo EH, Spain DA, Wilson MA, Miller FB, Richardson JD. Alternatives in the management of penetrating injuries to the iliac vessels. *J Trauma.* 1998;44:1024–1029.
53. Picard E, Marty-Ane CH, Vernhet H, et al. Endovascular management of traumatic infrarenal abdominal aortic dissection. *Ann Vasc Surg.* 1998;12:515–521.
54. Huang W, Villavicencio JL, Rich NM. Delayed treatment and late complications of a traumatic arteriovenous fistula. *J Vasc Surg.* 2005;43:715–717.
55. Spencer TA, Smyth SH, Wuttuch G, Hunter GC. Delayed presentation of traumatic aortocaval fistula: a report of two cases and a review of the associated compensatory and structural changes. *J Vasc Surg.* 2006;43:836–840.
56. Waldrop JL, Dart BW 4th, Barker DE. Endovascular stent graft treatment of a traumatic aortocaval fistula. *Ann Vasc Surg.* 2005;19:562–565.
57. Elliot SP, Olweny EO, McAninch JW. Renal artery injuries: a single center analysis of management strategies and outcomes. *J Urol.* 2007;178:2451–2455.
58. Tillou A, Romero J, Asensio JA, et al. Renal vascular injuries. *Surg Clin North Am.* 2001;81:1417–1430.

59. Villas PA, Cohen G, Putnam SG. Wallstent placement in a renal artery after blunt abdominal trauma. *J Trauma*. 1999;46:1137–1139.
60. Patel MI, Hardman DT, Fisher CM, Appleberg M. Current views on the pathogenesis of abdominal aortic aneurysms. *J Am Coll Surg*. 1995;181:371–382.
61. Dobrin PB, Mrkvicka R. Failure of elastin or collagen as possible critical connective tissue alterations underlying aneurysmal dilatation. *Cardiovasc Surg*. 1994;2:484–488.
62. Shah PK. Inflammation, metalloproteinases, and increased proteolysis: an emerging pathophysiological paradigm in aortic aneurysm. *Circulation*. 1997;96:2115–2117.
63. McMillan WD, Pearce WH. Increased plasma levels of metalloproteinase-9 are associated with abdominal aortic aneurysms. *J Vasc Surg*. 1999;29:122–127.
64. Johansen K, Koepsell T. Familial tendency for abdominal aortic aneurysms. *JAMA*. 1986;256:1934–1936.
65. Vardulaki KA, Walker NM, Day NE, et al. Quantifying the risks of hypertension, age, sex and smoking in patients with abdominal aortic aneurysm. *Br J Surg*. 2000;87:195–200.
66. Bengtsson H, Bergqvist D. Ruptured abdominal aortic aneurysm: a population-based study. *J Vasc Surg*. 1993;18:74–80.
67. Bown MJ, Sutton AJ, Bell PRF, Sayers RD. A meta-analysis of 50 years of ruptured abdominal aortic aneurysm repair. *Br J Surg*. 2002;89:714–730.
68. Kantonen I, Lepäntalo M, Brommels M, et al. Mortality in ruptured abdominal aortic aneurysms. The Finnvasc Study Group. *Eur J Vasc Endovasc Surg*. 1999;17:208–212.
69. Lederle FA, Johnson GR, Wilson SE, et al. Rupture rate of large abdominal aortic aneurysms in patients refusing or unfit for elective repair. *JAMA*. 2002;287:2968–2972.
70. Brewster DC, Cronenwett JL, Hallett JW, Jr, et al. Guidelines for the treatment of abdominal aortic aneurysms. Report of a subcommittee of the Joint Council of the American Association for Vascular Surgery and Society for Vascular Surgery. *J Vasc Surg*. 2003;37:1106–1117.
71. Cronenwett JL, Murphy TF, Zelenock GB, et al. Actuarial analysis of variables associated with rupture of small abdominal aortic aneurysms. *Surgery*. 1985;98:472–483.
72. Darling RC 3rd, Brewster DC, Darling RC, et al. Are familial abdominal aortic aneurysms different? *J Vasc Surg*. 1989;10:39–43.
73. Limet R, Sakalihassan N, Albert A. Determination of the expansion rate and incidence of rupture of abdominal aortic aneurysms. *J Vasc Surg*. 1991;14:540–548.
74. Verloes A, Sakalihassan N, Koulischer L, Limet R. Aneurysms of the abdominal aorta: familial and genetic aspects in three hundred thirteen pedigrees. *J Vasc Surg*. 1995;21:646–655.
75. Brown LC, Powell JT. Risk factors for aneurysm rupture in patients kept under ultrasound surveillance. UK Small Aneurysm Trial Participants. *Ann Surg*. 1999;230:289–296.
76. Weinbaum FI, Dubner S, Turner JW, Pardes JG. The accuracy of computed tomography in the diagnosis of retroperitoneal blood in the presence of abdominal aortic aneurysm. *J Vasc Surg*. 1987;6:11–16.
77. Arthurs ZM, Sohn VY, Starnes BW. Ruptured abdominal aortic aneurysms: Remote aortic occlusion for the general surgeon. *Surg Clin North Am*. 2007; 87:1035–1045.
78. Moore WS, Kashyap VS, Vescera CL, Quiñones-Baldrich WJ. Abdominal aortic aneurysm: a 6-year comparison of endovascular versus transabdominal repair. *Ann Surg*. 1999;230:298–308.
79. Ohki T, Veith FJ. Endovascular therapy for ruptured abdominal aortic aneurysms. *Adv Surg*. 2001;35:131–151.
80. Mehta M, Taggart J, Darling RC III, et al. Establishing a protocol for endovascular treatment of ruptured abdominal aortic aneurysms: outcomes of a prospective analysis. *J Vasc Surg*. 2006;44:1–8.
81. Katz DJ, Stanley JC, Zelenock GB. Operative mortality rates for intact and ruptured abdominal aortic aneurysms in Michigan: an eleven-year statewide experience. *J Vasc Surg*. 1994;19:804–815.
82. Johansen K, Kohler TR, Nicholls SC, et al. Ruptured abdominal aortic aneurysm: the Harborview experience. *J Vasc Surg*. 1991;13: 240–247.
83. Johnston KW. Ruptured abdominal aortic aneurysm: six-year follow-up results of a multicenter prospective study. Canadian Society for Vascular Surgery Aneurysm Study Group. *J Vasc Surg*. 1994;19:888–900.
84. Starnes BW, Quiroga E, Tran NT, et al. Ruptured abdominal aortic aneurysms: the Harborview experience—part 2. *J Vasc Surg*. 2009;59(suppl):S7.
85. McPhee J, Eslami MH, Arous EJ, Messina LM, Schanzer A. Endovascular treatment of ruptured abdominal aortic aneurysms in the United States (2001–2006): A significant survival benefit over open repair is independently associated with increased institutional volume. *J Vasc Surg*. 2009;49:817–826.
86. Mehta M, Darling RC III, Roddy SP, et al. Factors associated with abdominal compartment syndrome complicating endovascular repair of ruptured abdominal aortic aneurysms. *J Vasc Surg*. 2005;42:1047–1051.
87. Berceli SA. Hepatic and splenic artery aneurysms. *Semin Vasc Surg*. 2005; 18:196–201.
88. Carr SC, Pearce WH, Vogelzang RL, et al. Current management of visceral artery aneurysms. *Surgery*. 1996;120:627–634.
89. Carr SC, Mahvi DM, Hoch JR, et al. Visceral artery aneurysm rupture. *J Vasc Surg*. 2001;33:806–811.
90. Lee PC, Rhee RY, Gordon RY, Fung JJ, Webster MW. Management of splenic artery aneurysms: the significance of portal and essential hypertension. *J Am Coll Surg*. 1999;189:483–490.
91. dePerrot M, Buhler L, Deleaval J, et al. Management of true aneurysms of the splenic artery. *Am J Surg*. 1998;175:466–468.
92. Stanley JC, Fry WJ. Pathogenesis and clinical significance of splenic artery aneurysms. *Surgery*. 1974;76:898–909.
93. Arca MJ, Gagner M, Heniford BT, et al. Splenic artery aneurysms: methods of laparoscopic repair. *J Vasc Surg*. 1999;30:184–188.
94. Kasirajan K, Greenberg RK, Clair D, Ouriel K. Endovascular management of visceral artery aneurysm. *J Endovasc Ther*. 2001;8:150–155.
95. Arepally A, Dagli M, Hofmann LV, et al. Treatment of splenic artery aneurysm with a stent graft. *J Vasc Interv Radiol*. 2002;13:631–633.
96. Abbas MH, Fowl RJ, Stone WM, et al. Hepatic artery aneurysm: factors that predict complications. *J Vasc Surg*. 2003;38:41–45.
97. Salo JA, Aarnio PT, Jarvinen AA, et al. Aneurysms of the hepatic arteries. *Am Surg*. 1989;55:705–709.
98. Messina LM., Shanley CJ. Visceral artery aneurysms. *Surg Clin North Am*. 1997;77:425–442.
99. DeBakey ME, Cooley DA. Successful resection of mycotic aneurysm of the superior mesenteric artery: case report and review of the literature. *Am Surg*. 1953;19:202–212.
100. Stone WM, Abbas M, Chery KJ, et al. Superior mesenteric artery aneurysms: Is presence an indication for intervention? *J Vasc Surg*. 2002;36:234–237.
101. Mammamo E, COsci M, Zanon A, et al. Celiomesenteric trunk aneurysm. *Ann Vasc Surg*. 2009;23:257.
102. Graham LM, Stanley JC, Whitehouse WM, Jr, et al. Celiac artery aneurysms: Historic (1745–1949) versus contemporary (1950–1984) differences in etiology and clinical importance. *J Vasc Surg*. 1985;5:757–763.
103. Shanley CJ, Shah NL, Messina LM. Uncommon splanchnic artery aneurysms: pancreaticoduodenal, gastroduodenal, superior mesenteric, inferior mesenteric, and colic. *Ann Vasc Surg*. 1996;10:506–515.
104. Papavassiliou V, Anderton M, Loftus IM, et al. The physiological effects of elevated intra-abdominal pressure following aneurysm repair. *Eur J Vasc Endovasc Surg*. 2003 Sep;26(3):293–298.
105. Levison JA, Halpern VJ, Kline RG, et al. Perioperative predictors of colonic ischemia after ruptured abdominal aortic aneurysm. *J Vasc Surg*. 1999;29:40–45.
106. Harris LM, Faggioli GL, Fiedler R, Curl GR, Ricotta JJ. Ruptured abdominal aortic aneurysms: factors affecting mortality rates. *J Vasc Surg*. 1991;14:812–818.



# ESOPHAGUS

*This page intentionally left blank*



# BENIGN ESOPHAGEAL DISORDERS

Saurabh Khandelwal • Brant K. Oelschlager

The esophagus is a muscular tube whose function is to transport ingested material from the pharynx to the stomach. Its function is the result of a complex symphony of neuromuscular coordination. The esophagus is subject to a variety of disorders, both congenital and acquired. This chapter deals with the most common benign disorders encountered by the surgeon. These include paraesophageal hernias (PEHs), esophageal diverticula, and motility disorders. Our goal is to provide a logical and efficient approach to the evaluation and management of these disorders. Esophageal malignancy and gastroesophageal reflux disease (GERD) are addressed elsewhere in this book.

## PARAESOPHAGEAL HERNIA

Paraesophageal hernias (PEHs) result from a defect at the diaphragmatic hiatus. Upward displacement of abdominal contents into the mediastinum occurs due to widening of the hiatal aperture between the right and left crura. The negative pressure of the chest creates a downward pressure gradient from the abdomen further facilitating this shift. Herniation may result from congenital anatomic causes, or it may be a result of trauma or iatrogenic causes. Prior surgery involving the gastroesophageal junction (GEJ), including esophageal mobilization, crural repair, or fundoplication, can result in PEH formation. The stomach is the organ most frequently involved; other organs including the colon, omentum, spleen, liver, and pancreas may also be associated.

## Etiology And Anatomic Classification

Hiatal hernias are classified according to the location of the GEJ in relation to the diaphragmatic hiatus and also by the contents of the hernia sac. Type I hiatal hernias are by far most common and are characterized by cephalad displacement of the GEJ above the hiatus into the mediastinum (Fig. 14-1). Type I hiatal hernias are often referred to as sliding hiatal hernias and are typically reducible. Patients with type I hiatal

hernias often suffer from gastroesophageal reflux (GER) as a consequence of the altered anatomy and mechanical function of the lower esophageal sphincter (LES) and hiatal complex. Loss of intra-abdominal esophageal length and alteration of the angle of His contribute to this. If type I hiatal hernias enlarge significantly, they may become fixed above the hiatus.

Type II hiatal hernias are considered true paraesophageal hernias and result from cephalad displacement of the fundus of the stomach into the mediastinum. The GEJ itself remains in its normal intra-abdominal location (Fig. 14-2). Dysphagia is a common symptom associated with a type II hiatal hernia, usually due to compression of the esophagus by the stomach. These types of hernia are also referred to as “rolling” hernias. Herniated portions of the stomach are typically found in the posterior mediastinum. These are the least common type of hiatal hernia.

Type III hiatal hernias are also true paraesophageal hernias and are best thought of as a combination of types I and II whereby both the GEJ and a portion of the stomach have herniated above the diaphragmatic hiatus (Fig. 14-3). These can become quite large and may involve complete herniation of the stomach into the thorax. The anchoring attachments of the stomach such as the gastrosplenic ligament and phrenogastric ligaments can become quite attenuated and stretched. This type of hernia can result in partial or complete outlet obstruction as well as in volvulus. Both organoaxial volvulus, where the stomach twists along its longitudinal axis, and mesoaxial volvulus, where the stomach flips anteriorly along its transverse axis, can occur. Organoaxial volvulus is more common. Patients will typically complain of reflux, dysphagia, regurgitation, and respiratory symptoms, all resulting from the displacement and altered mechanics of both the GEJ and the stomach.

Type IV hiatal hernias are distinguished by herniation of other abdominal viscera or omentum above the diaphragm. This can occur in association with either a type II or III PEH. The transverse colon and omentum are frequently involved, but other organs such as the spleen, liver, and pancreas may also be involved. Presenting symptoms can vary with particular organ involvement.

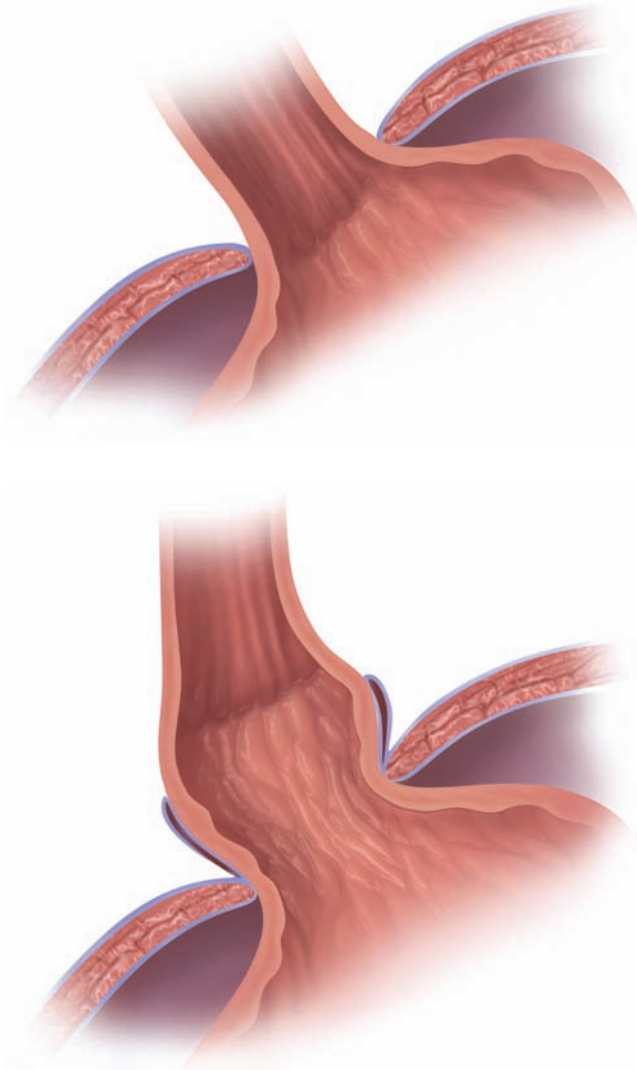


FIGURE 14-1 Type I hiatal hernia or sliding hiatal hernia. (Oelschlager B, Eubanks T, Pellegrini C. *Sabiston Textbook of Surgery*, 18th ed, Chapter 42.)

## Clinical Presentation

Presentation of patients with PEH can vary widely from an incidental finding to an emergent presentation involving strangulation. Symptoms are often nonspecific and can include nausea, dysphagia, dyspnea, heartburn, regurgitation, bloating, chest pain, abdominal pain, early satiety, and aspiration leading to pneumonia. Severe pain is an ominous sign and usually indicates volvulus or incarceration evolving to strangulation. Symptoms can also be vague and intermittent with patients experiencing relief of their symptoms with shifting of their hernia contents or with relief of visceral torsion.

Iron deficiency anemia resulting from gastrointestinal (GI) bleeding due to mucosal ischemia is a common presenting finding in patients with PEH, affecting over one-third of patients with this condition.<sup>1</sup> This results from mucosal

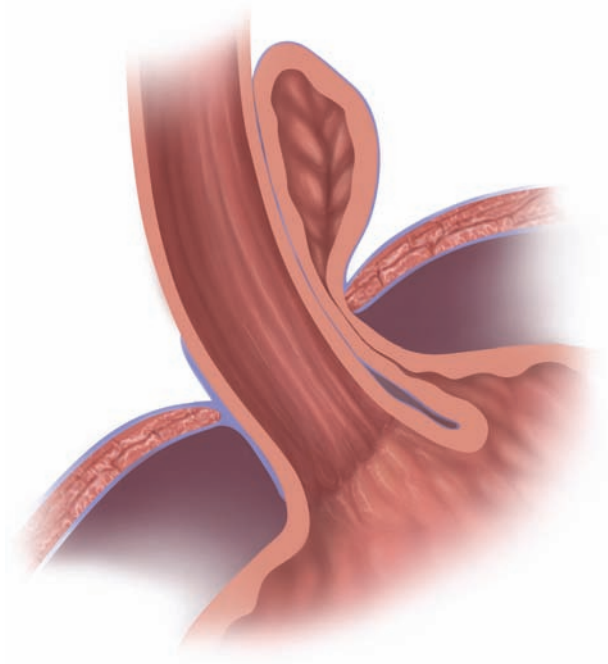


FIGURE 14-2 Type II hiatal hernia. (Oelschlager B, Eubanks T, Pellegrini C. *Sabiston Textbook of Surgery*, 18th ed, Chapter 42.)

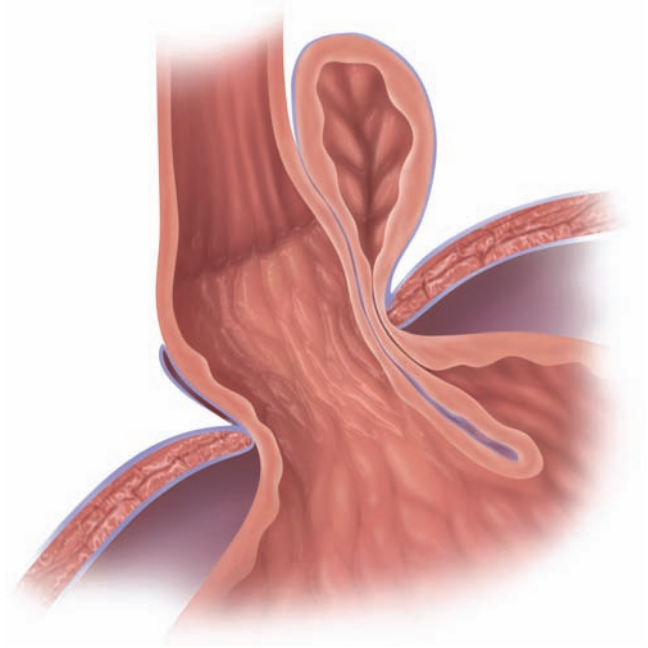


FIGURE 14-3 Type III hiatal hernia. (Oelschlager B, Eubanks T, Pellegrini C. *Sabiston Textbook of Surgery*, 18th ed, Chapter 42.)

irritation and ischemia occurring at the neck of the hernia sac where the crura are extrinsically compressing and rubbing against the gastric fundus, resulting in the linear gastric erosions known as *Cameron's ulcers*.<sup>1-3</sup> It is usually not until after exhaustive workup for other causes of anemia that the diagnosis of PEH as the offending agent is obtained. Surgical correction of the hernia results in resolution of the anemia.<sup>4</sup>

While the natural history of paraesophageal hernias is not clearly known, it is known that many of these hernias are incidental findings. They are commonly discovered on chest x-rays, CT scans, or during upper endoscopies being performed for other reasons. This is revealing as it tells us that the true incidence remains unclear.

## Diagnosis and Evaluation

The physical examination is frequently unimpressive and nonspecific in these patients. Abdominal examination is usually unremarkable. Chest examination with auscultation may reveal decreased breath sounds on the affected side or the presence of bowel sounds within the chest. It is not uncommon for patients to undergo extensive workup for noncardiac chest or abdominal pain, ultimately arriving at upper GI (UGI) evaluation with which the diagnosis is made. Upper GI endoscopy and imaging studies are the mainstays of diagnosis and evaluation.

## Imaging Studies

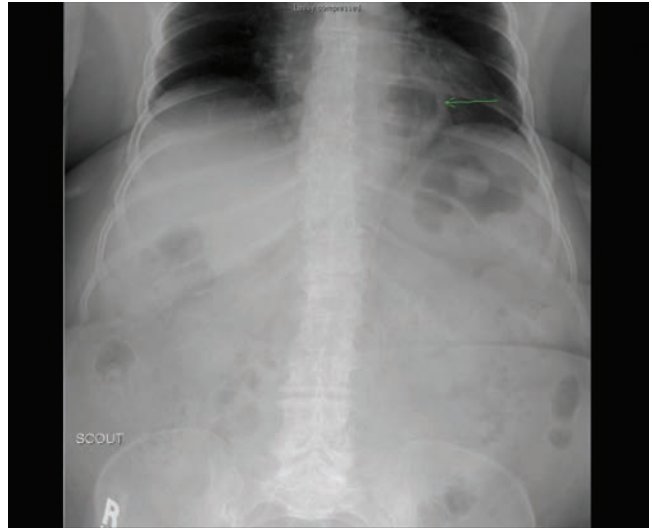
Chest x-rays, whether obtained for entirely unrelated reasons or not, can give the diagnosis of PEH. Common findings on chest films include a retrocardiac air-fluid level, resulting from an intrathoracic stomach (Fig. 14-4). Coiling of a nasogastric tube above the diaphragm is another classic finding.

The upper GI barium swallow/esophagogram is an essential part of the workup for these patients and often gives the most accurate information regarding the hernia's anatomy and position, as well as the location of the gastroesophageal junction. It can also offer some functional information regarding esophageal peristalsis and reflux, though it is not the best test to evaluate esophageal function (Fig. 14-5).

Computed tomography (CT) is not typically used in the workup of PEH. Its frequent use in patient workup for other reasons often leads to diagnosis of PEH when present. CT is a good modality to differentiate from other hernias of the diaphragm such as Morgagni's hernia or to evaluate hernia contents in a type IV hiatal hernia.

## Endoscopy

Flexible esophagogastroduodenoscopy (EGD) is an extremely useful diagnostic test and one that is necessary as part of the workup for PEH. EGD allows the operator to evaluate the gastroesophageal junction and the size of the hernia, which

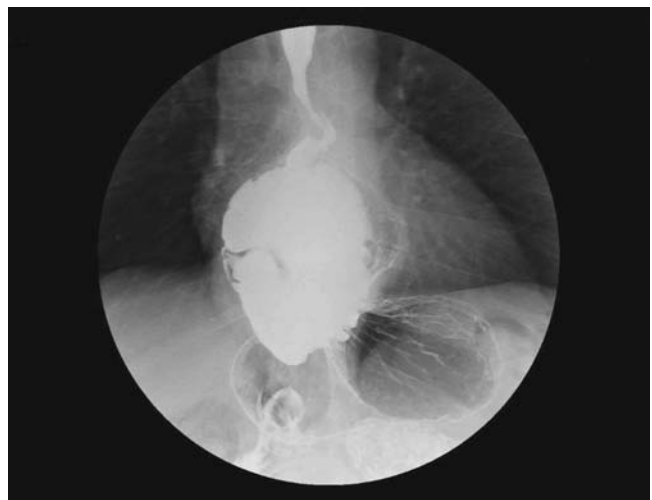

**FIGURE 14-4** Chest x-ray—retrocardiac air-fluid level (arrow) resulting from intrathoracic stomach with paraesophageal hernia. (Used with permission from Saurabh Khandelwal, MD, University of Washington.)

are both seen best on retroflexion. Navigating the anatomy can be a challenge as displacement and extrinsic compression of the esophageal lumen or stomach alter anatomic landmarks. An important part of the endoscopic evaluation is to screen for Barrett's esophagus and malignancy. The presence of either of these can alter therapy.

## Manometry and pH Testing

Ambulatory pH testing and esophageal manometry may be useful adjuncts in the workup of PEH. They can be technically



**FIGURE 14-5** Upper gastrointestinal (GI) barium study. Type III hiatal hernia demonstrated. (Used with permission from Saurabh Khandelwal, MD, University of Washington.)

hard to perform, as intubation of the LES may be impossible to achieve due to anatomic distortion. Clarifying esophageal function in these patients with manometry, while useful, very rarely changes our operative plan. Only under circumstances of complete aperistalsis of the esophagus do we deviate from performing a routine Nissen fundoplication as part of the PEH repair. In these circumstances, either the fundoplication is omitted, or a partial fundoplication (Dor or Toupet) is performed. Because of the difficulty in successfully performing the test and because reflux is addressed surgically in our standard PEH repair with Nissen fundoplication, we do not mandate 24-hour pH testing. For those who perform fundoplication selectively, it may make even more sense to pursue 24-hour pH studies. That said, preoperative pH studies are probably a poor predictor of GERD after repair if a fundoplication is not done, because the hernia itself stretches the phrenoesophageal membrane and the other natural antireflux anatomy. In other words, even if patients do not have GERD before repair, most will develop GERD if a fundoplication is not employed. For patients whose symptoms are primarily related to suspected GERD, pH monitoring should be done to confirm the reason for surgical intervention.

## Indications For Treatment

The indications for operating on patients with PEH continue to evolve over time. Earlier surgical tenets deemed the diagnosis of PEH an indication for surgical correction. This was largely in part due to retrospective observations, published by Skinner, Belsey, and Hill in the late 1960s and early 1970s and from other small case series or reports in which a high incidence of complications and mortality associated with observation or emergent operation was observed. Skinner followed 21 asymptomatic patients, of which 6 (29%) developed complications of bleeding, perforation, or strangulation with observation. This, in addition to an observed pooled mortality rate of 17% with emergent operation but a 1% mortality rate with elective repair, led to the recommendation that all patients fit for surgery should undergo repair of PEH.<sup>5-7</sup> We now know that these hernias are not always symptomatic, often discovered incidentally, less likely than previously thought to present with acute complications, and may not necessarily require repair.

Recently, Stylopoulos and colleagues performed a population-based study showing that mortality rates associated with observation to be lower than previously reported, and the mortality associated with emergent operation to be 5.4% rather than 17%. Their study used a population-based decision model to estimate the risk of watchful waiting versus repair in a cohort of 5 million patients, using available data from the 1997 Nationwide Inpatient Sample (NIS) on PEHs. They estimated that the perioperative mortality rate of those undergoing elective repair to be 1.4% and the annual risk of complications associated with watchful waiting to be 1%. As a result, they concluded that watchful waiting in an asymptomatic or minimally symptomatic population

is a reasonable strategy.<sup>8</sup> We believe that this is a reasonable approach, especially in elderly patients with multiple comorbidities and asymptomatic hernias. We have found their data to be consistent with our clinical experience. Young (<65 years) and fit patients, even if not symptomatic, should probably be considered candidates for repair because they have many years to become symptomatic or develop an acute volvulus. Obviously, patients who are symptomatic or who have demonstrated progression of their symptoms should be evaluated and taken for elective repair if their medical condition allows.

## Therapeutic Controversies

Widely differing opinions exist regarding the aspects of surgical management for paraesophageal hernias. They center on the ideal approach, the use of mesh, management of the shortened esophagus, and the use of fundoplication. As one develops an operative strategy, it is important to keep in mind the fundamental steps that are considered universal in PEH repair: reduction of the stomach into the abdomen without tension, excision of the hernia sac, reapproximation of the crura, and anchoring of the stomach.

### OPERATIVE APPROACH

Laparoscopic, open laparotomy, and transthoracic approaches have been described for PEH repair. Each has advantages and disadvantages. Thoracotomy offers excellent visualization and it is easier to perform gastroplasty for esophageal lengthening from this approach. Performing a fundoplication from the chest, however, is difficult to accomplish. This approach confers the most morbidity, with longer hospital stays, need for single-lung ventilation, and postoperative chest-tube drainage. Open laparotomy approach is familiar to most surgeons, avoids a chest incision and its associated morbidity, and may result in decreased operative time. Visualization of the mediastinal structures and exposure of the hiatus, however, are difficult with this approach.

The laparoscopic approach overcomes many of the drawbacks of the two conventional open approaches. It provides good visualization of the hiatus and mediastinal structures, and allows for easier creation of a fundoplication. High mobilization of the esophagus into the mediastinum is possible. Avoiding the chest as an open operative field eliminates the need for single-lung ventilation, chest tubes, and the postoperative pain associated with thoracotomy. Since the introduction of laparoscopic techniques, many studies have confirmed its feasibility, safety, quicker recovery, and shorter length of stay.<sup>9,10</sup> While our approach is laparoscopic, we cannot overemphasize that these are complex operations to perform laparoscopically, even for those with advanced laparoscopic foregut experience. They should be left in the hands of experienced laparoscopic foregut surgeons. No randomized clinical trials have been performed comparing the various approaches.



## CRURAL REPAIR

As recurrence is a major outcome measure with any hernia repair, it is important to examine the crural repair component of PEH repair. Crural repair and its longevity, as with any hernia repair, depends on a tension-free closure. Many strategies have been employed to overcome the tendency toward recurrence and improve the chances of healing at the hiatus. These have included the use of pledgets, relaxing incisions, and various types of prosthetic mesh. Two randomized trials comparing hiatal closure with and without mesh were performed by Frantzides et al and Carlson et al.<sup>11,12</sup> Carlson's study randomized patients with PEH to simple suture cruroplasty or cruroplasty with polytetrafluoroethylene (PTFE) and all patients had a Nissen fundoplication. They showed a reduction in hiatal hernia recurrence in patients who received a mesh closure (18.8% recurrence with simple cruroplasty vs 0% recurrence with PTFE-reinforced cruroplasty). Frantzides performed a study that included patients with all types of hiatal hernia (type I–IV) in which patients with hernia defects of greater than 8 cm were randomized to simple suture cruroplasty or cruroplasty with PTFE mesh. At a median follow-up of 2.5 years, a 22% recurrence rate with simple cruroplasty was observed and no recurrences with mesh repair.

Initial enthusiasm and results, mostly from small series, have been tempered with increasing reports of complications at the hiatus because of prosthetic mesh placement, including migration, infection, dysphagia, and erosion into the esophagus. Polypropylene exhibits significant shrinkage due to hydrolysis and adhesions, and we do not recommend its use at the hiatus. PTFE produces fewer adhesions, but erosion into the esophagus can occur.<sup>13</sup> Erosion into the esophagus is a serious complication that usually requires esophagogastrectomy for treatment and is a matter of high consequence.

Our preference has been to use a biologic mesh product to reinforce the primary closure. Biologic meshes act as a collagen-based absorbable bioscaffold into which native tissue ingrowth occurs. These materials potentially address the concerns of erosion, infection, and dysphagia associated with permanent prosthetic mesh placement at the hiatus.<sup>14</sup> To test this approach, we conducted a multicenter randomized trial in which patients were randomized to primary repair (n = 57) or primary repair buttressed with a biologic prosthesis (n = 51, small intestinal submucosa [SIS]). The primary outcome measure was recurrence seen on UGI. Upon completion of our study, we observed a reduction in hernia recurrence rate from 24% down to 9% in 95 patients at 6 months.<sup>15</sup> While our results only represent a 6-month follow-up, Jacobs and colleagues demonstrated excellent results with SIS mesh cruroplasty at a median follow-up of 28 months without complications and with similarly low recurrence rates.<sup>16</sup> Desai and colleagues performed a histologic analysis at 1-year follow-up in a canine model in which SIS mesh was used to repair hiatal defects. They demonstrated that good tissue ingrowth occurred and that SIS mesh cruroplasty did not

result in erosions or strictures.<sup>17</sup> Problems with stenosis and fibrosis at the hiatus have been reported with biologic mesh, but not erosion. A recent review of mesh-related complications by Stadlhuber and colleagues summarizes the current literature in this regard.<sup>18</sup> Like most surgical complications, we feel that the true incidence is likely underreported. At this time, we feel that biologic mesh offers the best efficacy and safety profile of the available hiatal mesh prostheses, and do recommend its use during PEH repair.

## ROUTINE FUNDOPLICATION

Routine partial or total fundoplication should be performed at the time of PEH repair for several reasons. First, there is a significant incidence of postoperative abnormal acid exposure as seen on 24-hour pH testing.<sup>19,20</sup> In addition to the already abnormal gastroesophageal junction anatomy associated with PEH, further dissection at the time of surgery likely disrupts this natural barrier even more, eliminating its contribution to the natural antireflux mechanism of the hiatus. Second, the creation of a fundoplication acts as a gastropexy mechanism anchoring the stomach below the diaphragm, likely reducing recurrence rates. Total fundoplication (360 degrees) has not been associated with increased rates of dysphagia in patients with impaired peristalsis.<sup>21,22</sup> In cases of complete aperistalsis, a partial fundoplication is a reasonable option.

## Operative Technique: Laparoscopic Paraesophageal Hernia Repair

### POSITIONING AND PORTS

The patient is positioned in the low lithotomy position, using a beanbag and gel pad to form a padded mold for support. The operation is performed in the steep reverse Trendelenburg's position (Fig. 14-6).

Access and insufflation are obtained per the surgeon's preference. We gain access at the left upper quadrant, immediately below the costal margin, using a Veress needle and an optical bladed trocar. Our ports are placed in what we refer to as our standard esophageal operating position (Fig. 14-7).

### DISSECTION

The surgeon begins by gently reducing the stomach into the abdomen. The short gastric vessels are then divided using an appropriate energy source. These vessels are usually long and attenuated due to the fundus' displacement into the chest, and they will lead to the base of the left crus. We use a left crus approach as our group previously described.<sup>23</sup> The hernia sac is sharply entered using electrocautery at the base of the left crus. It is important to stay in the correct plane and divide the entire hernia sac. Great care must be taken to avoid injuring the crural pillars, which are usually thin and attenuated. The dissection between the sac and the mediastinal structures is carried up and to the right, proceeding circumferentially

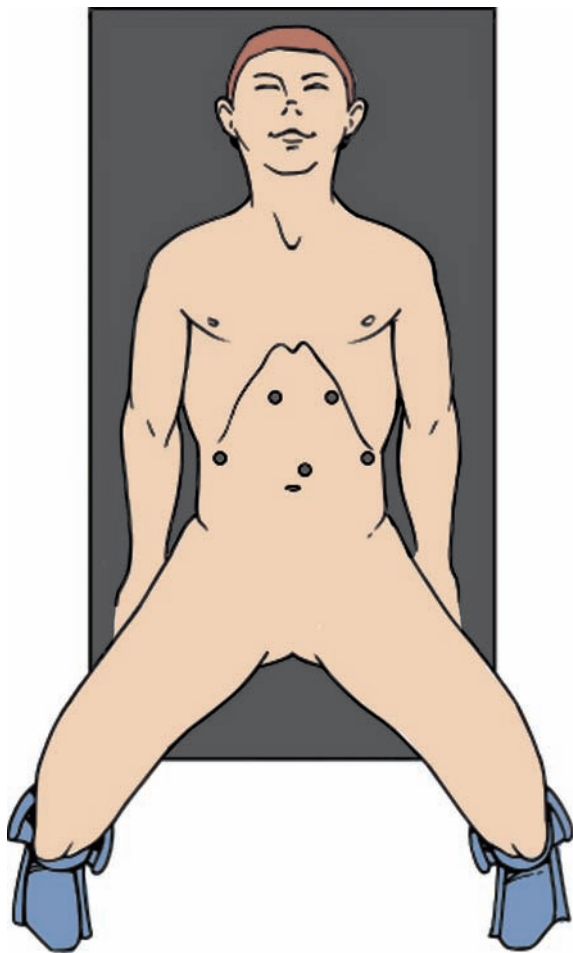


FIGURE 14-6 Patient in low lithotomy position for optimal access and exposure for the hiatus.

around the hiatus. The anterior vagus nerve (as it is often displaced away from the esophagus by the sac and is easily divided) and the esophagus must be clearly identified. The esophagus is distorted, and identification is aided by the careful passage of a lighted bougie placed in the esophagus. The bougie should be pulled back once the esophagus is identified, as traction against it can lead to perforation.

If an aberrant left hepatic artery is encountered, all attempts should be made to preserve it. The sac is then dissected off the right crus, taking care to identify and not injure the posterior vagus nerve. Great caution must be taken to identify and avoid injuring the left gastric artery and vein as they may be stretched and entering the mediastinum. Once the hernia sac is released and reduced from the mediastinum, ½-in Penrose drain is placed around the esophagus at the gastroesophageal junction and used to provide traction. The assistant, through the left flank port, grasps the drain to manipulate the esophagus in order to provide exposure.

All of the hernia sac should be reduced, after which mediastinal dissection is carried out to free up the esophagus and gain length. Dissection of the esophagus is routinely carried up to the level of the pulmonary veins and can be

taken higher if needed. The goal is to dissect enough so that the gastroesophageal junction lies easily and without tension within the abdomen. Once the sac is reduced and the esophagus mobilized, the sac is resected en bloc, beginning to the left of the anterior vagus nerve. We feel this aides with the creation of the fundoplication by keeping this extra tissue out of the wrap.

### CRURAL REPAIR

Posterior crural reapproximation is the next step after mobilization of the esophagus is completed. Either intracorporeal suturing with free needles or a laparoscopic suturing device can be used. We begin inferiorly just above the median arcuate ligament and proceed up the pillars with our sutures. Depending on the size of the defect, three to eight no. 0 or 1 braided, nonabsorbable sutures are placed in interrupted fashion. The 52F bougie can be advanced into the stomach at this time to gauge the cruroplasty. The tip of a blunt instrument should pass in the space between the bougie-filled esophagus and the reapproximated crura. On rare occasions, the final posterior crural sutures, if placed, can cause excessive anterior

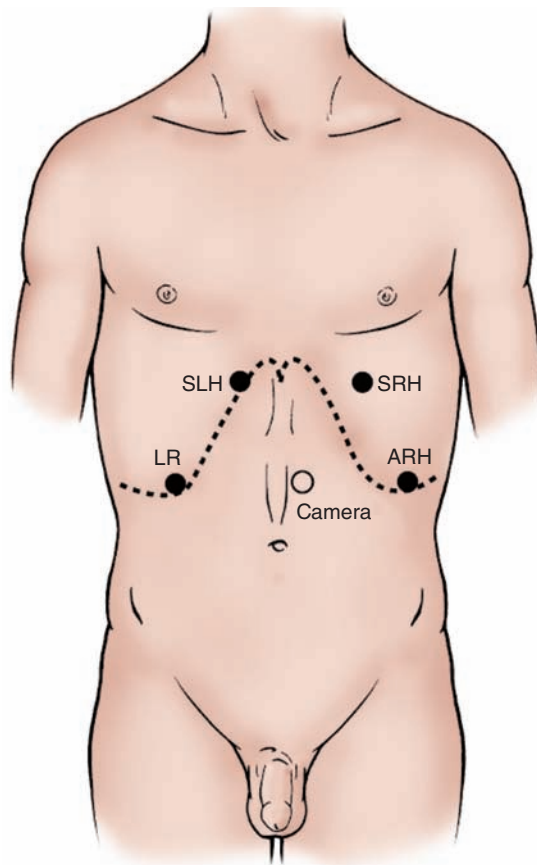
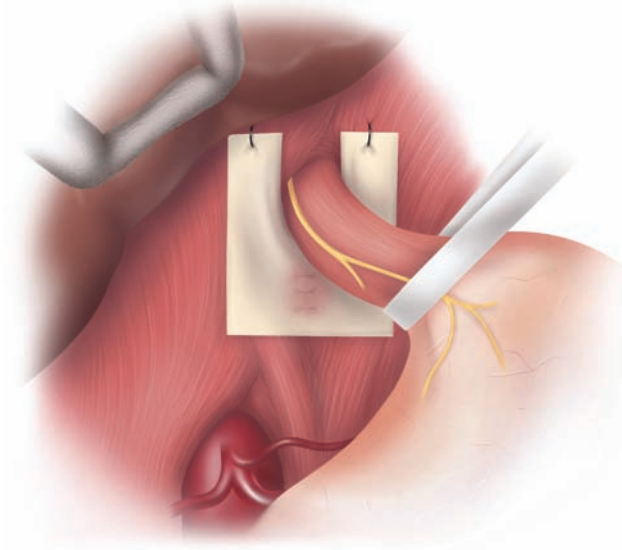


FIGURE 14-7 Port placement for access to the hiatus. ARH, assistant's right hand; LR, liver retractor; SLH, surgeon's left hand; SRH, surgeon's right hand. (Used with permission from Saurabh Khandelwal, MD, University of Washington.)



**FIGURE 14-8** Schematic of paraesophageal hernia (PEH) repair with U-shaped mesh in position. (Used with permission from Saurabh Khandelwal, MD, University of Washington.)

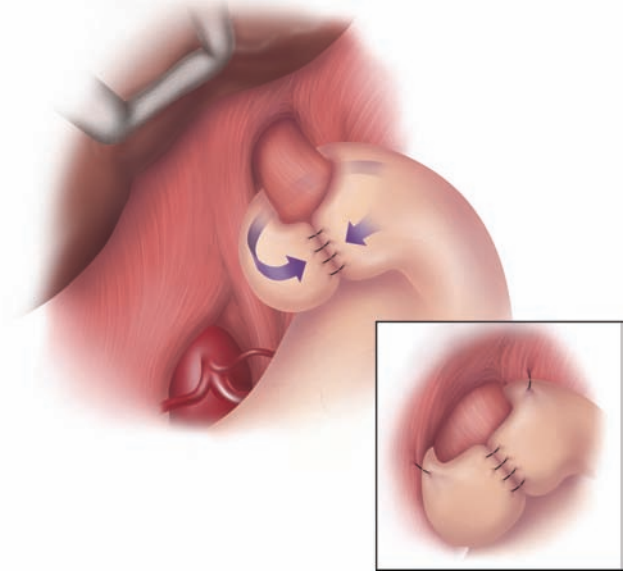
angulation of the esophagus. In this case, we omit them and place anterior crural sutures using the same technique.

A biologic mesh is next used to buttress the crural repair. A U-shaped mesh is fashioned, using six-ply mesh, and affixed to the apex of the right and left crura with suture, then secured posteriorly with fibrin glue (Fig. 14-8).

## FUNDOPLICATION

Fundoplication is then performed over a bougie to ensure appropriate sizing. To ensure correct geometry and positioning of the fundoplication, we first place a marking suture posteriorly on the fundus 3 cm below the gastroesophageal junction and 2 cm from the greater curve. This is brought to the patient's right side posteriorly through the retroesophageal window, at which point this suture is grasped. A mirror image is created with the anterior fundus, and they are brought together at the 10 o'clock position at the hiatus. A "shoeshine" maneuver is performed, bringing the posterior fundus back through the retroesophageal space to the left side, checking to see that an equal length of fundus is used on either side of the greater curve, as marked by the ligated short gastric vessels. This ensures that, when constructed, the sutures on the wrap should be 180 degrees opposite the greater curve.

Four sutures are placed, 1 cm apart, to create a 3-cm wrap. This is done over a 52F bougie. Three additional coronal sutures are placed. The first two are placed on the left and right sides respectively, through the top of the fundoplication, taking a good bite of the esophageal muscle, and finally through that respective right or left crus. The last suture is placed posteriorly where the fundoplication lies naturally against the now closed hiatus (Fig. 14-9).



**FIGURE 14-9** Construction of Nissen fundoplication after paraesophageal hernia (PEH) repair. (Oelschlager B, Eubanks T, Pellegrini C. *Sabiston Textbook of Surgery*, 18th ed, Chapter 42.)

For the open technique, essentially the same steps are taken but through a midline incision.

## MOTILITY DISORDERS

### Spastic Motility Disorders

Primary esophageal motility disorders (PEMDs) encompass both spastic disorders and achalasia. Spastic disorders include nutcracker esophagus, diffuse esophageal spasm (DES), and hypertensive lower esophageal sphincter (HLES). These rare disorders can present with variable or nonspecific symptoms and can be difficult to diagnose and treat. Symptoms frequently include chest pain, GERD, regurgitation, and less commonly dysphagia. The clinician must pay careful attention to presenting complaints and beware of what symptoms typically respond to treatments and which do not. It is important to distinguish between the primary motility disorders just mentioned and those symptoms secondary to GERD. GERD is a significant cause of esophageal dysmotility and should be evaluated for its presence. Its successful treatment, medically or surgically, often mitigates the symptoms suffered by many patients. These patients may be initially diagnosed with esophageal motility disorders but in actuality have a significant reflux component to their problem.<sup>24-27</sup> Secondary causes of esophageal motility disorders can include diabetes mellitus, Chagas' disease, collagen vascular diseases, and multiple sclerosis. If such conditions exist, their severity and prognosis should be taken into consideration when forming a diagnosis and prior to embarking on any therapy.



## PATIENT PRESENTATION AND EVALUATION

Prior to investigation of the esophagus as the cause of symptoms, a cardiopulmonary evaluation should be performed to rule out the heart or lungs as the cause. The evaluation of motility disorders should include a careful history taking. This may help clarify the diagnosis and should allow the examiner to pick up on any confounding psychiatric illness or disorder that may be responsible, such as rumination syndrome. A systematic workup should include endoscopy and UGI barium swallow to evaluate the anatomy and rule out malignancy or other lesions as a cause. Esophageal manometry is an essential component of the workup, and 24-hour pH study should be performed to evaluate for reflux (Fig. 14-10).

## DIFFUSE ESOPHAGEAL SPASM

Diffuse esophageal spasm (DES) was first described by Osgood in 1889.<sup>28</sup> Typically, patients affected by DES will complain of chest pain and dysphagia, and may present with functional obstructive symptoms. Symptoms of DES can be difficult to distinguish from GERD; both pH and manometry should be performed as part of the workup to evaluate the patient. If abnormal reflux is found on testing, the first treatment strategy should be to control GERD with antisecretory therapy. The defining characteristics of DES on manometry include greater than 10% (but <100%) of wet swallows that are followed by simultaneous esophageal contractions of amplitude 30 mm Hg or greater (Fig. 14-11).<sup>29,30</sup> LES dysfunction, manifested by improper relaxation and/or hypertensive state, is seen in over half of patients diagnosed with DES.<sup>31</sup> Intermittent peristalsis and prolonged contractions are also findings seen on manometry. DES is a rare true finding and is estimated to be found only in 3–5% of patients evaluated for an esophageal motility disorder.<sup>32</sup> Whereas previously there was thought to be little role for surgical treatment in DES, more recent reports of small series have shown good results for relief of dysphagia after esophageal myotomy in up to 80% of highly selected patients, while chest pain is more difficult to cure.<sup>24,31,33</sup> A careful, thorough workup and exclusion of GERD as a confounding factor should be done before attempting to diagnose and surgically treat DES. Medical management is an appropriate initial approach.

## NUTCRACKER ESOPHAGUS

Nutcracker esophagus (NE) was first described by Brand and associates<sup>34</sup> in 1977 and named as such by Castell several years later.<sup>35</sup> Typical presenting symptoms of patients with NE include chest pain and less frequently dysphagia. Its defining characteristics on manometry include hypertensive esophageal contractions of greater than 180 mm Hg (Fig. 14-12). Patti and colleagues performed myotomy for these patients and observed that dysphagia was controlled in 80% of patients, but that chest pain persisted in 50% of them.<sup>31</sup> Interestingly, in the patients with recurrent pain, they *developed* dysphagia postoperatively, possibly because of weakening of peristalsis

by performing the myotomy. Most patients with this manometric finding consistent with NE and presenting with chest pain do not need an operation, and consideration for surgery should rather be carefully given to patients with dysphagia as the presenting symptom. The best candidates may be a small subgroup in which manometry demonstrates a hypertensive LES in addition to NE findings as well as a functional obstruction on UGI. As with DES, one must evaluate for GERD and treat if present. GERD, when present in conjunction with hypertensive esophageal contractions, can be an inciting factor causing further esophageal irritation in a hypersensitive esophagus. Therapy aimed at correcting abnormal acid exposure and irritation can lead to significant improvement in symptoms. The mainstay of treatment is medical therapy. Calcium channel blockers have shown benefit in symptom improvement.<sup>36</sup> Tricyclic antidepressants may also provide symptom relief and benefit to patients.

## HYPERTENSIVE LOWER ESOPHAGEAL SPHINCTER

*Hypertensive lower esophageal sphincter* (HLES) is a condition defined as having a resting LES pressure of greater than 45 mm Hg with intact, normal peristalsis (Fig. 14-13). Incomplete relaxation of the LES may also be a feature. The condition was first described in 1960.<sup>37</sup> Patients with HLES can be a heterogeneous group and can present with symptoms of chest pain and/or dysphagia. They may also have symptoms of a functional obstruction at the LES. Presentation can be with isolated symptoms or in association with GERD. Careful history taking and a thorough workup with manometry and pH testing are essential to clearly define the symptoms and the primary problem in terms of esophageal function. Therapy should be tailored to the presenting symptoms. Medical management to reduce LES pressures with calcium channel blockers, botulinum toxin, and phosphodiesterase inhibitors is typically the first-line approach in management. These drugs can have significant side effects and decreasing efficacy with time. In patients with GERD and manometric findings of HLES, Nissen fundoplication has shown good results in improvement of dysphagia and chest pain.<sup>38,39</sup> This suggests that reflux disease may be the etiology in these patients. Patients with dysphagia or chest pain as their predominant symptom and workup findings of only isolated HLES without GERD are more likely to benefit from myotomy and partial fundoplication for symptom relief, suggesting a primary sphincter dysfunction as the etiology of their symptoms. Good results have been reported by several groups that have used myotomy and partial fundoplication to treat this subset of patients, with relief of symptoms persisting as far as 3 years out.<sup>31,38,40</sup> While medical management is usually a reasonable first-line, conservative approach to treatment of HLES, in carefully selected and thoroughly worked up patients surgical treatment with either Nissen fundoplication or myotomy and partial fundoplication (depending on manometric and pH test findings) can produce good results. As HLES is a rare disease with heterogeneous presentation, the importance of carefully and thoroughly working



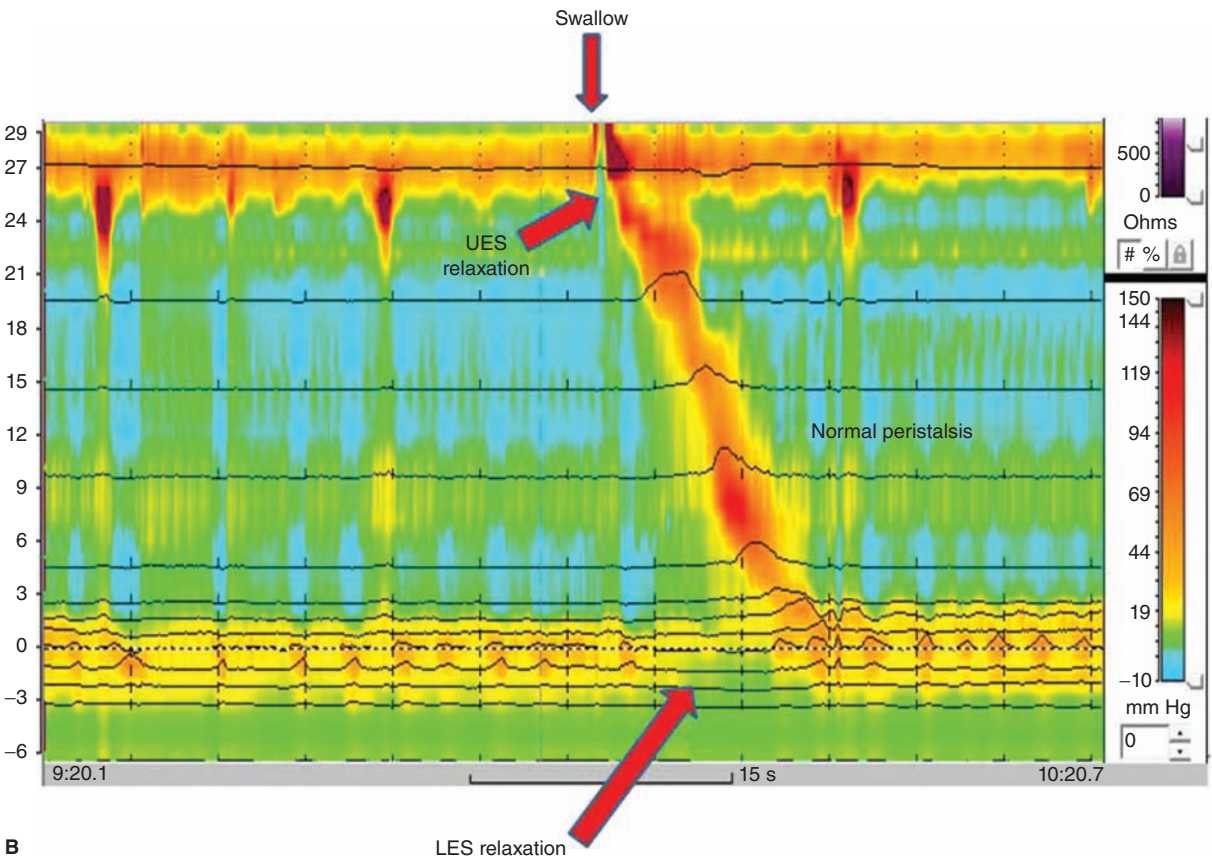
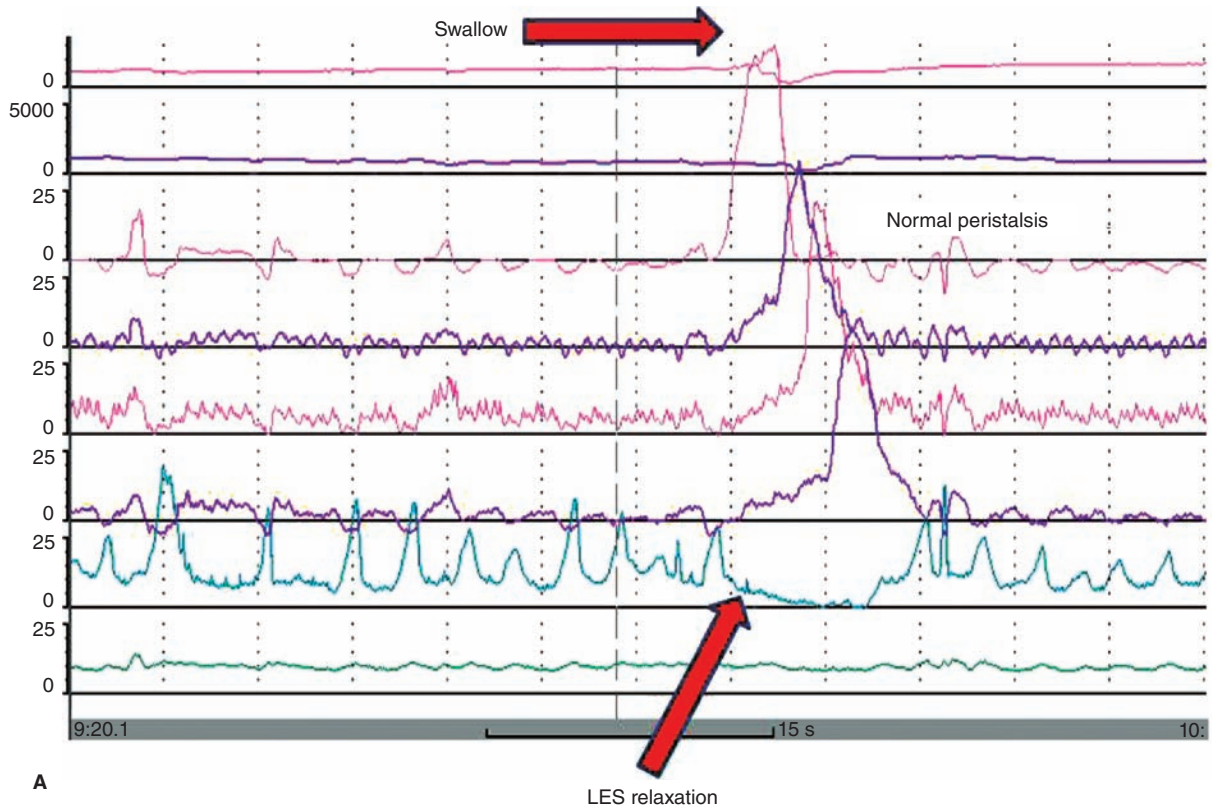
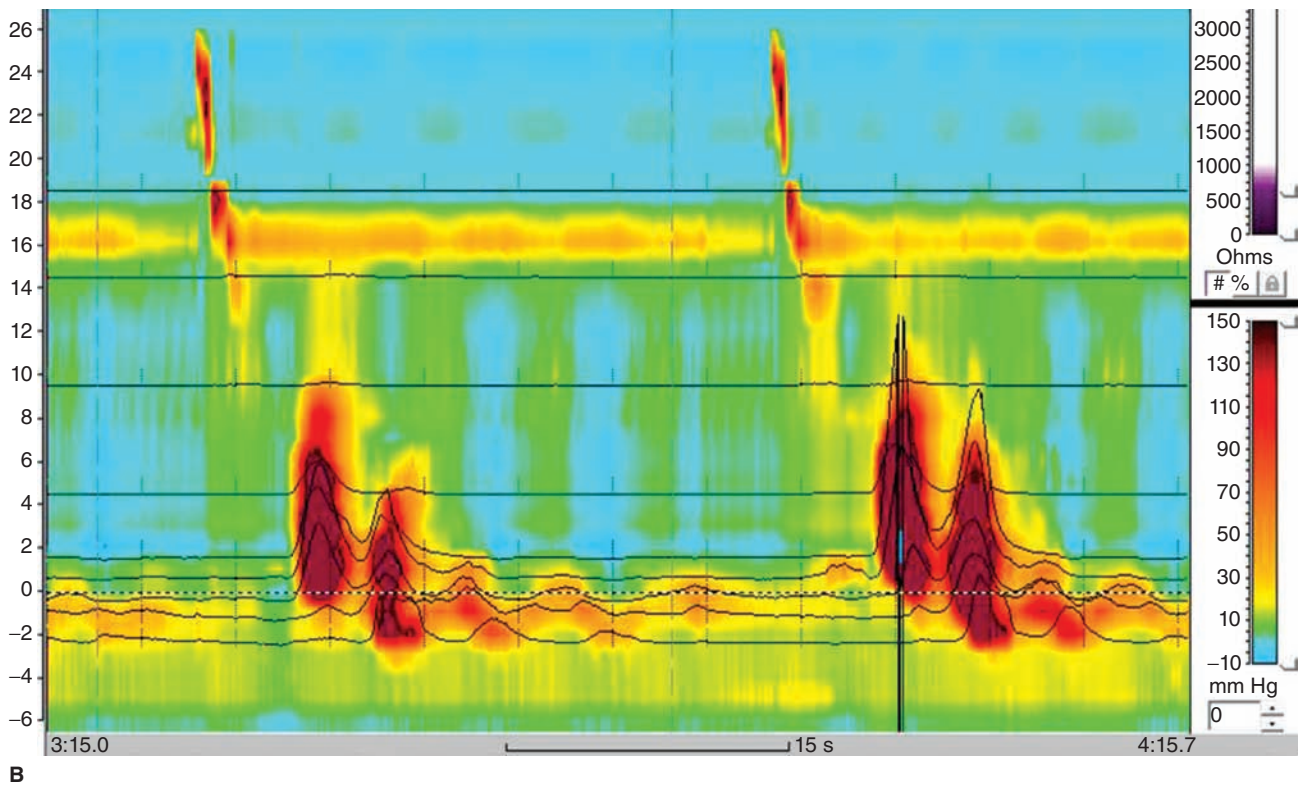
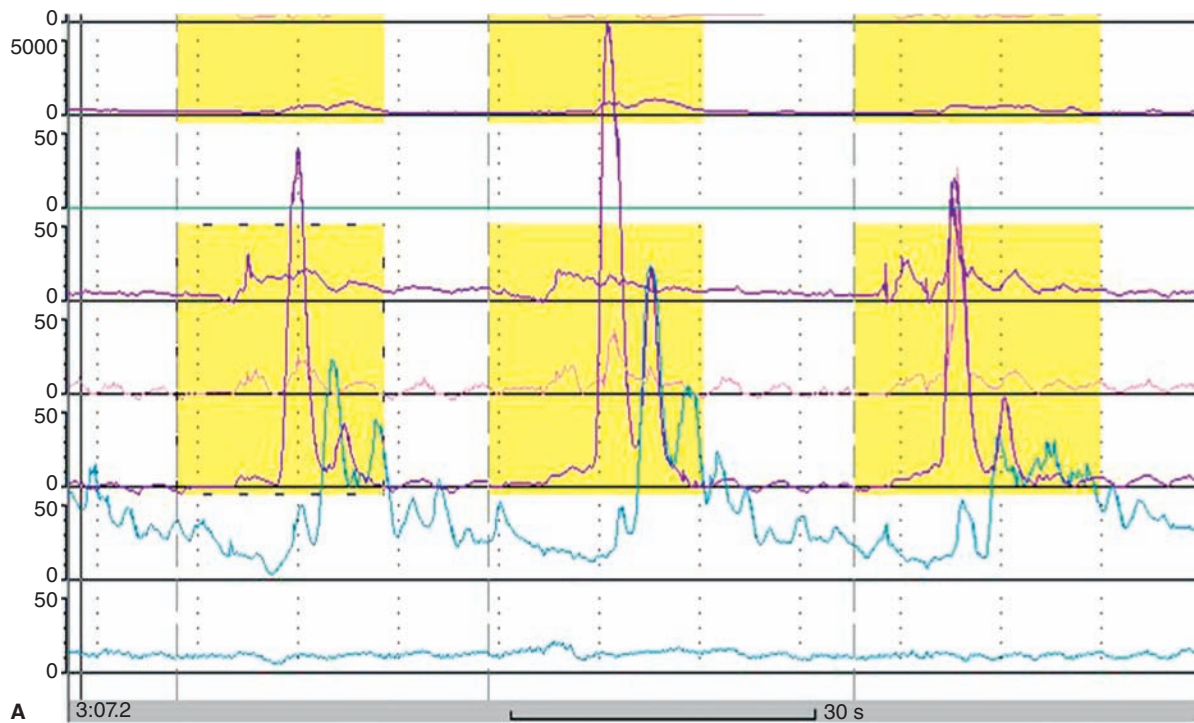
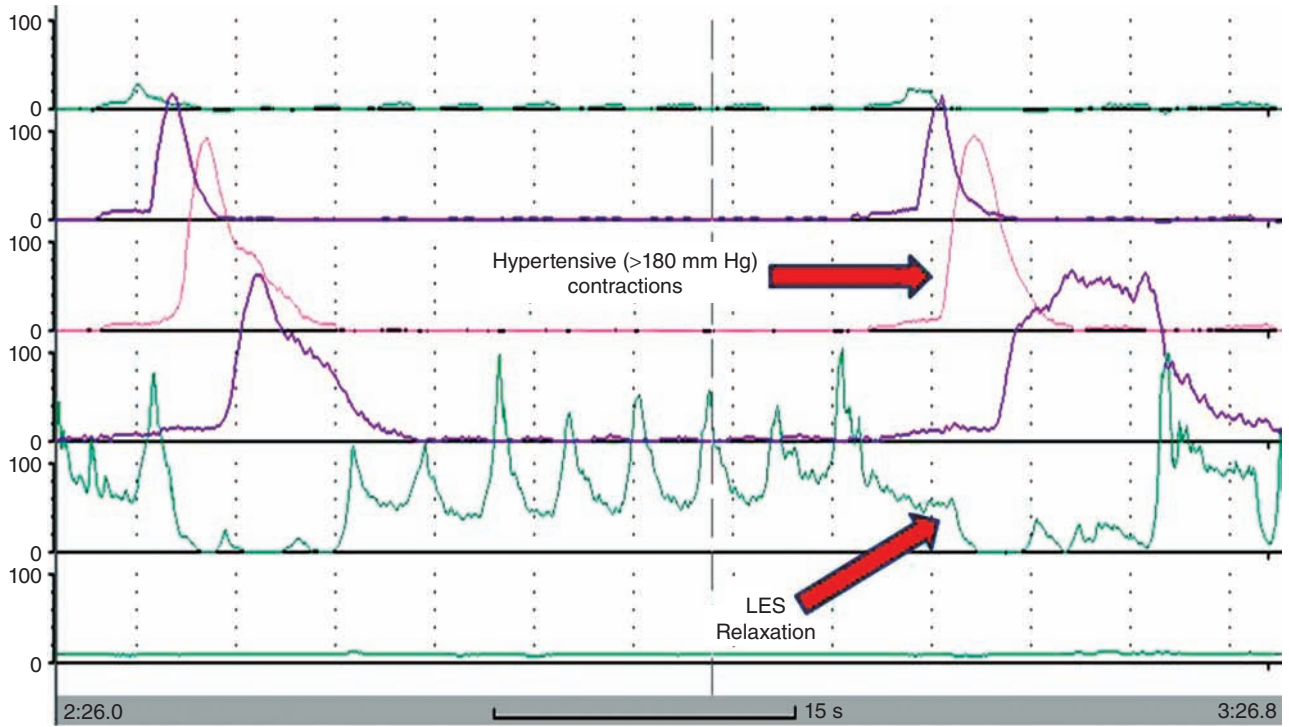


FIGURE 14-10 Normal swallow on manometry (conventional and high-resolution manometry [HRM]). LES, lower esophageal sphincter. (Used with permission from Roger P. Tatum, MD, Director, University of Washington Esophageal Motility Laboratory.)

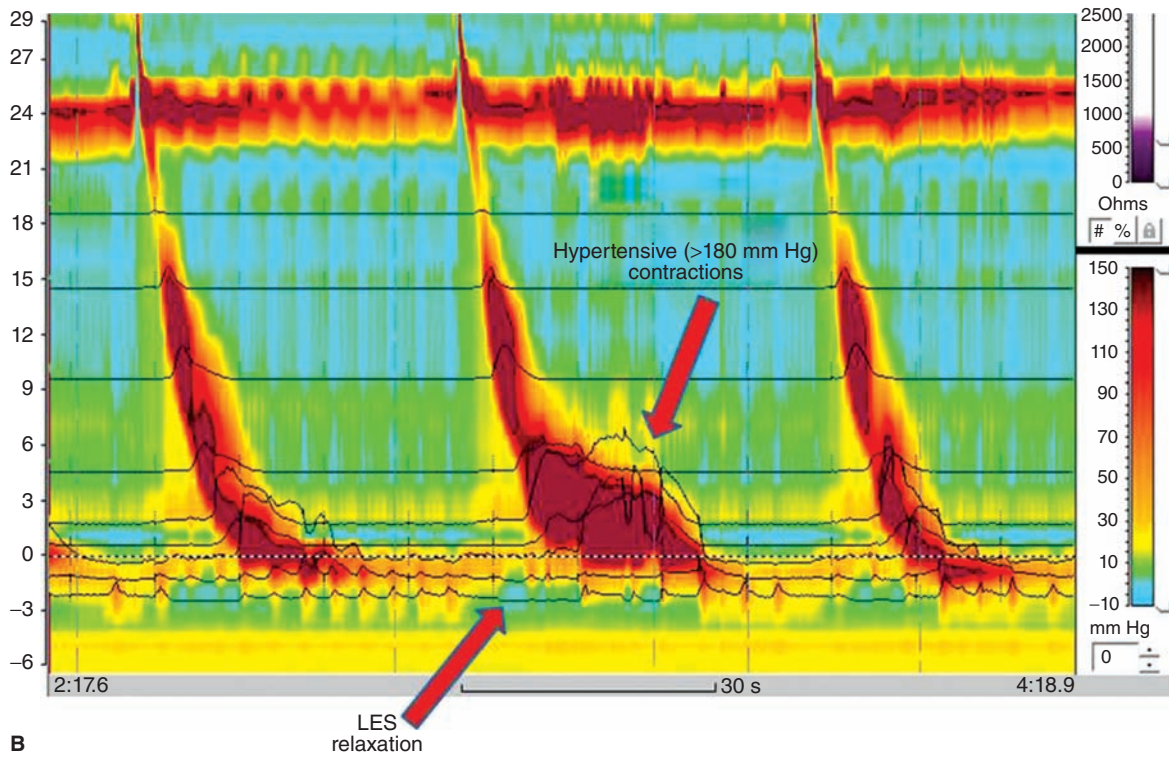


**FIGURE 14-11** Diffuse esophageal spasm (conventional and high-resolution manometry [HRM]). LES, lower esophageal sphincter; UES, upper esophageal sphincter. (Used with permission from Roger P. Tatum, MD, Director, University of Washington Esophageal Motility Laboratory.)





A



B

FIGURE 14-12 Nutcracker esophagus (conventional and high-resolution manometry [HRM]). LES, lower esophageal sphincter. (Used with permission from Roger P. Tatum, MD, Director, University of Washington Esophageal Motility Laboratory.)





up affected patients before embarking on therapy cannot be overemphasized.

## Summary

Spastic PEMDs (NE, HLES, DES) represent a diagnostic and therapeutic challenge to the clinician. Careful attention to presenting symptoms and thorough workup of esophageal function are of utmost importance for both diagnosis and discussion with patients regarding treatment options. Overlap with these disorders and GERD is frequent, and GERD can significantly contribute to and exacerbate presenting symptoms. Medical and surgical therapies have been tried in the past, most of which share the goal of relieving functional obstruction at the GEJ to allow for improved esophageal clearance. In most cases, a less invasive therapeutic approach with smooth muscle relaxing agents is a prudent first line of therapy. Surgery may be offered to carefully selected patients in whom an operation can address a discrete etiology such as abnormal GERD or isolated LES dysfunction.

## Achalasia

Idiopathic achalasia is a primary motor disorder affecting the esophagus. Achalasia, which is typified by complete aperistalsis of the esophagus, is the most frequently encountered motility disorder seen by surgeons. It is a rare condition, with an incidence of 1–3 per 100,000 population in the Western world.<sup>41</sup> It is, however, of all the previously mentioned motility disorders, the most common PEMD. The histopathologic hallmark of the disease remains near complete or total loss of the myenteric plexus ganglion cells as a result of injury and fibrosis of these cells and myenteric nerves. Recent inquiries into the cause suggest an autoimmune disorder, as evidenced by CD3/CD8 lymphocyte markers seen on immunohistochemical analysis of the inflammatory infiltrate.<sup>42–44</sup> The inciting event or trigger may relate to cytotoxic T-cell activation by latent herpes simplex virus 1 (HSV-1) antigen exposure.<sup>45,46</sup> In addition, nitric oxide (NO) synthesis, a mediator of LES relaxation, is often impaired in the face of preserved cholinergic neuronal function.<sup>47–49</sup> These two insults result in loss of peristalsis and impaired relaxation of the LES, which in turn lead to the pathophysiologic findings of impaired esophageal emptying, aperistalsis, and a nonrelaxing LES.

### PATIENT PRESENTATION

Achalasia can occur in patients of all ages but typically presents in patients in the second to fifth decades of life. It does not show a predilection toward either sex. Typical symptoms include dysphagia, regurgitation of indigested food, and complaints of food “sticking” in the chest. Symptoms

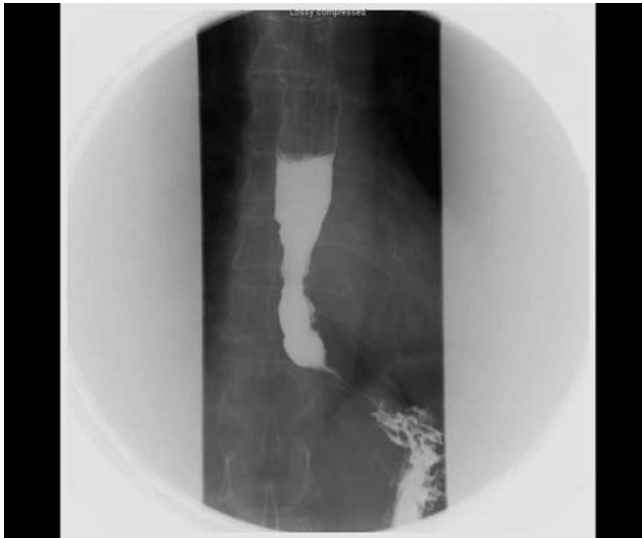
often worsen after lying supine, with regurgitation occurring even the next day of the previous day's meal. Cold liquids frequently exacerbate symptoms, with inability to ingest cold water being a common complaint. Patients may give a history of various maneuvers they employ in attempts to allow passage of food through their nonrelaxing LES. These include raising their arms over their head, swallowing liquids to try to “wash down” food, or remaining upright for extended periods of time. It is only after overcoming the LES pressure with a column of food and liquid that exerts a greater hydrostatic pressure that the patient is able to swallow. Prior to severe progression of their disease, these maneuvers may work for them. As the disease progresses and the esophagus dilates, in effect acting like a stomach reservoir, one finds that regurgitation of the prior day's food contents becomes more common. Symptoms such as these can lead to avoidance of social situations by patients in which they fear regurgitating food in front of others. In addition, frequent regurgitation and aspiration can lead to pulmonary complications. Weight loss can occur with achalasia and tends to correlate with disease severity. However, in older patients (>60 years), recent onset of symptoms (<6 months) and significant weight loss (>10–20 lb) should stimulate concern for neoplastic causes otherwise known as *pseudoachalasia*. In such cases, patients should be worked up with a CT of the chest and abdomen and/or endoscopic ultrasound before therapy.

### EVALUATION

Patients should be worked up in a systematic, methodical fashion. The workup has several components. An upper GI esophagram should first be performed to assess the anatomy. This is a common element used early in the workup of dysphagia and is a good screening tool. Particular attention to the morphology of the esophagus (ie, is a sigmoid esophagus present?) and anatomic location of the LES should be given attention. Classic findings on barium esophagram include distal tapering to the GE junction, resulting in a “bird's beak” appearance. Air fluid levels are often seen (Figs. 14-14 and 14-15). While radiologic reports often will comment on the peristaltic quality of the esophagus, we reserve such categorization for manometry.

Manometry is used to confirm the diagnosis of achalasia. Aperistalsis of the esophageal body and impaired relaxation of the LES are the hallmark findings on manometry, with aperistalsis being a requisite finding. Waveforms are typically low amplitude and simultaneous (Fig. 14-16). Vigorous achalasia, a variant in which high-amplitude waveforms are present can be encountered, and it is usually found in patients with earlier stages of the disease before complete destruction of the myenteric ganglion cells ensues.

Endoscopy is an essential part of the workup for achalasia patients. This offers the chance to directly inspect the mucosa and evaluate the GE junction. Any abnormalities should be biopsied to rule out causes of pseudoachalasia, as well as evaluated with CT and/or endoscopic ultrasound.

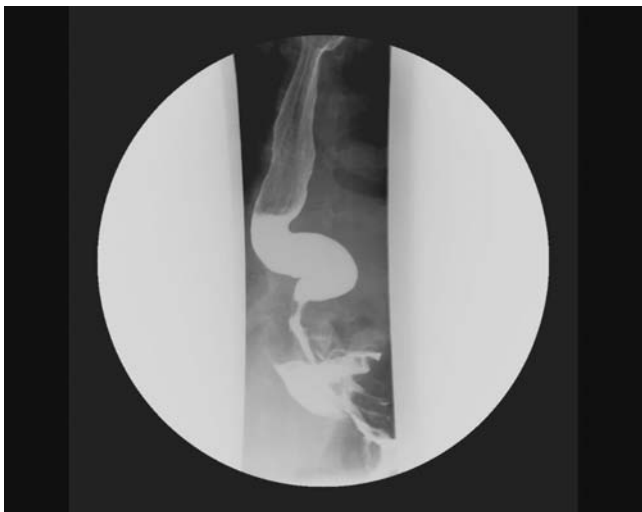

**FIGURE 14-14** UGI demonstrates distal tapering and “bird’s-beak” appearance in achalasia. (Used with permission from Saurabh Khandelwal, MD, University of Washington.)

We do not routinely perform 24-hour ambulatory pH monitoring on these patients, as it does not usually add to the clinical picture. False-positive results can occur as a result of fermentation of food within the esophagus.

## TREATMENT

Therapy for achalasia is palliative in nature and may involve pharmacologic, endoscopic, and surgical therapies. It must be emphasized to the patient that therapies do not cure or address the pathophysiologic abnormality, but instead they are designed to relieve symptoms of obstruction and impaired



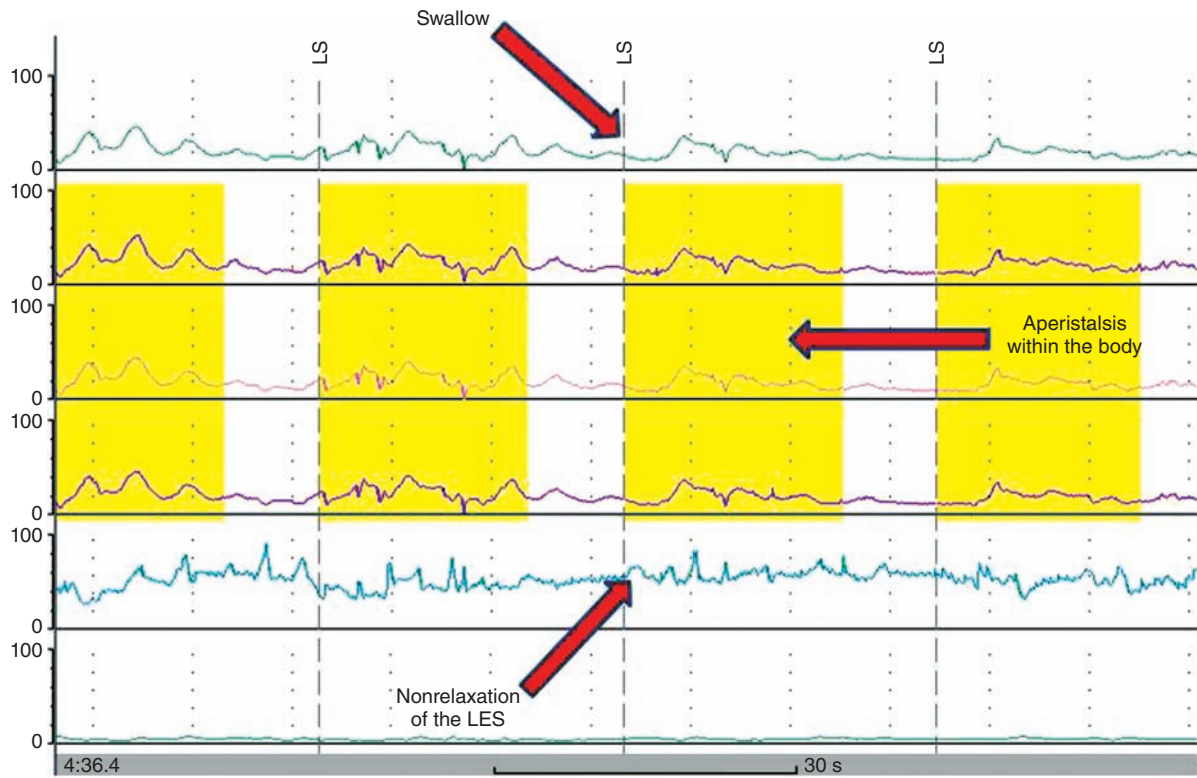
**FIGURE 14-15** Sigmoid esophagus seen with long-standing achalasia. (Used with permission from Saurabh Khandelwal, MD, University of Washington.)

esophageal emptying by relaxing or disrupting the muscle fibers of the LES.

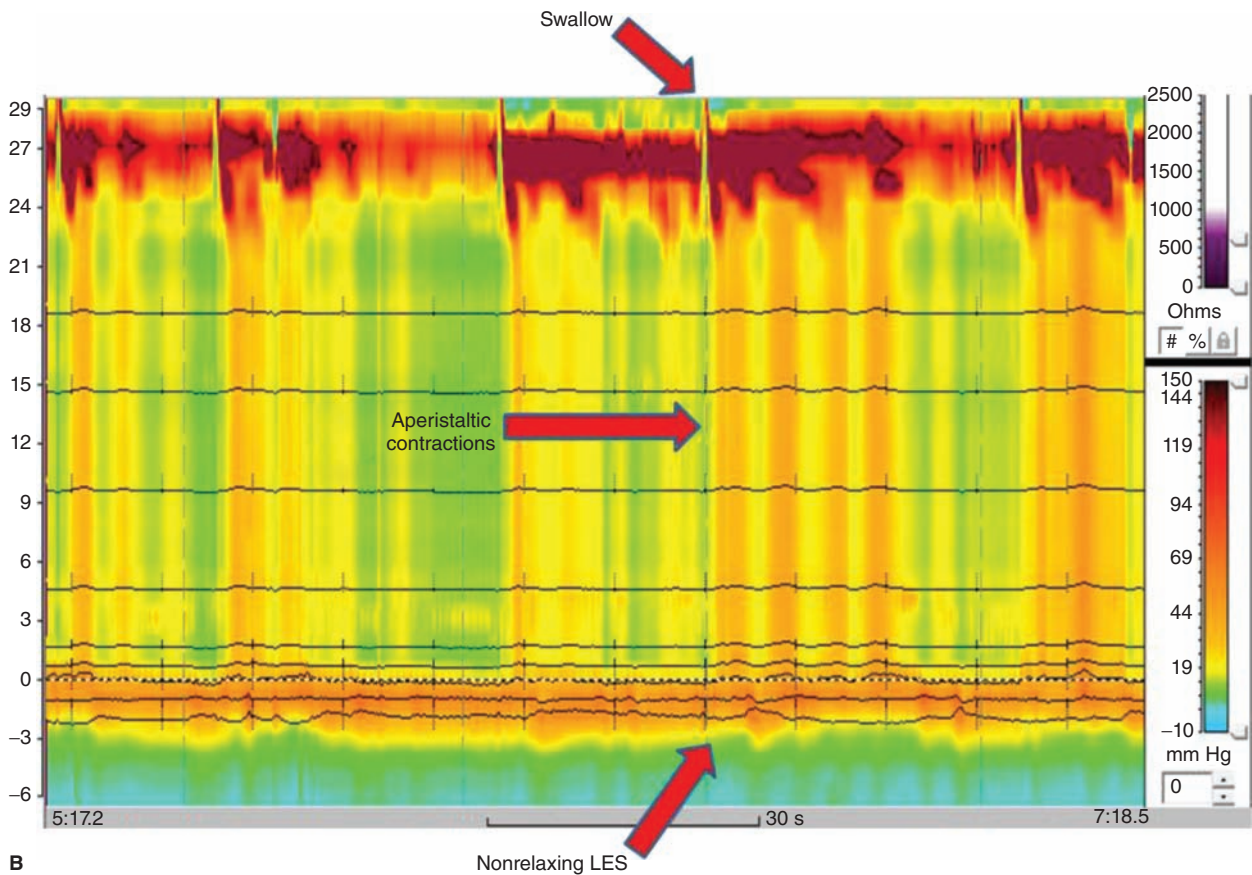
Medical therapy has focused on drugs that relax smooth muscle and decrease LES pressure. Nitrates and calcium channel blockers are used. Because of their limited effectiveness and inconsistent absorption, their use is limited. Impaired esophageal emptying can affect their ingestion and absorption. In randomized controlled trials, calcium channel blockers have not shown significant success in improving clinical symptoms, despite lowering LES pressures.<sup>50,51</sup> Sildenafil, a phosphodiesterase inhibitor, has been shown to have potent relaxing effects on the LES,<sup>52</sup> but its clinical use is limited by poor tolerance and side effects. Nitrates, which can be used in sublingual formulation to overcome poor absorption, tend to work better than calcium channel blockers for symptom relief.<sup>53</sup> Their use, however, can lead to undesired side effects such as hypotension and headache and, like all medical therapies, their efficacy decreases with time. Pharmacologic therapy should be pursued only in patients who, for medical reasons, are unable to undergo other therapies.

Endoscopic therapies include balloon dilation and botulinum toxin injection. Botulinum toxin injection works by inhibiting acetylcholine release at cholinergic nerve endings, thereby decreasing LES pressure. A recent meta-analysis of therapies for achalasia, by Campos et al, reviewed 315 patients in 9 studies who underwent botulinum toxin injection and found initial symptom relief of 78.7% at 1 month postprocedure. This steadily declined over time to 40.6% at 12 months, with 46.6% of patients requiring repeat injection.<sup>54</sup> While botulinum toxin injection therapy may offer temporary relief of symptoms, its effects are not durable as with surgery and repeat treatments are often needed. Moreover, when compared with myotomy, the results for botulinum toxin seem inferior. Zaninotto et al, in a randomized trial comparing botulinum toxin injection with laparoscopic Heller myotomy with fundoplication, observed at 1 year 60% remained asymptomatic in the botulinum injection arm compared with 87% of patients in the surgical arm being symptom free. At 2 years, only 34% of patients in the botulinum injection arm remained without symptoms, while 87% in the surgical arm remained symptom free.<sup>55</sup> Multiple injections can further complicate future surgical therapy due to the submucosal fibrosis that can result, making myotomy more difficult and increasing the risk of perforation.<sup>56</sup> Endoscopic botulinum toxin injection may offer an alternative to those unwilling or unable to undergo more invasive procedures but has a limited role in the treatment of the disease.

Endoscopic balloon dilation, which creates a controlled tear in the LES muscle, is another endoscopic therapy that has been used to treat achalasia and is probably the main alternative to surgery. Different types of dilations have been used in the past, including fixed diameter dilators, mercury-weighted balloons, and water-filled balloons. The most controlled and consistent results are seen with the use of noncompliant pneumatic balloon dilators, such as the Rigiflex balloon dilator (Boston Scientific, Boston, MA).<sup>57</sup> Campos et al, in their meta-analysis, evaluated 15 studies involving 1065 patients



A



B

FIGURE 14-16 Achalasia as demonstrated by conventional and high-resolution manometry (HRM). LES, lower esophageal sphincter. (Used with permission from Roger P. Tatum, MD, Director, University of Washington Esophageal Motility Laboratory.)



using new generation pneumatic dilators, and observed symptom relief rates of 84.8% at 1 month postprocedure, 73.8% at 6 months, and 68.2% at 12 months. After 36 months, the symptoms relief rate declined to 58.4%. One quarter of all patients required repeat endoscopic balloon dilation therapy.<sup>54</sup> Balloon dilation has more long-term efficacy than botulinum toxin injection but still shows significant rates of symptom recurrence and the need for repeat therapy. It does carry more risk than botulinum toxin injection due to the risk of perforation, which is nearly 2% with pneumatic dilation methods.<sup>54</sup> This risk increases with the presence of significant esophageal dilation, hiatal hernia, and epiphrenic diverticula (ED). These should be considered relative contraindications to pneumatic dilation. Between the endoscopic therapies mentioned, pneumatic balloon dilation is a more efficacious procedure but has greater risk of perforation compared to botulinum toxin injection.

Surgical myotomy was first described by Ernst Heller in 1913.<sup>58</sup> His original description involved performing both an anterior and posterior myotomy. This has evolved in most centers to performing an anterior myotomy only. Esophageal myotomy for achalasia is associated with good long-term results and relief from dysphagia. Long-term follow-up studies have demonstrated symptom relief in nearly 75% of patients at 20 years out. Shorter-term follow-up studies demonstrate that nearly 90% of patients are symptom free approximately 3 years postprocedure.<sup>41,54,59</sup> Prior hesitancy for referring patients for Heller myotomy was partially due to the invasive nature of the procedure, which in the past was performed via laparotomy or thoracotomy, as well as a long hospital stay and long recovery. These approaches eventually evolved to the minimally invasive approaches via thoracoscopy or laparoscopy. Shimi et al reported the first laparoscopic Heller myotomy in 1991, while Pellegrini et al reported the first thoracoscopic approach in 1992.<sup>60,61</sup> Drawbacks to this thoracoscopic approach included the need for single-lung ventilation, postoperative chest tubes, and being unable to perform an antireflux procedure. The minimally invasive approach has moved predominantly to the laparoscopic myotomy approach that has eliminated these drawbacks of the thoracoscopic approach. Laparoscopy offers excellent visualization of the hiatus and the mediastinal structures, does not require single-lung ventilation or postoperative chest tube drainage, and makes creation of an antireflux technically straightforward. In addition, the laparoscopic performance of myotomy, when compared with the thoracoscopic technique, has shown better symptomatic improvement (89.3 vs 77.6%) and a lower incidence of reflux symptoms when combined with a partial fundoplication (14.9 vs 28.3%).<sup>54</sup>

The two main debates surrounding surgical myotomy have centered on whether or not to include an antireflux procedure (and if so which one) and what the optimal length and extent of myotomy are that should be performed. GER symptoms and esophagitis represent common causes of treatment failure after myotomy if a fundoplication is not added. Addition of an antireflux procedure to a standard Heller myotomy has been thought to reduce these symptoms and improve outcomes.

This issue has been studied in a prospective, randomized trial by Richards et al, comparing Heller myotomy with Heller myotomy plus Dor (anterior) fundoplication. They demonstrated that the pathologic occurrence of GER, as defined by distal esophageal acid exposure of greater than 4.2% on 24-hour pH monitoring at 6 months postoperatively, was reduced from 47.6 to 9.1% with creation of a Dor fundoplication.<sup>62</sup> Some surgeons have advocated in the past for inclusion of a floppy Nissen fundoplication, rather than partial fundoplication, to prevent GER. Concern for postoperative dysphagia due to poor esophageal clearance and weak or absent propulsive force is clearly warranted in this instance. Rebecchi et al recently published the results of their study in which patients were randomized to Heller myotomy plus Dor fundoplication or Heller myotomy plus floppy-Nissen fundoplication. At 60 months of follow-up, no statistically significant difference in GER symptoms between the two groups were seen; the rate of dysphagia, however, was found to be significantly higher in the floppy-Nissen fundoplication group when compared to the Dor fundoplication group (15 vs 2.8%). They concluded that both antireflux procedures offered adequate protection from GER, but that recurrence of dysphagia was significantly higher when Nissen fundoplication was performed.<sup>63</sup> Toupet and Dor fundoplications with EM are being compared in a randomized, multicenter trial at this time, and the hope is that the data will help answer which is a superior antireflux procedure. Until the data can conclusively demonstrate superiority of one technique over the other, surgeon's preference and experience should guide which one is performed in conjunction with myotomy.

The length and extent of myotomy is another area of debate. Most surgeons agree that the proximal extent of the myotomy should extend 6–7 cm above the GE junction. This is carried out in a safe manner with appropriate dissection of the anterior esophagus. Distally, a standard myotomy has typically been performed and carried 0.5–1.5 cm below the GE junction. This length was chosen with the intent of being long enough to relieve the functional obstruction to the esophagus, while in an effort to preserve an antireflux barrier.<sup>64</sup> The result proved to fall short on both counts, with dysphagia and/or GERD being fairly common. In 1998, based on observations that reoperations for thoracoscopically performed myotomies that extended the myotomy onto the stomach resulted in improvement of dysphagia, we changed our practice to carry out the myotomy a full 3 cm below the GE junction (an extended myotomy) completely obliterating the LES fibers. We compared our extended myotomy/Toupet patients with standard myotomy/Dor patients and observed that patients who underwent extended myotomy had lower LES pressures (9.5 vs 15.8 mm Hg), less frequent and less severe dysphagia, and lower rates of recurrent severe dysphagia requiring interventions (3 vs 17%).<sup>65</sup> We continued to follow and then compared a cohort of 52 of these patients at a median follow-up of 46 months. No significant differences in heartburn frequency, esophageal acid exposure, or LES pressure were observed. However, dysphagia severity was reduced, and relief was improved in the EM and Toupet fundoplication group. Only 5% of patients who underwent EM/Toupet required reintervention (dilation)



versus 18% of SM/Dor patients (10% required endoscopic treatment, 8% required reoperation).<sup>66</sup> We feel that the Toupet is a better antireflux operation in combination with extended myotomy. Reasons for its superior efficacy may stem from its more physiologic angulation of the GE junction with its construction and its ability to stent open the myotomy and prevent reapproximation of muscle fibers and symptom recurrence. Our study compared two different operations (SM and Dor vs EM and Toupet), and we cannot answer which wrap is superior. At this time, we recommend performing either anterior or posterior fundoplication with extended myotomy. We continue to routinely perform extended myotomy and have seen excellent results and low rates of dysphagia. Rarely do we need to consider dilation, and we have essentially eliminated the need for reoperation with this approach. Because of this more complete obliteration of the LES, this should be used in conjunction with an antireflux procedure. We feel that extended myotomy of 3 cm below the GE junction should be a routine practice when performing a Heller myotomy.

## OPERATIVE TECHNIQUE

**Laparoscopic Heller Myotomy.** The setup is the same as previously described in this chapter for PEH repair, utilizing our standard esophageal operating position regarding patient positioning and trocar placement. We use a 10-mm, 30-degree laparoscope to ensure the best possible image for performing the myotomy. This is especially important during the creation of a myotomy. In contrast, we use 5-mm, 30-degree laparoscopes for PEH repairs and first-time Nissen funduplications. Patients are instructed to remain on a liquid diet for 2 days prior to surgery to minimize the amount of retained food within the esophagus and decrease the risk of aspiration at the time of surgery.

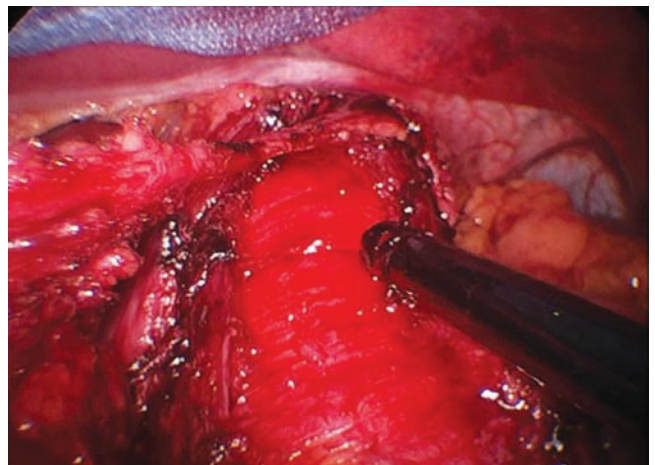
We begin by dividing the phrenogastric ligament sharply and then divide the short gastric vessels with ultrasonic shears. A left crus approach is employed as previously described, and left, right, and anterior mediastinal dissection of the esophagus is performed. It is not necessary to significantly dissect the posterior attachments of the esophagus, except to provide enough intra-abdominal esophagus to perform a good fundoplication. The main goal is to gain as much length as possible anteriorly to later perform the myotomy. It is important to identify and preserve the anterior (left) vagus nerve. This nerve and GEJ fat pad are carefully dissected away from the esophageal body and preserved so that a continuous myotomy can be performed, starting below on the stomach and extending above the vagus as it crosses from left to right on the anterior aspect of the GEJ. The anterior GEJ fat pad to the left of the anterior vagus nerve is resected. This allows for accurate identification of the GEJ at the time of myotomy.

At this time, a 50F lighted bougie is passed into the body of the stomach. The transillumination provided aids in identification of the submucosal plane. A laparoscopic Babcock clamp, first applied partially opened over the bougie, is used to gently drag the tissue over and around the bougie to

provide tension and exposure. The myotomy is started on the anterior stomach 3 cm below the GEJ. We prefer an L-shaped hook to perform the myotomy, but other devices can be used as well. We employ gentle use of cautery to start the myotomy and then use the L-shaped hook to gently tease the muscle fibers apart, exposing the submucosa. Entering the correct plane takes patience and careful dissection. The submucosa of the stomach contains a rich plexus of vessels that can be used as a visual identifier. Once the appropriate plane is identified, the myotomy is carried cephalad. Only minimal electrocautery is used during performance of the myotomy (Fig. 14-17).

The correct plane may be difficult to identify on the stomach, as the sling fibers of the cardia cross in variable directions and the mucosa tends to be thin. Once the GEJ is reached, the plane becomes easier to identify due to the organized outer, longitudinal, and inner circular muscle fibers of the esophagus. We first divide the outer longitudinal muscle fibers and then the inner circular layer. The myotomy is carefully extended and taken above the level of the anterior vagus nerve as it crosses from left to right over the esophagus. The extent of the myotomy is to take it as proximally as is safe. Typically, one can get 6–8 cm above the GE junction. The assistant repositions the Babcock clamp as needed to continually provide exposure and tension on the tissues over the bougie. As the myotomy is carried cephalad, the assistant can switch over to using an atraumatic grasper to hold the left side of the divided muscle fibers on tension, with the surgeon's left hand holding the right-sided fibers. In this fashion, the myotomy is completed.

Bleeding from submucosal vessels that are mistaken for muscle fibers occasionally occurs but is self-limited; gentle pressure is usually adequate to control and stop it. One must be very cautious in applying electrocautery as an unrecognized injury may result leading to delayed perforation, and thus should be avoided. If mucosal perforation occurs during the dissection, it is usually evident as saliva or gastric secretions or the light from the bougie will be seen

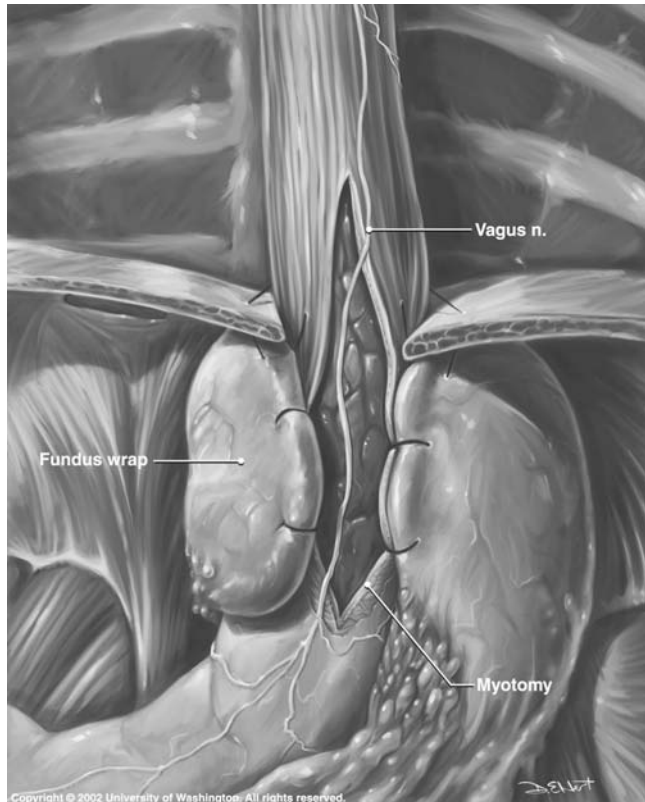


**FIGURE 14-17** Myotomy performed over 52F lighted bougie. (Used with permission from Saurabh Khandelwal, MD, University of Washington.)

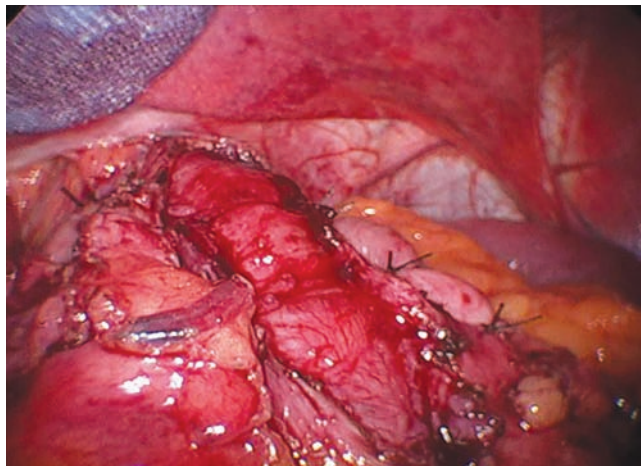
coming forth. Intraoperative endoscopy can be used to confirm injury as well as evaluate it after it has been repaired. Mucosal injuries should be repaired immediately with 4-0 absorbable suture, and consideration given to performing an anterior, buttressing fundoplication.

Intraoperative endoscopy is carefully performed to evaluate for the completeness of myotomy and to evaluate for injury. If all muscle fibers have been correctly divided, an open GE junction will clearly be visible on endoscopy, without indentations from undivided fibers. In addition, with gentle insufflation, injury to the mucosa can be seen both endoscopically and laparoscopically.

A Toupet (posterior) fundoplication is performed for the antireflux procedure as the final part of the operation. A suture is placed on the posterior portion of the fundus, 3 cm below the GE junction and 2 cm away from the line of the divided short gastric vessels. This is used as a reference point to ensure a symmetric posterior wrap. The fundus is brought posteriorly behind the GE junction, and the reference suture is grasped and brought up to the edge of the myotomy. The fundus is sutured to the right crus to alleviate tension, using 2-0 silk suture. The edge of the wrap is then sutured to the myotomized edge with three sutures. In similar fashion, the left component of the wrap is sutured to the edge of the myotomy and the left crus (Figs. 14-18 and 14-19).



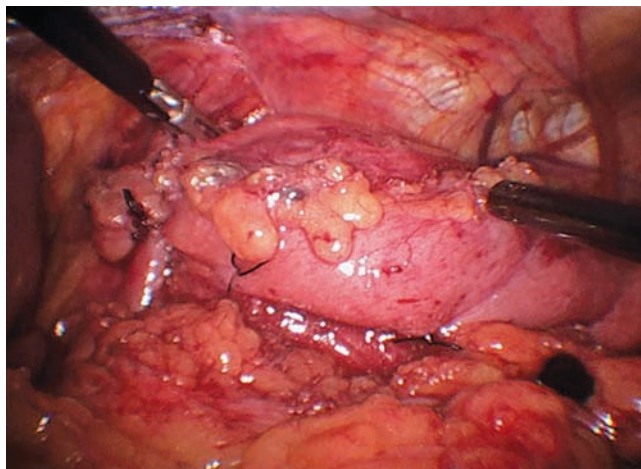
**FIGURE 14-18** Diagram of completed Heller myotomy with Toupet fundoplication. (Woltman TA, Pellegrini CA, Oelschlagel BK. Achalasia. *Surg Clin North Am.* 2005;85(3):483-493.)



**FIGURE 14-19** Intraoperative picture of completed Heller myotomy with Toupet fundoplication. (Used with permission from Saurabh Khandelwal, MD, University of Washington.)

After completing the wrap, the ports and liver retractor are removed and the port sites are closed, concluding the case.

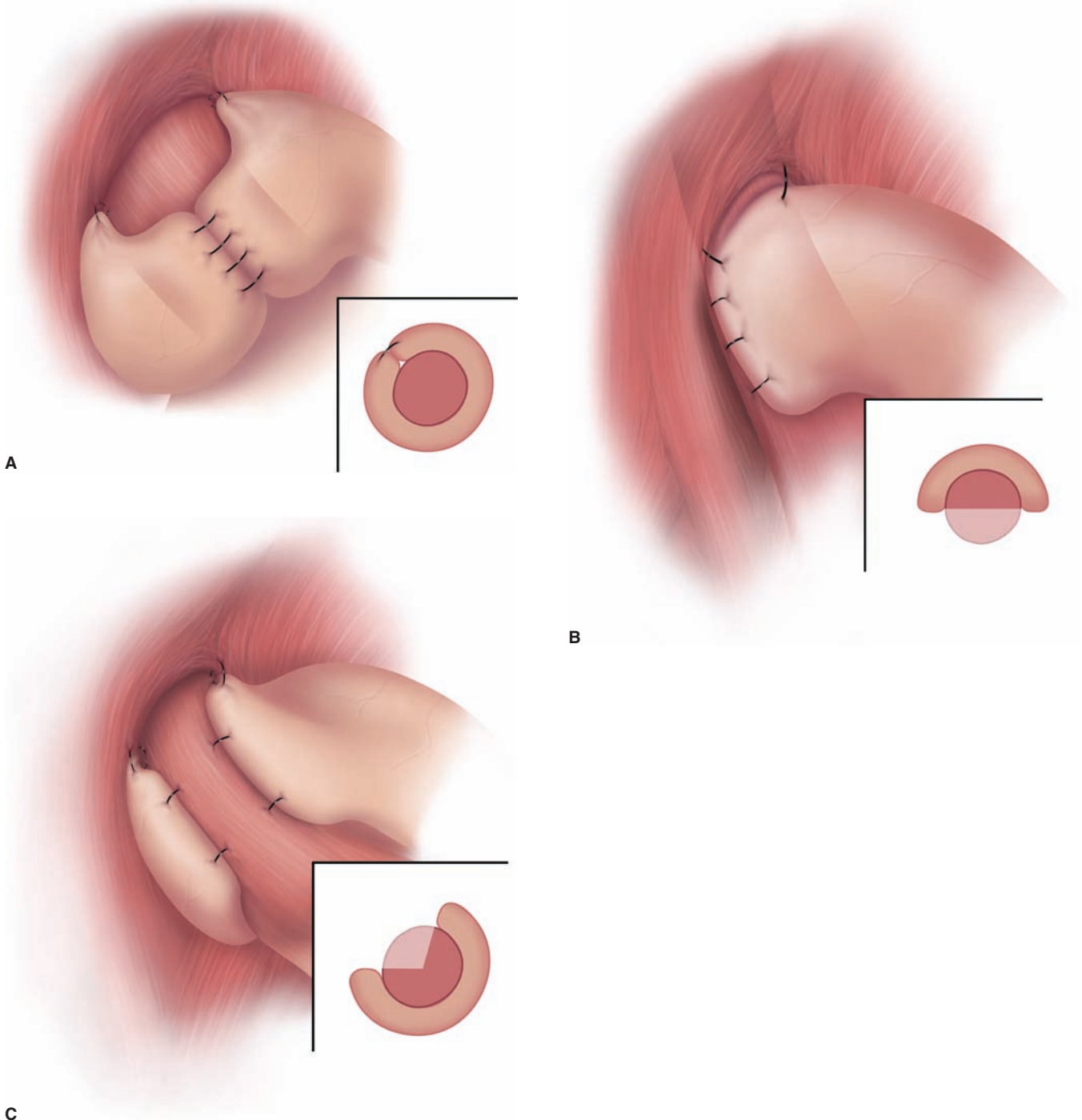
A Dor fundoplication is an acceptable antireflux procedure and is technically easier to perform than the Toupet, as it requires less dissection, especially of the posterior stomach (Fig. 14-20). The Toupet does a better job of stenting open the divided muscle fibers and with this mechanism may lead to lower rates of recurrence and dysphagia. For this reason, we prefer this posterior fundoplication. Figure 14-21 depicts the construction and geometry of full and partial fundoplications. In patients with a very tortuous or sigmoid shaped esophagus, we omit the antireflux portion of the procedure because of the high incidence of postoperative dysphagia we have observed when performing fundoplication in these patients.



**FIGURE 14-20** Completed anterior (Dor) fundoplication. (Used with permission from Saurabh Khandelwal, MD, University of Washington.)

Postoperatively, patients are started on a clear liquid diet and advanced slowly. We do not use nasogastric tubes. Nausea is controlled aggressively to prevent retching or emesis. Patients are typically discharged home on postoperative day 1. On routine follow-up, we assess for symptoms of reflux and dysphagia. At 4–6 months postoperatively, we request

patients to repeat manometry and obtain 24-hour pH testing to evaluate acid exposure. If abnormal acid exposure is present or the patient has symptoms of GER, a proton pump inhibitor (PPI) is started to ameliorate symptoms and to reduce the risk of peptic stricture formation.



**FIGURE 14-21** Different fundoplication wraps. **A.** Complete; **B.** anterior (Dor); **C.** posterior (Toupet). (Oelschlager B, Eubanks T, Pellegrini C. *Sabiston Textbook of Surgery*, 18th ed, Chapter 42.)



## Summary

Motility disorders of the esophagus share the hallmark symptom of dysphagia. Careful history taking, in conjunction with physiologic testing with pH and manometry, and appropriate imaging lead to the diagnosis. With the exception of achalasia, many of these disorders can be managed medically, especially after careful evaluation and control of GER. Achalasia is a disease best treated surgically with laparoscopically performed extended myotomy and partial fundoplication. Though endoscopic therapies exist, they have inferior outcomes and durability, and should be reserved for patients unwilling or unable to undergo surgery. Minimally invasive techniques have shown great promise in treating achalasia both in terms of patient recovery and long-term outcomes.

## ESOPHAGEAL DIVERTICULA

Diverticula of the esophagus are relatively uncommon. They are classified based upon their location: proximal or pharyngoesophageal, midesophageal, and distal or epiphrenic, with the latter being located within 10 cm of the GE junction. Midesophageal diverticula, which are usually traction diverticula and thus are true diverticula, are rare and usually do not require surgical treatment. They result from an extrinsic “pulling” inflammatory process and in the past were often associated with tubercular or granulomatous disease. Proximal and distal diverticula are more common and are false, or pulsion-type diverticula, as they are not composed of all layers of the esophageal wall but rather are outpouchings of mucosa. This chapter focuses on these types, specifically Zenker’s diverticulum (ZD) and epiphrenic diverticulum (ED), and their management.

### Zenker’s Diverticulum

Originally described by Ludlow in 1769,<sup>67</sup> this proximal esophageal diverticula was named by German pathologist Friedrich Albert Von Zenker, who, more than 100 years later in 1877, described their etiology as being that resulting from increased pharyngeal pressure leading to formation.<sup>68</sup> The anatomic location of this lesion is proximal to the upper esophageal sphincter (UES) and in the posterior hypopharynx. The area in the posterior wall of the pharynx between the cricopharyngeus muscle and the inferior constrictor muscles is known as *Killian’s triangle*. The weakest point in this space is the area between the two muscles, and it is here that herniation or outpouching of the mucosa and submucosa occurs, resulting in a Zenker diverticulum (ZD) formation (Fig. 14-22). In addition to a weak posterior wall, inelasticity and higher resting tone from fibrosis of the cricopharyngeus muscle are thought to contribute to the dysfunction of the

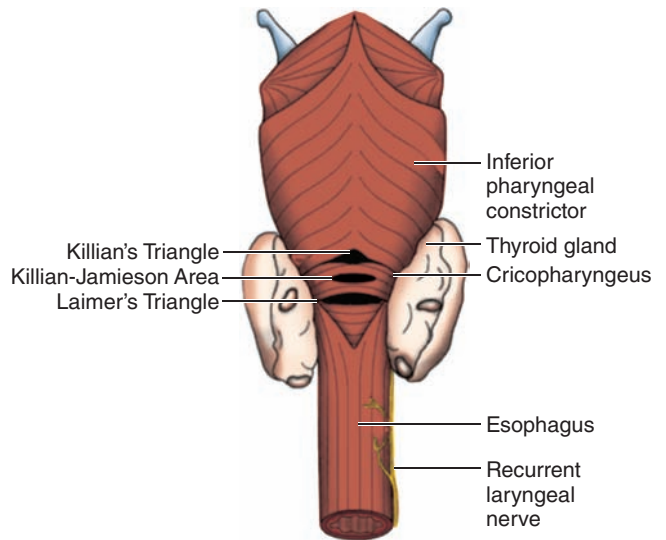


FIGURE 14-22 Schematic drawing of the posterior aspect of the pharyngoesophageal junction with areas of weakness identified.

pharyngoesophageal segment, leading to ZD formation.<sup>69,70</sup> A complete understanding of the causes for ZD formation does not exist, despite decades of research.

ZD usually presents in the seventh to eighth decades of life. It is not uncommon for significant lengths of time to elapse between the start of symptoms and presentation to a surgeon, because the symptoms are often vague, innocuous, with a lot of overlap with other benign conditions. Its incidence is difficult to estimate as the number of patients with ZD who are asymptomatic is unknown. Estimates in the United Kingdom place its incidence at 2 per 100,000 population per year.<sup>71</sup> Common symptoms include dysphagia, globus sensation, halitosis, aspiration, and regurgitation of undigested food. Physical examination findings are largely absent but may infrequently reveal a palpable mass, most often located in the left side of the neck.

Workup for ZD consists of barium swallow to delineate size, as measured in the craniocaudal dimension, and position. Only after this has been done, should endoscopy be attempted as perforation by blind intubation of the false lumen can lead to significant morbidity. Endoscopy largely serves to exclude other diagnoses, including tumors, mucosal abnormalities, synchronous esophageal lesions, malignant neoplasia within the diverticulum, and GERD. Manometry has not shown specific findings associated with ZD, though UES dysfunction may be present.

## TREATMENT

Therapeutic options have evolved over the last century from open diverticulectomy and myotomy or diverticulopexy toward peroral endoscopic methods, including mucomyotomy with staplers, CO<sub>2</sub> laser, argon plasma coagulation (APC), and needle-knife. No randomized trials have been conducted comparing the methods. Most methods have



comparable symptomatic improvement ranging near or above 90% and with low morbidity and mortality. Choice of therapy is often a matter of patient and physician choice. Trends in therapy, following the European experience, seem to be shifting toward endoscopic management due to its low morbidity and mortality, avoidance of an open surgical procedure, and good outcomes.<sup>69,72</sup> Despite trends toward endoscopic therapy, there are patients for whom the standard open surgical approach should be used, including those with narrow mandibles or small oral cavities, those in which the diverticulum cannot accommodate the scope, and instances in which the diverticulum is not posterior, for example Killian-Jamieson diverticula.<sup>73</sup> The instances in which open surgical resection should always be sought are with diverticula in which mucosal neoplastic changes are known to exist and those very large diverticula that cannot be approached safely with a perioral technique.

## OPERATIVE TECHNIQUE

**Open Cervical Diverticulectomy.** Patients with ZD are placed on a liquid diet for 2 days prior to surgery, to minimize the risk of retained food and aspiration. The patient is placed supine with the neck fully extended and the head turned to the right, exposing the left neck. The left cervical approach is used as the majority of diverticula occur posteriorly and on the left. In addition, the esophagus is most accessible here as the trachea has a natural slight rightward shift. An oblique cervical incision, overlying the anterior border of the sternocleidomastoid muscle (SCM) is made. The SCM is retracted laterally as is the carotid sheath, while the thyroid gland is retracted medially. Ligation of the middle thyroid vein and omohyoid muscle is necessary to gain medial retraction of the thyroid and exposure of the tracheoesophageal groove and esophagus. The left recurrent laryngeal nerve should be identified and preserved. A left-sided approach is also more desirable from this aspect as the recurrent laryngeal nerve on this side has better exposure and more consistent anatomy compared to the right.

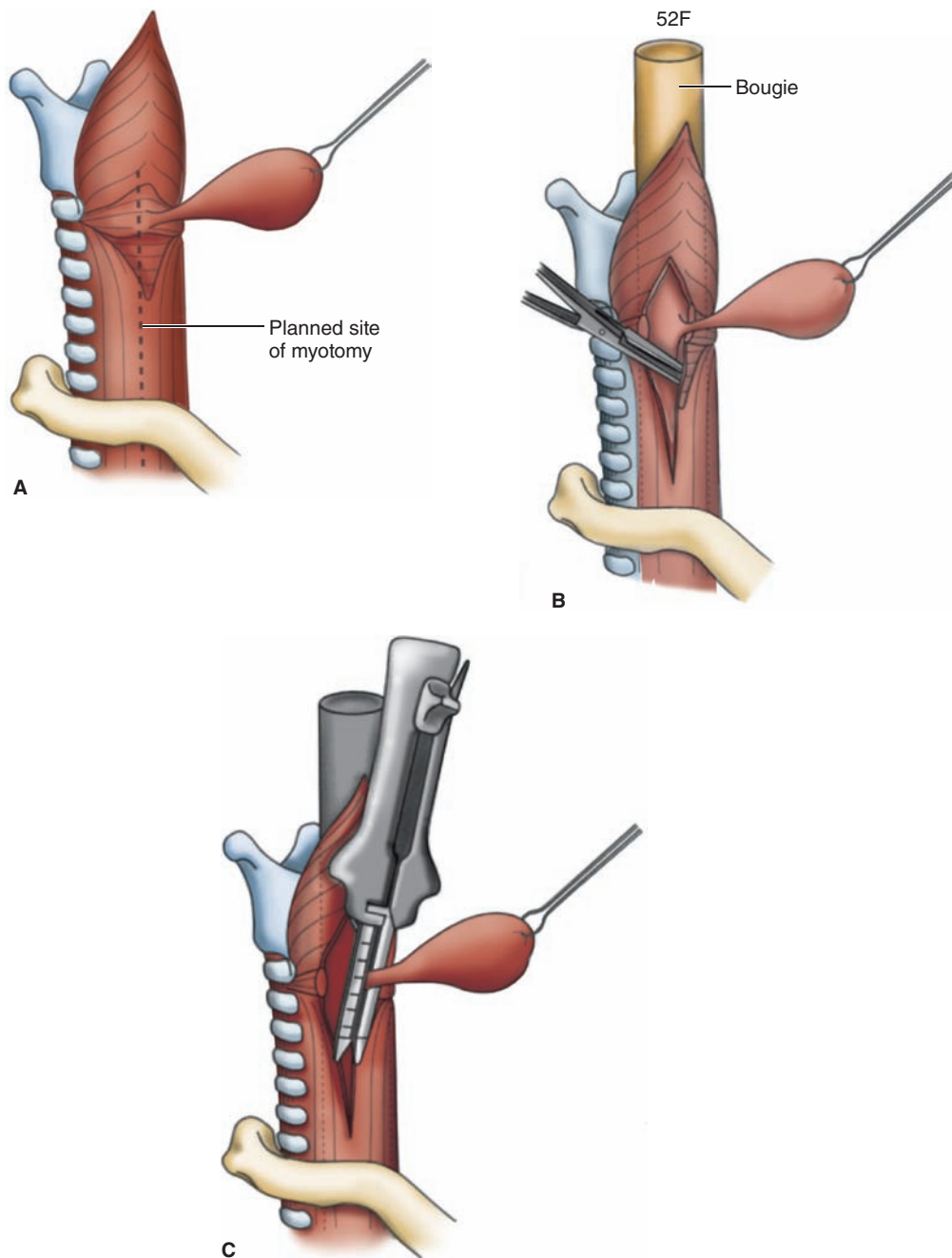
Dissection is carried distally and cephalad. A true ZD will be encountered in the posterior midline at Killian's triangle; it is grasped and its neck is dissected free. Next, a 50F bougie is placed under palpation and direct vision of the surgeon into the distal esophagus. A myotomy is performed, which must include the cricopharyngeus muscle and come down several centimeters onto the esophagus, which can be identified by its outer longitudinal and inner circular muscle fibers. The diverticulum is excised using a reticulating linear stapler (Fig. 14-23A–C). Resection of the diverticulum should be performed with the bougie in place to avoid narrowing of the esophagus. A drain may be placed at the discretion of the surgeon. The platysma is closed and the wound is closed in layers. If the patient is doing well clinically, he or she is started on a liquid diet the next day and can be discharged within 48 hours.

Surgical open diverticulectomy and myotomy are associated with excellent relief from symptoms in up to 82–94% of patients and low recurrence rates of 3.6–7%.<sup>69</sup> Mild to severe complications, including staple-line leak, fistula formation,

stenosis, recurrent laryngeal nerve palsy, mediastinitis, pneumonia, and hemorrhage have an occurrence rate of up to 25%. Mortality associated with the surgical approach ranges between 1.2 and 3.4%.<sup>69,74–78</sup>

**Endoscopic Treatment.** Endoscopic treatment of ZD was first described by Mosher<sup>79</sup> in 1917 and lost favor, because of complications, until revived by Dohlman and Mattsson in 1960.<sup>80</sup> They reintroduced the concept with use of electrocoagulation techniques. Collard et al in 1993 described the endoscopic stapled diverticulectomy (ESD) that is the predominant endoscopic method of treatment today.<sup>81</sup> Endoluminal treatments for ZD are the least invasive methods of treatment and the various forms all share the common principle of performing mucomyotomy by dividing the septum between the diverticulum and the esophageal lumen. CO<sub>2</sub> laser, electrocautery, needle-knife, clips, and staplers have been described and used.<sup>80–83</sup> The stapled diverticulectomy offers the additional advantage over these other methods of wound closure with the staples after division of the septum is completed. This is thought to decrease the risk of bleeding and possible perforation. Both rigid and flexible endoscopy platforms can be used. Rigid endoscopy is usually performed in the operating room by ENT (ear, nose, and throat) surgeons, and it incorporates the use of the stapler and a diverticuloscope, which can intubate both the esophageal lumen and diverticulum simultaneously (Fig. 14-24). Flexible endoscopic techniques employ various methods of cautery, cutting or clipping, or laser to divide the septum. Flexible endoscopy offers some advantages over the rigid method in that it can be done with sedation and analgesia, avoiding a general anesthetic, and can be performed in an outpatient setting with reduced stay and potential cost savings. It is associated with higher recurrence rate when compared to rigid endoscopy and ESD (up to 35% in some series vs up to 15.4% for ESD and rigid endoscopy). Head-to-head randomized trials comparing the differing endoluminal approaches have not been performed.

Endoluminal therapies demonstrate excellent symptom improvement in 80–96% of patients. Mild complications such as subcutaneous emphysema or mild hemorrhage are seen in up to 23% of patients; severe complications occur less frequently when compared to surgical treatment, ranging from 0 to 3.8%.<sup>69,84</sup> The most feared of these are esophageal or pharyngeal perforation. Mortality rates are low (0–0.4%) and no mortalities have been reported with the flexible endoscopic methods. Recurrence rates, however, are significantly higher than with surgical therapy and range between 3.3 and 35%.<sup>69</sup> Between the methods, the flexible platform has the highest recurrence rates; this can often be addressed with repeat therapy. While this is a drawback, the overall safety and lower-risk profile of endoluminal therapies may be a desirable factor when treating elderly patients, in which ZD most commonly presents. All patients are not candidates for endoluminal treatment of ZD, such as those with small oral cavities, large osteophytes, and small diverticula (<3 cm).<sup>73</sup>



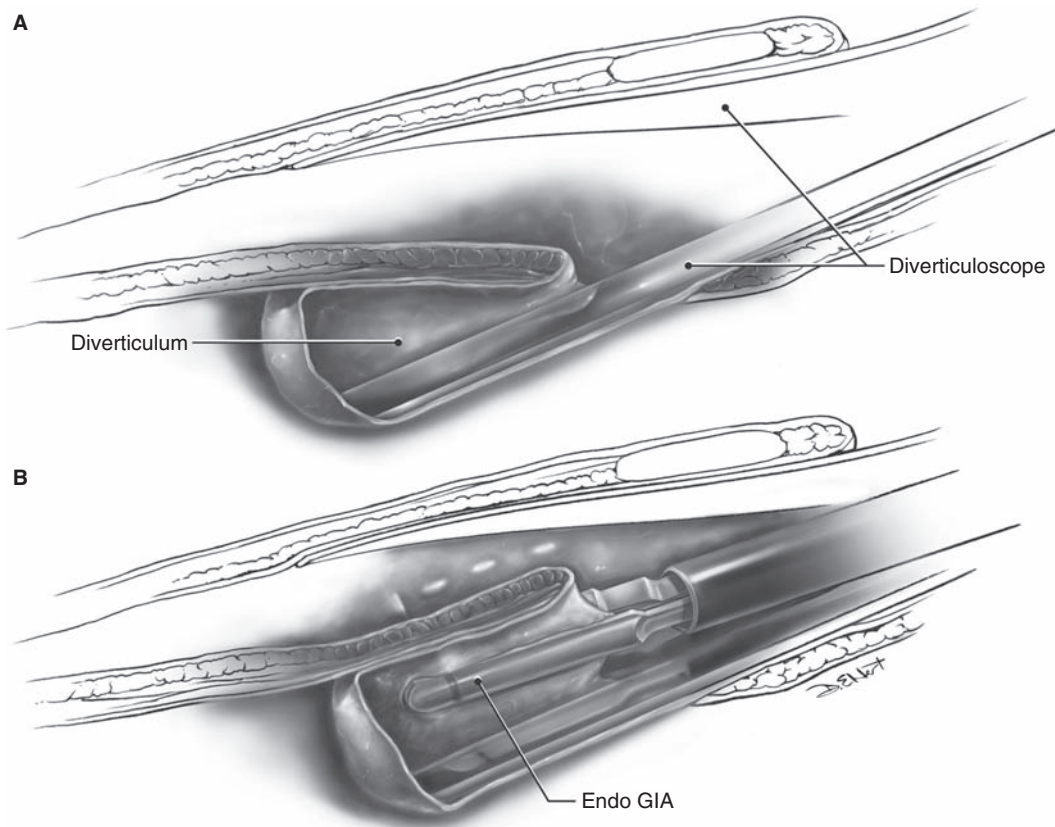
**FIGURE 14-23** A. Zenker's diverticulum, dashed line indicates proposed site of myotomy. B. Isolation of Zenker's diverticulum, with myotomy. C. Resection of Zenker's diverticulum with gastrointestinal anastomosis (GIA) stapler.

Small diverticula are difficult to engage with the stapling device and diverticuloscope.

## Summary

ZD is a rare disorder in which a pulsion-type diverticulum occurs in the posterior pharyngoesophageal region. Both surgical and endoscopic treatments (using rigid or flexible

endoscopy) are employed. All therapies are associated with greater than 90% symptom relief. Endoscopic therapies are associated with shorter length of stay, can be performed as outpatient procedures, and may avoid general anesthetic administration. However, they are associated with higher recurrence rates, which can often be addressed with repeat endoscopic treatment. These are important factors to consider as ZD usually presents in elderly patients who are more likely to be infirm. Both open surgical technique and peroral



Copyright © 2002, University of Washington. All rights reserved.

FIGURE 14-24 Zenker's diverticulectomy using diverticuloscope and stapler to perform mucomyotomy.

endoscopic methods are valid treatment methods and the choice of which to pursue should be based upon anatomic considerations, available expertise, and patient comorbidities.

## Epiphrenic Diverticula

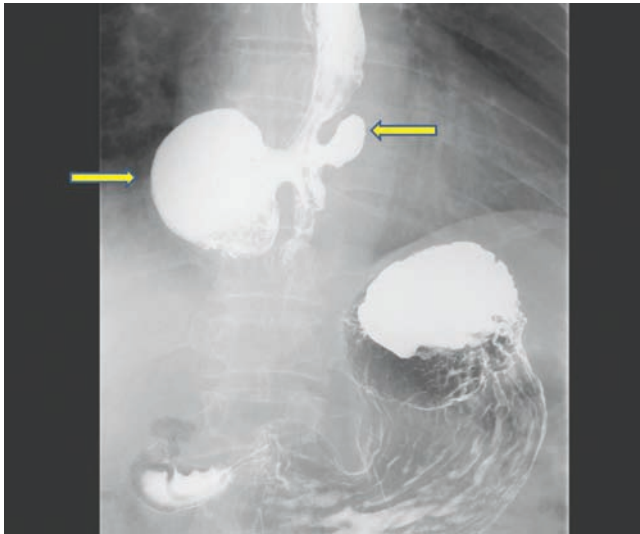
Diverticula present in the distal third of the esophagus, usually within 10 cm of the GE junction, are referred to as *epiphrenic diverticula* (ED). It is a rare condition, and its true incidence remains unclear as the number of patients with asymptomatic diverticula is not known. These are pulsion-type false diverticula, similar to ZD, as they are only outpouchings of mucosa and submucosa through the muscular wall of the esophagus. The pathophysiology underlying the disease, first recognized by Mondiere in 1833,<sup>85</sup> is assumed to be elevated esophageal intraluminal pressures, as a result of an underlying esophageal motility disorder, in conjunction with functional distal obstruction. With the advent of esophageal manometric testing, it is clear that EDs are commonly associated with a heterogeneous group of motility disorders and LES dysfunction, including achalasia, DES, Nutcracker esophagus, hypertensive LES, as well as nonspecific esophageal motility disorders (NSMD),<sup>86,87</sup> although often there is no detectable underlying motility

disorder. As such, these patients may present with symptoms similar to the aforementioned motility disorders, most commonly to include dysphagia, chest pain, heartburn, and regurgitation. Intermittent nocturnal aspiration is frequently seen and occurs in nearly 45% of patients.<sup>88,89</sup> The workup of these patients should include a complete history and examination, upper GI barium swallow, esophageal manometry and pH testing, and endoscopy (Fig. 14-25). Some controversy exists regarding who should be treated surgically. Those with mild symptoms and small-size diverticula, or those to whom surgery presents significant risk, can be safely observed. If symptoms of GERD are present, they may be controlled with medications. These patients should be followed for progression of their symptoms.<sup>90</sup> Those with severe symptoms who are candidates for surgery should be treated surgically.

## Treatment

Surgical treatment focuses on the concepts of resection of the diverticulum and treatment of the underlying esophageal motility disorder to relieve the functional obstruction, typically with long esophagogastric myotomy. Historically,





**FIGURE 14-25** Upper GI Barium study. Arrows demonstrating two epiphrenic diverticula. (Used with permission from Saurabh Khandelwal, MD, University of Washington.)

this was performed through a left thoracotomy to provide optimal exposure to the distal esophagus, GE junction, and cardia.<sup>91</sup> This was associated with excellent symptom relief in 76–94% of patients, but with mortality rates of up to 15% and complication rates of nearly 40%. Leak rates of 6–18% were observed.<sup>92–94</sup> Just as with treatment of achalasia and other benign esophageal disorders, the dominant operative technique has now shifted to the minimally invasive approach. Both the video-assisted thoracoscopic surgery (VATS) and laparoscopic approach have been described<sup>95,96</sup>; neither these nor the open approach have been compared in a randomized prospective fashion. When compared to thoracotomy approach, both minimally invasive techniques (VATS and laparoscopy) are associated with lower perioperative mortality rates (0–7.7%), shorter length of stay, and lower leak rates (14% cumulative rate); morbidity still ranges as high as 50%.<sup>94,97,98</sup> With the minimally invasive approaches, excellent relief of symptoms is seen in 83–100% of patients.<sup>94</sup> The laparoscopic approach, which has been the minimally invasive technique predominantly reported, capitalizes on these advantages and avoids single-lung ventilation and postoperative chest tubes. In addition, performing fundoplication is technically easier with the laparoscopic approach compared to the VATS approach. The laparoscopic method is the one we have adopted, in which we perform stapled resection of the diverticulum, long myotomy, and Toupet fundoplication.

## Operative Technique

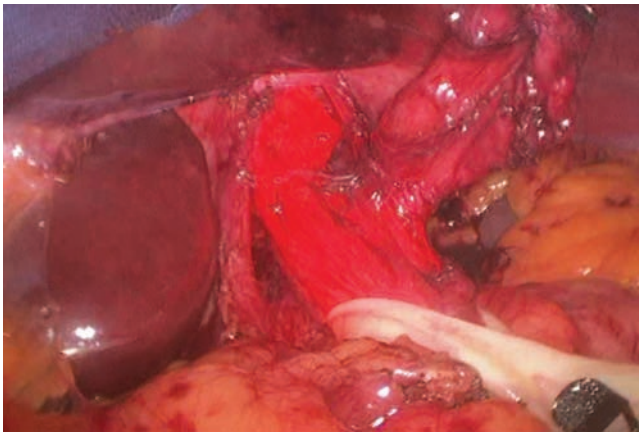
### LAPAROSCOPIC EPIPHRENIC DIVERTICULECTOMY

Patients are placed on a liquid diet for 48 hours prior to operation to minimize retained food in the diverticulum.

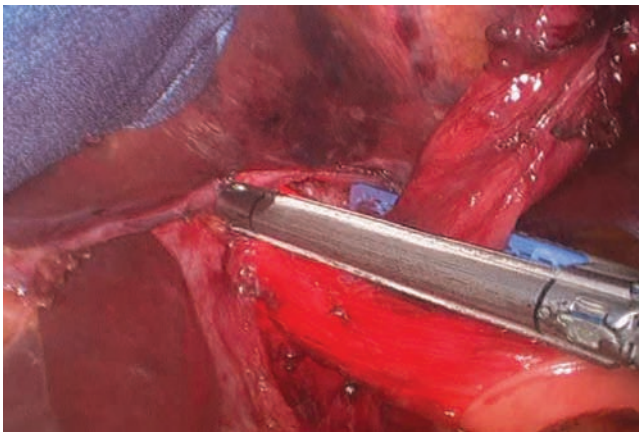
At the time of operation, endoscopy is performed prior to commencing, while the patient is under general anesthetic, to remove any retained debris and avoid its incorporation into the eventual suture line. The standard esophageal operating position is used, as previously described in this chapter. A 10-mm, 30-degree laparoscope is used to obtain the best image, and a liver retractor is placed to visualize the hiatus. The short gastric vessels are ligated, and the left crus technique is used to begin the division and dissection of the phrenoesophageal membrane. A Penrose drain is placed around the esophagus to aid with retraction. The esophagus is circumferentially dissected up into the mediastinum. The diverticulum usually becomes apparent at this time. Most diverticula are encountered on the right side. The diverticulum is freed from surrounding structures and dissected using both blunt and sharp dissection, taking care to cleanly expose the neck. The least obvious, but most important aspect of this is separating the diverticulum from the surrounding esophagus by dividing adhesions connecting the two. This is often underappreciated and can lead to incomplete resection of the diverticulum. An appropriately sized bougie is carefully placed in the esophagus (50–60 F) ensuring it does not enter the mouth of the diverticulum. The diverticulum is resected using an articulating laparoscopic stapling device, keeping the stapler parallel to the esophagus and using the bougie for guidance and to help avoid narrowing (Figs. 14-26A–C). The laparoscopic approach typically affords better visualization and stapler alignment than either VATS or open thoracotomy. The stapled edge is inspected to make sure there is no bleeding or disruption. A myotomy is performed opposite the suture line in the same fashion as previously described for achalasia, with extension of 3 cm onto the cardia. The separation of muscle fibers from the myotomy allows the suture line to be oversewn in Lembert fashion using interrupted sutures placed in intracorporeal fashion to protect it. Finally, a Toupet fundoplication is then performed as previously described to complete the operation, which provides protection from GER and in most cases will buttress the staple line. Endoscopy is performed to evaluate for leak or narrowing. Patients are admitted and an UGI barium study is performed on postoperative day 2. If no leak or stricture is seen, the patient is started on liquids and discharged home.

## Summary

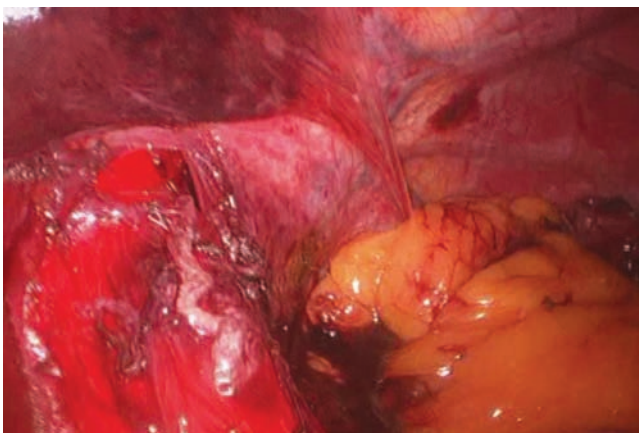
Epiphrenic diverticula are a rare type of pulsion diverticula that occur in the distal third of the esophagus. Treatment should be offered to those with symptomatic diverticula who are medically fit for surgery. Therapy should include surgical resection of the diverticulum and address the motility disorder to provide relief of distal obstruction, typically with long myotomy. Minimally invasive methods with either VATS or laparoscopy have demonstrated excellent symptomatic relief and lower mortality and morbidity compared to the older approach with thoracotomy.



A



B



C

**FIGURE 14-26 A-C.** Epiphrenic diverticulum resection. (Used with permission from Saurabh Khandelwal, MD, University of Washington.)

The laparoscopic method offers excellent visualization of the distal esophagus and is a technically easier approach for performing myotomy and partial fundoplication. The technique chosen should be based on anatomic considerations and surgeon experience.

## REFERENCES

1. Cameron AJ, Higgins JA. Linear gastric erosion. A lesion associated with large diaphragmatic hernia and chronic blood loss anemia. *Gastroenterology*. 1986;91(2):338–342.
2. Windsor CW, Collis JL. Anemia and hiatus hernia. *Proc R Soc Med*. 1968;61(3):213–215.
3. Windsor CW, Collis JL. Anaemia and hiatus hernia: experience in 450 patients. *Thorax*. 1967;22(1):73–78.
4. Hayden JD, Jamieson GG. Effect on iron deficiency anemia of laparoscopic repair of large paraesophageal hernias. *Dis Esophagus*. 2005;18(5):329–331.
5. Skinner DB, Belsey RH. Surgical management of esophageal reflux and hiatus hernia: long-term results with 1,030 patients. *J Thorac Cardiovasc Surg*. 1967;53:33–54.
6. Hill LD. Incarcerated paraesophageal hernia—surgical emergency. *Am J Surg*. 1973;126(2):286–291.
7. Skinner DB, Belsey RH. Surgical management of esophageal reflux and hiatus hernia. Long-term results with 1,030 patients. *J Thorac Cardiovasc Surg*. 1967;53(1):33–54.
8. Stylopoulos N, Gazelle GS, Rattner DW. Paraesophageal hernias: operation or observation? *Ann Surg*. 2002;236(4):492–500; discussion 500–501.
9. Draaisma WA, Gooszen HG, Tournioij E, Broeders IA. Controversies in paraesophageal hernia repair: a review of literature. *Surg Endosc*. 2005;19(10):1300–1308.
10. Davis SS, Jr. Current controversies in paraesophageal hernia repair. *Surg Clin North Am*. 2008;88(5):959–978, vi.
11. Frantzides CT, Madan AK, Carlson MA, Stavropoulos GP. A prospective, randomized trial of laparoscopic polytetrafluoroethylene (PTFE) patch repair vs simple cruroplasty for large hiatal hernia. *Arch Surg*. 2002;137(6):649–652.
12. Carlson MA, Richards CG, Frantzides CT. Laparoscopic prosthetic reinforcement of hiatal herniorrhaphy. *Dig Surg*. 1999;16(5):407–410.
13. Tatum RP, Shalhub S, Oelschlagel BK, Pellegrini CA. Complications of PTFE mesh at the diaphragmatic hiatus. *J Gastrointest Surg*. 2008;12(5):953–957.
14. Oelschlagel BK, Barreca M, Chang L, Pellegrini CA. The use of small intestine submucosa in the repair of paraesophageal hernias: initial observations of a new technique. *Am J Surg*. 2003;186(1):4–8.
15. Oelschlagel BK, Pellegrini CA, Hunter J, et al. Biologic prosthesis reduces recurrence after laparoscopic paraesophageal hernia repair: a multicenter, prospective, randomized trial. *Ann Surg*. 2006;244(4):481–490.
16. Jacobs M, Gomez E, Plasencia G, et al. Use of surgisis mesh in laparoscopic repair of hiatal hernias. *Surg Laparosc Endosc Percutan Tech*. 2007;17(5):365–368.
17. Desai KM, Diaz S, Dorward IG, et al. Histologic results 1 year after bioprosthetic repair of paraesophageal hernia in a canine model. *Surg Endosc*. 2006;20(11):1693–1697.
18. Stadlhuber RJ, Sherif AE, Mittal SK, et al. Mesh complications after prosthetic reinforcement of hiatal closure: a 28-case series. *Surg Endosc*. 2009;23(6):1219–1226.
19. Behrns KE, Schlinkert RT. Laparoscopic management of paraesophageal hernia: early results. *J Laparoendosc Surg*. 1996;6(5):311–317.
20. Trus TL, Bax T, Richardson WS, et al. Complications of laparoscopic paraesophageal hernia repair. *J Gastrointest Surg*. 1997;1(3):p. 221–227; discussion 228.
21. Patti MG, Robinson T, Galvani C, et al. Total fundoplication is superior to partial fundoplication even when esophageal peristalsis is weak. *J Am Coll Surg*. 2004;198(6):863–869; discussion 869–870.
22. Herbella FA, Tedesco P, Nipomnick I, et al. Effect of partial and total laparoscopic fundoplication on esophageal body motility. *Surg Endosc*. 2007;21(2):285–288.
23. Horgan S, Eubanks TR, Jacobsen G, et al. Repair of paraesophageal hernias. *Am J Surg*. 1999;177(5):354–358.
24. Herbella FA, Raz DJ, Nipomnick I, Patti MG. Primary versus secondary esophageal motility disorders: diagnosis and implications for treatment. *J Laparoendosc Adv Surg Tech A*. 2009;19(2):195–198.
25. Barreca M, Oelschlagel BK, Pellegrini CA. Outcomes of laparoscopic Nissen fundoplication in patients with the “hypercontractile esophagus.” *Arch Surg*. 2002;137(6):724–728, discussion 729.
26. Katzka DA. Motility abnormalities in gastroesophageal reflux disease. *Gastroenterol Clin North Am*. 1999;28(4):905–915.



27. Diener U, Patti MG, Molena D, et al. Esophageal dysmotility and gastroesophageal reflux disease. *J Gastrointest Surg.* 2001;5(3):260–265.
28. Osgood HA. A peculiar form of esophagismus. *Boston Med Surg J.* 1889; 120:401–403.
29. Spechler SJ, Castell DO. Classification of oesophageal motility abnormalities. *Gut.* 2001;49(1):145–151.
30. Richter JE. Oesophageal motility disorders. *Lancet.* 2001;358(9284): 823–828.
31. Patti MG, Gorodner MV, Galvani C, et al. Spectrum of esophageal motility disorders: implications for diagnosis and treatment. *Arch Surg.* 2005;140(5):442–448; discussion 448–449.
32. Richter JE, Bradley LA, Castell DO. Esophageal chest pain: current controversies in pathogenesis, diagnosis, and therapy. *Ann Intern Med.* 1989;110(1):66–78.
33. Leconte M, Douard R, Gaudric M, et al. Functional results after extended myotomy for diffuse oesophageal spasm. *Br J Surg.* 2007;94(9):1113–1118.
34. Brand DL, Martin D, Pope CE, 2nd. Esophageal manometrics in patients with angina-like chest pain. *Am J Dig Dis.* 1977;22(4):300–304.
35. Castell DO. The spectrum of esophageal motility disorders. *Gastroenterology.* 1979;76(3):639–640.
36. Cattau EL, Jr, Castell DO, Johnson DA, et al. Diltiazem therapy for symptoms associated with nutcracker esophagus. *Am J Gastroenterol.* 1991; 86(3):272–276.
37. Code CF, Schlegel JF, Kelley ML, Jr, et al. Hypertensive gastroesophageal sphincter. *Proc Staff Meet Mayo Clin.* 1960;35:391–399.
38. Tamhankar AP, Almogly G, Araim MA, et al. Surgical management of hypertensive lower esophageal sphincter with dysphagia or chest pain. *J Gastrointest Surg.* 2003;7(8):990–996; discussion 996.
39. Lamb PJ, Myers JC, Thompson SK, Jamieson GG. Laparoscopic fundoplication in patients with a hypertensive lower esophageal sphincter. *J Gastrointest Surg.* 2009;13(1):61–65.
40. Herbella FA, Tinelli AC, Wilson JL, Jr, Del Grande JC. Surgical treatment of primary esophageal motility disorders. *J Gastrointest Surg.* 2008;12(3) :604–608.
41. Ruffato A, Mattioli S, Lugaresi ML, et al. Long-term results after Heller-Dor operation for oesophageal achalasia. *Eur J Cardiothorac Surg.* 2006;29(6):914–919.
42. Goldblum JR, Rice TW, Richter JE. Histopathologic features in esophagomyotomy specimens from patients with achalasia. *Gastroenterology.* 1996;111(3):648–654.
43. Goldblum JR, Whyte RI, Orringer MB, Appelman HD. Achalasia. A morphologic study of 42 resected specimens. *Am J Surg Pathol.* 1994;18(4):327–337.
44. Clark SB, Rice TW, Tubbs RR, et al. The nature of the myenteric infiltrate in achalasia: an immunohistochemical analysis. *Am J Surg Pathol.* 2000;24(8):1153–1158.
45. Boeckxstaens GE. Novel mechanism for impaired nitrergic relaxation in achalasia. *Gut.* 2006;55(3):304–305.
46. Boeckxstaens GE. Achalasia: virus-induced euthanasia of neurons? *Am J Gastroenterol.* 2008;103(7):1610–1612.
47. Kashyap P, Farrugia G. Enteric autoantibodies and gut motility disorders. *Gastroenterol Clin North Am.* 2008;37(2):397–410, vi–vii.
48. Mearin F, Mourelle M, Guarner F, et al. Patients with achalasia lack nitric oxide synthase in the gastro-oesophageal junction. *Eur J Clin Invest.* 1993; 23(11):724–728.
49. Holloway RH, Dodds WJ, Helm JF, et al. Integrity of cholinergic innervation to the lower esophageal sphincter in achalasia. *Gastroenterology.* 1986;90(4):924–929.
50. Triadafilopoulos G, Aaronson M, Sackel S, Burakoff R. Medical treatment of esophageal achalasia. Double-blind crossover study with oral nifedipine, verapamil, and placebo. *Dig Dis Sci.* 1991;36(3):260–267.
51. Traube M, Dubovik S, Lange RC, McCallum RW. The role of nifedipine therapy in achalasia: results of a randomized, double-blind, placebo-controlled study. *Am J Gastroenterol.* 1989;84(10):1259–1262.
52. Tottrup A, Ny L, Alm P, et al. The role of the L-arginine/nitric oxide pathway for relaxation of the human lower oesophageal sphincter. *Acta Physiol Scand.* 1993;149(4):451–459.
53. Gelfond M, Rozen P, Gilat T. Isosorbide dinitrate and nifedipine treatment of achalasia: a clinical, manometric and radionuclide evaluation. *Gastroenterology.* 1982;83(5):963–969.
54. Campos GM, Vittinghoff E, Rabl C, et al. Endoscopic and surgical treatments for achalasia: a systematic review and meta-analysis. *Ann Surg.* 2009;249(1):45–57.
55. Zaninotto G, Annese V, Costantini M, et al. Randomized controlled trial of botulinum toxin versus laparoscopic Heller myotomy for esophageal achalasia. *Ann Surg.* 2004;239(3):364–370.
56. Horgan S, Hudda K, Eubanks T, et al. Does botulinum toxin injection make esophagomyotomy a more difficult operation? *Surg Endosc.* 1999;13(6): 576–579.
57. Rai RR, Shende A, Joshi A, et al. Rigiflex pneumatic dilation of achalasia without fluoroscopy: a novel office procedure. *Gastrointest Endosc.* 2005; 62(3):427–431.
58. Heller E. Extramukose Cardioplatic beim chronischen Cardiospasmus mit Dilatation des Oesophagus. *Mitt Grenzgeb Med Chir.* 1913;27:141.
59. Ortiz A, de Haro LF, Parrilla P, et al. Very long-term objective evaluation of Heller myotomy plus posterior partial fundoplication in patients with achalasia of the cardia. *Ann Surg.* 2008;247(2):258–264.
60. Shimi S, Nathanson LK, Cuschieri A. Laparoscopic cardiomyotomy for achalasia. *J R Coll Surg Edinb.* 1991;36(3):152–154.
61. Pellegrini C, Wetter LA, Patti M, et al. Thoracoscopic esophagomyotomy. Initial experience with a new approach for the treatment of achalasia. *Ann Surg.* 1992;216(3):291–296; discussion 296–299.
62. Richards WO, Torquati A, Holzman MD, et al. Heller myotomy versus Heller myotomy with Dor fundoplication for achalasia: a prospective randomized double-blind clinical trial. *Ann Surg.* 2004;240(3):405–412; discussion 412–415.
63. Rebecchi F, Giaccone C, Farinella E, et al. Randomized controlled trial of laparoscopic Heller myotomy plus Dor fundoplication versus Nissen fundoplication for achalasia: long-term results. *Ann Surg.* 2008;248(6): 1023–1030.
64. Patti MG, Pellegrini CA, Horgan S, et al. Minimally invasive surgery for achalasia: an 8-year experience with 168 patients. *Ann Surg.* 1999;230(4): 587–593; discussion 593–594.
65. Oelschlager BK, Chang L, Pellegrini CA. Improved outcome after extended gastric myotomy for achalasia. *Arch Surg.* 2003;138(5):490–495; discussion 495–497.
66. Wright AS, Williams CW, Pellegrini CA, Oelschlager BK. Long-term outcomes confirm the superior efficacy of extended Heller myotomy with Toupet fundoplication for achalasia. *Surg Endosc.* 2007;21(5):713–718.
67. Ludlow AA. A case of obstructed deglutition from a preternatural dilatation of and bag formed in the pharynx. *Medical Observations and Enquiries by Society of Physicians in London.* 1769;2nd ed. (3):85–101.
68. Zenker FA, von Ziemssen H. Krankheiten des oesophagus. *Handbuch der Speciellen Pathologie und Therapie.* Vol. 7(suppl). Leipzig, Germany: FCW Vogel; 1877:1–87.
69. Vogelsang A, Schumacher B, Neuhaus H. Therapy of Zenker's diverticulum. *Dtsch Arztebl Int.* 2008;105(7):120–126.
70. Ferreira LE, Simmons DT, Baron TH. Zenker's diverticula: pathophysiology, clinical presentation, and flexible endoscopic management. *Dis Esophagus.* 2008;21(1):1–8.
71. Siddiq MA, Sood S, Strachan D. Pharyngeal pouch (Zenker's diverticulum). *Postgrad Med J.* 2001;77(910):506–511.
72. Wasserzug O, Zikk D, Raziell A, et al. Endoscopically stapled diverticulostomy for Zenker's diverticulum: results of a multidisciplinary team approach. *Surg Endosc.* 2010;24(3):637–641.
73. Visosky AM, Parke RB, Donovan DT. Endoscopic management of Zenker's diverticulum: factors predictive of success or failure. *Ann Otol Rhinol Laryngol.* 2008;117(7):531–537.
74. Laing MR, Murthy P, Ah-See KW, Cockburn JS. Surgery for pharyngeal pouch: audit of management with short- and long-term follow-up. *J R Coll Surg Edinb.* 1995;40(5):315–318.
75. Bonafede JP, Lavertu P, Wood BG, Eliachar I. Surgical outcome in 87 patients with Zenker's diverticulum. *Laryngoscope.* 1997;107(6):720–725.
76. Payne WS. The treatment of pharyngoesophageal diverticulum: the simple and complex. *Hepatogastroenterology.* 1992;39(2):109–114.
77. Barthlen W, Feussner H, Hannig C, et al. Surgical therapy of Zenker's diverticulum: low risk and high efficiency. *Dysphagia.* 1990;5(1):13–19.
78. Aggerholm K, Illum P. Surgical treatment of Zenker's diverticulum. *J Laryngol Otol.* 1990;104(4):312–314.
79. Mosher H. Webs and pouches of the esophagus: their diagnosis and treatment. *Surg Gynecol Obstet.* 1917;25:175–187.
80. Dohlman G, Mattsson O. The endoscopic operation for hypopharyngeal diverticula: a roentgen cinematographic study. *AMA Arch Otolaryngol.* 1960;71:744–752.



81. Collard JM, Otte JB, Kestens PJ. Endoscopic stapling technique of esophagodiverticulostomy for Zenker's diverticulum. *Ann Thorac Surg.* 1993; 56(3):573–576.
82. van Overbeek JJ. Meditation on the pathogenesis of hypopharyngeal (Zenker's) diverticulum and a report of endoscopic treatment in 545 patients. *Ann Otol Rhinol Laryngol.* 1994;103(3):178–185.
83. Tang SJ, Jazrawi SF, Chen E, et al. Flexible endoscopic clip-assisted Zenker's diverticulotomy: the first case series (with videos). *Laryngoscope.* 2008;118(7):1199–1205.
84. Evrard S, Le Moine O, Hassid S, Deviere J. Zenker's diverticulum: a new endoscopic treatment with a soft diverticuloscope. *Gastrointest Endosc.* 2003; 58(1):116–120.
85. Mondiere JT. Notes sur quelques maladies de l'oesophage. *Arch Gen Med Paris.* 1833;3:28–65.
86. Nehra D, Lord RV, DeMeester TR, et al. Physiologic basis for the treatment of epiphrenic diverticulum. *Ann Surg.* 2002;235(3):346–354.
87. Melman L, Quinlan J, Robertson B, et al. Esophageal manometric characteristics and outcomes for laparoscopic esophageal diverticulectomy, myotomy, and partial fundoplication for epiphrenic diverticula. *Surg Endosc.* 2009;23(6):1337–1341.
88. Tedesco P, Fisichella PM, Way LW, Patti MG. Cause and treatment of epiphrenic diverticula. *Am J Surg.* 2005;190(6):891–894.
89. Benacci JC, Deschamps C, Trastek VF, et al. Epiphrenic diverticulum: results of surgical treatment. *Ann Thorac Surg.* 1993;55(5):1109–1113; discussion 1114.
90. Zaninotto G, Portale G, Costantini M, et al. Long-term outcome of operated and unoperated epiphrenic diverticula. *J Gastrointest Surg.* 2008; 12(9):1485–1490.
91. Belsey R. Functional disease of the esophagus. *J Thorac Cardiovasc Surg.* 1966;52(2):164–188.
92. Varghese TK, Jr, Marshall B, Chang AC, et al. Surgical treatment of epiphrenic diverticula: a 30-year experience. *Ann Thorac Surg.* 2007;84(6):1801–1809; discussion 1801–1809.
93. Streitz JM, Jr, Glick ME, Ellis FH, Jr. Selective use of myotomy for treatment of epiphrenic diverticula. Manometric and clinical analysis. *Arch Surg.* 1992;127(5):585–587; discussion 587–588.
94. Kilic A, Schuchert MJ, Awais O, et al. Surgical management of epiphrenic diverticula in the minimally invasive era. *JSLA.* 2009;13(2):160–164.
95. van der Peet DL, Klinkenberg-Knol EC, Berends FJ, Cuesta MA. Epiphrenic diverticula: minimal invasive approach and repair in five patients. *Dis Esophagus.* 2001;14(1):60–62.
96. Rosati R, Fumagalli U, Bona S, et al. Laparoscopic treatment of epiphrenic diverticula. *J Laparoendosc Adv Surg Tech A.* 2001;11(6):371–375.
97. Fraiji E, Jr, Bloomston M, Carey L, et al. Laparoscopic management of symptomatic achalasia associated with epiphrenic diverticulum. *Surg Endosc.* 2003;17(10):1600–1603.
98. Fernando HC, Luketich JD, Samphire J, et al. Minimally invasive operation for esophageal diverticula. *Ann Thorac Surg.* 2005;80(6):2076–2080.

*This page intentionally left blank*

# GASTROESOPHAGEAL REFLUX DISEASE AND HIATAL HERNIA (INCLUDING PARAESOPHAGEAL)

Toshitaka Hoppo • Shamus R. Carr • Blair A. Jobe

## GERD—OVERVIEW

### Definition

*Gastroesophageal reflux disease* (GERD) is a chronic disorder related to the retrograde flow of gastric contents into the esophagus, resulting in a spectrum of symptoms with or without tissue injury.<sup>1</sup> Classic GERD symptoms in the absence of esophageal mucosal complications are the hallmarks of nonerosive reflux disease (NERD). Patients with NERD account for up to 70% of those with GERD in the community.<sup>2</sup> Antireflux surgery is the only effective and long-term therapy. Although various endoscopic approaches to treat GERD have been introduced, none of them has been able to achieve an efficacy equivalent to antireflux surgery.<sup>3,4</sup>

### Symptoms

Heartburn (ascending retrosternal burning) and regurgitation are typical GERD symptoms. Epidemiologic studies have demonstrated that heartburn occurs monthly in as many as 40–50% of the Western population. The occurrence of heartburn at night and its effect on quality of life have recently been highlighted by a Gallup poll conducted by the American Gastroenterologic Society (Table 15-1).<sup>5</sup> Regurgitation of gastric contents often occurs when the patient is supine or with increases in intra-abdominal pressure, and may result in atypical symptoms, including cough, globus sensation, hoarseness, throat clearing, asthma, aspiration pneumonia, and pulmonary fibrosis. Dysphagia is a typical symptom of GERD and can be divided into (1) an oropharyngeal etiology, which is characterized by difficulty

transferring food out of the mouth into the esophagus, and (2) esophageal etiology, which is characterized by the sensation of food sticking in the lower chest. Dysphagia can be a sign of underlying malignancy and should be aggressively investigated with upper endoscopy. Chest pain can be caused by GERD; however, it is very important to exclude a cardiac etiology. DeMeester and colleagues reported that nearly 50% of patients with severe noncardiac chest pain had a positive 24-hour pH study implicating GERD as the underlying etiology.<sup>6</sup> Chest pain precipitated by meals, occurring at night while supine, nonradiating, responsive to antacid medication, or accompanied by other symptoms such as dysphagia and/or regurgitation should trigger an evaluation for an esophageal cause. Additionally, it should be noted that the distinction between heartburn and chest pain can be difficult to make, and the perception of these symptoms is highly variable between patients.<sup>7,8</sup>

## PATHOPHYSIOLOGY OF GERD

The antireflux mechanism includes four important components: (1) lower esophageal sphincter (LES); (2) crural diaphragm; (3) esophageal peristalsis; and (4) stomach (the reservoir).

### Lower Esophageal Sphincter

The *gastroesophageal junction* (GEJ) is a complex arrangement of specialized muscles composed of both intrinsic (LES) and extrinsic (crural diaphragm) contractile elements. The LES, which can be identified as a high-pressure zone located at the GEJ, creates the barrier between the esophagus and stomach that normally prevents reflux. LES relax-





**TABLE 15-1: AMERICAN GASTROENTEROLOGIC ASSOCIATION GALLUP POLL ON NIGHTTIME GASTROESOPHAGEAL REFLUX DISEASE SYMPTOMS**

- 50 million Americans have nighttime heartburn at least 1/wk
- 80% of heartburn sufferers had nocturnal symptoms—65% both day and night
- 63% report that it affects their ability to sleep and impacts their work the next day
- 72% are on prescription medications
- Nearly half (45%) report that current remedies do not relieve all symptoms

ation occurs in two situations: (1) immediately following a swallow, when it momentarily relaxes to allow passage of food into the stomach, and (2) when the fundus is distended with gas, it is eliminated to allow venting of the gas (a belch)—transient LES relaxation (TLESR). For an LES to be effective, it must possess three characteristics: an adequate (1) total length, (2) intra-abdominal length, and (3) resting pressure (Table 15-2).<sup>9</sup> Therefore, a defective LES is identified by one or more of the following characteristics: (1) a high-pressure zone with an average pressure of less than 6 mm Hg, (2) an average overall length of 2 cm or less, and (3) an average length exposed to the positive pressure environment of the abdomen (intra-abdominal length) of 1 cm or less. The most common cause of a permanently defective LES is an inadequate abdominal length, secondary to the high prevalence of a hiatal hernia in patients with GERD.<sup>9</sup> A TLESR is an LES relaxation that occurs *without* a swallow and accounts for the physiologic reflux and “venting” of the stomach, particularly in the postprandial state. Frequent and prolonged TLESR can be associated with the development of GERD, and this may explain the etiology of disease observed in the 40% of patients with a manometrically normal sphincter. A transient loss of the LES can also occur due to a functional problem of the gastric reservoir and delayed emptying.<sup>10</sup> In this setting, if excessive air and food are swallowed, there are gastric distention and an increase in intra-gastric pressure with shortening of the LES (Fig. 15-1). This process continues until a critical LES length is reached and eventually the pressure drops precipitously and reflux occurs. This “transient sphincter”



**TABLE 15-2: NORMAL MANOMETRIC VALUES OF THE LOWER ESOPHAGEAL SPHINCTER, N = 50**

Parameter	Median value	2.5th percentile	97.5th percentile
Pressure (mm Hg)	13	5.8	27.7
Overall length (cm)	3.6	2.1	5.6
Abdominal length (cm)	2	0.9	4.7

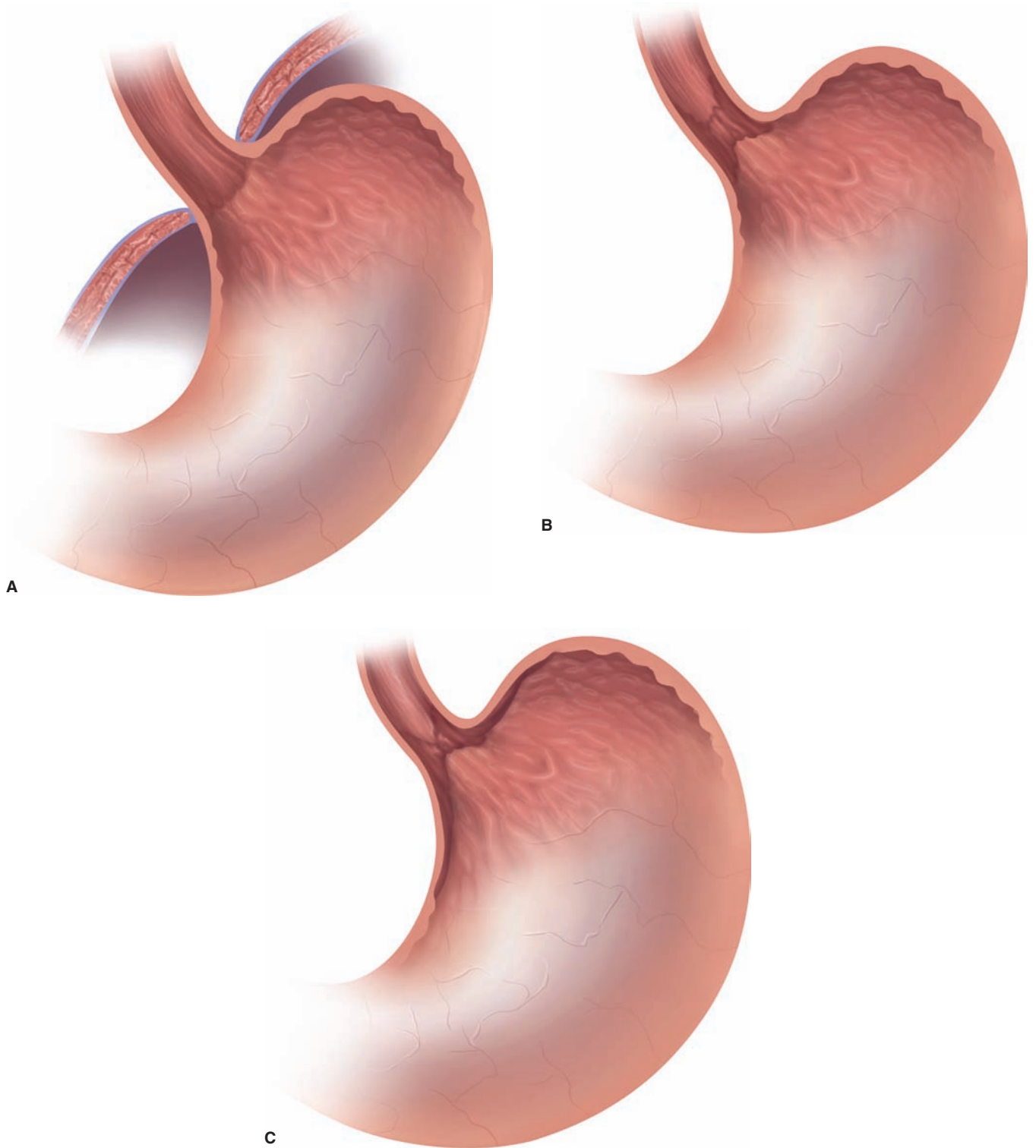
shortening occurs in the initial stages of GERD and is the mechanism for the early complaint of excessive postprandial reflux. This process is associated with the common complaints of belching and bloating in patients with GERD. To compound matters, there is an increased frequency of swallowing (air and saliva) observed in GERD patients because the ingestion of saliva (pH 7) serves to neutralize the acidic fluid (pH 1) in the esophagus.<sup>11</sup> Therefore, GERD may begin in the stomach, secondary to gastric distention due to overeating and a high-fat diet, which delays gastric emptying. Further, a close relationship between the geometry of the cardia and one’s propensity to reflux in the face of a given intragastric pressure has been established.<sup>10</sup> Greater gastric distension, as reflected by an increasing intragastric pressure, is necessary to “open” the sphincter in patients with an intact angle of His compared to those with hiatal hernia (Fig. 15-2).<sup>12</sup> These data elucidate why the presence of a hiatal hernia is often associated with GERD and explain the loss of the flap valve mechanism (intragastric portion of LES). In addition, in the presence of a hiatal hernia the intrinsic portion of the LES is no longer aided by the crural diaphragm (extrinsic LES).

## Esophageal Peristalsis

Esophageal peristalsis is an extremely important component of the antireflux mechanism and serves to clear physiologic reflux and thus reduces contact time between the esophageal epithelium and gastric fluid. Ineffective esophageal motility can result in an abnormal esophageal exposure to gastric juice even in individuals with a mechanically effective LES and normal gastric function.<sup>13</sup> However, ineffective motility is more often seen in patients with a mechanically defective LES, where distal esophageal body function deteriorates as a direct result of repetitive inflammation; this effect further prolongs the esophageal exposure to gastric juice, which creates a vicious cycle leading to more severe disease. Diener and colleagues reported that 40–50% of patients with GERD had abnormal esophageal peristalsis.<sup>13</sup> In these patients, esophageal clearance time was prolonged, and gastric fluid was in contact with the esophageal mucosa for a longer period of time and traveled more proximally when compared to GERD patients with intact esophageal motility. Therefore, these patients were prone to having more severe mucosal injury and extraesophageal symptoms such as cough.<sup>14,15</sup> To highlight these points, it is established that patients with mixed connective tissue diseases such as scleroderma commonly have an aperistaltic esophagus and absent LES, which results in the most severe form of GERD.<sup>16</sup>

## Crural Diaphragm

The crural diaphragm provides an extrinsic component to the gastroesophageal barrier. Mittal and colleagues demonstrated a direct correlation between intraluminal pressure of the GEJ and integrated electrical activity of the crural



**FIGURE 15-1** A graphic illustration of the shortening of the lower esophageal sphincter that occurs as the sphincter is “taken up” by the cardia as the stomach distends.

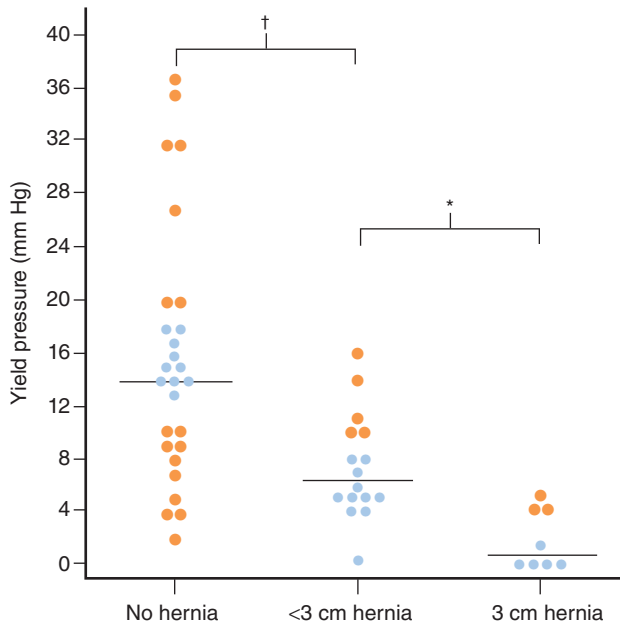


FIGURE 15-2 Yield pressure of the lower esophageal sphincter decreases as hiatal hernia size increases.

diaphragm.<sup>17</sup> Additionally, normal pressure of the GEJ from manometric tracings has been shown to range from  $15 \pm 11$  mm Hg at the end of expiration to  $40 \pm 13$  mm Hg at the end of inspiration mainly as a result of the diaphragmatic contribution.<sup>18</sup> This pinchcock action of the diaphragm is particularly important as a protection mechanism against reflux induced by sudden increases in intra-abdominal pressure.<sup>19</sup> This mechanism is obviously disrupted by the presence of a hiatal hernia where the intrinsic LES has “migrated” proximal to the diaphragmatic pinch.

## Stomach

Impaired function of the stomach such as abnormal gastric emptying may contribute to GERD by increasing intragastric pressure, distension, and LES unrolling.<sup>20</sup> This may occur in patients with a large hiatal hernia, in which the herniated stomach in the chest does not empty appropriately, gastric outlet obstruction either from malignancy or peptic ulcer disease, and diabetic gastroparesis.

## COMPLICATIONS OF GERD

The complications of GERD result from the damage inflicted by gastric juice on the esophageal mucosa, pharyngeal or respiratory epithelium, and the mucosal changes caused by their subsequent repair and fibrosis. These complications can be categorized into three groups: (1) mucosal complications such as esophagitis or stricture; (2) extraesophageal

**TABLE 15-3: COMPLICATIONS OF GASTROESOPHAGEAL REFLUX DISEASE: 150 CONSECUTIVE CASES WITH PROVEN GASTROESOPHAGEAL REFLUX DISEASE (24-HOUR ESOPHAGEAL pH MONITORING, ENDOSCOPY, AND MOTILITY)**

Complication	No.	Structurally Normal Sphincter (%)	Structurally Defective Sphincter (%)
None	59	58	42
Erosive esophagitis	47	23	77 <sup>a</sup>
Stricture	19	11	89
Barrett's esophagus	25	0	100
Total	150		

<sup>a</sup> Grade more severe with defective cardia.

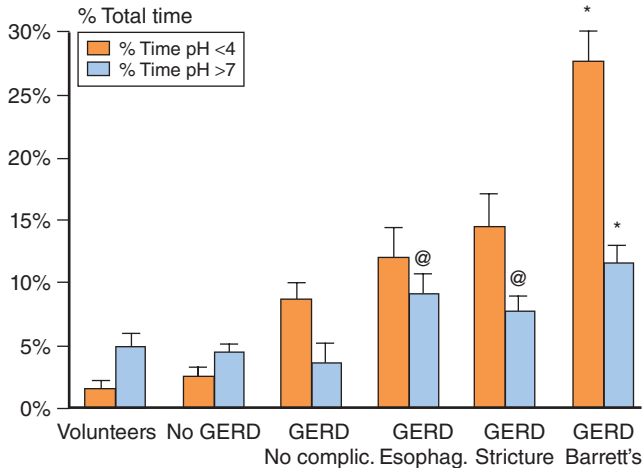
Reproduced, with permission, from DeMeester TR. Gastroesophageal reflux disease. In: Moody FG, Carey LC, Scott Jone R, et al, eds. *Surgical Treatment of Digestive Disease*. Chicago, IL: Year Book Medical; 1990:81.

or respiratory complications such as laryngitis, pneumonia, asthma, and pulmonary fibrosis; and (3) metaplastic and neoplastic complications such as Barrett's esophagus and adenocarcinoma. The prevalence and severity of GERD-related complications are positively correlated with the degree of LES dysfunction and impaired esophageal motility (Table 15-3).<sup>21</sup>

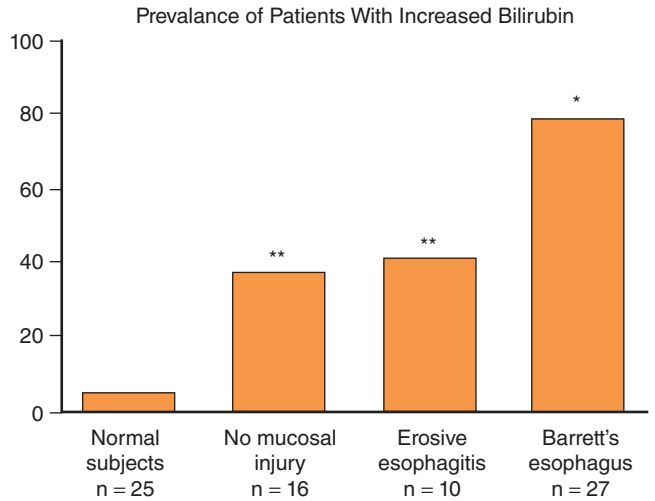
## Mucosal Complications

Mucosal complications such as esophagitis and stricture can occur in the presence of two predisposing factors: (1) a mechanically defective LES and (2) an increased esophageal exposure to the gastric fluid with a pH less than 4 and greater than 7 (Fig. 15-3).<sup>21</sup> The components of the refluxed gastric fluid can include acid and pepsin as well as biliary and pancreatic secretions that travel from the duodenum into the stomach.<sup>22,23</sup> Although acid and activated pepsin are the key ingredients of the gastric juice that leads to esophagitis, it has been established that the most severe epithelial injury occurs during exposure to bile salts combined with acid and pepsin.<sup>24</sup> Previous experimental studies have shown that gastric or duodenal juice alone causes minimal or little damage to the esophageal mucosa, but the combination of duodenal juice and gastric juice is highly noxious. Previous study to directly measure esophageal bilirubin exposure as a marker of duodenogastroesophageal reflux has shown that 58% of patients with GERD have increased esophageal exposure to duodenal juice and that this exposure occurs most commonly when the esophageal pH is between 4 and 7 (Fig. 15-4).<sup>25</sup> Within this pH range, there is formation of nonpolarized, soluble bile acids, which can diffuse through the cell membrane and cause damage to the mucosal cells. Additionally, this type of exposure correlates with the development of Barrett's esophagus (Fig. 15-5).<sup>25</sup> The fact that the combination of

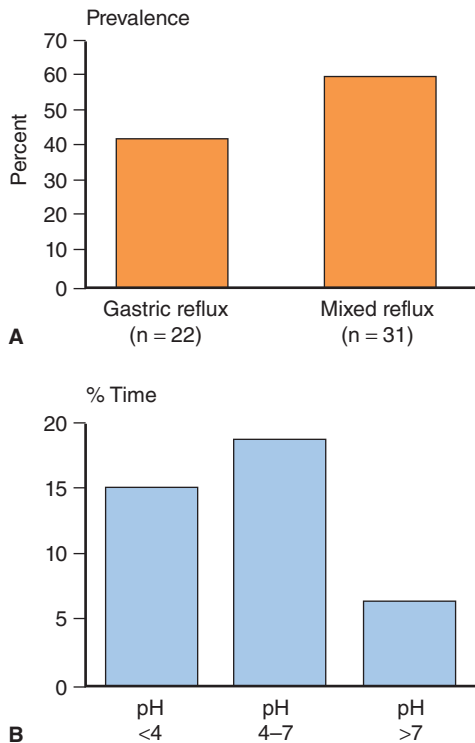




**FIGURE 15-3** Esophageal acid and alkaline exposure expressed as percentage of total time pH of less than 4 and more than 7. \* =  $p < .01$  versus gastroesophageal reflux disease patients with no complication. @ =  $p < .05$  versus gastroesophageal reflux disease patients with no complications. (Reproduced from Stein HG, Barlow AP, DeMeester TR, Hinder RA. Complications of gastroesophageal reflux disease: role of the lower esophageal sphincter, esophageal acid and acid/alkaline exposure, and duodenogastric reflux. *Ann Surg.* 1992;216:39.)



**FIGURE 15-5** Prevalence of abnormal esophageal bilirubin exposure in healthy subjects and in patients with gastroesophageal reflux disease with varied degrees of mucosal injury. (\*  $p < .03$  vs all other groups, \*\*  $p < .3$  vs healthy subjects.) (Reproduced from Kauer WK, Peters JH, DeMeester TR, et al. Mixed reflux of gastric juice is more harmful to the esophagus than gastric juice alone: the need for surgical therapy reemphasized. *Ann Surg.* 1995;222:525.)



**FIGURE 15-4** **A.** Prevalence of reflux types in 53 patients with gastroesophageal reflux disease. **B.** Esophageal luminal pH during bilirubin exposure. (Reproduced from Kauer WK, Peters JH, DeMeester TR, et al. Mixed reflux of gastric juice is more harmful to the esophagus than gastric juice alone: the need for surgical therapy reemphasized. *Ann Surg.* 1995;222:525.)

gastric and duodenal juice is more noxious to the esophageal mucosa than gastric juice alone may provide an explanation for the observation that 25% of patients with reflux esophagitis develop recurrent and/or progressive mucosal damage despite medical therapy.<sup>21</sup> Clinically, there is poor correlation between the symptom of heartburn and the endoscopic finding of esophagitis.<sup>26</sup> The reflux of acidic gastric juice combined with duodenal contents can irritate nerve endings close to the luminal surface and cause severe heartburn in the absence of endoscopically detectable erosions; bile salts inhibit pepsin and acid inactivates trypsin, and the patient exhibits little or no gross evidence of esophagitis. By contrast, the reflux of alkaline gastric juice may occur without symptoms because of the absence of hydrogen ions but cause endoscopically evident esophagitis secondary to bile-activated trypsin exposure to the esophageal epithelium. This is supported by recent clinical studies that demonstrated that the presence of alkaline reflux is associated with the development of mucosal injury.<sup>25,27</sup> In addition, several studies using either prolonged ambulatory aspiration techniques<sup>28</sup> or spectrophotometric bilirubin measurement<sup>29</sup> have shown that patients with GERD have more concentrated bile acid exposure to the esophageal mucosa than normal subjects, commonly in the supine position during sleep and in the upright position during the postprandial period. Furthermore, reflux of both acid and pancreaticobiliary juice is the most prevalent pattern of exposure and present in 100% of complicated Barrett's patients, 89% of uncomplicated Barrett's patients, 79% of patients with esophagitis, and 50% of patients with NERD.<sup>30,31</sup> These findings support that the reflux of duodenal juice containing bile acids is common in

patients with GERD and that proton pump inhibitor (PPI) therapy cannot prevent mucosal damage due to bile acids.

Esophageal stricture (circumferential scarring) formation and/or shortening (axial scarring) can be associated with severe esophagitis or Barrett's esophagus. Scarring occurs at the site of maximal inflammatory injury (ie, squamocolumnar junction). Thought by some to be a protective mechanism, the metaplastic columnar epithelium advances proximally into the area of inflammation leading to "protection" of that given length of esophagus; the proximal migration of the squamocolumnar junction leads to more proximal stricture formation within the esophagus. The presence of stricture can be an indicator of GERD even if there is no evidence of esophagitis or Barrett's esophagus. However, in patients with normal acid exposure, the stricture may be due to malignancy or a drug-induced chemical injury.<sup>32</sup> Biopsy should be obtained to exclude malignancy. A short esophagus should be suspected when there is a hiatal hernia of greater than 5 cm that does not reduce in the upright position on esophagram.

## Extraneousophageal or Pulmonary Complications

It has been increasingly recognized that a significant proportion of patients with GERD have laryngeal or respiratory symptoms such as cough, recurrent pneumonia, asthma, and progressive pulmonary fibrosis, sometimes in conjunction with typical GERD symptoms such as heartburn and regurgitation.<sup>33</sup> In addition, a strong association between GERD and the development of lung disease such as asthma and idiopathic pulmonary fibrosis has been established. Previous studies have demonstrated that up to 50% of asthmatics have either endoscopic evidence of esophagitis or increased esophageal acid exposure on 24-hour ambulatory pH monitoring,<sup>34,35</sup> and that 87% of patients with idiopathic pulmonary fibrosis<sup>36</sup> and 90.9% with cystic fibrosis<sup>37</sup> have documented GERD based on esophageal pH monitoring.

Two mechanisms have been proposed as the pathogenesis of reflux-induced respiratory symptoms: (1) aspiration of gastric contents and (2) vagally mediated bronchoconstriction. Recent clinical studies have demonstrated a strong correlation between idiopathic pulmonary fibrosis and hiatal hernia and a high association between GERD and pulmonary disease such as asthma.<sup>33</sup> Pathological acid exposure in the proximal esophagus is often identified in patients with respiratory symptoms and GERD. Scintigraphic studies have demonstrated aspiration of ingested radioisotope in patients with GERD and respiratory symptoms.<sup>38</sup> Simultaneous tracheal and esophageal pH monitoring has demonstrated the presence of concomitant acidification both in the trachea and the esophagus in patients with asthma.<sup>39</sup> Animal studies have shown an increased airway resistance after the instillation of hydrochloric acid into the trachea.<sup>40</sup> Additionally, it is well known that bronchoconstriction occurs following the acid exposure in the distal esophagus.<sup>41</sup> This can be explained by

the common embryologic origin of the trachea and esophagus and their shared vagal innervation.

It is difficult to document that respiratory symptoms and/or injury are caused the underlining GERD as both are very prevalent. In a substantial number of patients with reflux-induced respiratory symptoms, GERD is often silent and is only uncovered when investigation is initiated. A high index of suspicion is required, especially in patients with poorly controlled adult-onset asthma in spite of appropriate bronchodilator therapy. Objective esophageal testing should be performed to document evidence of GERD and to attempt to correlate extraesophageal symptoms with reflux events. Upper endoscopy may reveal the presence of esophagitis or Barrett's esophagus. Manometry may demonstrate a hypotensive LES or some degree of impaired esophageal motility. Traditionally, the diagnosis of reflux-induced respiratory symptoms has been made using ambulatory dual probe pH monitoring; one probe is positioned within the distal esophagus and the other at a proximal location such as the trachea, pharynx, or proximal esophagus. Although ambulatory esophageal pH monitoring allows a direct correlation between esophageal acidification and respiratory symptoms, the chronological relationship between reflux events and bronchoconstriction is complex. The sensitivity of this approach is poor as much of the acid exposure is neutralized proximally after mixing with saliva. Multichannel intraluminal impedance-pH (MII-pH) has been introduced as a promising tool to evaluate the extension of reflux and its symptom correlation regardless of the composition of refluxate (liquid, gas, mixed, alkaline, acidic), especially in patients with atypical symptoms. Although several studies have shown that combined 24-hour MII-pH has a high yield for detection of GERD with atypical symptoms,<sup>27</sup> the clinical utility of MII-pH is still being investigated.

Once GERD is suspected or thought to be responsible for respiratory symptoms, the treatment options may be either the trial of high-dose PPI therapy (BID or TID dosing) or antireflux surgery. A 3–6 months trial of high-dose PPI therapy may suggest that GERD is partly or completely responsible for the development of respiratory symptoms. However, the persistence of symptoms despite the maximal PPI therapy does not necessarily rule out the possible contribution of GERD. The algorithm depicted in Fig. 15-6 is made based on the outcome of dual-probe 24-hour pH monitoring and esophageal manometry in patients with respiratory symptoms and does not include impedance. Previous studies have demonstrated that acid suppressive therapy with PPI improves asthma symptoms and/or peak expiratory flow rates in up to 73% of asthmatics with GERD, although fewer than 15% can be expected to have objective improvements in their pulmonary function parameters.<sup>4,42,43</sup> Most studies were conducted with a relatively short course of acid suppressive therapy (<3 months). This time period may have been sufficient for symptomatic improvement but insufficient for recovery of pulmonary function. Given the fact that acid suppressive therapy can only reduce the acidity of the gastric fluid but does not reduce the total number of reflux events, the conflicting results regarding medical therapy in

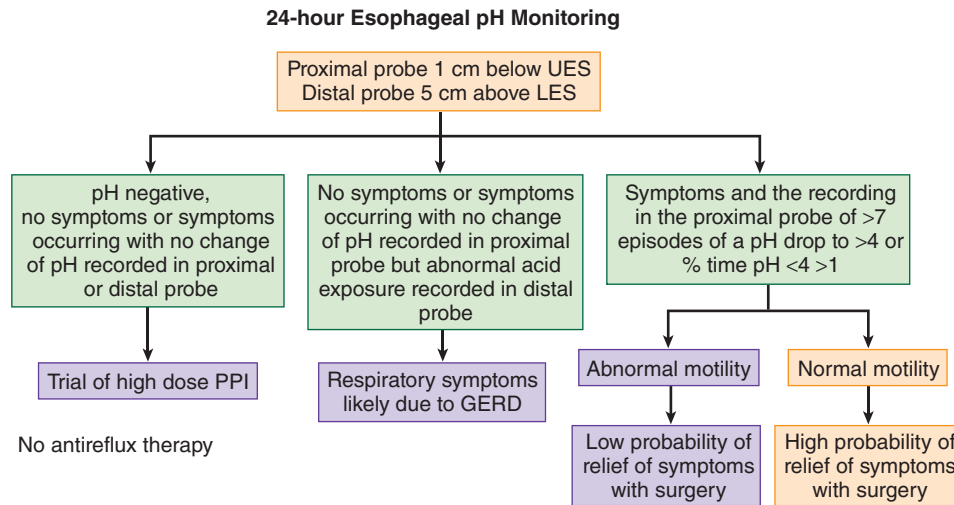


FIGURE 15-6 Correlation of symptoms with pH measurements predicts the likelihood that reflux symptoms are caused directly by acid reflux.

asthmatics may be secondary to the continued exposure of the aerodigestive tract by caustic nonacid gastric juice. This is supported by the literature indicating that antireflux surgery improves respiratory symptoms in nearly 90% of children and 70% of adults with asthma and GERD.<sup>35,44</sup> Additionally, improvements in pulmonary function were observed in around one-third of patients. A randomized controlled trial to compare surgical treatment with medical treatment for asthmatics with GERD demonstrated that fundoplication is the most effective approach to improve asthma symptoms and clinical course, although there was a minimal effect on pulmonary function, pulmonary medication requirement, or survival.<sup>35</sup> On the other hand, a potential benefit of antireflux surgery is to stabilize or delay the progression of end-stage lung disease such as idiopathic pulmonary fibrosis.<sup>45</sup>

## Metaplastic (Barrett's esophagus) and Neoplastic (Adenocarcinoma) Complications

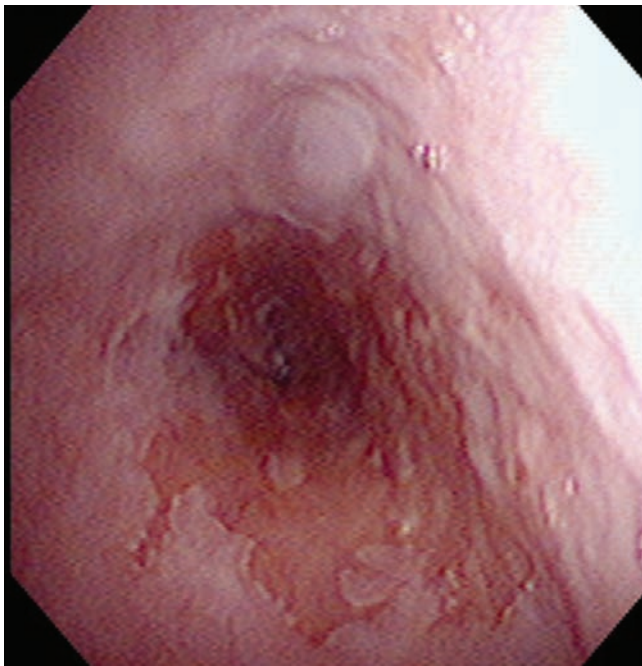*Barrett's esophagus* (BE) is defined as a columnar lined segment of esophagus of any length visible on endoscopy with a biopsy showing intestinal metaplasia with the presence of goblet cells (Fig. 15-7). Despite this classification, it is common to make the distinction between short-segment BE (<3 cm) and long-segment BE (≥3cm). Both short- and long-segment BE are considered pathologic and premalignant. The prevalence of BE in the general population has been reported to be 1–25%.<sup>46–50</sup> BE represents an end-stage form of GERD and carries a 30- to 50-fold increased risk of developing esophageal adenocarcinoma via the metaplasia-dysplasia-carcinoma sequence compared to people without BE.<sup>51</sup> The incidence of esophageal adenocarcinoma in patient with known BE may be as high as 0.5% per year.<sup>52–54</sup> BE is currently classified into four broad categories: (1) BE without dysplasia, (2)

indefinite for dysplasia, (3) low-grade dysplasia (LGD), and (4) high-grade dysplasia (HGD). Recent studies have identified a high prevalence of biopsy-proven intestinal metaplasia at an endoscopically normal appearing GEJ, which is termed *cardia intestinal metaplasia* (CIM). The significance and natural history of CIM remains unknown. However, CIM is currently considered a separate entity from BE, although the pathogenesis of CIM has been shown to be similar to reflux-induced BE.<sup>55</sup> Factors associated with the development of BE include abnormal bile reflux, hiatal hernia larger than 4 cm, a defective LES, and esophageal motility disorder.<sup>56</sup>

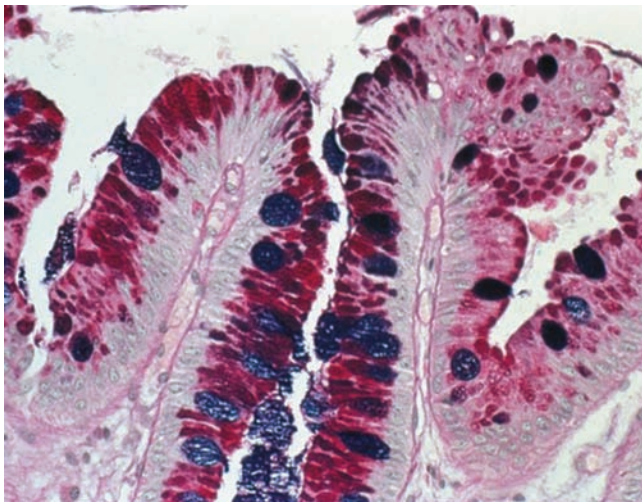
## Pathophysiology of Barrett's Metaplasia

The pathogenesis of BE begins with injury to the squamous epithelium of the distal esophagus, secondary to the repeated distension of the stomach with large volume fatty meals that result in effacement of the LES and exposure of the distal esophageal squamous epithelium to caustic gastric juice.<sup>10</sup> Continuous inflammatory injury in this area of the lower esophagus can cause permanent loss of the musculature of the LES, resulting in a mechanically defective LES. With further loss of the gastroesophageal barrier function, esophageal exposure worsens with resultant injury to progressively greater lengths of the squamous mucosa. Endoscopically, this injury can be observed as erosive esophagitis. The resulting columnar metaplasia that develops in a previous squamous-lined esophagus appears as a layer of mucus secreting columnar cells termed *cardiac mucosa*, which is a highly specific mucosa that arises to replace injured squamous epithelium and is believed to be an adaptive response to better tolerate exposure to gastric juice.<sup>57</sup> Eventually, cardiac mucosa can remain without changing, form parietal cells, or develop goblet cells to become intestinalized cardiac mucosa in the divergent differentiation pathways.<sup>58</sup>





A



B

**FIGURE 15-7** Barrett's esophagus. **A.** Endoscopic appearance. **B.** Microscopic findings.

## Screening and Surveillance

Although patients with the highest likelihood of BE are older (>50 years of age) Caucasian men with chronic reflux symptom,<sup>59</sup> screening for BE remains controversial because of the inability to predict who has BE prior to endoscopy, the lack of evidence-based criteria, the invasiveness and expense of standard sedated endoscopy, and the increasing documentation of a subgroup of patients with BE who lack reflux symptoms.<sup>60</sup> Surveillance endoscopy also

remains controversial because of the lack of randomized trials supporting its value.<sup>60</sup> However, previous retrospective studies have demonstrated that survival is statistically enhanced if cancer is detected by endoscopic surveillance rather than presenting with symptoms of obstruction.<sup>61,62</sup> Surveillance endoscopy should be performed in patients with documented BE and those who have reflux symptoms controlled with antisecretory therapy or antireflux surgery. The Seattle Protocol (biopsies with jumbo forceps in four quadrants, along every centimeter of metaplastic epithelium with extra biopsies taken from suspicious areas) has been widely accepted. It should be noted that these surveillance biopsies sample only a small fraction of the esophageal epithelium (possibility for sampling error) but are the only method available for recognizing dysplasia.<sup>63</sup> In patients with BE without dysplasia, we perform surveillance endoscopy every 3 years. The finding of low-grade dysplasia (LGD) requires a follow-up endoscopy within 6 months to ensure that more advanced disease is not present. If the 6-month surveillance is negative for high-grade dysplasia (HGD) or adenocarcinoma, yearly endoscopy is performed until no dysplasia is present on two consecutive annual endoscopies. The presence of HGD in flat mucosa should be confirmed by two experienced gastrointestinal pathologists and a subsequent endoscopy is performed within 3 months to reduce the chances of sampling error. Nodules within a field of HGD should undergo endoscopic resection to rule out malignancy. Patients with confirmed HGD should be counseled regarding the treatment options, including intensive surveillance, ablation therapies, and esophagectomy. Because the risk for the development of invasive cancer is 50% within 3 years of diagnosis, HGD is considered the threshold for therapeutic intervention. Patients with LGD or no dysplasia can also be a candidate for therapeutic intervention if they have excessive fear of the development of cancer or a significant family history of BE and esophageal cancer. In our practice, patients with nondysplastic BE who undergo antireflux surgery are also offered ablation of the involved segment of the esophagus.

## Management of Dysplastic BE

Given the fact that HGD has a high rate of progression to cancer and the prevalence of occult cancer in esophagectomy specimens of patients with a preoperative diagnosis of only HGD has been reported to be 38–73%,<sup>64–66</sup> esophagectomy has been recommended as a standard of care for HGD. However, esophagectomy is associated with significant mortality and morbidity even in experienced centers.<sup>67–69</sup> Additionally, esophagectomy may be unnecessary in the treatment of HGD because lymph node metastasis is unlikely (<5%).<sup>70–72</sup> In the recently updated guidelines by the American College of Gastroenterology, the authors state that “esophagectomy is no longer the necessary treatment response to HGD.”<sup>60</sup> Several endoscopic ablation therapies such as photodynamic therapy,<sup>73</sup> radiofrequency

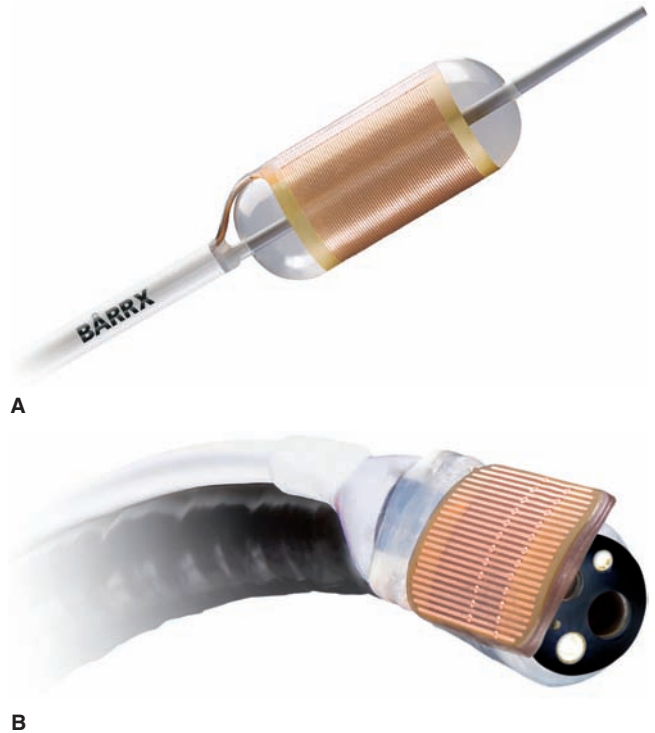


**TABLE 15-4: RISK FACTORS TO CONSIDER WHEN USING ENDOSCOPIC MANAGEMENT OF ESOPHAGEAL NEOPLASIA (BARRETT'S ESOPHAGUS WITH DYSPLASIA AND T1A ESOPHAGEAL ADENOCARCINOMA)**

Concurrent Cancer or Progression to Invasive Cancer	
Low-Risk	High-Risk
Unifocal (limited or focal), flat HGD	Multifocal HGD, HGD with nodules
Lymph Node Involvement	
Low-Risk	High-Risk
Type I, IIa <20 mm, IIb, IIc <10 mm	Type I, II >30 mm, type III
Well or moderately differentiated adenocarcinoma (grading G1/G2)	Poorly differentiated adenocarcinoma (grading G3), squamous cell carcinoma
Lesions limited to the mucosa (m)	Invasion into submucosal layer (sm)
No lymphovascular invasion	Presence of lymphovascular invasion

HGD, high-grade dysplasia.  
 Type I: polypoid type, II: flat type, IIa: flat, elevated, IIb: level with the mucosa, IIc: slightly depressed, III: ulcerated type.

ablation therapy,<sup>74</sup> and cryotherapy,<sup>75,76</sup> and endoscopic resection techniques such as endoscopic mucosal resection<sup>77</sup> and submucosal dissection<sup>78</sup> have been introduced. When considering these endoscopic therapies, the accurate clinical staging is critical to prevent an inappropriate endoscopic therapy on a patient with a high risk of invasive or metastatic disease (Table 15-4).<sup>79</sup> Currently, radiofrequency ablation therapy has been most commonly used since the results of a multicenter, sham-controlled trial was reported (Fig. 15-8).<sup>80</sup> In this trial, 127 patients with dysplastic BE were randomly assigned to treatment with radiofrequency ablation or a sham procedure. In patients with LGD, complete eradication of dysplasia occurred in 90.5% of those in the ablation group, as compared with 22.7% of those in the control group ( $p < .001$ ). In patients with HGD, complete eradication occurred in 81.0% of those in the ablation group, as compared with 19% of those in the control group ( $p < .001$ ). The rate of complications such as stricture and bleeding was 6%. This study demonstrated the safety and high efficacy of radiofrequency ablation therapy for dysplastic BE. Theoretically, antireflux surgery potentially prevents the progression to dysplasia and adenocarcinoma.<sup>81</sup> However, there have been no prospective randomized controlled studies documenting this supposition. Given the fact that BE results from GERD, antireflux surgery should be considered once BE is successfully treated.



**FIGURE 15-8** Radiofrequency ablation therapy. **A.** HALO<sup>360</sup> system, which is a balloon-based endoscopic ablation. **B.** HALO<sup>90</sup> system, which is a scope-mounted endoscopic ablation.

**PREOPERATIVE ASSESSMENT OF PATIENTS WITH GERD**

The purpose of esophageal objective testing is to determine if the patients' symptoms are due to gastroesophageal reflux events and to define the severity of GERD and esophageal motility that will impact on the selection of the type of surgical therapy. The esophageal objective testing includes barium esophagram, upper endoscopy, esophageal manometry, esophageal pH monitoring, and MII-pH. Gastric emptying studies may be considered in patients with suspicious symptoms such as bloating and nausea.

**Barium Esophagram**

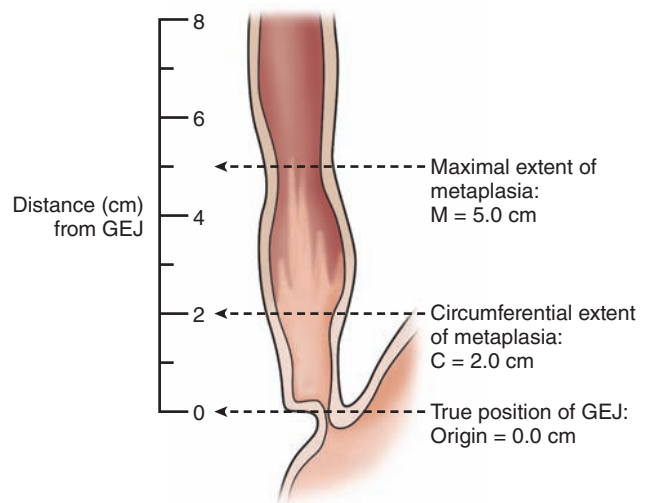
The *barium esophagram* is a test that is used to evaluate the entire anatomy of esophagus, including the esophageal body and both sphincters. This test is used to document the presence and size of a hiatal hernia, stricture severity and location, diverticula, esophageal emptying, and the presence of gastroesophageal reflux, both spontaneously and induced by provocative maneuvers. Esophageal motility can be assessed to some extent but is not the mainstay. Although the finding of reflux during the barium esophagram is thought by some to be a reliable indicator for GERD, the absence of roentgenographic evidence of reflux does not exclude disease.

## Upper Endoscopy

Upper endoscopy is performed to examine the mucosa from the esophagus to the second portion of duodenum and biopsies can be obtained if necessary. Although only 40–60% of patients with GERD have endoscopic evidence of esophagitis, upper endoscopy has an excellent specificity for this diagnosis when erosions are present. Upper endoscopy may identify unexpected findings such as BE, malignancy, a large hiatal hernia, eosinophilic esophagitis, and Zenker's diverticulum. The location of the diaphragmatic crura, the anatomic GEJ, and the squamocolumnar junction should be recorded.

Esophagitis is one of indicators of the presence of GERD. The severity of esophagitis is most commonly described by the Los Angeles classification<sup>82</sup>; LA grade A is defined by the presence of one or more mucosal breaks that are less than or equal to 5 mm in length. LA grade B is defined by the presence of one or more mucosal breaks that are longer than 5 mm. LA grade C represents a more advanced stage where one or more mucosal breaks are continuous between the tops of two or more mucosal folds, but that involve less than 75% of the esophageal lumen circumference. LA grade D classifies one or more mucosal breaks bridging the tops of folds and involving at least 75% of the esophageal lumen circumference. Nonerosive esophagitis is difficult to reliably recognize endoscopically and its presence may be confirmed based on the microscopic findings of mucosal infiltration with polymorphonuclear leukocytes (PMNs), lymphocytes, eosinophils, and the recently described balloon cells.<sup>83,84</sup> The extension of the relatively high mucosal papillae and hyperplasia of the basal zone are further evidence of mucosal injury. However, these microscopic findings do not prove the presence of increased exposure to gastric juice as they can occur from other forms of injury.<sup>85</sup>

Barrett's esophagus is suspected endoscopically when the squamocolumnar junction is located proximal to the anatomic GEJ, and the characteristic appearance of a "salmon pink color" mucosa is encountered in the lower esophagus. Multiple random biopsies should be performed, and the diagnosis of BE must be confirmed by the microscopic findings of columnar epithelium with intestinalization. To standardize the endoscopic findings of BE, the Prague classification system of circumferential (C) and maximal length (M) has been proposed (Fig. 15-9).<sup>86</sup> This system identifies the landmarks of the squamocolumnar junction, the GEJ, the extent of circumferential columnar lining, and the most proximal extension of the columnar mucosa excluding islands to determine the length of BE. However, proximal islands of columnar lining and ultrashort BE (<1 cm) are not included in this system. The presence of BE is diagnostic of GERD. Particular attention must be paid to the squamocolumnar junction, where a mass, ulcer, nodularity, or inflammatory tissue should be considered suspicious for malignancy and requires biopsy. Nodules encountered in a field of BE should be removed with endoscopic resection for histologic examination and deep staging.



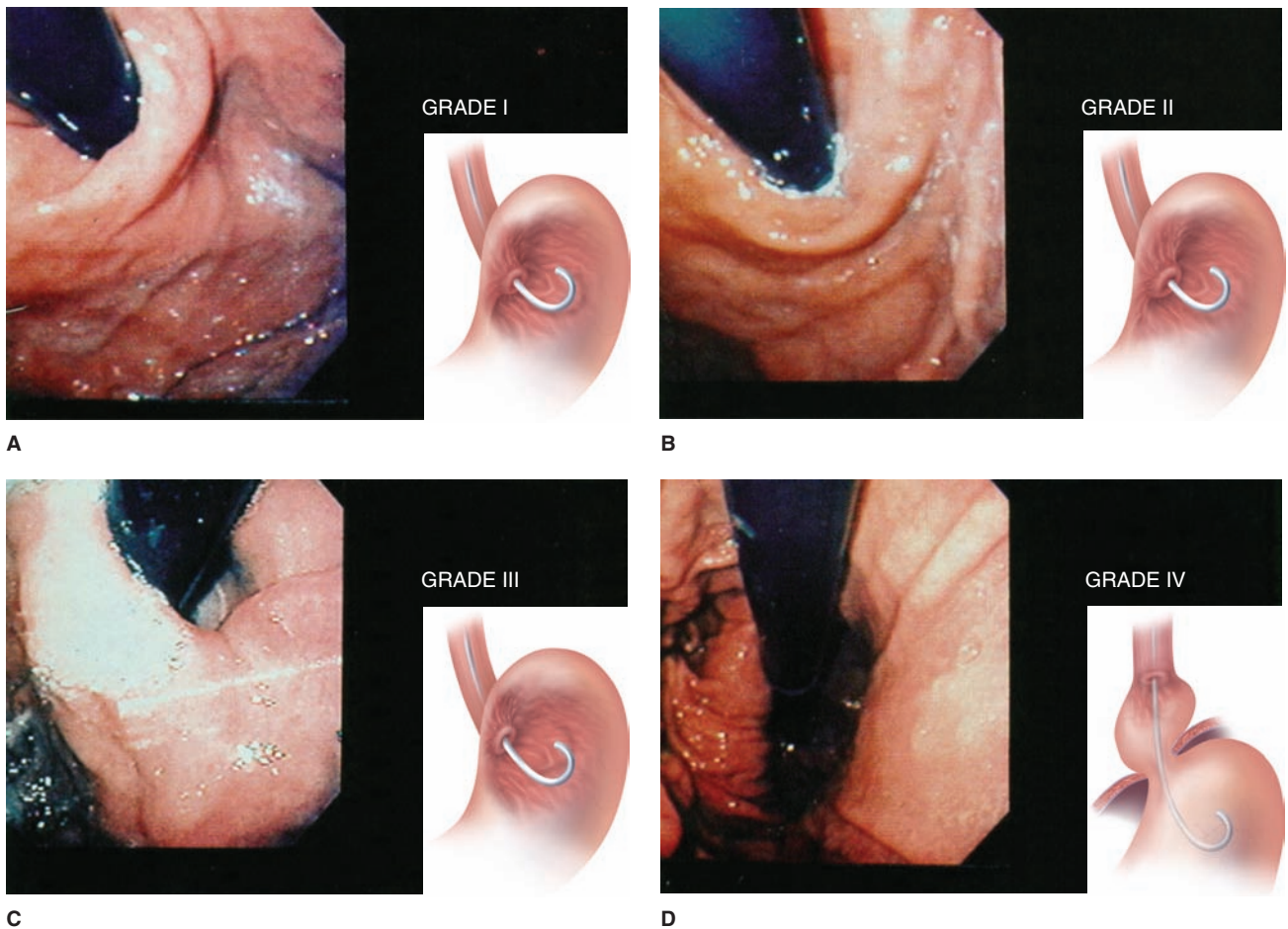
**FIGURE 15-9** Prague classification system to standardize Barrett's esophagus (BE). Diagrammatic representation of endoscopic BE showing an area classified as C2M5. C: extent of circumferential metaplasia; M: maximal extent of the metaplasia (C plus a distal "tongue" of 3 cm). (Reproduced from Sharma P, Dent J, Armstrong D, et al. The development and validation of an endoscopic grading system for Barrett's esophagus: the Prague C & M criteria. *Gastroenterology*. 2006;131:1392–1399.)

Abnormalities of the gastroesophageal flap valve (gastric portion of the LES) can be visualized by retroflexion of the endoscope. Hill and colleagues graded the appearance of the gastroesophageal valve from I to IV according to the degree of unfolding or deterioration of the normal valve architecture (Fig. 15-10).<sup>87</sup> The appearance of the valve correlates with the presence of increased esophageal acid exposure, occurring predominantly in patients with grades III and IV valves. Grade IV valve is compatible with a hiatal hernia. A hiatal hernia is endoscopically confirmed by the finding of a pouch lined with gastric rugal folds residing 2 cm or more proximal to the margins of the diaphragmatic crura. The presence of hiatal hernia is often associated with an increased esophageal exposure to gastric juice. When a paraesophageal hernia (PEH) is found, a gastric ulcer (Cameron ulcer) or gastritis within the hernia should be excluded. Patients who present with anemia and a PEH with Cameron's ulcers should also have colonoscopy to rule out blood loss from a colon cancer.

## Measurement of Gastroesophageal Reflux

### AMBULATORY pH MONITORING

Fuchs and colleagues demonstrated that 24-hour esophageal pH monitoring had a very high sensitivity and specificity (96%), as well as positive and negative predictive values



**FIGURE 15-10** Hill classification. **A.** Grade I flap valve appearance. Note the ridge of tissue that is closely approximated to the shaft of the retroflexed endoscope. It extends 3–4 cm along the lesser curve. **B.** Grade II flap valve appearance. The ridge is slightly less well defined than in grade I and it opens rarely with respiration and closes promptly. **C.** Grade III flap valve appearance. The ridge is barely present, and there is often failure to close around the endoscope. It is nearly always accompanied by a hiatal hernia. **D.** Grade IV flap valve appearance. There is no muscular ridge at all. The gastroesophageal valve stays open all the time, and squamous epithelium can often be seen from the retroflexed position. A hiatal hernia is always present. (Reproduced from Hill LD, Kozarek RA, Kraemer SJ, et al. The gastroesophageal flap valve. In vitro and in vivo observations. *Gastrointest Endosc.* 1996;44:541.)

(96%), with an overall accuracy of 96%.<sup>19</sup> Since this study was reported, 24-hour esophageal pH monitoring has been a gold standard for the diagnosis of GERD. It is particularly important that preoperative pH testing be performed off medication in patients being considered for antireflux surgery to evaluate the symptom correlation with reflux events and the severity of the disease. Antisecretory medications should be discontinued 10–14 days prior to the study. An abnormal pH score with good symptom correlation has been shown to be the most important predictor of a successful outcome following antireflux surgery.

Despite being the most reliable technique for quantifying acid exposure in the distal esophagus, catheter-based 24-hour ambulatory pH monitoring has significant methodological limitations. The nasally passed pH electrode is uncomfortable and can lead patients to minimize or avoid reflux-provoking stimuli such as diet and physical activity,

thus potentially resulting in a false-negative result. In addition, esophageal shortening during deglutition results in movement of the pH sensor closer to LES, thus potentially leading to a false-positive result.<sup>6,88</sup> In addition, patients with atrophic gastritis may be achlorhydric and have non-acid reflux that is not detected with pH testing. The recent development of a wireless pH capsule that can be implanted in the esophagus and transmit pH data to an external receiver has significantly changed patient tolerability and capability of performing extended recording periods of 2–4 days.<sup>8,89</sup> In addition, extended pH monitoring using wireless technology may improve the detection of reflux and increase the sensitivity of pH testing. Several studies have demonstrated that increasing the recording period from 24 to 48 hours results in an improvement in sensitivity of pH monitoring by 10–26%.<sup>7,8</sup> Several studies have also consistently demonstrated higher acid exposure values on day 2



compared to day 1 with the wireless pH capsule.<sup>10</sup> The pH probe should be correctly placed 5 cm (the capsule is placed 6 cm proximal to the LES or endoscopically measured anatomic GEJ) above the proximal border of the LES. This location minimizes potential noise from proximal stomach acid exposure, at the expense of decreased sensitivity.

Results of 24-hour pH monitoring are expressed in the form of a DeMeester score.<sup>12</sup> Six variables are measured and factored in to this composite score:

- The total number of reflux events
- The percentage of total time spent in an acid environment with a pH less than 4
- The percentage of upright time spent in an acid environment with a pH less than 4
- The percentage of supine time spent in an acid environment with a pH less than 4
- The duration of the longest reflux episode
- The number of reflux episodes lasting more than 5 minutes.

The first four of these factors evaluate the frequency and severity of reflux, and the last two assess the ability of the esophagus to clear acid. Normal values for these six components were determined from 50 asymptomatic control subjects. The mean values for esophageal acid exposure and 95th percentile results are shown in Table 15-5.<sup>12</sup>

### COMBINED MULTICHANNEL INTRALUMINAL IMPEDANCE-pH MONITORING

Combined multichannel intraluminal impedance-pH (MII-pH) detects the intraesophageal bolus movement on the basis of a change in the resistance to electric current across adjacent electrode pairs positioned in a serial manner along a catheter. Multiple electrodes positioned along the axial length of the impedance catheter can determine the proximal extent of a reflux event. Air has a high impedance, whereas liquid has a greater conductivity and a lower impedance (Fig. 15-11). Based on this, it is capable of differentiating antegrade (swallow) from retrograde (reflux)

bolus transit regardless of the composition of reflux (ie, liquid, gas, mixed) (Fig. 15-12). A pH monitor incorporated into the impedance catheter allows for simultaneous detection of both acid and nonacid contents. The configuration of impedance catheters can be modified depending on what type of reflux is targeted (ie, laryngopharyngeal reflux). MII-pH is a transnasal catheter-based system and the recording has been limited to 24 hours. As a result of the ability to detect, localize, and classify reflux events as acid, weakly acid, or nonacid, MII-pH has been posited as the future standard for reflux detection and monitoring, especially in patients with persistent typical and/or atypical GERD symptoms despite PPI therapy.<sup>27,33</sup> However, the clinical utility of MII-pH is still being investigated.<sup>25</sup>

## ASSESSMENT OF ESOPHAGEAL BODY AND LES FUNCTION

### Esophageal Manometry

Esophageal manometry is the most accurate method to assess the coordination and pressure of the lower esophageal sphincter (LES) and the esophageal body. Patients with GERD may have manometric findings of a defective LES or impaired esophageal motility. Manometry is an important component in the preoperative workup of patients who are candidates for antireflux surgery. First, this form of testing excludes achalasia that may be occasionally misdiagnosed as GERD. Second, esophageal manometry characterizes the esophageal motility, and this information will be used to determine the surgical approach (Nissen or partial fundoplication). Finally, manometry enables measurement of the precise location of the LES for accurate pH probe placement.

Esophageal manometry used to be performed using water-perfused catheters with lateral side holes attached to transducers outside the body. Usually a train of five pressure transducers are bound together with the transducers placed at 5 cm intervals from the tip and oriented radially at 72 degrees from each other around the circumference of the catheter. The recent introduction and clinical application of high-resolution manometry (HRM) has made esophageal manometry simple, fast, and accurate. The basic concept of HRM is that by vastly increasing the number of pressure recording sensors and decreasing the spacing between them, one can monitor intraluminal pressure without spatial gaps between recording sites or temporal gaps between sampling times. Consequently, the morphology of the gastroesophageal junction pressure and esophageal peristalsis can be dynamically monitored in real time and a consistent fashion with normal respiration and with minimal movement-related artifact. HRM is performed using a solid-state manometric assembly with 36 circumferential sensors spaced at 1 cm intervals (O.D. 4.2 mm) (Sierra Scientific Instruments Inc., Los Angeles, CA). This catheter allows each of the 36 pressure sensing elements to detect pressure over a length of 2.5 mm in each of

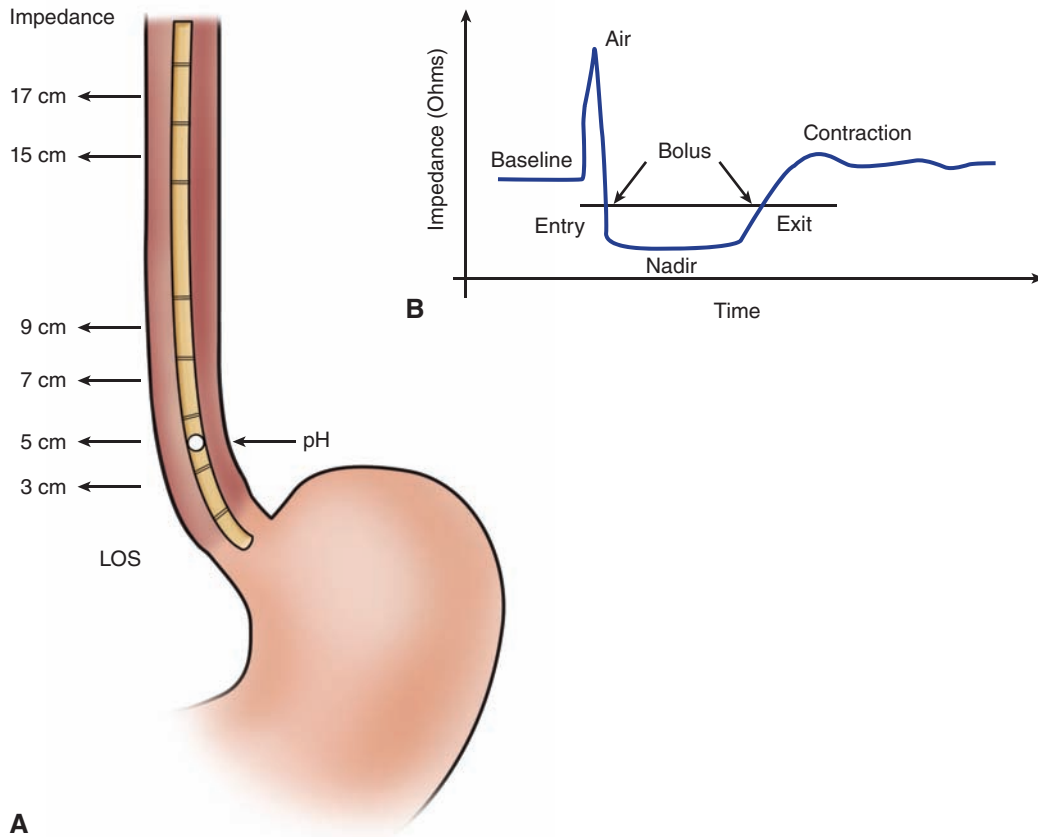
**TABLE 15-5: NORMAL VALUES FOR ESOPHAGEAL EXPOSURE TO pH <4 (N = 50)**

Component	Mean	SD	95%
Total time	1.51	1.36	4.45
Upright time	2.34	2.34	8.42
Supine time	0.63	1.0	3.45
No. of episodes	19.00	12.76	46.90
No. >5 min	0.84	1.18	3.45
Longest episode	6.74	7.85	19.80

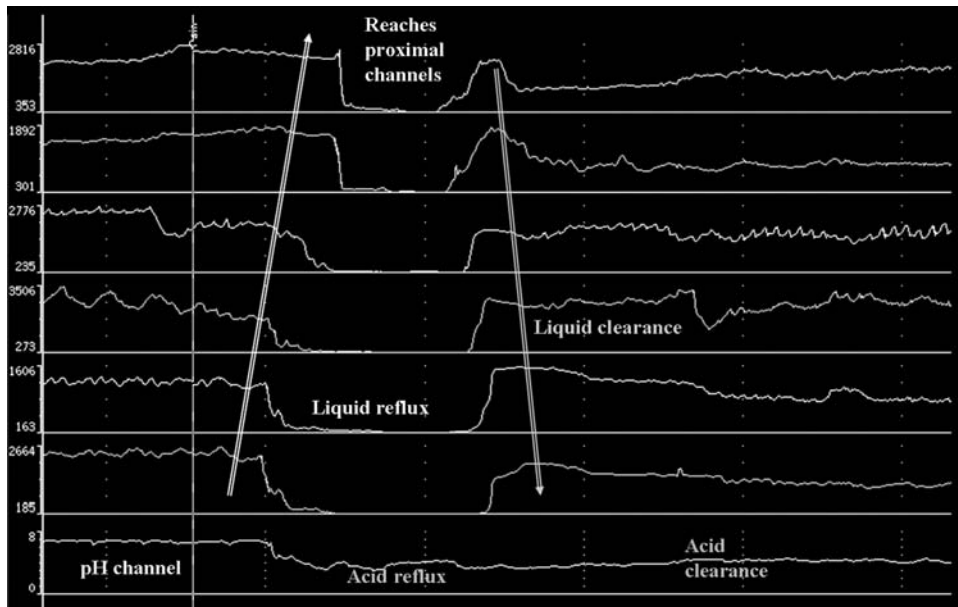
SD, standard deviation.

Reproduced, with permission, from DeMeester TR. Gastroesophageal reflux disease. In: Moody FG, Carey LC, et al, Scott Jone R, eds. *Surgical Treatment of Digestive Disease*. Chicago, IL: Year Book Medical; 1990:81.





**FIGURE 15-11** Combined multichannel intraluminal impedance-pH (MII-pH). **A.** Configuration of an impedance catheter. **B.** Structure of a typical appearance of a bolus. As a food bolus propagates down the esophagus, it pushes a pocket of air distally (small upward spike in impedance); as the bolus bridges the electrode pair, conductivity is increased and impedance drops; when the bolus passes the electrode pair, the resting impedance is restored.



**FIGURE 15-12** Typical tracing of a retrograde bolus movement (reflux) on multichannel intraluminal impedance (MII-pH). As the bolus bridges the electrode ring sets, the impedance decreases. The proximal extent of the bolus is traced as it crosses proximally located electrode pairs within the esophagus.

12 radially dispersed regions. The vast amount of data generated by these sensors is then processed and presented in traditional linear plots or as a visually enhanced spatiotemporal tracing that is readily interpreted. This enhanced spatial resolution allows real-time monitoring of contractile activity over the entire esophageal length and can be coupled with impedance measurement so as to determine whether pressure readings and bolus movement correlate (Fig. 15-13).

An incompetent LES is defined based on the comparison study between 50 healthy volunteers and patients with symptomatic GERD. An LES is considered defective by having one or more of the following characteristics: an average LES pressure of less than 6 mm Hg, an average length exposed to the positive-pressure environment in the abdomen (intra-abdominal length) of 1 cm or less, and an average overall sphincter length of 2 cm or less. *Achalasia* is defined by the manometric findings of a hypertensive, nonrelaxing LES with esophageal aperistalsis (100% failed or simultaneous contractions). *Ineffective esophageal motility* is defined by manometric findings of either failed peristalsis of greater than 30% or mean wave pressure of less than 30 mm Hg. *Nutcracker esophagus* is defined by peristaltic contractions that exceed 180 mm Hg within the smooth muscle

portion of the esophagus. *Diffuse esophageal spasm* is defined by greater than 20% simultaneous contractions. Depending on the integrity of esophageal peristalsis, the antireflux procedure can be tailored to include either a “floppy” Nissen fundoplication or partial fundoplication. In our practice, patients with ineffective or failed peristalsis undergo a Dor partial fundoplication.

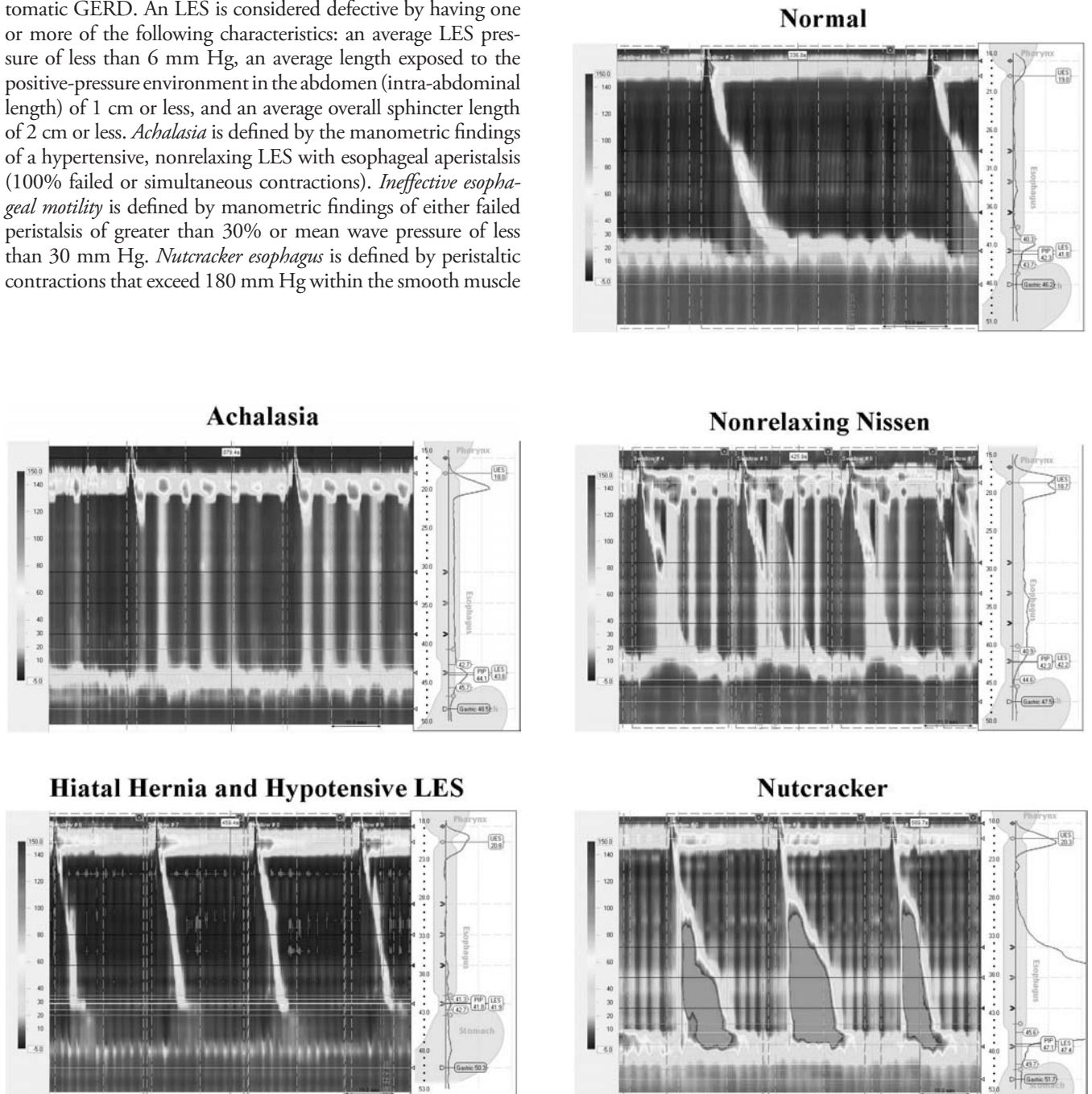


FIGURE 15-13 High-resolution manometry. Manometric appearances of normal peristalsis, achalasia, hiatal hernia and hypotensive lower esophageal sphincter (LES), nonrelaxing LES after Nissen, and nutcracker esophagus.

## GASTRIC EMPTYING

Delayed gastric emptying causes bloating, dyspepsia, postprandial nausea, and abdominal distension. Previous studies have demonstrated that GERD is associated with delayed gastric emptying in approximately 40% of patients, but the precise role of gastric emptying in the pathogenesis of GERD is unclear.<sup>90</sup> It has been established that fundoplication improves gastric emptying by reducing the storage capacity of the fundus.<sup>91–93</sup> However, persistent delayed gastric emptying can cause an unsatisfactory outcome after antireflux surgery as fundoplication itself can lead to bloating. Therefore, a gastric emptying study should be considered for candidates of antireflux surgery with suspicious symptoms such as nausea, vomiting, and bloating. The gastric emptying study is performed with a radionuclide-labeled meal. Emptying of solids and liquid can be assessed simultaneously by having both phases marked with different tracers. After ingestion of a labeled standard meal, gamma counter images of the stomach are obtained at 5- to 15-minute intervals for 1.5–2 hours. After collection of decay, the counts in the gastric area are plotted as a percentage of the total counts at the beginning of the imaging. The *gastric emptying half-time* ( $T_{1/2}$ ) is defined as the time required for 50% of the meal to exit the stomach. Patients with a  $T_{1/2}$  more than 90 minutes are considered to have delayed gastric emptying. It has been suggested that patients with a  $T_{1/2}$  of more than twice the upper limit of normal ( $T_{1/2} > 180$  minutes) undergo pyloroplasty at the time of fundoplication.<sup>91</sup> However, the management of patients with a  $T_{1/2}$  between the upper limit of normal and twice the upper limit of normal (90–180 minutes) remains controversial.<sup>94</sup> Postoperative bloating can be treated by reoperation and pyloroplasty, endoscopic dilation of the pylorus, or endoscopic botulinum toxin injection.

## SURGICAL THERAPY FOR GERD

### History of the Evolution of Antireflux Surgery

The first case of successful antireflux surgery was reported by Rudolph Nissen in 1956.<sup>95</sup> In this case, Nissen enveloped the lower esophagus with the gastric fundus over a large intraesophageal dilator. Subsequently, Nissen and Rossetti suggested that only the anterior wall of the stomach be wrapped around the lower esophagus.<sup>96</sup> Subsequently, the procedure has been modified in many ways. To avoid postoperative “gas bloat” syndrome, the partial anterior and posterior fundoplication techniques, in which the fundus encircles 270 degrees of the esophageal circumference, were developed and reported by Jacques Dor in 1962<sup>41</sup> and by Andre Toupet in 1963,<sup>43</sup> respectively. Donahue et al first described the “floppy” Nissen technique, in which the fundoplication was performed over a large-diameter esophageal dilator.<sup>97</sup> Then DeMeester et al further modified the operation by using a large dilator, limited the length of the fundoplication (2 cm),

and completely mobilized the gastric fundus by division of the short gastric vessels.<sup>98</sup> Since the first description of successful laparoscopic Nissen fundoplication by Dallemagne et al in 1991, the laparoscopic approach has been widely accepted.<sup>42</sup> Several randomized trials have established that the laparoscopic approach achieves equivalent results with regard to subjective and objective resolution of GERD, with less postoperative pain, a shorter recovery period, and lower complication rate.<sup>99</sup>

### Patient Selection for Surgery

Most patients have a relatively benign form of GERD that is responsive to life style and dietary modifications and medical therapy, and do not need surgical treatment. The mainstay of therapy for GERD is medical management. PPI therapy is highly effective, resulting in relief of symptoms and healing of esophagitis in more than 80% of patients.<sup>44</sup> However, most patients require lifelong treatment and discontinuation of therapy results in symptomatic relapse within 6 months in approximately 90% of patients with esophagitis and 75% of patients with NERD.<sup>55</sup> Additionally, it should be noted that PPI therapy does not reduce the esophageal injury associated with alkaline reflux and never addresses the mechanical incompetence of the barrier such as a defective LES and a hiatal hernia. A structurally defective LES is the most important factor predicting failure of medical therapy. Although the presence of a failed LES and esophagitis has been the primary indications for surgical treatment, antireflux surgery should be considered in any symptomatic patients with a documented GERD by pH testing or MII-pH regardless of presence of esophagitis and/or a defective LES. This is particularly true in patients who have PPI-responsive symptoms or persistent symptoms despite maximal PPI therapy. It is important to note that a good response to PPI therapy is a good indicator of the excellent outcome following antireflux surgery.

Young patients, especially women, with documented GERD are also excellent candidates for surgical treatment. They usually require lifelong medical therapy to control their GERD symptoms. The cost-effectiveness of surgical versus medical therapy in patients with GERD remains controversial.<sup>51,59,100</sup> Recent studies have suggested that long-term usage of PPI potentially causes impaired calcium absorption and osteoporosis, which may be associated with an increased risk of fractures.<sup>57</sup> This is particularly important for women.<sup>82</sup> Patients with esophageal stricture are excellent candidates for surgical treatment.<sup>101,102</sup> Esophageal stricture is often associated with a structurally defective LES and impaired esophageal contractility. Before proceeding with antireflux surgery, malignancy and a drug-related etiology of the stricture should be excluded, and the stricture should be dilated enough to resolve dysphagia. Esophageal manometry is then performed to evaluate the esophageal motility prior to laparoscopic fundoplication.

Patients with BE commonly have a severe structural defect of the LES and impaired esophageal motility.<sup>56</sup> The

presence of BE indicates the presence of GERD. In addition, BE may progress to adenocarcinoma. Antireflux surgery may prevent the development of adenocarcinoma, although there has been no prospective study performed that supports this supposition because of an extremely low incidence of adenocarcinoma arising from BE and the resultant inability to adequately power a comparison trial. BE should be first treated, followed by antireflux surgery. If BE with high-grade dysplasia and/or intramucosal carcinoma is found on biopsy specimens, an esophageal resection should be considered.

Patients with extraesophageal symptoms such as cough, aspiration, asthma, and progressive pulmonary fibrosis can also be good candidates for antireflux surgery. Before proceeding to surgical treatment, it is extremely important to document the correlation between reflux events and symptoms. Laryngopharyngeal reflux, a variant of GERD, may be associated with the development of extraesophageal symptoms.<sup>83</sup> Because the clinical presentation of laryngopharyngeal reflux is nonspecific and there has been no way to detect laryngeal events, it has been extremely difficult to demonstrate causality in the clinical setting. MII-pH could be an effective tool to make a diagnosis of laryngopharyngeal reflux.

## Principles of Surgical Therapy

The primary goal of antireflux surgery is to safely restore the structurally defective gastroesophageal valve, to prevent its shortening with gastric distention while preserving the patient's ability to swallow normally. To achieve this goal, several principles regarding the reconstruction of the valve should be considered. First, the operation should restore the adequate pressure and length of the distal esophageal sphincter to prevent reflux from the stomach. The effect is to augment sphincter characteristics and prevent unfolding of the valve in response to gastric distention. In normal swallowing, a vagally mediated relaxation of the distal esophageal sphincter and the gastric fundus occurs.<sup>85</sup> To achieve adequate relaxation of the sphincter, only the gastric fundus should be used to create the fundoplication. The fundoplication should be placed around the distal esophagus and not the proximal stomach because it does not relax well with swallowing and has poor peristalsis. A deep groove on the surface of the fundoplication indicates that the repair is too tight and there should be no hesitation to take the repair down and begin over. Intraoperative injury to the vagal nerves should be avoided because it may cause the failure of sphincter relaxation with deglutition as well as delayed gastric emptying. Second, the fundoplication should not increase the resistance of the relaxed sphincter to a level that exceeds the peristaltic pressure of the esophageal body. Therefore, preoperative esophageal manometry is important to evaluate the esophageal motility. A Nissen fundoplication should be no longer than 3 cm and created over a 60F bougie. After a circumferential mediastinal esophageal mobilization resulting in 3 cm of tension-free intra-abdominal esophageal length,

a posterior crural closure is performed to enable easy passage of the esophageal dilator. If adequate esophageal length cannot be achieved secondary to shortening of the esophagus, wedge gastroplasty as a lengthening procedure should be considered. Finally, an intraoperative endoscopic evaluation of the created valve is valuable to confirm the hallmarks of a successful fundoplication (Fig. 15-14). It should be noted that the initial fundoplication has the best chance to achieve the successful outcome.

## Procedure Selection

A laparoscopic approach has been widely accepted, and the laparoscopic Nissen fundoplication is the procedure of choice for a primary antireflux surgery in the majority of patients with good esophageal motility and normal esophageal length. Previous prospective studies and randomized controlled studies have shown that the Nissen fundoplication is an effective antireflux surgery with minimal side effects, which provides long-lasting relief of reflux symptoms in over 90% of patients. Patients with a severe esophageal motility disorder defined by greater than 50% failed swallows, low peristaltic pressure, or an aperistaltic esophagus are best treated with a partial fundoplication to avoid the excessive outflow resistance.

## PRIMARY ANTIREFLUX REPAIRS

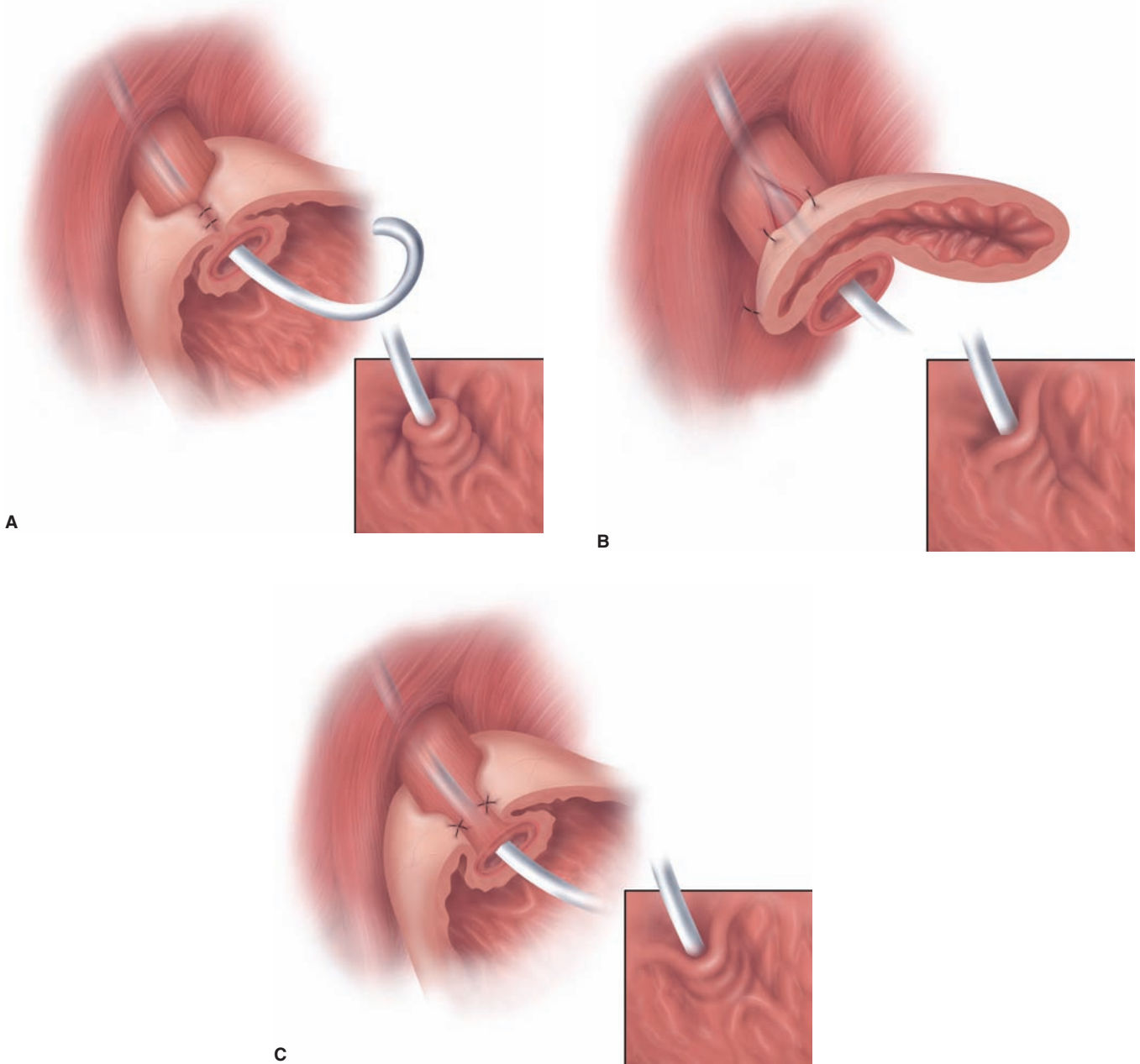
### Laparoscopic Nissen Fundoplication

The laparoscopic Nissen fundoplication is the most commonly performed antireflux procedure in the United States. The key points of this approach are the following:

- Preservation of both vagal nerves
- Complete mobilization of the gastric fundus by dividing the short gastric and posterior gastric vessels
- Extensive mediastinal dissection to obtain 3 cm length of tension-free intra-abdominal esophagus
- Creation of a large retroesophageal space
- Posterior crural closure
- Creation of a 2.5-cm "floppy" fundoplication around over a 60F bougie

The patient is placed supine and in a split-legged position, and the surgeon stands between the legs. A five-port technique is used: four 5-mm and one 12-mm ports are used. A 5-mm, 30-degree laparoscope is introduced through the 5-mm port placed in the left upper quadrant. All secondary ports should be placed under laparoscopic visualization. The second port (12 mm), which is used for the surgeon's right hand instruments, is placed 12 cm from the tip of the xiphoid process and 2 cm below the left costal margin. The third port (5 mm), which serves as the primary port site for the assistant, is placed





**FIGURE 15-14** Endoscopic appearance of a re-created valve. **A.** Nissen fundoplication. **B.** Dor fundoplication. **C.** Toupet fundoplication. The left panels represent oblique section of each fundoplication. The right panels represent the endoscopic appearance of the corresponding valves. Endoscopy shows a “stacked coils” appearing nipple valve in Nissen fundoplication, “S”-shaped flap valve in Dor fundoplication, and an omega-shaped valve in Toupet fundoplication.

within the left anterior axillary line along the costal margin. The fourth port (5 mm) is created immediately to the left of the xiphoid process for placement of the Nathanson liver retractor (Cook Medical, Bloomington, IN) that is used to expose the hiatal opening and gastrohepatic omentum. The fifth port (5 mm), which is for the surgeon’s left hand instruments, is placed inferior to the right costal margin immediately to the right of the falciform ligament (Fig. 15-15).

The first step in the hiatal dissection is opening the gastrohepatic omentum and then extending to the right and left crura to expose the esophagus circumferentially at the hiatus. In up to 12% of patients, an accessory left hepatic artery, originating from the left gastric artery, will accompany the hepatic vagal branch. This vessel should be preserved or, when necessary, divided between clips. The relationship between the division of hepatic vagal branch and the dysfunction of gallbladder

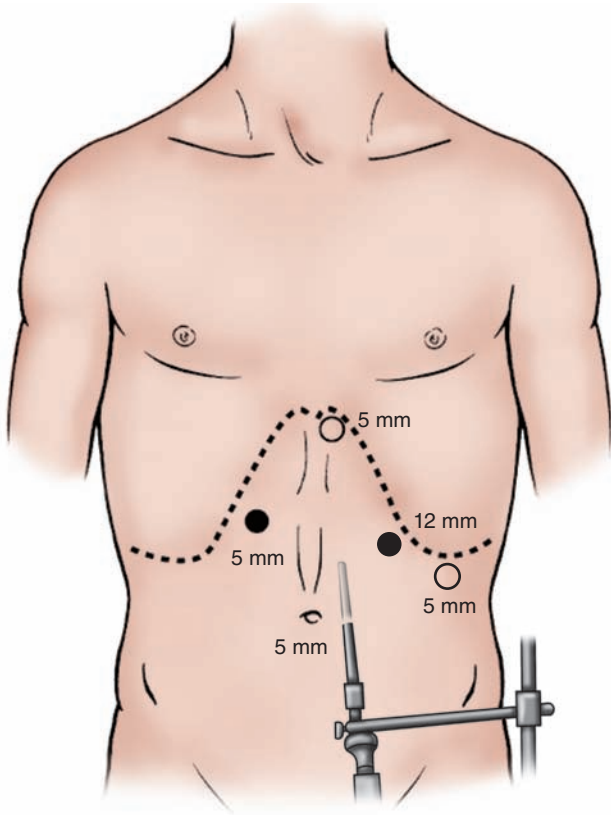


FIGURE 15-15 Patient position and port placement.

has been suggested. However, the benefit of preservation of the hepatic vagal branch remains controversial.<sup>86,103</sup> The gastrophrenic attachments over the anterior aspect of the left crus are divided, and this dissection is further extended so as to mobilize the angle of His and divide the highest short gastric vessels (Fig. 15-16). The phrenoesophageal ligament is then

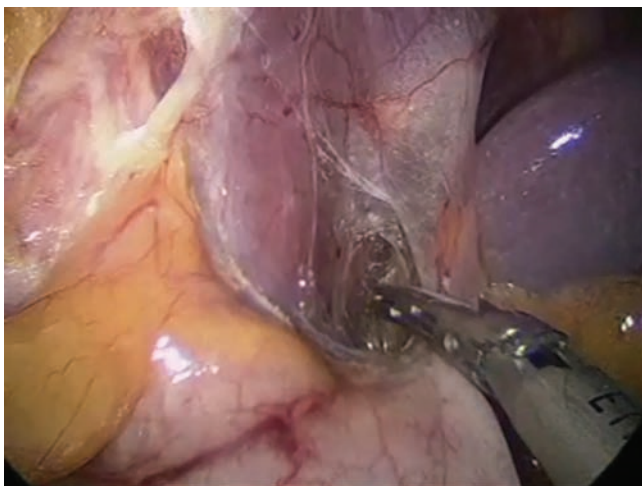


FIGURE 15-16 Division of the gastrophrenic attachments of the apex and pillar of the left crus anteriorly, angle of His, and highest short gastric vessels.

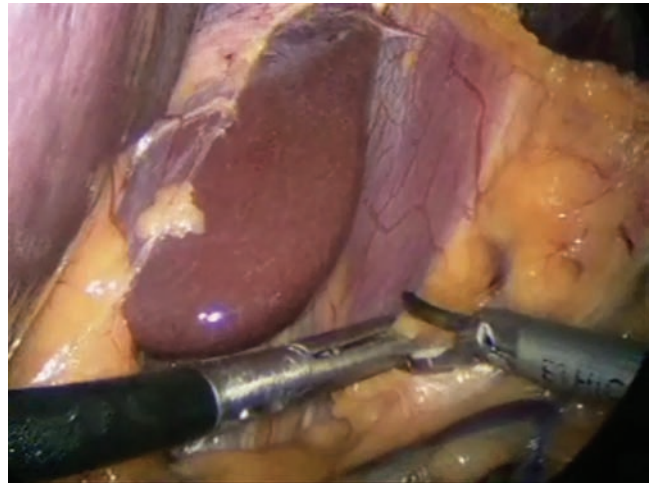


FIGURE 15-17 Dissection of the phrenoesophageal ligament.

opened at the right crus, and the dissection between the crus and esophagus is carried anteriorly (Fig. 15-17). During this maneuver, both anterior and posterior vagus nerves should be identified and preserved (Fig. 15-18). The hiatal dissection is then carried posteriorly until the union of the right and left crura is identified and the beginning of the posterior esophageal window is created (Fig. 15-19). Although the necessity of dividing the short gastric vessels remains controversial,<sup>104,105</sup> several studies have suggested that incomplete mobilization of the fundus can cause postoperative dysphagia.<sup>106</sup> Division of the short gastric vessels begins along the greater curvature of the stomach, at the level of the lower pole of the spleen (Fig. 15-20). After division of short gastric vessels, the posterior stomach is exposed, and the posterior pancreaticogastric fold and posterior gastric vessels are divided to achieve further mobilization of the fundus and expose the base of the left crus

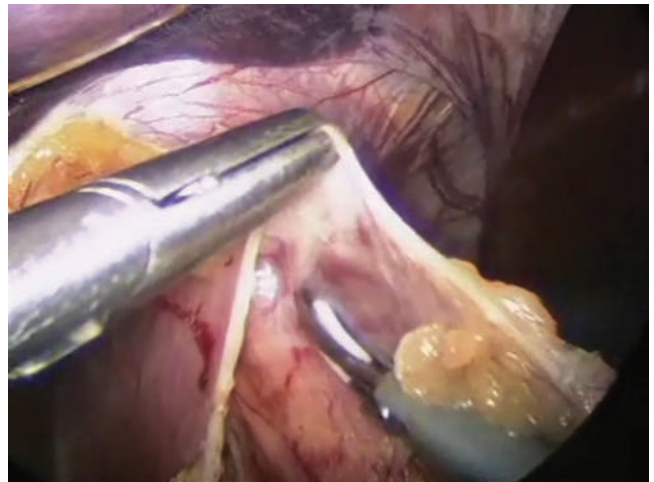


FIGURE 15-18 Identification of the anterior vagus nerve.

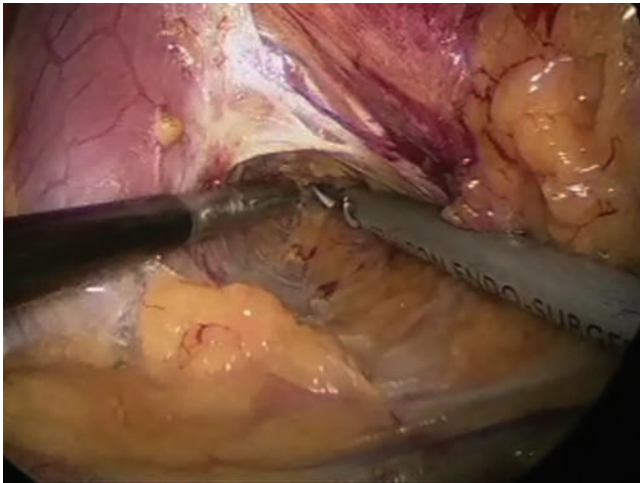


FIGURE 15-19 Beginning of the esophageal posterior window.

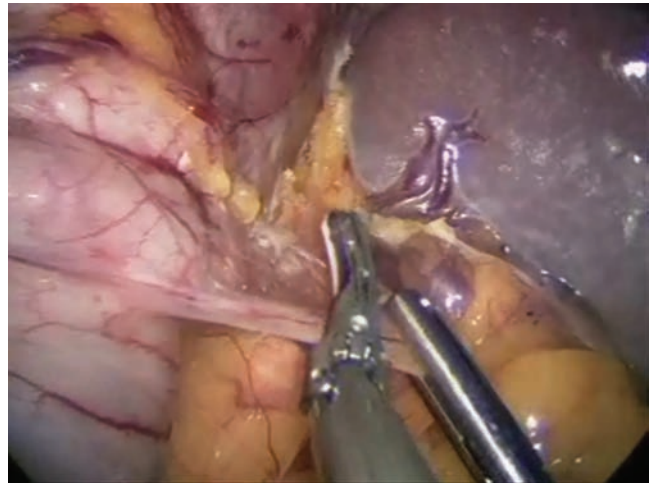


FIGURE 15-21 Division of the posterior gastric vessels.

(Fig. 15-21). A posterior esophageal window is then completely established from the right side, and a Penrose drain is inserted behind the esophagus and the ends secured together anterior to the esophagus with several clips. The Penrose drain facilitates retraction of the esophagus during the mediastinal dissection (Fig. 15-22).

An extensive mediastinal dissection of the esophagus is performed circumferentially until at least 3.0 cm of distal esophagus remains within the abdomen in a tension-free fashion (Fig. 15-23). Attention must be paid to preserve both vagus nerves. If an adequate length of intra-abdominal esophagus cannot be obtained even after extensive mediastinal dissection, a lengthening procedure such as a stapled-wedge Collis gastroplasty should be considered.<sup>107</sup> During the mediastinal dissection, attention should be paid to avoid injury of

both vagus nerves and mediastinal pleura (Fig. 15-24). If the pleural cavity is accidentally opened, tension pneumothorax can be prevented by transabdominal insertion of a 14F red rubber catheter into the affected pleural space. At the end of the procedure, the pleural space is evacuated with a Valsalva maneuver and the catheter is removed. At the completion of mediastinal dissection, the diaphragmatic crura are approximated using interrupted 0 nonabsorbable suture. The closure should be snug, but not tight, around the esophagus and enable facile passage of the bougie (Fig. 15-25).

The fundus of the stomach is brought through the posterior esophageal window. By grasping the greater curvature of the fundus on either side of the esophagus, a “shoeshine maneuver” is performed to ensure that there is a proper orientation of the fundus without twisting or torsion (Fig. 15-26). At

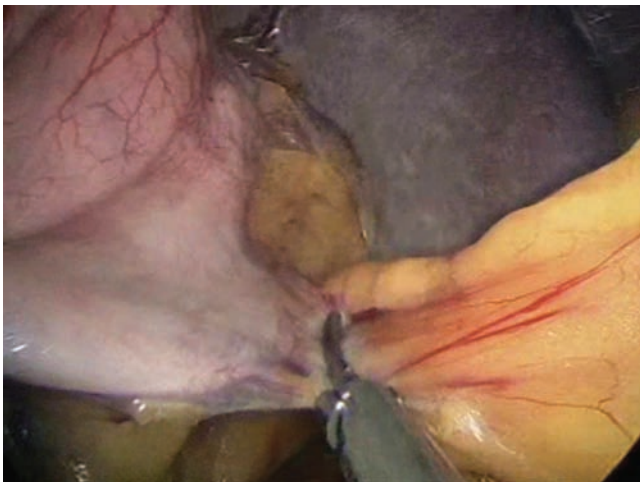

FIGURE 15-20 Division of the short gastric vessels.

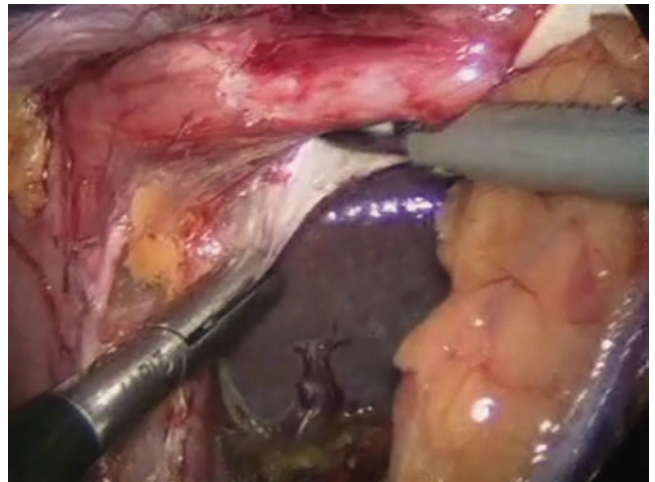
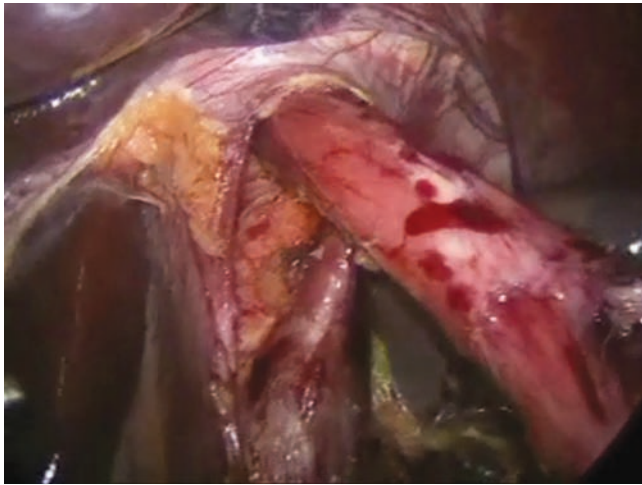


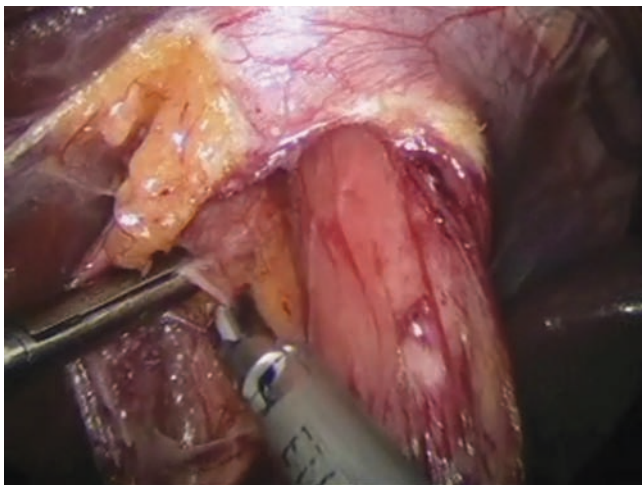FIGURE 15-22 Creation of a large retroesophageal space.



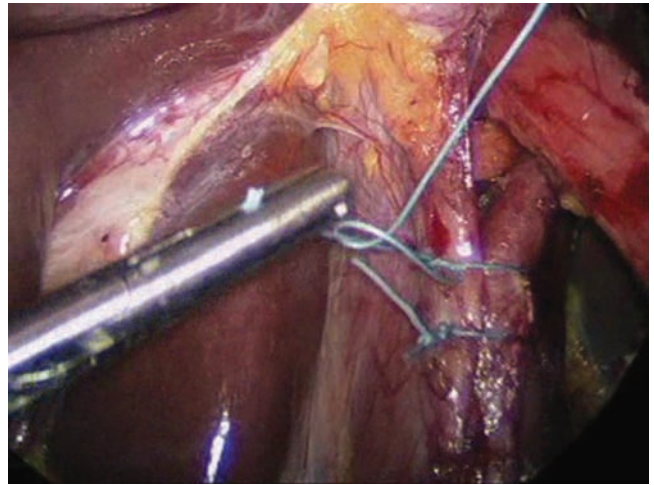


**FIGURE 15-23** At the completion of extensive mediastinal dissection, an adequate tension-free intra-abdominal esophageal length was achieved.

At this point, an esophageal dilator (60F) is inserted and guided along the lesser curvature of the stomach under laparoscopic visualization. A 2.5-cm fundoplication is then performed around the end of esophagus with 0 nonabsorbable sutures that incorporate the right and left limbs of the fundoplication along the greater curvature. At this point, an instrument is advanced through the fundoplication toward the diaphragm to ensure the fundoplication is not too tight. Eventually, the fundoplication is secured with 3 nonabsorbable, unpledgeted sutures. Sutures should incorporate a full thickness of the stomach and partial thickness of the anterior esophageal wall, with care taken to avoid placement into the anterior vagus nerve (Fig. 15-27). The dilator is then removed and the intraoperative upper endoscopy is performed to confirm the proper orientation of the valve.



**FIGURE 15-24** Mediastinal dissection. Attention must be paid to preserve the vagal trunks and prevent the injury to mediastinal pleura.



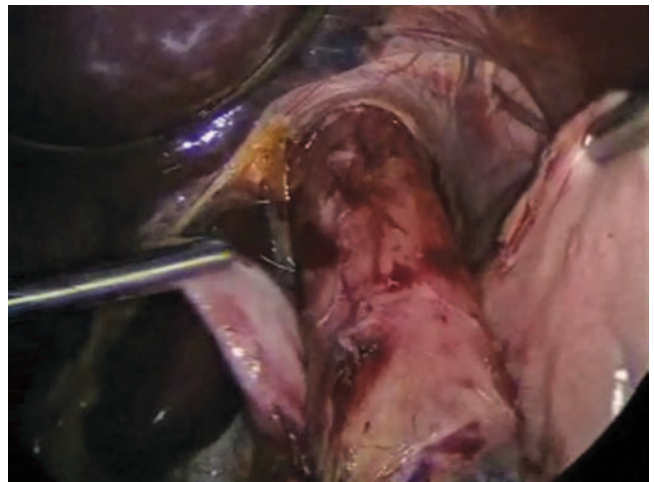
**FIGURE 15-25** Completion of the approximation of diaphragmatic crura.

## Laparoscopic Partial Fundoplication

Partial fundoplication is indicated in patients with impaired esophageal motility. The Dor and Toupet antireflux procedures consist of partial anterior and posterior fundoplication, respectively. Most of the key points are common with those listed for a Nissen fundoplication. The difference between a complete and a partial fundoplication is the structure of a newly created valve; a “nipple” valve in a complete fundoplication versus a “flap” valve in a partial fundoplication.

### DOR FUNDOPLICATION

After mobilization of the distal esophagus and GEJ and hiatal closure, a 60F Bougie is placed as described in the section on Nissen



**FIGURE 15-26** Shoeshine maneuver.



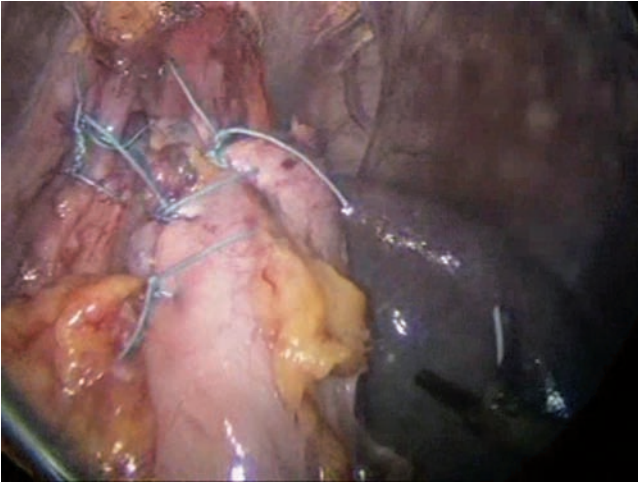


FIGURE 15-27 Completion of the fundoplication.

fundoplication. The initial suture of the Dor fundoplication incorporates the greater curvature side of the gastric fundus 2 cm distal to the GEJ, lateral wall of the esophagus 2 cm proximal to the GEJ, and base of the left crus to re-create the angle of His. Re-creation of the angle of His is an essential element of the Dor fundoplication. The greater curvature is then sutured to the arch of the diaphragm toward the apex of the crura, bringing the anterior fundus over the anterior wall of the distal esophagus with seven interrupted 0 nonabsorbable sutures. This repair is carried over to the right crus to the 9 o'clock position. At completion, the fundoplication should appear smooth without creases indicating the absence of tension.

### TOUPET FUNDOPLICATION

In an identical fashion to the Nissen fundoplication, the gastric fundus is passed behind the esophagus through the retroesophageal space after hiatal closure and placement of an esophageal dilator. The right side of the fundus is sutured to the right margin of the esophagus with four nonabsorbable sutures, and the most distal suture is placed to the lesser curvature of the stomach immediately distal to the GEJ. The right posterior aspect of the fundus is sutured to the right side of the proximal preaortic fascia. A similar line of sutures secures the left limb of the fundoplication to the esophagus. The posterior aspect of the gastric fundus on left is sutured to the base of the left crus.

## Outcome of Antireflux Surgery

The goal of surgical treatment for GERD is to relieve the symptoms by restoring a mechanically defective gastroesophageal barrier. This goal should be achieved without inducing postoperative complications such as dysphagia and gas bloat syndrome. Temporary dysphagia due to postoperative tissue edema of the wrap is common and generally resolves within 3 months

without requiring any intervention such as dilation. However, persistent dysphagia beyond 3 months has been reported in up to 10% of patients. Bloating and hyperflatulence are also common after antireflux surgery because patients with GERD tend to swallow excessive air with saliva in order to neutralized acid refluxate. Scheduled administration of Simethicone is effective to reduce gas in the GI tract, improving the symptoms. In addition, it is important to prevent constipation so as to not worsen bloating. Another common side effect after antireflux surgery is the inability to vomit, but this is rarely clinically relevant. It is critical to control perioperative nausea so as to prevent retching with subsequent disruption of the repair.

Studies of long-term outcome following laparoscopic fundoplication have demonstrated relief of typical GERD symptoms such as heartburn, regurgitation, and dysphagia in more than 90% of patients at the follow-up interval of 2–3 years and 80–90% of patients at 5 years or more.<sup>98,108–110</sup> Laparoscopic fundoplication results in a significant increase in LES pressure and length, generally restoring these values to normal. Postoperative pH studies indicate that more than 90% of patients normalize acid exposure to the esophagus. A randomized study with 11-year follow-up demonstrated that the open and laparoscopic approaches for the Nissen fundoplication have similar long-term subjective symptomatic outcome despite the significantly higher incidence of incisional hernia and endoscopically defective valves in the open group; from these data, the authors defined the laparoscopic approach as the procedure of choice in surgical management of GERD.<sup>111</sup> There is a less predictable outcome of atypical symptoms such as cough, asthma, and laryngitis after antireflux surgery, being relieved in only two-thirds of patients probably because the documentation of correlation between reflux events and atypical symptoms has been difficult.<sup>112–114</sup> This could be addressed with the introduction of a reliable esophageal objective testing tool such as MII-pH.

Quality-of-life analyses have become an important part of surgical outcome assessment, especially for the surgical treatment of benign disease such as GERD. Currently, both global and disease-specific questionnaires have been used to quantify quality of life before and after surgical intervention.<sup>115</sup> Most studies have utilized the Short Form 36 (SF-36) instrument that is rapidly administered and well-validated. The GERD Health-Related Quality of Life Scale (GERD-HRQL), which is a disease-specific questionnaire, is also commonly used to address symptom severity in GERD. Fernando et al compared quality of life after antireflux surgery with that of nonoperative management for severe GERD, and showed that both SF 36 and GERD-HRQL were significantly superior in patients who underwent laparoscopic fundoplication compared with those who had medical treatment. They indicated that laparoscopic fundoplication should be considered for patients who are dissatisfied with medical treatment.<sup>116</sup>

## Reoperation for Failed Antireflux Repairs

With the increased number of antireflux surgeries being performed, the reoperation for a failed repair has been more

frequent. Previous studies have shown that the failure rates for open fundoplication range from 9 to 30%,<sup>98,117,118</sup> whereas those for laparoscopic approach range from 2 to 17%.<sup>119,120</sup> Many patients with mild recurrent symptoms can be managed with nonoperative therapy. It has been estimated that between 3 and 6% of antireflux surgeries will require reoperation.<sup>121</sup> With the advance of minimally invasive surgical technique, more reoperations are being performed using a laparoscopic approach. However, the success rate for redo surgery does not equal to that of the initial antireflux surgery. Little et al reported that 84% of patients undergoing the first redo antireflux surgery achieved a satisfactory result, but only 42% of patients with three or more previous reoperations had a satisfactory result.<sup>118</sup> Although a recent systematic review of reoperations showed that recurrent reflux and dysphagia were the most frequent indications for redo antireflux surgery,<sup>122</sup> the etiology of recurrent symptoms varies considerably and patients with any persistent symptoms should be evaluated with objective testing. It is extremely important to identify the etiology of symptoms in order to choose an appropriate treatment option. Evaluation includes the repeat of esophageal objective testing such as upper endoscopy, barium swallow, manometry, pH monitoring, MII-pH, and gastric emptying. Based on radiographic findings, several patterns of recurrence have been reported (Fig. 15-28).<sup>123</sup> Herniation and disruption of the fundoplication were the most common causes of failure.<sup>122</sup> Additionally, inadequately treated short esophagus often contributed to repair herniation.<sup>124</sup>

There are several options for reconstructive antireflux surgery, including redo Nissen or partial fundoplication, Roux-en Y esophagojejunostomy, and esophagectomy. In redo fundoplication, it is essential to completely take down the previous repair in order to reestablish the normal anatomy, identify the “true” GEJ by medializing the gastroesophageal fat pad, preserve both vagus nerves, recognize a short esophagus, repair the crura, and re-create the proper fundoplication. The results of redo antireflux surgery are not as good as those of the primary antireflux surgery. However, good-to-excellent results can be achieved in more than 80% of patients using minimally invasive techniques at an experienced center.<sup>125,126</sup>

## HIATAL HERNIA

### History

In 1919, Soresi published the first report on the surgical treatment of hiatal hernia.<sup>127</sup> In 1950, Sweet described the transthoracic approach to hiatal hernia repair and 2 years later reported a series of 111 patients.<sup>128</sup> Allison established the relationship between hiatal hernia and gastroesophageal reflux and proposed surgical options to correct the defect, namely returning the stomach to the abdomen and repairing the diaphragmatic hiatus.<sup>129</sup> Subsequently, Barrett,<sup>130</sup> Hiebert and Sir Belsey,<sup>131</sup> and Hill et al<sup>132</sup> set the stage for the importance of reestablishing the cardiophrenic angle in correcting reflux symptoms. In 1967, Belsey and Skinner presented data on 1063 patients with

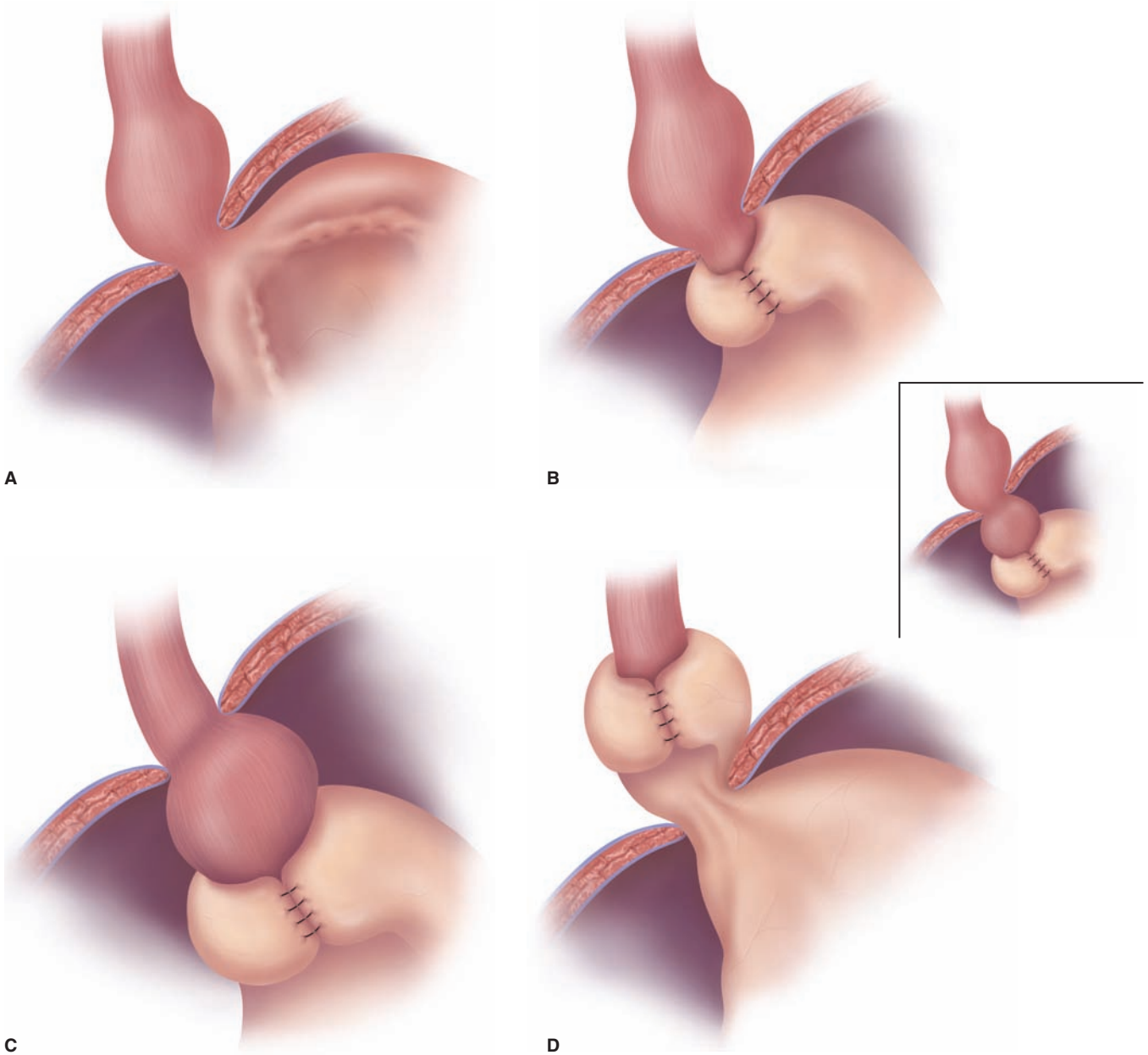
hiatal hernia.<sup>133</sup> The work was the first to distinguish between a sliding hiatal hernia and a paraesophageal hernia (PEH). Since then, further evaluation and subclassification of hiatal hernias has occurred. From this work, the overriding consensus for the next several decades was that PEH required surgical repair so as to prevent strangulation, gastric necrosis, and patient death.

### Categories of Hiatal Hernia

There are four types of hiatal hernia. Type I, sliding hiatal hernias, account for nearly 95% of all hiatal hernias.<sup>134,135</sup> The combination of hiatal enlargement, lengthening of the phrenoesophageal ligament, and increased intra-abdominal pressure allows the GEJ to become intrathoracic. Sliding hiatal hernias may be more likely to progress in patients who are obese, pregnant, or have a chronic cough. Because the GEJ is displaced from its normal anatomic position, there is concurrent dysfunction of the LES manifesting as decreased resting pressure. This causes a loss of the angle of His, thus distorting the esophageal flap valve.<sup>87</sup>

The other three types of hiatal hernias are broadly classified as paraesophageal. Compared with a type I hernia, which has no hernia sac, all PEHs are covered circumferentially by a layer of peritoneum that forms a true hernia sac. Type II PEH is the least common.<sup>136</sup> Type II hernias are characterized by preservation of the GEJ at its normal anatomic position within in the abdomen. The phrenoesophageal ligament is preserved, but the esophageal hiatus is enlarged and the fundus of the stomach is in the thoracic cavity. When there is proximal displacement of the GEJ and at least 30% of the stomach above the diaphragm, this is classified as a type III PEH, the most common type of PEH. When there is herniation of other organs into the thoracic cavity along with the stomach, this is termed a type IV PEH. Colon, small bowel, pancreas, spleen, omentum, and liver can migrate into the true anterior or posterior hernia sac. In addition to obstruction of the stomach, colon, or small bowel, there is the potential for compromised blood flow to the organs that are displaced intrathoracically.<sup>137</sup> The most common complaints associated with PEH are related to mechanical issues caused by the location of the fundus above the diaphragm while the GEJ is fixed in its proper anatomic position in the abdomen. These include chest pain or pressure, obstruction, incarceration, possible strangulation, and pulmonary dysfunction commonly associated with chronic aspiration. Additionally, about 40% of patients with a PEH have chronic anemia that may be the result of either mucosal venous engorgement or a Cameron ulcer.<sup>138</sup>

Hiatal hernias, including PEHs, occur most commonly in women. In the largest published series on treatment of PEH, 75% of patients were female.<sup>139</sup> About half of all patients presenting with PEH are older than 70, possibly because of loss of elasticity and muscle weakening. This loss of muscle tone around the diaphragmatic opening allows it to become dilated more easily. The gastric cardia then pushes into the opening and may or may not return to its normal anatomic position, thus further dilating the hiatus. Women may be affected more



**FIGURE 15-28** Pattern of failure of primary repair: four types of failure. **A.** Complete disruption; **B.** Slipped Nissen; **C.** Malpositioned wrap; **D.** Transhiatal herniation. (Reprinted from Hinder RA. Gastroesophageal reflux disease. In: Bell RH, Jr, Rikkers LF, Mulholland MW, eds. *Digestive Tract Surgery: A Text and Atlas*. Philadelphia, PA: Lippincott-Raven Publishers; 1996:19.)

frequently than men because of changes during pregnancy. Other etiologies that cause increases in intra-abdominal pressures (obesity, constipation, and abdominal ascites) are also implicated.

### PEH and Short Esophagus

*Short esophagus* is defined as less than 2.5 cm of tension-free intra-abdominal esophagus. Three types of esophageal

shortening have been identified.<sup>140</sup> The first is the apparent short esophagus, which is longitudinal compression of the esophagus in the mediastinum, but maintenance of normal esophageal length. The other two types are truly shortened esophagus and are classified as reducible and nonreducible. A reducible short esophagus is foreshortened, but with extensive mediastinal mobilization 2.5 cm of intra-abdominal esophagus can be obtained. In patients with a nonreducible short esophagus, extensive mediastinal mobilization fails to produce sufficient length and an esophageal lengthening



procedure must be considered. The ability to accurately identify a nonreducible short esophagus is critical to accomplish a tension-free PEH repair that results in a low risk of recurrence. The incidence of short esophagus in patients undergoing antireflux surgery is 3–10%,<sup>140,141</sup> while a higher incidence has been noted in patients with PEH, which is commonly identified as a risk factor for short esophagus.<sup>142–144</sup> Diagnosis of a short esophagus is made intraoperatively.

## Preoperative Evaluation

At the time of evaluation, a detailed history and physical examination are important. While symptoms of reflux and dysphagia occur in 40–70% of patients, other symptoms are also commonly experienced. In the largest series to date, regurgitation, dyspnea, chest pain, or abdominal pain was also seen in 40–70% of patients.<sup>139</sup> If a patient presents with acute-onset, severe abdominal pain with vomiting, the physician needs to be mindful of the possibility of gastric volvulus, especially in patients with a known history of PEH. In these cases, urgency is essential as timely diagnosis and emergent operative intervention can mean the difference between reduction of the hernia and repair and subtotal gastrectomy or death.

## ESOPHOGRAM

A barium esophogram will delineate how much stomach is herniated through the hiatus, and will determine whether there is organoaxial rotation of the stomach, which in conjunction with complaints of intermittent abdominal pain may be a harbinger of pending volvulus and either incarceration or strangulation necessitating elective repair on an urgent basis. Contrast examinations are also very important in the evaluation of recurrent PEH and may lend insight into the cause of the recurrence and assist in identifying complexities that may be encountered at the time of surgery.

## ENDOSCOPY

Endoscopy enables examination of the mucosa to evaluate for esophagitis, BE, stricture, or malignancy. Endoscopy may also estimate the size of the hiatus. In cases where there is concern for incarceration or strangulation, flexible endoscopy is a valuable diagnostic test of mucosal viability and enables gastric decompression.

## MANOMETRY AND pH TESTING

Most patients who have a PEH have poor esophageal motility. However, up to 80% may demonstrate improvement following surgical repair of the hiatal hernia.<sup>145</sup> The use of pH probe testing is not necessary; it can be difficult to get accurate results, and the results do not change the management algorithm. Esophageal manometry will determine whether there is

normal esophageal body function and enable tailoring of the antireflux procedure.

## GASTRIC EMPTYING STUDY

Gastric emptying studies are not obtained unless the patient is presenting with a recurrence of a PEH that will require reoperation. For patients who have previously undergone surgical repair of the PEH, a gastric emptying study is important to determine if the vagus nerves have been injured, as this may alter the surgical approach.

## Operative Approach

Surgery for PEH is reconstructive in nature with two primary goals: restore the normal anatomy by returning the GEJ and stomach to the abdomen and correct the condition that contributed to the development of the anatomic problem, namely GERD. Surgeons can either choose a transthoracic, transabdominal, or laparoscopic approach to repair a PEH.<sup>146–148</sup> The best approach is a point of considerable debate and the different approaches to PEH repair have not been compared in a prospective, randomized trial. Laparoscopic repair significantly decreases postoperative complications and is the procedure of choice in most centers. The tenants of surgical repair include sac excision with complete reduction of the hernia from the mediastinum, establish tension-free esophageal length, repair the diaphragmatic crura, and perform an antireflux procedure.

## TRANSTHORACIC APPROACH

A left posterolateral thoracotomy is performed with a planned entry at the seventh interspace. The inferior pulmonary ligament is incised to the level of the inferior pulmonary vein and the mediastinal pleura overlying the esophagus is opened. The esophagus is circumferentially mobilized from the carina toward the diaphragm. The hernia sac is then dissected free of surrounding structures until the crura are identified. The sac is then incised just above the crural fibers to avoid loss of the peritoneal covering of the crura. The esophagus and stomach are then dissected away from the crura. When the right crus is identified, the gastrohepatic ligament is divided to the level of the left gastric artery. The stomach is mobilized beginning with the highest short gastric vessels. Once the fundus is restored to its normal anatomic position, the crural approximation stitches are placed, but not tied. During mobilization of the anterior esophageal fat pad, the vagus nerves need to be identified and protected. Mobilization of the fat pad enables identification of GEJ to determine if there is appropriate intra-abdominal esophageal length. A fundoplication is then performed as described in section on Nissen fundoplication. The fundoplication is placed into the abdominal cavity and crural sutures are tied.

### LAPAROSCOPIC APPROACH

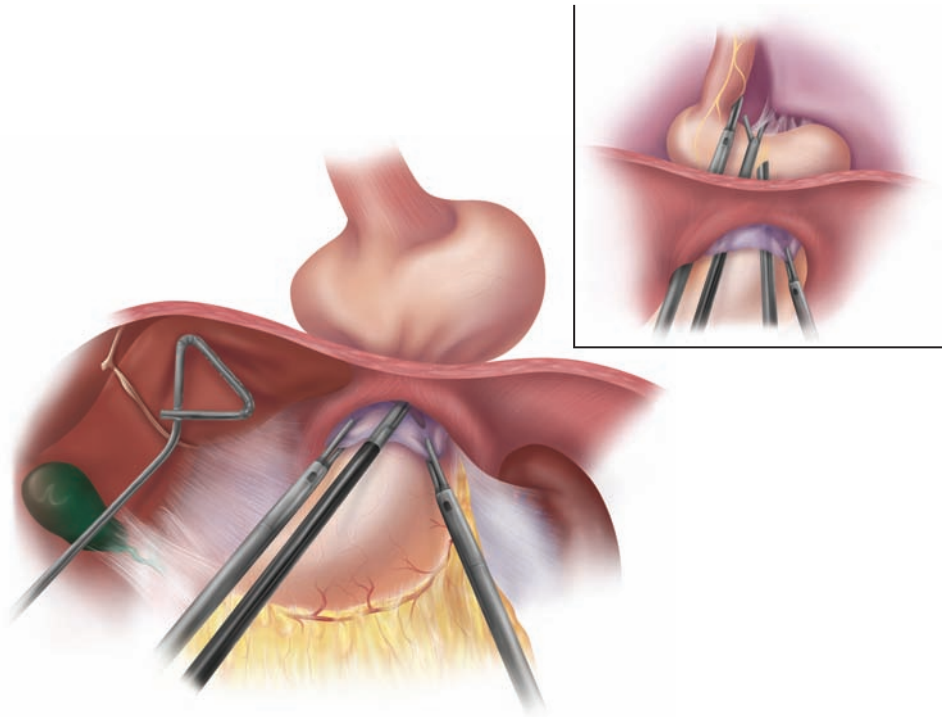
The hernia sac is gently reduced. This is accomplished by grasping the sac just inside the diaphragmatic crura at the 12 o'clock position (Fig. 15-29). The sac is incised providing access to the fibroareolar plane within the posterior mediastinum. Dissection in the correct plane is generally free of hemorrhage and provides excellent visualization of the pleura, esophagus, and vagus nerves. The borders of the dissection are the pleura laterally, the pericardium anteriorly, and the aorta posteriorly. Circumferential mobilization facilitates reduction of the entire hernia sac into the abdomen, thus returning the stomach to its normal anatomic position. The gastrohepatic ligament is divided and this provides access to the posterior aspect of the sac from the right side. Short gastric vessels are completely divided and the gastroesophageal fat pad is fully mobilized to allow visualization of the GEJ (Fig. 15-30). Anterior and posterior vagus nerves are identified and preserved. The GEJ is evaluated to determine that there is an adequate length of intra-abdominal esophagus (Fig. 15-31). If aggressive esophageal mobilization fails to produce an appropriate length of esophagus, an esophageal lengthening procedure is performed using a stapled wedge gastropasty.<sup>149</sup> (Fig. 15-32). An antireflux procedure is routinely performed (Fig. 15-33). The crura are reapproximated using nonabsorbable 0-suture. Bioprosthetic mesh is used selectively to buttress the hiatal closure.

### OUTCOMES—TRANSTHORACIC APPROACH

The University of Michigan retrospectively reported their 25-year experience with open transthoracic repair of PEH.<sup>146</sup> In their series, 240 patients underwent PEH repair via a left thoracotomy, and 96% had a Collis-Nissen gastropasty performed as part of the repair. At a median follow-up of 28 months, 86% of patients were satisfied with the results of the PEH repair, despite radiographic recurrence in 12% of patients. Maziak and colleagues followed 94 patients who underwent transthoracic PEH repair.<sup>150</sup> The majority of the patients underwent a Collis gastropasty with a Belsey fundoplication. With a median follow-up of 72 months, anatomic recurrence was identified in 2%, postoperative morbidity in 19%, and mortality in 2%. More than 90% of the patients had good-to-excellent symptom resolution.

### OUTCOMES—LAPAROSCOPIC APPROACH

Surgical repair of PEH is a complex operation and the minimally invasive approach requires advanced laparoscopic expertise. Very early experience of small, retrospective case reports was that these reports were able to demonstrate feasibility with good outcomes over a short follow-up.<sup>151</sup> The initial enthusiasm for laparoscopic repair of giant PEH waned as further reports were unable to reproduce the early results and were associated with high failure rates.<sup>152-154</sup> Recurrence rates as high as 40% with mortality



**FIGURE 15-29** Beginning the hernia sac dissection. The sac is opened providing access to the space between the outside of the sac and posterior mediastinal structures.

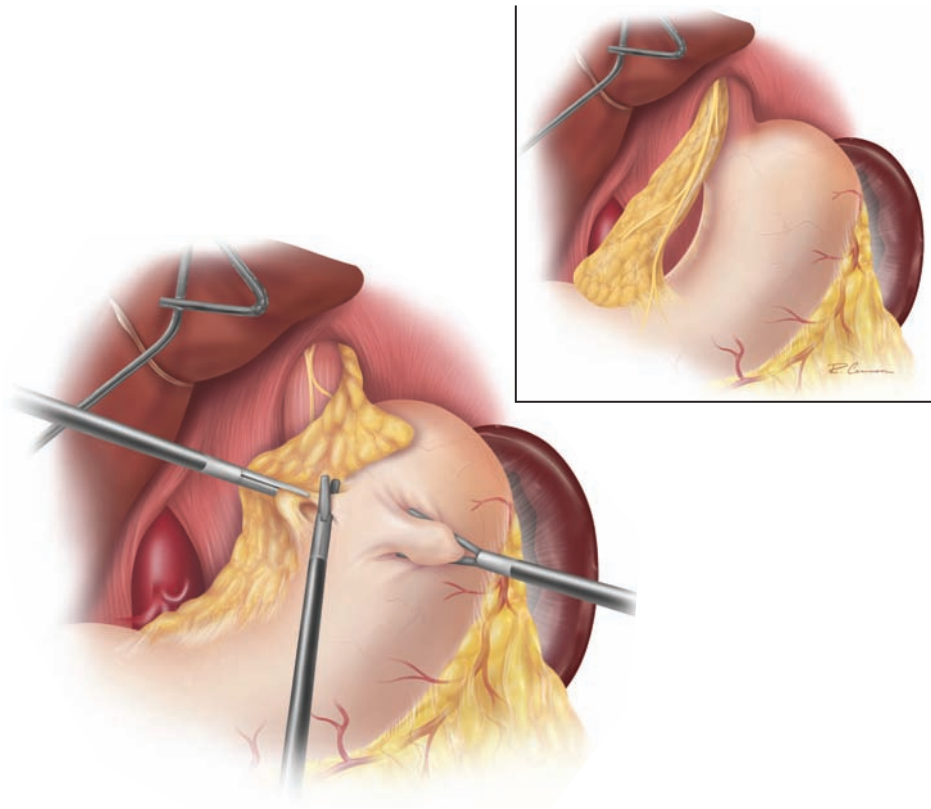


FIGURE 15-30 Medialization of the gastroesophageal fat pad so as to provide exposure of the anatomic gastroesophageal junction.

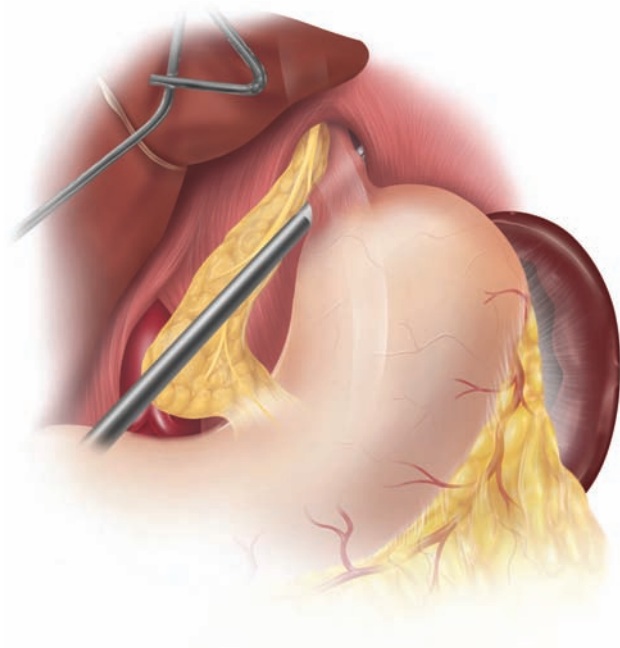


FIGURE 15-31 Evaluation of esophageal length. Dashed line indicates the planned wedge gastropasty in patients with less than 3cm of tension-free, intra-abdominal esophagus.

rates of up to 5%, both considerably higher than those for either open transthoracic or transabdominal repairs, were reported. However, over the past decade there has been a considerable evolution of the technique, and the feasibility and safety of the laparoscopic approach have been well established.<sup>139,155</sup> Operative mortality following laparoscopic PEH repair is now extremely low (0–2%) but is higher in patients older than 80 and in those requiring urgent repair.<sup>139,156</sup> Laparoscopic repair of PEH produces equivalent long-term outcomes to open approaches when all the surgical principles of the open technique are meticulously followed. At the University of Pittsburgh we have reported on 662 patients over the past 10 years who have undergone laparoscopic repair of PEH with low rates of radiographic recurrence (15.7%) and reoperations (3.2%). In the subset of these patients with a minimum follow-up of 5 years and a median of over 6 years, these results are durable and show unchanged rates of recurrence or reoperation.<sup>157</sup> Interestingly, we have found that radiographic recurrence was not associated with symptom recurrence and reflux-related quality-of-life scores indicated good-to-excellent results in 86.7% of patients. Additionally, laparoscopic repair significantly decreased postoperative complications, as well as length of intensive care unit



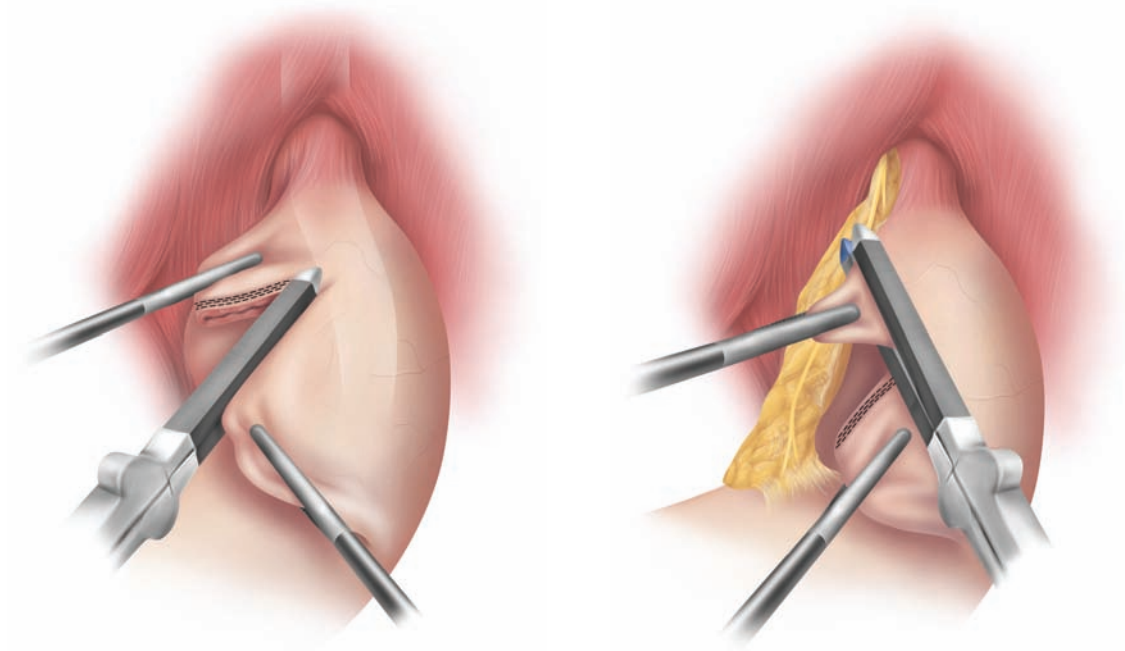


FIGURE 15-32 Wedge gastropasty. A 48F bougie is placed and the surgeon left hand port is enlarged to accommodate a roticulating stapler.

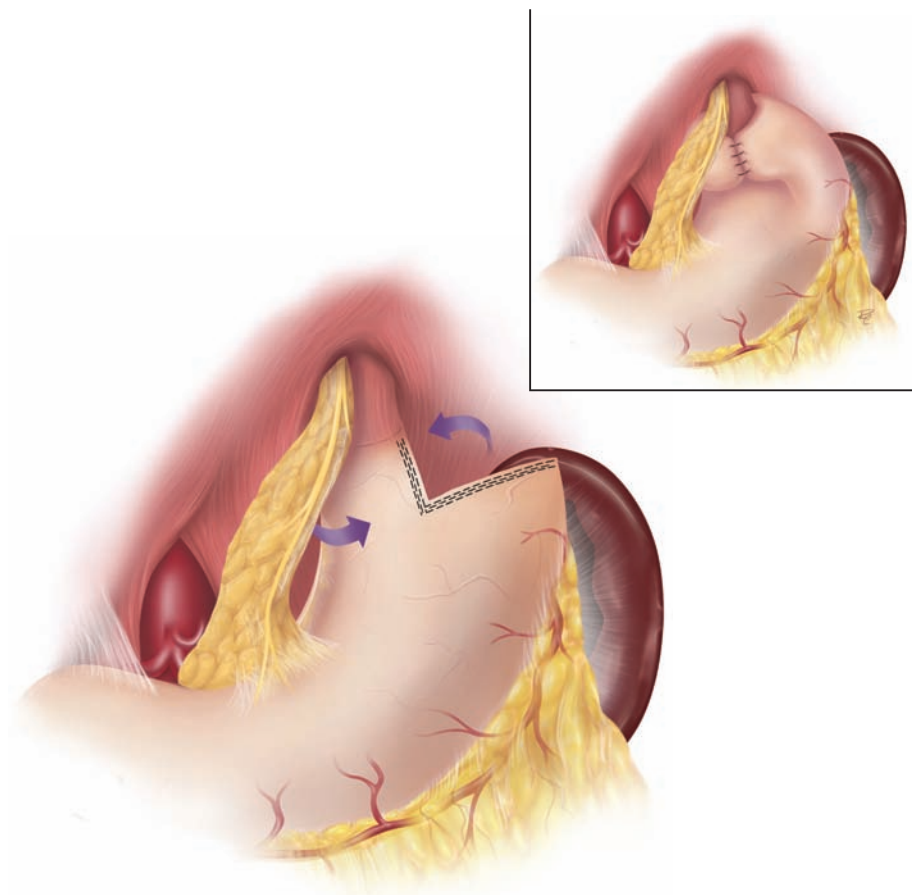


FIGURE 15-33 A neoesophagus is created with wedge gastropasty and a Nissen fundoplication is performed.

stay, length of hospital stay, time to oral intake, and pain medication use.<sup>158,159</sup>

The routine use of mesh to reinforce the esophageal hiatus after laparoscopic repair decreases recurrence rates. In the only prospective randomized study on the use of mesh in laparoscopic repair of PEH, the recurrence rate in patients who did not have mesh was 42% as compared with a recurrence rate of only 9% when mesh was used, with only 6-month follow-up.<sup>160</sup> Furthermore, while a number of studies have shown safe and effective use of mesh,<sup>161–163</sup> reinforcement with mesh may increase the incidence of complications. A recent paper by Stadlhuber and associates reports that complications from mesh reinforcement of the esophageal hiatus may be underreported.<sup>164</sup>

**Conclusion:** PEH are most commonly diagnosed in people older than 70 years. With the population aging, surgical repair of PEH may become more common in the future. A detailed history is important because PEH produces either gastrointestinal or pulmonary symptoms, such as shortness of breath. Over 90% of people who undergo PEH repair have a significant improvement in symptoms that are long lasting. While open repairs using transthoracic and transabdominal approaches have resulted in low complication rates and mortality, the laparoscopic repair, in experienced hands, results in excellent outcomes and is safe.

## REFERENCES

- Moraes-Filho J, Ceconello I, Gama-Rodrigues J, et al. Brazilian consensus on gastroesophageal reflux disease: proposals for assessment, classification, and management. *Am J Gastroenterol*. 2002;97(2):241–248.
- Fass R, Tougas G. Functional heartburn: the stimulus, the pain, and the brain. *Gut*. 2002 Dec;51(6):885–892.
- Hoppo T, Immanuel A, Schuchert M, et al. Transoral incisionless fundoplication 2.0 procedure using EsophyX for gastroesophageal reflux disease. *J Gastrointest Surg*. 2010;14(12):1895–1901.
- Watson DI, Immanuel A. Endoscopic and laparoscopic treatment of gastroesophageal reflux. *Expert Rev Gastroenterol Hepatol*. 2010 Apr;4(2):235–243.
- Shaker R, Castell DO, Schoenfeld PS, Spechler SJ. Nighttime heartburn is an under-appreciated clinical problem that impacts sleep and daytime function: the results of a Gallup survey conducted on behalf of the American Gastroenterological Association. *Am J Gastroenterol*. 2003;98(7):1487–1493.
- DeMeestre TR, O'Sullivan GC, Bermudez G, Midell AI, Cimochowski GE, O'Drobinak J. Esophageal function in patients with angina-type chest pain and normal coronary angiograms. *Ann Surg*. 1982;196(4):488–498.
- Hirano I, Richter JE. ACG practice guidelines: esophageal reflux testing. *Am J Gastroenterol*. 2007;102(3):668–685.
- Pandolfino JE, Richter JE, Ours T, Guardino JM, Chapman J, Kahrilas PJ. Ambulatory esophageal pH monitoring using a wireless system. *Am J Gastroenterol*. 2003;98(4):740–749.
- Zaninotto G, DeMeester TR, Schwizer W, Johansson KE, Cheng SC. The lower esophageal sphincter in health and disease. *Am J Surg*. 1988;155(1):104–111.
- Hakanson BS, Berggren P, Granqvist S, Ljungqvist O, Thorell A. Comparison of wireless 48-h (Bravo) versus traditional ambulatory 24-h esophageal pH monitoring. *Scand J Gastroenterol*. 2009;44(3):276–283.
- Bremner RM, DeMeester TR, Crookes PF, et al. The effect of symptoms and nonspecific motility abnormalities on outcomes of surgical therapy for gastroesophageal reflux disease. *J Thorac Cardiovasc Surg*. 1994;107(5):1244–1249; discussion 1249–1250.
- Johnson LF, DeMeester TR. Development of the 24-hour intraesophageal pH monitoring composite scoring system. *J Clin Gastroenterol*. 1986;8(suppl 1):52–58.
- Diener U, Patti MG, Molena D, Fisichella PM, Way LW. Esophageal dysmotility and gastroesophageal reflux disease. *J Gastrointest Surg*. 2001 May–Jun;5(3):260–265.
- Patti MG, Gasper WJ, Fisichella PM, Nipomnick I, Palazzo F. Gastroesophageal reflux disease and connective tissue disorders: pathophysiology and implications for treatment. *J Gastrointest Surg*. 2008;12(11):1900–1906.
- Meneghetti AT, Tedesco P, Damani T, Patti MG. Esophageal mucosal damage may promote dysmotility and worsen esophageal acid exposure. *J Gastrointest Surg*. 2005 Dec;9(9):1313–1317.
- Domsic R, Fasanella K, Bielefeldt K. Gastrointestinal manifestations of systemic sclerosis. *Dig Dis Sci*. 2008;53(5):1163–1174.
- Mittal RK, Rochester DF, McCallum RW. Electrical and mechanical activity in the human lower esophageal sphincter during diaphragmatic contraction. *J Clin Invest*. 1988;81(4):1182–1189.
- Richter JE, Wu WC, Johns DN, et al. Esophageal manometry in 95 healthy adult volunteers. Variability of pressures with age and frequency of “abnormal” contractions. *Dig Dis Sci*. 1987;32(6):583–592.
- Fuchs KH, DeMeester TR, Albertucci M. Specificity and sensitivity of objective diagnosis of gastroesophageal reflux disease. *Surgery*. 1987 Oct;102(4):575–580.
- Schwizer W, Hinder RA, DeMeester TR. Does delayed gastric emptying contribute to gastroesophageal reflux disease? *Am J Surg*. 1989;157(1):74–81.
- Stein HJ, Barlow AP, DeMeester TR, Hinder RA. Complications of gastroesophageal reflux disease. Role of the lower esophageal sphincter, esophageal acid and acid/alkaline exposure, and duodenogastric reflux. *Ann Surg*. 1992 Jul;216(1):35–43.
- Fiorucci S, Santucci L, Chiucchiu S, Morelli A. Gastric acidity and gastroesophageal reflux patterns in patients with esophagitis. *Gastroenterology*. 1992 Sep;103(3):855–861.
- Fletcher J, Wirz A, Young J, Vallance R, McColl KE. Unbuffered highly acidic gastric juice exists at the gastroesophageal junction after a meal. *Gastroenterology*. 2001 Oct;121(4):775–783.
- Harmon JW, Johnson LF, Maydonovitch CL. Effects of acid and bile salts on the rabbit esophageal mucosa. *Dig Dis Sci*. 1981;26(1):65–72.
- Shay S, Tutuian R, Sifrim D, et al. Twenty-four hour ambulatory simultaneous impedance and pH monitoring: a multicenter report of normal values from 60 healthy volunteers. *Am J Gastroenterol*. 2004;99(6):1037–1043.
- Venables TL, Newland RD, Patel AC, Hole J, Wilcock C, Turbitt ML. Omeprazole 10 milligrams once daily, omeprazole 20 milligrams once daily, or ranitidine 150 milligrams twice daily, evaluated as initial therapy for the relief of symptoms of gastro-oesophageal reflux disease in general practice. *Scand J Gastroenterol*. 1997;32(10):965–973.
- Bajbouj M, Becker V, Neuber M, Schmid RM, Meining A. Combined pH-metry/impedance monitoring increases the diagnostic yield in patients with atypical gastroesophageal reflux symptoms. *Digestion*. 2007;76(3–4):223–228.
- Marshall RE, Anggiansah A, Owen WJ. Bile in the oesophagus: clinical relevance and ambulatory detection. *Br J Surg*. 1997;84(1):21–28.
- de Caestecker JS. Measuring duodenogastro-oesophageal reflux (DGOR). *Eur Eur J Gastroenterol Hepatol*. 1997;9(12):1141–1143.
- Vaezi MF, Richter JE. Synergism of acid and duodenogastroesophageal reflux in complicated Barrett's esophagus. *Surgery*. 1995;117(6):699–704.
- Vaezi MF, Richter JE. Role of acid and duodenogastroesophageal reflux in gastroesophageal reflux disease. *Gastroenterology*. 1996 Nov;111(5):1192–1199.
- Bonavina L, DeMeester TR, McChesney L, Schwizer W, Albertucci M, Bailey RT. Drug-induced esophageal strictures. *Ann Surg*. 1987 Aug;206(2):173–183.
- Mainie I, Tutuian R, Shay S, et al. Acid and non-acid reflux in patients with persistent symptoms despite acid suppressive therapy: a multicenter study using combined ambulatory impedance-pH monitoring. *Gut*. 2006;55(10):1398–1402.
- Bais JE, Samsom M, Boudesteijn EA, van Rijk PP, Akkermans LM, Gooszen HG. Impact of delayed gastric emptying on the outcome of antireflux surgery. *Ann Surg*. 2001 Aug;234(2):139–146.
- Sontag SJ, O'Connell S, Khandelwal S, et al. Asthmatics with gastroesophageal reflux: long term results of a randomized trial of medical and surgical antireflux therapies. *Am J Gastroenterol*. 2003;98(5):987–999.

36. Raghu G, Freudenberger TD, Yang S, et al. High prevalence of abnormal acid gastro-oesophageal reflux in idiopathic pulmonary fibrosis. *Eur Respir J*. 2006;27(1):136–142.
37. Button BM, Roberts S, Kotsimbos TC, et al. Gastroesophageal reflux (symptomatic and silent): a potentially significant problem in patients with cystic fibrosis before and after lung transplantation. *J Heart Lung Transplant*. 2005;24(10):1522–1529.
38. Ruth M, Carlsson S, Mansson I, Bengtsson U, Sandberg N. Scintigraphic detection of gastropulmonary aspiration in patients with respiratory disorders. *Clin Physiol*. 1993;13(1):19–33.
39. Lopes FD, Alvarenga GS, Quiles R, et al. Pulmonary responses to tracheal or esophageal acidification in guinea pigs with airway inflammation. *J Appl Physiol*. 2002 Sep;93(3):842–847.
40. Lang IM, Haworth ST, Medda BK, Roerig DL, Forster HV, Shaker R. Airway responses to esophageal acidification. *Am J Physiol Regul Integr Comp Physiol*. 2008;294(1):R211–R219.
41. Dor J, Humbert P, Paoli JM, Miorclerc M, Aubert J. [Treatment of reflux by the so-called modified Heller-Nissen technic]. *Presse Med*. 1967 Nov 25;75(50):2563–2565.
42. Dallemagne B, Weerts JM, Jehaes C, Markiewicz S, Lombard R. Laparoscopic Nissen fundoplication: preliminary report. *Surg Laparosc Endosc*. 1991 Sep;1(3):138–143.
43. Toupet A. [Technic of esophago-gastroplasty with phrenogastropey used in radical treatment of hiatal hernias as a supplement to Heller's operation in cardiospasm]. *Mem Acad Chir (Paris)*. 1963 Mar 20–27; 89:384–389.
44. Chiba N, De Gara CJ, Wilkinson JM, Hunt RH. Speed of healing and symptom relief in grade II to IV gastroesophageal reflux disease: a meta-analysis. *Gastroenterology*. 1997;112(6):1798–1810.
45. Linden PA, Gilbert RJ, Yeap BY, et al. Laparoscopic fundoplication in patients with end-stage lung disease awaiting transplantation. *J Thorac Cardiovasc Surg*. 2006;131(2):438–446.
46. Gerson LB, Shetler K, Triadafilopoulos G. Prevalence of Barrett's esophagus in asymptomatic individuals. *Gastroenterology*. 2002 Aug;123(2):461–467.
47. Pera M. Trends in incidence and prevalence of specialized intestinal metaplasia, Barrett's esophagus, and adenocarcinoma of the gastroesophageal junction. *World J Surg*. 2003;27(9):999–1008; discussion 1006–1008.
48. Rex DK, Shaw M, Wong R. Prevalence of Barrett's esophagus. *Gastroenterology*. 2006;130(4):1373–1374; author reply 1374–1375.
49. Ronkainen J, Aro P, Storskrubb T, et al. Prevalence of Barrett's esophagus in the general population: an endoscopic study. *Gastroenterology*. 2005 Dec;129(6):1825–1831.
50. Hirota WK, Loughney TM, Lazas DJ, Maydonovitch CL, Rholi V, Wong RK. Specialized intestinal metaplasia, dysplasia, and cancer of the esophagus and esophagogastric junction: prevalence and clinical data. *Gastroenterology*. 1999;116(2):277–285.
51. Epstein D, Bojke L, Sculpher MJ. Laparoscopic fundoplication compared with medical management for gastro-oesophageal reflux disease: cost effectiveness study. *BMJ*. 2009;339:b2576.
52. Conio M, Bianchi S, Lapertosa G, et al. Long-term endoscopic surveillance of patients with Barrett's esophagus. Incidence of dysplasia and adenocarcinoma: a prospective study. *Am J Gastroenterol*. 2003;98(9):1931–1939.
53. Drewitz DJ, Sampliner RE, Garewal HS. The incidence of adenocarcinoma in Barrett's esophagus: a prospective study of 170 patients followed 4.8 years. *Am J Gastroenterol*. 1997;92(2):212–215.
54. Sharma P, Sampliner RE. The rising incidence of esophageal adenocarcinoma. *Adv Intern Med*. 2001;46:137–153.
55. Carlsson R, Dent J, Watts R, et al. Gastro-oesophageal reflux disease in primary care: an international study of different treatment strategies with omeprazole. International GORD Study Group. *Eur J Gastroenterol Hepatol*. 1998;10(2):119–124.
56. Clark GW, Ireland AP, Peters JH, Chandrasoma P, DeMeester TR, Bremner CG. Short-segment Barrett's esophagus: a prevalent complication of gastroesophageal reflux disease with malignant potential. *J Gastrointest Surg*. 1997 Mar-Apr;1(2):113–122.
57. Kwok CS, Yeong JK, Loke YK. Meta-analysis: Risk of fractures with acid-suppressing medication. *Bone*. 2010;48(4):768–776.
58. Kiesslich R, Gossner L, Goetz M, et al. In vivo histology of Barrett's esophagus and associated neoplasia by confocal laser endomicroscopy. *Clin Gastroenterol Hepatol*. 2006;4(8):979–987.
59. Arguedas MR, Heudebert GR, Klapow JC, et al. Re-examination of the cost-effectiveness of surgical versus medical therapy in patients with gastroesophageal reflux disease: the value of long-term data collection. *Am J Gastroenterol*. 2004;99(6):1023–1028.
60. Wang KK, Sampliner RE. Updated guidelines 2008 for the diagnosis, surveillance and therapy of Barrett's esophagus. *Am J Gastroenterol*. Mar 2008;103(3):788–797.
61. Cooper GS. Endoscopic screening and surveillance for Barrett's esophagus: can claims data determine its effectiveness? *Gastrointest Endosc*. 2003 Jun;57(7):914–916.
62. Corley DA, Levin TR, Habel LA, Weiss NS, Buffer PA. Surveillance and survival in Barrett's adenocarcinomas: a population-based study. *Gastroenterology*. 2002;122(3):633–640.
63. Oberg S, Johansson J, Wenner J, et al. Endoscopic surveillance of columnar-lined esophagus: frequency of intestinal metaplasia detection and impact of antireflux surgery. *Ann Surg*. 2001 Nov;234(5):619–626.
64. Collard JM. High-grade dysplasia in Barrett's esophagus. The case for esophagectomy. *Chest Surg Clin N Am*. 2002 Feb;12(1):77–92.
65. Falk GW, Rice TW, Goldblum JR, Richter JE. Jumbo biopsy forceps protocol still misses unsuspected cancer in Barrett's esophagus with high-grade dysplasia. *Gastrointest Endosc*. 1999;49(2):170–176.
66. Pennathur A, Awais O, Luketich JD. Minimally invasive esophagectomy for Barrett's with high-grade dysplasia and early adenocarcinoma of the esophagus. *J Gastrointest Surg*. 2010;14(6):948–950.
67. Birkmeyer JD, Stewers AE, Finlayson EV, et al. Hospital volume and surgical mortality in the United States. *New Engl J Med*. 2002 Apr 11;346(15):1128–1137.
68. Millikan KW, Silverstein J, Hart V, et al. A 15-year review of esophagectomy for carcinoma of the esophagus and cardia. *Arch Surg*. 1995;130(6):617–624.
69. Orringer MB, Marshall B, Iannettoni MD. Transhiatal esophagectomy: clinical experience and refinements. *Ann Surg*. 1999 Sep;230(3):392–400; discussion 400–393.
70. Oh DS, Hagen JA, Chandrasoma PT, et al. Clinical biology and surgical therapy of intramucosal adenocarcinoma of the esophagus. *J Am Coll Surg*. 2006 Aug;203(2):152–161.
71. Rice TW, Blackstone EH, Adelstein DJ, et al. Role of clinically determined depth of tumor invasion in the treatment of esophageal carcinoma. *J Thorac Cardiovasc Surg*. 2003;125(5):1091–1102.
72. Rice TW, Zuccaro G, Jr, Adelstein DJ, Rybicki LA, Blackstone EH, Goldblum JR. Esophageal carcinoma: depth of tumor invasion is predictive of regional lymph node status. *Ann Thorac Surg*. 1998;65(3):787–792.
73. Keeley SB, Pennathur A, Gooding W, Landreneau RJ, Christie NA, Luketich J. Photodynamic therapy with curative intent for Barrett's esophagus with high grade dysplasia and superficial esophageal cancer. *Ann Surg Oncol*. 2007;14(8):2406–2410.
74. Shaheen NJ, Sharma P, Overholt BF, et al. Radiofrequency ablation in Barrett's esophagus with dysplasia. *New Engl J Med*. 2009 May 28; 360(22):2277–2288.
75. Dumot JA, Vargo JJ, 2nd, Falk GW, Frey L, Lopez R, Rice TW. An open-label, prospective trial of cryospray ablation for Barrett's esophagus high-grade dysplasia and early esophageal cancer in high-risk patients. *Gastrointest Endosc*. 2009 Oct;70(4):635–644.
76. Shaheen NJ, Greenwald BD, Peery AF, et al. Safety and efficacy of endoscopic spray cryotherapy for Barrett's esophagus with high-grade dysplasia. *Gastrointest Endosc*. 2010;71(4):680–685.
77. May A, Gossner L, Behrens A, et al. A prospective randomized trial of two different endoscopic resection techniques for early stage cancer of the esophagus. *Gastrointest Endosc*. 2003 Aug;58(2):167–175.
78. Yamamoto H. Technology insight: endoscopic submucosal dissection of gastrointestinal neoplasms. *Nat Clin Pract Gastroenterol Hepatol*. 2007; 4(9):511–520.
79. Ell C, May A, Pech O, et al. Curative endoscopic resection of early esophageal adenocarcinomas (Barrett's cancer). *Gastrointest Endosc*. 2007; 65(1):3–10.
80. Shaheen NJ, Sharma P, Overholt BF, et al. Radiofrequency ablation in Barrett's esophagus with dysplasia. *N Engl J Med*. 2009 May 28;360(22): 2277–2288.
81. Gurski RR, Peters JH, Hagen JA, et al. Barrett's esophagus can and does regress after antireflux surgery: a study of prevalence and predictive features. *J Am Coll Surg*. 2003;196(5):706–712; discussion 712–703.
82. Gray SL, LaCroix AZ, Larson J, et al. Proton pump inhibitor use, hip fracture, and change in bone mineral density in postmenopausal women:



- results from the Women's Health Initiative. *Arch Intern Med.* 2010 May 10;170(9):765–771.
83. Barry DW, Vaezi MF. Laryngopharyngeal reflux: More questions than answers. *Cleve Clin J Med.* 2010;77(5):327–334.
  84. Narayani RI, Burton MP, Young GS. Utility of esophageal biopsy in the diagnosis of nonerosive reflux disease. *Dis Esophagus.* 2003;16(3):187–192.
  85. Lind JF, Duthie HL, Schlegel JF, Code CF. Motility of the gastric fundus. *Am J Physiol.* 1961 Jul;201:197–202.
  86. Purdy M, Nykopp TK, Kainulainen S, Paakkonen M. Division of the hepatic branch of the anterior vagus nerve in fundoplication: effects on gallbladder function. *Surg Endosc.* 2009;23(9):2143–2146.
  87. Hill LD, Kozarek RA, Kraemer SJ, et al. The gastroesophageal flap valve: in vitro and in vivo observations. *Gastrointest Endosc.* 1996 Nov;44(5):541–547.
  88. Fass R, Hell R, Sampliner RE, et al. Effect of ambulatory 24-hour esophageal pH monitoring on reflux-provoking activities. *Dig Dis Sci.* 1999;44(11):2263–2269.
  89. Tseng D, Rizvi AZ, Fennerty MB, et al. Forty-eight-hour pH monitoring increases sensitivity in detecting abnormal esophageal acid exposure. *J Gastrointest Surg.* 2005 Nov;9(8):1043–1051; discussion 1051–1042.
  90. Bais JE, Samsom M, Boudestein EA, van Rijk PP, Akkermans LM, Gooszen HG. Impact of delayed gastric emptying on the outcome of antireflux surgery. *Ann Surg.* 2001 Aug;234(2):139–146.
  91. Farrell TM, Richardson WS, Halkar R, et al. Nissen fundoplication improves gastric motility in patients with delayed gastric emptying. *Surg Endosc.* 2001;15(3):271–274.
  92. Maddern GJ, Jamieson GG. Fundoplication enhances gastric emptying. *Ann Surg.* 1985;201(3):296–299.
  93. Viljakka M, Saali K, Koskinen M, et al. Antireflux surgery enhances gastric emptying. *Arch Surg.* 1999;134(1):18–21.
  94. Van Sickle KR, McClusky DA, Swofford VA, Smith CD. Delayed gastric emptying in patients undergoing antireflux surgery: analysis of a treatment algorithm. *J Laparoendosc Adv Surg Tech A.* 2007 Feb;17(1):7–11.
  95. Nissen R. [A simple operation for control of reflux esophagitis]. *Schweiz Med Wochenschr.* 1956 May 18;86(suppl 20):590–592.
  96. Nissen R, Rossetti M. Fundoplication and gastropexy in the surgical treatment of cardia insufficiency and hiatal hernia. Indications, technique and results. *Ann Chir.* 1962;16:825–836.
  97. Donahue PE, Samelson S, Nyhus LM, Bombeck CT. The floppy Nissen fundoplication. Effective long-term control of pathologic reflux. *Arch Surg.* 1985;120(6):663–668.
  98. DeMeester TR, Bonavina L, Albertucci M. Nissen fundoplication for gastroesophageal reflux disease. Evaluation of primary repair in 100 consecutive patients. *Ann Surg.* 1986 Jul;204(1):9–20.
  99. Peters MJ, Mukhtar A, Yunus RM, et al. Meta-analysis of randomized clinical trials comparing open and laparoscopic anti-reflux surgery. *Am J Gastroenterol.* 2009;104(6):1548–1561; quiz 1547, 1562.
  100. Van Den Boom G, Go PM, Hameeteman W, Dallemagne B, Ament AJ. Cost effectiveness of medical versus surgical treatment in patients with severe or refractory gastroesophageal reflux disease in the Netherlands. *Scand J Gastroenterol.* 1996;31(1):1–9.
  101. Henderson RD, Henderson RF, Marryatt GV. Surgical management of 100 consecutive esophageal strictures. *J Thorac Cardiovasc Surg.* 1990; 99(1):1–7.
  102. Zaninotto G, DeMeester TR, Bremner CG, Smyrk TC, Cheng SC. Esophageal function in patients with reflux-induced strictures and its relevance to surgical treatment. *Ann Thorac Surg.* 1989;47(3):362–370.
  103. Morton JM, Bowers SB, Lucktong TA, et al. Gallbladder function before and after fundoplication. *J Gastrointest Surg.* 2002 Nov–Dec;6(6): 806–810; discussion 810–811.
  104. Kosek V, Wykypiel H, Weiss H, et al. Division of the short gastric vessels during laparoscopic Nissen fundoplication: clinical and functional outcome during long-term follow-up in a prospectively randomized trial. *Surg Endosc.* 2009;23(10):2208–2213.
  105. Mardani J, Lundell L, Lonroth H, Dalenback J, Engstrom C. Ten-year results of a randomized clinical trial of laparoscopic total fundoplication with or without division of the short gastric vessels. *Br J Surg.* 2009; 96(1):61–65.
  106. Hunter JG, Swanstrom L, Waring JP. Dysphagia after laparoscopic antireflux surgery. The impact of operative technique. *Ann Surg.* 1996 Jul;224(1):51–57.
  107. Terry ML, Vernon A, Hunter JG. Stapled-wedge Collis gastroplasty for the shortened esophagus. *Am J Surg.* 2004 Aug;188(2):195–199.
  108. Broeders JA, Rijnhart-de Jong HG, Draaisma WA, Bredenoord AJ, Smout AJ, Gooszen HG. Ten-year outcome of laparoscopic and conventional Nissen fundoplication: randomized clinical trial. *Ann Surg.* 2009 Nov;250(5):698–706.
  109. Ruiz-Tovar J, Diez-Tabernilla M, Chames A, Morales V, Martinez-Molina E. Clinical outcome at 10 years after laparoscopic versus open Nissen fundoplication. *J Laparoendosc Adv Surg Tech A.* 2010 Feb;20(1):21–23.
  110. Salminen P, Karvonen J, Ovaska J. Long-term outcomes after laparoscopic Nissen fundoplication for reflux laryngitis. *Dig Surg.* 2010;27(6): 509–514.
  111. Salminen PT, Hiekkanen HI, Rantala AP, Ovaska JT. Comparison of long-term outcome of laparoscopic and conventional Nissen fundoplication: a prospective randomized study with an 11-year follow-up. *Ann Surg.* 2007 Aug;246(2):201–206.
  112. So JB, Zeitels SM, Rattner DW. Outcomes of atypical symptoms attributed to gastroesophageal reflux treated by laparoscopic fundoplication. *Surgery.* 1998 Jul;124(1):28–32.
  113. Farrell TM, Richardson WS, Trus TL, Smith CD, Hunter JG. Response of atypical symptoms of gastro-oesophageal reflux to antireflux surgery. *Br J Surg.* 2001;88(12):1649–1652.
  114. Johnson WE, Hagen JA, DeMeester TR, et al. Outcome of respiratory symptoms after antireflux surgery on patients with gastroesophageal reflux disease. *Arch Surg.* 1996;131(5):489–492.
  115. Testa MA, Simonson DC. Assessment of quality-of-life outcomes. *New Engl J Med.* 1996 Mar 28;334(13):835–840.
  116. Fernando HC, Schauer PR, Rosenblatt M, et al. Quality of life after antireflux surgery compared with nonoperative management for severe gastroesophageal reflux disease. *J Am Coll Surg.* 2002;194(1):23–27.
  117. Hiebert CA, O'Mara CS. The Belsey operation for hiatal hernia: a twenty year experience. *Am J Surg.* 1979;137(4):532–535.
  118. Little AG, Ferguson MK, Skinner DB. Reoperation for failed antireflux operations. *J Thorac Cardiovasc Surg.* 1986;91(4):511–517.
  119. Hunter JG, Trus TL, Branum GD, Waring JP, Wood WC. A physiologic approach to laparoscopic fundoplication for gastroesophageal reflux disease. *Ann Surg.* 1996;223(6):673–685; discussion 685–677.
  120. Peters JH, DeMeester TR. Indications, benefits and outcome of laparoscopic Nissen fundoplication. *Dig Dis.* 1996; May–Jun 14(3):169–179.
  121. Collard JM, Verstraete L, Otte JB, Fiase R, Goncette L, Kestens PJ. Clinical, radiological and functional results of remedial antireflux operations. *Int Surg.* 1993 Oct–Dec;78(4):298–306.
  122. Furnee EJ, Draaisma WA, Broeders IA, Gooszen HG. Surgical reintervention after failed antireflux surgery: a systematic review of the literature. *J Gastrointest Surg.* 2009;13(8):1539–1549.
  123. Hinder RA. Gastroesophageal reflux disease. In: Bell RH, Jr, Rikkens LF, Mulholland MW, eds. *Digestive Tract Surgery: A Text and Atlas.* Philadelphia, PA: Lippincott-Raven Publishers. 1996:19.
  124. Morse C, Pennathur A, Luketich JD. Laparoscopic techniques in reoperation for failed antireflux repairs. In: Patterson GA, Cooper JD, Deslauriers J, et al, eds. *Pearson's textbook of thoracic and esophageal surgery.* Oxford, UK: Churchill Livingstone. 2008:367–375.
  125. Pennathur A, Awais O, Luketich JD. Minimally invasive redo antireflux surgery: lessons learned. *Ann Thorac Surg.* 2010;89(6):S2174–S2179.
  126. Awais O, Luketich JD, Tam J, et al. Roux-en-Y near esophageojejunostomy for intractable gastroesophageal reflux after antireflux surgery. *Ann Thorac Surg.* 2008;85(6):1954–1959; discussion 1959–1961.
  127. Soresi AL. Diaphragmatic hernia: its unsuspected frequency: its diagnosis: technic for radical cure. *Ann Surg.* 1919;69(3):254–270.
  128. Sweet RH. Esophageal hiatus hernia of the diaphragm; the anatomical characteristics, technic of repair, and results of treatment in 111 consecutive cases. *Ann Surg.* 1952;135(1):1–13.
  129. Allison PR. Reflux esophagitis, sliding hiatal hernia, and the anatomy of repair. *Surg Gynecol Obstet.* 1951;92(4):419–431.
  130. Barrett NR. Hiatus hernia: a review of some controversial points. *Br J Surg.* 1954 Nov;42(173):231–243.
  131. Hiebert CA, Belsey R. Incompetency of the gastric cardia without radiologic evidence of hiatal hernia. The diagnosis and management of 71 cases. *J Thorac Cardiovasc Surg.* 1961 Sep;42:352–362.
  132. Hill LD, Tobias J, Morgan EH. Newer concepts of the pathophysiology of hiatal hernia and esophagitis. *Am J Surg.* 1966;111(1):70–79.

133. Skinner DB, Belsey RH. Surgical management of esophageal reflux and hiatus hernia. Long-term results with 1,030 patients. *J Thorac Cardiovasc Surg.* 1967;53(1):33–54.
134. Hill LD, Tobias JA. Paraesophageal hernia. *Arch Surg.* 1968;96(5):735–744.
135. Ozdemir IA, Burke WA, Ikins PM. Paraesophageal hernia. A life-threatening disease. *Ann Thorac Surg.* 1973 Dec;16(6):547–554.
136. Landreneau RJ, Johnson JA, Marshall JB, Hazelrigg SR, Boley TM, Curtis JJ. Clinical spectrum of paraesophageal herniation. *Dig Dis Sci.* 1992;37(4):537–544.
137. Szwerc MF, Landreneau RJ. Splenic rupture as a consequence of giant paraesophageal hernia. *Ann Thorac Surg.* 2000 Nov;70(5):1727–1728.
138. Cameron AJ, Higgins JA. Linear gastric erosion. A lesion associated with large diaphragmatic hernia and chronic blood loss anemia. *Gastroenterology.* 1986 Aug;91(2):338–342.
139. Luketich JD, Nason KS, Christie NA, et al. Outcomes after a decade of laparoscopic giant paraesophageal hernia repair. *J Thorac Cardiovasc Surg.* 2010;139(2):395–404, 404 e391.
140. Horvath KD, Swanstrom LL, Jobe BA. The short esophagus: pathophysiology, incidence, presentation, and treatment in the era of laparoscopic antireflux surgery. *Ann Surg.* 2000 Nov;232(5):630–640.
141. Madan AK, Frantzides CT, Patsavas KL. The myth of the short esophagus. *Surg Endosc.* 2004;18(1):31–34.
142. Pearson FG, Cooper JD, Patterson GA, Ramirez J, Todd TR. Gastroplasty and fundoplication for complex reflux problems. Long-term results. *Ann Surg.* 1987 Oct;206(4):473–481.
143. Coster DD, Bower WH, Wilson VT, Brebrick RT, Richardson GL. Laparoscopic partial fundoplication vs laparoscopic Nissen-Rosetti fundoplication. Short-term results of 231 cases. *Surg Endosc.* 1997;11(6):625–631.
144. Mittal SK, Awad ZT, Tasset M, et al. The preoperative predictability of the short esophagus in patients with stricture or paraesophageal hernia. *Surg Endosc.* 2000;14(5):464–468.
145. Novitsky YW, Wong J, Kercher KW, Litwin DE, Swanstrom LL, Heniford BT. Severely disordered esophageal peristalsis is not a contraindication to laparoscopic Nissen fundoplication. *Surg Endosc.* 2007;21(6):950–954.
146. Patel HJ, Tan BB, Yee J, Orringer MB, Iannettoni MD. A 25-year experience with open primary transthoracic repair of paraesophageal hiatal hernia. *J Thorac Cardiovasc Surg.* 2004;127(3):843–849.
147. Low DE, Unger T. Open repair of paraesophageal hernia: reassessment of subjective and objective outcomes. *Ann Thorac Surg.* 2005 Jul;80(1):287–294.
148. Luketich JD, Raja S, Fernando HC, et al. Laparoscopic repair of giant paraesophageal hernia: 100 consecutive cases. *Ann Surg.* 2000 Oct;232(4):608–618.
149. Whitson BA, Hoang CD, Boettcher AK, Dahlberg PS, Andrade RS, Maddaus MA. Wedge gastroplasty and reinforced crural repair: important components of laparoscopic giant or recurrent hiatal hernia repair. *J Thorac Cardiovasc Surg.* 2006 Nov;132(5):1196–1202 e1193.
150. Maziak DE, Todd TR, Pearson FG. Massive hiatus hernia: evaluation and surgical management. *J Thorac Cardiovasc Surg.* 1998;115(1):53–60; discussion 61–52.
151. Pitcher DE, Curet MJ, Martin DT, Vogt DM, Mason J, Zucker KA. Successful laparoscopic repair of paraesophageal hernia. *Arch Surg.* 1995;130(6):590–596.
152. Dahlberg PS, Deschamps C, Miller DL, Allen MS, Nichols FC, Pairolero PC. Laparoscopic repair of large paraesophageal hiatal hernia. *Ann Thorac Surg.* 2001 Oct;72(4):1125–1129.
153. Hashemi M, Peters JH, DeMeester TR, et al. Laparoscopic repair of large type III hiatal hernia: objective followup reveals high recurrence rate. *J Am Coll Surg.* 2000;190(5):553–560; discussion 560–551.
154. Luostarinen M, Rantalainen M, Helve O, Reinikainen P, Isola J. Late results of paraesophageal hiatus hernia repair with fundoplication. *Br J Surg.* 1998;85(2):272–275.
155. Pierre AF, Luketich JD, Fernando HC, et al. Results of laparoscopic repair of giant paraesophageal hernias: 200 consecutive patients. *Ann Thorac Surg.* 2002 Dec;74(6):1909–1915; discussion 1915–1906.
156. Larusson HJ, Zingg U, Hahnloser D, Delport K, Seifert B, Oerli D. Predictive factors for morbidity and mortality in patients undergoing laparoscopic paraesophageal hernia repair: age, ASA score and operation type influence morbidity. *World J Surg.* 2009;33(5):980–985.
157. Nason KS, Luketich JD, Qureshi I, et al. Laparoscopic repair of giant paraesophageal hernia results in long-term patient satisfaction and a durable repair. *J Gastrointest Surg.* 2008;12(12):2066–2075; discussion 2075–2067.
158. Karmali S, McFadden S, Mitchell P, et al. Primary laparoscopic and open repair of paraesophageal hernias: a comparison of short-term outcomes. *Dis Esophagus.* 2008;21(1):63–68.
159. Schauer PR, Ikramuddin S, McLaughlin RH, et al. Comparison of laparoscopic versus open repair of paraesophageal hernia. *Am J Surg.* 1998 Dec;176(6):659–665.
160. Oelschlagel BK, Pellegrini CA, Hunter J, et al. Biologic prosthesis reduces recurrence after laparoscopic paraesophageal hernia repair: a multicenter, prospective, randomized trial. *Ann Surg.* 2006 Oct;244(4):481–490.
161. Granderath FA, Schweiger UM, Kamolz T, Asche KU, Pointner R. Laparoscopic Nissen fundoplication with prosthetic hiatal closure reduces postoperative intrathoracic wrap herniation: preliminary results of a prospective randomized functional and clinical study. *Arch Surg.* 2005;140(1):40–48.
162. Gryska PV, Vernon JK. Tension-free repair of hiatal hernia during laparoscopic fundoplication: a ten-year experience. *Hernia.* 2005 May;9(2):150–155.
163. Muller-Stich BP, Holzinger F, Kapp T, Klaiber C. Laparoscopic hiatal hernia repair: long-term outcome with the focus on the influence of mesh reinforcement. *Surg Endosc.* 2006;20(3):380–384.
164. Stadlhuber RJ, Sherif AE, Mittal SK, et al. Mesh complications after prosthetic reinforcement of hiatal closure: a 28-case series. *Surg Endosc.* 2009;23(6):1219–1226.

*This page intentionally left blank*



# PERSPECTIVE ON BENIGN ESOPHAGEAL DISEASE

John Hunter • Erin Gilbert

The preceding two chapters address benign diseases of the esophagus, including the diagnosis, evaluation, and management of hiatal hernia, motility disorders, and gastroesophageal reflux disease (GERD). In commenting on these entities, we follow the structure of these chapters.

## THE GIANT (PARAESOPHAGEAL) HIATAL HERNIA

Hiatal hernia (HH), as common as it is, is truly idiopathic. While HH is rare in Asian and African populations, exact predisposing features are difficult to pin down. In a North American population, GERD is more common among middle-aged males,<sup>1</sup> and giant hiatal hernias (often called paraesophageal hernias) are more common among elderly women.<sup>2</sup> The predisposing conditions for development of these large hernias in elderly women include diaphragmatic stress during pregnancy (years earlier), loss of abdominal domain, kyphosis (as a result of degenerative spine disease),<sup>3,4</sup> and greater longevity than their male counterparts. There may also be collagen ultrastructural defects responsible for hiatal hernia development, but there is insufficient evidence yet to confirm this hypothesis.<sup>5-8</sup>

The natural history of hiatal hernia may explain the changing symptoms seen in these patients. Early, small “sliding” hiatal hernias (type 1) predispose to GERD by separating the lower esophageal sphincter (LES) from the crural diaphragm, effacing the angle of His, and placing the LES in the thorax where negative intrathoracic pressure contributes to a reduced resting pressure relative to intra-abdominal pressure.<sup>9</sup> Over the years, and as the hernia defect grows larger, type 1 hiatal hernia may evolve into type 3 (aka mixed paraesophageal hernia) where the gastric fundus again resumes a position cephalad to the GE junction. This progression will often re-create a GE junction flap valve, and the patients will notice that GERD markedly improves. Replacing the GERD symptoms are symptoms of early satiety, postprandial chest pain, and iron deficiency anemia (in 30%) as a result of visible or occult gastric bleeding by erosions or ulcers at the level

of the diaphragm, known as *Cameron’s ulcers or erosions*.<sup>10,11</sup> Because of this natural progression, it is understandable why type 2 HH, in which the GE junction remains below the diaphragm, is distinctly rare and probably only occurs when the GE junction is so tightly anchored to the preaortic fascia that the development of a hiatal hernia only results in an attenuation of the phrenoesophageal ligament and cephalad displacement of the gastric fundus. An even rarer event is the para-hiatal hernia, where a diaphragmatic defect adjacent to the hiatus allows cephalad migration of the fundus. This is so rare that a true incidence has not been determined, but it presents as a type 2 HH and may be encountered once or twice in an esophageal surgeon’s career.

Despite evolving support for the strategy of “watchful waiting” for the asymptomatic hiatal hernia, the incidental detection of a giant HH will warrant questioning about upper GI symptoms. Close questioning reveals that most patients with this defect are either symptomatic or anemic. In either situation, repair is warranted. Far and away the most common approach to repair in the 21st century is laparoscopic hiatal hernia repair. There are no known advantages to open repair.<sup>12</sup> Esophageal lengthening is as easily performed with laparoscopic access, the wedge Collis gastroplasty,<sup>13</sup> as it is with thoracic access. As well, the recurrence rate of open and laparoscopic repair appears similar, despite the lack of randomized trials.

The “Achilles heel” of giant hiatal hernia repair (usually type 3, mixed paraesophageal hernia) is hiatal hernia recurrence. It was a bit of a shock to most laparoscopic surgeons when they began to see frequent hiatal hernia recurrences when they simple sutured repair (20–50%). The most common strategy to prevent recurrent HH is the placement of a large piece of bioprosthetic mesh in a U-shaped configuration, posterior to the esophagus. While early data suggested this technique to be much superior to sutured repair, late follow-up of a randomized controlled trial (RCT) demonstrated a disappointing greater than 50% recurrence rate with and without bioprosthesis.<sup>14</sup> Rather than abandoning the use of mesh, many surgeons are searching for a better bioprosthesis. New trials will better

tell us which bioprosthesis to use. Another strategy that appears to be of value is esophageal lengthening. When used selectively, in 20–40% of patients with giant hernias, HH recurrence rates seem to have decreased. Additionally, the symptomatic consequence of a small hiatal hernia recurrence is generally minimal, suggesting that it is a rare recurrence that will lead to reoperation.

The technique of repair described is little different from our approach, with a few exceptions. A split leg table is superior to low lithotomy stirrups, as the setup is simpler and the risk of lower extremity nerve compression and deep vein thrombosis (DVT) is decreased by the elimination of stirrup-related pressure points and knee flexion. We also use a mechanical scope holder, which increases operative efficiency and decreases surgeon fatigue, by maintaining a steady image. The pneumatic camera holder is attached to the right side of the bed, near the right hip.

Early in a surgeon's experience with laparoscopic giant HH repair, it was customary to recognize three problems: failure to identify the esophagus (leading to lighted dilator use), disorientation in the epiphrenic and lesser curvature fat, and bleeding from the lesser curvature vessels, including the left gastric artery. All of these problems may be solved by keeping the dissection focused on the diaphragmatic crura, detaching the hernia sac from the crura circumferentially and stripping the peritoneal sac from the lower posterior mediastinum. With this strategy, the esophagus becomes readily visible without the need for a lighted bougie, the fat is reduced by the reduction of the hernia sac, and the lesser curvature vessels are caudal to the field of dissection.

While the closure of a large defect may seem daunting, two strategies seem to allow closure of nearly all large hernias: (1) start posteriorly, as is described in this chapter, and (2) reduce the intra-abdominal pneumoperitoneum pressure to 5–8 mm Hg. With these steps it is almost never necessary to place anterior sutures, which are prone to tearing out because the diaphragm is often quite attenuated anteriorly, and the transverse orientation of the anterior crural arch makes closure technically difficult. Excessive anterior angulation of the distal esophagus is only a problem if the esophagus is not adequately mobilized off the aorta in the lower mediastinum.

## ESOPHAGEAL MOTILITY DISORDERS

The most common (albeit quite rare) esophageal motility disorder of surgical concern is achalasia. The etiology of achalasia outside of the tropics is unknown, but the disease is remarkably democratic, affecting young and old, male and female, and all ethnicities nearly equally.<sup>15,16</sup> Such a pattern strongly suggests the current hypothesis that an immunologic response to viral exposure is responsible for the observed myenteric neural degeneration.<sup>17,18</sup> While herpes virus has been implicated as the most likely “culprit” by some, the evidence is far from convincing.

The treatment of achalasia with laparoscopic Heller myotomy and partial fundoplication has become the predominant

primary therapy over the last 15 years. A recent randomized trial demonstrating equivalence of balloon dilation and Heller myotomy is unlikely to change our approach, as the balloon dilation strategy required intensive surveillance and frequent retreatment, as compared to laparoscopic Heller myotomy.<sup>19</sup> The only real “debate” in this field has been whether to fashion an anterior (Dor) or posterior (Toupet) fundoplication after dividing the LES. A recent randomized trial, closed due to lack of accrual, shows a slight, but not significant, advantage in diminished post-op reflux with the posterior fundoplication.<sup>20</sup> Nonetheless, worldwide, the anterior fundoplication is preferred as it requires less posterior dissection and it does not angle the GE junction anteriorly as the posterior fundoplication may do. The only “trap” of the Heller myotomy is carrying the myotomy too far above the diaphragm and inadequately on the stomach. If there is any esophageal outflow obstruction (from reflux stricture, angulation, or incomplete myotomy), the supradiaphragmatic myotomy site, lacking muscular support, may create an epiphrenic diverticulum, a result of the pressurized esophagus. Intraoperative endoscopy, immediately after the creation of the myotomy will identify easily if the myotomy extends to the dilated esophagus and onto the proximal stomach. A completely divided LES will open with air insufflations such that the endoscope “perched” in the distal esophagus can visualize the stomach through the previously spastic high-pressure zone, which will still appear as a waist.

Our performance of myotomy varies a bit from the technique described. Without a dilator in the esophagus (which may be hard to pass in the dilated esophagus), the anterior esophagus and upper 3 cm of stomach is cleared of all fat and neurovascular tissue such that the longitudinal muscle is clearly visible on the anterior wall of the esophagus (12 o'clock). We divide the epiphrenic fat pad with ultrasonic shears anteriorly, but we do not remove it as it makes a good handle for the first assistant. It is usually necessary to create a passage behind the anterior vagus nerve to remain on the anterior surface of the esophagus. When the esophagus and stomach are cleared off prior to myotomy, bleeding during the performance of myotomy is dramatically reduced. The submucosal plane is achieved just superior to the GE junction with Metzenbaum-type laparoscopic scissors. Firm lateral traction and countertraction by the surgeon's left hand pulling toward the liver and first assistant grasping a divided epiphrenic fat pad and pulling in the opposite direction will frequently disrupt the circular muscle with minimal sharp dissection. Once the submucosal plane is achieved, a blunt closed grasper can be run several centimeters up the esophagus in the submucosal plane, making subsequent division of the circular muscle quite easy with a pair of scissors. It is not necessary to use any thermal instruments (electrosurgery or ultrasonic dissector) near the mucosa. “Blanching” of the mucosa should be treated as a perforation *in situ* and should be oversewn as described in the text. The best strategy for dividing the proximal gastric portion of the LES is teasing distraction of the muscle fibers with two Hunter-type or Maryland-type graspers. It is critical that the mucosa be cleared of all circular smooth muscle, and blunt undermining

of the myotomy allows the cut edges of the muscle to retract out of sight behind the esophagus (frequently) just above the angle of His. Endoscopy is then performed as mentioned previously, and a “leak test” with air insufflation is then performed. Finally, a large (56–60F) Maloney dilator is passed by the surgeon or assistant to ensure that all circular muscle has been divided and undermining is adequate. Then, partial anterior (our favorite) or posterior fundoplication, as elegantly described in the previous chapter, is performed.

Failures of Heller myotomy are thankfully few, and the appropriate approach to failure has not been entirely defined. Some prefer balloon dilation, with a 3- to 3.5-cm balloon, but the same risk of perforation as with primary balloon dilation drives most surgeons to consider remyotomy. Esophagogastroduodenoscopy (EGD), to rule out cancer, ulcer, or stricture, should be complemented by video esophagram and high-resolution esophageal motility study. The appearance of a diverticulum at the supradiaphragmatic myotomy site should be addressed by an attempt at relieving the esophageal outflow obstruction. Rarely is diverticulectomy indicated and it will be ineffective at relieving recurrent dysphagia if the primary problem is not addressed. After complete LES myotomy, LES resting pressure should be less than 10 mm Hg. If the LES resting pressure is above 12–15, we usually recommend redo Heller myotomy. If the sphincter is already completely ablated (LES resting pressure <10), redo myotomy is unlikely to be successful. Under these circumstances, and especially with a mega or sigmoid esophagus, esophagectomy may be the best next step. The end-stage achalasia esophagus is amenable to minimally invasive surgery (MIS) esophagectomy techniques, but should not be treated with transhiatal esophagectomy or esophageal stripping, as the mediastinal blood vessels supplying a mega esophagus are much larger than normal and stripping may result in uncontrolled mediastinal bleeding.

The approach to other “named” esophageal motor disorders is a bit more controversial. As a general principle, nutcracker esophagus should not be treated with a long myotomy, (it won't help), and the dysphagia associated with diffuse esophageal spasm is best alleviated when the LES is divided. It may be unnecessary to take the myotomy as high as the top of the corkscrew appearance on contrast esophagram to achieve a successful outcome. In other words, the laparoscopic Heller myotomy and partial fundoplication may be the best operation for this condition. This is indeed a relief, as it may be difficult to tell vigorous achalasia from diffuse esophageal spasm (DES) in many patients. The treatment of esophageal diverticula is well described in the prior chapter. Because of the propensity of distal esophageal diverticulectomy staple lines to leak (up to 30% in some early studies), we have taken the following three steps that seem to have solved the problem: (1) perform a Heller myotomy to decrease intra-esophageal pressure, even in the absence of demonstrable LES hypertension, (2) sew the esophageal smooth muscle over the site of the staple line if possible and perform the myotomy 90 degrees away from the staple line and at least as far proximal as the proximal border of the diverticulum, and (3) leave the patient on a liquid diet for 7 days postoperatively to allow

staple line healing before introducing solid foods. Occasionally, safe and complete diverticulectomy can only be performed with thoracoscopic access when laparoscopic access cannot safely expose the proximal extent of the diverticulum.

## GASTROESOPHAGEAL REFLUX DISEASE

The diagnosis, evaluation, and management of gastroesophageal reflux disease (GERD) is extremely well covered in the text. I focus, in this commentary, on only four things: indications for surgery, proper use of the many tests available to assess the anatomy and pathophysiology of the esophagus and stomach, choice of an operation, and long-term effectiveness of laparoscopic antireflux surgery, especially as compared to treatment with proton pump inhibitor (PPI).

As has been pointed out, GERD is a very common condition, and a very small proportion of GERD patients elect to have antireflux surgery. While it is clear that the majority of patients are effectively managed with daily PPI, it is now recognized that as many as 40% of individuals will have persistent troublesome symptoms despite PPI treatment. Troublesome reflux is defined as mild GERD symptoms daily, or moderate to severe symptoms two to three times per week. Of all reflux symptoms, PPI therapy is most likely to control chest pain and heartburn. Only 17% of GERD patients will have regurgitation symptoms adequately controlled with PPI.<sup>21</sup> Therefore, we can define two populations poorly served with PPI for typical (esophageal) GERD symptoms, those with troublesome heartburn and chest pain despite adequately dosed PPI, and those with troublesome regurgitation that is unlikely to benefit from PPI. Both of these groups are ideally suited for laparoscopic antireflux surgery, as long as the diagnosis of GERD is secure, based on a standard evaluation.

The use of laparoscopic antireflux surgery for laryngopharyngeal reflux (LPR) may be equally effective, if used in the right patient. Because supraesophageal and/or laryngopharyngeal symptoms may be caused by so many common problems (eg, allergies, environmental factors, cigarette smoking, postnasal drip, infections), it is more difficult than it might appear to determine who truly has symptomatic LPR that would be improved by the elimination of all gastroesophageal reflux. While many technologies have been developed over the years to detect LPR, including dual-channel pH recording and nasopharyngeal pH recording, both these methods have proven difficult to validate. Two new promising methodologies, sputum pepsin measurement<sup>22</sup> and esophageal/nasopharyngeal impedance measurement, appear to be much more accurate for determining the presence of LPR and will probably become the test of choice in the near future to establish this diagnosis.

The preoperative evaluation of the patient with GERD is well described in the chapter outlined previously. Several years ago, we observed that all patients with heartburn responsive to PPI and erosive esophagitis, stricture, or Barrett's esophagus had an abnormal 24-hour pH study. Thus, we dropped routine pH testing in these patients as the diagnosis of GERD



was secure without pH testing in this population. Currently, we reserve pH testing for patients with no esophagitis, Barrett's esophagus or stricture, and for those with atypical symptoms. As mentioned previously, a pH study is not really needed prior to repair of the giant hiatal hernia, unless the patient's only symptom is heartburn and the EGD shows a pristine esophagus. This is rare indeed.

Operation choice for GERD is still a matter of some debate focused on the comparative long-term effectiveness of partial posterior (Toupet) fundoplication and total (Nissen) fundoplication. For many years the partial fundoplication was used in North America only for patients with ineffective or absent esophageal motility, as reflux control was less when a partial fundoplication was performed. When ineffective peristalsis is detected, it now appears that total and partial fundoplication create equivalent low levels of postoperative dysphagia. When peristalsis is completely absent (eg, achalasia or scleroderma), one should consider a partial fundoplication. Having said this, randomized data from Europe<sup>23</sup> suggest that the partial fundoplication provides equivalent reflux control in most GERD patients, regardless of motility pattern, while decreasing gas-related symptoms. Bottom line: either type of laparoscopic fundoplication may be performed. East of the Atlantic Ocean, perform a posterior partial fundoplication. On the west "bank" of the Atlantic Ocean, perform a total fundoplication.

Finally, there is great debate over the long-term effectiveness of laparoscopic Nissen fundoplication as compared to chronic PPI use. If one solely relies on the resumption of PPI as the indicator of fundoplication failure, the surgical failure rate may approach 30–40%, but physiologic assessment of these patients demonstrates that only 30% of this group will truly be refluxing, bringing the true failure rate (at 10 years) to about 10%.<sup>24</sup> Most patients who have had a good result from a first fundoplication will desire a redo fundoplication when the valve truly fails. The most common failure pattern is the recurrent HH, often a result of intra-abdominal stressors such as retching, straining, coughing, obesity, trauma, and excessive heavy lifting. The rate of reoperation following laparoscopic fundoplication performed by an expert is approximately 1%/year.

The comparative effectiveness of fundoplication to medical therapy has been tested in several randomized trials. When study entrance is restricted to those rendered asymptomatic on standard doses of PPI, surgery and medical therapy perform equivalently.<sup>25</sup> When the entrance criteria are broadened to include those with a partial response to PPI, fundoplication usually emerges as the most reliable and durable method for elimination of GERD symptoms.

## REFERENCES

- Menon S, Trudgill N. Risk factors in the aetiology of hiatus hernia: a meta-analysis. *Eur J Gastroenterol Hepatol*. 2011;23:133–138.
- Luketich JD, Nason KS, Christie NA, et al. Outcomes after a decade of laparoscopic giant paraesophageal hernia repair. *J Thorac Cardiovasc Surg*. 2010 Feb;139:395–404.
- Polomsky M, Siddall KA, Salvador R, et al. Association of kyphosis and spinal skeletal abnormalities with intrathoracic stomach: a link toward understanding its pathogenesis. *J Am Coll Surg*. 2009;208:562–569.
- Schuchert MJ, Adusumilli PS, Cook CC, et al. The impact of scoliosis among patients with giant paraesophageal hernia. *J Gastrointest Surg*. 2011;15:23–28.
- Asling B, Jirholt J, Hammond P, et al. Collagen type III alpha I is a gastro-oesophageal reflux disease susceptibility gene and a male risk factor for hiatus hernia. *Gut*. 2009;58:1063–1069.
- Curci JA, Melman LM, Thompson RW, Soper NJ, Matthews BD. Elastic fiber depletion in the supporting ligaments of the gastroesophageal junction: a structural basis for the development of hiatal hernia. *J Am Coll Surg*. 2008;207:191–196.
- Melman L, Chisholm PR, Curci JA, et al. Differential regulation of MMP-2 in the gastrohepatic ligament of the gastroesophageal junction. *Surg Endosc*. 2010;24:1562–1565.
- El Sherif A, Yano F, Mittal S, Filipi CJ. Collagen metabolism and recurrent hiatal hernia: Cause and effect? *Hernia*. 2006;10:511–520.
- Gordon C, Kang JY, Neild PJ, Maxwell JD. The role of the hiatus hernia in gastro-oesophageal reflux disease. *Aliment Pharmacol Ther*. 2004;20:719–732.
- Schieman C, Grondin SC. Paraesophageal hernia: clinical presentation, evaluation, and management controversies. *Thorac Surg Clin*. 2009;19:473–484.
- Wo JM, Branum GD, Hunter JG, Trus TN, Mauren SJ, Waring JP. Clinical features of type III (mixed) paraesophageal hernia. *Am J Gastroenterol*. 1996;91:914–916.
- Davis SS, Jr. Current controversies in paraesophageal hernia repair. *Surg Clin North Am*. 2008;88:959–978.
- Terry ML, Vernon A, Hunter JG. Stapled-wedge collis gastroplasty for the shortened esophagus. *Am J Surg*. 2004;188:195–199.
- Oelschlager BK, Pellegrini CA, Hunter JJ, et al. Biologic prosthesis to prevent recurrence after laparoscopic paraesophageal hernia repair: long-term follow-up from a multi-center, prospective, randomized trial. *J Am Coll Surg*. Presented at the 2010 American College of Surgeons 96th Annual Clinical Congress, Washington DC, October, 2010.
- Marlais M, Fishman JR, Fell JM, Haddad MJ, Rawat DJ. UK incidence of achalasia: an 11-year national epidemiological study. *Arch Dis Child*. 2011;96:192–194.
- Sadowski DC, Ackah F, Jiang B, Svenson LW. Achalasia: incidence, prevalence and survival. A population-based study. *Neurogastroenterol Motil*. 2010;22:e256–e261.
- Castagliuolo I, Brun P, Costantini M, et al. Esophageal achalasia: is the herpes simplex virus really innocent? *J Gastrointest Surg*. 2004;8:24–30.
- Lau KW, McCaughey C, Coyle PV, Murray LJ, Johnston BT. Enhanced reactivity of peripheral blood immune cells to HSV-1 in primary achalasia. *Scand J Gastroenterol*. 2010;45:806–813.
- Boeckxstaens GE, Annesse V, des Varannes SB, et al. Pneumatic dilation versus laparoscopic Heller's myotomy for idiopathic achalasia. *N Engl J Med*. 2011;364:1807–1816.
- Rawlings A, Soper NJ, Oelschlager B, et al. Laparoscopic Dor versus Toupet fundoplication following Heller myotomy for achalasia: results of a multicenter, prospective randomized-controlled trial. *Surg Endosc*. 2012;26(1):18–26.
- Kahrilas PJ, Howden CW, Hughes N. Response of regurgitation to proton pump inhibitor therapy in clinical trials of gastroesophageal reflux disease. *Am J Gastroenterol*. 2011;106(8):1419–1425.
- Wang L, Liu X, Liu YL, et al. Correlation of pepsin-measured laryngopharyngeal reflux disease with symptoms and signs. *Otolaryngol Head Neck Surg*. 2010;143:765–771.
- Mardani J, Lundell L, Engstrom C. Total or posterior partial fundoplication in the treatment of GERD: results of a randomized trial after 2 decades of follow-up. *Ann Surg*. 2011;253:875–878.
- Morgenthal CB, Shane MD, Stival A, et al. The durability of laparoscopic Nissen fundoplication: 11-year outcomes. *J Gastrointest Surg*. 2007;11:693–700.
- Galmiche JP, Hatlebakk J, Atwood S, et al. Laparoscopic antireflux surgery vs esomeprazole treatment for chronic GERD: the LOTUS randomized clinical trial. *JAMA*. 2011;305:1969–1977.

# CANCER OF THE ESOPHAGUS

*Simon Law*

## HISTORICAL PERSPECTIVES

One of the earliest descriptions of esophageal cancer was in the second century AD, when Galen described a fleshy obstructing growth in the esophagus, which was responsible for the inability to swallow and led to emaciation and death. In early Chinese literature, a patient who had esophageal cancer was described as “one suffers in autumn, and does not live to see the coming summer.” Improvement in treatment strategies has resulted in better outcome. However, most patients are still diagnosed at an advanced disease stage, with consequent poor prognosis. In 1877, Czerny was the first to successfully resect a cervical esophageal cancer and the patient lived for 15 months. Torek in 1913 performed the first successful transthoracic resection.<sup>1</sup> A 67-year-old woman had a squamous cell cancer of the midesophagus. Through a left thoracotomy, the esophagus was resected. The proximal cervical esophagus was brought out through an incision anterior to the sternocleidomastoid muscle and tunneled subcutaneously along the anterior chest wall, where a cutaneous esophagostomy was fashioned. The patient was fed via a rubber tube connecting the esophagostomy with a gastrostomy. The patient lived for 17 years.

The first successful resection of a thoracic esophageal cancer with reconstruction using the stomach was performed by Ohsawa, a Japanese surgeon in Kyoto, who reported the technique in 18 patients in 1933.<sup>2</sup> In 1946, Lewis described esophageal resection using a two-phase approach via a right thoracotomy and laparotomy.<sup>3</sup> Tanner independently also described the procedure in 1947.<sup>4</sup>

Although surgical resection has remained the mainstay treatment for esophageal cancer, recent years have seen a proliferation of treatment options especially with regards to different combinations of chemotherapeutic agents, radiotherapy and surgery. There has also been a divergence in the epidemiological pattern between Western and Eastern countries, which has made a major impact on the management of this disease.

## EPIDEMIOLOGY

Esophageal cancer is the eighth most common cancer worldwide and the sixth most common cause of death from cancer.<sup>5</sup> There is marked geographic variation in the incidence of cancer of the esophagus and, to some extent, among different ethnic groups within a common area. The disease is especially common in countries of the so-called “Asian esophageal cancer belt,” which stretches from eastern Turkey and east of the Caspian Sea through northern Iran, northern Afghanistan, and southern areas of the former Soviet Union, such as Turkmenistan, Uzbekistan, and Tajikistan, to northern China and India. High incidences are also found, in the Transkei province of South Africa and Kenya. In high-incidence areas, the occurrence of esophageal cancer is 50- to 100-fold higher than that in the rest of the world. It is the fourth most common cancer in China.<sup>6</sup> The age-standardized incidence rate of esophageal cancer in China is 27.4 per 100,000, compared to 10 in Japan, 7.9 in northern Europe and 7.6 in western Europe, 5.8 in North America, and 5.5 in Australia/New Zealand.<sup>5</sup> The provinces of Henan, Hebei, Shanxi in central/northern China, and areas within, such as Linxian and Cixian, have particularly high incidences.<sup>7,8</sup> The crude age-adjusted mortality is up to 140 per 100,000 and is the most common cause of cancer death.<sup>8</sup> Esophageal cancer most commonly presents in the sixth and seventh decades of life. In most countries it is a male-predominant disease, although in high-incidence areas, the male-to-female ratio approaches unity.

The most striking change in epidemiological pattern for esophageal cancer in the past three decades has been the shift from squamous cell cancers to adenocarcinomas of the lower esophagus and cardia in the Caucasian populations in Western countries. In the United States, squamous cell cancers predominate in African Americans, but the incidence of this cancer has seen a decline since the mid-1980s, while adenocarcinoma has been rising in incidence rapidly in the white population. The incidence of adenocarcinoma has surpassed squamous cell cancers since 1990.<sup>9</sup> Similar

changes have been observed in Europe and Australia. In Asia, however, esophageal cancers remain predominantly squamous cell in type and are mostly located in the mid-esophagus.<sup>10</sup>

Apart from squamous cell cancers and adenocarcinomas, other tumor types less commonly encountered include mucopapillary cancer,<sup>11</sup> adenosquamous cancer, small cell cancer,<sup>12</sup> basaloid squamous tumor,<sup>13</sup> sarcomatoid carcinoma, lymphoma, melanoma,<sup>14</sup> and various subtypes of stromal tumors.<sup>15</sup>

## ETIOLOGIC FACTORS

Various factors associated with the development of esophageal cancer are shown in (Table 17-1). Smoking and drinking as independent contributing factors are shown by prospective studies of patients who drink but do not smoke and, conversely, of patients who smoke but do not drink.<sup>16</sup>

Genetic predisposition may be important in the pathogenesis of esophageal squamous cell cancer. Case-controlled studies have identified familial aggregation; suggesting that the cancer may be heritable.<sup>17</sup> Mitochondrial studies have proved historical population migrations from central/northern to south-eastern China, where another high-incidence

area is found, again suggesting that hereditary factors may play a part.<sup>18,19</sup> Genetic polymorphism is important in individuals with chronic alcohol consumption.<sup>20</sup> Approximately 36% of East Asians show a physiologic response to drinking that includes facial flushing, nausea, and tachycardia. This facial flushing response is predominantly related to an inherited deficiency in the enzyme aldehyde dehydrogenase 2 (ALDH2). Alcohol is metabolized to acetaldehyde by alcohol dehydrogenase and the acetaldehyde is in turn metabolized by ALDH2 to acetate. Two main variants for ALDH2 exist, resulting from the replacement of glutamate with lysine at position 487. Only individuals homozygous with the glutamate allele have normal catalytic activity. Homozygotes with the lysine alleles have no detectable activity, while heterozygotes with Glu/Lys alleles have much reduced ALDH2 activity. The inability to fully metabolize acetaldehyde results in its accumulation in the body leading to the facial flushing and unpleasant side effects. Lys/Lys homozygotes could not tolerate much alcohol because of the intensity of the side effects, and so paradoxically they do not have increased risk because they simply would not consume significant amount of alcohol. Individuals who are glu/lys heterozygotes may become habitual drinkers because they could become tolerant to the side effects of alcohol and yet they had suboptimal catalytic activity and thus the acetaldehyde accumulates. These are the individuals most susceptible to the carcinogenic effects of alcohol consumption, which is related to acetaldehyde causing DNA damage and other cancer-promoting effects.<sup>21</sup> A simple questionnaire that elicits the history of a flushing response was shown to be useful in identifying at-risk individuals. They could be advised against drinking or to undergo screening endoscopy. The risk of developing cancer may be reduced or earlier diagnosis possible.<sup>22,23</sup>

For squamous cell cancer, in addition to drinking and smoking, dietary and environmental factors are important, especially in Asian countries. Nitrosamines and their precursors (nitrate, nitrite, and secondary amines), such as pickled vegetables, are incriminated.<sup>24</sup> Nutritional depletion of certain micronutrients, particularly vitamins A, C, E, niacin, riboflavin, molybdenum, manganese, zinc, magnesium, selenium, as well as fresh fruits and vegetables, together with an inadequate protein intake, predisposes the esophageal epithelium to neoplastic transformation.<sup>25</sup> Change in specific dietary habits, such as replacing traditional methods of food preservation and storage with refrigeration, together with consumption of vitamin-rich food, may have produced a drop in incidence rates in certain areas of China, especially in urban cities such as Shanghai.<sup>26</sup> Other dietary risk factors include consumption of hot beverages, opium smoking, chewing betel nuts, and maté drinking in South American countries.

The human papillomaviruses<sup>27</sup> and certain fungi belonging to the genera *Fusarium*, *Alternaria*, *Geotrichum*, *Aspergillus*, *Cladosporium*, and *Penicillium* are infective agents variably found to be associated with esophageal cancer.

Patients with other aerodigestive malignancies have a particularly high risk of developing squamous cell carcinoma (SCC) of the esophagus, presumably because of exposure

**TABLE 17-1: ETIOLOGIC FACTORS ASSOCIATED WITH PATHOGENESIS OF ESOPHAGEAL CANCER**

Factor	Squamous	
	Cell Cancer	Adenocarcinoma
Smoking	+++	+
Alcohol consumption	+++	–
Hot beverages	+	–
N-nitroso compounds, eg, pickled vegetables	+	–
Chewing betel nut	+	–
Maté drinking	+	–
Deficiencies of green vegetables, fruits, and vitamins	+	–
Low socioeconomic class	+	–
Fungal toxin or virus	+	–
History of radiation to mediastinum	+	+
Lye corrosive stricture	+	–
History of aerodigestive malignancy	+++	–
Plummer-Vinson syndrome	+	–
Achalasia	+	–
Obesity	–	++
Gastroesophageal reflux	–	+++
Barrett's esophagus	–	++++



to similar environmental carcinogens and “field cancerization.” Using esophageal cancer as the index tumor, multiple primary cancers were found in 9.5% of patients, of whom 70% were in the aerodigestive tract.<sup>28</sup> The overall incidence of synchronous or metachronous esophageal cancer in patients with primary head and neck cancer is estimated to be 3%.<sup>29</sup>

Diseases that are known to predispose to esophageal cancer are few. The risk from achalasia is estimated to be 7- to 33-fold, but symptoms of achalasia are present for an average of 15–20 years before the emergence of cancer.<sup>30</sup> Other diseases include lye corrosive strictures, Plummer-Vinson syndrome, tylosis, and celiac disease.

The reasons accounting for the dramatic rise in incidence of adenocarcinoma in Caucasian population is widely attributed to obesity, gastroesophageal reflux disease, and Barrett’s esophagus,<sup>31–33</sup> which are uncommon in Asian populations.<sup>34</sup> Gastroesophageal reflux disease affects up to 44% of the general population in the United States, and approximately 5–8% will develop Barrett’s esophagus,<sup>35</sup> with an estimated annual rate of neoplastic transformation of 0.5%.<sup>36</sup> Epidemiological data suggest a protective role of *Helicobacter pylori* against reflux. The high prevalence of *H. pylori* infection in Eastern populations may guard against reflux and Barrett’s esophagus, and may account for the differences in cancer cell type.<sup>37</sup> However, this association remains controversial.

## DIAGNOSIS

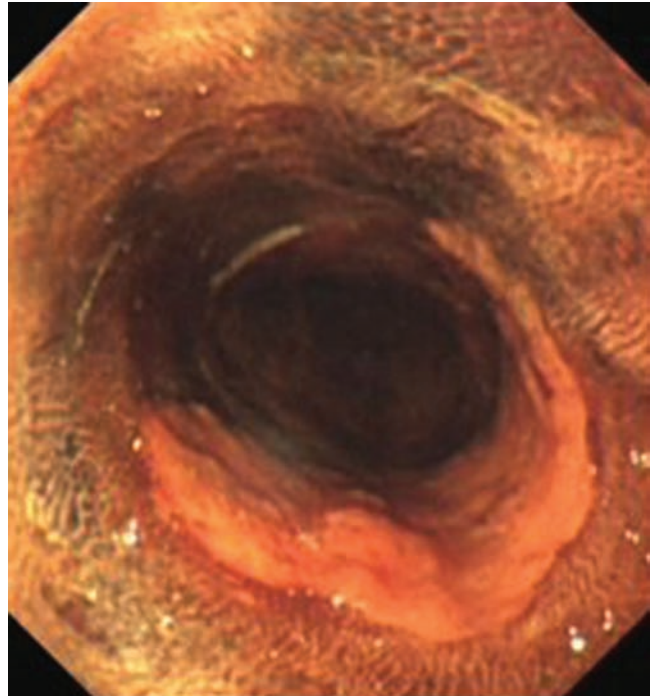
### Screening, Surveillance, and Prevention for Early Cancer

#### SQUAMOUS CELL DYSPLASIA AND CANCER

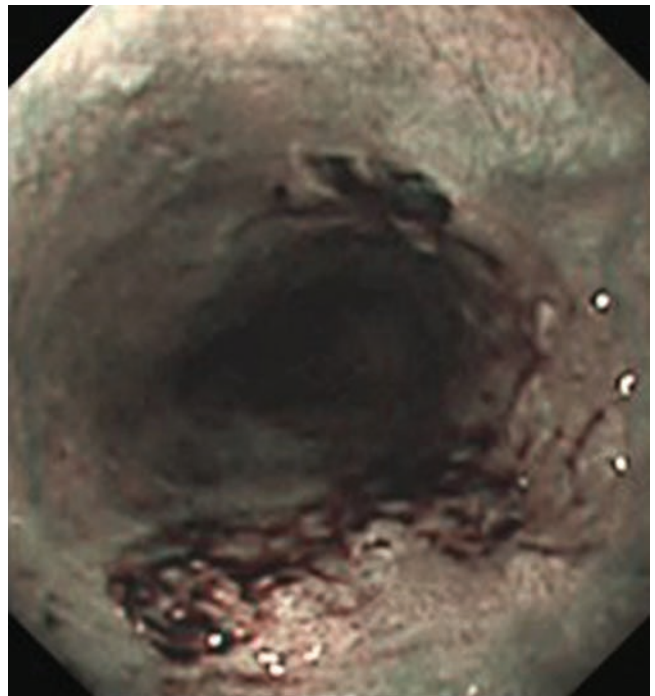Diagnosing esophageal cancer at its asymptomatic or early stage is crucial in improving prognosis, although at present this is only possible in the minority of patients. In high-incidence areas such as in China, abrasive cytology has been used for population screening. Two principal types of samplers have been used: an inflatable balloon developed in China<sup>38</sup> and an encapsulated sponge sampler developed in Japan.<sup>39</sup> When early-stage cancers are diagnosed by this method, excellent long-term results with 5-year survival rate approaching 90% and 25-year survival rate of 50% can be achieved, comparable to those of the normal population.<sup>40</sup>

Primary endoscopic screening with chromoendoscopy using Lugol’s iodine as a useful adjunct is carried out in high-incidence areas in China (Fig. 17-1). It has been shown that dysplastic lesions seen in the esophagus have a quantifiable risk of malignant transformation.<sup>41</sup> Long-term endoscopic screening studies are ongoing, integrating with early treatment and chemoprevention programs.<sup>42</sup>

Nutritional intervention trials were undertaken in Linxian in China for the general population in the 1980s as a form of chemoprevention. The trial was tested in 29,584 participants. At the end of 5-year intervention, the group receiving selenium,  $\beta$ -carotene and vitamin E was found to have a statistically



A



B

**FIGURE 17-1** A. Endoscopy using Lugol’s iodine stain. The unstained area is abnormal, showing an early squamous cell cancer of the esophagus. B. Narrow band imaging of the same lesion.



significant reduction in all causes of mortality and cancer death. However, mortality reduction in combined esophageal/gastric cardia cancer was 10%, not reaching statistical significance.<sup>43</sup> To date, no conclusive evidence is available for chemopreventive strategies for squamous cell esophageal cancer.

## BARRETT'S ESOPHAGUS AND ADENOCARCINOMA

For cancer due to Barrett's esophagus, screening and surveillance for early cancers have been controversial. Gastroesophageal reflux is prevalent; approximately 20% of adults have heartburn at least once per week, 5% of whom have Barrett's esophagus; thus a very substantial number of patients will require screening. However, the absolute risk of adenocarcinoma is low even in subgroups of patients with severe reflux symptoms. Moreover, 40% or more of patients with esophageal adenocarcinoma have no prior reflux symptoms and therefore would not be detected through screening programs targeted to those with such reflux symptoms.<sup>32</sup> Most patients with Barrett's esophagus also die from unrelated causes,<sup>44</sup> and the presence of Barrett's esophagus does not change life expectancy or overall survival.<sup>45,46</sup> These arguments, together with the high cost of endoscopy, mitigate against general population screening. Although retrospective studies have demonstrated survival benefits in patients with Barrett's esophagus undergoing surveillance,<sup>47,48</sup> these studies may have been biased because of selection, lead time, and length bias.<sup>49</sup> There is currently no confirmed evidence proving that screening or surveillance will lead to improved survival in patients with Barrett's esophagus.<sup>50</sup> Screening for Barrett's esophagus in the general population is not recommended. The use in selective populations at higher risk remains to be established.<sup>48</sup>

Despite the lack of clear evidence, individuals who are identified to have Barrett's esophagus should enter surveillance programs. Systemic four-quadrant, 2-cm biopsy protocol using large biopsy forceps is recommended.<sup>48</sup> Dysplasia is so far the only reliable indicator of risk development of invasive cancer. The recommendation given by the American College of Gastroenterology with regards to endoscopy interval and treatment is shown in Table 17-2. Endoscopy is performed every 3 years for those with no dysplasia and yearly

for low-grade dysplasia. Diagnosis of high-grade dysplasia implies the need for intervention (by surgery or endoscopic means), or intensive surveillance at 3-month intervals. If the latter is preferred, a four-quadrant, 1-cm protocol is required for diagnosis of early invasive cancer.

Endoscopy and systemic biopsies remains the gold standard for diagnosis of Barrett's esophagus, dysplasia, and early cancer. Other modalities such as cytology with or without fluorescence in situ hybridization (FISH), autofluorescence imaging, narrow band imaging, optical coherence tomography, and confocal laser endomicroscopy are investigational techniques aimed at enhancing diagnostic capabilities.<sup>51</sup>

Chemoprevention can potentially prevent Barrett's esophagus from developing into invasive cancer. Proton pump inhibitors (PPIs) and nonsteroidal anti-inflammatory drugs (NSAIDs) have drawn the most attention in recent years. Currently there are no data that directly support the use of PPIs to prevent cancer, although retrospective studies have shown decrease in development of dysplasia in long-term users.<sup>52</sup> For NSAIDs, a meta-analysis of pooled studies found a protective association between aspirin/NSAIDs and esophageal cancer of both histologic types.<sup>53</sup> However, a randomized controlled trial showed that celecoxib, a COX-2 inhibitor, was not more effective than placebo in patients with Barrett's esophagus and dysplasia in changing the proportion of biopsies with dysplasia.<sup>54</sup> An ongoing phase III randomized trial in the United Kingdom (AsPECT [Aspirin Esomeprazole Chemoprevention Trial] trail) aims at assessing whether intervention with aspirin results in decreased mortality or conversion rate from Barrett's metaplasia to adenocarcinoma or high-grade dysplasia.<sup>55</sup>

## Advanced Cancer

For symptomatic patients, the spectrum of symptoms varies depending on the extent of disease. Elderly patients who complain of dysphagia must be assumed to have esophageal cancer until proven otherwise, especially in high-risk areas. Patients with chronic reflux symptoms who develop dysphagia must have the diagnosis of tumor entertained in addition to a reflux stricture. In advanced cases the most common presenting symptom is dysphagia (80–95%), which is progressive in



**TABLE 17-2: DYSPLASIA GRADE AND SURVEILLANCE INTERVAL**

Dysplasia	Documentation	Follow-up
None	Two EGDs with biopsy within 1 y	Endoscopy every 3 y
Low grade	<ul style="list-style-type: none"> <li>• Highest grade on repeat EGD with biopsies within 6 mo</li> <li>• Expert pathologist confirmation</li> </ul>	1-y interval until no dysplasia × 2
High grade	<ul style="list-style-type: none"> <li>• Mucosal irregularity</li> <li>• Repeat EGD with biopsies to rule out invasive cancer within 3 mo</li> <li>• Expert pathologist confirmation</li> </ul>	Endoscopic resection Continue 3-mo surveillance or intervention based on results and patient

EGD, esophagogastroduodenoscopy.

Reproduced from Wang KK, Sampliner RE. Updated guideline 2008 for the diagnosis, surveillance and therapy for Barrett's esophagus. *Am J Gastroenterol*. 2008;103:788–797.

Reprinted by permission from Macmillan Publishers Ltd., copyright 2008.


**TABLE 17-3: COMPARISONS OF PATIENTS WITH SCC AND ADENOCARCINOMAS OF THE ESOPHAGUS ASIDE FROM ETIOLOGY: ASIA VERSUS WEST**

	Asia	West
Cell type	Squamous cell cancer	Adenocarcinoma
Location	Mid and lower esophagus	Lower esophagus/cardia
Comorbid diseases	<ul style="list-style-type: none"> <li>• Pulmonary disease</li> <li>• Cirrhosis</li> </ul>	Ischemic heart disease
Identifiable premalignant lesions	Dysplasia	Barrett's esophagus and dysplasia
Screening/surveillance	<ul style="list-style-type: none"> <li>• Balloon cytology</li> <li>• Endoscopy with Lugol's iodine</li> </ul>	Endoscopic surveillance for Barrett's esophagus and dysplasia
Surgical approaches	Predominantly transthoracic, two- and three-field lymphadenectomy Thoracoscopic ± laparoscopic surgery	Transthoracic/transhiatal, two-field or minimal lymphadenectomy Thoracoscopic ± laparoscopic <i>or</i> laparoscopic only
Prognosis	Worse?	Better?

SCC, squamous cell cancer.

severity. However, many patients delay seeking medical attention until severe dysphagia and weight loss have occurred. Regurgitation is common. In high-grade obstruction, this symptom may be worse at night when the patient lies supine. Fluid regurgitation can lead to bouts of coughing, aspiration, and even chest infection. Odynophagia (retrosternal pain associated with swallowing) is not uncommon. Hoarseness is the result of recurrent laryngeal nerve compression, either by the primary tumor or by metastatic lymph nodes.

The demographics of patients who suffer from squamous cell cancers and adenocarcinomas are different.<sup>56</sup> Patients with adenocarcinomas tend to be of higher socioeconomic class and have obesity-related chronic disease such as ischemic heart disease (Table 17-3). Examination of these patients therefore rarely reveals a wasted individual. Patients with squamous cell cancers are blue-collar workers, and general examination may show evidence of weight loss and muscle wasting. Chronic smoking and alcohol consumption leads to a higher prevalence of chronic lung disease and liver cirrhosis. The more proximal tumor location more easily predisposes to pneumonia from aspiration or the development of a tracheoesophageal fistula. Lymph nodes in the supraclavicular regions should be sought in all patients.

## TUMOR STAGING

### Staging System

Accurate staging serves to provide information for stage-directed therapies and is important for quality control for clinical trials.

The clinical staging system follows the American Joint Committee on Cancer (AJCC) staging or the International Union Against Cancer (UICC) TNM (tumor-node-metastasis) system, which are recently modified.<sup>57</sup> The definitions of TNM, tumor grade, level of tumors and nodal stations are shown in Tables 17-4 to 17-7 and Figs. 17-2 and 17-3.


**TABLE 17-4: DEFINITIONS OF TNM FOR ESOPHAGEAL CANCER**

#### T: Primary tumor

Tx	Tumor cannot be assessed
T0	No evidence of primary tumor
Tis	High-grade dysplasia
T1	Tumor invades lamina propria, muscularis mucosae, or submucosa
T1a	Tumor invades lamina propria or muscularis mucosae
T1b	Tumor invades submucosa
T2	Tumor invades into muscularis propria
T3	Tumor invades adventitia
T4	Tumor invades the adjacent structures
T4a	Resectable tumor invading pleura, pericardium, or diaphragm
T4b	Unresectable tumor invading other adjacent structures, such as aorta, vertebral body, trachea, etc

#### N: Regional lymph nodes<sup>a</sup>

NX	Regional nodal status cannot be assessed
N0	No regional lymph node involvement
N1	Regional lymph nodes metastases involving 1–2 nodes
N2	Regional lymph nodes metastases involving 3–6 nodes
N3	Regional lymph nodes metastases involving ≥7 nodes

#### M: Distant metastases

MX	Distant metastases cannot be assessed
M0	No distant metastasis
M1	Distant metastasis

TNM, tumor-node-metastasis.

<sup>a</sup> Regional nodes extend from the neck to the celiac nodes.

**TABLE 17-5: DEFINITIONS OF GRADE FOR ESOPHAGEAL CANCER**

Histologic grade (G) <sup>a</sup>	
GX	Grade cannot be assessed—stage grouping as G1
G1	Well differentiated
G2	Moderately differentiated
G3	Poorly differentiated
G4	Undifferentiated—stage grouping as G3 squamous

<sup>a</sup> Highest histologic grade on biopsy or resection specimen is used. If a tumor is mixed histologic type, it shall be recorded as squamous cell cancer. If grade is not available, it should be recorded as GX and stage grouped as a G1 cancer. G4, undifferentiated cancers, should be recorded as such and staged grouped similar to G3 squamous cell carcinoma.

This recently modified TNM system differs from the previous versions mainly on (1) the regional nodes encompass areas from the neck, through the mediastinum to the upper abdomen, including the celiac nodes; previously used M1a and M1b categories are deleted; (2) the separation of N1 to N3 depends on the number of nodes involved; (3) squamous cell cancers are stage-grouped differently to adenocarcinoma; and (4) location of tumor and grade of differentiation are also taken into consideration. Previously, it has been uncertain whether adenocarcinoma of the cardia should be staged as gastric or esophageal cancer. In this new edition, tumors whose epicenter is in the lower thoracic esophagus, gastro-esophageal junction (GEJ), or within the proximal 5 cm of

**TABLE 17-6: STAGE GROUPINGS FOR SQUAMOUS CELL CARCINOMA**

Stage	T	N	M	G	Location
0	In situ (HGD)	0	0	1	Any
IA	1	0	0	1	Any
IB	1	0	0	2–3	Any
	2–3	0	0	1	Lower
IIA	2–3	0	0	1	Upper, middle
	2–3	0	0	2–3	Lower
IIB	2–3	0	0	2–3	Upper, middle
	1–2	1	0	Any	Any
IIIA	1–2	2	0	Any	Any
	3	1	0	Any	Any
	4a	0	Any	Any	Any
IIIB	3	2	0	Any	Any
IIIC	4a	1–2	0	Any	Any
	4b	Any	0	Any	Any
	Any	N3	0	Any	Any
IV	Any	Any	1	Any	Any

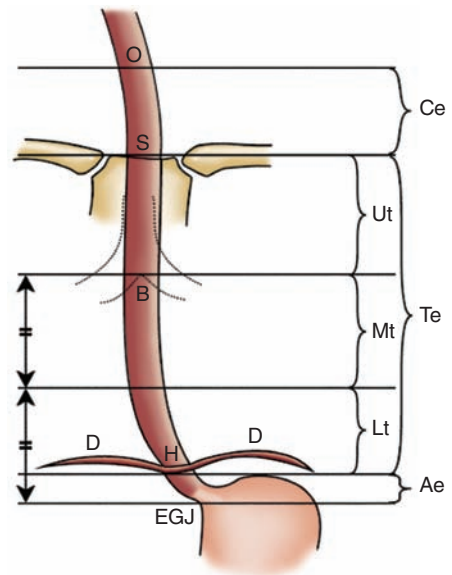
HGD, high-grade dysplasia.

**TABLE 17-7: STAGE GROUPINGS FOR ADENOCARCINOMA**

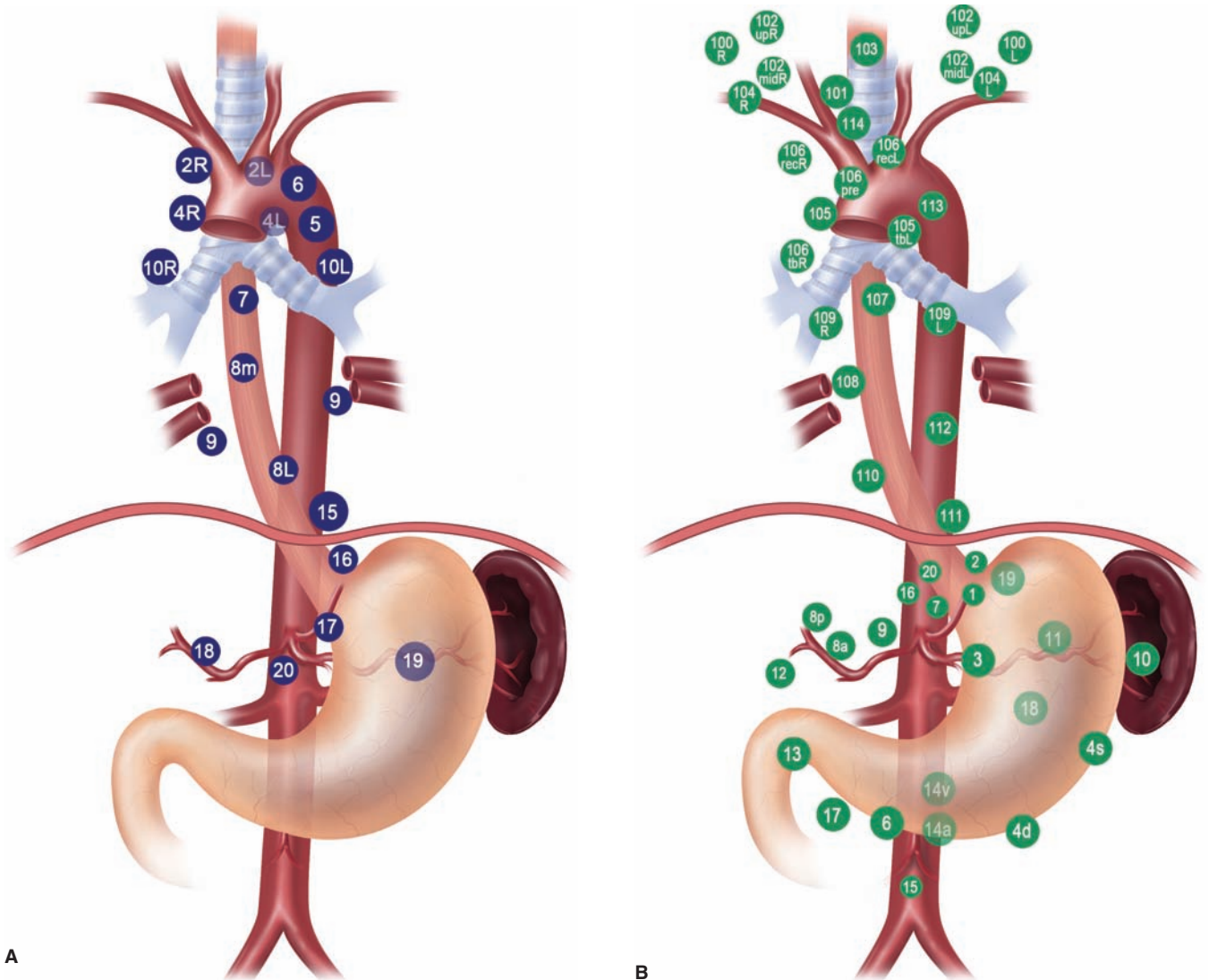
Stage	T	N	M	G
0	Tis (HGD)	0	0	1
IA	1	0	0	1–2
IB	1	0	0	3
	2	0	0	1–2
IIA	2	0	0	3
IIB	3	0	0	Any
	1–2	1	0	Any
IIIA	1–2	2	0	Any
	3	1	0	Any
	4a	0	0	Any
IIIB	3	2	0	Any
IIIC	4a	1–2	0	Any
	4b	Any	0	Any
	Any	N3	0	Any
IV	Any	Any	1	Any

HGD, high-grade dysplasia.

the stomach (cardia) that extend into the GEJ or esophagus are stage-grouped similar to adenocarcinoma of the esophagus and not that of the stomach. Cancers with their epicenter in the stomach greater than 5 cm distal to the GEJ, or those within 5 cm of the GEJ but not extending into the



**FIGURE 17-2** Description of the different levels of esophageal tumor. Ae, abdominal esophagus; B, tracheal bifurcation; Ce, cervical esophagus; D, diaphragm; EGJ, esophagogastric junction; H, hiatus; Lt, lower third; Mt=middle third; O, esophagus; S, sternal notch; Te, thoracic esophagus; Ut, upper third.



**FIGURE 17-3** **A.** Lymph node stations according to the American Joint Committee on Cancer (AJCC) classification. **B.** Lymph node stations according to the Japan Esophageal Society.

GEJ or esophagus, are stage-grouped using the gastric cancer staging system.

Siewert's classification aims at classifying tumors that are located 5 cm proximal and distal to the GEJ into types I to III (esophageal, cardiac, and subcardiac), depending on the relative extent of involvement of either the esophagus or stomach (Fig. 17-4). The three types of cancers are different in patient demographics, possible etiology, histopathologic features, and prognosis.<sup>58</sup> This classification is useful clinically but is not considered in the new staging system.

The Japan Esophageal Society further classifies T1a/T1b tumors into finer categories; as there are important therapeutic implications (Table 17-8). This is discussed in later sections.

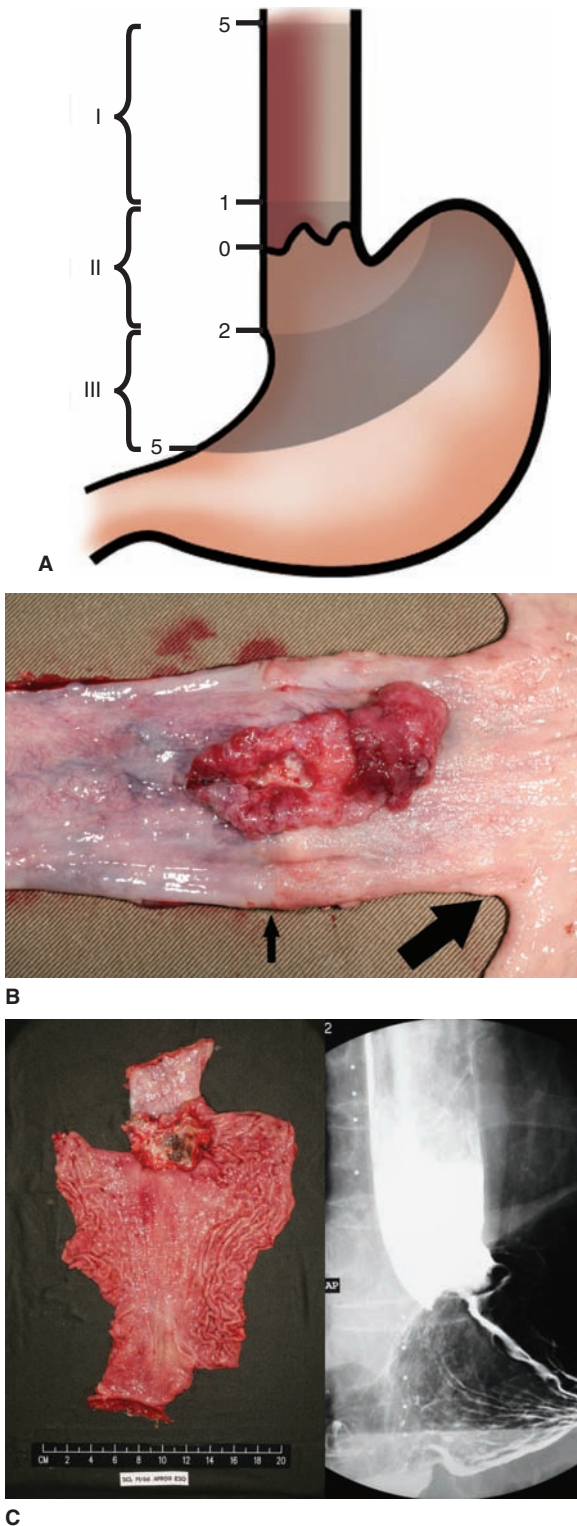
## METHODS OF STAGING

Apart from physical examination and simple chest radiograph, specific methods in clinical staging include barium contrast studies, bronchoscopy, computed tomography (CT) scan, percutaneous ultrasound of cervical lymph nodes  $\pm$  fine-needle aspiration (FNA) cytology, endoscopic ultrasound (EUS)  $\pm$  FNA, 2-<sup>[18F]</sup> fluoro-2-deoxy-D-glucose (FDG) positron emission tomography (PET) scan, and laparoscopy and/or thoracoscopy.

### Barium Contrast Studies

Typical features on a contrast barium study include mucosal irregularity and shouldering, narrowing of the lumen and





**FIGURE 17-4** **A.** Classification of adenocarcinomas around the gastroesophageal junction (GEJ) according to Siewert. Type I, esophageal; type II, cardiac; type III, subcardiac. **B.** A type I adenocarcinoma arising from Barrett's esophagus. The large arrow points at the gastroesophageal junction (GEJ) while the small arrow points at the squamocolumnar junction. **C.** A type II cardia cancer removed as a total gastrectomy specimen and its corresponding barium contrast study. There is no evidence of Barrett's esophagus.

### TABLE 17-8: DIVISIONS OF T1 TUMORS ACCORDING TO THE JAPAN ESOPHAGEAL SOCIETY

TX	Depth of tumor invasion cannot be assessed
T0	No evidence of primary tumor
T1a	Tumor invades mucosa
T1a-EP	Carcinoma in situ (Tis)—formerly corresponds to M1
T1a-LPM	Tumor invades lamina propria mucosa (LPM)—formerly corresponds to M2
T1a-MM	Tumor invades muscularis mucosa (MM)—formerly corresponds to M3
T1b	Tumor invades submucosa
SM1	Tumor invades the upper third of the submucosal layer
SM2	Tumor invades the middle third of the submucosal layer
SM3	Tumor invades the lower third of the submucosal layer

In endoscopically resected specimens, because the full thickness of the submucosa extending into the muscularis propria is not available for examination, a tumor invading the submucosa to a depth of 200  $\mu$ m is classified as SM1, while a tumor invading more than 200  $\mu$ m is classified as SM2.

proximal dilation of the esophagus (Fig. 17-5). Tortuosity, angulation, axis deviation from the midline, sinus formation, and fistulization to the bronchial tree are signs indicative of advanced tumor that has traversed the adventitia and involved the neighboring fixed organs.<sup>59</sup> With the availability of other staging modalities, barium studies are becoming less essential.

## Bronchoscopy

Use of the fiberoptic endoscope allows histologic confirmation of the cancer by biopsy or brush cytology. Flexible bronchoscopy is performed to assess tumor involvement of the tracheobronchial tree, especially for tumors in the middle and upper esophagus. Signs of involvement include a widened carina, external compression, tumor infiltration, and fistulization. The last two signs contraindicate resection.<sup>60</sup> Gross macroscopic bronchoscopic appearance may not be accurate, and biopsy and brush cytology is recommended.<sup>61</sup>

## Computer Tomography Scan

The main value of CT scan in staging of esophageal cancer lies with its ability to detect distant disease, such as that in liver, lungs, bone, and kidneys. When metastasis to the liver is more than 2 cm, sensitivity is 70–80% although it drops to approximately 50% when it is less than 1 cm.<sup>62</sup> Solitary lung metastases are rare in patients presenting with esophageal carcinoma<sup>63</sup> and thus, when seen on CT, are more likely to be primary lung cancers or benign nodules and should be investigated as such.

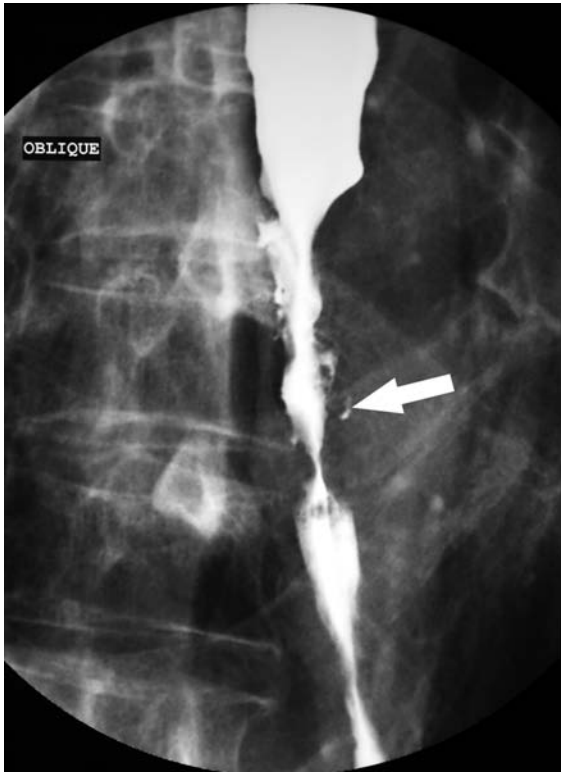

FIGURE 17-5 Barium contrast study showing a stenotic tumor. Mucosal irregularities and proximal dilation with retention of contrast material is evident. A sinus often indicates infiltrative disease (arrow).

In the diagnosis of T4 disease, obliteration of the fat plane between the esophagus and the aorta, trachea and bronchi, and pericardium is suggestive of invasion, but the paucity of fat in cachectic patients makes this criterion unreliable. When the area of contact between the esophagus and the aorta extends for more than 90 degrees of the circumference, an 80% accuracy of infiltration was reported,<sup>64</sup> but this is by no means absolute and the accuracy is inferior to that of EUS.

The sensitivity of detecting mediastinal and abdominal nodal involvement is suboptimal with CT scans because only size alone can be used as diagnostic criterion. However, normal-sized lymph nodes may contain metastatic deposits and enlargement of lymph nodes may be due to reactive and inflammatory hyperplasia. Studies using high-resolution helical CT scanning have demonstrated sensitivities of 11–77% as well as specificities of 71–95% for detection of regional nodal disease.<sup>65,66</sup> CT scanning is nowadays commonly performed together with PET scanning; a composite picture is created in the same setting to correlate more accurate anatomy with metabolic uptake (Fig. 17-6). Experience with magnetic resonance imaging (MRI) has shown limitations similar to those of CT.<sup>67</sup>

## Endoscopic Ultrasound and Percutaneous Ultrasound

Endoscopic ultrasound (EUS) is the only imaging modality able to distinguish the various layers of the esophageal wall, usually seen as five alternating hyper- and hypochoic layers

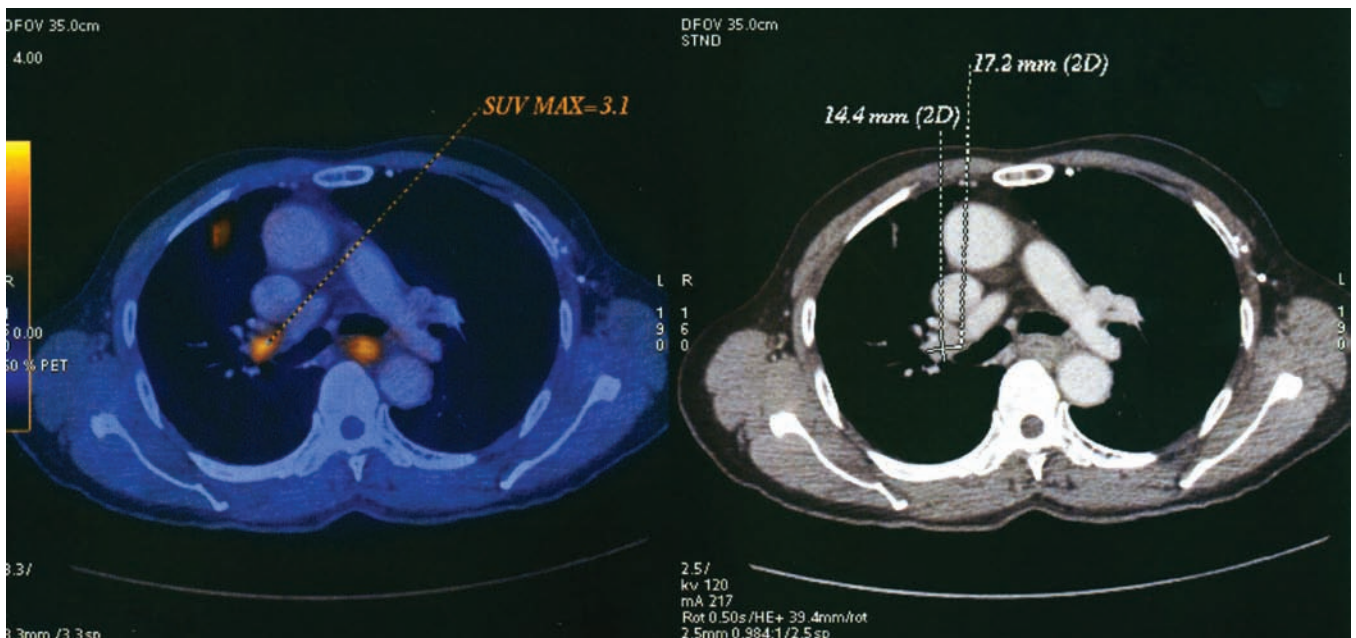
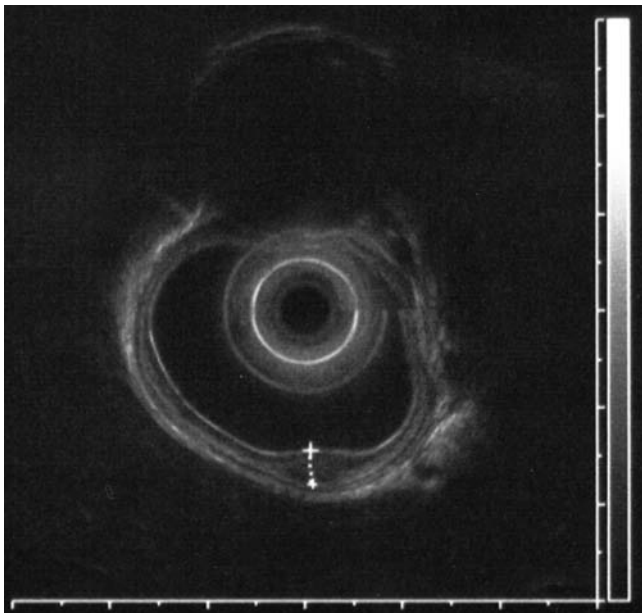


FIGURE 17-6 Combined PET and CT image: in addition to size of lymph nodes, the standard uptake value often will help to determine if the lymph node is involved by cancer. A right pulmonary hilar node identified with its corresponding PET image. Standard uptake value (SUV) uptake was 3.1.



**FIGURE 17-7** Endoscopic ultrasound (EUS) picture of an early tumor confined to the mucosa. Five layers of the esophagus could be seen; the two dark layers are the muscularis mucosae (inner layer) and muscularis propria (outer layer). In this tumor, the hyperechoic layer of the submucosa has not been reached. The tumor is at 6 o'clock. This lesion was removed with endoscopic submucosal dissection (ESD) technique.

(Fig. 17-7). The accuracy of EUS for tumor and nodal staging averages 85 and 75%, respectively, compared to 58 and 54% for CT scanning.<sup>68</sup> One problem with EUS is the nontraversable tumor stricture, which occurs in about one-third of patients.<sup>69,70</sup> Early studies showed that predilation may result in up to a 25% chance of perforation.<sup>71,72</sup> More recent results suggest that predilation is safe, and the success rate of complete examination depends on the size of dilation—36% for 11–12.8 mm, and 87% for 14–16 mm.<sup>73</sup> An alternative is to use miniaturized ultrasound catheter probes passed through the working channel of a conventional endoscope, which can achieve comparable accuracy to conventional EUS.<sup>74</sup>

Echo features of lymph nodes that suggest malignant involvement include echo-poor (hypoechoic) structure, sharply demarcated borders, rounded contour, and size greater than 10 mm, in increasing order of importance.<sup>75</sup> A collective review showed that the overall accuracy of staging nodal disease was 77%.<sup>68</sup> The accuracy of EUS may differ for different lymph node locations and is related to the depth of penetration of EUS (about 3 cm). It is best for detecting paraesophageal nodes, and sensitivity varies inversely with the axial distance of the nodes from the esophageal axis.<sup>76</sup> The ability to perform EUS-guided FNA cytology of suspicious nodes (such as celiac nodes) is another factor that makes EUS superior to CT scanning.<sup>77</sup>

Percutaneous ultrasound is particularly useful for obtaining FNA biopsies of cervical lymph nodes. In one large study in 519 patients, cervical lymph node metastasis was detected

in 30.8% of patients (160/519). The sensitivity, specificity, and accuracy of US diagnosis in patients who underwent subsequent cervical lymphadenectomy were 74.5%, 94.1%, and 87.6%, respectively. In those who did not undergo neck dissection, the chance of cervical nodal recurrence was low, at less than 5%.<sup>78</sup>

Information gained by combining preoperative cervical ultrasound and EUS can be highly prognostic. In one study, when the number of metastatic nodes was stratified into subdivisions of 0, 1–3, 4–7, and 8 or more, the number of involved lymph nodes was prognostically similar to the eventual subdivisions as determined by histological diagnosis.<sup>79</sup> However, both percutaneous and EUS are highly operator-dependent, and their meticulous application is required to produce these results.

## FDG-PET Scans

PET scan is gaining popularity in esophageal cancer staging (see Fig. 17-6).<sup>80,81</sup> For the detection of the primary tumor, the sensitivity of PET ranges from 78 to 95% with most false-negative tests occurring in patients with T1 or small T2 tumors.<sup>65,82</sup> Adenocarcinomas of the GEJ and proximal stomach sometimes show limited or absent FDG accumulation regardless of tumor volume (FDG nonavidity). Some investigators observed this phenomenon in as many as 20% of these patients, which seems to be related to the diffusely growing subtype and poorly differentiated tumors.<sup>83</sup>

PET does not provide definition of the esophageal wall and thus has no value in T stage. For locoregional nodal metastases, its spatial resolution is also insufficient to separate the primary tumor with juxtatumoral lymph nodes because of interference from the primary tumor, and thus most studies demonstrated poor sensitivity.<sup>82,84</sup> This is especially true for nodes in the middle and lower mediastinum, where most primary tumors are found. In one study, the sensitivities of PET for detecting cervical, upper thoracic, and abdominal nodes were 78%, 82%, and 60%, respectively, but was only 38 and 0% respectively for the mid- and lower mediastinum.<sup>65</sup> Specificity of PET in detecting regional nodes is usually much better, reaching 95–100% in some studies.<sup>82,84</sup> The low rate of false-positive findings is important in preoperative staging.

A meta-analysis of 12 publications on PET scanning in esophageal cancer showed that the pooled sensitivity and specificity for the detection of locoregional metastases were 0.51 (95% CI, 0.34–0.69) and 0.84 (95% CI, 0.76–0.91), respectively. For distant metastases, the corresponding figures were 0.67 and 0.97. When two studies (out of 11) that had particularly low sensitivities for detection of distant metastases were excluded (probably because they included more early tumors), the pooled sensitivity improved to 0.72 and specificity to 0.95.<sup>85</sup> This study highlights again that the accuracy of PET in locoregional nodes is only moderate. EUS-FNA is superior in this regard. PET is more useful for picking up distant metastases.



A multi-institutional trial with a primary objective to evaluate whether PET could detect metastatic disease that would preclude esophagectomy was recently published. Patients who had operable disease after conventional staging (including CT scan) were evaluated with PET scan. Of 189 patients, only 9 (4.8%) had M1b disease found and confirmed as true positives and were excluded from surgery. An additional 3.7% had unconfirmed M1b disease. However, apparent M1 findings by PET were also found in at least 3.7% of patients.<sup>86</sup> The true value of PET scan may therefore be limited and cost-effectiveness should be evaluated further.

## Thoracoscopy and Laparoscopy

Thoracoscopy and laparoscopy have their advocates. Thoracoscopic staging usually involves a right-sided approach, with opening of the mediastinal pleura from below the subclavian vessels to the inferior pulmonary vein with lymph node sampling. Laparoscopic staging can include celiac lymph node biopsy and the use of laparoscopic ultrasound for detecting liver metastases. One multi-institutional study (CALGB 9380) reported results in 113 patients, and the strategy was feasible in 73% of patients. Thoracoscopy and laparoscopy identified nodes or metastatic disease missed by CT scan in 50% of patients, by MRI in 40%, and by EUS in 30%. Although no deaths or major complications occurred, it did involve a general anesthesia, one-lung anesthesia, a median operating time of 210 minutes, and a hospital stay of 3 days.<sup>87</sup> Laparoscopy could be used in diagnosing metastases (especially peritoneal spread) or identifying unsuspected cirrhosis, which may contraindicate resection, and it could be performed as a preliminary procedure during the time of planned esophagogastrectomy. Its main contribution would be in lower esophageal and cardiac adenocarcinoma, while its value is expected to be minimal for more proximally located tumors.<sup>88</sup> Given their invasiveness, thoracoscopy and laparoscopy should be reserved for cases in whom positive confirmation of metastatic disease not otherwise obtainable is essential in deciding on treatment.

## TREATMENT

### Stage-Directed Therapy

In the past, esophageal cancer was treated by surgical resection alone, radiotherapy, or use of a plastic stent for palliation. Increasing choices and combinations of therapeutic options have made staging important; the treatment for early and advanced cancers should be individualized.

### Treatment for Early Squamous Cell Cancers

Early tumors include T1a-EP, LMP, MM and T1b-SM1, SM2, and SM3 lesions as defined in Table 17-8. The distinction is important because of the risk of nodal metastases.

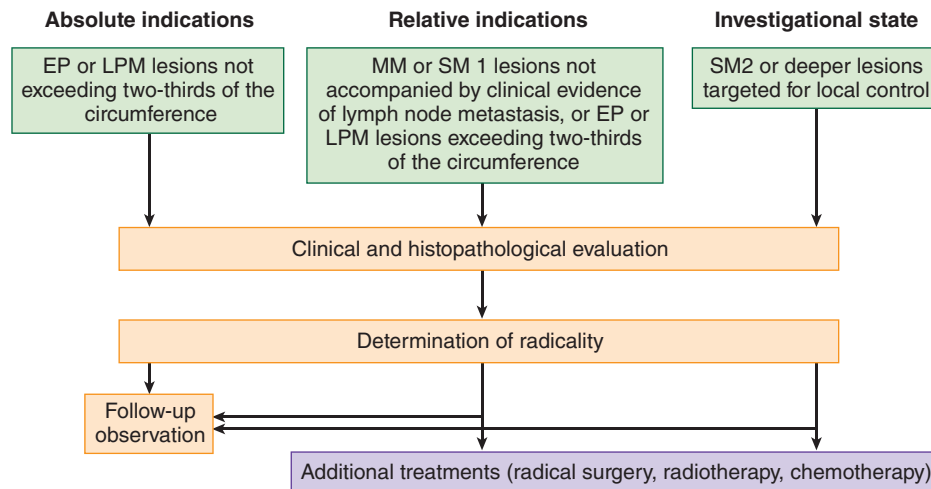
The incidence of lymph node involvement in T1a-EP, T1a-LMP, and T1a-MM tumors are 0%, 3.3%, and 12.2%, respectively. For T1b-SM1, SM2, and SM3 lesions, the respective incidences of lymph node involvement are 26.5, 35.8, and 45.9%, respectively.<sup>89</sup> For mucosal cancers 5-year survival rates are 80–100% and for submucosal cancers 50–65%.

T1a-EP or LMP tumors are amenable to endoscopic resection because they carry a very small risk of nodal metastases and endoscopic resection is a sufficiently radical treatment. Because circumferential resection is likely to be associated with cicatricial stenosis, this procedure is indicated for lesions not exceeding two-thirds of the circumference. Lesions reaching T1a-MM or T1b-SM1 (200  $\mu$ m deep from the muscularis mucosa) may be associated with nodal metastases, but endoscopic mucosal resection (EMR) is feasible for patients without clinical evidence of lymph node metastasis (relative indication). Lesions showing deep invasion (T1b-SM2 or SM3) are associated with metastasis at a frequency of about 30–50% and are treated in the same manner as advanced cancers. Recommendations by the Japan Esophageal Society with regards to endoscopic resection are shown in Fig. 17-8.<sup>90</sup> Other unfavorable features for endoscopic resection in addition to depth of infiltration and extent of involvement include poorly differentiated tumor and findings of lymphovascular infiltration in the resected specimen.

There are many techniques of EMR but the most commonly performed is perhaps EMR-cap EMR-C. Using a cap-fitted forward-viewing endoscope, saline is injected into the submucosal layer in order to raise the lesion from the deeper wall layer. The lesion is sucked into the cap and a snare wire that has been prelooped is used to snare the lesion. The strangulated mucosa is cut by blend-current electrocautery. In a series of 250 patients, 72% had absolute indications when EMR was performed for T1a-EP or LPM lesions. In these patients, no local or distant metastases occurred during follow-up. The 5-year survival rate was 95%. All those who died within 5 years died of non-cancer-related causes.<sup>91</sup>

Endoscopic submucosal dissection (ESD) techniques are now preferred by many endoscopists. In this method, the lesion's border is first marked, and like EMR, submucosal injection is carried out. Various types of fluid have been used for injection to delay dispersion, for example glycerol, hyaluronic acid, hypertonic saline, and mannitol. Through-the-scope "knives" such as hook, needle, flex, or insulated tip (with ceramic) knives are used to cut out the lesions. This technique is thus not limited by the size of the cap in EMR-C and can be used to remove large lesions of substantial length in one piece, thus achieving the aim of en bloc removal. The depth of resection can also be deeper and controlled, often revealing the underlying muscularis propria. Positive margins are less likely, and an en bloc specimen is more suitable for more complete pathological examination. The skill to perform ESD, however, is much more difficult to acquire compared to EMR. Complications common to both EMR and ESD include bleeding (which is usually minor), perforation (which can be prevented by adequate submucosal saline injection and can be treated sometimes with hemoclip), and stenosis (which tends to occur when the lesion is large).





**FIGURE 17-8** Recommendation by the Japan Esophageal Society for indications for endoscopic resection of esophageal cancer. (Reproduced from Guidelines for diagnosis and treatment of carcinoma of the esophagus part I. Japan Esophageal Society. *Esophagus*. 2008;5:61–73, with kind permission from Springer Science + Business Media.)

## Treatment for High-Grade Dysplasia and Early Adenocarcinoma

Barrett's high-grade dysplasia, synonymous with intraepithelial cancer, is the last preinvasive stage in the metaplasia-dysplasia-cancer sequence. Options of treatment include intensive surveillance, mucosal ablation, and esophagectomy.

### INTENSIVE SURVEILLANCE

Proponents of endoscopic surveillance claim that such a strategy can diagnose invasive cancer at an early stage and treatment can be delayed until then without compromising prognosis. The high morbidity and mortality rate of esophagectomy is also thought by some to be a deterrent to immediate surgical resection. Opponents of surveillance observe that most patients with high-grade dysplasia will have an invasive adenocarcinoma identified during the following 5 to 10 years, in approximately 25% of patients at 1.5 years, 50% at 3 years, and up to 80% 8 years later.<sup>31</sup> High-grade dysplasia is currently the only reliable marker in preinvasive cancer detection, but interobserver concordance is suboptimal in distinguishing invasive and noninvasive lesions.<sup>32</sup> When esophagectomy is carried out in patients who have high-grade dysplasia, invasive cancer is identified in the surgical specimen in up to 42% of patients, even when patients have been recruited in surveillance programs.<sup>33</sup> More recent evidence, however, suggests that this figure is an overestimation; a meta-analysis of histologic findings after esophagectomy for high-grade dysplasia revealed invasive adenocarcinoma (at least submucosal cancer) in 12.7% and most of these had visible lesions at endoscopy, a known risk for invasive cancer.<sup>34</sup> In the absence of visible lesions, this figure is as low as 6.7%.<sup>35</sup> Most would regard the finding of high-grade dysplasia as a threshold for intervention. In patients who have visible lesions, such as raised nodules and not just a flat Barrett's

mucosa, endoscopic resection is recommended to ensure no invasive cancer is present.<sup>48</sup> If surveillance is to be carried out, the American College of Gastroenterology recommends three-monthly surveillance.<sup>48</sup> The intensity that is required in surveillance of patients with high-grade dysplasia does make this an unattractive option.

### ENDOSCOPIC THERAPIES

The rationale of endoscopic mucosal treatments is that the incidence of nodal metastases is low in high-grade dysplasia or T1a (intramucosal) cancers, and therefore treating the mucosal disease alone will result in cure. In T1a lesions, the rate of nodal metastases is low, reported as 0–6%. Once the submucosa is invaded (T1b lesions), this figure rises to around 20%.<sup>96,97</sup> EMR methods can be used to locally resect visible lesions in Barrett's esophagus. The largest series on the use of localized EMR was reported by Ell and colleagues. One hundred patients were treated; all had mucosal lesions of a diameter up to 20 mm, without lymphovascular invasion proven by histology of the resected specimen and histologic grades G1 and G2 arising in Barrett's metaplasia. Complete local remission was achieved in 99% of patients, 11% developed recurrence (6% locally and 5% at different locations), but successful repeated treatments were possible in all. Calculated 5-year survival rate was 98%.<sup>98</sup>

One problem about Barrett's metaplasia is multifocality of dysplasia and potential malignant transformation. Thus, in addition to localized resection of suspicious lesions, ablation of the whole Barrett's mucosa is desirable. Mucosal ablative therapies consist of various methods for ablating the metaplastic mucosa combined with high-dose acid-suppressive therapy so that normal squamous mucosa will replace the ablated metaplastic mucosa in a pH-neutral environment. Methods include circumferential EMR, bipolar electrocautery, argon beam coagulation, photodynamic therapy (PDT), and radiofrequency ablation.

If circumferential EMR is possible, more than one procedure is usually necessary to lessen the chance of stricture formation. In a series of 41 Barrett's patients who had high-grade dysplasia or early adenocarcinoma, circumferential EMR achieved complete removal of the Barrett's epithelium in 76% after a median follow-up of 32 months. Recurrent or metachronous early cancer was found in 12% of patients.<sup>99</sup> Recurrence is thus a significant problem with this type of EMR; this is not unexpected as resection is piecemeal and not en bloc. Barrett's epithelium could be missed and grow again. The advantage of EMR compared to other forms of mucosal ablative therapy is that specimens are available for histopathologic examination.

PDT has been demonstrated in a randomized trial to reduce the cancer risk in Barrett's esophagus. In this study, 208 patients with high-grade dysplasia were randomized comparing PDT using porfimer sodium plus a PPI against PPI only. High-grade dysplasia was eliminated in 77% of the PDT group, although 39% in the PPI group also lost high-grade dysplasia on subsequent biopsies. Barrett's epithelium elimination was achieved in 52% in the PDT compared to 7% in the PPI group. Adenocarcinoma developed in 15% of the PDT group compared with 29% in the PPI group, with a longer time to progression to cancer favoring PDT.<sup>100</sup> The problems with PDT treatment include the need for repeated sessions, photosensitivity, stricture formation (6% in the series just described), and the phenomenon of buried glands or pseudoregression; residual metaplastic mucosa beneath the regenerated squamous mucosa can be present, which makes continual surveillance necessary. This incidence can be as high as 51%.<sup>101</sup> Because PDT does not treat nodal disease and there is not specimen histological examination, accurate pretherapy diagnosis of noninvasiveness is necessary.

Recently a more promising ablative method is shown to be effective in treating both nondysplastic and dysplastic Barrett's esophagus. It is a balloon-based circumferential endoscopic radiofrequency device (HALO360); 60 tightly spaced bipolar electrodes that deliver radiofrequency are wrapped around the balloon. A sizing balloon is first introduced into the esophagus; an appropriately sized radiofrequency frequency balloon is then used to ablate the mucosa. Ablation is based on frictional heating of cellular water molecules. The advantages of the system are that it is easy to use, and, because of its controlled depth of injury up to 500–1000  $\mu\text{m}$  (to the muscularis mucosae), stricture formation is uncommon. A more focal device (HALO90) mounted on the tip of a gastroscopie is also available. The upper surface of the device is a 20-mm-long  $\times$  13-mm-wide articulated platform with an electrode array identical in pattern to the circumferential device. It is best used for ablating residual Barrett's mucosa after initial HALO360 treatment.

The Ablation Intestinal Metaplasia-II (AIM-II) trial examined the use of the HALO system in ablating nondysplastic Barrett's esophagus up to 6 cm in length. HALO360 treatment was performed at baseline and repeated at 4 months if there was residual intestinal metaplasia. Focal ablation

with HALO90 was carried out after 12 months if needed. At 12 months complete remission of metaplasia was achieved in 48 of 69 patients (70%) and at 30 months 60 of 61 patients (98%). No stricture or buried glands were found.<sup>102</sup>

Another trial recently published examined the use of HALO system in ablating dysplastic Barrett's esophagus; 127 patients were randomly assigned in a 2:1 ratio to radiofrequency ablation or to a sham procedure. Randomization was stratified according to the grade of dysplasia and the length of Barrett's esophagus. Primary outcomes at 12 months included eradication rates of dysplasia and intestinal metaplasia. In the intention-to-treat analyses, among patients with low-grade dysplasia, complete eradication of dysplasia occurred in 90.5% of those in the ablation group as compared with 22.7% of those in the control group. Among patients with high-grade dysplasia, the respective figures were 81 and 19%. Overall, 77.4% of patients in the ablation group had complete eradication of intestinal metaplasia, compared with 2.3% in the control group. Patients in the ablation group had less disease progression (3.6 vs 16.3%) and fewer cancers (1.2 vs 9.3%). Stricture only developed in 6% of ablated patients.<sup>103</sup>

## ESOPHAGECTOMY

Surgical resection is the only method to ensure complete eradication of the dysplastic mucosa, and the frequently undetected invasive cancer. Surgical resection was considered a standard treatment because of the high frequency of invasive cancers found in surgical specimens when resection was performed for high-grade dysplasia (up to 42%), though more recent evidence suggests that this figure is much lower at 13%.<sup>94</sup> The supposedly high morbidity and mortality rates of esophagectomy are also deterrents against surgical resection. However, in specialized centers, the mortality rate from esophagectomy, especially in this group of patients, is minimal. Minimally invasive surgical methods, including thoracoscopy, laparoscopy, or esophageal stripping, further reduce the trauma of surgical access. Excellent long-term survival with good quality of life is reported.<sup>104,105</sup>

Vagal-sparing esophagectomy leaves the vagi intact, is another approach aimed at preserving quality of life, and has been shown to result in much fewer postvagotomy symptoms.<sup>106</sup> In the Merendino procedure, limited surgical resection of the distal esophagus and GEJ, together with lymphadenectomy of the lower mediastinum and upper abdominal compartment, has also been advocated. An isoperistaltic jejunal interposition graft is used to restore intestinal continuity. This method combines the adequacy of nodal dissection and improved quality of life, as the jejunal loop prevents gastroesophageal reflux.<sup>107</sup>

In summary, in patients with high-grade dysplasia or early intramucosal cancer, there is a definite risk of progression to invasive cancer, treatment needs to be individualized. The choice between intensive surveillance, mucosal ablative therapies, and esophagectomy needs to be considered based on available expertise and patient's preference.

## Treatment For Advanced Esophageal Cancer

### SURGICAL RESECTION FOR ESOPHAGEAL CANCER

Surgical resection remains the mainstay treatment for patients with localized esophageal cancer. In dedicated high-volume centers, mortality rate from surgery of 2–3% can be achieved.<sup>56,108–112</sup> A volume-outcome relationship is evident.<sup>111,113</sup> Centralization of service to high-volume hospitals also improves outcome.<sup>114</sup>

Important aspects to enhance better outcome after esophagectomy are (1) selecting appropriate patients for resection, (2) choice of surgical techniques and their execution, and (3) enhancing perioperative care.

**Patient Selection for Esophagectomy.** How stringent one selects patients for esophagectomy will influence the resection rate. Selection depends on many factors, including (1) the referral pattern of individual centers, (2) the prevailing treatment philosophy, (3) the availability of alternative therapies, and (4) the possible mortality that the surgeon and patient are prepared to accept. Reported resection rates range from 21 to 70–80%.<sup>110,115</sup> This wide variation suggests probable prereferral bias or a high prevalence of early cancers in those with high resection rates.

In studies that report on improvement of surgical results over time, more stringent patient selection often comes into play, either by excluding high-risk patients or by treating advanced disease by nonoperative means.<sup>116</sup> Resection with a clear aim for palliation is becoming uncommon, and most would only operate on patients for potential cure.

Factors often cited as being predictive of morbidity and mortality after esophagectomy include advanced age,<sup>112</sup> poor performance status,<sup>116</sup> nutritional depletion<sup>117</sup> and weight loss, more proximally located tumor,<sup>112</sup> poor pulmonary function,<sup>118</sup> cirrhosis,<sup>119</sup> and abnormal cardiac evaluation.<sup>116</sup> Patients suffering from adenocarcinoma and squamous cell cancers also have different risk profiles. Patients with squamous cell cancers are more likely to be malnourished, have high alcohol intake, are smokers, and have more impairment of pulmonary and hepatic function. Patients with adenocarcinomas on the other hand are more likely to be overweight and are more at risk from cardiovascular diseases.<sup>120</sup>

Assessing a patient's fitness is often based on the surgeons' experience and intuition and is not an exact science. Objective scores can help assess operative risk and patient selection.<sup>116,118,121</sup> In one series of studies using a scoring system based on compromised general status and poor cardiac, hepatic, and respiratory function as independent predictors of postoperative death, 30% of patients with otherwise resectable tumors were excluded from surgery. When this was applied in prospective patient selection, it led to decrease in postoperative mortality rates from 9.4 to 1.6%.<sup>116</sup>

It is uncertain if patient selection based on a strict mathematical scoring system is better than one based on surgeon

and anesthesiologist assessments alone. They are more likely to be complementary to each other.

**Choice of Surgical Approaches.** There are many important variables in esophagectomy, such as surgical access, the extent of resection and lymphadenectomy, the type and the method of preparation of the esophageal substitute, the route of reconstruction, and the technique of esophageal anastomosis. Many of these variables are interrelated and could affect immediate morbidity and mortality rates, long-term quality of life, and survival. Tumor location and stage, patient's risk profile, and surgeon's preference and experience are important variables in deciding the surgical procedure. The surgeon should be versatile and well versed with the many different techniques to adapt to different clinical situations.

**Cervical Esophageal Cancer.** In 1960, Ong and Lee first described the procedure of pharyngolaryngoesophagectomy (PLE) as a one-stage, three-phase operation that involved cervical and abdominal incisions and a thoracotomy.<sup>122</sup> Tumors involving the hypopharyngeal and upper cervical esophageal region were resected together with the whole esophagus, and the stomach was delivered via the posterior mediastinum to the neck for pharyngogastric anastomosis. A terminal tracheostomy was constructed. The thoracotomy was later replaced by transhiatal esophageal mobilization. Thoracoscopic esophageal mobilization has become another and our preferred alternative.<sup>123</sup> PLE is associated with significant morbidity and mortality, partly related to the fact that the procedure is often performed as a last resort for salvage when no other means of palliation exists.<sup>123</sup> So despite improvements in surgical care, results remain worse compared to patients with intrathoracic cancers. At the authors' institution, of 317 PLE performed from 1966 to 1995, mortality rate decreased from 31 to 9%.<sup>124</sup>

For tumors confined to the proximal portion of the cervical esophagus with sufficient distal margin, free jejunal interposition graft or deltopectoral or pectoralis major myocutaneous flaps are options for reconstruction after resection. The use of a free jejunal graft is advantageous because it avoids mediastinal dissection, though expertise in performing microvascular anastomosis is essential. Graft necrosis, fistula formation, and late graft strictures are specific problems. When compared with gastric pull-up, graft survival and leak rates are similar. Stricture was the most common late complication for free jejunal transfers, whereas reflux was most common in gastric pull-ups, both occurring in approximately 20% of patients.<sup>125</sup> Functional study showed a satisfactory swallowing mechanism in all patients.<sup>126</sup> The jejunal graft is also tolerant to postoperative radiotherapy.<sup>127</sup> The need to sacrifice the larynx does make surgical resection an unattractive option, and chemoradiation has been used up-front in many series, with surgery reserved for salvage.<sup>128</sup>

**Intrathoracic Esophageal Cancer.** For tumors in the upper thoracic esophagus, obtaining a sufficient proximal resection margin dictates an anastomosis placed in the neck.

For this reason, resection is best carried out by a three-phase esophagectomy or the McKeown approach.<sup>129</sup> In this procedure a right thoracotomy is first carried out to mobilize the thoracic esophagus together with lymphadenectomy; this is followed by abdominal and neck incisions for the mobilization of the esophageal substitute, placing the anastomosis in the neck. The split-sternum approach is an alternative, especially for tumors close to the thoracic inlet.<sup>130,131</sup>

The majority of intrathoracic cancers are squamous esophageal cancers located in the middle and lower esophagus, and Barrett's adenocarcinomas in the lower esophagus. The most widely used approach was that described independently by Lewis<sup>3</sup> and Tanner.<sup>4</sup> The operation begins with an abdominal phase, in which the stomach is prepared, followed by a right thoracotomy and resection of the tumor together with lymphadenectomy. The stomach is then brought up into the chest for anastomosis with the proximal esophagus at the apex of the pleural cavity.

An alternative approach involves a single left thoracotomy incision. Through a left thoracotomy and incision in the diaphragm, both the esophagus and stomach could be mobilized and resection carried out, and stomach delivered into the chest for anastomosis, either below or above the aortic arch. Proximally the aortic arch does hinder surgical access, making mobilization of the proximal esophagus and subsequent anastomosis difficult. The approach is therefore more suitable for cancer of the cardia or the distal esophagus where an adequate resection margin is obtained below the aortic arch.

A transhiatal approach, whereby the thoracic part of the esophagus is mobilized by blunt and often blind dissection through the enlarged esophageal hiatus, and the mobilized stomach is then delivered to the neck and anastomosed to the cervical esophagus. This is advocated especially for distal esophageal tumor or early-stage tumors of other parts of the esophagus.

#### ***Abdominal Esophagus and Gastric Cardia Tumors.***

For cancers that are limited to the abdominal esophagus or gastric cardia cancers, an abdominal-right thoracic approach as in a Lewis-Tanner esophagectomy is one option, with the proximal stomach also resected in order to gain an adequate distal resection margin. A left thoracoabdominal incision through the seventh or eighth rib space also gives excellent exposure of the low mediastinum and upper abdomen. A single left thoracotomy with opening up of the diaphragm is also an option. This gives reasonable exposure of the upper abdomen. However, lymphadenectomy toward the hepatoduodenal ligament is hampered. When a thoracotomy is not desired, opening the hiatus widely by splitting the crura laterally and the diaphragm anteriorly can gain access to the low posterior mediastinum, and distal esophagectomy can be performed with the anastomosis performed from the abdomen without the need for a thoracic incision. The anastomosis is made easier with a mechanical stapler. Recently a stapler designed with a transoral placement of the anvil into the distal esophagus makes construction of a lower mediastinal anastomosis easier. When the proximal stomach is involved by tumor, a total gastrectomy with Roux-en-Y reconstruction is preferred by many.

***Transthoracic Versus Transhiatal Resection.*** This continues to be controversial. Proponents of transhiatal resection believe that surgical resection for esophageal cancer is mostly palliative and a cure is a chance phenomenon for only those with very early tumors. More thorough lymphadenectomy through a thoracotomy merely improves staging but does not affect prognosis. The operating time is also shorter and postoperative morbidity is less with the transhiatal approach.<sup>132</sup> Conversely, surgeons who practice transthoracic esophagectomy (TTE) consider the open approach to be safer, with dissection under direct vision.<sup>133</sup> A more thorough lymphadenectomy leads to better staging and survival.

Population data from the Surveillance, Epidemiology, and End Results-Medicare linked database including 868 patients from 1992 to 2002 who underwent either transhiatal or transthoracic approach were studied in one recent study; 225 underwent transhiatal and 643 received TTE. Lower operative mortality rate was observed after a transhiatal than transthoracic approach (6.7 vs 13.1%). Survival was not different after adjusting for tumor stage, patient, and provider factor.<sup>134</sup> The largest randomized controlled trial comparing the two approaches studied 106 patients who underwent transhiatal esophagectomy and 114 patients who had the transthoracic approach for mid-lower third/cardia adenocarcinomas. Pulmonary complication rates were 27% in the former group compared to 57% in the later. Ventilation time, intensive care, and hospital stay were longer in the transthoracic group. There were, however, no significant differences in in-hospital mortality at 2 and 4%. Significantly more lymph nodes were dissected in the transthoracic group (16 vs 31). Overall 5-year survival was 34% (transhiatal) and 36% (transthoracic). Importantly, it showed that in individuals with limited nodal spread (one to eight positive lymph nodes), TTE imparted a survival advantage (64 vs 23%). Survival was not different in patients with no nodal metastases or in those with more nodal metastases.<sup>135</sup>

The location and stage of the primary tumor has bearing on which surgical approach is selected. From a purely safety point of view, transhiatal resection is not suitable for patients with advanced middle- or upper-third tumors, especially in patients with tumors closely related to the tracheobronchial tree and after neoadjuvant radiation therapy; tumor infiltration or fibrosis may obliterate tissue planes and make blind dissection unsafe. As such, its application is more suitable for lower esophageal tumors for which much of the mobilization can be performed under vision. From an oncological standpoint, the philosophy toward lymphadenectomy dictates the surgical approach.

***Minimally Invasive Esophagectomy (MIE).*** Various combinations of minimally invasive approaches including thoracoscopy, laparoscopy, mediastinoscopy, hand-assisted laparoscopy, and open laparotomy and thoracotomy have been explored.<sup>136</sup> The myriad of surgical methods implies a lack of consensus on which is superior.

Large single-center series are few; some have experience of over 100 patients.<sup>137-140</sup> Several reviews on MIE have been published<sup>136,141-144</sup>; none could conclusively show that MIE is better or worse than that of the open approach,



and no randomized controlled trial has been undertaken. Conversion rate is approximately 5%, respiratory complications 13–22%, and a very low mortality rate of 3% is achieved.<sup>142,143</sup> Biere and colleagues examined 10 comparative studies comparing MIE with open esophagectomy, comprising 1061 patients. Three comparative groups were created for meta-analysis: (1) total MIE versus open TTE; (2) thoracoscopy and laparotomy versus open TTE; (3) laparoscopy versus open transhiatal esophagectomy. There was a trend toward less mortality with MIE in groups 1 and 2, and fewer anastomotic leaks with MIE in group 2 were found. Again, definitive conclusions could not be reached because of selection bias and the variety of techniques used.<sup>144</sup>

Potentially serious intraoperative complications can occur with MIE, such as bleeding from the azygous vein<sup>145</sup> and from intercostal vessels,<sup>146</sup> injury to the aorta,<sup>147,148</sup> tracheobronchial tree,<sup>149–151</sup> and recurrent laryngeal nerve,<sup>152</sup> but certainly they are not specific for these methods. The increased magnification and excellent visualization offered by thoracoscopy might help lessen complications.

Whether MIE could reduce morbidity and mortality rates remains controversial. This is partly because of the number of patients studied generally was too small to have enough statistical power to demonstrate a difference. There are also other reasons why benefits are difficult to confirm. With modern analgesic methods, such as epidural analgesia, postoperative pain control is less critical a problem.<sup>153</sup> The genesis of cardiopulmonary complications is multifactorial and does not depend solely on the size of the incisions. Surgical trauma from mediastinal dissection is independent of the incision size. The benefit of smaller port sites compared with open thoracotomy may be offset by the lengthened time of single-lung anesthesia. A learning curve obviously exists for such complicated procedures.<sup>154,155</sup> The duration of the thoracoscopic procedure, blood loss, and the incidence of postoperative pulmonary infection were all less, and the number of mediastinal nodes retrieved was more, in the latter half of a group of 80 patients who had thoracoscopic esophagectomy.<sup>154</sup> Thus, for most series, the full technical potential may not have been realized. The number of procedures that need to be performed before the learning curve is overcome is uncertain.

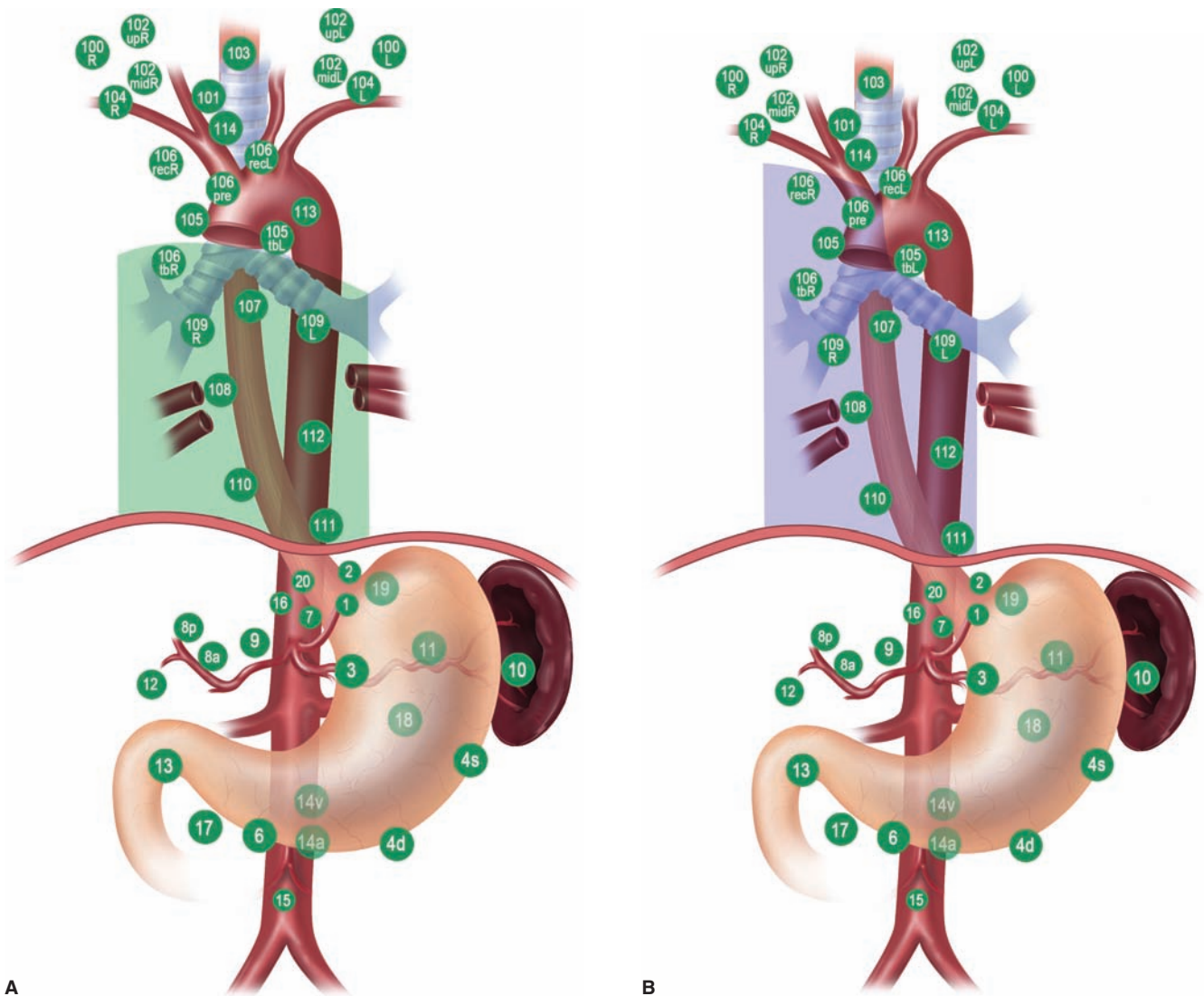
Patient selection is evident in many series, and in some studies most subjects had early-stage disease or high-grade dysplasia in Barrett's esophagus.<sup>138,156</sup> The most important test will be long-term survival by stage-by-stage comparison, but stage migration may be hard to eliminate. Most series do not report on survival data and, in those that do, there is no reported difference compared with historical controls. Existing data, however, do show that nodal harvesting can be equivalent to that of open surgery.<sup>136</sup> The place of MIE thus remains controversial without a well-conducted randomized controlled trial.

**Extent of Resection: Axial and Lateral Margin.** One of the most controversial aspects of treating gastrointestinal

malignancies is the appropriate extent of resection, and this debate is exemplified by esophageal cancer.<sup>157</sup>

An R0 resection is consistently identified as the most important prognostic factor for long-term survival. An R0 resection results in total removal of the tumor mass (primary and lymph nodes) with clear proximal, distal, and lateral margins. The need to obtain clear axial and lateral margins is less controversial. The propensity of esophageal cancer to spread intramurally and to have multiple separate tumors in the esophagus is well recognized. The prevalence of intraepithelial, subepithelial, or intramural spread was as high as 46 and 54%,<sup>158,159</sup> and multiplicity of tumor was found in around 30% of patients.<sup>159,160</sup> The deeper the wall penetration of the primary tumor, the farther away such spread can take place.<sup>158</sup> It is clear that the chance of a histologically positive margin declines with increasing distance at which the esophagus is transected away from the tumor edge, and that the frequency of anastomotic recurrence is a function of the length of proximal resection margin attained. Taking into account shrinkage of the specimen after resection, as a guide to surgery, an in situ margin of 10 cm (fresh contracted specimen of approximately 5 cm) should be aimed at, to allow a less than 5% chance of anastomotic recurrence.<sup>161</sup> Intraoperative frozen section is one method to ensure a negative margin. However, a histologically involved resection margin does not necessarily lead to definite anastomotic recurrence, and a negative margin does not preclude anastomotic recurrence. The occurrence of skip lesions or submucosal spread can be missed even by a conscientious pathologist; hence margins may be falsely negative. Extramural recurrence with infiltration back to the anastomosis may also be indistinguishable from true anastomotic recurrence. Patients who have positive histologic margins are those likely to have more advanced disease, and early recurrences at more distant sites may make anastomotic recurrence less relevant. In our study, a positive histologic margin (diagnosed with definitive histology and not with frozen section) occurred in 7.5% of patients who had esophagectomy, which had an anastomotic recurrence rate of 10.3% compared to 4.9% in those with a negative margin. The difference, however, did not reach statistical significance.<sup>161</sup>

Microscopic involvement of the lateral margin (macroscopically clear) results in increased chance of local recurrence and worse survival.<sup>162</sup> Obtaining a clear lateral margin is difficult with esophageal cancer because of its anatomical position and adjacent indispensable structures. Neoadjuvant therapy may help achieve this. Some Western centers advocate the concept of "en bloc" resection, which aims at removing the primary tumor together with the pericardium, thoracic duct, azygous vein, intercostal vessels, and bilateral pleurae overlying the primary tumor and a surrounding cuff of crura (where the primary tumor is abutting) to enhance lateral clearance.<sup>108,163</sup> Obviously this type of resection is less suitable for upper esophageal cancers in close proximity to the trachea. The concept of "en bloc" resection is thus more applicable for Western patients, where most tumors are adenocarcinomas of the lower esophagus.



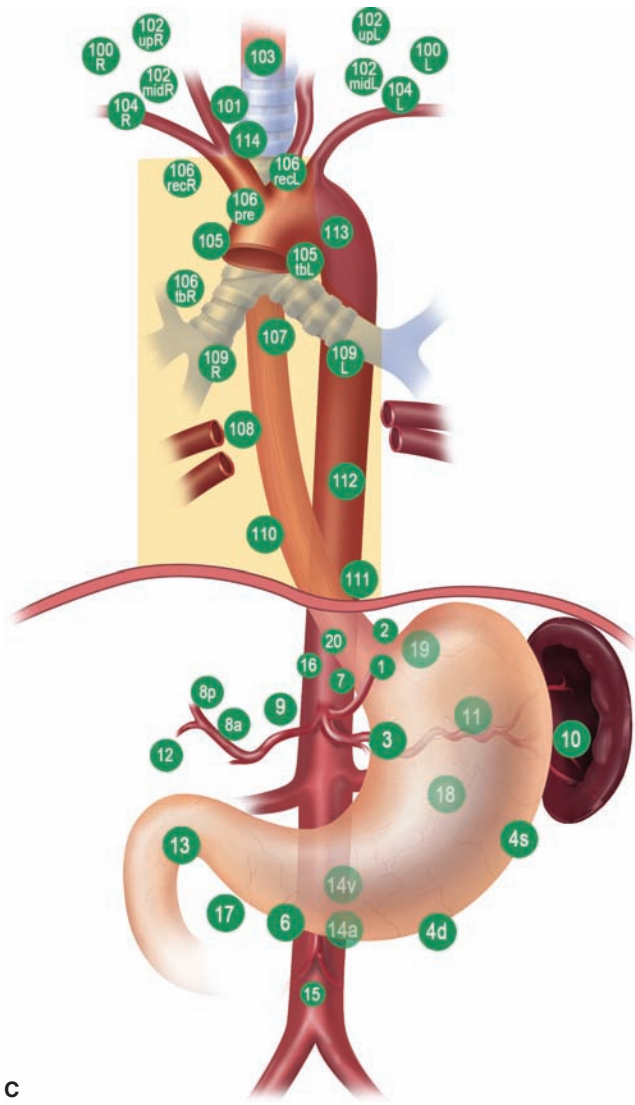
**FIGURE 17-9** The extent of mediastinal lymphadenectomy: **A.** Standard mediastinal lymphadenectomy includes removing the parasophageal nodes and subcarinal and right and left bronchial nodes below the tracheal bifurcation. **B.** Extended mediastinal lymphadenectomy involves standard lymphadenectomy plus right apical nodes, right recurrent laryngeal nerve nodes, and right paratracheal nodes.

#### **Extent of Lymphadenectomy: Squamous Cell Cancers.**

As discussed previously, the ability to perform lymphadenectomy is closely related to the surgical approach utilized, and an open transthoracic or thoracoscopic approach is necessary, unless only a limited lower mediastinal dissection is planned. In countries where squamous cell cancers are prevalent, transhiatal resection is uncommonly performed based on safety concerns, as well as because the value of lymphadenectomy is less questioned.

Conventional lymph node dissection for esophageal cancer usually involves a “standard two-field” lymphadenectomy, which entails removing the nodes and periesophageal tissue below the level of the carina, and the lymph node stations around the celiac trifurcation. When superior mediastinal lymph node dissection is performed, it is sometimes known as “extended two-field lymphadenectomy.” “Three-field”

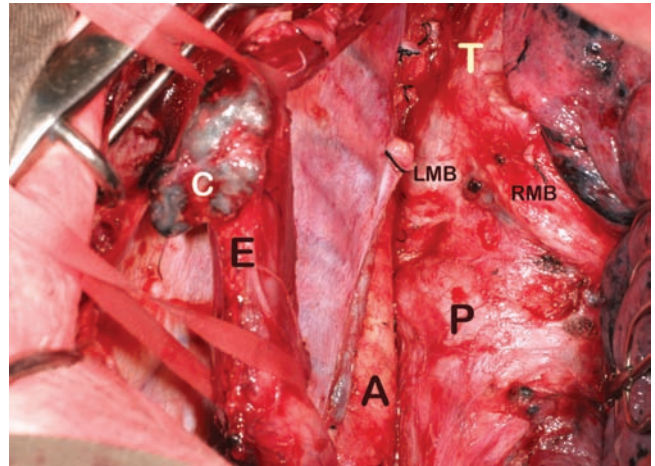
lymphadenectomy involves additional bilateral cervical lymph node clearance (Figs. 17-9 to 17-14). For intrathoracic squamous cell cancers, detailed lymph node mapping of metastatic disease in Japan shows that lymph nodes can spread to the neck, mediastinum, and upper abdomen around the celiac trifurcation. The overall rate of cervical lymph node metastases is approximately 30%. In relation to the level of primary tumor, cervical lymph nodes are involved in 60, 20, and 12.5% of upper-, middle-, and lower-third tumors, respectively. When nodes along the recurrent laryngeal nerves from the superior mediastinum are considered together with the cervical nodes as one entity, this “cervicothoracic” group nodes are involved in up to 63.4% of proximal-third, 45.2% of middle-third, and 42.0% of lower-third cancers.<sup>164</sup> These data provide the rationale behind “three-field” lymphadenectomy, where the true value of extended lymphadenectomy



**FIGURE 17-9** *Continued*—C. Total mediastinal lymphadenectomy includes an extended mediastinal lymphadenectomy plus the left recurrent laryngeal and paratracheal nodes.

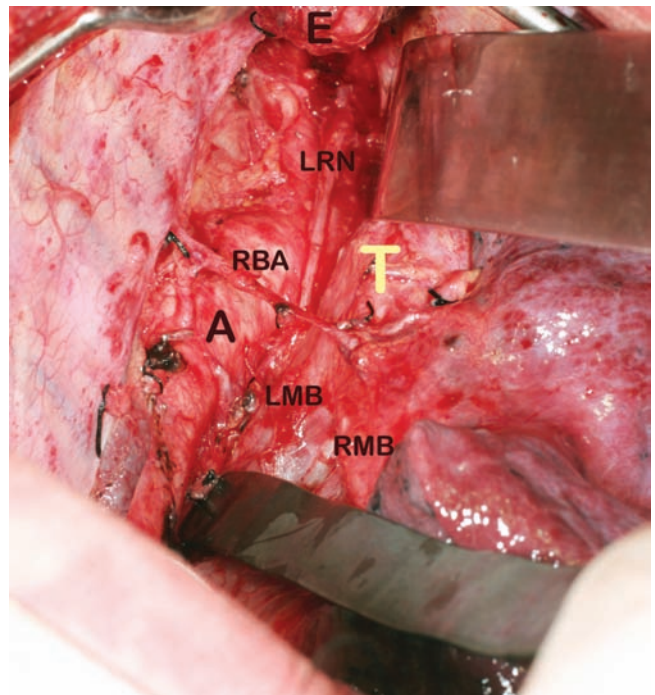
does not lie with the addition of a cervical phase, but the completeness of the superior mediastinal dissection along the recurrent laryngeal nerves to the neck.

Three-field lymphadenectomy as practiced in Japan shows an overall hospital mortality rate of 4%. Although this very low mortality rate is achieved, most of these results come from experienced and specialized institutions and such extensive surgery is expected to carry with it a more unfavorable outcome if it were more widely and unselectively applied. In addition, morbidity rates are substantial; septic complications were the most common at 26.8%, followed by pulmonary ones at 21.3%.<sup>165</sup> Recurrent laryngeal nerve injury can occur in more than 50% of patients, which predisposes to pulmonary complications and impairs long-term quality of life.<sup>166</sup>



**FIGURE 17-10** Infracarinal mediastinal dissection. A, aorta; C, carinal lymph node on esophagus; E, esophagus; LMB, left main bronchus; P, pericardium; RMB, right main bronchus; T, trachea.

Perhaps based on the realization that such an extensive operation carries with it substantial morbidity and that not all patients can benefit, the recent focus of research in this area is to further refine the indications for extended lymphadenectomy. A survival advantage was only evident for upper- and middle-third cancers in some studies.<sup>164,167,168</sup>



**FIGURE 17-11** Superior mediastinal dissection. Large metal retractor retracting the trachea anteriorly to expose the left recurrent laryngeal nerve (LRN). A, aortic arch; E, esophagus; LMB, left main bronchus; RBA, right bronchial artery, which is preserved; RMB, right main bronchus; T, trachea.



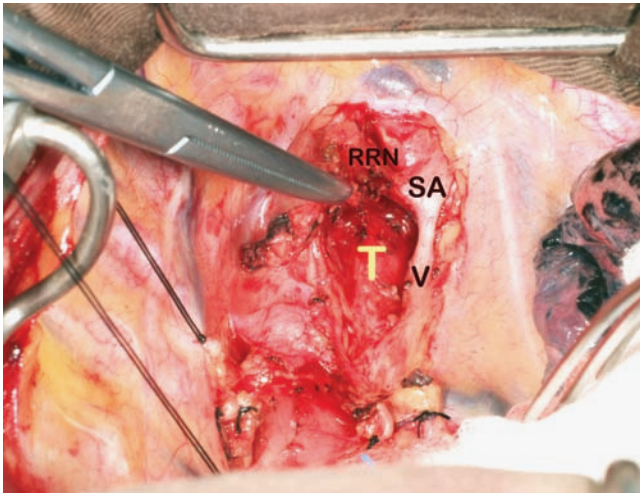


FIGURE 17-12 Right recurrent laryngeal nerve node dissection. RRN, right recurrent laryngeal nerve; SA, subclavian artery; T, trachea; V, vagus nerve.

Other poor prognostic factors include (1) when all three fields have metastatic nodes; (2) when a lower-third tumor has positive cervical nodes; and (3) when five or more lymph nodes are involved.<sup>169</sup> These situations suggest advanced metastatic disease and three-field lymphadenectomy may not be justified. Other suggested strategies include using intraoperative polymerase chain reaction to examine recurrent laryngeal nerve lymph nodes to predict the need for cervical dissection,<sup>170</sup> similar to the concept of sentinel lymph node metastasis,<sup>171</sup> and taking a two-stage operative approach to select patients suitable for cervical lymphadenectomy.<sup>172</sup> Replacing three-field lymphadenectomy by neoadjuvant, adjuvant, or intraoperative radiotherapy<sup>173</sup> are alternatives, but their roles remain controversial.

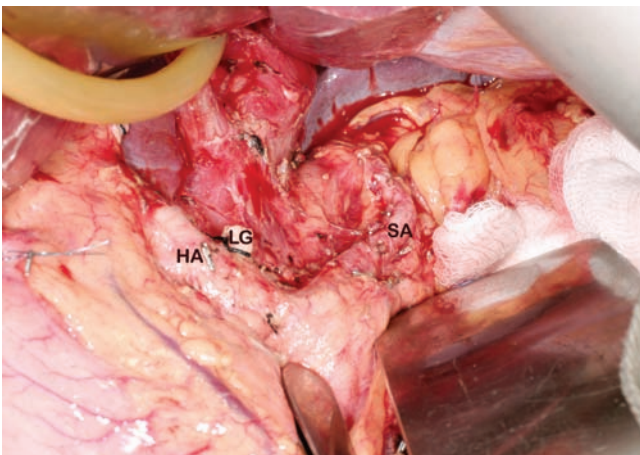


FIGURE 17-13 Abdominal lymphadenectomy involves dissection around the celiac trifurcation. HA, hepatic artery; LG, left gastric artery stump ligated; SA, splenic artery.

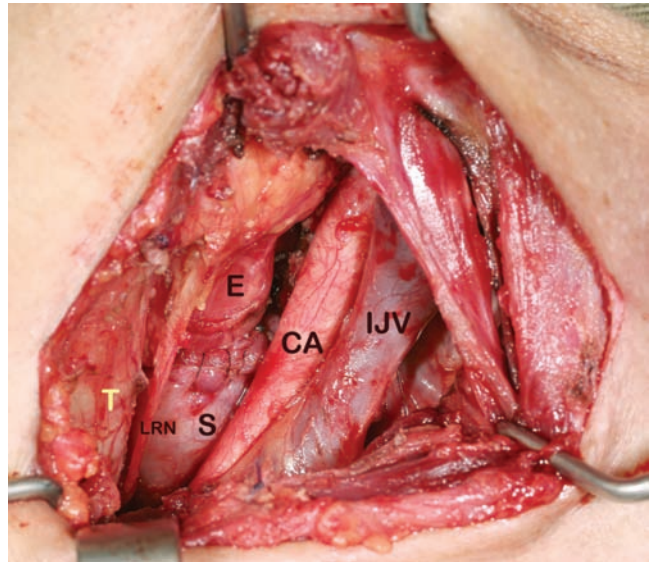


FIGURE 17-14 For cervical lymphadenectomy, the cranial landmark is the cricoid cartilage and the caudal border is the upper margin of the clavicle. The most important nodes are the paratracheal nodes along the recurrent laryngeal nerves. Left neck dissection. CA, carotid artery; E, esophagus; IJV, internal jugular vein; LRN, left recurrent laryngeal nerve; S, stomach; T, trachea. The esophagogastric anastomosis is seen, constructed with a one-layer continuous suturing technique.

Another major criticism of three-field dissection is that the prognostic superiority over conventional resection is only a result of stage migration. While retrospective studies provide evidence for benefits of three-field dissection,<sup>174,175</sup> the more robust evidence of a well-performed randomized controlled trial is lacking. Two small randomized trials could not demonstrate convincing survival advantage, and, in both, the patient groups appeared to be highly selected and not well-matched, and adjuvant therapies were not controlled for.<sup>176,177</sup>

#### **Barrett's Adenocarcinoma and Gastric Cardia Cancers.**

For Barrett's adenocarcinomas of the lower esophagus and cancer of the gastric cardia, data suggest that nodal spread tends to occur later than for squamous cell cancers. Positive nodes are found in approximately 10% of patients with squamous cell cancers for T1a lesions, while in Barrett's cancer this is only 0–6%. In T1b cancers, the respective figures are 30–50% for squamous cell and 20% for adenocarcinomas. In addition, the pattern of lymphatic spread also differs; more than 85% of all positive nodes in early adenocarcinoma are located in close proximity to the primary tumor in contrast to fewer than 60% in squamous cell cancers.<sup>178</sup> Nodes are not commonly found in the superior mediastinum and, when present, probably indicate very widespread disease.<sup>179</sup> Thus lymphadenectomy is generally performed using a standard two-field approach. The advent of transhiatal esophagectomy came at a time when esophagectomy was a high-risk operation with high mortality rates, and this less invasive method



probably contributed to reducing overall death rates. With improvement in surgical techniques and perioperative care, it seems that, in most experienced centers, when selected appropriately, both procedures can be carried out safely and the margin of benefit in reducing morbidity for most patients with the transhiatal operation is not overwhelming. There is also increasing evidence of the benefits of radical lymphadenectomy in recent years.

The concept of en bloc resection has been discussed in a previous section; this enhances lateral margin clearance, results in a complete lymphadenectomy within a fascial envelop surrounding the primary tumor,<sup>108,163</sup> and is especially advocated for adenocarcinoma of the lower esophagus. In dedicated centers, en bloc resection has a morbidity rate of 40%, a mortality rate of less than 5%, and a 5-year survival rate of 37–52%.<sup>163,180,181</sup> It has been suggested that local recurrence can be reduced to an impressive 5% within the field of dissection,<sup>163,182–184</sup> and nodal recurrences are mostly found outside the limits of dissection in the superior mediastinum or aortopulmonary window, in areas along the recurrent laryngeal nerves that are not routinely removed. Taking en bloc resection further, in selected centers in the United States and Europe, three-field lymphadenectomy has been tested and interestingly also yielded similar incidences of positive cervical lymph nodes of around 30%.<sup>109,184</sup> This type of resection, however, is not commonly performed in the West.

For tumor of the gastric cardia (Siewert types II and III tumors), most surgeons would perform a total gastrectomy with a Roux-en-Y jejunal loop reconstruction, though some would prefer to preserve the distal stomach for anastomosis. An upper abdominal compartment nodal dissection around the celiac axis seems routine for all, but complete lower mediastinal nodal dissection is somewhat controversial. Some argue that thorough lower mediastinal dissection is needed and this is only possible with the addition of a thoracotomy; others believe that this is unnecessary, and mediastinal nodal involvement could indicate advanced disease for which survival is poor regardless of the extent of lymphadenectomy. The Japanese Oncology Group trial 9502 addressed this question. Patients whose tumors were Siewert II or III adenocarcinomas and which have infiltrated into the esophagus for less than 3 cm were randomly assigned to a transabdominal ( $n = 82$ ) or left thoracoabdominal approach ( $n = 85$ ). A more thorough mediastinal dissection was deemed only possible with the later approach. The trial was closed prematurely after the first interim analysis, when the predicted probability of left thoracoabdominal approach having a significantly better overall survival than transabdominal route at the final analysis was only 3.65%. The morbidity rate was worse after the left thoracoabdominal approach. Thus a transabdominal approach seems adequate, though the surgeon must be prepared to add a thoracotomy when frozen section indicates a positive proximal resection margin.

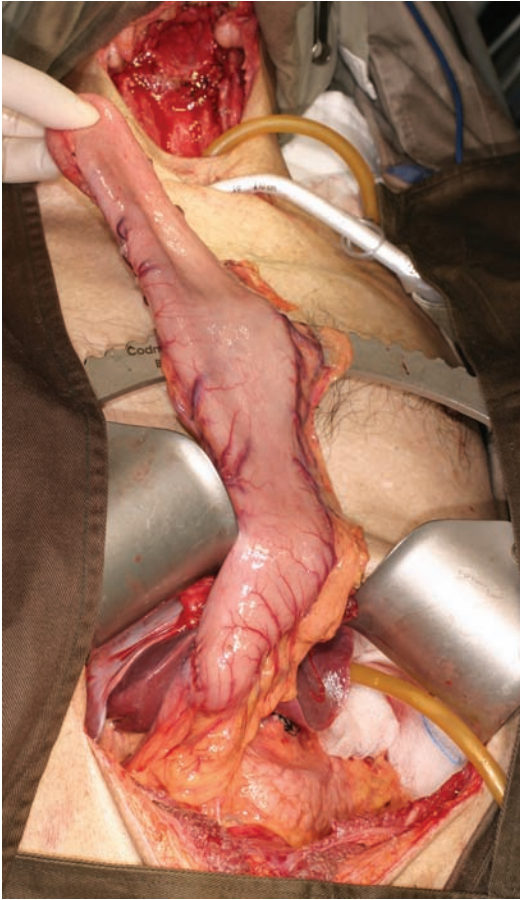
Regardless of tumor histologic type, increasing evidence is emerging to show that extended lymphadenectomy is related to survival, from single and multi-institutional studies,<sup>185,186</sup> as well as from population data.<sup>187,188</sup> The number of nodes

removed correlates significantly with long-term survival. One international multicenter study showed that the number of nodes removed was an independent prognostic factor, in addition to age, gender, cell type, presence of nodal metastases, number of nodes involved, and depth of tumor invasion.<sup>186</sup> The optimal number of nodes removed was identified as 23, though this number varies among studies. From a Worldwide Esophageal Cancer Collaboration including institutions from the United States, Europe, and Asia, the number of nodes that must be removed to maximize survival depends on the pT classification: for pT1, approximately 10 nodes must be resected; for pT2, 20 nodes; and for pT3 or pT4, 30 nodes or more.<sup>189</sup> Thus, one should resect as many regional nodes as possible, balancing the extent of lymphadenectomy with morbidity.

## RECONSTRUCTION AFTER ESOPHAGECTOMY

The reconstruction phase of an esophagectomy determines to a significant extent the postoperative morbidity and long-term quality of life. The most commonly used conduit is the gastric tube, and of the many configurations, a tailored isoperistaltic tube based on the greater curvature with preservation of the right gastric and right gastroepiploic vessels is most reliable. A 4-cm gastric tube on the greater curvature gives the best blood supply.<sup>190</sup> The simplicity of preparation, adequate length, and robust blood supply makes it the first choice as the esophageal substitute (Fig. 17-15). Disadvantages of the gastric conduit include the fact that patients who have an intrathoracic stomach often experience postprandial discomfort and early satiety related to loss of normal gastric functions such as receptive relaxation. Patients can also suffer from acid reflux, possible gastric ulceration, and dysfunctional propulsion.<sup>191</sup> In addition, Barrett's esophagus has been reported to develop in the esophageal remnant,<sup>192</sup> although the clinical relevance of this finding is at present unknown. These are important considerations though, in our experience, serious problems are uncommon. The level of the esophagogastric anastomosis has a bearing on the severity of reflux. Patients who have a low intrathoracic anastomosis tend to have more severe reflux and esophagitis compared with the high intrathoracic or cervical anastomosis. Preserving a longer length of esophagus, on the other hand, theoretically may enhance swallowing function. Inadequate gastric emptying can be a problem. A pyloric drainage procedure is not universally practiced. In a randomized trial, 13% of patients who did not have a pyloroplasty had problems with gastric emptying.<sup>193</sup> A meta-analysis suggested that a drainage procedure lessens the chance of early postoperative gastric stasis, but long-term function is not affected.<sup>194</sup>

Many other factors contribute to emptying of the intrathoracic gastric conduit. A smaller stomach enhances postoperative emptying.<sup>195</sup> The straighter position of the stomach, when delivered to the neck via the posterior mediastinal or the retrosternal route, may make the stomach empty more efficiently compared to one placed in the right pleural cavity, where the angulation at the diaphragmatic hiatus as the stomach continues from the right paravertebral gutter into the



**FIGURE 17-15** Gastric conduit prepared for transposition to the neck for pharyngoesophagostomy after pharyngolaryngoesophagectomy. Ample length is evident.

abdomen may produce relative obstruction. Rotation of the stomach at the hiatus should be avoided. With a gastric conduit, diet modifications and the use of acid suppressive and prokinetic drugs such as erythromycin may be useful.<sup>196,197</sup>

There are instances when the stomach cannot be used, such as after previous gastric resection, and tumor involvement of a substantial part of the stomach dictating its removal. In these situations the use of the colon is preferred. For most, colonic interposition remains an infrequently performed procedure and has the potential for more complications.<sup>198</sup> Mobilization of the colonic loop is more complex; its blood supply is less reliable than the gastric conduit; three anastomoses are required; when the colon becomes ischemic, the choice of alternative conduit is restricted. In our experience, use of a colon loop is associated with more blood loss, a longer operating time, and a higher anastomotic leak rate. Colon ischemia occurs in 1 of 42 patients (2.4%), which compares favorably to a rate of 3–10% reported in the literature.<sup>199</sup>

A colonic conduit provides good long-term swallowing function; it seems to have active peristalsis, and this is cited as an explanation for its superior function as an esophageal substitute when compared with a passive gastric conduit.<sup>200,201</sup>

Although peristalsis can be demonstrated immediately following surgery,<sup>202</sup> long-term emptying likely relies on gravity.<sup>203</sup> When the distal stomach is retained in the abdomen after a colon interposition with a cologastric anastomosis, the latter provides additional reservoir function.<sup>204</sup>

The jejunum is used most frequently after distal esophagectomy and total gastrectomy for cancer of the lower esophagus and gastric cardia. A Roux-en-Y configuration seems best, as it prevents bile reflux to the esophagus. A jejunal loop used in a modified Merendino procedure to interpose between the esophagus and proximal stomach after limited resection of the distal esophagus and GEJ has also been advocated.<sup>205</sup> Excellent postoperative quality of life and function is claimed. A long jejunal loop is sometimes used to reach the neck, but preparation is tedious and the vasculature may not be reliable; a “supercharge” using a microvascular anastomosis to cervical vessels may be required.<sup>206</sup> A free jejunal graft is used for reconstructing the defect after resection of the pharyngo-esophageal segment in the neck.<sup>127</sup>

The method of reconstruction is in part related to the surgical approach for resection. When a cervical anastomosis is chosen, one must decide whether to place the conduit via the orthotopic, retrosternal, or subcutaneous route. The subcutaneous route is rarely used because it is cosmetically unsightly. The retrosternal route has variably been shown to be associated with increased or similar cardiopulmonary morbidity and mortality rates.<sup>207–209</sup> The retrosternal route is 2–3 cm longer compared to the orthotopic route,<sup>210</sup> but this is rarely of relevance because the esophageal replacement conduit is usually of sufficient length. Some suggest that the tight space at the thoracic inlet in the neck could cause potential constriction on the conduit and recommend partial manubrial, clavicular head and first rib resection<sup>211</sup>; we have found this unnecessary. Functionally, although it was shown that there is a higher rate of gastric retention when the retrosternal route is used, quality of life is not adversely affected.<sup>208,212</sup>

When palliative resection is carried out for advanced tumor, recurrent tumor could infiltrate into the conduit placed in the posterior mediastinum. In a retrospective study of 209 patients who had undergone curative resection and orthotopic reconstruction, or 73 patients (35%) who had locoregional tumor recurrence, 46 (22%) had secondary dysphagia as a result. The authors concluded that in 27 patients (13%) dysphagia would likely have been prevented by using a retrosternal reconstruction route.<sup>213</sup> However, the site of the obstruction that produced dysphagia was not clearly stated. The stomach is usually spacious and tumor infiltration will not readily result in dysphagia. Only at the thoracic inlet and in the cervical region, where there is limited space, can tumor involvement lead to obstruction. Using the retrosternal route will eliminate tumor involvement in the posterior mediastinum, but infiltration from tumors in the neck cannot be avoided. The benefits of choosing the retrosternal route in reducing secondary dysphagia from recurrent tumor infiltration may be overemphasized. In our own study, only 4 out of 28 patients (14%) developed tumor infiltration into the gastric conduit in the posterior mediastinum. The main symptom was bleeding

in two patients and none had dysphagia.<sup>214</sup> It is our policy therefore to only use the retrosternal route for reconstruction when resection is palliative, especially when postoperative radiotherapy is planned, or when the reconstructive phase of the operation precedes tumor resection.

### PERIOPERATIVE CARE AND POSTOPERATIVE MORBIDITY AND MORTALITY

With adequate preoperative workup, serious cardiac events like myocardial infarction should be rare. Atrial arrhythmia is common, affecting about 20% of patients. In itself, atrial fibrillation is benign; rather it serves as a marker for more serious underlying pulmonary and septic surgical complications.<sup>215</sup> Occurrence of atrial arrhythmia should prompt thorough search for a more ominous underlying cause.

Pulmonary complications remain the most common and serious postoperative morbidity. Major complications can affect 30% of patients; most series report a rate of about 20%.<sup>216</sup> Pneumonia and respiratory failure occurred in 15.9% of our patients and were responsible for 55% of hospital deaths. Predictive factors include advanced age, supracarinal tumor location (in part related to recurrent laryngeal nerve injury), and lengthy operating time. Neoadjuvant therapy did not lead to increased morbidity.<sup>112</sup> Measures to improve respiratory outcome include cessation of smoking preoperatively, chest physiotherapy, avoidance of recurrent laryngeal nerve injury, cautious fluid administration to avoid fluid overload, use of smaller chest tubes,<sup>217</sup> early ambulation, regular bronchoscopy, and early tracheostomy for sputum retention.<sup>218</sup> Epidural analgesia is invaluable in postoperative pain relief and has been shown to improve outcomes.<sup>153</sup>

The most common surgical complication after esophagectomy is still anastomotic leak and can reach 30%,<sup>219</sup> although in experienced centers leak rates of below 5% can be achieved. Most leaks are probably related to technical errors,<sup>118,220</sup> such as tension between the conduit and the esophageal stump, ischemia of the conduit because of rough handling and poor preparation, and suboptimal technique. The intrinsic vascular perfusion of the stomach can be enhanced by certain methods, such as “ischemic preconditioning,” whereby partial mobilization of the gastric conduit is followed by a second stage-anastomosis later. The perfusion of the stomach could be shown to improve in the interim period.<sup>221</sup> Although an interesting concept and potentially useful, the existing wide range of reported leak rates (from 2–3 to 30%) suggests that much improvement is possible by other means, even without ischemic conditioning. It would be ideal if one could identify the right patients on whom to perform ischemic conditioning pre- or intraoperatively, so that such elaborate preparation can be selectively applied.

The actual method of anastomosis is perhaps less important than its proper application. Stapled anastomosis is popular for intrathoracic anastomosis while the hand-sewn technique is preferred in the neck. There is no evidence from randomized trials that leak rates differ between stapled and hand-sewn anastomoses, but the circular stapler may give rise to more strictures.<sup>222</sup> The linear stapler has also been

advocated in the neck. One group reduced their cervical leak rate from 10 to 15% using a hand-sewn technique to 2.7% using linear staples with a side-to-side anastomosis.<sup>223</sup> With experience, however, the hand-sewn method is as safe, if not more so, and certainly less expensive.

As mentioned already, technical variables play an important role in the genesis of postoperative complications. Anastomotic leaks (largely technical) and recurrent laryngeal nerve injury, for instance, are related to higher incidences of postoperative pulmonary morbidities. At the author's center, pulmonary complications occurred in 10% of patients without technical complications, and in 38% of patients who developed such morbidities, and mortality rates were 3.3 and 9.2%, respectively.<sup>224</sup> Multivariate analyses also demonstrated that a long operating time was related to pulmonary complications, and increasing intraoperative blood loss was related to postoperative mortality.<sup>112</sup> In sum, the meticulous and expeditious execution of an esophagectomy and its subsequent reconstruction are of paramount importance in lessening complication and mortality rates.

Vigilant and aggressive treatment of complications is important for good outcomes. Management of complications has improved with time. At the author's unit, anastomotic leak rate was 16% in the 1960s to 1970s, 61% of whom died, resulting in a leak-related mortality of 9.8%.<sup>225</sup> In the 1980s the leak rate was 3.5%, of whom 35% died, a leak-related mortality of 1.2%,<sup>220</sup> while in the late 1990s leak occurred in 3.2% of patients and none died as a result.<sup>226</sup>

Other surgical complications like chylothorax and herniation of bowel through the diaphragmatic hiatus are rare but should be recognized early; both are corrected by surgical reexploration.

## Combined Multimodal Treatment Strategies

The past two decades have seen a proliferation of additional treatments for esophageal cancer. The rationale is based on the suboptimal long-term results of surgery or radiotherapy. Both the spatial and synergistic actions of chemotherapeutic agents and radiotherapy are explored in multimodality treatments. How surgical resection and these new combinations should be integrated into treatment programs is an active area of research.

### NEOADJUVANT RADIOTHERAPY

Trials of neoadjuvant radiotherapy have failed to show increased resection rate or improved survival compared with surgery alone.<sup>227–232</sup> The European Organization for Research and Treatment of Cancer (EORTC) study suggested improved local disease control but no better long-term outcome.<sup>229</sup> One study, which also involved chemotherapy, suggested a survival advantage imparted by preoperative radiotherapy but only in the pooled groups of patients receiving radiotherapy.<sup>232</sup> A Cochrane meta-analysis showed that if preoperative radiotherapy regimens do improve survival, the effect is likely to be modest with



an absolute survival benefit of 3% at 2 years and 4% at 5 years that was not statistically significant ( $p = .062$ ).<sup>233</sup>

**ADJUVANT RADIOTHERAPY**

Postoperative radiotherapy was studied in three randomized trials<sup>234–236</sup>; all three demonstrated improved local disease control. The largest study randomized 495 patients with intrathoracic squamous cell cancers. Postoperative radiotherapy of 50–60 Gy was given in 220 patients to the entire mediastinum and bilateral supraclavicular fossae. Per protocol, analysis showed no overall difference in 5-year survival at 31.7% for the surgery alone group and 41.3% for the radiotherapy group. A benefit in the radiotherapy group was observed in stage III patients; 5-year survival rates were 13.1 and 35.1%, respectively. In patients with node-positive disease, the difference in survival was of borderline significance. The chance of mediastinal, cervical lymph node and anastomotic recurrence was also reduced.<sup>236</sup> Survival benefit was not demonstrated for the other trials. From these studies it seems reasonable to give postoperative radiotherapy to subgroups of patients, especially those who have palliative resections, to enhance local disease control.

**NEOADJUVANT CHEMOTHERAPY**

Eleven randomized trials studied the role of preoperative chemotherapy.<sup>232,237–246</sup> The two largest trials were the Intergroup (INT 0113) trial in the United States, and the Medical Research Council (MRC) trial in the United Kingdom (Table 17-9). The first study randomized patients to undergo surgery alone, or to have three cycles of cisplatin and 5-fluorouracil before surgery, and in those who had stable or responsive disease, two additional

postoperative courses.<sup>245</sup> Of 440 eligible patients, 213 were assigned to the neoadjuvant group. The median survival was 14.9 months for the chemotherapy group compared with 16.1 months for the surgery group. Two-year survival rates were no different at 35 and 37%, respectively. The MRC trial (OE02) involved 802 patients and similar preoperative regimens with two courses of cisplatin and 5-fluorouracil.<sup>246</sup> Overall survival was better in the chemotherapy group. Median survival was 16.8 versus 13.3 months, and 2-year survival rates were 43 and 34%. Recently the long-term follow-up data were presented; with a median follow-up is of 6 years and 93% of patients followed to 5 years or death, 5-year survival rates were 23% in the chemotherapy group compared with 17% in surgery group. Benefits were evident for both squamous cell cancer and adenocarcinoma.<sup>247</sup>

Many differences between the two studies could explain the different outcomes, including the chemotherapy regimen, distribution of histologic cell types (66% adenocarcinoma in MRC and 54% in INT trials), number of patients who underwent resection, time to resection, type of surgery performed, and number of patients who also had radiotherapy. The larger sample size in the MRC trial also could have facilitated the detection of a small improvement with chemotherapy.

A Japanese study conducted by the Japanese Clinical Oncology Group (JCOG 9907) randomized 330 patients with stage II/III squamous cell cancers (excluding T4 disease) comparing two courses of preoperative cisplatin and 5-fluorouracil to a similar regimen given after esophagectomy. Overall 5-year survival was significantly better at 60% in the preoperative chemotherapy group compared to 38% in the postoperative group.<sup>248</sup> Although this trial did not specifically compare preoperative chemotherapy to surgical resection

**TABLE 17-9: SELECTED RANDOMIZED TRIALS ON NEOADJUVANT ± ADJUVANT CHEMOTHERAPY VERSUS SURGICAL RESECTION**

	N	Histology (%)	Chemotherapy	Post-op Mortality (%)	Tumor Location (%)	Median Survival (mo)	Survival (%)
<b>MRC<sup>246,a</sup></b>							
Chemo + surgery	400	SCC (31)	Cisplatin	10	ESO: 90	16.8	2 y (43)
Surgery	402	Adeno (66)	5-FU	10	Cardia: 10	13.3	2 y (34) (sig)
<b>Kelsen et al<sup>245,b</sup></b>							
Chemo + surgery	213	SCC (46)	Cisplatin	6	ESO + cardia (% not indicated)	14.9	2 y (35)
Surgery	227	Adeno (56)	5-FU	6		2 y (37)	
<b>Cunningham et al<sup>249,c</sup></b>							
Chemo + surgery	250	Adeno (100)	ECF	5.6	Stomach: 74	26 <sup>d</sup>	5 y (36)
Surgery	253			5.9	GEJ: 12 Lower ESO: 14	20 <sup>d</sup>	5 y (23) (sig)

Adeno, adenocarcinoma; ECF, epirubicin, cisplatin, fluorouracil; ESO, esophageal cancer; 5-FU, 5-fluorouracil; GEJ, gastroesophageal junction; SCC, squamous cell carcinoma.

<sup>a</sup> Preoperative chemotherapy only.

<sup>b</sup> Three courses preoperatively, two courses postoperatively.

<sup>c</sup> Three courses preoperatively and three courses postoperatively.

<sup>d</sup> Extrapolated from graphs.

alone, this has quickly become a standard-of-care treatment in Japan. In the United Kingdom, the MRC OE02 trial has also established preoperative chemotherapy as a widely practiced strategy. Another ongoing trial (OE05) compares the OE02 preoperative chemotherapy regimen with four courses of preoperative epirubicin, cisplatin, and capecitabine (ECX) in treating patients with adenocarcinoma of the esophagus and GEJ. Accrual was planned for 1300 patients.

The Medical Research Council Adjuvant Gastric Infusional Chemotherapy (MAGIC) trial, a randomized study, included 503 patients with adenocarcinoma of the stomach, GEJ, and the lower esophagus. Initially planned for gastric cancers, eligibility criteria were extended to include lower esophageal adenocarcinoma coinciding with termination of OE02. Thus 14% of patients had lower esophageal tumors, and another 12% had GEJ tumors. Three courses of epirubicin, cisplatin, and infused fluorouracil (ECF) were given to patients before surgery, and three courses were repeated afterward, comparing this to patients undergoing surgical resection alone. Both progressive-free and overall survival rates were improved in the chemotherapy group.<sup>249</sup>

A recent individual patient data-based meta-analysis on nine randomized trials (2102 patients) showed a statistically significant overall survival benefit in favor of preoperative chemotherapy translating into a 5-year absolute increase of 4% (from 16 to 20%). Disease-free survival and curative resection rates were also improved.<sup>250</sup> Similar benefits were demonstrated by another meta-analysis, with a 2-year absolute survival benefit of 7%. However, adenocarcinomas may benefit more than squamous cell cancers.<sup>251</sup>

## ADJUVANT CHEMOTHERAPY

This is an area perhaps least well studied, and trials on pure postoperative chemotherapy are limited. JCOG 9907, mentioned in the previous section, was in fact a follow-up study on JCOG 9204, which randomized 242 patients comparing surgical resection with the addition of two courses of postoperative cisplatin and 5-fluorouracil.<sup>252</sup> The 5-year disease-free survival rate was significantly different at 45% with surgery alone and 55% with surgery plus chemotherapy. The overall 5-year survival rates were not significantly different at 52 and 61%, respectively. The effect was more marked in the subgroup with lymph nodes metastases.<sup>252</sup> However, another small French study also using cisplatin and 5-fluorouracil as adjuvant therapy did not show any advantage with chemotherapy.<sup>253</sup>

## NEOADJUVANT CHEMORADIATION

Several groups have explored chemoradiation as neoadjuvant therapy (Table 17-10).<sup>232,254-261</sup> The radiation dose ranged from 20 to 45.6 Gy. In five trials, only squamous cell cancers were recruited<sup>232,254,255,257,258</sup>; three included mostly adenocarcinomas<sup>259-261</sup> and one treated adenocarcinomas only.<sup>256</sup> A survival advantage with neoadjuvant chemoradiation over surgery alone was demonstrated only in two trials.<sup>256,260</sup> The trial

reported by Walsh and colleagues on adenocarcinomas only has been criticized because of inadequate preoperative staging, unclear surgical procedures, and the large number of protocol violations, and survival from the surgery group was exceptionally poor (3-year survival rates were 32 and 6% for the preoperative treatment group compared to surgery alone).<sup>256</sup> In CALGB 9781, 475 patients were planned, but the trial was terminated after 56 patients because of poor accrual. Nevertheless, a survival advantage was seen in the chemoradiation group; median survival was 4.5 versus 1.8 years and 5-year survival was 39 versus 16%.<sup>260</sup> However, the statistical analyses of the trial were much criticized.<sup>262</sup>

The results from these studies are conflicting and thus inconclusive. Several meta-analyses have addressed the role of neoadjuvant chemoradiation.<sup>251,263-267</sup> The latest published meta-analysis included the randomized trials comprehensively; 10 studies included 1209 patients. The hazard ratio for all-cause mortality with neoadjuvant chemoradiation versus surgery alone was 0.81 (95% CI 0.70-0.93;  $p = .002$ ), corresponding to a 13% absolute difference in survival at 2 years, with similar results for different histological tumor types: 0.84 (0.71-0.99;  $p = .04$ ) for SCC and 0.75 (0.59-0.95;  $p = .02$ ) for adenocarcinoma.

Although it cannot be said conclusively that neoadjuvant chemoradiation therapy is superior to surgery alone in the treatment of localized esophageal cancer, it is widely practiced, especially in the United States. Neoadjuvant chemoradiation therapy does result in more pathological complete responses compared with chemotherapy (25-30% vs <10%). One recent trial compared preoperative chemotherapy with preoperative chemoradiation therapy in advanced adenocarcinoma of the lower esophagus and GEJ. More pathological complete responses were observed in the chemoradiation group (16 vs 2%), and more patients had negative nodal involvement (64 vs 38%). A trend toward improved median survival (32.8 vs 21.1 months) and 3-year survival (47.4 vs 27.7%) were also seen, though these did not reach statistical significance.<sup>268</sup>

## DEFINITIVE CHEMORADIATION

The Radiation Therapy Oncology Group (RTOG 85-01) trial of chemoradiation versus radiotherapy provided convincing evidence of the superiority of chemoradiation.<sup>269</sup> The 5-year survival rate reported for the combined therapy group was 26% compared to 0% following radiotherapy (median survival 14 vs 9 months). Data on recurrence patterns showed that both local and distant disease control were superior with combined treatment. Local persistence of disease and recurrence were 47% compared to 65%. Intensification of radiation dose to beyond 50.4 Gy, whether by external beam<sup>270</sup> or by brachytherapy,<sup>271</sup> did not yield further advantage but potentially added complications.

A Cochrane meta-analysis on 13 randomized trials that compared chemoradiation with radiation confirmed the superiority of chemoradiation. Concurrent chemoradiation provides a significant overall reduction in mortality at 1-2 years, an absolute

**TABLE 17-10: RANDOMIZED TRIALS ON NEOADJUVANT CHEMORADIATION VERSUS SURGERY ALONE**

	No.	Histology	Chemotherapy Dose of RT(cGy)	CR Rate	Mortality (%)	Median Survival (mo)	3-y Survival (%)
Nygaard et al <sup>232</sup>							
S	41	SCC	Cisplatin, bleomycin	NA	13	7.5	9
C + S	47		3500		24	7.5	17
Apinop et al <sup>255</sup>							
S	34	SCC	Cisplatin, fluorouracil	NA	15	7.4	20
C + S	35		4000		14	9.7	26
Le Prise et al <sup>254</sup>							
S	41	SCC	Cisplatin, fluorouracil	12.5a	7	10	14
C + S	45		2000		8.5	10	19
Walsh et al <sup>256</sup>							
S	55	Adeno	Cisplatin, fluorouracil	25%	8	11	6
C + S	58		4500		4	16	32
Bosset et al <sup>257</sup>							
S	139	SCC	Cisplatin	26%	4	19	34 <sup>c</sup>
C + S	143		3700		12.3	19	37
Burmeister et al <sup>261</sup>							
S	128	SCC (39%)	Cisplatin, fluorouracil	15%	4.6 <sup>b</sup>	22	32 <sup>c</sup>
C + S	128	Adeno (61%)	3500	SCC (26%) Adeno (9%)		19	34
Urba et al <sup>259</sup>							
S	50	SCC (25%)	Cisplatin, vinblastine, fluorouracil	28%	2	17	16
C + S	50	Adeno (75%)	4500		7	17	30
Lee et al <sup>258</sup>							
S	50	SCC	Cisplatin, fluorouracil	21% (43% <sup>a</sup> )	NA	27	2 y (51)
C + S	52		4560			28	2 y (49)
Tepper et al <sup>260</sup>							
S	26	SCC (25%)	Cisplatin, fluorouracil	40% (out of 25 patients)	4	22	5 y (16)
C + S	30	Adeno (75%)	5040		0	54	5 y (39)

Adeno, adenocarcinoma; C, chemo; CR, complete response; NA, not available; RT, radiation therapy; S, surgery; SCC, squamous cell cancers.

<sup>a</sup> In patients who had resection.

<sup>b</sup> Treatment-related mortality.

<sup>c</sup> Extrapolated from graphs.

reduction in death rate by 7%, and a reduction in local persistence/recurrence rate by 12%. The downside is a 17% increase in grades 3–4 toxicities. Sequential chemoradiation provides no benefit, perhaps demonstrating the need to maximize the radiosensitizing properties of chemotherapy.<sup>272</sup>

## THE ROLE OF SURGERY

The RTOG trial suggested that, in patients with T1-3 N0-1 M0 disease a 14–26% 5-year survival can be expected. It has been suggested that surgery may be of no additional value to chemoradiation and should be relegated to use as an adjuvant treatment.

Two clinical trials attempted to examine whether surgical resection was necessary after chemoradiation. A French study (FFCD 9102) treated 444 patients with both squamous cell cancers and adenocarcinomas of stage T3-4 N0-1

M0 with two cycles of 5-fluorouracil, cisplatin, and concurrent radiation (46 Gy at 2 Gy/d or split course 15 Gy weeks 1 and 3). Only 259 patients who had at least a partial response were randomized to undergo immediate surgery or to have three more cycles of chemotherapy with 20 Gy at 2 Gy/d or split course 15 Gy. The death rate within 3 months after starting induction treatment was 9% for surgery group compared with 1% in the chemoradiation group. Two-year survival rates were not different at 34 and 40%, so were median survival at 17.7 and 19.3 months for surgical and nonsurgical groups, respectively. Patients in the surgical arm, however, required stenting less often (13 vs 27%) or dilations (22 vs 32%).<sup>273</sup> There was no difference in the long-term quality of life, but the surgery arm had transient deterioration in the immediate postoperative period.<sup>274</sup>

A German multicenter trial recruited 172 patients with squamous cell cancers (T3-4 N0-1 M0). Three cycles of



5-fluorouracil/leucovorin/etoposide/cisplatin were given followed by chemoradiation (cisplatin/etoposide + 40 Gy). Resection was then performed. This was compared to a control group with the same chemotherapy, followed by definitive chemoradiation (cisplatin/etoposide + >60 Gy).<sup>275</sup> Long-term data from this trial were presented recently.<sup>276</sup> A nonsignificant trend toward better overall survival at 5 and 10 years was observed: 27.9 and 19.2% in the resection group, compared to 17.0 and 12.2% in the chemoradiation alone group. Local tumor control was significantly worse in the nonsurgical arm. Three-year survival rate was 35% in nonresponders undergoing complete tumor resection compared to 11% in nonresponders who did not undergo resection. Both the French and German studies concluded that surgical resection may not be necessary after chemoradiation therapy.

It may be premature to negate the value of surgical resection. First, chemoradiation is by no means harmless, and surgical resection may not be as morbid as described. Treatment duration of chemoradiation is often long and compliance is problematic. Only 68% of the patients in the RTOG-8501 trial could complete the planned treatment.<sup>269</sup> In the control arm of INT 0123, acute grades 3 and 4 toxicity affected 43 and 26%, respectively, and long-term grades 3 and 4 toxicity affected 24 and 13% of patients, respectively.<sup>270</sup> Treatment-related mortality was 5–9% as reported by the INT trials.<sup>270,277</sup> In studies that showed a benefit for chemoradiation or questioned the value of surgical resection, the results of the surgical arm were often suboptimal. In the FFCD 9102 trial, death rate within 3 months in the surgical arm was 9% compared to 1% in the nonsurgical arm<sup>273</sup>; in the German trial again the mortality rates were 10 and 3.5%, respectively.<sup>276</sup> The early surgical deaths likely biased the long-term survival results. Comparisons with nonoperative treatments will only be valid when better results from high-volume centers are integrated into clinical trials.

Second, local disease control with chemoradiation alone is less than satisfactory. It can be shown that with increasing extent of lymphadenectomy, better local control is achieved with surgery; by comparison, nonoperative chemoradiation has a much higher local persistence/recurrence rate of over 50%.<sup>270</sup> The relief of dysphagia, the main symptom requiring palliation, is much more certain with surgical resection; the need to treat dysphagia with a stent was twice in the nonsurgical group in the FFCD 9102 trial.<sup>273</sup>

Third, residual disease exists for the majority of patients treated by chemoradiation. The pathological complete response rate for most trials is in the region of 25%. Thus it is logical to assume that surgical resection would enhance cure at least in the remaining 75%, who did not completely respond. In the German trial, the 3-year survival of nonresponding patients who underwent resection was 35% compared with 11% in those who did not.<sup>276</sup> In the FFCD 9102 trial, 192 patients were not randomized primarily because of lack of objective response but also because of medical contraindications or patient refusal. Out of these, 112 patients had operations; among these 80 had R0 resection (42%). The median survival for the patients who underwent surgery was 17.3 ver-

sus 6.1 months for those who did not, and was comparable for those who were randomized. The data suggest that salvage surgery could benefit a subset of patients who do not respond to initial therapy.<sup>278</sup> Conversely, the role of surgery is less obvious in those with a complete response. However, ascertaining true complete response is difficult, whether by endoscopy, EUS, or CT scanning.<sup>279,280</sup> Recent studies using 18-FDG-PET scans show promise,<sup>82,281</sup> but, while PET scan can more reliably distinguish responders and nonresponders, it is not accurate enough to pinpoint the complete pathological responders.<sup>282</sup>

## PREDICTION OF RESPONSE AND RESPONSE-DIRECTED THERAPY

Reliable predictors for response to chemoradiation would be useful, because multimodality treatments are toxic, time consuming, and costly. Various markers have been explored, such as simple histology,<sup>283</sup> proliferative cell nuclear antigen (PCNA), epithelial growth factor (EGFR), Ki-67, cyclin D1, thymidylate synthase, and microvessel density, both in tissue and serum. To date none have been proven to help clinical decision making.<sup>284</sup>

Metabolic imaging with PET scan has some promise. The degree of response detected by PET imaging has been shown by many studies to correlate with pathological response after chemotherapy or chemoradiation therapy (Fig. 17-16).<sup>82,281</sup>

The MUNICON (the Metabolic response evalUatioN for Individualization of neoadjuvant Chemotherapy in oesophageal and oesophagogastric adenocarcinoma) trial evaluated patients with locally advanced adenocarcinoma of the distal esophagus or type II cardia tumors undergoing neoadjuvant chemotherapy. Early metabolic response was defined as a reduction of 35% or more in the mean glucose standard uptake value (SUV) measured by serial PET scans at the beginning and at 2 weeks after commencement of treatment. Responders carried on chemotherapy for an additional 12 weeks before resection, while nonresponders went directly to immediate surgery. Out of 119 patients, 110 were evaluable for metabolic responses, of whom 54 (49%) were responders. Significantly improved R0 resection rate (96 vs 74%), major pathological response rate (defined as <10% residual tumor) (96 vs 0%), longer median event-free survival (29.7 vs 14.1 months), and median overall survival (median not reached versus 25.8 months) were found for metabolic responders versus nonresponders. More importantly, the outcomes for nonresponders were not different from previous results in such patients who completed 3 months of chemotherapy, indicating that such a strategy did not compromise these patients and could save them from suboptimal chemotherapy.<sup>285</sup>

The same investigators reported on their MUNICON-2 trial recently. Metabolic nonresponders as defined in MUNICON were switched to chemoradiotherapy (both chemotherapy and chemoradiotherapy were cisplatin-based). Out of 32 patients recruited, 13 (41%) were metabolic nonresponders. Subtotal histologic response (<10% residual tumor) following chemoradiotherapy was reported in three patients (23%), but no complete responses was observed. In contrast, complete histological response rate in metabolic responders were seen in 16%. Higher

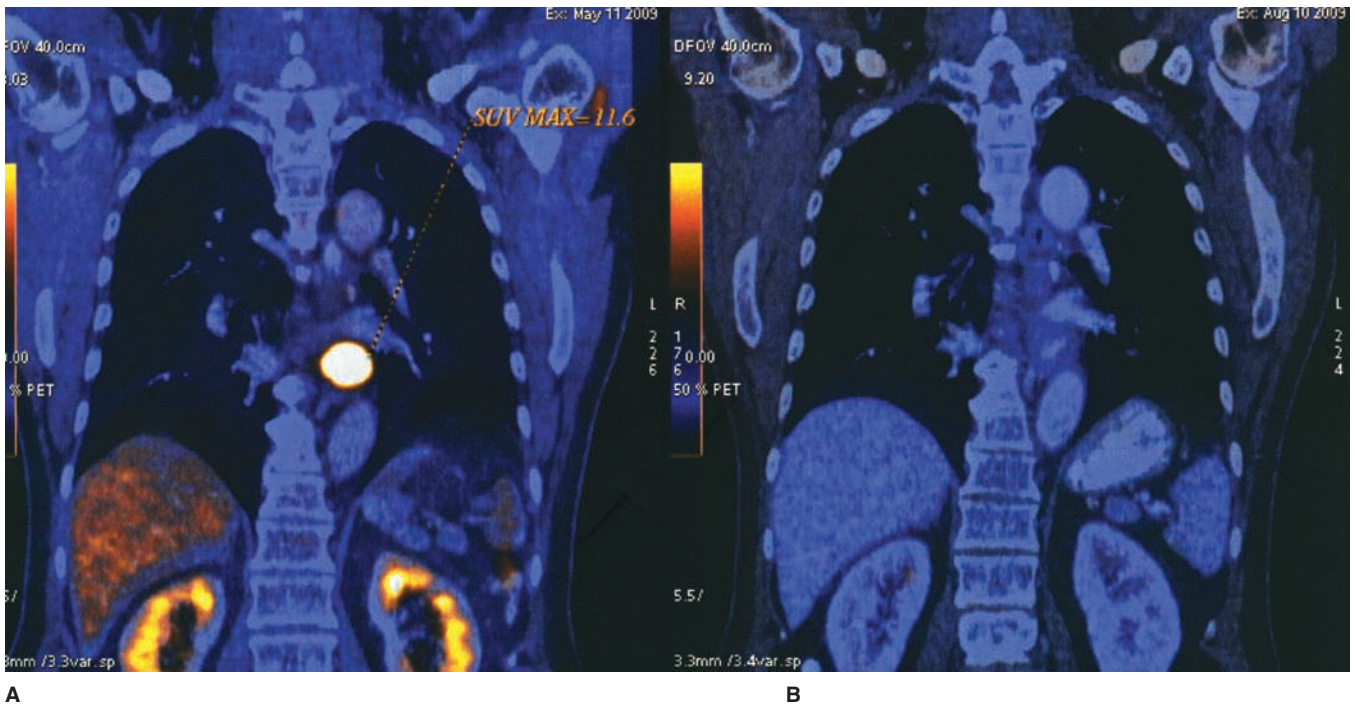


FIGURE 17-16 PET/CT before (A) and after (B) chemoradiation therapy; the tumor has become completely eumetabolic.

rates of R1/2 resections were also observed for nonresponders (31 vs 16%). One-year progressive-free survival was also inferior (46 vs 63%). The study suggested that merely adding radiotherapy to the same cisplatin-based chemotherapy in nonresponders was only marginally better.<sup>286</sup> Another strategy may be to switch to alternative, non-cross-resistant chemotherapy during radiation.

It seems that cisplatin and 5-fluorouracil-based chemoradiation therapy has reached its therapeutic limit in treating esophageal cancer. More novel chemotherapeutic agents are being explored, including paclitaxel, docetaxel, the topoisomerase I inhibitor irinotecan (CPT-11), vinorelbine, gemcitabine, Herceptin (trastuzumab), oxaliplatin, and biomodulators such as interferon or targeted therapies with bevacizumab or cetuximab. This remains a very active area of research. In addition, advances in techniques in radiation delivery, such as intensity-modulated radiotherapy, may further reduce radiation toxicity.<sup>287</sup>

## Endoscopic Palliation

Endoscopic palliative treatments for more advanced tumors include placement of an esophageal prosthesis, laser therapy, intralesional injection of various substances, and PDT. The most commonly employed technique is perhaps insertion of a prosthesis, especially self-expanding metallic stents (SEMS) (Fig. 17-17). The smaller diameter of the delivery mechanism makes aggressive dilation of the tumor before insertion unnecessary. These stents are more flexible than conventional plastic prostheses; membrane-covered versions

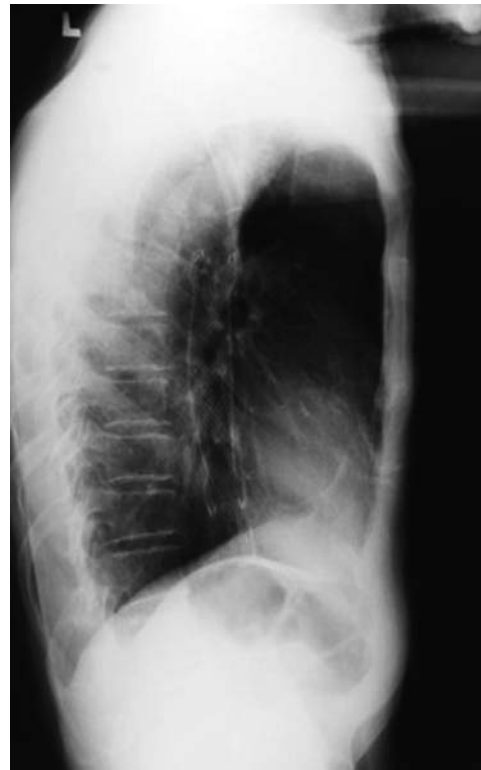

FIGURE 17-17 A self-expanding metallic stent (SEMS) in situ.

have been developed to seal esophagoairway fistulae and prevent tumor ingrowth. Three randomized trials were reported comparing the use of metallic stents with plastic prostheses. Perforation, pneumonia, bleeding, or migration rates were significantly less with metallic stents. Because of the lower morbidity, metallic stents were also more cost-effective despite their higher initial cost.<sup>288–290</sup> The choice of various metallic stents depends on their individual characteristics, in terms of flexibility, tensile force, and degree of shortening on deployment in relation to the site of placement. Compared with more conventional methods of palliation such as laser therapy, patients with SEMS spent less time in the hospital and required less frequent reinterventions.<sup>291</sup>

The main problems with SEMS are stent migration, tumor ingrowth or overgrowth, and, if placed across the GEJ, they allow acid reflux. Placing uncovered stents across the cardia lessens the chance of migration, and stents have been developed with a one-way flap valve to prevent reflux.<sup>292</sup> It has also been shown that “tumor” ingrowth is sometimes due to granulation tissue or hyperplastic reaction by the esophageal mucosa.<sup>293</sup> Patency can be achieved again by laser, argon beam application, or sometimes placement of a second stent within the first. One recent randomized trial compared the use of the Ultraflex stent (Boston Scientific, MA) with the Polyflex stent (Boston Scientific, MA), and the Niti-S double stent (Taewoong Medical, Seoul, Korea). The Polyflex stent is a silicone device with an encapsulated monofilament braid made of polyester. The silicone and polyester material is designed to lessen nontumoral tissue overgrowth, a problem common with SEMS. The Niti-S stent has an inner polyurethane layer over its entire length, and an outer uncovered nitinol wire tube to allow the mesh to embed itself in the esophageal wall. Success rates were similar for all three stents, but recurrent dysphagia was more common with the Ultraflex stent, because of tissue ingrowth and overgrowth, and, to lesser degree, the Niti-S stent. Polyflex stent had a higher chance of migration, not surprisingly, because the stent is also designed to be removable in benign esophageal stenosis.<sup>294</sup>

Another problem of stent insertion is for placement near to the upper esophageal sphincter. Foreign body sensation, pain, odynophagia, and airway compression can be troublesome and demand accurate placement. This is illustrated in the situation when recurrent disease is found at the anastomosis or in the esophageal remnant after subtotal esophagectomy. Placement of SEMS is still possible and achieves good palliation.<sup>295</sup>

## SUMMARY AND FUTURE PERSPECTIVES

Advances have been made in the management of esophageal cancer; survival of patients has improved.<sup>296</sup> The key is to select the most appropriate combination for individual patients. Surgeons play a central role in directing management treatment of this disease by advising on how best to integrate surgical resection with nonoperative programs. Surgeons should aim at improving their results further, so that low mortality

rates for resections are used to compare with seemingly safer therapies. The technique and extent of surgical resection may change when more information is made available, and should vary with patients and disease stage. MIE will be more widely practiced; it should achieve the same radicality of operation with less morbidity. Chemoradiation therapy has made a real impact on current management strategies,<sup>296</sup> but perhaps its overenthusiastic adoption and its presumed benefit have to be balanced against the lack of clear evidence of superiority over surgery.<sup>297</sup> Distant failure remains a major problem, and search for more effective systemic drugs as well as our ability to predict responders with precision must be therapeutic targets. Management strategies are going to evolve further, with improvements in molecular techniques, imaging methods, and introduction of more novel tumoricidal agents. The challenge for the future is for us to critically test our strategies in a scientific, unbiased manner, and to explore other innovative treatments.

## REFERENCES

1. Torek F. The first successful case of resection of the thoracic portion of the esophagus for carcinoma. *Surg Gynecol Obstet.* 1913;16:614.
2. Ohsawa T. Esophageal surgery. *J Jpn Surg Soc.* 1933;34:1318–1950.
3. Lewis I. The surgical treatment of carcinoma of the esophagus with special reference to a new operation for growths of the middle third. *Br J Surg.* 1946;34:18.
4. Tanner NC. The present position of carcinoma of the esophagus. *Postgrad Med J.* 1947;23:109.
5. Parkin DM, Bray F, Ferlay J, Pisani P. Global cancer statistics, 2002. *CA Cancer J Clin.* 2005;55(2):74–108.
6. Li L, Lu F, Zhang S. [Analysis of cancer modality and distribution in China from year 1990 through 1992—an epidemiologic study]. *Zhonghua Zhong Liu Za Zhi.* 1996;18(6):403–407.
7. Tran GD, Sun XD, Abnet CC, et al. Prospective study of risk factors for esophageal and gastric cancers in the Linxian general population trial cohort in China. *Int J Cancer.* 2005;113(3):456–463.
8. He YT, Hou J, Qiao CY, et al. An analysis of esophageal cancer incidence in Cixian county from 1974 to 1996. *World J Gastroenterol.* 2003;9(2):209–213.
9. Devesa SS, Blot WJ, Fraumeni-JF J. Changing patterns in the incidence of esophageal and gastric carcinoma in the United States. *Cancer.* 1998; 83(10):2049–2053.
10. Law S, Wong J. Changing disease burden and management issues for esophageal cancer in the Asia-Pacific region. *J Gastroenterol Hepatol.* 2002;17(4):374–381.
11. Fegelman E, Law SY, Fok M, et al. Squamous cell carcinoma of the esophagus with mucin-secreting component. Mucoepidermoid carcinoma. *J Thorac Cardiovasc Surg.* 1994;107(1):62–67.
12. Law SY, Fok M, Lam KY, Loke SL, Ma LT, Wong J. Small cell carcinoma of the esophagus. *Cancer.* 1994;73(12):2894–2899.
13. Lam KY, Law S, Luk JM, Wong J. Oesophageal basaloid squamous cell carcinoma: a unique clinicopathological entity with telomerase activity as a prognostic indicator. *J Pathol.* 2001;195(4):435–442.
14. Lam KY, Law S, Wong J. Malignant melanoma of the oesophagus: clinicopathological features, lack of p53 expression and steroid receptors and a review of the literature. *Eur J Surg Oncol.* 1999;25(2):168–172.
15. Lam KY, Law SY, Chu KM, Ma LT. Gastrointestinal autonomic nerve tumor of the esophagus. A clinicopathologic, immunohistochemical, ultrastructural study of a case and review of the literature. *Cancer.* 1996;78(8):1651–1659.
16. Cheng KK, Duffy SW, Day NE, Lam TH. Oesophageal cancer in never-smokers and never-drinkers. *Int J Cancer.* 1995;60(6):820–822.
17. Chang-Claude J, Becher H, Blettner M, Qiu S, Yang G, Wahrendorf J. Familial aggregation of oesophageal cancer in a high incidence area in China. *Int J Epidemiol.* 1997;26(6):1159–1165.



18. Li XY, Su M, Huang HH, Li H, Tian DP, Gao YX. mtDNA evidence: genetic background associated with related populations at high risk for esophageal cancer between Chaoshan and Taihang Mountain areas in China. *Genomics*. 2007;90(4):474–481.
19. Su M, Liu M, Tian DP, et al. Temporal trends of esophageal cancer during 1995–2004 in Nanao Island, an extremely high-risk area in China. *Eur J Epidemiol*. 2007;22(1):43–48.
20. Brooks PJ, Enoch MA, Goldman D, Li TK, Yokoyama A. The alcohol flushing response: an unrecognized risk factor for esophageal cancer from alcohol consumption. *PLoS Med*. 2009;6(3):e50.
21. Baan R, Straif K, Grosse Y, et al. Carcinogenicity of alcoholic beverages. *Lancet Oncol*. 2007;8(4):292–293.
22. Yokoyama T, Yokoyama A, Kato H, et al. Alcohol flushing, alcohol and aldehyde dehydrogenase genotypes, and risk for esophageal squamous cell carcinoma in Japanese men. *Cancer Epidemiol Biomarkers Prev*. 2003;12(11 Pt 1):1227–1233.
23. Yokoyama A, Kumagai Y, Yokoyama T, et al. Health risk appraisal models for mass screening for esophageal and pharyngeal cancer: an endoscopic follow-up study of cancer-free Japanese men. *Cancer Epidemiol Biomarkers Prev*. 2009;18(2):651–655.
24. Cheng KK, Day NE, Duffy SW, Lam TH, Fok M, Wong J. Pickled vegetables in the aetiology of oesophageal cancer in Hong Kong Chinese. *Lancet*. 1992;339(8805):1314–1318.
25. Yang CS. Research on esophageal cancer in China: a review. *Cancer Res*. 1980;40(8 Pt 1):2633–2644.
26. Ke L. Mortality and incidence trends from esophagus cancer in selected geographic areas of China circa 1970–90. *Int J Cancer*. 2002;102(3):271–274.
27. He D, Zhang DK, Lam KY, et al. Prevalence of HPV infection in esophageal squamous cell carcinoma in Chinese patients and its relationship to the p53 gene mutation. *Int J Cancer*. 1997;72(6):959–964.
28. Poon RT, Law SY, Chu KM, Branicki FJ, Wong J. Multiple primary cancers in esophageal squamous cell carcinoma: incidence and implications. *Ann Thorac Surg*. 1998;65(6):1529–1534.
29. Shaha AR, Hoover EL, Mitrani M, Marti JR, Krespi YP. Synchronicity, multicentricity, and metachronicity of head and neck cancer. *Head Neck Surg*. 1988;10(4):225–228.
30. Ribeiro U, Posner MC, Safatle RA, Reynolds JC. Risk factors for squamous cell carcinoma of the oesophagus [see comments]. *Br J Surg*. 1996;83(9):1174–1185.
31. Peters JH, Hagen JA, DeMeester SR. Barrett's esophagus. *J Gastrointest Surg*. 2004;8(1):1–17.
32. Lagergren J, Bergstrom R, Lindgren A, Nyren O. Symptomatic gastroesophageal reflux as a risk factor for esophageal adenocarcinoma. *N Engl J Med*. 1999;340(11):825–831.
33. Lagergren J, Bergstrom R, Nyren O. Association between body mass and adenocarcinoma of the esophagus and gastric cardia. *Ann Intern Med*. 1999;130(11):883–890.
34. Goh KL, Chang CS, Fock KM, Ke M, Park HJ, Lam SK. Gastro-oesophageal reflux disease in Asia. *J Gastroenterol Hepatol*. 2000;15(3):230–238.
35. Romero U, Cameron AJ, Schaid DJ, et al. Barrett's esophagus: prevalence in symptomatic relatives. *Am J Gastroenterol*. 2002;97(5):1127–1132.
36. Shaheen N, Ransohoff DF. Gastroesophageal reflux, Barrett esophagus, and esophageal cancer: scientific review. *JAMA*. 2002;287(15):1972–1981.
37. Graham DY. The changing epidemiology of GERD: geography and *Helicobacter pylori*. *Am J Gastroenterol*. 2003;98(7):1462–1470.
38. Shen Q, Wang D, Xiang Y, Liu S, Dawsey S. Esophageal balloon cytology (EBC) in China: a 30-year review. *Acta Cytol*. 1998;43(suppl):566.
39. Nabeya K, Hanaoka T, Onozawa K, Ri S, Nyumura T, Kaku C. Early diagnosis of esophageal cancer. *Hepatogastroenterology*. 1990;37(4):368–370.
40. Wang GQ, Jiao GG, Chang FB, et al. Long-term results of operation for 420 patients with early squamous cell esophageal carcinoma discovered by screening. *Ann Thorac Surg*. 2004;77(5):1740–1744.
41. Wang GQ, Abnet CC, Shen Q, et al. Histological precursors of oesophageal squamous cell carcinoma: results from a 13 year prospective follow up study in a high risk population. *Gut*. 2005;54(2):187–192.
42. Dong Z, Tang R Li L, Wang G. The strategy for esophageal cancer control in high-risk areas of China. *Jpn J Clin Oncol*. 2002;32(suppl):S10–S12.
43. Blot WJ, Li JY, Taylor PR, Guo W, Dawsey SM, Li B. The Linxian trials: mortality rates by vitamin-mineral intervention group. *Am J Clin Nutr*. 1995;62(6 suppl):1424S–1426S.
44. van der Burgh A, Dees J, Hop WCJ, van Blankenstein M. Oesophageal cancer is an uncommon cause of death in patients with Barrett's oesophagus. *Gut*. 1996;39:5–8.
45. Shaheen NJ. Does surveillance endoscopy improve life expectancy in those with Barrett's esophagus? *Gastroenterology*. 2001;121(6):1516–1518.
46. Eckardt VF, Kanzler G, Bernhard G. Life expectancy and cancer risk in patients with Barrett's esophagus: a prospective controlled investigation. *Am J Med*. 2001;111(1):33–37.
47. Peters JH, Clark GW, Ireland AP, Chandrasoma P, Smyrk TC, DeMeester TR. Outcome of adenocarcinoma arising in Barrett's esophagus in endoscopically surveyed and non-surveyed patients. *J Thorac Cardiovasc Surg*. 1994;108(5):813–821; discussion 821–822.
48. Wang KK, Sampliner RE. Updated guidelines 2008 for the diagnosis, surveillance and therapy of Barrett's esophagus. *Am J Gastroenterol*. 2008;103(3):788–797.
49. Shaheen NJ, Provenzale D, Sandler RS. Upper endoscopy as a screening and surveillance tool in esophageal adenocarcinoma: a review of the evidence. *Am J Gastroenterol*. 2002;97(6):1319–1327.
50. Sharma P, McQuaid K, Dent J, et al. A critical review of the diagnosis and management of Barrett's esophagus: the AGA Chicago Workshop. *Gastroenterology*. 2004;127(1):310–330.
51. Bird-Lieberman EL, Fitzgerald RC. Barrett's esophagus. *Gastroenterol Clin North Am*. 2008;37(4):921–942, x.
52. El Serag HB, Aguirre TV, Davis S, Kuebler M, Bhattacharyya A, Sampliner RE. Proton pump inhibitors are associated with reduced incidence of dysplasia in Barrett's esophagus. *Am J Gastroenterol*. 2004;99(10):1877–1883.
53. Corley DA, Kerlikowske K, Verma R, Buffler P. Protective association of aspirin/NSAIDs and esophageal cancer: a systematic review and meta-analysis. *Gastroenterology*. 2003;124(1):47–56.
54. Heath EI, Canto MI, Piantadosi S, et al. Secondary chemoprevention of Barrett's esophagus with celecoxib: results of a randomized trial. *J Natl Cancer Inst*. 2007;99(7):545–557.
55. Jankowski J, Barr H. Improving surveillance for Barrett's oesophagus: AsPECT and BOSS trials provide an evidence base. *BMJ*. 2006;332(7556):1512.
56. Siewert JR, Stein HJ, Feith M, Bruecher BL, Bartels H, Fink U. Histologic tumor type is an independent prognostic parameter in esophageal cancer: lessons from more than 1,000 consecutive resections at a single center in the Western world. *Ann Surg*. 2001;234(3):360–367.
57. American Joint Committee on Cancer. Esophagus. *AJCC Cancer Staging Manual*. New York, NY: Springer Verlag; 2009.
58. Siewert JR, Feith M, Werner M, Stein HJ. Adenocarcinoma of the esophagogastric junction: results of surgical therapy based on anatomical/topographic classification in 1,002 consecutive patients. *Ann Surg*. 2000;232(3):353–361.
59. Akiyama H, Kogure T, Itai Y. The esophageal axis and its relationship to the resectability of carcinoma of the esophagus. *Ann Surg*. 1972;176(1):30–36.
60. Cheung HC, Siu KF, Wong J. A comparison of flexible and rigid endoscopy in evaluating esophageal cancer patients for surgery. *World J Surg*. 1988;12(1):117–122.
61. Riedel M, Stein HJ, Mounyam L, Lembeck R, Siewert JR. Extensive sampling improves preoperative bronchoscopic assessment of airway invasion by supracarinal esophageal cancer: a prospective study in 166 patients. *Chest*. 2001;119(6):1652–1660.
62. Rice TW. Clinical staging of esophageal carcinoma. CT, EUS, and PET. *Chest Surg Clin N Am*. 2000;10(3):471–485.
63. Margolis ML, Howlett P, Bubanj R. Pulmonary nodules in patients with esophageal carcinoma. *J Clin Gastroenterol*. 1998;26(4):245–248.
64. Picus D, Balfe DM, Koehler RE, Roper CL, Owen JW. Computed tomography in the staging of esophageal carcinoma. *Radiology*. 1983;146(2):433–438.
65. Kato H, Kuwano H, Nakajima M, et al. Comparison between positron emission tomography and computed tomography in the use of the assessment of esophageal carcinoma. *Cancer*. 2002;94(4):921–928.
66. Berger AC, Scott WJ. Noninvasive staging of esophageal carcinoma. *J Surg Res*. 2004;117(1):127–133.
67. Lehr L, Rupp N, Siewert JR. Assessment of resectability of esophageal cancer by computed tomography and magnetic resonance imaging. *Surgery*. 1988;103(3):344–350.
68. Rosch T. Endoscopic staging of esophageal cancer: a review of literature results. *Gastrointest Endosc Clin N Am*. 1995;5(3):537–547.
69. Fok M, Cheng SW, Wong J. Endosonography in patient selection for surgical treatment of esophageal carcinoma. *World J Surg*. 1992;16(6):1098–1103.

70. Bumm R. Staging and risk-analysis in esophageal carcinoma. *Dis Esophagus* 1996;9(1 suppl):20–29.
71. Vickers J, Alderson D. Influence of luminal obstruction on oesophageal cancer staging using endoscopic ultrasonography. *Br J Surg*. 1998; 85(7):999–1001.
72. Van Dam J, Rice TW, Catalano MF, Kirby T, Sivak-MV J. High-grade malignant stricture is predictive of esophageal tumor stage. Risks of endosonographic evaluation. *Cancer*. 1993;71(10):2910–2917.
73. Wallace MB, Hawes RH, Sahai AV, Van Velse A, Hoffman BJ. Dilation of malignant esophageal stenosis to allow EUS guided fine-needle aspiration: safety and effect on patient management. *Gastrointest Endosc*. 2000;51(3):309–313.
74. Hunerbein M, Ghadimi BM, Haensch W, Schlag PM. Transendoscopic ultrasound of esophageal and gastric cancer using miniaturized ultrasound catheter probes. *Gastrointest Endosc*. 1998;48(4):371–375.
75. Catalano MF, Sivak-MV J, Rice T, Gragg LA, Van DJ. Endosonographic features predictive of lymph node metastasis. *Gastrointest Endosc*. 1994; 40(4):442–446.
76. Chandawarkar RY, Kakegawa T, Fujita H, Yamana H, Toh Y, Fujitoh H. Endosonography for preoperative staging of specific nodal groups associated with esophageal cancer. *World J Surg*. 1996;20(6):700–702.
77. Parmar KS, Zwischenberger JB, Reeves AL, Waxman I. Clinical impact of endoscopic ultrasound-guided fine needle aspiration of celiac axis lymph nodes (M1a disease) in esophageal cancer. *Ann Thorac Surg*. 2002;73(3):916–920.
78. Natsugoe S, Yoshinaka H, Shimada M, et al. Assessment of cervical lymph node metastasis in esophageal carcinoma using ultrasonography. *Ann Surg*. 1999;229(1):62–66.
79. Natsugoe S, Yoshinaka H, Shimada M, et al. Number of lymph node metastases determined by presurgical ultrasound and endoscopic ultrasound is related to prognosis in patients with esophageal carcinoma. *Ann Surg*. 2001;234(5):613–618.
80. Flanagan FL, Dehdashti F, Siegel BA, et al. Staging of esophageal cancer with 18F-fluorodeoxyglucose positron emission tomography. *AJR Am J Roentgenol*. 1997;168(2):417–424.
81. Luketich JD, Friedman DM, Weigel TL, et al. Evaluation of distant metastases in esophageal cancer: 100 consecutive positron emission tomography scans. *Ann Thorac Surg*. 1999;68(4):1133–1136.
82. Flamen P, Lerut A, Van Cutsem E, et al. Utility of positron emission tomography for the staging of patients with potentially operable esophageal carcinoma. *J Clin Oncol*. 2000;18(18):3202–3210.
83. Flamen P, Lerut T, Hausermans K, Van Cutsem E, Mortelmans L. Position of positron emission tomography and other imaging diagnostic modalities in esophageal cancer. *Q J Nucl Med Mol Imaging*. 2004;48(2):96–108.
84. Rasanen JV, Sihvo EI, Knuuti MJ, et al. Prospective analysis of accuracy of positron emission tomography, computed tomography, and endoscopic ultrasonography in staging of adenocarcinoma of the esophagus and the esophagogastric junction. *Ann Surg Oncol*. 2003;10(8):954–960.
85. van Westreenen HL, Westertep M, Bossuyt PM, et al. Systematic review of the staging performance of 18F-fluorodeoxyglucose positron emission tomography in esophageal cancer. *J Clin Oncol*. 2004;22(18): 3805–3812.
86. Meyers BF, Downey RJ, Decker PA, et al. The utility of positron emission tomography in staging of potentially operable carcinoma of the thoracic esophagus: results of the American College of Surgeons Oncology Group Z0060 trial. *J Thorac Cardiovasc Surg*. 2007;133(3):738–745.
87. Krasna MJ, Reed CE, Nedzwicki D, et al. CALGB 9380: a prospective trial of the feasibility of thoracoscopy/laparoscopy in staging esophageal cancer. *Ann Thorac Surg*. 2001;71(4):1073–1079.
88. Stein HJ, Kraemer SJ, Feussner H, Fink U, Siewert JR. Clinical value of diagnostic laparoscopy with laparoscopic ultrasound in patients with cancer of the esophagus or cardia. *J Gastrointest Surg*. 1997;1(2):167–173.
89. Kodama M, Kakegawa T. Treatment of superficial cancer of the esophagus: a summary of responses to a questionnaire on superficial cancer of the esophagus in Japan. *Surgery*. 1998;123(4):432–439.
90. Japan Esophageal Society. Guidelines for diagnosis and treatment of carcinoma of the esophagus part 1. *Esophagus*. 2008;5(2):61–73.
91. Inoue H, Fukami N, Yoshida T, Kudo SE. Endoscopic mucosal resection for esophageal and gastric cancers. *J Gastroenterol Hepatol*. 2002; 17(4):382–388.
92. Ormsby AH, Petras RE, Henricks WH, et al. Observer variation in the diagnosis of superficial oesophageal adenocarcinoma. *Gut*. 2002;51(5):671–676.
93. Korst RJ, Altorki NK. High grade dysplasia: surveillance, mucosal ablation, or resection? *World J Surg*. 2003;27(9):1030–1034.
94. Konda VJ, Ross AS, Ferguson MK, et al. Is the risk of concomitant invasive esophageal cancer in high-grade dysplasia in Barrett's esophagus overestimated? *Clin Gastroenterol Hepatol*. 2008;6(2):159–164.
95. Wang VS, Hornick JL, Sepulveda JA, Mauer R, Ponerros JM. Low prevalence of submucosal invasive carcinoma at esophagectomy for high-grade dysplasia or intramucosal adenocarcinoma in Barrett's esophagus: a 20-year experience. *Gastrointest Endosc*. 2009;69(4):777–783.
96. Altorki NK, Lee PC, Liss Y, et al. Multifocal neoplasia and nodal metastases in T1 esophageal carcinoma: implications for endoscopic treatment. *Ann Surg*. 2008;247(3):434–439.
97. Feith M, Stein HJ, Siewert JR. Pattern of lymphatic spread of Barrett's cancer. *World J Surg*. 2003;27(9):1052–1057.
98. Ell C, May A, Pech O, et al. Curative endoscopic resection of early esophageal adenocarcinomas (Barrett's cancer). *Gastrointest Endosc*. 2007;65(1):3–10.
99. Lopes CV, Hela M, Pesenti C, et al. Circumferential endoscopic resection of Barrett's esophagus with high-grade dysplasia or early adenocarcinoma. *Surg Endosc*. 2007;21(5):820–824.
100. Overholt BF, Wang KK, Burdick JS, et al. Five-year efficacy and safety of photodynamic therapy with Photofrin in Barrett's high-grade dysplasia. *Gastrointest Endosc*. 2007;66(3):460–468.
101. Ban S, Mino M, Nishioka NS, et al. Histopathologic aspects of photodynamic therapy for dysplasia and early adenocarcinoma arising in Barrett's esophagus. *Am J Surg Pathol*. 2004;28(11):1466–1473.
102. Fleischer DE, Overholt BF, Sharma VK, et al. Endoscopic ablation of Barrett's esophagus: a multicenter study with 2.5-year follow-up. *Gastrointest Endosc*. 2008;68(5):867–876.
103. Shaheen NJ, Sharma P, Overholt BF, et al. Radiofrequency ablation in Barrett's esophagus with dysplasia. *N Engl J Med*. 2009;360(22):2277–2288.
104. Perry KA, Enestvedt CK, Pham T, et al. Comparison of laparoscopic inversion esophagectomy and open transhiatal esophagectomy for high-grade dysplasia and stage I esophageal adenocarcinoma. *Arch Surg*. 2009;144(7):679–684.
105. Moraca RJ, Low DE. Outcomes and health-related quality of life after esophagectomy for high-grade dysplasia and intramucosal cancer. *Arch Surg*. 2006;141(6):545–549.
106. Peyre CG, DeMeester SR, Rizzetto C, et al. Vagal-sparing esophagectomy: the ideal operation for intramucosal adenocarcinoma and Barrett with high-grade dysplasia. *Ann Surg*. 2007;246(4):665–671.
107. Stein HJ, Feith M, Mueller J, Werner M, Siewert JR. Limited resection for early adenocarcinoma in Barrett's esophagus. *Ann Surg*. 2000;232(6): 733–742.
108. Hagen JA, DeMeester SR, Peters JH, Chandrasoma P, DeMeester TR. Curative resection for esophageal adenocarcinoma: analysis of 100 en bloc esophagectomies. *Ann Surg*. 2001;234(4):520–530.
109. Altorki N, Kent M, Ferrara C, Port J. Three-field lymph node dissection for squamous cell and adenocarcinoma of the esophagus. *Ann Surg*. 2002;236(2):177–183.
110. Ando N, Ozawa S, Kitagawa Y, Shinozawa Y, Kitajima M. Improvement in the results of surgical treatment of advanced squamous esophageal carcinoma during 15 consecutive years. *Ann Surg*. 2000;232(2):225–232.
111. Birkmeyer JD, Stukel TA, Siewers AE, Goodney PP, Wennberg DE, Lucas FL. Surgeon volume and operative mortality in the United States. *N Engl J Med*. 2003;349(22):2117–2127.
112. Law S, Wong KH, Kwok KF, Chu KM, Wong J. Predictive factors for postoperative pulmonary complications and mortality after esophagectomy for cancer. *Ann Surg*. 2004;240(5):791–800.
113. Birkmeyer JD, Sun Y, Wong SL, Stukel TA. Hospital volume and late survival after cancer surgery. *Ann Surg*. 2007;245(5):777–783.
114. Wouters MW, Karim-Kos HE, le Cessie S, et al. Centralization of esophageal cancer surgery: does it improve clinical outcome? *Ann Surg Oncol*. 2009;16(7):1789–1798.
115. Pye JK, Crumplin MK, Charles J, Kerwat R, Foster ME, Biffin A. One-year survey of carcinoma of the oesophagus and stomach in Wales. *Br J Surg*. 2001;88(2):278–285.
116. Bartels H, Stein HJ, Siewert JR. Preoperative risk analysis and postoperative mortality of oesophagectomy for resectable oesophageal cancer. *Br J Surg*. 1998;85(6):840–844.
117. Fekete F, Belghiti J. Nutrition factors and oesophageal resection. In: Jamieson GG, ed. *Surgery of the Oesophagus*. Edinburgh, UK: Churchill Livingstone, 1988:110–124.

118. Law SY, Fok M, Wong J. Risk analysis in resection of squamous cell carcinoma of the esophagus. *World J Surg.* 1994;18(3):339–346.
119. Peracchia A, Bonavina L, Fumagalli U, Bona S, Chella B, eds. Esophageal and cardiac cancers concomitant with liver cirrhosis: prevalence and treatment results in 273 consecutive cases. In: *Recent Advances in Diseases of the Esophagus.* Bologna, Italy: Monduzzi Editore; 1996.
120. Bollschweiler E, Schroder W, Holscher AH, Siewert JR. Preoperative risk analysis in patients with adenocarcinoma or squamous cell carcinoma of the oesophagus. *Br J Surg.* 2000;87(8):1106–1110.
121. Lagarde SM, Maris AK, de Castro SM, Busch OR, Obertop H, van Lanschot JJ. Evaluation of O-POSSUM in predicting in-hospital mortality after resection for oesophageal cancer. *Br J Surg.* 2007;94(12):1521–1526.
122. Ong GB, Lee Y. Pharyngogastric anastomosis after oesophago-pharyngectomy for carcinoma of the hypopharynx and cervical oesophagus. *Br J Surg.* 1960;48:193–200.
123. Law SY, Fok M, Wei WI, et al. Thoracoscopic esophageal mobilization for pharyngolaryngo-oesophagectomy. *Ann Thorac Surg.* 2000;70(2):418–422.
124. Wei WI, Lam LK, Yuen PW, Wong J. Current status of pharyngolaryngo-oesophagectomy and pharyngogastric anastomosis. *Head Neck.* 1998;20(3):240–244.
125. Schusterman MA, Shestak K, de VE, et al. Reconstruction of the cervical esophagus: free jejunal transfer versus gastric pull-up. *Plast Reconstr Surg.* 1990;85(1):16–21.
126. Reece GP, Schusterman MA, Miller MJ, et al. Morbidity and functional outcome of free jejunal transfer reconstruction for circumferential defects of the pharynx and cervical esophagus. *Plast Reconstr Surg.* 1995;96(6):1307–1316.
127. Wei WI, Lam LK, Yuen PW, Kwong D, Chan KW. Mucosal changes of the free jejunal graft in response to radiotherapy. *Am J Surg.* 1998;175(1):44–46.
128. Burmeister BH, Dickie G, Smithers BM, Hodge R, Morton K. Thirty-four patients with carcinoma of the cervical esophagus treated with chemoradiation therapy. *Arch Otolaryngol Head Neck Surg.* 2000;126(2):205–208.
129. McKeown KC. Total three-stage oesophagectomy for cancer of the oesophagus. *Br J Surg.* 1976;63(4):259–262.
130. Orringer MB. Partial median sternotomy: anterior approach to the upper thoracic esophagus. *J Thorac Cardiovasc Surg.* 1984;87(1):124–129.
131. Moorehead RJ, Paterson I, Wong J. The split-sternum approach to carcinoma of the superior mediastinal esophagus. *Dig Surg.* 1989;6:114–117.
132. Orringer MB, Marshall B, Chang AC, Lee J, Pickens A, Lau CL. Two thousand transhiatal esophagectomies: changing trends, lessons learned. *Ann Surg.* 2007;246(3):363–372.
133. Katariya K, Harvey JC, Pina E, Beattie EJ. Complications of transhiatal esophagectomy. *J Surg Oncol.* 1994;57(3):157–163.
134. Chang AC, Ji H, Birkmeyer NJ, Orringer MB, Birkmeyer JD. Outcomes after transhiatal and transthoracic esophagectomy for cancer. *Ann Thorac Surg.* 2008;85(2):424–429.
135. Omloo JM, Lagarde SM, Hulscher JB, et al. Extended transthoracic resection compared with limited transhiatal resection for adenocarcinoma of the mid/distal esophagus: five-year survival of a randomized clinical trial. *Ann Surg.* 2007;246(6):992–1000.
136. Law S. Minimally invasive techniques for oesophageal cancer surgery. *Best Pract Res Clin Gastroenterol.* 2006;20(5):925–940.
137. Smithers BM, Gotley DC, Martin I, Thomas JM. Comparison of the outcomes between open and minimally invasive esophagectomy. *Ann Surg.* 2007;245(2):232–240.
138. Luketich JD, Alvelo-Rivera M, Buenaventura PO, et al. Minimally invasive esophagectomy: outcomes in 222 patients. *Ann Surg.* 2003;238(4):486–494.
139. Yamamoto S, Kawahara K, Maekawa T, Shiraishi T, Shirakusa T. Minimally invasive esophagectomy for stage I and II esophageal cancer. *Ann Thorac Surg.* 2005;80(6):2070–2075.
140. Palanivelu C, Prakash A, Senthilkumar R, et al. Minimally invasive esophagectomy: thoracoscopic mobilization of the esophagus and mediastinal lymphadenectomy in prone position—experience of 130 patients. *J Am Coll Surg.* 2006;203(1):7–16.
141. Law S, Wong J. Use of minimally invasive oesophagectomy for cancer of the oesophagus. *Lancet Oncol.* 2002;3:215–222.
142. Gemmill EH, McCulloch P. Systematic review of minimally invasive resection for gastro-oesophageal cancer. *Br J Surg.* 2007;94(12):1461–1467.
143. Decker G, Coosemans W, De Leyn P, et al. Minimally invasive esophagectomy for cancer. *Eur J Cardiothorac Surg.* 2009;35(1):13–20.
144. Biere SS, Cuesta MA, van der Peet DL. Minimally invasive versus open esophagectomy for cancer: a systematic review and meta-analysis. *Minerva Chir.* 2009;64(2):121–133.
145. Peracchia A, Rosati R, Fumagalli U, Bona S, Chella B. Thoracoscopic dissection of the esophagus for cancer. *Int Surg.* 1997;82(1):1–4.
146. Collard JM, Lengele B, Otte JB, Kestens PJ. En bloc and standard esophagectomies by thoracoscopy. *Ann Thorac Surg.* 1993;56(3):675–679.
147. McAnena OJ, Rogers J, Williams NS. Right thoracoscopically assisted esophagectomy for cancer. *Br J Surg.* 1994;81:236–238.
148. Cuschieri A. Thoracoscopic subtotal oesophagectomy. *Endosc Surg Allied Technol.* 1994;2(1):21–25.
149. Bumm R, Feussner H, Bartels H, et al. Radical transhiatal esophagectomy with two-field lymphadenectomy and endodissection for distal esophageal adenocarcinoma. *World J Surg.* 1997;21(8):822–831.
150. Kawahara K, Maekawa T, Okabayashi K, et al. Video-assisted thoracoscopic esophagectomy for esophageal cancer. *Surg Endosc.* 1999;13(3):218–223.
151. Gosso D, Cattani P, Fritsch S, Halimi B, Sarfati E, Celerier M. Can the morbidity of esophagectomy be reduced by the thoracoscopic approach? *Surg Endosc.* 1995;9(10):1113–1115.
152. Dexter SP, Martin IG, McMahon MJ. Radical thoracoscopic esophagectomy for cancer. *Surg Endosc.* 1996;10(2):147–151.
153. Tsui SL, Law S, Fok M, et al. Postoperative analgesia reduces mortality and morbidity after esophagectomy. *Am J Surg.* 1997;173(6):472–478.
154. Osugi H, Takemura M, Higashino M, et al. Learning curve of video-assisted thoracoscopic esophagectomy and extensive lymphadenectomy for squamous cell cancer of the thoracic esophagus and results. *Surg Endosc.* 2003;17(3):515–519.
155. Akaishi T, Kaneda I, Higuchi N, et al. Thoracoscopic en bloc total esophagectomy with radical mediastinal lymphadenectomy. *J Thorac Cardiovasc Surg.* 1996;112(6):1533–1540.
156. Nguyen NT, Roberts P, Follette DM, Rivers R, Wolfe BM. Thoracoscopic and laparoscopic esophagectomy for benign and malignant disease: lessons learned from 46 consecutive procedures. *J Am Coll Surg.* 2003;197(6):902–913.
157. Law S, Wong J. Lymph node dissection in surgical treatment of esophageal neoplasms. *Surg Oncol Clin N Am.* 2007;16(1):115–131.
158. Tsutsui S, Kuwano H, Watanabe M, Kitamura M, Sugimachi K. Resection margin for squamous cell carcinoma of the esophagus. *Ann Surg.* 1995;222(2):193–202.
159. Lam KY, Ma LT, Wong J. Measurement of extent of spread of oesophageal squamous carcinoma by serial sectioning. *J Clin Pathol.* 1996;49:124–129.
160. Pesko P, Rakic S, Milicevic M, Bulajic P, Gerzic Z. Prevalence and clinicopathologic features of multiple squamous cell carcinoma of the esophagus. *Cancer.* 1994;73:2687–2690.
161. Law S, Arcilla C, Chu KM, Wong J. The significance of histologically infiltrated resection margin after esophagectomy for esophageal cancer. *Am J Surg.* 1998;176:286–290.
162. Dexter SP, Sue-Ling H, McMahon MJ, Quirke P, Mapstone N, Martin IG. Circumferential resection margin involvement: an independent predictor of survival following surgery for oesophageal cancer. *Gut.* 2001;48(5):667–670.
163. Altorki N, Skinner D. Should en bloc esophagectomy be the standard of care for esophageal carcinoma? *Ann Surg.* 2001;234(5):581–587.
164. Akiyama H, Tsurumaru M, Udagawa H, Kajiyama Y. Radical lymph node dissection for cancer of the thoracic esophagus. *Ann Surg.* 1994;220(3):364–372.
165. Tachibana M, Kinugasa S, Yoshimura H, Dhar DK, Nagasue N. Extended esophagectomy with 3-field lymph node dissection for esophageal cancer. *Arch Surg.* 2003;138(12):1383–1389.
166. Baba M, Aikou T, Natsugoe S, et al. Quality of life following esophagectomy with three-field lymphadenectomy for carcinoma, focusing on its relationship to vocal cord palsy. *Dis Esophagus.* 1998;11(1):28–34.
167. Fujita H, Kakegawa T, Yamana H, et al. Mortality and morbidity rates, postoperative course, quality of life, and prognosis after extended radical lymphadenectomy for esophageal cancer. Comparison of three-field lymphadenectomy with two-field lymphadenectomy. *Ann Surg.* 1995;222(5):654–662.
168. Baba M, Aikou T, Yoshinaka H, et al. Long term results of subtotal esophagectomy with three-field lymphadenectomy for carcinoma of the thoracic esophagus. *Ann Thorac Surg.* 1994;219(3):310–316.



169. Nishimaki T, Suzuki T, Suzuki S, Kuwabara S, Hatakeyama K. Outcomes of extended radical esophagectomy for thoracic esophageal cancer. *J Am Coll Surg*. 1998;186(3):306–312.
170. Yoshioka S, Fujiwara Y, Sugita Y, et al. Real-time rapid reverse transcriptase-polymerase chain reaction for intraoperative diagnosis of lymph node micrometastasis: clinical application for cervical lymph node dissection in esophageal cancers. *Surgery*. 2002;132(1):34–40.
171. Kitagawa Y, Fujii H, Mukai M, Kubo A, Kitajima M. Sentinel lymph node mapping in esophageal and gastric cancer. *Cancer Treat Res*. 2005;127:123–139.
172. Noguchi T, Wada S, Takeno S, Hashimoto T, Moriyama H, Uchida Y. Two-step three-field lymph node dissection is beneficial for thoracic esophageal carcinoma. *Dis Esophagus*. 2004;17(1):27–31.
173. Hosokawa M, Shirato H, Ohara M, et al. Intraoperative radiation therapy to the upper mediastinum and nerve-sparing three-field lymphadenectomy followed by external beam radiotherapy for patients with thoracic esophageal carcinoma. *Cancer*. 1999;86(1):6–13.
174. Udagawa H, Akiyama H. Surgical treatment of esophageal cancer: Tokyo experience of the three-field technique. *Dis Esophagus*. 2001;14(2):110–114.
175. Isono K, Sato H, Nakayama K. Results of a nationwide study on the three fields of lymph node dissection in esophageal cancer. *Oncology*. 1991;48:411–420.
176. Kato H, Watanabe H, Tachimori Y, Iizuka T. Evaluation of neck lymph node dissection for thoracic esophageal carcinoma. *Ann Thorac Surg*. 1991;51:931–935.
177. Nishihira T, Hirayama K, Mori S. A prospective randomized trial of extended cervical and superior mediastinal lymphadenectomy for carcinoma of the thoracic esophagus. *Am J Surg*. 1998;175(1):47–51.
178. Stein HJ, Feith M, Bruecher BL, Naehrig J, Sarbia M, Siewert JR. Early esophageal cancer: pattern of lymphatic spread and prognostic factors for long-term survival after surgical resection. *Ann Surg*. 2005;242(4):566–573.
179. Lagarde SM, Cense HA, Hulscher JB, et al. Prospective analysis of patients with adenocarcinoma of the gastric cardia and lymph node metastasis in the proximal field of the chest. *Br J Surg*. 2005;92(11):1404–1408.
180. Johansson J, DeMeester TR, Hagen JA, et al. En bloc vs transhiatal esophagectomy for stage T3 N1 adenocarcinoma of the distal esophagus. *Arch Surg*. 2004;139(6):627–631.
181. Portale G, Hagen JA, Peters JH, et al. Modern 5-year survival of resectable esophageal adenocarcinoma: single institution experience with 263 patients. *J Am Coll Surg*. 2006;202(4):588–596.
182. Clark GW, Peters JH, Ireland AP, et al. Nodal metastasis and sites of recurrence after en bloc esophagectomy for adenocarcinoma. *Ann Thorac Surg*. 1994;58(3):646–653.
183. Hagen JA, Peters JH, DeMeester TR. Superiority of extended en bloc esophagectomy for carcinoma of the lower esophagus and cardia. *J Thorac Cardiovasc Surg*. 1993;106(5):850–858.
184. Lerut T, Coosemans W, De Leyn P, et al. Reflections on three field lymphadenectomy in carcinoma of the esophagus and gastroesophageal junction. *Hepatogastroenterology*. 1999;46(26):717–725.
185. Altorki NK, Zhou XK, Stiles B, et al. Total number of resected lymph nodes predicts survival in esophageal cancer. *Ann Surg*. 2008;248(2):221–226.
186. Peyre CG, Hagen JA, DeMeester SR, et al. The number of lymph nodes removed predicts survival in esophageal cancer: an international study on the impact of extent of surgical resection. *Ann Surg*. 2008;248(4):549–556.
187. Greenstein AJ, Litle VR, Swanson SJ, Divino CM, Packer S, Wisnivesky JP. Effect of the number of lymph nodes sampled on postoperative survival of lymph node-negative esophageal cancer. *Cancer*. 2008;112(6):1239–1246.
188. Schwarz RE, Smith DD. Clinical impact of lymphadenectomy extent in resectable esophageal cancer. *J Gastrointest Surg*. 2007;11(11):1384–1393.
189. Rizk NP, Ishwaran H, Rice TW, et al. Optimum lymphadenectomy for esophageal cancer. *Ann Surg*. 2010;251:46–50.
190. Liebermann-Meffert DMI, Meier R, Siewert JR. Vascular anatomy of the gastric tube used for esophageal reconstruction. *Ann Thorac Surg*. 1992;54:1110–1115.
191. Cerfolio RJ, Allen MS, Deschamps C, Trastek VF, Pairolero PC. Esophageal replacement by colon interposition. *Ann Thorac Surg*. 1995;59(6):1382–1384.
192. O'Riordan JM, Tucker ON, Byrne PJ, et al. Factors influencing the development of Barrett's epithelium in the esophageal remnant postesophagectomy. *Am J Gastroenterol*. 2004;99(2):205–211.
193. Fok M, Cheng SW, Wong J. Pyloroplasty versus no drainage in gastric replacement of the esophagus. *Am J Surg*. 1991;162(5):447–452.
194. Urschel JD, Blewett CJ, Young JE, Miller JD, Bennett WF. Pyloric drainage (pyloroplasty) or no drainage in gastric reconstruction after esophagectomy: a meta-analysis of randomized controlled trials. *Dig Surg*. 2002;19(3):160–164.
195. Bemelman WA, Taat CW, Slors JFM, van Lanschoot JJB, Ober-top H. Delayed postoperative emptying after esophageal resection is dependent on the size of the gastric substitute. *J Am Coll Surg*. 1995;180:461–464.
196. Nakabayashi T, Mochiki E, Garcia M, et al. Gastropyloric motor activity and the effects of erythromycin given orally after esophagectomy. *Am J Surg*. 2002;183(3):317–323.
197. Gutschow CA, Collard JM, Romagnoli R, Michel JM, Salizzoni M, Holscher AH. Bile exposure of the denervated stomach as an esophageal substitute. *Ann Thorac Surg*. 2001;71(6):1786–1791.
198. Furst H, Huttel TP, Lohe F, Schildberg FW. German experience with colon interposition grafting as an esophageal substitute. *Dis Esophagus*. 2001;14(2):131–134.
199. Davis PA, Law S, Wong J. Colonic interposition after esophagectomy for cancer. *Arch Surg*. 2003;138(3):303–308.
200. Moreno-Osset E, Tomas-Ridocci M, Paris F, et al. Motor activity of esophageal substitute (stomach, jejunal, and colon segments). *Ann Thorac Surg*. 1986;41(5):515–519.
201. Paris F, Tomas-Ridocci M, Galan G, et al. The colon as oesophageal substitute in non-malignant disease. Long-term clinical results and functional studies. *Eur J Cardiothorac Surg*. 1991;5(9):474–478.
202. Myers JC, Mathew G, Watson DI, Jamieson GG. Peristalsis in an interposed colonic segment immediately following total oesophagogastricectomy. *Aust N Z J Surg*. 1998;68(4):278–280.
203. Isolaure J, Koskinen MO, Markkula H. Radionuclide transit in patients with colon interposition. *J Thorac Cardiovasc Surg*. 1987;94(4):521–525.
204. DeMeester TR, Johansson KE, Franze I, et al. Indications, surgical technique, and long-term functional results of colon interposition or bypass. *Ann Surg*. 1988;208(4):460–474.
205. Stein HJ, Feith M, von Rahden BH, Siewert JR, Rahden BA. Approach to early Barrett's cancer. *World J Surg*. 2003;27(9):1040–1046.
206. Ascoti AJ, Hofstetter WL, Miller MJ, et al. Long-segment, supercharged, pedicled jejunal flap for total esophageal reconstruction. *J Thorac Cardiovasc Surg*. 2005;130(5):1391–1398.
207. Bartels H, Thorban S, Siewert JR. Anterior versus posterior reconstruction after transhiatal oesophagectomy: a randomized controlled trial. *Br J Surg*. 1993;80(9):1141–1144.
208. Gawad KA, Hosch SB, Bumann D, et al. How important is the route of reconstruction after esophagectomy: a prospective randomized study. *Am J Gastroenterol*. 1999;94(6):1490–1496.
209. van Lanschoot JJ, van Blankenstein M, Oei HY, Tilanus HW. Randomized comparison of prevertebral and retrosternal gastric tube reconstruction after resection of oesophageal carcinoma. *Br J Surg*. 1999;86(1):102–108.
210. Ngan SYK, Wong J. Lengths of different routes for esophageal replacement. *J Thorac Cardiovasc Surg*. 1986;91:790–792.
211. Orringer MB, Marshall B, Iannettoni MD. Transhiatal esophagectomy: clinical experience and refinements. *Ann Surg*. 1999;230(3):392–400.
212. van Lanschoot JJ, Hop WC, Voormolen MH, van Deelen RA, Blomjous JG, Tilanus HW. Quality of palliation and possible benefit of extra-anatomic reconstruction in recurrent dysphagia after resection of carcinoma of the esophagus. *J Am Coll Surg*. 1994;179(6):705–713.
213. van Lanschoot JJ, Tilanus HW, Voormolen MH, van Deelen RA. Recurrence pattern of oesophageal carcinoma after limited resection does not support wide local excision with extensive lymph node dissection. *Br J Surg*. 1994;81(9):1320–1323.
214. Wong AC, Law S, Wong J. Influence of the route of reconstruction on morbidity, mortality and local recurrence after esophagectomy for cancer. *Dig Surg*. 2003;20(3):209–214.
215. Murthy SC, Law S, Whooley BP, Alexandrou A, Chu KM, Wong J. Atrial fibrillation after esophagectomy is a marker for postoperative morbidity and mortality. *J Thorac Cardiovasc Surg*. 2003;126(4):1162–1167.
216. Bailey SH, Bull DA, Harpole DH, et al. Outcomes after esophagectomy: a ten-year prospective cohort. *Ann Thorac Surg*. 2003;75(1):217–222.
217. Law S, Boey JP, Kwok KF, Wong KH, Chu KM, Wong J. Pleural drainage after transthoracic esophagectomy: experience with a vacuum system. *Dis Esophagus*. 2004;17(1):81–86.

218. Whooley BP, Law S, Murthy SC, Alexandrou A, Wong J. Analysis of reduced death and complication rates after esophageal resection. *Ann Surg.* 2001;233(3):338–344.
219. Hsu HK, Hsu WH, Huang MH. Prospective study of using fibrin glue to prevent leak from esophagogastric anastomosis. *J Surg Assoc ROC.* 1992;25:1248–1252.
220. Whooley BP, Law S, Alexandrou A, Murthy SC, Wong J. Critical appraisal of the significance of intrathoracic anastomotic leakage after esophagectomy for cancer. *Am J Surg.* 2001;181(3):198–203.
221. Holscher AH, Schneider PM, Gutschow C, Schroder W. Laparoscopic ischemic conditioning of the stomach for esophageal replacement. *Ann Surg.* 2007;245(2):241–246.
222. Law S, Fok M, Chu KM, Wong J. Comparison of hand-sewn and stapled esophagogastric anastomosis after esophageal resection for cancer: a prospective randomized controlled trial. *Ann Surg.* 1997;226(2):169–173.
223. Orringer MB, Marshall B, Iannettoni MD. Eliminating the cervical esophagogastric anastomotic leak with a side-to-side stapled anastomosis. *J Thorac Cardiovasc Surg.* 2000;119(2):277–288.
224. Ferri LE, Law S, Wong KH, Kwok KF, Wong J. The influence of technical complications on postoperative outcome and survival after esophagectomy. *Ann Surg Oncol.* 2006;13(4):557–564.
225. Lorentz T, Fok M, Wong J. Anastomotic leakage after resection and bypass for esophageal cancer: lessons learned from the past. *World J Surg.* 1989;13(4):472–477.
226. Law S, Suen DT, Wong KH, Kwok KF, Wong J. A single-layer, continuous, hand-sewn method for esophageal anastomosis: prospective evaluation in 218 patients. *Arch Surg.* 2005;140(1):33–39.
227. Launois B, Delarue D, Campion JP, Kerbaol M. Preoperative radiotherapy for carcinoma of the esophagus. *Surg Gynecol Obstet.* 1981;153:690–692.
228. Fok M, McShane J, Law SY, Wong J. A prospective randomized study on radiotherapy and surgery in the treatment of oesophageal carcinoma. Symposium on oesophageal carcinoma in the Asian-Pacific rim. *Asian J Surg.* 1994;17:223–229.
229. Gignoux M, Roussel A, Paillot B, et al. The value of preoperative radiotherapy in esophageal cancer: results of a study of the E.O.R.T.C. *World J Surg.* 1987;11(4):426–432.
230. Wang M, Gu XZ, Yin WB, Huang GJ, Wang LJ, Zhang DW. Randomized clinical trial on the combination of preoperative irradiation and surgery in the treatment of esophageal carcinoma: report on 206 patients. *Int J Radiat Oncol Biol Phys.* 1989;16(2):325–327.
231. Arnott SJ, Duncan W, Kerr GR, et al. Low dose preoperative radiotherapy for carcinoma of the oesophagus: results of a randomized clinical trial. *Radiother Oncol.* 1992;24(2):108–113.
232. Nygaard K, Hagen S, Hansen HS, et al. Pre-operative radiotherapy prolongs survival in operable esophageal carcinoma: a randomized, multicenter study of pre-operative radiotherapy and chemotherapy. The second Scandinavian trial in esophageal cancer. *World J Surg.* 1992;16(6):1104–1109.
233. Arnott SJ, Duncan W, Gignoux M, et al. Preoperative radiotherapy for esophageal carcinoma (Cochrane Review). The Cochrane Library. Chichester, UK: John Wiley & Sons Ltd; 2004.
234. Ténrière P, Hay J-M, Fingerhut A, Fagniez P-L. Postoperative radiation therapy does not increase survival after curative resection for squamous cell carcinoma of the middle and lower esophagus as shown by a multicenter controlled trial. *Surg Gynecol Obstet.* 1991;173:123–130.
235. Fok M, Sham JS, Choy D, Cheng SW, Wong J. Postoperative radiotherapy for carcinoma of the esophagus: a prospective, randomized controlled study. *Surgery.* 1993;113(2):138–147.
236. Xiao ZF, Yang ZY, Liang J, et al. Value of radiotherapy after radical surgery for esophageal carcinoma: a report of 495 patients. *Ann Thorac Surg.* 2003;75(2):331–336.
237. Law S, Fok M, Chow S, Chu KM, Wong J. Preoperative chemotherapy versus surgical therapy alone for squamous cell carcinoma of the esophagus: a prospective randomized trial. *J Thorac Cardiovasc Surg.* 1997;114(2):210–217.
238. Roth JA, Pass HI, Flanagan MM, Graeber GM, Rosenberg JC, Steinberg S. Randomized clinical trial of preoperative and postoperative adjuvant chemotherapy with cisplatin, vindesine, and bleomycin for carcinoma of the esophagus. *J Thorac Cardiovasc Surg.* 1988;96(2):242–248.
239. Schlag PM. Randomized trial of preoperative chemotherapy for squamous cell cancer of the esophagus. *Arch Surg.* 1992;127(12):1446–1450.
240. Kok TC, van Lanschot JJ, Siersema PD, et al. Neoadjuvant chemotherapy compared with surgery in esophageal squamous cell cancer. *Can J Gastroenterol.* 1998;12(suppl B):297.
241. Wang C, Ding T, Chang L. [A randomized clinical study of preoperative chemotherapy for esophageal carcinoma]. *Zhonghua Zhong Liu Za Zhi.* 2001;23(3):254–255.
242. Maipang T, Vasinanukorn P, Petpichetchian C, et al. Induction chemotherapy in the treatment of patients with carcinoma of the esophagus. *J Surg Oncol.* 1994;56(3):191–197.
243. Baba M, Natsugoe S, Shimada M, et al. Prospective evaluation of preoperative chemotherapy in resectable squamous cell carcinoma of the thoracic esophagus. *Dis Esophagus.* 2000;13(2):136–141.
244. Ancona E, Ruol A, Santi S, et al. Only pathologic complete response to neoadjuvant chemotherapy improves significantly the long term survival of patients with resectable esophageal squamous cell carcinoma: final report of a randomized, controlled trial of preoperative chemotherapy versus surgery alone. *Cancer.* 2001;91(11):2165–2174.
245. Kelsen DP, Ginsberg R, Pajak TF, et al. Chemotherapy followed by surgery compared with surgery alone for localized esophageal cancer. *N Engl J Med.* 1998;339(27):1979–1984.
246. Medical Research Council Oesophageal Cancer Working Party. Surgical resection with or without preoperative chemotherapy in oesophageal cancer: a randomised controlled trial. *Lancet.* 2002;359(9319):1727–1733.
247. Allum W, Fogarty P, Stenning S, Langley R; NCRI Upper GI Cancer Clinical Studies Group. Long term results of the MRC OEO2 randomized trial of surgery with or without preoperative chemotherapy in resectable esophageal cancer. Proceedings of the Gastrointestinal Cancers Symposium, Orlando, FL, Abstract 9. 2008.
248. Ando N, Kato H, Shinoda M, et al. A randomized trial of postoperative adjuvant chemotherapy with cisplatin and 5-fluorouracil versus neoadjuvant chemotherapy for localized squamous cell carcinoma of the thoracic esophagus (JCOG 9907). Proceedings of the Gastrointestinal Cancers Symposium, Orlando, FL, Abstract 10. 2008.
249. Cunningham D, Allum WH, Stenning SP, et al. Perioperative chemotherapy versus surgery alone for resectable gastroesophageal cancer. *N Engl J Med.* 2006;355(1):11–20.
250. Thirion P, Michiels S, Le Maître A, Tierney J. Individual patient data-based meta-analysis assessing pre-operative chemotherapy in resectable oesophageal carcinoma. *J Clin Oncol.* 2007;25(June 20 suppl, No. 18S):4512.
251. Gebski V, Burmeister B, Smithers BM, Foo K, Zalberg J, Simes J. Survival benefits from neoadjuvant chemoradiotherapy or chemotherapy in oesophageal carcinoma: a meta-analysis. *Lancet Oncol.* 2007;8(3):226–234.
252. Ando N, Iizuka T, Ide H, et al. Surgery plus chemotherapy compared with surgery alone for localized squamous cell carcinoma of the thoracic esophagus: a Japan Clinical Oncology Group Study—JCOG9204. *J Clin Oncol.* 2003;21(24):4592–4596.
253. Poulliquen X, Levard H, Hay JM, McGee K, Fingerhut A, Langlois ZO. 5-Fluorouracil and cisplatin therapy after palliative surgical resection of squamous cell carcinoma of the esophagus. A multicenter randomized trial. French Associations for Surgical Research. *Ann Surg.* 1996;223(2):127–133.
254. Le Prise E, Etienne PL, Meunier B, et al. A randomized study of chemotherapy, radiation therapy, and surgery versus surgery for localized squamous cell carcinoma of the esophagus. *Cancer.* 1994;73(7):1779–1784.
255. Apinop C, Puttisak P, Preecha N. A prospective study of combined therapy in esophageal cancer. *Hepatogastroenterology.* 1994;41(4):391–393.
256. Walsh TN, Noonan N, Hollywood D, Kelly A, Keeling N, Hennessy T. A comparison of multimodal therapy and surgery for esophageal adenocarcinoma. *N Engl J Med.* 1996;335:462–467.
257. Bosset JF, Gignoux M, Triboulet JP, et al. Chemoradiotherapy followed by surgery compared with surgery alone in squamous-cell cancer of the esophagus. *N Engl J Med.* 1997;337(3):161–167.
258. Lee J, Kim S, Jung H, et al. A single institutional phase III trial of preoperative chemotherapy with hyperfractionation radiotherapy plus surgery (CRT-S) versus surgery (S) alone for stage II, III resectable esophageal squamous cell carcinoma (SCC): an interim analysis [abstr 1043]. *Proc Am Soc Clin Oncol.* 2003;22:260.
259. Urba SG, Orringer MB, Turrisi A, Iannettoni M, Forastiere A, Strawderman M. Randomized trial of preoperative chemoradiation versus surgery alone in patients with locoregional esophageal carcinoma. *J Clin Oncol.* 2001;19(2):305–313.
260. Tepper J, Krasna MJ, Niedzwiecki D, et al. Phase III trial of trimodality therapy with cisplatin, fluorouracil, radiotherapy, and surgery compared

- with surgery alone for esophageal cancer: CALGB 9781. *J Clin Oncol*. 2008;26(7):1086–1092.
261. Burmeister BH, Smithers BM, GebSKI V, et al. Surgery alone versus chemoradiotherapy followed by surgery for resectable cancer of the oesophagus: a randomised controlled phase III trial. *Lancet Oncol*. 2005;6(9):659–668.
  262. Pereira B, Gourgou-Bourgade S, Azria D, Ychou M. Neoadjuvant chemoradiotherapy in esophageal cancer: is it still the question? *J Clin Oncol*. 2008;26(31):5133–5134.
  263. Urschel JD, Vasan H. A meta-analysis of randomized controlled trials that compared neoadjuvant chemoradiation and surgery to surgery alone for resectable esophageal cancer. *Am J Surg*. 2003;185(6):538–543.
  264. Kakkamanos IG, Walker GR, Ferry K, Franceschi D, Livingstone AS. Neoadjuvant treatment for resectable cancer of the esophagus and the gastroesophageal junction: a meta-analysis of randomized clinical trials. *Ann Surg Oncol*. 2003;10(7):754–761.
  265. Fioricca F, Di Bona D, Schepis F, et al. Preoperative chemoradiotherapy for oesophageal cancer: a systematic review and meta-analysis. *Gut*. 2004;53(7):925–930.
  266. Malthaner RA, Wong RK, Rumble RB, Zuraw L. Neoadjuvant or adjuvant therapy for resectable esophageal cancer: a systematic review and meta-analysis. *BMC Med*. 2004;2:35.
  267. Greer SE, Goodney PP, Sutton JE, Birkmeyer JD. Neoadjuvant chemoradiotherapy for esophageal carcinoma: a meta-analysis. *Surgery*. 2005;137(2):172–177.
  268. Stahl M, Walz MK, Stuschke M, et al. Phase III comparison of preoperative chemotherapy compared with chemoradiotherapy in patients with locally advanced adenocarcinoma of the esophagogastric junction. *J Clin Oncol*. 2009;27(6):851–856.
  269. Cooper JS, Guo MD, Herskovic A, et al. Chemoradiotherapy of locally advanced esophageal cancer: long-term follow-up of a prospective randomized trial (RTOG 85-01). Radiation Therapy Oncology Group. *JAMA*. 1999;281(17):1623–1627.
  270. Minsky BD, Pajak TE, Ginsberg RJ, et al. INT 0123 (Radiation Therapy Oncology Group 94-05) phase III trial of combined-modality therapy for esophageal cancer: high-dose versus standard-dose radiation therapy. *J Clin Oncol*. 2002;20(5):1167–1174.
  271. Gaspar LE, Winter K, Kocha WI, Coia LR, Herskovic A, Graham M. A phase I/II study of external beam radiation, brachytherapy, and concurrent chemotherapy for patients with localized carcinoma of the esophagus (Radiation Therapy Oncology Group Study 9207): final report. *Cancer*. 2000;88(5):988–995.
  272. Wong R, Malthaner R. Combined chemotherapy and radiotherapy (without surgery) compared with radiotherapy alone in localized carcinoma of the esophagus (Cochrane Review). The Cochrane Library. Chichester, UK: John Wiley & Sons, Ltd; 2004:CD002092.
  273. Bedenne L, Michel P, Bouche O, et al. Chemoradiation followed by surgery compared with chemoradiation alone in squamous cancer of the esophagus: FFCD 9102. *J Clin Oncol*. 2007;25(10):1160–1168.
  274. Bonnetain F, Bouche O, Michel P, et al. A comparative longitudinal quality of life study using the Spitzer quality of life index in a randomized multicenter phase III trial (FFCD 9102): chemoradiation followed by surgery compared with chemoradiation alone in locally advanced squamous resectable thoracic esophageal cancer. *Ann Oncol*. 2006;17(5):827–834.
  275. Stahl M, Stuschke M, Lehmann N, et al. Chemoradiation with and without surgery in patients with locally advanced squamous cell carcinoma of the esophagus. *J Clin Oncol*. 2005;23(10):2310–2317.
  276. Stahl M, Wilke N, Lehmann N, Stuschke M; German Oesophageal Cancer Study Group. Long-term results of a phase III study investigating chemoradiation with and without surgery in locally advanced squamous cell carcinoma (LA-SCC) of the esophagus [abstr 4530]. *J Clin Oncol*. 2008;26(May 20 suppl).
  277. Minsky BD, Neuberger D, Kelsen DP, et al. Final report of Intergroup Trial 0122 (ECOG PE-289, RTOG 90-12): phase II trial of neoadjuvant chemotherapy plus concurrent chemotherapy and high-dose radiation for squamous cell carcinoma of the esophagus. *Int J Radiat Oncol Biol Phys*. 1999;43(3):517–523.
  278. Jouve J, Michel P, Mariette C, et al. Outcome of the non-randomized patients in the FFCD 9102 trial: chemoradiation followed by surgery compared with chemoradiation alone in squamous cancer of the esophagus [abstr 4555]. *J Clin Oncol*. 2008;26(May 20 suppl).
  279. Jones DR, Parker LAJ, Dettterbeck FC, Egan TM. Inadequacy of computed tomography in assessing patients with esophageal carcinoma after induction chemoradiotherapy. *Cancer*. 1999;85(5):1026–1032.
  280. Zuccaro G, Rice TW, Goldblum J, et al. Endoscopic ultrasound cannot determine suitability for esophagectomy after aggressive chemoradiotherapy for esophageal cancer. *Am J Gastroenterol*. 1999;94(4):906–912.
  281. Weber WA, Ott K, Becker K, et al. Prediction of response to preoperative chemotherapy in adenocarcinomas of the esophagogastric junction by metabolic imaging. *J Clin Oncol*. 2001;19(12):3058–3065.
  282. Wieder HA, Brucher BL, Zimmermann F, et al. Time course of tumor metabolic activity during chemoradiotherapy of esophageal squamous cell carcinoma and response to treatment. *J Clin Oncol*. 2004;22(5):900–908.
  283. Lam KY, Law S, Ma LT, Ong SK, Wong J. Pre-operative chemotherapy for squamous cell carcinoma of the oesophagus: do histological assessment and p53 overexpression predict chemo-responsiveness? *Eur J Cancer*. 1997;33:1221–1225.
  284. Walsh TN, Grannell M, Mansoor S. Predictive factors for success of neoadjuvant therapy in upper gastrointestinal cancer. *J Gastroenterol Hepatol*. 2002;17 Suppl:S172–S175.
  285. Lordick F, Ott K, Krause BJ, et al. PET to assess early metabolic response and to guide treatment of adenocarcinoma of the oesophagogastric junction: the MUNICON phase II trial. *Lancet Oncol*. 2007;8(9):797–805.
  286. Lordick F, Ott K, Krause BJ, et al. Salvage radiochemotherapy in locally advanced gastroesophageal junction tumors that are metabolically resistant to induction chemotherapy: The MUNICON-2 trial. Proceedings of Gastrointestinal Cancers Symposium, Orlando, FL, Abstr 104. 2008.
  287. Nutting CM, Bedford JL, Cosgrove VP, Tait DM, Dearnaley DP, Webb S. A comparison of conformal and intensity-modulated techniques for esophageal radiotherapy. *Radiother Oncol*. 2001;61(2):157–163.
  288. Knyrim K, Wagner HJ, Bethge N, Keymling M, Vakil N. A controlled trial of an expansile metal stent for palliation of esophageal obstruction due to inoperable cancer. *N Engl J Med*. 1993;329(18):1302–1307.
  289. De Palma G, Di Matteo E, Romano G, Fimmano A, Rondinone G, Catanzano C. Plastic prosthesis versus expandable metal stents for palliation of inoperable esophageal thoracic carcinoma: a controlled prospective study. *Gastrointest Endosc*. 1996;43(5):478–482.
  290. Siersema PD, Hop WCJ, Dees J, Tilanus HW, van Blankenstein M. Coated self-expanding metal stents versus latex prostheses for esophagogastric cancer with special reference to prior radiation and chemotherapy: a controlled, prospective study. *Gastrointest Endosc*. 1998;47:113–120.
  291. Nicholson DA, Haycox A, Kay CL, Rate A, Attwood S, Bancewicz J. The cost effectiveness of metal oesophageal stenting in malignant disease compared with conventional therapy. *Clin Radiol*. 1999;54(4):212–215.
  292. Kocher M, Dlouhy M, Neoral C, et al. Esophageal stent with antireflux valve for tumors involving the cardia: work in progress. *J Vasc Interv Radiol*. 1998;9(6):1007–1010.
  293. Mayoral W, Fleischer D, Salcedo J, Roy P, Al Kawas F, Benjamin S. Non-malignant obstruction is a common problem with metal stents in the treatment of esophageal cancer. *Gastrointest Endosc*. 2000;51(5): 556–559.
  294. Verschuor EM, Repici A, Kuipers EJ, Steyerberg EW, Siersema PD. New design esophageal stents for the palliation of dysphagia from esophageal or gastric cardia cancer: a randomized trial. *Am J Gastroenterol*. 2008;103(2):304–312.
  295. Law S, Tung PH, Chu KM, Wong J. Self-expanding metallic stents for palliation of recurrent malignant esophageal obstruction after subtotal esophagectomy for cancer. *Gastrointest Endosc*. 1999;50(3):427–436.
  296. Law S, Kwong DL, Kwok KF, et al. Improvement in treatment results and long-term survival of patients with esophageal cancer: impact of chemoradiation and change in treatment strategy. *Ann Surg*. 2003;238(3): 339–348.
  297. Law S. Chemoradiotherapy—panacea for esophageal cancer? Commentary for chemoradiotherapy of locally advanced esophageal cancer. Long-term follow-up of a prospective randomized trial (RTOG 85-01). *JAMA South-east Asia* 1999;15(5):9–11.



# SURGICAL PROCEDURES TO RESECT AND REPLACE THE ESOPHAGUS

Jon O. Wee • David J. Sugarbaker

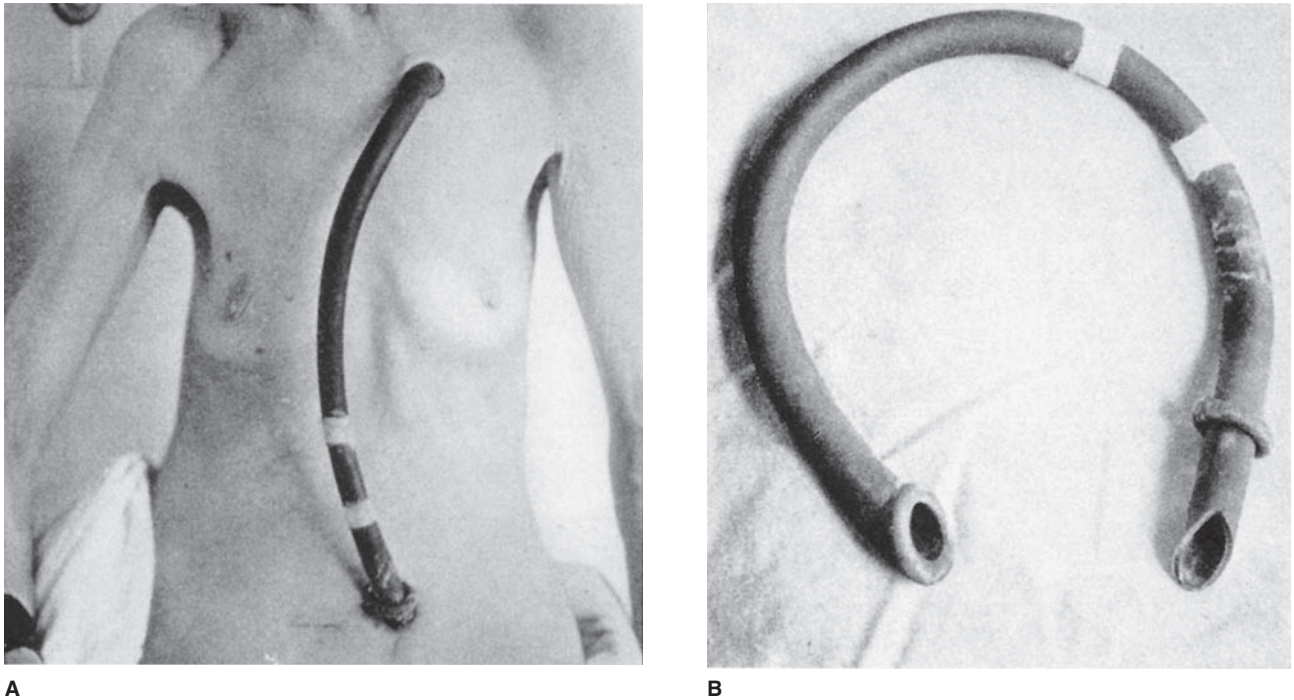
Billroth and Czerny described the first esophageal resections in the 1870s, and they consisted of resections of the cervical esophagus without reconstruction. Later, resection of gastroesophageal (GE) junction tumors was performed by laparotomy with gastroesophageal anastomosis to reestablish intestinal continuity. Because there were concerns over respiratory compromise, surgeons were hesitant to enter the chest to perform esophageal resection. In 1915, Torek described the first transthoracic esophageal resection.<sup>1</sup> He used a left thoracotomy to resect the esophagus but did not attempt reconstruction. Instead, a cervical esophagostomy and abdominal gastrotomy were performed. A 3-ft-long external rubber tube was used to connect the ostomies, and it allowed the patient to eat for 17 more years (Fig. 18-1). Turner performed the first transhiatal esophagectomy in 1933.<sup>2</sup> Oshawa reported the first transthoracic resection of the esophagus with esophagogastric anastomosis in 1933.<sup>3</sup> Knowledge of this procedure did not become widespread in the Western community until Adams and Plemister described the procedure in 1938.<sup>4</sup>

Ivor Lewis is credited with popularizing transthoracic resection of the esophagus. Initially, he performed the procedure in two stages: first, mobilizing the stomach via laparotomy and several days later resecting the intrathoracic esophagus and reconstructing with the stomach. The Ivor Lewis approach, which is an upper midline laparotomy for mobilization of the gastric conduit followed by right thoracotomy for resection and reconstruction, and the transhiatal approach are currently the two most commonly used techniques of esophageal resection. In 1962, McKeown described a tri-incisional approach. He used a right thoracotomy to mobilize the esophagus. The patient was then repositioned in the supine position, the gastric conduit was mobilized by laparotomy, and the anastomosis was performed in the neck.<sup>5</sup> Minimally invasive options for surgical resection have also become increasingly popular.<sup>6,7</sup> Combined thoracoscopic and laparoscopic techniques in some combination with open techniques have created a wider hybrid experience and are discussed in other chapters.

## NEOADJUVANT TREATMENT

Historically, surgery has been the primary mode of treatment for localized esophageal cancer. Nonetheless, the long-term results of surgery alone for esophageal cancer are disappointing.<sup>8</sup> Preoperative chemoradiation has been proposed as a means of improving long-term survival. Eight randomized trials have been performed using preoperative chemoradiation. Although the two largest randomized trials comparing preoperative chemoradiation followed by surgery to surgery alone showed no difference in survival,<sup>9,10</sup> two smaller randomized trials have been used to support the use of preoperative chemoradiation. Urba and colleagues looked at 100 total patients randomized to preoperative chemoradiation or surgery alone.<sup>11</sup> Median survival was about 18 months in both groups, although there was a trend toward improved survival at 3 years (30 vs 16%; not statistically significant). Walsh and associates randomized 113 patients, and at 3 years 32% of those receiving preoperative chemoradiation were alive versus 6% of those undergoing surgery alone.<sup>12</sup> This study, however, has been heavily criticized for its lack of adequate pretreatment staging as well as a very poor survival in the surgical arm that is far below all other reported series. Hence, although there are no definitive data to support the use of chemotherapy and radiation in the neoadjuvant setting, it remains widely used.

CALGB 9781 (Cancer and Leukemia Group B 9781) was a prospective randomized intergroup trial that evaluated patients with stages 1–3 esophageal cancer. Patients were randomized to surgery alone or to preoperative cisplatin and 5-FU with concurrent radiation (50.4 Gy) followed by surgery. Poor accrual resulted in premature closure of the study with 56 patients, well short of its goal of 500 patients. Nonetheless, with median follow-up of 6 years, 5-year survival was 39% for the trimodality group versus 16% for the surgery-alone group. Median survival was 4.5 years for the trimodality group versus 1.8 years for the surgery-alone group ( $p = .02$ ).<sup>13</sup> A meta-analysis by Urschel and Vasan in 2003



**FIGURE 18-1** **A.** Depiction of Torek's first patient after esophageal resection. The rubber tube connected the lower end of the esophagus with a gastrostomy. The patient lived 17 years after the surgery and died at age 80. **B.** Removable rubber tube conduit with beveled ends. (Reproduced, with permission, from Torek F. The operative treatment of carcinoma of the esophagus. *Ann Surg* 1915;61:385.)

combined the results of over 1100 patients from nine randomized controlled studies comparing neoadjuvant chemoradiotherapy followed by surgery versus surgery alone. This study did favor neoadjuvant chemoradiotherapy with surgery over surgery alone.<sup>14</sup>

There is substantial comparative evidence of the benefit of neoadjuvant chemotherapy for locally advanced esophageal cancer. The MRC (Medical Research Council) trial of 2002 demonstrated a statistically significant survival benefit (43 vs 34%) in those patients who received preoperative chemotherapy with an increase in median survival from 13.3 to 16.8 months.<sup>15</sup> This report was followed by the MAGIC (Medical Research Council Adjuvant Gastric Infusional Chemotherapy) trial in 2006, which further demonstrated an improved survival in patients with GE junction adenocarcinoma at 2 years (50 vs 41%) and at 5 years (36 vs 23%).<sup>16</sup> A head-to-head comparison of neoadjuvant chemotherapy versus neoadjuvant chemoradiotherapy by the German Esophageal Cancer Study Group did not demonstrate any improved ability to achieve R0 resection with the addition of x-ray therapy (XRT).<sup>17</sup> The study was underpowered, but there was a trend toward increased mortality in the radiation arm. Paradoxically, there also was a trend toward improved survival with the addition of radiation, although this finding was not statistically significant. Unfortunately, no clear determination was made regarding which method is better. The relatively low incidence of esophageal cancer, the variable response to treatment between squamous cell carcinoma and

adenocarcinoma, and the regional practice patterns make a large, randomized study difficult to envision.

## STAGING

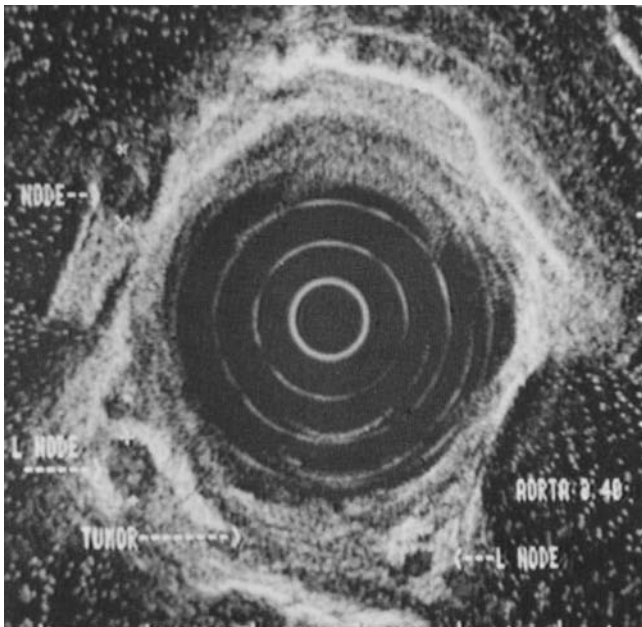
It is important to recognize those patients with stage IV disease because the mean survival in these patients is 6–10 months. In the past, palliative esophagectomy was often thought necessary to restore swallowing and oral nutrition. With advances in photodynamic therapy, expandable endoscopic stents, and other endoluminal therapies, it is unusual for anyone to require esophageal replacement to reestablish swallowing ability. Hence, stage IV patients should be spared the perioperative mortality, morbidity, and recovery time associated with esophagectomy. The appropriate use of neoadjuvant treatment requires accurate staging. Patients with nodal involvement, invasion through the esophagus, or possibly even invasion into the muscularis often undergo preoperative chemoradiation, while patients with simple mucosal involvement generally proceed directly to surgery.

The main staging modalities available today are computed tomography (CT) scan, positron emission tomography (PET) scan, and endoscopic ultrasound (EUS). CT scans are used mainly for detecting distant metastases in the lungs, liver, or other remote sites, including the brain. CT scan may be useful for excluding T4 tumors if a fat plane can be demonstrated between the adjacent structure and the esophagus.

Such staging is often not possible if the patient is severely cachectic or if there are no natural fat planes, such as that between the trachea and esophagus. In regard to nodal status, CT is not as sensitive or as accurate as EUS.

PET scan is superior to CT scan for detecting distant metastatic disease. In a series of 91 patients, CT scan had a sensitivity of 46%, a specificity of 74%, and an overall accuracy of 73%. In contrast, PET scan had a sensitivity of 69%, specificity of 93%, and overall accuracy of 84%. All metastases that were missed by PET were less than 1 cm in size.<sup>7</sup> Other studies have shown similar results.<sup>18,19</sup> In addition, PET scan may aid in the diagnosis of primary tumor where it may be difficult to perform biopsy because of obstruction. Conversely, a certain percentage of nonbulky tumors of the esophagus may be PET-negative.

EUS gives detailed images of the esophageal wall and nearby structures (Fig. 18-2). Accurate identification of the layers of the esophageal wall is possible. Muscle layers tend to be hypoechoic with intervening hyperechoic mucosal layers. The first hyperechoic layer and second hypoechoic layer correspond to the mucosa and muscularis mucosa. The third hyperechoic layer is submucosa. The fourth hypoechoic layer is the muscularis propria, and the fifth hyperechoic layer is the outside of the esophagus. Tumor infiltration of the wall disrupts the normal-layered appearance, and extent of penetration is usually clearly visible. EUS has an overall accuracy of 80–90% in ascertaining T status. The differentiation between T1 and T2 is most difficult. In addition,



**FIGURE 18-2** Endoesophageal ultrasound image of an adenocarcinoma of the esophagus (T3) and multiple lymph nodes suspicious for metastatic disease (N1). (Reproduced with permission from Van Dam J, Sivak MV, Catalano MF, et al. High-grade malignant stricture is predictive of esophageal tumor stage: risks of endosonographic evaluation. *Cancer*. 1993;May 15; 71(10):2910–2917.)

biopsy of deeper layers of tumor not accessible by traditional grasping forceps is possible. It should be noted that EUS is not accurate in defining postneoadjuvant treatment T status because of fibrosis induced by the chemoradiation.

Nodal status is determined by examining four characteristics. Malignant nodes tend to be round and hypoechoic. They have discrete borders and are larger than 1 cm in size. Nodes that meet such criteria have a 90% chance of being malignant. Fine-needle aspiration (FNA) further increases the accuracy in determining nodal status. If the tumor is from a node, the cytopathologist should be able to identify lymphoid tissue in the specimen. False positives can result with FNA if the needle passes through the primary tumor. The accuracy of EUS in N-status staging is between 70 and 80%. EUS is 10–15% more accurate than CT scan.<sup>20</sup>

Developments in EUS and PET scanning have lessened the enthusiasm for pre-resection operative staging of esophageal cancer patients. Operative staging involving laparoscopy and thoracoscopy is more invasive but may be superior to EUS. Luketich and associates studied 26 patients and detected N1 disease in a considerable number of patients staged NO by EUS.<sup>21</sup> It should be noted, however, that the sensitivity of EUS in this series was only 60%, considerably lower than that described in other series. In addition, 15% of patients with no radiographic metastatic disease were found to have liver metastases by laparoscopic staging. The average cost of surgical staging was \$20,000–\$25,000 versus \$2000 for EUS.

A common algorithm used in staging patients includes endoscopy for primary diagnosis, CT scanning with PET to evaluate for metastatic disease, and EUS if the patient is an operative candidate and neoadjuvant therapy is considered. In cases of esophageal obstruction, where EUS scanning is known to be less accurate, the incidence of lymph node metastasis is very high (90%) and neoadjuvant therapy should be considered.

## APPROACH TO THE CERVICAL LESION

The treatment of a cancer of the cervical esophagus is challenging and requires a multidisciplinary approach involving an otorhinolaryngologist, a thoracic surgeon, and occasionally a plastic surgeon. Frequently, radiation will be required preoperatively to maximize margins and spare the larynx, if possible. The neck incision is made along the anterior border of the sternocleidomastoid muscle and can be extended across the midline if additional exposure is needed. If the tumor is fixed to the spine or neck vessels, the procedure is aborted and palliative radiotherapy is considered. If the larynx is involved, it is removed en bloc with the upper esophagus along with the upper paraesophageal nodes bilaterally. A radical neck dissection is not routinely performed. The dissection spares the jugular vein, sternocleidomastoid muscles, and spinal accessory nerves. The trachea is transected, leaving enough length to allow construction of a permanent end tracheostomy. The endotracheal tube is inserted into the distal trachea and the hypopharynx is divided sharply.



By this point, a separate midline abdominal incision will have been performed, and blunt dissection is begun on the esophagus from the abdomen. A two-team approach should be considered with one team at the neck, while the other prepares the gastric conduit. The gastric conduit is elevated to the neck with traction and the gastroesophageal junction is divided. The pharyngogastrostomy anastomosis is performed using a single-layer, interrupted hand-sewn anastomosis with a nonabsorbable suture. The cervical tracheostomy is performed above the sternal notch. If too much trachea has been resected to allow for this, manubrial resection will permit placement of the end tracheostomy lower in the midline.

## STRATEGY FOR LESIONS BELOW THE THORACIC INLET

Lesions below the thoracic inlet can be divided according to their location in the upper esophagus (below the thoracic inlet but above the carina), midesophagus (between the carina and inferior pulmonary vein), or lower esophagus (below the inferior pulmonary vein). While we favor the tri-incisional approach for all malignant lesions (for reasons to be discussed later), lesions in the upper thoracic esophagus generally must be approached with this technique to ensure adequate proximal margins. If the lesion is in the midthoracic esophagus, either the tri-incisional approach or the Ivor Lewis approach may be adequate. Lower esophageal tumors can be resected with either of these two approaches, or additionally with a transhiatal approach or left thoracotomy and distal esophagectomy. With any resection, accommodation must be made for additional resection with reconstruction if frozen margins are involved with tumor.

## Transhiatal Versus Transthoracic Techniques

Numerous retrospective analyses have been performed comparing the transhiatal to the transthoracic (mainly Ivor Lewis) approach. These are summarized in two meta-analyses. Rindani and associates reviewed 44 trials involving either Ivor Lewis or transhiatal esophagectomy that were published in the English language between 1986 and 1996.<sup>22</sup> Overall, the incidence of bleeding, cardiac complications, or pneumonia was no different between the two groups. Differences were seen in the anastomotic leak rate (16% transhiatal vs 10% Ivor Lewis), stricture rate (28% transhiatal vs 16% Ivor Lewis), and incidence of recurrent nerve injury (11% transhiatal vs 5% Ivor Lewis). Mortality was higher after the Ivor Lewis approach (9.5%) than the transhiatal approach (6.3%). Long-term survival was about 25% with either technique. Hulscher and colleagues also performed a meta-analysis of 50 studies published between 1990 and 1999 involving transthoracic and transhiatal resection.<sup>23</sup> Cardiac complications (20 vs 7%), anastomotic

leakage (24 vs 7%), and vocal cord paralysis (10 vs 4%) were higher in the transhiatal group as opposed to the transthoracic group. Pulmonary complications (19 vs 13%), in-hospital mortality (9 vs 6%), and operative time (5 vs 4.2 hours) were higher in the transthoracic group. Overall long-term survival was similar between the two groups (23% for transthoracic and 21.7% for transhiatal resections). These reviews are retrospective and nonrandomized, and caution should therefore be used in applying these findings to individual institutions and patients.

Three prospective, randomized trials have been performed comparing transhiatal to transthoracic resection. The first was published in 1993 by Goldmine and associates.<sup>24</sup> Sixty-seven patients younger than 70 years with squamous cell cancer were randomized to Ivor Lewis resection or transhiatal resection. Operative time was longer (6 vs 4 hours) in the Ivor Lewis group. There was no difference in the incidence of pneumonia (20%), anastomotic leak, recurrent nerve injury, bleeding, perioperative mortality, or length of hospital stay. For those patients with nodal disease, however, none of the transhiatal patients was alive at 18 months, while 30% of the transthoracic patients were alive at 18 months.

Chu and coworkers randomized 39 patients with lower-third esophageal cancers to either Ivor Lewis or transhiatal resection.<sup>25</sup> Limitations of the study were small sample size, short follow-up (mean 15 months), and patient exclusions. Patients undergoing neoadjuvant therapy or those with forced expiratory volume in 1 second (FEV<sub>1</sub>) less than 70% of expected were excluded. There were no perioperative deaths in either group. Intraoperative hypotension occurred in 60% of transhiatal patients but only in 5% of transthoracic patients. There was no difference in blood loss, pneumonia, or recurrent nerve injury. The mean proximal margin was 3 cm longer in the transhiatal group. No significant difference was seen in tumor recurrence or survival during the brief follow-up period.

A study comparing transhiatal resection to transthoracic, tri-incisional en bloc resection for distal adenocarcinoma of the esophagus or cardia was performed in the Netherlands. One hundred and six patients were randomized to transhiatal resection and 114 patients to transthoracic resection. In-hospital mortality was 2–4% in each group. Chyle leak was higher in the transthoracic resection group (10 vs 2%). Respiratory complications including atelectasis and pneumonia were higher in the transthoracic group (57 vs 27%). Although statistical significance was not reached, 39% of the transthoracic group was alive at 5 years, while only 29% of the transhiatal group survived 5 years.<sup>26</sup> Meta-analyses show that the incidence of bleeding, ischemic cardiac events, and length of stay are not necessarily different between the transthoracic and transhiatal approaches. Placement of the anastomosis in the cervical position appears to increase the risk of recurrent laryngeal nerve injury, anastomotic leak, and stricture. The mortality rate from an anastomotic leak, however, is less than that of a leak in the chest. The transthoracic approach increases operative time and in-hospital mortality.

An update of this study following with a full 5-year follow-up continued to show no statistically significant overall survival in either approach.<sup>27</sup> However, in a subgroup of patients who had one to eight positive lymph nodes in the resection specimen, the transthoracic approach (TTE) demonstrated improved overall survival compared with the transhiatal approach (THE) (39% TTE vs 19% THE,  $p = .05$ ). Disease-free survival was similarly improved with the transthoracic approach (64% TTE vs 23% THE,  $p = .02$ ).

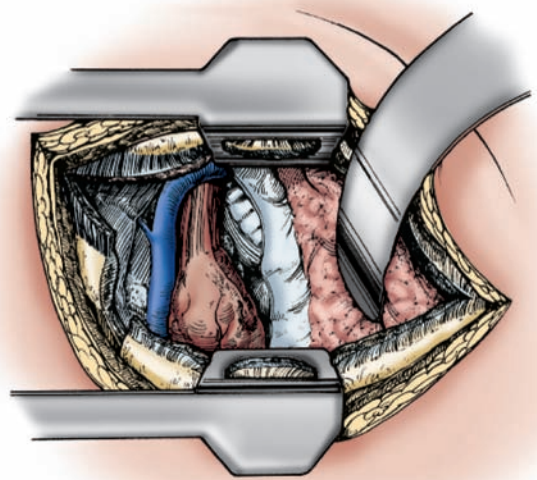
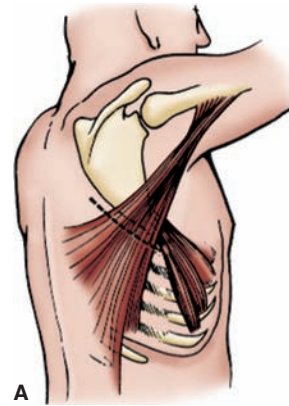
The randomized trials show no statistically significant difference in survival, but they are small, and trends toward improved survival are observed in patients undergoing transthoracic dissection. No difference in mortality, blood loss, or incidence of pneumonia was detected. It should also be noted that unlike the meta-analyses, the randomized trials showed no difference in recurrent nerve injury or anastomotic leak. This is a testament to the importance of experience and volume in preventing these complications. Wong noted intraoperative hypotension in 60% of transhiatal dissections, but in only 5% of transthoracic dissections.<sup>28</sup> This finding confirms every surgeon's experience with transhiatal resection. While some may argue that transhiatal dissection may be less taxing on an elderly or debilitated patient (either because of shorter operative time or avoidance of a thoracotomy), the operation may be more taxing to a patient with severe cardiac valvular or atherosclerotic disease who cannot tolerate fluctuations in blood pressure. In these patients, transthoracic esophagectomy is safer.

## SURGICAL APPROACHES TO LESIONS BELOW THE THORACIC INLET

### Tri-incisional Esophagectomy (McKeown Technique)

The tri-incisional technique of esophageal resection combines the most attractive aspects of the Ivor Lewis and transhiatal approaches. It allows for dissection of the intrathoracic esophagus under direct vision with complete nodal resection and brings the anastomosis to the neck, allowing for maximal proximal margins and minimizing the risk of an intrathoracic leak.

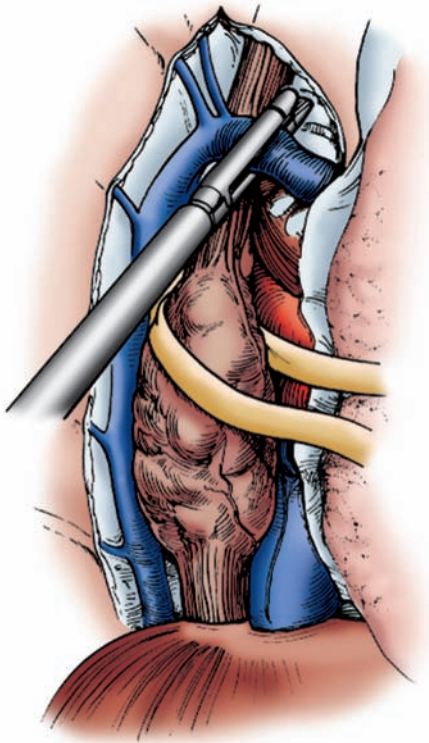
Under general anesthesia, bronchoscopy is performed to rule out tracheal or bronchial (most commonly left main bronchial) involvement with tumor. Esophagogastroduodenoscopy is performed to localize the tumor and rule out disease of the stomach or duodenum. The patient is then reintubated with a double-lumen endotracheal tube and placed in the left lateral decubitus position. A right posterolateral thoracotomy incision is made large enough, approximately 10 cm in length, to introduce the surgeon's hand (Fig. 18-3). The serratus muscle is spared. Division of the intercostal muscles anteriorly and posteriorly often permits adequate rib spreading without the need to remove a small portion, or shingle, a rib. The chest is entered through the fifth or sixth interspace depending on the location of the tumor. The inferior



**FIGURE 18-3** **A.** The right chest has been entered through the fifth interspace. A piece of the posterior sixth rib has been “shingled” to aid in exposure. The lung is retracted anteromedially, and the mediastinal pleura has been incised posteriorly to expose the esophageal tumor. *Inset:* The patient is placed in the left lateral decubitus position. The *dotted line* marks the skin incision for a right posterolateral thoracotomy. **B.** The latissimus muscle is divided as caudally as possible, and the serratus muscle is spared and reflected medially.

pulmonary ligament is divided using electrocautery, and the lung is retracted anteriorly.

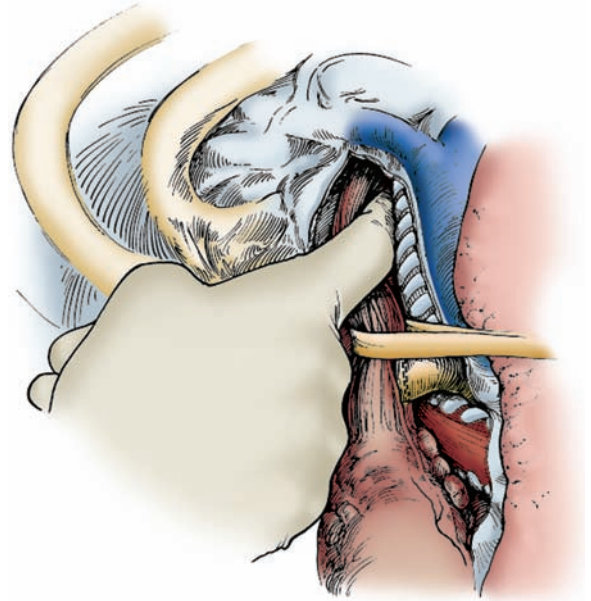
Dissection of the esophagus begins at a point away from tumor and any associated scarring, and the esophagus is encircled with a Penrose drain. Traction on the Penrose drain allows for cautery dissection encompassing all adjacent nodes. Arterial branches directly off the aorta are clipped or ligated. The settings on the electrocautery should be low when cauterizing near the trachea. The azygos vein is typically divided, although this is not always necessary (Fig. 18-4). At this level, the vagus nerves are identified. Dissection cranial to this level involves the vagus nerves; the vagus nerves are peeled off and away from the esophagus to avoid injury to the recurrent vagus branches.



**FIGURE 18-4** The esophagus has been isolated circumferentially at a point superior to the tumor and encircled with a Penrose drain. An endostapling device is used to divide the azygos vein near its caval connection.

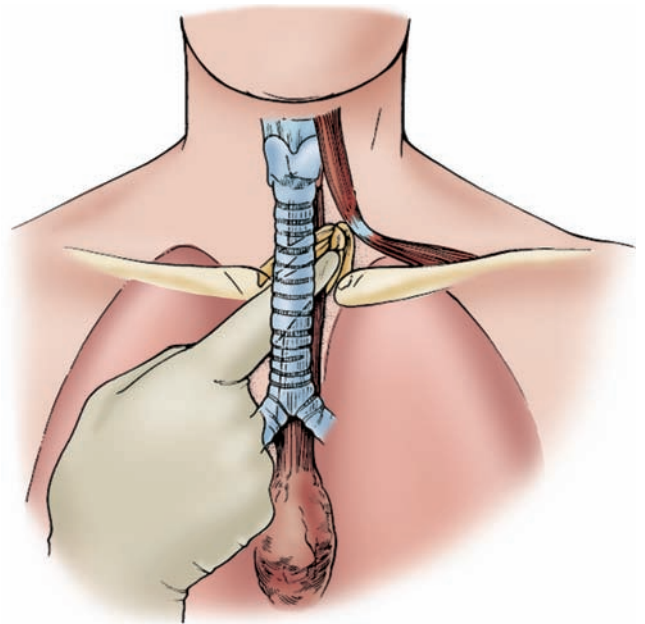
Dissection between the trachea and esophagus must be done with care and with low cautery dissection to avoid injury to the membranous trachea. Much of the dissection high in the chest can be done bluntly (Fig. 18-5). The cranial aspect of the dissection is complete when one's fingers reach easily above the first rib. The Penrose drain is knotted and passed into the lower neck with the knot against the vertebral body for later retrieval during the neck phase of the dissection (Fig. 18-6).

Another Penrose drain is used to gain traction on the lower esophagus and dissection continues caudally. All tissue between the pericardium, aorta, and azygos vein is dissected and incorporated into the specimen. No effort is made to resect the thoracic duct, although it is sometimes injured. For tumors near the gastroesophageal junction, a rim of diaphragm is incorporated into the specimen. The knotted Penrose drain is placed in the abdomen for later retrieval (Fig. 18-7). At this point, careful inspection is made for hemostasis and injury to the thoracic duct. Often, injury to the thoracic duct is evident when slightly cloudy or crystallized fluid is seen pooling in the region of the duct. If an injury to the duct is seen, it should be closed with a pledgeted fine suture such as 5-0 Prolene. Mass ligation of the duct, as it enters the chest, is then performed by encompassing all tissue between the spine,



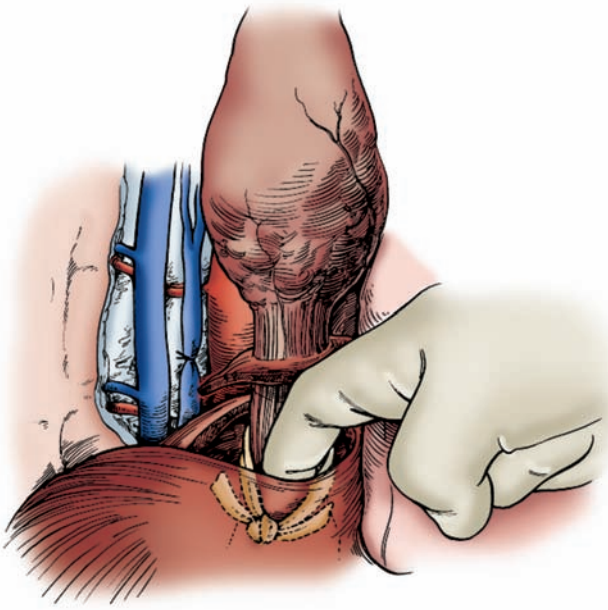
**FIGURE 18-5** With countertraction applied to the Penrose drain encircling the esophagus above the tumor, blunt finger dissection is used to develop the tracheoesophageal plane to and above the thoracic inlet.

aorta, and azygos vein at the level of the hiatus with a 0 silk suture. A 28F straight chest tube is inserted via a separate stab incision and directed to the apex of the chest. An additional hole in the tube can be made to facilitate dependent fluid drainage. The ribs are reapproximated with 2-0 Vicryl sutures.



**FIGURE 18-6** The knotted Penrose drain is pushed up through the thoracic inlet and left to lie beneath the omohyoid muscle on the left side of the neck.

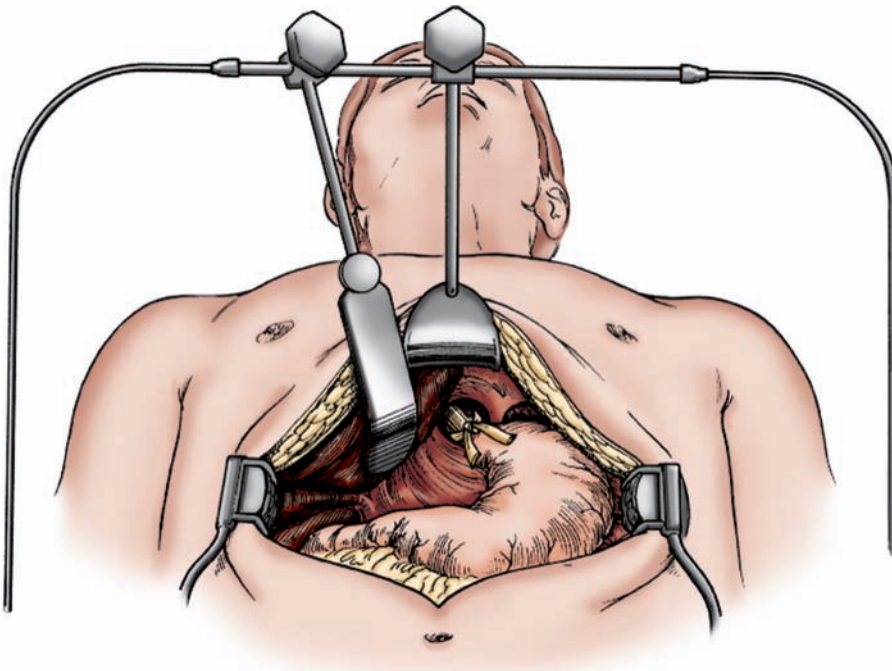




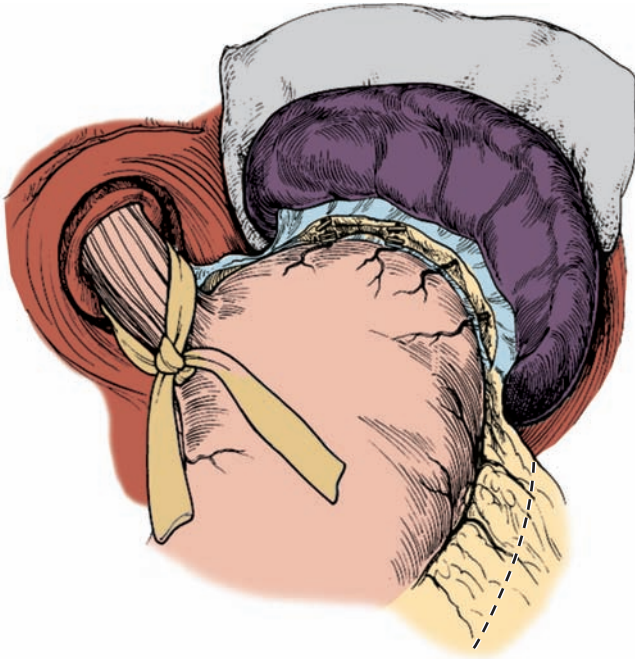
**FIGURE 18-7** The lower Penrose drain is pushed down onto the gastroesophageal junction below the diaphragm. The thoracic duct is shown ligated, and a rim of the diaphragmatic hiatus encircles the lower esophagus.

The latissimus layer is closed using a running 0 Vicryl suture. A subdermal layer is closed with 2-0 Vicryl and the skin is closed in subcuticular fashion.

The patient is placed in the supine position and is reintubated with a single-lumen tube. A roll is placed under the back to permit neck extension, and the head is turned to the right. A midline laparotomy is performed from the umbilicus to the xiphoid. Exploration of the abdomen should include a careful palpation of the liver and inspection of the serosal surfaces for tumor implants. Palpation of the GE junction and proximal stomach should be performed to rule out gastric spread of tumor. The left lobe of the liver is mobilized and retracted to the right. The Penrose drain left from the chest dissection is used for retraction of the GE junction (Fig. 18-8). The gastroepiploic artery is identified and palpated. The pulse should be easily palpable provided the patient has a physiologic blood pressure. Staying at least 2 cm away from the gastroepiploic artery, the lesser sac is entered. Dissection continues cranially on the stomach along the greater curvature. Dissection may be performed by dividing tissue and ligating with 2-0 silk ties or by using an ultrasonic scalpel. The stomach is retracted medially and the omentum laterally. The artery itself should not be grasped or used for retraction. The gastroepiploic arcade ends near the point where the short gastric arteries begin. A pack placed behind the spleen often aids in exposure of the short gastric vessels (Fig. 18-9). The short gastric vessels can be ligated, double-clipped, or divided with an ultrasonic scalpel. Large vessels should be tied. Care should be taken not to incorporate stomach wall in the ligature, as this may result in delayed necrosis of stomach wall and a postoperative intrathoracic leak.



**FIGURE 18-8** Exposure achieved by upper midline laparotomy. The large Balfour retractor is on the lateral abdominal walls, and the upper hand retractor reflects the liver to the right exposing the hiatus and lower Penrose drain around the GE junction.

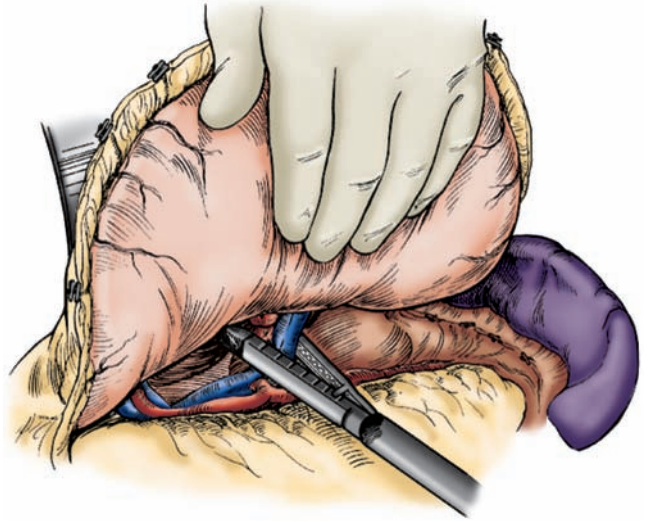


**FIGURE 18-9** Gastric mobilization is begun at the superior greater curvature near the hiatus. A rolled Mikulicz pad is placed behind the spleen to aid in exposure. The short gastric vessels between the spleen and the stomach are divided, and the transition zone between the left and right gastroepiploic arteries is identified. Mobilization proceeds at least 2 cm away from the right gastroepiploic arcade (*dotted line*).

Dissection on the greater curvature proceeds to the hiatus and is complete when the Penrose drain is reached.

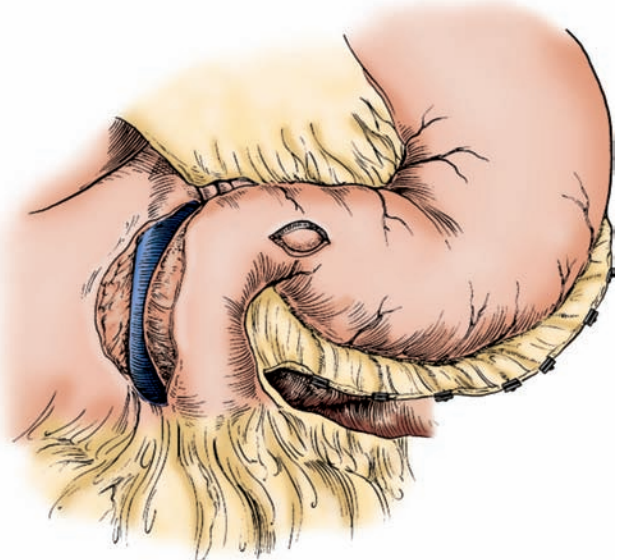
Proximal dissection on the greater curvature of the stomach proceeds in likewise fashion. The gastroepiploic artery migrates farther from the stomach as one dissects toward the pylorus, and care must be taken not to injure the vessel. The gastrohepatic ligament is divided with cautery up to the GE junction. The stomach is lifted anteriorly, and thin adhesions between the stomach and pancreas are divided with cautery. The left gastric vessels are approached from behind the stomach (Fig. 18-10). The vessels are skeletonized, and lymph nodes are swept up onto the specimen. The vessels are clamped with a vascular endoscopic 30-mm stapler. The gastroepiploic pulse should be palpated at this time to ensure that the celiac axis itself has not been clamped, and the stapler is then fired. The duodenum is then mobilized using a Kocher maneuver, bringing it to the midline (Fig. 18-11). A pyloromyotomy or pyloroplasty may be performed with equivalent efficacy in aiding gastric emptying. If a pyloroplasty is performed, it is best to close it in a single layer with interrupted (3-0 silk) sutures. A leak is exceedingly rare.

A neck incision is then made 6 cm in length along the anterior border of the left sternocleidomastoid muscle starting at the sternal notch. Deep to the platysma, dissection proceeds medial to the sternocleidomastoid muscle and carotid sheath and lateral to the thyroid. The omohyoid



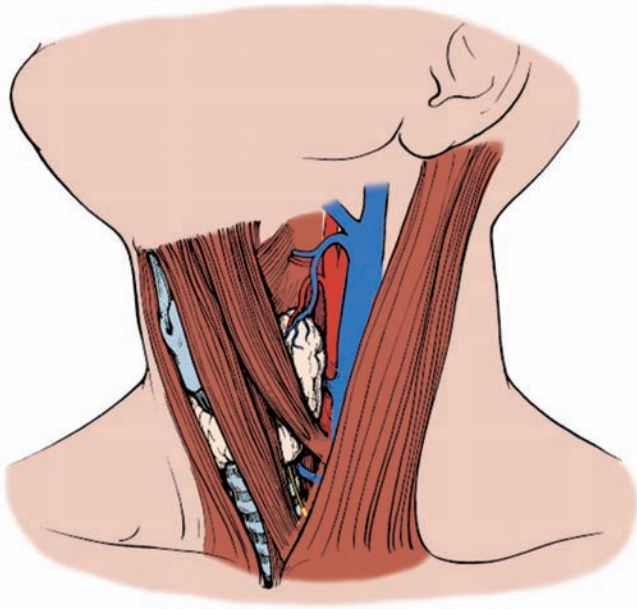
**FIGURE 18-10** After the greater curvature is mobilized, the stomach is reflected superiorly and to the right, exposing the left gastric artery and coronary vein. These are ligated and divided with an endostapler, near their origin, from the celiac axis.

can be divided with cautery (Fig. 18-12). Blunt dissection is then used to approach the vertebral bodies (Fig. 18-13). Lying along the vertebral body, the Penrose drain is grasped and brought out into the neck wound with the encircled esophagus. Proximally, the esophagus can be gently mobilized. The nasogastric tube is removed, and the esophagus is divided with a GIA 75-mm stapler (Fig. 18-14). A 2 silk suture is attached to the proximal margin, and the specimen is drawn out into the abdomen (Fig. 18-15). The cervical end of this tie is fastened to a clamp.

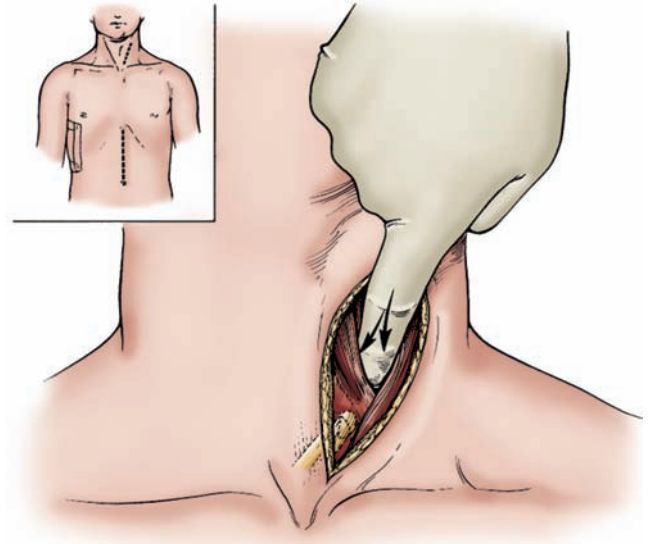


**FIGURE 18-11** A Kocher maneuver to mobilize the duodenum and a pyloromyotomy are performed.





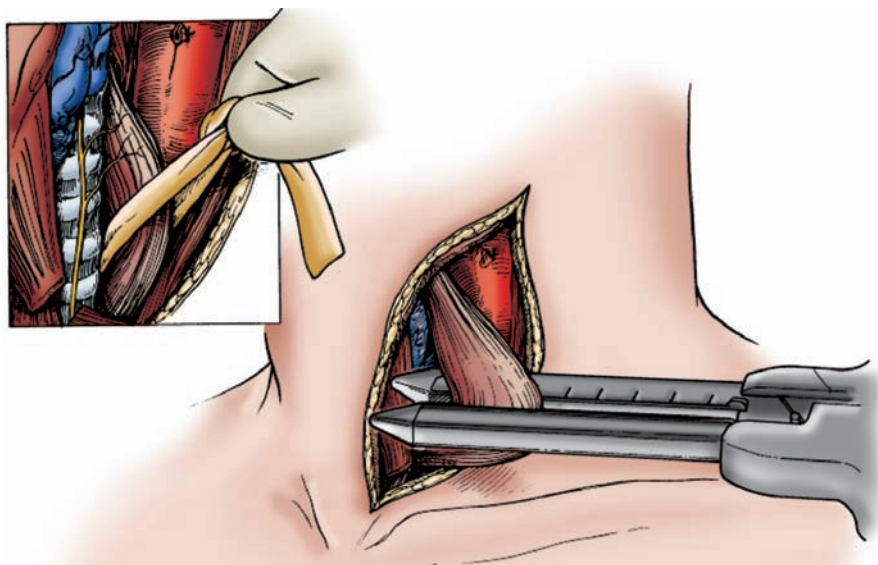
**FIGURE 18-12** Anatomic structures of the left neck below platysma level. The incision line along the medial border of the sternocleidomastoid muscle is shown. Division of the omohyoid muscle along with ligation of the middle thyroid vein allows for exposure of the underlying esophagus.



**FIGURE 18-13** Left cervical incision with the sternocleidomastoid muscle reflected laterally. Finger dissection beneath the omohyoid muscle develops a plane to the knotted Penrose drain. *Inset:* The patient is placed supine for the neck and abdominal incisions (*outlined*).

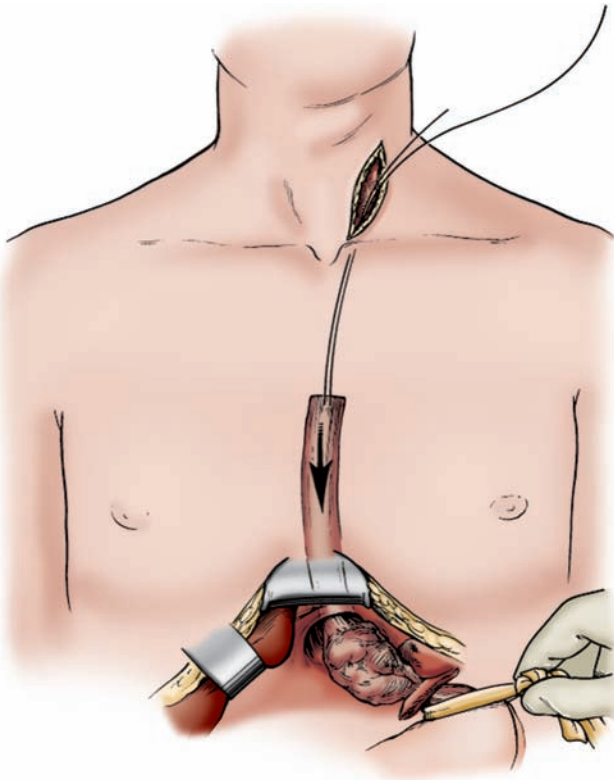
The gastric tube is then constructed by resecting the GE junction and the lesser curvature of the stomach down to the crow's foot of veins with a series of thick tissue 75-mm gastrointestinal anastomosis (GIA) staplers (Fig. 18-16). A narrow gastric tube is believed to aid in emptying; however,

a diameter of less than 5–6 cm may compromise conduit perfusion. The right gastric artery along the lesser curvature can be divided in order to allow elongation of the conduit (Fig. 18-17). The specimen is removed, and frozen sections are performed on the margins. Inspection for hemostasis is

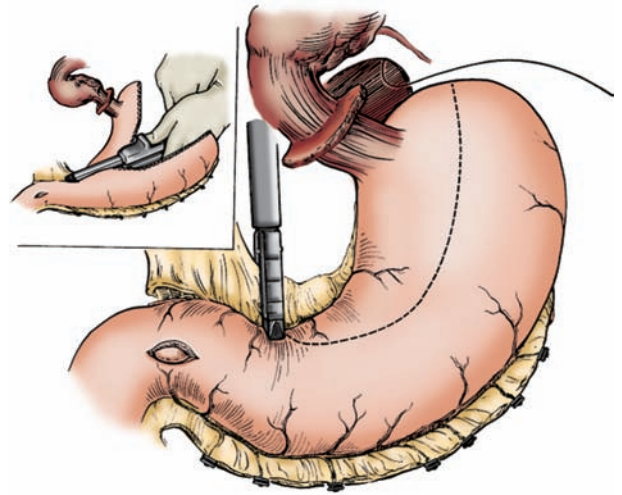


**FIGURE 18-14** A GIA stapler is used to divide the cervical esophagus. Note the ligated middle thyroid vein and divided omohyoid muscle. *Inset:* Traction is placed on the Penrose drain around the cervical esophagus.

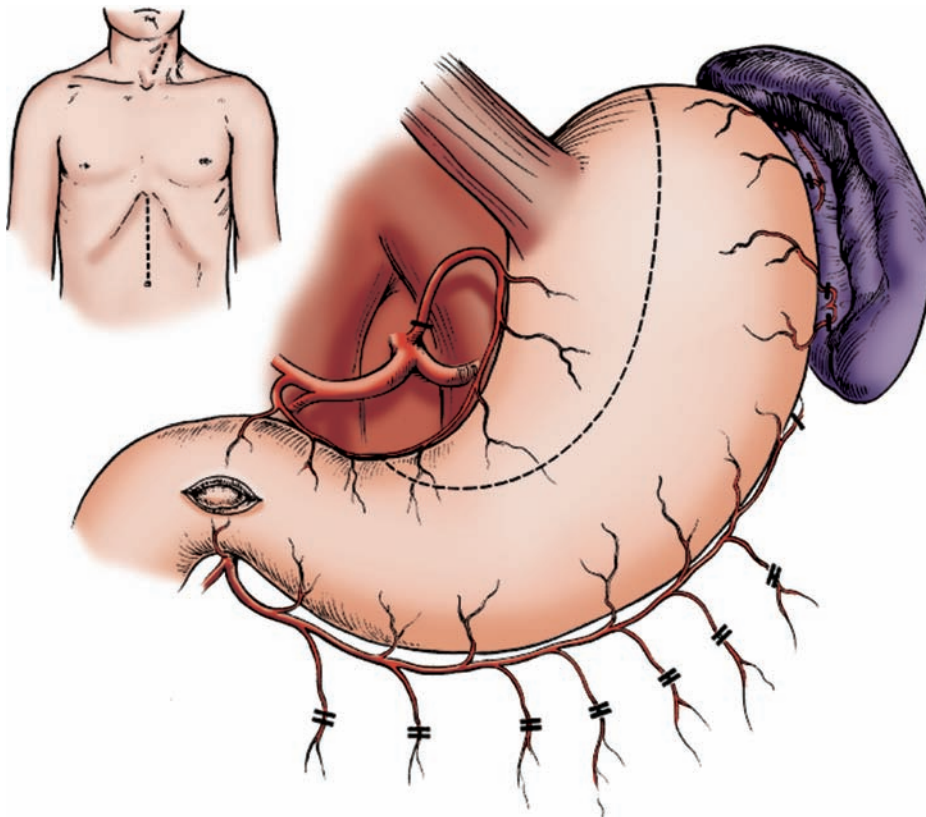




**FIGURE 18-15** The specimen is removed through the abdominal incision with a long heavy silk suture attached to the end of the esophagus.



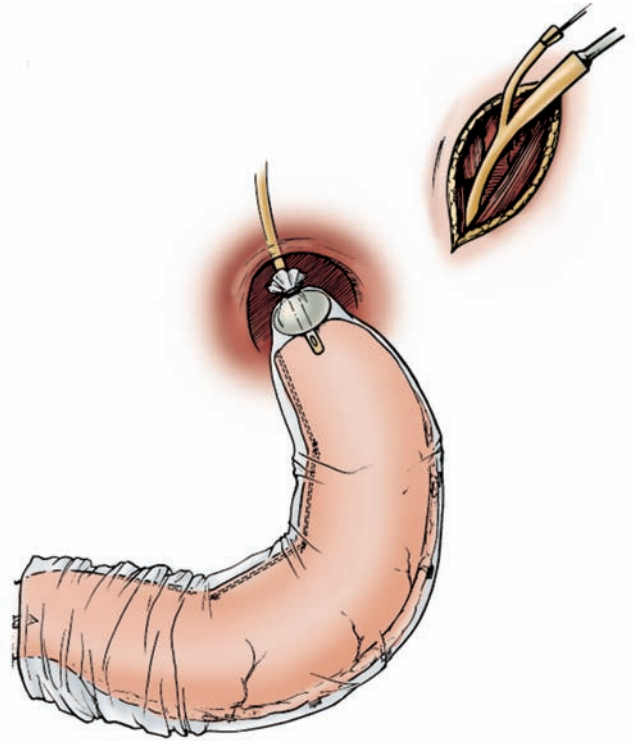
**FIGURE 18-17** The right gastric artery and lesser omentum are divided with an endostapling device. *Inset:* A GIA stapler divides the stomach along the lesser curvature, creating the gastric conduit.



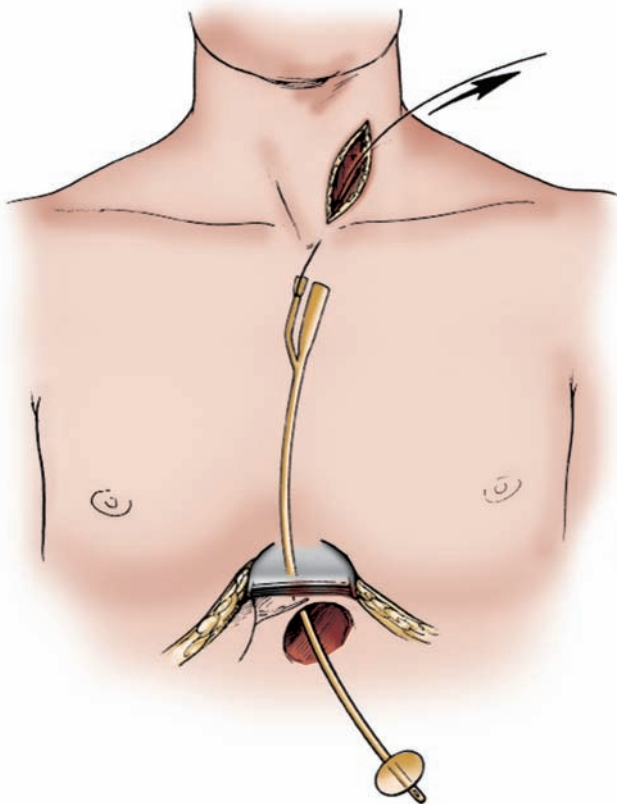
**FIGURE 18-16** The stomach is mobilized as a pedicle based on the right gastroepiploic vessels. *Inset:* Incisions illustrated.

made of the gastric bed. The esophageal hiatus should admit four fingers. One ampule of IV glucagons is administered to ensure relaxation and lengthening of the gastric conduit. The silk tie that traverses the mediastinum is then attached to the valved end of a Foley catheter with a 30-cc balloon (Fig. 18-18). An endoscopic camera bag is secured around the 30-cc balloon (Fig. 18-19). The conduit is advanced into the bag, ensuring appropriate orientation. Suction is applied to the bag via the Foley catheter, and the conduit is drawn up into the neck incision (Fig. 18-20). The assistant must actively guide the conduit through the hiatus. At the end, the pylorus should sit at the hiatus.

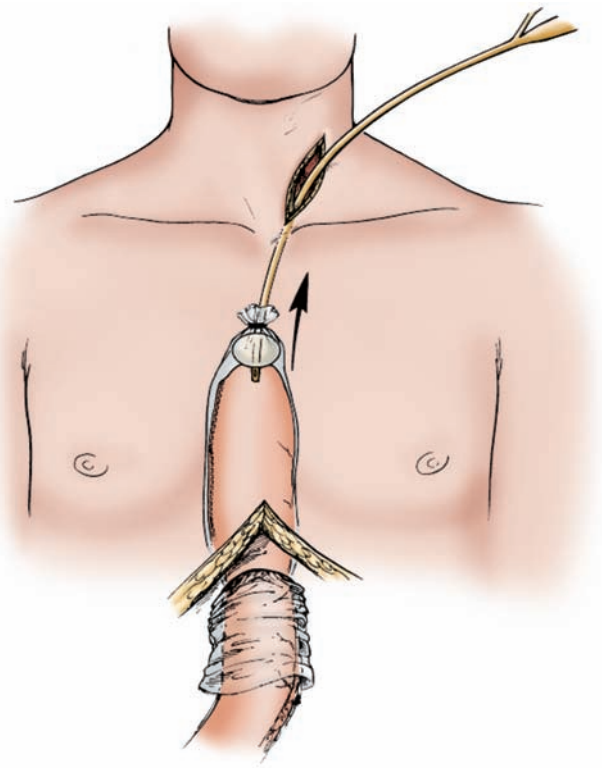
The neck anastomosis can be hand-sewn using interrupted full-thickness 3-0 silk sutures (Fig. 18-21). The anastomosis may also be stapled in side-to-side, functional end-to-end fashion. A portion of the esophageal staple line is removed, an enterotomy is created on the posterior aspect of the gastric tube, and a linear GIA 75-mm stapler is inserted to create the anastomosis (Fig. 18-22). An additional fire of an endoscopic 30-mm stapler may be used to gain additional length on the anastomosis. The enterotomy is usually closed with a TA 30 or 60 stapler after guiding the nasogastric tube down toward the hiatus. Hybrid anastomosis has been described with the back wall of the anastomosis created using a 30-mm stapler and the anterior wall closed with sutures. A



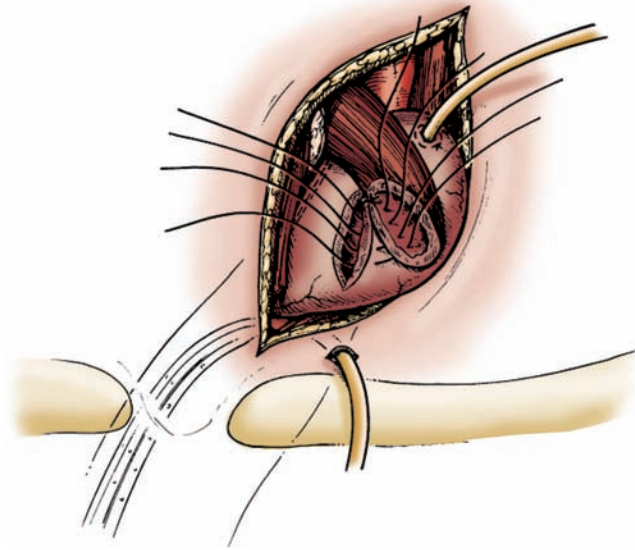
**FIGURE 18-19** An arthroscopy camera bag is tied around the Foley catheter balloon and the gastric conduit is placed in the folded-up arthroscopy bag ensuring the proper axial orientation. *Inset:* A Yankauer suction is attached to the Foley catheter to collapse the bag around the neoesophagus.



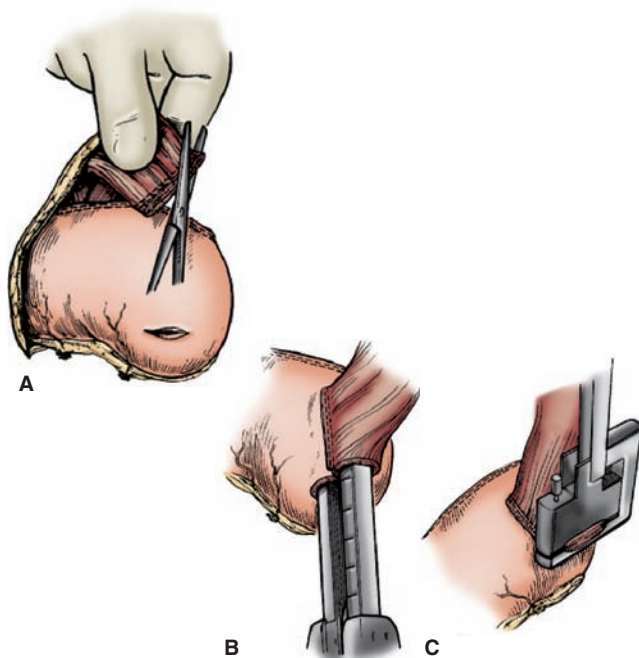
**FIGURE 18-18** The heavy silk is tied to the port of a 30-cc balloon Foley catheter and is pulled up partially through the neck incision.



**FIGURE 18-20** The gastric conduit is atraumatically pulled through the posterior mediastinum into the cervical wound.



**FIGURE 18-21** The esophago-gastric anastomosis is performed with a single layer of full-thickness interrupted nonabsorbable sutures. The Silastic sump drain is shown emanating from the fundus of the gastric conduit. A Jackson-Pratt drain is shown positioned alongside the gastric conduit inferiorly and exiting from a separate stab wound above the clavicle.



**FIGURE 18-22** **A.** and **B.** The stapled functional end-to-end anastomosis is performed using the GIA stapler to approximate the side of the esophagus to the anterior wall of the stomach. **C.** The TA linear stapler is then used to close the defect between the two free walls.

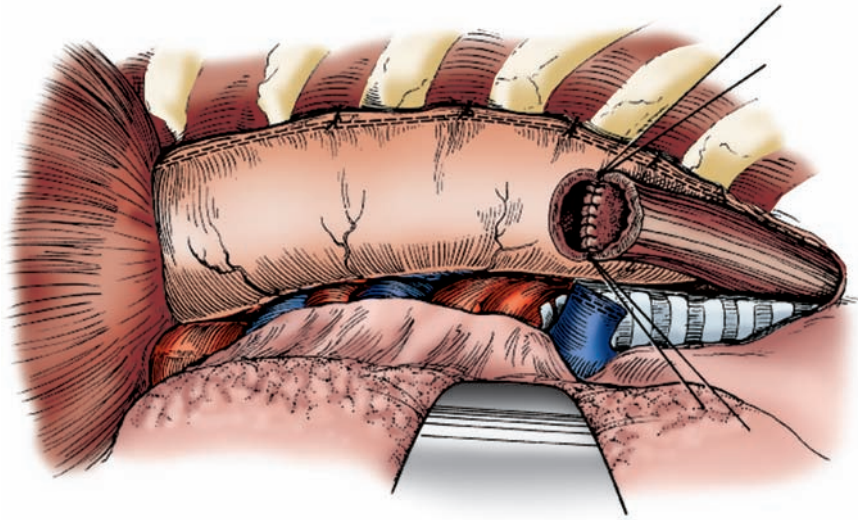
soft drain should be placed posterior to the anastomosis and the platysma and skin are closed separately. It is wise to use an interrupted closure, as this will allow for reopening of a portion of the wound should a cervical leak develop. Before closing the abdomen, a J-tube should be inserted at a point approximately 40 cm distal to the ligament of Treitz. The fascia is closed using a #2 running monofilament suture and the skin is closed with staples.

### Ivor Lewis Technique

The patient is placed in the supine position. Bronchoscopy to rule out tracheobronchial invasion and esophagoscopy to confirm the location of the tumor are performed. An upper midline incision is made from the umbilicus to the xiphoid. The abdominal phase of this operation is identical to the previously described tri-incisional technique. Enlargement of the hiatus and dissection of the lower esophagus are more easily performed through the abdomen than through a high thoracotomy incision. The GE junction and lesser curvature of the stomach are resected using a GIA stapler. The specimen is left attached to the esophagus to facilitate mobilization into the chest. A J-tube is placed before closing the abdomen.

A double-lumen endotracheal tube is placed and the patient is repositioned in the left lateral decubitus position. A right posterolateral thoracotomy is performed, and the chest is entered through the fourth or fifth interspace. The azygos vein is divided and the intrathoracic esophagus is dissected. All lymphatic tissue is included with the esophagus. Because a gross margin of 5 cm, and ideally 10 cm, is desired, the anastomosis is usually performed high in the chest at or above the level of the azygos vein. The proximal esophagus is dissected only several centimeters above the proposed level of transection to preserve its blood supply. The mobilized stomach is pulled up into the chest. The anastomosis can be constructed using an EEA stapler or hand-sewn technique. If a hand-sewn anastomosis is chosen, a double-layer technique is advisable (Fig. 18-23). In 1942, Churchill and Sweet described a method of double-layer anastomosis that is still often used today.<sup>29,30</sup> A point on the gastric tube at least 2 cm away from the staple line is chosen for the anastomosis. A circle of stomach serosa 2 cm in diameter is scored and the underlying gastric vessels are ligated with 4-0 silk sutures. The back outer layer of the anastomosis is constructed with interrupted 4-0 silk horizontal mattress sutures. These are placed 4 mm away from the serosal edge. Full-thickness stomach and esophageal wall are used. The esophagus is opened with a sharp instrument and the inner layer is constructed with interrupted suture incorporating esophageal mucosa and full-thickness stomach edge. The nasogastric tube is passed after completion of the posterior wall. A continuous Connell suture may also be used. The anterior outer layer anastomosis is constructed with 4-0 silk horizontal mattress sutures. The anastomosis should be wrapped or buttressed with omentum. At all times, atraumatic handling of mucosal edges and tying of sutures without crushing of tissues are advised. Some surgeons advise tacking





**FIGURE 18-23** View through a right thoracotomy incision showing an esophagogastric end-to-side anastomosis in the apical right chest. Note the tacking sutures from stomach to the posterior chest wall to avoid torsion.

the edge of the stomach wall to mediastinal tissue or paravertebral fascia to decrease tension on the anastomosis, although it is not clear if this is necessary. A 28F straight chest tube is placed into the apex of the chest via a separate stab incision. The chest is closed with interrupted #2 Vicryl paracostal sutures, followed by a 0 Vicryl running latissimus layer, a 2-0 Vicryl running subdermal layer, and a 3-0 Vicryl subcuticular layer. Postoperative toilet bronchoscopy should be performed.

## Transhiatal Technique

### CONSIDERATIONS

We believe that a tri-incisional approach gives better exposure to the thoracic esophagus, allowing for a safer and wider resection and better lymphadenectomy. As discussed, there may be survival advantages to the radical resection permitted by the transthoracic technique, although trials to date have not shown a statistically significant survival advantage using this approach. In cases in which the thoracic esophagus is not involved with tumor (either high-grade dysplasia or a laryngeal tumor involving the proximal esophagus), the transhiatal technique may be performed with equivalent oncological efficacy.

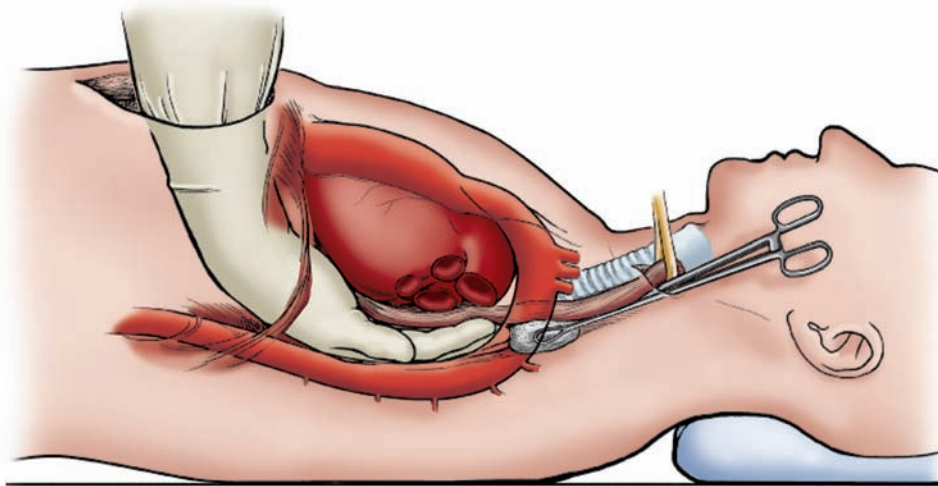
### TECHNIQUE

The patient is placed in the supine position with the head rotated 45 degrees to the right. The abdominal phase of the operation is performed in identical fashion to that described in the tri-incisional section above. An upper-hand retractor is useful in elevating the sternum and costal margin. The phrenoesophageal ligament is divided using cautery, and the lower esophagus is

encircled with a 1 in wide Penrose drain. The phrenic vein must first be identified and ligated. This will also enlarge the window for dissection of the intrathoracic esophagus. The hiatus is dilated to allow entry of the surgeon's hand. Arterial branches from the aorta are clipped on the aortic side and divided using cautery. Thin handheld malleable retractors are used to retract either side of the pleura during the dissection. Dissection under direct vision is usually possible up to the level of the inferior pulmonary veins.

At this point, an incision is made in the left neck along the anterior border of the sternocleidomastoid muscle starting at the sternal notch and extending 6–8 cm. The platysma is divided. The sternocleidomastoid muscle and carotid sheath are retracted laterally. The omohyoid is often divided. The middle thyroid vein is ligated and divided. A retractor may be used but must not rest on the recurrent nerve in the tracheoesophageal groove. The esophagus is palpated anterior to the spine and posterior to the trachea. Sharp dissection is carried out immediately on the esophagus, separating the esophagus from the membranous trachea and recurrent nerve. The esophagus is looped with a 1-in Penrose drain.

Blunt dissection of the posterior plane of the esophagus is performed first. From the abdomen, the surgeon's hand is placed in between the spine and esophagus with the palmar aspect of the fingertips immediately against the esophagus (Fig. 18-24). This is performed in conjunction with raising the esophagus anteriorly with the aid of the Penrose drain. An identical maneuver is performed through the cervical incision. When sufficient dissection has been done from either side, both hands are introduced simultaneously and an attempt is made to touch fingertips. Intervening loose areolar tissue must then be torn, uniting the fingertips. If the surgeon's fingertips will not reach from the neck, a sponge stick can be used. While the surgeon's hand is behind the

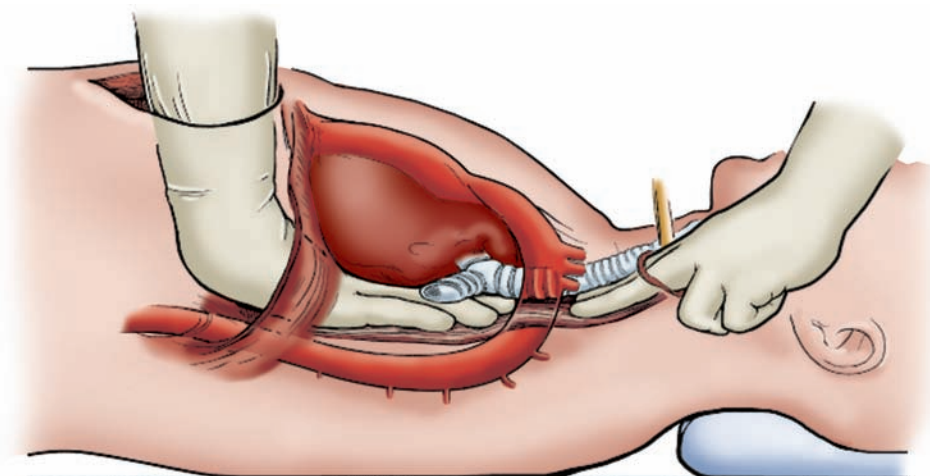


**FIGURE 18-24** Lateral view of the blunt dissection posterior to the esophagus in the chest. A sponge stick is used, as it may be difficult to insert one's hand completely through the cervical incision. (Redrawn, with permission, from Orringer MB, Sloan H. Esophagectomy without thoracotomy. *J Thorac Cardiovasc Surg.* 1978;76:643.)

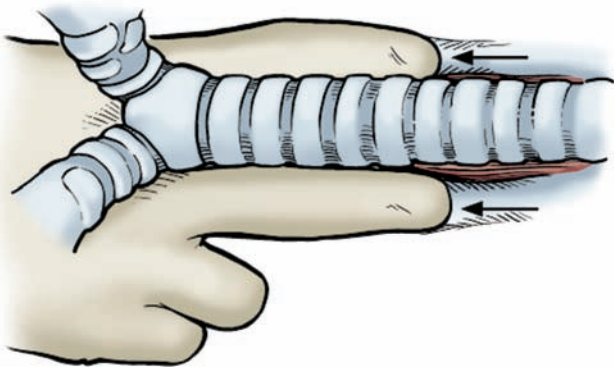
heart, there must be constant communication between the surgeon and the anesthesiologist. Hypotension often results from compression of the left atrium and impairment of left ventricular filling. It is wise to have the arterial line tracing and numbers in direct view of the surgeon; the surgeon's eyes should be on these numbers as he/she performs the blind dissection with his/her fingers.

Dissection anterior to the esophagus is then performed in nearly identical fashion. The palmar aspect of the hand is again kept directly against the esophagus (Fig. 18-25). As dissection approaches the carina from below, the surgeon will note an increase in the tenacity of the anterior attachments to the esophagus. Dissection must be gentler in this area. A gentle side-to-side motion of the fingertips will also

separate the trachea from esophagus. Eventually the fingertips from both hands are united. Once the anterior and posterior dissection has been completed, the lateral attachments are then divided. From the neck incision, as much blunt dissection of the lateral attachments as possible is performed under direct vision. Next the surgeon's hand is introduced anterior to the esophagus with the palmar aspect of the hand facing the esophagus. The hand is inserted until the first and second fingers are above the level of dissection of the lateral attachments. These attachments are pressed against the spine, and using a raking motion the surgeon pulls his hand back toward the abdomen, releasing the lateral attachments (Fig. 18-26). Care must be taken in the region of the azygos vein and its branches.



**FIGURE 18-25** Anterior blunt dissection of the esophagus in the chest. Dissection must be gentle and deliberate around the level of the carina to avoid tracheal as well as azygos vein injury.



**FIGURE 18-26** The esophagus has been freed from the trachea, and the lateral attachments are avulsed from a cranial to caudal direction.

The remainder of the operation, including the anastomosis, is identical to that of the tri-incisional technique. After removing the specimen, it is wise to pack the mediastinum with a lap pad (without compressing the heart) to facilitate hemostasis. Prior to drawing the conduit into the neck, a final inspection is made for hemostasis and for entry into either pleural space. If either pleural space is entered, a chest tube should be placed.

## Left Thoracoabdominal Approach

### CONSIDERATIONS

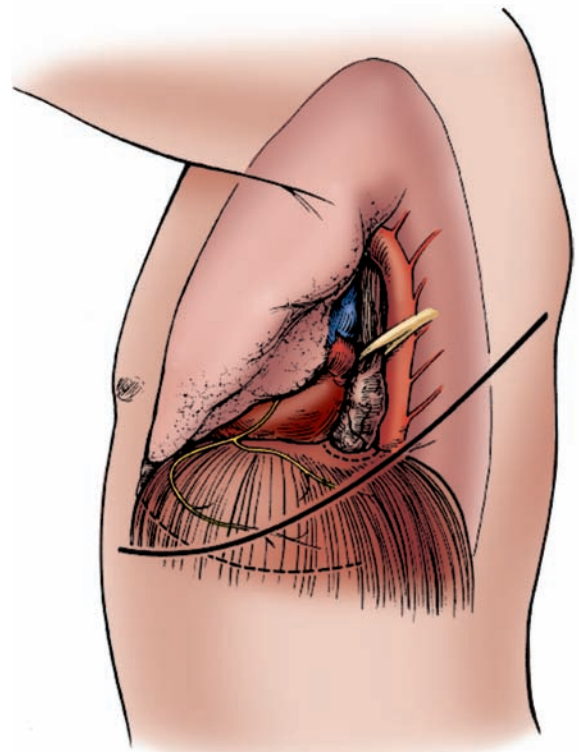
Limited resection of the distal esophagus via left thoracotomy is almost always a compromise procedure. Only the distal esophagus is readily accessible via the left chest, as the aortic arch obscures much of the upper esophagus. A tumor that extends more proximally than 30 cm should not be approached through the left, as a difficult dissection behind the aortic arch will be required. In addition, placement of the esophagogastric anastomosis low in the left chest can be associated with severe GE reflux. This approach is best reserved for a GE junction cancer that involves a significant portion of the proximal stomach and when there is concern that the residual stomach may be of insufficient length to reach the neck.

A variety of incisions or a combination of left thoracic and abdominal incisions can be used for this approach. An upper midline laparotomy can be extended across the costal margin. This is the least versatile approach and its use is limited to instances in which use of the esophagus is unexpected, as with proximal extension of a gastric tumor. A second approach involves placing the patient in full right lateral decubitus position and taking the diaphragm down in radial fashion 2–3 cm from the chest wall to gain exposure to the abdomen. This approach permits good exposure to the upper abdomen, although exposure to the pylorus and duodenum may be difficult.

### TECHNIQUE

The most versatile thoracoabdominal approach involves positioning the patient in the right lateral decubitus position with the hips rotated posteriorly 45 degrees. A left sixth interspace thoracotomy is performed beginning at the tip of the scapula and extending across the costal margin toward the abdominal midline. The latissimus is divided and the serratus is spared. The costal margin is divided with a rib cutter. The left lung is deflated. The diaphragm is incised circumferentially 2–3 cm away from the chest wall (Fig. 18-27). Doing so avoids injury to the radial branches of the phrenic nerve. The abdomen is explored for metastatic disease. Cautery is used to divide the inferior pulmonary ligament. The mediastinal pleura overlying the esophagus is incised, and the esophagus is encircled in the lower chest including all tissue from the aorta to the pericardium. The esophagus is dissected proximally behind the inferior pulmonary vein. A proximal gross in situ margin of 10 cm is ideal, though lesser margins, if confirmed negative by frozen section, may be adequate. A point of division of the proximal esophagus is identified and mobilization above this point is minimized to preserve blood supply to the anastomosis. The thoracic duct can be located at this level and ligated if desired.

The incision permits excellent exposure of the short gastric vessels, which are ligated starting at the hiatus. Care is taken



**FIGURE 18-27** Left thoracoabdominal approach; dotted lines delineate the circumferential diaphragmatic incision as well as the hiatal margin incision. A Penrose drain encircles the esophagus above the tumor.



along the greater curvature, where the short gastric vessels end and the right gastroepiploic vessel begins. The right gastroepiploic artery is preserved. The gastrohepatic ligament is divided. The left gastric artery is identified and all celiac lymph nodes are swept up onto the specimen. The stomach is retracted anteriorly and the left gastric artery is divided with a vascular endoscopic stapler. The gastric tube is constructed by sequential fires of GIA staplers starting at the fundus and extending down to the crow's foot of veins. Six centimeters of distal margin is desirable. A Kocher maneuver and pyloroplasty or pyloromyotomy are performed, and the tube is passed through the enlarged hiatus into the chest. The anastomosis is typically constructed inferior to the aortic arch and may be hand-sewn as described in the previous section or stapled.

If needed, the dissection can be carried to the neck with this incision with some difficulty. The proximal esophagus can be dissected bluntly under the aortic arch, and provided the neck has been prepped into the field, a left cervical incision is made as in the tri-incisional technique and the conduit pulled into the neck. Closure begins with careful reapproximation of the diaphragm with interrupted horizontal mattress 0 silk sutures followed by solid reapproximation of the costal margin with figure-of-eight wire or heavy nonabsorbable suture such as no. 1 Prolene. Some surgeons prefer not to divide the costal margin and, instead, perform all intra-abdominal work through the divided diaphragm.

## ALTERNATIVE METHODS OF RECONSTRUCTION: COLON AND JEJUNUM

### Colonic Interposition

The stomach is the preferred organ for esophageal replacement because of its blood supply, the resistance of these vessels to atherosclerotic disease, the need for a single anastomosis, and the ability of the stomach to reach the neck without difficulty. Prior gastric surgery, scarring from peptic ulcer disease or involvement with tumor may preclude use of the stomach as a conduit. In this instance, colon interposition may be employed. The left colon is preferred over the right colon for several reasons. Its diameter more closely resembles that of the esophagus, its vascular supply has less variation, and greater length can be obtained. Unfortunately, atherosclerotic disease most commonly affects the inferior mesenteric artery, and the left colon is often more affected by diverticular disease than the right.

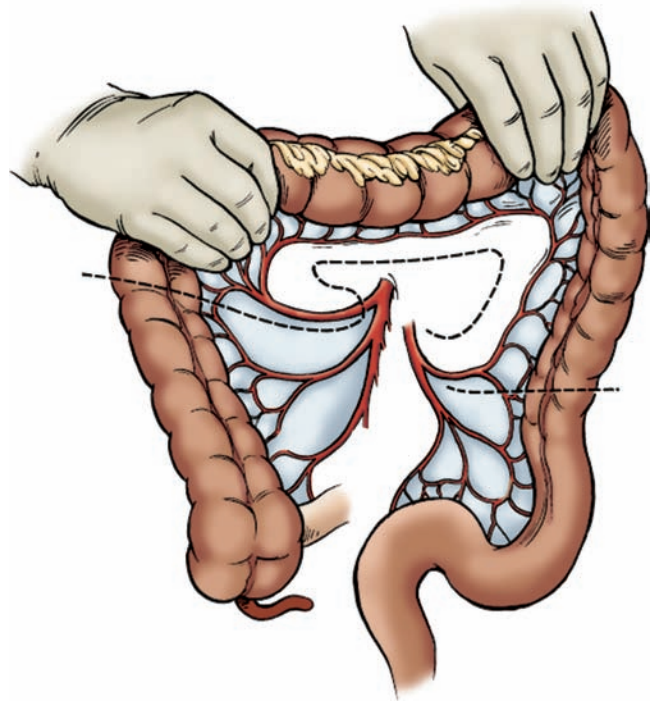
Preoperative preparation includes colonoscopy or barium enema to ensure normal anatomy and the absence of any intrinsic colonic disease. Patients older than 40 years or any patients with atherosclerotic risk factors should undergo mesenteric angiography. Significant vascular disease of the conduit vessel would preclude its use as a conduit. A complete bowel prep and oral antibiotics are necessary prior to operation.

### LEFT COLON

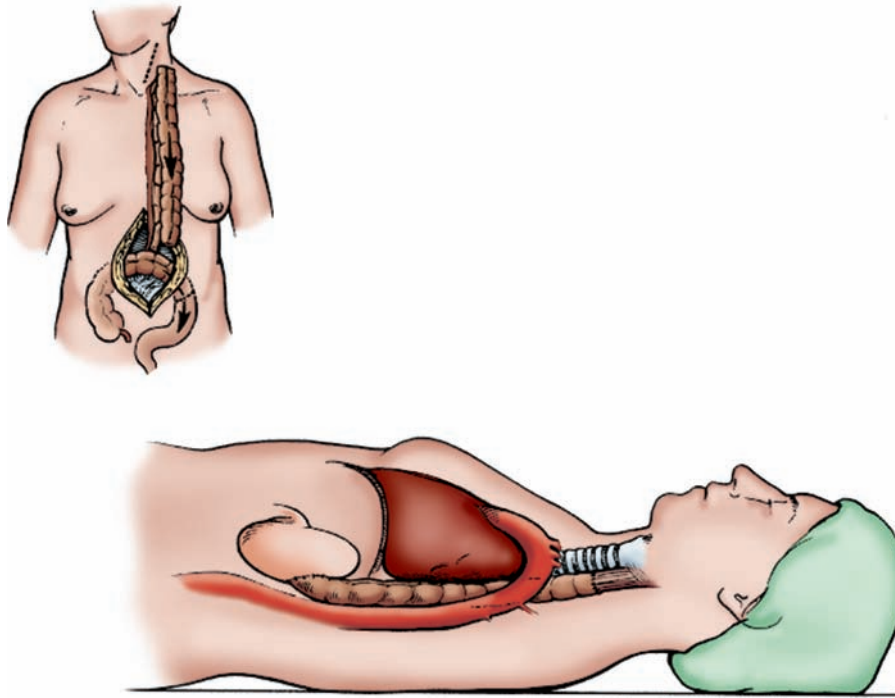
After completion of the thoracic phase of the operation, the patient is placed in the supine position and a midline laparotomy is performed. After a careful search for metastatic disease, the left colon is mobilized by dividing the white line of Toldt and by dividing the attachments to the spleen and omentum. The colon is freed proximal to the hepatic flexure. A careful inspection is made of the vascular supply, including the marginal artery of Drummond (Fig. 18-28). A pulse should be palpable in the left colonic artery as well as the marginal artery. The middle colic artery supplying the hepatic flexure is clamped with a soft bulldog clamp and its perfusion is inspected for 10 minutes.

Prior to conduit isolation, the GE junction is isolated and the cardia and lesser curvature are dissected with division of the phrenoesophageal ligament and the gastrohepatic ligament. The stomach is divided using a GIA stapler. A pyloric drainage procedure is performed. The length of colon needed is estimated by placing an umbilical tie along the proposed route of colonic interposition. This tie is placed alongside the colon and the length of required colon is determined.

After ensuring adequate blood supply to the conduit, the marginal artery is ligated distal to both branches of the left colic artery. The middle colic artery is divided near its origin. The mesentery is scored and divided between clamps. The colon is divided with GIA staplers and the conduit is packed in moist gauze. The colocolonic anastomosis is most



**FIGURE 18-28** The mobilized colon is elevated, and the arterial supply and venous drainage are examined. The arterial and venous ligation sites and the mesenteric incision lines are illustrated for an isoperistaltic conduit based on a left colic artery supply.



**FIGURE 18-29** Lateral view of the colonic conduit in the posterior mediastinal esophageal bed. Cervical esophagocolonic and posterior cologastric anastomoses are shown. *Inset:* Neck incision marked and left colon conduit mobilized on the anterior chest wall, based on the marginal artery pedicle of left colonic artery and placed in isoperistaltic position.

easily stapled in side-to-side functional end-to-end fashion. The mesenteric defect is closed with a running suture to avoid internal herniation. The esophagus is identified in the neck and the esophagectomy is completed as previously described in the tri-incisional esophagectomy section.

The colon can be brought to the neck via either the anterior mediastinum (substernal) or the in situ route (bed of the resected esophagus). The in situ route is preferred, as it provides the shortest route to the neck (Fig. 18-29). In instances of prior infection or scarring (as seen with gastric conduit necrosis or leak), the in situ route may be scarred and unusable. The substernal route may then be used with resection of the manubrium required to prevent acute angulation and possible obstruction in the neck. The colon is oriented in isoperistaltic position and drawn to the neck in an endoscopic camera bag as described previously. The proximal anastomosis is most easily performed using a single-layer interrupted technique with fine 4-0 silk sutures. An EEA or functional end-to-end stapled anastomosis is also acceptable. The nasogastric tube is guided through prior to completion of the anastomosis. The cologastric anastomosis is then performed onto the posterior aspect of the stomach. The easiest method of anastomosis employs an EEA stapler. The handle is placed through an anterior gastrotomy and creates the anastomosis in the posterior wall of the stomach. The gastrotomy is then closed with a TA stapler. The nasogastric tube must be guided through the anastomosis into the stomach. Any excess length in the conduit should be

pulled into the abdomen; if it remains in the chest, obstruction may result. The colon is sutured to the left crus of the diaphragm at the hiatus using seromuscular sutures in a two-third circumferential fashion in order to prevent herniation of abdominal contents into the chest.

## RIGHT COLON

There are numerous conditions that may make the left colon unsuitable as a conduit, including extensive diverticular disease, stricture from ischemia or infection, atherosclerotic occlusion of the inferior mesenteric artery, or splenic vein thrombosis and thrombosis of the inferior mesenteric vein. In these instances the right colon may be used as a conduit to reach the neck. The right colon is mobilized by lysis of its retroperitoneal attachments. The length of colon needed is estimated with an umbilical tape as described previously. The greater omentum is removed from the hepatic flexure and proximal half of the transverse colon. Its mesentery is transilluminated revealing the ileocolic, right colic, middle colic, and marginal arteries. The ileocolic and right colic arteries are clamped in preparation for division of these vessels and mobilization of the conduit based on the middle colic artery. If perfusion appears adequate, these vessels are ligated. The peritoneum overlying the base of the mesentery is scored, and the remainder of the mesentery is divided between clamps and ligated. The proximal and distal ends of the conduit are divided with a linear cutting stapler. Some incorporate the

ileocecocolic valve and distal ileum in the conduit because the diameter of the ileum closely approximates that of the esophagus. Others prefer not to use distal ileum in the anastomosis, as the valve may contribute to dysphagia.

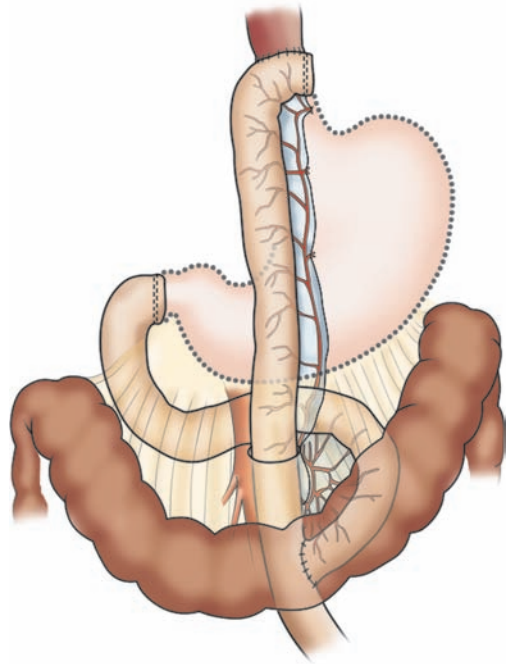
The colocolonic anastomosis is performed with staplers. The right colon conduit is then rotated in clockwise fashion (as the surgeon looks into the abdomen) in preparation for isoperistaltic transfer into the chest. As stated previously, the preferred route is via the esophageal bed. This route is often unavailable for use in colon transposition, as one of the most common indications is a failed gastric conduit placed in the esophageal bed. The retrosternal route is most often used. The diaphragm is bluntly detached from its inferior sternal attachments, and blunt dissection with the hand is performed to enlarge the tract. Division of cartilaginous attachments behind the manubrium is also necessary. The conduit is drawn into the neck via a plastic endoscopy bag as described previously. If the thoracic inlet is thought to be too constricting, the head of the clavicle, manubrium, and anterior aspect of the first rib may be resected. The proximal and distal anastomoses are performed as described for left colon conduits. The conduit may also be passed to the neck via the transpleural or subcutaneous route (with great cosmetic deformity).

## Jejunal Interposition

Jejunal interposition may be applied as a free graft, pedicled graft, or Roux-en-Y replacement. Jejunum is often the third choice (after stomach and colon) for esophageal replacement, because it cannot replace the entire esophagus to the neck, but can be used to replace a portion of the distal or proximal esophagus. When distal esophagectomy is necessary for peptic stricture, jejunum or colon interposition is preferred, as both conduits are relatively resistant to reflux. The isoperistaltic conduits are believed to have a lower incidence of recurrent reflux than the simple gastric pull-up procedure. Free jejunal grafts are used in limited reconstructions of the cervical esophagus. Patients undergoing jejunal interposition should receive preoperative antibiotics. Although a mechanical bowel preparation is not needed, it should be used if it is possible that colon may be needed.

## ROUX-EN-Y REPLACEMENT

Roux-en-Y replacement is most commonly used after total gastrectomy and distal esophagectomy (Fig. 18-30). Unlike stomach, it will not reliably reach to the cervical esophagus. The jejunum is divided approximately 20–30 cm beyond the ligament of Treitz. The jejunum and its mesentery are held up and its arcade is transilluminated. The proposed point of division is identified, as are the mesenteric vessels to be divided. The first few arcades are not divided to preserve blood flow to the native jejunum. Up to 60 cm of jejunum can be mobilized using this technique. The mesentery is scored and these vessels are clamped near their origin from the superior



**FIGURE 18-30** Roux-en-Y jejunal replacement of the distal esophagus.

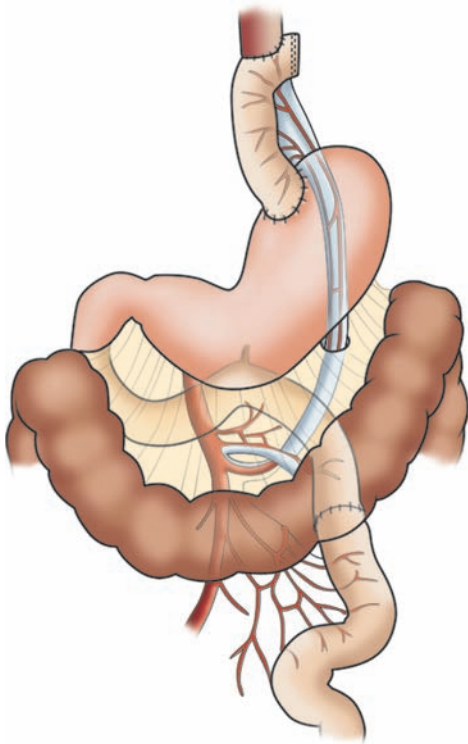
mesenteric artery with soft bulldog clamps. The conduit is observed for about 10 minutes for evidence of ischemia. The vessels are then ligated and divided. A hole is made in the transverse mesocolon to the left of the middle colic artery, just large enough to pass the jejunum and its mesentery. For replacement after total gastrectomy, the proximal anastomosis is made to the very distal esophagus in the upper abdomen. If resection of the distal esophagus is required, the incision is usually extended across the costal margin to the sixth or seventh interspace. If additional length is needed on the conduit, the next vessel in the arcade is identified, test-clamped, and then divided. The anastomosis can be performed by stapled or hand-sewn technique. The stapled anastomosis is most easily performed with an EEA stapler. The largest EEA stapler possible should be used for the anastomosis. The distal esophagus may first be dilated with a lubricated metal dilator. A full-thickness 2-0 Prolene suture is used to create a purse string in the distal esophagus. The shaft may be introduced by opening the stapled end of the jejunum. It can then be passed out the side of the jejunum and united with the anvil. Care must be taken not to occlude the ongoing lumen of the jejunum with the stapler. Two full-thickness anastomotic doughnuts should be verified. After removing the stapler, the jejunal end is closed with a TA 60 stapler. A hand-sewn anastomosis in one or two layers can also be performed. The jejunum is tacked to the hiatus at several points using interrupted silk sutures. This prevents herniation of abdominal contents into the chest and limits tension on the esophagojejunal anastomosis. Likewise, defects in the colonic mesentery should be closed to prevent an internal hernia. The distal anastomosis can be hand-sewn



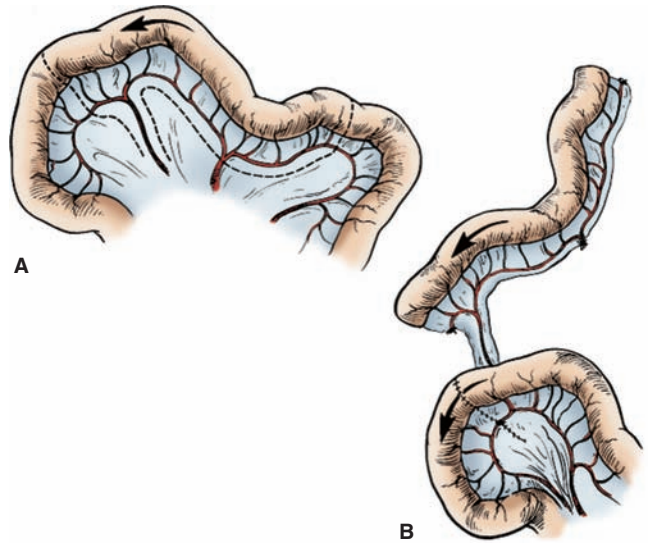
or more rapidly performed with a side-to-side functional end-to-end stapled anastomosis.

### PEDICLED JEJUNAL INTERPOSITION

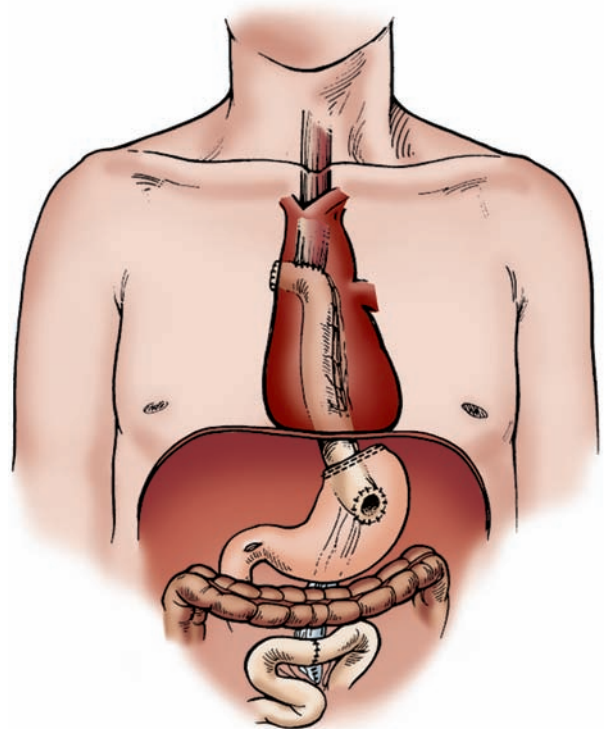
Pedicled jejunal interposition is most often used to replace a strictured distal esophagus (Fig. 18-31). A left thoracoabdominal incision is employed with a left seventh interspace incision extended across the costal margin and rectus muscle. The jejunum is transilluminated and an appropriate length of jejunum is selected, beginning 20 cm beyond the ligament of Treitz. A single large vessel is chosen as the conduit feeder vessel. The jejunum is transected proximally and distally using a GIA stapler, and the mesentery is divided down each side toward the feeder vessel (Fig. 18-32A). The jejunum is reconnected using a side-to-side functional end-to-end stapled anastomosis (Fig. 18-32B). The pedicled jejunum is tunneled through the colonic mesocolon and brought up to the left chest through an enlarged hiatus. (Fig. 18-33) The proximal anastomosis can be constructed with an EEA stapler (usually 28 cm in size, but a larger anastomosis may be more resistant to postoperative stricture). The jejunogastric anastomosis is easily performed using an EEA stapler (inserting the handle through a separate gastrotomy). A two-layered hand-sewn anastomosis may also be used.



**FIGURE 18-31** Pedicled jejunal replacement of the distal esophagus. The jejunum is brought through an incision in the transverse mesocolon.



**FIGURE 18-32** **A.** The jejunum is prepared in an isoperistaltic fashion (arrows) based on a distal mesenteric branch and proximal marginal arcade. The dotted line illustrates the line of resection of mesentery and the division of vessels. **B.** After dividing the mesentery and preserving the pedicle, jejunal continuity is restored and the mesenteric defect closed.



**FIGURE 18-33** Jejunum interposition graft to reconstruct the lower esophagus. An end-to-side esophagojejunostomy is performed to avoid tension on the vascular pedicle. A posterior jejunogastric anastomosis avoids tortuosity of the conduit while an 8- to 12-cm segment of the jejunal graft situated below the hiatus aids in the control of reflux.

### FREE JEJUNAL TRANSFER

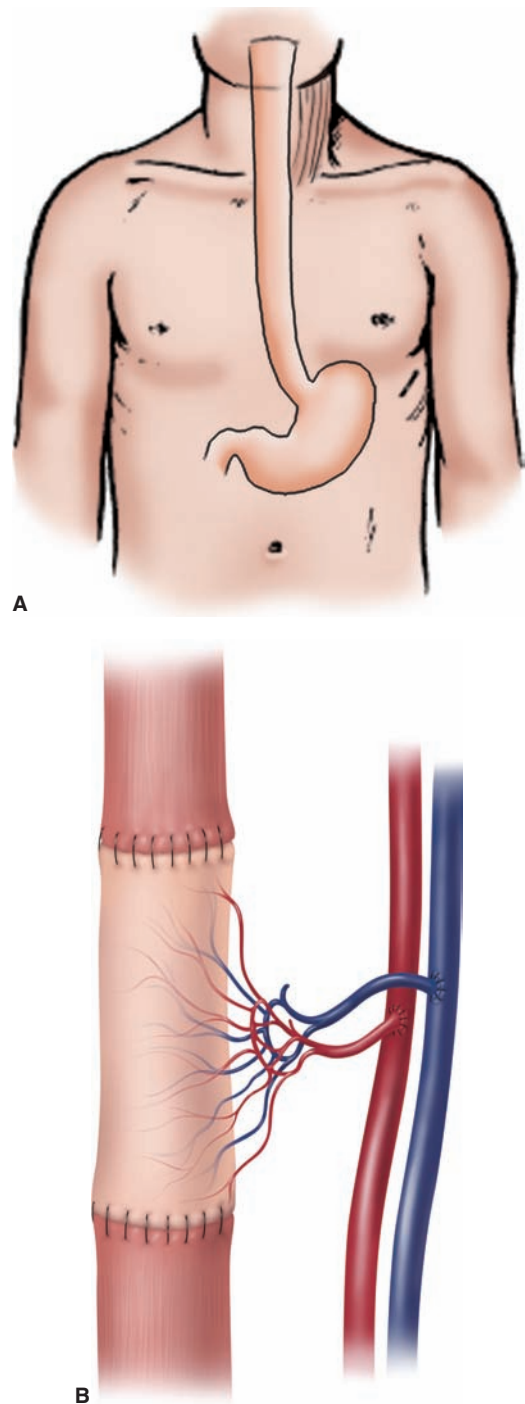
Free jejunal transfer is needed if the pedicle is not of sufficient length, such as in replacement of a portion of the cervical esophagus for benign disease. It is not clear whether use of a free jejunal transfer is preferable to total esophagectomy and gastric pull-up. The use of jejunum does carry a lower incidence of postoperative reflux and avoids dissection of the thoracic esophagus; however, there is increased risk of graft ischemia and gangrene. Two anastomoses are required and there is an increased risk of anastomotic leak. As with a pedicled jejunal graft, a short segment of jejunum is chosen for harvest. A left cervical incision is made, and the esophagus as well as the carotid artery and jugular vein are isolated. A dominant feeder vessel in the jejunal segment is identified and divided with a scalpel. The artery and vein are flushed with heparinized saline. The proximal anastomosis is constructed first and is performed with a two-layer end-to-side hand-sewn anastomosis. An operating microscope is then used to perform the arterial and venous anastomosis to the carotid artery and jugular vein with 9-0 or 10-0 Prolene suture. The distal anastomosis is then performed in fashion identical to the proximal anastomosis (Fig. 18-34). Typically, a meshed skin graft is placed over the conduit for continuous postoperative monitoring. A feeding jejunostomy tube is placed as with every case of esophageal replacement.

### COMPLICATIONS AND HOW TO AVOID THEM

#### Anastomotic Leak

The incidence of anastomotic leak is higher following cervical anastomosis (10–15%) than intrathoracic anastomosis (5–10%).<sup>22,30,31</sup> The incidence of leak is believed to be higher in the cervical position for several reasons. First, increased length is needed and this may place increased tension on the anastomosis. The tip of the stomach, which is used in the cervical anastomosis, may have a more tenuous blood supply, as it is farther from the gastroepiploic artery. Additionally, venous engorgement due to a tight thoracic inlet may impair blood supply. An analysis of anastomotic leaks found that albumin level below 3 g/dL, positive margins, and cervical anastomosis were risk factors for anastomotic leak following esophagectomy.<sup>32</sup> A randomized comparison of hand-sewn versus stapled anastomosis in 102 patients undergoing Ivor Lewis esophagectomy did not show any significant difference in the incidence of anastomotic leak. The incidence was 5% after a single-layer monofilament anastomosis and 2% after a stapled anastomosis.<sup>33</sup> The incidence of leak following hand-sewn anastomosis is more operator-dependent, and those who perform few of these procedures may wish to use a stapled technique.

Anastomotic leak following Ivor Lewis esophagectomy is a feared complication that in the past was associated with a 50% mortality rate. Centers that routinely employ this technique have refined their techniques, resulting in very low leak rates in the 2% range. Early detection and aggressive management



**FIGURE 18-34** Free jejunal graft used as a cervical esophageal replacement. It is typically covered with a meshed skin graft so that conduit health can be observed postoperatively.

can reduce the high mortality rate usually associated with this complication. Unexplained fever, elevated white cell count, respiratory failure, delirium, hypotension, or low urine output may signal the onset of an intrathoracic leak. Confirmation is usually possible by Gastrografin swallow or instillation of

contrast through the nasogastric tube. Immediate intervention is required, and attempts at direct repair with muscle flap reinforcement and wide drainage are often successful. Patients who are unstable or severely ill should be diverted with a spit fistula, and either excluded at the hiatus, or have the conduit closed and returned to the abdomen. In rare instances, a clinically silent, small, contained leak that is not adjacent to vital structures such as the trachea or aorta may be observed and treated with strict NPO status and enteral feeds.

Although leak is more common following cervical anastomosis, it is rarely life-threatening. Occasionally a cervical anastomosis may leak into the chest and must be treated like an intrathoracic leak. Initially, mortality from a cervical leak was estimated at 20%, though recent series have shown that the mortality is much lower.<sup>34</sup> Cervical anastomotic leak is usually signaled by fever, erythema, and fluctuance in the neck incision. Opening of the neck incision and probing down to the prevertebral fascia (with placement of a drain) is usually all that is needed. Patients can be allowed clear liquids by mouth and may be fed via jejunostomy tube until the leak is sealed. Barium swallow following esophagectomy may miss 10% of cervical leaks. Giving patients purple grape juice to drink and observing the drain during swallow may detect leaks missed by barium swallow.

## Anastomotic Stricture

The same risk factors that predispose to anastomotic leak also predispose one to stricture. Indeed, it is very common to present with stricture following treatment for an anastomotic leak. Retrospective meta-analyses have shown that the incidence of stricture is higher after cervical reconstruction (28%) than after Ivor Lewis reconstruction (16%).<sup>22</sup> The definition of stricture is not precise and is usually determined by the need for intervention (ie, dilation). As some surgeons are more aggressive than others with regard to dilation, this value may be misleading. A retrospective analysis of transhiatal esophagectomy patients revealed that the use of a stapled anastomosis, anastomotic leak, and the presence of cardiac disease were the only risk factors associated with the development of stricture.<sup>35</sup> Other studies have mentioned intraoperative blood loss and poor conduit vascularization as risk factors. A unifying theme in anastomotic stricture (other than mechanical stapler issues) is impaired blood supply to the region of anastomosis. In an effort to avoid ischemia, it is wise not to place the anastomosis too close to the tip of the gastric conduit. Careful handling of the gastroepiploic artery, ensuring systemic oxygen delivery, and avoidance of congestion all are important in avoiding anastomotic leak and stricture.

Mechanical factors may also contribute to development of stricture, especially when an EEA-stapled anastomosis is performed. In a randomized evaluation of the EEA stapler for Ivor Lewis anastomosis, the incidence of stricture was found to be 40% with a stapled anastomosis versus 9% with a hand-sewn anastomosis. When a small (25-mm) EEA stapler was used, the incidence of stricture was 43% as opposed to a

12.5% incidence with a 29-mm stapler, and no strictures was seen with a 33-mm stapler.<sup>33</sup>

Postoperative strictures may nearly always be managed by bougie dilation. Often, repeat dilations are needed. In the aforementioned study of strictures following Ivor Lewis esophagectomy, 53% of patients needed one dilation, 20% required two, 12% required three, and 8% required four. No patient was treated with reoperation. In Honkoop and associates' study of anastomotic stricture following transhiatal esophagectomy, the average patient required three dilations to achieve normal swallowing. Perforations occurred in 2 of the 519 patients requiring dilation.<sup>35</sup>

## Recurrent Laryngeal Nerve Injury

The clearest risk factor for recurrent nerve injury is cervical anastomosis. In a retrospective analysis, the incidence of recurrent nerve injury with a cervical anastomosis was double (11%) that for intrathoracic anastomosis (5%).<sup>22</sup> The recurrent nerve can be injured at any point, from its "recurrence" from the vagus nerve (around the subclavian artery on the right and around the aortic arch on the left), to its course in the tracheoesophageal groove, to its insertion into the larynx. Although an Ivor Lewis resection should not touch the recurrent nerve, traction or cautery injury to the vagus nerve may cause injury to the recurrent nerve.

A left neck incision is often used to approach the cervical esophagus. The right recurrent nerve is farther from the esophagus than the left, and it is easier to avoid the right nerve from a left neck incision than it is to avoid the left nerve from a right neck incision. During neck dissection, it is important to stay immediately against the esophagus in order to avoid injury to the nerve. In a review of tri-incisional esophagectomy by Swanson and colleagues, refinements in technique resulted in a reduction of recurrent nerve injury from 14% to 7%.<sup>36</sup> In the Brigham and Women's Hospital technique, the vagus nerves are divided at the level of the azygos vein, and cranial dissection of the esophagus proceeds within the nerves. A Penrose drain is used to surround the esophagus and is positioned in the neck for later retrieval during the cervical phase of the operation to ensure isolation of the esophagus inside the recurrent nerves.

Early recognition and aggressive treatment is necessary to minimize respiratory complications from recurrent nerve injury. Recurrent nerve injury prevents cord apposition, making an effective cough impossible and interfering with protective reflexes involved in swallowing. Hoarseness is present with recurrent nerve injury but may be present after any intubation. Loss of effective cough is another hallmark of recurrent nerve injury but may not be present immediately following extubation, because there may be swelling of the cords after use of a double-lumen tube, a prolonged operation, and large fluid shifts. Effective cough may be lost between 24 and 48 hours after extubation as cord swelling decreases. Any patient with hoarseness and ineffective cough should undergo fiberoptic laryngoscopy. Immediate injection of the affected cord with gel-foam will allow an effective cough and clearance of secretions.



## Respiratory Complications

In early series, anastomotic leak and infection were the most common cause of death following esophagectomy. In modern series, the most common cause of death is respiratory failure. The incidence of pneumonia following esophagectomy ranges from 2 to 57%.<sup>26,31,37</sup> The assumption that the incidence of pneumonia is higher with transthoracic esophagectomy than with transhiatal esophagectomy has not been definitively borne out by the literature. A large meta-analysis by Rindani and coworkers showed no difference in incidence of pneumonia between the two techniques.<sup>22</sup> Two randomized trials, one by Goldmine and associates and one by Chu and colleagues, also showed no difference in the incidence of pneumonia.<sup>24,25</sup> A larger randomized trial comparing tri-incisional, en bloc esophagectomy with transhiatal esophagectomy did show a higher incidence of combined atelectasis and pneumonia in the tri-incisional group (57%) versus the transhiatal group (27%). The unexpectedly high incidence of pulmonary complications in the transthoracic group should, however, be questioned, as reported rates are typically around 20–35%.<sup>20,21</sup>

A variety of modifications and maneuvers can be employed to limit the incidence of pulmonary complications. All efforts must be made to spare injury to the recurrent nerve, and, if injured, aggressive intervention including cord medialization is necessary. Efforts at limiting pain associated with thoracotomy, including a limited muscle-sparing thoracotomy, are helpful. The use of thoracic epidurals has been shown to decrease the incidence of pulmonary complications in thoracotomy patients. Early ambulation and aggressive pulmonary toilet are necessary.

## Bleeding

Bleeding following esophagectomy occurs about 5% of the time regardless of the technique used. Meta-analyses have shown that estimates of blood loss are slightly higher with the transthoracic group as opposed to the transhiatal group.<sup>23</sup> Preoperatively, antiplatelet agents should be stopped well in advance of surgery. Low-dose subcutaneous heparin or low-dose low-molecular-weight heparin should not increase the incidence of perioperative bleeding. Intraoperatively, arterial branches from the aorta to the esophagus should be clipped whenever possible. If blunt dissection is used, staying immediately against the esophagus should help avoid larger arteries, as the esophageal arterioles tend to form a fine plexus of vessels approximately 1–2 cm away from the wall of the esophagus. A notorious site of bleeding during the transhiatal dissection is the azygos vein or one of its branches. This bleeding usually occurs at about the level of the carina, and, as always, extra care should be taken at this level. A common site of bleeding after any thoracotomy is the chest wall itself, including intercostal vessels; these should be inspected after removing the retractor.

## Chyle Leak

The thoracic duct enters the chest through the aortic hiatus and lies between the spine, azygos vein, and aorta at the level of the diaphragm. At approximately the T6 level, it crosses to the left side and eventually empties into the left subclavian vein. The incidence of chyle leak following esophagectomy ranges from 2 to 10% and is at greatest risk during en bloc resection. If the thoracic duct is taken during en bloc dissection, the duct is ligated at the hiatus and inspected for leak. It is wise to inspect the area of the thoracic duct at the end of any transthoracic dissection of the esophagus. Often, clear fluid (in the unfed patient) can be seen welling up in the area and may lead one to a laceration of the thoracic duct. In such instances, the leak should be repaired directly with pledgeted 4-0 Prolene sutures. Prophylactic ligation of the thoracic duct following esophagectomy is sometimes performed. In this maneuver, all tissue between the aorta, spine, and azygos vein at the level of the hiatus is ligated with a large (0 or 1) ligature.

The diagnosis of a thoracic duct leak should be suspected if chest tube output remains high (>800 mL/d) in a patient despite a normal volume status. Definitive diagnosis may be difficult, because chyle is not milky unless the patient has been fed fats. Fluid should be sent for Gram's stain, triglyceride level, cell count, and cholesterol level. A triglyceride level greater than 1 mmol/L is strongly suggestive of a chyle leak, as is a lymphocyte count greater than 90%. If chylomicrons can be confirmed by electrophoresis, the diagnosis can also be established. A good bedside test involves feeding the patient cream enterally 200–300 mL over 2 hours and observing for a change in character of chest tube effluent, from serous to milky white.

Chyle leak following esophagectomy must be repaired. These patients are recovering from major surgery and most are malnourished. The loss of protein and lymphocytes associated with a chyle leak may be associated with infections and may interfere with healing. Once the diagnosis is confirmed, or even if it is strongly suspected, patients should be brought to the operating room and the thoracotomy incision reopened. The patient is given enteral cream 1 hour before the procedure to help locate the leak. The defect is repaired with a pledgeted 4-0 or 5-0 Prolene suture. A careful inspection for other leaks should be performed before closure, and mass ligation of the duct at the hiatus should be considered as well.

CT or MRI-guided noninvasive methods have been proposed for repairing chyle leaks. The cisterna chyli can sometimes be located under CT guidance, cannulated, and injected with either coils or glue. In a published trial of 42 patients (including 9 postesophagectomy patients), the thoracic duct could be embolized in 26 and 16 of these cases were cured.<sup>38</sup>

## Impaired Conduit Emptying

Numerous factors affect conduit emptying postesophagectomy. These include vagotomy, drainage through the pylorus, width

of the conduit, redundancy and/or kinking of the conduit, and postoperative swelling. Studies objectively looking at conduit emptying following esophagectomy give conflicting results as to the effect of pyloroplasty on gastric conduit emptying time. A prospective trial studied 200 patients and randomized half to pyloroplasty and half to no pyloroplasty following Ivor Lewis esophagectomy.<sup>39</sup> The average daily postoperative nasogastric drainage was no different between the two groups. Thirteen patients who did not undergo pyloroplasty had symptoms from delayed gastric emptying, and two died of aspiration pneumonia. There were no complications from the pyloroplasty procedure. Six months after the procedure, gastric emptying was 6 minutes in the pyloroplasty group versus 24 minutes in the group without pyloroplasty. These patients had more symptoms attributable to delayed emptying as well. The same group conducted a randomized trial of pyloroplasty versus pyloromyotomy and found both to be equally effective and safe.

Width of the gastric conduit may also affect emptying. A thin gastric tube has been shown to have a lower incidence of symptoms related to poor gastric emptying (3%) than patients either with the whole stomach (38%) or distal two-third stomach (14%) acting as the conduit.<sup>40</sup> A conduit diameter of 5–6 cm is probably ideal. Excess conduit length or angulation may also impair emptying, and excess colon conduit length or angulation is known to cause immediate or delayed problems with emptying. However, a conduit that is too thin can lead to an increased anastomotic leak rate.<sup>41</sup>

## CONCLUSION

Esophagectomy can be a technically challenging operation. Mortality rates can vary greatly with experience. Hospital volume and surgeon experience play significant roles. Analysis of the relationship between volume and mortality shows a large variance in mortality from almost 25% in low-volume and low-experience centers to as low as 2.5% in high-volume centers.<sup>42,43</sup> With improvements and increased penetration of minimally invasive techniques, mortality has been reported as low as 1.4%.<sup>41</sup> Careful patient selection, preoperative preparation, and choice of operation, as well as meticulous surgical technique, excellent anesthetic and intensive care, and aggressive management of postoperative complications can limit the morbidity and mortality of this operation.

## REFERENCES

1. Torek F. The operative treatment of carcinoma of the esophagus. *Ann Surg.* 1915;61:385.
2. Turner G. Excision of the thoracic esophagus for carcinoma of the esophagus with construction of an ex-tracheal gullet. *Lancet.* 1933;2:1315–1316.
3. Oshawa T. The surgery of the esophagus. *Arch Jpn Chir.* 1933;10:605.
4. Adams W, Phemister D. Carcinoma of the lower thoracic esophagus: report of a successful resection and esophagogastric anastomosis. *J Thoracic Surg.* 1938;7:621–632.
5. McKeown K. Total three-stage oesophagectomy for cancer of the oesophagus. *Br J Surg.* 1976;63:259.
6. Swanstrom L, Hansen P. Laparoscopic total esophagectomy. *Arch Surg.* 1997;132:943–949.
7. Nguyen N, Schauer P, Luketich J. Combined laparoscopic and thoracoscopic approach to esophagectomy. *J Am Coll Surg.* 1999;188:328–332.
8. Ellis FH, Jr, Watkins E, Jr, Krasna MJ, et al. Staging of carcinoma of the esophagus and cardia: a comparison of different staging criteria. *J Surg Oncol.* 1993;52:231–235.
9. Burmeister B, Smithers B, Fitzgerald L, et al. A randomized phase III trial of preoperative chemoradiation followed by surgery versus surgery alone for localized resectable cancer of the esophagus. *Prog Proc Am Soc Clin Oncol.* 2002;21:130A.
10. Bosset JF, Gignoux M, Triboulet JP, et al. Chemoradiotherapy followed by surgery compared to surgery alone in squamous-cell cancer of the esophagus. *N Engl J Med.* 1997;337:161–167.
11. Urba SG, Orringer MB, Turrisi A, et al. Randomized trial of preoperative chemoradiation versus surgery alone in patients with locoregional esophageal carcinoma. *J Clin Oncol.* 2001;19:305–313.
12. Walsh TN, Noonan N, Hollywood D, et al. A comparison of multimodal therapy and surgery for esophageal adenocarcinoma. *N Engl J Med.* 1996;335:462–467.
13. Tepper JE, Krasna M, Niedzwiecki D, et al. Superiority of trimodality therapy to surgery alone in esophageal cancer: results of CALGB 9781 [abstr 4012]. ASCO Annual Meeting Proceedings Part I. *J Clin Oncol.* 2006;24(18):2.
14. Urschel JD, Vasani H. A meta-analysis of randomized controlled trials that compared neoadjuvant chemoradiation and surgery to surgery alone for resectable esophageal cancer. *Am J Surg.* 2003;185(6):538–543.
15. Medical Research Council Oesophageal Cancer Working Group. Surgical resection with or without preoperative chemotherapy in oesophageal cancer: a randomised controlled trial. *Lancet.* 2002;359(9319):1727–1733.
16. Cunningham D, Allum WH, Stenning SP, et al. Perioperative chemotherapy versus surgery alone for resectable gastroesophageal cancer. *N Engl J Med.* 2006;355(1):11–20.
17. Stahl M, Walz MK, Stuschke M, et al. Phase III comparison of preoperative chemotherapy compared with chemoradiotherapy in patients with locally advanced adenocarcinoma of the esophagogastric junction. *J Clin Oncol.* 2009;27(6):851–856.
18. Flanagan FL, Dehdashti F, Siegel BA, et al. Staging of esophageal cancer with 18-fluorodeoxyglucose positron emission tomography. *Am J Roentgenol.* 1997;168:417–424.
19. Block M, Patterson G, Sundaresan R, et al. Improvement in staging of esophageal cancer: 100 consecutive positron emission tomography scans. *Ann Thorac Surg.* 1999;68:1133.
20. Saltzman J. Endoscopic and other staging techniques. *Semin Thorac Cardiovasc Surg.* 2003;15:180–186.
21. Luketich JD, Schauer P, Landreneau R, et al. Minimally invasive surgical staging is superior to endoscopic ultrasound in detecting lymph node metastases in esophageal cancer. *J Thorac Cardiovasc Surg.* 1997;114:817–821; discussion 821–823.
22. Rindani R, Martin C, Cox M. Transhiatal versus Ivor-Lewis oesophagectomy: is there a difference? *Aust N Z J Surg.* 1999;69:187–194.
23. Hulscher J, Tijssen J, Lanschot J. Transthoracic versus transhiatal resection for carcinoma of the esophagus: a meta-analysis. *Ann Thorac Surg.* 2001;72:306–313.
24. Goldmine M, Maddern G, Le Prise E, et al. Oesophagectomy by a transhiatal approach or thoracotomy: a prospective randomized trial. *Br J Surg.* 1993;80:367–376.
25. Chu KM, Law SY, Fok M, et al. A prospective randomized comparison of transhiatal and transthoracic resection for lower-third esophageal carcinoma. *Am J Surg.* 1997;174:320–324.
26. Hulscher J, Van Sandick J, Van Lanschot J. Extended transthoracic resection compared with limited transhiatal resection for adenocarcinoma of the esophagus. *N Engl J Med.* 2002;347:1662–1669.
27. Omloo JMT, Lagarde SM, Hulscher JBF, et al. Extended transthoracic resection compared with limited transhiatal resection for adenocarcinoma of the mid/distal esophagus: five-year survival of a randomized clinical trial. *Ann Surg.* 2007;246:992–1001.
28. Wong J. Esophageal resection for cancer: the rationale of current practice. *Am J Surg.* 1987;153:18–24.
29. Churchill E, Sweet R. Transthoracic resection of tumors of the stomach and esophagus. *Ann Surg.* 1942; 115:897.

30. Mathisen DJ, Grillo HC, Wilkins EW, Jr, Moncure AC, Hilgenberg AD. Transthoracic esophagectomy: a safe approach to carcinoma of the esophagus. *Ann Thorac Surg.* 1988;45:137.
31. Orringer M, Marshall B, Iannettoni M. Transhiatal esophagectomy: clinical experience and refinements. *Ann Surg.* 1999;230:392–403.
32. Patil P, Patel S, Desai P. Cancer of the esophagus: esophagogastric anastomotic leak—a retrospective study of predisposing factors. *Surg Oncol.* 1992;49:163–167.
33. Law S, Fok M, Chu KM, Wong J. Comparison of hand-sewn and stapled esophagogastric anastomosis after esophageal resection for cancer. A prospective randomized controlled trial. *Ann Surg.* 1997;226:169–173.
34. Urschel J. Esophagogastrostomy anastomotic leaks complicating esophagectomy: a review. *Am J Surg.* 1995;169:634–639.
35. Honkoop P, Siersema PD, Tilanus HW, et al. Benign anastomotic strictures after transhiatal esophagectomy and cervical esophagogastrostomy: risk factors and management. *J Thorac Cardiovasc Surg.* 1996;111:1141–1146.
36. Swanson SJ, Batirel HE, Bueno R, et al. Transthoracic esophagectomy with radical mediastinal and abdominal lymph node dissection and cervical esophagogastrostomy for esophageal carcinoma. *Ann Thorac Surg.* 2001;72:1918–1925.
37. Orringer MB, Marshall B, Chang AC, et al. Two thousand transhiatal esophagectomies: changing trends, lessons learned. *Ann Surg.* 2007;246(3):363–372; discussion 372–374.
38. Cope C, Kaiser L. Management of unremitting chylothorax by percutaneous embolization and blockage of retroperitoneal lymphatic vessels in 42 patients. *J Vase Intervent Radiol.* 2002;13:1139–1148.
39. Fok M, Cheng S, Wong J. Pyloroplasty versus no drainage in gastric replacement of the esophagus. *Am. J Surg.* 1991;162:447–452.
40. Bemelman W, Taat C, Slors F. Delayed postoperative emptying after esophageal resection is dependent on the size of the gastric substitute. *J Am Coll Surg.* 1995;180:461–464.
41. Luketich JD, Alvelo-Rivera M, Buenaventura PO, et al. Minimally invasive esophagectomy: outcomes in 222 patients. *Ann Surg.* 2003;238(4):486–494; discussion 494–495.
42. Birkmeyer JD, Stukel TA, Siewers AE, et al. Surgeon volume and operative mortality in the United States. *N Engl J Med.* 2003;349(22):2117–2127.
43. Dimick JB, Wainess RM, Upchurch GR, Jr, et al. National trends in outcomes for esophageal resection. *Ann Thorac Surg.* 2005;79(1):212–216; discussion 217–218.



# VIDEO-ASSISTED THORACIC SURGERY OF THE ESOPHAGUS

Ryan M. Levy • James D. Luketich

## INTRODUCTION

Since the initial description of laparoscopic fundoplication in 1991,<sup>1</sup> there has been continued interest in minimally invasive approaches to esophageal disease. While proponents of minimally invasive surgery claim decreases in perioperative pain and length of stay, critics often express concerns over compromised outcomes, prolonged operating times, and increased cost. However, numerous reports have documented that for both gastroesophageal (GE) reflux and achalasia,<sup>2,3</sup> the laparoscopic approach offers equal efficacy and safety as well as decreased recovery times compared with traditional open surgery. These reports and the benefits of minimally invasive surgery perceived by the general public have increased referrals to surgeons who offer these approaches to esophageal disorders, even though alternative medical therapies are available.<sup>4,5</sup>

Although laparoscopic approaches for many benign conditions involving the distal esophagus and GE junction are now standard of care, this is not necessarily the case for minimally invasive approaches to the thoracic esophagus. This is particularly true for esophageal cancer. Concerns regarding the high degree of technical complexity, significant operator learning curves, reproducibility of outcomes in lower-volume centers, and equivalence of oncologic outcomes are at the forefront of the discussion. Despite evolving techniques and improvements in both the transhiatal and Ivor Lewis surgical approaches, esophagectomies are complex operations that are associated with significant morbidity and mortality. Furthermore, surgical candidates are often elderly patients with coexisting medical comorbidities, including respiratory and cardiovascular diseases. Nationwide, the mortality rates from esophagectomies range from 8% in high-volume centers to as high as 23% in low-volume centers.<sup>6</sup>

The application of minimally invasive surgery to complex cases may offer several potential benefits. First, open esophagectomy, even in experienced centers, continues to be associated with a significant morbidity, lengthy hospital stay, and

delay in returning to preoperative activities.<sup>7</sup> This high complication rate along with the disappointing 25% 5-year survival rate after esophagectomy has led to ongoing concern over the role of surgery in the treatment of esophageal cancer. Consequently, for some patients, alternative approaches such as definitive chemoradiation alone, palliative photodynamic therapy, or stents may be chosen by health care providers. Minimally invasive approaches to esophagectomy that promise to decrease perioperative morbidity and allow for faster postoperative recovery are, therefore, appealing to patients and referring physicians. The caveat, however, is that the minimally invasive approach should not compromise operative technique or oncologic and functional outcomes.

There has been a significant evolution in technique since the initial descriptions of hybrid approaches to esophagectomy that employed thoracoscopic esophageal mobilization with a laparotomy.<sup>8-10</sup> Although no randomized studies of minimally invasive esophagectomy (MIE) have been performed, experience in our first 222 patients has suggested that MIE is associated with a complication rate and mortality lower than most reports of open esophagectomy.<sup>11</sup> In our experience, a minimally invasive approach reduces postoperative pain and pulmonary complications while comparing favorably to the best published open series with regard to morbidity, mortality, and oncologic outcomes. In addition, we and others have shown that minimally invasive staging of esophageal cancer patients is superior to conventional staging by computed tomography (CT) and endoscopic ultrasound (EUS)<sup>12</sup> and may allow for a better selection of patients to receive combined modality therapy. In this chapter, we review our experience with minimally invasive surgery for esophageal cancer, as well as detail surgical techniques for several other diseases of the thoracic esophagus, such as resection of benign esophageal tumors and thoracoscopic treatment of esophageal dysmotility. Laparoscopic approaches to other complex esophageal operations, including achalasia and paraesophageal hernia, are covered in Chapters 14 and 15.

## ESOPHAGEAL CANCER

The optimal management of patients with potentially resectable esophageal cancer is still evolving. Although surgery remains the standard of care for early disease, several studies have suggested that definitive chemoradiation may be an acceptable alternative. This position is supported by the results of a randomized, prospective trial conducted by the Radiation Therapy Oncology Group (RTOG 8501), which compared definitive chemoradiation versus radiation therapy alone for patients with locally advanced esophageal cancer, who were not considered surgical candidates.<sup>13</sup> The study was closed after accrual of 121 patients, due to a clear survival benefit in the combined treatment group. The surprising finding in this study was that the 5-year survival in the chemoradiation group was 27%, a rate not appreciably different from the survival rates following esophagectomy alone.<sup>14</sup>

Additional support for the use of chemoradiation for esophageal cancer comes from the results of two, large prospective European studies. In these studies, chemoradiation followed by surgery was compared to chemoradiation alone.<sup>15,16</sup> In both studies, overall survival was equivalent between the two treatment arms. Chemoradiation with surgery decreased locoregional recurrence within 2 years of surgery. However, with chemoradiation alone, treatment-related mortality was decreased and hospital stays were shorter.<sup>15,16</sup>

These reports have led some clinicians to recommend nonoperative therapy for marginal surgical candidates, such as the elderly or those with multiple comorbidities. Indeed, the National Comprehensive Cancer Network now considers definitive chemoradiation to be an acceptable alternative to esophagectomy in their recent guidelines.<sup>17</sup> It is incumbent upon esophageal surgeons, therefore, to continue to refine the technique of esophagectomy, in order to offer therapy with either lower morbidity, improved survival, or both compared to traditional esophagectomy and other approaches.

### Staging for Esophageal Cancer

Unlike lung cancer, in which mediastinoscopy is an accepted and proven staging technique, no invasive modality is considered standard for staging patients with esophageal cancer. However, to date none of the noninvasive staging techniques currently available, such as CT, EUS, or positron emission tomography (PET), has proven accurate enough to preclude the need for invasive staging. A recent evidence-based review concluded that there exists a benefit for laparoscopic staging of esophageal cancer based on level 2 evidence, showing a sensitivity of 71 and 78% for detection of peritoneal and nodal metastasis, respectively.<sup>18</sup> This compared favorably and exceeded sensitivities for endoscopic ultrasound and CT imaging.

The current noninvasive technology suffers from several, well-described limitations. CT, often the initial staging test performed for patients with esophageal cancer, is an appropriate

tool to screen for distant disease, such as pulmonary or liver metastases. However, even in this role, occult metastatic disease is missed by CT scans in up to 15–20% of patients.<sup>19</sup> Furthermore, CT is clearly unable to provide sufficient anatomic detail to either accurately stage the depth of invasion of the esophageal wall or determine the presence of local nodal involvement. Indeed, the accuracy of CT scanning for nodal disease is only 45–60% in most series.<sup>20,21</sup>

PET scanning is a recently introduced technology that is based on imaging the differential uptake of radio-labeled glucose by malignant and normal cells. PET scanning has been extensively studied in the context of both lung and esophageal cancer. Indeed in some centers, PET scanning has become a routine component of the preoperative evaluation of lung cancer patients. This practice is justified by several meta-analyses that have demonstrated the superiority of PET over CT in staging nodal disease in the mediastinum.<sup>22,23</sup> However, equal efficacy for PET scanning has not been demonstrated for esophageal cancer patients. We have found the accuracy of PET scanning to assess locoregional lymph nodes in patients with esophageal cancer to be only about 50%.<sup>24</sup> The specificity is improved, compared to CT, but the sensitivity remains poor. In our experience PET scanning has been more useful in detecting distant metastatic disease. In a series of 100 consecutive patients with potentially resectable esophageal cancer staged at our institution by PET and CT, PET identified metastatic disease in 16% of patients missed by CT.<sup>25</sup> The false-negative rate for PET in this series was only 10% and usually occurred in cases of subcentimeter disease that was below the detection threshold of PET scans.

Another staging tool available in specialized centers is EUS. Although EUS is operator dependent, in experienced hands its accuracy for assessing T stage is greater than 90%, and it has an image resolution of 0.2 mm.<sup>26</sup> The accuracy of determining T stage increases with penetration of the esophageal wall: the accuracy for T1 tumors is 80%, T2 tumors 90%, and T3/4 tumors 95%.<sup>27</sup> However, the accuracy of EUS to determine nodal status is far lower than its ability to determine tumor depth and has been reported to be 65–86%.<sup>12,28</sup>

### Technique of Minimally Invasive Surgical Staging

Currently, all patients at the University of Pittsburgh with a diagnosis of esophageal cancer undergo noninvasive staging with CT scans, PET scanning, and EUS. If any of these studies indicates metastatic disease or nodal involvement (in the case of EUS), a needle biopsy is performed. If distant metastatic disease is proven, palliative options are generally pursued. For patients without proven metastatic disease and GE junction tumors, we then, generally, proceed to laparoscopic staging. Laparoscopic staging is performed with the patient in a steep reverse Trendelenburg position with the surgeon standing on the patient's right side.

### OPERATIVE STEPS OF MINIMALLY INVASIVE STAGING—LAPAROSCOPY

1. An initial 10-mm blunt trocar is placed via an open, cut-down technique in the right epigastrium. The location of this port is approximately 3 cm to the right of the junction between the lower and middle third of a line connecting the xiphoid and umbilicus. After the first port is placed, a visual assessment is made of the liver and peritoneal surfaces, and, if obvious metastatic disease is present, biopsy confirmation is obtained and the staging is complete. If no metastatic disease is seen on this initial survey, a more thorough staging is performed with placement of additional port sites. These are placed in the same locations utilized for MIE.
2. The five ports generally include one 10-mm blunt cut-down port just to the patient's right of midline, midway between the xiphoid and umbilicus (for the surgeon's right hand instruments), one 10-mm port at the same level to the left of midline for the laparoscope, two additional 5-mm ports along the right costal margin (for liver retraction and dissection), and one 5-mm port on the left costal margin for countertraction by the assistant (Fig. 19-1). The liver surfaces are carefully examined and any abnormalities biopsied.

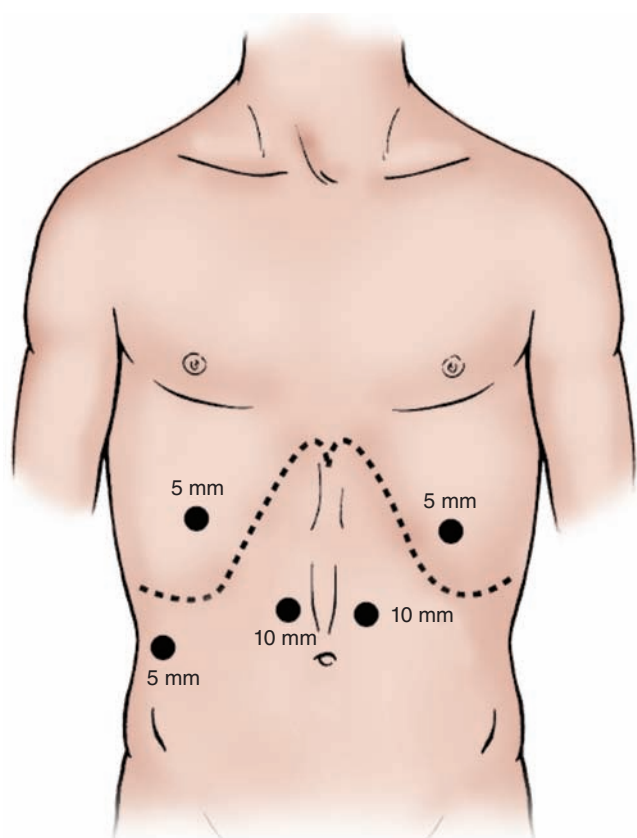


FIGURE 19-1 Abdominal port placement for staging laparoscopy and totally minimally invasive Ivor Lewis esophagectomy.

Ultrasound examination of the liver may then be performed, although in our experience, the yield of ultrasound examination in patients who do not have some visual evidence of liver metastases is low.<sup>19</sup>

3. The stomach is carefully assessed for gastric extension of the tumor to determine the suitability of the stomach for gastric pull-up.
4. Nodal assessment is initiated by incising the gastrohepatic ligament. The lesser sac is entered, and nodes along the lesser curve and at the base of the celiac artery are sampled.
5. We have been evaluating preoperative “conditioning” of the esophagus. This may be performed at the time of laparoscopic staging and includes lymph node dissection of the left gastric artery and vein and division with an Autosuture Endo GIA stapler (Covidien, Mansfield, MA) with a vascular load. We also divide the short gastric vessels from the left crus to the right gastroepiploic arcade.
6. At the conclusion of the staging procedure, a laparoscopic feeding tube may be placed. However, we have found that, in most cases, dysphagia will respond to chemotherapy, rendering a feeding tube unnecessary. If chemotherapy is planned, an Infusaport is placed at the time of staging.

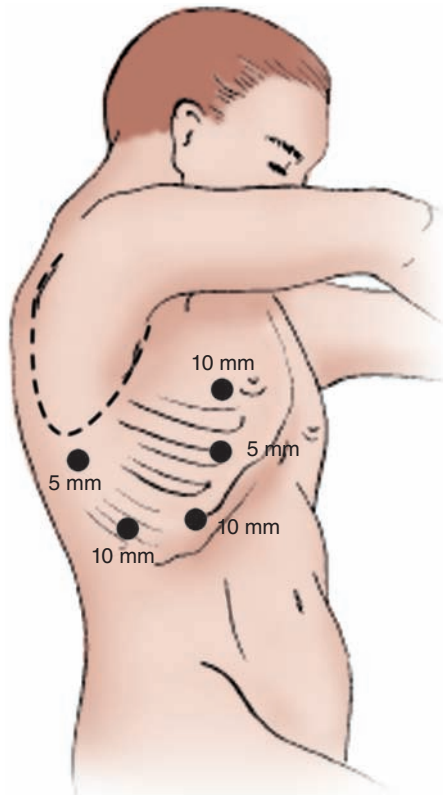
If the patient has no metastatic disease and minimal or no nodal disease is apparent on laparoscopy, we proceed to MIE. We have not found routine thoracoscopic staging to be very beneficial for most adenocarcinomas of the distal esophagus. Thoracoscopy is used selectively for tumors of the midthoracic esophagus, once laparoscopic staging has excluded gross intra-abdominal disease. This practice is based on our prospective series of 53 patients all of whom underwent both laparoscopic and thoracoscopic staging. Of the 36 patients with adenocarcinoma of the GE junction, those who were identified as node-positive using minimally invasive staging, 31 were identified by laparoscopy.<sup>12</sup> If thoracoscopy is indicated, the approach is normally through the right chest, although a left-sided approach may be appropriate if suspicious pulmonary lesions are identified on that side.

### OPERATIVE STEPS OF MINIMALLY INVASIVE STAGING—THORACOSCOPY

1. Five ports are used for access and placed as depicted in Fig. 19-2.
2. The initial step is to mobilize the inferior pulmonary ligament and to sample the level 9 nodes.
3. Next, the pleura overlying the lower third of the esophagus is opened. Once this plane is developed, nodes from the periesophageal (level 8) and subcarinal stations (level 7) may be harvested. Lymph node dissection is continued until a positive node is found or an adequate sampling indicates benign nodes only.

Two large, prospective studies have investigated the benefits of minimally invasive staging for esophageal cancer. The first, from our institution, showed significant advantages





**FIGURE 19-2** Thoracoscopic port placement for staging and totally minimally invasive Ivor Lewis esophagectomy.

for minimally invasive staging compared with more standard modalities.<sup>12</sup> All 53 patients in this report underwent CT and concurrent laparoscopy and thoracoscopy. Forty-seven patients also underwent endoscopic ultrasound. The sensitivities of CT and EUS to document nodal metastases were only 33 and 63%, respectively. Even when these two modalities were combined, inaccuracies in staging were seen in 32% of cases, compared with minimally invasive staging. Only two complications were seen in this series: a prolonged air leak and a port site hernia that was repaired on the first postoperative day.

The second study, comprising 134 patients, was a multi-institution, National Cancer Institute (NCI)–sponsored study designed to determine the feasibility of minimally invasive staging.<sup>29</sup> Successful minimally invasive staging was defined as documentation of T4 or M1 disease, the procurement of at least one abdominal and three thoracic lymph nodes, or one node that documented metastatic disease. Minimally invasive staging was successful in 73% of patients and was performed with no mortality and only minimal morbidity. Noninvasive tests, such as CT and EUS, failed to identify positive lymph nodes documented by minimally invasive staging in 20% of patients. Unfortunately, the true sensitivity of minimally invasive staging was not determined by this study because

the majority of patients underwent induction chemotherapy prior to resection.

Ultimately the role of minimally invasive staging should be clarified by clinical trials that demonstrate a survival advantage for patients with node-positive disease who receive induction therapy. To date, most randomized trials have had significant limitations and demonstrated marginal benefits for preoperative chemoradiation.<sup>30</sup> However, the poor survival obtained after surgery alone ensures that the neoadjuvant approach will continue to be investigated. We believe that a significant limitation of the studies performed to date is that patients have not been accurately staged prior to undergoing combined modality therapy. Accurate staging may identify a subpopulation of patients who would benefit from such aggressive treatment, and studies not designed for subgroup analysis may report false-negative conclusions.

## Molecular Staging of Esophageal Cancer

It is estimated that between 30 and 50% of patients who are staged as node-negative by routine histological evaluation following esophagectomy will develop a recurrence of their disease.<sup>31</sup> This suggests that these patients harbored micrometastatic disease that was undetected by routine histology. In an attempt to improve the staging of these patients, we have used minimally invasive staging to obtain lymph nodes that are evaluated with molecular biology techniques, such as reverse transcription polymerase chain reaction (RT-PCR), to determine the presence of micrometastases.<sup>32</sup> We evaluated nodes from 30 patients who were histologically staged as node-negative.<sup>33</sup> Of these 30 patients, 11 were identified by RT-PCR as harboring micrometastatic disease. Furthermore, the quantitative expression of carcinoembryonic antigen by RT-PCR was a powerful, independent predictor of disease recurrence and death. We believe that these techniques may identify patients with early-stage disease who have a high risk of recurrence and may benefit from additional therapy.

## Minimally Invasive Esophagectomy

The technique of minimally invasive esophagectomy (MIE) that has evolved as our experience with other minimally invasive foregut procedures, such as laparoscopic Heller's myotomy, repair of giant paraesophageal hernia, and staging for esophageal cancer, has grown. At present, minimally invasive techniques for esophagectomy include laparoscopic transhiatal, laparoscopic-thoracoscopic three-hole (McKeown), and laparoscopic-thoracoscopic (Ivor Lewis) esophagectomy. Each of these can be performed with lymph node sampling or a more complete lymph node dissection. While the choice between approaches is to a large degree based on surgeon preference, the operative approach is at times dictated by anatomic location of the tumor margins.

Initial attempts at MIE were hybrid operations combining traditional open surgery with minimally invasive techniques. One of the first reports by Collard et al in 1993 included 12 patients who underwent thoroscopic mobilization of the esophagus followed by laparotomy and preparation of the gastric conduit.<sup>9</sup> In that series, two patients required conversion to thoracotomy for bleeding. Several subsequent reports have demonstrated the feasibility of this approach; however no definitive benefit has been shown compared to open esophagectomy.<sup>34–36</sup>

A completely laparoscopic transhiatal esophagectomy has also been described. The largest series, published by DePaula et al in 1995,<sup>37</sup> described 48 patients who required esophagectomy predominantly for end-stage achalasia secondary to Chagas' disease. Only two patients required conversion to laparotomy. Early experience with MIE in the United States was reported in 1997, when Swanstrom and Hansen described a carefully selected group of nine patients with small tumors, benign strictures, and Barrett's disease.<sup>38</sup> Eight of these patients had a totally laparoscopic transhiatal esophagectomy, while one required the addition of a right video-assisted thoracoscopic surgery (VATS) procedure.

Similar to these early reports, our initial efforts at MIE were with the transhiatal approach. Advantages of a totally laparoscopic approach include single patient positioning and no need for single-lung ventilation. However, we found that the disadvantages of this approach were significant. The small working space through the hiatus allowed limited access to the middle and upper third of the esophagus and made any thoracic lymph node dissection extremely difficult. Because of this, we added a right VATS to mobilize the thoracic esophagus followed by laparoscopy to prepare the gastric tube. To date, we have performed over 1000 MIEs at the University of Pittsburgh Medical Center. For the majority of our initial experience, we utilized a three-hole laparoscopic-thoracoscopic approach. In our earlier publications with this technique, we demonstrated that MIE could be performed safely with equivalent stage-specific survival as compared to the larger open series in the existing literature.<sup>11</sup> Though technically demanding and associated with a significant operator learning curve, data from our series revealed a decrease in operative blood loss, length of stay, pulmonary complications, and narcotic requirements. In both our own experience and publications elsewhere, concerns arose regarding an increased incidence of technical complications associated with cervical esophagogastric anastomosis, including anastomotic leak, stricture, recurrent laryngeal nerve injury, and pharyngoesophageal swallowing dysfunction.<sup>39–41</sup> In light of these concerns and the dominance of GE junction cancers in our current referral pattern, our technique has evolved to a completely laparoscopic-thoracoscopic (Ivor Lewis) esophagectomy with complete lymph node dissection. Unless contraindicated by tumor location or previous thoracic surgery, we presently favor the totally minimally invasive Ivor Lewis approach.

The main criteria favoring the Ivor Lewis approach include the following: (1) The surgical margin afforded by the Ivor

Lewis approach is adequate for almost all GE junction tumors. (2) The technical experience of most training programs in thoracic and general surgery residencies is in the abdomen and chest and not in the neck. (3) The morbidity of recurrent laryngeal nerve injury is as high as 20–30% with neck anastomosis. (4) The length of gastric conduit needed to reach the neck may be up to 10 cm longer than that needed for an intrathoracic esophagogastric anastomosis. (5) Although easier management of leaks through the neck incision may be considered an advantage of cervical anastomoses, leaks from the neck may still drain into the chest after laparoscopic-thoracoscopic three-hole (McKeown) techniques especially when a narrow gastric conduit is constructed.

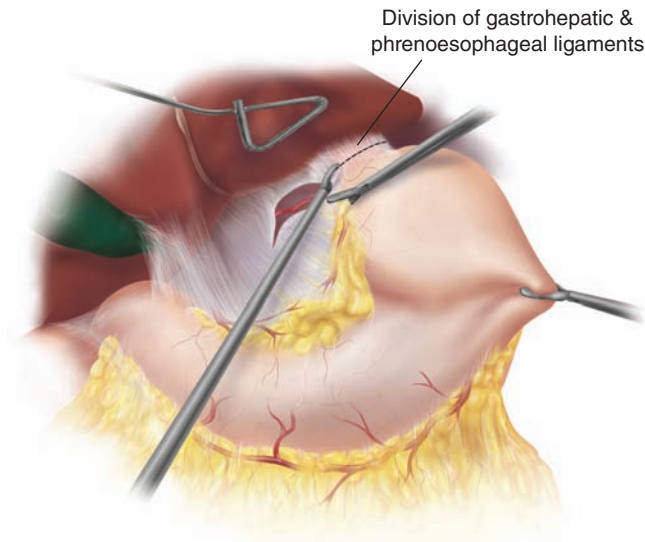
Early in our experience, MIE was only offered to patients with Barrett's disease and early-stage tumors; however, we now offer MIE to patients with more advanced disease. Patients found to have bulky celiac nodal metastases by CT or staging laparoscopy are not felt to be immediate candidates for MIE, and consideration is given to an open operation, a neoadjuvant protocol, or definitive chemoradiation.

## Operative Technique

As previously mentioned, our preferred approach has evolved to a totally minimally invasive laparoscopic-thoracoscopic (Ivor Lewis) esophagectomy. The patient is positioned supine on the operating room table with a foot board in place. A double-lumen endotracheal tube is placed for single-lung ventilation during the thoracoscopic portion of the procedure. The laparoscopic portion of the procedure is performed first.

### LAPAROSCOPIC PHASE

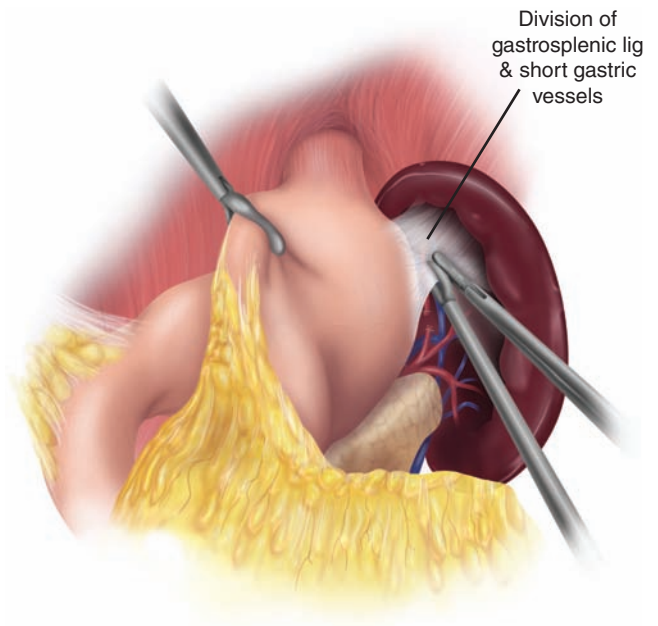
1. The initial step of MIE is an on-table esophagogastroduodenoscopy (EGD) to confirm the precise location of the tumor, evaluate proximal and distal extent with careful attention to involvement of the cardia, and assess the suitability of the stomach as a conduit for reconstruction. It is important to minimize insufflation during the endoscopy as overdistention of the small bowel can complicate the laparoscopic phase of the procedure.
2. The laparoscopic portion of the procedure is then initiated. The surgeon stands on the right side and the assistant on the left. Five ports (three of 5 mm and two of 10 mm) are placed, similar to the staging procedure (see Fig. 19-1). Initially, we place the 10-mm port via a cut-down technique approximately 3 cm to the right of the junction between the lower and middle third of a line connecting the xiphoid and umbilicus. Carbon dioxide insufflation is utilized for pneumoperitoneum to a pressure of 15 mm Hg. The remaining ports are then placed: 5 cm to the left of the operating port (30-degree camera port), subcostal on the right and left midclavicular lines (tissue grasper ports), and in the right flank (liver retractor port). If clinically indicated, we then perform laparo-



**FIGURE 19-3** Initial dissection, division of gastrohepatic ligament and crura, hiatal mobilization.

scopic staging as described previously. This lower position of the ports may make the hiatal dissection somewhat difficult but greatly facilitates the mobilization of the gastric tube. This emphasizes the importance of completely mobilizing the esophagus and any hiatal hernia sac circumferentially during the thoracoscopic dissection.

3. The gastrohepatic ligament (lesser omentum) is first divided and the right and left crura of the diaphragm are dissected to mobilize the lateral wall of the esophagus (Fig. 19-3). Care is taken not to divide the phrenoesophageal membrane at this point so as to prevent loss of pneumoperitoneum into the chest cavity. The left gastric artery/vein pedicle is identified, and by tracing its course proximally the celiac lymph nodes are then examined. A complete lymph node dissection is carried out to include the celiac nodes, sweeping all nodal and fatty tissue with the specimen; the nodal dissection is later continued along the splenic artery and the superior border of the pancreas during gastric mobilization. This plane continues cephalad toward the right and left crus, continuous with the preaortic dissection plane into the lower thoracic cavity. All lymph nodes are removed, and any lymph nodes suspicious for metastatic involvement are dissected and sent for frozen-section analysis.
4. Gastric mobilization (Fig. 19-4). The dissection is then carried anteriorly and superiorly over the esophagus to finally expose the anterior hiatus. As the dissection is continued toward the left crus, the fundus of the stomach begins to be mobilized. The medial border of the right crus is dissected inferiorly until the decussation of the right and left crural fibers, thereby exposing a retrosophageal window and completing the mobilization of the superior portion of the lesser curvature and GE junction. The greater curvature of the stomach is



**FIGURE 19-4** Gastric mobilization. (Modified from Tsai WS, Levy RM, Luketich JD. Technique of minimally invasive Ivor Lewis esophagectomy. *Op Techn Thorac Cardiovasc Surg.* 2009;14:176–192. Copyright 2009, with permission from Elsevier.)

then mobilized by first dividing the short gastric vessels, followed by division of the gastrocolic omentum while carefully preserving the right gastroepiploic arcade (see Fig. 19-4). We utilize either the ultrasonic shears such as Autosonix (Covidien, Mansfield, MA) or the LigaSure device (Valleylab, Boulder, CO). Occasionally, clips will be required during division of large-diameter, short gastric vessels. Recently, on the basis of published data<sup>42</sup> and personal communication (Dr Earl Wilkins), we have selectively utilized an omental pedicle wrap of the intrathoracic esophagogastric anastomosis. At this point in the operation, we mobilize a long, narrow tongue of omentum from the middle to upper third of the greater curvature. We attempt to base this omental pedicle off of two feeding vessels to ensure viability (Fig. 19-5). After the gastrocolic omentum is identified, the antrum of the stomach is retracted and a window is created in the greater omentum, thus allowing access to the lesser sac. Dissection is carried along the greater curve of the stomach until the end of the gastroepiploic arcade is reached. During this mobilization, it is important to be constantly mindful of the location of the right gastroepiploic vessel.

5. The mobilized stomach is retracted superiorly, and any remaining adhesions between the posterior wall of the stomach and the pancreas are divided as well. The left gastric vessels are then identified, dissected, and



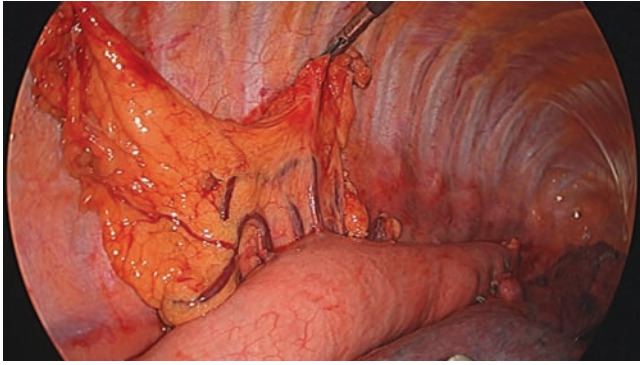


FIGURE 19-5 Creation of omental pedicle flap.

divided with a vascular load of the stapler. This is done by approaching the pedicle from the lesser curve. Prior to division, a complete celiac lymph node dissection is performed, continuing along the superior border of the splenic artery and pancreas toward the splenic hilum. Adherence to oncologic principles is important at this step, so the pedicle should be dissected completely clean with all celiac and left gastric nodes swept up into the specimen.

6. Attention is then turned to mobilization of the pyloric antral area and subsequent pyloroplasty (Fig. 19-6).

There are often significant adhesions in the retroantral and periduodenal regions that also need to be dissected to allow for adequate mobilization of the inferior portion of the stomach. Particular attention to mobilization of the pyloric antral area is needed in patients who have had prior cholecystectomy. Adequate mobilization is evident when the pylorus can be gently lifted up to the level of the right crus in a tension-free manner. This may require a partial or complete Kocher maneuver. Two traction sutures are placed at the edges of the pylorus with the 2-0 Endo Stitch (US Surgical, Norwalk, CT). The pyloroplasty is performed by incising the pylorus longitudinally with the ultrasonic shears and closing it transversely with interrupted sutures using the Endo Stitch device in a Heineke-Mikulicz fashion. This usually requires four to five sutures. Prior to completing the abdominal portion of the procedure, a tongue of omentum is mobilized to fashion an omental patch that is sutured to the pyloroplasty site.

7. Creation of the gastric tube. All tubes previously in the stomach or esophagus are pulled back. A 4- to 5-cm-diameter gastric conduit is then constructed using multiple fires of the stapler (4.8 mm) beginning from the lesser curve antral area, just proximal to the pylorus and heading toward the angle of His (Figs. 19-7 and 19-8). It is essential to avoid excessive manipulation and resulting trauma to the gastric conduit during all steps. To facilitate exposure, staple alignment, and conduit

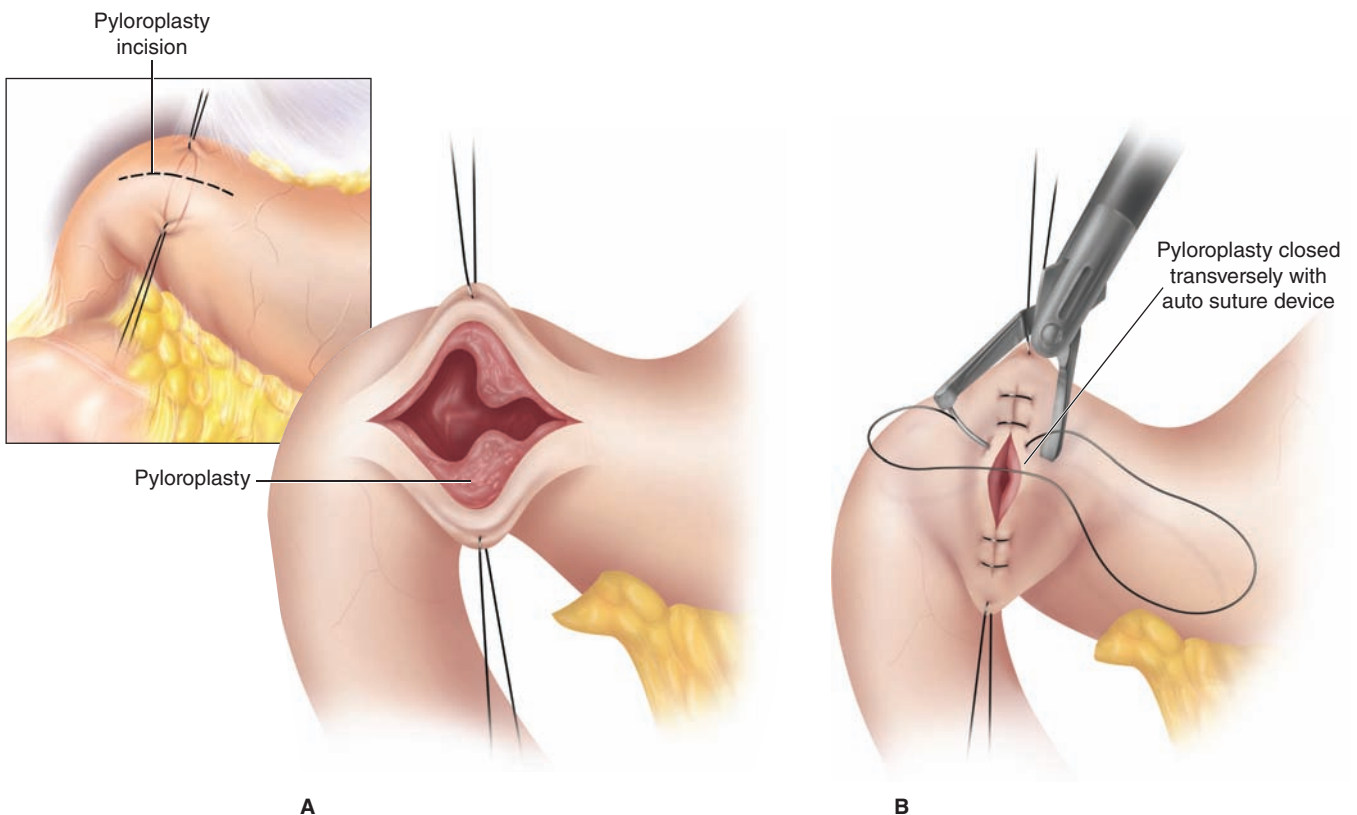


FIGURE 19-6 Creation of the laparoscopic pyloroplasty.

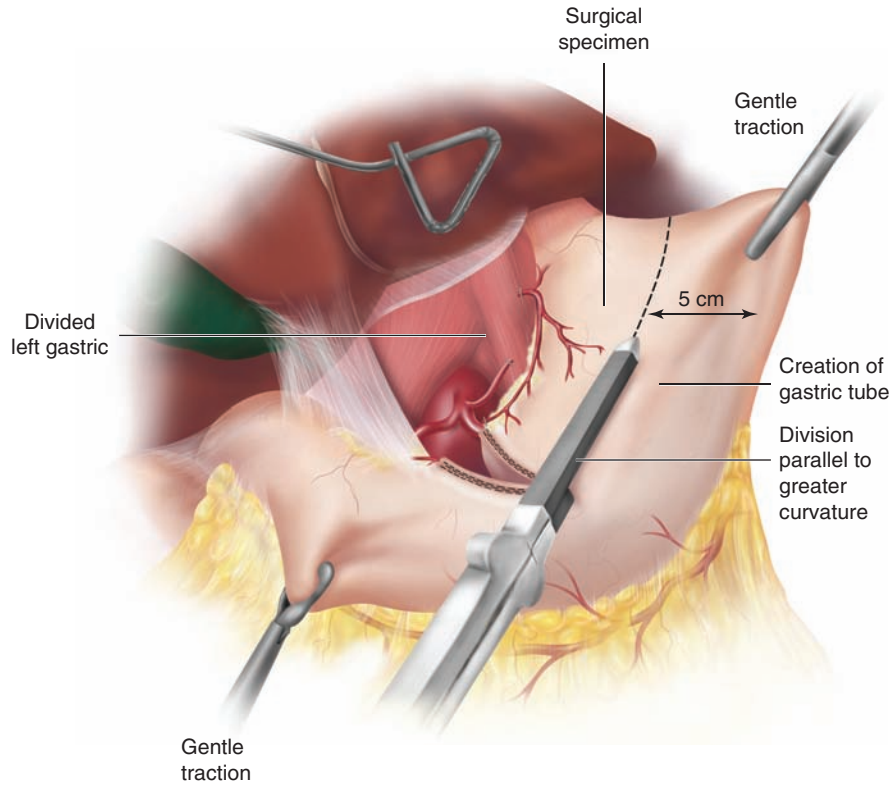


FIGURE 19-7 A vascular stapler is fired across the lesser curvature near the incisura to begin formation of the gastric tube.

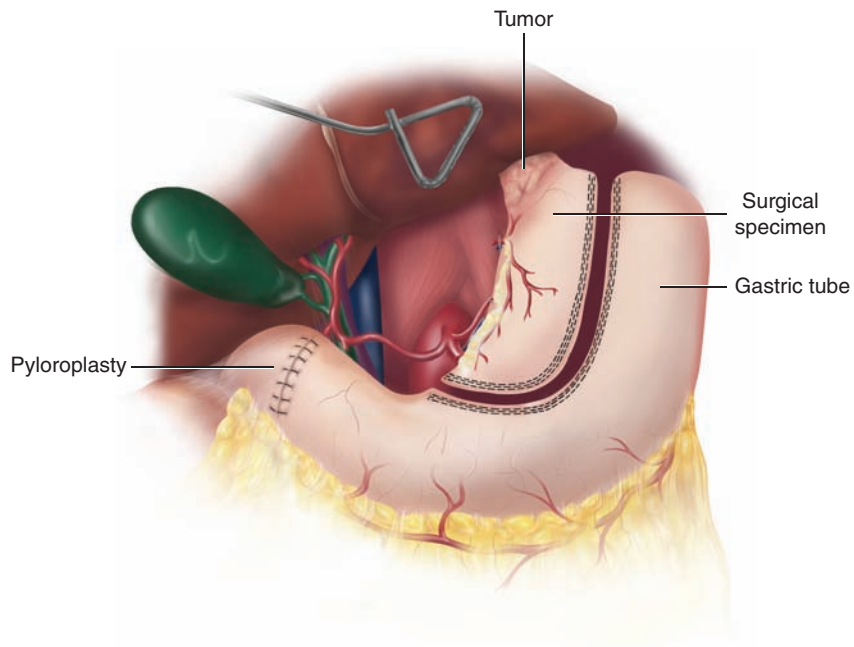


FIGURE 19-8 Completion of gastric tube construction.

length during this step, we have found it helpful to have the assistant gently lift the greater curve of the stomach, along the line of the proximal short gastric arteries and retract gently toward the spleen. Simultaneously, another assistant grasps the antrum and retracts inferiorly. This is accomplished through an additional 12-mm port placed in the right lower quadrant to assist with the creation of the gastric tube. This essentially elongates the entire stomach and provides the alignment necessary to construct a consistent diameter gastric conduit without spiraling. The first stapler used for this is a vascular load to control bleeding from the adipose tissue and vessels along the lesser curve. The stapler is placed just up to, but not onto, the gastric antrum as this tends to be thicker tissue. The initial 12-mm right midclavicular port is changed to a 15-mm port to allow for the placement of a 4.8-mm Endo GIA stapler. Creation of the gastric tube is then started by dividing the stomach at the lower end of the lesser curve near the incisura using a vascular load (2.5-mm) stapler, with care being taken to preserve the main right gastric vessels and one or two of the first branches entering the antral area. The stomach is first divided across the antrum with 4.8-mm staple loads. Because this region of the stomach is generally quite thick and muscular, larger staples are required to secure its closure. Early in our experience, we discovered that very narrow gastric conduits (2–3 cm in diameter) were associated with increased gastric tip necrosis and anastomotic leaks, and therefore we now construct wider conduits measuring about 4–5 cm in diameter. Once the thicker antrum has been divided, the operating port is changed back to an 11-mm port and the fundus is divided using a 3.5-mm stapler. As the fundus is divided, the graspers are readjusted to keep the stomach constantly stretched. If

there is extension of tumor onto the gastric cardia, a wider margin is left in this region.

8. Feeding jejunostomy. Under direct vision, a jejunostomy catheter (10F) is then placed using the Seldinger technique as depicted in Fig. 19-9. The patient is placed in the Trendelenburg position with the transverse colon and greater omentum retracted cranially. The 12-mm, previously placed, right lower quadrant port is used as the operating port while the right upper quadrant epigastric port is used for the camera to facilitate this maneuver. The ligament of Treitz is identified, and approximately 30 cm distal to this point, a suitable limb of proximal jejunum is tacked to the lateral, anterior abdominal wall in the left midquadrant with a single 2-0 Endo Stitch. Under direct visualization, a jejunostomy catheter (Compat Biosystems, Minneapolis, MN) is then placed, with intraluminal position confirmed by distending the jejunum with 10 mL of air insufflated via the catheter. The jejunum is then securely tacked to the abdominal wall at the catheter entry site with a purse-string type circumferential tacking stitch using a 2-0 Surgidac Endo Stitch. A second simple 2-0 Surgidac Endo Stitch is placed 3 cm distal to the catheter insertion site so as to prevent torsion and possible strangulation around a single fixed point (see Fig. 19-9).
9. The tip of the gastric conduit is then secured to the specimen with 2-0 Endo Stitch (Fig 19-10). During this step, care is taken to maintain alignment so that subsequent retrieval of the specimen through the hiatus into the chest does not lead to any rotation and maintains perfect anatomic alignment of the gastric conduit with the short gastrics facing the direction of the spleen and the lesser curve staple line facing the right chest. With our recent use of omental pedicles, we have also started tacking the omental pedicle wrap to the proximal end of the conduit so as to

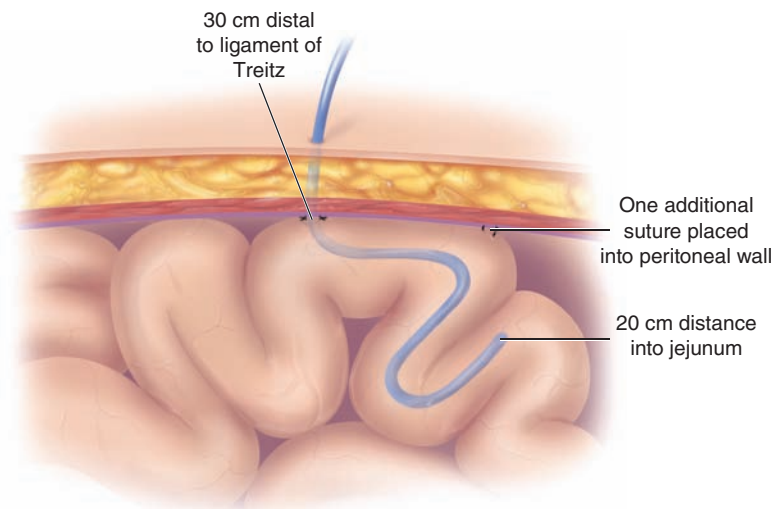


FIGURE 19-9 Feeding jejunostomy.



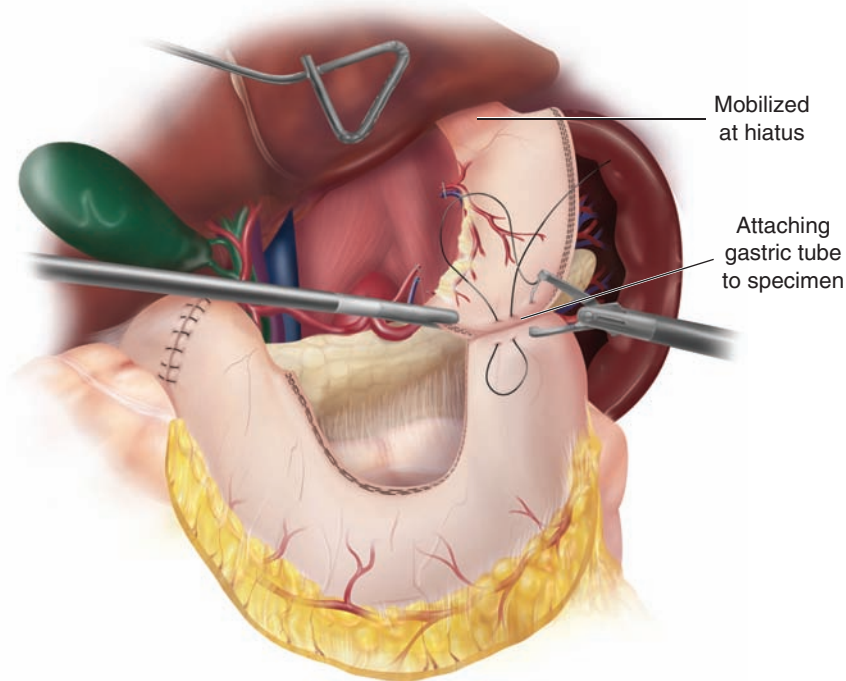


FIGURE 19-10 Completion of laparoscopic phase of minimally invasive Ivor Lewis esophagectomy.

facilitate bringing it through the hiatus without trauma to the omentum or the supplying vasculature.

10. If the hiatus appears wide, we add one or two 0 Surgidac sutures (Covidien, Mansfield, MA) to approximate the right and left crus to minimize the likelihood of a delayed herniation of the conduit into the chest. The pyloroplasty site is covered with an omental patch as described previously. The initial Hasson trocar site is closed with the Carter-Thompson suture passer with 0 Vicryl suture, the abdomen is desufflated, and the skin incisions are closed accordingly.

### THORACOSCOPIC PHASE

1. The patient is placed in the left lateral decubitus position. The operating surgeon stands on the right side of the table (facing the patient's back) and the assistant on the left side of the table.
2. Five thoracoscopic ports are used (see Fig. 19-2; Fig. 19-11). A 10-mm camera port is placed in the seventh or eighth intercostal space, just anterior to the midaxillary line. The surgeon's working port is a 10-mm port that is placed at the eighth or ninth intercostal space, posterior to the posterior axillary line. Ultimately, this eighth posterior interspace port will be enlarged to 5 cm to enable passage of the end-to-end stapler (EEA, US Surgical, Norwalk, CT) and removal of the specimen. Another 10-mm port is placed in the anterior

axillary line at the fourth intercostal space, through which a fan-shaped retractor aids in retracting the lung to expose the esophagus. A 5-mm port is placed just inferior to the tip of the scapula, and this is used by the surgeon's left hand for countertraction. A final port is placed at the sixth rib, at the anterior axillary line for suction, and is especially useful while fashioning the anastomosis.

3. An important initial step to aid in exposure is placement of a traction suture (0-Silk) through the central tendon of the diaphragm (Fig. 19-12), which is brought out through a 2-mm stab incision in the antero-lateral chest wall near the costophrenic angle using an Endo Close

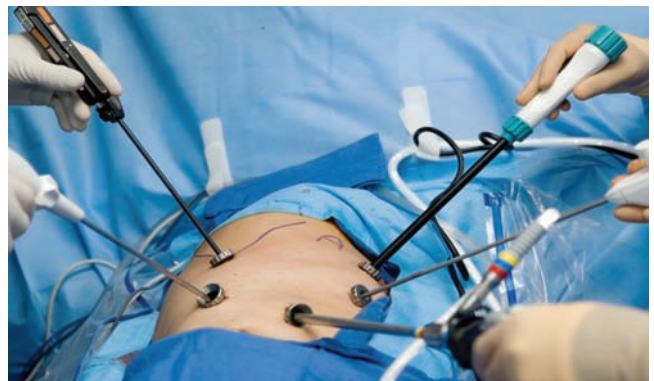

FIGURE 19-11 Thoracoscopic (right VATS) port placement.

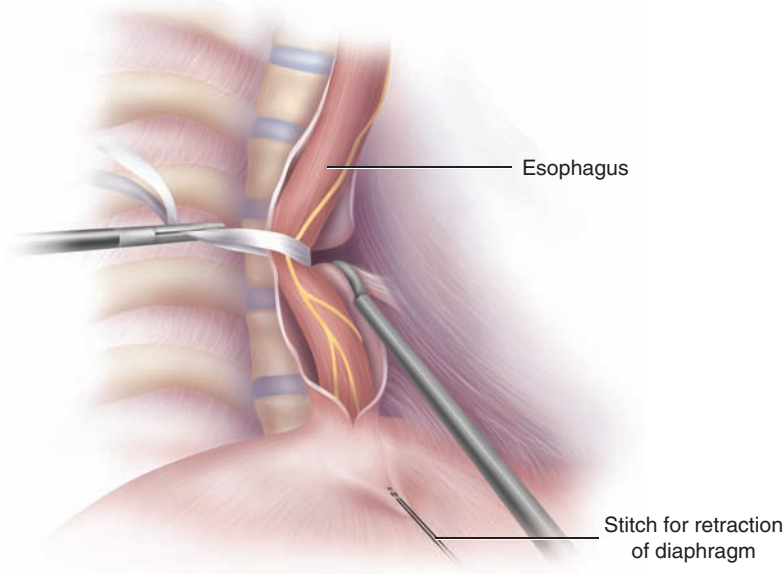


FIGURE 19-12 Thoracoscopic mobilization of esophagus.

device (Covidien, Mansfield, MA). This suture retracts the diaphragm inferiorly and allows excellent visualization of the lower one-third of the esophagus.

4. Thoracic esophageal mobilization (see Fig. 19-12). Mobilization of the esophagus is begun by dividing the inferior pulmonary ligament to the level of the inferior pulmonary vein and retracting the lung anterior. This facilitates incision of the mediastinal pleura over the esophagus. Dissection moves in a cranial direction from this point along the line of the mediastinal pleura. It should be noted that the dissection should be carried down to the pericardium as it is actually the medial boundary of the line of dissection. The deep boundary is the contralateral pleura. The esophagus and accompanying periesophageal tissue and level 7 lymph nodes are mobilized circumferentially en bloc toward the right mainstem bronchus and carina. Care is taken not to injure the posterior membranous wall of the right mainstem bronchus in this area. We use the ultrasonic shears for much of the dissection, as the sharp blade of this instrument is ideal for a precise dissection plane. Endoscopic clips are utilized for hemostasis on larger vessels. Because of the extensive lymphatics in this area and fragile vessels attached to the subcarinal nodes, careful use of endoclips also aids in minimizing oozing of chyle and blood. Lateral dissection is facilitated by opening the mediastinal pleura in the groove posterior to the esophagus. This should be done in a superficial dissection plane so as to avoid injury to the aorta and the thoracic duct. The azygous vein is mobilized and divided as it overlies the esophagus posteriorly with a vascular staple load. The vagus nerve is transected above the

level of the divided azygous vein to prevent any traction injuries to the recurrent nerve during the mobilization of the esophagus. The esophagus is then mobilized circumferentially from the hiatus to near the thoracic inlet, the ultimate cephalad extent depending on the proximal extent of the tumor and/or Barrett's esophagus and the length and condition of the gastric conduit. Above the azygous vein, the plane of dissection should stay directly on the esophagus so as to prevent injury to the posterior membranous trachea and recurrent laryngeal nerve. We do not perform an aggressive lymph node dissection at level 2 or level 4 unless preoperative PET, CT, or EUS confirmed presence of malignant nodes at this level.

5. The distal esophagus and previously constructed gastric conduit are then brought up through the hiatus into the chest (Fig. 19-13). Maintaining proper orientation of the gastric conduit is critical to avoid spiraling or twisting of the conduit. The staple line should face the camera so as to avoid spiraling of the conduit. The stitch is cut between the specimen and the conduit, and the specimen are retracted anteriorly and superiorly. We carefully estimate the amount of conduit that will lie in the chest. It is a common mistake to bring an excess amount of stomach into the chest in an effort to minimize tension on the anastomosis. This excess conduit will often assume a sigmoid conformation above the diaphragm and may lead to significant problems with gastric emptying.
6. The proximal esophagus is then transected above the azygous vein with Endo Shears (Covidien, Mansfield, MA). Again, the precise location of this division and ultimate location of the anastomosis tends to be high, near the thoracic inlet. However, cutting the esophagus too proximal

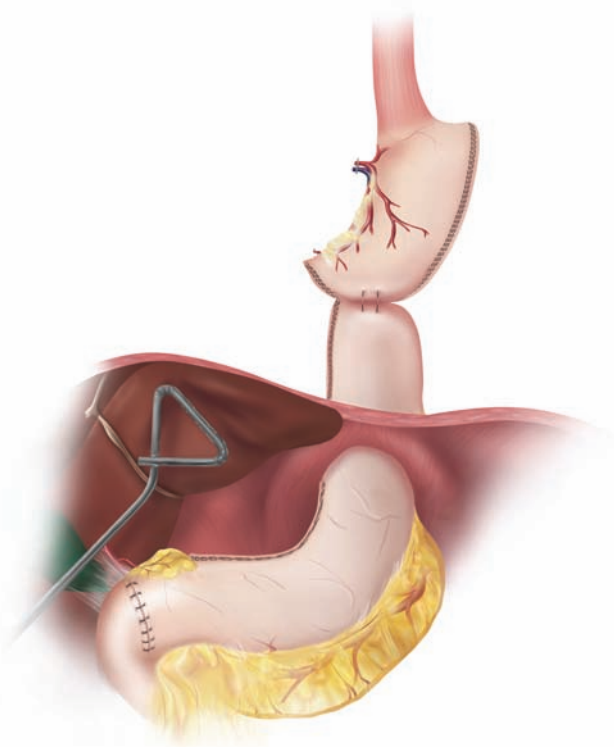


FIGURE 19-13 Specimen and gastric tube are carefully pulled to intrathoracic position.

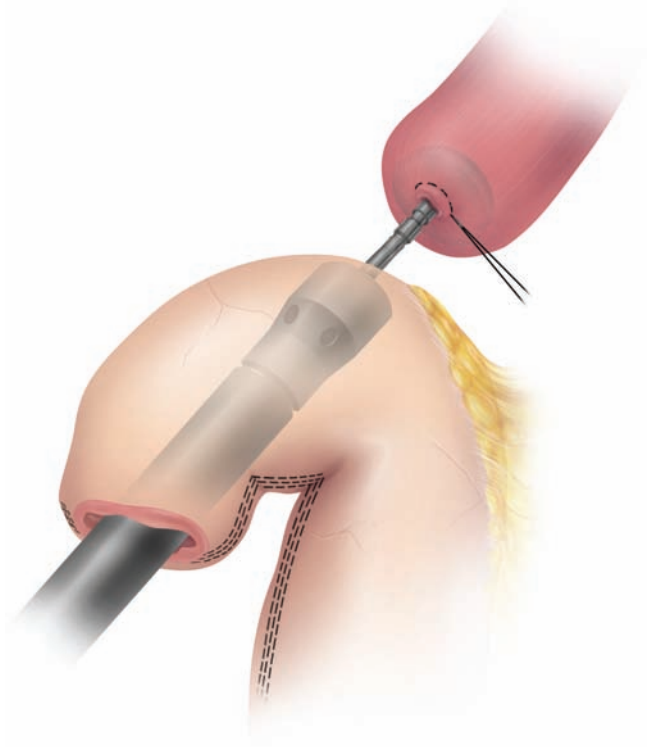


FIGURE 19-14 Creation of intrathoracic esophago-gastric anastomosis.

may make the anastomosis technically difficult and should be avoided. In the case of concern over tumor margin, we may rescope at this point to precisely determine where to transect the esophagus.

7. The eighth interspace port site is enlarged, and an Alexis wound protector (Applied Medical, Rancho Santa Margarita, CA) is placed for specimen removal after cutting the previously placed sutures that secured the conduit to the specimen. The specimen is then sent for frozen-section analysis of the esophageal and gastric margins.
8. Creation of intrathoracic esophago-gastric anastomosis (Figs. 19-14 and 19-15). The anvil of a 28-mm EEA stapler is placed in the proximal esophagus, and a 2-0 Endo Stitch purse-string suture is placed and tied (intracorporeal technique) to secure the anvil in position. It is technically challenging to make this first stitch perfect as the anvil has a tendency to migrate out of the open end of the proximal esophagus. For this reason, a second purse-string suture is placed to further secure the anvil and pull in any mucosal defects, thereby ensuring complete rings following EEA firing. Ultrasonic shears are used to open up the tip of the gastric conduit along the staple line. The EEA stapler is then introduced through the eighth interspace incision into the tip of the gastric conduit via the gastrotomy at the apex of the conduit. This is technically challenging for most trainees, and care must be taken to angle the gastric tube facing straight up to accept the tip of the EEA device aimed

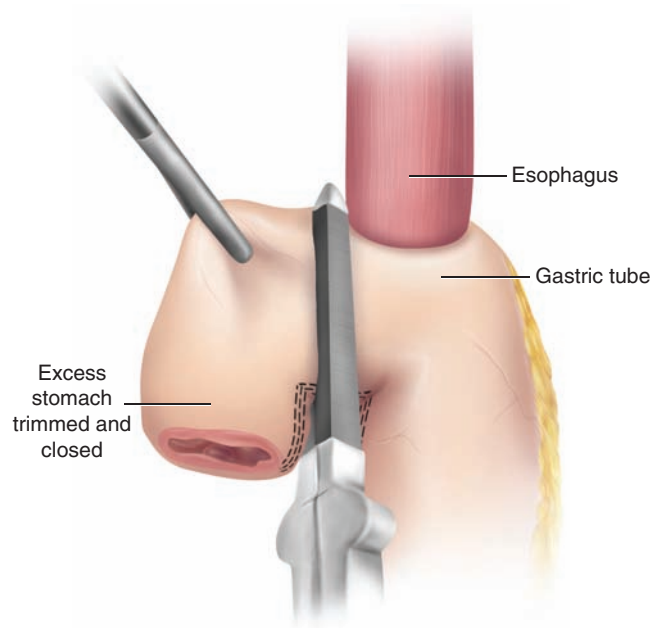


FIGURE 19-15 Resection of redundant gastric tube tip.



straight down, much the same way one angles the tip of your foot as you pull on your sock. The anvil is then docked into the stapler. A circular anastomosis is then created in an end- (proximal esophagus) to-side (gastric conduit) fashion above the level of the azygous vein. A reticulating Endo GIA stapler is used to close the gastrotomy closure and excise the redundant portion of the gastric conduit tip. Routine endoscopy is *not* performed.

9. As previously mentioned, we have recently starting selectively wrapping a tongue of omentum mobilized from the greater curve of the stomach around the anastomosis, securing in place with 2-0 Surgidac Endo Stitch at several points (Fig. 19-16). It is important to ensure that the conduit is not twisted in the process of wrapping the omentum around the anastomosis.
10. Under direct vision, a nasogastric tube is advanced beyond the anastomosis to just above the hiatus. The chest is drained with a 28F chest tube placed posteriorly but not on the anastomosis, and a number 10 Jackson Pratt drain placed directly posterior to the anastomosis, behind the gastric conduit, down to the diaphragmatic hiatus, across the dome of the diaphragm, and out through a small stab incision near the costophrenic angle. To prevent herniation, the conduit is tacked to the right crus with one or two interrupted 2-0 Endo Stitches.

## Outcomes and Complications Following MIE

In 2003, we published our series of 222 consecutive patients who had undergone McKeown or “three-hole” (laparoscopic-thoracoscopic with cervical anastomosis) MIE at the University of Pittsburgh.<sup>11</sup> To this date, the approximately half of our MIEs (>500 cases) was performed with this three-field technique. Indeed, the procedure was the mainstay of our initial experience in the first 10 years with reduced perioperative morbidity and mortality compared with many other open series. Although early in the series we selectively performed MIE on patients with smaller tumors and no previous therapy, 35% of the patients in the overall series had been treated with chemotherapy and 16% with radiation. In addition, 25% of patients had undergone prior open abdominal surgery.

MIE was completed as planned in 206 patients (93%). There were no emergent conversions to an open procedure. Of the 16 cases who required nonemergent conversion, 11 required a minithoracotomy for adhesions and, in one case, oversewing of an intercostal vessel that could not be controlled by VATS.

There were three deaths in the series (mortality 1.4%). These deaths were from postoperative pneumonia and multisystem organ failure in one patient, a myocardial infarction on postoperative day 5 in another, and pericardial tamponade that developed 3 days after MIE in the third patient. None of these deaths were in patients who developed an anastomotic leak or gastric tube necrosis. Presumably, traction injury to the

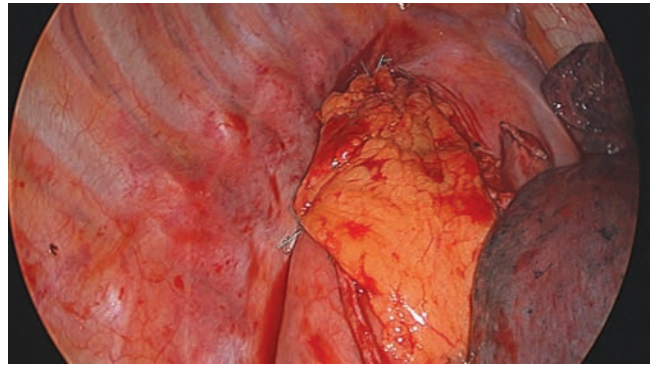


FIGURE 19-16 Completed anastomosis with omental pedicle wrap.

pericardium during VATS was the mechanism for the development of postoperative tamponade in the third patient.<sup>43</sup> This very low mortality rate compares favorably with the largest series of open esophagectomy (Table 19-1).

The rate of anastomotic leak in this series was 11.7%. In our experience, this complication was frequently related to the diameter of the gastric tube. The leak rate associated with a 3-cm-diameter tube was 26% in 56 consecutive patients. In the latter half of the series, those patients who underwent creation of a larger diameter conduit had the leak rate of only 6%. Thus, there is invariably an operator learning curve.

Injury to the recurrent laryngeal nerve is a complication associated with significant morbidity. Mechanisms related to this complication include excessive traction on the nerve during the neck dissection or injury during dissection of the upper one-third of the esophagus. In our series, vocal cord palsy occurred in 3.6% of patients. This is lower than our open experience and is in part due to enhanced visualization of the upper thoracic esophagus during VATS. We believe early division of the vagus nerve and limiting lymph node dissection above the azygous vein are important technical details that contribute to lower rates of injury to the nerve in this area. However, as previously mentioned, in addition to recurrent nerve injury, a significant number of patients experience pharyngoesophageal swallowing dysfunction after cervical anastomosis. These are among the concerns that prompted our recent switch to a totally minimally invasive Ivor Lewis approach in the last several years.

Other complications seen after MIE, as well as open esophagectomy, include chylothorax, delayed gastric emptying, and airway injuries. All of these complications are potentially related to surgical technique. Inadequate control of small ductules that branch off of the thoracic duct or a gross tear of the main duct is typically the cause of a chylothorax. Seven patients (3%) developed this complication early in our series. Following this early experience, we have liberally applied clips to even small branches emanating from the thoracic duct along the right esophageal border during VATS, and this complication has fallen to less than 1%. Delayed gastric emptying is reported to occur in up to 10% of patients following esophagectomy. This


**TABLE 19-1: MORTALITY AND MORBIDITY FOLLOWING MIE COMPARED TO OPEN ESOPHAGECTOMY**

	Pittsburgh n = 222 (%)	Michigan n = 1085 (%)	VA n = 1777 (%)	Sloan-Kettering n = 510 (%)	Duke n = 379 (%)
Mortality	1.4	4	9.8	4	5.8
Anastomotic leak	11.7	13	NR	21	14
Pneumonia	7.7	2	21.4	21	16
Vocal cord palsy	3.6	7	NR	4	NR
Gastric tube necrosis	3.2	0.83	NR	1	NR
Chylothorax	3.2	1.7	0.02	2.4	NR
Myocardial infarct	1.8	NR	1.2	NR	NR
Delayed gastric emptying	1.8	NR	NR	NR	NR
Tracheal tear	0.9	0.4	NR	NR	NR
Renal failure	0.9	NR	2.1	NR	NR
Splenectomy	0	3.1	NR	NR	NR
Delayed (>30 days) diaphragmatic hernia	1.8	NR	NR	1.2	NR

NR, not reported.

Reprinted from Schuchert MJ, Luketich JD, Fernando HC. Complications of minimally invasive esophagectomy. *Semin Thorac Cardiovasc Surg.* 2004;16:133–141. Copyright 2004, with permission from Elsevier.

may be due to a number of factors, including the vagotomy itself, the creation of a full-size gastric conduit that may empty poorly compared to a tubularized conduit, incomplete pyloromyotomy or pyloroplasty, spiraling of the gastric tube, excess stomach above the diaphragm leading to a sigmoid loop effect, and an inadequate crural opening. In our series, only 2% of patients developed delayed gastric emptying after MIE. The creation of a pyloroplasty rather than a pyloromyotomy and attention to all of the details listed previously have contributed to this low complication rate.

Fortunately, significant airway injuries in our experience have been exceedingly rare, occurring in only two patients. One of these injuries occurred postoperatively during reintubation for respiratory distress and one was believed to result from injury to the posterior membranous trachea from unintentional contact of the autasonic shears. In other series, tracheal injury has been associated with the resection of bulky, midthoracic tumors. This is usually either due to traction or cautery injury during esophageal mobilization. In these cases of bulky tumors, we would therefore recommend a thoracotomy, particularly if the patient has received neoadjuvant radiation.

With a median follow-up of 19 months, overall survival was similar to that after open esophagectomy. Of importance in assessing outcomes is not only overall survival but also the quality of life following esophagectomy. We have documented this by administering a validated quality-of-life instrument (Short Form-36 [SF-36]) and a disease-specific questionnaire (the Gastroesophageal Reflux Disease Health-Related Quality of Life [GERD-HR-QOL] index<sup>44</sup>) to patients before and after MIE. The GERD-HR-QOL instrument noted that dysphagia

and heartburn scores following esophagectomy were excellent, and that only 4% of patients had severe, poorly controlled reflux. In addition, the overall quality of life as measured by the SF-36 was no different than that of age-matched controls.

In our experience, perhaps the most significant technical concern with the minimally invasive McKeown approach is the cervical dissection. Recurrent laryngeal nerve injuries, perturbations in pharyngeal transit, and swallowing dysfunction even in the absence of recurrent nerve injury are not infrequent. Moreover, as described in open series using a cervical anastomosis, anastomotic stricture and leak have been shown to occur with increased frequency.<sup>45</sup> Out of these concerns emerged our more recent experience with completely thoracoscopic-laparoscopic Ivor Lewis esophagectomy. However, we did first evolve through a transition phase whereby a minithoracotomy (hybrid approach) was performed for creation of the intrathoracic anastomosis.

Outside of case reports, there are currently few series reporting experience with laparoscopic-thoracoscopic Ivor Lewis esophagectomy.<sup>46,47</sup> Kunisaki et al described a small series of laparoscopic-thoracoscopic Ivor Lewis esophagectomies (n = 15), but the anastomotic leak rate was somewhat high (13.3%) and length of stay was prolonged (30 days).<sup>48</sup> We recently reported the largest series of minimally invasive Ivor Lewis esophagectomies (n = 50) published to date.<sup>49</sup> Of these, the first 35 included hybrid approach with a planned minithoracotomy. The last 15 patients in this series were performed with a completely laparoscopic-thoracoscopic method without need for minithoracotomy. The median length of stay was 9 days for the entire group, with the completely minimally invasive group having a significantly shorter hospitalization (7 vs 9 days). The median ICU stay was 1 day for both groups.

The anastomotic leak rate was 6%. All pneumonias (10%) occurred in the hybrid minithoracotomy group. Importantly, there were no recurrent nerve injuries.

We believe that the experience with totally thoracoscopic-laparoscopic Ivor Lewis esophagectomy will ultimately reproduce the low morbidity and mortality we have previously published with our established MIE technique. The omission of a cervical dissection has reduced our recurrent nerve injury rate to near zero. From a theoretical standpoint, one would presume that pharyngeal transit problems and oropharyngeal swallowing dysfunction should be reduced as well with a chest anastomosis. It should be emphasized that there is a steep operator learning curve associated with this approach. Both blood and lung can obscure visualization of the esophagus, which lies at the dependent aspect of the operative field. Prone positioning has been described as an alternative approach that may facilitate operative exposure and address such technical concerns.<sup>50</sup>

## BENIGN ESOPHAGEAL DISEASE

### Resection of Esophageal Leiomyoma

Leiomyomas represent the most common benign tumor of the esophagus, accounting for approximately two-thirds of all cases.<sup>51</sup> These tumors occur in the middle (33%) and lower (56%) esophagus, a distribution that parallels the degree of smooth muscle in the esophageal wall.<sup>51</sup> Consequently, leiomyoma are rarely found in the cervical esophagus, which is composed predominantly of skeletal muscle. The majority of these tumors arise from the muscularis propria and extend into the lumen of the esophagus. On occasion, however, they may arise from the muscularis mucosa, in which case they tend to pedunculate because of peristalsis.<sup>52</sup>

Over 85% of patients with small leiomyoma are asymptomatic. When present, symptoms are often nonspecific, such as chest pain, regurgitation, and dysphagia. On rare occasion, these tumors may ulcerate and present with gastrointestinal bleeding. Interestingly, there does not appear to be a clear correlation between the size of the tumor and either the frequency or severity of symptoms.<sup>53,54</sup>

The natural history of these uncommon tumors is not well understood, and therefore the guidelines for resection of asymptomatic tumors are unclear. Certainly, resection of either symptomatic tumors or those in which a malignant histology is suspected is appropriate. In most series, the criterion for resection of asymptomatic lesions has been a size greater than 3–5 cm. However, it has been well-documented that the size of these tumors can remain stable over several years.<sup>55</sup> Furthermore, unlike smooth muscle tumors of the stomach, the propensity of these tumors to degenerate into leiomyosarcoma is extremely rare, and in fact only two cases have ever been documented.<sup>56,57</sup> What is clear is that the decision to recommend surgery will depend on the morbidity associated with the procedure.

### Technique of Resection

The approach to resection depends on the location of the tumor. Including our own experience, in most published series, benign esophageal tumors (ie, leiomyoma) of the thoracic esophagus are approached through a right VATS or right thoracotomy, whereas a laparoscopic transhiatal approach is employed for most distal tumors at or near the GE junction.<sup>58–60</sup> Although there are published case series that report resection of GE junction leiomyoma with left-sided thoracoscopy,<sup>61</sup> we are not in favor of this approach. Similarly, although a distal intrathoracic, benign esophageal tumor could be enucleated through a laparoscopic transhiatal approach, we believe the best exposure is achieved through the right chest. Our preference is to resect tumors through a minimally invasive approach, reserving thoracotomy or laparotomy for tumors larger than 7 cm. For the purposes of this chapter, we focus on the right VATS approach.

1. The patient is intubated with a double-lumen endotracheal tube for single-lung ventilation.
2. Esophagoscopy is performed prior to draping to confirm location of the tumor. The scope is frequently left in place to assist the surgeon in determining where to begin the myotomy. In some cases, a 54F bougie may be left in place to facilitate dissection and accentuate tumor location.
3. The patient is positioned in the left lateral decubitus position. The surgeon stands at the patient's back.
4. The thoracoscopic ports are essentially the same as those used for MIE as depicted in Fig. 19-2.
5. Exposure of the tumor is obtained by placing the diaphragm stitch, as previously described, above for tumors in the distal thoracic esophagus. Removal of benign midesophageal lesions does not always require this maneuver. Subsequently, the inferior pulmonary ligament is divided with the ultrasonic shears. The mediastinal pleura overlying the esophagus is opened sharply. Care must be exercised at this point to preserve the vagus nerve trunk and its branches. The esophagus may need to be dissected circumferentially for exposure, particularly if the tumor appears to arise from the left side of the esophagus. A Penrose drain can be placed around the esophagus and manipulated to help expose left-sided tumors (Fig. 19-17).
6. A myotomy is performed on the esophageal wall overlying the tumor (Fig. 19-18). The longitudinal muscular layer is then opened sharply and the leiomyoma is exposed. The vagal trunks should be identified and preserved during this maneuver. Because of the firm, rubbery nature of the tumor, it is often difficult to grasp and we frequently place a stitch into the tumor for traction. The plane between the tumor, muscularis propria, and submucosa is developed.
7. The tumor is then enucleated with the ultrasonic dissector, hook electrocautery, and the Endo Peanut (Covidien, Mansfield, MA).



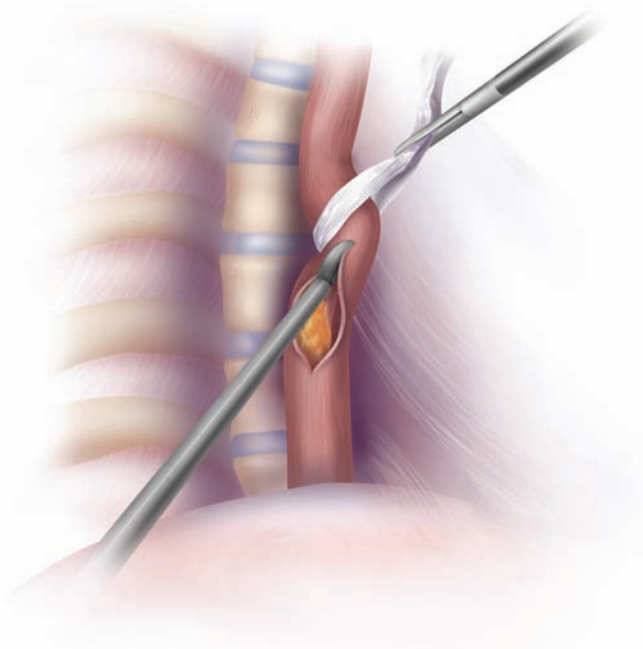


FIGURE 19-17 Resection of an esophageal leiomyoma is facilitated by use of a Penrose drain.

8. The tumor is removed with an endoscopic specimen bag.
9. After the tumor is removed, the esophagus is submerged under water and insufflated with air from the esophagoscope to determine mucosal integrity.
10. The myotomy is then closed using interrupted 2-0 Surgidac Endo Stitch (Fig. 19-19). Although not all surgeons feel

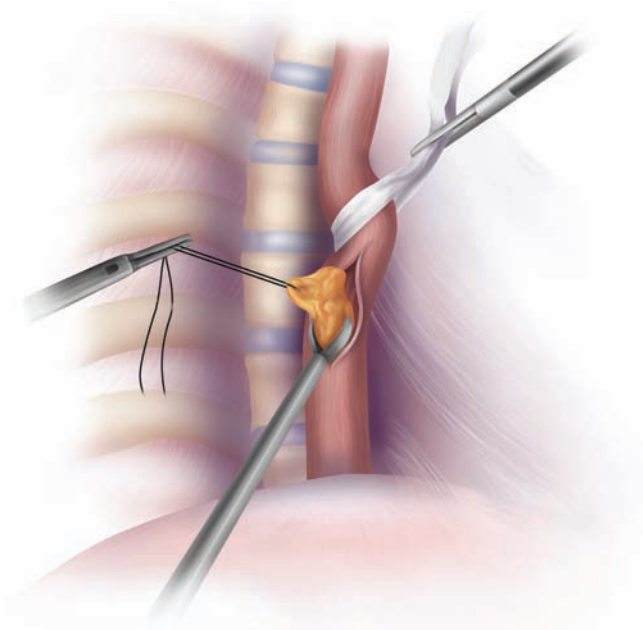


FIGURE 19-18 Thoracoscopic myotomy.

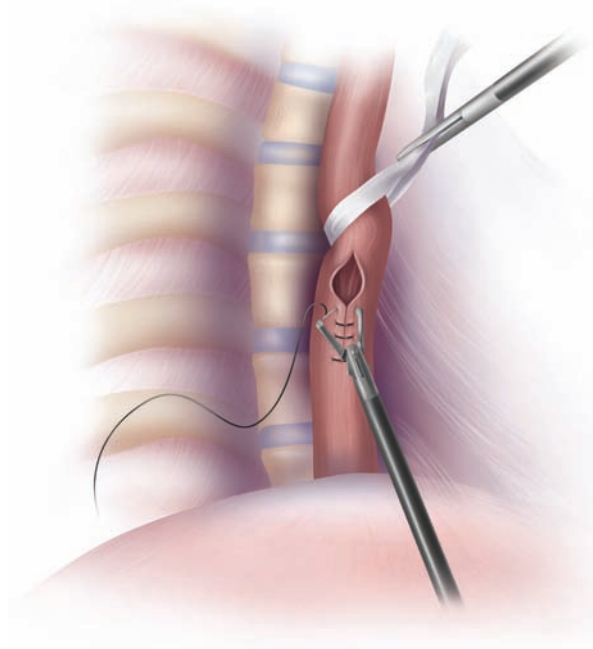


FIGURE 19-19 Closure of myotomy.

that this step is necessary,<sup>62</sup> several studies have documented the occurrence of postoperative dysphagia due to the formation of a mucosal pseudodiverticulum at the myotomy site. In these cases, symptoms resolved after approximation of the myotomy.

### Outcomes of Minimally Invasive Thoracoscopic Resection for Leiomyoma

Between 1990 and 2005, we resected 15 patients with esophageal leiomyoma.<sup>63</sup> In this series, the tumor location was midesophageal in eight patients and distal third of the esophagus in six patients. All the patients with a tumor less than 7 cm in the thoracic esophagus were approached with a right VATS. Four patients with midesophageal tumors went on to require an additional antireflux procedure for either new-onset or worsening reflux. Among all patients, there were no perioperative complications and the median hospital stay was 2.3 days. One patient was noted to have a mucosal injury at time of surgery; this was repaired using an endo-GIA stapler over a bougie without complication. The mean tumor size was 2.7 cm; however, we have safely resected tumors up to 8 cm in size using minimally invasive techniques. Larger tumors do pose a greater technical challenge. As such, we recommend reserving thoracoscopic resection for tumors less than 7 cm. On the basis of this limited data set, the size of the tumor does not correlate with the development of postoperative reflux. Patients require close follow-up because of the potential for delayed postoperative reflux.

## Treatment of Achalasia

The introduction of minimally invasive techniques has revolutionized the treatment paradigm of patients with achalasia. The long-term benefits of surgery over medical management have been clearly documented for many years.<sup>64,65</sup> However, in the past, patients were often not referred for surgery because of the morbidity of the thoracotomy necessary for an esophagomyotomy. The advent of minimally invasive techniques has led to a resurgence in surgery as the primary treatment modality for this disease.<sup>4</sup>

Most surgeons experienced in the treatment of achalasia have adopted laparoscopy as their preferred approach (refer to Chap. 14). Indeed in our own series of minimally invasive esophagomyotomy, 92% of patients underwent laparoscopy as opposed to thoracoscopy.<sup>66,67</sup> Similarly, the initial group to describe VATS myotomy has now come to favor laparoscopy.<sup>68</sup> However, there are reasons to consider thoracoscopy as an acceptable alternative. During thoracoscopy, the distal esophagus and GE junction are visualized without the necessity of dividing the phrenoesophageal ligament. Proponents of thoracoscopy claim, consequently, that the preservation of this ligament will prevent postoperative reflux and obviate the need for an antireflux procedure, which is usually added after a laparoscopic esophagomyotomy.<sup>69</sup>

However, there are some inherent disadvantages to thoracoscopic myotomy. First, anesthesia is complicated by the need for single-lung ventilation. In addition, thoracoscopy is more uncomfortable for the patient, particularly because a “minithoracotomy” access incision<sup>70,71</sup> and a chest tube are often required for the procedure. More important is the concern that the myotomy may be incomplete when performed thoracoscopically. Critics of the operation cite the difficulty of working in a plane perpendicular to the esophagus and extending the myotomy adequately onto the stomach when working through the chest.<sup>72</sup> Additionally, the addition of a partial fundoplication to myotomy for the treatment of achalasia has become standard practice and is readily performed and with reproducible results using laparoscopy.

Overall, thoracoscopic myotomy has been shown to provide symptomatic improvement in 76% of patients with achalasia. These results do not compare favorably to laparoscopy, in which 94% of the nearly 500 patients reported in the literature have had relief of their dysphagia.<sup>72</sup> In addition, a 35% rate of postoperative reflux is associated with thoracoscopy, compared with a rate of only 9% following laparoscopic myotomy and fundoplication.<sup>73</sup>

Most recent reports of thoracoscopic myotomy describe a “hybrid operation,” which utilizes a minithoracotomy through which standard instruments are used.<sup>74,75</sup> Additional port sites are placed to provide illumination and counter-retraction. This approach likely reflects the preferences of thoracic surgeons who may not be as familiar with techniques of laparoscopy. We favor laparoscopy, as do the vast majority of surgeons performing myotomy. In our opinion, only the rare patient with a hostile abdomen from multiple prior abdominal procedures would be a potential candidate for

VATS myotomy. Even in this setting, a laparoscopic approach would still be considered preferable.

## Other Indications

A variety of other thoracoscopic esophageal procedures have been described, though their merit is difficult to determine due to the rarity of the diseases and the small number of patients studied. Aside from esophageal tumors (benign and malignant) and achalasia, thoracoscopic management of esophageal diverticulum has also been reported in the literature. Similar to the literature on leiomyoma, many authors report utilizing a laparoscopic transhiatal approach for epiphrenic diverticula at or near the GE junction. Palanivelu et al reported one of the larger more recent experiences with a minimally invasive approach.<sup>76</sup> In their series, eight epiphrenic (defined as within 10 cm of the GE junction) and four thoracic (“midesophageal”) diverticula were resected. Laparoscopy (with or without myotomy and fundoplication) was employed for the epiphrenic diverticula whereas prone position right-sided thoracoscopy was used for the thoracic diverticula. Myotomy was included only when an underlying motility disorder was present. The only anastomotic leak occurred with a midthoracic diverticulum resected by VATS. In a few, very small series (fewer than five patients), results were described as “excellent.”<sup>77,78</sup> However, in a larger series of 11 patients from France, three developed an esophageal fistula and two required reoperation.<sup>79</sup> The authors of that study concluded, “Minimally invasive surgery does not confer significant benefit compared with open surgery in the treatment of diverticula of the thoracic esophagus.” We have reviewed our experience with this disease.<sup>80</sup> Of 20 patients who underwent minimally invasive surgery for esophageal diverticula (either laparoscopy or VATS) at UPMC, four patients developed an esophageal leak and one death occurred as a result. Overall, the results from these small case series of thoracoscopic resection of midesophageal diverticula suggest the potential for considerable morbidity with a 20–30% leak rate. Management of epiphrenic diverticula with a minimally invasive laparoscopic approach (resection with or without myotomy and fundoplication depending on underlying pathology) seems to yield better results with low morbidity.

Thoracoscopic treatment of Boerhaave’s syndrome<sup>81,82</sup> and repair of an anastomotic leak following esophagectomy<sup>83</sup> have also been described in case reports. A minimally invasive approach certainly merits consideration in these cases only if the surgeon feels he/she can make safe and expeditious progress in these semiurgent cases. In general, we approach the majority of these cases through an open approach.

## REFERENCES

1. Dallemagne B, Weerts JM, Jehaes C, Markiewicz S, Lombard R. Laparoscopic Nissen fundoplication: preliminary report. *Surg Laparosc Endosc*. 1991 Sep;1(3):138–143.

2. Ackroyd R, Watson DI, Majeed AW, Troy G, Treacy PJ, Stoddard CJ. Randomized clinical trial of laparoscopic versus open fundoplication for gastro-oesophageal reflux disease. *Br J Surg*. 2004;91(8):975-982.
3. Douard R, Gaudric M, Chaussade S, Couturier D, Houssin D, Dousset B. Functional results after laparoscopic Heller myotomy for achalasia: a comparative study to open surgery. *Surgery*. 2004 Jul;136(1):16-24.
4. Patti MG, Fisichella PM, Perretta S, et al. Impact of minimally invasive surgery on the treatment of esophageal achalasia: a decade of change. *J Am Coll Surg*. 2003;196(5):698-703; discussion 703-705.
5. Little AG. Gastroesophageal reflux disease: a historical review of surgical therapy. *J Surg Res*. 2004 Mar;117(1):30-33.
6. Birkmeyer JD, Siewers AE, Finlayson EV, et al. Hospital volume and surgical mortality in the United States. *New Engl J Med*. 2002 Apr 11;346(15):1128-1137.
7. Millikan KW, Silverstein J, Hart V, et al. A 15-year review of esophagectomy for carcinoma of the esophagus and cardia. *Arch Surg*. 1995;130(6):617-624.
8. McAnena OJ, Rogers J, Williams NS. Right thoracoscopically assisted oesophagectomy for cancer. *Br J Surg*. 1994;81(2):236-238.
9. Collard JM, Lengele B, Otte JB, Kestens PJ. En bloc and standard esophagectomies by thoracoscopy. *Ann Thorac Surg*. 1993 Sep;56(3):675-679.
10. Peracchia A, Rosati R, Fumagalli U, Bona S, Chella B. Thoracoscopic esophagectomy: are there benefits? *Semin Surg Oncol*. 1997 Jul-Aug;13(4):259-262.
11. Luketich JD, Alvelo-Rivera M, Buenaventura PO, et al. Minimally invasive esophagectomy: outcomes in 222 patients. *Ann Surg*. 2003 Oct;238(4):486-494; discussion 94-95.
12. Luketich JD, Schauer P, Landreneau R, et al. Minimally invasive surgical staging is superior to endoscopic ultrasound in detecting lymph node metastases in esophageal cancer. *J Thorac Cardiovasc Surg*. 1997 Nov;114(5):817-821; discussion 21-23.
13. al-Sarraf M, Martz K, Herskovic A, et al. Progress report of combined chemoradiotherapy versus radiotherapy alone in patients with esophageal cancer: an intergroup study. *J Clin Oncol*. 1997;15(1):277-284.
14. Hulscher JB, van Sandick JW, de Boer AG, et al. Extended transthoracic resection compared with limited transhiatal resection for adenocarcinoma of the esophagus. *New Engl J Med*. 2002 Nov 21;347(21):1662-1669.
15. Bedenne L, Michel P, Bouche O, et al. Chemoradiation followed by surgery compared with chemoradiation alone in squamous cancer of the esophagus: FFC09102. *J Clin Oncol*. 2007 Apr 1;25(10):1160-1168.
16. Stahl M, Stuschke M, Lehmann N, et al. Chemoradiation with and without surgery in patients with locally advanced squamous cell carcinoma of the esophagus. *J Clin Oncol*. 2005 Apr 1;23(10):2310-2307.
17. Ajani J, D'Amico TA, Hayman JA, Meropol NJ, Minsky B. Esophageal cancer. Clinical practice guidelines in oncology. *J Natl Compr Canc Netw*. 2003;1(1):14-27.
18. Chang L, Stefanidis D, Richardson WS, Earle DB, Fanelli RD. The role of staging laparoscopy for intraabdominal cancers: an evidence-based review. *Surg Endosc*. 2009;23(2):231-241.
19. Luketich JD, Meehan M, Nguyen NT, et al. Minimally invasive surgical staging for esophageal cancer. *Surg Endosc*. 2000;14(8):700-702.
20. Flanagan FL, Dehdashti F, Siegel BA, et al. Staging of esophageal cancer with 18F-fluorodeoxyglucose positron emission tomography. *AJR Am J Roentgenol*. 1997;168(2):417-424.
21. Kole AC, Plukker JT, Nieweg OE, Vaalburg W. Positron emission tomography for staging of oesophageal and gastroesophageal malignancy. *Br J Cancer*. 1998 Aug;78(4):521-527.
22. Dwamena BA, Sonnad SS, Angobaldo JO, Wahl RL. Metastases from non-small cell lung cancer: mediastinal staging in the 1990s—meta-analytic comparison of PET and CT. *Radiology*. 1999 Nov;213(2):530-536.
23. Hellwig D, Ukena D, Paulsen F, Bamberg M, Kirsch CM. [Meta-analysis of the efficacy of positron emission tomography with F-18-fluorodeoxyglucose in lung tumors. Basis for discussion of the German Consensus Conference on PET in Oncology 2000]. *Pneumologie (Stuttgart, Germany)*. 2001;55(8):367-377.
24. Luketich JD, Schauer PR, Meltzer CC, et al. Role of positron emission tomography in staging esophageal cancer. *Ann Thorac Surg*. 1997 Sep;64(3):765-769.
25. Luketich JD, Friedman DM, Weigel TL, et al. Evaluation of distant metastases in esophageal cancer: 100 consecutive positron emission tomography scans. *Ann Thorac Surg*. 1999 Oct;68(4):1133-1136; discussion 6-7.
26. Tytgat GN, Tio TL. Esophageal ultrasonography. *Gastroenterol Clin North Am*. 1991 Dec;20(4):659-671.
27. Saunders HS, Wolfman NT, Ott DJ. Esophageal cancer. Radiologic staging. *Radiol Clin North Am*. 1997 Mar;35(2):281-294.
28. Vickers J. Role of endoscopic ultrasound in the preoperative assessment of patients with oesophageal cancer. *Ann R Coll Surg Engl*. 1998 Jul;80(4):233-239.
29. Krasna MJ, Reed CE, Nedzwiecki D, et al. CALGB 9380: a prospective trial of the feasibility of thoracoscopy/laparoscopy in staging esophageal cancer. *Ann Thorac Surg*. 2001;71(4):1073-1079.
30. Walsh TN, Noonan N, Hollywood D, Kelly A, Keeling N, Hennessy TP. A comparison of multimodal therapy and surgery for esophageal adenocarcinoma. *New Engl J Med*. 1996 Aug 15;335(7):462-467.
31. Steup WH, De Leyn P, Deneffe G, Van Raemdonck D, Coosemans W, Lerut T. Tumors of the esophagogastric junction. Long-term survival in relation to the pattern of lymph node metastasis and a critical analysis of the accuracy or inaccuracy of pTNM classification. *J Thorac Cardiovasc Surg*. 1996;111(1):85-94; discussion 94-95.
32. Kassis ES, Nguyen N, Shriver SP, Siegfried JM, Schauer PR, Luketich JD. Detection of occult lymph node metastases in esophageal cancer by minimally invasive staging combined with molecular diagnostic techniques. *JSLs*. 1998 Oct-Dec;2(4):331-336.
33. Godfrey TE, Raja S, Finkelstein SD, Gooding WE, Kelly LA, Luketich JD. Prognostic value of quantitative reverse transcription-polymerase chain reaction in lymph node-negative esophageal cancer patients. *Clin Cancer Res*. 2001;7(12):4041-4048.
34. Akaishi T, Kaneda I, Higuchi N, et al. Thoracoscopic en bloc total esophagectomy with radical mediastinal lymphadenectomy. *J Thorac Cardiovasc Surg*. 1996 Dec;112(6):1533-1540; discussion 40-41.
35. Robertson GS, Lloyd DM, Wicks AC, Veitch PS. No obvious advantages for thoracoscopic two-stage oesophagectomy. *Br J Surg*. 1996;83(5):675-678.
36. Law S, Wong J. Use of minimally invasive oesophagectomy for cancer of the oesophagus. *Lancet Oncol*. 2002;3(4):215-222.
37. DePaula AL, Hashiba K, Ferreira EA, de Paula RA, Grecco E. Laparoscopic transhiatal esophagectomy with esophagogastric anastomosis. *Surg Laparosc Endosc*. 1995 Feb;5(1):1-5.
38. Swanstrom LL, Hansen P. Laparoscopic total esophagectomy. *Arch Surg*. 1997;132(9):943-947; discussion 7-9.
39. Atkins BZ, Shah AS, Hutcheson KA, et al. Reducing hospital morbidity and mortality following esophagectomy. *Ann Thorac Surg*. 2004 Oct;78(4):1170-1176; discussion 1170-1176.
40. Martin RE, Letsos P, Taves DH, Inculet RI, Johnston H, Preiksaitis HG. Oropharyngeal dysphagia in esophageal cancer before and after transhiatal esophagectomy. *Dysphagia*. 2001 Winter;16(1):23-31.
41. Easterling CS, Bousamra M, 2nd, Lang IM, et al. Pharyngeal dysphagia in postesophagectomy patients: correlation with deglutitive biomechanics. *Ann Thorac Surg*. 2000;69(4):989-992.
42. Bhat MA, Dar MA, Lone GN, Dar AM. Use of pedicled omentum in esophagogastric anastomosis for prevention of anastomotic leak. *Ann Thorac Surg*. 2006 Nov;82(5):1857-1862.
43. Cheria V, Divatia JV, Kulkarni A, Dasgupta D. Cardiomeastinal tamponade and shock following three-stage transthoracic oesophagectomy. *J Postgrad Med*. 2001 Jul-Sep;47(3):185-187.
44. Velanovich V, Vallance SR, Gusz JR, Tapia FV, Harkabus MA. Quality of life scale for gastroesophageal reflux disease. *J Am Coll Surg*. 1996 Sep;183(3):217-224.
45. Rizk NP, Bach PB, Schrag D, et al. The impact of complications on outcomes after resection for esophageal and gastroesophageal junction carcinoma. *J Am Coll Surg*. 2004;198(1):42-50.
46. Watson DI, Davies N, Jamieson GG. Totally endoscopic Ivor Lewis esophagectomy. *Surg Endosc*. 1999;13(3):293-297.
47. Nguyen NT, Folllette DM, Lemoine PH, Roberts PF, Goodnight JE, Jr. Minimally invasive Ivor Lewis esophagectomy. *Ann Thorac Surg*. 2001 Aug;72(2):593-596.
48. Kunisaki C, Hatori S, Imada T, et al. Video-assisted thoracoscopic esophagectomy with a voice-controlled robot: the AESOP system. *Surg Laparosc Endosc Percutan Tech*. 2004 Dec;14(6):323-327.
49. Bizakis C, Kent MS, Luketich JD, et al. Initial experience with minimally invasive Ivor Lewis esophagectomy. *Ann Thorac Surg*. 2006 Aug;82(2):402-406; discussion 6-7.
50. Palanivelu C, Prakash A, Senthilkumar R, et al. Minimally invasive esophagectomy: thoracoscopic mobilization of the esophagus and mediastinal



- lymphadenectomy in prone position—experience of 130 patients. *J Am Coll Surg.* 2006;203(1):7–16.
51. Seremetis MG, Lyons WS, deGuzman VC, Peabody JW, Jr. Leiomyomata of the esophagus. An analysis of 838 cases. *Cancer.* 1976 Nov;38(5):2166–2177.
  52. Lee LS, Singhal S, Brinster CJ, et al. Current management of esophageal leiomyoma. *J Am Coll Surg.* 2004;198(1):136–146.
  53. Hatch GF, 3rd, Wertheimer-Hatch L, Hatch KF, et al. Tumors of the esophagus. *World J Surg.* 2000;24(4):401–411.
  54. Fountain SW. Leiomyoma of the esophagus. *Thorac Cardiovasc Surg.* 1986 Jun;34(3):194–195.
  55. Glanz I, Grunebaum M. The radiological approach to leiomyoma of the oesophagus with a long-term follow-up. *Clin Radiol.* 1977 Mar;28(2):197–200.
  56. Biasini A. Su di un caso di fibroleiomyoma dell'esofago ipobronchiale in trasformazione maligna asportazione per via transpleurodiaframmatica ed esofago-gastrotomia guarigione. *Pathologica.* 1949;41:260–267.
  57. Calmenson M, Claggett O. Surgical removal of leiomyomas of the esophagus. *Am J Surg.* 1946;72:745–747.
  58. Bonavina L, Segalin A, Rosati R, Pavanello M, Peracchia A. Surgical therapy of esophageal leiomyoma. *J Am Coll Surg.* 1995 Sep;181(3):257–262.
  59. Roviato GC, Maciocco M, Varoli F, Rebuffat C, Vergani C, Scarduelli A. Videothoracoscopic treatment of oesophageal leiomyoma. *Thorax.* 1998;53(3):190–192.
  60. Samphire J, Naftoux P, Luketich J. Minimally invasive techniques for resection of benign esophageal tumors. *Semin Thorac Cardiovasc Surg.* 2003;15(1):35–43.
  61. Li ZG, Chen HZ, Jin H, et al. Surgical treatment of esophageal leiomyoma located near or at the esophagogastric junction via a thoracoscopic approach. *Dis Esophagus.* 2009;22(2):185–189.
  62. Hennessy TPJ, Cuschieri A. Tumours of the esophagus. In: Hennessy TPJ, Cuschieri A, eds. *Surgery of the Oesophagus.* 2nd ed. Oxford, UK; Boston, MA: Butterworth Heinemann; 1992:275–327.
  63. Kent M, d'Amato T, Nordman C, et al. Minimally invasive resection of benign esophageal tumors. *J Thorac Cardiovasc Surg.* 2007 Jul;134(1):176–181.
  64. Ellis FH, Jr. Oesophagomyotomy for achalasia: a 22-year experience. *Br J Surg.* 1993;80(7):882–885.
  65. Ferguson MK, Reeder LB, Olak J. Results of myotomy and partial fundoplication after pneumatic dilation for achalasia. *Ann Thorac Surg.* 1996 Aug;62(2):327–330.
  66. Luketich JD, Fernando HC, Christie NA, et al. Outcomes after minimally invasive esophagomyotomy. *Ann Thorac Surg.* 2001 Dec;72(6):1909–1912; discussion 12–13.
  67. Schuchert MJ, Luketich JD, Landreneau RJ, et al. Minimally-invasive esophagomyotomy in 200 consecutive patients: factors influencing postoperative outcomes. *Ann Thorac Surg.* 2008;85(5):1729–1734.
  68. Pellegrini C, Wetter LA, Patti M, et al. Thoracoscopic esophagomyotomy. Initial experience with a new approach for the treatment of achalasia. *Ann Surg.* 1992 Sep;216(3):291–296; discussion 6–9.
  69. Codispoti M, Soon SY, Pugh G, Walker WS. Clinical results of thoracoscopic Heller's myotomy in the treatment of achalasia. *Eur J Cardiothorac Surg.* 2003 Oct;24(4):620–624.
  70. Lee JM, Wang CH, Huang PM, et al. Enduring effects of thoracoscopic Heller myotomy for treating achalasia. *World J Surg.* 2004;28(1):55–58.
  71. Kesler KA, Tarvin SE, Brooks JA, Rieger KM, Lehman GA, Brown JW. Thoracoscopy-assisted Heller myotomy for the treatment of achalasia: results of a minimally invasive technique. *Ann Thorac Surg.* 2004;77(2):385–391; discussion 91–92.
  72. Abir F, Modlin I, Kidd M, Bell R. Surgical treatment of achalasia: current status and controversies. *Dig Surg.* 2004;21(3):165–176.
  73. Richards WO, Torquati A, Holzman MD, et al. Heller myotomy versus Heller myotomy with Dor fundoplication for achalasia: a prospective randomized double-blind clinical trial. *Ann Surg.* 2004 Sep;240(3):405–412; discussion 12–15.
  74. Agrawal D, Meekison L, Walker WS. Long-term clinical results of thoracoscopic Heller's myotomy in the treatment of achalasia. *Eur J Cardiothorac Surg.* 2008 Aug;34(2):423–426; discussion 6.
  75. Ma N, Zhong H, Ye C, Shan G, Zhang F, Mei J. Minimally invasive thoracoscopy-assisted Heller myotomy for achalasia. *Asian Cardiovasc Thorac Ann.* 2008 Dec;16(6):459–462.
  76. Palanivelu C, Rangarajan M, Maheshkumar GS, Senthilkumar R. Minimally invasive surgery combined with peroperative endoscopy for symptomatic middle and lower esophageal diverticula: a single institute's experience. *Surg Laparosc Endosc Percutan Tech.* 2008 Apr;18(2):133–138.
  77. Beckerhinn P, Kriwanek S, Pramhas M, Armbruster C, Roka R. Video-assisted resection of pulsative midesophagus diverticula. *Surg Endosc.* 2001;15(7):720–722.
  78. Dado G, Bresadola V, Terrosu G, Bresadola F. Diverticulum of the midthoracic esophagus: pathogenesis and surgical treatment. *Surg Endosc.* 2002;16(5):871.
  79. Levard H, Carbonnel F, Perniceni T, et al. [Minimally invasive surgery for diverticula of the thoracic esophagus. Results in 11 patients]. *Gastroenterol Clin Biol.* 2001;25(10):885–890.
  80. Fernando HC, Luketich JD, Samphire J, et al. Minimally invasive operation for esophageal diverticula. *Ann Thorac Surg.* 2005 Dec;80(6):2076–2080.
  81. Ikeda Y, Niimi M, Sasaki Y, Shatari T, Takami H, Kodaira S. Thoracoscopic repair of a spontaneous perforation of the esophagus with the endoscopic suturing device. *J Thorac Cardiovasc Surg.* 2001;121(1):178–179.
  82. Landen S, El Nakadi I. Minimally invasive approach to Boerhaave's syndrome: a pilot study of three cases. *Surg Endosc.* 2002;16(9):1354–1357.
  83. Nguyen NT, Follette DM, Roberts PF, Goodnight JE, Jr. Thoracoscopic management of postoperative esophageal leak. *J Thorac Cardiovasc Surg.* 2001;121(2):391–392.

*This page intentionally left blank*

# PERSPECTIVE ON MALIGNANT ESOPHAGEAL DISEASE

Thomas R. DeMeester

It was a pleasure to receive a letter from Dr Michael Zinner inviting me to write a perspective on the chapters of Dr Simon Law's group from Hong Kong on the diagnosis and treatment of esophageal cancer, Dr David Sugarbaker's group from Boston on the techniques used to resect the esophagus and reconstruct the foregut, and Dr James Luketich's group from Pittsburgh on minimally invasive esophagectomy. Of truth, I have rarely read such well-written and thoroughly thought-out reviews. While reading, I identified areas where I was motivated to comment on the discussion from my personal experience. These usually took the form of helpful thoughts or alternatives. Occasionally, they raised a note of caution or took a controversial point of view.

The reason for the dramatic rise in adenocarcinoma of the esophagus continues to remain a mystery even though it represents the largest epidemiologic change ever recorded for a solid cancer. The rise is largely confined to the Caucasian population and is widely attributed to gastroesophageal reflux disease and its complication, Barrett's esophagus. Some have also evoked the rise in obesity as the cause. Based on sound logic, I still support the hypothesis that potent acid suppression therapy played a role in the epidemiologic change. The incidence of adenocarcinoma began to rise in 1975; the same time acid suppression with H<sub>2</sub> blockers became widely available. Over time the H<sub>2</sub> blockers were largely replaced by proton pump inhibitors that had a greater capacity to suppress acid. Although this hypothesis has been difficult to prove short of a large and long prospective randomized study, an unbiased review of the small nonrandomized studies published in the surgical and medical literature to date will convince the practitioner of the truth of this hypothesis. A recent study<sup>1</sup> showed that medically treated patients who had relief or mildly persistent reflux symptoms while on proton pump inhibitors have significantly higher odds of developing esophageal adenocarcinoma than medically treated patients who have persistent severe reflux symptoms. My explanation for this observation is that acid suppression therapy decreases reflux symptoms by decreasing the acid content of gastric juice and causing the

pH to rise from less than 2 to 4 or greater, that is, in the range of a weak acid. On the stealth side, this increase in pH also increases the solubility of bile acids in the refluxed neutralized gastric juice. Bile acids at the pH of 4–6 have ready access into the Barrett's epithelial cell. When in the cell, bile acids are known stimulants of CDX2, the most powerful genetic stimulus for the development of intestinal metaplasia. They also stimulate the expression of genes involved in the carcinogenesis of intestinalized Barrett's epithelium to adenocarcinoma. In contrast, the persistence of severe reflux symptoms while on medication indicates incomplete acid suppression. The persistent acidic gastric juice causes bile acids to precipitate out of solution. This nullifies their effect, hence less or no intestinal metaplasia or adenocarcinoma.

I take exception, as does Dr Law, with the current dogma that there is no evidence proving that surveillance will result in a better survival of patients with Barrett's esophagus who progress to adenocarcinoma. Rather, I believe that all individuals who are identified as having Barrett's esophagus should enter a surveillance program. In our experience surveillance of patients with Barrett's esophagus does detect tumors at an earlier stage. Indeed, the percentage of patients presenting with an early T1 N0 adenocarcinoma has increased over time and, in the more recent years, account for nearly 50% of all resected tumors. Looked at from a different perspective, 86% of esophageal adenocarcinomas identified by Barrett's surveillance have stage I disease.

In the new staging system cancers of the gastric cardia that extend into the gastroesophageal junction are classified as adenocarcinomas of the esophagus rather than the stomach. This is an improvement but still is imprecise due to the inability to consistently define the location of the gastroesophageal junction. In 2000, the Association of Directors of Anatomic and Surgical Pathology defined the *gastroesophageal junction* as a horizontal line drawn across the end of the tubular esophagus at the point where it begins to flare into the stomach. Using this definition, there is evidence that adenocarcinomas of the gastric cardia commonly



arise in areas of intestinal metaplasia within the gastric cardia that have strong similarities to adenocarcinomas of the distal esophagus. We have suggested that the location of the gastroesophageal junction is defined more accurately by histology as the proximal limit of gastric oxyntic mucosa. The area cephalad to this limit is histologically the esophagus and in normal people is lined by squamous epithelium and in patients with reflux is lined, to a variable extent, with different types of metaplastic columnar epithelium (cardiac, oxyntocardiac, and intestinal). Important to understanding disease at this location is to obtain an accurate estimate of the incidence of Barrett's adenocarcinoma. With greater precision it is likely that the number of Barrett's adenocarcinomas would be more than double. This would give us a greater appreciation for the exponential rise of adenocarcinoma in this area and could well make the screening of patients with Barrett's more cost-effective.

Endoscopic surveillance of patients with Barrett's esophagus has identified a rather large number with high-grade dysplasia in the Barrett's segment. Most regard this finding as a threshold for intervention. The new technique of endoscopic mucosal ablation has allowed the treatment of high-grade dysplasia with preservation of the esophagus and a morbidity and mortality lower than an esophagectomy. The survival following either treatment is similar. This has reduced the use of surgical resection to treat these patients. Many, however, have visible lesions within the flat Barrett's segment such as a nodule or ulcer. Such lesions must be removed by endoscopic mucosal resection to determine the nature of the lesion and, if a cancer, its depth of penetration into the esophageal wall. If a cancerous lesion is limited to the lamina propria, ablation of the Barrett's segment can proceed. If a cancerous lesion extends beyond the muscularis mucosa, there is a significant increase in the probability of lymph node metastasis and an esophagectomy is required. Despite flawed statements to the contrary, there is no "safe" level of invasion into the submucosa that would extend the use of endoscopic resection. To manage these patients correctly requires that surgeons become adept at endoscopy and endoscopic mucosal resection. The opportunity for this training is limited and is an issue that must get the attention of the Residency Review Committee for Surgery and the American Board of Surgery. The new therapy is extremely work intensive and is associated with the risk of developing cancer during the treatment. Consequently a vigilant support staff is necessary to handle the patients. In our experience patients who have high-grade dysplasia in a long segment of Barrett's esophagus, or in an anatomically short esophagus with a large hiatal hernia, or in an esophagus with a severe motility problem, or have multifocal high-grade dysplasia or multiple failures of ablation therapy are not candidates for esophageal preservation therapy and are better off having a vagal sparing esophagectomy. This form of esophagectomy is associated with less perioperative morbidity and a shorter hospital stay than a standard transthoracic or transhiatal esophagectomy. Further, its late morbidity, including weight loss, dumping, and diarrhea, is significantly less.<sup>2</sup>

Surgical resection remains the mainstay of treatment for fit patients with localized esophageal carcinoma that has invaded into the submucosa or beyond. In my mind, the only exception to this rule is a cervical esophageal cancer that is located sufficiently close to the cricopharyngeal muscle to prevent a clear resection margin. These patients are better off receiving definitive radiochemotherapy. If a recurrence occurs, a pharyngolaryngoesophagectomy is performed as a salvage procedure. It is critical that these patients understand this approach prior to treatment and are willing to submit to yearly surveillance after the definitive radiochemotherapy. Fit patients with tumors in the lower cervical or upper thoracic esophagus are treated with cytoreduction of the tumor by radiochemotherapy followed by resection and reconstruction with a free jejuno-interposition. Fit patients with tumors in the mid or lower thoracic esophagus, gastroesophageal junction, or gastric cardia are treated with an en bloc esophagectomy and complete lymphadenectomy. The superiority of this approach has become gradually apparent over the years with the greatest benefit seen in patients with fewer than eight lymph nodes involved in specimens that contain more than 30 resected nodes. The historical development of this position is nicely documented in the 10 publications.<sup>3-13</sup>

Critical in performing an en bloc esophagectomy is that the proximal, distal, and radial margins are free of tumor. I agree with Dr Law's comment that the proximal esophageal margin is most critical and a good guide is to obtain 10 cm of grossly normal esophagus above the superior margin of the tumor. After removal, the fresh specimen contracts to approximately 50% of its length or down to 5 cm of grossly normal appearing esophagus. With this length of margin, there is less than a 5% chance of an anastomotic recurrence. Similarly, it is important to have a greater than 1-mm free circumferential radial margin on the specimen after a curative resection. This has been shown to be an important independent prognostic variable.<sup>13</sup> Simply put, patients with less than a 1-cm free circumferential radial margin in what would otherwise have been a curative resection doubles their risk of dying from cancer. As would be expected, the effect of a clear circumferential radial margin is most important in patients who have limited or no lymph node involvement.

An en bloc resection includes a complete lymphadenectomy. The number of lymph nodes removed is an independent predictor of survival. To maximize this survival benefit, a minimum of 23-29 nodes need to be removed. Taking additional nodes is of benefit, but the effect begins to drop off. When analyzed by Cox regression, the number of lymph nodes removed modeled as a continuous variable was the third most important prognostic factor behind the number of involved nodes and the depth of tumor invasion. Of the three factors, the number of nodes removed is the only predictor of survival that can be influenced by the surgeon. The operation most likely to maximize the number of nodes removed is the two-field en bloc esophagectomy.

I am not convinced that adding a third field, that is a cervical node dissection, improves the survival sufficiently to overcome the increased morbidity. Rather, we have taken

the approach of obtaining a positron emission tomography (PET) scan and ultrasound examination 1 year after the initial resection and performing a modified radical neck dissection if involved neck nodes are detected or suspected. An exception to this policy is when unsuspected involved recurrent laryngeal nodes are discovered while performing the neck dissection during the initial operation in preparation for a neck anastomosis. In this situation a cervical node dissection is added to the initial operation to remove recurrent laryngeal and deep cervical nodes on the left.

In a unique study, the en bloc and transhiatal resections were compared using a retrospective case-control study of nonrandomized patients with similar-size transmural tumors (T3) and lymph node metastasis selected at random from our registry. The result showed that the survival benefit of an en bloc resection was limited to patients with eight or fewer involved nodes. There was no difference in outcome when nine or more lymph nodes were involved. When this information was applied to the 5-year outcome of the only randomized studies done to compare the two resections, only those patients with one to eight involved lymph nodes significantly benefited from an en bloc resection. This finding fits with the results of a multi-institutional international study showing that the probability of systemic disease is 50% when three nodes are involved and approaches 100% when more than eight nodes are involved. Based on these studies, the en bloc resection is most likely to benefit patients with eight or fewer lymph nodes involved. Beyond this number the likelihood of systemic disease approaches 100%, and neither an en bloc nor a transhiatal resection provides a long-term benefit.

The most dreaded complication of esophagectomy is ischemic injury to the conduit used for reconstruction. This is often the cause for an anastomotic leak and a cascade of sepsis, multiorgan failure, and death. Factors known to contribute to this complication are diabetes, hypertension, cardiac arrhythmia, chronic obstructive pulmonary disease, and neoadjuvant therapy. Indeed, I believe that conduit ischemia is the "Achilles heel" of a successful esophageal resection and reconstruction. When faced with a worrisome ischemic conduit, we pull the conduit up and anchor it in the neck without performing the anastomosis. A Prolene stitch is placed into the conduit and brought out to the subcutaneous tissue for a guide to find the conduit at the time of delayed reconstruction. The proximal esophageal remnant is brought out to the neck as an esophagostomy and a feeding jejunostomy constructed in the abdomen. Ninety days after the esophagectomy, a cervical esophagogastrostomy is performed through the original neck incision. Over the years we have used this strategy in 35 patients. At the time of reconstruction, all had well-perfused gastric conduits and the delayed anastomosis healed without a leak, wound infection, or sepsis.<sup>14</sup>

As Dr Law pointed out, the past two decades have witnessed a proliferation in chemotherapy and chemoradiotherapy trials in esophageal cancer. The basis for this explosion is the suboptimal surgical cure rate for advanced cancer. True, distant failure remains a major problem in patients with advanced cancer, and a search for more effective systemic drugs as well as

a method to select the right drugs for the right patient needs to be supported and encouraged. I agree with Dr Law that currently the results of neoadjuvant chemoradiation therapy are conflicting, and that published meta-analysis show minimal to no benefit. Despite this, neoadjuvant chemoradiation is widely practiced in the United States. A limitation of the current randomized trials is the lack of accurate staging prior to randomization. If randomization is done correctly, major known factors that affect survival, such as stage of disease, need to be evenly distributed in the study groups prior to randomization as the concept of randomization is used only to manage unknown factors that affect survival. I have concluded that the studies done to date have shown neoadjuvant therapy to be only effective in causing cytoreduction of the primary tumor. The lack of a similar response in the secondary lesions is an indication that their sensitivity to chemotherapy is different than the primary tumor, perhaps through tumor cell interaction with host tissues cells and their cellular immune response. I would recommend that future neoadjuvant studies be done only on patients of similar stage based on carefully done pretreatment minimally invasive surgical staging. I would also suggest an adjuvant chemotherapy trial where the chemotherapy given is based on chemosensitivity studies done on the involved lymph nodes removed at the time of surgery or on biopsies of solid-organ metastasis done at the time they are discovered after surgery. Clearly, a new approach is needed. The movement toward definitive chemotherapy is based on its known cytoreduction effect on the primary tumor. The concept is designed to eliminate surgical therapy because surgery as currently performed has failed to control local disease. This is largely due to the resistance and inability of surgeons to perform an en bloc resection. After an appropriately done en bloc resection the local recurrence rate is less than 2% whereas after transhiatal resection it is 25% or greater. My concern is that our failure to centralize esophageal surgery in the United States, as is currently being done in England, will relegate surgical therapy from a primary position in esophageal cancer to an adjuvant role.

Dr Wee and Dr Sugarbaker provide an excellent description of the en bloc esophagogastrectomy done through what is known as the *tri-incision* or *McKeown technique*. We perform the operation similar to their description with a few exceptions. We begin in the right chest by dividing the intercostal veins as they join the azygos vein from the arch down to the diaphragmatic hiatus. We then dissect out the intercostal arteries and follow them to where they join the aorta. The aorta is then easily skeletonized from the right and over into the left chest as the left intercostal arteries pass directly posterior to the costospinous junctions and have never interfered with this dissection. The mobilized azygos vein is divided at its junction with the superior vena cava. Both the azygos vein and the thoracic duct are taken with the specimen. The distal azygos vein and thoracic duct are ligated adjacent to the spine deep within the esophageal diaphragmatic hiatus, using a laparoscopic endo-loop. The proximal thoracic duct is divided later in the dissection and does not leak because of proximal valves. Both the right and left sides of the chest are drained

using ½-in Jackson-Pratt (J-P) drains positioned adjacent to the spine on the right and aorta on the left and both resting on the posterior chest wall. The drains are placed through the esophageal diaphragmatic hiatus during the abdominal portion of the procedure after the specimen has been removed and before the gastric conduit has been pulled up. The drains are brought out through stab wounds in the right and left upper quadrant. This allows the right and only chest tube to be removed on the first or second postoperative day. We also skeletonize the superior and anterior wall of the common and right hepatic artery, the superior and inferior wall of the portal vein, and the superior and anterior wall of the splenic artery out to the splenic hilum. Skeletonizing the inferior wall of the portal vein is done by using a vein retractor to displace the vein caudally and using the cautery along the superior border of the pancreatic head. The width of our gastric conduit is 3–4 cm, and a pyloroplasty is performed using an end-to-end stapler (EEA, US Surgical, Norwalk, CT) inserted through the conduit staple line near the antrum and taking a cookie bite out of the anterior portion of the pyloric ring.

Dr Luketich's group deserves the credit for being on the frontier of adapting esophagectomy into a laparoscopic and thoracoscopic procedure. Their work is commendable and has shown that there is some reduction in procedural morbidity, postoperative discomfort, and length of hospital stay, but not as much as one would suspect. To their credit they appear not to have limited the extent of the resection to accommodate the new approach but rather creatively altered their approach to maintain the extent of the dissection. There is a point when the benefits of minimally invasive surgery are overcome by the extensiveness of the internal surgical dissection and manipulation. When that point is reached, the advantages of a minimally invasive procedure will diminish and the world of surgery will continue to do such a procedure openly until further technological developments occur that will allow us to go further in our quest for "user-friendly" surgery. I believe minimally invasive esophagectomy is near that point.

## REFERENCES

1. Nason KS, Wichienkuer PP, Awais O, et al. Gastroesophageal reflux disease symptom severity, proton pump inhibitor use, and esophageal carcinogenesis. *Arch Surg.* 2011;146:851–858.
2. Peyre CG, DeMeester SR, Rizzetto C, et al. Vagal-sparing esophagectomy: the ideal operation for intramucosal adenocarcinoma and Barrett with high-grade dysplasia. *Ann Surg.* 2007;246:665–674.
3. DeMeester T, Zaninotto G, Johansson KE, et al. Selective therapeutic approach to cancer of the lower esophagus and cardia. *J Thorac Cardiovasc Surg.* 1988;95:42–52.
4. Letters to the editor; J Kirklin J, Blackstone E. The DeMeester paper on carcinoma of the esophagus. *J Thorac Cardiovasc Surg.* 1990;100:456–458.
5. Hagen J, Peters JH, DeMeester TR, et al. Superiority of extended en bloc esophagogastrectomy for carcinoma of the lower esophagus and cardia. *J Thorac Cardiovasc Surg.* 1993;106:850–859.
6. Hagen J, DeMeester SR, Peters JH, Chandrasoma P, DeMeester TR. Curative resection for esophageal adenocarcinoma, analysis of 100 en bloc esophagectomies. *Ann Surg.* 2001;234:520–531.
7. Hulscher JBF, van Sandick JW, de Boer AG, et al. Extended transthoracic resection compared with limited transhiatal resection for adenocarcinoma of the esophagus. *N Eng J Med.* 2002;347:1662–1709.
8. Johansson J, DeMeester TR, Hagen JA, et al. En bloc vs. Transhiatal esophagectomy for stage T3 N1 adenocarcinoma of the distal esophagus. *Arch Surg.* 2004;139:627–633.
9. Portale G, Hagen JA, Peters JH, et al. Modern 5-year survival of resectable esophageal adenocarcinoma: single institution experience with 263 patients. *J Am Coll Surg.* 2006;202:588–598.
10. Omloo JMT, Lagarde SM, Hulscher JBF, et al. Extended transthoracic resection compared with limited transhiatal resection for adenocarcinoma of the mid/distal esophagus: five-year survival of a randomized clinical trial. *Ann Surg.* 2007;246:922–1001.
11. Peyre CG, Hagen JA, DeMeester SR, et al. The number of lymph nodes removed predicts survival in esophageal cancer: an international study on the impact of extent of surgical resection. *Ann Surg.* 2008;248:549–556.
12. Peyre CG, Hagen JA, DeMeester SR, et al. Predicting systemic disease in patients with esophageal cancer after esophagectomy: a multinational study on the significance of the number of involved lymph nodes. *Ann Surg.* 2008;248:979–985.
13. Dexter SP, Sue-Ling H, McMahon MJ, Quirke P, Mapstone N, Martin IG. Circumferential resection margin involvement: an independent predictor of survival following surgery for oesophageal cancer. *Gut.* 2001;48:667–670.
14. Oezcelik A, Banki F, DeMeester SR, et al. Delayed esophagogastromy: a safe strategy for management of patients with ischemic gastric conduit at time of esophagectomy. *J Am Coll Surg.* 2009;208:1030–1034.



# PERSPECTIVE ON MALIGNANT ESOPHAGEAL DISEASE

Lee L. Swanstrom

Descriptions of the techniques and reasons for esophageal resections are presented by three leaders in esophageal surgery, working at major, high-volume esophageal centers. A thorough review of the epidemiology (such as is known) and international differences in approaches and outcomes for esophageal cancer treatments is made by Dr Law who points out the ever-increasing differences between the Western and Eastern hemispheres. In the East and Middle East, mid and proximal squamous cell cancers are by far the most prevalent, related to the persistence of carcinogenic environmental exposures. The rapid growth of adenocarcinoma in the West is a more complex issue; at our center, Barrett's esophagus-related cancers now represent 92% of esophageal cancers presenting for treatment. Unfortunately this is not totally related to the decrease in squamous cancers secondary to the decreasing incidence of smoking and other environmental factors. It is more related to the incredibly rapid growth in the incidence adenocarcinoma—now the most rapidly increasing cancer in North America. As Dr Law points out, this is probably related to the increasing incidence of both morbid obesity and gastroesophageal reflux (GER). An additional factor in either the development or, more likely, the progression to cancer may be the widespread use of proton pump inhibitors (PPIs) as a symptomatic treatment of GER. Avissar et al have shown that, at the biologic level, genetic damage that is related to dysplasia progression is facilitated by the pH environment created by usual doses of PPIs.<sup>1</sup> Certainly the fact that many patients with Barrett's esophagus have no or minimal GER symptoms complicates the possibility of screening to turn the tide of this cancer. Dr Law presents the arguments against screening very well—basically, too rare a cancer in too large an “at-risk” population. There remains a movement, however, that argues strongly for screening of high-risk individuals.<sup>2</sup> Their argument includes the ease of screening, the high percentage of Barrett's esophagus in the gastroesophageal reflux disease (GERD) population (8–17%), and the 0.5–1% per annum dysplasia progression, which screening advocates describe as the equivalent risk profile of colon

polyps. Colon polyps occur in 15% of colonoscopies, have a cancer progression risk of 0.5–1% per year, and yet claim a high priority for endoscopic screening. Finally, the argument that Barrett's screening is irrelevant because nothing would be done for anything but high-grade dysplasia (HGD) Barrett's esophagus is falling by the way as technologies like radiofrequency ablation (RFA) or cryotherapy show good efficacy at eradicating Barrett's esophagus<sup>3,4</sup> and laparoscopic antireflux surgery induces regression in 30–40% of cases.<sup>5</sup> Therefore, we may still see a future where routine screening for Barrett's esophagus makes sense, particularly as cancer rates continue to increase and better risk factor stratification is developed.<sup>6</sup>

All three chapters cover the never-ending controversy over the transhiatal/transthoracic approaches. Save the obvious holdout,<sup>7</sup> there seems to be a gradual move to a more aggressive node-removing approach with a very gradual shift in outcomes data to support better cancer outcomes with en bloc resection at the cost of markedly increased operative morbidity.<sup>8</sup> The introduction of laparoscopic/thoroscopic surgical approaches has further muddied these waters. This confusion arises from the conflict between the aspects of minimally invasive esophagectomy (MIE) that emphasizes less patient morbidity (with perhaps the implication of poorer oncologic outcomes) versus the absolute push for curative resection (for those that survive the surgery). This movement toward “less invasiveness” is not unexpectedly resisted by many established programs who have worked hard to optimize surgical outcomes for esophageal cancers and who are sought out by patients familiar with their well-publicized expertise. The majority of institutions, however, are faced with the referral dilemma engendered by the perception of esophagectomy being a highly morbid procedure, with poor long-term quality of life and having no survival advantage over chemoradiation. An actual quote from a leading medical periodical states “Recent trials fail to identify any significant advantage associated with the routine use of surgery for most patients.”<sup>9</sup> In my opinion, the migration to endoscopic techniques is inevitable—not only because it offers a new paradigm of a better (or equivalent) oncologic outcomes

due to better imaging, better access, and less patient morbidity, but also because most surgeons will never see patients with esophageal cancer in referral if all they offer is “traditional” esophagectomy. Arguments for minimally invasive approaches to GI cancers have intrinsic appeal: applying the “minimally invasive philosophy” to evidenced-based colorectal cancer treatments has resulted in recommendations that all colorectal cancers be approached laparoscopically whenever possible. In 2009, the National Health Service (NHS) in the United Kingdom, recognizing the preponderance of data in support of an MIS approach, mandated its use to all HMS participants.<sup>10</sup> I would propose that esophageal cancer treatments will eventually follow the same path.

As both Dr Sugarbaker and Dr Luketich have emphasized, esophagectomy is all about the details. This is true both for intraoperative technique and for postoperative care. Increasingly, it is obvious that to achieve a lower mortality and morbidity rate, the institutional system may be more important than a particular surgical approach or even to the experience of the surgeon.<sup>11</sup> Ideally though, esophagectomy is done both by a skilled experienced surgeon and in a high-volume system-oriented institution. Nonetheless, it is eternally interesting for surgeons to discuss the operative details of a surgical procedure and esophagectomy is a fertile field for controversy and differing opinions.

To date, most MI esophagectomy techniques have sought to replicate their open equivalents, but the focus is on the minimally invasive approach; this has led to an implication that minimally invasive approaches would be a patient-pleasing compromise to oncologic outcomes. Perhaps a better mindset would be to address the question: Can the potential advantages of an MI approach (magnification, precision, shorter hospital stay, fewer wound complications, quicker return to presurgical activity levels, less immunosuppression) be hybridized onto current established techniques? Our group has explored the possibility of using laparoscopy or thoracoscopy to replicate en bloc esophagectomy in a less morbid way—either by transhiatal laparoscopic en bloc esophagectomy for distal tumors or thoracoscopic formal en bloc resections.<sup>12</sup> Replicating the “gold standard” open procedure with no compromise and with expected patient benefit has been demonstrated feasible by the aggressive program at the University of Pittsburgh.<sup>13</sup> Unfortunately it remains a consistent concern that MI approaches take more time and demand extraordinary (unobtainable?) skills. While the latter is perhaps irrefutably true, but not insurmountable, the time element may require innovative thinking to overcome.

## STAGED ESOPHAGECTOMY

There has been some interest in performing MIE in a two-stage manner—primarily to provide an ischemic preconditioning of the gastric conduit in order to minimize the chance of ischemic complications at the anastomosis but also to compensate for the increased operative times of MIE and the increased mental

workload of an endoscopic approach.<sup>14</sup> No randomized comparisons have yet been published that would document any advantages with this approach, but it has appeal for MIE as it can be conceived as an initial staging laparoscopy followed by the definitive resection 7 days later. Our current protocol calls for laparoscopic staging, celiac/hepatic node dissection, left gastric division, and placement of a feeding jejunostomy.

Changes in the thoracic portion of the procedure are an interesting change from a standard approach. Cadier has popularized the performance of the thoracic mobilization in the prone position. This has the advantage of having gravity as a retractor for the lung, which permits the surgeon to have fewer ports and superb visualization.<sup>15</sup> We have also adopted the use of positive-pressure capnothorax to perform thoracic mobilization. This involves the use of standard laparoscopic trocars rather than thoracoports without valves. The ports are connected to a standard laparoscopic insufflator set to a low pressure (10 mm Hg) that effectively collapses the lung without the need for a double-lumen endotracheal tube. This has the additional advantage of displacing the mediastinum, creating more operative space. Having used this technique for the past 20 years, we have found that the vast majority of patients will tolerate it and that the exposure and simplicity of the approach are superior to standard VATS techniques.

A final comment is made regarding the width of the gastric conduit or “neoesophagus.” Narrow tubes versus wide tubes versus full gastric pull-up remain a controversial topic. We have favored a narrow conduit as per Akiyama, all be it at a cost of a higher leak rate due to elevated intraluminal pressures during the period of mucosal edema.<sup>16</sup> We feel that the benefits of long-term esophageal clearance and better swallowing outweigh the troublesome but self-limited risk of anastomotic leaks. Once again, however, there is no prospective comparative data that confirm this personal bias.

## CONCLUSION

Esophageal cancer and cancer surgery are rapidly changing—epidemiologically and from the “consumer’s” (ie, patient’s and referring physician’s) viewpoint. Surgery has been slow to react to this change and is in danger of becoming increasingly irrelevant in the face of improvements in noninvasive early cancer treatments (mainly endoscopic), definitive chemoradiation, and, in the future, highly targeted novel therapies. It is good that leaders in the field are exploring improvements in standard surgery outcomes as well as novel minimally invasive approaches—providing patient-friendly alternatives will help ensure the continued relevancy of surgeons in esophageal cancer treatments.

## REFERENCES

1. Avissar NE, Toia L, Hu Y, et al. Bile acid alone, or in combination with acid, induces CDX2 expression through activation of the epidermal growth factor receptor (EGFR). *J Gastrointest Surg.* 2009;13(2):212–222.

2. Wong T, Tian J, Nagar AB. Barrett's surveillance identifies patients with early esophageal adenocarcinoma. *Am J Med.* 2010;123(5):462–467.
3. Fleischer DE, Odze R, Overholt BF, et al. The case for endoscopic treatment of non-dysplastic and low-grade dysplastic Barrett's esophagus. *Dig Dis Sci.* 2010;55(7):1918–1931.
4. Chen AM, Pasricha PJ. Cryotherapy for Barrett's esophagus: Who, how, and why? *Gastrointest Endosc Clin N Am.* 2011;21(1):111–118.
5. Rossi M, Barreca M, de Bortoli N, et al. Efficacy of Nissen fundoplication versus medical therapy in the regression of low-grade dysplasia in patients with Barrett esophagus: a prospective study. *Ann Surg.* 2006;243(1):58–63.
6. Zhu W, Appelman HD, Greenson JK, et al. A histologically defined subset of high-grade dysplasia in Barrett mucosa is predictive of associated carcinoma. *Am J Clin Pathol.* 2009 Jul;132(1):94–100.
7. Chang AC, Ji H, Birkmeyer NJ, Orringer MB, Birkmeyer JD. Outcomes after transhiatal and transthoracic esophagectomy for cancer. *Ann Thorac Surg.* 2008;85(2):424–429.
8. Rizzetto C, DeMeester SR, Hagen JA, Peyre CG, Lipham JC, DeMeester TR. En bloc esophagectomy reduces local recurrence and improves survival compared with transhiatal resection after neoadjuvant therapy for esophageal adenocarcinoma. *J Thorac Cardiovasc Surg.* 2008;135:1228–1236.
9. Suntharalingam M. Definitive chemoradiation in the management of locally advanced esophageal cancer. *Semin Radiat Oncol.* 2007;17(1):22–28.
10. NICE Technology Appraisal Guidance 105: Laparoscopic Surgery for Colorectal Cancer (review). [www.nice.org.uk/TA105](http://www.nice.org.uk/TA105). Accessed
11. Brennan MF, Radzyner M, Rubin DM. Outcome—more than just operative mortality. *J Surg Oncol.* 2009 Jun 15;99(8):470–477.
12. Dunst CM, Swanström LL. Minimally invasive esophagectomy. *J Gastrointest Surg.* 2010 Feb;14(suppl 1):S108–S114.
13. Pennathur A, Zhang J, Chen H, Luketich JD. The “best operation” for esophageal cancer? *Ann Thorac Surg.* 2010;89(6):S2163–S2167.
14. Hölscher AH, Schneider PM, Gutschow C, Schröder W. Laparoscopic ischemic conditioning of the stomach for esophageal replacement. *Ann Surg.* 2007;245(2):241–246.
15. Cadière GB, Dapri G, Himpens J, Rajan A. Thoracoscopic esophagectomy in prone position. *Ann Surg Oncol.* 2011;18(3):838; Epub 2010 Oct 23.
16. Pierie JP, de Graaf PW, van Vroonhoven TJ, Obertop H. The vascularization of a gastric tube as a substitute for the esophagus is affected by its diameter. *Dis Esophagus.* 1998 Oct;11(4):231–235.



*This page intentionally left blank*

IV

# STOMACH AND DUODENUM

*This page intentionally left blank*



# BENIGN GASTRIC DISORDERS

Ian S. Soriano • Daniel T. Dempsey

## INTRODUCTION

The surgical management of benign gastric disorders has evolved significantly over the past 30 years. Elective surgery for ulcer disease has largely been abandoned in favor of medical management with surgery being utilized mainly for complications after failed medical treatment. Most elective (and some emergent) gastric procedures can now be performed with laparoscopy if local expertise is available, augmented by either radiologic (mainly via intra-operative ultrasound) or endoscopic guidance for more accurate localization. These techniques can help the surgeon perform a more targeted resection because wide margins are not necessary.

## HELICOBACTER PYLORI INFECTION

When Marshall and Warren elucidated the relationship between *Helicobacter pylori* and peptic ulcer disease, a discovery for which they were later awarded the Nobel Prize in Medicine, they rekindled the hypothesis that this common clinical malady was an infectious disease.<sup>1</sup> *H. pylori* is a gram-negative spiral flagellated organism that currently infects more than half of the people in the world. The prevalence of *H. pylori* infection varies among populations and is strongly correlated with socioeconomic conditions. In a number of developing countries, *H. pylori* infection affects more than 80% of middle-aged adults. Infection rates are lower in industrialized countries. Epidemiological data indicate that the prevalence of infection in the United States has been declining since the second half of the 19th century, with the decreases corresponding to improvements in sanitation. Nonetheless, *H. pylori* infection is predicted to remain endemic in the United States for the next century.

Human beings are the only reservoir for *H. pylori*. Infection is presumed to occur by oral ingestion of the bacterium. Direct transmission from person to person occurs via saliva and feces, and infection also occurs through contact with contaminated water. In developing countries, most

individuals are infected during childhood. Family members are at increased risk of infection. A number of occupations also show increased rates of *H. pylori* infestation, notably health care workers. Infection with *H. pylori* is a chronic disease and does not resolve spontaneously without specific treatment.

*H. pylori* has evidently adapted to the hostile gastric environment and displays a number of features that permit its entry into the surface mucus layer, attachment to gastric epithelial cells, evasion of immune responses, and persistent colonization despite luminal acidity. Up to 15% of the protein in a helicobacter organism is composed of cytoplasmic urease that converts periplasmic urea into CO<sub>2</sub> and ammonia, the latter buffering the surrounding acid.<sup>2</sup>

## Host Response to *H. Pylori*

*H. pylori* infestation is followed by continuous gastric inflammation in virtually all individuals. Because spontaneous cure is unusual for most infected individuals, this means that *H. pylori* gastritis is a lifelong affliction. Worldwide, *H. pylori*-induced gastritis accounts for 80–90% of all gastritis.

*H. pylori* infection is not invasive of the gastric mucosa, and the host immune response is triggered by the attachment of bacteria to surface epithelial cells. The initial inflammatory response is characterized by recruitment of neutrophils, followed sequentially by T and B lymphocytes, plasma cells, and macrophages. The resultant chronic gastric inflammation in affected individuals is characterized by enhanced expression of multiple cytokines.

The relationship between *H. pylori* infection and ulceration is overwhelmingly strong; multiple observations establish *H. pylori* as a factor in the pathogenesis of duodenal ulceration.<sup>3–7</sup> Most of the evidence is inferential. An effective vaccine has not yet been developed.

Observations that support *H. pylori* as a factor in the pathogenesis of human duodenal ulceration include the following:

1. *H. pylori* infection is invariably followed by the development of chronic gastritis, and the organism is the primary cause of chronic active gastritis worldwide. The infectious response to *H. pylori* is characterized by nonerosive inflammation of the gastric mucosa. Antral gastritis is present histologically in patients with duodenal ulcer, and *H. pylori* can be isolated from gastric mucosa of ulcer patients.
2. *H. pylori* binds only to gastric-type epithelium. Gastric metaplasia of the duodenal bulb is a nonspecific response to damage, which develops after infestation of the gastric mucosa. Antral gastritis with *H. pylori* is preceded by active chronic duodenitis. Metaplastic gastric epithelium is colonized by *H. pylori* from gastric sources. Gastric metaplasia is extremely common in duodenal epithelium surrounding areas of ulceration.
3. Eradication of *H. pylori* with antibiotics that have no effect on acid secretion leads to ulcer healing.
4. Therapy of peptic ulceration with bismuth compounds, which eradicate *H. pylori*, is associated with reduced rates of ulcer relapse relative to acid suppression therapy.
5. Relapse of duodenal ulcer after eradication of *H. pylori* is preceded by reinfection of the gastric mucosa by the organism.

However, infection by *H. pylori* alone does not cause peptic ulceration in most individuals, suggesting the existence of other pathogenetic factors. Half of patients evaluated for dyspepsia have histologic evidence of bacterial infection. In developed countries, one-fifth of healthy volunteers harbor the bacteria, and the incidence of bacterial infestation increases with age in the healthy, asymptomatic population. The occurrence of peptic ulcers in only a fraction of individuals who harbor the organism suggests that other factors must also act to induce ulceration.

*H. pylori* infection can be diagnosed by both invasive and noninvasive means. Noninvasive methods include the urea breath test, serology, and detection of antigen in stool samples. The urea breath test is based on production of urease by *H. pylori* in the gastric mucosa. C<sup>14</sup>-labeled urea is ingested and C<sup>14</sup>-labeled CO<sub>2</sub> is produced and excreted in the breath. This test has a sensitivity and specificity of greater than 90% and indicates ongoing infection. The urea breath test is useful for initial diagnosis of infection and for follow-up after eradication therapy.

The stool antigen test is another noninvasive test to detect both initial *H. pylori* infection as well as response to treatment. Both polyclonal and monoclonal kits have been developed. Likewise, different kits are available for both out- and in-patient settings. Overall results have been comparable to those obtained using the urea breath test method.<sup>8</sup>

Because *H. pylori* induces a strong immunologic response, serological testing is useful but may not be as accurate as the urea breath test or the stool antigen test. Validation with either of the two tests is recommended. It may be used for epidemiologic studies. Because *H. pylori*-induced serology does not return to normal after bacterial eradication, this test is not reliable in monitoring therapy.

*H. pylori* infection can also be diagnosed on the basis of biopsies in patients undergoing upper endoscopic examination.

Individuals older than 50 years, or those with significant symptoms including gastrointestinal (GI) bleeding, anemia, and weight loss, should undergo endoscopic diagnosis. During endoscopy, antral biopsies can be obtained and the organism cultured in agar containing both urea and a pH-sensitive colorimetric agent. *H. pylori* hydrolysis of urea causes a diagnostic change in color. The sensitivity of this test varies from 80 to 100% and specificity exceeds 90%. The test is associated with false-negative results in patients with active or recurrent bleeding and in those taking antibiotics or antisecretory compounds. Biopsy also permits histologic examination with visualization of the organism. Culture of *H. pylori* is not routine and is usually reserved for recurrent infection and for antibiotic sensitivity testing when second-line therapy has failed.

Complete eradication of *H. pylori* infection is the goal of treatment, and recurrence of disease signifies reinfection in most circumstances. An enormous worldwide experience has developed relating to *H. pylori* eradication. More than 2000 articles report the results of antibiotic trials, and a large number of summary articles and meta-analyses are available. It is important to note that none of the therapeutic regimens reported to date cure *H. pylori* infection in 100% of patients. To be effective, antimicrobial drugs must be combined with gastric acid secretion inhibitors or bismuth salts.

In the absence of treatment, eradication of *H. pylori* infection is very rare. Three consensus conference meetings as well as numerous clinical guidelines in various regions have been published in the past decade to further define the approach to diagnosis and treatment of *H. pylori*. The Maastricht III Consensus Report brought together a multidisciplinary group in 2007 from around the world to publish an update on the initial guidelines published in 1996 (known then as the European *Helicobacter* Study Group) and subsequently revised in 2000 after including a review of published guidelines from North America, Europe, China, and Japan (Table 21-1).<sup>9</sup>

Current evidence indicates that eradication therapy with a proton pump inhibitor, metronidazole, and amoxicillin



**TABLE 21-1: FIRST CHOICE TREATMENT FOR *H. PYLORI* INFECTION**

1. For PPI (standard dose BID) clarithromycin (500 mg BID), amoxicillin (1000 mg BID), or metronidazole (400 or 500 mg BID), 14-d treatment is more effective than that of 7-d by 12% (95% confidence interval 7–17%). A 7-d treatment may be acceptable where local studies show that it is effective.
2. PPI-clarithromycin-amoxicillin or metronidazole treatment is the recommended first-choice treatment in populations with < 15–20% clarithromycin resistance. In populations with < 40% metronidazole resistance, PPI-clarithromycin-metronidazole is preferable. Quadruple treatments are alternative first-choice treatments.
3. The same first-choice *H. pylori* treatments are recommended worldwide, although different doses may be appropriate.

Malfetheriner P, Megraud F, Bazzoli F, et al. Current concepts in the management of *Helicobacter pylori* infection: the Maastricht III Consensus Report. *Gut*. 2007;56:772–781.

decreases the prevalence of metronidazole-resistant *H. pylori* strains. The prevalence of clarithromycin-resistant strains varies greatly from country to country, with the highest rates reported in southern Europe. In this region, clarithromycin resistance now approximates 15%. This rate is predicted to rise over the next several years with increasing use of macrolide antibiotics. In patients failing therapy, culture of *H. pylori* from gastric mucosa is possible for resistance testing. Also, a recent multicenter trial in Spain demonstrated that a 10-day regimen of levofloxacin (500 mg BID), amoxicillin (1 g BID), and omeprazole (20 mg BID) had 97% compliance and 77% eradication based on a negative <sup>13</sup>C urea breath test done 4–8 weeks after completion of therapy.<sup>10</sup>

## NONULCERATIVE DYSPEPSIA

Dyspepsia is a very common symptom complex that is characterized by pain and discomfort centered in the upper abdomen. Dyspepsia is among the most common disorders encountered by primary care physicians and gastroenterologists in the United States and Western countries. It is estimated that approximately 25% of the population will experience dyspepsia and that this problem accounts for 5% of visits to primary care providers.

Dyspepsia is characterized by symptoms that are focused in the upper abdomen. Symptoms may include heartburn, but a symptom complex limited to this complaint suggests gastroesophageal reflux disease and excludes the diagnosis of dyspepsia. Nonulcerative dyspepsia is considered when no anatomic or biochemical abnormality is discovered that explains the patient's symptoms. This common disorder is not associated with increased morbidity or mortality. However, it is generally long lasting and responsible for impaired quality of life. Investigation of nonulcerative dyspepsia and its treatment represent a large economic burden. Optimal treatment is controversial.

Since the description of *H. pylori* as a cause of gastritis, its association with nonulcerative dyspepsia has been disputed. *H. pylori* infestation is always associated with histologic gastritis, but may be absent in cases of nonulcerative dyspepsia. A large number of studies have reported the efficacy of therapy for *H. pylori* infection on symptoms of nonulcerative dyspepsia.<sup>11–13</sup> A recent Cochrane review of the literature showed a small but statistically significant effect of *H. pylori* treatment in nonulcer dyspepsia but recommended further research before making any definitive recommendations.<sup>14</sup>

For surgeons, the importance of nonulcerative dyspepsia relates to its place in the differential diagnosis of epigastric pain. There is no role for surgery in the treatment of this disorder.

## PEPTIC ULCER DISEASE

### Epidemiology

Peptic ulcer disease is a major public health problem in the United States and a source of substantial health care expenditure.<sup>15</sup>

Overall, peptic ulcer mortality and hospitalization rates have declined for the past two decades from over 200,000 admissions in 1993 down to a little over 150,000 in 2006. Hemorrhage continues to be the most frequent presentation at admission, followed by perforation and obstruction. A significant shift was also seen in the management of ulcer hemorrhage from surgery (21% decrease) to endoscopy (59% increase). Although overall mortality rates decreased slightly (2.7%, down from 3.8%), no change was seen in the determinants of mortality, with perforation still being associated with the highest mortality, followed by obstruction and then bleeding. The mortality from surgical intervention decreased over the time period but remains high compared to endoscopy and embolization.<sup>16</sup>

In parallel with the discovery of *H. pylori* and the subsequent development of improved therapies for its eradication, surgical treatment of peptic ulcer has changed dramatically, with the virtual elimination of elective operations for ulcer disease. Operative therapy is now used mostly for emergent treatment of complicated disease. Antibiotics have become primary antiulcer therapy with the realization that, in most cases, peptic ulceration is an infectious disease. A wide variety of antisecretory drugs are available for clinical practice. Endoscopic and surgical therapies are frequently integrated in the care of individual patients.

### Pathophysiology

The pathogenesis of peptic ulceration is multifactorial but increasingly understood to be a consequence of *H. pylori* infection. Before the recognition of the role of *H. pylori*, ulcer disease was conceived as an imbalance between acid and pepsin secretion and mucosal defense, with the balance shifted toward peptic injury and disease. In groups of patients, increases in acid secretion are well-documented, and, although gastric acid is crucial in the development of ulcers, an acquired defect in mucosal defense exists to tip the balance away from health. Mucosal infestation with *H. pylori* is the factor that contributes to ulceration in most patients; nonsteroidal anti-inflammatory drug (NSAID) use is the second most important factor in ulcer pathogenesis.

## OTHER FACTORS

Substantial evidence implicates cigarette smoking as an additive risk factor in the development of duodenal ulcers. Smokers appear to have an increased risk of developing *H. pylori* infection relative to nonsmokers. Cigarette smoking impairs ulcer healing and increases the risk of recurrent ulceration. Continued smoking blunts the effectiveness of active ulcer therapy. Cigarette smoking increases both the probability that surgery will be required and the risks of operative therapy. When *H. pylori* is eradicated in smokers, they appear to have no greater risk of peptic ulceration than nonsmokers.<sup>17,18</sup> This observation suggests that smoking is probably not an independent risk factor for ulcer disease but acts by increasing the harmful effects of

bacterial infection. Cessation of smoking is a key goal of anti-ulcer therapy.

Abnormalities of gastric acid secretion in patients with peptic ulceration have been recognized for more than 50 years. The formation of duodenal ulcers clearly depends on gastric secretion of acid and pepsin. This association is emphasized by the dictum “no acid-no ulcer.” *H. pylori* infection is now known to secondarily induce alterations in gastric acid secretion as a prerequisite for ulcer development, and a more complete and accurate statement might be “no acid and no *H. pylori*—no ulcer.”

Abnormalities of mucosal function have been invoked as contributing factors to peptic injury. In support of this concept, several agents that are used to treat peptic ulceration are cytoprotective. Cytoprotective agents inhibit mucosal injury at concentrations lower than threshold doses that suppress acid secretion.<sup>19</sup> The ability of such agents to heal ulcers suggests that abnormalities in mucosal defense, in addition to abnormalities in acid secretion, cause ulceration. Most cytoprotective agents act via mucosally secreted bicarbonate or on mucosal prostaglandin production.

NSAIDs are a major risk factor for the development of acute ulceration and for hemorrhagic complications of ulceration. NSAIDs produce a variety of lesions, ranging from superficial mucosal erosions to deeper ulcerations. While the mucosal injury caused by NSAIDs is more common in the stomach than in the duodenum, ulcer complications occur with equal frequency in these two sites. *H. pylori* and NSAID use independently increase the risk of peptic ulcer and ulcer bleeding. These agents also act synergistically. In the duodenum, it appears likely that invasive *H. pylori*-associated ulcers are compounded by the direct injurious effects of NSAIDs.

The injurious actions of NSAIDs are secondary to systemic suppression of prostaglandin production. Numerous experimental models have demonstrated that NSAIDs injure the gastroduodenal mucosa. Ulcers resembling those occurring in humans can be produced by administration of NSAIDs to animals, and NSAID-associated gastric ulcers can be prevented by the coadministration of prostaglandin analogues. Ulcers associated with NSAIDs heal rapidly when the drug is withdrawn, corresponding temporally to reversal of antiprostaglandin effects.

None of the currently available NSAIDs are free of the hazard of gastroduodenal ulceration.<sup>19</sup> Clinically significant ulceration of the stomach and duodenum is estimated to occur at a rate of 2–4% per patient-year. The risks of long-term NSAID use are increased by *H. pylori* infection and cigarette smoking. The incidence of NSAID-related ulcer complications is highest in older patients, as is attendant mortality rate. Peptic ulcer disease is rare in individuals who are *H. pylori*-negative and who do not receive NSAID medications.<sup>20</sup>

## Diagnosis

Duodenal ulceration is characterized by epigastric pain. The pain is usually localized to the upper abdomen without radiation and is described as burning, stabbing, or gnawing. In the absence of complications such as perforation or penetration into the

head of the pancreas, referral of pain to extra-abdominal sites is not common. Many patients report that pain is worsened by fasting. Ingestion of antacids usually provides prompt relief. In uncomplicated cases, physical examination is usually normal.

The differential diagnosis includes a variety of diseases originating in the epigastrium and upper GI tract. Common disorders to be distinguished include nonulcer dyspepsia, gastritis, gastric neoplasia, cholelithiasis and related diseases of the biliary system, neoplastic lesions of the liver, and both inflammatory and neoplastic disorders of the pancreas. In dyspeptic patients, especially those older than 50 years of age, the most important differential diagnoses are peptic ulceration and gastric cancer.

The evaluation of patients with suspected peptic ulceration usually involves endoscopic examination of the esophagus, stomach, and duodenum. In most circumstances, contrast radiography is not the preferred initial diagnostic method; endoscopy has become the standard to which other modalities are compared. Endoscopy eliminates the need for radiation, is safe, is tolerated by elderly patients, and permits both visual inspection and biopsy of the esophagus, stomach, and duodenum. In controlled trials, endoscopy was both more sensitive (92 vs 54%) and more specific (100 vs 91%) than radiographic examination.<sup>21</sup> Endoscopy must be utilized with discretion because of the potential for perforation (approximately 1 per 5000 cases) and cost.

Endoscopically, duodenal ulceration is characterized by lesions that are erosive to the intestinal wall. When viewed endoscopically, peptic ulcers have a typical appearance, with edges that are usually sharply demarcated. The ulcer consists of the exposed underlying submucosa. With chronic ulcers, the base is usually clean and smooth. Acute ulcers and ulcers with recent hemorrhage may demonstrate clot, eschar, or adherent exudate. The surrounding duodenal mucosa may be friable, but marked inflammation is uncommon. The most frequent site for peptic ulceration is the first portion of the duodenum, with the second portion less frequently involved. Peptic ulceration of the third or fourth portions of the duodenum is distinctly unusual; occurrence of ulcers in these locations raises the possibility of gastrinoma. Peptic ulcers in the pyloric channel or the prepyloric area are similar in appearance to duodenal ulcers. Endoscopic demonstration of a duodenal ulcer does not require duodenal biopsy but should prompt mucosal biopsy of the gastric antrum to demonstrate the presence of *H. pylori* and guide subsequent therapy.

Contrast radiographs demonstrate retention of contrast within the ulcer. When viewed tangentially, the ulcer projects beyond the level of the duodenal mucosa. Distortion of the duodenal bulb by spasm or scarring is a secondary sign of current or previous ulceration.

## OPERATIVE TREATMENT OF ULCER DISEASE

The realization that peptic ulceration is an infectious disease has fundamentally altered the role of surgery in ulcer treatment.<sup>22,23</sup> Indications for operative intervention have changed over the past 20 years as a consequence, with the virtual elimination of



elective operations.<sup>24</sup> Operative intervention is now reserved for the treatment of complicated ulcer disease. Three complications are most common and constitute contemporary indications for peptic ulcer surgery: hemorrhage, perforation, and obstruction. Evolving indications are also reflected in the forms of operative therapy and in surgical training experience.<sup>25,26</sup>

The first goal of current surgical therapy is treatment of anatomic complications, such as pyloric stenosis or perforation. The second major goal should be patient safety in the acute setting, combined with freedom from undesirable chronic side effects. The third goal in contemporary surgical treatment of complicated ulcer disease should be alteration of the ulcer diathesis so that ulcer healing is achieved and recurrence is minimized. To achieve these goals, the gastric surgeon can combine therapy through endoscopic, radiologic, or operative means, the appropriate choice depending on the clinical circumstances.

## Operative Procedures

There is currently no indication for surgical treatment of uncomplicated ulcer disease. A number of operative procedures have been developed to treat peptic ulcer but have been used with decreasing frequency in the past decade. Operative treatment of gastric outlet obstruction has decreased by approximately 50%. The majority of surgical patients are currently treated emergently for the complications of bleeding or perforation.

Truncal vagotomy and drainage, truncal vagotomy and antrectomy, and proximal gastric vagotomy are the most widely utilized procedures in the operative treatment of peptic ulcer disease. However, surgical therapy of complicated peptic ulcer disease is directed increasingly at correction of the immediate problem without gastric denervation. The underlying cause of the ulcer diathesis may then be addressed after recovery from surgery by antibiotic therapy directed at *H. pylori* and by long-term acid suppression therapy. This approach is applicable to most patients with peptic ulcer undergoing emergent operation and is also reflected by the fact that the use of gastrectomy and vagotomy has decreased significantly from 4.4 to 2.1% (gastrectomy) and 5.7 to 1.7% (vagotomy) over the last two decades.<sup>16</sup>

Transection of both vagal trunks at the esophageal hiatus, termed *truncal vagotomy*, denervates the acid-producing fundus of the stomach. The procedure also denervates the remainder of the supplied viscera, including the liver and biliary tree, pancreas, small bowel, and colon to the midtransverse portion. Because denervation impedes normal pyloric coordination and impairs gastric emptying, truncal vagotomy is usually combined with a procedure to eliminate or bypass pyloric sphincter function. A pyloroplasty or gastrojejunostomy is performed for gastric drainage.

Several methods of pyloroplasty have been developed. The Heineke-Mikulicz pyloroplasty (Fig. 21-1) consists of a longitudinal incision of the pyloric sphincter extending into the antrum and the duodenum. The incision is closed transversely, eliminating sphincteric closure and increasing the lumen of the pyloric channel.

The Finney pyloroplasty (Fig. 21-2) extends the pyloric incision 5 cm onto the duodenal wall forming an inverted

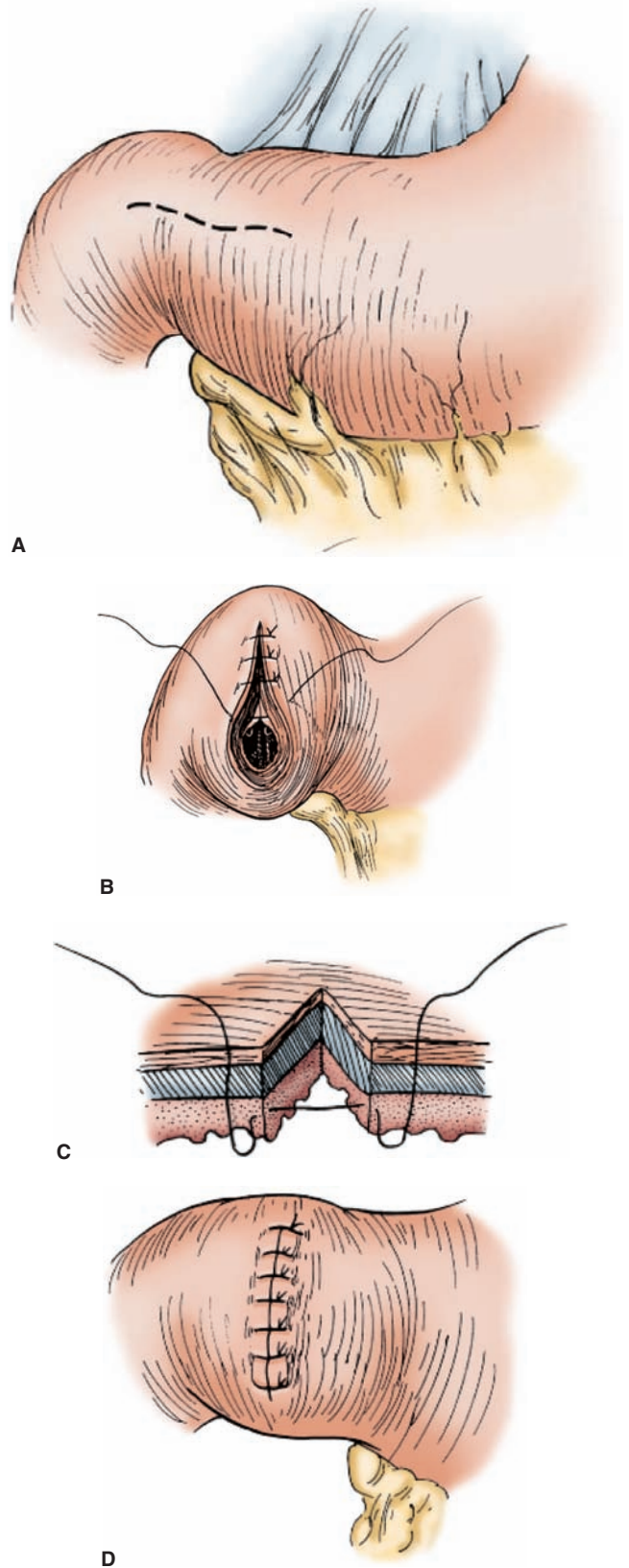


FIGURE 21-1 Heineke-Mikulicz pyloroplasty. (Redrawn with permission from Zinner MJ. *Atlas of Gastric Surgery*. New York, NY: Churchill Livingstone; 1992. Illustrated after Gwynne Gloege.)

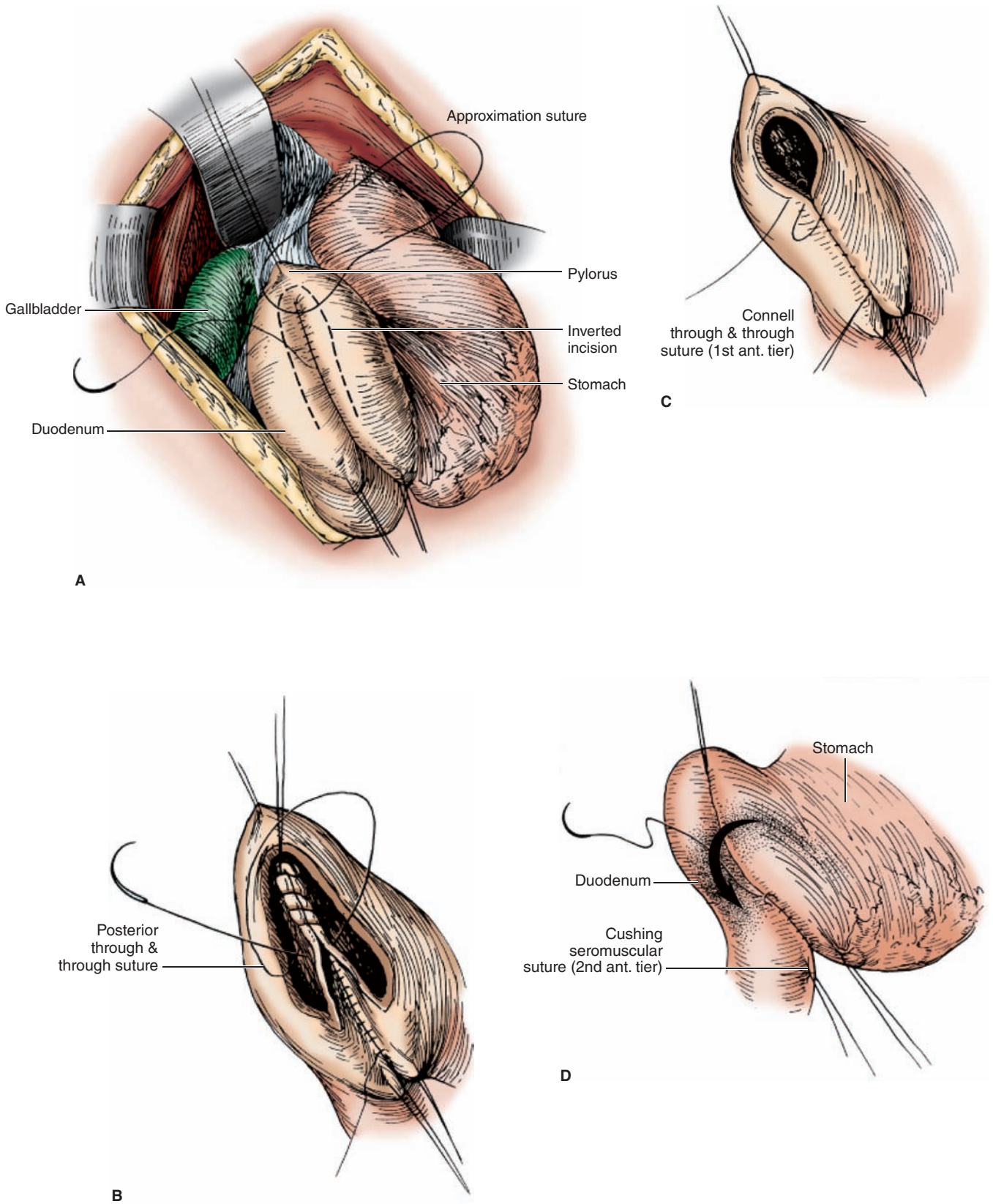


FIGURE 21-2 Finney pyloroplasty (From Soybel DI, Zinner MJ. Stomach and duodenum: operative procedures. In: Zinner MJ, Schwartz SI, Ellis H, eds. *Maingot's Abdominal Operations*. 10th ed. London, UK: Prentice Hall Inc.; 1997:Chap. 13.)

U-shaped incision after the placement of superior and inferior traction sutures. Once traction is applied, the two limbs of the inverted U-shaped incision are lined up and sutured to each other to complete the procedure, with the inferior suture line forming the posterior wall and the superior suture line forming the anterior wall of the pyloroplasty.

A Jaboulay gastroduodenostomy (Fig. 21-3) requires more extensive dissection beginning with a Kocher maneuver followed by corresponding incisions on the stomach and the duodenum proximal and distal to the pylorus respectively. Traction sutures are then placed between the stomach and duodenum to approximate the two incisions, and the anastomosis is then performed.

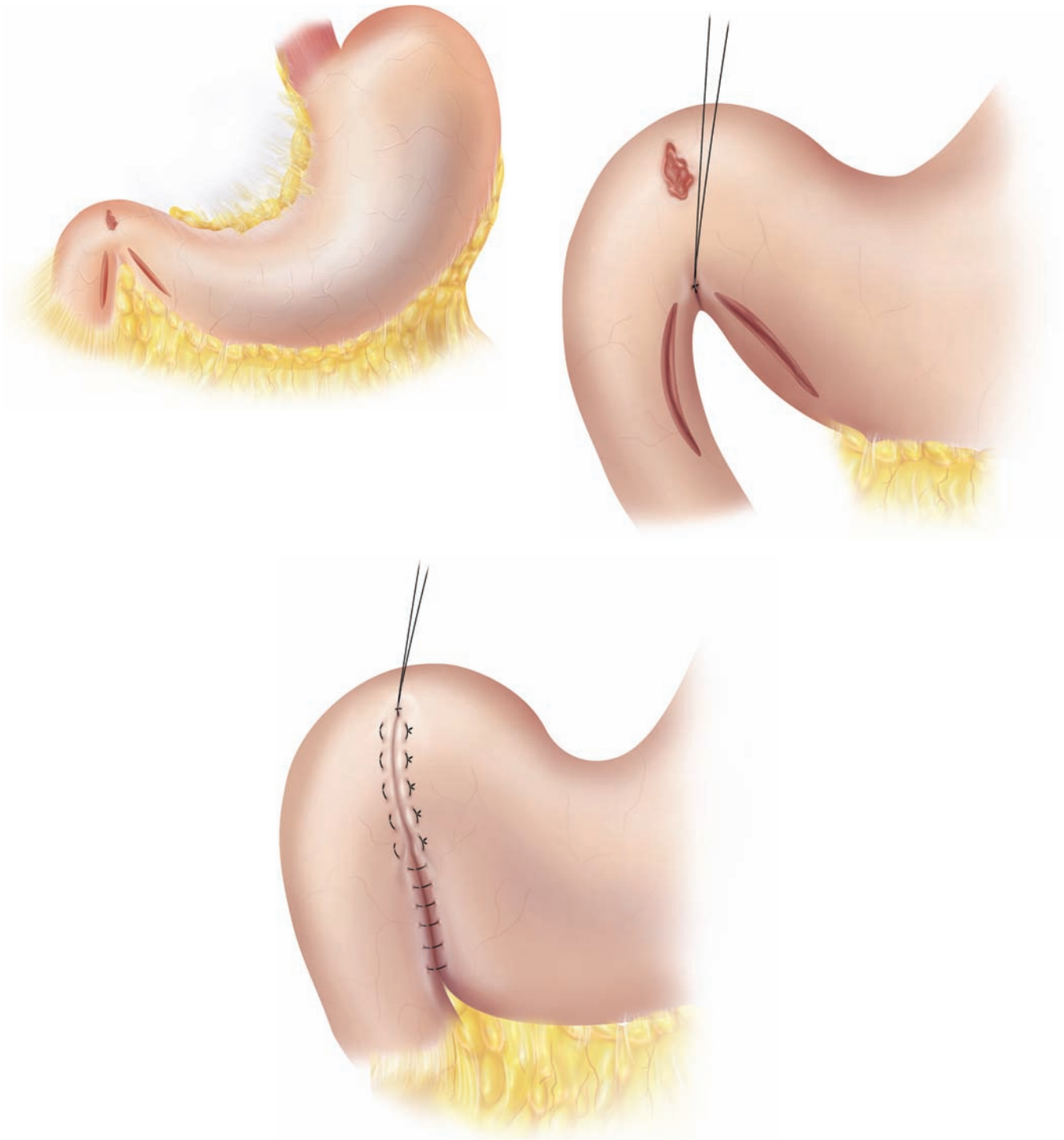


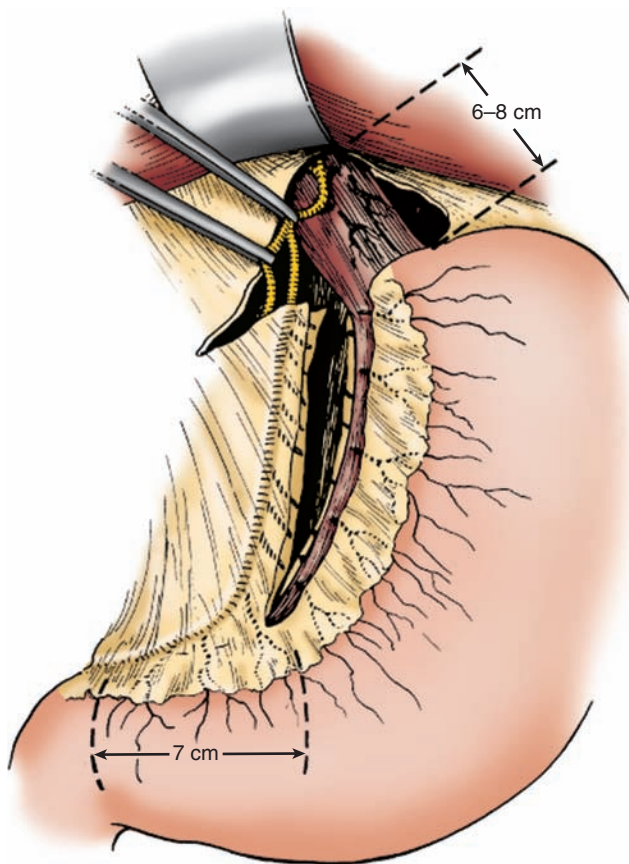
FIGURE 21-3 Jaboulay gastroduodenostomy.



Truncal vagotomy can be combined with resection of the gastric antrum to further reduce acid secretion by removing antral sources of gastrin. The limits of antral resection are defined by external landmarks. The stomach is divided proximally along a line from a point above the incisura angularis to a point along the greater curvature midway from the pylorus to the gastroesophageal junction. Reconstruction via a gastroduodenostomy is called a *Billroth I procedure*. A *Billroth II procedure* uses a gastrojejunostomy to restore GI continuity.

Proximal gastric vagotomy, also termed *highly selective vagotomy* (HSV), differs from truncal vagotomy in that only the nerve fibers to the acid-secreting fundic mucosa are transected (Fig. 21-4). The hepatic and celiac divisions are not divided, and vagal nerve fibers to the antrum and pylorus remain intact. The operation has also been called parietal cell vagotomy to emphasize the intended functional consequence.

Proximal gastric vagotomy is a safe operation. The procedure has a reported operative mortality rate of less than 0.05%, lower than the reported mortality for any other gastric procedure for peptic ulcer. Truncal vagotomy and pyloroplasty has an accepted mortality rate of 0.5–0.8%, whereas mortality



**FIGURE 21-4** Technique of proximal gastric vagotomy. The distal 6 cm of the esophagus is skeletonized. Denervation spares the antrum and pylorus by stopping 7 cm proximal to the pylorus. (Reproduced with permission from Holle F, Anderson S. *Vagotomy: Latest Advances*. New York: Springer; 1994.)

after truncal vagotomy and antrectomy approximates 1.5%. These statistics require an important caveat; almost all large series report the results of elective operations on patients with peptic ulceration and may not accurately reflect expected results when similar procedures are performed emergently.

## Postoperative Alterations

Division of vagal nerve fibers alters gastric acid secretion by reducing cholinergic stimulation of parietal cells. Vagal denervation also decreases parietal cell responsiveness to gastrin and histamine. Basal acid secretion is diminished by approximately 80% in the immediate postoperative period and is maintained over time. The maximal acid output in response to secretagogues such as pentagastrin is reduced by approximately 70%. After 1 year, pentagastrin-stimulated maximal acid output increases to 50% of prevagotomy values but remains at this level on subsequent testing. Acid secretion due to meal stimulation is reduced by 60–70% relative to normal subjects. The inclusion of antrectomy to truncal vagotomy further reduces acid secretion. Maximal acid output is reduced by 85% relative to values recorded before antrectomy.

Both forms of vagotomy cause postoperative hypergastrinemia. Fasting gastrin values are increased to approximately twice preoperative levels. Postprandial gastrin response is exaggerated. Hypergastrinemia is due to decreased luminal acid, with loss of feedback inhibition of gastrin release. Chronic hypergastrinemia is caused by mucosal gastrin cell hyperplasia in addition to loss of inhibitory feedback. When antrectomy is performed, circulating gastrin levels are decreased. Basal gastrin values are reduced by approximately half and postprandial gastrin levels by two-thirds.

Operations that involve vagotomy affect gastric emptying. Both truncal vagotomy and proximal gastric denervation abolish vagally mediated receptive relaxation that normally allows the ingestion of a meal with no increase in intragastric pressure. After vagotomy, the intragastric pressure rise is greater for any given volume ingested, and the gastroduodenal pressure gradient higher than in normal subjects. As a result, emptying of liquids, which depends on the gastroduodenal pressure gradient, is accelerated. Because nerve fibers to the antrum and pylorus are preserved with proximal gastric vagotomy, the function of the distal stomach to mix solid food is preserved and emptying of solids is nearly normal. Truncal vagotomy affects the motor activity of the distal stomach, and solid and liquid emptying rates are usually increased when truncal vagotomy is accompanied by pyloroplasty.

Dumping is defined by a postprandial symptom complex of abdominal discomfort, weakness, and vasomotor symptoms of sweating and dizziness. Dumping occurs transiently in 10–15% of patients after truncal vagotomy and antrectomy and is persistent in 1–2%. Dumping is present initially in 10% of patients undergoing truncal vagotomy and pyloroplasty, and remains in approximately 1%. Permanent symptoms of dumping are unusual after proximal gastric vagotomy. The incidence of diarrhea, presumably caused by denervation of the pylorus



and small bowel and by elimination of pyloric function, parallels the incidence of dumping when truncal vagotomy is performed. Persistent and disabling diarrhea is present in fewer than 1% of patients after proximal gastric vagotomy.

The largest surgical series examining ulcer recurrence rates were reported at a time before the pathogenic role of *H. pylori* was appreciated. With appropriate use of antibiotics directed against *H. pylori*, ulcer recurrence rates as low as 0.22% have been reported.<sup>27</sup> Although recurrence rates (without *H. pylori* treatment) as low as 5% have been reported, a more generally representative figure is 10%. This rate is similar to that of reinfection with *H. pylori* after successful eradication. Ulcer recurrence rates after proximal gastric vagotomy can be adversely affected by the inclusion of prepyloric and pyloric channel ulcers. Proximal gastric vagotomy is significantly less effective when used to treat ulcers in this position than when used for duodenal ulceration.

## Ulcer Hemorrhage

Hemorrhage continues to be a major source of morbidity in patients with peptic ulceration. Bleeding is the leading cause of death associated with peptic ulcer. The incidence of hemorrhage has not changed since the introduction of H<sub>2</sub>-receptor antagonists.<sup>23</sup> The lifetime risk of hemorrhage for patients with duodenal ulcer who do not undergo specific therapy approximates 35%. Hemorrhage usually occurs during the initial episode of ulceration or during relapse; patients who have bled previously have a higher risk of bleeding again. Patients with recurrent bleeding and elderly patients are at greatest risk of death.<sup>25,28</sup>

The risk of mortality from bleeding peptic ulcer is surprisingly high at 10–20%. When surgery is necessary, operative risk is increased in patients who have shock at admission, recurrent bleeding, delay in operative intervention, or comorbid illnesses. Surgical delay leads to recurrent hypovolemia and subsequently multisystem organ failure.

Upper GI endoscopy is the appropriate initial diagnostic test, following resuscitation, when hemorrhage from ulceration is suspected. Endoscopy identifies the site and source of bleeding in over 90% of patients. An ulcer should be accepted as the bleeding source only if it exhibits stigmata of active or recent hemorrhage (Table 21-2). Active hemorrhage is defined by an arterial jet, active oozing, or oozing beneath an adherent clot. Signs of recent hemorrhage include adherent clot without oozing, adherent slough in the ulcer base, or visible vessel in the ulcer. Up to 30% of patients who have stigmata of recent hemorrhage experience rebleeding, and most of the patients who bleed recurrently require emergency treatment. The signs are not sufficiently accurate, nor are rebleeding rates high enough, to be indications for surgery. Endoscopic stigmata indicate that aggressive therapy is needed and close follow-up mandatory. The occurrence of hypovolemic shock, rebleeding during hospitalization, and a posteroinferior location of the ulcer are clinical features that are associated with increased risk of recurrent bleeding. Acute



**TABLE 21-2: ULCER STIGMATA AND REBLEEDING IN PEPTIC ULCERS**

	Prevalence (%)	Rebleeding (%)
Active arterial bleeding	12	88
Nonbleeding visible vessel	22	50
Nonbleeding flat clot	10	33
Oozing	14	10
Nonbleeding flat spots	10	7
Clean ulcer base	32	3

Machicado G. Thermal probes alone or with epinephrine for the endoscopic haemostasis of ulcer haemorrhage. *Baillieres Clin Gastroenterol.* 2000;14:442–458.

reduction of acid secretion by H<sub>2</sub>-receptor antagonists or proton pump inhibitors is not sufficient to prevent recurrent hemorrhage. However, the continuous infusion of proton pump inhibitors has been shown to decrease rebleeding.<sup>26</sup>

The ability to visualize bleeding duodenal ulcers endoscopically permits endoscopic treatment. Methods of endoscopic therapy include thermal coagulation by bipolar electrocoagulation or direct application of heat through a heater probe.<sup>29</sup> Injection of epinephrine into the base of the bleeding ulcer is also an established method to control ulcer hemorrhage.

Both reduced rebleeding rates and avoidance of operation have been demonstrated for endoscopic hemostasis.<sup>29,30</sup> Proof of efficacy for endoscopic treatment of hemorrhage is complicated by the 70% rate of spontaneous, sometimes temporary, cessation of bleeding without intervention (Table 21-3). In addition to endoscopic stigmata, hemodynamic instability, continuing transfusion requirements, red stool or hematemesis, age older than 60 years, and medical comorbidity are clinical features that mandate endoscopic therapy. Rebleeding during hospitalization and the endoscopic findings of visible vessel, oozing, or bleeding associated with an adherent clot are also indications for endoscopic hemostasis. Ulcers with clean bases and no stigmata of recent hemorrhage require no treatment.

Failure of endoscopic treatment is usually due to inaccessibility of the ulcer that is caused by pyloric scarring, rapid active bleeding, or an obscuring clot. Patients treated endoscopically should be observed closely for further hemorrhage. Those who rebleed within 72 hours of initial endoscopic control may be successfully retreated without increased risk of mortality.<sup>30</sup>



**TABLE 21-3: FAILURE RATES FOR ENDOSCOPIC HEMOSTASIS**

Rebleed (%)	Urgent Surgery (%)	Mortality (%)
0–40	0–32	0–16

Data from Lundell L. Upper gastrointestinal hemorrhage—surgical aspects. *Dig Dis.* 2003;21:16–18.

**TABLE 21-4: REBLEEDING RATES BY PROCEDURE FOR BLEEDING PEPTIC ULCER**

Ulcer Suture or Excision (%)	Truncal Vagotomy and Pyloroplasty (%)	Truncal Vagotomy and Antrectomy (%)
10–30	0–30	0–10

Data from Legrand MJ, Jacquet N. Surgical approach in severe bleeding peptic ulcer. *Acta Gastroenterol Belg.* 1996;59:240–244.

The efficacy of endoscopy diagnosis and therapy depends on timing. Early endoscopy correctly classifies patients as low risk for recurrent hemorrhage and permits safe avoidance of hospitalization. Early endoscopy also benefits high-risk patients by directing specific, active hemostatic therapy. Patients with early endoscopy have been demonstrated to have fewer episodes of rebleeding, lower rates of operation, less resource consumption, and shorter hospitalizations.<sup>31</sup>

Operative intervention is indicated for the following:

- Massive hemorrhage leading to shock or cardiovascular instability
- Prolonged blood loss requiring continuing transfusion
- Recurrent bleeding during medical therapy or after endoscopic therapy
- Recurrent hemorrhage requiring hospitalization

The need for emergency intervention significantly increases surgical risks, and not surprisingly, mortality is increased 10-fold. Emergent operative therapy should consist of duodenotomy with direct suture ligation of the bleeding vessel in the ulcer base (Table 21-4). Postoperatively, patients should receive proton pump inhibitors and antibiotics directed against *H. pylori*. This treatment approach is based on the observation, in medically treated patients, that peptic ulcer hemorrhage recurs in 20% of patients when *H. pylori* is not eradicated, while rebleeding is reduced to 3% in patients who receive *H. pylori* antibiotic therapy.<sup>31–34</sup> This recommendation is an extrapolation; the studies that support this practice were not designed to evaluate postoperative hemorrhage (Table 21-5).

## PERFORATION

The lifetime risk for perforation in patients with duodenal ulceration not receiving therapy approximates 10%, while ulcer perforation is unusual if initial ulcer healing has been achieved. Duodenal ulcer perforation is followed by sudden and severe epigastric pain. The pain is caused by contact of the peritoneum with highly caustic gastric secretions. Pain is often instantaneous and remains constant. Peritoneal irritation is usually intense and causes most patients to avoid movement.

Physical examination reveals fever, diminished bowel sounds, rigidity of the abdominal musculature, and guarding.

**TABLE 21-5: ERADICATION OF *H. PYLORI* AND ULCER REBLEEDING**

Treatment Group		
No. of Patients	Eradication Rate (%)	Rebleeding (%)
133	83	6
Control Group		
No. of Patients	Eradication Rate (%)	Rebleeding (%)
129	4	28

Data from Sharma VK, Sahai AV, Corder FA, et al. *Helicobacter pylori* eradication is superior to ulcer healing with or without maintenance therapy to prevent further ulcer hemorrhage. *Aliment Pharmacol Ther.* 2001;15:1939–1947.

Upright abdominal radiographs demonstrate pneumoperitoneum in 80% of cases. If free air is not present, computed tomography of the abdomen is very sensitive for demonstrating perforation.

Occasional reports have described nonoperative treatment of this complication, but this approach is not appropriate for the large majority of patients with perforated peptic ulcer. Perforation is a strong indication for surgery in most circumstances. Laparotomy or laparoscopy affords the opportunity to relieve intraperitoneal contamination and to close the perforation.

The results of surgical treatment of duodenal perforation in the era preceding the recognition of *H. pylori* are instructive. Signs of preexisting duodenal ulceration, in terms of history of prior symptoms and anatomic evidence of duodenal scarring, should be sought, but a lack of antecedent symptoms is not protective. Patients without antecedent symptoms are at substantial risk for recurrent ulceration. By 5–6 years, symptomatic ulcer recurrence in patients with acute ulcer perforation is similar to that for patients with chronic disease. Before the role of *H. pylori* was appreciated, simple omental closure of duodenal perforation had not provided satisfactory long-term results; up to 80% of patients so treated had recurrent ulceration and 10% experienced reperforation. It is now known that four-fifths of all patients with perforation have *H. pylori* infestation and therefore are at risk of recurrent disease.

The mortality of emergency operation for ulcer perforation is most clearly correlated with the existence of preoperative shock, coexisting medical illness, and the presence of perforation beyond 48 hours.<sup>35</sup> For stable patients who receive prompt surgical attention, the operation can be performed with safety.<sup>36</sup> Proximal gastric vagotomy with omental patch closure of the perforation is one option in this circumstance. This procedure has been shown to be both safe and effective in preventing ulcer relapse. Incorporation of the site of perforation as part of a pyloroplasty or resection of the perforation during antrectomy can also be combined with truncal vagotomy. The performance of these operations has declined significantly, however, with the focus on *H. pylori* as the cause of most ulcer recurrences.

Several investigators advocate omental patch closure alone with postoperative anti-*H. pylori* therapy.<sup>37–41</sup> Omental patching can also be accomplished laparoscopically in select patients.<sup>42</sup> This approach rests upon three assumptions: (1) that most perforated duodenal ulcers are caused by *H. pylori*; (2) that the duodenal perforation is small enough that secure closure can be obtained; and (3) that further surgical therapy will be obviated by the effects of postoperative antibiotic therapy and acid suppression. Minimally invasive approaches are becoming frequently performed.

## OBSTRUCTION

Gastric outlet obstruction can develop either acutely or chronically in patients with duodenal ulcer disease. Surprisingly, the incidence of *H. pylori* infection in this subgroup of patients may not be as high as that seen in patients presenting with hemorrhage or perforation.<sup>43</sup> Acute obstruction, due to edema and inflammation, is associated with ulcers in the pyloric channel and the first portion of the duodenum. Pyloric obstruction causes recurrent vomiting and dehydration. Hypochloremic alkalosis, due to loss of hydrochloric acid in gastric secretions, is distinctive of gastric obstruction. Hypokalemia may develop as a secondary renal compensation for alkalosis. Acute gastric outlet obstruction is treated by nasogastric suction, rehydration, and intravenous administration of antisecretory agents. Acute obstruction due to pyloric inflammation resolves with supportive measures within a few days.

Repeated episodes of ulceration can lead to pyloric scarring and a fixed stenosis with chronic gastric outlet obstruction. In cases of recurrent duodenal ulceration, the lifetime risk of chronic pyloric stenosis approximates 10%.

Initial investigation begins with upper GI endoscopy to confirm the site of obstruction and to exclude intrinsic or extrinsic obstruction due to malignancy, the most common cause of gastric outlet obstruction in the modern era. Endoscopic balloon dilation of the area of peptic ulcer obstruction can also be attempted; with success obtained in up to 85% of patients.<sup>44</sup> Most treated patients note immediate symptomatic improvement, but only 40% have sustained improvement by 3 months after balloon dilation. Recurrent symptoms are presumed due to residual scarring in the pyloric channel. In most cases, operative correction is required. This should include treatment of the underlying ulcer disease and relief of the anatomic abnormality. Truncal vagotomy with antrectomy and parietal cell vagotomy with gastrojejunostomy have both been used with success in this circumstance.

## GASTRIC ULCER DISEASE

### Diagnosis

In the United States, benign gastric ulcers are found in approximately 90,000 new patients a year, about one-fifth that of

duodenal ulceration. The opposite is found in Japan where gastric ulcers are 5–10 times more common. Gastric ulcer is more common in men than women and occurs in a patient cohort approximately 10 years older than that of duodenal ulceration. In symptomatic patients, upper GI endoscopy is the preferred method for diagnosing gastric ulceration. The visual appearance of benign and malignant gastric ulcers may be identical, and differentiation may be made only by biopsy. Benign gastric ulcers appear smooth and flat and are often covered by a gray, fibrous exudate. The margin is often raised and erythematous. The ulcer margin is friable and may bleed with manipulation. All gastric ulcers should undergo multiple biopsies, obtained from the perimeter of the lesion. The addition of endoscopic brushings to multiple biopsies increases diagnostic accuracy to approximately 95%.

Although benign gastric ulcers may occur in any location in the stomach, more than half are located along the lesser curvature proximal to the incisura angularis. Fewer than 10% of benign ulcers are located on the greater curvature. Most benign gastric ulcers lay within 2 cm of the histologic transition between fundic and antral mucosa.

Similar to duodenal ulceration, *H. pylori* infection is the key to the pathogenesis of benign gastric ulcers. Antibiotic treatment regimens useful for duodenal ulcer have also been used for benign gastric ulceration. The response of gastric ulcers to antibiotic therapy is equivalent to that of duodenal ulcers. Recurrence of gastric ulcers after *H. pylori* eradication is equal to the rate of reinfection.

In addition to *H. pylori* infection, alterations in gastric motility have been demonstrated in some patients with benign gastric ulcers. Motility defects include delayed gastric emptying, abnormal pyloric sphincter function, prolonged high-amplitude gastric contractions, duodenogastric reflux, and alterations in the gastric migrating motor complex. These alterations have not been definitively demonstrated to be pathogenic, and their relevance to gastric ulceration is unsettled. A definite association between chronic NSAID use and benign gastric ulceration has been recognized. As with duodenal ulceration, cigarette smoking is associated with development of gastric ulceration, and continued smoking impairs medical therapy. Gastric and duodenal ulcers may occur in patients who receive hepatic artery chemotherapy if improper placement of the catheter permits perfusion of gastric and duodenal mucosa. A variety of agents, including 5-fluorouracil, cisplatin, doxorubicin, and mitomycin C, have been implicated.

### Therapy

The primary therapy for benign gastric ulceration is antibiotic treatment of *H. pylori* infection using treatment protocols similar to those for duodenal ulceration. Antibiotic response rates are similar. Cessation of NSAID therapy is required to improve results. Operative treatment is reserved for complications of gastric ulcer, including hemorrhage and perforation. Unlike duodenal ulcer, failure of a recurrent

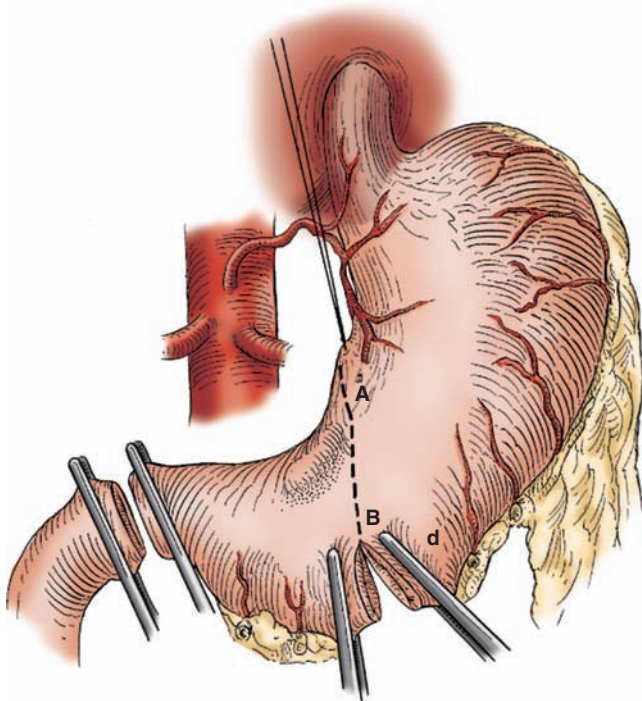


ulcer to respond to medical therapy may be an indication for operation, usually because nonhealing raises concerns about malignant disease.

For benign gastric ulcers, the elective operation of choice is usually a distal gastrectomy with either gastroduodenal (Billroth I) or gastrojejunal (Billroth II) anastomosis. The ulcer should be excised with the gastrectomy specimen (Fig. 21-5). Performed electively, operative mortality approximates 2–3%, and ulcer recurrence rates are less than 5%. Inclusion of vagotomy does not improve recurrence rates, which is not surprising given the variability of acid secretion in patients with gastric ulcers. The occurrence of a benign ulcer near the gastroesophageal junction (type IV ulcer) represents a difficult surgical problem. The ulcer may be excised via a distal gastrectomy with an extension along the lesser curvature and reconstruction with gastrojejunostomy. Emergency treatment of hemorrhage or perforation requires ulcer excision. Distal gastrectomy, including the site of perforation or bleeding, is usually the procedure of choice. Operative mortality rates average 10–20% in the presence of hemorrhage or perforation.

## Intractability or Nonhealing Ulcers

This should indeed be a rare indication for surgery performed today. Arguably, the patient referred for surgical evaluation of intractable peptic ulcer disease should raise red flags for the



**FIGURE 21-5** Points of transection for distal gastrectomy performed to resect a gastric ulcer along the lesser curvature. d, the approximate diameter of the duodenum.



## TABLE 21-6: DIFFERENTIAL DIAGNOSIS OF INTRACTABILITY OR NONHEALING PEPTIC ULCER DISEASE

Cancer
Gastric
Pancreatic
Duodenal
Persistent <i>H. pylori</i> infection
Tests may be false negative
Consider empiric treatment
Noncompliant patient
Failure to take prescribed medication
Surreptitious use of nonsteroidal anti-inflammatory drugs
Motility disorder
Zollinger-Ellison syndrome

Brunicaudi FC, Anderson DK, Billiar TR, et al. *Schwartz's Principles of Surgery*. 8th ed. New York, NY: McGraw-Hill; 2005:969.

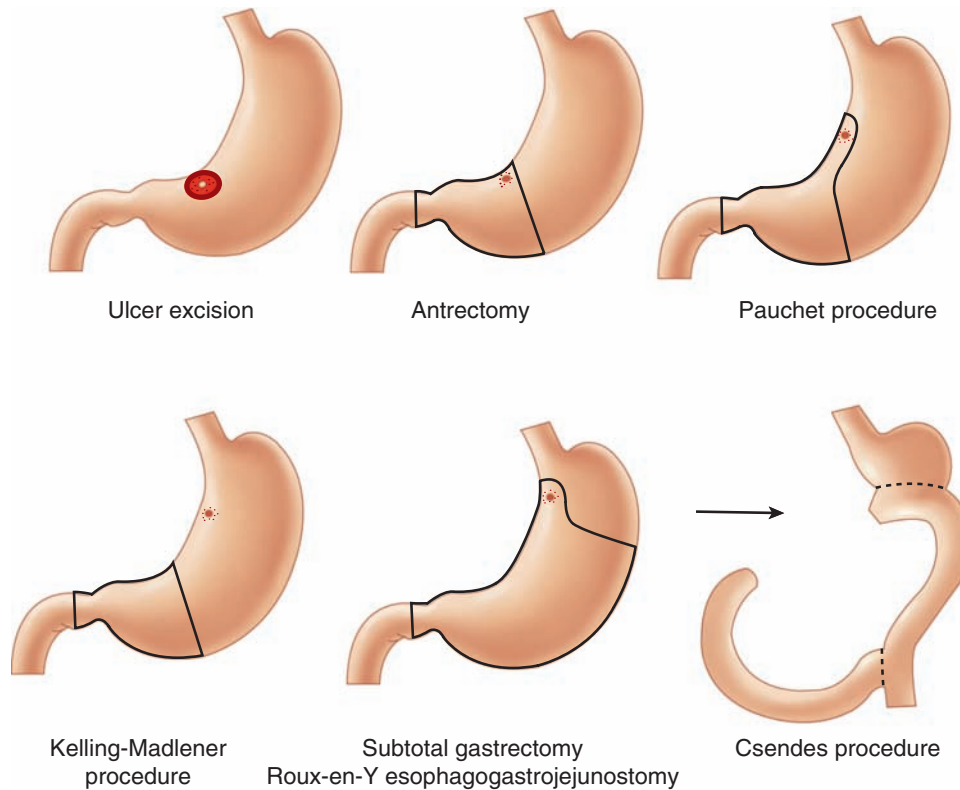
surgeon. Acid secretion can be totally blocked and *H. pylori* eradicated with modern medication; therefore, the question remains: “Why does the patient have a persistent ulcer diathesis?” The surgeon should review the differential diagnosis of nonhealing ulcer prior to any consideration of operative treatment (Table 21-6).

Surgical treatment should be considered in patients with nonhealing or intractable peptic ulcer disease who have multiple recurrences, large ulcers (>2 cm), complications (obstruction, perforation, or hemorrhage), or suspected gastric cancer. Surgery should be approached most cautiously in the thin or marginally nourished individual.

It is important that the surgeon not fall into the trap of performing a large, irreversible operation on these patients, based on the unproven theory that if all other methods have failed, a larger operation is required. Today's patients are different than those of three or four decades ago. One might argue that modern medical care has healed the minor ulcer, and that patients presenting with true intractability or nonhealing will be more difficult to treat and are likely to have chronic problems after a major ulcer operation. If surgery is necessary, less is often better. It is the practice of the authors never to perform a gastrectomy as the initial elective operation for intractable duodenal ulcer in the thin or asthenic patient. Instead, the preferred operation for this group of patients is HSV. In patients with nonhealing gastric ulcer, wedge resection with HSV should be considered in thin or frail patients. Otherwise distal gastrectomy (to include the ulcer) is recommended. It is unnecessary to add a vagotomy in patients with type I gastric ulcer.

Juxtaesophageal gastric ulcers (type IV) are pathophysiologically akin to type I gastric ulcers (ie, associated with gastric acid hyposecretion) but are often difficult to resect as part of a distal gastrectomy. A variety of techniques have been used to treat these ulcers surgically, including the Csendes operation, the Pauchet gastrectomy, and the Kelling-Madlener procedure (Fig. 21-6).





**FIGURE 21-6** Operations for gastric ulcer. (Reproduced with permission from Seymour NE. Operations for peptic ulcer and their complications. In: Feldman M, Scharschmidt BF, Sleisenger MH, eds. *Gastrointestinal and Liver Disease*, 6th ed. Philadelphia, WB Saunders; 1998.)

## POSTGASTRECTOMY SYNDROMES

A number of syndromes have been described after gastric operations performed for peptic ulceration as well as gastric neoplasm. The occurrence of permanent disabling postoperative symptoms is uncommon, occurring only in about 1–3% of cases, and unpredictable. The two most common postgastrectomy syndromes are dumping and alkaline reflux gastritis.

### Dumping

*Dumping* is defined as a postoperative clinical syndrome with gastrointestinal and vasomotor symptoms. The cause of dumping is uncertain but is likely related to unregulated entry of ingested food into the proximal small bowel following resection, bypass, or division of the pyloric sphincter. Early dumping symptoms occur within 1 hour of ingestion of a meal and include nausea, epigastric discomfort, tremulousness, and sometimes dizziness or syncope. Late dumping symptoms follow a meal by 1–3 hours. Late symptoms are usually due to reactive hypoglycemia.

Most patients who undergo vagotomy or gastrectomy do not experience dumping symptoms postoperatively.

For patients who experience mild dumping symptoms in the early postoperative period, dietary alterations, and time bring improvement in all but approximately 1–2%. For those who remain persistently symptomatic, the long-acting somatostatin analogue, octreotide, improves dumping symptoms when administered subcutaneously before a meal.<sup>45</sup> The effects of somatostatin on the vasomotor symptoms of dumping are summarized below (Table 21-7).

#### TABLE 21-7: MECHANISMS OF ACTION OF OCTREOTIDE IN DUMPING SYNDROME

- Delay in the accelerated gastric emptying
- Delay in small intestine transit time
- Inhibition of enteral hormone secretion
- Inhibition of insulin release
- Inhibition of postprandial vasodilation/splanchnic vasoconstriction
- Increase in intestinal absorption of water and sodium

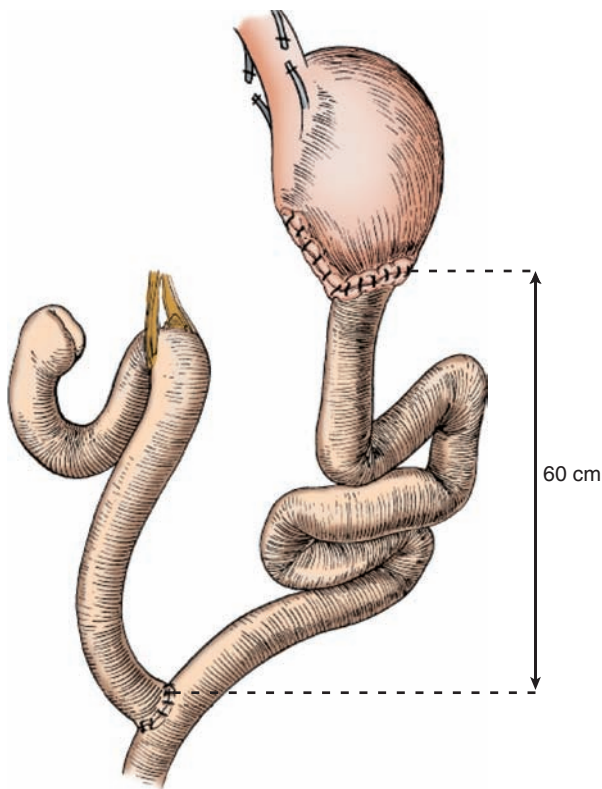
Ukleja A. Dumping syndrome: pathophysiology and treatment. *Nutr Clin Pract.* 2005 Oct;20:517–525.

## Alkaline Reflux Gastritis

Alkaline reflux gastritis is a postoperative syndrome characterized by postprandial epigastric pain associated with nausea and bilious vomiting. Endoscopic examination reveals reflux of bile into the stomach, and biopsy demonstrates histologic evidence of gastritis.

Alkaline reflux gastritis is a diagnosis of exclusion. The differential diagnosis of postoperative epigastric pain includes recurrent ulceration, calculous biliary disease, pancreatic inflammation, afferent loop obstruction, and esophagitis. Upper endoscopic examination is essential to exclude recurrent ulcer. The gastric mucosa appears inflamed, friable, and edematous. Gastric inflammation is often uneven and nonulcerative. Histologic examination shows glandular atrophy, mucosal and submucosal edema, and the presence of acute and chronic inflammatory cells in the lamina propria. Intestinal metaplasia may be present.

Postoperative alkaline reflux gastritis is resistant to medical treatment. Antacids, proton pump inhibitors, and dietary manipulations have not been definitively demonstrated to be beneficial. The most effective treatment for persistent alkaline reflux gastritis is operative diversion of intestinal contents from contact with the gastric mucosa. This solution usually requires conversion of a Billroth I or II gastrectomy to a Roux-en-Y gastrojejunostomy with an intestinal limb of 50–60 cm (Fig. 21-7). The length of the Roux limb prevents



**FIGURE 21-7** Roux-en-Y gastrojejunostomy used to treat alkaline reflux gastritis. (Redrawn from Schwartz SI, Ellis H. *Maingot's Abdominal Operations*. 9th ed. Stamford, CT: Appleton & Lange; 1989:716.)

reflux of intestinal contents. This procedure is very effective in eliminating bilious vomiting. However, persistent pain is reported in up to 30% of patients, and 20% of patients develop postoperative delayed gastric emptying.

## STRESS ULCER DISEASE

Gastritis and gastric ulceration can be induced by physiologic stress. Usually occurring in hospitalized patients with critical illness, stress gastritis can be demonstrated endoscopically in the majority of patients recovering from shock. While occult bleeding in this population is common, clinically significant hemorrhage defined by the need for blood transfusion, hypotension, or alteration in other vital signs occurs in only 0.5–5% of patients. In four recent surgical series comprising more than 28,000 patients, the incidence of clinically significant stress ulceration was 0.4%.<sup>46</sup> In another series of 16,612 hospitalized patients, the incidence of overt stress bleeding was only 0.1%.<sup>47</sup> In a review of patients admitted to both surgical and medical intensive care units (ICUs), the incidence of clinically significant and endoscopically proven stress ulceration was 0.17%.<sup>48</sup>

Major trauma, especially if accompanied by hypotension, sepsis, respiratory failure, hemorrhage, or multiple injuries, predisposes to acute stress gastritis (Table 21-8). Acute stress gastritis is also common after thermal injury with greater than 35% total body surface area burned. A form of gastritis similar to that following trauma may complicate central nervous system injury or intracranial hypertension. When viewed endoscopically, multiple ulcerations are observed in the proximal, acid-secreting portion of the stomach. Fewer lesions are found in the antrum, and only rare ulcerations in the duodenum.

The major complication of stress gastritis is hemorrhage. Patients with coagulopathy and those requiring mechanical ventilation are at increased risk of hemorrhage. Patients without these two risk factors have been reported to have an overall risk of hemorrhage of only 0.1%, while those with both demonstrate clinically significant bleeding in 3.7% of



### TABLE 21-8: RISK FACTORS FOR STRESS ULCER BLEEDING

- Respiratory failure
- Coagulopathy
- Hypotension
- Sepsis
- Hepatic failure
- Renal failure
- Steroids
- Injury Severity Score > 16
- Spinal cord injury
- Age >55 y

cases. Respiratory failure is defined as greater than 48 hours on a mechanical ventilator. Coagulopathy is defined as a platelet count less than 50,000/mm<sup>3</sup>, an international normalized ratio greater than 1.5, or a partial thromboplastin time greater than two times control.

Admission to an ICU by itself does not place patients at risk for hemorrhage, and patients undergoing major GI surgery do not have an increased risk of stress-related bleeding in the absence of complications. Increased patient age, emergency surgery, need for reoperation, and the occurrence of hypotension are risk factors for postoperative gastric bleeding. The occurrence of sepsis and respiratory failure are also risk factors. Multiple regression analysis has shown that mechanical ventilation and coagulopathy impart the greatest risk.

The diagnosis of stress ulceration requires endoscopic examination. Acute mucosal ulcerations may be observed as early as 12 hours postinsult; lesions appear as multiple shallow areas of erythema and friability, accompanied by focal hemorrhage. Histologically, the lesions consist of coagulation necrosis of the superficial endothelium with infiltration of leukocytes into the lamina propria. Signs of chronicity, such as fibrosis and scarring, are absent. With resolution of injury or sepsis, healing is accomplished by mucosal restitution and regeneration.

A survey of Society of Critical Care Medicine members showed that ranitidine, famotidine, sucralfate, and cimetidine were the drugs used most commonly for prophylaxis. The presence of bright red blood in the nasogastric tube was considered by most to define prophylaxis failure, and the addition of a second drug from a different therapeutic class was the preferred mode of treatment.<sup>49</sup>

Because hemorrhage does not occur in all patients, studies that use bloody nasogastric discharge as a sign of stress gastritis underestimate the true incidence in critically ill patients. In one endoscopically controlled study, 100% of patients with life-threatening injuries had evidence of gastric erosions by 24 hours. A high prevalence of gastric erosions is also noted in burn patients, while GI hemorrhage occurs in only 25–50% of patients with burn wound infection. Barium contrast examinations have no role in the diagnosis of stress gastritis and interfere with endoscopic examination.

It is important to distinguish stress ulceration from other causes of postoperative hemorrhage. Several recent studies have demonstrated that duodenal ulceration and gastric ulcers are common in postoperative patients. In one series, sources of clinically significant bleeding included duodenal ulcer in 26%, gastric ulcer in 13%, esophagitis in 18%, and esophageal varices in 7%. Similar results have been reported in other series, emphasizing the need for specific diagnosis.

## UPPER GASTROINTESTINAL BLEEDING

Acute upper gastrointestinal (GI) hemorrhages are frequent medical events occurring at a rate of approximately 50 cases per 100,000 persons per year. Acute GI hemorrhage still

has a significant associated mortality, approximating 10%. Although urgent endoscopy has been used for the past 20 years for the diagnosis and management of acute upper GI hemorrhage, the mortality rate has not substantially declined even with the introduction of endoscopic intervention. Patients with acute upper GI hemorrhage are increasingly of advanced age and have preexisting medical comorbidities.

Endoscopy has become the preferred method for diagnosis in patients with acute upper GI bleeding. This method is informative in most patients, correctly identifying the site and source of bleeding in 90% of cases. While the efficacy of upper endoscopy has been established for diagnosing acute upper GI tract hemorrhage, optimal timing has been controversial. The majority of existing studies support the claim that early endoscopy is both safe and effective for all risk groups.

For low-risk patients, the current evidence demonstrates that early endoscopy promotes safe patient disposition. In many instances, these patients can avoid hospitalization with a very low risk of recurrent bleeding. For high-risk patients, there is benefit of early endoscopy for outcomes, including transfusion requirements, rebleeding rate, and the need for emergency surgery. Early endoscopy directs therapy and significantly reduces length of hospitalization relative to delayed endoscopy without evidence of cost shifting to the outpatient setting. In this sense, early endoscopy provides prompt diagnosis and assists in decision making regarding clinical triage and subsequent management. Current evidence does not demonstrate, however, that early endoscopy decreases overall mortality. There is no evidence that the practice of early endoscopic intervention results in patient harm.

Based on current information, gastroduodenal ulceration accounts for approximately 40% of cases of acute upper GI hemorrhage. Other diagnoses, in decreasing frequency, include acute gastritis, esophageal variceal bleeding, esophagitis, duodenitis, Mallory-Weiss tears, and upper GI tract malignancies.

Initial treatment of upper GI tract hemorrhage begins with restoring intravascular volume. Hemodynamic monitoring is crucial. Unstable patients should be initially treated in an ICU setting. Interestingly, although numerous trials have examined the efficacy of H<sub>2</sub>-receptor antagonists in patients with bleeding peptic ulcers, none of these have demonstrated consistent therapeutic benefit either individually or when examined by meta-analysis. Sixteen prospective trials have also examined the use of proton pump inhibitors in the setting of acute ulcer bleeding. Only 7 of these 16 trials have demonstrated a statistically significant benefit in terms of rebleeding or need for urgent surgical intervention. None of the trials showed a reduction in mortality. Over half (9 of 16) of the studies did not demonstrate reduction in any of the primary outcomes that included rebleeding, surgery, or mortality.

In addition to providing diagnostic information, aggressive endoscopy also presents an opportunity for therapeutic intervention. Relative to medical therapy alone, patients with stigmata of active bleeding, visible vessels, and nonbleeding adherent clots benefit from endoscopic ulcer hemostasis.



The major modalities used include bipolar electrocautery probes, heater probes, and epinephrine injection.

Mechanisms by which epinephrine injections cause ulcer hemostasis have been examined experimentally. Epinephrine causes intense vasoconstriction, platelet aggregation, and vessel sclerosis. These combined effects permit permanent control of arterial hemorrhage in most patients. Absolute alcohol has also been used for injection therapy with good results.

Potential complications of endoscopic therapy include bowel perforation and incitement of active bleeding from a nonbleeding vessel. The rate of perforation is low and has been reported to approximate 0.7%. New bleeding is induced by therapy in fewer than 1% of patients.

Under selective circumstances, repeated attempts at endoscopic therapy may also be used. In a prospective randomized trial, investigators evaluated whether emergency surgery or repeated endoscopic therapy resulted in better outcomes for patients with severe ulcer hemorrhage. Endoscopic therapy consisted of a combination of epinephrine injection and heater probe application. Definitive hemostasis was significantly higher in surgically treated patients (93 vs 73%), but the complication rate was significantly higher in the surgery group (36%) relative to the endoscopy group (15%).

Acute therapy of variceal bleeding may also be directed endoscopically. Major approaches have included variceal injection with sclerosants and band ligation. Because of efficacy and safety, endoscopic variceal ligation has largely replaced sclerotherapy as the endoscopic method of choice for acute variceal hemorrhage.<sup>50</sup> This method has also been used for secondary prevention of esophageal variceal hemorrhage. Prospective randomized trials indicate that prophylactic variceal ligation decreases the risk of first variceal bleeding relative to no treatment or to treatment with propranolol. In addition, ligation decreases the risk of recurrent bleeding and associated mortality relative to no treatment. In this circumstance, however, relative to propranolol therapy, ligation does not improve mortality.

In patients with acute peptic ulcer as a cause for upper GI hemorrhage, *H. pylori* is a common etiology. After initial control of hemorrhage, eradication of infection should be a treatment imperative. Because eradication of *H. pylori* eliminates ulcer recurrence, it is logical to assume that it would also decrease the rate of recurrent ulcer bleeding. Randomized trials demonstrate that recurrent hemorrhage usually occurs in patients who have persistent or recurrent *H. pylori* infection. Without antibiotic treatment, recurrent hemorrhage occurs in as many as 20% of patients. The risk of recurrent hemorrhage can be reduced to approximately 3% in individuals treated with an effective antibiotic regimen after hemorrhage.

## POLYPS

Gastric epithelial polyps are the most common benign tumor of the stomach. There are essentially five types of benign epithelial polyps: adenomatous, hyperplastic (regenerative), hamartomatous, inflammatory, and heterotopic (eg, ectopic

pancreas). The most common gastric polyp (~75% in most series) is the hyperplastic or regenerative polyp, which frequently occurs in the setting of gastritis and has a low but real malignant potential. Adenomatous polyps may undergo malignant transformation, similarly to adenomas in the colon. They constitute about 10–15% of gastric polyps. Hamartomatous, inflammatory, and heterotopic polyps have negligible malignant potential. Polyps that are symptomatic, larger than 2 cm, or adenomatous should be removed, usually by endoscopic snare polypectomy. Consideration should also be given to removing hyperplastic polyps, especially if large. Repeat esophagogastroduodenoscopy (EGD) for surveillance should be done following removal of adenomatous polyps.

A fourfold rise in the incidence of nonfamilial fundic gland polyps has been noted due to the increased use of proton pump inhibitors. However, no increased risk of dysplasia has been noted.<sup>51</sup>

## LIPOMA

Lipomas are benign submucosal fatty tumors that are usually asymptomatic, found incidentally on upper GI series or EGD. Endoscopically they have a characteristic appearance; there also is a characteristic appearance on endoscopic ultrasound. Excision is unnecessary unless the patient is symptomatic.

## BEZOARS

Bezoars are collections of undigestible matter that accumulate in the stomach and small bowel. They are the most common foreign body found in the stomach and may be seen in patients who have undergone prior gastric surgery, including after bariatric surgery.<sup>52–54</sup> The most common bezoar is composed of hair (trichobezoars). It occurs most commonly in young women. Phytobezoars are composed of vegetable matter and are usually seen in association with gastroparesis or gastric outlet obstruction. Other types of bezoars include lactobezoars (concentrated milk formula), mixed medication bezoars, and food bolus bezoars.<sup>55</sup> Bezoars may present with obstruction, ulceration or bleeding, and rarely as intussusception.<sup>56</sup> Diagnosis is suggested by upper GI series and confirmed by endoscopy. Enzyme therapy with papain, cellulase, or acetylcysteine may be used, but most patients will need endoscopic or surgical disruption and extraction.

## DIEULAFOY'S LESION

Dieulafoy's lesion is a congenital arteriovenous malformation of the proximal stomach, typically on the lesser curve where it derives its supply from branches of either the left or right gastric artery. It is seen in middle-aged or elderly men and characterized by an unusually large tortuous submucosal artery. Prior to widespread endoscopy, Dieulafoy's lesions were

diagnosed postoperatively but are now becoming diagnosed and treated routinely via endoscopy.<sup>57</sup> It clinically presents as an upper GI bleed if eroded and on endoscopy appears as a stream of arterial blood emanating from what appears grossly to be a normal gastric mucosa. Patients may also present with intermittent episodes of mild upper GI bleeding, and endoscopy can miss the lesion if it is not actively bleeding. Most lesions are now treated via endoscopic therapy (injection of epinephrine or other sclerosants, electrocoagulation, hemoclipping, rubber band ligation, and photocoagulation) or via angiographic embolization. Surgery is sometimes necessary, at which time the lesion may be oversewn or resected.

Dieulafoy's lesions may occasionally be seen in the duodenum and jejunum, as well as in the colon.<sup>58–60</sup> These lesions have also been successfully managed via endoscopy or surgery.<sup>61</sup>

## DIVERTICULA

Gastric diverticula are typically solitary and may either be congenital or acquired. Congenital diverticula are rare, true diverticula that typically occur near the gastroesophageal junction and are found on the lesser curve or in the posterior area. They will demonstrate all three layers of the gastric wall on endoscopic ultrasound.<sup>62</sup> Acquired or pseudodiverticula usually have a negligible outer muscle layer and are due to either pulsion or traction and most are found in the antrum. Symptoms are due to inflammation and may produce pain or bleeding but perforation is rare. Symptomatic lesions should be removed and can be done laparoscopically.

## Foreign Bodies

Ingested foreign bodies are usually asymptomatic, but removal of sharp or large objects should be considered to avoid bleeding, perforation or obstruction. This can usually be done endoscopically. Aspiration of the foreign body during removal may occur, as well as potential rupture of drug-containing bags in “body packers.” Both complications can be fatal. In body packers as well as in patients with large jagged objects, surgical removal is recommended.

## Mallory-Weiss Tear

The Mallory-Weiss lesion is a longitudinal tear in the mucosa of the GE junction, usually due to forceful vomiting and/or retching, and is commonly seen in alcoholics. It typically presents with impressive upper GI bleeding. Endoscopy confirms the diagnosis and may be useful in controlling the bleeding, but 90% of patients stop bleeding spontaneously. In patients who continue to bleed, balloon tamponade; angiographic embolization; or selective infusion of vasopressin, systemic vasopressin, and surgery are other treatment options. At surgery, the bleeding lesion is oversewn via a long gastrotomy.

## VOLVULUS

Gastric volvulus occurs when the stomach twists around one of its axes, usually seen with a large hiatal hernia. It can also occur in the unusually mobile stomach without a hiatal hernia. Typically, the stomach twists along its long axis (organoaxial volvulus), and the greater curvature flips up. Less frequently, it occurs around the transverse axis, called mesoaxial volvulus. It is usually a chronic condition that can be surprisingly asymptomatic and expectant nonoperative management is usually advised, especially in the elderly. The risk of strangulation and infarction has been overestimated in asymptomatic patients.

Surgery is recommended for symptomatic patients, especially if these are severe and/or progressive. These patients complain of pain and pressure related to the intermittently distending and poorly emptying twisted stomach. Dyspnea, palpitations, and dysphagia may be seen due to compressive effects of the distended stomach on the surrounding organs. Symptoms are often relieved with vomiting or, if possible, passage of a nasogastric tube. The patient who presents moribund most likely has an infarcted stomach and is a case of surgical emergency requiring resection. Elective operation may often be done laparoscopically and usually involves reduction of the stomach and repair of hiatal hernia, with or without gastropexy. Gastropexy alone may be considered for high-risk patients.

## GASTROPARESIS

Gastroparesis is a chronic gastric motility disorder defined by delayed gastric emptying of solids without evidence of mechanical obstruction.<sup>63</sup> Primary gastroparesis affects mostly young and middle-aged women who present with nausea, abdominal pain, early satiety, vomiting, fullness, bloating, anorexia, and weight loss, with nausea and vomiting being the most disquieting of all the symptoms. The condition is diagnosed by symptom assessment and delayed gastric emptying of a solid meal. Gastric retention of more than 10% of the standard low-fat meal at 4 hours is indicative of delayed emptying.

Severe gastroparesis might result in recurrent hospitalizations, malnutrition, and significant mortality. Patients failing medical therapy are often considered for a variety of surgical interventions, the efficacy of which is not well studied. These procedures include gastrostomy, jejunostomy, gastric pacing/stimulation, and gastrectomy or surgical drainage procedures. Completion gastrectomy seems to provide symptom relief in postsurgical gastroparesis.<sup>64</sup>

## LAPAROSCOPIC GASTRIC OPERATIONS

Perhaps the most common laparoscopic gastric operations performed today are for gastroesophageal reflux disease and obesity. Most of the procedures described in this chapter can be performed with minimally invasive techniques.

Some (eg, partial or total gastric resection) are technically difficult or are of debatable merit (eg, laparoscopic resection for cancer).

The operations, described previously, that lend themselves most readily to minimally invasive techniques are highly selective vagotomy, vagotomy and gastrojejunostomy, and gastrostomy. Laparoscopic wedge resection, combined with either intra-operative endoscopic or radiologic localization, often is possible for most localized, benign lesions such as lipomas, or gastric diverticula, although the incision required to retrieve the specimen may be larger than the initial port incisions.<sup>65,66</sup> Combined endoscopic and laparoscopic techniques have also been described.<sup>67</sup> Diagnostic laparoscopy may prevent a futile laparotomy in some patients with gastric cancer. The number as well as the location of ports is determined by triangulating around the target organ, and most procedures can be performed using four to five ports. The benefits of laparoscopic surgery (less post-op pain, quicker recovery, and decreased hospital stay) are all realized without compromising surgical principles of adequate resection and tension-free anastomosis.

## REFERENCES

- Marshall BJ, Warren JR. Unidentified curved bacilli in the stomach of patients with gastritis and peptic ulceration. *Lancet*. 1984;1:1311-1315.
- Atherton JC, Blaser MJ. Co-adaptation of *Helicobacter pylori* and humans: ancient history, modern implications. *J Clin Invest*. 2009;119(9):2475-2487.
- National Institutes of Health. *Helicobacter pylori* in peptic ulcer disease. *NIH Consensus Statement*. 1994;12:1-18.
- Suerbaum S, Michetti P. *Helicobacter pylori* infection. *N Engl J Med*. 2002;347:1175-1186.
- Kokoska ER, Kauffman GL, Jr. *Helicobacter pylori* and the gastroduodenal mucosa. *Surgery*. 2001;130:13-16.
- Blaser MJ. *Helicobacter* are indigenous to the human stomach: duodenal ulceration is due to changes in gastric microecology in the modern era. *Gut*. 1998;43:721-727.
- Atherton JC. The clinical relevance of strain types of *Helicobacter pylori*. *Gut*. 1997;40:701-703.
- Gisbert JP, Pajares JP. Stool antigen test for the diagnosis of *H pylori* infection: a systematic review. *Helicobacter*. 2004;9(4):347-368.
- Malferteiner P, Megraud F, Bazzoli F, et al. Current concepts in the management of *Helicobacter pylori* infection: the Maastricht III Consensus Report. *Gut*. 2007;56:772-781.
- Gisbert JP, Bermejo F, Castro-Fernandez M, et al. Second-line rescue therapy with levofloxacin after *H. pylori* treatment failure: a Spanish multicenter study of 300 patients. *Am J Gastroenterol*. 2008;103:71-76.
- Lassen AT, Pedersen FM, Bytzer P, et al. *Helicobacter pylori* test-and-eradicate versus prompt endoscopy for management of dyspeptic patients: a randomized trial. *Lancet*. 2000;356:455-460.
- Moayyedi P, Soo S, Deeks J, et al. Eradication of *Helicobacter pylori* for non-ulcer dyspepsia [review]. *Cochrane Database Syst Rev*. 2006;2:CD002096.
- Laine L, Schoenfeld P, Fennerty MB. Therapy for *Helicobacter pylori* in patients with nonulcer dyspepsia. *Ann Intern Med*. 2001;134:361-369.
- Moayyedi P, Soo S, Deeks J, et al. Eradication of *Helicobacter pylori* for non-ulcer dyspepsia [review]. *Cochrane Database Sys Rev*. 2006;2:CD002096.
- Logan RPH, Hirschl AM. Epidemiology of *Helicobacter pylori* infection. *Curr Opin Gastroenterol*. 1996;12:1-5.
- Wang, YR, Ritcher JE, Dempsey DT. Trends and outcomes of hospitalizations for peptic ulcer disease in the United States, 1993-2006. *Ann Surg*. 2010;251(1):51-58.
- Parasher G, Eastwood GL. Smoking and peptic ulcer in the *Helicobacter pylori* era. *Eur J Gastroenterol Hepatol*. 2000;12:843-853.
- Sontag S, Graham DY, Belsito A, et al. Cimetidine, cigarette smoking, and recurrence of duodenal ulcer. *N Engl J Med*. 1984;311:689.
- Cryer B. Mucosal defense and repair. *Gastroenterol Clin North Am*. 2001;30:877-894.
- Peskar BM, Maricic N, Gretzer B, et al. Role of cyclooxygenase-2 in gastric mucosal defense. *Life Sci*. 2001;69: 2993-3003.
- Huang JQ, Sridhar S, Hunt RH. Role of *Helicobacter pylori* infection and non-steroidal anti-inflammatory drugs in peptic-ulcer disease: a meta-analysis. *Lancet*. 2002;359:14-22.
- Hopkins RJ, Girardi LS, Turney EA. Relationship between *Helicobacter pylori* eradication and reduced duodenal and gastric ulcer recurrence: a review. *Gastroenterology*. 1996;110:1244-1252.
- Johnson AG. Proximal gastric vagotomy: does it have a place in the future management of peptic ulcer? *World J Surg*. 2000;24:259-263.
- Kleeff J, Friess H, Büchler MW. How *Helicobacter pylori* changed the life of surgeons. *Dig Surg*. 2003;20:93-102.
- Houben MHMG, Van De Beek D, Hensen EF, et al. A systematic review of *Helicobacter pylori* eradication therapy—the impact of antimicrobial resistance on eradication rates. *Aliment Pharmacol Ther*. 1999;13:1047-1055.
- Espat NJ, Ong ES, Helton WS, et al. 1990-2001 U.S. General Surgery chief resident operative experience: analysis of paradigm shift. *J Gastrointest Surg*. 2004;8:471-477.
- Bustamante M, Stollman N. The efficacy of proton-pump inhibitors in acute ulcer bleeding. A qualitative review. *J Clin Gastroenterol*. 2000;30:7-13.
- Gisbert JP, Calvet X, Faust F, et al. Eradication of *Helicobacter pylori* for the prevention of peptic ulcer rebleeding. *Helicobacter*. 2007;12:279-286.
- Millat B, Fingerhut A, Borie F. Surgical treatment of complicated duodenal ulcers: controlled trials. *World J Surg*. 2000;24:299-306.
- Machicado GA, Jensen DM. Thermal probes alone or with epinephrine for the endoscopic haemostasis of ulcer haemorrhage. *Baillieres Best Pract Res Clin Gastroenterol*. 2000;14:443-458.
- Hepworth CC, Swain CP. Mechanical endoscopic methods of haemostasis for bleeding peptic ulcers: a review. *Baillieres Best Pract Res Clin Gastroenterol*. 2000;14:467-476.
- Spiegel BMR, Vakil NB, Ofman JJ. Endoscopy for acute nonvariceal upper gastrointestinal tract hemorrhage: is sooner better? *Arch Intern Med*. 2001;161:1393-1404.
- Gisbert JP, Khorrami S, Carballo F, et al. *H. pylori* eradication therapy vs. antisecretory non-eradication therapy (with or without long-term maintenance antisecretory therapy) for the prevention of recurrent bleeding from peptic ulcer [review]. *Cochrane Database Syst Rev*. 2004;2:CD004062.
- Sharma VK, Sahai AV, Corder FA, et al. *Helicobacter pylori* eradication is superior to ulcer healing with or without maintenance therapy to prevent further ulcer haemorrhage. *Aliment Pharmacol Ther*. 2001;15:1939-1947.
- Leivonen MK, Haglund CH, Nordling SFA. *Helicobacter pylori* infection after partial gastrectomy for peptic ulcer and its role in relapsing disease. *Eur J Gastroenterol Hepatol*. 1997;9:369-374.
- Boey J, Wong J, Ong GB. A prospective study of operative risk factors in perforated duodenal ulcers. *Ann Surg*. 1982;195:265.
- Matsuda M, Nishiyama M, Hanai T, et al. Laparoscopic omental patch repair for perforated peptic ulcer. *Ann Surg*. 1995;221:236-240.
- Lau W-Y, Leung K-L, Kwong K-H, et al. A randomized study comparing laparoscopic versus open repair of perforated peptic ulcer using suture or sutureless technique. *Ann Surg*. 1996;224:131-138.
- Dubois F. New surgical strategy for gastroduodenal ulcer: laparoscopic approach. *World J Surg*. 2000;24:270-276.
- Lagoo S, McMahon RL, Kakihara M, et al. The sixth decision regarding perforated duodenal ulcer. *JLS*. 2002;6:359-368.
- Donovan AJ, Berne TV, Donovan JA. Perforated duodenal ulcer: an alternative therapeutic plan. *Arch Surg*. 1998;133:1166-1171.
- Matsuda M, Nishiyama M, Hanai T, et al. Laparoscopic omental patch repair for perforated peptic ulcer. *Ann Surg*. 1995;221:236-240.
- Gibson JB, Behrman SW, Fabian TC, et al. Gastric outlet obstruction resulting from peptic ulcer disease requiring surgical intervention is infrequently associated with *Helicobacter pylori* infection. *J Am Coll Surg*. 2000 Jul;191(1):32-37.
- Hogan RB, Hamilton JK, Polter DE. Preliminary experience with hydrostatic balloon dilation of gastric outlet obstruction. *Gastrointest Endosc*. 1986;32:71.
- Lamers CBHW, Bijlstra AM, Harris AG. Octreotide, a long-acting somatostatin analog, in the management of postoperative dumping syndrome. *Dig Dis Sci*. 1993;38:359.



46. Hiramoto JS, Terdiman JP, Norton JA. Evidence-based analysis: postoperative gastric bleeding: etiology and prevention. *Surg Oncol.* 2003;12:9–19.
47. Wijdicks EF, Fulgham JR, Batts KP. Gastrointestinal bleeding in stroke. *Stroke* 1994;25:2146–2148.
48. Lam N, Lê PD, Crawford S, et al. National survey of stress ulcer prophylaxis. *Crit Care Med.* 1999;27(1):98–103.
49. Pimental M, Roberts DE, Bernstein CN, et al. Clinically significant gastrointestinal bleeding in critically ill patients in an era of prophylaxis. *Am J Gastroenterol.* 2000;95:2801–2806.
50. Imperiale TF, Chalasani N. A meta-analysis of endoscopic variceal ligation for primary prophylaxis of esophageal variceal bleeding. *Hepatology.* 2001;33:802–807.
51. Jalving M, Koornstra JJ, Wesseling J, et al. Increased risk of fundic gland polyps during long-term proton-pump inhibitor therapy. *Aliment Pharm Ther.* 2006 Nov;24(9):1341–1348.
52. Pinto D, Carrodegua L, Soto F, et al. Gastric bezoar after laparoscopic Roux-en-Y gastric bypass. *Obes Surg.* 2006;16:365–368.
53. Ionescu AM, Rogers AM, Pauli EM, et al. An unusual suspect: coconut bezoar after laparoscopic Roux-en-Y gastric bypass. *Obes Surg.* 2008;18:756–758.
54. White NB, Gibbs KE, Goodwin A, et al. Gastric bezoar complicating laparoscopic adjustable gastric banding and review of literature. *Obes Surg.* 2003;13:948–950.
55. Erzurumlu K, Malazgirt Z, Bektas A, et al. Gastrointestinal bezoars: a retrospective analysis of 34 cases. *World J Gastroenterol.* 2005;11(12):1813–1917.
56. Dalshaug GB, Wainer S, Hollaar GL. The Rapunzel syndrome (trichobezoar) causing atypical intussusception in a child: a case report. *J Pediatr Surg.* 1999;34(3):479–480.
57. Schmulewitz N, Baillie J. Dieulafoy lesions: a review of 6 years of experience at a tertiary referral center. *Am J Gastroenterol.* 2001;96(6):1688–1694.
58. Matuchansky C, Babin P, Abadi JC, et al. Jejunal bleeding from a solitary large submucosal artery. *Gastroenterology.* 1978;75(1):110–113.
59. Goldenberg SP, DeLuca VA, Marignani P. Endoscopic treatment of Dieulafoy's lesion of the duodenum. *Am J Gastroenterol.* 1990;85(4):452–454.
60. Barbier P, Luder P, Trinek J, et al. Colonic hemorrhage from a solitary minute ulcer. *Gastroenterology.* 1985;88:1065–1068.
61. Meister TE, Varilek GW, Marsano LS, et al. Endoscopic management of rectal Dieulafoy-like lesions: a case series and review of literature. *Gastrointest Endosc.* 1998;48(3):302–305.
62. Simon M, Zuber-Jerger I, Schölmerich J. True gastric diverticulum. *Dig Liver Dis.* 2009;41:370.
63. AGA Clinical Practice Committee. American Gastroenterological Association Technical Review on the Diagnosis and Treatment of Gastroparesis. *Gastroenterology.* 2004;127:1592–1622.
64. Jones MP, Kalyani M. A systematic review of surgical therapy for gastroparesis. *Am J Gastroenterol.* 2003;98(10):2122–2129.
65. Buyske J, McDonald M, Fernandez C, et al. Minimally invasive management of low-grade and benign gastric tumors. *Surg Endosc.* 1997;11:1084–1087.
66. Cugat E, Hoyuela C, Rodriguez-Santiago JM, et al. Laparoscopic ultrasound guidance for laparoscopic resection of benign gastric tumors. *J Laparoendosc Adv Surg Tech A.* 1999;9(1):63–67.
67. Omori T, Nakajima K, Ohashi S, et al. Laparoscopic intragastric surgery under carbon dioxide pneumostomach. *J Laparoendosc Adv Surg Tech A.* 2008;18(1):47–51.

*This page intentionally left blank*

# GASTRIC ADENOCARCINOMA AND OTHER GASTRIC NEOPLASMS (EXCEPT GASTROINTESTINAL STROMAL TUMORS)

John T. Langell • Sean J. Mulvihill

## EPIDEMIOLOGY OF GASTRIC CANCER

*Gastric cancer* describes a broad mix of malignant neoplasms derived from the different histological components that make up the stomach. These include adenocarcinoma, lymphoma, carcinoid, and sarcoma. Gastric adenocarcinoma accounts for over 90% of all cases of gastric cancers globally.<sup>1,2</sup> The incidence of gastric cancer decreased dramatically in the latter half of the 20th century; however, a recent rise in proximal gastric cancer incidence has been noted. Gastric cancer remains the second leading cause of cancer-related deaths worldwide (Fig. 22-1).<sup>1-4</sup> As is the case for many cancers, the epidemiological distribution of gastric cancer demonstrates a marked variation in regional incidence—with as much as a 10-fold difference between the highest- and lowest-risk populations.<sup>5</sup> An estimated 900,000–950,000 newly diagnosed gastric cancer cases per year occurred worldwide at the beginning of the 21st century, with the great majority of these cases found in developing countries and China.<sup>2,3,5-7</sup> Industrialized nations continue to see a marked decline in the incidence of gastric cancer, particularly in the body and antrum. In the United States, the estimated number of new cases diagnosed in 2009 was 21,130 with the number of gastric cancer–associated deaths estimated to be 10,620.<sup>7</sup> These numbers highlight the continued decreasing trend in both gastric cancer incidence and mortality (Table 22-1). In fact, death rates attributed to gastric cancer in the United States fell by over 40% for males and 32% for females between the years 1990 and 2005.<sup>7</sup>

The diagnosis of gastric cancer portends a poor prognosis with reported overall 5-year survival rates between 20

and 25% in most industrialized nations.<sup>1,6,8</sup> Stage of disease at time of diagnosis is clearly one of the most important correlates of cancer survival. Patients diagnosed with earlier stages of gastric cancer have a distinct advantage in 5-year survival compared to those with more advanced-stage disease (Fig. 22-2). Although the 5-year survival rate for all cases of gastric cancer in the United States between the years 1996 and 2004 was 25%, it was as little as 3% for patients with distant disease and as high as 61% for those who had only localized disease at time of diagnosis.<sup>7</sup> The survival advantage of early diagnosis is best exemplified by Japan's overall 5-year gastric cancer survival rate of 52%. This has been attributed to a high percentage of early-stage diagnosis due to mass photofluoroscopic screening of their population.<sup>2,6</sup> In the United States where the relatively low incidence of gastric cancer does not support routine population screening, only about one-quarter of all patients are found to have localized disease at the time of diagnosis.<sup>6</sup>

## ASSOCIATED RISK FACTORS

The risk of developing gastric cancer is associated with a complex interrelationship between environmental factors and their influence on an individual's genetic and epigenetic make up.<sup>1,2,6,9,10</sup> Aside from *Helicobacter pylori* infection, smoking, and possibly a high dietary salt intake, very few proposed environmental risk factors have been validated through scientific analysis.<sup>1-3</sup> The effect of regional environmental influences seems apparent given the marked



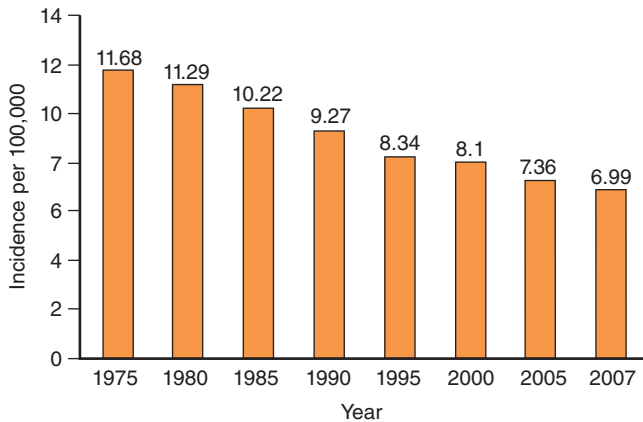


FIGURE 22-1 Incidence of invasive gastric cancer in the United States. (From the SEER Cancer Database, 1975–2007.)

variation in the incidence of gastric cancer between different geographical regions of the world.<sup>6</sup> Although regional and racial genetic variation could account for a portion of this effect, mass global migration of the population and immigrant cancer susceptibility studies indicate a large environmental effect.<sup>11–15</sup> Epidemiological studies have shown that immigrants who travel from high- to low-prevalence regions still maintain an overall gastric cancer risk about equal to the region they emigrated from.<sup>3</sup> The progenies of these immigrants who are born in the low-prevalence regions, on the other hand, exhibit a prevalence similar to local peoples of comparable ethnic origin.<sup>11–15</sup> This effect points to likely environmental factors that impact an individual's risk of gastric cancer development at an early age of exposure.

In addition to environmental factors, a clear impact of genetic susceptibility on the risk of developing gastric cancer has been identified.<sup>9</sup> This includes not only familial associated genetic cancer syndromes but the effects of similar common genomic composition in individuals sharing ethnic origins. This may account for the notable ethnic variations in gastric cancer observed among members of a population in the same geographic region.<sup>17,10</sup> Not only does a geographic subpopulation's

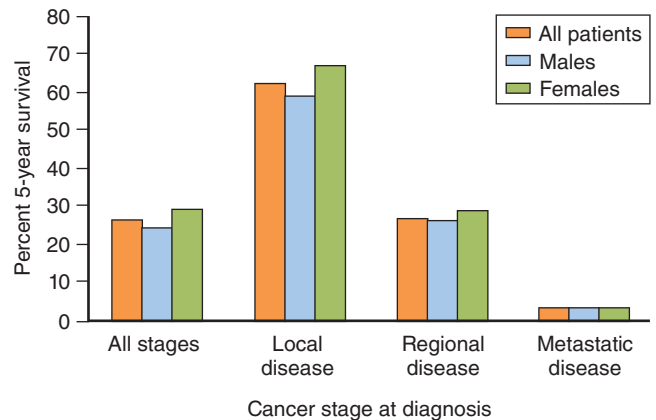


FIGURE 22-2 Gastric cancer 5-year survival rate in the United States. (From the SEER Cancer Database, 1999–2006.)

ethnicity seem to impact their risk of developing gastric cancer, it also affects their average age of presentation and response to therapy.<sup>10</sup> What is not clear is what proportion of these observed effects are secondary to a subpopulations' shared genetic background and what may be due to shared local cultural differences within their geographic regions.

## Helicobacter pylori

*H. pylori* infection has been demonstrated to be linked to the development of distal gastric cancers but not cancer of the gastric cardia.<sup>16,17</sup> The clear association between *H. pylori* infection and the development of gastric cancer led the International Agency for Research on Cancer (IARC) to classify *H. pylori* infection as a type I human carcinogen in 1994.<sup>18</sup> This has been supported by numerous prospective trials that have estimated that *H. pylori* infection confers an increased relative risk for the development of gastric cancer of 2.1–20 fold.<sup>1,2,19,20</sup> Further, a prospective Japanese study of patients tested for *H. pylori* by serology found that gastric cancer developed in 2.9% of patients who were *H. pylori* seropositive, but in none of the patients in the *H. pylori*-seronegative group.<sup>21</sup> Based on early data, Correa proposed a model of gastric carcinogenesis whereby *H. pylori* initiated an inflammatory cascade leading to the sequential development of chronic gastritis, gastric atrophy, intestinal metaplasia, and dysplasia followed by carcinoma.<sup>22</sup> This concept is supported by the linkage between chronic inflammation and cancer development in many other organs.

## Smoking

Convincing evidence has been derived from the European Prospective Investigation into Cancer and Nutrition (EPIC) trial showing cigarette smoking as a causal factor in



**TABLE 22-1: U.S. GASTRIC CANCER INCIDENCE AND MORTALITY PER 100,000 POPULATION, 2001-2005**

	White	African American	Asian American Pacific Islander	American Indian	Hispanic
Incidence	14.7	26.3	29.1	24.5	25
Mortality	7.5	17	16	15.1	13.6

Data from Jemal A, Siegel R, Ward E, et al. Cancer statistics 2009. *CA Cancer J Clin.* 2009;59:225-249.

the development of gastric cancer. In this study, there was a marked increased risk for developing gastric cancer in patients who had a history of smoking tobacco products with a hazard ratio (HR) of 1.45. The HR increased to 1.73–1.87 for current smokers with an increased risk of gastric cancer proportional to the duration and intensity of the smoking history. Further, cigarette smoking had a more profound effect on the development of gastric cardia cancer (HR 4.10) than of antral cancer (HR 1.94). Overall, the large population-based EPIC trial found that 17.6% of gastric cancer cases may be attributable to smoking tobacco products.<sup>23</sup>

## Obesity

Obesity has also emerged as a possible significant risk factor for the development of several cancer types, including cancer of the gastroesophageal junction and gastric cardia.<sup>1,2,24–27</sup> A Swedish population-based study completed by Lagergren et al demonstrated a 2.3-fold increased risk of gastric cancer in the heaviest-weight quartile of the population compared to the lightest-weight quartile and a 4.3-fold increased risk for patients classified as obese.<sup>26</sup> These findings were supported by the results of a large case-control study performed in the United Kingdom that demonstrated a strong association between an increased body mass index and the development of gastric cardia cancer (odds ratio [OR] 1.46), but not noncardia gastric cancer.<sup>25</sup> Furthermore, this effect was dose-dependent and seemed independent of the presence of gastroesophageal reflux disease. The mechanism of increased cancer risk in the obese population has not been elucidated but has been hypothesized to be linked to altered metabolism and/or increased gastroesophageal reflux disease.<sup>24–26</sup>

## Diet

Numerous studies have examined the possible association between dietary intake and either the development or prevention of gastric cancer.<sup>1,2</sup> Specifically, a diet rich in fruits and vegetables has been proposed to be protective against the development of gastric cancer. Although evidence from several retrospective studies support an association between a high dietary intake of fruits and vegetables and a decreased gastric cancer risk, this association proved not to be statistically significant in prospective trial analyses.<sup>2</sup>

Another dietary association that has been extensively studied is the possible increased risk of gastric cancer in patients who consume a high intake of salts and nitrates.<sup>28,29</sup> The evidence for this association is still heavily debated, though most published cohort and case-control studies have found a strong association between a high dietary salt intake and gastric cancer.<sup>28,29</sup> These findings, however, have not been uniform. In fact a well-publicized population-based study out of Norway evaluating a cohort of over 73,000 patients

found no association between dietary salt intake and cancer.<sup>30</sup> Despite these findings, the majority of studies support a possible association between a high dietary salt intake and the development of gastric cancer in higher-risk populations.

## Hereditary Forms of Gastric Cancer

One of the first documented cases of hereditary gastric cancer dates back to the 17th century and was described for the family of the French emperor Napoleon Bonaparte.<sup>31</sup> We now know that up to 3% of gastric cancers are the result of hereditary syndromes.<sup>4</sup> Although many more are likely to be characterized, several well-studied hereditary syndromes include hereditary diffuse gastric cancer (HDGC), Li-Fraumeni syndrome, hereditary nonpolyposis colon cancer, and BRCA2.<sup>9</sup>

The majority of known hereditary gastric cancers are due to HDGC that carries a high penetrance and incidence of gastric cancer in the studied kindreds.<sup>4,9</sup> These patients usually present at an early age with a diffuse multifocal form of gastric cancer. Between 30 and 40% of kindreds with HDGC demonstrate a germline mutation of a single *CDH1* allele, the gene encoding for the structural glycoprotein *E-cadherin*.<sup>32</sup> A complete understanding of the sequence of events that lead to gastric cancer through this single allelic mutation is still unfolding, but there is evidence for loss of heterozygosity though somatic cell epigenetic dysregulation of the normal *CDH1* allele via promoter site methylation in several well-studied cases. Because these patients have a 60–90% lifetime risk of developing a diffuse-type gastric cancer, they present an unusual therapeutic challenge.<sup>9,33</sup> Some have advocated curative early prophylactic gastrectomy in patients who carry the *CDH1* mutation, while others advocate early and routine surveillance endoscopy reserving surgery for patients found to have cancer on surveillance biopsy.<sup>33,34</sup>

## CLINICAL PRESENTATION

### Signs and Symptoms of Gastric Cancer

The signs and symptoms of gastric cancer are nonspecific and commonly found in unaffected individuals in the general population. They include dyspepsia, fatigue, and malaise among others. Other, more concerning symptoms that are often referred to as alarm symptoms, include weight loss, dysphagia, persistent vomiting, gastrointestinal bleeding, anemia, and a palpable abdominal mass.<sup>35</sup>

Dyspepsia is a very common complaint among patients presenting to primary care physicians.<sup>36</sup> Dyspepsia is also a frequent complaint in patients with gastric cancer; however, peptic ulcer disease, gastroesophageal reflux disease, and functional dyspepsia are far more common causes of dyspepsia.<sup>35</sup> The presence of alarm symptoms presents a more concerning clinical picture in patients with a history of dyspepsia and should alert the evaluating physician that a more extensive

workup to rule out malignancy may be indicated. The presence of alarm symptoms is not specific for malignancy; in fact the incidence of alarm symptoms in dyspeptic patients is high, whereas the incidence of gastric cancer is low.<sup>35</sup> Despite this, prospective and retrospective studies have shown that 56–90% of patients with gastric cancer had alarm symptoms at the time of endoscopy.<sup>37–40</sup> A meta-analysis of seven prospective endoscopic studies involving over 13,000 patients reported the presence of alarm symptoms in 30% of all patients and in 62% of patients found to have gastrointestinal cancer.<sup>41</sup> Of these, no single alarm symptom was present in more than 30% of patients with malignancy.

Another study analyzing patients who underwent urgent endoscopy for the presence of alarm symptoms or dyspepsia unresponsive to empiric therapy found that 3.8% had a gastrointestinal malignancy.<sup>42</sup> In this study, the only alarm symptoms that were predictive of cancer were dysphagia and weight loss with ORs of 3.1 and 2.6, respectively. The presence of uncomplicated dyspepsia, on the other hand, was found to be a negative predictor for cancer with an OR of 0.1.

Although the presence of alarm symptoms is poorly predictive for the presence of cancer, when they are present in gastric cancer patients, the presence and number of alarm symptoms has been shown to correlate with an advanced stage of disease.<sup>43,44</sup> Therefore, the presence of specific alarm symptoms may be of prognostic value in gastric cancer patients. This notion is supported by a recent study completed by Stephens et al where the presence or absence of alarm symptoms correlated with patient survival time. Here, patients were followed from their initial diagnosis of gastric cancer to their date of death. Those patients who presented with alarm symptoms had a survival range of only 7–11 months, whereas patients without alarm symptoms survived between 24 and 39 months.<sup>44</sup>

Physical examination abnormalities in early gastric cancer are generally not present. In patients with advanced disease, a palpable supraclavicular mass, generally on the left side, can be a sign of distant nodal metastasis (the Virchow node). A bulky antral tumor or extensive nodal metastases will occasionally lead to jaundice from bile duct obstruction in the hepatoduodenal ligament. A palpable abdominal mass may be found, sometimes from a bulky primary tumor, but more commonly from omental caking with metastases. Abdominal distension and ascites is a finding concerning for peritoneal carcinomatosis, as is the finding of a palpable nodule at the umbilicus (the Sister Mary Joseph node). Rectal examination may identify an anterior mass in the pouch of Douglas related to peritoneal carcinomatosis and drop metastasis to the pelvis (the Blumer shelf). In advanced disease, pallor related to anemia and evidence of weight loss may be present.

## DIAGNOSIS AND STAGING

In symptomatic patients or those with a history of familial gastric cancer undergoing screening evaluation, the diagnosis of cancer is most commonly made by the finding of

a mass lesion or concerning ulceration during upper endoscopy. Other patients presenting with more advanced disease may have the diagnosis of malignancy made by CT scan and biopsy of metastatic lesions. Although commonly used in the past, upper gastrointestinal contrast studies with barium or water-soluble contrast agents have largely been replaced by the complementary nature of the combination of endoscopy and CT. Once the diagnosis of gastric cancer has been made, the patient must undergo a staging workup to determine the extent of the disease and potential for curative resection.

## Preoperative Staging and Selection of Patients for Surgery

Accurate preoperative staging is essential for appropriate treatment planning. The workup should include upper endoscopy with or without endoscopic ultrasonographic (EUS) evaluation to assess the extent of local and regional disease. The addition of EUS to the preoperative evaluation may improve the accuracy of preoperative staging because it has been shown to be slightly superior to computed tomography (CT) imaging in assessing tumor depth of invasion and locoregional lymph node involvement.<sup>45,46</sup> Because EUS may provide only limited additional information to CT scan in most cases, the recent 2010 Practice Guidelines of the National Comprehensive Cancer Network consider it an optional adjunctive study.<sup>4</sup>

A CT scan of the abdomen with contrast should be performed on all patients along with pelvic CT or ultrasound in females and thoracic imaging in all patients to evaluate the tumor (T) stage, nodal (N) stage, and distant metastatic disease (M) stage, for the purpose of treatment planning. Though CT scan is a recommended and routine part of the preoperative evaluation, it has a relatively low sensitivity for evaluating tumor depth and the presence of metastatic lymph nodes.<sup>4</sup> Newer modalities such as multidetector CT, helical CT, and positron emission tomography CT (PET-CT) have been shown to provide better preoperative staging data; however, their routine use has not yet been advocated as an essential or necessary part of the preoperative staging workup.<sup>4</sup>

In addition to radiographic staging, a complete history and physical examination, an assessment of exercise tolerance, relevant laboratory testing, and indicated physiological evaluations must be performed. These studies help provide evidence of advanced disease as well as the presence and extent of comorbid conditions that may need to be considered prior to treatment. In some patients, the presence of significant comorbid illness or limited performance status may preclude certain treatment options.

Preoperative laboratory testing should include a comprehensive metabolic panel to assess the patient's nutritional status, renal and hepatic function. Patients with a poor nutritional status may benefit from preoperative nutritional supplementation before considering surgical resection. Those with evidence of reduced renal function or poor hepatic synthetic function may not tolerate radical surgical resection or

may be demonstrating signs of advanced disease that will need more extensive staging studies. A complete blood (cell) count (CBC) and basic coagulation studies should be performed to assess the status of known or possible bleeding disorders. Anemia is common in gastric cancer and may represent bleeding from the primary tumor or a vitamin B<sub>12</sub> deficiency from associated atrophic gastritis

Patients who have signs and symptoms suggestive of cardiopulmonary disease should have at minimum an electrocardiogram (ECG) and chest x-ray (CXR) performed. Additional more extensive testing will be guided by the extent of the patient's symptoms and the findings of the ECG and CXR.

NCCN guidelines recommend that all patients with a diagnosis of gastric cancer, and particularly those with gastroesophageal junction lesions, should undergo comprehensive review of their staging, findings, and treatment planning options by a multidisciplinary cancer treatment team. Unless the patient is to be enrolled in a treatment study protocol approved by an institutional review board, treatment should be based on the current NCCN Practice Guideline recommendations.<sup>4</sup>

### Staging

In the United States and the majority of the Western world, staging is based on the TNM (tumor-node-metastasis) system jointly developed by the American Joint Committee on Cancer (AJCC) and the International Union Against Cancer.<sup>47</sup> Table 22-2 summarizes the TNM-based staging system for gastric cancer. This system stratifies patients to a stage of disease that correlates strongly with patient survival. This staging system is based on tumor depth relative to the gastric wall histological layers, presence and number of involved regional lymph nodes, and the presence or absence of distant metastatic disease.

NCCN Practice Guidelines for treatment recommendations for initial therapy are based on the preoperative TNM stage of the disease.<sup>4</sup> To be considered a candidate for curative resection, a patient must be found medically fit to withstand a major abdominal surgery, have limited locoregional disease amenable to resection with negative margins, and be free of evidence of distant metastatic disease. Those who have local disease but are found medically unfit to undergo a major surgical procedure may be candidates to undergo endoscopic mucosal resection (EMR) as discussed below. Those with advanced disease who are otherwise good surgical candidates may be candidates for palliative procedures if indicated. Patients with unresectable disease and those with extensive locoregional disease who are medically unfit to safely withstand radical surgery should be treated in a nonsurgical treatment arm based on current treatment guidelines.

Patients with advanced locoregional disease who are medically fit and have a marked response to a neoadjuvant treatment protocol should undergo complete preoperative restaging once treatment has been completed to determine whether their response to therapy renders them a potential candidate for curative surgical resection.

**TABLE 22-2: AJCC TNM CLASSIFICATION OF GASTRIC CANCER**

Stage	Primary Tumor	Regional Lymph Node	Distant Metastasis
<b>Stage 0</b>	Tis	N0	M0
<b>Stage IA</b>	T1	N0	M0
<b>Stage IB</b>	T1	N1	M0
	T2a/b	N0	M0
<b>Stage II</b>	T1	N2	M0
	T2a/b	N1	M0
	T3	No	M0
<b>Stage IIIA</b>	T2a/b	N2	M0
	T3	N1	M0
	T4	N0	M0
<b>Stage IIIB</b>	T3	N2	M0
<b>Stage IV</b>	T4	N1–3	M0
	T1–3	N3	M0
	Any T	Any N	M1

Primary Tumor Definition	Regional Lymph Node Definition	Distant Metastasis Definition
<b>Tis:</b> Carcinoma in situ	<b>N0:</b> No nodes involved	<b>M0:</b> No distant metastasis
<b>T1:</b> Invades lamina propria or submucosa	<b>N1:</b> 1–6 regional nodes involved	<b>M1:</b> Distant metastasis
<b>T2a:</b> Invades muscularis propria	<b>N2:</b> 7–15 regional nodes involved	
<b>T2b:</b> Invades subserosa	<b>N3:</b> >15 regional nodes involved	
<b>T3:</b> Penetrates serosa		
<b>T4:</b> Invades adjacent structures		

AJCC, American Joint Committee on Cancer; TNM, tumor-node-metastasis. Data from Greene FL, Page DL, Fleming ID, et al. *AJCC Cancer Staging Manual*. 6th ed. Philadelphia, PA: JB Lippincott; 2002:111–118.

### ADJUNCTIVE THERAPIES

The 5-year survival rate for gastric cancer remains dismally low even for resectable disease. Surgical resection with curative intent remains the mainstay of therapy; however, the addition of neoadjuvant and/or adjuvant therapy has been shown to improve both disease-free survival and overall survival rates in patients with select stages of disease.<sup>4,48–50</sup> The literature is replete with case series, retrospective studies, and a few prospective randomized control trials (RCTs) that sought to investigate the efficacy of various adjunctive therapeutic regimens in patients who have undergone a curative surgical resection for gastric cancer. In general, these studies have been plagued with inconsistent results and complicated by



the use of diverse therapeutic regimens, many of which are thought to be suboptimal. Fortunately, a handful of well-designed studies and more recent meta-analysis of these data have demonstrated their therapeutic efficacy.

Neoadjuvant therapy consists of a combination of chemotherapeutic agents or chemotherapy plus radiation therapy instituted in the preoperative setting. The theoretical advantages of preoperative treatment include assessing tumor chemosensitivity preoperatively to help tailor postoperative therapy, potential early treatment of micrometastatic disease, better tolerance of therapeutic side effects, and disease down-staging to improve the number of potentially curative resections.<sup>48,49</sup> Preoperative radiation therapy alone or in combination with chemotherapy has been demonstrated to provide a significant increase in down-staging, tumor resectability, and overall 5-year survival rates. Unfortunately, these data were obtained from RCTs of patients with predominantly gastroesophageal junction tumors and therefore may not have similar efficacy with cancers of the gastric body or antrum.<sup>48</sup>

The MAGIC (Medical Research Council Adjuvant Gastric Infusional Chemotherapy) trial<sup>51</sup> demonstrated that the addition of combined preoperative and postoperative chemotherapy consisting of epirubicin, cisplatin, and 5-fluorouracil leads to a significant increase in overall survival and reduced disease progression when compared to patients who received surgery alone, establishing the benefit of neoadjuvant chemotherapy without radiation. Currently, the NCCN guidelines recommend the addition of neoadjuvant chemotherapy or combined chemoradiation therapy for any patient without metastatic disease who is either node positive or staged as T2 or greater in the preoperative setting.<sup>4</sup>

The role of combined modality chemoradiation adjuvant therapy in the postoperative period has been established to significantly increase patient overall survival rates.<sup>4</sup> Until recently, the benefit of adjuvant chemotherapy in the absence of radiation has been more controversial. A recent meta-analysis published in the *Journal of the American Medical Association* by the Global Advanced/Adjuvant Stomach Tumor Research International Collaboration (Gastric) Group provided the first level I evidence to support the benefits of fluorouracil-based adjuvant chemotherapy.<sup>50</sup> They reported a statistically significant increase in both overall survival and disease-free survival, when compared to surgery alone. The current NCCN guidelines recommend adjuvant therapy for patients without distant disease based on their pathological disease stage and resection margin status. The addition of adjuvant therapy is optional for those who undergo an R0 resection with stage T2/N0/M0 or lesser disease. For those who underwent an R1 resection or an R0 resection with greater than T2 or node-positive disease, an adjuvant fluoropyrimidine-based chemoradiation regimen (preferred) or alternative chemotherapy alone is recommended. Patients who undergo an R2 resection, regardless of T or N stage, have the option of undergoing therapy as noted previously for an R1 section or alternatively may be treated with best supportive care in the absence of adjuvant therapy. Unless patients

are enrolled in an approved study protocol, we recommend adherence to the most current published treatment guidelines outlined by the NCCN.<sup>4</sup>

## SURGICAL APPROACH TO GASTRIC CANCER

The principles of surgical resection are to obtain resection margins that are grossly at least 5 cm from the visible or palpable mass.<sup>52</sup> The specimen should be sent for frozen-section pathological analysis to assess margin status. Ideally, margins should be microscopically free from cancer, often referred to as an R0 resection.<sup>53</sup> If the surgical margins are not initially free of microscopic disease, an additional resection should be performed if anatomically feasible. Obtaining an R0 resection is the guiding principle in determining whether to perform a distal gastrectomy, a total gastrectomy, or an esophagogastrectomy. The long-term survival rates for patients undergoing a total gastrectomy and a distal gastrectomy are similar provided that negative surgical margins are obtained.<sup>54</sup> However, a more limited surgical resection may provide a lower rate of postoperative complications and a higher quality of life.<sup>55</sup> Although some authors advocate performing a proximal gastrectomy for limited proximal gastric cancers, the authors of this chapter have not found consistent convincing evidence for its benefit over total gastrectomy. In proximal gastrectomy, the antrum can be preserved; however, it is not highly distensible and provides little capacity advantage compared to total gastrectomy. We have therefore decided not to include the technique for proximal gastrectomy in this chapter but recognize that it is a reasonable surgical option practiced at some centers.

It is important to acknowledge that preoperative staging is not always correct and that some patients will be found to be unable to undergo curative resection at the time of surgery. These include patients found to have previously undiagnosed distant metastatic disease, carcinomatosis, or advanced locoregional disease. It is for this reason that many authors advocate laparoscopic staging prior to advancing to a full laparotomy.<sup>4</sup> Relatively asymptomatic patients found to have unresectable disease on laparoscopic evaluation can be referred for nonsurgical treatment options without suffering the attendant risks of a full laparotomy or radical surgical resection. Functional, but symptomatic, patients presenting with marked anemia or obstructive symptoms may benefit from a limited surgical approach to include intestinal bypass or partial gastric resection as a palliative measure. These patients do not necessarily need to undergo laparoscopic staging because they will need a palliative procedure if they are found to be unresectable for cure.

In experienced centers, patients with limited disease may be candidates for laparoscopic gastrectomy for cancer. Recent published case series and one randomized control study have shown patients undergoing laparoscopic gastric resections to have similar oncological outcomes to patients undergoing

open gastrectomy techniques.<sup>56–58</sup> The data from these studies are limited, and the selection criteria defining patients appropriate for laparoscopic resection have not yet been well defined. Sufficient randomized data have not convincingly demonstrated equivalent or superior survival following laparoscopic resection compared to laparotomy and resection. If applied, the laparoscopic approach should follow the same surgical principles as for open gastric resection. The major differences will lie in the unique requirements of the laparoscopic approach. Because it has not been studied sufficiently to regard it as the standard of care, we have elected not to include a detailed description of nuances of the laparoscopic approach in this chapter.

## Extent of Lymph Node Dissection

The importance of the presence and extent of lymph node metastasis is reflected in the system used to stage the disease and provide prognosis for the patient's extent of disease. What is less clear, however, is the impact of surgical resection of regional lymph nodes on survival. The locoregional gastric nodes have been characterized based on their anatomical location relative to the stomach and are described according to their stations 1–11.<sup>59</sup> As demonstrated in Fig. 22-3, stations 1, 3, and 5 lymph nodes are located along the lesser curvature of the stomach. Stations 2, 4, and 6 nodes lie along the greater curvature of the stomach. Station 7 nodes are found in the tissue along the left gastric artery, station 8 nodes along the common hepatic artery, station 9 nodes along the celiac artery, and stations 10 and 11 nodes along the splenic artery.

The perigastric lymphatics located at nodal stations 1–6 make up a subset of lymph nodes referred to as N1 nodes.<sup>5</sup> Lymph nodes located at nodal stations 7–11 are referred to

as N2 nodes. All other nodes encountered in the surgical dissection are considered distant nodes and are thought to preclude a curative resection when positive for metastasis. The extent of surgical lymph node dissection has traditionally been categorized as a D1 resection when care is taken to completely dissect and remove all of the N1 nodes with the surgical specimen, a D2 resection when all N1 and N2 nodes are completely dissected and removed, or a D0 resection when stations 1–6 are not completely removed.<sup>4</sup> The extent of resection is important when the Japanese gastric cancer staging system is used; however, it is not used as a prognostic factor in the TNM staging system adopted by Western nations. When the TNM staging system is used, the most important principles of lymph node dissection that have emerged are to remove all grossly involved nodes and to obtain at least 15 perigastric lymph nodes for pathological sampling.<sup>47</sup>

The extent of lymph node dissection to be performed and its impact on postoperative survival is perhaps the most debated topic in surgery for gastric cancer. The Japanese and, more recently, several European centers have published studies advocating more extensive D2 and D3 lymph node dissections for patients undergoing surgery with curative intent.<sup>60–62</sup> The literature on this topic contains a large number of small case series, retrospective studies, and uncontrolled noncomparative studies on the impact of various degrees of lymph node dissection concurrent with both partial and total gastrectomy for gastric cancer. Only two RCTs from Western centers that had adequate study designs and appropriate statistical analysis of outcomes measures have been published comparing D1 and D2 lymph node dissections in gastric cancer patients.<sup>63–67</sup> Both studies evaluated similar primary outcomes measures looking at 5-year survival rates, postoperative morbidity, and postoperative mortality. Both studies concluded that a more extensive D2 dissection provided no significant benefit to 5-year survival, while those patients undergoing D2 lymph node dissections had significantly more postoperative complications and a higher in-hospital mortality rate. Other, nonrandomized single-arm trials evaluating outcomes after D2 dissections completed at specialized centers noted much lower postoperative morbidity and mortality rates, similar to rates reported for D1 dissections. These authors have criticized the data from the previously described RCT, stating that they suffered from lack of surgeon experience and operative standardization.<sup>62,68</sup>

In 2004 the Cochrane collaboration attempted to determine the superiority of D1 versus D2 lymph node dissections for gastric cancer through a meta-analysis and systematic review of the literature.<sup>68</sup> Here they critically analyzed the literature, then evaluated properly conducted studies from both randomized control trials and nonrandomized trials with similar outcomes measures. Based on a meta-analysis of RCT, they concluded there was no survival benefit to patients undergoing a D2 dissection, with the possible exception of patients with T3-positive disease. They also concluded that there was a markedly higher operative mortality rate specifically associated with D2 dissection and concurrent spleen and pancreas resection. They also noted that both RCTs were

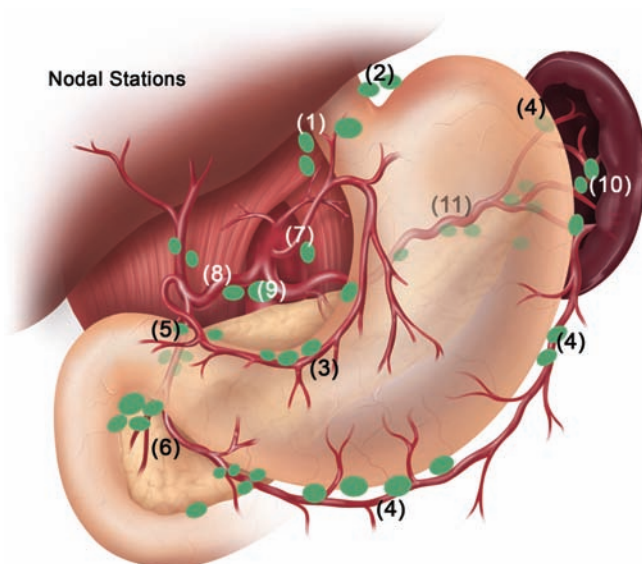


FIGURE 22-3 Gastric lymph node stations.

confounded by a lack of surgeon compliance and inexperience. Based on published nonrandomized comparative studies, they concluded that D2 dissections may provide a survival benefit to patients with intermediate-stage gastric cancer. In addition, based on their analysis of published observational studies, they found that patients undergoing D2 dissections may have an overall survival advantage without a markedly increased operative mortality rate when performed at experienced centers. Overall, they noted the available published data comparing D1 and D2 lymph node dissections to be limited and seriously flawed.<sup>68</sup>

Since the publication of the Cochrane review, numerous nonrandomized comparative studies and single-armed observational studies have continued to argue the case for the benefit of a D2 dissection over a D1 dissection. The majority of these studies have shown that patients undergoing D2 dissections have superior 5-year survival rates with equivalent or better rates of operative-associated morbidity and mortality. Most authors attribute these findings to improved surgical skill and experience along with performance of D2 dissections without performing concurrent spleen and pancreas resections, as was standard for both of the published RCTs.<sup>60–62,69–71</sup> In support of this, the Dutch RCT study group recently published a 15-year follow-up of their trial and noted an increased trend in the overall 15-year survival rate of patients undergoing D2 resections (29%) compared to patients undergoing D1 resections (21%), though the difference proved not to be statistically significant ( $p = .34$ ). They did, however, find a significantly lower gastric cancer–related death rate and lower rate of locoregional recurrence in the D2 population. Based on these data, and contrary to previous recommendations from this group, they now advocate D2 lymphadenectomy for patients undergoing curative resection when performed at experienced high-volume centers using safer spleen-preserving techniques.<sup>71</sup> Despite the increasing trend in the literature advocating D2 lymph node dissections, it is clear that further multicenter RCTs are needed to determine the risks and benefits of more extensive lymph node dissection techniques. Currently, the question of whether to perform a D1 versus a D2 dissection for patients undergoing surgery with curative intent remains to be determined by individual surgeons and their associated multidisciplinary cancer treatment teams (Table 22-3).

The system of lymph node staging in gastric cancer also continues to be a topic of debate. In a recent study of over 700 gastric cancer patients, four lymph node staging systems, including the Japanese and TMN systems were compared for their ability to predict patient outcomes. In this study the system found to be easiest to use and most predictive of postoperative outcomes was a method based on the ratio of nodes positive for metastatic disease to the total number of nodes collected, independent of the total number of nodes sampled.<sup>72</sup> In light of data from this and other recent studies and the ongoing intense debate regarding the optimal staging of lymph nodes in gastric cancer, we are likely to see modifications to the current systems in the future.

**TABLE 22-3: RANDOMIZED CONTROLLED TRIAL RESULTS COMPARING D1 VERSUS D2 LYMPH NODE DISSECTION IN PATIENTS UNDERGOING GASTRECTOMY WITH CURATIVE INTENT**

Authors	Study Groups	Number of Patients	Outcomes Measure	Findings
Bonenkamp et al <sup>63</sup>	Dutch	711	Perioperative mortality	D2 dissection had significantly higher mortality rate
Bonenkamp et al <sup>64</sup>	Dutch	711	Mean 5-y survival rate	No difference in 5-y survival rate between groups
Hartgrink et al <sup>67</sup>	Dutch	711	Mean 11-y survival rate	No difference in 11-y survival rate between groups
Songun et al <sup>71</sup>	Dutch	711	Mean 15-y survival rate	No difference in overall survival rate between groups Statistically higher local recurrence rate in D1 group Statistically higher cancer-specific death rate in D1 group
Cuschieri et al <sup>65</sup>	British	400	Perioperative mortality	D2 dissection had significantly higher mortality rate
Cuschieri et al <sup>66</sup>	British	400	Mean 5-y survival rate	No difference in 5-y survival rate between groups

## Endoscopic Submucosal Resection

Endoscopic submucosal resection (ESR) is a minimally invasive resection technique usually performed by gastroenterologists, primarily in Japan and a few specialized centers worldwide.<sup>4,73</sup> This procedure is reserved for relatively small (<2 cm) mucosal lesions that have a very low risk of lymph node metastasis and no findings consistent with metastatic disease.<sup>74</sup> Recently this technique was extended to include lesions at high risk for lymph node metastasis in patients with a poor performance status or in higher-risk lesions when ESR is accompanied by a laparoscopic lymph node dissection. The results of ESR case series on patients meeting these later criteria are published in the literature, but appropriate controlled studies and scientific analysis of this technique for higher-risk lesions are absent.<sup>75,76</sup>



## SURGICAL TECHNIQUES FOR GASTRIC CANCER

### Distal Gastrectomy

Laparoscopic exploration of the peritoneal cavity should be considered prior to initiation of a formal laparotomy to ensure absence of carcinomatosis or distant disease that would preclude a curative resection. Patients in whom the yield of laparoscopy may be higher include those with a prolonged duration of symptoms, those with weight loss, and those with equivocal CT findings of metastatic disease. NCCN guidelines suggest that the use of laparoscopy may be helpful in complete clinical staging prior to resection, but the level of evidence supporting its use is not high enough to make it the standard of care for all patients.<sup>4</sup> Next, an upper midline or bilateral subcostal incision is made of adequate length to allow placement of a fixed surgical retractor and facilitate adequate operative exposure. The operative sequence that follows may vary depending on the extent of lymph node dissection and the reconstructive technique chosen.

Step 1 is to identify the location of the tumor through manual palpation, or for smaller lesions, visualization of an endoscopically placed tattoo. This first step is essential in order to determine the extent of resection necessary to obtain an adequate resection margin. It is critically important in proximal lesions to ensure that a negative esophageal margin can be obtained before transaction of the duodenum. Next, if there is a high concern for metastatic disease, the duodenum and pancreatic head are mobilized in order to expose the para-aortic lymph nodes that may demonstrate signs of distant nodal spread and help establish whether there is potential for a curative resection. The retroperitoneum is then incised along the lateral border of the second portion of the duodenum. Medial visceral rotation of the duodenum and pancreatic head is performed, exposing the inferior vena cava (IVC) and aorta. The exposed para-aortic lymph nodes located in the aortocaval space are dissected and sampled. If pathologic-appearing nodes are encountered, frozen-section analysis should be performed to exclude distal nodal spread, as this would preclude a curative resection. Once the absence of distal nodal spread is confirmed, we commence with the inferior portion of the dissection.

The gastrocolic ligament is detached from the transverse colon along the avascular plane using electrocautery (Fig. 22-4). The anterior layer of the transverse mesocolon is sharply dissected to the level of the inferior border of the pancreas. This step separates the anterior mesocolonic peritoneum from the underlying vessels and posterior layer, thus skeletonizing the mesocolonic vessels (Fig. 22-5). The exposed right gastroepiploic vessels are ligated and transected. Dissection of the anterior layer of the mesocolon is typically continued to its confluence with the anterior capsule of the pancreas. The dissection will expose the left gastroepiploic vessels, which must be ligated and transected. Continued dissection of the anterior pancreatic capsule is continued to the superior margin of the pancreas, allowing

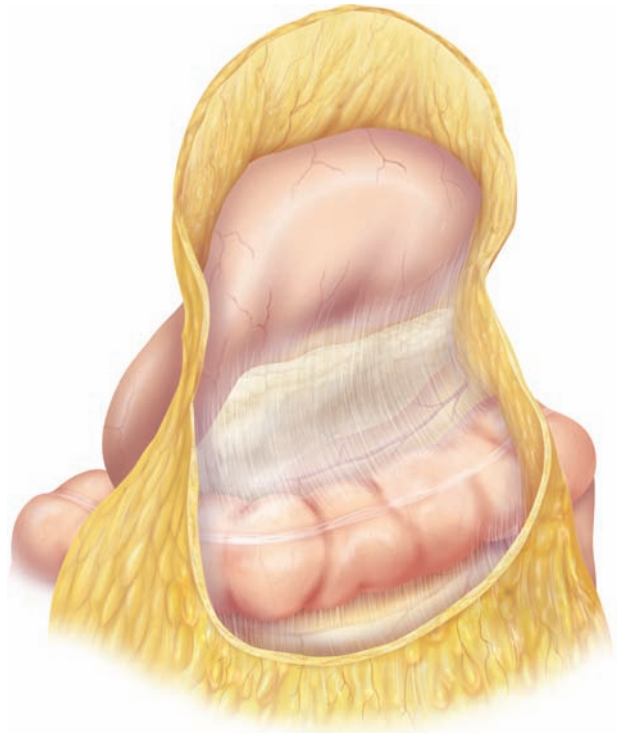


FIGURE 22-4 Detachment of the greater omentum from the colon through the avascular plane.

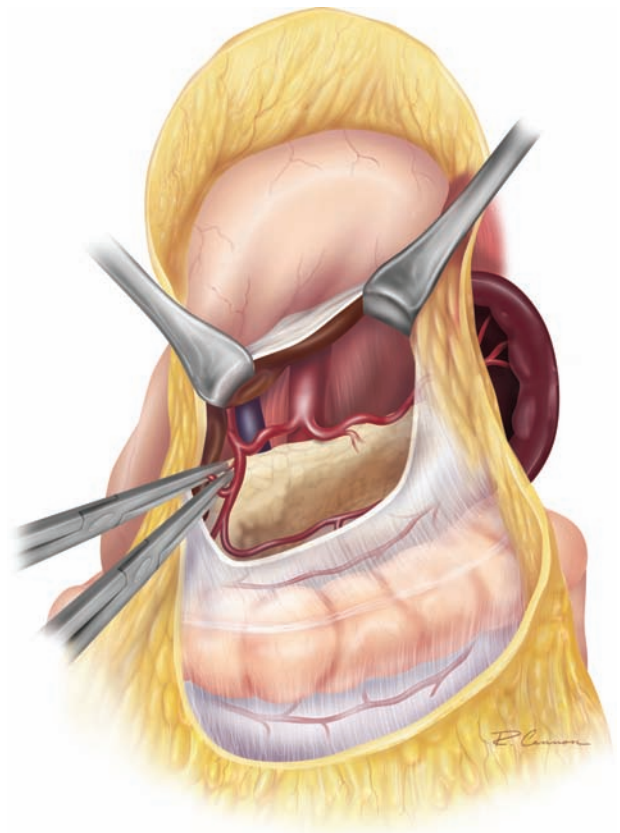


FIGURE 22-5 The anterior mesocolon is separated from the underlying vessels and posterior layer.



exposure of the celiac, splenic, and hepatic arteries and their associated nodal beds. When a D2 node dissection is to be performed, these nodal beds are cleared of lymphatic tissue. Ideally, dissection of these nodes is delayed until the duodenum has been divided in order to facilitate exposure.

The gastroduodenal junction is palpated and evaluated for distal tumor involvement. If the area appears free of malignancy, the duodenum is divided 1–2 cm distal to the pylorus (Fig. 22-6). If tumor is palpable at the pylorus or proximal duodenal bulb, the duodenum is divided 1–2 cm distal to that point to obtain a microscopically negative resection margin. In this situation, however, care must be taken not to injure the retroduodenal portion of the common bile duct, the minor papilla, or the ampulla of Vater. The gastroduodenal artery serves as a useful landmark as it passes behind the duodenal bulb. The retroduodenal common bile duct usually lies within 1 cm to the right of this vessel. We generally complete the division of the duodenum with a GIA stapler. Others prefer to transect the duodenum between bowel clamps and close the duodenal stump with a running 3-0 absorbable monofilament suture such as PDS. There are no data to support the superiority of one method over the other. Some surgeons invaginate the duodenal staple/suture line with interrupted sutures in a standard Lembert fashion (Fig. 22-7).

If a D2 node dissection is performed, division of the duodenum provides improved exposure to the nodal bearing tissue adjacent to the hepatic, celiac, and splenic arteries located along the superior border of the pancreas. This tissue should be dissected and cleared from the region of the gastroduodenal artery to the basin adjacent to the proximal splenic artery. Care must be taken not to injure the pancreatic parenchyma or the celiac plexus.

Dissection of the lesser omentum is completed along the lesser curvature of the stomach from the inferior edge of the

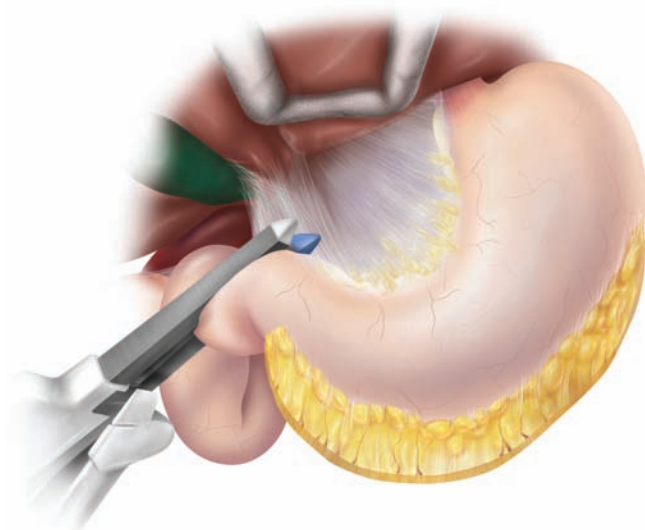
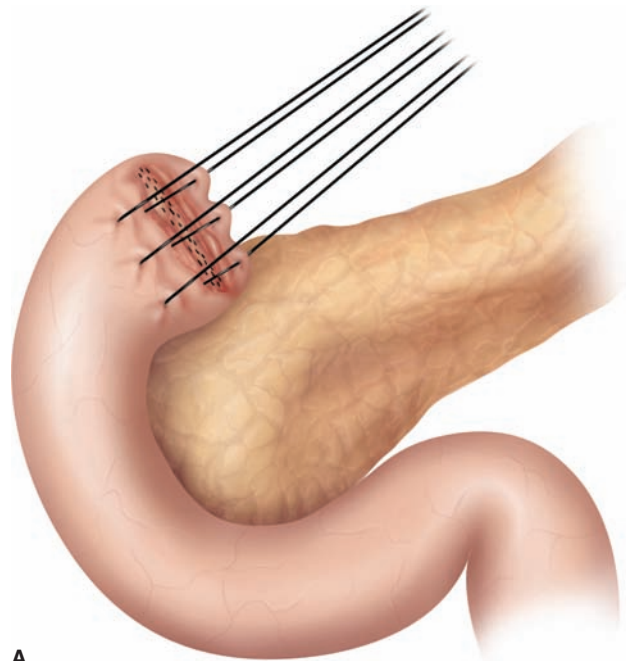
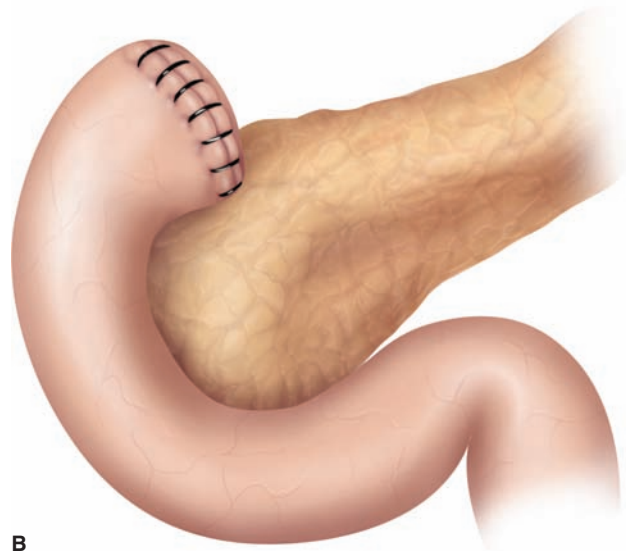


FIGURE 22-6 The duodenum is divided 1–2 cm distal to the pylorus.



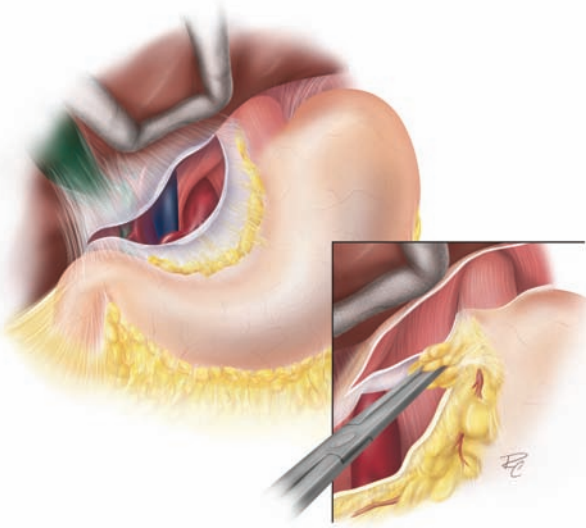
A



B

FIGURE 22-7 A. and B. The duodenal staple/suture line is invaginated with interrupted Lembert sutures.

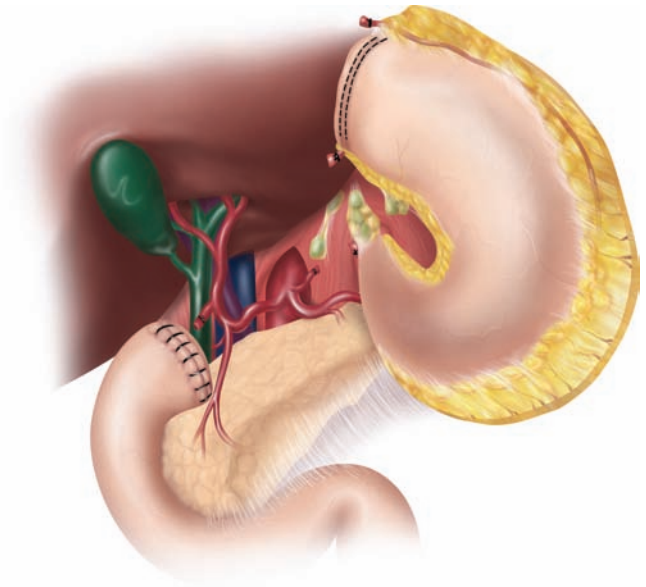
hepatoduodenal ligament to the right crus of the diaphragm. The retroperitoneal incision created along the lateral border of the second portion of the duodenum is extended superiorly to the confluence with the hepatoduodenal ligament at the inferior aspect of the foramen of Winslow. Next, the left lobe of the liver is retracted superiorly and to the right to expose the region of the diaphragmatic hiatus. The hepatogastric ligament is then incised from the diaphragmatic crus anterior to the gastroesophageal junction and along the hepatic border to the level of the porta hepatis at its confluence with the hepatoduodenal ligament (Fig. 22-8). The incision is then carried



**FIGURE 22-8** The hepatogastric ligament is incised from the diaphragmatic crus anterior to the gastroesophageal junction and along the hepatic border from the porta hepatis to the hepatoduodenal ligament.

inferiorly along the left border of the left hepatic artery to just above the junction with the duodenum, then medially to join with the retroperitoneal incision created previously. The hepatoduodenal ligament is then incised superiorly at the level of the cystic duct, and then reflected medially, exposing the structures of the porta hepatis inferiorly. The superior and inferior resection margins of the hepatoduodenal ligament are carried posteriorly behind the portal vein. The right gastric artery and vein are identified, ligated, and transected. The hepatoduodenal ligament that had been freed circumferentially from the porta hepatis can now be taken along with the nodal bearing connective tissue medial to the portal triad. The retroperitoneal dissection is then continued to the right of the aorta superiorly to the median arcuate ligament. The left gastric artery and vein are then exposed and ligated at their origins. If a D2 dissection is to be completed, dissection and clearance of the nodal bearing tissue around the left gastric artery should be performed at this point. The retroperitoneal dissection is then carried to the left and inferiorly to join the retroperitoneal resection margin along the superior border of the pancreas (Fig. 22-9).

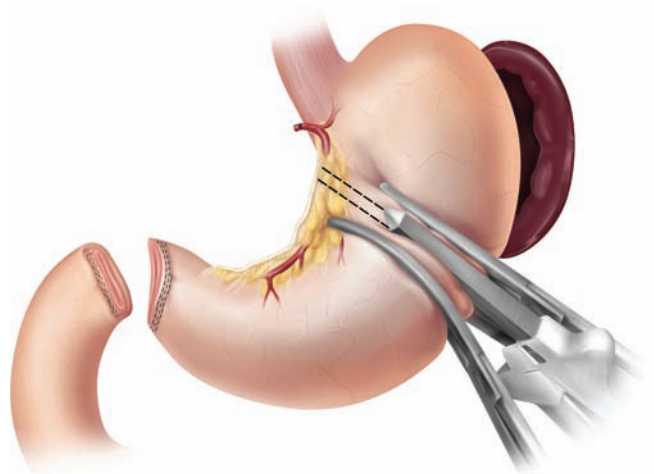
The point of proximal gastric resection must be determined based on the location of the lesion. This requires resection of the entire lesion with a minimum 5-cm margin free of cancer. For a distal gastrectomy, the proximal resection plane is created from approximately 2 cm distal to the esophagogastric junction along the lesser curvature to a point along the greater curvature that will allow for a 5-cm resection margin. Division of the remaining greater omentum is performed to the level of the greater curvature resection point either by dividing between clamps and suture ligating the short gastric vessels or with an appropriate surgical energy source. Care should be exercised to avoid injury to the short gastric vessels located in the unresected greater omentum. With the proximal resection



**FIGURE 22-9** The left gastric artery and vein are exposed and ligated. The retroperitoneal dissection is carried to the left and inferiorly to join the retroperitoneal resection margin along the superior border of the pancreas.

line delineated, the stomach is transected either between clamps or with a surgical stapler (Fig. 22-10). The en bloc specimen should be marked to orient the pathologist to the appropriate margins and sent for frozen pathological analysis to ensure an adequate resection margin free of cancer has been obtained. Failure to obtain a cancer-free resection margin necessitates one or more attempted proximal gastric resections until appropriate margins are obtained if anatomically feasible.

Once the resection is complete, the decision as to which reconstructive technique will be used must be made. We

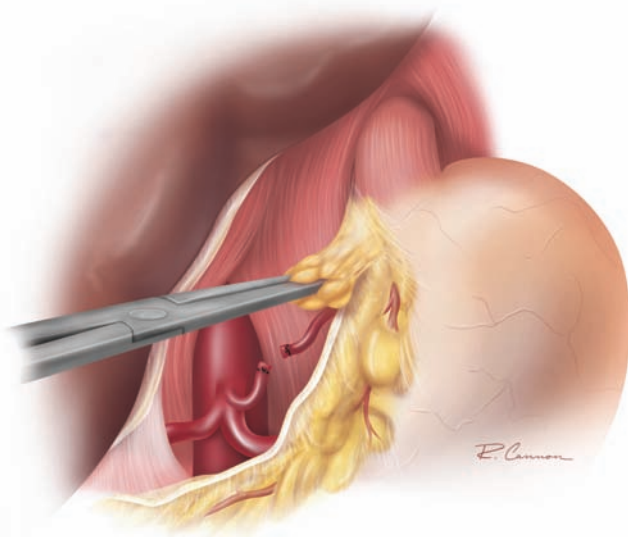


**FIGURE 22-10** With the proximal resection line delineated, the stomach is transected either between clamps or with a surgical stapler.

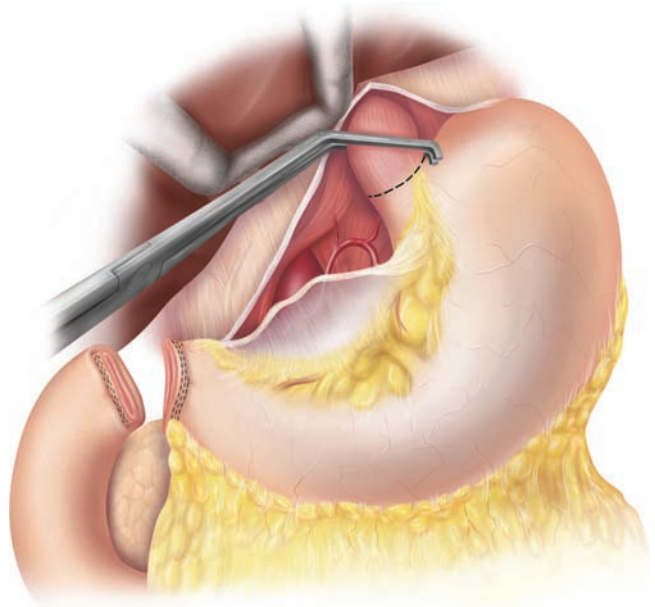
generally perform a Billroth II reconstruction. For details on reconstructive options and surgical techniques, please review the section on operative reconstruction options below.

## Total Gastrectomy

The surgical approach for a proximal gastric lesion is very similar to that outlined previously for a distal gastric lesion. The only major variation is completion of the proximal dissection at the gastroesophageal junction and diaphragmatic crura with en bloc removal of the gastric pericardial and paraesophageal lymph nodes (Fig. 22-11). The dissection of the omentum along the greater curvature must also be completed, taking care to divide the remaining short gastric vessels close to the spleen. Once the preceding dissection is completed, the proximal transaction margin is identified on the esophagus, just proximal to the gastroesophageal junction. Esophageal division can be completed with an intestinal stapling device or an angled bowel clamp can be placed proximal to the planned transaction margin using a scalpel to divide the esophagus (Fig. 22-12). As with the distal gastrectomy, frozen-section analysis of the proximal margin must be completed in order to ensure a curative resection. If a cancer-free margin cannot be obtained, the surgeon must determine whether the patient is a candidate for a curative esophagogastrectomy. Once the en bloc resection is complete and frozen-section pathological analysis has confirmed adequate operative margins, the intestinal reconstruction must be completed through the use of a Roux-en-Y esophagojejunostomy. The surgical approach to this reconstructive method is described in detail in the following text.



**FIGURE 22-11** Proximal dissection at the gastroesophageal junction and diaphragmatic crura with en bloc removal of the gastric pericardial and paraesophageal lymph nodes.



**FIGURE 22-12** Esophageal division is completed with an intestinal stapling device or an angled bowel clamp.

## GASTROINTESTINAL RECONSTRUCTIVE TECHNIQUES

When determining the appropriate reconstructive method to restore intestinal continuity after gastric resection, it is important to choose a technique that will minimize long-term postoperative nutritional deficiencies.<sup>77,78</sup> The most common of these complications include marked weight loss and dumping syndrome.<sup>77-79</sup> Some authors have asserted that this is best accomplished by restoring gastroduodenal integrity through construction of a jejunal interposition graft after total or subtotal gastrectomy.<sup>80-82</sup> Although numerous case reports and case series have been published on various jejunal interposition techniques, there is currently no convincing evidence to support their use or a consensus on a standardized or optimal technique. Given the lack of adequate scientific evidence to support the merits of jejunal interposition grafts, we do not currently recommend their use. What does seem clear from published studies is that the most important concepts of reconstruction are to choose a technique that restores gastrointestinal continuity while reducing the incidence of bile reflux and anastomotic strictures.

## Intestinal Reconstruction After Distal Gastrectomy

### BILLROTH II RECONSTRUCTION

Given its technical ease, reasonable long-term patency rate, and good functional outcome, we generally recommend the



use of a Billroth II reconstruction after distal gastrectomy. This is achieved by identifying the jejunal origin at the ligament of Treitz, by tracing the Billroth II reconstruction distally to identify the shortest amount of jejunum necessary to create a tension-free anastomosis, roughly 15 cm from the ligament of Treitz. A shorter limb is thought to reduce the incidence of afferent limb syndrome. Once this point has been identified, it is marked with a suture to facilitate ease of future identification. Next, it must be decided whether to bring the jejunal limb to the proximal gastric remnant through a retrocolic or antecolic approach. Although there are advocates of both approaches, neither has been shown to have a true functional advantage over the other. We prefer the antecolic approach when the jejunal limb can easily reach in this manner, as it does not carry the attendant risk of retrocolic internal herniation. If limb length is an issue, the retrocolic approach may shorten the distance involved for a tension-free anastomosis. In this setting, we prefer to bring the gastric remnant down through the mesocolic defect so that the anastomosis is completely inframesocolic. This may reduce the incidence of afferent limb obstruction.

The gastrojejunal anastomosis is then created by placing the segment of the jejunal limb previously marked with suture adjacent to and in parallel with the proximal gastric remnant along its posterior-inferior margin. Once the location of the gastrojejunal anastomosis has been determined, a posterior row of Lembert-type sutures is placed to join the jejunum to the gastric wall. This is accomplished using either 3-0 Vicryl or silk-interrupted sutures along the entire posterior aspect of the anastomosis. Electrocautery is then used to create a full-thickness defect in the gastric wall anterior to the row of the posterior Lembert sutures that is long enough to facilitate a 5-cm anastomotic opening. A similar full-thickness defect is made in the adjacent segment of jejunum. An anastomosis is created using 3-0 or 4-0 PDS beginning at the posterior-middle segment. Two 3-0 PDS sutures are placed immediately next to each other and run in opposite directions until they meet in the anterior aspect of the anastomosis. The two PDS sutures are then tied together to complete the anastomosis. Next, an anterior row of Lembert-type sutures is placed using either 3-0 Vicryl or silk suture (Fig. 22-13). If a retrocolic approach was used, the defect in the transverse mesocolon must be closed by sutures between the mesocolon and the stomach to avoid internal herniation.

### ROUX-EN-Y RECONSTRUCTION

An acceptable alternative reconstruction method is Roux-en-Y gastrojejunostomy. The Roux technique has the advantage of eliminating bile reflux into the gastric remnant but has the disadvantages of two anastomoses and the possibility of Roux-stasis syndrome. The Roux technique is approached by identifying the origin of the jejunum at the ligament of Treitz. The jejunum is traced distally to approximately 10–15 cm. A defect is created in the jejunal mesentery just below the mesenteric border of the jejunum. The jejunum is then divided either between bowel clamps, or, as we prefer, with a gastrointestinal stapler (Fig. 22-14). The mesentery is divided enough to

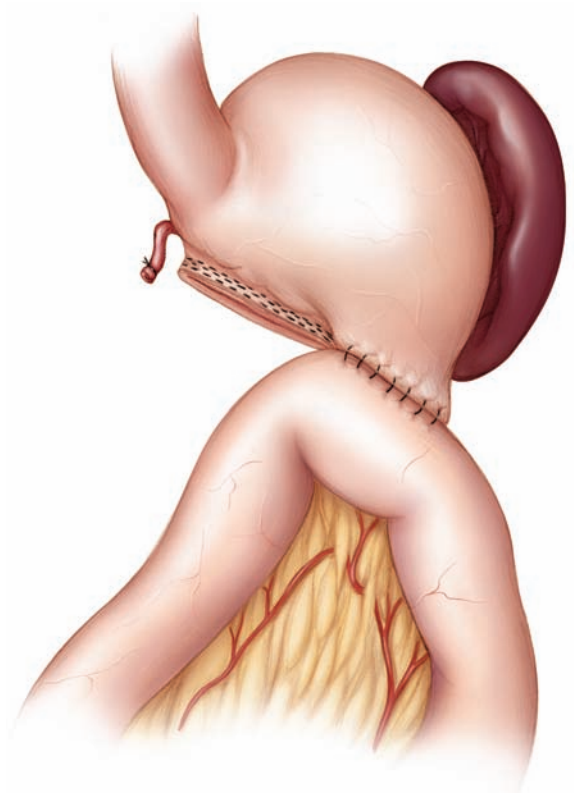


FIGURE 22-13 For a Billroth II anastomosis, a gastrojejunal anastomosis is performed with a running absorbable monofilament sutures.

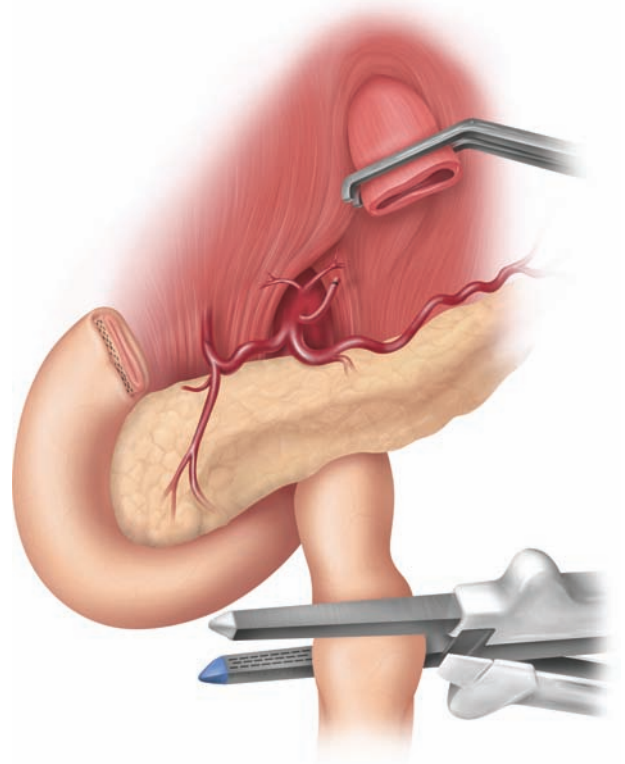


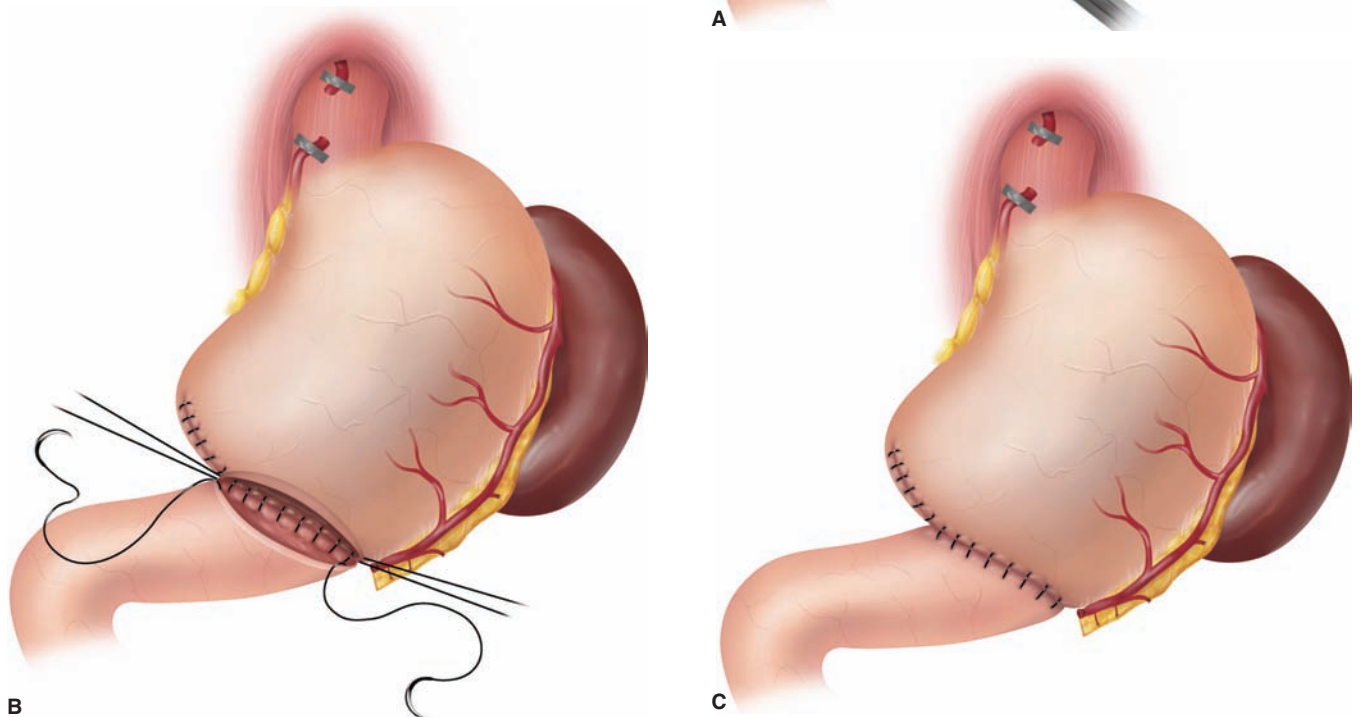
FIGURE 22-14 For Roux-en-Y reconstruction, the jejunum is divided 10–15 cm distal to the ligament of Treitz.



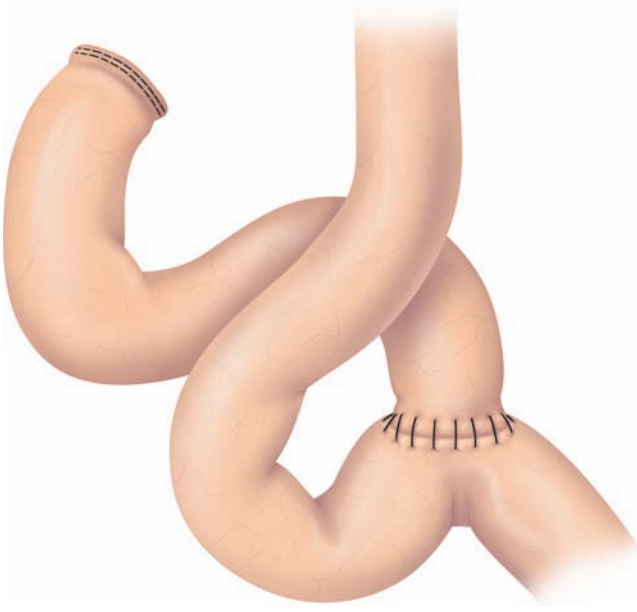
permit the limb to reach to the gastric remnant while avoiding bowel devascularization. This usually includes division of the first anastomotic arcade of the jejunum. Care should be taken with transillumination of the mesentery to understand the vascular anatomy and preserve blood supply to both limbs of the jejunum. The distal segment of the transected jejunum is brought to lie along the posterior-inferior aspect of the gastric margin as with the Billroth II reconstruction above. A posterior row of Lembert-type sutures is placed to attach the jejunum to the gastric wall. This is accomplished using either 3-0 Vicryl or silk-interrupted sutures along the entire posterior aspect of the anastomosis. Electrocautery is then used to create a full-thickness defect in the gastric wall anterior to the row of the posterior Lembert sutures that is long enough to facilitate a 5-cm anastomotic opening. A similar full-thickness defect is made in the adjacent segment of jejunum. An anastomosis is created using 3-0 or 4-0 PDS beginning at the posterior-middle segment. Two 3-0 PDS sutures are placed immediately next to each other and run in opposite directions until they meet in the anterior aspect of the anastomosis. The two PDS sutures are then tied together to complete the anastomosis. Next, an anterior row of Lembert-type sutures are placed using either 3-0 Vicryl or silk suture (Fig. 22-15).

Attention is then turned to creation of the jejunojejunostomy. The proximal jejunal staple line is anastomosed to the distal jejunal segment approximately 45–50 cm distal to the gastrojejunostomy. This distance has previously been

shown to be the optimal length of the Roux limb needed to reduce the incidence of bile reflux, while also reducing excessive limb length, which may contribute to stasis and malnutrition. The two segments of jejunum to be anastomosed are aligned parallel to each other in order to create a 5-cm antimesenteric anastomosis. The anastomosis may be



**FIGURE 22-15** **A.** The distal segment of the transected jejunum is brought to lie along the posterior-inferior aspect of the gastric margin, and a posterior row of Lembert type sutures is placed to attach the jejunum to the gastric wall. **B.** Two 3-0 PDS sutures are placed immediately next to each other and run in opposite directions until they meet in the anterior aspect of the anastomosis. **C.** An anterior row of interrupted reinforcing Lembert suture is placed to complete the superior anastomosis.



**FIGURE 22-16** The two segments of jejunum to be anastomosed are aligned parallel to each other, and a 5-cm antimesenteric anastomosis is created.

created with the use of a gastrointestinal stapler or may be hand-sewn in the same manner as described for the gastrojejunostomy above (Fig. 22-16). Care must be taken to close all mesenteric defects with either 3-0 Vicryl or silk to prevent the development of an internal hernia.

## Intestinal Reconstruction After Total Gastrectomy

Total gastrectomy is associated with worse postoperative weight loss and increased dumping symptoms when compared to distal gastrectomy. This is thought to be due to lack of a gastric reservoir. This has resulted in an ongoing debate of whether to create a jejunal pouch either with or without a jejunal interposition technique in order to simulate the gastric reservoir function. The literature in this area has generally been inconclusive due to the lack of appropriate controls, standardized outcomes measures, and poor study design.<sup>80-82</sup> A recent meta-analysis and systematic review of the literature has provided level IA evidence to support the use of an inverted J pouch or S pouch in conjunction with a Roux-en-Y reconstruction as a means of improving postgastrectomy-associated dumping, long-term weight loss, loss, and patient quality of life.<sup>78</sup> This study did not find evidence to support the benefit of a pouch with a jejunal interposition in order to maintain duodenal passage of enteric contents.

In most patients, a standard Roux-en-Y reconstruction will be the preferred technique to restore intestinal continuity. The procedure will be conducted as described previously for

reconstruction after distal gastrectomy with one notable variation. Instead of creating a proximal gastrojejunostomy, the proximal anastomosis will be an end-to-end or end-to-side esophagojejunostomy. This may be performed as a hand-sewn anastomosis as described previously for a gastrojejunostomy or may be performed as a stapled technique using an appropriately sized EEA stapler.

As described previously, the hand-sewn technique entails performing a circumferential reinforcing row of Lembert-type sutures using 3-0 Vicryl or silk. The posterior row is placed after aligning the anastomotic segments, ensuring the jejunal limb is not twisted. The anastomosis is then performed with two full-thickness 3-0 or 4-0 PDS sutures placed immediately next to each other in the posterior segment of the anastomosis. The two sutures are then run circumferentially in opposite directions until they meet in the anterior midline. The sutures are then tied, completing the anastomosis. When feasible, an anterior row of interrupted reinforcing Lembert sutures are placed in the same manner as was completed in the posterior row (Fig. 22-17).

If a stapled technique is used, the anastomosis is created between the transected end of the esophagus and the antimesenteric border of the proximal Roux limb near the staple line. The anastomosis is performed in an end-to-side fashion. The EEA sizes are placed in the esophageal lumen, choosing an anvil size that will allow the largest possible diameter anastomotic lumen without causing undue tension on the esophageal or jejunal wall, preferably a 25- to 28-mm stapler. A purse-string suture is placed circumferentially at the distal end of the esophagus, just superior to the transection border using a 3-0 monofilament suture. The anvil is placed in to the esophageal lumen, and the purse-string suture is tightened and tied snugly around the anvil rod. The stapled end of the Roux limb is opened, and the EEA stapler is placed through the lumen in such a manner as to allow the staple pin to be punctured through the antimesenteric jejunal border several centimeters distally. The EEA anvil is then mated to the stapling device and closed, ensuring that the Roux limb is not twisted and no extraneous tissue is present between the anvil and stapler surface. Once stapling is completed, the device and anvil are removed through the jejunum and the stapler is inspected to ensure that the presence of two completed donuts of tissue are present (Fig. 22-18). The esophageal donut should be marked as “proximal esophageal margin” and sent to pathology for permanent section. The proximal end of the Roux limb must then be closed either with a surgical stapler or hand-sewn technique.

Once the esophagojejunostomy has been performed, attention is turned to creation of the jejunojejunostomy as described for the Roux-en-Y technique for distal gastrectomy previously (Fig. 22-19).

For select patients who are thought to have a good long-term prognosis, use of a jejunal pouch should be considered in an attempt to reduce postoperative weight loss and dumping syndrome. The jejunal S pouch or inverted J pouch are both reasonable choices, although no data exist to prove the benefits of one over the other. The reconstruction

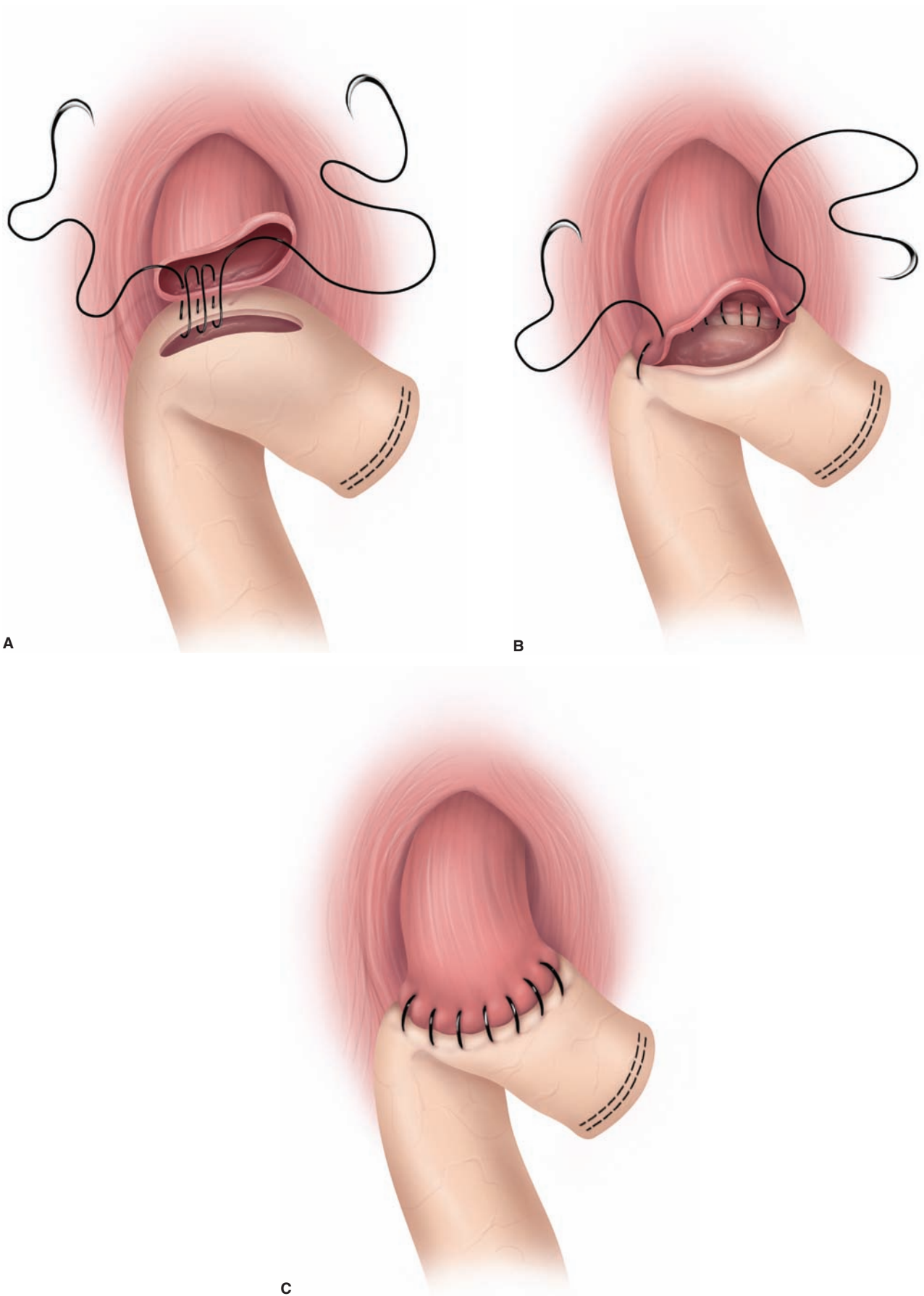


FIGURE 22-17 A–C. Roux-en-Y reconstruction with hand-sewn anastomosis after total gastrectomy.

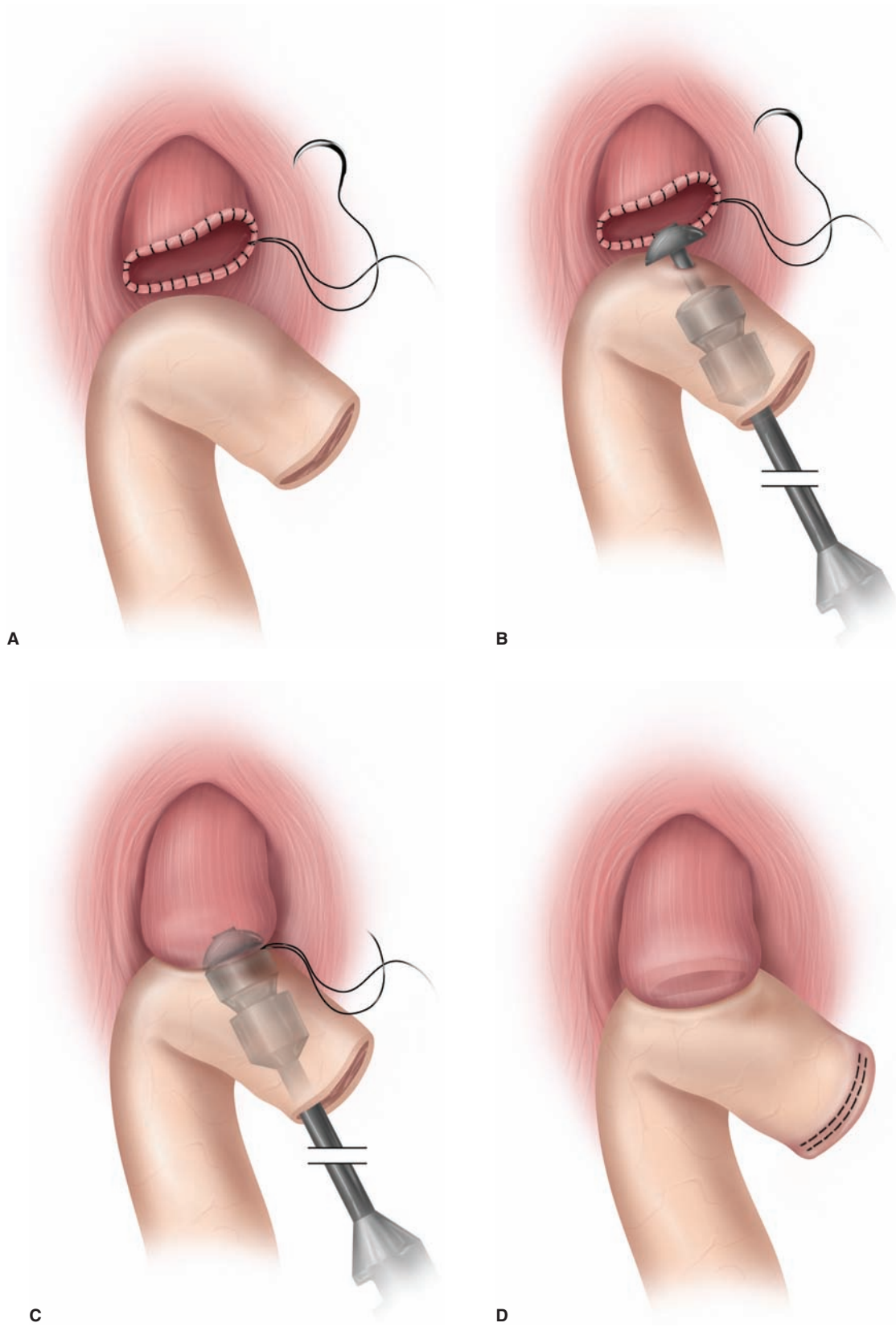


FIGURE 22-18 A–D. Roux-en-Y reconstruction with stapled anastomosis after total gastrectomy.





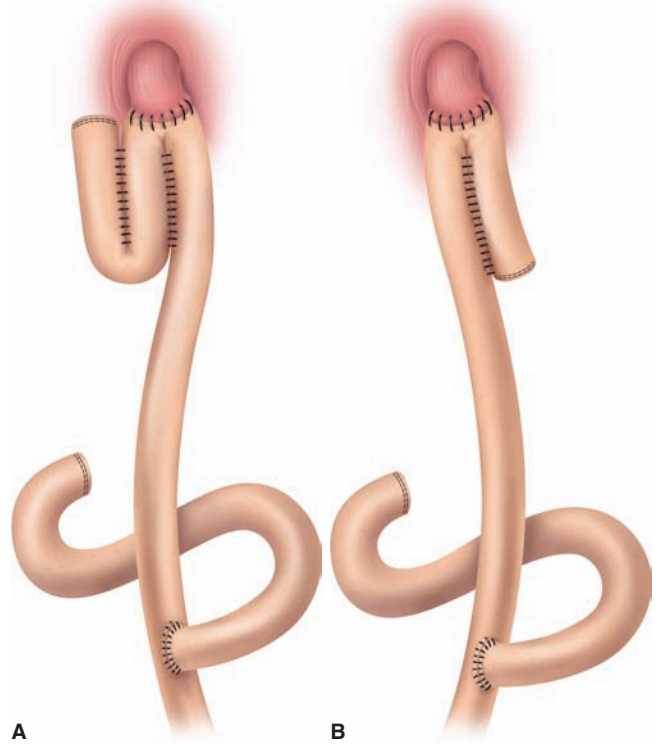
**FIGURE 22-19** Completed Roux-en-Y reconstruction after total gastrectomy.

is performed just as a standard Roux-en-Y technique with the exception that the pouch is created at the proximal Roux limb prior to creating the esophagojejunostomy. The pouch is created by aligning the proximal jejunum in an inverted J or an S configuration, then by creating a common channel between the overlapping jejunal segments with a GIA stapler (Fig. 22-20). Once the pouch has been formed, a standard Roux-en-Y with esophagojejunostomy is performed as was described previously.

## PRIMARY GASTRIC LYMPHOMA

### Epidemiology

Gastric lymphoma is the second most common primary malignancy of the stomach, accounting for approximately 5% of gastric cancers.<sup>83</sup> Over the past four decades, there has been a nearly 80% increase in the incidence of lymphoma in the United States.<sup>84</sup> This marked increase in lymphoma incidence



**FIGURE 22-20** **A.** Creation of a jejunal S pouch. **B.** Creation of a jejunal J pouch.

has been especially notable for extranodal lymphomas, where up to 40% of cases present as primary gastrointestinal tract lesions.<sup>85–87</sup> Gastric lymphoma accounts for the majority of these cases, representing approximately 50–75% of primary gastrointestinal lymphomas.<sup>83,88,89</sup> Primary gastric lymphoma is typically an extranodal form of a non-Hodgkin's lymphoma (NHL), whereas, Hodgkin's lymphomas, are rarely found to involve the stomach.<sup>83,90</sup>

Lymphomas represent a diverse and heterogeneous group of neoplasms and, as a result, have been very difficult to classify. Currently, the World Health Organization (WHO) lymphoma classification system is the accepted standard used by most medical professionals worldwide.<sup>91</sup> This classification system categorizes lymphomas based on their cell of origin and specific molecular, phenotypic, and genetic characteristics. Its most recent revision also takes into account clinical features such as patient age, site of involvement, and associated etiologic conditions.<sup>92</sup> Although the WHO classification system has facilitated treatment approaches and standardization of research protocols, it remains a very complex diagnostic schematic due to the intrinsic heterogeneity of lymphoproliferative disorders. The revised 2008 WHO lymphoma classification system recognizes more than 25 main categories of lymphoma derived from a mature B-cell origin and more than 20 derived from a T cell or NK cell of origin.<sup>92,93</sup>

## Histology

Histologically, up to 98% of primary gastric lymphomas are derived from a B-cell origin.<sup>93</sup> Nearly 60% of these are classified as diffuse large B-cell lymphomas (DLBCL) and approximately 38% are marginal zone B-cell lymphomas of the mucosa-associated lymphoid tissue (MALT) (Table 22-4).<sup>94</sup> Both DLBCL and MALT-associated B-cell lymphomas are thought to be associated with chronic *H. Pylori* infection. This linkage is better established for MALT-associated B-cell lymphomas, where as many as 90% of cases are thought to be the result of *H. pylori* infection and where *H. pylori* eradication therapy usually leads to a durable remission.<sup>95–98</sup> The association between *H. pylori* infection and DLBCL is more controversial. Approximately 35% of patients with DLBCL are found to be *H. pylori* positive, with the majority of these patients showing concurrent MALT areas on endoscopic evaluation. Despite these data, up to 63% of patients with DLBCL have a durable treatment response to *H. Pylori* eradication therapy alone.<sup>98</sup>

Diffuse large B-cell lymphomas are aggressive high-grade lymphomas that may be derived from MALT-associated B-cell lymphomas.<sup>87,88</sup> Diffuse large B-cell lymphomas frequently express high levels of Bcl-6, an oncogene found on chromosome 3.<sup>83</sup> There are two recognized subcategories of DLBCL that can be immunohistochemically differentiated: those that resemble germinal center (GC)-type B cells (CD10+, Bcl-6–, and BCL2+/-) and those that are not GC-like (CD10–, Bcl-6+, and BCL2–).<sup>83</sup> GC-type B cells are thought to be derived de novo from mature B lymphocytes, while non-GC-type DLBCL is thought to arise from MALT-associated B-cell lymphomas.

MALT-associated B-cell lymphomas are typically multifocal lesions. They arise from gastric mucosal lymphatic tissue, which is thought to occur as a result of chronic *H. pylori* infection, in most cases. MALT-associated B-cell lymphomas express the CD20 cell surface antigen, generally produce IgG light-chain antibodies, and may express CD43. Three genetic translocations have been identified for MALT-associated

B-cell lymphomas that, when combined, may be present in up to 65% of cases. These characteristic translocations include t(11;18)(q21;q21), t(1;14)(p22;q32), and t(14;18)(q32;q21).<sup>83,98</sup> Although each of these translocations produces a different direct upstream impact on cellular regulation, they all result in activation of the nuclear factor-κB cell activation pathway.<sup>99</sup>

## Sings and Symptoms

The clinical presentation of patients with primary gastric lymphoma is similar to patients with gastric adenocarcinoma. The signs and symptoms tend to be nonspecific, with dyspepsia, abdominal pain, nausea, vomiting, anorexia, and change in bowel habits being the most common.<sup>83,91,98,100</sup> Gastrointestinal bleeding may also occur and is the initial presentation in up to 30% of patients.<sup>88</sup> With the exception of weight loss, B symptoms (weight loss, fevers, and night sweats) are rarely present in primary gastric lymphomas.<sup>83</sup> A complete history and physical examination must be performed with particular emphasis paid to examination of all accessible nodal beds, including Waldeyer's ring. A detailed abdominal examination should be performed to evaluate for an abdominal masses or organomegaly. The patient's presenting history provides the most important diagnostic clues, as the physical examination will fail to reveal any diagnostic findings up to 60% of the time.<sup>83</sup>

## Diagnostic Workup and Staging

Patients with presenting histories or objective findings on clinical examination concerning for gastric malignancy must be undergo immediate upper endoscopic evaluation. Comprehensive upper endoscopy with biopsy of concerning lesions will make the diagnosis of gastric lymphoma in more than 95% of cases.<sup>91</sup> Once the diagnosis of gastric lymphoma has been pathologically confirmed, the patient must undergo staging of their disease to ensure initiation of the appropriate treatment algorithm and provide the patient with prognostic information. Although nearly universal acceptance of the 2008 WHO lymphoma classification system has helped to standardize the lymphoma staging workup, some variations still exist depending on the histological subtype.

All patients should undergo laboratory testing to include *H. Pylori* serology, a CBC with differential, liver function tests, serum chemistry panel with lactate dehydrogenase (LDH) and B<sub>2</sub> microglobulin, and serum electrophoresis to evaluate for M proteins. Additionally, although the bone marrow is rarely involved in primary gastric lymphoma, a bone marrow aspirate and biopsy should be completed. A spiral CT scan of the neck, chest, abdomen, and pelvis is performed to evaluate for additional lesions.<sup>91,99</sup> When DLBCL has been conformed by pathological analysis, a PET scan has been demonstrated to increase staging accuracy above that of CT scan alone with a sensitivity of more than 80% and a specificity of more than

**TABLE 22-4: DISTRIBUTION OF LYMPHOMA HISTOLOGICAL SUBTYPE IN 398 PATIENTS WITH PRIMARY GASTRIC LYMPHOMA (REAL CLASSIFICATION)<sup>94</sup>**

Lymphoma Histological Distribution	Frequency (%)
Diffuse large B-cell lymphoma	59
Without MALT component	14
With MALT component	45
Malt lymphoma of the marginal zone	38
Peripheral T-cell lymphoma	1.5
Mantle lymphoma	1
Follicular lymphoma	0.5

MALT, mucosa-associated lymphoid; REAL, Revised European-American Lymphoma.

90%.<sup>101–103</sup> When MALT-associated B-cell lymphoma has been confirmed, additional staging should include a second, more extensive, endoscopy with mapping. Twenty to thirty biopsy specimens should be obtained from both normal- and abnormal-appearing gastric and duodenal mucosa.<sup>104,105</sup> This is an important step because MALT-associated B-cell lymphoma is frequently multifocal and MALT-lymphoma containing mucosa may look normal on endoscopy. Repeat endoscopy with extensive biopsy has been shown to diagnose a previously unrecognized DLBCL component in as many as 10% of patients (Table 22-5).<sup>91</sup> The addition of colonoscopy and magnetic resonance imaging (MRI) of the salivary and lacrimal glands, in addition to the standard staging practices above, may lead to the finding of multiorgan involvement in as many as 25% of patients.<sup>93</sup> As discussed previously for adenocarcinoma, endoscopic ultrasound (EUS) may be of increased value in the locoregional N and T staging.<sup>26,106</sup>

The data obtained from the staging protocols described previously may then be used to stratify patients into a staging system to facilitate standardized treatment planning and obtain prognostic information. Several staging systems have been developed for primary gastrointestinal lymphomas and include the modified Ann Arbor staging system, the Lugano classification system, and the Paris staging system.<sup>91</sup> Although the modified Ann Arbor staging system is the oldest of the three, it is still the most frequently used system in the United States (Table 22-6).<sup>107</sup>

## Treatment

Historically, surgical resection was the primary treatment for gastric lymphoma but is now generally reserved to treat complications of the disease, including perforated viscus, bleeding, and gastrointestinal obstruction. Recent data from RCTs demonstrated comparable durable treatment outcomes



**TABLE 22-5: RECOMMENDED STAGING PROTOCOL FOR PRIMARY GASTRIC LYMPHOMA**

### All patients

Physical examination, EGD with EUS, CT scan (neck, chest, abdomen, and pelvis), CBC with immunophenotyping, liver function tests, chemistry panel, immunoelectrophoresis, B<sub>2</sub> microglobulin, bone marrow biopsy, *H. Pylori* serology

### Histology-specific staging

DLBCL—PET scan

MALT—Second endoscopy with mapping biopsy protocol

CBC, complete blood (cell) count; CT, computed tomography; DLBCL, diffuse large B-cell lymphoma; EGD, esophagogastroduodenoscopy; EUS, endoscopic ultrasound; MALT, mucosa-associated lymphoid tissue; PET, positron emission tomography.

Data from Boot H. Diagnosis and staging in gastrointestinal lymphoma. *Best Pract Res Clin Gastroenterol.* 2010;24:3–12.



**TABLE 22-6: ANN ARBOR STAGING SYSTEM (MUSHOFF MODIFICATION)<sup>107</sup>**

Stage	Extent of Disease
I <sub>1</sub>	Confined to stomach. Involves submucosa or mucosa only. No lymph node involvement.
I <sub>2</sub>	Confined to stomach. Extends beyond submucosa. No lymph node involvement.
II <sub>1</sub>	Any depth of gastric wall involvement with regional lymph node involvement confined to the same side of the diaphragm.
II <sub>2</sub>	Any depth of gastric wall involvement with distant lymph node involvement confined to the same side of the diaphragm.
III	Any depth of gastric wall involvement with lymph node involvement on both sides of the diaphragm or splenic involvement.
IV	Lymphoma disseminated beyond gastrointestinal tract to other extranodal organs.

Modified for extranodal primary gastric lymphoma.

for chemotherapy, radiation therapy, or surgery.<sup>83,108,109</sup> Furthermore, chemotherapeutic treatment approaches yielded far lower treatment-associated complication rates.<sup>99</sup> The evolution of the treatment of primary gastric lymphoma continued into the 21st century as our understanding of lymphoma histological types continued to progress. The current treatment recommendations are radically different for MALT-associated B-cell lymphomas, than for the high-grade DLBCL.<sup>83,91,99</sup>

MALT-associated B-cell lymphoma treatment arms are generally based on *H. pylori* status and stage of disease. Early-stage *H. pylori*-positive disease has a high rate of complete remission with use of antibiotics to eradicate the *H. pylori* infection.<sup>83,96,97</sup> The treatment of early-stage *H. pylori*-negative MALT-lymphoma and *H. pylori*-positive antibiotic unresponsive disease remains unclear.<sup>99</sup> Although some *H. pylori*-negative patients will respond to antibiotic therapy, it is generally recommended that these patients be treated with either radiation therapy alone, rituximab, or chemotherapy.<sup>83,99,110</sup> Asymptomatic advanced-stage MALT-associated lymphoma is usually observed without treatment, given its indolent nature. Treatment, including chemotherapy and radiation therapy, is usually reserved for the relief of symptomatic disease to include bleeding, organ dysfunction, or gastrointestinal obstruction.<sup>83,99</sup>

Diffuse large B-cell lymphomas are a much more aggressive lesion than MALT lymphomas. The standard treatment regimen for DLBCL should include rituximab in addition to an anthracycline-based chemotherapy regimen.<sup>83,99</sup> Although early studies have suggested that either complete or partial gastrectomy in patients with early-stage DLBCL may have better survival outcomes and a reduced incidence of perforated viscus, obstruction, and bleeding, when compared to chemotherapy alone, more recent data contest these findings.<sup>83</sup>

Currently, the role for surgical intervention for any stage or histological type of gastric lymphoma is generally reserved for complications of the primary disease or the chemotherapy used to treat it.<sup>83,99</sup>

## GASTRIC CARCINOIDS

### Introduction

Carcinoids are an unusual group of neoplasms that arise from cells of neuroendocrine origin.<sup>111</sup> These tumors were first characterized as “carcinoids” by Siegfried Orbendorfer in 1907 based on their microscopic similarity to carcinomas, but generally indolent clinical course.<sup>112</sup> Carcinoids can occur in nearly any location, with approximately 55% arising from the gastrointestinal tract and 30% from the bronchopulmonary tree.<sup>113</sup> Gastric carcinoids represent only 11.7% of all gastrointestinal carcinoids, but their reported incidence has more than tripled over the past 50 years.<sup>114,115</sup> Although some of the observed increase may be due to more frequent use of upper endoscopic procedures over the past few decades, the increase in gastric carcinoid incidence is up relative to that of other gastric neoplasms. Overall, gastric carcinoids represent only a small fraction of gastric tumors accounting for about 1.8% of primary gastric neoplasms.<sup>116</sup>

Unlike carcinoids derived from the embryologic midgut and hindgut, gastric carcinomas do not typically secrete serotonin, characteristic of carcinoids derived from enterochromaffin cells. Gastric carcinoids generally arise from enterochromaffin-like (ECL) cells found in the acid-producing mucosa of the gastric body and fundus. These ECL cells account for approximately a third of all gastric endocrine-type cells and typically produce histamine as a means of regulating gastric acid production.<sup>117,118</sup>

### Classification

Three main types of gastric carcinoids are generally recognized, although a fourth type has recently been reported. Each of the three main types of carcinoids has distinct pathological and physiologically associated conditions, different potentials for metastasis and treatment algorithms.

Type I gastric carcinoids are the most benign and by far the most common gastric carcinoid, accounting for up to 85% of cases.<sup>111,119</sup> These lesions develop in the setting of chronic atrophic gastritis with concomitant achlorhydria, occurring in more than 1% of these patients.<sup>120</sup> Chronic atrophic gastritis creates a hypoacidic state with development of hypergastrinemia as a result of unabated G-cell stimulation. Chronic hypergastrinemia stimulates ECL-cell upregulation and may lead to ECL-cell hyperplasia that can progress to dysplasia and the development of carcinoid.<sup>121</sup> Type I gastric carcinoids tend to be multicentric and are limited to the body and the fundus of the stomach. They are almost always small, benign, polypoid lesions limited to the gastric mucosa and

submucosa.<sup>111,122</sup> They are generally asymptomatic lesions and have a low metastatic potential, with greater than 90% of lesions found to be confined to the gastric wall at the time of diagnosis.<sup>123,124</sup>

Type II gastric carcinoids are the rarest of gastric carcinoids accounting for only 5–10% of cases.<sup>111</sup> They also occur as a result of ECL-cell stimulation in response to hypergastrinemia; however, in these cases the hypergastrinemic state is the result of unchecked gastrin secretion from a gastrinoma rather than from chronic atrophic gastritis. The majority of type II gastric carcinoids are found in patients with Zollinger-Ellison syndrome (ZES) secondary to multiple endocrine neoplasia type I (MEN1) and a small minority in patients with sporadic ZES. There is undoubtedly more to the linkage between type II gastric carcinoids and ZES hypergastrinemia because the incidence of type II carcinoids in patients with ZES/MEN1 is up to 37%, whereas it is typically found in fewer than 2% of patients with sporadic ZES.<sup>125</sup> Like type I gastric carcinoids, type II gastric carcinoids are frequently multicentric, small tumors (<2 cm) with a relatively indolent clinical course. They occur in the gastric body and fundus and are confined to the gastric mucosa and submucosa in the majority of cases. Despite their relatively low metastatic potential, about 30% of patients have local lymph node involvement and as many as 12% will have metastatic disease at the time of diagnosis.<sup>123,126</sup>

Unlike types I and II gastric carcinoids, type III gastric carcinoids occur in the absence of hypergastrinemia or other notable pathological conditions and are therefore often described as “sporadic.” Although type III gastric carcinoids are usually found in the gastric body and fundus, they may occur in any portion of the stomach. They are the second most frequent type of gastric carcinoid, accounting for 15–25% of cases.<sup>111,119</sup> Type III carcinoids are typically larger (>2cm) lesions that demonstrate a high mitotic rate and nuclear atypia under light microscopy.<sup>119</sup> They are aggressive lesions that are found to be metastatic or involve locoregional lymph nodes in over 75% of patients at the time of diagnosis.<sup>125</sup> Type III gastric carcinoids carry a poorer long-term prognosis than types I and II gastric carcinoids, with a 5-year survival rate of less than 50%.<sup>127</sup> In addition, unlike types I and II carcinoids, type III carcinoids may be functional tumors, productive of histamine. When histamine is actively secreted by these lesions, patients may develop atypical carcinoid syndrome characterized by pruritus, cutaneous flushing, and bronchospasm.<sup>126</sup>

### Presentation and Diagnostic Workup

The diagnosis of gastric carcinoid is typically made in symptomatic patients undergoing diagnostic gastroscopy.<sup>128,129</sup> The most common presenting signs and symptoms in patients with gastric carcinoid are abdominal pain, gastrointestinal bleeding, and anemia. Other, less common symptoms include weight loss, reflux, obstruction, pruritus, wheezing, and skin flushing (Table 22-7).<sup>111,128,129</sup> Upper



**TABLE 22-7: PRESENTING SYMPTOMS IN A SERIES OF PATIENTS WITH GASTRIC CARCINOID<sup>126</sup>**

Symptoms	Percent of Patients
Abdominal pain	40
Gastrointestinal (GI) bleeding	14
Anemia without GI bleeding	17
Weight loss	6
Reflux	6

endoscopy with biopsy is generally sufficient to make the pathological diagnosis of gastric carcinoid. Lesion(s) must be biopsied and removed, if possible. In addition, multiple biopsies should be obtained from the gastric antrum, body, and fundus along both the greater and lesser curvatures in order to improve diagnostic accuracy and assess for atrophic gastritis.<sup>111,130</sup> EUS-guided fine-needle aspiration may be useful for submucosal lesions not amenable to standard endoscopic biopsy techniques.

A full history and physical examination should be performed with careful attention to a history of gastritis, abdominal pain, anemia, flushing, or wheezing. Additionally, a detailed personal and family history must be obtained looking for signs, symptoms, or a history of MEN1 syndrome. As with gastric lymphoma, the physical examination will rarely provide diagnostic clues suggestive of gastric carcinoid. Laboratory analysis can be helpful in establishing the diagnosis and type of carcinoid. All patients should have a CBC, chromogranin A, serum gastrin, serum calcium, and parathyroid hormone (PTH) level. Patients with anemia present on CBC should also have a serum B<sub>12</sub> and anti-intrinsic factor level evaluated. Gastric pH testing will be helpful in establishing the type of gastric carcinoid present, as it is expected to be high in type I, low in type II, and normal in type III gastric carcinoids.<sup>111</sup> Data combined from the CBC, B<sub>12</sub>, and anti-intrinsic factor studies in anemic patients help to determine whether pernicious anemia is present, indicative of type I carcinoids. A serum gastrin level will help differentiate between patients with type I/II carcinoids that typically have hypergastrinemia from those with type III carcinoid who will typically have normal gastrin levels. An elevated serum calcium and PTH level may be diagnostic of hyperparathyroidism and should alert the clinician to the potential diagnosis of MEN1 syndrome (Table 22-8). Elevation of chromogranin A is a relatively sensitive and specific marker for neuroendocrine cell tumors. An elevated chromogranin A level may be helpful in narrowing the prebiopsy differential diagnosis of carcinoid, but, more importantly, if elevated, it serves as a marker to follow the therapeutic response or disease progression and recurrence.<sup>131</sup>

For small (<1 cm) types I and II gastric carcinoids, staging workup beyond endoscopy and biopsy is generally not

**TABLE 22-8: GASTRIC CARCINOID CHARACTERISTICS BY TYPE<sup>108,114,116</sup>**

	Type I	Type II	Type III
<b>Percent of gastric carcinoids</b>	70–85%	5–10%	15–25%
<b>Gastric pH</b>	High	Low	Normal
<b>Serum gastrin</b>	High	High	Normal
<b>Associated conditions</b>	Atrophic gastritis Pernicious anemia	ZES MEN1	None
<b>Metastatic at presentation</b>	<5%	10–30%	50–100%
<b>Typical size</b>	<2 cm	<2 cm	>2 cm
<b>Location</b>	Fundus/body	Fundus/body	Fundus/ body/antrum
<b>Prognosis</b>	Good	Moderate	Poor

MEN1, multiple endocrine neoplasia type I; ZES, Zollinger-Ellison syndrome.

necessary, given the low potential for spread beyond the submucosa. Tumors larger than 1 cm, however, should undergo EUS to evaluate tumor depth of invasion and characterize possible local lymph node involvement.<sup>132</sup> All patients with type III carcinoids and those with large types I and II tumors found to invade the muscularis propria or involve local lymph nodes on EUS should undergo more extensive workup to rule out advanced locoregional or metastatic disease.<sup>132</sup> These patients should have a CT scan of the chest, abdomen, and pelvis at minimum with consideration for a somatostatin receptor scintigraphic study. The former is especially useful in detecting small diffuse disease that may be missed by CT.<sup>133,134</sup>

## Treatment

Treatment of gastric carcinoid is based on the type and the extent of disease. Treatment algorithms are similar for both types I and II gastric carcinoids with a few notable exceptions. Type III lesions, on the other hand, are treated far more aggressively because of their relatively high metastatic potential.

Both types I and II carcinoids have a generally indolent course and develop as a result of hypergastrinemia. The treatment for these lesions remains somewhat controversial, but, until appropriate clinical studies have been completed to support less invasive approaches, a more conservative treatment regimen should be pursued. If the lesion(s) are smaller than 1 cm, confined to the mucosa or submucosa and there are fewer than six total lesions in the stomach, endoscopic resection and close endoscopic follow-up is an appropriate treatment approach.<sup>111,135</sup> Somewhat more controversial are the recent recommendations of the European Neuroendocrine Tumor Society (ENETS) that is now advocating endoscopic surveillance only for type I gastric

carcinoids less than 1 cm.<sup>123</sup> These guidelines do not apply to type II carcinoids.

If more than six gastric lesions are present, partial gastrectomy is recommended. Because type I lesions develop as a result of G-cell–induced hypergastrinemia, a surgical antrectomy is also recommended.<sup>111</sup> Antrectomy is not indicated for type II carcinoids because the hypergastrinemia is the result gastrinoma. In these cases, surgical resection of the gastrinoma should be completed when feasible. In all cases, if these lesions recur, clear margins are not obtained, or surveillance demonstrates progression of the disease, surgical reexcision or gastrectomy should be performed. For patients undergoing surveillance endoscopy for small type I gastric carcinoids per ENETS guidelines and showing progression of disease, surgical resection of the lesion(s) with antrectomy versus total gastrectomy is indicated, depending on the extent of involvement.

When distant metastatic disease is present, traditionally treatment has involved medical therapy including, chemotherapeutic agents, radionuclides, and/or somatostatin analogues with minor benefit but no notable impact on long-term survival. Surgical therapy for these patients, on the other hand, has generally been reserved to treat limited metastatic lesions or complications of the disease, including gastrointestinal obstruction and bleeding. Recently, a small case series of patients undergoing aggressive surgical resection for metastatic gastric carcinoid had a mean 5-year survival rate of 82% with a reported increase in quality of life.<sup>136</sup> These data are intriguing; however, more substantial studies must be completed before this can be recommended as standard of care. Limited metastatic recurrences after gastrectomy may also be treated through surgical resection for favorable lesions or with radiofrequency ablation or chemoembolization if patients are not appropriate surgical candidates.<sup>137</sup>

Type III gastric carcinoids are far more aggressive lesions and should be approached similar to gastric adenocarcinoma.<sup>111</sup> Once extensive metastatic disease has been ruled out, all patients should undergo partial or total radical gastrectomy, depending on the extent of the disease at the time of diagnosis. An extended lymph node dissection has been advocated by some, but data showing any benefit of a D1 versus D2 node dissection for gastric carcinoid are absent.<sup>117</sup> Chemotherapy either as an adjunct to surgery or as the sole therapeutic modality in patients with a poor performance status or with widely metastatic disease is recommended, although it has been shown to be of limited benefit.<sup>117</sup>

## REFERENCES

- Crew KD, Neugut AI. Epidemiology of gastric cancer. *World J Gastroenterol.* 2006;12(3):354–362.
- Brenner H, Rothenbacher D, Arndt V. Epidemiology of stomach cancer. In: Verma M, ed. *Methods of Molecular Biology, Cancer Epidemiology.* Vol. 23. Totowa, NJ: Humana Press; 2009:467–477.
- Fock KM, Moayyedi P, Hunt R, et al. Asian-pacific consensus guidelines on gastric cancer prevention. *J Gastroenterol Hepatol.* 2008;23:351–365.
- Gastric cancer. In: *NCCN Clinical Practice Guidelines in Oncology.* V. 2. National Comprehensive Cancer Network; 2010.
- Parkin DM. International variation. *Oncogene.* 2004;23:6329–6340.
- Parkin D, Bray F, Ferlay J, et al. Global cancer statistics 2002. *CA Cancer J Clin.* 2005;55:74–108.
- Jemal A, Siegel R, Ward E, et al. Cancer statistics 2009. *CA Cancer J Clin.* 2009;59:225–249.
- Hundahl SA, Phillips JL, Menck HR. The national cancer data base report on poor survival of U.S. gastric carcinoma patients treated with gastrectomy. *Cancer.* 2000;88(4):921–932.
- Milne AN, Carneiro F, O'Morain C, et al. Nature meets nurture: molecular genetics of gastric cancer. *Hum Genet.* 2009;126(5):615–628.
- Al-Refaie WB, Tseng JF, Gay G, et al. The impact of ethnicity on the presentation and prognosis of patients with gastric adenocarcinoma. *Cancer.* 2008;113(3):461–469.
- Parkin DM, Whelan SL, Ferlay. *Cancer Incidence and Five Continents.* Vol VII. Lyon, France: International Agency for Research on Cancer; 1991:822–823.
- Nomura A. Stomach cancer. In: Scottenfeld D, Fraumeni JF, eds. *Cancer Epidemiology and Prevention.* 2nd ed. New York, NY: Oxford University Press; 1996:707–724.
- McMichael AJ, McCall MG, Hartshorne JM, et al. Patterns of gastrointestinal cancer in European immigrants to Australia: the role of dietary change. *Int J Cancer.* 1980;25:431–437.
- Coggon D, Osmond C, Barker DJ. Stomach cancer and migration with England and Wales. *Br J Cancer.* 1990;61:573–574.
- Lee J, Demissie J, Lu Se, et al. Cancer incidence among Korean-American immigrants in the United States and native Koreans in South Korea. *Cancer Control.* 2007;14(1):78–85.
- Helicobacter and cancer collaborative group. Gastric cancer and *Helicobacter pylori*: a combined analysis of 12 case control studies nested within prospective cohorts. *Gut.* 2009;49(3):347–353.
- Campbell DI, Warren BF, Thomas J, et al. The African enigma: low prevalence of gastric atrophy, high prevalence of chronic inflammation in West African adults and children. *Helicobacter.* 2001;6:263–267.
- IARC monograph on the evolution of carcinogenic risks to humans. Vol. 61: *Schistosomes, Liver Flukes and Helicobacter pylori.* Lyon, France: International Agency for Research on Cancer; 1994.
- Barreto-Zuinga R, Maruyama M, Kato Y, et al. Significance of *Helicobacter pylori* infection as a risk factor in gastric cancer: serological and histological studies. *J Gastroenterol.* 1997;32:289–294.
- Ekaström AM, Held M, Hansson LE, et al. *Helicobacter pylori* in gastric cancer established by CagA immunoblot as a marker of past infection. *Gastroenterology.* 2001;121:784–791.
- Uemura N, Okamoto S, Yamamoto S, et al. *Helicobacter pylori* infection and the development of gastric cancer. *N Engl J Med.* 2001;345:784–789.
- Correa P. *Helicobacter pylori* and gastric cancer: state of the art. *Cancer Epidemiol Biomarkers Prev.* 1996;5:477–481.
- González CA, Pera G, Agudo A, et al. Smoking and the risk of gastric cancer in the European Prospective Investigation into Gastric and Nutrition (EPIC). *Int J Cancer.* 2003;107:629–634.
- Calle EE. Obesity and cancer. *BMJ.* 2007;335:1107–1108.
- Lindblad M, Garcia Rodriguez LA, Lagergren J. Body mass, tobacco and alcohol and risk of esophageal, gastric cardia, and gastric non-cardia adenocarcinoma among men and women in a nested case-control study. *Cancer Causes Control.* 2005;16:285–294.
- Lagergren J, Bergström R, Nyren O. Association between body mass and adenocarcinoma of the esophagus and gastric cardia. *Ann Intern Med.* 1999;130:883–890.
- Calle EE, Rodriguez C, Walker-Thurmond K, et al. Over-weight, obesity and mortality from cancer in a prospectively studies cohort of U.S. adults. *New Engl J Med.* 2003;348:1625–1638.
- Tsugane S, Sasazuki S. Diet and the risk of gastric cancer: review of epidemiological evidence. *Gastric Cancer.* 2007;10:75–83.
- Wang X, Terry PD, Yan H. Review of salt consumption and stomach cancer risk: epidemiological and biological evidence. *World J Gastroenterol.* 2009;15(18):2204–2213.
- Sjodahl K, Jia C, Vatten L, et al. Salt and gastric adenocarcinoma: a population-based cohort study in Norway. *Cancer Epidemiol Biomarkers Prev.* 2008;17(8):1997–2001.
- Sokoloff B. Predisposition to cancer in the Bonaparte family. *Am J Surg.* 1938;40:637–638.

32. Slavotinek AM, Stone EM, Mykytyn K, et al. Methylation of the CDH1 promoter as the second genetic hit in hereditary diffuse gastric cancer. *Nat Genet.* 2000;26:16–17.
33. Cisco RM, Norton JA. Hereditary diffuse gastric cancer: surgery, surveillance and unanswered questions. *Future Oncol.* 2008;4(4):553–559.
34. Lynch HT, Silva E, Wirtzfield D, et al. Hereditary diffuse gastric cancer: prophylactic surgical oncology implications. *Surg Clin North Am.* 2008;88(4):759–778.
35. Maconi G, Manes G, Porro GB. Role of symptoms in diagnosis and outcome of gastric cancer. *World J Gastroenterol.* 2008;14(8):1149–1155.
36. Bodger K, Eastwood PG, Manning SI, et al. Dyspepsia workload in urban general practice and implications of the British society of gastroenterology dyspepsia guidelines. *Aliment Pharmacol Ther.* 2000;14:413–420.
37. Fransen GA, Janssen MJ, Muris JW, et al. Meta-analysis: the diagnostic value of alarm symptoms for upper gastrointestinal malignancy. *Aliment Pharmacol Ther.* 2004;20:1045–1052.
38. Breslin NP, Thomson AB, Bailey RJ, et al. Gastric cancer and other endoscopic diagnoses in patients with benign dyspepsia. *Gut.* 2000;46:93–97.
39. Sundar N, Muraleedharan V, Pandit J, et al. Does endoscopy diagnose early gastrointestinal cancer in patients with uncomplicated dyspepsia? *Postgrad Med J.* 2006;82:52–54.
40. Lieberman D, Fennerty MB, Morris CD, et al. Endoscopic evaluation of patients with dyspepsia: results from the national endoscopic data repository. *Gastroenterology.* 2004;127:1067–1075.
41. Janssen MJR, Fransen GAJ, Voutilainen M, et al. Alarm symptoms for gastric/oesophageal malignancy: a meta-analysis using individual patient data. *Gut.* 2005;54:A42.
42. Kapoor N, Basil A, Sturges R, et al. Predictive value of alarm features in a rapid access upper gastrointestinal cancer service. *Gut.* 2005;54:40–45.
43. Stephens MR, Lewis WG, White S, et al. Prognostic significance of alarm symptoms in patients with gastric cancer. *Br J Surg.* 2005;92:840–846.
44. Bowrey DJ, Griffin SM, Wayman J, et al. Use of alarm symptoms to select dyspeptics for endoscopy causes patients with curable esophago-gastric cancer to be overlooked. *Surg Endosc.* 2006;20:1725–1728.
45. Abdalla EK, Pisters PW. Staging and preoperative evaluation of upper gastrointestinal malignancies. *Semin Oncol.* 2004;31(4):513–529.
46. Kwee RM, Kwee TC. Imaging in local staging of gastric cancer: a systematic review. *J Clin Oncol.* 2007;25(15):2107–2116.
47. Greene FL, Page DL, Fleming ID, et al. *AJCC Cancer Staging Manual.* 6th ed. Philadelphia, PA: JB Lippincott; 2002:111–118.
48. Mezhir M, Tang L, Coit G. Neoadjuvant therapy of locally advanced gastric cancer. *J Surg Oncol.* 2010;101:305–314.
49. Moehler M, Lycos O, Gockel I, et al. Multidisciplinary management of gastric and gastroesophageal cancers. *World J Gastroenterol.* 2008;14:3773–3780.
50. Paoletti X, Obab K, Burzykowski T, et al. Benefit of adjuvant chemotherapy for resectable gastric cancer. A Meta-analysis. *JAMA.* 2010;303:1729–1737.
51. Cunningham D, Allum WH, Stenning SP, et al. Perioperative chemotherapy versus surgery alone for resectable gastroesophageal cancer. *N Engl J Med.* 2006;355:11–20.
52. Ito H, Clancy TE, Osteen RT, et al. Adenocarcinoma of the gastric cardia: what is the optimal surgical approach? *J Am Coll Surg.* 2004;199(6):880–886.
53. Hermanek P, Wittekind C. Residual tumor classification and prognosis. *Semin Surg Oncol.* 1994;10:12–20.
54. Bozzetti F, Marubini E, Bonfanti G, et al. Subtotal versus total gastrectomy for gastric cancer: five-year survival rates in a multicenter randomized Italian trial. Italian gastrointestinal tumor study group. *Ann Surg.* 1999;230:170–178.
55. Davies J, Johnston D, Sue-Ling H, et al. Total or subtotal gastrectomy for gastric cancer? A study of quality of life. *World J Surg.* 1998;22(10):1048–1055.
56. Kojima K, Yamada H, Inokucji M, et al. Current status and evaluation of laparoscopic surgery for gastric cancer. *Dig Endosc.* 2007;20(1):1–5.
57. Kiyama T, Mizutani T, Okuda T, et al. Laparoscopic surgery for gastric cancer: 5 years' experience. *J Nihon Med Sch.* 2006;73(4):214–220.
58. Kiyama T, Jijita I, Kanno H, et al. Laparoscopy-assisted distal gastrectomy for gastric cancer. *J Gastrointest Surg.* 2008;12(10):1807–1811.
59. Kajitani T. Japanese research society for the study of gastric cancer. The general rules for gastric cancer study in surgery and pathology. *Jpn J Surg.* 1981;11:127–145.
60. Zhang H, Liu C, Wu D, et al. Does D3 surgery offer a better survival outcome compared to D1 surgery for gastric cancer? A result based on a hospital population of two decades as taking D2 surgery for reference. *BMC Cancer.* 2010;10:308.
61. Roviello F, Pedrazzani C, Marrelli D, et al. Super-extended (D3) lymphadenectomy in advanced gastric cancer. *Eur J Surg Oncol.* 2010;36:439–446.
62. Deguli A, Sasako M, Ponti A. Survival results of a multicentre phase II study to evaluate D2 gastrectomy for gastric cancer. *Br J Cancer.* 2004;90:1727–1732.
63. Bonenkamp JJ, Songun I, Hermans J, et al. Randomized comparison of morbidity after D1 and D2 dissection for gastric cancer 996 Dutch patients. *Lancet.* 1995;345:745–748.
64. Bonenkamp JJ, Hermans J, Sasako M, et al. Extended lymph node dissection for gastric cancer. *N Engl J Med.* 1999;340:908–958.
65. Cuschieri A, Fayers P, Fielding J, et al. Postoperative morbidity and mortality after D1 and D2 resections for gastric cancer: preliminary results of the MRC randomized controlled surgical trial. *Lancet.* 1996;347:995–999.
66. Cuschieri A, Weeden S, Fielding J, et al. Patient survival after D1 and D2 resections for gastric cancer: long term results of the MRC surgical trial. *Br J Cancer.* 2000;79:1522–1530.
67. Hartgrink CJH, van de Velde H, Putter JJ, et al. Extended lymph node dissection for gastric cancer: who may benefit? Final results of the randomized Dutch Gastric Cancer Group Trial. *J Clin Oncol.* 2004;22:2069–2077.
68. McCulloch P, Nita ME, Kazi H, et al. Extended versus limited lymph nodes dissection technique for adenocarcinoma of the stomach [review]. *Cochrane Database Syst Rev.* 2009;1:1–28.
69. Marrelli D, De Stefano A, de Manzoni G, et al. Italian research group for cancer. Prediction of recurrence after radical surgery for gastric cancer: a scoring system obtained from a prospective multicenter study. *Ann Surg.* 2005;241:247–255.
70. Sasako M, Sano T, Yamamoto S, et al. D2 lymphadenectomy alone or with para-aortic nodal dissection for gastric cancer. *New Engl J Med.* 2008;359:453–462.
71. Songun I, Putter H, Meershoek-Klein Kranenbarg E, et al. Surgical treatment of gastric cancer: 15-year follow-up results of the randomized nationwide Dutch D1D2 trial. *Lancet.* 2010;11:439–449.
72. Zhang M, Zhu G, Ma Y, et al. Comparison of four staging systems of lymph node metastasis in gastric cancer. *World J Surg.* 2009;33(11):2383–2388.
73. Ono H, Kondo H, Gotoda T, et al. Endoscopic mucosal resection for treatment of early gastric cancer. *Gut.* 2000;48:225–229.
74. Gotoda K, Yanagisawa A, Sasako M, et al. Incidence of lymph node metastasis from early gastric cancer. The estimation using a large number of cases in two large centers. *Gastric Cancer.* 2000;3:219–225.
75. Abe M, Mori T, Takeuchi H, et al. Laparoscopic lymph node dissection after endoscopic submucosal dissection: a novel and minimally invasive approach to treating early-stage gastric cancer. *Am J Surg.* 2005;190(3):496–503.
76. Abe N, Mori T, Izumisato Y, et al. Successful treatment of an undifferentiated early gastric cancer by combined en bloc endoscopic mucosal resection and laparoscopic regional lymphadenectomy. *Gastrointest Endosc.* 2003;57:972–975.
77. Liedman B. Symptoms after total gastrectomy on food intake, body composition, bone metabolism, and quality of life in gastric cancer patients—is reconstruction with a reservoir worthwhile? *Nutrition.* 1999;15(9):676–682.
78. Gertler R, Rosenberg R, Feith M, et al. Pouch vs. no pouch following total gastrectomy: meta-analysis and systematic review of the literature. *Am J Gastroenterol.* 2009;104(11):2838–2851.
79. de Almeida AC, dos Santos NM, Aldeia FJ. Total gastrectomy for cancer: is reconstruction or a gastric replacement reservoir essential? *World J Surg.* 1994;18(6):883–888.
80. Mochiki E, Kamiyama Y, Aihara R, et al. Postoperative functional evaluation of jejunal interposition with or without a pouch after a total gastrectomy for gastric cancer. *Am J Surg.* 2004;187(6):728–735.
81. Iwata T, Kurita AT, Ikemoto T, et al. Evaluation of reconstruction after proximal gastrectomy: prospective comparative study of jejunal interposition and jejunal pouch interposition. *Hepatogastroenterology.* 2006;53(68):301–303.
82. Tono C, Terashima M, Takagane A, et al. Ideal reconstruction after total gastrectomy by the interposition of a jejunal pouch considered by emptying time. *World J Surg.* 2003;27:1113–1118.
83. Ferrucci PF, Zucca E. Primary gastric lymphoma pathogenesis and treatment: what has changed over the past 10 years? *Br J Haematol.* 2006;136:521–538.



84. Parkin DM, Pisani P, Ferlay J. Global cancer statistics. *CA Cancer J Clin.* 1999;49:31–64.
85. Groves FD, Linet MS, Travis LB, et al. Cancer surveillance series; non-Hodgkin's lymphoma incidence by histologic subtype in the United States from 1978–1995. *J Natl Cancer Inst.* 2000;92:1240–1251.
86. D'Amore F, Brincker H, Gronbaek, et al. Non-Hodgkin's lymphoma of the gastrointestinal tract: a population-based analysis of incidence, geographic distribution, clinicopathologic presentation features, and prognosis. Danish Lymphoma Study Group. *J Clin Oncol.* 1994;12:1673–1684.
87. D'Amore F, Christensen BE, Brincker H, et al. Clinicopathological features and prognostic factors in extranodal non-Hodgkin lymphomas. Danish LYFO Study Group. *Eur J Cancer.* 1991;27:1201–1208.
88. Koch P, del Valle F, Berdel WE, et al. Primary gastrointestinal non-Hodgkin's lymphoma: 1. Anatomic and histologic distribution, clinical features, and survival data of 371 patients registered in the German Multicenter Study GIT HIH 01/92. *J Clin Oncol.* 2001;19:3861–3873.
89. Papaxoinis G, Papageorgiou S, Rontogianni D, et al. Primary gastrointestinal non-Hodgkin's lymphoma: a clinicopathologic study of 128 cases in Greece. A Hellenic Cooperative Oncology Group study (HeCOG). *Leuk Lymphoma.* 2006;47:2140–2146.
90. Venizelos I, Tamiolakis D, Bolioti S, et al. Primary gastric Hodgkin's lymphoma: a case report and review of the literature. *Leuk Lymphoma.* 2005;46:147–150.
91. Boot H. Diagnosis and staging in gastrointestinal lymphoma. *Best Pract Res Clin Gastroenterol.* 2010;24:3–12.
92. Jaffe E. The 2008 WHO classification of lymphomas: implications for clinical practice and translational research. *Hematology Am Soc Hematol Educ Program.* 2009;523–531.
93. Swerdlow SH, Campo E, Harris NL, et al. *WHO Classification of Tumors of Haematopoietic and Lymphoid Tissues.* 4th ed. Lyon, France: IARC Press; 2008.
94. Koch P, Probst A, Berdel WE, et al. Treatment results in localized primary gastric lymphoma: data from patients registered with the German Multicenter Study (GIT NHL 02/96). *J Clin Oncol.* 2005;23:7050–7059.
95. Wotherspoon AC, Ortiz-Hidalgo C, Falzon MR, et al. *Helicobacter pylori*-associated gastritis and primary B-cell gastric lymphoma. *Lancet.* 1991;338:1175–1176.
96. Wundisch T, Thiede C, Morgner A, et al. Long-term follow-up of gastric MALT lymphoma after *Helicobacter pylori* eradication. *J Clin Oncol.* 2005;23:8018–8024.
97. Wundisch T, Mosch C, Neubauer A, et al. *Helicobacter pylori* eradication in gastric mucosa-associated lymphoid tissue lymphoma: results of a 196-patient series. *Leuk Lymphoma.* 2006;47:2110–2114.
98. Ferreri AJ, Freschi M, Del'oro S, et al. Prognostic significance of the histopathologic recognition of low- and high-grade components in stage I-II B-cell gastric lymphomas. *Am J Surg Pathol.* 2001;25:95–102.
99. Psyrris A, Papageorgiou S, Economopoulos T. Primary extranodal lymphomas of stomach: clinical presentation, diagnostic pitfalls and management. *Ann Oncol.* 2008;19:1992–1999.
100. Farinha P, Gascoyne RD. Molecular pathogenesis of mucosa-associated lymphoid tissue lymphoma. *J Clin Oncol.* 2005;23:6370–6378.
101. Cogliatti SB, Schmid U, Schumacher U, et al. Primary B-cell gastric lymphoma: a clinicopathological study of 145 patients. *Gastroenterology.* 1991;101:1159–1170.
102. Elstrom R, Guan L, Baker G, et al. Utility of FDG-Pet scanning in lymphoma by WHO classification. *Blood.* 1971;101:3875–3876.
103. Alinari L, Castellucci P, Elstrom R, et al. 18F-FDG PET in mucosa-associated lymphoid tissue (MALT) lymphoma. *Leuk Lymphoma.* 2006;10:2096–2101.
104. Boot h, de Jong D. Diagnosis, treatment decisions and follow-up in primary gastric lymphoma. *Gut.* 2002;51:621–622.
105. Fischbach W. Gastric mucosa-associated lymphoid tissue lymphoma: a challenge for endoscopy. *Gastrointest Endosc.* 2008;68:623–626.
106. Fischbach W, Goebeler-Kolve ME, Greiner A. Diagnostic accuracy of EUS in local staging of primary gastric lymphoma: results of a prospective, multicenter study comparing EUS with histologic stage. *Gastrointest Endosc.* 2002;56:696–700.
107. Musshoff K. Clinical staging classification of non-Hodgkin's lymphoma. *Strahlentherapie.* 1977;153:218–221.
108. Fischbach W, Goebeler-Kolve M, Dragosics B, et al. Long-term results of the German-Austrian prospective multicenter study in patients with localized primary gastric B-cell lymphoma. *Gastroenterology.* 2001;120(suppl. 1):A612.
109. Fischbach W. Long-term follow-up of gastric lymphoma after stomach conserving treatment. *Best Pract Res Clin Gastroenterol.* 2010;24:71–77.
110. Aviles A, Nambo MJ, Neri N, et al. Mucosa-associated lymphoid tissue (MALT) lymphoma of the stomach: results of a controlled clinical trial. *Med Oncol.* 2005;22:57–62.
111. Massironi S, Sciola V, Spampatti MP, et al. Gastric carcinoids: Between underestimation and overtreatment. *World J Gastroenterol.* 2009;15(18):2177–2183.
112. Obendorfer S. Karzinoide tumoren des dunndarms. *Frankf Zschr Pathol.* 1907;1:426–430.
113. Maggard MA, O'connell JB, Ko CY. Updated population-based review of carcinoid tumors. *Ann Surg.* 2004;240:117–122.
114. Landry CS, Brock G, Scoggins CR, et al. A proposed staging system for gastric carcinoid based on an analysis of 1,543 patients. *Ann Surg Oncol.* 2009;16:51–60.
115. Soga J. Gastric carcinoids: a statistical evaluation of 1,094 cases collected from the literature. *Surg Today.* 1997;27:892–901.
116. Modlin IM, Iye KD, Kidd M. A 50-year analysis of 562 gastric carcinoids: small tumor or larger problem? *Am J Gastroenterol.* 2004;99:23–32.
117. Mulkeen A, Cha C. Gastric carcinoid. *Curr Op Oncol.* 2005;17:1–6.
118. Burkit MD, Pritchard DM. Review article: pathogenesis and management of gastric carcinoid tumours. *Aliment Pharmacol Ther.* 2006;24:1305–1320.
119. Delle Fave G, Capurso G, Milione M, et al. Endocrine tumours of the stomach. *Best Pract Res Clin Gastroenterol.* 2005;19(5):659–673.
120. Annibale B, Azzoni C, Corleto VD, et al. Atrophic body gastritis patients with enterochromaffin-like cell dysplasia are at increased risk for the development of type I gastric carcinoid. *Eur J Gastroenterol Hepatol.* 2001;13:1449–1456.
121. Peracchi M, Gebbia C, Basilisco G, et al. Plasma chromogranin A in patients with autoimmune chronic atrophic gastritis, enterochromaffin-like cell lesions and gastric carcinoids. *Eur J Endocrinol.* 2005;152:443–448.
122. Bordi C. Gastric carcinoids. *Ital J Gastroenterol Hepatol.* 1999;31(suppl 2):S94–S97.
123. Rindi G, Bordi C, Rappell S, et al. Gastric carcinoids and neuroendocrine carcinomas: pathogenesis, pathology and behavior. *World J Surg.* 1996;20:168–172.
124. Schindl M, Kaserer K, Niederle B. Treatment of gastric neuroendocrine tumors—the necessity of a type-adapted treatment. *Arch Surg.* 2001;136:49–54.
125. Jensen RT. Management of the Zollinger-Ellison syndrome in patients multiple endocrine neoplasia type 1. *J Intern Med.* 1998;243:477–488.
126. Rindi G, Luinetti O, Cornaggia M, et al. 3 Subtypes of gastric argyrophil carcinoid and gastric neuroendocrine carcinoma—a clinicopathological study. *Gastroenterology.* 1993;104:994–1006.
127. Modlin IM, Kidd M, Iye KD. Biology and management of gastric carcinoid tumours: a review. *Eur J Surg.* 2002;168:669–683.
128. Onaitis MW, Kirshbom PM, Hayward TZ, et al. Gastrointestinal carcinoids: characterization by the site of origin and hormone production. *Ann Surg.* 2000;232:549–555.
129. Borch K, Ahren B, Ahlman, H, et al. Gastric carcinoids: biologic behavior and prognosis after differentiated treatment in relation to type. *Ann Surg.* 2005;242:64–73.
130. Bordi C, Azzoni C, Ferraro G, et al. Sampling strategies for analysis of enterochromaffin-like cell changes in Zollinger-Ellison syndrome. *Am J Clin Pathol.* 2000;114:419–425.
131. Campana D, Nori F, Piscitelli L, et al. Chromogranin A: is it a useful marker for neuroendocrine tumors? *J Clin Oncol.* 2007;25:1967–1973.
132. Ruzsniowski P, Delle Fave G, Cadiot G, et al. Well-differentiated gastric tumours/carcinomas. *Neuroendocrinology.* 2006;84:158–164.
133. Lamberts SW, Bakker WH, Reubi JC, et al. Somatostatin-receptor imaging in the localization of endocrine tumors. *N Engl J Med.* 1990;323:1246–1249.
134. Reubi JC, Krenning E, Lamberts SW, et al. Somatostatin receptors in malignant tissues. *J Steroid Biochem Mol Biol.* 1990;37:1073–1077.
135. Ichikawa J, Tanabe S, Koizumi W, et al. Endoscopic mucosal resection in the management of gastric carcinoid tumors. *Endoscopy.* 2003;35:203–206.
136. Siperstein A, Garland A, Engle K, et al. Local recurrence after laparoscopic radiofrequency ablation of hepatic tumors. *Ann Surg Oncol.* 2000;7:106–113.
137. Steinmuller T, Kianmanesh R, Falconi M, et al. Consensus guidelines for the management of patients with liver metastasis from digestive (neuro) endocrine tumors: foregut, midgut, hindgut and unknown primary. *Neuroendocrinology.* 2008;87:47–62.



*This page intentionally left blank*

# PERSPECTIVE ON GASTRIC CANCER

Mitsuru Sasako • Hisashi Shinohara

## CURATIVE SURGERY FOR GASTRIC CANCER

### Theoretical Background

Dissection of regional lymph nodes had been controversial until recently, but an accumulation of evidence has led us to conclude that D2 dissection should be the standard surgery for potentially curable advanced gastric cancer in most of the world, including Europe. Details of these studies are included in the Chap. 22. It is worth emphasizing the importance of the quality of surgical treatment in clinical trials. The initial three trials—the South African, the Hong Kong, and the Medical Research Council (MRC) trials<sup>1-3</sup>—had problems with the quality of the surgery. The first two trials were single institutional studies and, although hospital mortality was not high, survival data were poor. In the MRC study, there was no serious quality control for D2 surgery, and both hospital mortality and survival results for the D2 arm were poor. In the Dutch study, their quality effort made the results better than in the MRC study, but hospital mortality was nearly 10% after D2 dissection.<sup>4</sup> Regarding overall long-term survival, D2 dissection was better than D1, although not systematically significantly. In 15-year follow-up, they demonstrated significantly better local control and disease-specific overall survival (OS).<sup>5</sup> These results are not clear evidence but strongly suggest the benefit of D2 dissection in a Western population. Even in the Dutch study, most of participating surgeons had a quite limited experience with D2 surgery before the study and had quite low hospital volumes throughout the study. We would suggest that the quality of the surgery and postoperative care was not sufficient. All the meta-analyses comparing D1 and D2 resection are therefore unreliable. The Taiwanese study, a single institutional study comparing D1 versus D2, demonstrated significantly better OS after D2 dissection in Asian patients.<sup>6</sup> Later, Hundahl et al, both in the INT-0116 and the Dutch studies, reported that insufficient nodal dissection reduces the OS of gastric cancer patients.<sup>7,8</sup>

### Safe Surgical Margin

According to the recent Japanese gastric cancer treatment guidelines of the Japan Gastric Cancer Association (JGCA),<sup>9</sup> a proximal margin of at least 3 cm is recommended for T2 or deeper tumors with an expansive growth pattern, and 5 cm is recommended for those with infiltrating growth pattern. When these rules cannot be applied, a frozen-section examination of the resection margin (in such cases as those invading the esophagus) is recommended. For T1 tumors, a gross resection margin of 2 cm should be obtained. However, tumor borders of T1 tumors are often unclear; stepwise biopsies are often appropriate preoperatively.

### Laparoscope-Assisted Gastrectomy for Gastric Cancer

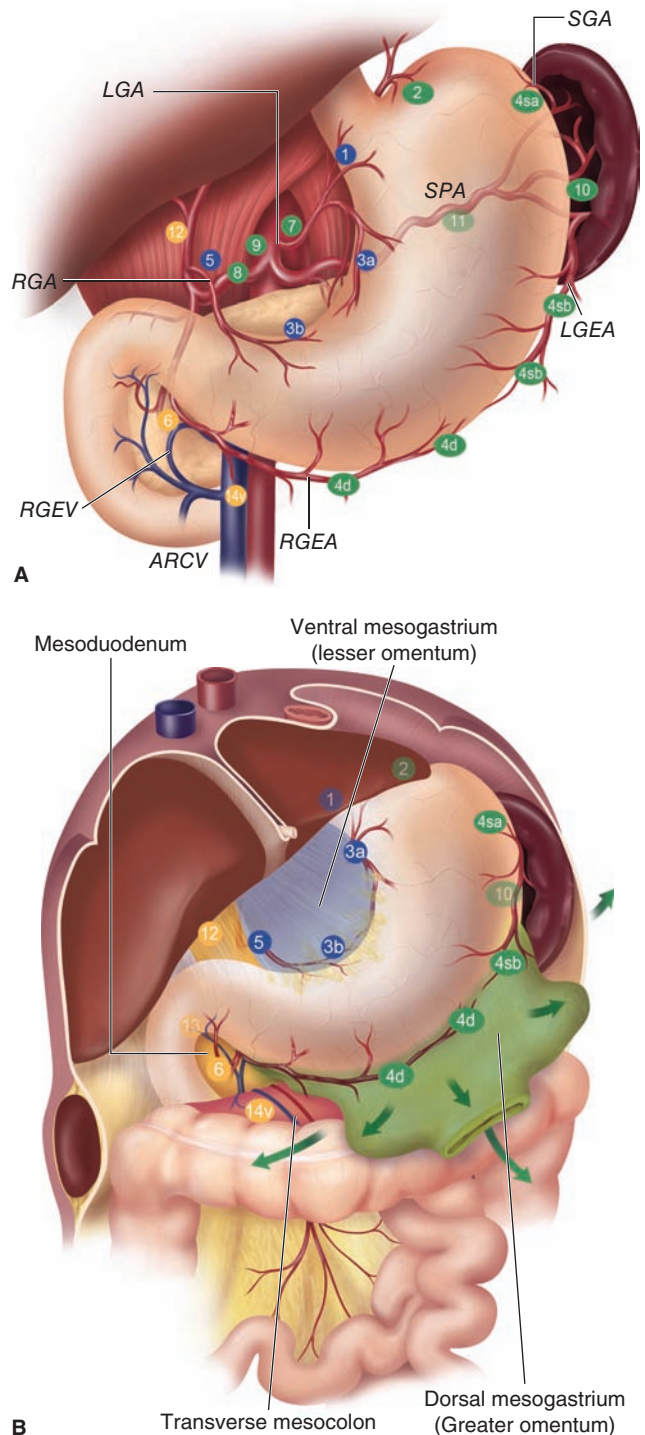
In Japan, many surgeons are performing laparoscope-assisted gastrectomy (LAG) for stage I tumors, although LAG is regarded as an experimental treatment even for stage I lesions in the guidelines. At the moment, there is no evidence demonstrating equivalence of long-term survival with this procedure. There are two large randomized controlled trials (RCTs) comparing LAG versus open gastrectomy for stage I tumors. The Korean RCT (KLASS study) is expected to enroll 1400 patients and the Japan Clinical Oncology Group (JCOG 0912) study will enroll 920 patients. In many respects, LAG has limitations: lack of tactile sensation; difficulty or impossibility of widely spreading the membranes, which is essential for proper D2 dissection; a compromised reconstruction technique; and a much larger variation in surgical skill. Gastric cancer has a high incidence of peritoneal recurrence, and with the frequent appearance of tumor deposits in fatty tissue surrounding the organ and the preservation of vessels during lymphadenectomy, the risk of increasing recurrence using laparoscopic approaches seems higher than is the case for colorectal cancer surgery.

## SURGICAL TECHNIQUE

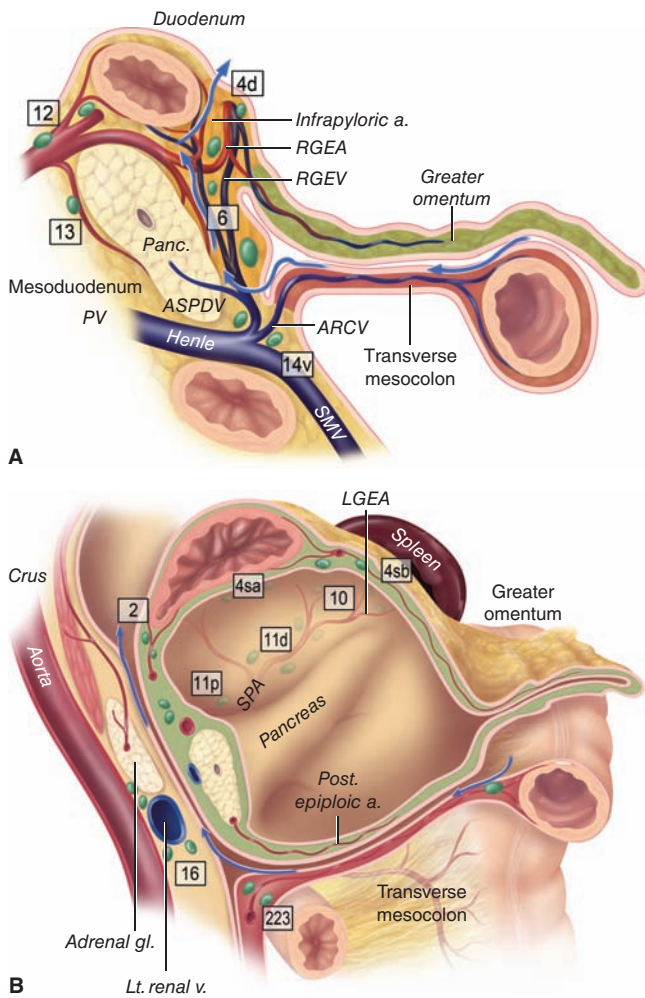
The basic technique of lymph node dissection is common for all gastrointestinal cancers, but, because of the high incidence of tumor deposits in the adipose tissue and significant tendency of developing peritoneal metastasis in gastric cancer, dissection without destroying the thin membranes surrounding the fatty tissue where all nodes and tumor deposits are imbedded is of paramount importance. To perform a proper lymph node dissection of the stomach, an understanding of the unique anatomical structure is essential. The stomach has two mesenteries: the dorsal mesogastrium and the ventral mesogastrium. Moreover, the distal part of the organ is fed by the ventral and dorsal mesoduodenum. During the rotation of the intestinal system, the ventral mesogastrium becomes the lesser omentum and the dorsal mesogastrium becomes the greater omentum. Arteries originating in the ventral mesogastrium include the right gastric artery from the proper hepatic artery and the gastric branch of the left gastric artery, which becomes quite short during the rotation of the intestinal tract, although the origin of the left gastric artery is located in the dorsal mesogastrium. The location of regional lymph node stations and vessels to the stomach<sup>10</sup> is shown in Fig 23-1A. The last part of the antrum (4–6 cm) and the first portion the duodenum (duodenal bulb) are fed by the inferior pyloric vessels in the dorsal mesoduodenum and by the supraduodenal vessels in the ventral mesoduodenum. To treat an antral cancer, proper dissection of both the mesogastrium and also the mesoduodenum is essential. The incidence of metastasis to the infrapyloric node station is nearly 50% for distal cancers that are T2 or more, and more than 40% of those having such metastasis will survive more than 5 years. The greater omentum originally hangs between the dorsal pancreas and the stomach and gradually fuses with the mesocolon. Then it elongates toward and over the ventral pancreas and the duodenum (see Fig. 23-1B, Fig. 23-2A). To carry out complete omentectomy, dissection from the anterior pancreatic fascia is essential. The omentobursectomy is the best way to safely access the root of the right gastroepiploic vein (see Fig 23-2A).

A. About 26% of metastatic nodes are 4 mm or less in largest dimension and they look normal.<sup>11</sup> However, they are sometimes swollen and adhere to the membranes wrapping the fatty tissue and perinodal deposits, or directly invade the neural sheath surrounding the major branches of the celiac artery. In the latter case, nodal dissection should extend along the adventitial layer of the major arteries (common or proper hepatic, splenic and celiac arteries), and, in the former case, the nerves should be preserved as well.

To carry out a D2 dissection without splenectomy, meticulous dissection along the splenic vessels and the splenic hilum is needed. For safe dissection of this area, accurate knowledge of the basic anatomy and its variations is essential. The branch-off point of the posterior gastric artery varies widely; it is sometimes at 3–4 cm from the root of the splenic artery and sometimes close to the splenic hilum. There are three or four short gastric



**FIGURE 23-1** **A.** Numbers in circles indicate lymph node stations according to the Japanese classification of gastric carcinoma (3rd English edition). Blue ones belong to the ventral mesogastrium, green ones to dorsal mesogastrium, and yellow ones to mesoduodenum. ARCV, accessory right colic vein; IPA, inferior pyloric artery; LGA, left gastric artery; LGEA, left gastroepiploic artery; RGA, right gastric artery; RGEA, right gastroepiploic artery; RGEV, right gastroepiploic vein; SDA, supraduodenal artery; SGA, short gastric artery; SPA, splenic artery. **B.** Development of omentum, mesogastrium, and mesoduodenum. Numbers in circles indicate lymph node stations according to the Japanese classification of gastric carcinoma.



**FIGURE 23-2** **A.** Sagittal transactional scheme near the origin of the right gastroepiploic vessels. Anatomical structures of the greater omentum, transverse colon and mesocolon, pancreas head, and duodenum are shown with vessels surrounding the organs. The ventral mesoduodenum includes the supraduodenal vessels, and the dorsal mesoduodenum includes infrapyloric vessels. The origins of the dorsal mesoduodenum and mesogastrium share the common root that joins with the anterosuperior pancreatoduodenal vein and the accessory right colic vein, making Henle's common trunk. ARCVC, accessory right colic vein; ASPDV, anterosuperior pancreatoduodenal vein; GDA, gastroduodenal artery; IPA, infrapyloric artery; Pnac, pancreas; PV, portal vein; RGEA, right gastroepiploic artery; RGEV, right gastroepiploic vein; SDA, supraduodenal artery; SMV, superior mesenteric vein. **B.** Sagittal transaction near the root of the splenic artery and 3D scheme of the structures left lateral to the transection. All lymph nodes along the splenic vessels and posterior gastric vessels and in the splenic hilum are located between the posterior pancreatic fascia of Toldt and the posterior floor of the Bursa omentalis. Numbers in rectangles indicates lymph node stations according to the Japanese classification. LRV, left renal vein; PEA, posterior epiploic artery; PGA, posterior gastric artery; SPA, splenic artery.

arteries, each of which comes ventrally from the final branches of the splenic artery going into the splenic parenchyma. The left gastroepiploic artery is usually the most caudal branch of the splenic artery coming caudal along the splenic hilum. Often, it has a common trunk with the inferior pole branch to the spleen. As demonstrated in the Fig 23-2B, all nodes are included in the layer between the posterior pancreatic fascia of Toldt and the posterior floor of the Bursa omentalis. In the past, when the majority of gastric cancers were large and accompanied by large nodal metastasis surrounding the left gastric, splenic, and celiac arteries, en bloc resection of the entire tumor required the combined resection of the pancreatic tail with the spleen. This procedure that had been carried out for prophylactic dissection of the splenic artery and hilar lymph nodes was abandoned because of the higher mortality and morbidity with limited survival benefit compared with pancreas-preserving total gastrectomy. Now, this extended surgery is utilized only for T4b tumors invading the pancreas.

- B.** Our preferred method of reconstruction after a distal gastrectomy is a Roux-en-Y (RY), via a retrocolic route. There are a few reasons. First, anastomotic leak is much less common after gastrojejunostomy (including Billroth type II) than gastroduodenostomy (Billroth type I). Second, there is much less risk of reflux esophagitis caused by bile reflux, which is often seen after gastroduodenostomy. Third, severe gastritis of the remnant stomach is rare, which is often seen after Billroth type I. On the other hand, some authors claim a high incidence of so-called RY stasis and the uncut RY has been proposed to avoid it. As we personally seldom have patients who develop RY syndrome, this is not caused by interruption of the peristaltic signal but by hampered movement of the anastomosed intestine due to kinking or bending that is caused by adhesions to the dissected area above the mesocolon. We construct the gastrojejunostomy using a retrocolic route and fix the distal part of the stomach to the orifice of the hole in the mesocolon, so that the entire jejunum is located below the mesocolon and has less chance to kink or bend.

## REFERENCES

- Dent DM, Madden MV, Price SK. Randomized comparison of R1 and R2 gastrectomy for gastric carcinoma. *Br J Surg.* 1988;75:110-112.
- Robertson CS, Chung SCS, Woods SDS, et al. A prospective randomized trial comparing R1 subtotal gastrectomy with R3 total gastrectomy for antral cancer. *Ann Surg.* 1994;220:176-182.
- Cuschieri A, Weeden S, Fielding J, et al. Patient survival after D1 and D2 resection for gastric cancer: long-term results of the MRC randomized surgical trial. *Br J Cancer.* 1999;79:1522-1530.
- Bonenkamp JJ, Hermans J, Sasako M, van de Velde CJH. Extended lymph-node dissection for gastric cancer. *N Engl J Med.* 1999;340:908-914.
- Songun I, Putter H, Kranenbarg EMK, Sasako M, van de Velde CJH. Surgical treatment of gastric cancer: 15-year follow-up results of the randomised nationwide Dutch D1D2 trial. *Lancet Oncol.* 2010;11:439-449.
- Wu CW, Hsiung CA, Lo SS, et al. Nodal dissection for patients with gastric cancer: a randomised controlled trial. *Lancet Oncol.* 2006;7:309-315.



7. Hundahl SA, Macdonald JS, Benedetti J, Fitzsimmons T; Southwest Oncology Group and the Gastric Intergroup. Surgical treatment variation in a prospective randomized trial of chemoradiotherapy in gastric cancer: the effect of undertreatment. *Ann Surg Oncol*. 2003;9:278–286.
8. Peeters KCMJ, Hundahl SA, Kranenbarg EK, Hartgrink H, van de Velde CJH. Low Maruyama index surgery for gastric cancer: blinded reanalysis of the Dutch D1-D2 trial. *World J Surg*. 2005;29:1576–1584.
9. Japanese Gastric Cancer Association. Japanese gastric cancer treatment guideline 2010 [ver. 3]. *Gastric Cancer*. 2011;14:113–123.
10. Japanese Gastric Cancer Association. Japanese classification of gastric carcinoma: 3rd English edition. *Gastric Cancer*. 2011;14:101–112.
11. Noda N, Sasako M, Yamaguchi N, Nakanishi Y. Ignoring small lymph nodes can be a major cause of staging error in gastric cancer. *Br J Surg*. 1998;85:831–834.

# GASTROINTESTINAL STROMAL TUMORS

Chandrajit P. Raut

## INTRODUCTION

Gastrointestinal stromal tumors (GISTs) are rare neoplasms. Although they represent only 0.1–3% of all gastrointestinal (GI) malignancies,<sup>1–4</sup> they account for 80% of gastrointestinal mesenchymal neoplasms.<sup>5</sup> Approximately 5000–6000 new cases are diagnosed per year in the United States, for an annual incidence of 14.5 per million and prevalence of 129 per million.<sup>6</sup> In the last 12 years, the understanding and treatment of GIST has witnessed remarkable advances due to two key developments: (1) the identification of constitutively active signals (oncogenic mutation of the *c-kit* and platelet-derived growth factor receptor alpha [*PDGFRA*] gene–encoding receptor tyrosine kinases) and (2) the development of therapeutic agents that suppress tumor growth by specifically targeting and inhibiting this signal (imatinib mesylate, sunitinib malate). These developments in the management of GIST represent a proof of the principle of translational therapeutics in oncology, confirming that specific inhibition of tumor-associated receptor tyrosine kinase activity may be an effective cancer treatment. The advent of effective therapy for GIST has not diminished but rather redefined the role of surgery for this disease. This chapter reviews the biology, treatment, and emerging clinical challenges of these mesenchymal neoplasms.

## PATHOLOGIC FEATURES

### Historical Background

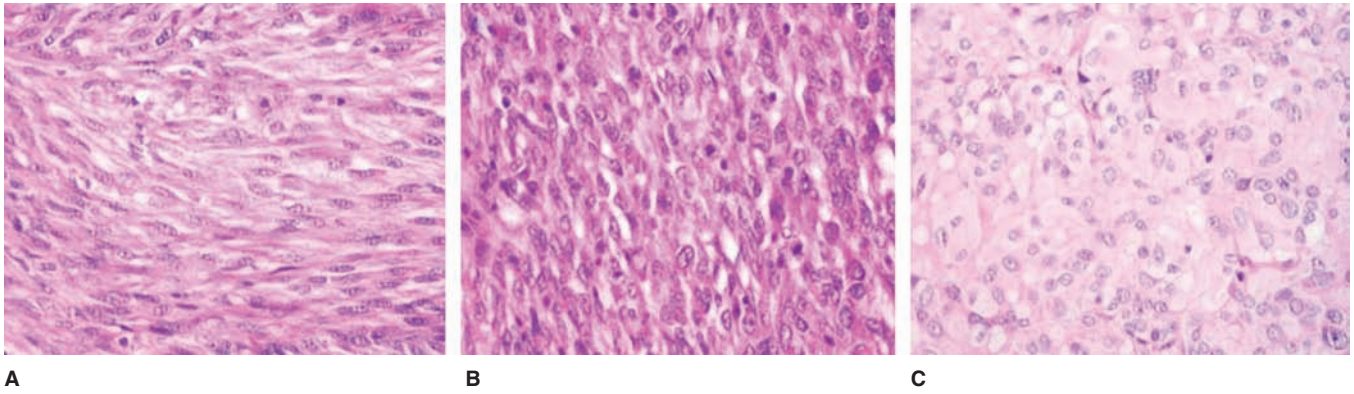
The term “GIST” was initially coined in 1983 by Mazur and Clark to describe intra-abdominal nonepithelial neoplasms that lacked the ultrastructural features of smooth muscle cells and the immunohistochemical characteristics of Schwann cells.<sup>7</sup> GISTs typically exhibit heterogeneous histologic features. They are most commonly composed of long fascicles of spindle cells with pale to eosinophilic cytoplasm and rare nuclear pleomorphism, but may occasionally exhibit epithelioid characteristics, including sheets

of round- to oval-shaped cells with abundant eosinophilic cytoplasm and nuclear atypia (Fig. 24-1). Based on their histologic and immunohistochemical features, GISTs are believed to arise from the interstitial cells of Cajal, components of the intestinal autonomic nervous system that serve as intestinal pacemakers.<sup>8</sup> Nonetheless, until the late 1990s, there were no objective criteria to classify GISTs. They were frequently misclassified as leiomyomas, leiomyoblastomas, leiomyosarcomas, Schwannomas, gastrointestinal autonomic nerve tumors, or other similar soft tissue histologies.<sup>9</sup> Consequently, interpreting clinical results for reports on “GISTs” published before 2000 can be challenging.

### Receptor Tyrosine Kinase Mutations

In a landmark publication in 1998, Hirota and colleagues reported two critical findings: (1) near-universal expression of the transmembrane receptor tyrosine kinase KIT in GIST, and (2) presence of gain-of-function mutations in the corresponding *c-kit* proto-oncogene.<sup>10</sup> The KIT receptor is activated by binding its cytokine ligand known as *steel factor* or *stem cell factor*.<sup>11</sup> KIT plays a critical role in the development and maintenance of components of hematopoiesis, gametogenesis, and intestinal pacemaker cells.<sup>12–14</sup> Oncogenic *KIT* mutations have been identified in neoplasms corresponding to these functions, including mast cell tumors, myelofibrosis, chronic myelogenous leukemia, germ cell tumors, and GIST.<sup>12</sup> Mutated KIT remains constitutively active even in the absence of ligand binding and results in both unregulated cell growth and malignant transformation.<sup>10</sup>

GISTs are now identified by immunohistochemical staining for the CD117 antigen, part of the KIT receptor, in the appropriate histopathologic context (Fig. 24-2). CD117 expression is characteristic of most GISTs but not of other gastrointestinal smooth muscle tumors such as leiomyosarcoma, which are more likely to express high levels of desmin and smooth muscle actin.<sup>12–15</sup> Application of CD117 staining as a diagnostic criterion for GIST has altered understanding of the prevalence of this disease (see the following section Epidemiology).



**FIGURE 24-1** Gastrointestinal stromal tumor (GIST) histology. Staining of tumor paraffin sections with hematoxylin and eosin (H&E) reveals three patterns of GIST histology: **(A)** spindle cell, **(B)** mixed cell, and **(C)** epithelioid cell type.

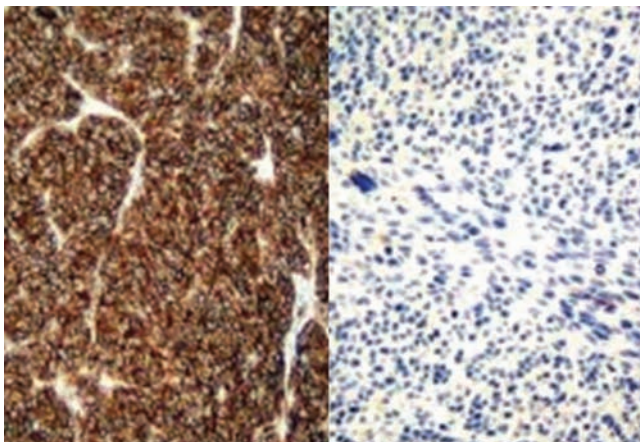
Over 85% of GISTs have activating *KIT* mutations (Fig. 24-3).<sup>12</sup> These mutations commonly occur in exon 11 (in 57–71% of cases), exon 9 (10–18%), exon 13 (1–4%), and exon 17 (1–4%).<sup>16–19</sup> Some GISTs may stain strongly for KIT (CD117) by immunohistochemistry (KIT–positive) yet lack *KIT* mutations,<sup>12</sup> while others that do not stain for KIT (KIT–negative) may nevertheless harbor *KIT* mutations.<sup>20</sup> Approximately 35% of neoplasms lacking *KIT* mutations have activating mutations in a gene encoding a related receptor tyrosine kinase, the PDGFRA.<sup>21–23</sup> *PDGFRA* mutations have been identified in exon 12 (1–2% of GISTs), exon 18 (2–6%), and exon 14 (<1%).<sup>21,24</sup> Finally, a few GISTs, the so-called wild-type (WT) GISTs, exhibit no detectable *KIT* or *PDGFRA* mutations and presumably have alternative

pathways for pathogenesis. Recently, additional putative mutations have been identified. A *BRAF* exon 15 mutation was identified in a small percentage of WT tumors.<sup>25</sup> Insulin-like growth factor 1 receptor (IGF–1R) overexpression was documented in some WT GISTs as well.<sup>26</sup>

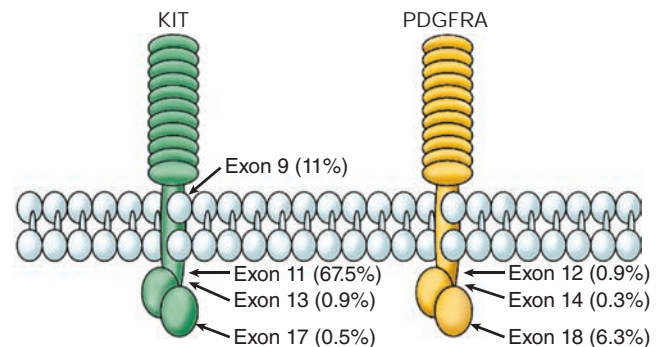
## EPIDEMIOLOGY

### Age

The median age at diagnosis of GIST is 60 years (range 40–80 years).<sup>2,6</sup> They are equally common in men and women, and there is no racial or ethnic predilection. GIST does occur rarely in children, often as a familial syndrome or as part of Carney's triad (see the following text).<sup>27,28</sup> The clinical presentation is typically different in children, who



**FIGURE 24-2** Immunohistochemistry to detect *c-kit* expression. Immunohistochemistry to detect expression of KIT (CD117) is present in approximately 95% of gastrointestinal stromal tumor (GIST) and varies among tumors from predominantly cytoplasmic (*left*), to perinuclear and dot-like (*right*). Variable expression within a given tumor also occurs (*right*).



**FIGURE 24-3** *KIT* and platelet-derived growth factor receptor alpha (*PDGFRA*) mutations in gastrointestinal stromal tumor (GIST). *KIT* and *PDGFRA* mutations in GIST produce constitutive ligand-independent receptor activation. Response to tyrosine kinase inhibitors correlates with the location of the activating mutation, with best response in patients whose tumors contain mutations in *KIT* exon 11.<sup>35</sup>

tend to present with multifocal gastric GISTs, harbor *WT/KIT/PDGFR*A genes, and have a higher incidence of lymph node metastases.<sup>25</sup>

## Hereditary GIST

The overwhelming majority of GISTs are sporadic. Nevertheless, 17 kindreds with germline *KIT* mutations and 3 with a *PDGFR*A mutation have been reported.<sup>29–37</sup> Individuals with GISTs secondary to germline *KIT* mutations are usually younger than those with sporadic GISTs, manifest multifocal disease at presentation, and only rarely develop metastatic disease.<sup>36</sup> The phenotype includes skin hyperpigmentation and diffuse hyperplasia of the intestinal myenteric plexus.<sup>38</sup>

Approximately 7% of individuals with von Recklinghausen's neurofibromatosis (NF1) have GIST, most commonly in the small intestine.<sup>39–41</sup> In addition to their *NF1* mutations, these individuals express *KIT* and *PDGFR*A point mutations in 8 and 6% of GISTs, respectively.<sup>42</sup> Conversely, *NF1* mutations have not been identified in non-NF1 individuals with sporadic GISTs.<sup>43</sup>

Gastric GISTs are components of both Carney's triad and Carney–Stratakis syndrome. Fewer than 100 cases of Carney's triad, consisting of gastric GISTs, pulmonary chondromas, and paragangliomas, have been reported.<sup>28,44</sup> Approximately 85% occur in women and 80% are diagnosed before the age of 30. Patients with Carney's triad do not have somatic *KIT* or *PDGFR*A mutations. The similarly eponymous Carney–Stratakis syndrome describes familial cases expressing the dyad of gastric GIST and paraganglioma.<sup>30</sup> Recently, mutations in several succinate dehydrogenase subunits have been reported in Carney–Stratakis syndrome kindreds.<sup>45</sup>

## Incidence

Investigators have attempted to determine the true incidence of GIST using the Surveillance, Epidemiology, and End Results (SEER) database from the National Cancer Institute. However, these data are difficult to interpret because many GISTs were previously misclassified as other GI mesenchymal neoplasms.<sup>46</sup> Although a near doubling of the incidence of all GI mesenchymal tumors (over 80% were GIST) has been reported (0.17/100,000 in 1992 to 0.31/100,000 in 2002), this may be due to increased recognition, increased screening, and/or true increased incidence.<sup>46</sup> The annual incidence in the United States is estimated to be approximately 5000 new cases per year.<sup>47</sup> European population–based studies identified annual incidence rates ranging from 11 to 14.5 cases per million population.<sup>6,48</sup>

## CLINICAL PRESENTATION

GISTs commonly arise in the stomach (50–70%), small intestine (25–35%), colon and rectum (5–10%), mesentery

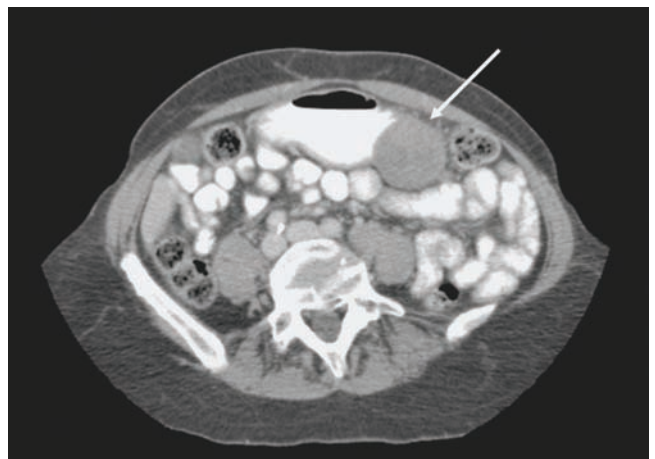or omentum (7%), and esophagus (<5%).<sup>9,49</sup> Occasionally, GIST may arise in the duodenal ampulla, appendix, gallbladder, and urinary bladder.<sup>50–55</sup>

GISTs are generally found due to symptoms. In one study, 69% of tumors were symptomatic, 21% were discovered incidentally at surgery, and 10% were discovered at autopsy.<sup>6</sup> GISTs are often highly vascular, soft, and friable, and bleeding is a common presenting symptom. They may cause life-threatening hemorrhage by erosion into the bowel lumen. Alternatively, tumor rupture may cause potentially catastrophic intraperitoneal bleeding and/or dissemination by peritoneal seeding. Intestinal obstruction may lead to perforation. Smaller tumors may remain asymptomatic, incidentally detected on radiographic studies, endoscopy, or laparotomy. Between 15 and 47% of patients with GIST have metastatic disease at diagnosis.<sup>2,56</sup> Common sites of metastasis include liver, peritoneum, and omentum; lymph node metastases are rare.<sup>5</sup> Extra-abdominal metastases (lung, bone, subcutaneous tissues, and brain) are rare, observed in approximately 5% of patients.<sup>57</sup>

## DIAGNOSIS

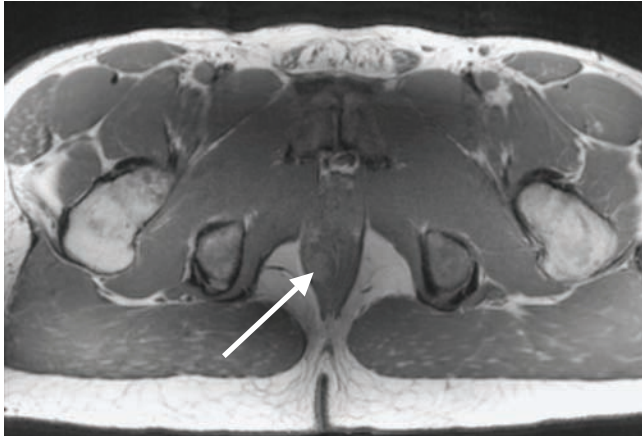
### Radiographic Studies

The initial imaging study for a suspected or confirmed GIST is a contrast-enhanced computed tomography (CT) of the abdomen and pelvis.<sup>58</sup> Primary GISTs are typically well-circumscribed masses within the walls of hollow viscera (Fig. 24-4). Magnetic resonance imaging (MRI) may help characterize metastatic liver or primary perirectal disease (Fig. 24-5). Although [<sup>18</sup>F]fluoro-2-deoxy-D-glucose positron emission tomography (FDG-PET) may help characterize masses ambiguous on CT, monitor response to therapy, and detect emergence of drug-resistant clones, it



**FIGURE 24-4** CT image of primary gastric gastrointestinal stromal tumor (GIST) presenting as an exophytic mass (arrow) off of the greater curvature of the stomach.





**FIGURE 24-5** MRI image of gastrointestinal stromal tumor (GIST) along right posterolateral rectal wall (*arrow*).

is not specific for GIST and thus is not recommended for most patients with suspected primary disease.<sup>59–61</sup>

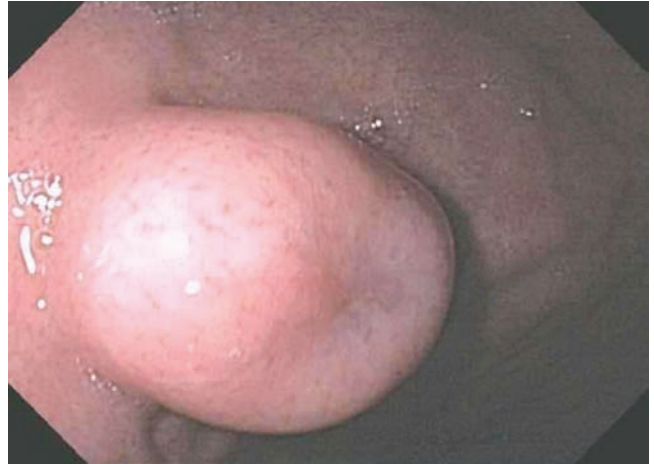## Endoscopy, Fine–Needle Aspiration, and Biopsy

Endoscopically, a primary GIST may appear as a submucosal lesion, with or without ulceration, present in the upper or lower GI tract. They are often indistinguishable from other GI tumors of smooth muscle origin, such as leiomyomas (Fig. 24-6). Endoscopic ultrasound (EUS) is not necessary to evaluate a confirmed GIST. However, EUS–guided fine–needle aspiration (FNA) may be attempted to establish diagnosis. Nevertheless, EUS–FNA is not consistently diagnostic.<sup>62</sup> Additional cytologic morphology, immunohistochemistry, and reverse–transcriptase polymerase chain reaction analysis for *KIT* mutations may be required to confirm a diagnosis.<sup>63</sup>

A preoperative biopsy is not routinely necessary for a primary, resectable neoplasm suspicious for GIST. In fact, preoperative biopsy may rupture a suspected GIST and increase the risk of dissemination. However, if the differential diagnosis includes entities such as lymphoma that would be treated differently, if neoadjuvant therapy is under consideration, or if there is metastatic disease, biopsy is appropriate.

## PROGNOSTIC FACTORS

While tumors under 1 cm likely have a low risk of recurrence, no tumors can be definitively called benign and most large tumors have malignant potential. The three established prognostic factors are tumor size, mitotic index, and tumor site of origin, with mitotic count the most important (Table 24-1).<sup>15,64,65</sup> Individuals with small bowel GISTs have a higher risk of progression than those with gastric GISTs of comparable size and mitotic count.



**FIGURE 24-6** Endoscopic image of incidentally identified primary gastric gastrointestinal stromal tumor (GIST), presenting as an asymptomatic submucosal mass in the proximal along the lesser curvature.

Additional adverse prognostic factors observed in some but not in all studies include high cellular proliferation index,<sup>66</sup> aneuploidy,<sup>66,67</sup> telomerase expression,<sup>68,69</sup> *KIT* exon 9 mutations,<sup>65</sup> and *KIT* exon 11 deletions involving amino acid W557 and/or K558.<sup>70</sup> Point mutations and insertions of *KIT* exon 11 appear to have a favorable prognosis.<sup>65</sup>

The ideal margin of resection is unknown. While a macroscopically complete resection with negative or positive microscopic margins (R0 or R1 resection, respectively) is associated with a better prognosis than a macroscopically incomplete resection (R2 resection), there are no data to confirm that a positive microscopic margin (R1 resection) impacts survival.<sup>2</sup>

## THERAPY FOR PRIMARY DISEASE

### Surgery

#### TECHNIQUE

Surgery remains the standard of care and only potentially curative therapy for patients with primary, resectable, localized GIST. The goal of the operation should be an R0 resection. Tumor rupture or violation of the tumor capsule during surgery is associated with an increased risk of recurrence.

At laparotomy, the abdomen is thoroughly explored to identify and remove any previously undetected peritoneal metastatic deposits. Although primary GISTs may demonstrate inflammatory adhesions to surrounding organs, they do not generally invade other organs beyond the site of origin despite CT appearance. The extent of surgery is usually a wedge or segmental resection of the involved stomach or bowel without the wide margins necessary for adenocarcinoma. In a series of 140 patients with gastric GISTs, wedge resections were performed in 68%, partial gastrectomies in


**TABLE 24-1: RISK ASSESSMENT FOR PRIMARY GASTROINTESTINAL STROMAL TUMORS<sup>64</sup>**

Mitotic Rate	Tumor Size	% of Patients With Progressive Disease/Risk Classification, Based on Site of Origin			
		Stomach	Duodenum	Jejunum/Ileum	Rectum
≤5/50 HPF	≤2 cm	0	0	0	0
	>2, ≤5 cm	1.9/very low	8.3/low	4.3/low	8.5/low
	>5, ≤10 cm	3.6/low	—*	24/moderate	—*
	>10 cm	12/moderate	34/high	52/high	57/high
>5/50 HPF	≤2 cm	—*	—*	—*	54/high
	>2, ≤5 cm	16/moderate	50/high	73/high	52/high
	>5, ≤10 cm	55/high	—*	85/high	—*
	>10 cm	86/high	86/high	90/high	71/high

HPF, high-power field; \*, insufficient data.

Note: Risk of recurrence is based on data from the pre-imatinib era.

Adapted from Miettinen M, Lasota J. Gastrointestinal stromal tumors: pathology and prognosis at different sites. *Semin Diagn Pathol.* 2006 May;23(2):70–83.

28%, and total gastrectomies in only 4%.<sup>71</sup> Occasionally, a more extensive resection (total gastrectomy for a large proximal gastric GIST, pancreaticoduodenectomy for a periampullary GIST, or abdominoperineal resection for a low rectal GIST) may be necessary. There are also no data indicating that patients who have an R1 resection require reexcision.<sup>47</sup> The value of wide surgical margins is unknown, particularly in the era of the targeted therapies described in the following text. Furthermore, margins may retract after resection, or the pathologist may trim away the staple line (converting a technically negative microscopic margin into a positive one). Therefore, all cases of positive microscopic margins should be carefully reviewed by a multidisciplinary team of surgical oncologists, pathologists, and medical oncologists to assess the need for reexcision. Lymphadenectomy is not required because lymph nodes are rarely involved (in adult patients).

All GISTs 2 cm in size or greater should be resected when possible, as none of these can be considered benign.<sup>64</sup> However, the natural history of GISTs under 2 cm in size is unknown, and thus their management is more debatable. Any small GISTs that are symptomatic (eg, hemorrhage from erosion through the mucosa) or increase in size on serial follow-up should be resected.

It is probable that most GISTs under 1 cm in size may be followed (especially gastric GISTs). Two studies have established that subcentimeter gastric GISTs are relatively common, detected in 22.5% of autopsies in adults older than 50 in Germany and in 35% of patients undergoing gastrectomy for gastric cancer in Japan.<sup>72,73</sup> Despite their relative frequency, few of these neoplasms appear to become clinically relevant. Until further data are available, the most appropriate management of such small tumors remains uncertain. Although endoscopic resection of small gastric GISTs has been reported, this cannot be recommended.<sup>74</sup> Unlike early gastric cancers (mucosal malignancies) amenable to endoscopic mucosal resection, GISTs involve the muscularis

propria, so attempts at endoscopic resection risk leaving a positive margin and, due to the depth of the lesion, could result in perforation.

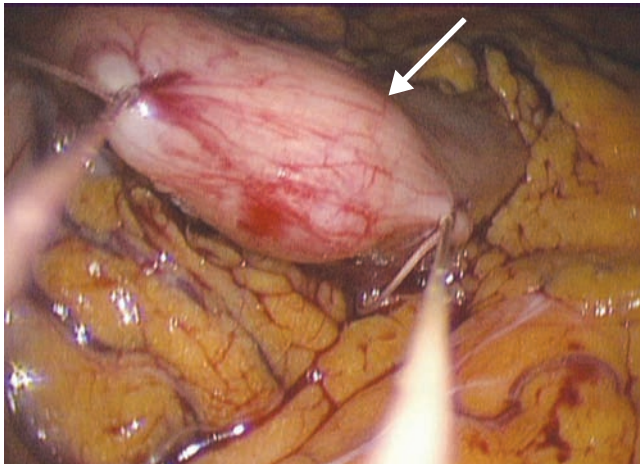
The management of gastric GISTs 1–2 cm in size is even more confusing. On the one hand, the very low risk of recurrence in conjunction with a low mitotic index supports a more conservative, nonoperative approach. On the other hand, an accurate mitotic index cannot be determined by biopsy or FNA. Therefore, observation cannot be recommended based on size alone. Resection (laparoscopic if possible) should be considered, and the risks and benefits of surgery versus observation should be reviewed with the patient.

Little data exist on the natural history of small nongastric GISTs. Given the higher risk of aggressive behavior of small bowel and colon GISTs, any tumor in such locations should be resected irrespective of size.

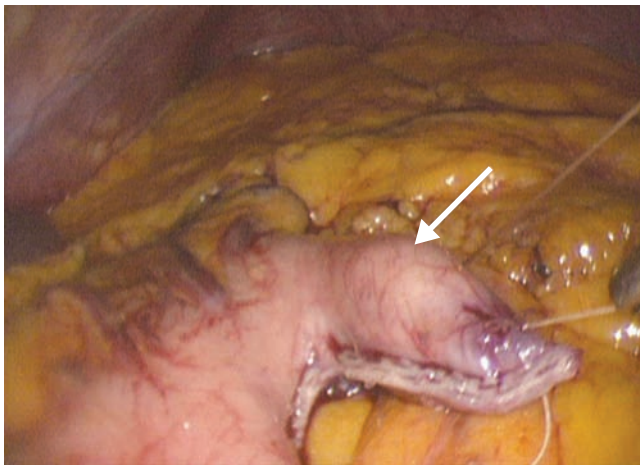
Laparoscopic or laparoscopy–assisted resection of primary GISTs may be performed following standard oncologic principles (Fig. 24-7). Two early studies confirmed both the safety and feasibility of a laparoscopic approach. Otani et al reported that in a series of 35 gastric GISTs (2–5 cm), resected laparoscopically, no local or distant recurrences were observed for tumors under 4 cm in size with a median follow-up of 53 months.<sup>75</sup> Novitsky et al reported a study of 50 patients with gastric GISTs (1.0–8.5 cm) resected laparoscopically or using laparoscopy–assistance, with 92% of patients disease-free with a mean follow-up of 3 years.<sup>76</sup>

## OUTCOMES

Despite a macroscopically complete resection, as many as 50% of individuals may develop recurrent disease at a median of 24 months.<sup>2,77</sup> An R0 or R1 resection is associated with 5-year overall survival (OS) rates of 34–63% whereas R2 resection is associated with 5-year OS rates of as low as 8%.<sup>1,2,78–82</sup>



A



B

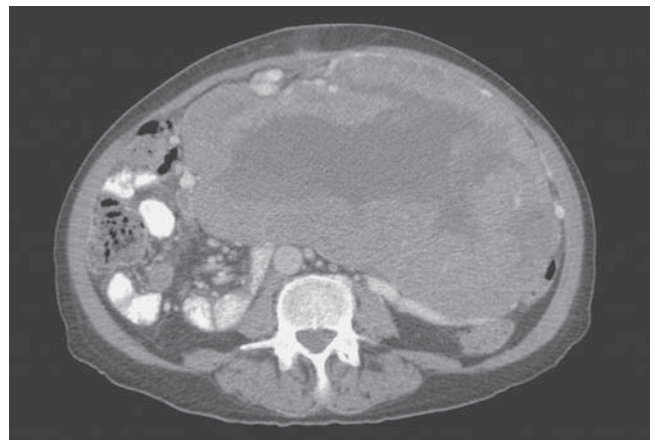
**FIGURE 24-7** Laparoscopic image of gastric gastrointestinal stromal tumor (GIST) along greater curvature of stomach (*arrows*) isolated between traction sutures (**A**) and with stomach partially divided using linear stapler (**B**).

## Neoadjuvant Therapy for Primary Disease

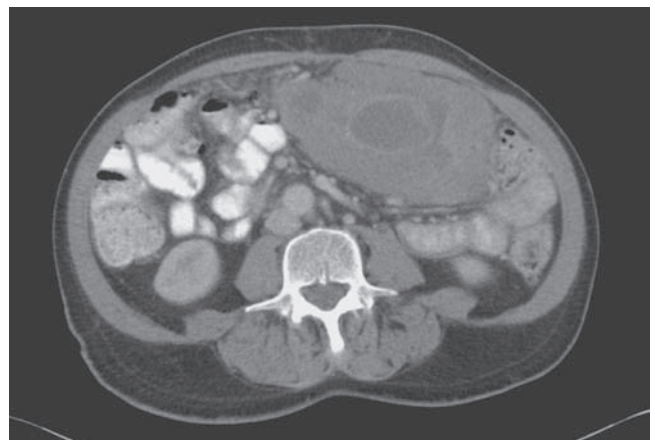The identification of two effective, relatively well-tolerated orally available targeted tyrosine kinase inhibitors (TKI)—imatinib mesylate (STI571, Gleevec) and sunitinib malate (SU11248, Sutent)—has revolutionized the treatment of GIST (discussed in a later section). These agents were initially developed for the management of patients with metastatic disease. Imatinib selectively inhibits several tyrosine kinases, including KIT, PDGFRA, and BCR-ABL.<sup>18,83-85</sup> Several clinical trials have confirmed that up to 80% of patients with metastatic GIST achieve a complete or partial response or demonstrated stable disease on imatinib.<sup>86,87</sup>

As demonstrated previously, recurrence rates are high and survival rates are low after an R0/R1 resection. Therefore, the role of neoadjuvant therapy with imatinib combined with

resection has been explored in one multi-institutional<sup>88</sup> and one single-institution<sup>89</sup> prospective trial. For the sake of brevity, only the former is discussed here. The Radiation Therapy Oncology Group (RTOG) 0312 phase II trial is the only multicenter study reported thus far evaluating the use of imatinib as a neoadjuvant agent. Patients with resectable primary or recurrent GIST were treated with 600 mg/d of imatinib for 8–12 weeks prior to surgery (Table 24-2). Nonprogressing patients underwent surgery and were then maintained on adjuvant imatinib for 2 years. An objective response was demonstrated in 90% of patients with primary GIST, and 92% underwent R0/R1 resections. Two-year recurrence-free survival (RFS) was 83%. Although this trial confirmed the safety of imatinib as a neoadjuvant therapy, it is still unclear what the optimal length of preoperative therapy is. Data from trials of advanced GIST have demonstrated that maximal radiographic response to imatinib generally required 6–9 months of treatment.<sup>86,90,91</sup> Thus, the optimal preoperative imatinib regimen may be 6 months or more as long as continued radiographic response is observed (Fig. 24-8).



A



B

**FIGURE 24-8** Patient with primary gastric gastrointestinal stromal tumor (GIST) before (**A**) and after (**B**) 9 months of neoadjuvant imatinib. Neoadjuvant therapy resulted in dramatic tumor shrinkage.



**TABLE 24-2: MULTI-INSTITUTIONAL TRIALS EVALUATING NEOADJUVANT OR ADJUVANT IMATINIB IN THE PERIOPERATIVE MANAGEMENT OF RESECTED PRIMARY GASTROINTESTINAL STROMAL TUMORS**

Trial	Imatinib Therapy	Design	Eligibility	Dose	Primary Endpoint	Status
RTOG S0132	Neoadjuvant	Phase II	Either of the following: 1. Primary tumor $\geq 5$ cm 2. Recurrent tumor $\geq 2$ cm Potentially resectable	600 mg daily $\times$ 8–10 wk <i>preoperatively</i> + 600 mg daily $\times$ 24 mo <i>postoperatively</i>	RFS	Published <sup>d88</sup>
ACOSOG Z9000	Adjuvant	Phase II	Any of the following: 1. Tumor $\geq 10$ cm 2. Rupture/hemorrhage 3. Multiple tumors ( $< 5$ ) Complete resection	400 mg daily $\times$ 12 mo	RFS	Reported <sup>92</sup>
ACOSOG Z9001	Adjuvant	Phase III	Tumor $\geq 3$ cm Complete resection	400 mg daily vs placebo $\times$ 12 mo	RFS	Published <sup>93</sup>
China Gastrointestinal Cooperative Group SSG XVIII	Adjuvant	Phase II	Either of the following: 1. Tumor $> 5$ cm 2. Mitotic rate $> 5/50$ HPF	400 mg daily $\times$ 12 mo	RFS	Reported <sup>94</sup>
	Adjuvant	Phase III	Any of the following: 1. Tumor $\geq 10$ cm 2. Rupture 3. Mitotic rate $> 10/50$ HPF 4. Tumor $> 5$ cm + mitotic rate $> 5/50$ HPF 5. Primary tumor + liver/peritoneal metastases Complete resection	400 mg daily $\times$ 12 or 36 mo	RFS	Completed
EORTC 62024	Adjuvant	Phase III	Any of the following: 1. Tumor $> 5$ cm 2. Mitotic rate $> 10$ 3. Tumor $< 5$ cm + mitotic count 6–10/50 HPF Complete resection	400 mg daily vs no treatment $\times$ 24 mo	Time to second-line therapy	Completed
Korea	Adjuvant	Phase II	Any of the following: 1. Tumor $> 5$ cm + mitotic count $> 5/50$ HPF 2. Tumor $> 10$ cm 3. Mitotic count $> 10/50$ HPF Complete resection	400 mg daily $\times$ 24 mo	RFS	Reported <sup>95</sup>
CSIT571BUS282	Adjuvant	Phase II	Either of the following: 1. Tumor $\geq 2$ cm + mitotic count $\geq 5/50$ HPF 2. Any nongastric tumor $\geq 5$ cm Complete resection	400 mg daily $\times$ 5 y	RFS	Ongoing

ACOSOG, American College of Surgeons Oncology Group; EORTC, European Organization for the Research and Treatment of Cancer; HPF, high-power fields; RFS, recurrence-free survival; RTOG, Radiation Therapy Oncology Group.



## Adjuvant Therapy for Primary Disease

The role of adjuvant therapy with imatinib combined with resection of primary disease was or is being explored in six prospective multi-institutional trials. The trials tested durations of adjuvant imatinib of 12 months (American College of Surgeons Oncology Group Z9000,<sup>92</sup> ASOSOG Z9001,<sup>93</sup> China Cooperative Group<sup>94</sup>), 24 months (European Organization for the Research and Treatment of Cancer [EORTC] 62024, Korean trial<sup>95</sup>), 12 versus 36 months (Scandinavian Sarcoma Group [SSG] XVIII), or 5 years (ongoing phase II multi-institutional trial, CSIT571BUS282) (see Table 24-2).<sup>92-94</sup> Data from the only published trial, ACOSOG Z9001, are discussed in detail. In this phase III trial, patients with completely resected primary GISTs at least 3 cm in size were randomized to receive either placebo or imatinib postoperatively for 1 year. The trial was halted early after a planned interim analysis of 644 evaluable patients confirmed that the 1-year RFS was significantly better in the imatinib arm (97 vs 83%,  $p = .0000014$ ). However, the slopes of the Kaplan-Meier curves representing the two treatment arms, once recurrences were observed, were similar. Thus, adjuvant imatinib may delay recurrence but may not necessarily cure anyone over the short follow-up interval. Furthermore, there was no difference in OS between the two treatment arms. Additional follow-up is necessary to determine if a difference in OS will eventually be observed. Finally, the optimal length of adjuvant therapy is uncertain. The EORTC 62024 and SSG XVIII trials have completed accrual, but data are not yet available. Data from these two trials plus the ongoing CSIT-571BUS282 trial will help determine the comparative benefit of 2, 3, or 5 years of imatinib. Perhaps the most important question is whether administration of imatinib after resection of primary disease or after disease recurrence delays time to second-line therapy (imatinib dose escalation or changing to sunitinib). However, with the recent approval of imatinib for adjuvant use by both the Food and Drug Administration in the United States and the European Medicines Agency in Europe, it seems unlikely that any trial will ever be designed to answer this question.

## THERAPY FOR ADVANCED DISEASE

### Targeted Therapy

Historically, patients with recurrent GIST have been treated by a combination of the three traditional cancer therapeutic modalities: surgery, intravenous chemotherapy, and radiotherapy. Surgery is effective for patients with resectable disease, but disease may recur in as many as 50% of individuals. Traditional intravenous chemotherapy (including standard sarcoma regimens employing doxorubicin and/or ifosfamide) and radiotherapy have shown little efficacy.<sup>1,2,91</sup>

To date, two TKIs have been approved for the treatment of metastatic GIST: imatinib mesylate and sunitinib malate.

Imatinib is the first-line therapy for advanced (unresectable primary or metastatic) GIST, based on data from international phases I, II, and III trials.<sup>60,86,87,90,96</sup> Partial responses (PRs) or stable disease (SD) were noted in nearly 85% of patients with advanced GIST treated with imatinib.<sup>60</sup> In the US phase III trial, the median progression-free survival (PFS) and OS with imatinib therapy were 18–20 months and 51–55 months, respectively.<sup>86</sup> The starting dose for imatinib is generally 400 mg once daily. In patients who develop progressive disease on 400 mg, dose escalation up to 400 mg twice daily is effective.<sup>97-100</sup> However, greater toxicity and more dose reductions are generally required at doses above 400 mg/d. In a meta-analysis of the two large phase III studies, a slight advantage in PFS was noted in patients initially treated with higher-dose imatinib, but that advantage was essentially limited to patients with *KIT* exon 9 mutations.<sup>101</sup>

Imatinib should be continued indefinitely. A French randomized imatinib discontinuation study demonstrated that patients with GIST on imatinib who stop imatinib therapy after 1 and 3 years had a much higher rate of disease progression than those who continued on therapy.<sup>102,103</sup>

If patients continue to progress on higher doses of imatinib or do not tolerate such doses, second-line sunitinib is started. Sunitinib is a multitargeted TKI whose targets include *KIT*, *PDGFR*, vascular endothelial growth factor receptor (*VEGFR1*, *VEGFR2*, *VEGFR3*), the ret proto-oncogene receptor (*RET*), and *Fms*-like tyrosine kinase-3 receptor (*Flt3*). A placebo-controlled phase III trial demonstrated significant improvement in time to progression in patients treated with sunitinib compared to those treated with placebo (27.3 vs 6.4 weeks, respectively), as well as PFS and OS.<sup>104</sup> Initially dosed as 50 mg daily in a 4-week-on-2-week-off cycle, many oncologists now favor a continuous dose regimen of 37.5 mg daily.<sup>105</sup>

When sunitinib resistance develops, protocol-based therapies should be considered. Additional TKIs under investigation include sorafenib,<sup>106</sup> nilotinib,<sup>107</sup> masitinib,<sup>108</sup> and vatalanib.<sup>109</sup> Novel and potentially attractive targets include heat shock protein-90 (*HSP-90*)<sup>110</sup> and *IGF-1R*.<sup>26</sup>

### Surgery

Cytoreductive surgery for resectable advanced or metastatic disease is a relatively common practice for disseminated solid tumors originating in the colon, appendix, ovary, and testicle. With the advent of imatinib and sunitinib therapy, a number of investigators have pursued a similar strategy of aggressive cytoreductive surgery in patients with metastatic GIST on TKI therapy. Three observations support such an approach. First, the majority of patients experience durable periods of PR or SD on imatinib, lasting months to years. Second, pathologic complete responses are rare, noted in fewer than 5% of patients.<sup>99,100</sup> Third, response to imatinib is not maintained indefinitely; the median time to progression due to the development of secondary resistance to imatinib 18–24

**TABLE 24-3: SINGLE-INSTITUTION RETROSPECTIVE STUDIES EVALUATING PFS AND OS RATES AFTER RESECTION OF ADVANCED GASTROINTESTINAL STROMAL TUMOR ON IMATINIB THERAPY**

Author	No. of Patients	TKI Therapy	PR/SD on TKI (%)	PD on TKI (%)	R0/R1 (%)	1-y PFS (%)	1-y OS (%)
Raut et al <sup>112</sup>	69	IM/SU	33	Limited 47 Generalized 20	83	PR/SD 80 Limited PD 33 Generalized PD 0	PR/SD 80 Limited PD 33 Generalized PD 0
Rutkowski et al <sup>116</sup>	24	IM	75	25	91		
Bonvalot et al <sup>114</sup>	22	IM	95	5	68		
Andtbacka et al <sup>117</sup>	46	IM	45	55	48		
DeMatteo et al <sup>111</sup>	40	IM/SU	50	Limited 33 Generalized 17	80	PR/SD 70 Limited PD 48 Generalized PD 14	PR/SD 100 Limited PD 90 Generalized PD 36
Gronchi et al <sup>115</sup>	38	IM	71	Limited 21 Generalized 8	82	PR/SD 96 PD 0	PR/SD 100 PD 60

IM, imatinib mesylate; OS, overall survival; PD, progressive disease; PFS, progression-free survival; PR, partial response; R0, macroscopically complete resection with negative microscopic margins; R1, macroscopically complete resection with positive microscopic margins; SD, stable disease; SU, sunitinib malate; TKI, tyrosine kinase inhibitor.

months.<sup>86,87</sup> Once drug resistance develops, disease progression may be either limited (progression at one site of tumor, with other tumor deposits showing ongoing response to TKI) or generalized (progression at more than one site).<sup>111,112</sup>

Several single-institution retrospective studies have documented the PFS and OS rates following extensive cytoreductive surgery in patients with advanced GIST treated with TKI therapy (Table 24-3).<sup>111-116</sup>

In the experience at Brigham and Women's Hospital/Dana-Farber Cancer Institute (BWH/DFCI), the best results were generally seen in patients whose disease was still responsive to TKI therapy at the time of surgery. The ability to remove all macroscopic disease was greatest in patients demonstrating ongoing response to TKI therapy. After surgery, there was no evidence of any residual disease in 78, 25, and 7% of patients with responsive disease, limited progression, and generalized progression, respectively ( $p < .0001$ ).<sup>112</sup> In contrast, bulky residual disease remained postoperatively in 4, 16, and 43% of patients with responsive disease, limited progression, and generalized progression, respectively.

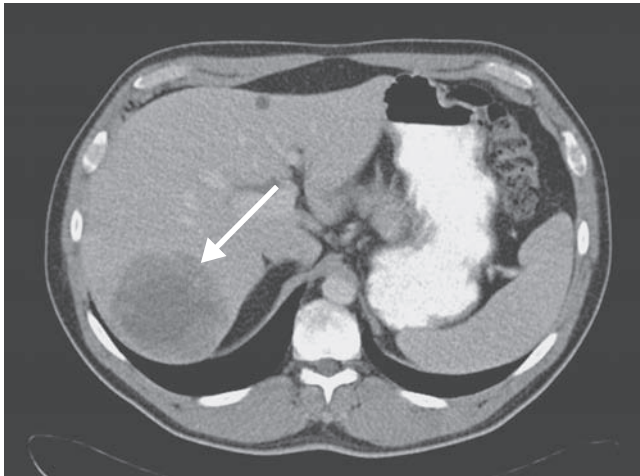
The series from BWH/DFCI, Memorial Sloan-Kettering Cancer Center, and Istituto Nazionale Tumori each demonstrated that the highest rates of PFS and OS were observed when cytoreductive surgery occurred while the patients were still responding to TKI therapy. PFS rates for patients with ongoing response to TKI therapy (ie, PR or SD at the time of surgery) were 70–96% at 1 year after surgery and 72% at 4 years from the start of imatinib therapy, whereas the 1-year PFS for patients with generalized progression ranged from 0 to 14%.<sup>111,112,115</sup> OS rates approached 100% at 1 year after surgery in patients responding to TKI therapy and only 0–60% at 1 year in the setting of generalized progression. Although patients with limited progression had lower rates of PFS than those with responsive disease, the rates of OS were

not significantly different; thus the benefits of surgery in this population are unclear.

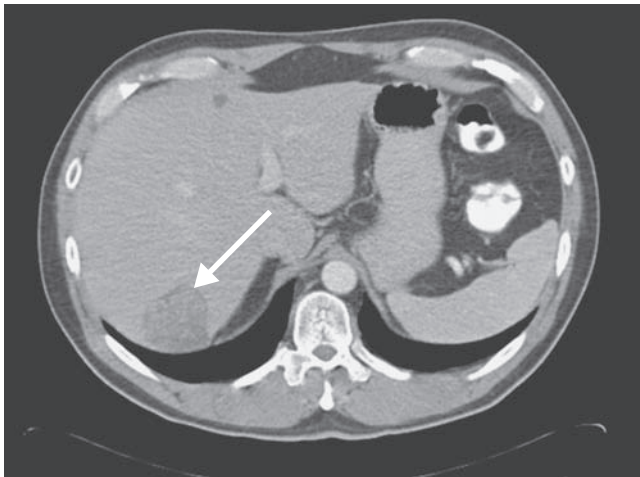
In the BWH/DFCI series, approximately 40% of patients required liver resections, over 60% underwent peritonectomy and/or omentectomy, and over 60% needed multivisceral resections.<sup>112</sup> Radiofrequency ablation may be considered for liver disease. Complication rates ranged from 40 to 60% in the three large series, though the majority were minor.<sup>111</sup> Perioperative deaths were rare, usually occurring in the setting of emergency procedures, as reported in the French study.<sup>114,116</sup>

The goal of such operations is to perform a macroscopically complete (R0 or R1) resection when safely possible. However, the disease may frequently be too extensive to be removed completely, in which case progressing lesions are preferentially removed. Following surgery, these patients should remain on imatinib indefinitely, as failure to resume imatinib results in rapid disease recurrence.

Based on these data, from limited single-institution series, the patients who seemed to derive the most benefit from cytoreductive surgery were the ones still responding to TKI therapy at the time of surgery (PR or SD, Fig. 24-9). Such patients should be considered for surgery on an individual basis. Patients with generalized progression do not appear to derive any benefit from cytoreductive surgery and are best treated nonoperatively. Such patients may nevertheless need urgent surgery for palliative or emergency purposes such as obstruction or hemorrhage (Fig. 24-10). Although cytoreductive surgery is feasible in patients with responsive disease, there is still no evidence that outcomes are superior or even equal to those for patients who continue on TKI therapy without surgery. This question will hopefully be answered in randomized clinical trials under development in the United States and open in Europe and China. Figure 24-11 is a schema for the management of primary and advanced GIST.



A



B

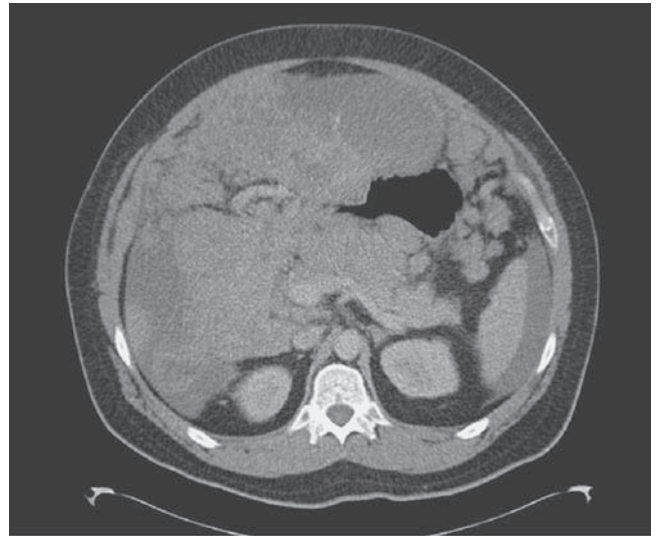
**FIGURE 24-9** Patient with duodenal gastrointestinal stromal tumor (GIST) metastatic to the liver (*arrows*) before (**A**) and after (**B**) 8 months of imatinib, demonstrating partial response to therapy. The patient underwent resection of his intact primary disease, a right hepatectomy, and wedge resection of a left hepatic lesion.

## SURVEILLANCE

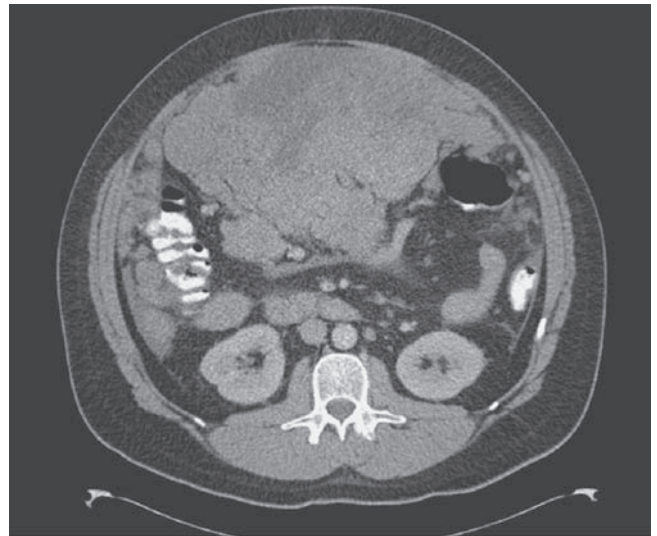
The NCCN consensus panel recommended that patients who have had resection of a primary GIST should undergo a history, physical examination, and abdomen/pelvis CT scans with intravenous contrast every 3–6 months during the first 3–5 years and then annually thereafter.<sup>47</sup>

## CONCLUSION

The principal and only potentially curative treatment for GIST is surgery. However, recurrences are common. In the era prior to the institution of TKI therapy, survival in the setting of recurrent or metastatic disease was poor. Because



A

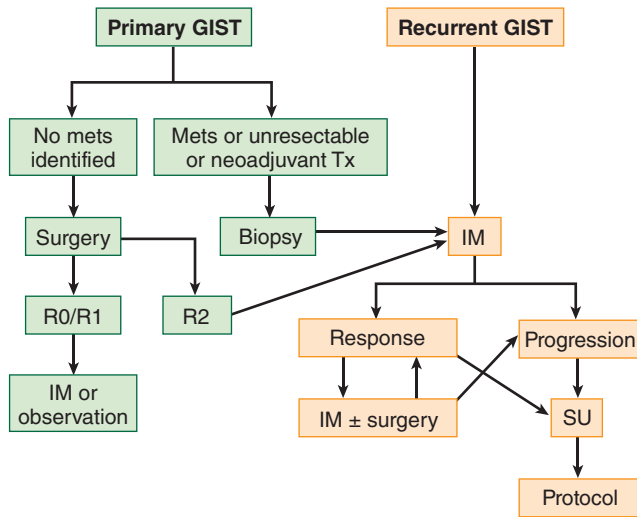


B

**FIGURE 24-10** Patient with unresectable metastatic gastrointestinal stromal tumor (GIST) (**A** and **B**). Therapy with imatinib failed to control growth of the disease. The patient underwent a palliative debulking to relieve proximal gastric obstruction, but the resection as anticipated was macroscopically incomplete.

of its relatively low toxicity and significant efficacy in the treatment of GIST, TKI therapy has dramatically altered the natural history of this disease. The type and dose of TKI administered may soon be guided by mutational analysis. The role of imatinib has been expanded to patients with primary GIST, where it may be used safely as a neoadjuvant agent and improves RFS as an adjuvant agent following complete macroscopic resection. Ongoing studies will address the issues of optimal length and dose of adjuvant and neoadjuvant imatinib therapy, define the subset of candidates most likely to benefit from such therapy, and determine the long-term





**FIGURE 24-11** Schema for management of primary and advanced gastrointestinal stromal tumor (GIST). IM, imatinib mesylate; R0, macroscopically complete resection with negative microscopic margins; R1, macroscopically complete resection with positive microscopic margins; R2, macroscopically incomplete resection; SU, sunitinib malate; Tx, treatment.

impact on OS. Cytoreductive surgery may be considered in a subset of patients with advanced disease, but phase III trial data are necessary to determine if surgery adds any PFS or OS benefit over continuing imatinib therapy alone.

Future studies will focus on the integration of surgery with targeted therapy and the development of new agents for drug-resistant GIST.

## REFERENCES

- Crosby JA, Catton CN, Davis A, et al. Malignant gastrointestinal stromal tumors of the small intestine: a review of 50 cases from a prospective database. *Ann Surg Oncol*. Jan–Feb 2001;8(1):50–59.
- DeMatteo RP, Lewis JJ, Leung D, Mudan SS, Woodruff JM, Brennan MF. Two hundred gastrointestinal stromal tumors: recurrence patterns and prognostic factors for survival. *Ann Surg*. 2000;231(1):51–58.
- Lewis JJ, Brennan MF. Soft tissue sarcomas. *Curr Probl Surg*. 1996;33(10):817–872.
- Nishida T, Hirota S. Biological and clinical review of stromal tumors in the gastrointestinal tract. *Histol Histopathol*. 2000 Oct;15(4):1293–1301.
- Miettinen M, Lasota J. Gastrointestinal stromal tumors—definition, clinical, histological, immunohistochemical, and molecular genetic features and differential diagnosis. *Virchows Arch*. 2001;438(1):1–12.
- Nilsson B, Bummig P, Meis-Kindblom JM, et al. Gastrointestinal stromal tumors: the incidence, prevalence, clinical course, and prognostication in the preimatinib mesylate era—a population-based study in western Sweden. *Cancer*. 2005 Feb 15;103(4):821–829.
- Mazur MT, Clark HB. Gastric stromal tumors. Reappraisal of histogenesis. *Am J Surg Pathol*. 1983 Sep;7(6):507–519.
- Kindblom LG, Remotti HE, Aldenborg F, Meis-Kindblom JM. Gastrointestinal pacemaker cell tumor (GIPACT): gastrointestinal stromal tumors show phenotypic characteristics of the interstitial cells of Cajal. *Am J Pathol*. 1998;152(5):1259–1269.

- Miettinen M, Majidi M, Lasota J. Pathology and diagnostic criteria of gastrointestinal stromal tumors (GISTs): a review. *Eur J Cancer*. 2002 Sep;38(suppl 5):S39–S51.
- Hirota S, Isozaki K, Moriyama Y, et al. Gain-of-function mutations of c-kit in human gastrointestinal stromal tumors. *Science*. 23 1998 Jan 23;279(5350):577–580.
- Savage DG, Antman KH. Imatinib mesylate—a new oral targeted therapy. *N Engl J Med*. 2002 Feb 28;346(9):683–693.
- Rubin BP, Singer S, Tsao C, et al. KIT activation is a ubiquitous feature of gastrointestinal stromal tumors. *Cancer Res*. 2001 Nov 15;61(22):8118–8121.
- Tian Q, Frierson HF, Jr, Krystal GW, Moskaluk CA. Activating c-kit gene mutations in human germ cell tumors. *Am J Pathol*. 1999;154(6):1643–1647.
- Ward SM, Burns AJ, Torihashi S, Sanders KM. Mutation of the proto-oncogene c-kit blocks development of interstitial cells and electrical rhythmicity in murine intestine. *J Physiol*. 1994 Oct 1;480 (pt 1):91–97.
- Fletcher CD, Berman JJ, Corless C, et al. Diagnosis of gastrointestinal stromal tumors: a consensus approach. *Hum Pathol*. 2002;33(5):459–465.
- Heinrich MC, Blanke CD, Druker BJ, Corless CL. Inhibition of KIT tyrosine kinase activity: a novel molecular approach to the treatment of KIT-positive malignancies. *J Clin Oncol*. 2002 Mar 15;20(6):1692–1703.
- Corless CL, Fletcher JA, Heinrich MC. Biology of gastrointestinal stromal tumors. *J Clin Oncol*. 2004;22(18):3813–3825.
- Heinrich MC, Corless CL, Demetri GD, et al. Kinase mutations and imatinib response in patients with metastatic gastrointestinal stromal tumor. *J Clin Oncol*. 2003 Dec 1;21(23):4342–4349.
- De Giorgi U, Verweij J. Imatinib and gastrointestinal stromal tumors: where do we go from here? *Mol Cancer Ther*. 2005;4(3):495–501.
- Emile JF, Theou N, Tabone S, et al. Clinicopathologic, phenotypic, and genotypic characteristics of gastrointestinal mesenchymal tumors. *Clin Gastroenterol Hepatol*. 2004;2(7):597–605.
- Heinrich MC, Corless CL, Duensing A, et al. PDGFRA activating mutations in gastrointestinal stromal tumors. *Science*. 2003 Jan 31;299(5607):708–710.
- Hirota S, Ohashi A, Nishida T, et al. Gain-of-function mutations of platelet-derived growth factor receptor alpha gene in gastrointestinal stromal tumors. *Gastroenterology*. 2003 Sep;125(3):660–667.
- Medeiros F, Corless CL, Duensing A, et al. KIT-negative gastrointestinal stromal tumors: proof of concept and therapeutic implications. *Am J Surg Pathol*. 2004;28(7):889–894.
- Corless CL, Schroeder A, Griffith D, et al. PDGFRA mutations in gastrointestinal stromal tumors: frequency, spectrum and in vitro sensitivity to imatinib. *J Clin Oncol*. 2005 Aug 10;23(23):5357–5364.
- Agaram NP, Laquaglia MP, Ustun B, et al. Molecular characterization of pediatric gastrointestinal stromal tumors. *Clin Cancer Res*. 2008 May 15;14(10):3204–3215.
- Tarn C, Rink L, Merkel E, et al. Insulin-like growth factor 1 receptor is a potential therapeutic target for gastrointestinal stromal tumors. *Proc Natl Acad Sci U S A*. 2008 Jun 17;105(24):8387–8392.
- Miettinen M, Lasota J. Gastrointestinal stromal tumors (GISTs): definition, occurrence, pathology, differential diagnosis and molecular genetics. *Pol J Pathol*. 2003;54(1):3–24.
- Carney JA. Gastric stromal sarcoma, pulmonary chondroma, and extra-adrenal paraganglioma (Carney triad): natural history, adrenocortical component, and possible familial occurrence. *Mayo Clin Proc*. 1999;74(6):543–552.
- Beghini A, Tibiletti MG, Roversi G, et al. Germline mutation in the juxtamembrane domain of the kit gene in a family with gastrointestinal stromal tumors and urticaria pigmentosa. *Cancer*. 2001 Aug 1;92(3):657–662.
- Carney JA, Stratakis CA. Familial paraganglioma and gastric stromal sarcoma: a new syndrome distinct from the Carney triad. *Am J Med Genet*. 2002 Mar 1;108(2):132–139.
- Hirota S, Nishida T, Isozaki K, et al. Familial gastrointestinal stromal tumors associated with dysphagia and novel type germline mutation of KIT gene. *Gastroenterology*. 2002;122(5):1493–1499.
- Isozaki K, Terris B, Belghiti J, Schiffmann S, Hirota S, Vanderwinden JM. Germline-activating mutation in the kinase domain of KIT gene in familial gastrointestinal stromal tumors. *Am J Pathol*. 2000 Nov;157(5):1581–1585.
- Li FP, Fletcher JA, Heinrich MC, et al. Familial gastrointestinal stromal tumor syndrome: phenotypic and molecular features in a kindred. *J Clin Oncol*. 2005 Apr 20;23(12):2735–2743.



34. Maeyama H, Hidaka E, Ota H, et al. Familial gastrointestinal stromal tumor with hyperpigmentation: association with a germline mutation of the c-kit gene. *Gastroenterology*. 2001;120(1):210–215.
35. Nishida T, Hirota S, Taniguchi M, et al. Familial gastrointestinal stromal tumours with germline mutation of the KIT gene. *Nat Genet*. 1998 Aug;19(4):323–324.
36. Robson ME, Glogowski E, Sommer G, et al. Pleomorphic characteristics of a germ-line KIT mutation in a large kindred with gastrointestinal stromal tumors, hyperpigmentation, and dysphagia. *Clin Cancer Res*. 2004 Feb 15;10(4):1250–1254.
37. Chompret A, Kannengiesser C, Barrois M, et al. PDGFRA germline mutation in a family with multiple cases of gastrointestinal stromal tumor. *Gastroenterology*. 2004;126(1):318–321.
38. Corless CL, Fletcher JA, Heinrich MC. Biology of gastrointestinal stromal tumors. *J Clin Oncol*. 2004 Sep 15;22(18):3813–3825.
39. Shinomura Y, Kinoshita K, Tsutsui S, Hirota S. Pathophysiology, diagnosis, and treatment of gastrointestinal stromal tumors. *J Gastroenterol*. 2005;40(8):775–780.
40. Miettinen M, Fetsch JF, Sobin LH, Lasota J. Gastrointestinal stromal tumors in patients with neurofibromatosis 1: a clinicopathologic and molecular genetic study of 45 cases. *Am J Surg Pathol*. 2006;30(1):90–96.
41. Zoller ME, Rembeck B, Oden A, Samuelsson M, Angervall L. Malignant and benign tumors in patients with neurofibromatosis type 1 in a defined Swedish population. *Cancer*. 1997 Jun 1;79(11):2125–2131.
42. Takazawa Y, Sakurai S, Sakuma Y, et al. Gastrointestinal stromal tumors of neurofibromatosis type I (von Recklinghausen's disease). *Am J Surg Pathol*. 2005;29(6):755–763.
43. Kinoshita K, Hirota S, Isozaki K, et al. Absence of c-kit gene mutations in gastrointestinal stromal tumors from neurofibromatosis type 1 patients. *J Pathol*. 2004;202(1):80–85.
44. Carney JA, Sheps SG, Go VL, Gordon H. The triad of gastric leiomyosarcoma, functioning extra-adrenal paraganglioma and pulmonary chondroma. *N Engl J Med*. 1977 Jun 30;296(26):1517–1518.
45. McWhinney SR, Pasini B, Stratakis CA. Familial gastrointestinal stromal tumors and germ-line mutations. *N Engl J Med*. 2007 Sep 6;357(10):1054–1056.
46. Perez EA, Livingstone AS, Franceschi D, et al. Current incidence and outcomes of gastrointestinal mesenchymal tumors including gastrointestinal stromal tumors. *J Am Coll Surg*. 2006;202(4):623–629.
47. Demetri GD, Benjamin RS, Blanke CD, et al. NCCN Task Force report: management of patients with gastrointestinal stromal tumor (GIST)—update of the NCCN clinical practice guidelines. *J Natl Compr Canc Netw*. 2007 Jul;5(suppl 2):S1–S29; quiz S30.
48. Tryggvason G, Gislason HG, Magnusson MK, Jonasson JG. Gastrointestinal stromal tumors in Iceland, 1990–2003: the icelandic GIST study, a population-based incidence and pathologic risk stratification study. *Int J Cancer*. 2005 Nov 1;117(2):289–293.
49. Emory TS, Sobin LH, Lukes L, Lee DH, O'Leary TJ. Prognosis of gastrointestinal smooth-muscle (stromal) tumors: dependence on anatomic site. *Am J Surg Pathol*. 1999;23(1):82–87.
50. Miettinen M, Monihan JM, Sarlomo-Rikala M, et al. Gastrointestinal stromal tumors/smooth muscle tumors (GISTs) primary in the omentum and mesentery: clinicopathologic and immunohistochemical study of 26 cases. *Am J Surg Pathol*. 1999;23(9):1109–1118.
51. Miettinen M, Sarlomo-Rikala M, Sobin LH, Lasota J. Esophageal stromal tumors: a clinicopathologic, immunohistochemical, and molecular genetic study of 17 cases and comparison with esophageal leiomyomas and leiomyosarcomas. *Am J Surg Pathol*. 2000;24(2):211–222.
52. Miettinen M, Sobin LH. Gastrointestinal stromal tumors in the appendix: a clinicopathologic and immunohistochemical study of four cases. *Am J Surg Pathol*. 2001;25(11):1433–1437.
53. Lasota J, Carlson JA, Miettinen M. Spindle cell tumor of urinary bladder serosa with phenotypic and genotypic features of gastrointestinal stromal tumor. *Arch Pathol Lab Med*. 2000;124(6):894–897.
54. Peerlinck ID, Irvin TT, Sarsfield PT, Harington JM. GIST (gastro-intestinal stromal tumour) of the gallbladder: a case report. *Acta Chir Belg*. 2004 Feb;104(1):107–109.
55. Takahashi Y, Noguchi T, Takeno S, Uchida Y, Shimoda H, Yokoyama S. Gastrointestinal stromal tumor of the duodenal ampulla: report of a case. *Surg Today*. 2001;31(8):722–726.
56. Roberts PJ, Eisenberg B. Clinical presentation of gastrointestinal stromal tumors and treatment of operable disease. *Eur J Cancer*. 2002;38(suppl 5):S37–S38.
57. Bertulli R, Fumagalli E, Coco P, et al. Unusual metastatic sites in GIST [abstr 10566]. *J Clin Oncol*. 2009;27:15s.
58. Demetri GD, Delaney T. NCCN: sarcoma. *Cancer Control*. Nov–Dec 2001;8(6 suppl 2):94–101.
59. Blay JY, Bonvalot S, Casali P, et al. Consensus meeting for the management of gastrointestinal stromal tumors. Report of the GIST Consensus Conference of 20–21 March 2004, under the auspices of ESMO. *Ann Oncol*. 2005;16(4):566–578.
60. Demetri GD, von Mehren M, Blanke CD, et al. Efficacy and safety of imatinib mesylate in advanced gastrointestinal stromal tumors. *N Engl J Med*. 2002 Aug 15;347(7):472–480.
61. Gayed I, Vu T, Iyer R, et al. The role of 18F-FDG PET in staging and early prediction of response to therapy of recurrent gastrointestinal stromal tumors. *J Nucl Med*. 2004;45(1):17–21.
62. Demetri GD, Morgan JA, Raut CP. Local treatment for gastrointestinal stromal tumors, leiomyomas, and leiomyosarcomas of the gastrointestinal tract. [http://www.updatdate.com/contents/local-treatment-for-gastrointestinal-stromal-tumors-leiomyomas-and-leiomyosarcomas-of-the-gastrointestinal-tract?source=search\\_result&search=GIST&selectedTitle=2%7E56](http://www.updatdate.com/contents/local-treatment-for-gastrointestinal-stromal-tumors-leiomyomas-and-leiomyosarcomas-of-the-gastrointestinal-tract?source=search_result&search=GIST&selectedTitle=2%7E56). Accessed May 5, 2012.
63. Rader AE, Avery A, Wait CL, McGreevey LS, Faigel D, Heinrich MC. Fine-needle aspiration biopsy diagnosis of gastrointestinal stromal tumors using morphology, immunocytochemistry, and mutational analysis of c-kit. *Cancer*. 2001;93(4):269–275.
64. Miettinen M, Lasota J. Gastrointestinal stromal tumors: pathology and prognosis at different sites. *Semin Diagn Pathol*. 2006 May;23(2):70–83.
65. Dematteo RP, Gold JS, Saran L, et al. Tumor mitotic rate, size, and location independently predict recurrence after resection of primary gastrointestinal stromal tumor (GIST). *Cancer*. 2008 Feb 1;112(3):608–615.
66. Rudolph P, Gloeckner K, Parwaresch R, Harms D, Schmidt D. Immunophenotype, proliferation, DNA ploidy, and biological behavior of gastrointestinal stromal tumors: a multivariate clinicopathologic study. *Hum Pathol*. 1998;29(8):791–800.
67. Cooper PN, Quirke P, Hardy GJ, Dixon MF. A flow cytometric, clinical, and histological study of stromal neoplasms of the gastrointestinal tract. *Am J Surg Pathol*. 1992;16(2):163–170.
68. Gunther T, Schneider-Stock R, Hackel C, et al. Telomerase activity and expression of hTERT and hTR in gastrointestinal stromal tumors in comparison with extragastrointestinal sarcomas. *Clin Cancer Res*. 2000;6(5):1811–1818.
69. Ng EH, Pollock RE, Munsell MF, Atkinson EN, Romsdahl MM. Prognostic factors influencing survival in gastrointestinal leiomyosarcomas. Implications for surgical management and staging. *Ann Surg*. 1992;215(1):68–77.
70. Martin J, Poveda A, Llombart-Bosch A, et al. Deletions affecting codons 557–558 of the c-KIT gene indicate a poor prognosis in patients with completely resected gastrointestinal stromal tumors: a study by the Spanish Group for Sarcoma Research (GEIS). *J Clin Oncol*. 2005 Sep 1;23(25):6190–6198.
71. Fujimoto Y, Nakanishi Y, Yoshimura K, Shimoda T. Clinicopathologic study of primary malignant gastrointestinal stromal tumor of the stomach, with special reference to prognostic factors: analysis of results in 140 surgically resected patients. *Gastric Cancer*. 2003;6(1):39–48.
72. Agaimy A, Wunsch PH, Hofstaedter F, et al. Minute gastric sclerosing stromal tumors (GIST tumorlets) are common in adults and frequently show c-KIT mutations. *Am J Surg Pathol*. 2007;31(1):113–120.
73. Kawanowa K, Sakuma Y, Sakurai S, et al. High incidence of microscopic gastrointestinal stromal tumors in the stomach. *Hum Pathol*. 2006;37(12):1527–1535.
74. Davila RE, Faigel DO. GI stromal tumors. *Gastrointest Endosc*. 2003;58(1):80–88.
75. Otani Y, Furukawa T, Yoshida M, et al. Operative indications for relatively small (2–5 cm) gastrointestinal stromal tumor of the stomach based on analysis of 60 operated cases. *Surgery*. 2006;139(4):484–492.
76. Novitsky YW, Kercher KW, Sing RF, Heniford BT. Long-term outcomes of laparoscopic resection of gastric gastrointestinal stromal tumors. *Ann Surg*. 2006;243(6):738–745; discussion 745–737.
77. Ng EH, Pollock RE, Romsdahl MM. Prognostic implications of patterns of failure for gastrointestinal leiomyosarcomas. *Cancer*. 1992 Mar 15;69(6):1334–1341.
78. Besana-Ciani I, Boni L, Dionigi G, Benevento A, Dionigi R. Outcome and long term results of surgical resection for gastrointestinal stromal tumors (GIST). *Scand J Surg*. 2003;92(3):195–199.

79. Carboni F, Carlini M, Scardamaglia F, et al. Gastrointestinal stromal tumors of the stomach. A ten-year surgical experience. *J Exp Clin Cancer Res.* 2003 Sep;22(3):379–384.
80. Langer C, Gunawan B, Schuler P, Huber W, Fuzesi L, Becker H. Prognostic factors influencing surgical management and outcome of gastrointestinal stromal tumours. *Br J Surg.* 2003;90(3):332–339.
81. Pierie JP, Choudry U, Muzikansky A, Yeap BY, Souba WW, Ott MJ. The effect of surgery and grade on outcome of gastrointestinal stromal tumors. *Arch Surg.* 2001;136(4):383–389.
82. Wu PC, Langerman A, Ryan CW, Hart J, Swiger S, Posner MC. Surgical treatment of gastrointestinal stromal tumors in the imatinib (STI-571) era. *Surgery.* Oct 2003;134(4):656–665; discussion 665–656.
83. Druker BJ, Talpaz M, Resta DJ, et al. Efficacy and safety of a specific inhibitor of the BCR-ABL tyrosine kinase in chronic myeloid leukemia. *N Engl J Med.* 2001 Apr 5;344(14):1031–1037.
84. Druker BJ, Tamura S, Buchdunger E, et al. Effects of a selective inhibitor of the Abl tyrosine kinase on the growth of Bcr-Abl positive cells. *Nat Med.* 1996;2(5):561–566.
85. Heinrich MC, Griffith DJ, Druker BJ, Wait CL, Ott KA, Ziegler AJ. Inhibition of c-kit receptor tyrosine kinase activity by STI 571, a selective tyrosine kinase inhibitor. *Blood.* 2000 Aug 1;96(3):925–932.
86. Blanke CD, Rankin C, Demetri GD, et al. Phase III randomized, intergroup trial assessing imatinib mesylate at two dose levels in patients with unresectable or metastatic gastrointestinal stromal tumors expressing the kit receptor tyrosine kinase: S0033. *J Clin Oncol.* 2008 Feb 1;26(4):626–632.
87. Verweij J, Casali PG, Zalcberg J, et al. Progression-free survival in gastrointestinal stromal tumours with high-dose imatinib: randomised trial. *Lancet.* 2004 Sep 25–Oct 1;364(9440):1127–1134.
88. Eisenberg BL, Harris J, Blanke CD, et al. Phase II trial of neoadjuvant/adjuvant imatinib mesylate (IM) for advanced primary and metastatic/recurrent operable gastrointestinal stromal tumor (GIST): early results of RTOG 0132/ACRIN 6665. *J Surg Oncol.* 2008 Oct 21;99(1):42–47.
89. McAuliffe JC, Hunt KK, Lazar AJ, et al. A randomized, phase II study of preoperative plus postoperative imatinib in GIST: evidence of rapid radiographic response and temporal induction of tumor cell apoptosis. *Ann Surg Oncol.* 2009;16(4):910–919.
90. Blanke CD, Demetri GD, von Mehren M, et al. Long-term results from a randomized phase II trial of standard- versus higher-dose imatinib mesylate for patients with unresectable or metastatic gastrointestinal stromal tumors expressing KIT. *J Clin Oncol.* 2008 Feb 1;26(4):620–625.
91. Joensuu H, Fletcher C, Dimitrijevic S, Silberman S, Roberts P, Demetri G. Management of malignant gastrointestinal stromal tumours. *Lancet Oncol.* 2002;3(11):655–664.
92. DeMatteo R, Owzar K, Antonescu C, et al. Efficacy of adjuvant imatinib mesylate following complete resection of localized, primary GIST at high risk of recurrence: U.S. intergroup phase II trial ACOSOG Z9000. *ASCO Gastrointestinal Symposium.* January 2008.
93. Dematteo RP, Ballman KV, Antonescu CR, et al. Adjuvant imatinib mesylate after resection of localised, primary gastrointestinal stromal tumour: a randomised, double-blind, placebo-controlled trial. *Lancet.* 2009 Mar 28;373(9669):1097–1104.
94. Zhan WH, Group CGC. Efficacy and safety of adjuvant post-surgical therapy with imatinib in patients with high risk of relapsing GIST [abstr 10045]. *Proc Am Soc Clin Oncol.* 2007;25.
95. Kang Y, Kang B, Ryu M, et al. A phase II study of imatinib mesylate as adjuvant treatment for curatively resected high-risk localized gastrointestinal stromal tumors with c-kit exon 11 mutation [abstr 95]. *ASCO Gastrointestinal Symposium.* 2009.
96. van Oosterom AT, Judson I, Verweij J, et al. Safety and efficacy of imatinib (STI571) in metastatic gastrointestinal stromal tumours: a phase I study. *Lancet.* 2001 Oct 27;358(9291):1421–1423.
97. Raut CP, Hornick JL, Bertagnoli MM. Advanced gastrointestinal stromal tumor: potential benefits of aggressive surgery combined with targeted tyrosine kinase inhibitor therapy. *Am J Hematol/Oncol.* 2006;5(12):707–712.
98. Bummig P, Andersson J, Meis-Kindblom JM, et al. Neoadjuvant, adjuvant and palliative treatment of gastrointestinal stromal tumours (GIST) with imatinib: a centre-based study of 17 patients. *Br J Cancer.* 2003;89:460–464.
99. Scaife CL, Hunt KK, Patel SR, et al. Is there a role for surgery in patients with “unresectable” cKIT+ gastrointestinal stromal tumors treated with imatinib mesylate? *Am J Surg.* 2003 Dec;186(6):665–669.
100. Bauer S, Hartmann JT, de Wit M, et al. Resection of residual disease in patients with metastatic gastrointestinal stromal tumors responding to treatment with imatinib. *Int J Cancer.* 2005 Nov 1;117(2):316–325.
101. (MetaGIST) GSTM-AG. Comparison of two doses of imatinib for the treatment of unresectable or metastatic gastrointestinal stromal tumors: a meta-analysis of 1,640 patients. *J Clin Oncol.* 2010 Mar 1;28(7):1247–1253.
102. Blay JY, Le Cesne A, Ray-Coquard I, et al. Prospective multicentric randomized phase III study of imatinib in patients with advanced gastrointestinal stromal tumors comparing interruption versus continuation of treatment beyond 1 year: the French Sarcoma Group. *J Clin Oncol.* 2007 Mar 20;25(9):1107–1113.
103. Adenis A, Cassier PA, Bui BN, et al. Does interruption of imatinib (IM) in responding patients after three years of treatment influence outcome of patients with advanced GIST included in the BFR14 trial? *J Clin Oncol.* 2008;26:A10522.
104. Demetri GD, van Oosterom AT, Garrett CR, et al. Efficacy and safety of sunitinib in patients with advanced gastrointestinal stromal tumour after failure of imatinib: a randomised controlled trial. *Lancet.* 2006 Oct 14;368(9544):1329–1338.
105. George S, Blay JY, Casali PG, et al. Clinical evaluation of continuous daily dosing of sunitinib malate in patients with advanced gastrointestinal stromal tumour after imatinib failure. *Eur J Cancer.* 2009 Jul;45(11):1959–1968.
106. Wiebe L, Kasza K, Maki RG, et al. Sorafenib is active in patients with imatinib- and sunitinib-resistant gastrointestinal stromal tumors (GIST): a phase II trial of the University of Chicago Phase II Consortium [abstr 10502]. *J Clin Oncol.* 2008;26:553s.
107. Blay JY, Casali PG, Reichardt P, et al. A phase I study of nilotinib alone and in combination with imatinib in patients with imatinib-resistant gastrointestinal stromal tumors (GIST): study update [abstr 10553]. *J Clin Oncol.* 2008;26.
108. Bui BN, Blay JY, Duffaud F, Hermine O, Le Cesne A. Preliminary efficacy and safety results of masitinib, front line in patients with advanced GIST. A phase II study [abstr 10025]. *J Clin Oncol.* 2007;25.
109. Joensuu H, De Braud F, Coco P, et al. Phase II, open-label study of PTK787/ZK222584 for the treatment of metastatic gastrointestinal stromal tumors resistant to imatinib mesylate. *Ann Oncol.* 2008;19(1):173–177.
110. Bauer S, Yu LK, Demetri GD, Fletcher JA. Heat shock protein 90 inhibition in imatinib-resistant gastrointestinal stromal tumor. *Cancer Res.* 2006 Sep 15;66(18):9153–9161.
111. DeMatteo RP, Maki RG, Singer S, Gonen M, Brennan MF, Antonescu CR. Results of tyrosine kinase inhibitor therapy followed by surgical resection for metastatic gastrointestinal stromal tumor. *Ann Surg.* 2007;245(3):347–352.
112. Raut CP, Posner M, Desai J, et al. Surgical management of advanced gastrointestinal stromal tumors after treatment with targeted systemic therapy using kinase inhibitors. *J Clin Oncol.* 2006 May 20;24(15):2325–2331.
113. Andtbacka RH, Ng CS, Scaife CL, et al. Surgical resection of gastrointestinal stromal tumors after treatment with imatinib. *Ann Surg Oncol.* 2007;14(1):14–24.
114. Bonvalot S, Eldweny H, Pechoux CL, et al. Impact of surgery on advanced gastrointestinal stromal tumors (GIST) in the imatinib era. *Ann Surg Oncol.* 2006;13(12):1596–1603.
115. Gronchi A, Fiore M, Miselli F, et al. Surgery of residual disease following molecular-targeted therapy with imatinib mesylate in advanced/metastatic GIST. *Ann Surg.* 2007;245(3):341–346.
116. Rutkowski P, Nowecki Z, Nyckowski P, et al. Surgical treatment of patients with initially inoperable and/or metastatic gastrointestinal stromal tumors (GIST) during therapy with imatinib mesylate. *J Surg Oncol.* 2006 Mar 15;93(4):304–311.
117. Andtbacka RH, Ng CS, Scaife CL, et al. Surgical resection of gastrointestinal stromal tumors after treatment with imatinib. *Ann Surg Oncol.* 2007;14(1):14–24.

*This page intentionally left blank*

# PERSPECTIVE ON GASTROINTESTINAL STROMAL TUMORS

Ronald P. DeMatteo

## INTRODUCTION

In the accompanying chapter, Dr Raut provides an overview of gastrointestinal stromal tumor (GIST). Clearly, the development of tyrosine kinase inhibitors for GIST is one of the most remarkable achievements to date for any solid tumor. Patients with metastatic GIST historically had a median survival of 12 months, but it is now 5 years.<sup>1,2</sup> The paradigm of targeted molecular therapy has been subsequently expanded to lung adenocarcinoma with epidermal growth factor receptor (EGFR) inhibitors, renal carcinoma with vascular endothelial growth factor receptor (VEGFR) inhibitors, and most recently melanoma with B-Raf inhibitors. Although GIST is an uncommon tumor, lessons from “the GIST story” will have relevance to the multimodality therapy of these more common tumors and other cancers for which targeted therapy is developed.

Despite the advances in molecular therapy, it is critical to realize that surgery remains the only potentially curative treatment for GISTs. There are no data to support chronic therapy with molecular agents instead of surgical removal in patients who are otherwise healthy and expected otherwise to have prolonged survival. Thus, a thorough understanding of the surgical principles for GIST is essential.

## SPECIFIC SURGICAL ISSUES

There are a variety of surgical issues in GIST that deserve emphasis. First, it is important to handle GISTs gently, as they are often soft and prone to tumor rupture. They may become even more friable after response to neoadjuvant therapy. During laparoscopic resections, specimens should be placed into a plastic bag prior to removal from the abdominal cavity. Large GISTs tend to have extensive arterial and venous collaterals. Thus, careful dissection is necessary to minimize the chance of significant blood loss. While GISTs tend to push surrounding structures as opposed to invading them, if a GIST is adherent to a contiguous organ, it is necessary to remove the tumor en bloc with a portion of that organ.

The site and size of a primary GIST influence the surgical approach. For small- to medium-sized tumors, laparoscopic resection can be used. Some of these tumors will be cured by surgery alone as they generally tend to have low mitotic rates. Gastric GISTs are often easily identified at surgery because they tend to be exophytic. Tumors that grow more inward toward the gastric lumen may require intraoperative endoscopy to localize the exact site for partial gastrectomy. Intraoperative ultrasound may also be useful and is facilitated by instilling water into the stomach. Tumors arising from the posterior wall of the stomach are slightly more challenging to remove but still often can be removed laparoscopically after adequate stomach mobilization. It is often helpful during laparoscopy to retract the left lateral segment of the liver to the right to fully expose the stomach. Most gastric tumors can be removed using surgical staplers. Generally, a 1-cm margin of normal tissue is adequate. As Dr Raut mentions, it may not be possible or necessary to have a preoperative tissue diagnosis. Therefore, patients should be informed that their tumor may not prove to be a GIST. Other entities that can masquerade as GISTs include leiomyoma, Schwannoma, and even ectopic pancreas.

Occasionally, gastric GISTs arise near the gastroesophageal junction. In general, we prefer to remove these GISTs using laparotomy, especially if they arise from the posterior stomach. It may be necessary to open the stomach to facilitate adequate removal and proper reconstruction. If, instead, surgical staplers are used, it is advisable to use a bougie to avoid narrowing the entrance to the stomach.

Massive gastric tumors may be inseparable from the splenic hilum, distal pancreas, splenic flexure of the colon, or the fourth portion of the duodenum. In patients with large GISTs, neoadjuvant imatinib mesylate is highly recommended as it may reduce the extent of the operation required to remove the tumor. Generally, we perform a computed tomography (CT) 2–4 weeks after starting imatinib to check for tumor response, which can be detected by a decrease in tumor perfusion and density. Size is not a reliable indicator of response initially, because a responsive



tumor may not decrease in size and occasionally may even swell temporarily. Therefore, it is important that the surgeon personally review the radiologic films. In the absence of tumor progression, imatinib is then continued and scans are repeated 3 and 6 months later. Generally, resection is attempted between 6 and 9 months following the start of a tyrosine kinase inhibitor. Rarely, a total gastrectomy is required to remove adequately a proximal gastric GIST, especially if it is large. This possibility should be discussed with the patient preoperatively.

The small intestine is the next most common site of origin. The same basic surgical principles apply. GISTs of the duodenum are particularly complex to treat. A GIST in the second portion of the duodenum may require a pancreaticoduodenectomy, unless it is on the lateral wall and small in size. In that case, a lateral duodenal resection can be performed. Reconstruction can be performed with a Roux-en-Y jejunal limb. Sometimes, though, the defect can be closed primarily. GISTs in the fourth portion of the duodenum can be removed and reconstructed with a direct anastomosis between the duodenum and jejunum or closure of the distal duodenum with a Roux-en-Y jejunal limb that is sewn to the second portion of the duodenum. Neoadjuvant imatinib therapy is often useful in duodenal GISTs.

Although colonic GISTs are rare, GISTs arise from the rectum 5% of the time. Neoadjuvant therapy may reduce the extent of the operation and in particular preserve the anal sphincter and avoid an abdominoperineal resection. For distal tumors, local resection can be performed via the transanal route. The value of postoperative radiation following the local excision of a rectal GIST is uncertain.

## PERIOPERATIVE CARE

Unlike many cytotoxic chemotherapeutic agents, imatinib and sunitinib (as well as sorafenib, dasatinib, and nilotinib) can just be stopped a day or two prior to surgery. For patients requiring postoperative therapy, the agent can be restarted when the patient is tolerating a regular diet well, usually within 2 weeks of surgery.

## ADJUVANT THERAPY

As covered by Dr Raut, certain patients are considered for adjuvant therapy with imatinib following the resection of a primary, localized GIST. The results of a phase 3 trial demonstrated prolonged recurrence-free survival in patients assigned to 1 year of imatinib therapy compared with those assigned to placebo.<sup>3</sup> Overall survival is not different at this time. This trial included “all comers” with a tumor at least 3 cm in size. Subsequent analyses have shown that patients at low risk of recurrence (see Table 24-1) probably do not benefit from adjuvant imatinib because the chance of tumor recurrence is so low.

Recently, we have developed a nomogram based on tumor size, location, and mitotic rate to provide a numerical estimation of recurrence-free survival for any particular patient (<http://www.mskcc.org/mskcc/html/98103.cfm>).<sup>4</sup> The nomogram results can be used to guide the discussion of adjuvant therapy with a particular patient. As we accumulate more data on the impact of specific mutations in GIST, the nomogram will be further refined. The central question for patients who are at moderate to high risk of tumor recurrence and are receiving adjuvant imatinib is when the drug should be discontinued. It appears that 1 year of adjuvant imatinib may not be enough. As pointed out by Dr Raut, several ongoing trials are attempting to identify the optimal duration of adjuvant imatinib therapy.

## SURGERY FOR METASTATIC GIST

The standard of care for metastatic GIST is treatment with tyrosine kinase inhibitors. However, in selected patients with resectable metastases, I and others have recommended surgical resection when all residual disease can be removed. Dr Raut references several retrospective series that have shown the safety of this approach. The results of course are confounded by selection bias. In addition, there is lead-time bias, because many of the patients underwent surgery early on after starting medical therapy. The true efficacy of surgery therefore remains unproven. The hypothesis is that the time to resistance to tyrosine kinase inhibition is proportional to the amount of residual tumor following the response to a tyrosine kinase inhibitor. There are two open trials in which patients are being randomized to a tyrosine kinase inhibitor with or without surgery. For obvious reasons, accrual may be problematic. As radiologic surveillance of patients who have undergone surgical removal of a primary GIST increases, it will become more commonplace to detect minimal amounts of metastatic disease that are amenable to surgical removal. In the absence of randomized data, it seems reasonable to perform surgery for metastatic GIST in well-informed patients when the disease has responded to tyrosine kinase inhibition and all the disease can be removed.

## REFERENCES

1. Gold JS, van der Zwan SM, Gonen M, et al. Outcome of metastatic GIST in the era before tyrosine kinase inhibitors. *Ann Surg Oncol.* 2007;14:134–142.
2. Blanke CD, Demetri GD, von Mehren M, et al. Long-term results from a randomized phase II trial of standard- versus higher-dose imatinib mesylate for patients with unresectable or metastatic gastrointestinal stromal tumors expressing KIT. *J Clin Oncol.* 2008;26:620–625.
3. DeMatteo RP, Ballman KV, Antonescu CR, et al. Adjuvant imatinib mesylate after resection of localised, primary gastrointestinal stromal tumour: a randomised, double-blind, placebo-controlled trial. *Lancet.* 2009;373:1097–1104.
4. Gold JS, Gonen M, Gutierrez A, et al. Development and validation of a prognostic nomogram for recurrence-free survival after complete surgical resection of localised primary gastrointestinal stromal tumour: a retrospective analysis. *Lancet Oncol.* 2009;10:1045–1052.

# STOMACH AND DUODENUM: OPERATIVE PROCEDURES

David I. Soybel • Michael J. Zinner

## HISTORICAL PERSPECTIVE

The earliest recorded operations on the stomach were performed for penetrating injuries.<sup>1</sup> In the late 1800s, experimental studies in the surgical laboratories of Billroth confirmed the feasibility of removing the pylorus, a concept developed by Michaelis in the early part of that century. In 1881, Rydygier performed the first successful pylorotomy, and in 1884 he performed the first gastroenterostomy. Both of these operations were performed for complications of benign peptic ulcer disease. In 1881, Billroth performed the first successful pylorotomy for malignancy. In this case, the duodenum was anastomosed to the lesser curvature of the stomach and the greater curvature was oversewn. The patient initially did well but died from disseminated abdominal carcinomatosis 4 months later. In 1885, Billroth performed a resection of a large pyloric carcinoma, using an anterior gastrojejunostomy for the reconstruction. In subsequent years, Billroth, his students, and others devised several approaches to gastroduodenal and gastrojejunal reconstruction.<sup>1-3</sup> Following popularization of gastrojejunostomy for reconstruction after gastric resection or palliation of unresectable gastric malignancy, surgeons were confronted with early complications such as bleeding, anastomotic leak, intestinal obstruction, and late complications such as stomal ulceration, bilious vomiting, afferent and efferent limb obstructions, and dumping.<sup>4,5</sup> At present, these problems remain only partially understood and controllable.

Pyloroplasty was initially devised by Heineke for treatment of congenital hypertrophic pyloric stenosis, and the results were poor. Jaboulay's side-to-side anastomosis of the distal greater curvature and duodenum in 1892, and the Faience extension of this anastomosis to include the pylorus itself were subsequently refined by Kocher. Kocher improved the technical ease of the operation by including a mobilization of the duodenum from its lateral peritoneal attachments. The first pyloromyotomy was performed for this lesion in 1912 by Ramstedt.

In the early part of the 20th century, a dramatic rise was observed in the incidence of duodenal ulceration. A period

of intense clinical and laboratory investigation from 1920 through 1940 led to the recognition that surgically performed vagotomy could reduce gastric acidity under resting conditions and in response to luminal and humoral stimuli. The use of vagotomy for patients with complications of ulcer disease was pioneered by Latarjet, who reported 24 such cases in 1922. Latarjet himself recognized that vagotomy might lead to delayed gastric emptying and had added a drainage procedure, gastrojejunostomy. Confusion regarding the role of delayed gastric emptying in the pathogenesis of peptic ulcers, however, led many surgeons away from vagotomy and drainage as a treatment for recurrent peptic ulceration. It remained for Dragstedt and his colleagues at the University of Chicago to resurrect this concept in the 1940s.<sup>5</sup> Subsequently, Farmer, Smithwick, and others introduced the combination of truncal vagotomy (TV) and hemigastrectomy, an operation that also removed the gastrin-producing antral mucosa.<sup>3</sup> In the 1950s, Harkins' group in Seattle began to evaluate forms of vagotomy that left intact the celiac and hepatic branches (proximal selective vagotomy), along with or in combination with the preservation of vagal motor branches to the antrum (highly selective vagotomy [HSV] or parietal cell vagotomy). These modifications arose from an appreciation of the contributions of antral motility to proper digestion, as well as improved understanding of specific postvagotomy complications such as dumping and diarrhea. The popularization of HSV is largely attributable to the efforts of Johnston, Goligher, Amstrup, and others, who in the 1960s and 1970s demonstrated the feasibility of obtaining ulcer recurrence rates as low as those of conventional TV without the incidence of dumping and diarrhea that was associated with TV with drainage or gastrectomy.<sup>6,7</sup> It is worth noting that surgeons have done more than developing new and interesting operative approaches to acid peptic disease. They played a major role in advancing current concepts of pathophysiology in ulcer disease and recurrence, and in understanding the physiological consequences of ulcer treatments, both medical and surgical.<sup>4,5</sup>

## VAGOTOMY

Even though the increasing use of medications that inhibit gastric acid secretion, such as proton pump inhibitors, has made elective antisecretory operations essentially nonexistent, these medications remain part of the surgeon's armamentarium in dealing with patients who remain refractory to maximal medical therapy for ulcer disease, and in some selected cases for patients with ulcer perforation and bleeding. To understand the importance of the technical details in the execution of antisecretory operations, it is necessary to fully appreciate the anatomy of the vagus nerve and the gastric microvasculature, as well as the physiology of acid secretion, mucosal barrier function, and gastric motility, which are expanded upon in the following text.

### Tests of Vagal Control of Acid Secretion

Historically, vagal control of acid secretion has been assessed by measuring acid secretion in response to various stimuli. Acid secretion can be measured directly by the placement of a tube into the stomach, through which gastric juice is aspirated and the titratable acidity is measured by adding known quantities of 0.1 N NaOH. Gastric output is measured at baseline and after stimulation with pentagastrin or sham feeding. Measurements of gastric acid output pre- and post-vagotomy operations can be measured to assess the efficacy of vagotomy.<sup>8,9</sup> Acid secretion also can be assessed semiquantitatively, using pH-sensitive dyes, such as Congo red, that coat the mucosa and turn color when acid is being secreted from the gastric glands.<sup>10,11</sup> Although the former analytic methods permit accurate and quantitative assays of secretory capacity before and after the operation, the latter colorimetric methods can provide relatively rapid means of assessing secretory capacity of the stomach during the operation itself. These tests are rarely used today with the increasing use of medications that inhibit gastric acid secretion such as proton pump inhibitors and the consequent rarity of performing elective antiulcer gastric acid-reducing operations.

### Vagal Regulation of Gastric Motility and Emptying

As stated by Professor David Johnson in a previous edition of this book, "... Only when one fully understands the physiologic rationale of highly selective vagotomy will be one sufficiently motivated to do it well." This statement was made not in reference to the innervation of parietal cells that secrete HCl, but to the neural regulation of gastric motor function and emptying. The vagus dominates the motor activity of the normally functioning stomach in three ways. First, it mediates receptive relaxation and gastric accommodation; that is, the relaxation of the gastric fundus when intraluminal pressures in the proximal esophagus and stomach are increased by

the presence of chyme. Second, the vagus mediates increases in antral myoelectrical activity that result from distention of the proximal stomach by chyme. Third, the vagus appears to mediate coordination of pyloric emptying with antral myoelectrical activity, in response to changes in proximal gastric motor activity, and perhaps in response to changes in composition and pH of duodenal content.<sup>12</sup>

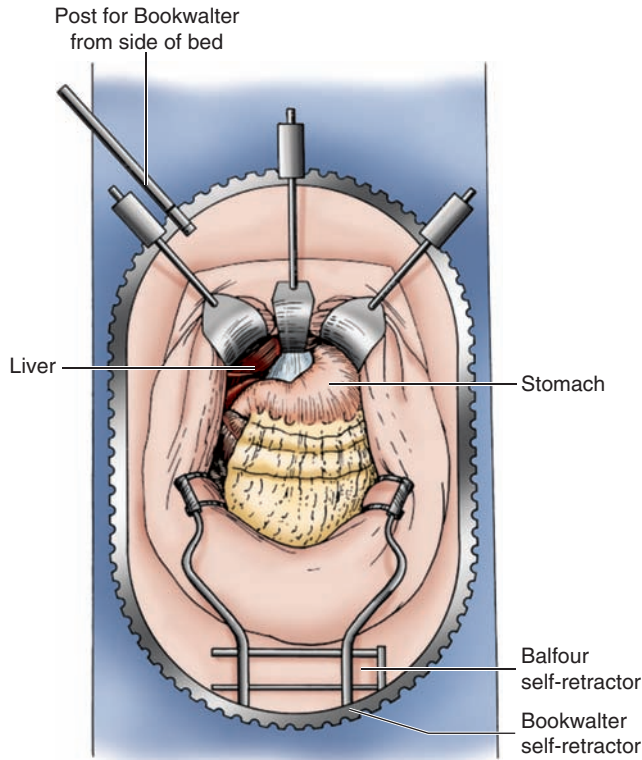
It should be recognized that while truncal or selective vagotomy interrupts the vagal pathways to the antrum and pylorus, all three forms of vagotomy (truncal, selective, and highly selective) abolish receptive relaxation and gastric accommodation. It has been claimed that in the absence of pyloric scarring or stenosis, vagotomy only temporarily impairs gastric emptying. This rationale has been used to justify combinations of selective and relatively nonselective approaches, such as a posterior truncal and anterior highly selective (or anterior seromyotomy) vagotomy. Such arguments become important in thinking about potential adverse consequences of laparoscopic approaches to the vagus and the need for, and choice of, drainage procedures. The assumptions that antral/pyloric coordination will return after truncal vagotomy or that gastric emptying after pyloromyotomy is as good as that after pyloroplasty now seems valid.<sup>13-15</sup> In addition, the spectrum of complications following such mixtures of approach has now been characterized and is not substantially different than those reported in symmetric operations.<sup>15,16</sup> Nevertheless, for open or laparoscopic procedures, it is advisable to use the same caution in utilizing mixtures of approach or dispensing with drainage procedures after truncal or selective vagotomy.

### Open Approaches to the Vagus

#### PATIENT POSITION, INCISIONS, AND EXPOSURE

To perform a complete vagotomy, access to the upper part of the stomach and lower esophagus is crucial. It is helpful for the operating surgeon, standing on the patient's right, to wear a headlight. When access to the duodenum is required, as in a gastrectomy, excellent exposure is available through a chevron incision. However, in most patients, both thin and obese, a midline incision carried up along the xiphoid will be adequate. In the obese, extension of the incision below the umbilicus facilitates exposure. Placing the patient in reverse Trendelenburg position is helpful. A nasogastric (NG) tube is placed with its tip at the most dependent portion of the greater curvature. The NG tube helps to keep the position of the esophagus in mind. A self-retaining retractor is required. We use an upper abdominal self-retaining retractor that provides excellent accessories for securing wide exposure to the upper abdomen, and by means of well-placed Mikulicz's pads, for holding the small bowel and transverse colon in the lower abdomen (Fig. 26-1). Some surgeons advocate routine mobilization of the left lobe of the liver by dividing the left triangular ligament. This mobilization is not always necessary and, when the lobe is floppy, can impede exposure. If this maneuver is performed, the lateral segment of the left lobe is



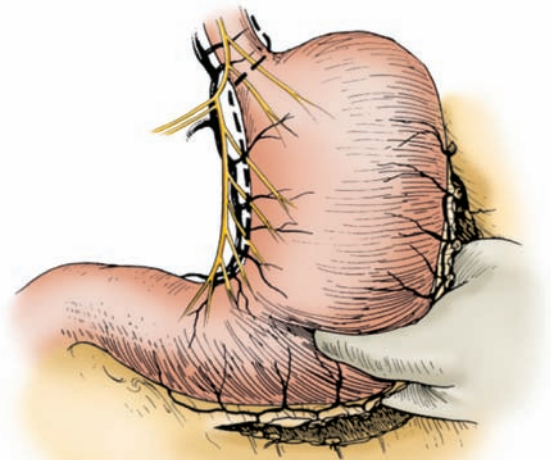


**FIGURE 26-1** The use of the Bookwalter retractor for exposure of the upper abdomen.

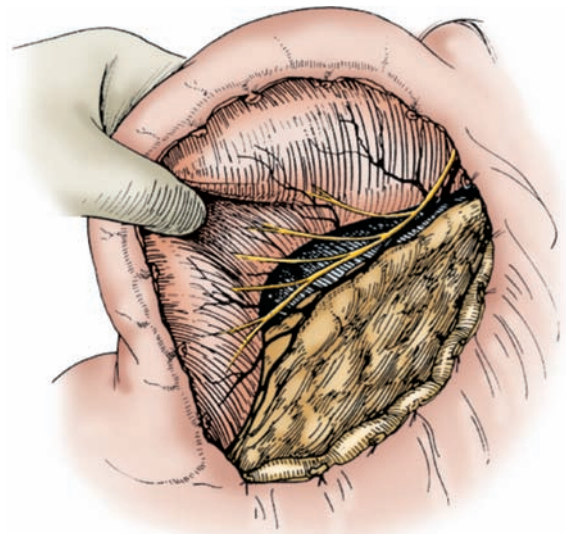
held upward and to the right by a Richardson or Herrington-type retractor accessory. Care must be taken to place sponges or a pack between the retractor attachment and liver, and not to put much tension on the liver. Otherwise, fracture of the liver parenchyma and bleeding will result.

### TRUNCAL VAGOTOMY

Truncal vagotomy (TV) is performed in conjunction with some form of drainage procedure. In the elective setting, it is used in conjunction with antrectomy for definitive management of refractory symptoms of duodenal ulcer, pyloric channel ulcer (gastric ulcer type III), or gastric ulcers combined with duodenal (Dragstedt) ulcers. In the current era of highly effective antisecretory therapies such as omeprazole, and anti-*Helicobacter* antibiotics, the main indication for TV and antrectomy is in the setting of pyloric outlet obstruction with a long-standing history of ulcer symptoms or complications such as bleeding and perforation. TV and pyloroplasty are reserved for emergency operations for complications such as bleeding or perforation. Occasionally, TV plus gastroenterostomy will be an appropriate compromise when the duodenum is too scarred to permit safe antrectomy and duodenal closure. The anatomy of the vagal trunks and nerves of Latarjet has been reviewed<sup>17</sup> and is shown schematically in Figs. 26-2 and 26-3.



**FIGURE 26-2** The distribution of the anterior vagus nerve is shown. The dotted line indicates the line of dissection. Note that it goes around the incisura to within about 6 cm of the pylorus. The gastrocolic omentum has been partially divided to permit access to the posterior nerve of Latarjet and to allow the stomach to be grasped and used as a retractor. Note that the gastroepiploic arteries are carefully preserved. (Redrawn, with permission, from Johnston D. Vagotomy. In: Schwartz SI, Ellis H, eds. *Maingot's Abdominal Operations*. 8th ed. Norwalk, CT: Appleton-Century-Crofts; 1985. After R.N. Lane.)



**FIGURE 26-3** The posterior wall of the stomach and posterior nerve of the Latarjet are shown. The terminal Y fork of the nerve is preserved, and all of the branches to the stomach are divided, leaving about 5 cm of the distal portion of the stomach innervated. (Redrawn, with permission, from Johnston D. Vagotomy. In: Schwartz SI, Ellis H, eds. *Maingot's Abdominal Operations*. 8th ed. Norwalk, CT: Appleton-Century-Crofts; 1985. After R.N. Lane.)



Using a Mikulicz pad or carefully applied Babcock clamps, the assistant places downward traction on the greater curvature of the stomach, thereby placing traction on the gastroesophageal junction and lower esophagus. The first step is to incise the peritoneal covering of the gastroesophageal junction. The peritoneum is opened horizontally, from the angle at the lesser curvature to the cardiac notch at the greater curvature. The surgeon's thumb and right index finger are used in a blunt dissection to encircle the esophagus. When teaching this maneuver, it is not uncommon for the trainee to confuse the right crus of the diaphragm with the esophagus itself or even the posterior vagal trunk. Extra time spent at this juncture to correctly identify all structures is an essential aspect in teaching the operation. A Penrose drain can be passed around the junction in order to place more effective downward traction on the gastroesophageal junction. When encircling the esophagus, the surgeon stays wide of the esophagus in order to prevent inadvertent entry into the lumen and to include the vagal trunks. In the course of this maneuver, the posterior vagal trunk usually will be palpated as a taut cord.

A single anterior vagal trunk is usually identified in the anterior midportion of the esophagus, 2–4 cm above the gastroesophageal junction (Fig. 26-4). At this level, however, it is not uncommon for vagal fibers to be distributed between two or three smaller cords. These cords are palpable as much as they are visible and can be separated from surrounding esophageal muscle fibers using a nerve hook. These trunks are individually lifted up, and 2- to 4-cm segments of each are separated from surrounding tissues. A medium-sized clip is applied at the most superior end, and a clamp is applied inferiorly. The 2-cm length of nerve is resected and a clip is applied below the clamp; small bleeders are cauterized precisely. If it has not been done, the esophagus should be more widely mobilized for a distance of 4–5 cm above the gastroesophageal junction. Smaller, individual vagal fibers that ramify from the main trunks toward the lesser curvature and the cardiac notch then can be identified and cut or cauterized. The “criminal nerve” of Grassi, discussed in more detail in the section describing parietal cell vagotomy, also may be identified here, wrapping around the cardiac notch from its origin in the posterior trunk.

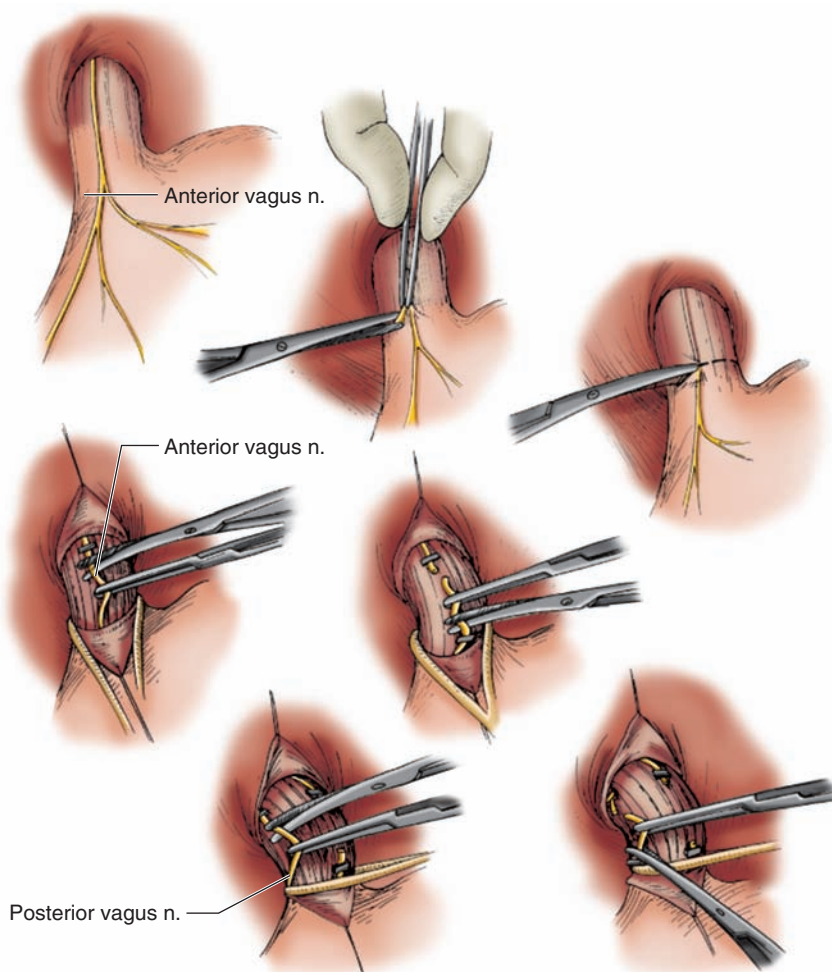


FIGURE 26-4 Division at both vagus nerves. (Redrawn, with permission, from Zinner MJ. *Atlas of Gastric Surgery*. New York, NY: Churchill Livingstone; 1992. After Gloege.)

The posterior vagal trunk itself usually will have been identified along the right edge of the esophagus. If the anterior vagus has already been divided, the esophagus is more mobile. This mobility allows the surgeon to place downward traction on the gastroesophageal junction, or along the most caudal portion of the greater curvature, thereby applying gentle tension on the EG junction, which causes the posterior vagus to “bow-string” and make it easier to identify. A 2- to 4-cm segment is separated from surrounding tissues, its margins marked with clips, and resected. Major branches of the anterior vagus and the posterior vagal trunk should be sent to pathology for examination in frozen section. Care should be taken to note the results of the pathologist’s frozen section diagnosis in the dictated operative note.

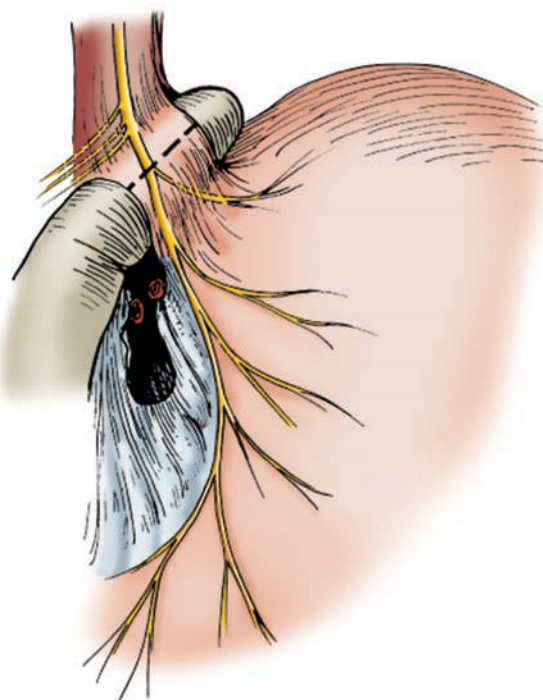
### SELECTIVE VAGOTOMY

Selective vagotomy (SV) is not commonly practiced in the United States, but it has found favor with European surgeons, who prefer not to cut the posteriorly derived vagal branch that innervates the small intestine and pancreas and anteriorly derived vagal branch that supplies the gallbladder and liver. There is evidence that preservation of such branches can avoid alterations in gallbladder motility that might lead to stasis and stone formation.<sup>18</sup> However, it is not clear whether preservation of the small intestinal and pancreatic nerves protects against some symptoms of the dumping syndrome.<sup>19–22</sup> SV involves interruption of both nerves of Latarjet and therefore does not avoid the need for a drainage procedure.<sup>22</sup> Thus the main indication for SV may be in patients undergoing elective antrectomy with vagotomy for refractory ulcer symptoms or obstruction.

Exposure to the vagus, gastroesophageal junction, and esophagus is obtained in the same way that the surgeon would perform TV. Anteriorly, the nerve of Latarjet is identified by following the anterior vagal trunk as it descends from the esophagus to the lesser curvature of the stomach. Frequently, the descending branch of the left gastric artery is in close proximity to the site where the hepatic/gallbladder branches take off toward the liver in the gastrohepatic (lesser) omentum. A segment of the nerve of Latarjet is severed between clips and sent for examination on frozen section. The most expeditious way to perform this maneuver is to cross-clamp the portion of the lesser omentum that contains the artery and nerve, ligating and dividing these structures together (Fig. 26-5). The dissection continues upward along the lesser curvature, gastroesophageal junction, and esophagus. Division and ligation of blood vessels and nerves in this bundle avoids the hepatic/gallbladder branches and denervates the cardia, as was described for TV. This dissection opens up the plane for dissection and ligation of the posterior nerve of Latarjet.

### HIGHLY SELECTIVE VAGOTOMY

Generally accepted indications for highly selective vagotomy (HSV) include elective management of intractable symptoms



**FIGURE 26-5** Selective vagotomy. The descending branch of the left gastric artery has been divided, and the anterior gastric branches of the anterior vagus are about to be divided.

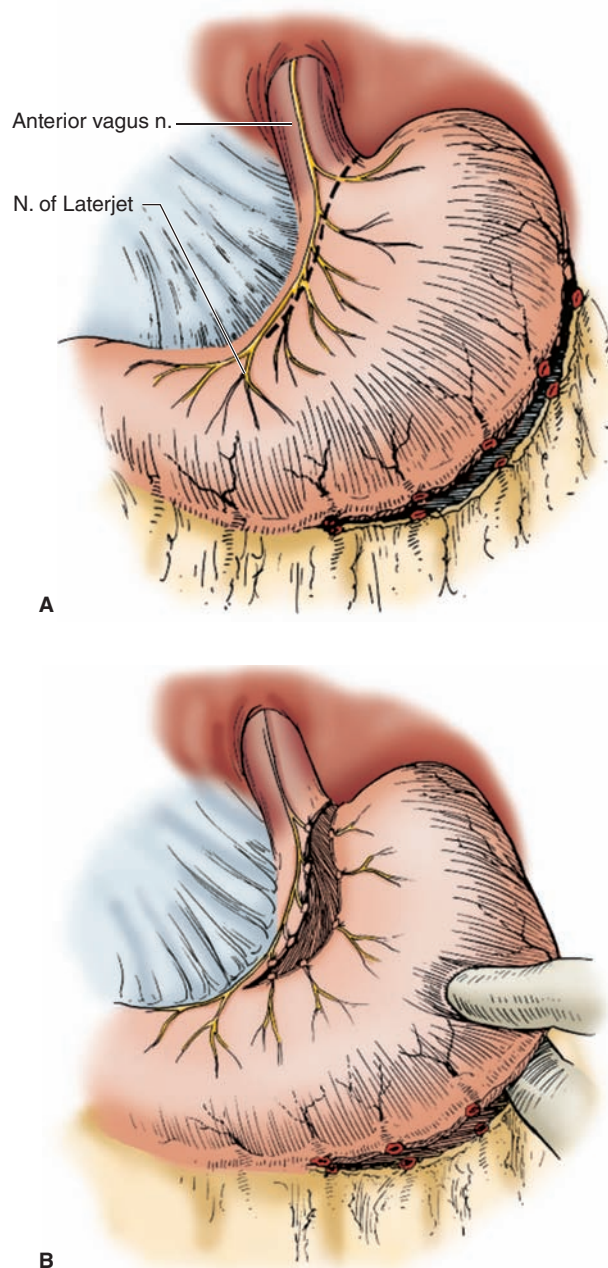
of duodenal ulcer disease, emergency treatment for perforated duodenal ulcer, and emergency treatment of perforated gastric ulcer when the ulcer is to be excised in a wedge rather than resected in continuity with the distal stomach. HSV also has been advocated for management of bleeding gastric or duodenal ulcers, but this has not been widely practiced. Finally, there is published experience in pyloric outlet obstruction using HSV in combination with finger or endoscopic balloon dilation,<sup>19,23–25</sup> but systematic audits of long-term persistence or recurrence rates of obstructing symptoms have yet to be reported.

A number of variations of the technique have been described and all are not reviewed here. However, it is worth cataloguing the decisions that the surgeon must make in preparing for and performing this operation. The first decision is whether to use Congo red dye for intraoperative testing of the completeness of vagotomy, in countries where it is approved for this application. It may be difficult, and sometimes contraindicated, to perform endoscopy in the setting of acute bleeding or perforation. If the test is to be used, the endoscopic equipment and reagents should be assembled in the operating room before the operation begins.<sup>26</sup> Conceptually then, the operation is divided into four phases: (1) exposure and gastric mobilization; (2) dissection of the anterior leaf of the lesser omentum; (3) dissection of the posterior leaf of the lesser omentum; and (4) dissection of vagal fibers traveling to the stomach along the distal esophagus.

**Exposure and Gastric Mobilization.** Exposure of the vagus nerves, esophagus, and gastroesophageal junction is obtained as described previously. A wide-bore (18F) NG tube should be placed by the anesthesia team. A number of authors have emphasized the importance of the stomach as a retractor in this operation. We recommend mobilization of the distal part of gastrocolic omentum. The dissection should be carried outside the gastroepiploic arcade, in order to avoid loss of any blood supply to the greater curvature. Congenital adhesions between the stomach and peritoneum overlying the pancreas are divided sharply. The goal of this dissection is to obtain sufficient mobility of the stomach so that it can be rotated upward and to the patient's right, thus permitting visualization of the posterior leaf of the lesser omentum and the posterior nerve of Latarjet through the lesser sac. The nerve can be seen running close to the descending branch of the left gastric artery. Vagal fibers can be seen running transversely toward the lesser curvature.

**Dissection of the Anterior Leaf of the Lesser Omentum.** The anterior leaf of the lesser omentum now is dissected. The next decision point is to define the distal margin of the dissection of the branches of the nerve of Latarjet (Fig. 26-6). An important landmark is the incisura angularis. The "crow's foot" is the neurovascular bundle that innervates the junction of the corpus and antrum, and has three characteristic branches from which its name derives. These nerves contain motor branches to the antrum and secretory branches to the oxyntic mucosa. Thus, leaving this bundle intact makes the antisecretory operation less complete, but fully severing it may lead to disturbances in gastric emptying. Two approaches for defining the distal margin of the dissection have been advocated. First, one may arbitrarily begin the dissection at a predetermined point 6–7 cm proximal to the pylorus, a distance that usually corresponds to the most proximal of the three branches of the crow's foot. Alternatively, one may identify this most proximal branch and begin the dissection there. It is helpful to begin the dissection a few centimeters proximal to the agreed-upon distal margin, because strong traction during subsequent parts of the operation may cause traction injury on the antral motor branches and vessels that accompany them. These last few centimeters are dealt with last.

The assistant provides downward and leftward traction on the greater curvature, thus placing tension on the anterior nerve of Latarjet as it runs along the lesser curvature. The hepatic fibers usually are visualized without difficulty in the upper part of the lesser omentum. It is helpful to "score" the serosa of the lesser curvature, from the incisura to the cardia, and then transversely across the gastroesophageal junction. The incision is performed with dissecting scissors or a no. 15 knife, not electrocautery. This maneuver widens the gap between the nerve and the gastric wall. Individual vessels run transversely from the lesser omentum onto the lesser curvature. These structures are ligated in continuity with 3-0 silk ligatures before division. (We avoid the use of hemostats in this dissection.) This part of the operation is performed

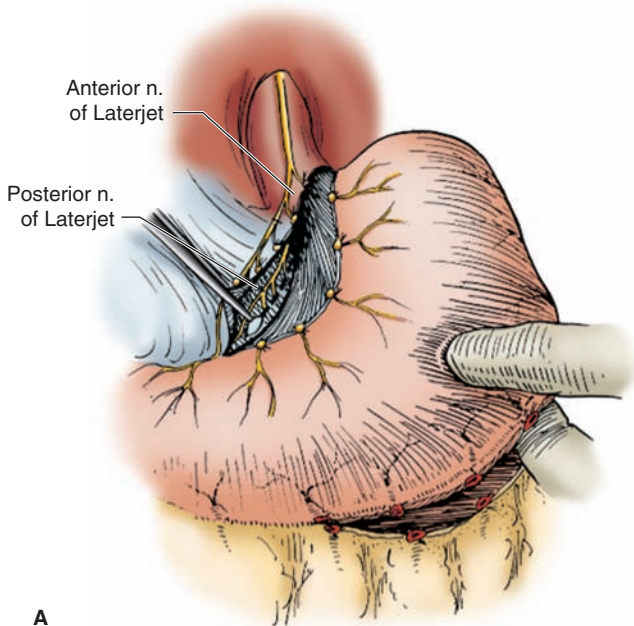


**FIGURE 26-6** Highly selective vagotomy. **A.** Planned line of dissection of the anterior leaf of the gastrohepatic ligament. **B.** The dissection is carried out, beginning just proximal to the crow's foot and extending upward, to the left of the gastroesophageal junction. (Redrawn, with permission, from Zinner MJ. *Atlas of Gastric Surgery*. New York, NY: Churchill Livingstone; 1992. After Gloege.)

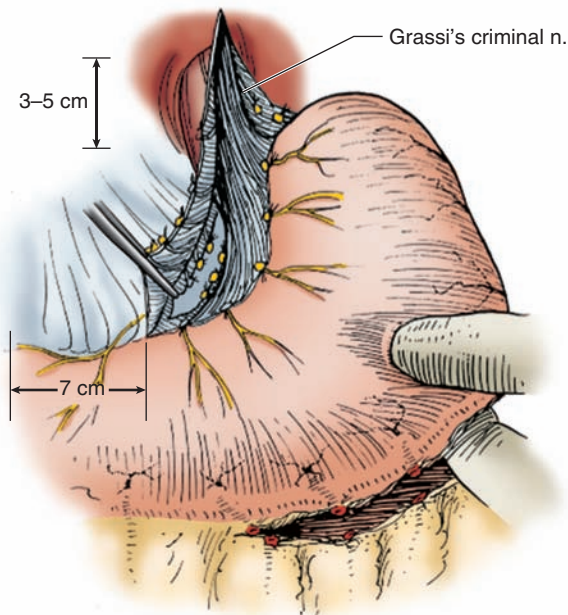
gently and should not cause blood loss. The dissection proceeds along the lesser curvature until the gastroesophageal junction is reached. The left anterior aspect of the esophagus is now uncovered, and, for the moment, the dissection stops. Care should be taken not to continue up the right side to avoid interrupting the main anterior vagus.



**Dissection of the Posterior Leaf of the Lesser Omentum.** The posterior leaf of the lesser omentum then is dissected. Care should be taken in setting up exposure for this part of the operation. In one approach, the stomach is rotated upward and to the patient's right. Alternatively, the posterior leaf can be reached by working through the anterior leaf as illustrated in Fig. 26-7. Using the thumbs and fingers,



A



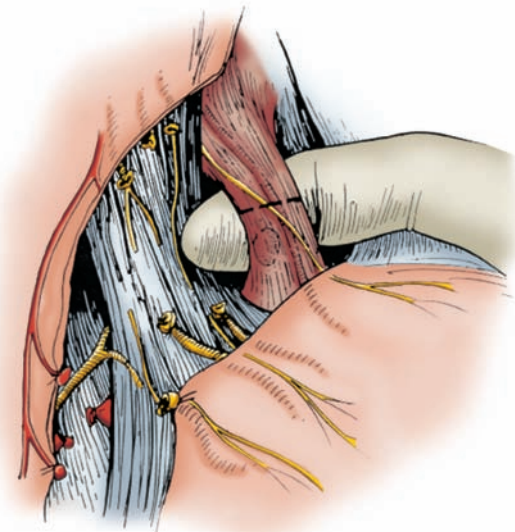
B

**FIGURE 26-7** Parietal cell vagotomy. **A.** The line of dissection of the posterior leaf of the gastrohepatic ligament is illustrated. **B.** The dissection is carried out through the window created by prior dissection of the anterior leaf. (Redrawn, with permission, from Zinner MJ. *Atlas of Gastric Surgery*. New York, NY: Churchill Livingstone; 1992. After R.N. Lane.)

the gastroesophageal junction is “rolled” counter clockwise so that the posterior wall moves to the right and the anterior wall moves to the left. The nerve branches and their accompanying vessels then are ligated in continuity and divided. The dissection should not be carried to less than 6 cm from the pylorus. To avoid the main left gastric vessels, this approach to the dissection should be carried about two-thirds of the distance along the lesser curvature. After reaching the left gastric vessels, the surgeon returns to the anterior approach, ligating and dividing the remainder of the posterior leaf through the window in the anterior leaf.

**Dissection of the Distal Esophagus.** The goal of this dissection is to clear the distal esophagus of all nerve fibers for a distance of approximately 5 cm above the gastroesophageal junction. The importance of this part of the dissection is well documented.<sup>27</sup> It should be noted that the prior dissection of the lesser omentum has allowed the main vagal trunks to move upward and to the patient's right, thereby minimizing the risk of damaging the main trunks in this part of the dissection. The operative technique requires that this dissection stay close to the lesser curvature and esophagus. Any dissection toward the tissues to the right (ie, toward the main vagal trunks) should be avoided.

This part of the procedure begins with the dissection of the left side of the esophagus (Fig. 26-8). Denuding the surface can be performed gently, using a finger or “peanut” dissector to isolate the adventitia that contains nerves, vessels,

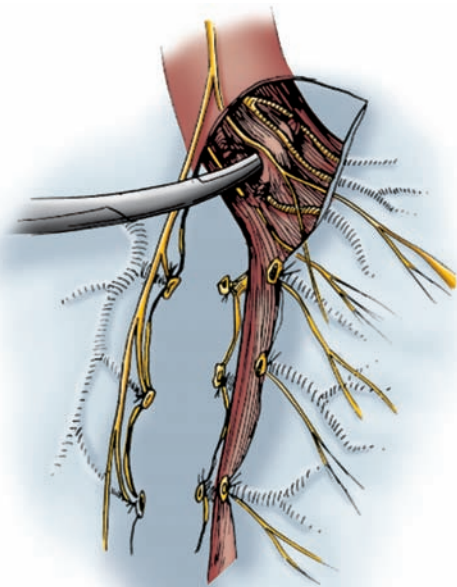


**FIGURE 26-8** The serosa has been cut to the left of the esophagus, and fatty areolar tissue to the left of the esophagus, containing nerve fibers, blood vessels, and lymphatics, is hooked up by the right index finger. The angle of His and the adjacent esophagus with a 2- to 3-cm portion of the fundus of the stomach are thoroughly cleaned. In this way, small nerve fibers running to the proximal 3-cm portion of fundus (“criminal nerves of Grassi”) are eliminated. (Redrawn, with permission, from Johnston D. Vagotomy. In: Schwartz SI, Ellis H, eds. *Maingot's Abdominal Operations*. Norwalk, CT: Appleton-Century-Crofts; 1985. After R.N. Lane.)



and lymphatics. This dissection is where the “criminal nerve” of Grassi is likely to be encountered. Tissues are ligated in continuity and divided. This dissection should also clear 2 or 3 cm of the cardia, just distal to the gastroesophageal junction, and small fibers running to the greater curvature will be divided here. It is usually not necessary to divide any of the short gastric arteries.

The anterior aspect of the esophagus is now cleared of vagal fibers (Fig. 26-9). Gentle traction and lifting of the fibers will isolate them for division between ligatures or by cautery. We prefer ligation in continuity with fine (4-0 or 5-0) silk to avoid injury to the esophageal muscle. The posterior aspect is now reexposed with downward traction of the gastroesophageal junction and a counter clockwise rotation of the distal esophagus. Working through the window of the anterior leaflet, the upward branches of the left gastric artery are visualized as they pass to the cardia and the gastroesophageal junction. They are ligated in continuity and divided. The dissection continues upward along the cardia and gastroesophageal junction, until it is possible to encircle the lower esophagus with a Penrose drain. Downward traction on the gastroesophageal junction is provided by this drain, and additional nerve fibers are seen in the adventitia. Smaller fibers are cauterized while held away from the esophageal muscularis, whereas larger ones are ligated with clips or fine silk and divided. Throughout this dissection, the positions of the nerves of Latarjet and the main trunks should be checked.



**FIGURE 26-9** Anterior gastric branches of the anterior vagal trunk running downward on the anterior surface of the esophagus are gently lifted with a hemostat and either ligated or clipped before being divided or destroyed with diathermy. (Redrawn, with permission, from Johnston D. Vagotomy. In: Schwartz SI, Ellis H, eds. *Maingot's Abdominal Operations*. 8th ed. Norwalk, CT: Appleton-Century-Crofts; 1985. After R.N. Lane.)

The final part of the operation involves completion of the distal dissection to the crow's foot and checks for hemostasis. A number of authors have in the past suggested that reperi-tonealization of the lesser curvature be performed. Although we do not routinely do this, the rationale for this maneuver is that the devascularization that is part of HSV may lead to small areas of necrosis of the gastric wall and localized perforations. Such leaks have been reported in about 0.2% of patients.<sup>28,29</sup> Also, it has been argued that reperi-tonealization might impede reestablishment of vagal nerve connections to the gastric wall.<sup>30</sup> The reperi-tonealization would thus protect against such leaks. The reperi-tonealization can be performed by inversion of the serosa of the lesser curvature with running or continuous 3-0 long-acting absorbable suture. Alternatively, a vascularized pedicle of omentum can be used to cover the deserosalized lesser curvature. Bleeding complications have been reported with this latter method, but it minimizes tension within the gastric wall.

#### REOPERATIVE APPROACHES TO THE VAGUS NERVES

Approximately two-thirds of patients with duodenal or pyloric channel ulcer recurrence after an initial antisecretory operation (TV, SV, or HSV) have evidence of persistent (or possibly reestablished) vagal innervation.<sup>9,31,32</sup> Although many such recurrences are amenable to medical regimens, a small fraction ultimately may be considered for reoperation, especially if surgery is required to control an acute complication such as bleeding or perforation following a period of ulcer-related symptoms. Prior surgery will have made the standard approaches to the lesser curvature and gastroesophageal junction hazardous, which is often caused by dense adhesions to a previously mobilized left lobe of the liver. Thus, two approaches to the vagus, both nonselective, may be considered for completion of the failed vagotomy, especially if it was performed in conjunction with antrectomy. It should be stressed that when such a reoperation is contemplated, especially in a nonemergent setting, it is prudent to obtain some form of acid secretion profile to document the hypersecretory state. Also, because of the nonselective nature of the completion vagotomy, an antrectomy or drainage procedure must be performed.

In the setting in which standard access is difficult due to prior surgery, Barroso and associates have utilized a transabdominal suprahepatic approach to the vagi.<sup>33</sup> A high midline incision is used, with mechanical retraction to elevate the subcostal margin. An 18F NG tube is placed. The triangular, left coronary, and falciform ligaments and adhesions are divided, permitting downward retraction of the left lobe. Using the NG tube, the esophagus and hiatus are located. The esophagus and vagi are dissected at the level of the diaphragm at the hiatus and incised anteriorly for a distance of 3–5 cm, exposing the esophagus at the lower mediastinum. The trunks are easily identified and ligated in the untouched lower thoracic esophagus. The hiatus is closed with interrupted nonabsorbable sutures.

A transthoracic approach to this region has also been used,<sup>34</sup> and with the advent of thoracoscopy it may become increasingly attractive for this limited set of patients. Specific issues in anesthesia for this approach have been reviewed.<sup>35</sup> The operation is performed through the left chest, entered via the eighth intercostal space. An NG tube is positioned with its tip in the stomach. After division of the inferior pulmonary ligament, the base of the left lung is retracted upward and laterally. The mediastinal pleura overlying the esophagus is incised for a distance of 8 cm. The esophagus is then mobilized and encircled with a Penrose drain. Vessel loops are used to retract individual vagal trunks as they are identified. The supradiaphragmatic anterior vagus nerve may have multiple branches above the level of the diaphragm, but rarely are there multiple branches at a level 4 cm above the diaphragm.<sup>30</sup> In contrast, the posterior vagus has multiple branches above the level of the diaphragm, but is a single trunk at this level more than 90% of the time (Fig. 26-10). Thus, the best opportunity for a complete vagotomy lies 4 cm above the diaphragm for the posterior trunk. A circumferential dissection of the 6 cm of esophagus just above the diaphragm is carried out, with technique similar to that performed during the HSV. Tube thoracostomy is required for 2–3 days postoperatively.

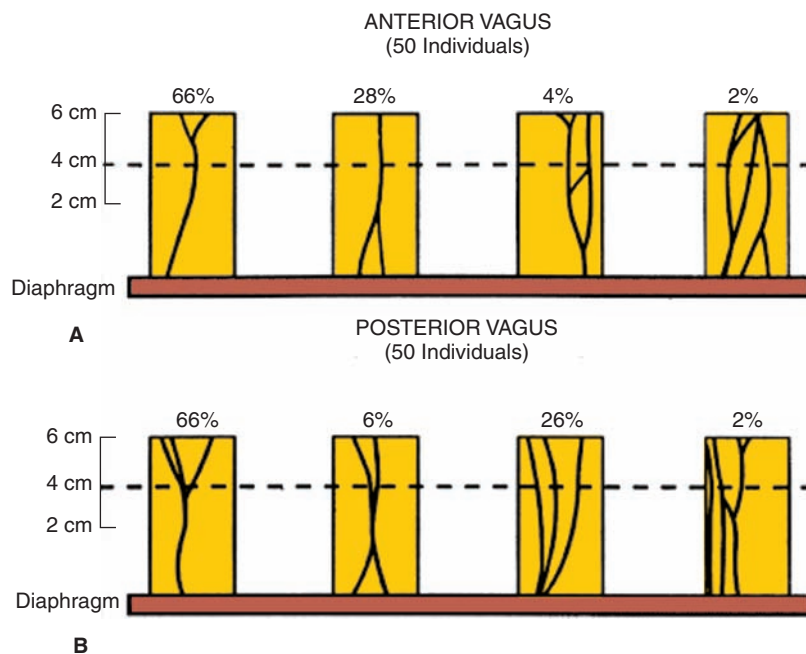
## DRAINAGE PROCEDURES

In the context of bilateral truncal or selective vagotomies, the purpose of a drainage procedure is to preserve the pylorus but bypass or render it ineffective. The options for drainage include

(1) gastroenterostomy; (2) pyloric dilation; (3) pyloromyotomy; and (4) pyloroplasty. Generally, these techniques are used when TV or SV is performed, but they also may be used with HSV in order to treat obstruction resulting from peptic acid scarring. We discuss techniques for performing gastrojejunostomy in the subsequent discussion of gastric resection.

## Pyloric Dilation

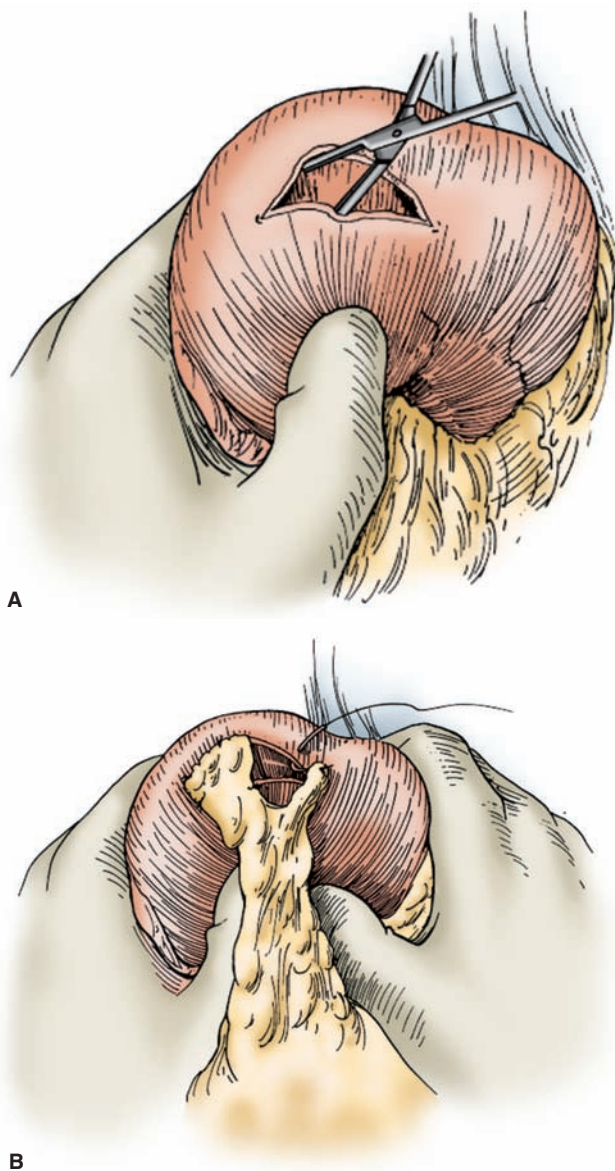
In open procedures, the simplest technique reported for performing pyloric dilation is to perform a small gastrotomy, approximately 3–4 cm in length, proximal to the pylorus. A finger is introduced through the pylorus, forcing it to widen. The gastrotomy then is used with a single layer of 3-0 silk interrupted sutures or staples. A second technique, advocated for use in laparoscopic cases, is to use a balloon. The balloon, 15 mm in length, may be positioned through a gastrotomy, endoscopically, or with radiologic control, and inflated to 45 psi (pounds per square inch) for 10 minutes.<sup>25,36,37</sup> Other dilators are available for positioning over a wire and inflation to higher pressures, which may prevent pyloric spasm. Advocates of pyloric dilation after laparoscopic TV or SV have suggested that a drainage procedure is not required as often as previously thought or may only be necessary in the early postoperative phase and not permanently.<sup>25,36–38</sup> Thus, it is argued that dilation can be repeated postoperatively and in the outpatient setting. Most surgeons, however, subscribe to the need for some form of formal drainage procedure after SV or TV.



**FIGURE 26-10** Anatomy of the anterior (**A**) and posterior (**B**) vagus nerves above the diaphragm in 50 cadavers. Incidence of each anatomic group is indicated by percentage. (Redrawn, with permission, from Jackson RG. Anatomy of the vagus nerve in the region of the lower esophagus and stomach. *Anat Rec.* 1949;103:1.)

## Pyloromyotomy

Pyloromyotomy is performed using the same techniques as those described in the setting of hypertrophic pyloric stenosis in the infant (Fig. 26-11). An incision is made to score the anterior surface of the stomach from 1 to 2 cm proximal to 1 cm distal to the pyloric ring. The separation of pyloric muscles is accomplished mainly with a fine-tip hemostat and the knife. Caution is avoided and only used in the muscularis, not the submucosa. When this procedure is performed in the setting of esophagogastrectomy, the pylorus is usually soft and unscarred. In the setting of chronic duodenal ulcer disease, the pylorus is



**FIGURE 26-11** Pyloromyotomy. **A.** Dissection of seromuscular layers, avoiding entry into bowel. **B.** An omental patch is used to cover the dissected area. (Redrawn, with permission, from Welch CE. *Surgery of the Stomach and Duodenum*. Chicago, IL: Year Book Medical; 1973.)

often scarred, and it is difficult to perform the gentle, meticulous dissection of muscle layers, which is required, and at the same time to avoid entering the mucosa. Laparoscopic versions of this procedure also have been advocated in the setting of laparoscopic TV or SV.<sup>39</sup> Occasionally omentum is placed over the myotomy.

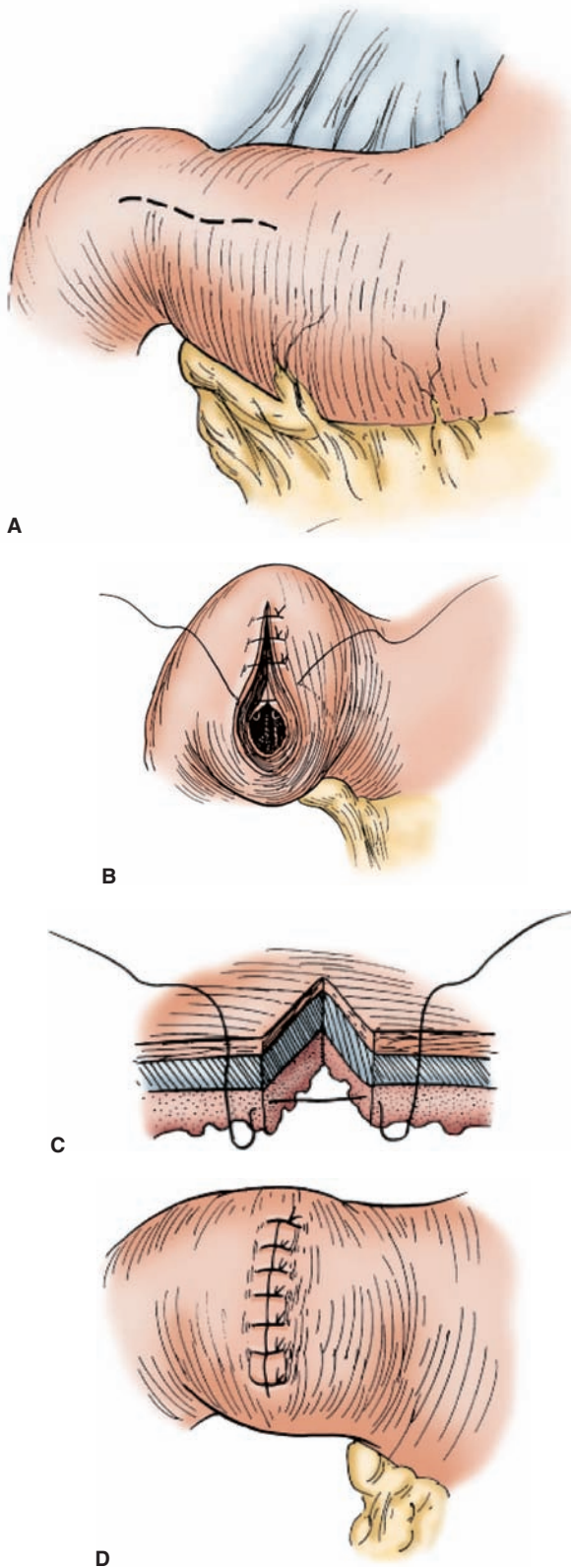
## Pyloroplasty

The most expeditiously performed pyloroplasty is the Heineke-Mikulicz procedure (Fig. 26-12).<sup>40</sup> This is difficult to perform if the pyloric region is very scarred. The operation usually is performed in the setting of emergency surgery for bleeding or perforation of a gastric or duodenal ulcer. A vagotomy is performed, usually after bleeding has been controlled. If the indication is a bleeding or perforated duodenal or pyloric channel ulcer, the incision for pyloroplasty may include the ulcer or be used to gain access to the ulcer. The incision is thus the planned pyloroplasty incision.

It is not always necessary to perform a Kocher maneuver; however, duodenal mobilization is usually helpful in relieving any tension on the intended suture line. Unless the duodenal bulb is unusually mobile, we recommend this as the initial step. In this maneuver, the peritoneum along the right border of the duodenum is incised from the lateral border of the common bile duct to the junction of the second and third portions of the duodenum. After duodenal mobilization, 3-0 silk stay sutures are placed untied, superior and inferior to the site of the intended incision, which then is made on the anterior surface in a longitudinal direction, using electrocautery, from 2 cm distal to the pyloric muscle to 3 cm proximal to the pylorus. The closure of the pyloroplasty is performed vertically, in order to minimize narrowing of the lumen. The Gambee stitch (see Fig. 26-12) is a single-layer inverting suture used in this setting. The suture, usually performed with 3-0 or 2-0 silk, begins on the outside and is (1) placed full thickness (serosa to mucosa) on the same side; (2) brought, on the same side, back through the mucosa to the submucosa; (3) carried through the submucosa to the mucosa on the opposite side; and (4) brought full thickness from mucosa to serosa on that side. When the pylorus is scarred and the tissues inflexible, it is often helpful to tie the sutures after they have been placed, rather than as they are being placed. The stay sutures then are removed, after completion of the pyloroplasty. A tongue of vascularized omentum (as shown for pyloromyotomy in Fig. 26-11) may be brought up to cover the closure and it is sutured to the gut wall with 3-0 absorbable (polyglactin 910) sutures.

The Finney pyloroplasty<sup>1</sup> can be used when scarring has involved the pylorus and duodenal bulb and would not permit a tension-free, patulous Heineke-Mikulicz pyloroplasty. The Finney pyloroplasty is in essence a side-to-side gastroduodenostomy (Fig. 26-13). When this operation begins, dense adhesions often are encountered surrounding the pylorus and duodenal bulb. These must be lysed systematically. The Kocher maneuver then is performed, carrying the





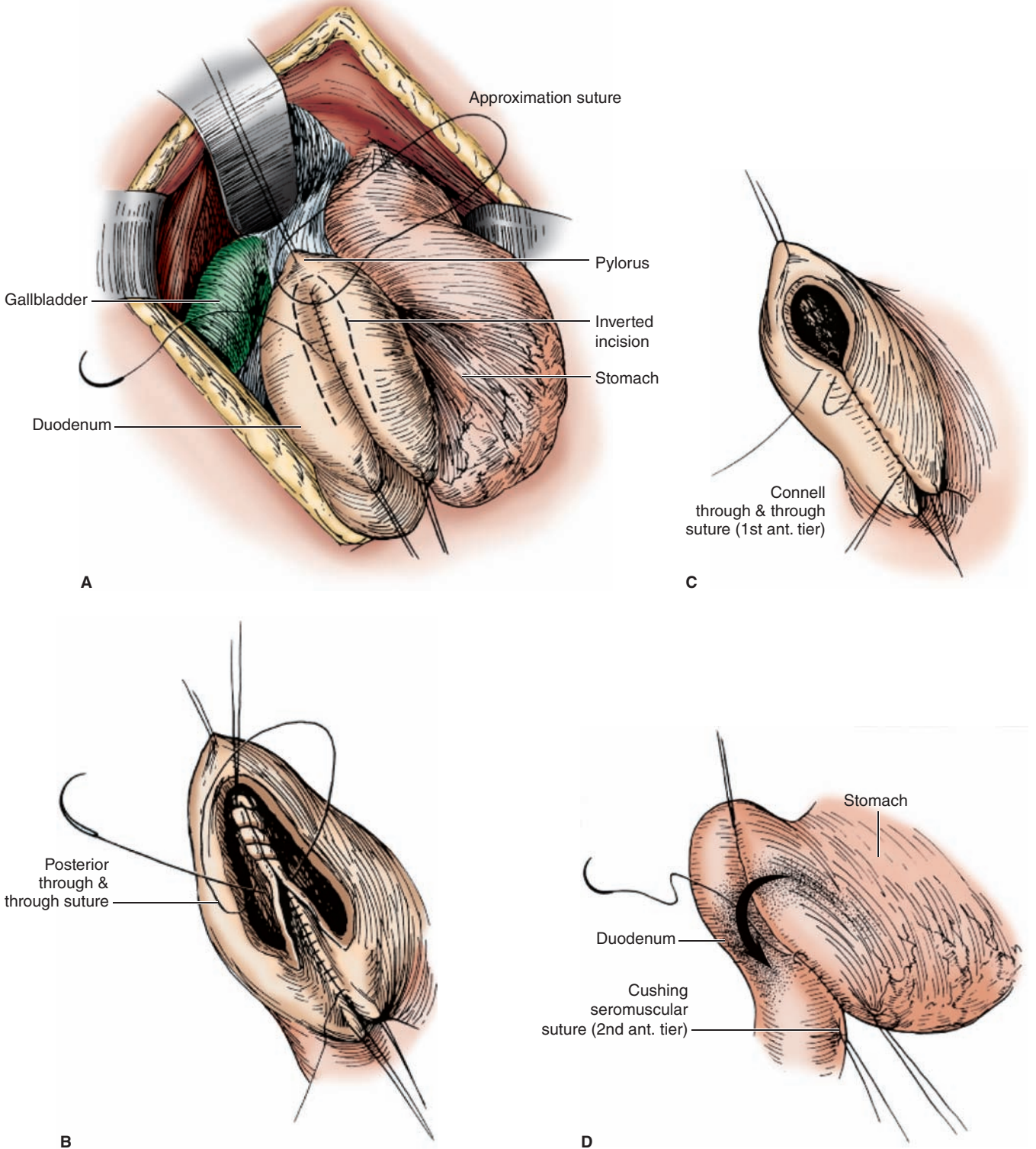
**FIGURE 26-12** Heinecke-Mikulicz pyloroplasty. **A.** Full-thickness incision extends from 2 cm proximal to 1–2 cm distal to the pyloric ring. **B.** The incision is closed vertically. **C.** Illustration of Gambee stitch. **D.** Finished pyloroplasty. (Redrawn, with permission, from Zinner MJ. *Atlas of Gastric Surgery*. New York, NY: Churchill Livingstone; 1992. After Gloege.)

mobilization distally. Complete mobility of the duodenum and freedom from surrounding adhesions are essential to this operation.

A 2-0 silk stay suture is placed on the upper anterior surface of the pyloric ring. Another stay suture is placed on the greater curvature of the stomach approximately 10 cm proximal to the pylorus, and a third stay suture is placed approximately 10 cm distal to the pylorus. Traction cranially on the pyloric suture and caudally on the other two sutures brings the anterior surfaces on the stomach and duodenum into apposition. The apposed surfaces are sutured together using interrupted 3-0 silk Lembert seromuscular sutures. Using electrocautery, an inverted U-shaped incision is made beginning on the gastric side just distal to the traction suture, traveling longitudinally through the pylorus, then distally to a point just proximal to the traction suture. If the ulcer is present on the anterior surface of the duodenal bulb, it is excised. The posterior inner layer between the stomach and the duodenum then is sutured closed with a continuous over-and-over 3-0 Vicryl, chromic catgut suture, or DDS. This closure is begun at the superior edge, carried caudally, and then converted into a Connell inverting technique as the suture is brought around the inferior edge to begin closing the anterior portion of the inner layer. The anterior outer layer then is closed using interrupted 3-0 seromuscular inverting sutures (Lembert) sutures. Some surgeons use 3-0 Maxon or PDS suture material for single-layer continuous closure, as additional insurance against a suture line leak.

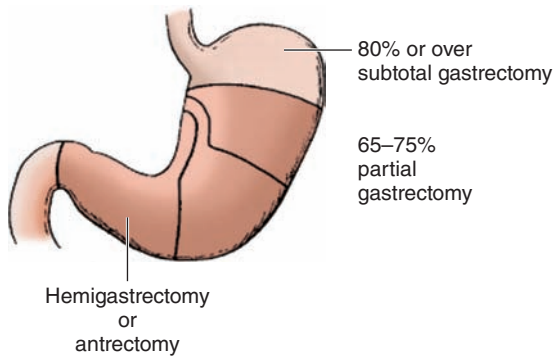
## GASTRIC RESECTIONS

The common indications for gastric resections include peptic ulcer disease and tumors of the stomach. Safe performance of gastric resection requires an understanding of the following: (1) the physiology of vagal innervation and gastric emptying; (2) the surface and vascular anatomy of the stomach; (3) the principles of reconstruction following resection, specifically the Billroth I (B-I) gastroduodenostomy, the Billroth II (B-II) gastrojejunostomy, and the Roux-en-Y configuration; (4) the principles of surgical stapling techniques as well as hand-sewn suturing techniques; and (5) the specific early and late postoperative complications that arise from different gastric resections and different forms of reconstruction. Degrees of resection are correlated to the surface anatomy, as shown in Fig. 26-14. This discussion is divided into three sections. The first section describes techniques for performing wedge resections and closure of gastric wall for ulcers, polyps, or tumors derived from neuroendocrine elements or stromal tissue. Carcinomas are not amenable to wedge resection and should be removed, for cure or palliation, by formal regional resection. The second section describes techniques for distal gastric resection, focusing on antrectomy or hemigastrectomy (with or without vagotomy) for peptic ulcer disease and when the major decision involves the choice of B-I or B-II reconstruction. The third section describes techniques used



**FIGURE 26-13** Finney U-shaped pyloroplasty. **A.** The distal stomach and proximal duodenum are aligned with traction strands and their adjacent walls approximated with a Cushing suture; the inverted U-shaped incision into the lumens of the stomach and duodenum is indicated. **B.** Suture of the posterior septum of the stomach and duodenum. **C.** The first anterior tier of sutures (Connell) is placed. **D.** The operation is completed with a reinforcing tier of Cushing sutures. (Redrawn, with permission, from Zuidema GD, ed. *Shackelford's Surgery of the Alimentary Tract*. Vol. II, 4th ed. Philadelphia, PA: WB Saunders; 1996.)





**FIGURE 26-14** Amount of stomach removed in antrectomy or hemigastrectomy: 60–75% for partial gastrectomy and 80% or over for subtotal gastrectomy. Note that most of the lesser curvature of the stomach is excised in all these resections.

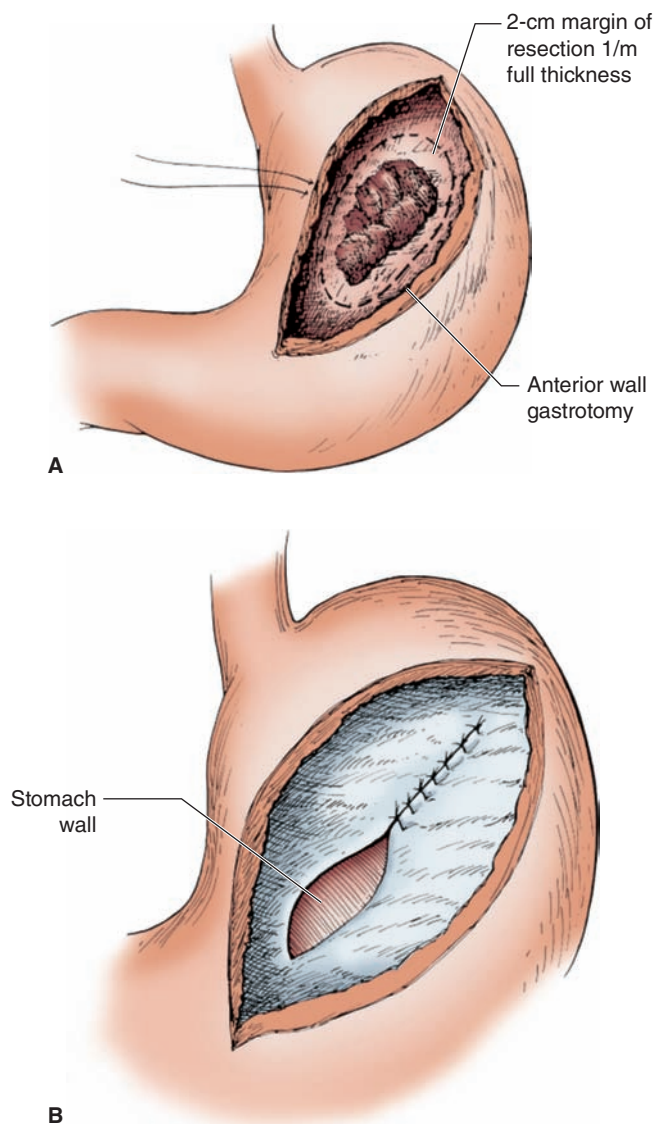
in management of gastric carcinoma, focusing on proximal, subtotal, or total resection, and the techniques of regional node dissection.

## Wedge Resection of the Stomach

Exposure is gained through an upper midline incision, carried from the xiphoid to the umbilicus. A Bookwalter or other self-retaining mechanical retractor is highly desirable, especially for lesions located on the lesser curvature or the proximal stomach. The technique of wedge resection depends on the location of the lesion. When a gastric tumor, such as a carcinoid or gastrointestinal stromal tumor (GIST), is located on the greater curvature of the stomach, it is important to note the proximity to the pylorus or gastroesophageal junction. Wedge resection may not be possible if the lesion lies too close (within 2 cm) to these borders, because the closure might narrow the lumen and cause partial obstruction to the flow of chyme. Formal resection may then be necessary. If proximity to these borders is not a problem, omental adhesions to the tumor are left in contact with the lesion. Farther away from the tumor, the portion of the omentum that is adherent is divided between clamps and will come with the specimen. Branches of the gastroepiploic arteries that supply the gastric wall adjacent to the tumor are ligated in continuity with 3-0 silk ligatures and divided. The gastroepiploic artery need not be divided, unless it is adherent to the surface of the tumor. At a distance of 2 cm from the base of the tumor, the serosa of the gastric wall is scored using cautery, inscribing a circle. The cautery then is used to deepen the incision through the muscularis. As the muscularis is divided, submucosal bleeders will pop through, requiring precise cauterization to secure hemostasis. When the tumor and the surrounding gastric wall have been excised, the gastrotomy is closed longitudinally in two layers. The inner layer is a full-thickness hemostatic layer sewn continuously using 3-0 chromic or Vicryl suture and the outer layer used interrupted seromuscular 3-0 silk Lembert sutures. An omental patch is

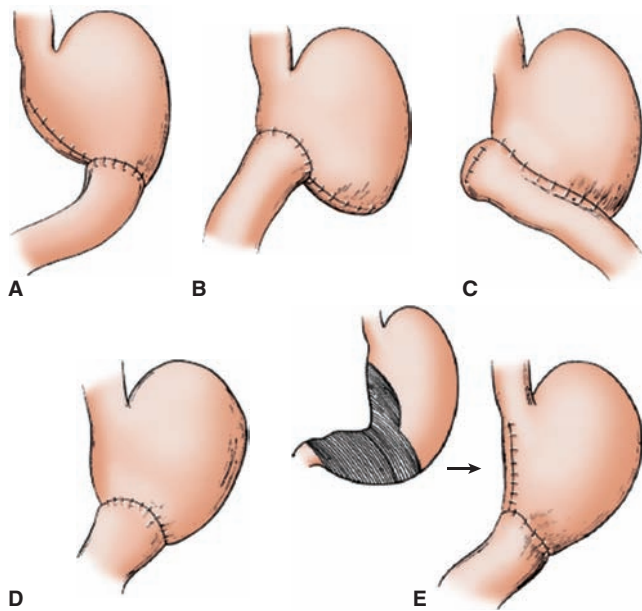
not necessary, unless there are specific concerns about the blood supply to the closure. When situated favorably, such lesions are also amenable to laparoscopic resection<sup>41–43</sup> and to combined endoscopic-laparoscopic approaches involving intraluminal resections.<sup>44,45</sup> As long as the lumen is not compromised, stapled or open excision is possible.

When tumors are located on the lesser curvature, or it is necessary to perform a gastrotomy in order to stop ongoing bleeding from a gastric ulcer, the excision can be performed from the mucosal side of the lesion (Fig. 26-15). Once the inside borders of the lesion have been identified, it is important to obtain optimal exposure of the lesion from the serosal aspect. It may be necessary to sacrifice one or both nerves of Latarjet or the



**FIGURE 26-15** Small tumors or polyps not amenable to endoscopic polypectomy can be excised with surrounding wedge of normal gastric wall. **A.** A 2-cm margin is advisable. **B.** The gastrotomy can be closed in one or two layers, using 2-0 nonabsorbable sutures sewn in interrupted fashion.





**FIGURE 26-16** Billroth I operations. **A.** Billroth I. **B.** Horsley. **C.** von Haberer-Finney. **D.** von Haberer. **E.** Shoemaker.

left or right gastric arteries, and this determination can only be made from the outside of the stomach. A stapled option also exists if the lesion can be excised without narrowing the lumen. If the lesion is located on the lesser curvature and cannot be removed without sacrifice of both nerves of Latarjet, a pyloroplasty should be performed. In such cases, our preference is that the resection is extended to include the distal stomach and a B-I or B-II reconstruction (Fig. 26-16). One variation on this latter approach for high-lying bleeding or perforated gastric ulcers is Pauchet's operation, a modification of an operation described by Shoemaker. This procedure involves removal of the antrum and a tongue of the corpus that extends upward to include the ulcer (Fig. 26-16E).<sup>46</sup>

## Distal Gastric Resections and Reconstruction

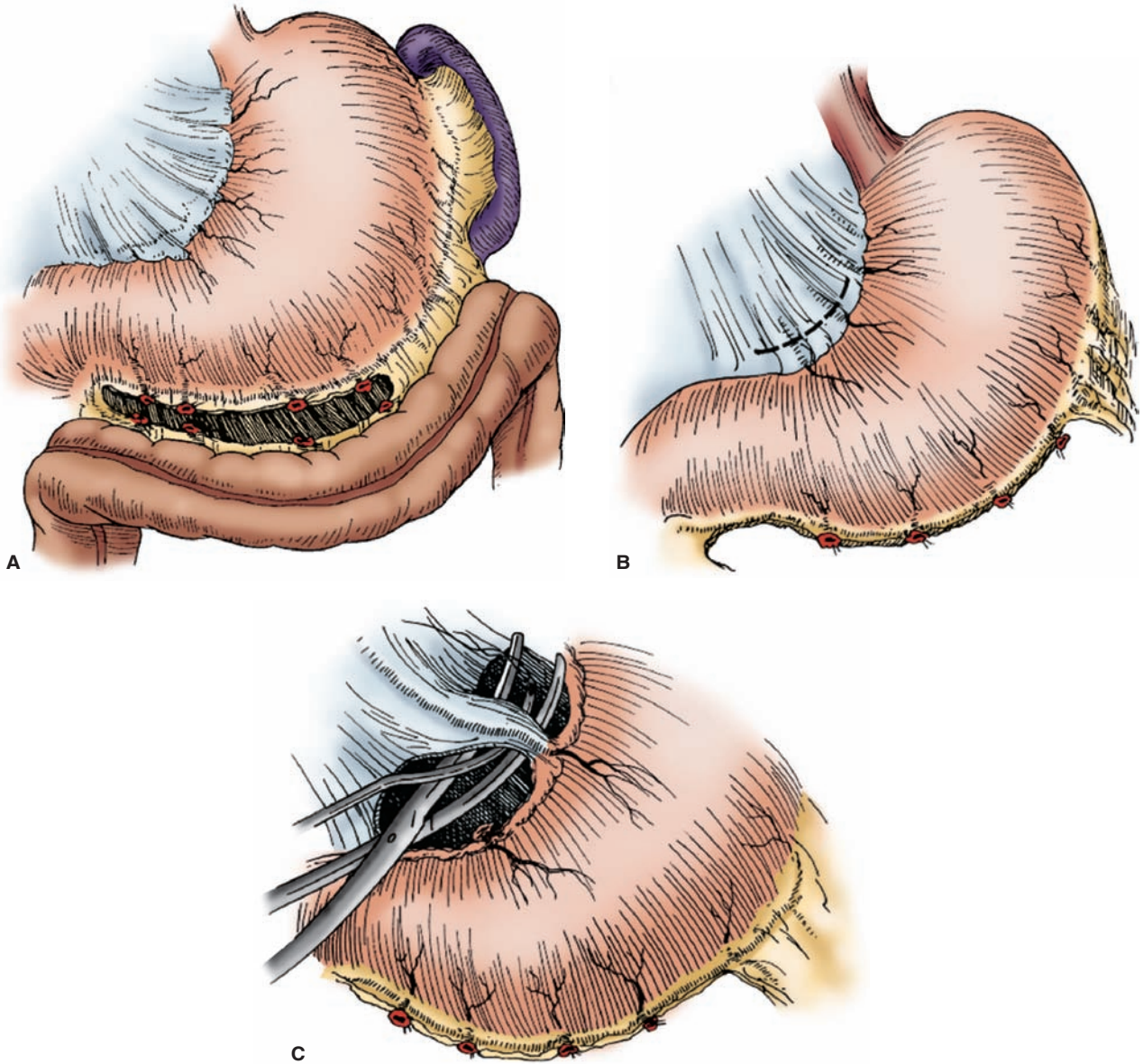
### VAGOTOMY AND ANTRECTOMY

An antrectomy for duodenal or pyloric channel ulcer removes about 35% of the distal stomach and must include the entire non-acid-secreting portion. The incision is made in the upper midline and a Bookwalter or other self-retaining mechanical retractor is helpful. An NG tube is positioned under the surgeon's guidance, with its tip in the midportion of the stomach. TV is performed first, as described earlier. The incisura is a reasonable landmark for the proximal margin of resection on the lesser curvature, while the terminal portions of the right gastroepiploic artery indicate the margin on the greater curvature.

The distal stomach is mobilized in the following fashion: first, the lesser sac is entered by incising the gastrocolic ligament.

These attachments are sometimes avascular but usually are divided between clamps and ligated with 3-0 silk ligatures. The stomach may thus be lifted upward, revealing the posterior gastric wall. Congenital adhesions from the posterior wall and pancreas capsule are divided sharply. The dissection is carried distally along the greater curvature (Fig. 26-17), dividing the small branches of the gastroepiploic artery to the gastric wall. The dissection reaches the main right gastroepiploic artery, which sometimes has to be divided between Kelly clamps and ligated with 2-0 silk ligatures. When possible, the dissection should be carried between the gastric wall and artery, thereby preserving the main gastroepiploic artery as additional collateral blood supply to the suture lines and coming anastomosis. When the dissection reaches the pylorus, small bleeders should be divided between fine hemostats and ligated with fine silk ligatures. The dissection should be meticulous and gentle, because pancreatic tissue lurks in this area and inflammation can be activated in this dissection. The dissection should be carried about 1 cm past the pylorus if a B-I reconstruction is anticipated. If B-II is anticipated, the dissection need only be carried far enough to comfortably place the transverse linear stapler past the pylorus or to oversee the duodenum by a hand-sewn technique.

The assistant's left hand is used to lift the distal stomach forward and inferiorly. The more flimsy tissues of the lesser omentum are divided along the lesser curvature, using electrocautery. Starting at the incisura and working toward the pylorus, the tissues of substance are divided between clamps and ligated with 3-0 silk ligatures. This dissection generally will include the descending branch of the left gastric artery. When the right gastric artery is reached, it is divided and ligated with 2-0 silk ligatures. At this point (Fig. 26-18), we prefer to divide the stomach. This is accomplished with a 90-mm GIA stapler or the gastric TA-90. If the latter stapler is used, the stomach distal to the staple line is occluded with a crushing intestinal clamp and the gastric wall is divided. The clamp is then used as a handle for manipulating the distal stomach. The final portion of the dissection involves gentle dissection of the posterior duodenal wall from the pancreas. Because this dissection may involve separation of pancreas elements from the posterior duodenal wall, cautery is used minimally or not at all and tissues are separated gently with fine hemostats and ligated with 4-0 silk. If a B-I anastomosis is anticipated, the duodenum is divided using the electrocautery, just distal to the pyloric ring. If a B-II anastomosis is anticipated, the transverse TA-30 stapler is placed flush with the pyloric ring. After firing the stapler, a knife is used to sever the pylorus from the staple line. The specimen then is removed to a sterile table. The staple line can be inverted with 3-0 silk Lambert sutures or covered with an omental patch, if there is a concern about vascular supply or tension in the staple line. The specimen then can be opened and turned inside out to reveal the gastric mucosa. The proximal border of the resection should contain transverse and obliquely oriented rugae characteristic of the acid-secreting gastric corpus and distinguishable from the longitudinally oriented antral folds. This maneuver verifies complete removal of the antrum.

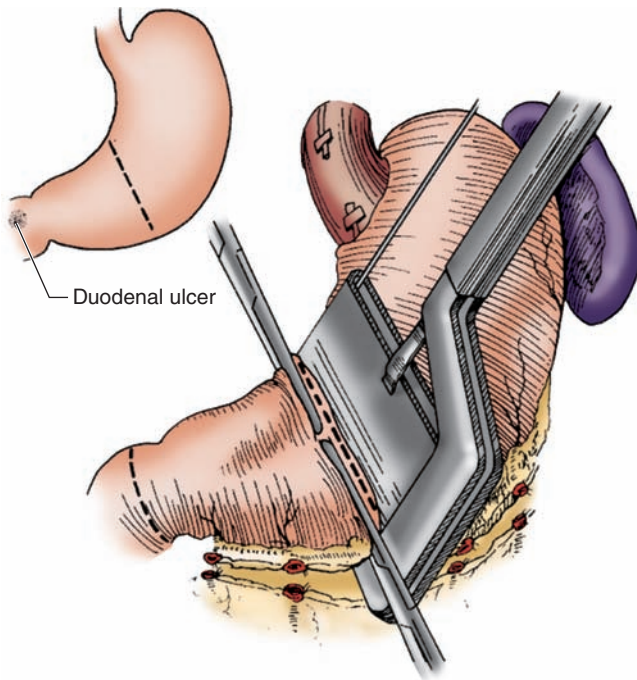


**FIGURE 26-17** Billroth I operation. **A.** Use of the ligate-divide-stapler, LDS II. This instrument, employing a disposable cassette, applies two stainless steel clips and cuts between, thus reducing operating time and effort significantly. **B.** Extent of dissection of lesser curvature. **C.** Division of vessels entering the lesser curvature in much the same way as when performing proximal gastric vagotomy.

**Billroth-I Reconstruction.** When distal gastrectomy is performed for type I gastric ulcer, B-I anastomosis is preferable. A B-I anastomosis can be used safely for duodenal or pyloric channel ulcer, if scarring of the duodenal bulb and pylorus are minimal. If this form of reconstruction is planned, a Kocher maneuver should be performed prior to distal gastrectomy. This will help to minimize tension on the anastomosis. As shown in Fig. 26-19, the lower portion of the gastric staple line is removed by excision of gastric wall just posterior to the staple line. The length of the staple line to be removed is the width of the duodenal stump. The gastroduodenostomy is

performed in two layers (Fig. 26-20). The posterior layer of interrupted 3-0 silk Lembert seromuscular sutures is placed first. The inner 3-0 Vicryl sutures are placed next to each other, sewn away from each other in an over-and-over fashion until the sutures are brought around the edges to the anterior aspect. Connell sutures are used to invert the inner anterior layer. The anterior outer layer is closed with interrupted 3-0 silk Lambert sutures. The junction of the sewn anastomosis and superior portion of the gastric staple line has been called the “angle of sorrow” because of the complication of leakage where these suture/staple lines meet. A number of authors recommend





**FIGURE 26-18** Billroth I operation. Division of stomach beyond the incisura. The gastric 90 stapler facilitates this maneuver. Note the truncal vagotomy has already been performed. (Redrawn, with permission, from Zinner MJ. *Atlas of Gastric Surgery*. New York, NY: Churchill Livingstone; 1992. After Gloege.)

inversion of the upper staple line by 3-0 silk Lembert sutures and a special covering suture for this junction. A second strategy is to cover this area with a tongue of omentum.

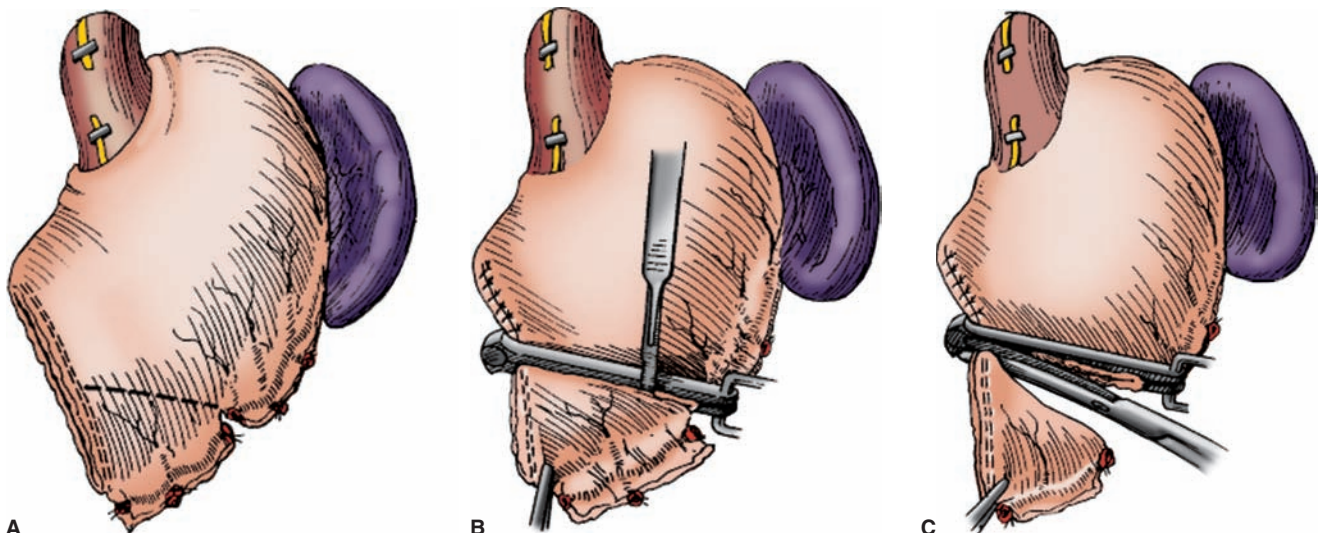
A B-I anastomosis also may be performed using mechanical stapling techniques. As shown in Fig. 26-21, the duodenum

is transected just distal to the pylorus with the knife and a purse-string suture is positioned circumferentially around its edge. The anvil of the circular stapler, usually a size 25 mm, is secured in the duodenal stump by the purse string. The circular stapler is inserted through an anterior gastrotomy and fired through the posterior wall of the stomach (Fig. 26-22). It is important that the margin of the stapled suture line be placed 3 cm proximal to the stapled gastric closure, to provide maximum blood supply to both staple lines. The anterior gastrotomy then is closed with a TA-55 stapler or sutured closed in two layers.

**Billroth-II Reconstruction.** When scarring or undue tension precludes B-I anastomosis following distal gastrectomy, a B-II gastrojejunostomy is indicated. Before describing our technique, it is worth pointing out the decisions that one will make in performing this reconstruction.

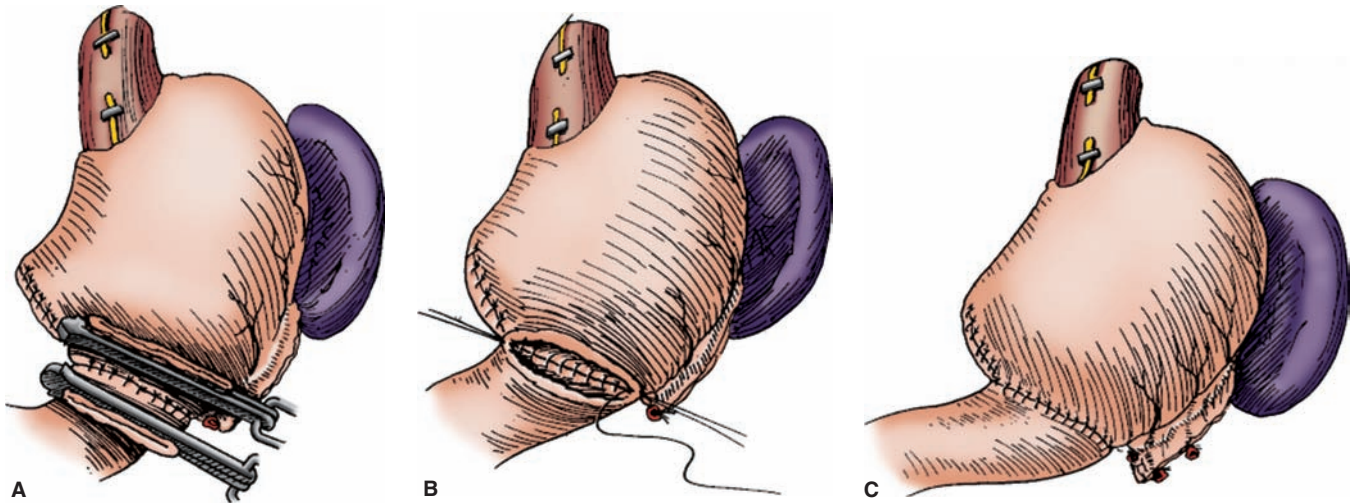
**Closure of the Duodenal Stump.** The first set of decisions focus on the technique used for closure of the duodenal stump. Careful attention should be given to mobilizing the duodenal stump and obtaining a secure tension-free closure. If the duodenum is relatively free of scar or inflammation, this presents no problem and the TA-55 or TA-60 stapler may be used for closure as described previously. If heavily scarred, dissection of the duodenum and performance of the antrectomy may be abandoned in favor of a safer vagotomy and gastroenterostomy.

If one is committed to the antrectomy and scarring prevents mobilization of the pylorus and duodenal bulb, one may rarely find a need to perform a Bancroft procedure, in which the most distal portion of the pyloric channel and antrum are left in situ after resection of the more proximal antrum (Fig. 26-23). The mucosa of the retained segment is stripped,<sup>47</sup> removing all gastrin-secreting tissue that could

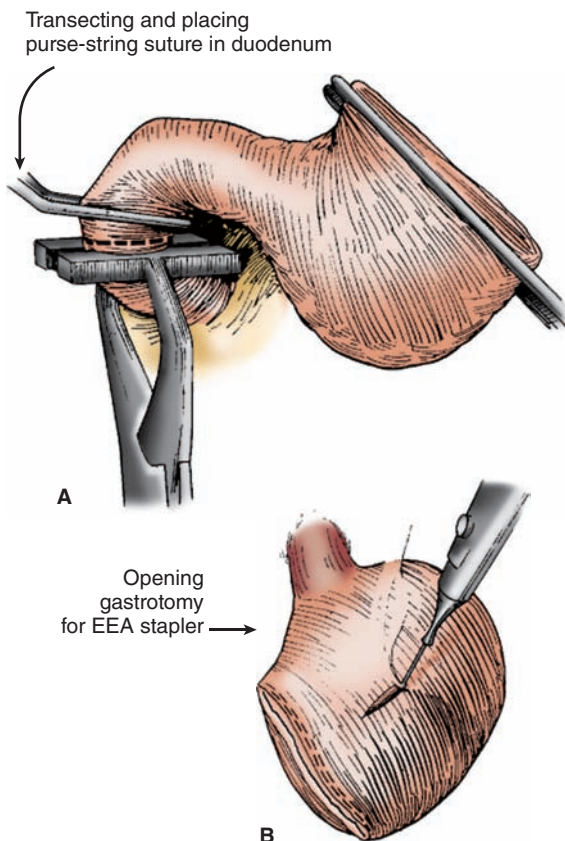


**FIGURE 26-19** Billroth I operation. Division of the lower portion of the suture line. (Redrawn, with permission, from Zinner MJ. *Atlas of Gastric Surgery*. New York, NY: Churchill Livingstone; 1992. After Gloege.)





**FIGURE 26-20** Billroth I operation. The construction of the gastrodudenostomy is performed end to end in two layers. (Redrawn, with permission, from Zinner MJ. *Atlas of Gastric Surgery*. New York, NY: Churchill Livingstone; 1992. After Gloege.)



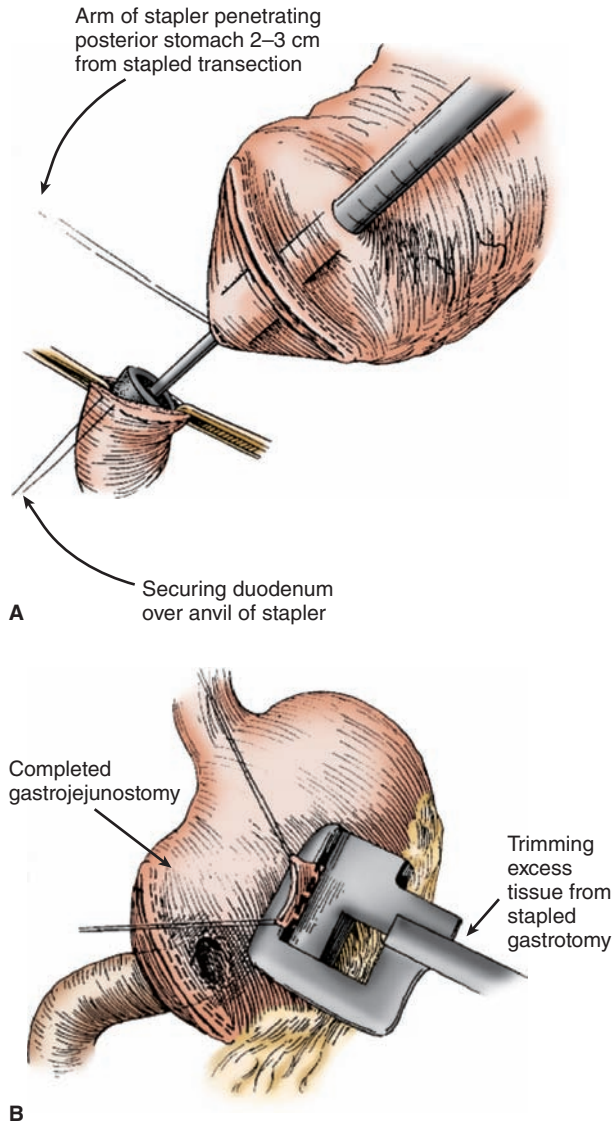
**FIGURE 26-21** **A.** A Dennis clamp can be placed across the proximal duodenum, and the purse-string device can be placed at the selected site of duodenal division. **B.** A gastrotomy is made with the cautery on the anterior surface of the stomach, carefully avoiding large vascular arcades. This should be done at least 3 cm proximal to the row of staples. The gastrotomy should be large enough to accommodate the end-to-end stapling device easily. (Redrawn, with permission, from Siegler HF. Gastric resection: Billroth I. In: Sabiston DC, Jr, ed. *Atlas of General Surgery*. Philadelphia, PA: WB Saunders; 1994. After R. Gordon.)

cause a retained antrum syndrome. In the classic approach for this procedure, the greater and lesser curvatures are mobilized without dissecting too far into the tissues surrounding the pylorus. About 7–8 cm from the pylorus, the seromuscular coat of the antrum is incised circumferentially down to the level of the submucosa. Using sharp dissection, the muscle coat is separated from underlying mucosa. This dissection can be facilitated by submucosal injection of 1:100,000 epinephrine solution, as has been described for the mucosal proctectomy in ileal pouch–anal anastomosis procedures.<sup>48</sup> When the pyloric channel opening is reached, a fine purse-string absorbable suture (3-0 chromic catgut or Vicryl) picks up small bites of submucosa at the pyloric ring. Transfixion and ligation of the mucosa is tempting, but it should be avoided as this would lead to mucosal ischemia and subsequent perforation. A small margin of mucosa is left to be invaginated into the pylorus as the purse string is gently closed and tied. The proximal margins of the seromuscular cuff are excised, leaving just enough to close over the purse string. Omentum is used to cover this closure, if possible.

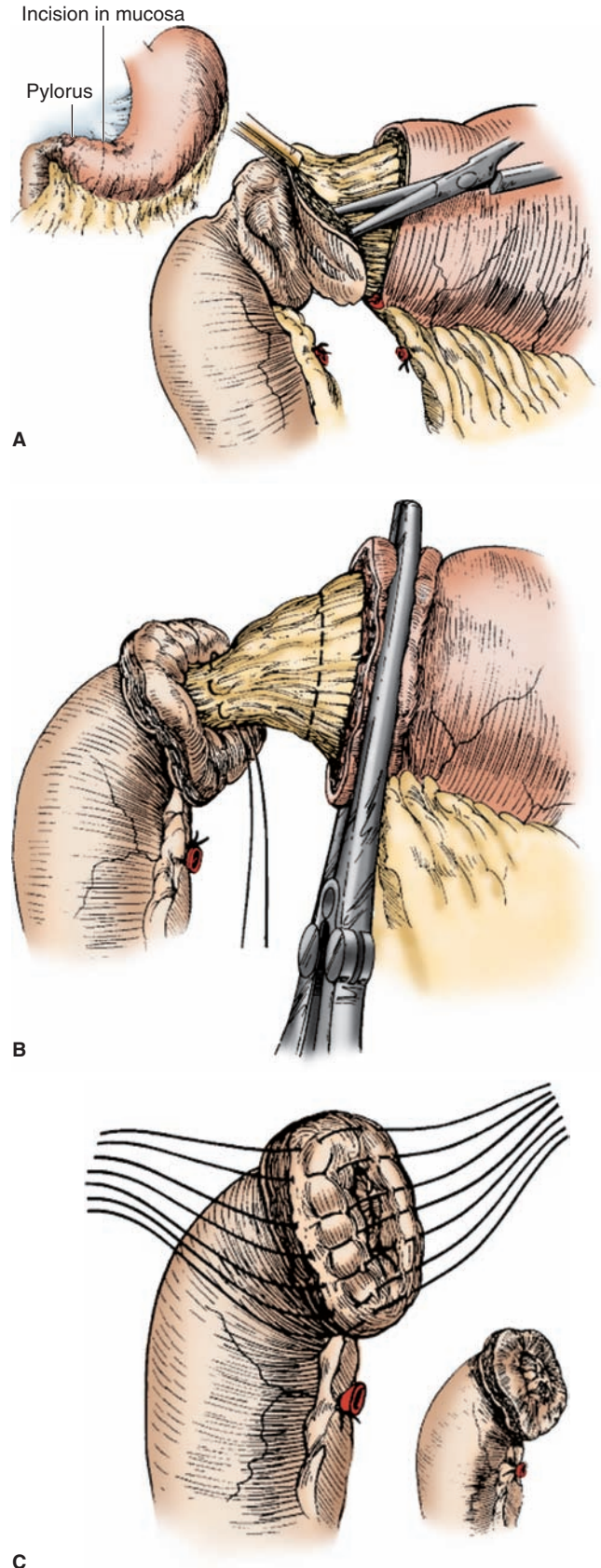
One other important circumstance to be prepared for is the closure of the duodenum distal to a posteriorly perforated or deeply penetrating ulcer. In this setting, the ulcer crater is left in situ (Fig. 26-24). In other settings, the anterior wall of the duodenum can be sutured to the ulcer base, with care being taken to suture-ligate any exposed vessels. The suture line can be protected by a vascularized tongue of omentum.

#### **Position of the Jejunal Loop: Antecolic or Retrocolic.**

The second decision in performing a B-II reconstruction is whether to bring the loop of jejunum behind (retro) or in front of (ante) the transverse colon. In performing the gastrectomy for benign disease, there is no clear evidence that this makes any difference and we prefer the retrocolic position. For malignant disease, it has generally been held that the retrocolic position may be predisposed to

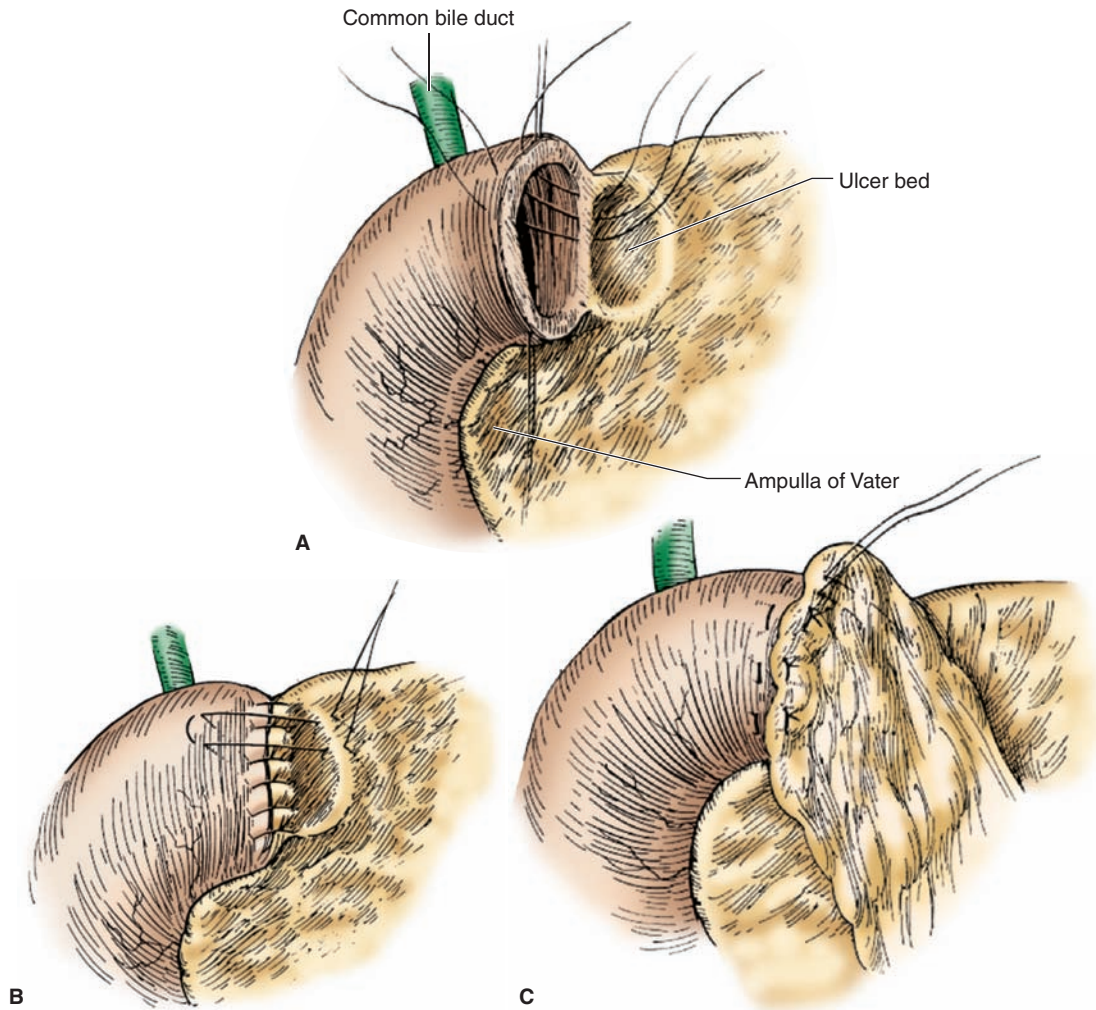


**FIGURE 26-22** **A.** The gastrotomy edges should be grasped with two Babcock clamps, and the end-to-end stapling device, minus the anvil, should be passed into the lumen of the stomach. The center rod should be gently pressed against the posterior wall of the stomach approximately 4 cm from the gastric line, and cautery should be used to permit passage of the rod through the posterior wall of the stomach. A purse-string suture will ensure that the stomach does not tear at the site of center rod penetration. The selected anvil size should be applied, and the open end of the duodenum should be grasped with Allis clamps. The duodenal wall should be gently pulled over the anvil, and the purse-string suture should be snugly tied around the center rod. **B.** The cartridge and the anvil should then be approximated, being certain that no extraneous tissues are caught between the anvil and the circular cartridge. The instrument should be fired, and the anastomosis should then be carefully observed by direct visualization to ensure that hemostasis is adequate. The surgeon should then remove the anvil and check the circular tissue from both the duodenum and the stomach to be certain that the tissue doughnuts are intact. If the doughnuts are defective, external Lambert sutures will need to be applied to secure a complete anastomosis. The gastrotomy is closed by grasping each end with Allis clamps and incorporating the entire thickness of the stomach wall through the jaws of the 55-mm stapler. (Redrawn, with permission, from Siegler HF. Gastric resection: Billroth I. In: Sabiston DC, Jr, ed. *Atlas of General Surgery*. Philadelphia, PA: WB Saunders; 1994. After R. Gordon.)



**FIGURE 26-23** Bancroft procedure. (Redrawn, with permission, from Kirkham JS. Partial and total gastrectomy. In: Schwartz SI, Ellis H, eds. *Maingot's Abdominal Operations*. Norwalk, CT: Appleton Century-Crofts; 1985.)





**FIGURE 26-24** Closure of a chronic, ulcer-scarred duodenal stump. (Redrawn, with permission, from Zinner MJ. *Atlas of Gastric Surgery*. New York, NY: Churchill Livingstone; 1992. After Gloege.)

obstruction owing to enlargement of lymph nodes or serosal implants in the transverse mesocolon. Whether or not this predisposition exists, positioning the jejunal limb in front of the colon requires a somewhat longer mesentery. As long as the anastomosis will not be under tension, the antecolic position will permit emptying as effective as that through a retrocolic anastomosis. If a retrocolic position is chosen, the window in the transverse mesocolon should be wide enough to permit both the afferent and efferent limbs of the jejunum to slide comfortably through. When this window is closed following construction of the anastomosis, it is preferable to tack the mesentery above, on the gastric side, rather than on the jejunal side. This will prevent kinking and obstruction of the jejunal limbs and positions the anastomosis below the mesentery.

**Length of the Afferent Limb.** The third decision is the choice of the segment of jejunum used for the anastomosis. In general, the segment should be as close to the ligament of Treitz as possible and still reach the stomach

without tension. This generally leaves 10–20 cm of the proximal jejunum as the afferent limb. The shorter this length, the less likely the possibility of an afferent limb syndrome developing. The incidence of other complications such as alkaline reflux gastritis, dumping, or postvagotomy diarrhea should not be influenced by the length of the afferent limb.

**Anastomosis: Site on the Gastric Wall and Technique.** Schematically illustrated in Fig. 26-25 are a number of described variations on the B-II reconstruction. We describe here one hand-sewn and one stapled technique for anastomosis. As shown in Fig. 26-26, a portion of the gastric staple line is excised with electrocautery, taking a small wedge of stomach behind the staple line. The superior portion of the staple line can be reinforced with 3-0 silk Lembert sutures at this time or can be reinforced later by tacking the afferent limb of jejunum, just beyond the anastomosis, to the gastric wall. The proximal jejunal limb is brought, untwisted, through a window in the transverse mesocolon (Fig. 26-27). Traction seromuscular



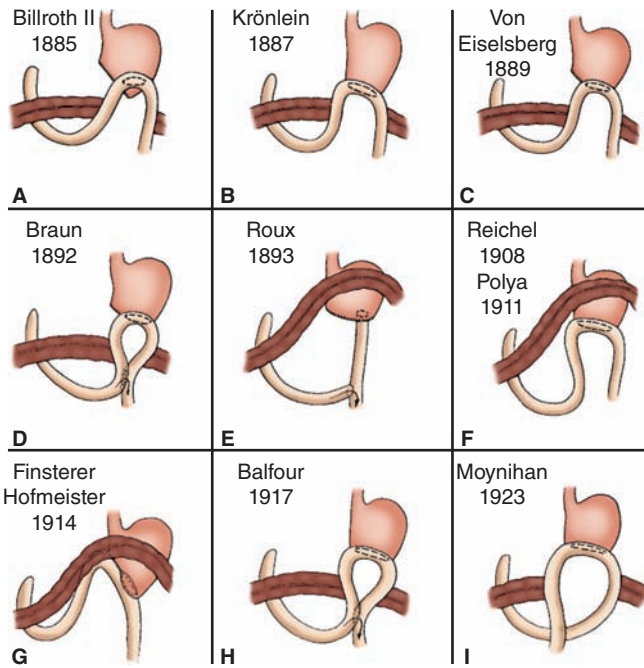


FIGURE 26-25 Billroth II operation and some of its modifications.

sutures (2-0 or 3-0 silk) are placed at both corners of the anastomosis. The gastrojejunal anastomosis is performed in two layers (Fig. 26-28), between the most caudal part of the stomach and the jejunal limb. The outer layer is composed of 3-0 silk Lembert seromuscular sutures. The inner layer is performed in the posterior row by running two 3-0 Vicryl sutures in opposite

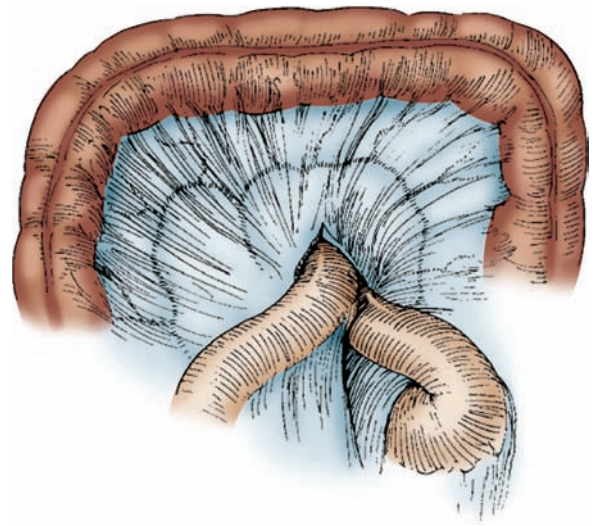


FIGURE 26-27 Billroth II operation. The jejunal segment, located 10–20 cm beyond the ligament of Treitz, is brought through a window in the retrocolic mesentery. (Redrawn, with permission, from Zinner MJ. *Atlas of Gastric Surgery*. New York, NY: Churchill Livingstone; 1992. After Gloege.)

directions around the corners and then in Connell fashion for the anterior row. Placement of the anastomosis on the posterior gastric wall, about 2–3 cm from the gastric staple line, also will provide a suitably dependent position for drainage of gastric contents. The window in the transverse mesocolon is closed, as illustrated in Fig. 26-29.

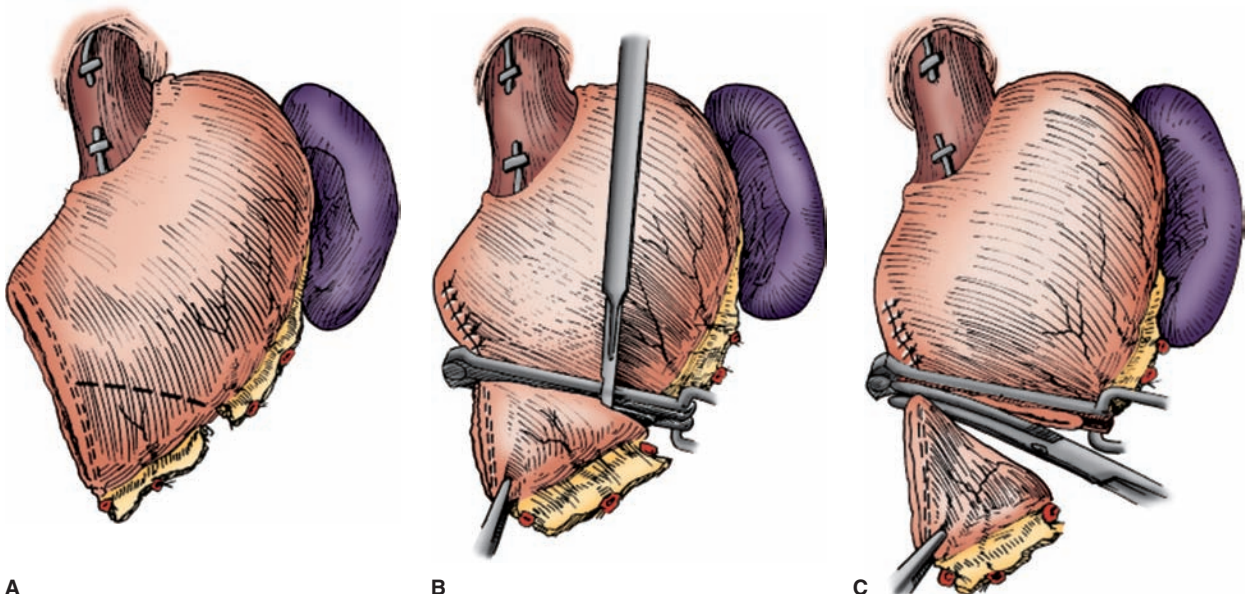
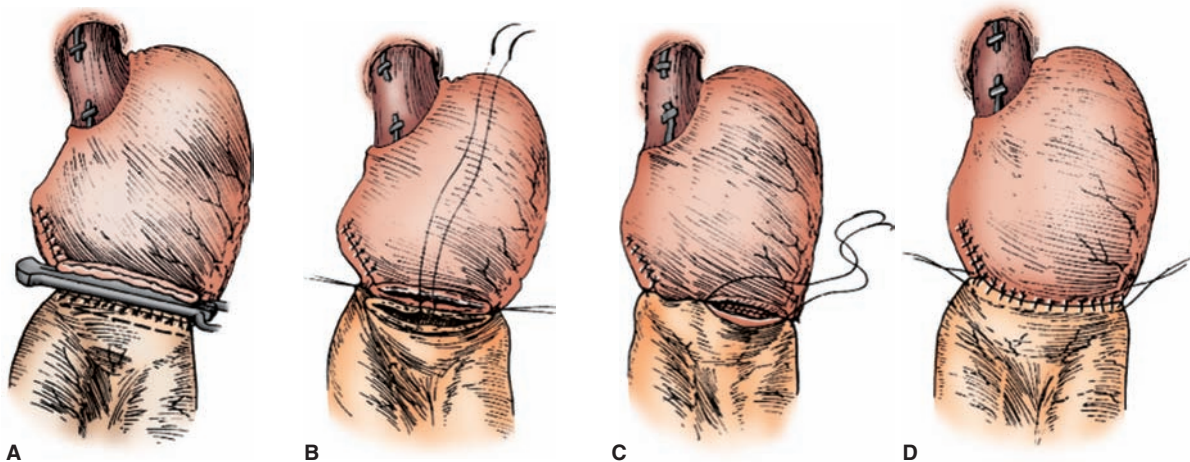
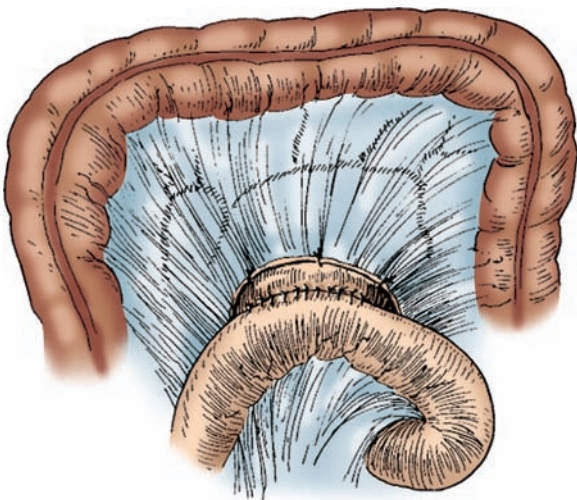


FIGURE 26-26 Billroth II operation. The antrum is resected as in a Billroth I operation. The distal portion of the resection line is excised. (Redrawn, with permission, from Zinner MJ. *Atlas of Gastric Surgery*. New York, NY: Churchill Livingstone; 1992. After Gloege.)



**FIGURE 26-28** Billroth II operation. The gastrojejunal anastomosis is constructed in two layers, as described in the text. (Redrawn, with permission, from Zinner MJ. *Atlas of Gastric Surgery*. New York, NY: Churchill Livingstone; 1992. After Gloege.)

Illustrated in Figs. 26-30 and 26-31 is the technique for stapled gastroenterostomy. As before, the jejunal limb is placed in the retrocolic position. Traction sutures are placed on the gastric wall posterior to the anastomosis, bringing the jejunal limb into apposition. The 55-mm GIA stapler is fired after its two limbs are placed through a small gastrotomy and small enterotomy, respectively. The open end of the anastomosis is then closed with a TA-55 stapler. It should be noted that these staple lines, especially from the TA-55, are difficult to reinforce without undue tension. The blood supply of the gastric and intestinal walls is ample, and reinforcement with Lembert sutures generally is not necessary.



**FIGURE 26-29** Billroth II operation. The retrocolic window in the mesentery is closed in order to avoid herniation of other viscera. The mesentery is linked to gastric wall, positioning the anastomosis below the closure. (Redrawn, with permission, from Zinner MJ. *Atlas of Gastric Surgery*. New York, NY: Churchill Livingstone; 1992. After Gloege.)

## Subtotal and Total Gastric Resections

The main indications for subtotal (70–80%) gastric resection are carcinoma of the antrum or pylorus or primary gastric lymphoma. However, in cases of ulcers that lie very proximal on the lesser curvature, the proximity to the gastroesophageal junction prevents excision without significant narrowing of the gastric inlet. Similarly, the main indication for total gastric resection is a bulky carcinoma of the body or distal fundus, and rarely, otherwise unmanageable symptoms of an unresectable gastrinoma. Indications for near-total (>90%) gastric resection include the uncommon settings of the Roux stasis syndrome and gastroparesis unresponsive to medical management, as well as carcinoma or lymphoma of the body of the stomach. The approaches for subtotal and near-total gastrectomy are discussed here only briefly, focusing on issues of exposure and techniques for resection of the stomach itself and reconstruction. The principles of resection for gastric carcinoma will be presented subsequently in conjunction with the discussion of radical total gastrectomy for carcinoma.

### SUBTOTAL AND NEAR-TOTAL GASTRIC RESECTIONS

In principle, a subtotal gastrectomy is simply an extended antrectomy or hemigastrectomy. A few technical issues are worth noting. First, the exposure provided by midline incision is usually not as adequate as that provided by a chevron incision. Second, the left gastric artery always is ligated and divided in this dissection, and, once the level of gastric transection has been determined, the branches of the left gastroepiploic artery and short gastric arteries are ligated in continuity and divided up to this predetermined level. Third, in opting for a near-total gastric resection, a 1- to



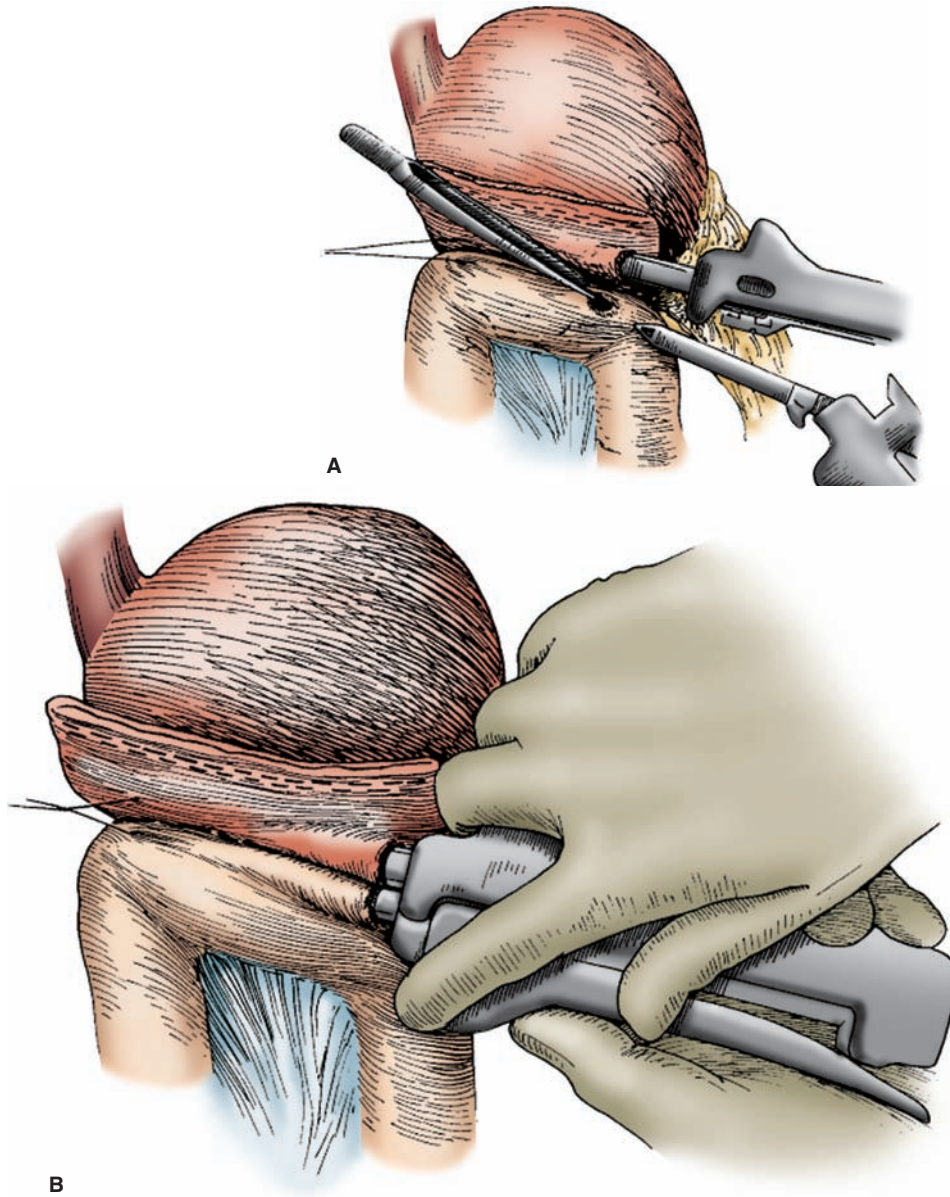


FIGURE 26-30 Stapling technique for Billroth II gastrojejunostomy.

2-cm cuff of gastric wall is left behind and is the margin for the anastomosis. For this operation, it is desirable to preserve the uppermost one or two short gastric vessels, in order to ensure the adequacy of the blood supply for the gastric side of the anastomosis.

One final issue is that a greater extent of lymph node dissection has shown in some series, both Japanese and Western series, improvement in survival for gastric cancer after resection<sup>49,50</sup> although with increased morbidity in some<sup>51</sup> but not necessarily in all<sup>52</sup> centers. Extended lymphadenectomy (D2 resection) involves dissection and removal of the perigastric lymph nodes, as well as those of the celiac axis,

and the hepatoduodenal ligament.<sup>53,54</sup> Skeletonization of the celiac artery and its branches (left gastric artery, common hepatic artery, and splenic artery) is required to achieve adequate lymphadenectomy if it is desired. However, further studies are needed before it can be routinely recommended outside of highly specialized centers with surgeons who have specific expertise in this dissection.<sup>52</sup> Finally, although it is often possible to reconstruct with a standard gastrojejunostomy, we prefer a Roux-en-Y reconstruction because this minimizes tension on the suture line and theoretically reduces the risk of anastomotic obstruction by persistence or recurrence of tumor.



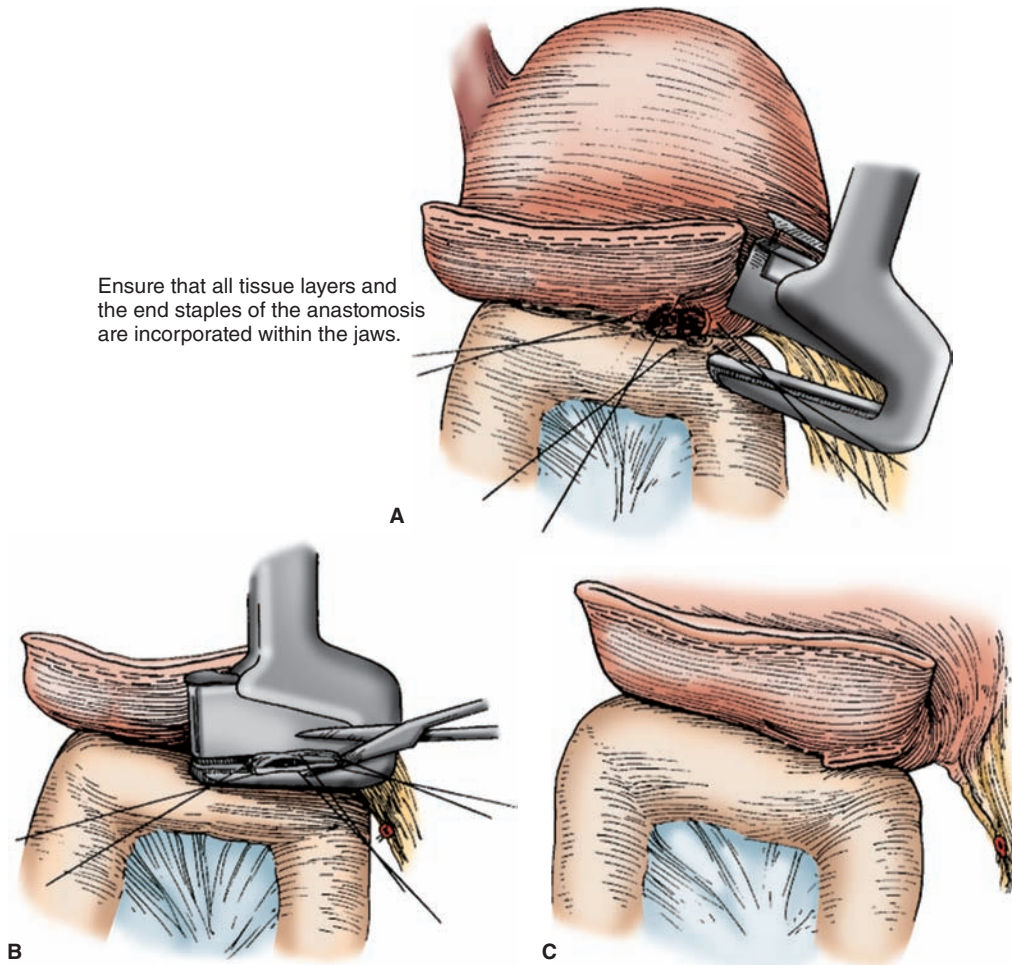


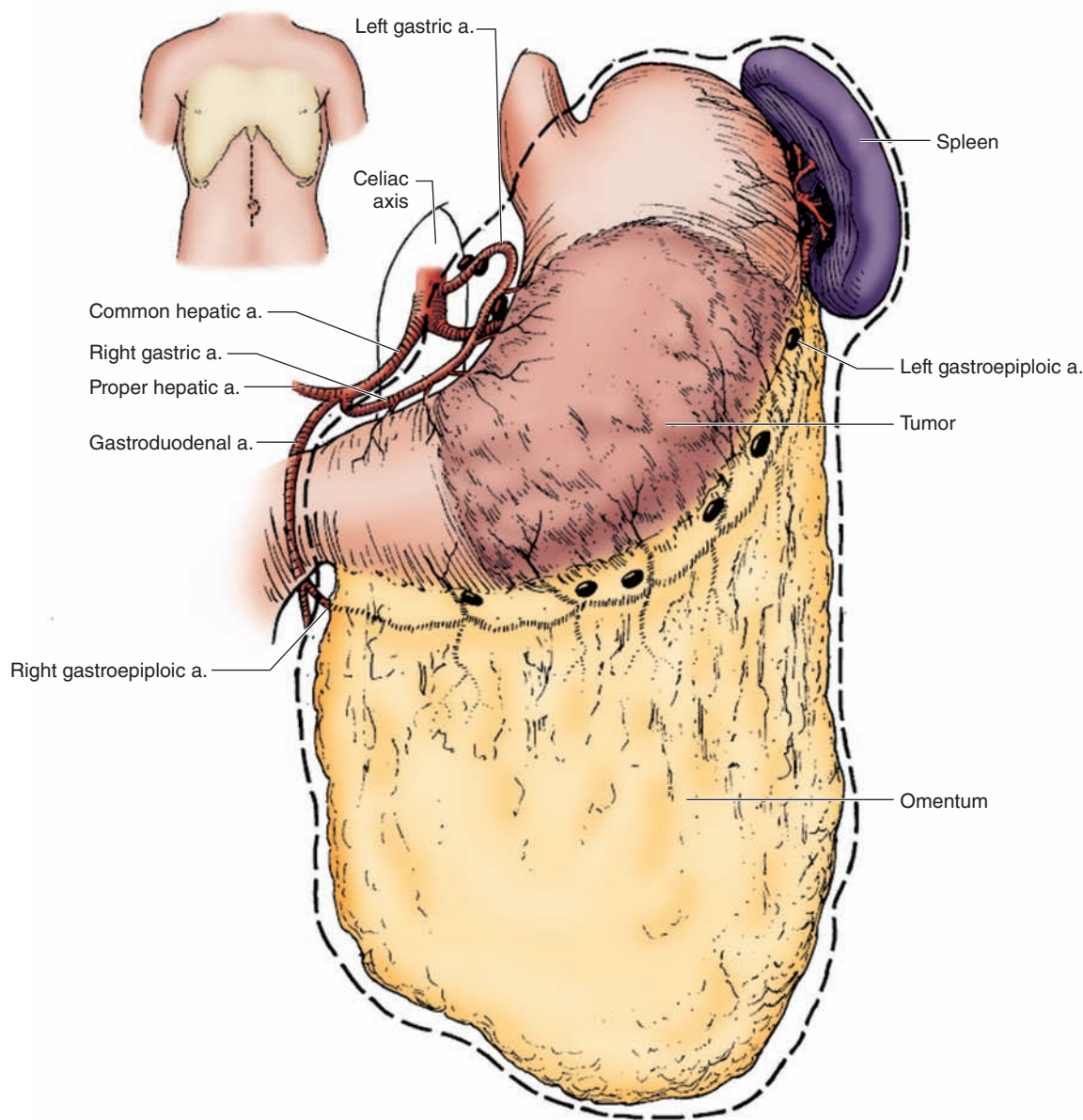
FIGURE 26-31 A. Billroth II operation. B and C. The transverse stapler is used to close the common opening over the gastrojejunal anastomosis.

### TOTAL GASTRECTOMY FOR CARCINOMA

The goals of total gastrectomy for carcinoma are (1) clearing of margins on both esophageal and duodenal sides; (2) removal of local and regional lymph node-bearing tissues, including those surrounding the right and left gastric arteries, right gastroepiploic artery, and short gastric arteries; (3) removal of the omentum en bloc with the stomach; and (4) removal of the lymphatic tissues overlying the pancreatic capsule. Extended lymph node dissection (D2 resection) can be done here as described in the prior section.<sup>40-43</sup> However, as before, its potential survival benefit, as shown in some studies, must be weighed against its increased morbidity. After total gastric resection, we favor a Roux-en-Y reconstruction with a direct esophagoenterostomy rather than a jejunal pouch, although the techniques for both forms of reconstruction will be described.

Illustrated in Fig. 26-32 is the final specimen in an en bloc resection. Generally, an upper midline or chevron incision will provide good exposure. A thoracoabdominal

incision (Fig. 26-33) is rarely necessary but can provide better exposure when the patient's habitus suggests a deep hiatus. This latter incision also should be considered when preoperative endoscopy suggests that the tumor is close enough to the cardia so that the distal thoracic portion of the esophagus might be included with the resection. If this latter approach is chosen, the abdominal portion of the incision is performed first, in order to assess resectability. The patient is placed in a left thoracotomy position. The incision is carried from the line of the eighth rib obliquely toward the umbilicus. If resection appears feasible, the incision is extended over the eighth rib to the posterior angle. Occasionally, the seventh rib will provide better exposure. A separate rib retractor for the chest and a self-retaining retractor without a ring for the abdominal portion provide the best retraction. The diaphragm is divided toward the hiatus, but the muscle does not always have to be divided completely. Thus it may be possible to spare the neurovascular bundle. Significant bleeding is encountered and it requires suture ligation with 2-0 or 0-0 Vicryl.

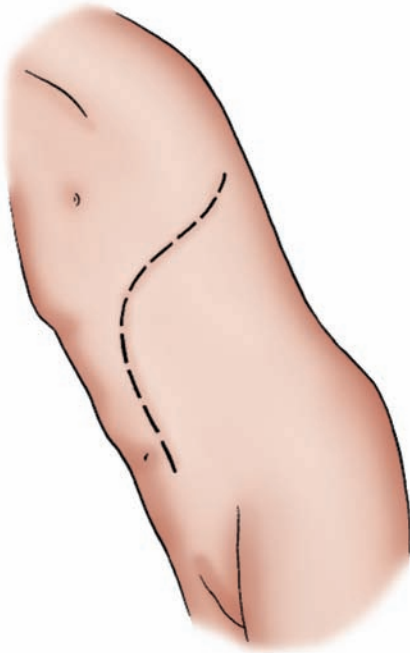


**FIGURE 26-32** Anatomy relevant to resections for gastric carcinoma. (Redrawn from Zinner MJ. *Atlas of Gastric Surgery*. New York, NY: Churchill Livingstone; 1992. After Gloege.)

In the abdominal approach, the Bookwalter retractor is used. Extra care in positioning retractors on the left lobe of the liver, diaphragm, and small intestine, for optimal exposure of the hiatus is time well spent. The dissection is begun by dividing the omentum from the transverse colon (Fig. 26-34). This relatively avascular plane can be separated using the electrocautery. Deviation from this plane will injure the colon or require tedious ligation and division of omental blood vessels. The lesser sac is then entered, allowing assessment of the retroperitoneum, with regard to local tumor extension and lymph node involvement. The distal portion of the gastrectomy is then performed. The origin of the right gastric artery at the common hepatic artery is

identified, ligated in continuity with 2-0 silk ligatures, and divided.

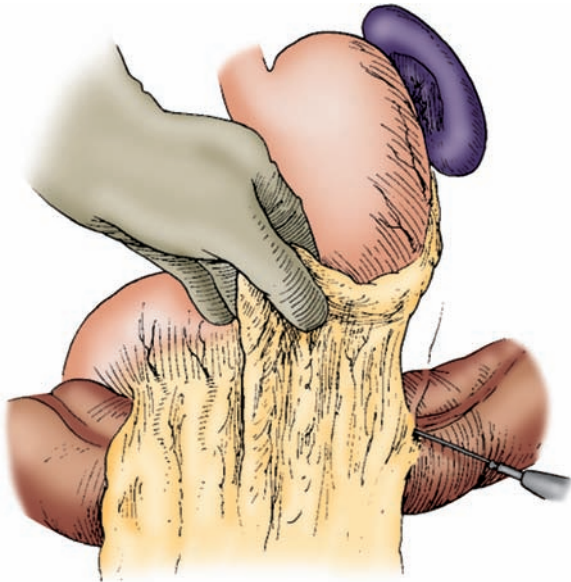
Lymphatic-bearing tissues are swept toward the gastric side. The right gastroepiploic artery is identified, usually by palpation, and traced as far to its base as possible. It is usually possible to trace the artery to its origin at the gastroduodenal artery, which is similarly ligated in continuity and divided. Using the electrocautery, the lesser omentum is incised near the liver and its tissues are swept toward the lesser curvature, from the duodenum to the esophagus. Any small vessels are ligated with 3-0 ligatures. The dissection is carried onto the peritoneal surface of the esophagus. The duodenum may then be divided using the GIA stapler or a TA-55 stapler that is



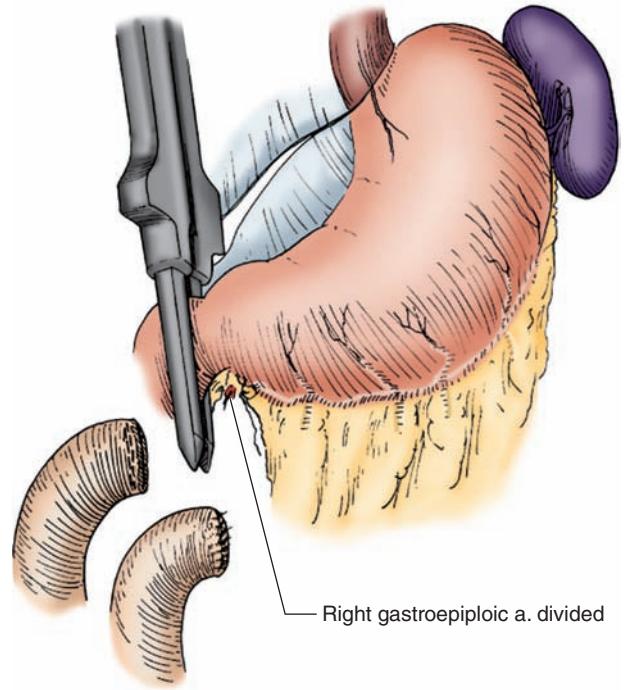
**FIGURE 26-33** Thoracoabdominal incision for radical total gastrectomy for carcinoma of the stomach. The incision is carried along the seventh or the eighth interspace.

fired twice, once on the duodenum and once directly on the pylorus. The duodenum is divided just distal to the pyloric ring (Fig. 26-35).

With the distal portion of the stomach divided, full access to the left gastric artery is obtained posteriorly through



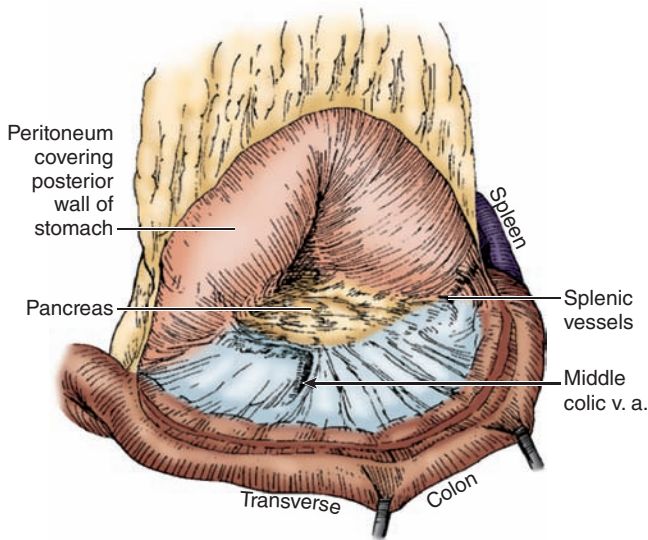
**FIGURE 26-34** Resection for gastric carcinoma. The gastrocolic omentum is detached from the transverse colon using electrocautery. (Redrawn, with permission, from Zinner MJ. *Atlas of Gastric Surgery*. New York, NY: Churchill Livingstone; 1992. After Gloege.)



**FIGURE 26-35** Resection for gastric carcinoma. The duodenum is divided beyond the pylorus. Either the linear cutter or transverse stapling instruments are appropriate. If feasible, the duodenal staple line is reinforced using 3-0 silk Lambert sutures. (Redrawn, with permission, from Zinner MJ. *Atlas of Gastric Surgery*. New York, NY: Churchill Livingstone; 1992. After Gloege.)

the lesser sac. This approach optimizes visualization of the celiac axis and its branches. With the assistant retracting the stomach upward and anteriorly, a number of congenital adhesions between the posterior gastric wall and the peritoneum overlying the pancreas are observed (Fig. 26-36). If tumor is invading this plane, a decision must be made regarding inclusion of the body and tail of the pancreas in the specimen. The plane made by the peritoneum overlying the pancreas is a natural plane, and there may be sense in taking this peritoneum with the en bloc specimen. This layer can be dissected off the anterior face of the pancreas and swept gently to the front toward the left gastric vessels and splenic hilum. If a curative resection appears to be feasible but would require removal of the body and/or tail of the pancreas, we do not see this as a contraindication to resection. The origin of the left gastric artery is then identified at the celiac axis, ligated in continuity using 2-0 silk, and divided (Fig. 26-37). The stump of the artery is suture-ligated as well. From the celiac axis side, the tissue surrounding the artery contains lymphatics and is swept toward the lesser curvature. When the tumor is located in the more proximal body and corpus, the case for inclusion of the spleen with the en bloc specimen has not been persuasive,<sup>55,56</sup> a recent meta-analysis suggesting no oncologic benefit<sup>57</sup> for removal of a spleen not apparently involved by direct extension. Inclusion of the spleen is indicated if there are obvious tumor-bearing nodes or if there is



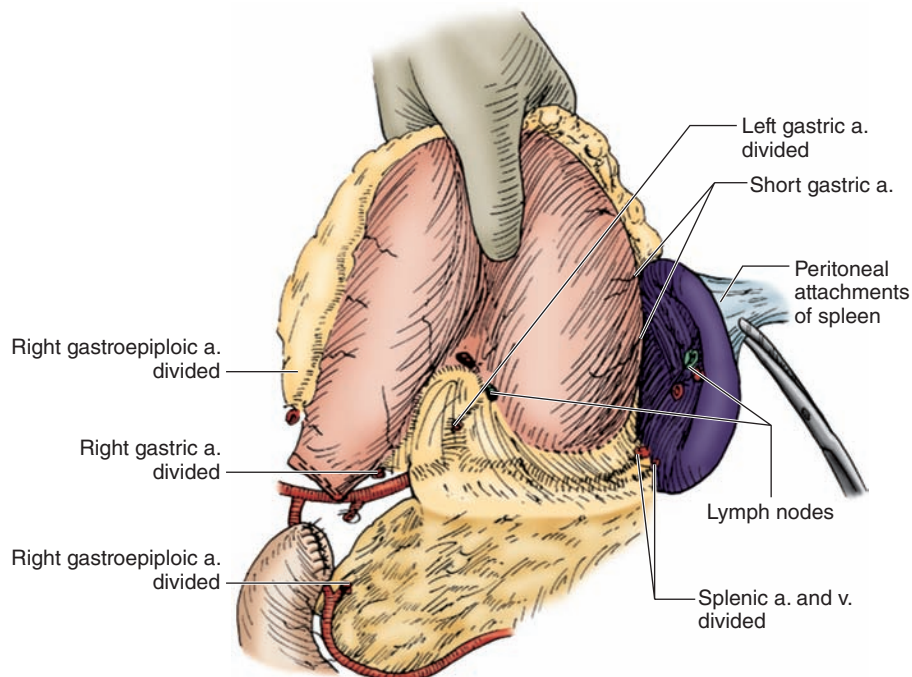


**FIGURE 26-36** Resection for gastric carcinoma. With the lesser sac fully visualized, the thin layer of tissue overlying the pancreas is exposed and can be removed with the en bloc specimen. (Redrawn, with permission, from Zinner MJ. *Atlas of Gastric Surgery*. New York, NY: Churchill Livingstone; 1992. After Gloege.)

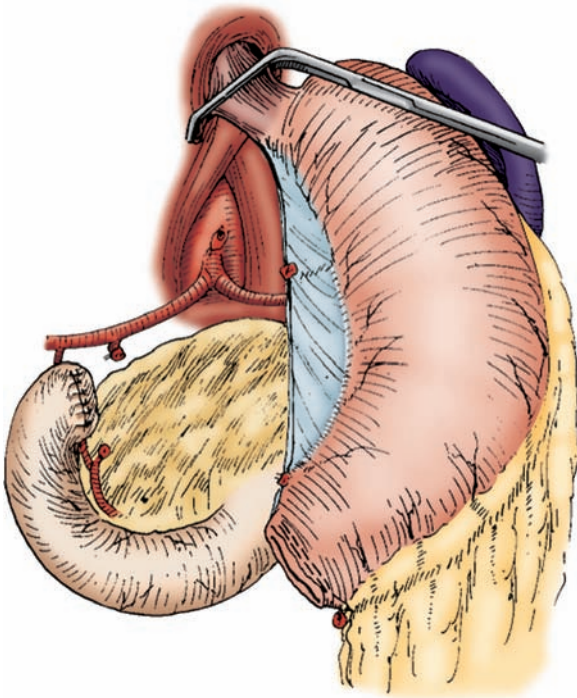
direct invasion of the splenic hilum. Through the lesser sac, the tail of the pancreas is identified. The splenic artery and vein are separated, suture-ligated, and divided individually. At this point, the short gastric vessels are then part of the en bloc specimen and are not dissected or divided.

The posterior aspect of the esophagus then comes into view as the stomach and spleen are lifted upward. Posteriorly, the front of peritoneal tissue can be dissected bluntly until the superior border of the pancreas is reached. The peritoneum is continuous with the peritoneum investing the gastric side of the gastroesophageal junction. If this layer has not been included with the dissection, the peritoneum must be divided here, exposing the gastroesophageal junction posteriorly. Figure 26-38 demonstrates the stomach completely mobilized except for its attachment to the esophagus. A noncrushing clamp is placed on the mobilized esophagus and the specimen is resected. To minimize spillage of luminal contents, a second clamp is placed on the gastric side or the TA-55 stapler may be fired below the line of resection and above the gastroesophageal junction.

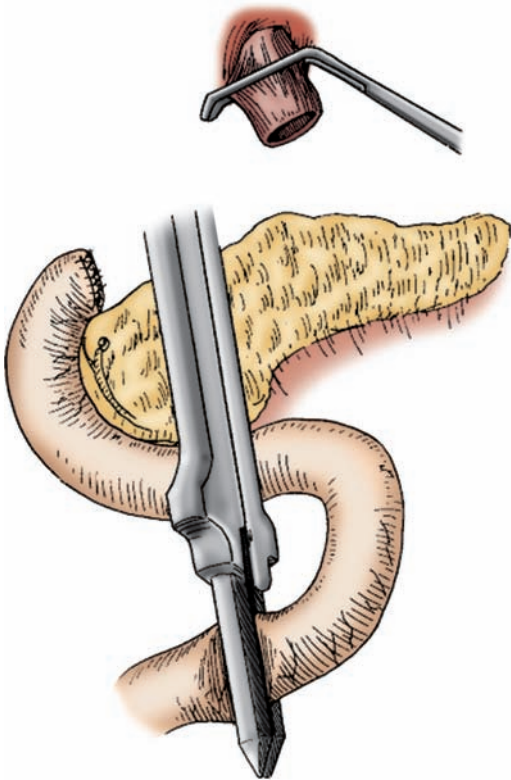
Our preferred technique for reconstruction is a simple Roux-en-Y, with an end-to-side esophagojejunal anastomosis with the Roux limb. Using the GIA stapler, a section of jejunum is divided 10–15 cm beyond the ligament of Treitz (Fig. 26-39). The Roux limb is brought antecolic up to the esophagus. An enteroenterostomy is constructed between the jejunum on the duodenal side of the Y and the jejunum, 40–45 cm distal to the Roux limb staple line (Fig. 26-40). The enteroenteral anastomosis can be performed using hand-sewn two-layer technique or stapling technique. The esophagojejunal anastomosis is performed using interrupted 3-0 silk sutures for both the inner and outer layers, as shown in Fig. 26-41. The completed reconstruction is shown in Fig. 26-42. This figure emphasizes the antecolic position of the anastomosis when the operation is performed for malignant disease. Areas of potential internal



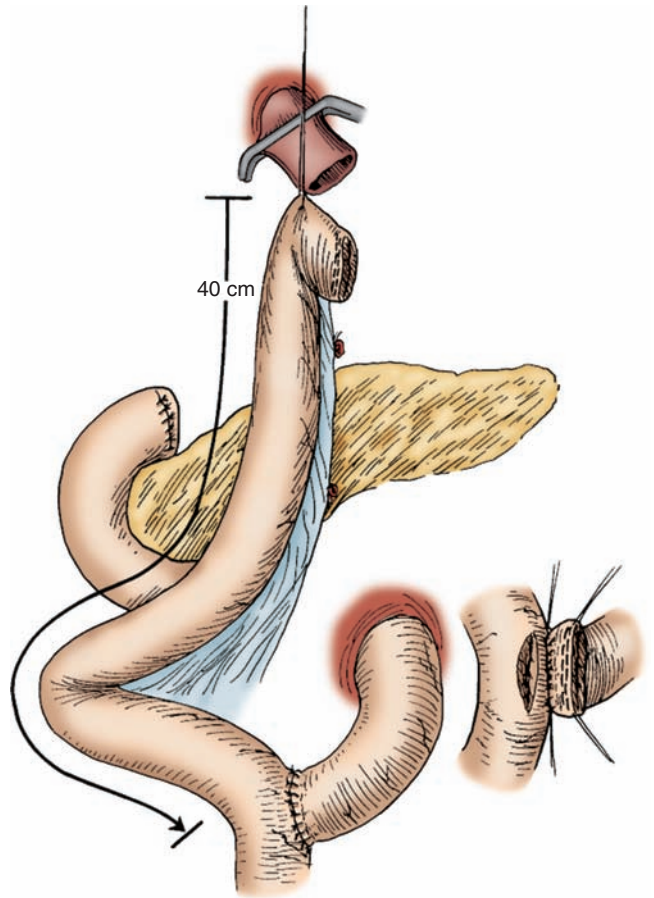
**FIGURE 26-37** Resection for gastric carcinoma. Exposure of the left gastric artery through the lesser sac. (Redrawn, with permission, from Zinner MJ. *Atlas of Gastric Surgery*. New York, NY: Churchill Livingstone; 1992. After Gloege.)



**FIGURE 26-38** Gastric resection for carcinoma. The esophagus is transected just above the gastroesophageal junction. (Redrawn, with permission, from Zinner MJ. *Atlas of Gastric Surgery*. New York, NY: Churchill Livingstone; 1992. After Gloege.)



**FIGURE 26-39** Gastric insert for carcinoma. Construction of Roux-en-Y limb begins with division of the jejunum beyond the ligament of Treitz. (Redrawn, with permission, from Zinner MJ. *Atlas of Gastric Surgery*. New York, NY: Churchill Livingstone; 1992. After Gloege.)

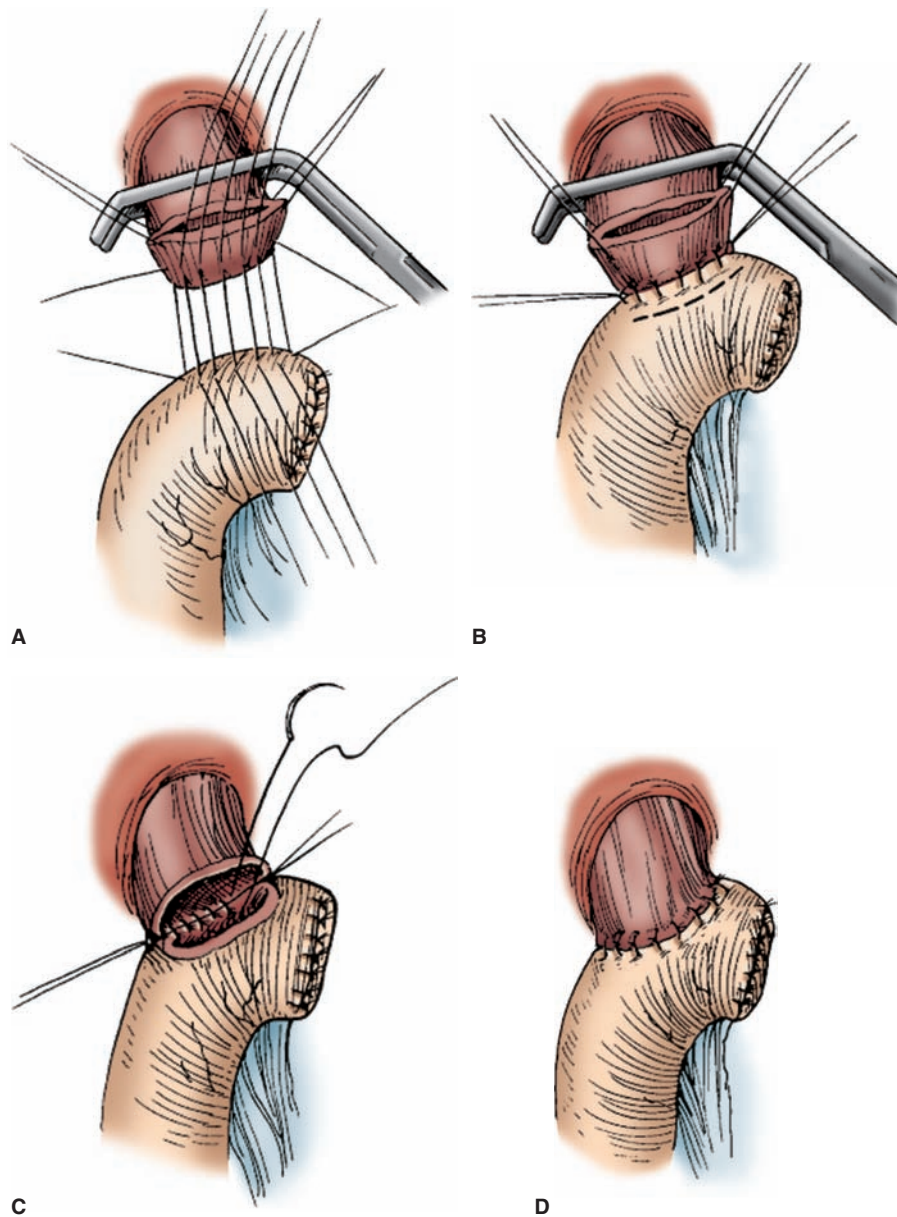


**FIGURE 26-40** Construction of Roux-en-Y anastomosis. The enteroenterostomy is performed in two layers. The length of the Roux limb measures 40 cm. (Redrawn, with permission, from Zinner MJ. *Atlas of Gastric Surgery*. New York, NY: Churchill Livingstone; 1992. After Gloege.)

herniation in the mesentery are closed with absorbable 3-0 sutures.

A jejunal pouch (Hunt-Lawrence pouch) also may be constructed, with the idea of anastomosing the esophagus in end-to-side fashion with the antimesenteric border of the pouch.<sup>58,59</sup> The technique is illustrated in Figs. 26-43 through 26-45 and can be performed expeditiously using surgical staplers. The pouch is constructed with the goal of providing a reservoir function. Alternatively, a number of surgeons expressed a preference for leaving an island of undivided intestine at the bend in the pouch. This should theoretically optimize the blood supply to the anastomosis. The circular stapler can be passed through the open end of the Roux limb in order to perform the end-esophagus to side-jejunum anastomosis. The linear stapler then can be fired in such a way as to leave the island of undivided intestine. One important point is that the pouch can be made too long, giving rise to stasis and ineffective clearance of food from the pouch into the intestine. The pouch should not be more than 15 cm in length.





**FIGURE 26-41** Roux-en-Y reconstruction following total gastrectomy. The anastomosis is prepared using two layers of interrupted 3-0 silk sutures. (Redrawn, with permission, from Zinner MJ. *Atlas of Gastric Surgery*. New York, NY: Churchill Livingstone; 1992. After Gloege.)

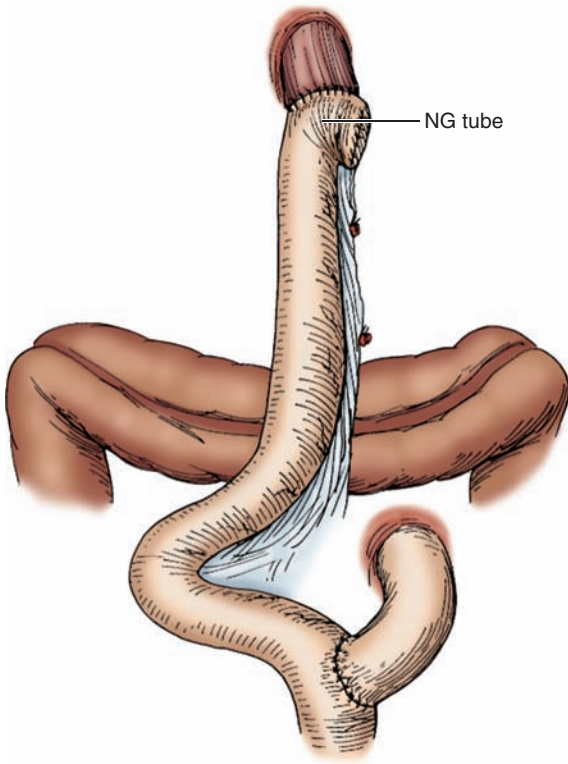
## Laparoscopic Approaches

### LAPAROSCOPIC APPROACHES TO THE VAGUS NERVE

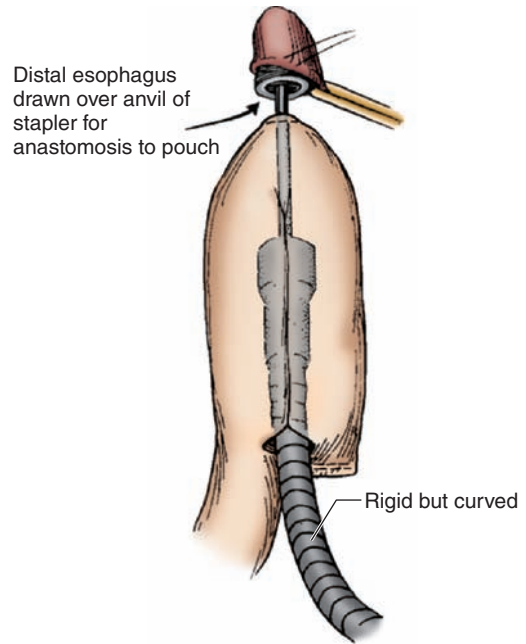
As noted previously, the advent of laparoscopic approaches has led surgeons to reconsider traditional approaches to peptic ulcer disease. The advantages of minimally invasive approaches revolve largely around the minimal postoperative discomfort and rapid recovery, with a potential benefit in reduced cost of surgery versus the cost of long-term medication.<sup>60</sup> At the same time, rapid advances have occurred in our understanding of the role of *Helicobacter*

*pylori* and mucosal growth, and angiogenic factors in ulcer healing and recurrence. In addition, limitations in access and suturing techniques have increased the difficulty of access to the lesser sac and of performing drainage procedures. These considerations have led surgeons to question the rationale for routine drainage whenever TV has been performed.<sup>15,37</sup> A number of approaches have evolved to address these difficulties and have been given credibility in the laparoscopic experience. One such approach has been to combine truncal vagotomy with pyloric dilation or seromyotomy.<sup>26,16,21</sup> Another has been to combine a posterior truncal vagotomy with an anterior highly selective vagotomy or with

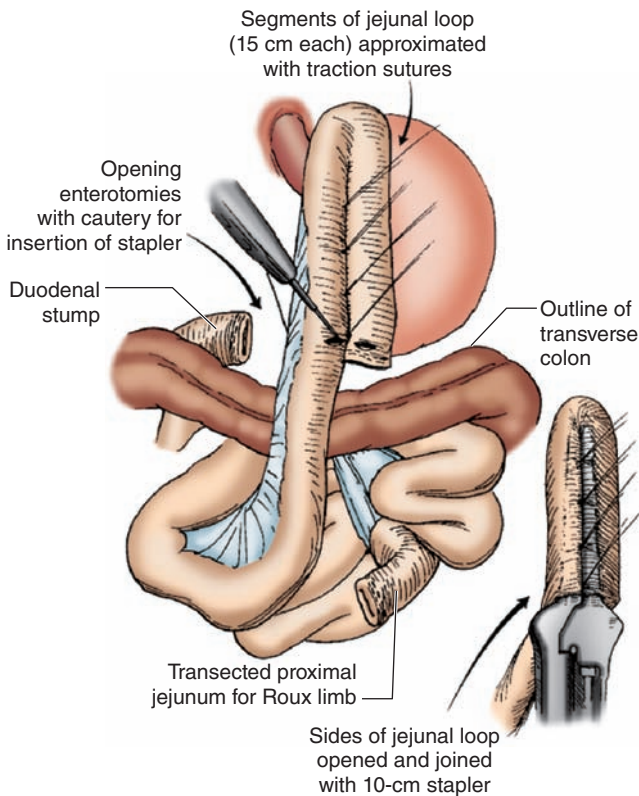




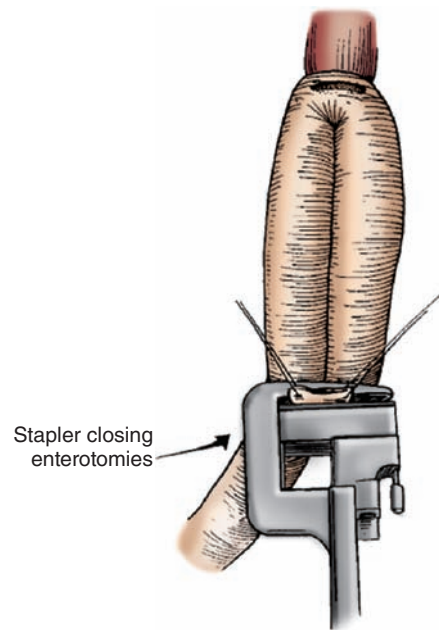
**FIGURE 26-42** Roux-en-Y reconstruction completed. NG, nasogastric. (Redrawn, with permission, from Zinner MJ. *Atlas of Gastric Surgery*. New York, NY: Churchill Livingstone; 1992. After Gloege.)



**FIGURE 26-44** Total gastrectomy. The circular stapler is positioned via the enterotomies. The center rod is pushed through the antimesenteric border of the jejunum using cautery to prevent tearing. (Redrawn, with permission, from Siegler HF. Total gastrectomy: stapler. In Sabiston DC, Jr, ed. *Atlas of General Surgery*. Philadelphia, PA: WB Saunders; 1994.)



**FIGURE 26-43** Total gastrectomy with jejunum pouch reconstruction.



**FIGURE 26-45** Completed pouch and esophagojejunum anastomosis. The enterotomy is closed with the transverse 55-mm stapler. (Redrawn, with permission, from Siegler HF. Total gastrectomy: stapler. In: Sabiston DC, Jr, ed. *Atlas of General Surgery*. Philadelphia, PA: WB Saunders; 1994.)

an anterior seromyotomy.<sup>16</sup> The important elements of the laparoscopic approach to the vagi are discussed here.

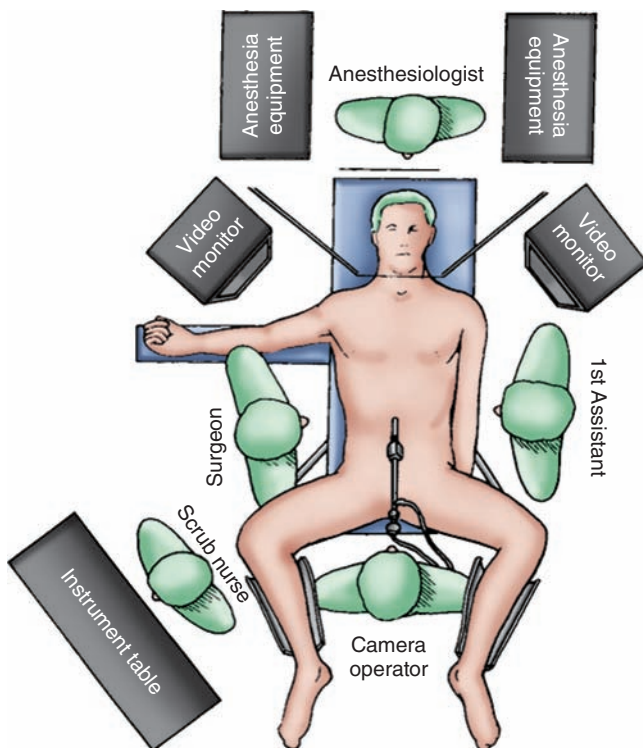
### PATIENT POSITION AND PORT PLACEMENT

The patient is placed on the operating room table with legs in stirrups and apart (Fig. 26-46). Video monitors are placed on either side at the head; often, the surgeon works best when standing between the legs, with the camera operator on the right and the first assistant on the patient's left. The scrub nurse/technician and instrument table are placed at the patient's right foot. A large esophageal tube or even a gastroscope is placed in the stomach to facilitate visualization of the distal esophagus. Frequent aspiration of the gastric contents is crucial to maintain total collapse of the stomach and the best visualization. We recommend an open technique to gain access to the peritoneum, insufflating to a pressure of 14 mm Hg. Five ports are placed in the following locations: (1) a 12-mm laparoscope port at the superior edge of the umbilicus or placed 5 cm above and lateral to the left of midline; (2) a 5-mm irrigation/suction and dissection port in the subxiphoid position, just to the right of midline; (3) a 10-mm port for retraction and grasping forceps midway between the umbilicus and xiphoid, to the right of the rectus, and possibly as far as the midclavicular line; (4) a 10-mm port for grasping forceps midway between the umbilicus and

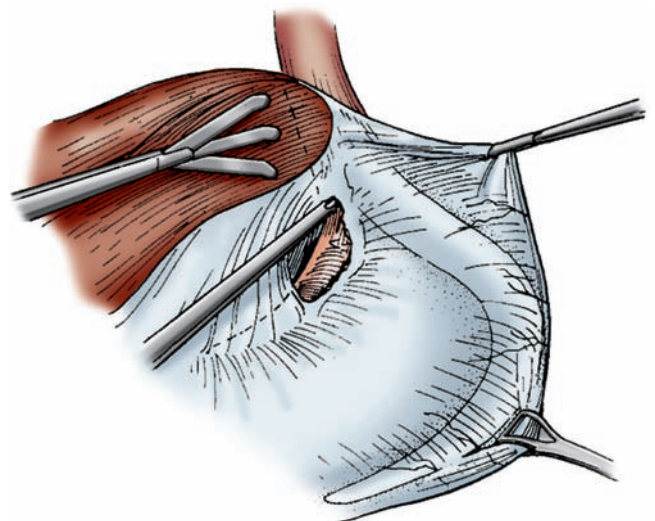
xiphoid, almost to the anterior axillary line on the left; and (5) a 12-mm operating port just lateral to the rectus 3 cm above the umbilicus. A number of surgeons prefer the angled 30-degree laparoscope for this operation.

### LAPAROSCOPIC TRUNCAL VAGOTOMY

The left lobe of the liver is retracted using a probe placed via the subxiphoid port or the 10-mm fan retractor placed via the higher right-side port (Fig. 26-47). Visualization is improved when tissues from the hiatus are dissected away from the esophagus and lesser curvature (Figs. 26-48 and 26-49). One can encounter a coronary hepatic vein or accessory hepatic artery in this dissection. These do not always need to be sacrificed. The right crus of the diaphragm usually is seen here and can be retracted with one of the blades of the liver retractor (Fig. 26-50). A Babcock clamp or other atraumatic grasper is used to retract the anterior greater curvature (distal to the cardia) to the patient's left. A hook coagulator or dissecting forceps is used to incise the lesser omentum, entering the lesser sac just above the takeoff of the hepatic branch of the anterior vagus nerve. A plane is developed between the right crus and the esophagus and continued posteriorly. Continued dissection along the wall of the esophagus reveals the posterior trunk, which is ligated between clips and divided (Fig. 26-51). The excised nerve segment is sent for frozen-section examination. The next step is identification of the anterior vagal trunk(s). The phrenoesophageal membrane usually has been entered and incision is extended toward the left, first by scoring the membrane with scissors and then bluntly pushing away the membrane with a cotton dissector. The visualization of major anterior trunks is often easier in the laparoscopic approach, owing to magnification and excellent video optics. These branches also are ligated and divided between clips (Fig. 26-52), with frozen-section confirmation of the nerve segment. Smaller anterior branches are identified and cauterized after being held away from the esophageal wall.



**FIGURE 26-46** Setup for laparoscopically-assisted vagotomy. (Redrawn, with permission, from Bailey RW, Zucker KA, Flowers JL. Vagotomy. In: Ballantyne GH, ed. *Laparoscopic Surgery*. Philadelphia, PA: WB Saunders; 1994.)



**FIGURE 26-47** Laparoscopic view of the hiatus.



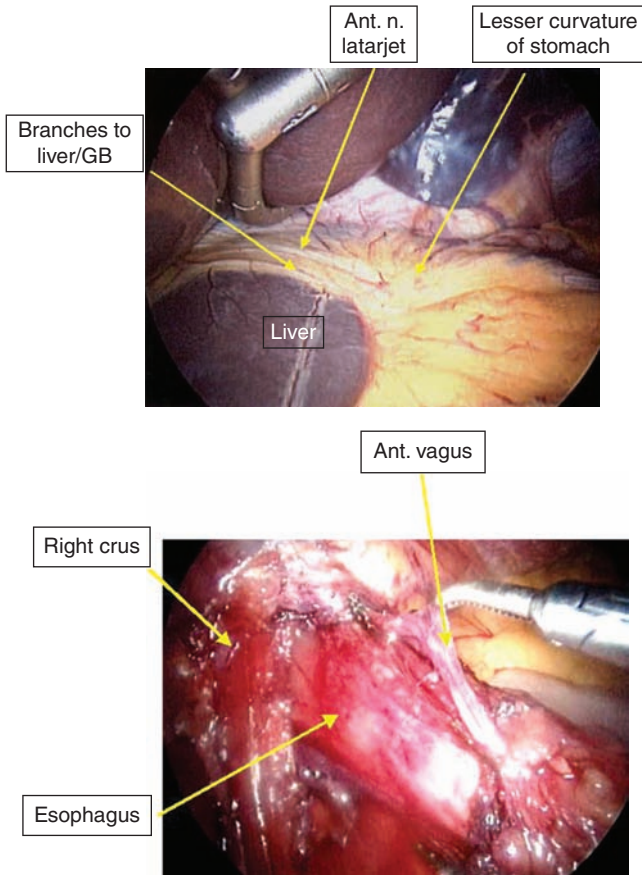


FIGURE 26-48 Laparoscopic view of the anterior vagus nerve. A. Before dissection. B. After dissection.

It is possible to dissect tissues on either side of the esophagus for a distance of 5–6 cm, thereby ensuring division of any nerve branches to the lesser curvature and cardia. The main difficulty can occur in visualizing the angle of His and possibly missing major vagal branches, including the

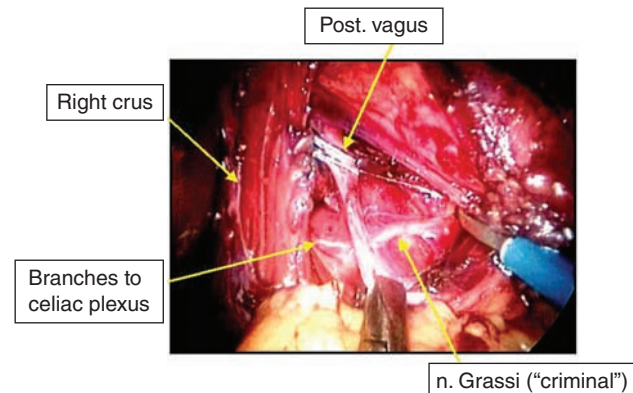


FIGURE 26-49 Laparoscopically assisted vagotomy. The gastrohepatic ligament is dissected anteriorly without injury to the vagus nerves.

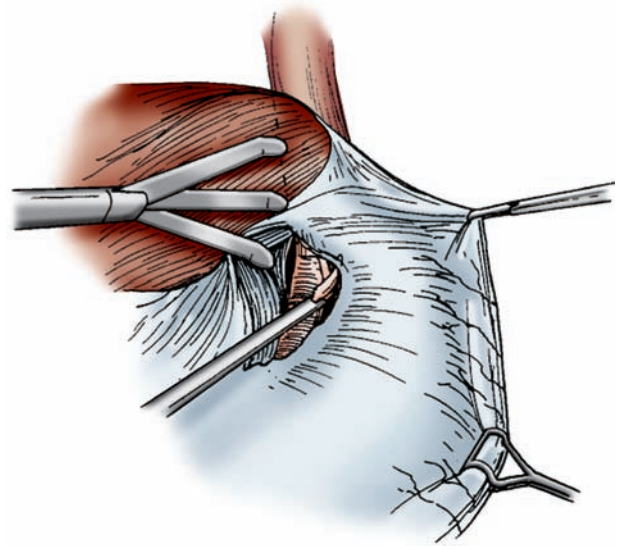


FIGURE 26-50 Laparoscopically assisted vagotomy. The crus of the diaphragm is retracted to the patient’s right. The anterior vagal trunk is exposed at the gastroesophageal junction. (Redrawn, with permission, from Katkhouda N, Mouiel J. Laparoscopic treatment of peptic ulcer disease. In: Brooks DC, ed. *Current Techniques in Laparoscopy*. Philadelphia, PA: Current Medicine; 1994, with kind permission of Springer Science + Business Media.)

“criminal nerve.” With the use of a traction forceps placed through the subxiphoid port and a cotton dissector placed via the left grasping forceps, it is possible to expose the left edge of the gastroesophageal junction and cauterize or clip any branches.

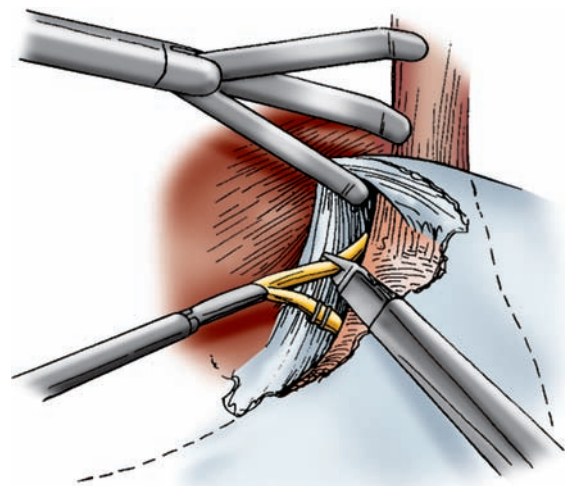
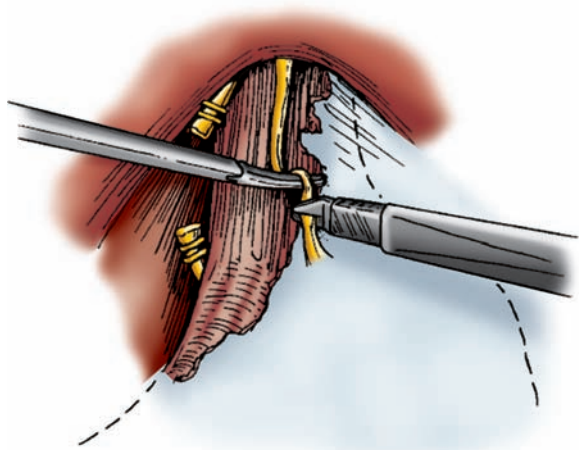


FIGURE 26-51 Laparoscopically assisted vagotomy. The posterior trunk is ligated between clips and divided. (Redrawn, with permission, from Katkhouda N, Mouiel J. Laparoscopic treatment of peptic ulcer disease. In: Brooks DC, ed. *Current Techniques in Laparoscopy*. Philadelphia, PA: Current Medicine; 1994, with kind permission of Springer Science + Business Media.)



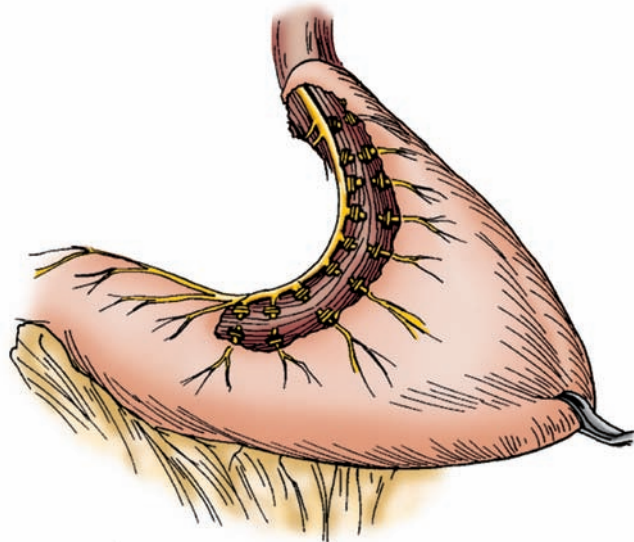


**FIGURE 26-52** Laparoscopically assisted vagotomy. Ligation and division of the anterior vagus between clips. (Redrawn, with permission, from Katkhouda N, Mouiel J. Laparoscopic treatment of peptic ulcer disease. In: Brooks DC, ed. *Current Techniques in Laparoscopy*. Philadelphia, PA: Current Medicine; 1994, with kind permission of Springer Science + Business Media.)

#### ANTERIOR PROXIMAL VAGOTOMY OR SEROMYOTOMY

A laparoscopic dissection of the posterior leaf is feasible.<sup>61,62</sup> However, the combination of posterior TV and an anterior selective operation is appealing, because it avoids the difficult maneuver of working through the lesser sac in order to visualize the posterior lesser omentum and nerves accompanying the ascending left gastric artery branches. For HSV, dissection is begun at the crow's foot, approximately 6 cm from the pylorus. Retraction of the greater curvature is performed using a Babcock clamp (Fig. 26-53). With the magnification available through the scope, the proximal branch of the crow's foot is often, but not always, relatively easy to identify. The anterior leaf of the lesser omentum is approached by dividing and ligating the neurovascular bundle between clips. Electrocautery is used sparingly, and preferably not at all. The serosa overlying the gastroesophageal junction is scored as in the open procedure. Dissection of the distal 5 cm of esophagus and cardiac branches is carried out as described previously for TV.

The goal of an anterior seromyotomy, as described originally by Taylor et al<sup>63</sup> and then others,<sup>13,26,64</sup> is to sever the neurovascular bundles dividing the serosa and muscularis that transmit these nerves to the mucosa. The anterior surface of the stomach is retracted and placed on stretch using the right and left grasping ports. The outline of the seromyotomy is scored using a coagulator hook or spatula, on the anterior surface of the stomach, 1 cm from the visible border of the lesser curvature. Moving caudad and parallel to the lesser curvature, a line is traced from the gastroesophageal junction to the first branch of the crow's foot, or arbitrarily 6 cm from the pylorus. The hook coagulator is most suitable for performing the seromyotomy, using monopolar current



**FIGURE 26-53** Laparoscopically assisted parietal cell vagotomy. Dissection of the anterior leaf of the gastrohepatic ligament. (Redrawn, with permission, from Katkhouda N, Mouiel J. Laparoscopic treatment of peptic ulcer disease. In: Brooks DC, ed. *Current Techniques in Laparoscopy*. Philadelphia, PA: Current Medicine; 1994, with kind permission of Springer Science + Business Media.)

for electrocoagulation. The hook cuts through successive layers of gastric wall, of the serosa, outer oblique muscle fibers, middle longitudinal fibers, and inner circular fibers. The two grasping ports then are used to place traction on the two edges of the gastric wall, exposing the deep circular fibers that may split as much from traction as from cautery. The darker submucosa/mucosa layer pops through the muscularis. This layer is inspected for any evidence of full-thickness cautery injury or perforation. With a complete seromyotomy, the gap between the cut edges should be about 6–8 mm. Alternatively, a laparoscopic surgical stapling device can be used for creation of a modified seromyotomy.<sup>26</sup>

A number of decent-sized vessels may be encountered in the dissection. Prolonged cauterization may provide hemostasis but risks a full-thickness burn and subsequent perforation. The hook can be used to isolate these vessels and lift them for clipping in continuity. Recent advances in the design of needle holders may make it possible to suture these vessels in continuity before division by scissors. Surgical stapling devices can be used for this purpose, as well as newer devices such as the harmonic scalpel, which utilizes ultrasonic energy for coagulating vessels, or electrothermal bipolar coagulator devices. After creation of the seromyotomy, the integrity of the mucosa should be verified by moderate expansion of the stomach using the NG tube for insufflation. Some authors use methylene blue solution (1 vial per 200 mL), placed intragastrically, for this maneuver. The seromyotomy then is closed using a continuous suturing technique. A tongue of omentum may be mobilized and secured over the seromyotomy as a patch, secured with sutures placed through either edge of the seromyotomy.

## LAPAROSCOPIC APPROACHES TO THE GASTRIC RESECTION

The patient is positioned the same way as for laparoscopic antisecretory surgery, with the patient supine with legs in stirrups and apart as shown in Fig. 26-46. Port placement is similar with five ports placed in the following locations: (1) a 12-mm laparoscope port at the superior edge of the umbilicus or placed 5 cm above and lateral to the left of midline; (2) a 5-mm irrigation/suction and dissection port in the subxiphoid position, just to the right of midline; (3) a 10-mm port for retraction and grasping forceps midway between the umbilicus and xiphoid, to the right of the rectus and possibly as far as the midclavicular line; (4) a 10-mm port for grasping forceps midway between the umbilicus and xiphoid, almost to the anterior axillary line on the left; and (5) a 12-mm operating port just lateral to the rectus 3 cm above the umbilicus. A 30- or 45-degree angled laparoscope is useful for gastric resections, as it allows improved visualization of the stomach from multiple perspectives. If resections high in the lesser curvature are planned, retraction of the left lobe of the liver using a probe placed via the subxiphoid port or the 10-mm fan retractor placed via the higher right-side port (see Fig. 26-51) is useful as described for laparoscopic TV.

Wedge resections of benign but symptomatic masses on the greater curvature can be done by grasping the greater curvature with a Babcock or other atraumatic grasper and use of a laparoscopic stapling device to resect the involved portion of stomach. Occasionally intraoperative endoscopic confirmation of the position of intraluminal masses not readily apparent intraoperatively is useful. Wedge resections on the lesser curvature are more difficult due to the presence of the left lobe of the liver, which usually needs to be retracted, and the proximity of the esophagus and vagus nerves. However, with careful attention to the gastroesophageal junction, wedge resections of the lesser curvature can be done. Intraluminal approaches can also be utilized.<sup>44,45</sup> If the vagus nerve or its major branches are sacrificed in lesser curvature resections, a laparoscopic or endoscopic drainage procedure is recommended (endoscopic pyloric dilation or laparoscopic pyloric seromyotomy).

Distal, subtotal, and total gastrectomy procedures have all been adapted for laparoscopic approaches. With recent advances in equipment and concentrated experience, all approaches seem to be finding increasing application, with promising results in selected patients.<sup>65-68</sup> In laparoscopic subtotal or total gastrectomy, port placement is similar to that for wedge resections and antisecretory procedures (Fig. 26-54). Gastric mobilization, resection, and reconstruction are done in a similar fashion to that of the open procedures. After entry into the abdominal cavity and port placement, the left lobe of the liver is mobilized and retracted laterally with a fan retractor or probe through the subxiphoid port if the lesser curvature cannot be adequately visualized or if extensive dissection of the lesser curvature is required. The stomach is grasped with a laparoscopic Babcock clamp, and the distal stomach is mobilized by incising the gastrocolic ligament, which is taken bluntly if the plane is avascular and with the harmonic scalpel

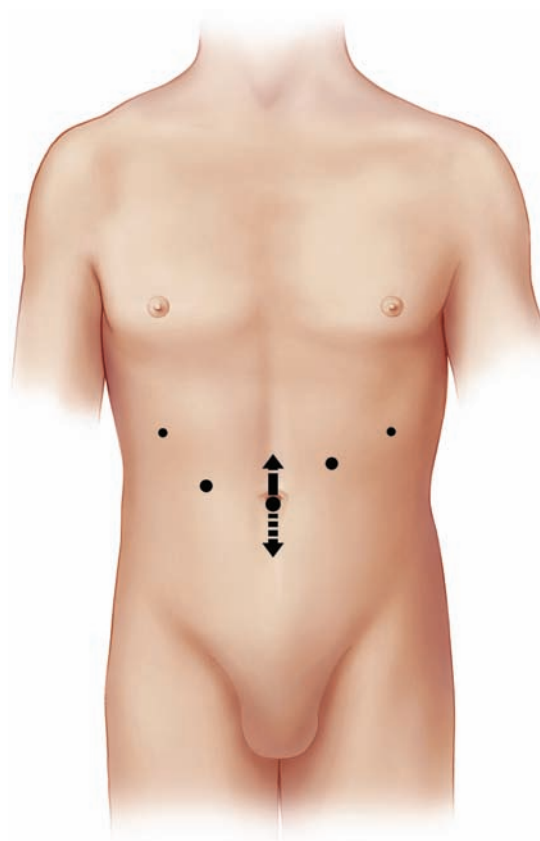
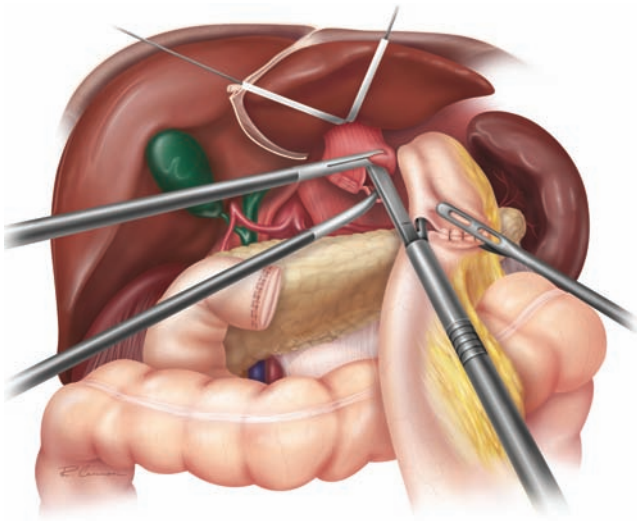


FIGURE 26-54 Port placement for laparoscopic subtotal or total gastrectomy.

or electrothermal bipolar coagulator device if small vessels are encountered. The dissection is carried distally along the greater curvature, dividing the small branches of the gastroepiploic artery to the gastric wall similarly with the harmonic scalpel or electrothermal bipolar coagulator device. Others have used endoscopic vascular staplers to take much of gastrocolic omentum and its vessels. Once the proximal portion of the gastric dissection is reached, the stomach is divided with laparoscopic staplers at our institution (2.5-mm stapler load on US Surgical, Norwalk, CT, or laparoscopic staplers on Ethicon, Somerville, NJ). The gastric resection is then completed by division of the distal stomach at or just past the pylorus with a laparoscopic stapler. Reconstruction is completed as a B-II gastrojejunal anastomosis. Babcock clamps are used to locate the jejunum at the ligament of Treitz and bring a freely mobile portion of jejunum typically 20–30 cm distal to the ligament of Treitz up to the proximal gastric remnant in an antecolic or retrocolic fashion through an avascular window in the transverse colon mesentery. The gastric remnant and jejunum are aligned together, being careful not to twist the jejunal mesentery, and then secured to each other at the proximal and distal suture lines by interrupted 3-0 Vicryl sutures placed either with an Endo Stitch (Auto Suture Company, Norwalk, CT) or with a laparoscopic needle driver. After the gastric and jejunal limbs are aligned, Bovie cautery is used to place



**FIGURE 26-55** Schematic view of laparoscopic total gastrectomy. The esophagojejunal anastomosis is performed using the stapling device.

enterotomies in the proximal gastric remnant and jejunum. A laparoscopic stapler is placed into the gastric and jejunal limbs and then deployed to form the anastomotic staple line. The proximal portion of the anastomosis is then closed using a laparoscopic stapler or suture-closed using an Endo Stitch device or with a laparoscopic needle driver. For total gastrectomy, the esophagojejunal anastomosis is performed using the stapling device as illustrated in Fig. 26-55. The mesenteric defect in the transverse colon is then closed if a retrocolic anastomosis has been performed.

### Laparoendoscopically Assisted Sentinel Node Navigation.

One of the concerns with laparoscopic gastrectomy procedures, done in patients with gastric cancer, is to determine whether a radical lymphadenectomy would be required. For early-stage gastric lesions (clinical and radiologic stage T1N0), sentinel node identification and so-called “sentinel node navigation” of the operation<sup>69–71</sup> have been advocated. Both single- and double-tracer methods have been described.<sup>72</sup> For complementary tracer injection, a method similar to that described recently by Orsenigo, et al would be utilized.<sup>73,74</sup> On the day prior to operation, endoscopy is performed to inject radioactive tracer (<sup>99</sup>Tc-colloid, 2 mL total) at four equally spaced points in direct proximity to the tumor; at the beginning of the actual operation, blue dye (2% patent blue, 2 mL divided among four sites) is injected endoscopically. The accumulation of radioactive tracer in the nodal basin occurs over a period of 2–20 hours, while the transfer of blue dye to the sentinel node occurs very quickly. As a result, the sentinel node seems reliably identified when the blue node contains at least 10-fold higher radioactive counts than background.<sup>73</sup>

It has been suggested that the radical lymphadenectomy may be limited to a D1 dissection if the sentinel node is clearly identified and clearly negative, but long-term outcomes in controlled trials are not yet fully known.<sup>75</sup>

### REFERENCES

1. Finney J. The development of surgery of the stomach with special reference paid to the part played by American surgeons. *Ann Surg.* 1929;90:829–846.
2. Absolon KB. The surgical school of Theodor Billroth. *Surgery.* 1961;50:697–715.
3. Herrington J. Historical aspects of gastric surgery. In: Scott H, Sawyers J, eds. *Surgery of the Stomach, Duodenum, and Small Intestine.* 2nd ed. Boston, MA: Blackwell Scientific; 1992:1–28.
4. Stabile BE, Passaro E, Jr. Duodenal ulcer: a disease in evolution. *Curr Probl Surg.* 1984;21:1–79.
5. Waisbren SJ, Modlin IM, Lester R. Dragstedt and his role in the evolution of therapeutic vagotomy in the United States. *Am J Surg.* 1994;167:344–359.
6. Amdrup E, Johnston D, Goligher JC. 110 highly selective vagotomies without drainage (HSV) for duodenal ulcer. *Gut.* 1970;11:1062.
7. Goligher JC, et al. Proximal gastric vagotomy without drainage for duodenal ulcer: results after 5–8 years. *Br J Surg.* 1978;65:145–151.
8. Thirlby RC. Studies of gastric secretion, In: Scott H, Sawyers J, eds. *Surgery of the Stomach, Duodenum, and Small Intestine.* 2nd ed. Boston, MA: Blackwell Scientific; 1992:124–143.
9. Feldman M, Richardson CT, Fordtran JS. Experience with sham feeding as a test for vagotomy. *Gastroenterology.* 1980;79:792–795.
10. Peetsalu A, Peetsalu M. Interpretation of postvagotomy endoscopic Congo red test results in relation to ulcer recurrence 5 to 12 years after operation. *Am J Surg.* 1998;175:472–476.
11. Donahue PE, et al. Endoscopic Congo red test during proximal gastric vagotomy. *Am J Surg.* 1987;153:249–255.
12. Mayer EA. The physiology of gastric storage and emptying. In: Johnson LR, ed. *Physiology of the Gastrointestinal Tract.* New York, NY: Raven; 1994:929–976.
13. Petrakis I, Vassilakis SJ, Chalkiadakis G. Anterior lesser curve seromyotomy using a stapling device and posterior truncal vagotomy for the treatment of chronic duodenal ulcer: long term results. *J Am Coll Surg.* 1999;188:623–628.
14. Kollmorgen CF, et al. Proximal gastric vagotomy. Comparison between open and laparoscopic methods in the canine model. *Ann Surg.* 1996;224(1):43–50.
15. Oelschlager BK, et al. Vagotomy during hiatal hernia repair: a benign esophageal lengthening procedure. *J Gastrointest Surg.* 2008;12(7):1155–1162.
16. Palanivelu C, et al. Laparoscopic management of acid peptic disease. *Surg Laparosc Endosc Percutan Tech.* 2006;16(5):312–316.
17. Skandalakis LJ, Gray SW, Skandalakis JE. The history and surgical anatomy of the vagus nerve. *Surg Gynecol Obstet.* 1986;162(1):75–85.
18. Pechlivanides G, et al. Gallbladder emptying after antiulcer gastric surgery. *Am J Surg.* 1994;168:335–339.
19. Rossi RL, et al. A five to ten year follow-up study of parietal cell vagotomy. *Surg Gynecol Obstet.* 1986;162:301–306.
20. Saik RB, Greenburg AG, Peskin GW. Pros and cons of parietal cell versus truncal vagotomy. *Am J Surg.* 1984;148:93–98.
21. Morris DL, et al. Posterior truncal vagotomy and stapling of the anterior stomach wall in 30 patients with duodenal ulcer: acid inhibition, gastric emptying, and endoscopic dye spraying. Prospects for endoscopic vagotomy. *Surg Laparosc Endosc.* 1993;3:375–380.
22. Chang TM, et al. Differences in gastric emptying between highly selective vagotomy and posterior truncal vagotomy combined with anterior seromyotomy. *J Gastrointest Surg.* 1999;3(5):533–536.
23. Wang CS, et al. Effects of highly selective vagotomy and additional procedures on gastric emptying in patients with obstructing duodenal ulcer. *World J Surg.* 1994;18:261–267.
24. Artifon EL, et al. An evaluation of gastric scintigraphy pre- and postpyloroduodenal peptic stenosis dilation. *Surg Endosc.* 2006;20(2):243–248.
25. Ozalp N, et al. Solid gastric emptying after highly selective vagotomy and pyloroplasty in patients with obstructing duodenal ulcer. *J Int Med Res.* 2005;33(2):245–251.



26. Schneider TA, 2nd, Andrus CH. The endoscopic Congo red test during proximal gastric vagotomy: an essential procedure. *Surg Endosc.* 1992;6(1):16–17.
27. Hallenbeck GA, et al. Proximal gastric vagotomy: effects of two operative techniques on clinical and gastric secretory results. *Ann Surg.* 1976;184:435–442.
28. Johnston D. Vagotomy. In: Schwartz SI, ed. *Maingot's Abdominal Operations*. 8th ed. Norwalk, CT: Appleton-Crofts; 1985:797–820.
29. Johnston D, Wilkinson A. Highly selective vagotomy without a drainage procedure in the treatment of duodenal ulcer. *Br J Surg.* 1970;57:289–296.
30. Grassi G. Highly selective vagotomy with intraoperative acid secretive test of completeness of vagal section. *Surg Gynecol Obstet.* 1975;140:259–264.
31. Peetsalu M, et al. Changes in the histology and function of gastric mucosa and in *Helicobacter pylori* colonization during a long-term follow-up period after vagotomy in duodenal ulcer patients. *Hepatogastroenterology.* 2005;52(63):785–791.
32. Gutschow C, et al. Denervated stomach as an esophageal substitute recovers intraluminal acidity with time. *Ann Surg.* 2001;233(4):509–514.
33. Barroso FL, Caltabiano A, Ornellas A. Transabdominal suprahepatic approach to repeat vagotomy after proximal gastric vagotomy. *Surg Gynecol Obstet.* 1990;171:167–168.
34. Thirlby RC, Feldman M. Transthoracic vagotomy for postoperative peptic ulcer. Effects on basal, sham feeding- and pentagastrin-stimulated acid secretion, and on clinical outcome. *Ann Surg.* 1985;201:648–655.
35. Chui PT, Gin T, Chung SC. Anaesthesia for a patient undergoing transthoracic endoscopic vagotomy. *Br J Anaesth.* 1992;68(3):318–320.
36. Bemelman WA, Brummelkamp WH, Bartelsman JF. Endoscopic balloon dilation of the pylorus after esophagogastrostomy without a drainage procedure. *Surg Gynecol Obstet.* 1990;170:424–426.
37. McDermott EW, J.J. Murphy JJ. Laparoscopic truncal vagotomy without drainage. *Br J Surg.* 1993;80:236.
38. Pringle R, et al. Randomized trial of truncal vagotomy with either pyloroplasty or pyloric dilatation in the surgical management of chronic duodenal ulcer. *Br J Surg.* 1983;70(8):482–484.
39. Pietrafitta JJ, et al. Laser laparoscopic vagotomy and pyloromyotomy. *Gastrointest Endosc.* 1991;37:338–343.
40. Mikulicz-Radecki J. Small contributions to the surgery of the intestinal tract. *Trans Am Surg Assoc.* 1903;21:124.
41. Ke CW, et al. Extraluminal laparoscopic wedge resection of gastric submucosal tumors: a retrospective review of 84 cases. *Surg Endosc.* 2010;24:1962–1968.
42. Sokolich J, et al. Expanding the indications for laparoscopic gastric resection for gastrointestinal stromal tumors. *JSLs.* 2009;26(2):165–169.
43. Tabrizian P, Nguyen SQ, Divino CM. Laparoscopic management and longterm outcomes of gastrointestinal stromal tumors. *J Am Coll Surg.* 2009;208(1):80–86.
44. Schubert D, et al. Laparoscopic-endoscopic rendezvous resection of upper gastrointestinal tumors. *Dig Dis.* 2005;23(2):106–112.
45. Abe N, et al. Endoscopic full-thickness resection with laparoscopic assistance as hybrid NOTES for gastric submucosal tumor. *Surg Endosc.* 2009;23(8):1908–1926.
46. Donahue PE, Nyhus LM. Surgical excision of gastric ulcers near the gastroesophageal junction. *Surg Gynecol Obstet.* 1982;155:85–88.
47. Bancroft FW. A modification of the Devine operation of pyloric exclusion for duodenal ulcer. *Am J Surg.* 1932;16:223–230.
48. Becker JM, et al. Proximal gastric vagotomy and mucosal antrectomy: a possible operative approach to duodenal ulcer. *Surgery.* 1983;94:58–64.
49. Degiuli M, et al. Morbidity and mortality after D1 and D2 gastrectomy for cancer: interim analysis of the Italian Gastric Cancer Study Group (IGCSG) randomised surgical trial. *Eur J Surg Oncol.* 2004;30:303–308.
50. Degiuli M, et al. Survival results of a multicentre phase II study to evaluate D2 gastrectomy for gastric cancer. *Br J Cancer.* 2004;90:1727–1732.
51. McCulloch P, et al. Extended versus limited lymph nodes dissection technique for adenocarcinoma of the stomach. *Cochrane Database Syst Rev.* 2004(4):CD001964.
52. Degiuli M, Sasako M, Ponti A. Italian Gastric Cancer Study Group. Morbidity and mortality in the Italian Gastric Cancer Study Group randomized clinical trial of D1 versus D2 resection for gastric cancer. *Br J Surg.* 2010;97(5):643–649.
53. Roukos DH, Lorenz M, Encke A. Evidence of survival benefit of extended (D2) lymphadenectomy in western patients with gastric cancer based on a new concept: a prospective long-term follow-up study. *Surgery.* 1998;123:573–578.
54. Collard JM, et al. Skeletonizing en-bloc gastrectomy for adenocarcinoma in Caucasian patients. *Gastric Cancer.* 2003;6:210–216.
55. Brady MS, et al. Effect of splenectomy on morbidity and survival following curative gastrectomy for carcinoma. *Arch Surg.* 1991;126:359–364.
56. Robertson CS, et al. A prospective randomized trial comparing R1 subtotal gastrectomy with R3 total gastrectomy for antral cancer. *Ann Surg.* 1994;220:176–182.
57. Yang K, et al. Effectiveness and safety of splenectomy for gastric carcinoma: a meta-analysis. *World J Gastroenterol.* 2009;15(42):5352–5359.
58. Gioffre Florio MA, et al. Simple versus double jejunal pouch for reconstruction after total gastrectomy. *Am J Surg.* 2000;180:24–28.
59. Lehnert T, Buhl K. Techniques of reconstruction after total gastrectomy for cancer. *Br J Surg.* 2004;91:528–539.
60. Millat B, Fingerhut A, Borie F. Surgical treatment of complicated duodenal ulcers: controlled trials. *Br J Surg.* 2000;24:299–306.
61. Dallemagne B, et al. Laparoscopic highly selective vagotomy. *Br J Surg.* 1994;81:554–556.
62. Cadere GB, et al. Laparoscopic highly selective vagotomy. *Hepatogastroenterology.* 1999;46(27):1500–1506.
63. Taylor TV, et al. Anterior lesser curve seromyotomy and posterior truncal vagotomy versus truncal vagotomy and pyloroplasty in the treatment of chronic duodenal ulcer. *Br J Surg.* 1990;77:1007–1009.
64. Katkhouda N, Heimbucher J, Mouiel J. Laparoscopic posterior truncal vagotomy and anterior seromyotomy. *Semin Laparosc Surg.* 1994;1:154–160.
65. Memon MA, et al. Meta-analysis of laparoscopic and open distal gastrectomy for gastric carcinoma. *Surg Endosc.* 2008;22(8):1781–1789.
66. Yakoub D, et al. Laparoscopic assisted distal gastrectomy for early gastric cancer: is it an alternative to the open approach? *Surg Oncol.* 2009;18(4):322–333.
67. Kim HH, et al. Morbidity and mortality of laparoscopic gastrectomy versus open gastrectomy for gastric cancer: an interim report—a phase III multicenter, prospective, randomized trial (KLASS Trial). *Ann Surg.* 2010;251(3):417–420.
68. Hanisch E, et al. Laparoscopic total gastrectomy: further progress in gastric cancer. *Surg Endosc.* 2010;24(9):2355–2357.
69. Kitagawa Y, et al. Laparoscopic detection of sentinel lymph nodes in gastrointestinal cancer: a novel and minimally invasive approach. *Ann Surg Oncol.* 2001;8:86S–89S.
70. Kitagawa Y, et al. Intraoperative lymphatic mapping and sentinel lymph node sampling in esophageal and gastric cancer. *Surg Oncol Clin N Am.* 2002;11:293–304.
71. Ohdaira H, et al. Validity of modified gastrectomy combined with sentinel node navigation surgery for early gastric cancer. *Gastric Cancer.* 2007;10(2):117–122.
72. Kitagawa Y, et al. Recent advances in sentinel node navigation for gastric cancer: a paradigm shift of surgical management. *J Surg Oncol.* 2005;90(3):147–151; discussion 151–152.
73. Orsenigo E, et al. Sentinel node mapping during laparoscopic distal gastrectomy for gastric cancer: technical notes. *Surg Endosc.* 2010;24(9):2324–2326.
74. Orsenigo E, et al. Sentinel node mapping during laparoscopic distal gastrectomy for gastric cancer. *Surg Endosc.* 2008;22(1):118–121.
75. Takeuchi H, Kitagawa Y. Is lymphadenectomy a predictor or savior for patients with gastric cancer? *Ann Surg Oncol.* 2010;17(5):1257–1258.

*This page intentionally left blank*

# MORBID OBESITY AND ITS SURGICAL TREATMENT

Bruce Schirmer • Peter Hallowell

## INTRODUCTION

Obesity looms as the single largest threat to world health in the next few decades. In countries such as the United States, its consequences pose the very real likelihood that the next generation may not live longer or be more healthier than the previous one.<sup>1</sup> This would reverse a trend that has been present for centuries. The rate of obesity is rising worldwide, not just in countries that enjoy privileged economic status. The rise in obesity over the past 25 years in the United States has been dramatic. Currently nearly one-third of adults in the United States are obese, defined as having a body mass index (BMI, calculated as being weight in kg divided by height in meters squared) of 30 kg/m<sup>2</sup> or greater.<sup>2</sup> More concerning yet, the rate of obesity in young adolescents and teenagers is approaching or exceeding the adult rate in many geographic areas. Because obese adolescents have a very high likelihood of being obese adults, this predicts that the problem will continue to grow in terms of its consequences on the health of the population.

Obesity was not a major health problem in many areas of the world, such as Asia and Africa, until the past decade. Now even those countries, where the problem was previously rare, are experiencing a significant increase in its prevalence. It is likely that wider access to high-calorie fast-food meals and other higher-calorie foods from Western countries, combined with the decreased need for physical labor and activity with increasing mechanization present in these countries, are significant contributing factors. The flattening of the world has also led to its fattening.

Obesity also remains the only major characteristic or attribute for which discrimination is not illegal. Laws exist to prevent discrimination on the basis of gender, sexual preference, race, religion, or handicapped status. However, there are no laws to prevent the current and prevalent discrimination against obesity in the workplace, in travel, in accommodations, and in other areas of life that are often overlooked by nonobese individuals. Most damaging, however, is the persistent belief by the majority of the public that obesity stems from laziness and gluttony, rather than being a disease. Even more sadly, there are still medical care providers who hold

such opinions. The Centers for Medicare and Medicaid Services (CMS) has officially recognized obesity as a disease and sanctioned its treatment as appropriate for recipients of federal insurance.<sup>3</sup> Unfortunately, the insurance industry overall, including those companies assigned to administer services to federally insured patients and the federal administrators as well in certain situations, has consistently raised barriers and made it difficult for patients with obesity, and particularly those with severe obesity, to obtain optimal treatment for their disease.<sup>4</sup> While such short-sighted behavior may save money for their balance sheets in the short term, it will not make the problem go away. The next generation worldwide will be required to pay the price of addressing the needs of the population with this disease.

One feasible reason for the aversion of insurance carriers toward funding surgical therapy for severe obesity is increased costs. The cost of obesity is now a huge part of the health care budget and rising more rapidly than the overall high rate of increasing health care costs. It is estimated that in 2007 the direct cost in dollars for treating obesity was \$93 billion or over 9% of all direct health care costs.<sup>5</sup> That cost is likely higher today. In addition, such a number is based only on direct hospital or physician charges for diagnosis codes of obesity and related conditions. They do not include the increased cost that obesity confers to many other situations. An example would be a severely obese individual with a large incisional hernia. That person has a much higher risk of the recurrence of the hernia, the need for further operative care, and even for more severe complications such as bowel injury, fistula, or obstruction. Yet these costs are not at all calculated in to the cost of obesity, because incisional hernia is the problem. Similarly, the huge cost annually to the population of diets and other nonmedical-related costs of obesity are also not included in this figure.

This text focuses more on the surgical therapy of obesity than medical treatment options. As such, it also focuses largely on the individuals of the obese population that are surgical candidates. Table 27-1 defines the categories of obesity that we follow in this chapter. The term *severe obesity* will be used in preference to morbid obesity, as recommended by the National Institutes of Health (NIH) Consensus Conference



**TABLE 27-1: DEFINITION OF TERMS FOR OBESITY**

BMI 26–29.9	Overweight
BMI 30–34.9	Obese (class 1)
BMI 35–39.9	Obese (class 2)
BMI 40–49.9	Severely obese
BMI >50	Superobese

BMI, body mass index.

that also established the still adhered to guidelines for the indications for surgical therapy for obesity.<sup>6</sup> Arguments exist that, probably correctly, call for a reexamination of the data regarding bariatric surgery and revision of these quite old NIH guidelines, established long before laparoscopic surgery, and when vertical banded gastroplasty was still a commonly performed operation in the United States.<sup>7</sup>

Similarly, arguments have been voiced that BMI is not an adequately accurate predictor of health deficits related to obesity.<sup>8</sup> A highly muscular individual could have a high BMI but very little body fat, for example. Thus the risk to his or her health would not be nearly as great as the individual with the same BMI but high-body-fat content. While both such arguments have validity, and this is hereby recognized, barring the creation of newer NIH guidelines or the creation of a better and more easily calculated measure of obesity than BMI, this text accepts current use of current NIH guidelines and BMI as the gold standards for indications for bariatric surgery and measurement of obesity respectively.

## PATHOPHYSIOLOGY OF OBESITY

Obesity is a poorly understood disease. Currently much investigation is ongoing to try and determine the aberrancies that occur both at a cellular level and at the level of the intact individual to determine its manifestations. It is hoped that such research will provide insights as to treatments for the metabolic consequences of obesity, as well as treatments for the metabolic causes of it. Until such time, however, individuals who develop obesity are highly susceptible to also developing one or more of the medical illnesses associated with obesity. These are listed in Table 27-2. It is these comorbid medical problems that jeopardize the length and quality of the lives of individuals with obesity and especially severe obesity. It is estimated that a male who is severely obese from childhood will live an average of 12 years less than his nonobese counterpart, while for a woman the difference is 9 years.<sup>9</sup> There is some variability by race and sex as to the consequences of obesity on health. The consequence of being a male patient with severe obesity and its limitation of lifespan is shown in Table 27-3, which gives the percentage of the population in the United States with severe obesity based on age and sex. Note that old males do not represent as high a

**TABLE 27-2: MEDICAL DISEASES ASSOCIATED WITH OBESITY**

General	Increased mortality risk Poor wound healing
Cardiovascular	Hypertension Hyperlipidemia Hypercholesterolemia Atherosclerosis Coronary artery disease Congestive heart failure Venous stasis disease Cardiomyopathy Left ventricular hypertrophy
Pulmonary	Obstructive sleep apnea Obesity hypoventilation syndrome Asthma Pulmonary hypertension
Gastrointestinal	Nonalcoholic fatty liver disease Gastroesophageal reflux disease (GERD) Cholelithiasis
Renal	Stress urinary incontinence
Musculoskeletal	Osteoarthritis Gout Back pain
Neurologic	Stroke Pseudotumor cerebri Carpal tunnel
Metabolic/endocrine	Type 2 diabetes Metabolic syndrome Infertility Polycystic ovarian syndrome
Neoplastic	Cancer of the esophagus, stomach, liver, pancreas, kidney, gallbladder, colon, rectum, uterus, cervix, ovaries, breast, prostate; multiple myeloma; non-Hodgkin's lymphoma
Other	Depression Hypercoagulable state Proinflammatory state Intertrigo Lymphedema

**TABLE 27-3: INCIDENCE OF SEVERE OBESITY IN THE UNITED STATES BY AGE AND SEX**

Age	20–39	40–59	60+
Male	3.3%	3.9%	1.7%
Female	6.4%	7.8%	5.6%

Data from Hedley, Ogden CL, Johnson CL, et al. Prevalence of overweight and obesity among US children, adolescents, and adults, 1999–2002. *JAMA*. 2004;291:2847–2850.

percentage of the population as females, largely because they are already dead of their comorbid medical diseases. Flum et al<sup>10</sup> showed that for males with Medicare insurance (and hence disabled if under age 65) undergoing bariatric surgery, the average mortality during the year after surgery was 6.4% for males age 18–65.

In addition to medical illnesses commonly associated with obesity, there is an increased incidence of certain types of malignancy in obese individuals. Cancers of the uterus, breast, prostate, and pancreas are all increased in this patient population.

Finally, among the major reasons for individuals to seek surgical therapy for severe obesity, lifestyle issues are often more important than medical problems. The loss of ability to perform common daily activities, the inability to participate fully as a parent, the lack of ability to perform on the job, and the social discrimination against obesity are all often cited by patients as the primary reason they seek surgical therapy for this condition.

Deciphering the likely multifactorial causes of the pathophysiology of obesity has given rise to several lines of investigation. Alterations of metabolism at the cellular level, genetic predispositions and patterns, and environmental influences all likely are active in contributing to the disease process etiology and mechanisms. The focus of this text is not on that subject, but a few observations from many years of clinical practice are offered. Certainly the alteration in satiety has to be forefront among the abnormalities in individuals with severe obesity. Appetite is often insatiable in these individuals, despite high-calorie intake daily. Body fat distribution is known to affect the incidence of comorbid problems. For example, the incidence of the metabolic syndrome is much higher in individuals with central obesity than those with pear-shaped body habitus. Higher amounts of organ fat and omentum are associated with conditions such as metabolic syndrome and diabetes. Genetic analysis of the different properties of adipose tissue is ongoing. Considerable investigation has been focused in the past 5 years on the mechanisms of rapid improvement of type 2 diabetes after Roux-en-Y gastric bypass. Such mechanisms almost certainly involve alterations in glucose metabolism by peripheral tissues based in turn on the altered pathway of food through the upper gastrointestinal tract. This gut influence on glucose metabolism is now under intense scrutiny. Hopefully one day the mechanisms of appetite regulation, satiety, and metabolism of adipose tissue will be better understood. When they are, perhaps we will have a better understanding of the complex disease process that is obesity.

## MEDICAL THERAPY FOR OBESITY

All individuals with the problem of obesity need to make modifications in their eating habits, lifestyle, and exercise habits as a lifelong commitment to overcoming the disease. For individuals with class 1 obesity, such modifications have the possibility of altering weight and in turn altering the

health risk of comorbid medical problems enough to make a difference in the toll that comorbid medical problems take on their life and health. However, as the amount of obesity increases, modest weight loss from medical therapy is less likely to make a profound difference in health. It is also less likely to be successfully sustained. The figure generally given for the likelihood of a severely obese individual successfully losing enough weight by dieting to become only obese or overweight is approximately 3%. In short, medical therapy is highly unlikely to be successful in reversing the problems of severe obesity. Nevertheless, because medical therapy has little risk involved (except the time lost from the benefit of potentially more effective therapy), it is uniformly agreed that a trial of medical therapy should occur first in any individual with morbid obesity prior to the use of surgical therapy. Unfortunately, this practice is not data-driven, but driven instead by the practicality of attempting the less risky and invasive therapy first prior to one that is more invasive. In reality, there are extraordinarily few patients who seek bariatric surgery who have not had multiple attempts at dieting during their lifetime. The motivation of those few individuals who have never dieted must be questioned, as they often perceive of surgery as a “magic bullet” which will eliminate obesity but not require any other changes in eating habits or lifestyle to produce or sustain these effects.

The role of medical therapy in the sense of dieting, exercising, and otherwise attempting to control weight by nonsurgical means is often not addressed further in texts on bariatric surgery beyond the simple statement that it is effective therapy in a minority of cases. However, it is our opinion that no surgical therapy can hope to have long-term effects without an accompanying change in eating and exercise habits by the recipient of the operation. Even the most effective bariatric operation can have its weight loss benefits mitigated over time by the patient who will not adapt better eating and exercise habits. Fortunately, the physical and mental metamorphosis that accompanies the postoperative period after bariatric surgery is usually profound enough in most patients to reinforce the need to make such changes to preserve this alteration in body habitus and health. The typical mindset of the long-term successful postbariatric surgery patient is that he or she will never allow themselves to go back to being severely obese again, now that they have been given the chance to be relatively normal in weight, had their medical diseases go into remission, and enjoy a lifestyle free of the burdens of obesity. Such a mindset is usually successful in maintaining the benefits of bariatric surgery. When patients do not have enough metamorphosis or if they regress to poor eating habits and stop exercising, erosion of the benefits of the operation is inevitable and they eventually join the estimated 30% of patients who regain weight and ultimately are considered to have failed bariatric surgery. The exact formula for bariatric surgery success is not well defined, but it includes selection of a motivated patient, success of the operation to produce significant physical, mental and medical changes, and the persistence of the patient in maintaining exercise and diet habits to preserve these changes. Thus surgical therapy

is truly only part, though the pivotal part, of the long-term success of therapy for the patient with severe obesity. Attention to the follow-up of patients, maintaining motivation to sustain appropriate exercise and diet habits, and any other such supportive measures that can be done postoperatively can all help ensure long-term success of bariatric surgery. In this sense, the “medical” treatment of obesity is quite important as an adjunct to maintaining the benefits achieved by surgical weight loss.

## SELECTION OF PATIENTS FOR BARIATRIC SURGERY

The basic guidelines generally adhered to for performing bariatric surgery were defined by the NIH Consensus Conference in 1991.<sup>6</sup> Eligible patients must have a BMI of greater than or equal to 40 kg/m<sup>2</sup> or a BMI of greater than or equal to 35 kg/m<sup>2</sup> and the presence of a disease caused by or exacerbated by obesity such as diabetes, hypertension, or other comorbidities. Beyond these basic criteria, most centers advocate that the patient have the ability to understand the planned procedure and the major changes it will cause in eating and the required changes in diet and exercise to optimize results. The patient should be appropriately motivated. Areas less well defined, but which usually have some limitations from center to center, include age, upper limit of weight, substance abuse, psychiatric history and problems, compliance problems, ambulatory status, and severity of comorbid medical conditions.

While all patients should be given information on the types of available operations, some operations may be more appropriate or effective or feasible as the procedure of choice for a patient, depending on the individual circumstances. The expertise and ability of the bariatric surgeon is another factor that affects operative choice for many patients. The relative advantages and disadvantages of the various operative procedures are discussed within their following respective sections.

Unfortunately, often the operative procedure that a patient undergoes for weight reduction is governed by the procedures that his or her insurance company will cover. Access to surgery for patients is currently limited by numerous factors. Many insurance companies have set a variety of preoperative requirements for patients otherwise medically qualified for bariatric surgery. These include the need to follow a medically supervised diet for 3–12 months, the need for a psychological evaluation, and other measures. Available evidence suggests that these requirements add no benefit to operative outcomes, and if anything delay potentially helpful surgical intervention.<sup>4,11</sup> Their presence does serve as a deterrent for patients who may not be fully motivated or otherwise do not have the ability to meet these additional requirements. Some insurance companies will require a psychological evaluation, for example, but not cover the cost of such an evaluation.

Information about bariatric surgery and the availability of bariatric surgeons to the public as well as to the referring physician is now much more easily obtained than even a decade

ago, and certainly much more available than two decades ago. Internet websites of bariatric societies, physician provider networks, hospital providers, and others all offer information on available surgeons. Use of search engines will usually produce surgeons in a prospective patient’s geographic area.<sup>12</sup>

Access to care is still an issue for some patients with certain forms of insurance coverage. Some patients have policies that exclude bariatric surgery. Others have policies that include it only if the patient or their employer pays a significant fee for a rider to the policy. Even if a patient has coverage, some insurance policies, such as Medicare, reimburse the surgeon at such a low rate that only surgeons serving on the staff of public health care institutions will offer surgical care to such patients.

Once a patient is seen by a bariatric surgeon who will offer surgical services, the choice of operation is usually determined by a combination of any insurance restrictions, procedures offered by that surgeon, and patient interest. Medical comorbidities and conditions can affect operative choice as well. Limitations of indications of the various bariatric operations in terms of efficacy and overall outcomes and effectiveness are discussed with each individual operation in the following text.

## PREOPERATIVE PREPARATION

Patients who are preparing for bariatric surgery need preparation for surgery in two major areas:

1. Specific knowledge about the planned bariatric operation and its expected outcomes, course, and potential complications and side effects
2. General preparation for a major surgical operation, including maximization of treatment of existing comorbid medical problems

Specific knowledge of the planned bariatric operation allows the patient to prepare for the changes in diet, lifestyle, daily activities, exercise patterns, and body image that will occur after the operation. *No bariatric operation will produce optimal long-term results without significant changes in diet, exercise, and lifestyle by the patient.* Hopefully, the combination of the power and durability of the operation to force an effective change in eating patterns, a decrease in appetite, an increase in satiety with eating, and a change in exercise patterns by the patient will serve to create an adequate metamorphosis of the patient and his or her lifestyle to promote a mindset that is strong enough to sustain these changes and resist any intrinsic genetic or behavioral tendency for recidivism to previous eating patterns that resulted in the preoperative morbidly obese condition. This alteration of the patient’s physical and mental state of being is inherently necessary for the long-term success of bariatric surgery. Fortunately, such an alteration is achieved and sustained in the majority of patients who undergo bariatric operations. A frequently heard quotation from patients who are years out from bariatric surgery and who have successfully maintained weight loss and reversal of their comorbid



medical conditions associated with obesity is, “I will never go back to being the way I was before.”

While not essential, personal interaction by prospective patients with other patients who have successfully undergone the same bariatric operation they are planning to undergo can be very helpful in terms of reassurance for likely success, as well as information exchange. The more the prospective bariatric patient is educated and familiar with the expected postoperative course of events, the more likely they will be to have less preoperative anxiety and more compliance with recommended postoperative treatment plans. Such interactions can be facilitated by support groups, Internet chat groups, and personal relationships. The surgeon and his or her staff should always inquire as to the support network available to the patient after surgery and their potential interaction with other individuals who have undergone the same operation. In our practice, we become concerned when a patient is pursuing bariatric surgery in opposition to the wishes of their family and/or spouse. While such patients may be strong-willed enough to do well postoperatively, if any complications result, there is often a significant adverse reaction by the family in these circumstances. Certainly the patient’s wishes should always prevail, but a word of caution in such situations is in order.

## LAPAROSCOPIC ADJUSTABLE GASTRIC BANDING

Procedure-specific preparation prior to surgery is always indicated. For patients planning to undergo Lap-Band (Allergan, Inc., Irvine, CA) procedures, we have found the following list of criteria tend to produce the optimal results after this operation:

1. Patient is able and willing to undergo the recommended schedule of band adjustments. This includes the coverage for such adjustments by their insurance carrier. Lack of such coverage inevitably leads to decreased compliance with suggested follow-up, and often less optimal results.
2. Patient is able and willing to undergo a regular exercise regimen. Our experience shows a strong correlation between exercise and postoperative weight loss for patients undergoing laparoscopic adjustable gastric banding (LAGB).
3. Patients expected and optimal weight loss is in the 100 lb or less range. We have found, and the literature supports, the fact that patients whose weight is over approximately 350 lb, and who have a BMI over 50–55, have a less optimal outcome after LAGB than those who have lower preoperative BMI and expected weight loss.
4. Patient can maintain a “dieter’s mentality”. This is usually documented by the fact that the patient has had at least one previous episode in their life of successful dieting, sustained over greater than 6 months. While the obvious fact is that such a diet did not have long-term effectiveness due to the patient now planning LAGB, the fact that LAGB is a relatively, but not overwhelmingly, powerful suppressant of appetite in patients makes this requirement important.

The patient who can diet successfully without any appetite suppression is likely to be able to maintain an appropriate eating pattern after LAGB, which suppresses but does not eliminate appetite in most patients.

5. The Lap-Band is an excellent operation for the patient whose BMI is 50 or less, and who has no severe comorbid condition better treated by an alternative operation (such as severe diabetes better treated with a gastric bypass). Patients who have a BMI over 50 may do well with a Lap-Band, provided they do exercise and the band provides adequate suppression of appetite to alter eating habits. Most series in the literature reporting LAGB outcomes have either a limited number of patients with BMI over 50 or have a decreased success rate of the operation in that patient population.

## LAPAROSCOPIC ROUX-EN-Y GASTRIC BYPASS

1. Patients who choose this as their bariatric operation of choice must be prepared to undergo a significant change in their eating pattern and ability. Laparoscopic Roux-en-Y gastric bypass (LRYGB) is a very powerful operation, usually eliminating appetite in most patients for a period of at least several months and altering the ability to intake food volume dramatically in most cases. Patients who rely on food as a significant psychological crutch may find the altered eating pattern forced on them to be a particular problem. However, most often the patient is delighted by the elimination of appetite and the rapidity of weight loss with concurrent resolution of comorbid medical conditions.
2. Patients planning LRYGB must understand that the operation will intrinsically limit their ability to absorb the critical nutrients of iron and calcium.
3. LRYGB is now the most commonly performed bariatric operation in the United States, and for good reason. The operation has the longest track record of continuous use, having first been performed in the late 1960s in slightly different form and of course using an open surgery approach in those days. Modifications to the operation have improved it, but not changed the basic essence of a largely restrictive operation with reduction in the gastric reservoir capacity to a minimal volume. In addition, the gastrojejunostomy of the proximal gastric pouch eliminates the pyloric sphincter’s regulation of slowly delivering food to the small intestine, resulting in variably profound dumping syndrome in these patients. While the dumping is often ameliorated with time, its initial presence usually is instrumental in forcing a behavioral modification in eating habits by patients, which involves the avoidance of highly concentrated sweets in their diet.
4. Other benefits generated by the anatomic alteration of the gastric bypass include a profound improvement in insulin sensitivity in patients with type 2 diabetes due to elimination of food substances passing through the duodenum. Gastroesophageal reflux disease (GERD) is also resolved in over 90% of patients after gastric bypass, because the

volume of available gastric acid or secretions from the diminutive proximal gastric pouch is minimal. The operation thus is particularly indicated or effective for severely obese patients who suffer from GERD or type 2 diabetes.

5. It is an effective operation for the patient who needs to lose a significant amount of weight and is not a candidate for a malabsorptive operation. Overall, gastric bypass avoids the majority of the metabolic complications inherent in malabsorptive operations, yet is powerful and durable enough to provide good weight loss even in superobese individuals.
6. Gastric bypass has few contraindications. It does limit iron absorption, so it may not be a good choice for the patient with preexisting significant iron deficiency anemia. In populations where there is an appreciable incidence of gastric cancer, it may also not be a good choice as it eliminates the ability to monitor the majority of the stomach for potential development of that disease.
7. Performing gastric bypass using a laparoscopic approach has resulted in drastic reduction in the most common postoperative complication after open Roux-en-Y gastric bypass (RYGB)—that of incisional hernia. Wound infections are less severe. Benefits established for laparoscopic versus open operations of other types also apply to LRYGB, such as quicker return to normal activities, decreased pain, and so forth.

## LAPAROSCOPIC SLEEVE GASTRECTOMY

1. The laparoscopic sleeve gastrectomy (LSG) is the most recent addition to the armamentarium of operations used by bariatric surgeons. Its adoption as a commonly performed operation is only evolving. Few centers had a large experience with the operation more than 3 years ago. The longest published follow-up data in the literature show only a small number of cases followed out to or beyond 5 years. The operation is, as with all primary bariatric operations, optimally performed laparoscopically, hence LSG.
2. LSG is a restrictive operation. It is technically easier to perform, in general, than LRYGB and avoids the risk of two anastomoses. It is more invasive than LAGB, as it involves resection of the majority of the stomach. Data to date show that the operation has a risk profile between that of LAGB (safest) and LRYGB for frequency of potentially severe complications.
3. Not all insurance companies currently cover LSG. Federal insurance and some other major private insurance companies still do not provide coverage for this operation.
4. The LSG originally had its birth as the first of a staged procedure to perform a laparoscopic duodenal switch (LDS) operation with less morbidity. Original experience with LDS showed a higher mortality rate than expected. LSG was then adopted as the first stage of the operation, to be followed by the malabsorptive component after initial weight loss.<sup>13</sup> The success of the LSG caused many patients to decline the second step and led to the adoption of LSG as a primary procedure.
5. Concerns still remain among experienced bariatric surgeons that this operation bears a strong resemblance anatomically and functionally to the vertical banded gastroplasty, which was a very popular bariatric operation two to three decades ago. It has been largely abandoned for poor long-term weight loss results.
6. Candidates for LSG would be patients appropriate for a restrictive operation of almost any weight class above or including class 2 obesity. Because its initial use was in higher-weight individuals felt to be candidates for the DS procedure, LSG is technically feasible on very large patients, a positive factor from the bariatric surgeon's viewpoint. Published data show LSG is also effective as a primary operation for patients with BMI less than 50.<sup>14,15</sup>

## LAPAROSCOPIC DUODENAL SWITCH

1. This operation has been the least frequently performed of the commonly approved and accepted bariatric operations. It is technically the most challenging of the bariatric operations and is associated with both the highest durable weight loss as well as the highest frequency of complications, especially when metabolic complications are considered as well.
2. Laparoscopic duodenal switch (LDS) causes relative malabsorption of fats and proteins. Fat-soluble vitamins as well as the elements iron and calcium are not well absorbed. Supplements to replace these vitamins and minerals are indicated postoperatively. These supplements can be expensive.
3. Patients undergoing malabsorptive operations require close and long-term follow-up, due to the high potential for metabolic deficiencies and problems that may arise after such procedures.
4. Another malabsorptive operation, the biliopancreatic diversion (BPD), is now less frequently performed than the duodenal switch (DS), due to its higher incidence of marginal ulcers.<sup>16</sup> Both operations involve comparable rearrangement of the alimentary tract distal to the duodenum, with the gastric resection for BPD being distal, while for DS it involves the greater curvature.
5. Most patients who are felt to be candidates for LDS are those with higher weights initially, who are felt to likely not achieve adequate weight loss with a restrictive operation alone. Patients with preoperative BMI over 60 certainly should be considered for such procedures if the patient is able to be closely followed and is willing and able to take required nutritional supplements. Patients interested in the most effective operation for large amounts of weight loss who are willing to accept the increased risk profile are candidates for LDS.
6. The technical difficulty of this operation as well as the concern for follow-up requirements has limited its performance to only certain centers specializing in this procedure or centers where it is offered as a choice among other bariatric operations.

## OPERATIVE DESCRIPTIONS AND OUTCOMES

### Laparoscopic Adjustable Gastric Banding

Laparoscopic adjustable gastric banding (LAGB) for the treatment of morbid obesity was first described independently by Kuzmak in the United States and Halberg and Forsell in Sweden.<sup>17,18</sup> The band is an inflatable silicone balloon placed around the proximal stomach connected by thin tubing to a reservoir implanted subcutaneously usually on the abdomen. The reservoir is accessed via a noncoring needle to adjust the diameter of the balloon. In 2001 the Food and Drug Administration approved for use the one band currently marketed by Allergan called the Lap-Band, and subsequently the Swedish band was added in 2007, which is now marketed by Ethicon and called the Realize band. The bands can be placed either laparoscopically or open although most authors will argue for the laparoscopic route. Recently the FDA also approved the use of the Lap-Band for use in patients with a BMI 30–35 with comorbid medical problems or a BMI greater than 35 without comorbid medical problems.

### OPERATIVE PROCEDURE

The preoperative evaluation and indications are similar for any bariatric operation and are described previously in the chapter. The patient should receive appropriate perioperative antibiotics as well as deep venous thrombosis prophylaxis. The patient will need to be positioned comfortably on the operating table with care taken to ensure the patient cannot slip when placed into steep reverse Trendelenburg's position.

Port number and position vary among surgeons. We describe what works in our practice. The pneumoperitoneum is established in the left upper quadrant, at the midclavicular line, one hand breath below the xiphoid. We prefer to use a Veress needle through an incision just large enough to admit a 15-mm trocar. We elevate the fascia with a tracheostomy hook that facilitates insertion of the needle into the appropriate space. Alternatively, access can be gained with an optical viewing trocar; this is again dependent on surgeon experience and preference. Once pneumoperitoneum is established, the abdomen is inspected for any evidence of injury. Additional trocars are placed. We place a 12-mm port for the camera in the midline approximately 15 cm from the xiphoid. A 5-mm port is placed in the right upper quadrant for the surgeon's left hand. A 5-mm port in the left upper quadrant is placed for the assistant and a port in the epigastrium is placed to assist in retracting the left lobe of the liver (Fig. 27-1).

The patient is placed in steep reverse Trendelenburg and dissection is begun with either the hook cautery or a harmonic scalpel at the angle of His. The peritoneum over the left crus and the gastrophrenic ligament is opened, and the dissection is carried down into the retrogastric fat. The gastrohepatic omentum is then opened in its avascular area, the *pars flaccida*. This allows exposure of the base of the right crus. If a

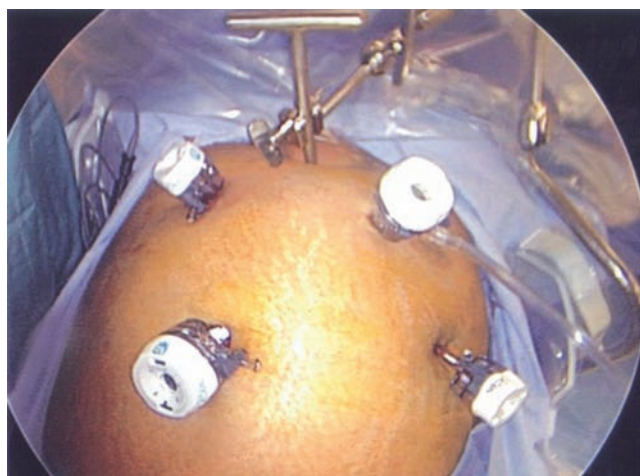

FIGURE 27-1 Port positions for laparoscopic adjustable gastric banding (LAGB).

hiatal hernia is appreciated, it should be repaired at this point and a standard posterior esophageal dissection is performed with suture closure of the crura. If no hernia is found, the peritoneum over the right crus is incised just wide enough to allow a grasper (Lap-Band) or the gold finger (Realize band) to pass (Fig. 27-2). It is important to note that these instruments should pass into the left upper quadrant in the previously dissected space with ease; any resistance indicates a wrong dissection plane. The grasper is passed just cephalad to the attachments of the proximal stomach to the retroperitoneum, thus remaining outside the lesser sac. Positioning the band in this space has decreased posterior slippage or prolapse of the gastric band. Once the instrument is visualized in the left upper quadrant, the band is placed into the abdomen through the 15-mm port. The tubing or suture is grasped and pulled through behind the stomach, pulling the band into place posteriorly (Fig. 27-3). The band is then buckled into its

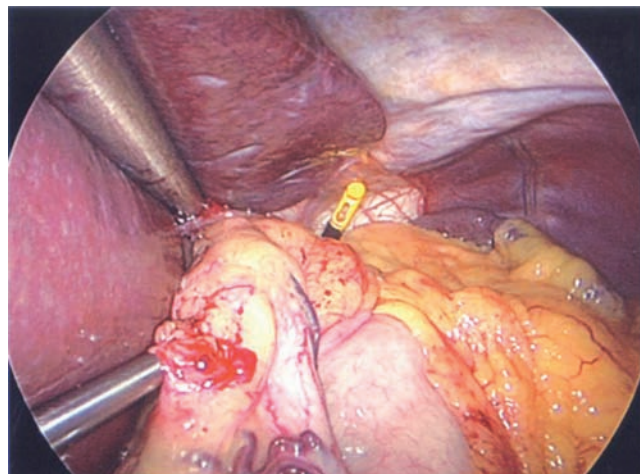


FIGURE 27-2 Passing grasper behind stomach.



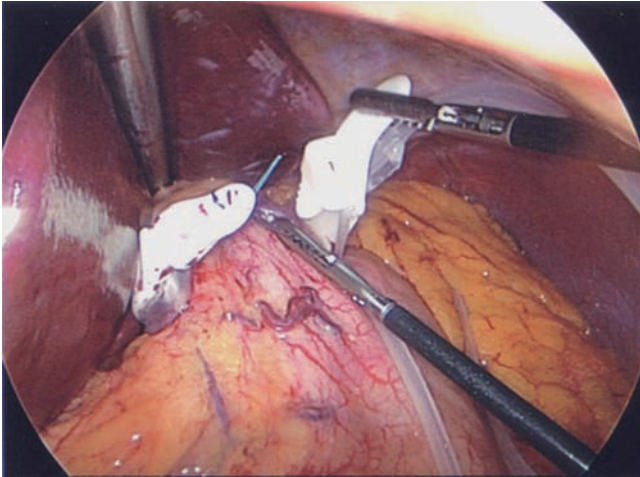


FIGURE 27-3 Pulling band into place.

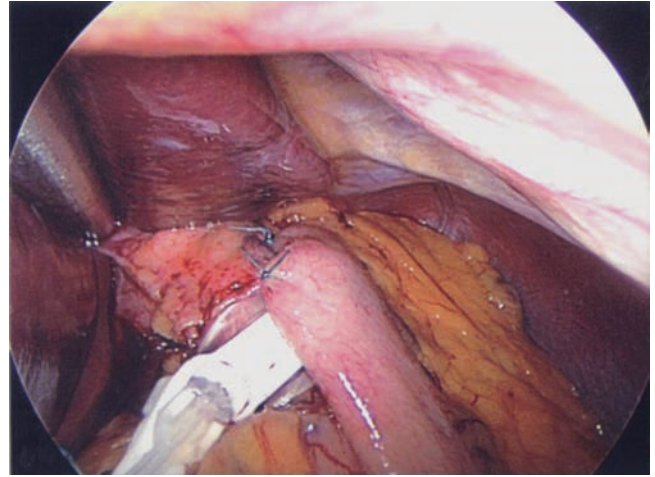


FIGURE 27-5 Suturing fundus imbrication sutures.

ring configuration (Fig. 27-4). Gastrogastric plication sutures secure the anterior fundus to the small portion of the stomach (optimally about 1–2 cm) above the band (Fig. 27-5). Usually two to three sutures are sufficient. It is important to not cover the buckle of the band as this may lead to band erosion. The tubing is removed from the abdomen through the epigastric or 15-mm port, depending on the surgeon's preference, and attached to the reservoir port. The reservoir port is secured to the abdominal wall fascia (Fig. 27-6). It is important to place the port in as thin a portion of the abdominal wall as possible to facilitate future access. The band system is accessed percutaneously with a Huber needle (Piwanja Technologies Pvt. Ltd., New Delhi, India) to add and withdraw to confirm reservoir capacity and rule out leakage. All fluid is then removed from the reservoir at the end of the procedure, to be added later in adjustments postoperatively. It is recommended to begin with the band system empty so as not to have too much restriction initially for the patient.

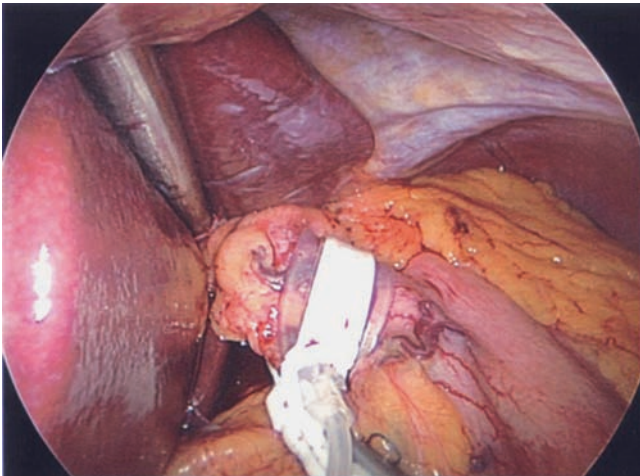


FIGURE 27-4 Buckling band.

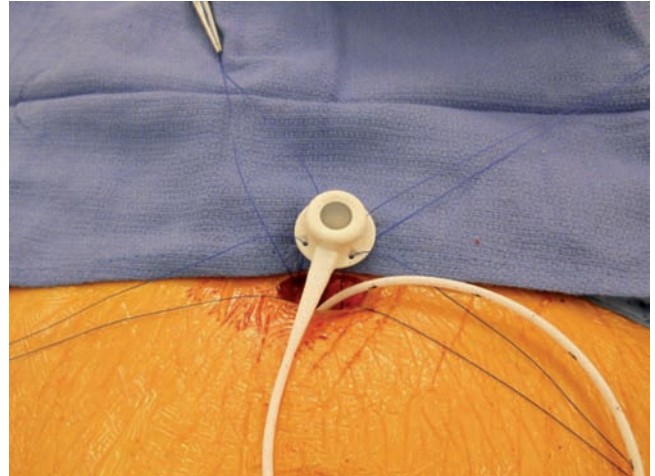


FIGURE 27-6 Securing reservoir to fascia.

## POSTOPERATIVE CARE

The LAGB is now primarily performed as an outpatient procedure, unless medical or insurance issues require an overnight stay. Preoperatively and prior to discharge, the patient as well as family members should receive instructions on diet, activity, and pain medications. Instructions should be given on when and whom to call in case of emergencies. The patient is discharged on a liquid diet for 2–3 weeks. We usually see our patients back at this time to check the wounds and advance the diet. The diet is advanced to a soft diet and medications are checked as well as comorbidities. A multivitamin is recommended as sufficient supplementation as LAGB does not cause nutritional deficiencies seen in other bariatric procedures. Patients are often ready to return to work, if they have not done so already.

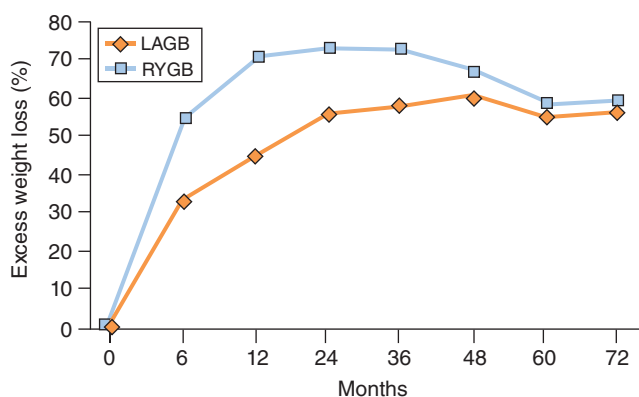
The success of LAGB depends on adjustments, adherence to dietary changes, and exercise. The timing of adjustments varies among surgeons; however, there is wide agreement that

the goal rate of weight loss is 1–2 lb/wk. Less weight loss, later satiety, or larger meal size are indications that an adjustment may be in order. This is done after careful evaluation of the patients' weight, dietary history, and exercise.

Band adjustments are typically office-based minor procedures. On occasion fluoroscopic assistance may be required to access the port or evaluate the restriction of the band. There are several adjustment algorithms, with the amount of fluid added based on hunger, weight loss, ability to eat bread, and type of band.<sup>19</sup> This is an area that is frequently more art than science.

## OUTCOMES

Outcomes after LAGB are generally good in terms of weight loss and resolution of comorbidities versus significant adverse problems. The average weight loss for the larger series in the literature is usually reported for % excess weight loss (%EWL) at 1, 2, or multiple years after surgery. Generally speaking, patients undergoing LAGB will have a slower weight loss curve and take longer to achieve maximum weight loss than patients with either RYGB or LSG or DS. Figure 27-7 illustrates the weight loss curve for one such series.<sup>20</sup> The %EWL at two years after surgery has been reported in the 45–55% range from various authors.<sup>21–23</sup> Resolution of medical comorbidities is certainly seen after LAGB. Perhaps the most heralded study on this topic is the prospective randomized trial by Dixon et al<sup>24</sup> in which the group of patients with type 2 diabetes showed a 73% remission rate of their disease 2 years after undergoing LAGB, as opposed to the control group that had a very low resolution rate. Other comorbidities are improved as well after LAGB and generally correlate with successful weight loss.



**FIGURE 27-7** The percentage of excess weight loss after Lap-Band surgery and a comparison of Roux-en-Y gastric bypass (RYGB). Data include all published series with initial recruitment of at least 50 patients reporting data at least 3 years or more following surgery. There were eight RYGB studies and seven laparoscopic adjustable gastric banding (LAGB) studies. (From Dixon JB, O'Brien PE. Laparoscopic adjustable gastric banding: outcomes. In: Schauer PR, Schirmer BD, Brethauer SA, eds. *Minimally Invasive Bariatric Surgery*. New York, NY: Springer; 2007:190.)

Optimal outcomes for patients with LAGB seem to be correlated with frequent band adjustments, participation in support groups, and regular physical exercise.<sup>25</sup>

## COMPLICATIONS

Complications following gastric banding include prolapse or slippage, erosion, port or tubing complications, over-filling of the band, esophageal dilation, and weight loss failure.

Prolapse or slippage is the most common complication requiring reoperation. The mechanics of the process are that too much gastric tissue from below the band lumen pushes up through the band circumference (prolapse) or, similarly, the band slips down on the stomach further than desired, resulting in too much stomach above the circumference of the band (slippage). The effect of both is similar: the excess tissue causes almost immediate complete food intolerance if severe, or heartburn and moderate food intolerance if not severe. New onset of GERD symptoms in an LAGB patient strongly suggests prolapse, which should be ruled out.

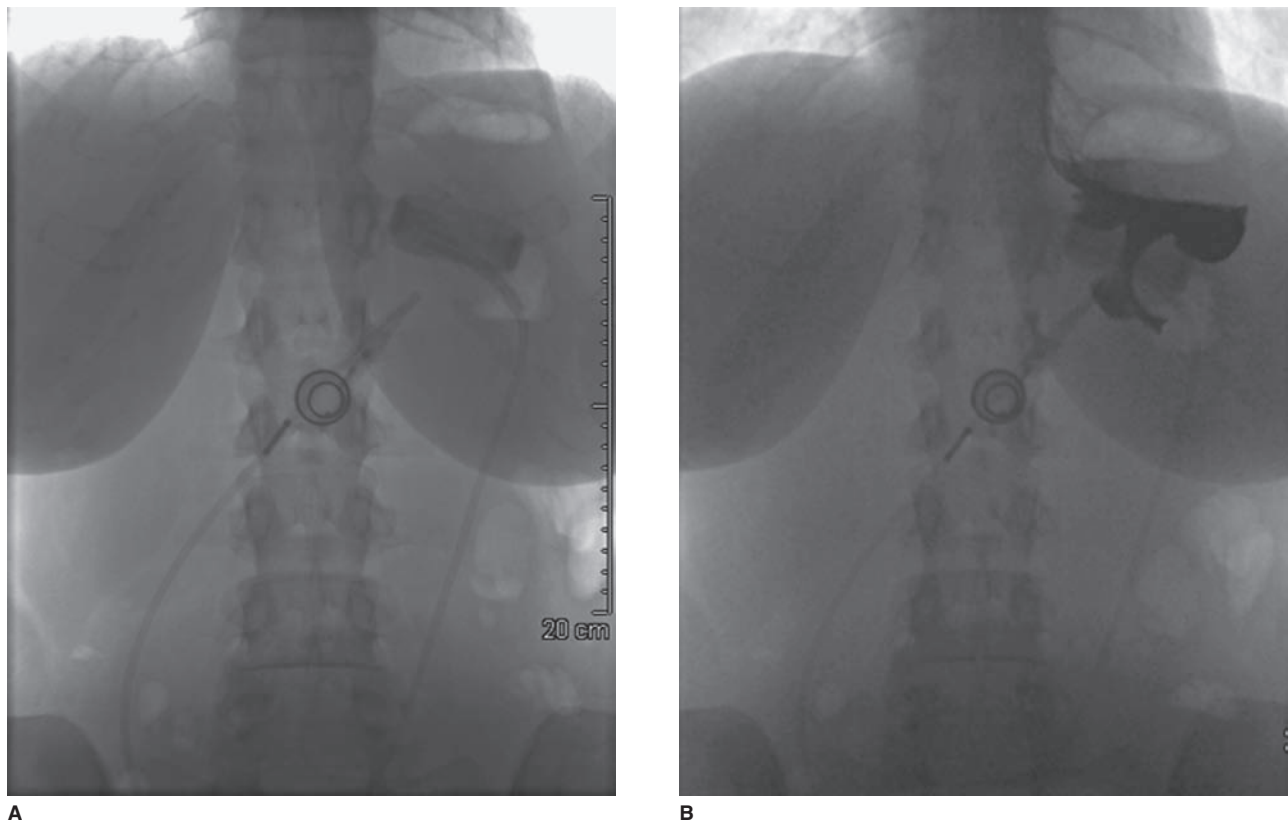
Diagnosis of prolapse begins with the above clinical picture. A plain radiograph will usually show the band in an abnormally horizontal position (Fig. 27-8A). Barium swallow will show a significantly greater amount of stomach above the band than would be expected, confirming the prolapse (Fig. 27-8B). The prolapse can be anterior or posterior.

Initial treatment of the prolapse is withdrawal of all fluid from the band. This will often allow the prolapse to spontaneously resolve. Radiographic confirmation of this can be performed. If symptoms persist and radiographic evidence shows persistence of the prolapse, operative intervention to reduce the prolapse is indicated. This can usually be done laparoscopically. Often, the band must be unbuckled to allow full reduction of the prolapse. Repositioning the band and resuturing the fundic plication to maintain its position complete the operation.

Band erosion is an uncommon problem, occurring in 1% or less of most large series.<sup>26</sup> Band removal and repair of the erosion, with appropriate antibiotic and supportive care, are indicated.

Esophageal dilation is perhaps one of the most severe complications that may result from LAGB. This complication arises when the band position is too high, restricting the distal esophagus instead of the proximal stomach. The incidence is in the 1–2% range in most series. Reflux, dysphagia, pain, and food intolerance may be presenting symptoms. Resultant dilation of the esophagus occurs. Esophageal motor dysfunction may occur if the condition becomes longstanding. Treatment for the problem, once discovered, is to immediately remove all fluid from the band, minimizing the restriction and obstruction. Hopefully this will reverse the dilation of the esophagus, and restore function. Band repositioning may be needed to prevent recurrence of the problem.

Port and tubing problems occur from 2–5% in most series.<sup>26</sup> These are usually issues that can be repaired with procedures under local anesthesia or limited intervention under general anesthesia. Repositioning the reservoir that tilts to a



**FIGURE 27-8** **A.** Picture of a plain film of a prolapsed band with the port flat. **B.** Picture of UGI showing band prolapse.

position that does not allow access is a not uncommon problem. Care in attaching the reservoir to the fascia at the index operation is the best prevention of this problem.

Band overfilling is usually an easily correctable problem. When the adjustment is done, the patient may not have immediate symptoms. However, dysphagia ensues within the next day, and persists. Removal of all or most of the fluid added from the last adjustment will usually promptly resolve the problem.

Poor weight loss is, unfortunately, a problem with all bariatric operations. However, some centers have experienced an unusually high incidence of poor weight loss in their LAGB patients. We have found that attention to the criteria listed previously for selection has decreased but not eliminated the incidence of individuals with poor weight loss. While our institutional band removal rate is well under 5%, there are well over 15% of our patients who have had poor weight loss (as defined by <25% EBW) after LAGB. Some centers in Europe, which have had over a 15-year experience in LAGB at this time, are reporting an increasing incidence of abandoning the use of LAGB because of poor long-term efficacy.<sup>27</sup> On the other hand, in Australia, LAGB is by far the main bariatric operation used, and the outcomes from that continent are generally the best published.<sup>28</sup>

Nutritional complications after LAGB are rare and are solely based on poor intake. LAGB does not alter the digestive process whatsoever, and hence there is no malabsorption

of any nutrients. A standard multivitamin supplement is all that is necessary for patients following LAGB.

## Laparoscopic Sleeve Gastrectomy

Laparoscopic sleeve gastrectomy (LSG) is the most recently recognized standard bariatric operation performed. The American Society for Metabolic and Bariatric Surgery recognized the procedure as being an appropriate standard operation for the surgical production of weight loss in 2009.<sup>29</sup> The operation is now rapidly increasing in popularity in the United States and is currently the third most common procedure performed (after LRYGB and LAGB). Insurance reimbursement is still not uniform for all carriers, which has likely limited its rise in popularity to some extent. It is predicted that recognition and reimbursement by all major insurers in the near future will lead to its increasing performance over the next several years. Midterm data are available in a few instances, but most of the reported results thus far for the procedure are short-term results. As with all bariatric operations, long-term data will solidify or nullify this operation's position as a standard bariatric operation in the years ahead.

Patient selection for LSG, described previously, varies widely based on surgeon experience and alternative operations available to the patient by the treating surgeon, as well as patient preference and insurance reimbursement capacity.



## OPERATIVE PROCEDURE

The patient is positioned supine, with adequate support of the feet and legs such that reverse Trendelenburg's position is safely possible. The operating table must have capacity to safely maneuver with the largest of patients on it; hence hydraulic control is essential. The surgeon stands on the patient's right side, the assistant on the patient's left side, and the camera operator adjacent to the surgeon, on his or her right. A suggested port configuration is given in Fig. 27-9. Port placement can be varied, however. There are reports now in the literature of single-port performance of this procedure, with three instruments being placed through an enlarged single umbilical port.<sup>30</sup>

The LSG begins by dividing the blood supply along the greater curvature of the stomach, beginning at a point approximately 5 cm proximal to the pylorus on the greater curvature of the stomach. The gastroepiploic vessels are divided as they come off the greater curvature of the stomach, proceeding from distal to proximal along the greater curvature. An ultrasonic scalpel or other specialized energy device is used; electrocautery is insufficient to secure hemostasis of these vessels (Fig. 27-10). The division of vessels continues with the short gastric vessels, until the top of the greater curvature of the

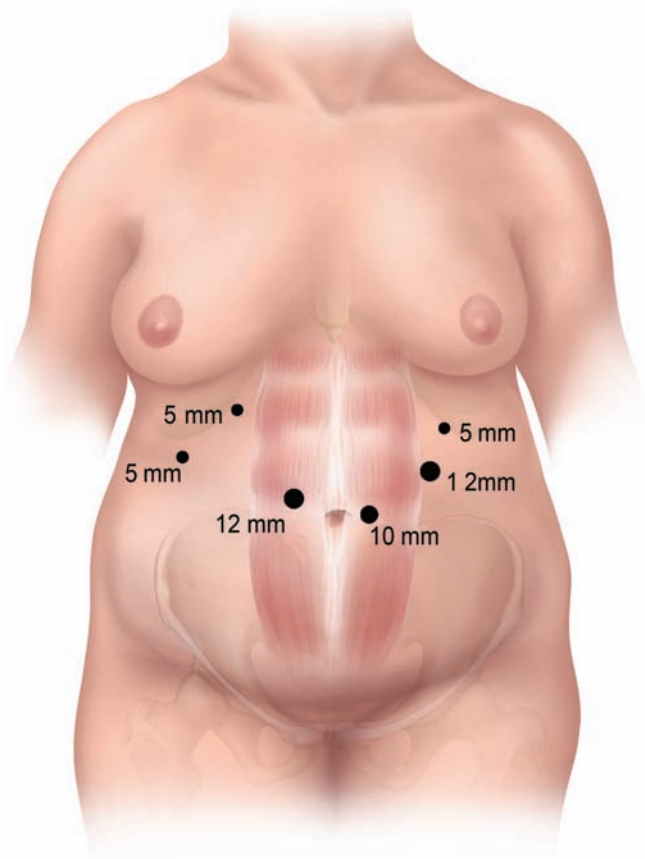


FIGURE 27-9 Picture of ports for laparoscopic sleeve gastrectomy (LSG).

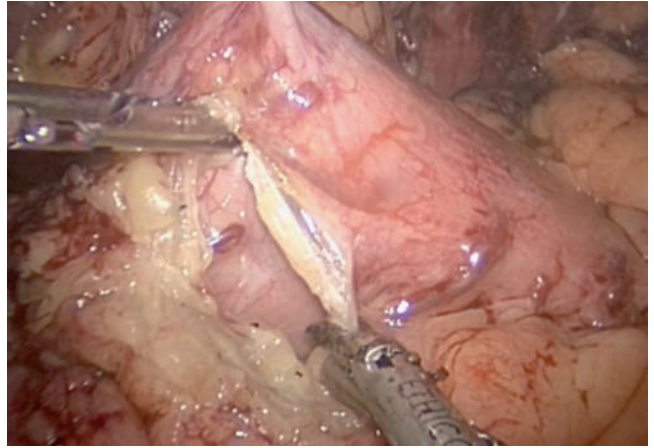


FIGURE 27-10 Dividing the greater curvature vessels during laparoscopic sleeve gastrectomy (LSG) with a harmonic.

stomach is reached and a complete devascularization of the greater curvature above the distal antrum has been achieved.

A bougie, dilator, or comparable space-occupying device (some surgeons prefer a flexible endoscope) is positioned along the lesser curvature of the stomach. This bougie may be in the 32–40F range, based on surgeon preference and experience. The smaller the bougie, the better the postoperative weight loss, but also the greater the potential for a stricture of the gastric channel. A linear stapler is now used to begin dividing the stomach. In the antrum area, the height of the staples used should be longer than in the upper stomach. Division of the stomach is begun from the area where devascularization was initiated. The stomach is divided adjacent to the bougie or endoscope, leaving only a relatively narrow tube of lesser curvature stomach to serve as the passageway for ingested food (Fig. 27-11). Care should be taken not to divide the proximal fundus portion of the stomach too close to the gastroesophageal junction and the angle of His. Devascularization of this narrow segment of tissue may produce

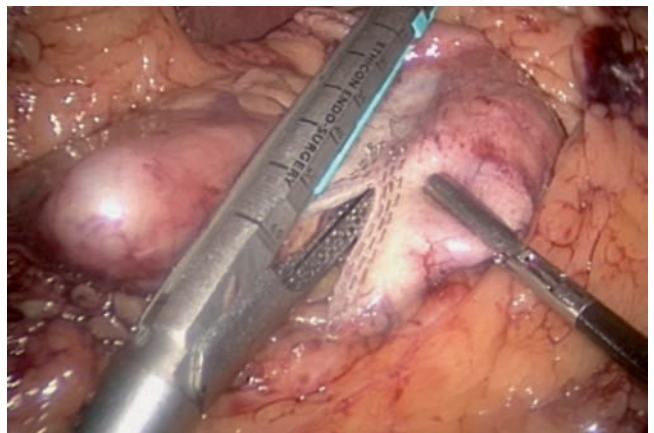


FIGURE 27-11 Stapling the stomach during laparoscopic sleeve gastrectomy (LSG).

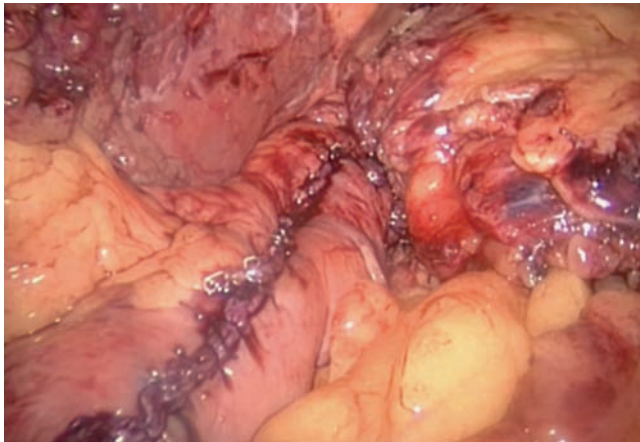


FIGURE 27-12 Completed laparoscopic sleeve gastrectomy (LSG).

an ischemic leak postoperatively, which is a difficult and persistent problem to heal. Some surgeons feel that staple line reinforcement material offers the advantage of decreasing bleeding and leakage, while others feel this is not established and the material is too costly. In either case, it is appropriate to take particular care to avoid the complications of staple line bleeding or leakage after surgery during the stapled division of the stomach. Similarly, stenosis must be avoided as well. The completed division of the stomach and thus the operation is pictured in Fig. 27-12. The devascularized piece of greater curvature stomach is removed through the largest of the ports in a laparoscopic bag. Intraoperative performance of a leak test is not uniform but often done by surgeons at the completion of the operation.

### POSTOPERATIVE CARE

LSG is normally performed as an inpatient procedure, though the stay in the hospital may be as short as 24 hours. Postoperative length of stay is often determined by the patient's medical comorbidities. Pain control is initially achieved with appropriate parenteral medications. Once oral medications are begun, usually within 24 hours, a liquid form of narcotic medication is preferred initially for pain control. Routine radiographic study on the first postoperative day is performed by many surgeons. Whether this becomes standard or optional is still controversial, as it is with LRYGB, which has a much longer history. Once the patient takes adequate liquid intake, has adequate pain control, and shows no signs of leakage, hemorrhage, or stenosis from the operation, they are discharged from the hospital.

Following LSG, patients must adhere to a liquid diet until they become accustomed to the restriction of the long and narrow gastric lumen. The length of such a liquid diet is variable, but usually in the 2- to 3-week range. Thereafter, initiation of soft followed by well-chewed solid food over the next few weeks ensues. Patients have a limited appetite due to the anatomic arrangement of the operation. This facilitates the diet and slow progression to solid food.

Follow-up for the first year should be frequently enough to detect problems of long-term stenosis, and occasional nutritional issues that may arise. Protein intake must be encouraged, and liquid protein supplements as well as dairy-related protein foods often serve as the initial largest component of protein intake. Later, once a larger volume of solid food is consumed, standard protein sources in the diet serve to meet protein needs. Vitamin B<sub>12</sub> needs supplementation for most patients in the long term, and levels should be checked beginning a few months after surgery. Iron intake, due to low intake of iron-rich foods, may need supplementation. A multivitamin is a standard recommendation for daily intake by patients. LSG is still in its early phases of follow-up, and thus far no other major nutritional deficiencies have been identified after the procedure.

### OUTCOMES

LSG has produced excellent weight loss as a primary bariatric operation. Reports in the literature show 1-year follow-up of 50–70% EWL.<sup>31,32</sup> Resolution of comorbidities has also been reported, and is excellent and mirrors the percentage of excess weight lost. Patient satisfaction with the operation has been reported to be very high as well.

LSG is currently in its “honeymoon” period as a bariatric operation. The short-term results have been excellent, overall, in most reported series. However, the operation does not have a long enough track record to determine what will be the long-term problems seen with the operation. Particularly, the incidence of weight regain or recidivism is not yet reported after this procedure. An anatomically similar operation, the vertical banded gastroplasty, relied on a shorter lesser curvature tunnel of stomach with a band to constrict outflow.<sup>33</sup> It too enjoyed immense initial popularity in the 1980s and, like LSG, was a technically easier operation to perform than a procedure like RYGB. During the 1980s, the vertical banded gastroplasty was the most commonly performed bariatric operation in the United States. However, long-term follow-up showed a high incidence of patients changing their diet to accommodate for the restriction, and eating a high-calorie liquid diet. Weight regain slowly resulted, and after a decade one institution reported the number of patients with still successful weight loss after vertical banded gastroplasty was under 25%.<sup>34</sup>

### COMPLICATIONS

Mortality for the operation has been under 1% in all major series and generally in the 0.2–0.3% range. Complications include bleeding, stenosis, and staple line leakage as problems arising soon after surgery, with overall short-term complication incidences reported in the range of 2–5%.<sup>29,35,36</sup> Stenosis, food intolerance, and reflux are the most commonly cited problems after the immediate postoperative period.

Treatment of postoperative hemorrhage may be difficult endoscopically, due to the tightness of the lumen of the gastric tube. Operative treatment may be needed if initial

conservative therapy with transfusions fails or hemodynamic instability occurs.

Leaks from the staple line are probably best treated initially with operative intervention to repair them. Depending on the circumstances, tissue quality, degree of peritonitis and soiling, a jejunal feeding tube may be appropriately placed for a safe site for enteral nutrition. Drainage of the repaired area is always indicated. Recurrent leakage may be amenable to endoscopic stent placement as treatment, depending on the lumen of the gastric pouch and the location of the leakage.

Stenosis of the gastric lumen after LSG is a difficult problem. Balloon endoscopic or fluoroscopic dilation is indicated as the initial treatment of choice if feasible. Few results have been published in the literature. The role of temporary endoscopic stents in treating this problem is also not established but potentially may prove effective.<sup>37</sup>

Longer-term problems of reflux and food intolerance have been reported, but the number of reports is still small and the relative frequency and severity of these problems have yet to be accurately determined.

Nutritional complications have not been reported with any significant frequency as of yet after LSG. Because most of the stomach is removed, it is anticipated that low vitamin B<sub>12</sub> levels and potential megaloblastic anemia and vitamin B<sub>12</sub>-related neuropathy could result from LSG. Other nutritional deficiencies would, based on the anatomy of the operation, need to arise from inadequate intake of nutrients, because there is no malabsorption associated with LSG.

## Laparoscopic Roux-en-Y Gastric Bypass

Laparoscopic Roux-en-Y gastric bypass is the most frequently performed bariatric operation in the United States. While there are many variations on the theme, there are certain defined characteristics and components of the operation that are common to all procedures bearing this name. The operative description below will favor our own approach at the University of Virginia, although the two coauthors of this chapter also have differences in their own techniques. Wherever possible, mention of common variations on each step of the operation will be included.

### PATIENT POSITIONING AND PREPARATION IN THE OPERATING ROOM

The operation is performed with the patient in the supine position, with the legs together. The surgeon gains little from operating between the patient's legs, and allowing the legs to be together and supported directly in line on the operating table decreases the potential for neural injuries to the legs if they were to be placed in any spread or supported position that would allow the surgeon to work between them. We also have found that the use of a footboard, large sponge cushion blocks to surround the feet, and taping those blocks securely to the operating table all allow the patient to be more easily placed into the reverse Trendelenburg position, which

is advantageous for the gastric portion of the operation. The supine position also likely results in less venous thromboembolism (VTE) than if the legs are apart and supported.

The patient is positioned initially supine for the intestinal part of the operation but later in steep reverse Trendelenburg's position for the gastric portion. Both arms are normally out to the sides for vascular access, and supported appropriately. It is key to place padding under the axillary/upper arm areas of extremely obese individuals, as the body is so massive that the arms are not supported adequately in the supine position.

Preoperative antibiotics, of an appropriate dose, are indicated. Normally a first-generation cephalosporin will suffice to cover the proximal gut floras that are potential pathogens in this operation. The severity of wound infections has dramatically decreased with laparoscopic surgery as compared to open surgery in the past.

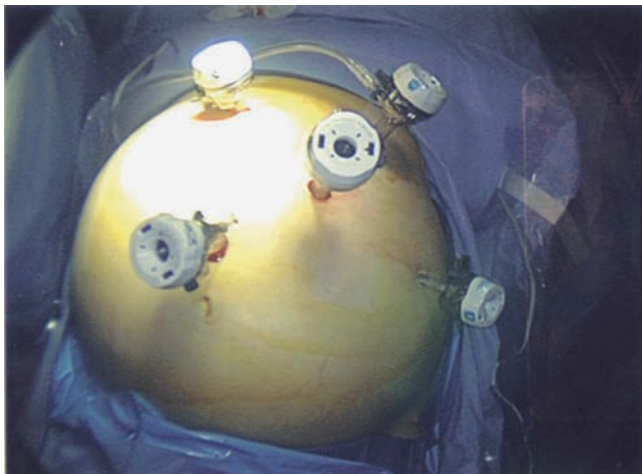
Prophylaxis against VTE is more controversial. Pulmonary embolism is one of the leading causes of death after bariatric surgery, and many surgeons use all measures feasible to decrease its incidence. This includes early ambulation after surgery. However, measures prior to surgery usually are at least foot or leg sequential compression devices or some form of heparin therapy. At our institution, after having had 1 year with a high incidence of VTE in the past, we use low-molecular-weight heparin subcutaneously, given just prior to the start of surgery, as well as sequential compression boots. Many papers have been written on this subject in the literature, without a clear consensus.<sup>38</sup> However, it is now the practice of most bariatric surgeons to use both mechanical and chemical prophylaxis against VTE. Very high-risk patients, such as those with a hypercoagulable state or who have a history of VTE, may be candidates for use of a temporary prophylactic inferior vena cava (IVC) filter as the ultimate measure of protection against pulmonary embolism.

Skin preparation is with a standard chlorhexidine or iodine-based solution, with coverage of the entire abdominal wall up to a level 2 in above the xyphoid.

### OPERATIVE PROCEDURE

**Pneumoperitoneum and Port Placement.** The pneumoperitoneum in the severely obese patient is best established, in our experience, using a Veress needle. A Hasson trocar has almost no place in bariatric surgery: it is difficult to make a deep incision to place it while maintaining tissue security around it to seal the pneumoperitoneum. Instead, using a standard tracheostomy hook to elevate the fascia produces an excellent countertraction of the abdominal wall that allows the Veress needle to penetrate the peritoneal cavity despite the thickness of the abdominal wall. The tracheostomy hook must continue to hold up the abdominal wall during the initial phase of insufflation, until there is an adequate pneumoperitoneum such that the tip of the Veress needle no longer touches any tissue or organs when this traction is released. Our preferred site of creation of the pneumoperitoneum is the left upper quadrant, near the costal margin, where the assistant will have his or her right hand 12-mm trocar port. This quadrant of the





**FIGURE 27-13** Port position for laparoscopic Roux-en-Y gastric bypass (LRYGB).

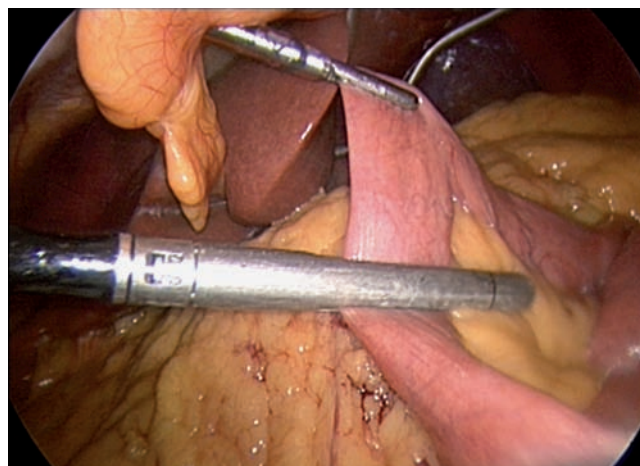
abdomen has, on average, the least amount of adhesions from previous surgery. If there has been surgery in this quadrant but not on the right, we will use a site in the right upper quadrant, where the surgeon's left-hand port is to be positioned. In super obese patients, a pneumoperitoneum pressure of 18 is often required for adequate visualization. Extremely thick abdominal walls may require extra long ports.

While there are a variety of port positions used for the performance of LRYGB, the configuration in Fig. 27-13 is our preference. The camera is placed through a port above the umbilicus, usually at the maximum of the "dome" created by the pneumoperitoneum. The ports are 12 mm for the surgeon's right and left hands and the assistant's right hand. These positions are chosen because of the ease and advantage of the angles created by these positions for firing the stapler during various steps of the operation. The assistant's left hand is a 5-mm trocar. At times, in extremely obese individuals, the addition of an extra port or two is needed. The intestinal portion of the operation may be difficult if the camera port is too close to the operative field. If this proves to be the case, we simply insert an additional port lower in the midline. The gastric stapling portion may also prove difficult, and the supraumbilical camera port may be very far from the operative field. In this situation, we do not hesitate to move the camera to the assistant's right-hand port, and add another 5-mm trocar higher up along the costal margin on the left for the assistant's right hand.

Liver retraction may be performed using one of several liver retraction devices. The T-Boone (Haynes and Boone, Dallas, TX) retractor, a simple tubular-shaped slightly curved piece of metal with a short cross bar, holds the left lobe of the liver out of the way adequately for most patients. Larger livers require the Nathanson retractor. The liver retractor is optimally placed in the epigastric region, high enough to be above the liver edge and hence hold the liver up when the retractor is inserted directly downward into the peritoneal cavity.

**Intestinal Portion: Creating the Roux limb.** This portion of the operation is begun by identifying the ligament of Treitz. This is only possible by having the omentum free from adhesions to other abdominal structures, at least for the midportion and left half of the omentum. Adhesions to the right lateral side wall can be usually ignored. Once the omentum is free, it is placed above the level of the transverse colon, and the transverse colon mesentery then grasped and elevated to help expose the ligament of Treitz. Once identified, the proximal jejunum is then divided between 30 and 50 cm distal to the ligament. The shorter the distance, the better iron and calcium absorption occur. However, longer distances are needed for larger patients where there is a greater distance to the proximal stomach and the Roux limb must therefore be able to reach more proximally. Generally, dividing the bowel at the 50 cm level provides a proximal end of the Roux limb that can reach the proximal stomach in even very large patients.

The jejunum is divided using one or two firings of the GIA-type stapler, using a white staple cartridge load. It is placed through the surgeon's right hand port, which gives a good angle for dividing the bowel (Fig. 27-14). The second staple load may often extend into the mesentery. This is helpful to begin increasing the mobility of the Roux limb. However, the division of the mesentery must continue in a direction directly downward on the mesentery, equally dividing the mesentery between the two segments of divided bowel. Straying to either side will cause ischemia to one of the bowel segments, requiring further resection back to viable tissue. The ultrasonic scalpel is used to continue the division of the mesentery below the staple load, carrying this division down to the root of the mesentery (Fig. 27-15). Care should be taken to apply slow application of energy in several adjacent points when dividing the major crossing vessels of the jejunal mesentery. Once the base of the leaflet of mesentery is reached, no further division should be attempted due to the



**FIGURE 27-14** Stapling the proximal jejunum in laparoscopic Roux-en-Y gastric bypass (LRYGB).

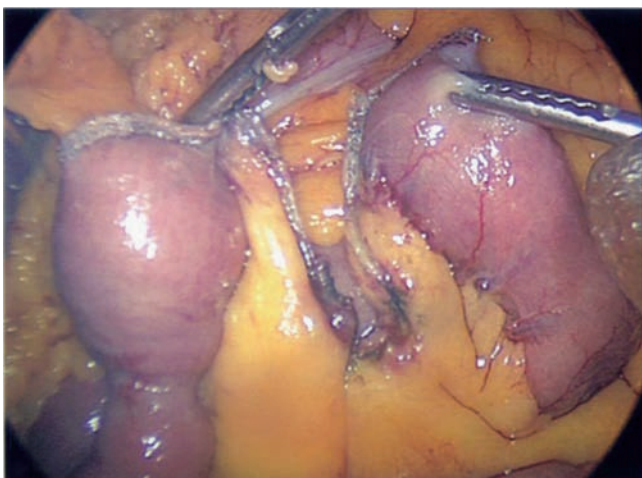


FIGURE 27-15 Harmonic division of mesentery of Roux limb.

risk of encountering major hemorrhage from vessels not easily controlled with laparoscopic energy devices.

The ends of the jejunum are assessed for viability. Any ischemic portion is resected back. Resected pieces of intestine are either removed directly now or placed in a specimen bag for later removal, depending on their size. If the end of the Roux limb is quite healthy, a 0.25-in Penrose drain is sewn to its end immediately (Fig. 27-16). If it needs resection, the drain is placed as soon as resection is performed. The end of the Roux limb should always be held by a grasper until the drain is attached. This is done to prevent any possibility of confusing the Roux limb with the biliopancreatic limb.

The proximal jejunum is now oriented adjacent to the ligament of Treitz, with its mesentery straight and pointed caudally. This leaves the stapled end of the biliopancreatic limb (the proximal jejunal segment) facing the camera and on the left of the operative field. The Roux limb is now measured for length. With experience this can be done by visual estimate,

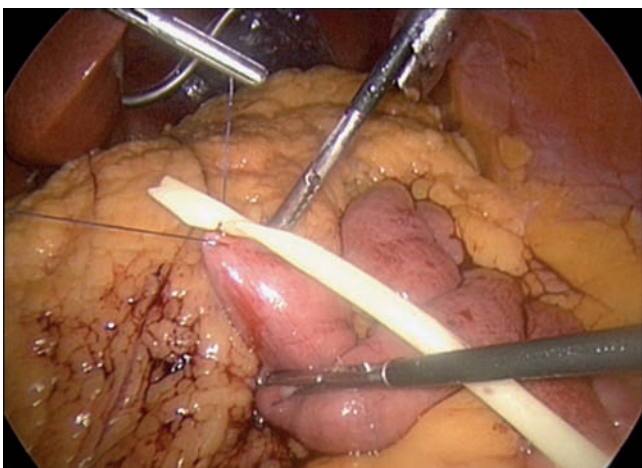


FIGURE 27-16 Sewing on Penrose drain.

but in the beginning the surgeon may wish to use an instrument or some marker that helps estimate intestinal length. As the Roux limb is measured, it is pulled up and to the right on the screen, or to the patient's left upper quadrant. In this way the mesentery of the Roux limb has a continuous bend in a counter-clockwise direction as the limb is being measured. We generally make our Roux limb lengths approximately 100 cm for the patients with a BMI of 40–50, 125–130 cm for patients with a BMI of 50–55, and 150 cm for a BMI over 55. Once the appropriate length of Roux limb is measured, that point is sutured to the biliopancreatic limb with a single suture on the antimesenteric side of the Roux limb connecting to the antimesenteric surface of the biliopancreatic limb about 6 cm proximal to its end.

**Enteroenterostomy.** The harmonic scalpel is now used to create enterotomies 1 cm distal to the suture holding the two segments of bowel together, on the antimesenteric sides of each segment of bowel. These enterotomies should be adjacent to each other. The white load 45-mm GIA stapler legs are now placed into each enterotomy from the surgeon's left-hand port, and the stapler is fully inserted into the bowel lumen, closed and fired (Fig. 27-17). A second white load is placed into the enterotomy site from the assistant's right hand, which usually is in a good position for the easy placement of the stapler in the opposite direction. The stapler is placed fully into the bowel lumen, which usually is just long enough to accommodate the upper leg in the short segment of the distal biliopancreatic limb. The stapler is closed and fired. We have found that this double-firing technique essentially eliminates the occasional issue of stenosis of this distal anastomosis, a complication that can prove fatal. The enterotomy is now sutured closed, beginning at the alimentary side of the opening and closing it upward toward the biliopancreatic limb (Fig. 27-18). Finally, the mesenteric defect of the enteroenterostomy is closed with a running permanent suture, beginning at the base of the mesenteric defect and completing the suture by sutures between the end of the biliopancreatic limb and the side of the Roux limb a few centimeters beyond the enteroenterostomy (Fig. 27-19).

Some surgeons choose to create the enteroenterostomy using a single-stapled technique. If this is done, it is highly advisable to suture the stapler defect, as trying to close it with a stapler may cause stenosis. The double staple technique is more amenable to stapling closed the stapler defect. Some surgeons also prefer to create this anastomosis with a hand-sutured technique.

**Passing the Roux Limb.** Our preference is to perform a retrocolic retrogastric pathway for the Roux limb. The authors prefer this configuration because it allows the Roux limb to pass via the shortest distance to the proximal stomach, minimizing the risk of tension on the anastomosis. It also minimizes the risk for Petersen's hernia, based on the configuration of the Roux limb and biliopancreatic limb. Proponents for an antecolic Roux limb argue that this method is quicker and has little risk of anastomotic problems due to tension. They



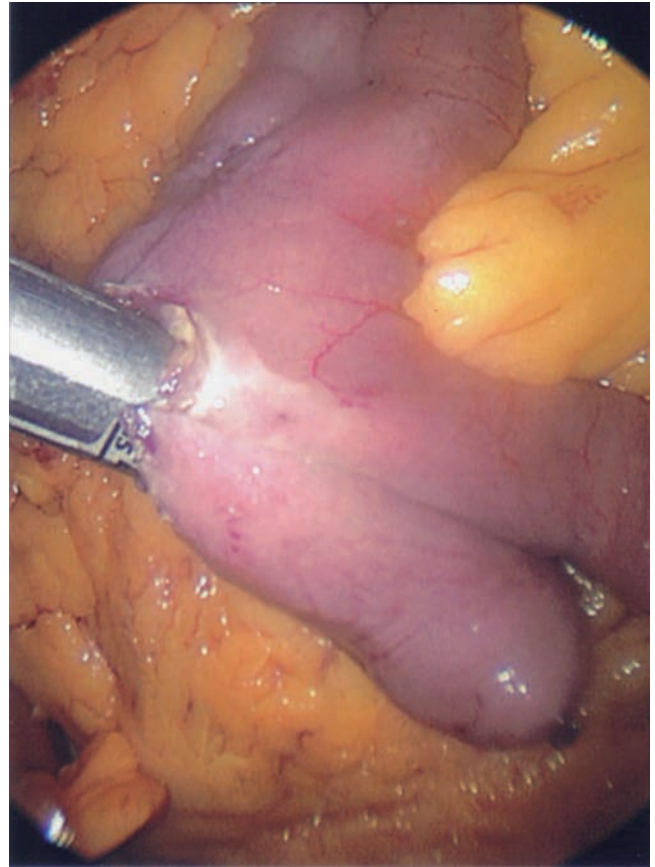
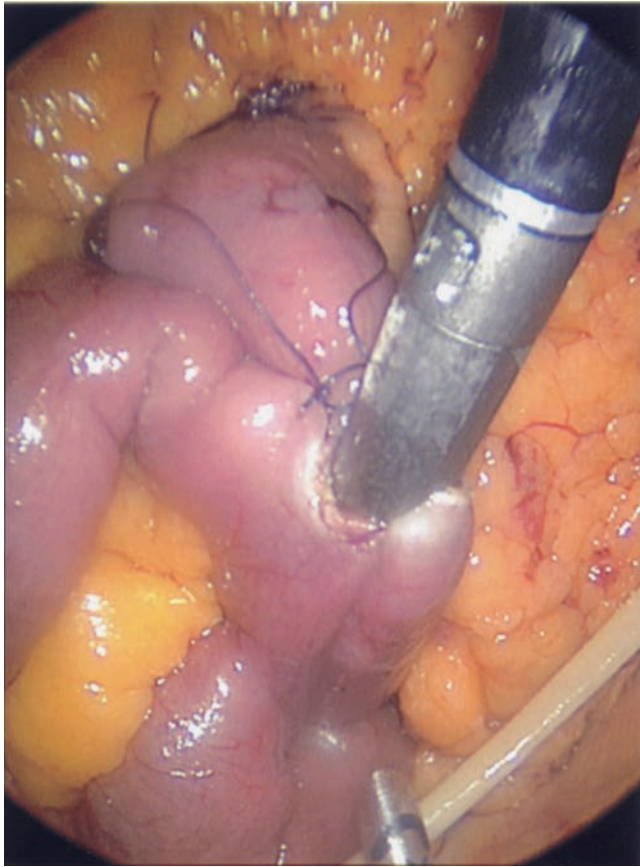


FIGURE 27-17 Stapling enteroenterostomy.

also argue there is a decreased incidence of internal hernias without a defect in the transverse colon mesentery.<sup>39</sup>

The biliopancreatic limb is now traced back to find the ligament of Treitz again. Then the transverse colon mesentery just to the left of the ligament of Treitz is held up and stretched so that it presents a solid flat surface. We find that the area just to the left and above the ligament of Treitz usually serves as a safe location to create an opening in the transverse colon mesentery with the ultrasonic scalpel. A longitudinal opening several centimeters in length is made, and the mesentery is then carefully divided with the ultrasonic scalpel. Usually larger vessels are not encountered, but caution must be taken in case of aberrant vascular distribution. Once an opening is made into the lesser sac, the stomach is usually readily visible and can be grasped and pulled up to the opening in the mesentery. Enlarging the mesenteric opening allows enough room to pass the Roux limb into the retrogastric space. This is facilitated by locating the Penrose drain and passing it into the space first, followed by the first 2–3 in of the Roux limb (Fig. 27-20). Care must be taken that the mesentery of the Roux limb is not twisted but instead is oriented straight up and down below the bowel as it is being passed through the transverse colon mesentery.

Difficulties in passing the Roux limb can be overcome with several tricks that have been learned over the years. The

large and bulky mesentery presents more difficulty. In this situation the gastrocolic ligament often needs to be opened with the ultrasonic scalpel over a 4- to 6-in area. This allows a wide visualization of the superior surface of the transverse colon mesentery. The assistant then grasps the end of the Penrose drain, pushes it into the transverse colon mesentery through the standard incision in the inferior surface of the mesentery. The distention of the superior surface of the mesentery usually allows identification of the grasper and the Penrose drain just under the mesenteric surface. The surface can then be pierced with the grasper under direct vision, and the opening in the mesentery then also enlarged under direct vision to allow the Roux limb to pass through. A careful check of the mesentery is also needed in this situation as well.

**Creating the Proximal Gastric Pouch.** The proximal gastric pouch is best constructed from the upper lesser curvature of the stomach, with only a minimal amount of fundus included. In order to better expose the stomach, we place the patient in relatively steep reverse *Trendelenburg's* position, after first placing the liver retractor (which is not needed until this point). The ultrasonic scalpel is then used to create an opening in the lesser curvature mesentery adjacent to the lesser curvature of the stomach. If the patient is larger, the pouch is best made a bit longer, starting within 1 or 2 cm



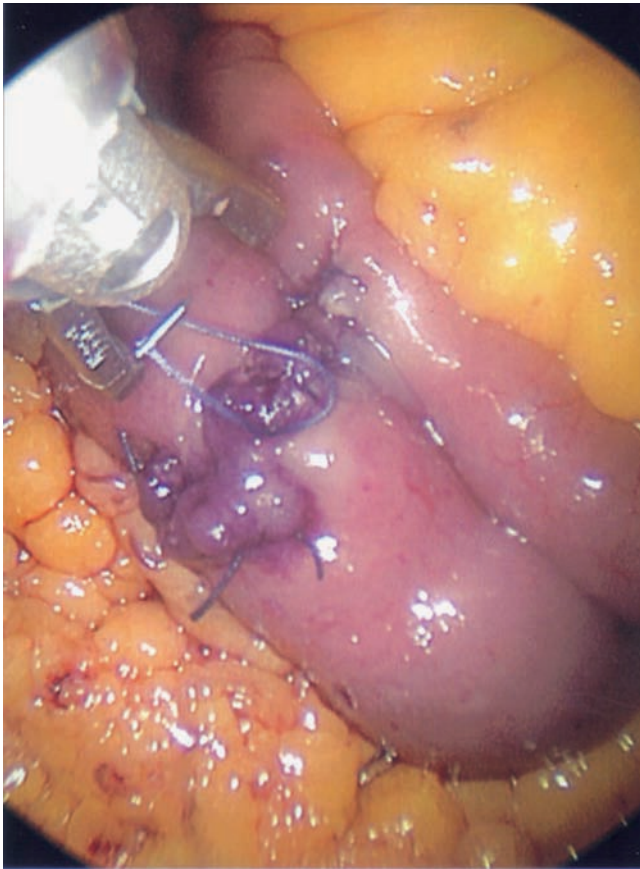


FIGURE 27-18 Sewing closed stapler defect of enteroenterostomy.

above the incisura, to ensure that the Roux limb will reach the pouch. More often, the pouch is created starting several centimeters above the incisura. Once an opening is made, the blue load (or green load for thicker stomach) GIA stapler is fired directly across the stomach, creating a divided cut into

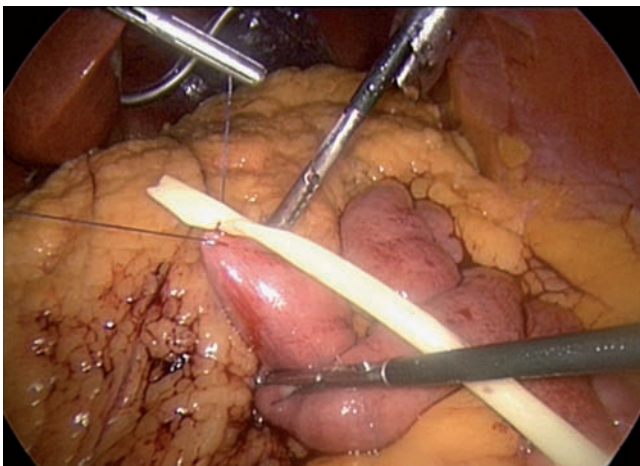


FIGURE 27-19 Completion of suturing closed the mesenteric defect of the enteroenterostomy.

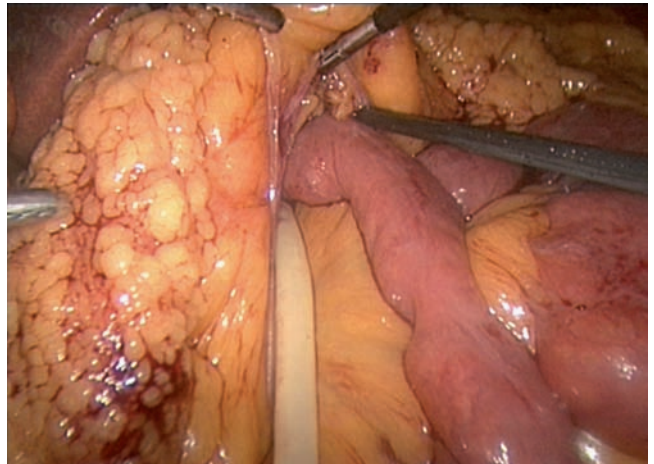


FIGURE 27-20 Passage of the Roux limb.

the stomach from the lesser curvature side (Fig. 27-21). The surgeon must double-confirm with the anesthesiologist that any nasogastric tubes, temperature probes, or other tubes that could possibly be in the lumen of the stomach have been removed prior to firing the stapler.

We have found the next best step for guiding the size of the pouch is to have the anesthesiologist pass an Ewald tube, which is a gastric lavage tube used to evacuate the stomach of large clot or particles, measuring 32F in diameter. This tube is then positioned along the lesser curvature of the stomach, and it serves as a guide for creating the pouch size. The pouch is created just slightly larger than the size of the tube. The GIA stapler is then fired several times adjacent to the side of the tube until the top of the stomach is reached in the area of the angle of His (Fig. 27-22). An opening through the mesentery underneath the edge of the top of the fundus should be created to facilitate the final firing of the stapler and allow

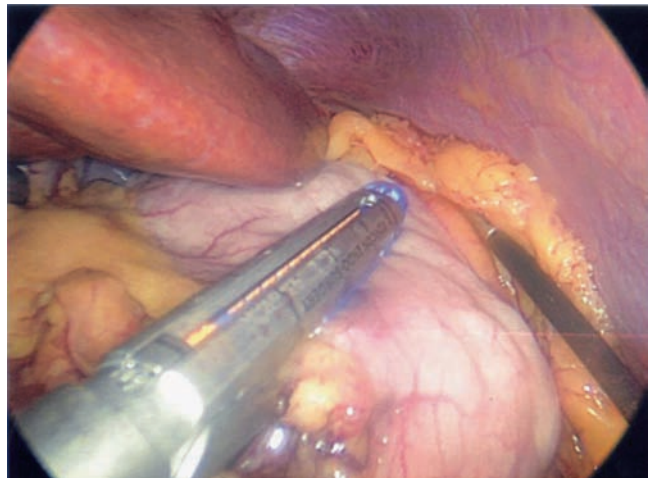


FIGURE 27-21 First stapling to begin creation of proximal gastric pouch.

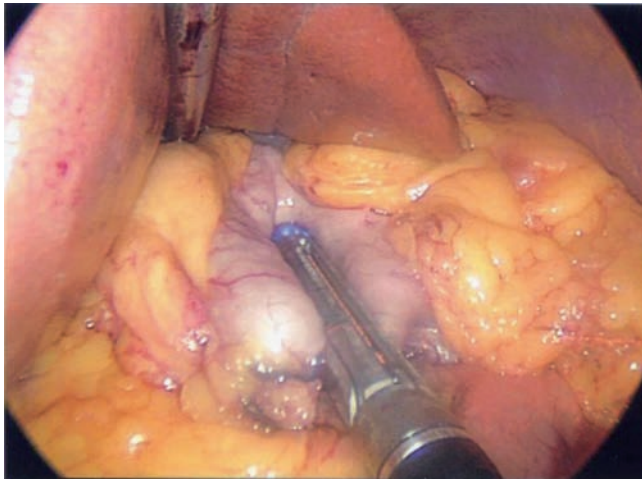


FIGURE 27-22 Stapling to create proximal gastric pouch.

complete division of the stomach and thus complete separation of the proximal gastric pouch from the distal stomach.

Some surgeons prefer to use a flexible endoscope, esophageal dilator, or other space-occupying tube to help as a guide to create the proximal gastric pouch.

**Creating the Gastrojejunostomy.** Once the gastric pouch is created, the Penrose drain is usually visible behind the lower stomach. If not, the gastrocolic ligament may need to be opened to locate it and facilitate passage of the Roux limb up to the proximal gastric pouch. Retrogastric adhesions are a problem that must be recognized if they prevent easy passage of the Roux limb or, worse, act as a bowstring across the mesentery of the proximal Roux limb, rendering it ischemic. Any limitation to the easy passage of the Roux limb should be investigated by opening the gastrocolic ligament and assessing the posterior gastric surface.

Once the Penrose drain is located, it is used to gently pull the Roux limb up past the lower stomach. The proximal end of the Roux limb is placed adjacent to the lowermost end of the proximal gastric pouch, and the more distal Roux limb is gently teased up to approximate the entire length of the proximal gastric pouch. Once the two organs are thus aligned, a running suture is used to connect the side of the Roux limb to the staple line of the proximal gastric pouch. The suture is begun at the top end of the gastric staple line, and, when completed and tied, one end is left long for later use (Fig. 27-23). The Ewald tube is now used as a backstop to create a gastrotomy in the distal stomach pouch, about 1 cm from the end. An adjacent enterotomy is made in the Roux limb, using the ultrasonic scalpel for both. The anesthesiologist is asked to withdraw the Ewald tube 6–8 cm, so as to avoid stapling it. Visual confirmation of this is mandatory. The blue load of the GIA stapler is now inserted into the two lumens, one leg in each, and is best passed from the surgeon's

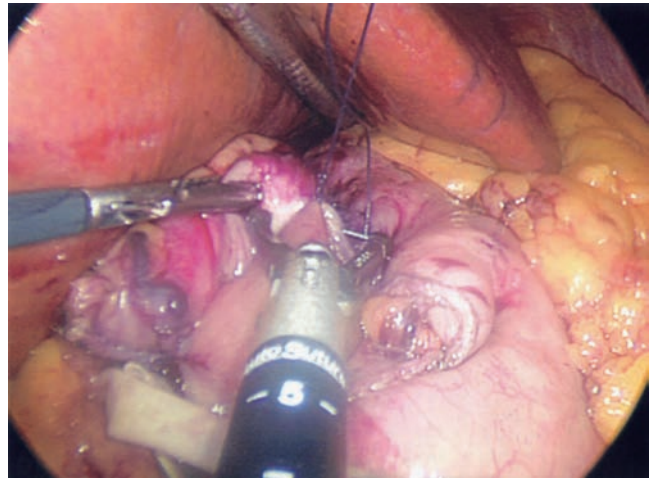


FIGURE 27-23 Starting the suture line to approximate Roux limb adjacent to gastric pouch.

left-hand port. This aligns it with the natural direction of the organs. Once the stapler is inserted to its full length, it is fired (Fig. 27-24). The enterotomy remaining is now closed using a running layer of absorbable suture, starting at the inferior apex of the opening near the knot of the running suture used to approximate the organs. This enterotomy closure is then reinforced with an outer layer of absorbable suture, after first having the anesthesiologist advance the Ewald tube so that it is just across the anastomosis, and thus stenting it open to prevent any stenosis by the second layer of closure. We then test the anastomosis for leaks by forcefully injecting methylene blue into the Ewald tube while holding pressure on the Roux limb just beyond the anastomosis. Distention without leakage must be accomplished.

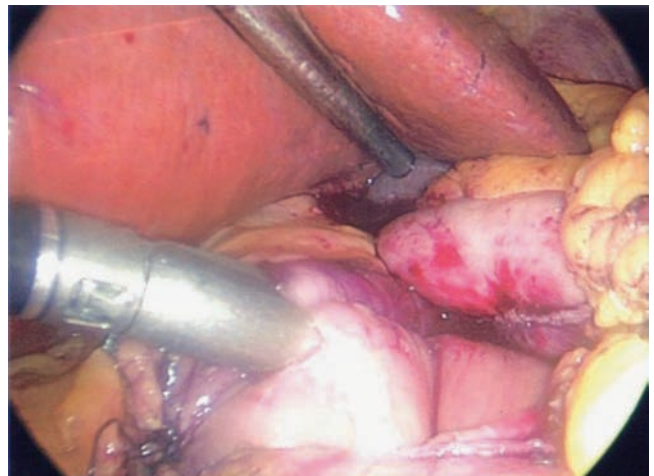


FIGURE 27-24 Stapler placement for gastrojejunostomy.



Many surgeons use the circular stapler to create the gastrojejunostomy. The first author also used this technique for many years but has abandoned it in favor of the linear stapler. Using the linear stapler, without trying to limit anastomotic size, we have experienced that the incidence of anastomotic stenosis is under 2% (it was 10–14% with the circular stapler) and the amount of weight loss is comparable to that seen with the circular-stapled anastomosis.<sup>40</sup> The linear stapler is also technically easier than the circular one for the surgeon to use if he or she does not have a highly skilled first assistant.

**Closure of the Mesenteric Defects.** The retrocolic Roux limb must be secured to a reliable structure to keep it from telescoping up behind the stomach. Should it do so, the Roux limb will assume the shape of an accordion, and multiple partial obstructions or a single dominant point of obstruction will often then result. We prevent this by tacking the Roux limb to the adjacent proximal portion of the biliopancreatic limb, just distal to the ligament of Treitz, with several nonabsorbable sutures (Fig. 27-25). We also suture the Roux limb to the mesenteric defect both above and laterally to the patient's left side, to prevent herniation in either of these areas. Although our incidence of internal hernias is low with this technique, it is not zero, as sometimes sutures will fail or spaces develop between sutures that allow an internal herniation.

**Completion of the Operation.** The 12-mm port sites are closed at the fascial/peritoneal level using a suture passer to pass absorbable 0 weight sutures. Then all ports are removed and the pneumoperitoneum decompressed. Skin closure is with subcuticular absorbable suture, and the skin sites are dressed with Dermabond (cyanoacrylate). Bupivacaine (0.25%) with epinephrine is infiltrated at all port sites, as it was when they were created.

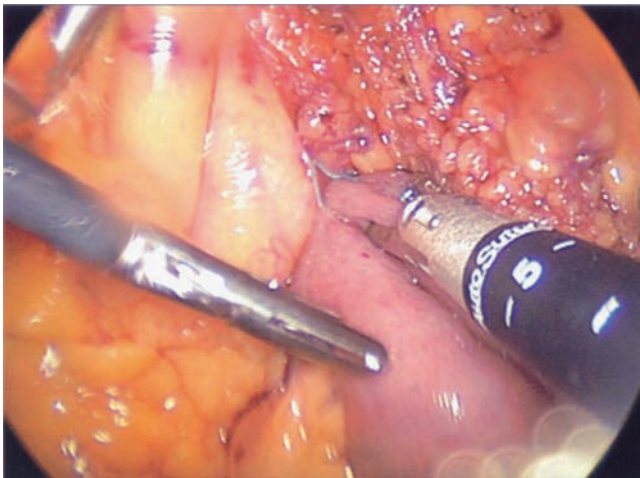


FIGURE 27-25 Triple stitch suturing mesentery.

## Open Roux-en-Y Gastric Bypass

### OPERATIVE PROCEDURE

The open approach to performing Roux-en-Y gastric bypass (RYGB) is a time-tested bariatric operation that is the only procedure with considerable longevity. However, the benefits of doing the same operation laparoscopically cannot be denied, because there is a clear decrease in wound complications, incisional hernias, and also a more rapid return to normal function after surgery. The bariatric surgeon must, however, be able to perform an open operation if needed, as certain patients will require this approach. The most common reasons that a laparoscopic approach cannot be performed include excessive intra-abdominal scarring (almost always present at revision operations), massively thick abdominal wall precluding adequate mobility of the ports, a massive liver unable to be retracted using laparoscopic retractors, and intraoperative complications requiring conversion to an open incision for optimal treatment.

The open RYGB that we now perform is modeled on the laparoscopic operation, because we now have so much more experience with the latter approach and use it as our routine or default operation. There are a few differences, summarized in the following text.

**Incision and Exposure.** The open incision must be made high enough to expose the diaphragm. Usually the skin incision must extend above the xyphoid by about 1–2 cm, and the division of the fascia and muscle should continue alongside the left side of the xyphoid process. This will allow the surgeon to look down and visualize the diaphragm. If the diaphragm is not visible, the exposure is not high enough to allow a safe procedure. Use of mechanical retractors is mandatory to help maintain adequate exposure. Human retractors are not adequate or appropriate. The length of the incision should be long enough to allow good exposure of the transverse colon and a few inches below it, where the enteroenterostomy is created.

Liver retraction using the open approach may be different than the laparoscopic one. Because there is no telescope to look up at the stomach from a lower plane, simple elevation of the left lobe of the liver with a retractor under it often does not move it adequately out of the field of vision of the operation. Instead, division of the triangular ligament of the left lobe of the liver and folding the liver inferiorly and medially exposes the gastroesophageal junction area much more adequately. This liver retraction should only be maintained during the gastric portion of the operation to prevent excessive compression of the liver over a longer time.

**Enteroenterostomy.** We now begin the open operation with this part of the procedure and perform it in an identical manner as the laparoscopic approach. The Roux limb is marked with a suture instead of a Penrose drain. It is not passed until the gastric pouch is created, however.



**Creation of the Gastric Pouch.** The proximal gastric pouch is created in a similar manner, except that the open approach allows the easy division of the gastrocolic ligament, and thus the placement of the surgeon's finger behind the stomach when creating the mesenteric defect along the lesser curvature. Palpation and upward pressure of the mesentery from behind the stomach facilitates creating the opening in the mesentery adjacent to the stomach. The pouch is then created in a similar manner with the stapler. The green load is more often used with the open approach, because the individuals having open surgery are often larger with thicker stomachs.

**Passage of the Roux Limb.** The opening in the gastrocolic ligament allows the surgeon to palpate the superior surface of the transverse colon mesentery, exposing the inferior surface of it for division in an optimal place where palpation ensures a thin layer of tissue. The opening is usually made in about the same location as the laparoscopic procedure, but the manual palpation assists its creation in this setting. The Roux limb is now gently passed both retrocolic and retrogastric manually, positioning it adjacent to the proximal gastric pouch. Confirmation that the mesentery is not twisted is again mandatory.

The remainder of the operation is done essentially the same as the laparoscopic approach, with of course the exception of closing the incision. We favor the use of a looped no. 1 PDS-type suture to close fascia and peritoneum in a single layer. The subcutaneous tissues are copiously irrigated before the skin is stapled closed and dressed with sterile gauze.

**Drains, Oversewing, and Gastrostomies.** In general, it is the authors' contention that a gastrointestinal anastomosis should be closed, not drained. However, if the intraoperative methylene blue test has shown a leak that needed repair, or if the quality of the tissue or the anastomosis is at all in doubt, or for those extremely technically challenging operations where visualization was just barely optimal, then in those situations the patient is treated in a manner to prophylactically anticipate a possible leak. If there is any concern about the stapling during the creation of the proximal gastric pouch, the staple line is oversewn with a running absorbable suture. If the gastrojejunostomy is of concern, a closed-suction drain is left adjacent to it, placed just inferior to it and coursing behind the spleen and out through the left flank. It is usually removed before discharge, or at latest on the first clinic visit. A distal gastrostomy is also placed during difficult open operations or converted operations where complications may have arisen. A standard Stamm-type gastrostomy with a 28- to 32-size tube is created to access and drain the distal stomach.

## POSTOPERATIVE CARE

Postoperative care for LRYGB has now been formulated into a protocol at our institution that serves to generally avoid lapses in major postoperative desired treatments or orders,

facilitates nursing care by following a routine, and promotes earlier discharge while maintaining attention to important postoperative needs of the patient. Major aspects of this protocol are as follows:

Intravenous isotonic fluids are given at a rate of 250 mL/h for the first 12–24 hours and adjusted as needed based on urine output. Some bariatric patients have been on diuretics for many years. In these individuals, care must be taken not to excessively bolus them postoperatively with multiple liters of fluid to treat oliguria. If no evidence of bleeding or other signs of fluid loss are present, we will give several liters of volume at most, then give a dose of intravenous diuretic, which usually produces appropriate urine output.

Early ambulation is a key component to the prevention of VTE. Patients are expected to ambulate within a few hours of their operation. Getting out of bed frequently is encouraged and stressed. Sequential compression foot devices are to be worn by the patient when in bed. Low-molecular-weight subcutaneous heparin is used for VTE prophylaxis until discharge in average risk patients. In high-risk patients, it is continued at home for 3 more weeks on a twice daily subcutaneous injection dosing.

Oral intake is limited to ice chips the night after surgery. An upper GI study with water-soluble contrast is done the following day. If there are no problems on the study, a clear liquid diet is begun. This is advanced to a blenderized diet the next day. While many authorities have written that such a postoperative study is inaccurate and cost-ineffective,<sup>41</sup> we still use it to detect any potential problems of obstruction distal to the anastomosis and to document gastric pouch size.

Pain control is achieved through a combination of intravenous medications graduated to oral medications by the first postoperative day. Patient-controlled analgesia (PCA) pumps are often used in the first 24 hours and then stopped as oral medications are introduced.

Intravenous antibiotics are stopped after a postoperative dose in addition to the preoperative dose.

Wound care is simplified by the Dermabond, which allows wounds to be exposed to water if needed. No special care is required.

Oxygen is supplied the first 24 hours and then removed as appropriate based on oxygen saturation levels. As per our policy, patients with obstructive sleep apnea are required to bring their continuous positive airway pressure (CPAP) masks and use them while in the hospital. High-risk pulmonary patients all have a mandatory arterial blood gas done preoperatively to determine their "baseline" status. This is important in case postoperative ventilatory support is needed, which is rare. If it is, the pre-op ABG serves as a guideline for extubation. Otherwise, the surgeon is often confronted with an intensive care unit (ICU) team who wants to see "normal" blood gases prior to any extubation attempt.

Our normal protocol for patients undergoing LRYGB is for discharge at noon on the second postoperative day. Most patients achieve this timeframe for discharge, while occasional patients are detained an extra day for issues, including hypoxia, urinary retention, pain control, other medical

problems, or social issues. Patients undergoing open RYGB undergo the same postoperative protocol, except they often are not able to wean off intravenous narcotic pain medications or are not adequately ambulatory until the third postoperative day.

### FOLLOW-UP

Patients undergoing LRYGB are seen back for follow-up clinic visits at approximately 3 weeks, 3 months, 6 months, and 1 year after surgery, then annually thereafter. More frequent visits are scheduled as needed. The 3-week visit is focused on adjustment issues to new eating habits, recovery from postoperative problems, advancement of diet, initiation of an exercise program, and adjustment of any medications (always done in coordination with the patient's primary care physician). The 3-month visit confirms the effectiveness of the diet and exercise plans, as well as improvements in comorbid medical problems and further medication adjustments as indicated. The 6-month visit assesses for any potential diet or nutrient deficiencies and reemphasizes the need for a consistent exercise program. Medications are again reviewed. Medication that is being taken to prevent gallstone formation with rapid weight loss (ursodiol 400 mg twice daily) is discontinued. The 1-year visit assesses changes in comorbid medical conditions, reviews the improvements that have resulted from the operation, and emphasizes the need to continue the diet and exercise changes that the patient has established during the year. The patients are cautioned that weight regain is a major issue if such diet and exercise habits are abandoned, because adaptation to the operation will allow greater oral intake than before (though still limited) and often is accompanied by a return of appetite as well.

It cannot be emphasized enough that *any and all* bariatric operations will not produce the durable weight loss sought and the long-term improvements in health and comorbid medical problems desired unless the adjustments to eating, exercise habits, and lifestyle produced by the operation are maintained long term. Regaining weight, or recidivism, is the single greatest long-term problem facing the patient who undergoes bariatric surgery.

### OUTCOMES

Laparoscopic RYGB produces excellent weight loss, with 1 year percentage of excess body weight loss (%EBWL) being reported as between 60 and 75% in most series.<sup>42-44</sup> The laparoscopic approach has only been commonly used for a decade, and it did not achieve a position as being more frequently done than the open RYGB until probably 2003. Therefore, most of the long-term outcomes of RYGB have been published about patients who underwent open RYGB. For this approach, the weight loss was very comparable to that of LRYGB, although there were few reports of %EBWL of over 70%. Long-term maintenance of weight loss has been reported by Pories et al<sup>45</sup> and the Swedish Obesity Study<sup>46</sup> that included RYGB as well as gastroplasty for its

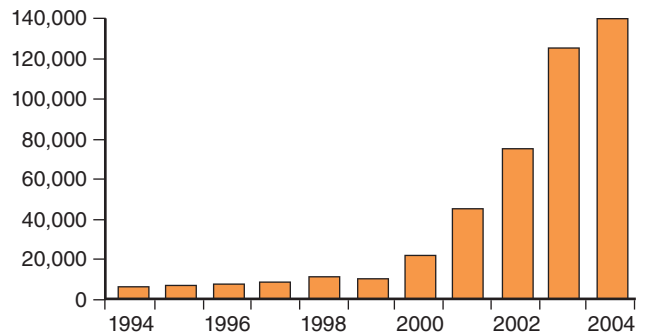


FIGURE 27-26 Graph of increase in Roux-en-Y gastric bypass (RYGB) during era around 2000.

operative procedures. The laparoscopic approach has probably been associated with slightly higher weight loss in many series because of two factors. The first is the average size of patients undergoing RYGB since the laparoscopic era has decreased. Prior to having a laparoscopic option for the operation, not nearly as many patients with BMI in the 40–50 range wished to undergo surgery, especially when it entailed an open incision. The popularity of RYGB was immeasurably enhanced by having the laparoscopic option, as evidenced by the rapid rise in popularity of RYGB being performed in the United States, between 1999 and 2003, during which time the number of procedures went from approximately 25,000 to 120,000 per year (Fig. 27-26). While other factors, such as Internet communication and publicity in national media probably also contributed to the rise in popularity of the procedure, they were most likely a secondary by-product of the sudden increase in demand and popularity of the operation. The costs of performing RYGB have been shown to be less, over a short follow-up period of 5 years, than the costs of medical care for patients who qualified for but do not undergo surgery.<sup>47</sup>

RYGB is known to have had many beneficial effects for patients who have undergone the procedure. It has been shown to improve longevity.<sup>48-50</sup> It has been shown to reduce medical comorbidities, the results of which are summarized

#### TABLE 27-4: RESULTS OF RYGB ON COMORBID MEDICAL PROBLEMS

Excess weight loss (EWL)	62%
Mortality	0.5%
Resolution of diabetes	84%
Resolution of hyperlipidemia	97%
Resolution of hypertension	68%
Resolution of sleep apnea	80%

Based on references 51–53.

in Table 27-4.<sup>51-53</sup> Certain specific medical problems merit more detail in terms of the effect of RYGB on them.

## DIABETES

RYGB has been shown to be a highly effective treatment for type 2 adult-onset diabetes. Patients suffering from this disease will often experience remission of symptoms of the disease after only a few weeks of time have passed since surgery. The amount of weight lost during such a period of time does not alone explain this rapid amelioration of the disease. This clinical observation had been made by many surgeons performing RYGB and was best summarized in a study by Pories et al.<sup>54</sup> Over the past decade, a significant amount of research work on the mechanism of how RYGB improves diabetes has been performed. Studies in obese mice done by Rubino et al.<sup>55</sup> demonstrated that the diversion of the food stream from the proximal intestinal tract resulted in remission of the animal's obesity and diabetes, and reversal of the operation resulted in reappearance of both conditions. The metabolic aspects of how RYGB may change the entero-insular axis are still being debated.<sup>56</sup> It appears that glucagon-like peptide-1 (GLP-1) is important in the process, but other gut hormones have also been implicated as potentially having a role in the metabolic changes seen after RYGB. Entire conferences and symposia have been held since 2007 on this topic, and the subject continues to be one of intense interest among scientists studying the metabolic effect of RYGB on diabetes, the metabolic syndrome, hyperlipidemia, and other metabolic conditions.

## CHOLELITHIASIS

Gallstones may form with rapid weight loss for any reason, be it surgical or diet-induced. This was first observed after subjects following diet programs in the 1980s were noted to have high incidences of gallstones. Subsequent studies have shown that the incidence of sludge or stone formation after rapid weight loss to be in the 30% range.<sup>57</sup> This condition must be therefore considered in the planning of LRYGB, LSG, and DS for patients. Fortunately, it has also been shown that the consumption of prophylactic bile acids, specifically ursodiol at a dose of 300 mg twice daily for 6 months following RYGB surgery, can decrease the incidence of gallstone formation to 4%.<sup>58</sup>

Performance of synchronous therapeutic cholecystectomy is generally recognized as appropriate for patients with symptomatic cholelithiasis. There are some surgeons, however, that do not direct preoperative attention to the biliary system or feel such attention is unwarranted. Historical data do not support such a position, but some recent short-term follow-up studies have suggested a low incidence of biliary complications within the first year or two after surgery using such an approach.<sup>59,60</sup> However, studies with longer follow-up are more likely to document the not insignificant incidence of biliary complications that result from untreated cholelithiasis long term.<sup>61-63</sup>

More controversial is the question of whether to treat asymptomatic cholelithiasis if discovered prior to elective bariatric surgery. While some studies have concluded that the length of hospital stay or the complications associated with performing simultaneous cholecystectomy do not warrant its performance,<sup>64</sup> our experience has shown that synchronous prophylactic cholecystectomy, when performed with RYGB, either open or laparoscopic, has little effect on outcomes other than to lengthen operating time slightly.<sup>65</sup>

During the era of open bariatric surgery, performing a synchronous cholecystectomy was commonplace among many practices, including our own. The rationale was that the incidence of postoperative development of cholelithiasis and the need for subsequent operation outweighed the risk of performing a synchronous prophylactic procedure, provided the latter was done under good operative conditions following the successful completion of the bariatric operation. Now with most bariatric operations being done laparoscopically, the ability to perform a laparoscopic cholecystectomy as a second procedure is very high, and hence the need for the prophylactic cholecystectomy for the patient with a normal gallbladder has greatly diminished.

Our current recommendation for this issue is synchronous cholecystectomy for any patient with biliary pathology undergoing RYGB, strong consideration for synchronous cholecystectomy for all patients undergoing malabsorptive operations where bile salt pool will be depleted, and use of oral chemoprophylaxis in the form of ursodiol 400 mg BID for 6 months following performance of an operation that will produce rapid (>50 lb/3 mo) weight loss. Because most patients who undergo LAGB will not lose weight as rapidly as with malabsorptive or RYGB operations, the need for prophylactic cholecystectomy is minimal and not indicated. Nor is the routine use of ursodiol. However, for patients with cholelithiasis, it should be the judgment by the surgeon as to whether synchronous cholecystectomy at the time of LAGB is indicated, based on comfort of not spilling bile during the procedure as well as the patient's preoperative symptoms.

## GASTROESOPHAGEAL REFLUX DISEASE

This comorbid medical problem also warrants some special consideration in the recommendation of operative bariatric choices for patients. Patients with gastroesophageal reflux disease (GERD) will have significantly greater improvement in symptoms after RYGB<sup>66</sup> than after LAGB<sup>67</sup> or LSG.<sup>32</sup> Patients who undergo RYGB have as higher a symptomatic relief from preoperative GERD than those who undergo specific surgical fundoplication for GERD.<sup>66,68</sup> In fact, patients who are referred for surgical fundoplication with a BMI of greater than 35 should be offered the option of having a LRGYB as an alternative to a laparoscopic fundoplication. The former will treat the patient's reflux symptoms as well as improve their physical and medical issues related to severe obesity.<sup>69</sup>



## COMPLICATIONS

Mortality from LRYGB has now decreased considerably from the figure of approximately 1% reported in the literature a decade ago. Recent reports from very large databases have given the incidence as 0.13–0.18%.<sup>70,71</sup> Increased experience of surgeons, an overall less ill and less large patient population undergoing surgery, improvements in care through centers of excellence programs, and the decreased burden of an open incision have all likely contributed to this decrease in mortality. LRYGB is now safer than almost all intra-abdominal operations with perhaps the exception of cholecystectomy.

Morbidity from LRYGB has also decreased as well with improving experience over the past decade. Major operative morbidity is now given as under 2% in most series and total 30-day comprehensive morbidity as reported by our NSQIP (National Surgical Quality Improvement Program) database and for the University Health System Consortium (UHC) has been 15 and 14% respectively.<sup>72</sup> NSQIP outcomes data for our institution and the UHC consortium are summarized in Table 27-5.

## SPECIFIC COMPLICATIONS AND THEIR TREATMENT

Complications after LRYGB and open RYGB are comparable except the latter has a higher incidence of wound complications and incisional hernias. Intraoperative complications are generally low in incidence, in the 2% range. These include hemorrhage, organ injury, twisting the Roux limb during performance of anastomosis, and anastomotic leakage as documented by intraoperative testing. Postoperative complications that are commonly described in the early postoperative period include intra-abdominal and anastomotic hemorrhage<sup>73</sup>; mechanical bowel obstruction due to technical error, severe edema, or intraluminal hematoma<sup>74</sup>; and anastomotic leakage.<sup>75,76</sup> Other nonbariatric specific complications also

certainly occur, including VTE, cardiac arrhythmias, pulmonary atelectasis, and pneumonia.

Of these immediate postoperative complications, anastomotic leak is the one that is most feared by bariatric surgeons, because of its potentially fatal consequences. The condition may be difficult to diagnose clinically, with many documented cases of patients having isolated tachycardia as the only presenting symptom. Other common symptoms and signs suggesting a leak include fever, abdominal pain, tachypnea, a sense of impending doom, oliguria, and hypotension. In general, after RYGB, a patient who becomes ill in the first week after surgery has a leak until proven otherwise. Radiographic testing may not always diagnose the problem, because of the combination of lack of 100% sensitivity as well as the fact that leaks may occur in the distal gastric staple line or at the enteroenterostomy, where little or no contrast may be present on a fluoroscopic study.<sup>77</sup> If clinical symptoms are concerning for a leak, lack of radiographic confirmation should not keep the surgeon from reexploring the patient for the problem. While very small leaks that already are drained may be considered for conservative treatment,<sup>78</sup> in general the appropriate treatment of a leak is operative.<sup>79</sup> Treatment includes primary repair, placement of adequate drains in case of re leakage, provision of an enteral feeding route (usually a gastrostomy in the lower defunctionalized stomach), and, for persistent or severe cases, consideration of use of an endoscopic stent.<sup>80</sup>

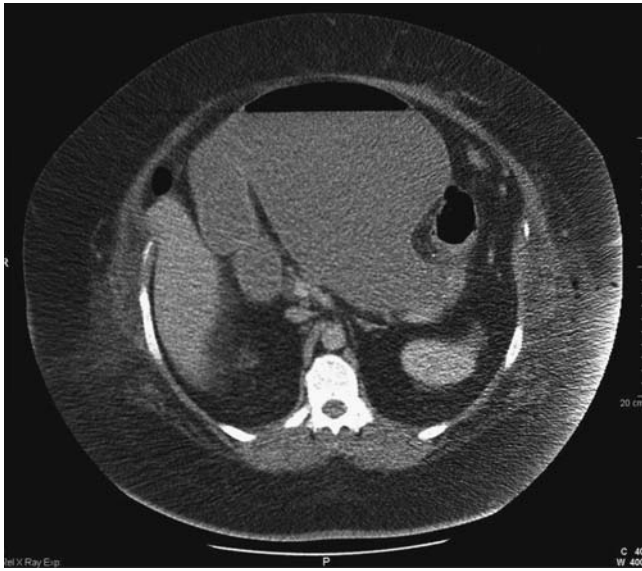
Vomiting within the first week after LRYGB or RYGB should be considered a very worrisome sign of potential early bowel obstruction. Stenosis, mechanical or technical issues, edema, and hematoma at the enteroenterostomy can all produce a relative or near-complete obstruction of the alimentary tract in this location. While the patient may vomit to clear the Roux limb, the biliopancreatic limb and distal stomach cannot be decompressed and are subject to massive distention and staple line rupture, with potentially fatal consequence (Fig. 27-27). Thus vomiting must be considered a sign of obstruction requiring vigorous investigation and reoperation if at all in doubt about the patient's condition.<sup>81</sup>

Long-term complications of RYGB are less numerous in terms of type, but several conditions are common and must be recognized to prevent life-threatening situations. By far the most dangerous and life-threatening is that of small bowel obstruction from an internal hernia.<sup>82,83</sup> Loss of a significant portion of the small bowel from ischemic necrosis may result if this condition is not promptly appreciated, diagnosed, and treated when it occurs. *Any patient who has had a LRYGB and presents with abdominal pain and signs of a bowel obstruction should be considered to have a bowel obstruction with internal herniation until proven otherwise. The surgeon should NEVER treat this condition with a nasogastric tube and observation if there is any doubt this condition may exist.* Operative treatment is the only appropriate approach. This diagnosis requires a high index of suspicion and can be compared to the diagnosis of ischemic bowel in the nonbariatric patient population. Symptoms usually are present in greater severity than physical, radiographic, or laboratory findings. Sometimes there may be a “swirling” pattern on the CT scan (Fig. 27-28). The

**TABLE 27-5: UHC AND UVA NSQIP DATA ON BARIATRIC SURGERY (LAPAROSCOPIC GASTRIC BYPASS, 2005–2008)**

	UVA	National Sites
Number of cases	562	18,423
Morbidity	9.8%	7.5%
	55/562	1388/18,423
Mortality	0.36%	0.16%
	2/562	30/18,423
Return to OR	5%	2.9%
	28/562	534/18,423

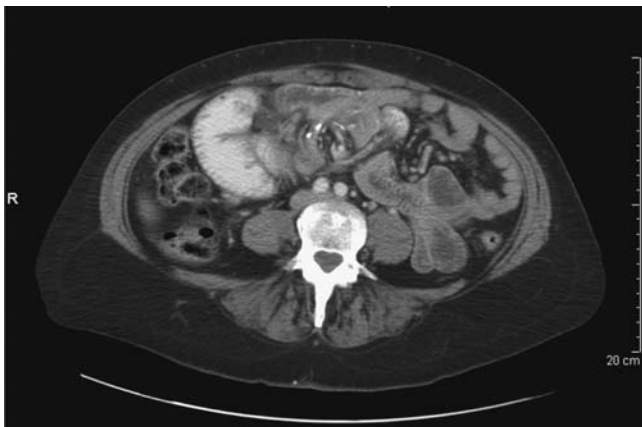OR, operating room; UHC, University Health System Consortium; UVA, University of Virginia.



**FIGURE 27-27** Picture of distended distal stomach due to enterostomy obstruction.

authors have had several patients who presented with intermittent pain after eating but without confirmatory laboratory or radiographic signs. In these cases, much of the small bowel had herniated through an internal hernia and fortunately had not yet developed strangulation. Reduction of the hernia is facilitated by beginning at the terminal ileum in these cases, as this will reliably identify the more distal bowel and allow reduction in the correct direction. Many of these cases may be treated laparoscopically, but distention preventing visualization and edema to the bowel precluding safe laparoscopic manipulation are the limiting factors.

Stenosis of the gastrojejunostomy following LRYGB presents as progressive food intolerance in the 4–12 week period after surgery. The symptoms should prompt the



**FIGURE 27-28** Swirling pattern on CT seen with internal hernia obstruction after laparoscopic Roux-en-Y gastric bypass (LRYGB).

performance of a flexible upper endoscopy, which may then be both diagnostic for the condition as well as therapeutic. The opening of the anastomosis may be very stenotic. Fortunately, however, the use of an endoscopic balloon can usually produce significant, if not complete, remission of the obstruction. If one endoscopic balloon dilation does not produce relief of symptoms, either another endoscopic or a subsequent fluoroscopic dilation with a larger-size balloon usually treats this condition quite adequately.<sup>84,85</sup>

Reoperation for stenosis is usually not needed unless the condition has been allowed to persist or is secondary to the presence of a marginal ulcer, which then causes further scarring and stenosis.<sup>86</sup> We have found by experience that the use of a linear stapler dramatically reduces the incidence of stenosis of the gastrojejunostomy after LRYGB when compared to the use of a circular stapler for this anastomosis.<sup>40</sup>

Marginal ulcer is the other major long-term problem after LRYGB or RYGB that deserves special discussion as well. The etiology of marginal ulcers is still controversial and felt to likely be multifactorial.<sup>87</sup> The incidence is increased in the setting of mechanical stapling or permanent suture to create the anastomosis.<sup>88</sup> The presence of *Helicobacter pylori* colonization leads to a higher incidence of marginal ulcer postoperatively than if the condition is treated preoperatively.<sup>89</sup> Ischemia is also felt to play a role in the formation of some marginal ulcers. Cigarette smoking is a risk factor for persistence, recurrence, and nonhealing of a marginal ulcer.<sup>90</sup> Many bariatric surgeons will not offer an LRYGB to a patient who is a smoker for this reason.

Persistent burning epigastric pain, relatively unchanged by eating, though possibly slightly relieved in some cases, is the hallmark for marginal ulcer. A high index of suspicion and performance of endoscopy will yield the diagnosis. The incidence of the problem is between 2 and 14%.<sup>91,92</sup> This variability is likely based on aggressiveness of diagnosis as well as risk factors. Treatment of the problem is medical, which is effective in the vast majority of cases. Nonhealing of a marginal ulcer should precipitate performance of a Gastrografin (diatrizoate meglumine) contrast study to rule out the possibility of the ulcer having penetrated into the lower stomach. If that has happened, surgical intervention is needed as the gastrogastic fistula tract is unlikely to close spontaneously.<sup>93</sup> Similarly, if the patient had an RYGB without a divided stomach and the gastric staple line has broken down to allow communication from lower to upper stomach, surgery is needed to separate the lower stomach from the proximal gastric pouch and thereby eliminate the backwash of acid onto the anastomosis and ulcer.

## NUTRITIONAL ISSUES AND COMPLICATIONS

Because LRYGB diverts food only from the majority of the stomach and the duodenum and up to 50 cm of proximal jejunum, the incidence of major malnutrition issues or nutrient deficiencies is limited to those nutrients specifically absorbed in those areas or those nutrients taken at a significantly lower volume after surgery. Protein malnutrition is rare without the presence of depression or other illness essentially

minimizing intake. Liver disease can contribute to hypoalbuminemia. Much more common nutritional problems arise from the lack of ability to absorb iron and calcium due to the diversion of the alimentary stream from the proximal small bowel. Similarly, lack of gastric nutrient presence decreases the secretion of vitamin B<sub>12</sub> because of lack of gastric production of intrinsic factor required to absorb the nutrient. These three elements should be measured for all patients undergoing RYGB. Folate can, on occasion, also be deficient in these patients. Another uncommon but problematic vitamin deficiency is thiamine deficiency. This may arise in the setting of progressive and significant vomiting and can, if untreated, result in permanent neurologic sequelae such as Korsakoff's syndrome.<sup>94</sup> Vitamin D has been shown to be deficient in a high percentage of the obese population and therefore is, as expected, also deficient in a high percentage of postoperative patients.<sup>95</sup> While the incidence of significant osteoporosis is not known after RYGB, the prudent approach to vitamin D deficiency is to treat it with supplementation.<sup>96</sup>

Summarizing the vitamin and nutrient needs of patients undergoing LRYGB, we follow what is likely a common set of recommendations for postoperative vitamin supplementation. This includes the following:

1. A daily multivitamin with iron (ferrous gluconate or fumarate)
2. Ferrous gluconate 300 mg BID for women of reproductive age or with documented iron deficiency
3. Calcium citrate 400–600 mg with vitamin D 300–400 IU BID for most individuals who have had RYGB and especially for those who have documented low levels of vitamin D<sub>3</sub>
4. Vitamin B<sub>12</sub> intramuscular injection (usually 1000 µg) or sublingual tablets (1000 µg combined with folate, vitamin B<sub>6</sub>, and biotin, one or two daily) as needed for biochemically low levels of vitamin B<sub>12</sub> on testing

Probably the most common clinically significant vitamin deficiency is iron deficiency anemia. This is usually adequately treated with the appropriate oral supplement. Ferrous sulfate requires an acid medium for optimal breakdown and absorption and should not be prescribed in this patient population. Ferrous gluconate is appropriate instead. Low biochemical levels of vitamin D<sub>3</sub> are common, and, if significant, we treat those with additional vitamin D beyond the amount in the usual vitamin plus calcium supplements. Clinically significant vitamin B<sub>12</sub> deficiency after RYGB is rare, but despite this, patients with biochemically low levels do receive parenteral or sublingual supplementation until normal levels are achieved.

## Biliopancreatic Diversion and Duodenal Switch

Biliopancreatic diversion (BPD) was first described by Scopinaro et al in 1976.<sup>97</sup> The modification of the BPD to a duodenal switch (DS) was performed by Hess and Hess in 1988.<sup>98</sup> These are some of the most difficult bariatric operations to

perform and have the highest postoperative complications. They also produce the most durable weight loss, especially in superobese patients. BPD and DS procedures together used to represent less than 5% of all bariatric cases performed in the United States<sup>99</sup> and now represent perhaps fewer than 1% of cases.<sup>70</sup> These operations are best suited to the superobese, for those patients who have failed a restrictive operation, or for those patients who value the ability to continue to eat larger portions of food as a most important aspect of life after bariatric surgery. Patients must be prepared to take a significant number of vitamin supplements after these operations.

### OPERATIVE PROCEDURE

The BPD and DS have been performed using both laparoscopic and open approaches. The technical details are similar other than the access to the abdomen, which is similar to all other laparoscopic bariatric operations. Port positions for doing the operation may vary among surgeons, but one example of port placement for laparoscopic DS (LDS) is given in Fig. 27-29.

In performing the BPD, a subtotal horizontal distal gastrectomy is performed, leaving a 200- to 400-mL gastric remnant. The ileocecal valve is identified and the bowel is

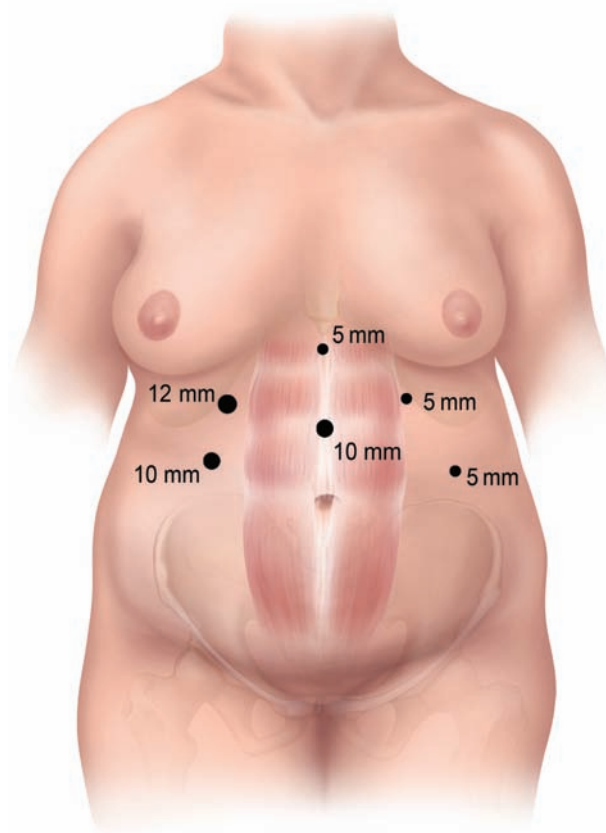


FIGURE 27-29 Picture of ports for laparoscopic duodenal switch (LDS).



measured back 250 cm and divided. The distal end of the divided bowel is anastomosed to the proximal gastric pouch. Either a linear or circular stapler may be used, with the linear the most common choice. The proximal end of the divided ileum is then anastomosed side to side using a linear stapler to the terminal ileum at a point 100 cm from the ileocecal valve. The completed operation is shown in Fig. 27-30. Previously surgeons performed this anastomosis 50 cm proximal to the valve, but this produced higher complications with protein malabsorption. Even Scopinaro and associates described the need to make this “common channel” longer in patients from southern Italy who ate a less protein-rich diet than those from northern Italy.<sup>100</sup> A prophylactic cholecystectomy should be performed due to the high risk of postoperative cholelithiasis.

The DS differs from BPD in the type of gastrectomy. It was developed to reduce the incidence of dumping syndrome and marginal ulceration. In a DS a vertical or sleeve gastrectomy based on the lesser curve of the stomach is performed (Fig. 27-31). The sleeve is calibrated over a bougie typically

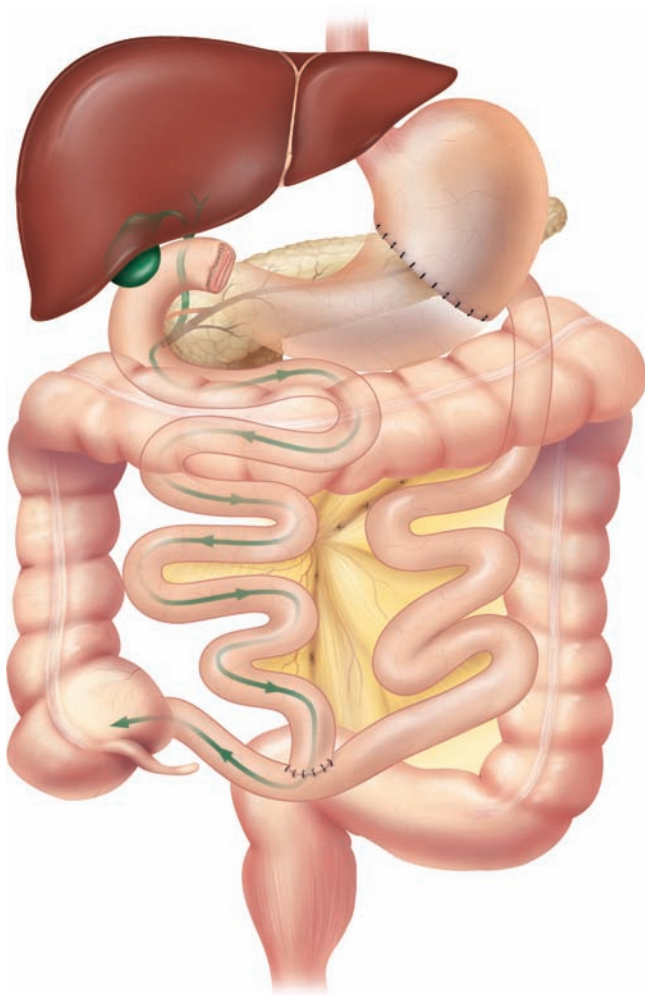


FIGURE 27-30 Picture of completed biliopancreatic diversion (BPD).

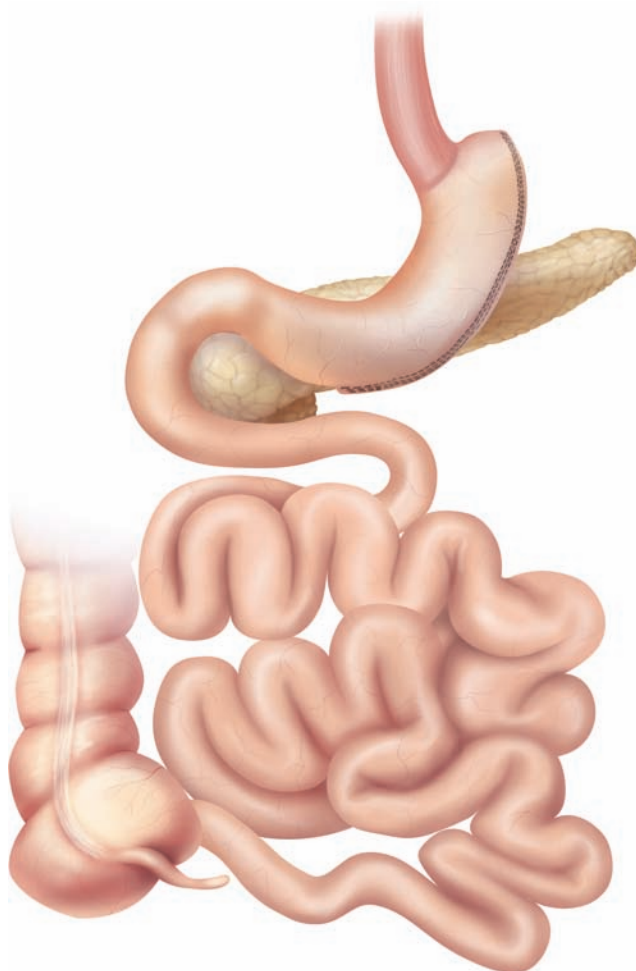


FIGURE 27-31 Sleeve part of duodenal switch (DS).

32–40F leaving a gastric volume of approximately 100–200 mL. The first portion of the duodenum is then divided approximately 2 cm from the pylorus. The end of the distal ileum and the duodenal cuff are then anastomosed. Usually this anastomosis is best done using a hand suturing technique, whether open or laparoscopic. The distal small bowel anastomosis proceeds as previously mentioned, and this is most often performed with a standard linear stapling device. The completed DS is shown in Fig. 27-32. A cholecystectomy should also be performed.

#### POSTOPERATIVE CARE

Both BPD and DS operations are comparable in terms of most of the issues that must be addressed both in postoperative care and follow-up. The DS is now an accepted procedure in the United States and reimbursed by most third-party payers. The BPD is rarely done in the United States. Thus the remaining discussion pertains to the DS rather than the BPD, unless specified. It should be reemphasized that the BPD poses virtually the same risk and complication spectrum.

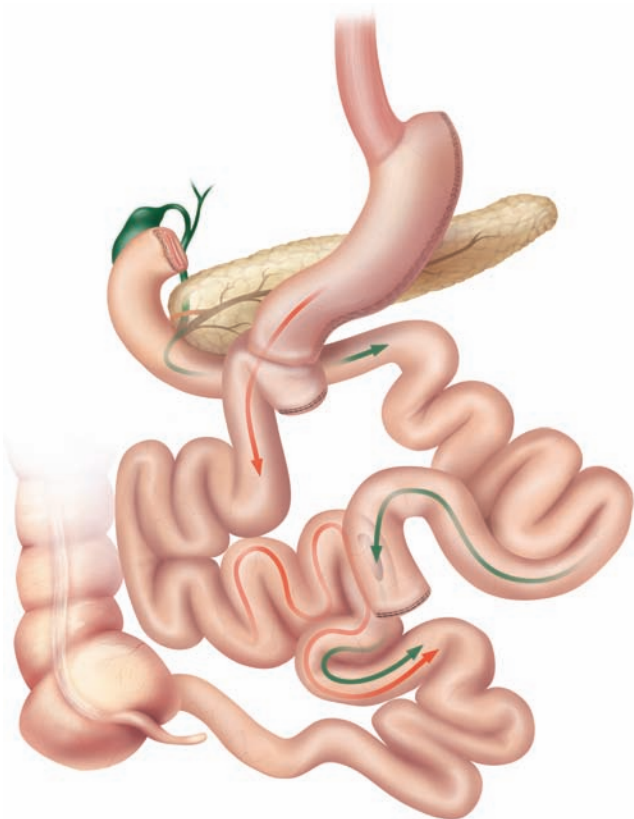


FIGURE 27-32 Completed duodenal switch (DS).

Following DS, patients are at risk for anastomotic leak, gastrointestinal bleeding, pulmonary embolism, bowel obstruction, and stenosis. The complications present with a similar clinical picture to their counterparts after LRYGB. Treatment is also usually similar and outlined in the section under complications later.

The BPD and DS procedures are primarily malabsorptive. Patients must be educated as to the consequences of the operation. They should be instructed to expect diarrhea after any large meal. This diarrhea serves as a powerful behavioral modification to eating. DS patients eat, on average, more calories per day than LRYGB patients but surprisingly only a small amount more.<sup>101</sup> The prolific diarrhea that follows overeating precludes significant excessive food intake. Patients also will learn which foods, primarily those high in fat content, produce the worst diarrhea. Patients should be cautioned about the potential perianal problems that can follow prolific diarrhea, as well as eating patterns that will improve the situation.

Nutritional deficiencies are inherently likely after malabsorptive operations. Education as to proper intake of nutrients and supplements is essential. These patients are at risk for protein-calorie malnutrition, fat-soluble vitamin, and micronutrient deficiency. Because the duodenum and proximal jejunum are diverted from the food stream, they are at risk for iron and calcium deficiency as patients undergoing

RYGB. Vitamin B<sub>12</sub> must also be supplemented because of the lack of much of the stomach. Thus one of the main issues regarding postoperative care in DS patients is to ensure that they understand the need for, and have obtained and are taking the proper vitamin and mineral supplements. These may be costly, and that cost should have been part of the preoperative discussion with the patient prior to undertaking the procedure. Magnesium deficiency may also result from short gut syndrome and malabsorption, which was more commonly seen after intestinal bypass operations. It is less common but still possible after DS.

1. A typical recommended supplementation scheme for patients undergoing DS is as follows:
2. Parenteral fat-soluble vitamin injections to include vitamins A, D, and K
3. Oral ferrous gluconate supplementation and oral vitamin D and calcium supplementation
4. Parenteral or sublingual vitamin B<sub>12</sub> supplements monthly or weekly, respectively
5. Standard multivitamin supplementation orally daily

#### FOLLOW-UP

Following DS, patients *must* be closely followed by the surgical team, as other care providers may not fully appreciate the problems related to malabsorption. This is particularly true of longer-term protein malnutrition. The primary care physician may mistake the protein-calorie malnutrition seen after DS with manifestations of congestive heart failure or liver disease, which can produce peripheral edema and hypoalbuminemia. If an exacerbation of protein-calorie malnutrition occurs, hospitalization and parenteral nutrition may be needed. Multiple such admissions are an indication to revise the operation and make the common channel longer. The potential for vitamin or mineral deficiency or protein malnutrition never is eliminated for patients after DS; it is a lifetime condition. Thus semiannual blood testing is recommended for such patients even years after surgery.

#### OUTCOMES

DS produces the best weight loss and the most durable weight loss of any of the commonly recognized and reimbursed bariatric operations.<sup>40</sup> Weight loss in the 75% of EWL is expected after this operation. Furthermore, the weight loss after DS is usually preserved, and recidivism is lower than after either LAGB or LRYGB.<sup>102</sup> Patient satisfaction is generally given as high after the operation.

Resolution of comorbidities after DS is also remarkably good. Conditions that are especially well treated after this procedure include hyperlipidemia, diabetes, and metabolic syndrome.<sup>40,103</sup>

#### COMPLICATIONS

Immediate postoperative complications that are seen after LRYGB are also seen after DS. These complications present in

a similar manner to those described previously after LRYGB, with the exception of stenosis. This may occur at the proximal anastomosis but may also occur along the length of the sleeve gastrectomy. Such a stenosis may be amenable to balloon dilation, but success is not as likely as with the stenosis of the gastrojejunostomy after LRYGB. Options to treat the ischemic stricture or a severely stenotic stricture of the gastric sleeve are limited to local revision versus a gastrojejunostomy to a Roux limb brought above the stenosis, effectively converting the operation to a RYGB. Bowel obstruction from an internal hernia is also possible after DS, although just at the enteroenterostomy from an internal hernia. Leak at the duodenoileostomy is the most common site of leakage after DS and occurs in the 2–4% range. Treatment of this problem may require a period of parenteral nutritional support before eating is possible.

Fat-soluble vitamin deficiencies may result as a consequence of DS. Vitamin A deficiency, which clinically presents as night blindness, was present in over 70% of patients in one series.<sup>104</sup> In that same series, vitamin D was found deficient in 63% of patients after 4 years. Vitamin K deficiency, manifested as coagulopathy, is more uncommon. Vitamin D deficiency is very prevalent in the population as a whole, and so supplementation after DS is always indicated and low levels are not uncommon. Osteoporosis may result from chronic vitamin D deficiency. The condition is further exacerbated by the fact that calcium is poorly absorbed after DS as well. Iron deficiency anemia will invariably also arise if no supplementation occurs. Although there is no consensus, generally it is recommended to supplement all the above elements as needed, with careful monitoring by serum blood tests serving as the ultimate guide for each patient.<sup>105</sup>

The most feared nutritional complication after DS is protein-calorie malnutrition. Clinical manifestations of this problem include edema, weight loss, skin and nail problems, hair loss, and general malaise. Laboratory tests reveal low albumin and serum protein levels. Increasing oral intake of high-quality proteins may help, but, if the condition is more advanced, parenteral nutrition is often needed. When parenteral nutrition is consistently required, reoperation to lengthen the distance of the “common channel” or intestine below the level of the enteroenterostomy is indicated. Most surgeons make that initial channel about 100 cm. If revision is required, there is no exact formula as to the appropriate length of the revised common channel, but most surgeons would consider adding at least 50 cm if not more to the length to prevent recurrence of protein-calorie malnutrition. Long-term follow-up studies of DS show the incidence of reoperation to be in the 3–5% range.<sup>106</sup>

The BPD has a higher rate of marginal ulcers than DS, with the incidence being over 12% in the original report by Scopinaro et al.<sup>100</sup>

## Revisional Surgery

Revisional surgery is a highly controversial area of bariatric surgery. Wide variability exists in the philosophies of bariatric

surgeons as to the appropriateness as well as their enthusiasm for performing revisional surgery. A few generalized statements regarding revisional surgery are as follows:

1. The revisional operation will usually produce less of a major change in the patient's weight or reduction in comorbid medical problems than did the index operation.
2. The complications of the revisional operations are higher than the index operation.
3. There should be even greater scrutiny and assessment of patients undergoing revisional surgery than initial operations.
4. Care should be taken to avoid severe nutritional complications that may accompany the combination of too much restriction and malabsorption with revisional surgery.

In general, revisional operations fall under two broad categories:

1. Those done to correct technical shortcomings of the index operation, or complications developing as a result of it
2. Those done as a consequence of poor weight loss from the index operation

Because only RYGB has a track record of durable success of more than two decades among all the restrictive operations, the revision of the others has been a frequent issue. Malabsorptive operations have also enjoyed two decades of success, though their popularity has been significantly lower than restrictive operations. Few patients who have had either a BPD or DS have had the operation reversed, or at least there are few publications reporting this process. The jejunoleal bypass, commonly performed 35 years ago, resulted in an extremely high incidence of revisional surgery for consequences of its malabsorption.<sup>107</sup> Most of these revisional operations were performed years ago. Reversal of the operation was done, and those patients who did not have an associated new bariatric operation performed often regained weight and suffered from recurrent severe obesity.<sup>108</sup>

The vertical banded gastroplasty (VBG) was performed with high frequency in the 1980s but was found to have poor long-term weight loss preservation. As a result, many of the patients who underwent VBG have subsequently undergone revisional surgery. There are numerous accounts in the literature of conversion of VBG to RYGB.<sup>109–111</sup> Most of these accounts include a mixture of patients who had poor weight loss as well as other complications or shortcomings, such as the reported 17% incidence of stenosis after VBG,<sup>112</sup> as the reason for reoperation. Thus the indications for reoperation for VBG have been both as a consequence of both poor weight loss and technical complications. Most of the series of VBG revised to RYGB have had acceptable results in terms of weight loss and resolution of comorbidities. However, these revisional surgeries have also been accomplished with a higher incidence of morbidity than index operations of RYGB.<sup>113</sup>

During the 1970s and 1980s there were a number of gastric stapling operations performed to provide weight loss for patients.<sup>114</sup> Unfortunately, these had uniformly poor long-term outcomes in terms of durable weight loss. Many



patients undergoing those procedures were then converted to operations with a better results record, including VBG and RYGB. This text does not belabor the numerous accounts of these revisions, all of which proved no more effective than an index operation of either RYGB or VGB, and often less effective as a revisional procedure.

Current candidates for revisional surgery include patients who have failed any of the current commonly performed operations. There are increasing reports of poor long-term weight loss outcomes of LAGB from some centers in Europe.<sup>115</sup> Increasing percentages of patients who have requested band removal for poor results are seen in more recent reports regarding LAGB. For patients wishing revision after LAGB, the options would include conversion to LRYGB or to LSG or to DS. Reports of successful conversion to both exist in the literature, but the complication rate is still higher than for the index operation.<sup>116,117</sup>

Revision of RYGB has focused on several different types of problems with the index operation and thus several alternative treatments. Prior to the laparoscopic era, many surgeons performing open RYGB did not actually divide the stomach, but stapled across it with multiple staple rows to create the proximal gastric pouch. Long-term follow-up studies have shown that the risk of dividing the stomach at the index operation proved to be less than the risk of that staple line subsequently breaking down and allowing loss of restriction of the gastric pouch with weight regain, marginal ulcer, or both resulting in the need for reoperation.<sup>118</sup>

Another theory of failure of RYGB is that if the anastomotic opening of the RYGB is too large, it has resulted in the weight regain. From that theory follows the recommendation that an operation or endoscopic procedure to narrow the anastomosis in patients who have regained weight after LRYGB or RYGB will be effective in reversing the weight gain and produce new weight loss. As a result, over the past several years, there have been several reports in the literature about endoscopic<sup>119,120</sup> or other operative procedures to restrict the anastomosis of the RYGB.<sup>121</sup> Unfortunately, the long-term follow-up of those procedures to produce durable weight loss has shown that they are likely to accomplish limited short-term weight loss but not significant durable long-term weight loss.<sup>122,123</sup> The fact that increasing the anastomotic size after LRYGB was associated with a decrease in stomal stenosis after surgery, while still producing comparable weight loss, should have been ample evidence to demonstrate that anastomotic size has only minimal effect on the overall weight loss for patients after LRYGB. This observation is likely true for other operations as well but has not been nearly as well documented. The failure of VBG, however, which depended on the restriction of a small outflow and maintained a fixed small gastric outflow, should have also provided evidence that anastomotic size is not an important determinant of weight loss after bariatric surgery.

Revisional bariatric surgery could encompass quite a long list of relatively small series of revisional procedures of all existing operations. The success of any of these series has been limited. Clearly if one overwhelmingly successful bariatric

operation had been discovered among these perturbations and variations on the theme, it is likely it would have been greeted with considerable enthusiasm and publicity. This has not occurred. Therefore, this text does not delve into further details regarding revisional bariatric surgery until data exist supporting its use for improved outcomes over any of the existing index bariatric operations. To date no such data exist.

It also should be freely admitted that the lead author follows the philosophy noted previously, as to whether the operation or the patient has failed as being the determinant of whether revisional surgery is indicated.

## Special Situations

### PREGNANCY

It has been well established that the desire to bear children does not preclude a woman from having bariatric surgery. Normal pregnancy and childbirth without risk to the fetus is the norm for patients who have had LAGB.<sup>124</sup> The ability to loosen the band by removing fluid from the reservoir is a feature that is desirable for pregnancy, especially if the pregnancy produces any limited ability to eat and drink itself. It has also been well established that patients who have recovered from LRYGB are at minimal to no risk for any problems during pregnancy and childbirth due to the operation.<sup>125</sup> It is generally recommended that patients undergoing LRYGB not become pregnant soon after surgery, during the rapid weight loss phase of the postoperative period. While even this probably has only small risks to the pregnancy, it is best to avoid pregnancy during this time, when weight loss is inevitable and the change in body hormone composition is ongoing due to the operation. Pregnancy during this rapid weight loss phase is a more challenging problem to ensure that the mother has adequate nutrition for the fetus.

### AGE LIMIT

There is no distinct guideline for age limit for bariatric surgery. On the younger side, performing bariatric operations for teenagers is well established.<sup>126,127</sup> The youngest appropriate age for a bariatric operation is controversial and still unknown. Limiting further growth potential is a concern when performing bariatric surgery on the adolescent population. This must be weighed against the risk of a high likelihood of lifelong of severe obesity if the adolescent does not lose weight and become closer to normal weight by the time adulthood has arrived. Currently in the United States, the laparoscopic adjustable band is not FDA approved for individuals younger than 18 years of age. This is somewhat ironic in that many bariatric surgeons who perform bariatric surgery for the pediatric age group feel that LAGB offers the best option for this age group, providing weight loss with the least amount of nutrient malabsorption and the most ability to reverse or revise the operation in the future. Indications for performing bariatric surgery itself for adolescent individuals involve all

the same steps and precautions as for adults. Parental consent is obviously needed, and preoperative education, planning, and counseling for a bariatric operation must by necessity be a family affair in the pediatric and adolescent age group. It is controversial as to which operation is best performed for individuals younger than 18 years of age, but currently in the United States LRYGB seems to be the procedure of choice for severely obese adolescents.

Upper age limit for bariatric surgery is similarly controversial. Data do show that in experienced surgeon's hands, individuals who are older than 65 will still have comparable outcomes to their younger counterparts after bariatric surgery.<sup>128,129</sup> However, there must be some limitation of age after which the natural aging process and the toll of organ dysfunction at that age make performance of bariatric surgery an unwise decision. This age is likely more a functional than a chronologic one, and it should be the judgment of the bariatric surgeon to determine age appropriateness for patients for surgery. Individuals who present as candidates for surgery and have been severely obese all their lives are less likely to have good organ function than those prospective patients who became severely obese later in life. The lead author's personal philosophy on this topic is that individuals who have been severely obese all their lives tend to have significant organ dysfunction over age 60 and more so over age 65, and become less optimal candidates for any bariatric operation at that age. However, there are always exceptions to this general guideline. It should also be remembered that the goal of bariatric surgery is to produce improved function and quality of life for a significant period of time in the foreseeable future to warrant the risk of the operation. When life expectancy is limited by age, the potential gain from the operation is thus limited as well.

## WEIGHT LIMITS

While the NIH guidelines are clear as to when bariatric surgery should be performed for individuals in terms of being heavy enough to warrant surgery, there are no guidelines as to the patient who presents at the upper echelons of weight. Certainly it has been shown that patients with a BMI exceeding 50 have increased risk of mortality from any complication after bariatric surgery.<sup>130</sup> There are few reports in the literature about performing bariatric surgery for patients with BMI over 70 on a regular basis. We have recently reviewed our own institutional experience and found that patients with a BMI over 60 have had a surprisingly low mortality of under 2% after LRYGB and RYGB. Based on the follow-up study of Christou et al,<sup>50</sup> this patient population would have had a much higher mortality than observed without bariatric surgery. Surgery on individuals with exceedingly high weights is complicated by the logistics of providing care for them as well as the ability to safely complete any bariatric operation. Assuming the latter itself could be overcome, the former still poses a major problem for hospitals in terms of imaging capacity, nursing care and patient hygiene, transportation, and the capacity of hospital clothing, instruments such as blood pressure cuffs, and other aspects of patient care. The

Centers of Excellence model of the ACS and ASMBS have required institutions to provide such special availability of equipment for individuals undergoing bariatric surgery, but even those institutions are hard pressed to have any capacity to routinely accommodate the patient with a BMI over 80 or a weight over 500 lb for the above list of needs and equipment. No clear guidelines exist as to what an appropriate upper weight or BMI limit should be for the performance of bariatric surgery at this time.

## ENDOSCOPIC SURGERY

The ideal operation to produce weight loss in the bariatric population would be one that could be done without any incisions, but endoscopically. Currently no procedure has been established as having the ability to endoscopically convey durable weight loss for patients. Recent trials of such endoscopic procedures have taken place, only to fail to produce durable weight loss. Short-term nondurable weight loss has been reported for space-occupying devices such as intragastric balloons. However, these procedures are to be viewed with great skepticism, as they can only produce short-term weight loss that must then be followed by performance of a more established bariatric operation if the benefits of any weight loss are to be preserved or enhanced. Performing a single procedure for patients is always more desirable.<sup>13</sup>

It is likely that more trials of endoscopic procedures will continue as the ability of technology to perform endoscopic suturing, tissue approximation, and other key steps in the performance of surgical operations evolves. Perhaps at the next edition of this text, such an operation will be included in a chapter on this subject.

## REFERENCES

1. Olshansky SJ, Passaro DJ, Hershov RC, et al. A potential decline in life expectancy in the United States in the 21st century. *N Engl J Med*. 2005;352:1138–1145.
2. Mokdad AH, Ford ES, Bowman BA, et al. Prevalence of obesity, diabetes, and obesity-related health risk factors, 2001. *JAMA*. 2003;289:76–79.
3. Hedley AA, Ogden CL, Johnson CL, et al. Prevalence of overweight and obesity among US children, adolescents, and adults, 1999–2002. *JAMA*. 2004;291:2847–2850.
4. Nguyen NT, Hohmann S, Slone J, et al. Improved bariatric surgery outcomes for Medicare beneficiaries after implementation of the medicare national coverage determination. *Arch Surg*. 2010;14:72–78.
5. RAND report Washington Post, April 10, 2007.
6. Gastrointestinal surgery for severe obesity: National Institutes of Health Consensus Development Conference Statement. *Am J Clin Nutr*. 1992; 55(suppl 2):S615–S619.
7. Buchwald H. Consensus Conference Statement. Bariatric surgery for morbid obesity: health implications for patients, health professionals, and third-party payers. *Surg Obes Rel Dis*. 2005;1:371–381.
8. Pories WJ, Dohm LG, Mansfield CJ. Beyond the BMI: the search for better guidelines for bariatric surgery. *Obesity*. 2010;18:865–871.
9. Fontaine KR, Redden DT, Wang C, et al. Years of life lost due to obesity. *JAMA*. 2003;289:187–193.
10. Flum DR, Salem L, Elrod JAB, et al. Early mortality among Medicare beneficiaries undergoing bariatric surgical procedures. *JAMA*. 2005;294:1903–1908.
11. Jamal MK, Demaria EJ, Johnston JM, et al. Insurance-mandated preoperative dietary counseling does not improve outcome and increases

- dropout rates in patients considering gastric bypass surgery for morbid obesity. *Surg Obes Rel Dis*. 2006;2:122–127.
12. <http://www.asbms.org>. Accessed July 16, 2012.
  13. Milone L, Strong V, Gagner M. Laparoscopic sleeve gastrectomy is superior to endoscopic intragastric balloon as a first stage procedure for super-obese patients (BMI  $\geq$  50). *Obes Surg*. 2005;15:612–617.
  14. Arias E, Martinez PR, Ka Ming LV, et al. Mid-term follow-up after sleeve gastrectomy as a final approach for morbid obesity. *Obes Surg*. 2009;19:544–548.
  15. Sanchez-Santos R, Masdevall C, Baltasar A, et al. Short- and mid-term outcomes of sleeve gastrectomy for morbid obesity: the experience of the Spanish National Registry. *Obes Surg*. 2009;19:1203–1210.
  16. Marceau D, Hould FS, Simard S, et al. Biliopancreatic diversion with duodenal switch. *World J Surg*. 1998;22:947–954.
  17. Kuzmak L. Silicone gastric banding: a simple and effective operation for morbid obesity. *Contemp Surg*. 1986;28:13–18.
  18. Halberg D, Forsell P. Ballongband vid behandling av massiv Gvervikt. *Svensk Kirurgi*. 1985;43:106.
  19. Ren CJ. Laparoscopic adjustable gastric banding: postoperative management. In: Schauer PR, Schirmer BD, Brethauer SA, eds. *Minimally Invasive Bariatric Surgery*. New York, NY: Springer; 2007:197–203.
  20. Dixon JB, O'Brien PE. Laparoscopic adjustable gastric banding: outcomes. In: Schauer PR, Schirmer BD, Brethauer SA, eds. *Minimally Invasive Bariatric Surgery*. New York, NY: Springer; 2007:190.
  21. Dixon AF, Dixon JB, O'Brien PE. Laparoscopic adjustable gastric banding induces prolonged satiety: a randomized blind crossover study. *J Clin Endo Metab*. 2005;90:813–819.
  22. Dargent J. Laparoscopic adjustable gastric banding: lessons learned from the first 500 patients in a single institution. *Obes Surg*. 1999;9:446–452.
  23. Favretti F, Segato G, DeLuca M, Busetto L. Laparoscopic adjustable gastric banding: revisional surgery. In: Schauer PR, Schirmer BD, Brethauer SA, eds. *Minimally Invasive Bariatric Surgery*. New York, NY: Springer; 2007:216–217.
  24. Dixon JB, O'Brien PE, Playfair J, et al. Adjustable gastric banding and conventional therapy for type 2 diabetes: a randomized controlled trial. *JAMA*. 2008;299:316–323.
  25. Colles SL, Dixon JB, O'Brien PE. Hunger control and regular physical activity facilitate weight loss after laparoscopic adjustable gastric banding. *Obes Surg*. 2008;18:833–840.
  26. O'Brien PE, Dixon JB. Weight loss and early and late complications—the international experience. *Am J Surg*. 2002;184:S42–S45.
  27. Boza C, Gamboa C, Awruch D, et al. Laparoscopic Roux-en-Y gastric bypass versus laparoscopic gastric adjustable banding: five years of follow-up. *Surg Obes Rel Dis*. 2010;6:470–475.
  28. O'Brien PE, Dixon JB. Lap-Band: outcomes and results. *J Laparoendosc Adv Surg Tech A*. 2003;13:265–270.
  29. Updated position statement on sleeve gastrectomy as a bariatric procedure. Clinical Issues Committee of the American Society for Metabolic and Bariatric Surgery. *Surg Obes Rel Dis*. 2010;6:1–5.
  30. Taller J, Wisbach G, Bertucci W. Single incision laparoscopic sleeve gastrectomy for morbid obesity: video technique and review of first 10 cases. *Surg Obes Rel Dis*. 2010;6:559–560.
  31. Menekos E, Stamou KM, Albanopoulos K, et al. Laparoscopic sleeve gastrectomy performed with intent to treat morbid obesity: a prospective single-center study of 261 patients with a median follow-up of one year. *Obes Surg*. 2010;20:276–282.
  32. Himpens J, Dobbelaier J, Peeters G. Long-term results of laparoscopic sleeve gastrectomy for obesity. *Ann Surg*. 2010;252:319–324.
  33. Mason EE. Vertical banded gastroplasty. *Arch Surg*. 1982;117:701–706.
  34. Balsiger BM, Poggio JL, Mai J, et al. Ten and more years after vertical banded gastroplasty as primary operations for morbid obesity. *J Gastrointest Surg*. 2000;4:598–605.
  35. Fuks D, Verhaege P, Brehant O, et al. Results of laparoscopic sleeve gastrectomy: a prospective study in 135 patients with morbid obesity. *Surg*. 2009;145:106–111.
  36. Ou Yang O, Loi K, Liew V, et al. Staged laparoscopic sleeve gastrectomy followed by Roux-en-Y gastric bypass for morbidly obese patients: a risk reduction strategy. *Obes Surg*. 2008;18:1575–1580.
  37. Oshiro T, Kasama K, Umezawa A, et al. Successful management of staple line leakage at the esophagogastric junction after a sleeve gastrectomy using the HANAROSTENT. *Obes Surg*. 2010;20:530–534.
  38. Wu EC, Barba CA. Current practices in the prophylaxis of venous thromboembolism in bariatric surgery. *Obes Surg*. 2000;10:7–13.
  39. Champion JK, Williams M. Small bowel obstruction and internal hernias after laparoscopic Roux-en-Y gastric bypass: incidence, treatment, and prevention. *Obes Surg*. 2003;13:596–600.
  40. Schirmer BD, Lee SK, Northup CJ, et al. Gastrointestinal anastomosis stenosis is lower using linear rather than circular stapling during Roux-en-Y gastric bypass. Presented Society of American Gastrointestinal Surgeons 2006 Scientific Session, Dallas, TX, April 2006.
  41. Singh R, Fisher BL. Sensitivity and specificity of postoperative upper GI series following gastric bypass. *Obes Surg*. 2003;73–75.
  42. Schauer PR, Ikramuddin S, Gourash W, et al. Outcomes after laparoscopic Roux-en-Y gastric bypass for morbid obesity. *Ann Surg*. 2000;232:515–529.
  43. Nguyen NT, Goldman C, Rosenquist CJ, et al. Laparoscopic versus open gastric bypass: a randomized study of outcomes, quality of life, and costs. *Ann Surg*. 2001;234:279–291.
  44. Higa HD, Ho T, Boone KB. Laparoscopic Roux-en-Y gastric bypass: technique and 3-year follow-up. *J Laparoendosc Adv Surg Tech A*. 2001;11:377–382.
  45. Pories WJ, Swanson MS, MacDonald KG, et al. Who would have thought it? An operation proves to be the most effective therapy for adult-onset diabetes mellitus. *Ann Surg*. 1995;222:339–352.
  46. Sjostrom L, Narbro K, Karason K, et al. Effects of bariatric surgery on mortality in Swedish obese subjects. *New Engl J Med*. 2007;357:753–761.
  47. Sampalis JS, Liberman M, Auger S, Christou NV. The impact of weight-reduction surgery on health-care costs in morbidly obese patients. *Obes Surg*. 2004;14:939–947.
  48. MacDonald KG, Jr, Long SD, Swanson MS, et al. The gastric bypass operation reduces the progression and mortality of noninsulin-dependent diabetes mellitus. *J Gastrointest Surg*. 1997;1:213–220.
  49. Adams T, Gress R, Smith S, et al. Long-term mortality after gastric bypass surgery. *New Engl J Med*. 2007;357:753–761.
  50. Christou NV, Sampalis JS, Liberman M, et al. Surgery decreases long-term mortality, morbidity, and health care use in morbidly obese patients. *Ann Surg*. 2004;240:416–423.
  51. Buchwald H, Avidor Y, Braunwald E, et al. Bariatric surgery: a systematic review and meta-analysis. *JAMA*. 2004;292:1724–1737.
  52. Maggard MA, Shugarman LR, Suttorp M, et al. Meta-analysis: surgical treatment of obesity. *Ann Int Med*. 2005;142:547–559.
  53. Sugerman HJ, Sugerman EL, DeMaria EJ, et al. Bariatric surgery for severely obese adolescents. *J Gastrointest Surg*. 2003;232:515–529.
  54. Pories WJ, MacDonald KG, Jr, Flickinger EG, et al. Is type II diabetes mellitus (NIDDM) a surgical disease? *Ann Surg*. 1992;215:633–643.
  55. Rubino F, Marescaux J. Effect of duodenal-jejunal exclusion in a non-obese animal model of type 2 diabetes: a new perspective for an old disease. *Ann Surg*. 2004;239:1–11.
  56. Cummings DE. Endocrine mechanisms mediating remission of diabetes after gastric bypass surgery. *Int J of Obes (Lond)*. 2009;33:S33–S40.
  57. Shiffman ML, Sugerman HJ, Kellum JM, et al. Gallstone formation after rapid weight loss: a prospective study in patients undergoing gastric bypass surgery for treatment of morbid obesity. *Am J Gastroenterol*. 1991;86:1000–1005.
  58. Sugerman HJ, Brewer WH, Shiffman ML, et al. A multi-center, placebo-controlled, randomized, double-blind, prospective trial of prophylactic ursodiol for the prevention of gallstone formation following gastric bypass-induced rapid weight loss. *Am J Surg*. 1995;169:90–96.
  59. Fuller W, Rasmussen JJ, Ghosh J, Ali MR. Is routine cholecystectomy indicated for asymptomatic cholelithiasis in patients undergoing gastric bypass? *Obes Surg*. 2007;17:747–751.
  60. Patel JA, Patel NA, Piper GL, Smith DE, 3rd, et al. Perioperative management of cholelithiasis in patients presenting for laparoscopic Roux-en-Y gastric bypass: have we reached a consensus? *Am Surg*. 2009;75:470–476.
  61. Amaral JF, Thompson WR. Gallbladder disease in the morbidly obese. *Am J Surg*. 1985;149:551–557.
  62. Schmidt JH, Hocking MP, Rout WR, et al. The case for prophylactic cholecystectomy concomitant with gastric restriction for morbid obesity. *Am Surg*. 1988;54:269–272.
  63. Tucker ON, Fajnwaks P, Szomstein S, Rosenthal RJ. Is concomitant cholecystectomy necessary in patients undergoing laparoscopic gastric bypass surgery? *Surg Endosc*. 2008;22:2450–2454.



64. Hamad GG, Ikramuddin S, Gourash WF, et al. Elective cholecystectomy during laparoscopic Roux-en-Y gastric bypass: is it worth the wait? *Obes Surg.* 2003;13:76–81.
65. Kim JJ, Schirmer B. Safety and efficacy of simultaneous cholecystectomy at Roux-en-Y gastric bypass. *Surg Obes Rel Dis.* 2009;5:48–50.
66. Frezza EE, Ikramuddin S, Gourash WF, et al. Symptomatic improvement in gastroesophageal reflux disease (GERD) following laparoscopic Roux-en-Y gastric bypass. *Surg Endosc.* 2002;16:1027–1031.
67. Weiss HG, Nehoda H, Labeck B, et al. Treatment of morbid obesity with laparoscopic adjustable gastric banding affects esophageal motility. *Am J Surg.* 2000;180:479–482.
68. Madalosso CA, Gurski RR, Callegari-Jacques SM, et al. The impact of gastric bypass on gastroesophageal reflux in patients with morbid obesity: a prospective study based on the Montreal Consensus. *Ann Surg.* 2010;25:244–248.
69. Thodiyil PA, Mattar SA, Schauer PR. Gastroesophageal reflux disease in the bariatric surgery patient. In: Schauer PR, Schirmer BD, Brethauer SA, eds. *Minimally Invasive Bariatric Surgery.* New York, NY: Springer; 2007:441–442.
70. DeMaria EJ, Pati V, Warthen M, Winegar DA. Baseline data from American Society for Metabolic and Bariatric Surgery—designated Bariatric Surgery Centers of Excellence using the Bariatric Outcomes Longitudinal Database. *Surg Obes Rel Dis.* 2010;6:347–355.
71. Hutter MJ, Schirmer DB, Jones DB, et al. Coverage for bariatric surgery should be extended to American College of Surgeons—Bariatric Surgery Center Network (ACS-BSCN) level two (lower volume) accredited centers. *Ann Surg.* 2011;254:410–420.
72. <http://www.acsnsqip.org>: National Surgical Quality Improvement Program database, 2010, American College of Surgeons. Comparison of University of Virginia to 15 other centers. Accessed April 2010.
73. Nguyen NT, Longoria M, Chalifoux S, Wilson SE. Gastrointestinal hemorrhage after laparoscopic gastric bypass. *Obes Surg.* 2004;14:1308–1312.
74. AwAwa O, Raftopoulos I, Luketich JD, Courcoulas A. Acute, complete proximal small bowel obstruction after laparoscopic gastric bypass due to intraluminal blood clot formation. *Surg Obes Rel Dis.* 2005;1:418–423.
75. Lee S, Carmody B, Wolfe L, et al. Effect of location and speed of diagnosis on anastomotic leak outcomes in 3828 gastric bypass patients. *J Gastrointest Surg.* 2007;11:708–713.
76. DeMaria EJ, Sugeran HJ, Kellum JM, et al. Results of 281 consecutive total laparoscopic Roux-en-Y gastric bypasses to treat morbid obesity. *Ann Surg.* 2002;235:640–645.
77. Ganci-Cerrud G, Herrera MF. Role of radiologic contrast studies in the early postoperative period after bariatric surgery. *Obes Surg.* 1999;9:532–534.
78. Thodiyil PA, Yenumula P, Rogula T, et al. Selective non operative management of leaks after gastric bypass: lesson learned from 2675 consecutive patients. *Ann Surg.* 2008;248(5):782–792.
79. Durak E, Inabnet WB, Schroppe B, et al. Incidence and management of enteric leaks after gastric bypass for morbid obesity during a 10-year period. *Surg Obes Rel Dis.* 2008;4:389–393.
80. Thaler K. Treatments of leaks and other bariatric complications with endoluminal stents. *J Gastrointest Surg.* 2009;13:1567–1569.
81. Lewis CE, Jensen C, Tejirian T, et al. Early jejunojunostomy obstruction after laparoscopic gastric bypass: case series and treatment algorithm. *Surg Obes Rel Dis.* 2009;5:203–207.
82. Koppman JS, Li C, Gandsas A. Small bowel obstruction after laparoscopic Roux-en-Y gastric bypass: a review of 9,527 patients *J Am Coll Surg.* 2008;206:571–584.
83. Higa K, Boone K. Laparoscopic Roux-en-Y gastric bypass: complications. In: Schauer PR, Schirmer BD, Brethauer SA, eds. *Minimally Invasive Bariatric Surgery.* New York, NY: Springer; 2007:292–296.
84. Nguyen NT, Stevens CM, Wolfe BM. Incidence and outcome of anastomotic stricture after laparoscopic gastric bypass. *J Gastrointest Surg.* 2003;7:997–1003.
85. Vance PL, de Lange EE, Shaffer HA, Jr, Schirmer B. Gastric outlet obstruction following surgery for morbid obesity: efficacy of fluoroscopically guided balloon dilatation. *Radiology.* 2002;222:70–72.
86. Go MR, Muscarella P, Needleman BJ, et al. Endoscopic management of stomal stenosis after Roux-en-Y gastric bypass. *Surg Endosc.* 2004;18:56–59.
87. Sanyal AJ, Sugeran HJ, Kellum JM, et al. Stomal complications of gastric bypass: incidence and outcome of therapy. *Am J Gastroenterol.* 1992;87:1165–1169.
88. Sacks BC, Mattar SG, Qureshi FG, et al. Incidence of marginal ulcers and the use of absorbable anastomotic sutures in laparoscopic Roux-en-Y gastric bypass. *Surg Obes Rel Dis.* 2006;2:11–16.
89. Erenoglu C, Schirmer BD, Miller A. Flexible endoscopy in the management of patients undergoing Roux-en-Y gastric bypass. *Obes Surg.* 2002;12:634–638.
90. Patel RA, Brolin RE, Gandhi A. Revisional operations for marginal ulcer after Roux-en-Y gastric bypass. *Surg Obes Rel Dis.* 2009;5:317–322.
91. Csendes A, Burgos AM, Altuve J, Bonacic S. Incidence of marginal ulcer 1 month and 1 to 2 years after gastric bypass: a prospective consecutive endoscopic evaluation of 442 patients with morbid obesity. *Obes Surg.* 2009;19:135–138.
92. Pope GD, Goodney PP, Burchard KW, et al. Peptic ulcer/stricture after gastric bypass: A comparison of technique and acid suppression variables. *Obes Surg.* 2002;12:30–33.
93. Nguyen NT, Hinojosa MW, Gray J, Fayad C. Reoperation for marginal ulceration. *Surg Endosc.* 2007;21:1919–1921.
94. Aasheim ET. Wernicke encephalopathy after bariatric surgery: a systematic review. *Ann Surg.* 2008;248:714–720.
95. Cizmecioglu FM, Etiler N, Gormus U, et al. Hypovitaminosis d in obese and overweight school children. *J Clin Res Pediatr Endocrinol.* 2008;1:89–96.
96. Williams SE. Metabolic bone disease in the bariatric surgery patient. *J Obes.* 2011;2011:634614.
97. Scopinaro N, Gianetta E, Pandolfo N, Anfossi A, Berretti B, Bachi V. Bilio-pancreatic bypass. Proposal and preliminary experimental study of a new type of operation for the functional surgical treatment of obesity. *Minerva Chir.* 1976;31(10):560–566.
98. Hess DS, Hess DW. Biliopancreatic diversion with a duodenal switch. *Obes Surg.* 1998;8(1):53–59.
99. Buchwald H, Williams SE. Bariatric surgery worldwide 2003. *Obes Surg.* 2004;14:1157–1164.
100. Scopinaro N, Adami GF, Marinari GM, et al. Biliopancreatic diversion. *World J Surg.* 1998;22:936–946.
101. Laurenus A, Taha O, Maleckas A, et al. Laparoscopic biliopancreatic diversion/duodenal switch or laparoscopic Roux-en-Y gastric bypass for super-obesity-weight loss versus side effects. *Surg Obes Rel Dis.* 2010;6:408–414.
102. Scopinaro N, Gianetta E, Adami GF, et al. Biliopancreatic diversion for obesity at eighteen years. *Surgery.* 1996;119:261–268.
103. Anthonie GJ, Lord RV, Demeester TR, et al. The duodenal switch operation for the treatment of morbid obesity. *Ann Surg.* 2003;238:618–628.
104. Slater G, Ren CJ, Siegel N, et al. Serum fat-soluble vitamin deficiency and abnormal calcium metabolism after malabsorptive bariatric surgery. *J Gastrointest Surg.* 2004;8:48–55.
105. Hong D, Patterson EJ. Laparoscopic malabsorptive procedures: Post-operative management and nutritional evaluation. In: Schauer PR, Schirmer BD, Brethauer SA, eds. *Minimally Invasive Bariatric Surgery.* New York, NY: Springer; 2007:339–343.
106. Baltasar A, Bou R, Miro J, et al. Laparoscopic biliopancreatic diversion with duodenal switch: technique and initial experience. *Obes Surg.* 2002;12:245–248.
107. Zollinger RW, Coccia MR, Zollinger RW, II. Critical analysis of jejunioileal bypass. *Am J Surg.* 1983;146:626–630.
108. Vage V, Solhaug JH, Berstad A, et al. Jejunioileal in the treatment of morbid obesity: a 25-year follow-up study of 36 patients. *Obes Surg.* 2002;12:312–318.
109. Sugeran HJ, Kellum JM, DeMaria EJ, et al. Conversion of failed or complicated vertical banded gastroplasty to gastric bypass in morbid obesity. *Am J Surg.* 1996;171:263–269.
110. Jones KB, Jr. Revisional bariatric surgery—safe and effective. *Obes Surg.* 2001;11:183–189.
111. Calmes JM, Guisti V, Suter M. Reoperative laparoscopic Roux-en-Y gastric bypass: an experience with 49 cases. *Obes Surg.* 2005;15:316–322.
112. Gavert N, Szold A, Abu-Abied S. Laparoscopic revisional surgery for life-threatening stenosis following vertical banded gastroplasty, together with placement of an adjustable gastric band. *Obes Surg.* 2003;13:399–403.
113. Cariani S, Nottola D, Grani S, et al. Complications after gastroplasty and gastric bypass as a primary operation and as a reoperation. *Obes Surg.* 2001;11:487–490.
114. Buchwald H., Buchwald JN. Evolution of operative procedures for the management of morbid obesity. *Obes Surg.* 2002;12:705–717.

115. Kasza J, Brody F, Vaziri K, et al. Analysis of poor outcomes after laparoscopic adjustable gastric banding. *Surg Endosc.* 2011;25:41–47.
116. Mognol P, Chosidow D, Marmuse JP. Laparoscopic conversion of laparoscopic gastric banding to Roux-en-Y gastric bypass: a review of 70 patients. *Obes Surg.* 2004;14:1349–1353.
117. Slater GH, Fielding GA. Combining laparoscopic adjustable gastric banding and biliopancreatic diversion after failed bariatric surgery. *Obes Surg.* 2004;14:677–682.
118. MacLean LD, Rhode BM, Nohr C, Katz S, McLean AP. Stomal ulcer after gastric bypass. *J Am Coll Surg.* 1997;185:87–88.
119. Thompson CC, Slattery J, Bundga ME, Lautz DB. Peroral endoscopic reduction of dilated gastrojejunal anastomosis after Roux-en-Y gastric bypass: a possible new option for patients with weight regain. *Surg Endosc.* 2006;20:1744–1748.
120. Leitman IM, Virk CS, Avgerinos DV, et al. Early results of trans-oral endoscopic placcation and revision of the gastric pouch and stoma following Roux-en-Y gastric bypass surgery. *JSLs.* 2010;14:217–220.
121. Bessler M, Daud A, DiGiorgi MF, et al. Adjustable gastric banding as revisional bariatric procedure after failed gastric bypass—intermediate results. *Surg Obes Rel Dis.* 2010;6:31–35.
122. Mullady DK, Lautz DB, Thompson CC. Treatment of weight regain after gastric bypass surgery when using a new endoscopic platform: initial experience and early outcomes (with video). *Gastrointest Endosc.* 2009;70:440–444.
123. Mikami D, Needleman B, Narula V, et al. Natural orifice surgery: initial U.S. experience utilizing the StomaphyX to reduce gastric pouches after Roux-en-Y gastric bypass. *Surg Endosc.* 2010;24:233–238.
124. Dixon JB, Dixon ME, O'Brien PE. Pregnancy after Lap-Band surgery: management of the band to achieve healthy weight outcomes. *Obes Surg.* 2001;11:59–65.
125. Richards DS, Miller DK, Goodman GN. Pregnancy after gastric bypass for morbid obesity. *Obes Surg.* 1998; 8:461–466.
126. Zitsman JL, Fennoy I, Witt MA, et al. Laparoscopic adjustable gastric banding in adolescents: short-term results. *J Ped Surg.* 2011;46:157–162.
127. Kalra M, Inge T, Garcia V, et al. Obstructive sleep apnea in morbidly obese adolescents: effect of bariatric surgical intervention. *Obes Res.* 2005;13:1175–1179.
128. Gonzalez R, Lin E, Mattar SG, et al. Gastric bypass for morbid obesity in patients 50 years or older: laparoscopic technique safe? *Am Surg.* 2003;69:547–553.
129. Willkomm CM, Fisher TL, Barnes GS, et al. Surgical weight loss > 65 years old: is it worth the risk? *Surg Obes Rel Dis.* 2010;6:491–496.
130. Livingston EH, Huerta S, Arthur D, et al. Male gender is a predictor of morbidity and age a predictor of mortality in patients undergoing gastric bypass surgery. *Ann Surg.* 2002;236:576–582.

*This page intentionally left blank*



# PERSPECTIVE ON MORBID OBESITY AND ITS SURGICAL TREATMENT

Stacy A. Brethauer • Philip R. Schauer

In this chapter, Dr Schirmer and Dr Hallowell provide a detailed and comprehensive overview of the surgical management of morbid obesity. The authors appropriately point out the tremendous worldwide impact that the obesity epidemic will have in the coming years. The chapter provides excellent clinical and technical advice from two experienced bariatric surgeons, and there is little to add regarding the thoughtful approach to patient care that the authors outline. There are, however, several areas within bariatric surgery that remain controversial. The field of bariatric surgery continues to evolve, and new procedures, new technologies, and expanding indications for surgery provide excellent opportunities for research, innovation, and debate. We address several of these areas in our commentary to this excellent chapter.

## DIABETES SURGERY

As the obesity epidemic has gained recognition as a major public health issue, though, the closely associated epidemic of type 2 diabetes mellitus (T2DM) has also emerged. In fact, the number of people with diabetes mellitus worldwide has more than doubled in the last three decades.<sup>1</sup> In 2010, an estimated 285 million people worldwide had diabetes and this is projected to increase to 439 million by the year 2030.<sup>2</sup> This staggering number represents nearly 8% of the world population between ages 20 and 79. In addition, while there is little argument that preventative and societal measures must be taken to mitigate this crisis, the importance of having safe, effective, and durable therapies for patients who already have these diseases has taken on greater importance.

The surgical treatment of diabetes, or metabolic surgery, is now gaining acceptance even among physicians who were ardent critics of this concept several years ago. Important advances in our understanding of how these operations effect

glucose homeostasis are emerging and partly account for the increased acceptance. Insulin sensitivity improves due to weight loss (visceral fat loss). In addition, several studies suggest that an enhanced incretin effect driven by increased secretion of gut hormones such as glucagon-like peptide 1 (GLP-1) and peptide YY (PYY) may account for improvement in insulin secretion following bypass procedures but not purely restrictive operations.<sup>3,4</sup> Improvements in insulin secretion occur rapidly, even before much weight loss occurs, explaining why remission of diabetes may occur so quickly after bypass surgery.<sup>5</sup> Much more investigation into mechanisms of diabetes improvement after metabolic surgery is required to gain a clear understanding of how these operations effect glucose homeostasis.

Convincing clinical outcomes resulting in diabetes remission rates of 40–80% have provided a foundation for a more collaborative effort between medical and surgical colleagues in treating this disease. This effort began in earnest at the 2007 Diabetes Surgery Summit in Rome<sup>6</sup> and was followed by the American Diabetes Association's recognition of the role of bariatric surgery in the treatment of diabetes in 2009.<sup>7</sup> More recently, the International Diabetes Federation (IDF), an umbrella organization of more than 200 national diabetes associations in more than 160 countries, published a position statement on bariatric surgery concluding that "Bariatric surgery is an appropriate treatment for people with type 2 diabetes and severe obesity (BMI  $\geq$  35 kg/m<sup>2</sup>)." The IDF statement states that surgery "should be prioritized for severely obese patients (BMI 35 kg/m<sup>2</sup>) with T2DM," instead of suggesting that it is merely "an option."<sup>8</sup>

Further high-quality evidence is needed to support this change in management strategy, and there are many ongoing prospective randomized trials that will provide more definitive evidence in the next 2–3 years. Of note, many of these trials include patients with body mass index (BMI) in the 30–35 range and these data will hopefully provide further evidence regarding the role of metabolic surgery, even in the absence of severe obesity.

## SLEEVE GASTRECTOMY

The authors discuss sleeve gastrectomy as a relatively new procedure and offer some skepticism regarding this procedure's future as a bariatric operation. While it is certainly true that there is not one perfect bariatric procedure, it is important to develop and investigate new procedures that offer various risk/benefit profiles to our patients. The sleeve gastrectomy has now clearly established itself as a procedure with a risk/benefit profile that lies between the laparoscopic adjustable gastric band and the gastric bypass.<sup>9,10</sup> Laparoscopic sleeve gastrectomy's (LSG) irreversibility and the potential for complications are detractors for some patients, but the lack of a foreign body and paucity of long-term complications make it very appealing to others.

Sleeve gastrectomy is often compared to the now abandoned vertical banded gastroplasty (VBG) by some critics, but sleeve gastrectomy is a fundamentally different operation than VBG. First, it is a resectional procedure and this seems to have a powerful effect on hunger and satiety. Second, the LSG does not include a prosthetic band as the VBG did. The presence of a fixed, nonadjustable, stenotic ring in the middle of the stomach was a major reason the VBG failed from an anatomic and behavioral standpoint. Intolerance to solid food, severe refractory gastroesophageal reflux, maladaptive eating behaviors, and loss of restriction (gastrogastric fistula) are either not possible or are rarely seen after sleeve gastrectomy. As with any bariatric procedure, there are a percentage of patients who will require revisional surgery for inadequate weight loss. In the current literature, the percentage of patients undergoing a second operation ranges from 3 to 20%.<sup>11,12</sup> The major advantage of LSG over other procedures in this regard is the relative ease of converting LSG to a bypass procedure. Revision of LSG to a gastric bypass or duodenal switch for patients who require further weight loss can be done safely and is effective.<sup>12,13</sup>

Additionally, there are good data to support the concept that the sleeve gastrectomy is a metabolic procedure and not just a restrictive operation. Ghrelin is suppressed immediately after LSG and this effect is durable.<sup>13</sup> Rapid gastric emptying and nutrient transport after LSG also results in early stimulation of the L cells in the distal bowel.<sup>14–16</sup> This early, exaggerated production of gut hormones like GLP-1 and PYY after LSG certainly places this operation in the category of metabolic procedures.

Another criticism of LSG is the lack of long-term data. As more surgeons used this operation as a primary procedure in the last 5 years, a robust body of literature, supporting LSG as a safe operation, developed. Current data also include many comparative studies and six randomized controlled trials that demonstrate equivalence or superiority to other accepted procedures. Most of the early published series, though, had follow-up periods of less than 3 years. More recently, though, there are several studies that report the long-term efficacy of LSG. In these series, the overall average excess weight loss (EWL) 5–8 years after LSG ranges between 53 and 69%.<sup>12,13,17–19</sup> These long-term results compare favorably to other widely accepted procedures. Based on these data, the American Society for Metabolic and Bariatric Surgery has recently endorsed sleeve gastrectomy as a primary operation and as a first-stage procedure in high-risk patients ([www.asmb.org](http://www.asmb.org)).

## INNOVATION

There is currently a large gap in our therapeutic armamentarium between medical therapy and surgery. Endoscopic therapy for the treatment of obesity is an appealing concept that could potentially fill this gap. As the authors point out, there have been several small trials and a few multicenter studies investigating

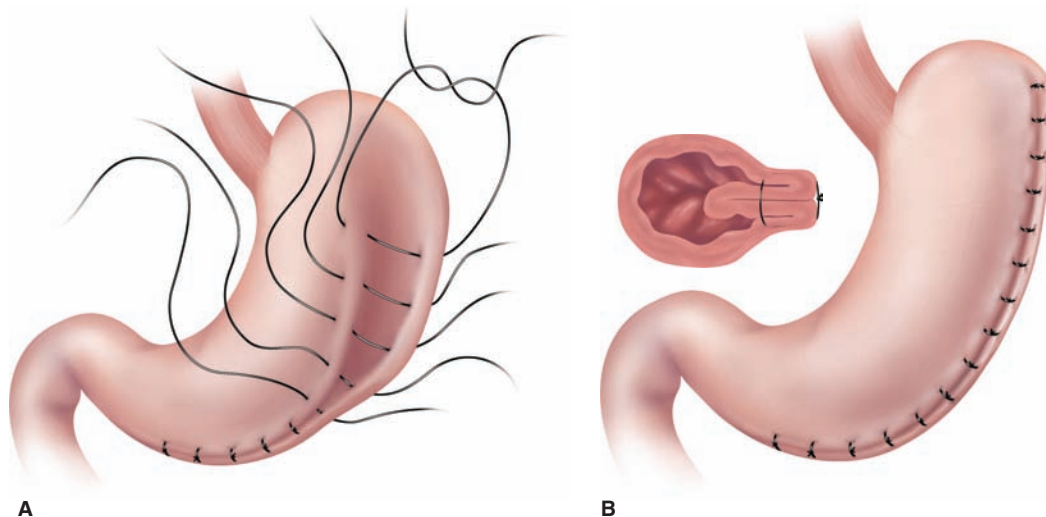


FIGURE 28-1 Laparoscopic greater curvature plication.

endoluminal suturing and stapling devices to achieve gastric restriction.<sup>20,21</sup> These early results have provided a starting point for this emerging field. There are many obstacles to overcome before endoluminal procedures, and devices are ready for general use. Developing devices and procedures that are reproducible with durable results is a formidable challenge. Replaceable devices or repeated therapy with suturing or plication may be a more reasonable clinical goal, but this paradigm is unlikely to be embraced by third-party payers or regulatory agencies.

In the meantime, developing new and less invasive surgical procedures is important to help broaden the options we have for patients. Investigational procedures such as greater curvature plication or the combination of gastric plication and banding have some promising early results (Fig. 28-1).<sup>22</sup> Identifying the true risk/benefit profiles of these new procedures and determining the optimal patients for them remain a challenge and require further long-term investigation.

Innovation has played an important role in the history of bariatric surgery and it should continue to do so. As new technologies and procedures emerge, they should be developed and investigated responsibly with patient safety as the primary goal.

## REFERENCES

1. Danaei G, Finucane MM, Lu Y, et al. National, regional, and global trends in fasting plasma glucose and diabetes prevalence since 1980: systematic analysis of health examination surveys and epidemiological studies with 370 country-years and 2.7 million participants. *Lancet*. 2011;378(9785):31–40.
2. Shaw JE, Sicree RA, Zimmet PZ. Global estimates of the prevalence of diabetes for 2010 and 2030. *Diabetes Res Clin Pract*. 2010;87(1):4–14.
3. Laferriere B, Teixeira J, McGinty J, et al. Effect of weight loss by gastric bypass surgery versus hypocaloric diet on glucose and incretin levels in patients with type 2 diabetes. *J Clin Endocrinol Metab*. 2008;93(7):2479–2485.
4. Kashyap SR, Daud S, Kelly KR, et al. Acute effects of gastric bypass versus gastric restrictive surgery on beta-cell function and insulinotropic hormones in severely obese patients with type 2 diabetes. *Int J Obes (Lond)*. 2010;34(3):462–471.
5. Schauer PR, Burguera B, Ikramuddin S, et al. Effect of laparoscopic Roux-en Y gastric bypass on type 2 diabetes mellitus. *Ann Surg*. 2003;238(4):467–484; discussion 84–85.
6. Rubino F, Kaplan LM, Schauer PR, et al. The Diabetes Surgery Summit consensus conference: recommendations for the evaluation and use of gastrointestinal surgery to treat type 2 diabetes mellitus. *Ann Surg*. 2010;251(3):399–405.
7. Standards of medical care in diabetes—2009. *Diabetes Care*. 2009;32(Suppl 1):S13–S61.
8. Dixon JB, Zimmet P, Alberti KG, et al. Bariatric surgery: an IDF statement for obese Type 2 diabetes. *Diabet Med*. 2011;28(6):628–642.
9. Finks JF, Kole KL, Yenumula PR, et al. Predicting risk for serious complications with bariatric surgery: results from the Michigan Bariatric Surgery Collaborative. *Ann Surg*. 2011;254(4):633–640.
10. Hutter MM, Schirmer BD, Jones DB, et al. First report from the American College of Surgeons Bariatric Surgery Center Network: laparoscopic sleeve gastrectomy has morbidity and effectiveness positioned between the band and the bypass. *Ann Surg*. 2011;254(3):410–420; discussion 420–422.
11. Sanchez-Santos R, Masdevall C, Baltasar A, et al. Short- and mid-term outcomes of sleeve gastrectomy for morbid obesity: the experience of the Spanish National Registry. *Obes Surg*. 2009;19(9):1203–1210.
12. Himpens J, Dobbelaire J, Peeters G. Long-term results of laparoscopic sleeve gastrectomy for obesity. *Ann Surg*. 2010;252(2):319–324.
13. Bohdjalian A, Langer FB, Shakeri-Leidenmuhler S, et al. Sleeve gastrectomy as sole and definitive bariatric procedure: 5-year results for weight loss and ghrelin. *Obes Surg*. 2010;20(5):535–540.
14. Karamanakos SN, Vagenas K, Kalfarentzos F, et al. Weight loss, appetite suppression, and changes in fasting and postprandial ghrelin and peptide-YY levels after Roux-en-Y gastric bypass and sleeve gastrectomy: a prospective, double blind study. *Ann Surg*. 2008;247(3):401–407.
15. Peterli R, Wolnerhanssen B, Peters T, et al. Improvement in glucose metabolism after bariatric surgery: comparison of laparoscopic Roux-en-Y gastric bypass and laparoscopic sleeve gastrectomy: a prospective randomized trial. *Ann Surg*. 2009;250(2):234–241.
16. Melissas J, Koukouraki S, Askoxylakis J, et al. Sleeve gastrectomy: a restrictive procedure? *Obes Surg*. 2007;17(1):57–62.
17. D'Hondt M, Vanneste S, Pottel H, et al. Laparoscopic sleeve gastrectomy as a single-stage procedure for the treatment of morbid obesity and the resulting quality of life, resolution of comorbidities, food tolerance, and 6-year weight loss. *Surg Endosc*. 2011;25(8):2498–2504.
18. Sarela AI, Dexter SP, O'Kane M, et al. Long-term follow-up after laparoscopic sleeve gastrectomy: 8-9-year results. *Surg Obes Relat Dis*. 2011. [Epub ahead of print]
19. Weiner RA, Weiner S, Pomhoff I, et al. Laparoscopic sleeve gastrectomy— influence of sleeve size and resected gastric volume. *Obes Surg*. 2007; 17(10):1297–1305.
20. Brethauer SA, Chand B, Schauer PR, et al. Transoral gastric volume reduction for weight management: technique and feasibility in 18 patients. *Surg Obes Relat Dis*. 2010;6(6):689–694.
21. Deviere J, Ojeda Valdes G, Cuevas Herrera L, et al. Safety, feasibility and weight loss after transoral gastroplasty: first human multicenter study. *Surg Endosc*. 2008;22(3):589–598.
22. Brethauer SA, Harris JL, Kroh M, et al. Laparoscopic gastric plication for treatment of severe obesity. *Surg Obes Relat Dis*. 2011;7(1):15–22.



*This page intentionally left blank*



# INTESTINE AND COLON

*This page intentionally left blank*



# SMALL BOWEL OBSTRUCTION

Guido M. Sclabas • George A. Sarosi  
• Saboor Khan • Michael G. Sarr • Kevin E. Behrns

Hippocrates, the father of medicine, recognized, described, and treated bowel obstruction many years ago. Praxagoras appears to have performed the earliest recorded operation for bowel obstruction circa 350 BC when he relieved the obstruction of a bowel segment by creating a decompressive, diverting enterocutaneous fistula.

Bowel obstruction continues to be one of the most common intra-abdominal problems faced by general surgeons in their practice. Independent of the underlying etiology, bowel obstruction remains a major cause of morbidity and mortality. Early recognition and aggressive treatment are crucial in preventing irreversible ischemia and transmural necrosis and thereby in decreasing mortality and long-term morbidity. Despite multiple recent advances in diagnostic imaging and marked advances in our treatment armamentarium, intestinal obstruction will continue to occur. The aim of this chapter is to review the etiologies, pathogenesis, diagnosis, and management in the current era with emphasis on early diagnosis and aggressive management, both operative and nonoperative.

## DEFINITION

Bowel obstruction occurs when the normal propulsion and passage of intestinal contents cannot occur for whatever reason. This obstruction can involve only the small intestine (small bowel obstruction), the large intestine (large bowel obstruction), or via systemic alterations in metabolism, electrolyte balance, or neuroregulatory mechanisms involving both the small and large intestine (generalized ileus). Mechanical obstruction is due to physical obstruction of the intestinal lumen either from something within the lumen in the wall of the intestine or from an extraluminal cause, while ineffective motility without any physical obstruction causes functional obstruction, also called “pseudo-obstruction,” or (paralytic) ileus. Classification can also be based on duration (acute vs chronic), extent (partial vs complete), and type of obstruction (simple vs closed-loop vs strangulation). Closed-loop and strangulation obstruction fall into the

category of complicated obstruction and require emergent intervention.

## Mechanical Bowel Obstruction

*Mechanical bowel obstruction* is defined as a physical blockage of the intestinal lumen. This blockage may be intrinsic or extrinsic to the wall of the intestine or secondary to luminal obstruction arising from the intraluminal contents (eg, an intraluminal gallstone or other foreign body) (Table 29-1). Partial obstruction implies that the intestinal lumen is narrowed, but some intestinal content still can transit aborally. In the presence of a complete obstruction, the lumen is obliterated, and no intestinal content can get beyond this point of obstruction. The risk of so-called strangulation, that is, vascular compromise of the intestine, is increased markedly in the presence of a complete obstruction, especially when caused by an extraluminal etiology such as a hernia defect of an adhesive band compressing the small bowel mesentery. Accordingly, complete obstruction can be categorized further into simple, closed-loop, and strangulation obstruction. A simple obstruction is an obstruction without any vascular compromise and the intestine can be decompressed proximally. Closed-loop obstruction occurs when both ends of the involved intestinal segment are obstructed (eg, volvulus or a compressive adhesive band), and results in increased intraluminal pressure secondary to increased intestinal secretion and accumulation of fluid in the involved intestinal segment. Closed-loop obstruction carries a much greater risk of vascular compromise and irreversible intestinal ischemia of the intestinal loop. Finally, strangulation occurs when the blood supply to the affected intestinal segment is compromised, leading to focal or segmental transmural necrosis. The affected segment may involve only a portion of the gut bowel wall compressed by a tight adhesive band or an entire intestinal segment as occurs with a strangulated hernia or a closed loop. If viability of the bowel is maintained after relief of the obstruction, strangulation can be reversed (reversible strangulation obstruction). In contrast, irreversible strangulation occurs if the vascular

**TABLE 29-1: MECHANICAL BOWEL OBSTRUCTION**

Lesions Extrinsic to the Intestinal Wall	Lesions Intrinsic to the Intestinal Wall
<b>Adhesions</b>	<b>Congenital</b>
Postoperative	Intestinal atresia
Congenital	Meckel's diverticulum
Postinflammatory	Duplications/cysts
<b>Hernia</b>	<b>Inflammatory</b>
External abdominal wall (congenital or acquired)	Crohn's disease
Internal	Eosinophilic granuloma
Incisional	<b>Infections</b>
<b>Congenital</b>	Tuberculosis
Annular pancreas	Actinomycosis
Malrotation (rotational abnormality)	Complicated diverticulitis
Omphalomesenteric duct remnant	Appendicitis
<b>Neoplastic</b>	<b>Neoplastic</b>
Carcinomatosis	Primary neoplasms
Extraintestinal neoplasm	Metastatic neoplasms
<b>Inflammatory</b>	<b>Miscellaneous</b>
Intra-abdominal abscess	Intussusception
"Starch" peritonitis	Endometriosis
<b>Miscellaneous</b>	Radiation enteropathy/stricture
Volvulus	Intramural hematoma
Gossypiboma	Ischemic stricture
Superior mesenteric artery syndrome	<b>Intraluminal/obstructor obstruction</b>
	Gallstone
	Enterolith
	Phytobezoar
	Parasite infestation
	Swallowed foreign body (magnets, illicit drug mules, sharp objects that perforate the bowel, etc)

Data from Tito WA, Sarr MG. Intestinal obstruction. In: Zuidema GD, ed. *Surgery of the Alimentary Tract*. Philadelphia, PA: WB Saunders; 1996;375–416.

compromise has caused irreversible bowel ischemia that will progress to transmural necrosis whether or not the strangulation is relieved. All irreversible strangulation obstructions start as a reversible strangulation obstruction and, thus, the urgency and importance of early diagnosis.

## Functional Bowel Obstruction

Functional obstruction or pseudo-obstruction is present when factors causing either paralysis or dysmotility of intestinal peristalsis prevent the coordinated transport of the luminal content aborally (distally) (Table 29-2); the term "paralytic ileus" is used for this condition in most of Europe and Asia and should be distinguished from mechanical ileus. In the United States, the term "ileus" usually refers to functional obstruction, while outside the United States, the term "ileus" is synonymous with

**TABLE 29-2: FUNCTIONAL BOWEL OBSTRUCTION, ILEUS, AND PSEUDO-OBSTRUCTION**

Intra-abdominal Causes	Extra-abdominal Causes
<b>Intraperitoneal problems</b>	<b>Thoracic problems</b>
Peritonitis (chemical infections)	Myocardial infarction
Intra-abdominal abscess	Severe congestive heart failure
Contained anastomotic leak	Pneumonia
Postoperative (physiologic)	Thoracic trauma
Chemical:	<b>Metabolic abnormalities</b>
Gastric juice	Electrolyte imbalance
Bile	Sepsis
Blood	Lead poisoning
Autoimmune:	Porphyria
Serositis	Hyperglycemia/ketoacidosis
Myositis	Hypothyroidism
Vasculitis	Hypoparathyroidism
Neuropathy	Uremia
Intestinal ischemia:	<b>Medicines</b>
Arterial or venous	Opiates
Sickle cell disease	Anticholinergics
<b>Retroperitoneal problems</b>	Alpha-adrenergic agonists
Urolithiasis	Antihistamines
Pyelonephritis	Psychotropic drugs
Metastasis	Catecholamines
Pancreatitis	<b>Miscellaneous</b>
Retroperitoneal trauma/hematoma	Acute spinal cord injury
	Pelvic fracture
	Head trauma
	Chemotherapy
	Radiation therapy
	Hip arthroplasty
	Renal transplantation
	Acute megacolon (ulcerative colitis, <i>Clostridium difficile</i> infection)

Used with permission from Helton WS, Fischella P. Intestinal obstruction. In: Souba et al., eds. *ACS Surgery Principles and Practice*. Hamilton, ONT, Canada: BC Decker; 1990; used with permission from PMPH-USA, LTD, Shelton, CT.

intestinal obstruction of any cause—thus, the use of the terms "mechanical ileus" and "paralytic ileus." With a functional obstruction, no physical site of mechanical obstruction is present. The most common form of functional bowel obstruction is postoperative ileus, because it is present to some extent after most all intra-abdominal operative procedures. Various types of extra-abdominal medical and surgical conditions may also cause a transient functional ileus. Besides these more frequent forms of functional bowel obstruction caused by a response to local or systemic stimuli, there is a group of rare, chronic, progressive, gastrointestinal (GI) "pseudo-obstructions." These rare forms of functional obstruction are related either to hereditary or acquired visceral myopathies, visceral neuropathies, or a poorly understood disruption of myoneural coordination of organized contractile activity.

Postoperative ileus represents the most common cause of delayed hospital discharge after abdominal operations.

Its duration tends to correlate with the degree of surgical trauma as well as the type of operation, and it might even be considered a “physiologic” response. A prolonged “pathophysiologic” postoperative ileus may develop in patients operated on for radiation enteropathy, chronic obstruction, or severe peritonitis; with radiation enteropathy, the ileus is probably related to radiation-induced damage to neuromuscular coordination in the irradiated segments. Recovery from a functional ileus after manipulation and local trauma differs among anatomic segments of the GI tract. The small bowel generally recovers effective motor function within several hours after the operation; indeed, contractile activity in the small intestine is evident even during a celiotomy as is demonstrable easily by transient focal intestinal compression. In contrast, it may take 24–48 hours for the stomach to regain normal motor activity leading to delayed gastric emptying, while the colon may take 3–5 days to recover propulsive activity postoperatively; neither spontaneous contractions nor response to manual compression are evident in these organs during celiotomy.<sup>1</sup> The differentiation of postoperative ileus from early postoperative mechanical bowel obstruction and from postoperative paralytic ileus is important, because they are caused by different pathophysiologic mechanisms.<sup>2</sup> In paralytic ileus, there is a prolonged inhibition of coordinated bowel activity that can take days or even weeks to resolve, depending on the etiology. Currently, there are no good pharmacologic agents to prevent or reverse the short-lived “physiologic” process of delayed gastric emptying or the “pathophysiologic” development of postoperative ileus.

### Early Postoperative (Mechanical) Bowel Obstruction

*Early postoperative bowel obstruction* is defined as bowel obstruction occurring within the first 6 postoperative weeks. This type of intestinal obstruction represents a distinct clinical entity with a unique pathophysiology and should be differentiated from both the classic mechanical bowel obstruction as well as from postoperative ileus. The formation of acute adhesions is the responsible cause in over 90% of early postoperative bowel obstructions necessitating surgical management. Other causes include internal herniation, fascial herniation especially after laparoscopic surgery, intra-abdominal abscess, intramural intestinal hematoma, and anastomotic edema or leak. Differential diagnosis may be difficult, and it is not always easy or possible to differentiate early postoperative mechanical obstruction from postoperative ileus. Nausea, vomiting, abdominal distention, and obstipation are themselves relatively common findings in the early postoperative period. Because the initial symptoms of early postoperative mechanical obstruction tend to be vague, patients are often considered to have “physiologic” postoperative ileus. Pain secondary to the recent incision and masked by the use of narcotic analgesics makes the physical examination often unreliable. Interpretation of imaging studies may

be difficult, because early postoperative bowel obstruction and ileus can present with similar findings on plain abdominal radiographs. Computed tomography (CT) and contrast studies can help differentiate patients who can be treated conservatively from those who may need operative intervention, especially those with either a focal site of obstruction or the presence of dilated proximal and decompressed distal small bowel; the latter defines a mechanical etiology.<sup>3</sup>

### EPIDEMIOLOGY

The etiologies and thereby the prevalence of bowel obstruction vary widely throughout the world depending on ethnicity, the age group considered, dietary habits, geographic location, and even time of the year among other factors. For instance, during Ramadan in Ibadan, the most common cause of small bowel obstruction is small bowel volvulus, believed secondary to the combination of a congenitally narrow base of the small bowel mesentery combined with a large volume of oral intake after sundown. Similarly, in the 18- to 30-year-old age group in Miami, FL, intestinal obstruction secondary to ingestion of drug-filled condoms is not an uncommon cause of intestinal obstruction.

There was a dramatic change in etiology and frequency during the 1900s. Incarcerated hernia used to be the most common cause of bowel obstruction during the first third of the 20th century combined with elective repair of inguinal hernias. The widespread performance of therapeutic intra-abdominal surgery in the second half of the 20th century led to an increase in the frequency of postoperative adhesive obstruction and a decrease in the relative frequency of obstruction secondary to hernias. In addition, early diagnosis and surgical treatment of most abdominal wall hernias resulted in a substantial decrease in intestinal obstruction secondary to incarcerated hernias, especially in industrialized countries where health care is readily available. In the underdeveloped world, however, bowel obstruction still manifests with a clinical picture resembling that found in the early 20th century in Western societies with incarcerated hernias leading the list in frequency. The wider application of minimal invasive surgical procedures with less adhesions may decrease the frequency of bowel obstruction secondary to postoperative adhesions,<sup>4</sup> but long-term follow-up is still short compared to the experience with open procedures.

Obstetric, gynecologic, and other pelvic surgical procedures represent important etiologies for the development of postoperative adhesions. It is not surprising that a slightly greater frequency of bowel obstruction is observed in women.

About 80–90% of bowel obstructions occur in the small intestine; the other 10–20% occur in the colon. Colorectal cancer is responsible for 60–70% of all large bowel obstructions, while diverticulitis and volvulus account for the majority of the remaining 30%. In contrast, small bowel obstruction in most advanced Western societies is caused most commonly by adhesions, abdominal wall hernias, or neoplasms.



Resources expended and costs incurred in the treatment of intestinal obstruction represent a substantive burden on the national health care system of any country. One study estimated that bowel obstruction accounted for over 1 million days of inpatient care and \$1.33 billion in health care expenditures in the United States in 1994. Indeed, it has been estimated that 1% of all hospitalizations, 3% of emergency surgical admissions to general hospitals, and 4% of major celiotomies (about 250,000) are undertaken because of bowel obstruction or procedures necessitating adhesiolysis.<sup>5</sup> Another study showed that between 12 and 17% of patients who have undergone a total colectomy are admitted for small bowel obstruction within 2 years of their index operation, while approximately 3% will require an operation to treat an established small bowel obstruction.

Bowel obstruction results in substantial overall mortality and morbidity. Depending on the clinical setting and the presence of related or unrelated comorbidities, mortality rates range from up to 3% for simple obstructions to as great as 30% when there is vascular compromise or perforation of the obstructed bowel. Further, bowel obstruction is frequently a recurrent problem, adding to the overall morbidity of an operation or even repetitive successful nonoperative management. Recurrence rates vary according to method of management (conservative or operative). Future intestinal obstruction will recur in about 12% of patients after a successful primary conservative treatment and in between 8 and 32% of patients after operative management for adhesive bowel obstruction. Another study showed that operatively treated patients had a decreased frequency of recurrence and a greater time interval to recurrence; however, they also had a greater hospital stay than patients treated conservatively. Also, there was no significant difference in incidence, type of treatment, or type of prior operative procedure among patients presenting with early or late small bowel obstruction. In this study, none of the analyzed variables were predictive of success of a particular treatment.<sup>6</sup>

## PATHOPHYSIOLOGY

Mechanical bowel obstruction results in numerous alterations of the normal intestinal physiology. The pathophysiology of bowel obstruction remains incompletely understood despite the many changes observed. Bowel distension, decreased absorption, intraluminal hypersecretion, and alterations in motility are found universally, but the mechanisms mediating these relatively dramatic pathophysiologic derangements are not clear. There also appears to be a considerable disruption of mechanisms of neural and hormonal control, the type and quantity of endogenous bacterial flora, and the innate immunity of the gut.

The older, classic literature addressing the pathophysiology of bowel obstruction considered a decrease in blood flow as the sentinel event leading to most of the observed pathophysiologic changes. More recent experimental work, however, suggests that many of the pathophysiologic changes

observed in bowel obstruction are related in part to an increase in blood flow in the early phase of bowel obstruction in association with an intense intramural inflammatory reaction. Indeed, there is strong evidence suggesting that this inflammatory reaction plays a key role in the pathophysiology of the intestinal response to obstruction. A recent study showed that mucosal production of reactive oxygen species may be one important mediator of changes observed in simple mechanical bowel obstruction.<sup>7</sup>

## Distension, Absorption, and Secretion

Bowel distension is a characteristic, fundamental, and constant physiologic derangement found in mechanical bowel obstruction, although its mechanism has not been fully elucidated. Accumulation of swallowed air is responsible for much of the small bowel distention in the early phases of obstruction. As would be expected, intraluminal gas consists of approximately 75% nitrogen in the obstructed bowel. Fermentation of sugars, production of carbon dioxide by interaction of gastric acid and bicarbonates from pancreatic and biliary secretions, and diffusion of oxygen and carbon dioxide from the blood are other sources of gas early in the obstruction. Dilation and inflammation of the bowel wall cause the accumulation of activated neutrophils and stimulation of resident macrophages within the muscular layer of the bowel wall, inhibiting or causing damage to secretory and motor processes by release of reactive proteolytic enzymes, cytokines, and other locally active substances. Local release of nitric oxide, a potent inhibitor of smooth muscle tone and contractility by the inflammatory response, aggravates intestinal dilation and inhibition of contractile activity. There is a correlation between the amount and activity of nitric oxide synthase, the enzyme responsible for nitric oxide synthesis, and the severity of intestinal dilation observed. Based on experimental data, there is also evidence that there is a close relationship between distention and the intramural production of reactive oxygen metabolites; in addition to disrupting gut motility, these metabolites also modulate permeability of the vasculature as well as the gut mucosa.

Secondary to a prominent decrease in net absorption, water and electrolytes accumulate within the lumen during the first 12 hours of small bowel obstruction. By 24 hours, intraluminal water and electrolytes accumulate more rapidly secondary to a further decrease in absorptive flux; this decrease in net absorptive flux occurs via stimulation of a concomitant increase in net intestinal secretion (secretory flux). These changes are caused apparently by increased permeability due to secondary mucosal injury resulting in intraluminal leakage of plasma, electrolytes, and extracellular fluid. Whether associated neural or systemic humoral/hormonal mechanisms aggravate this upregulation of unidirectional secretory flux also remains likely but poorly investigated or explained.

This net secretion of fluid into the lumen of the obstructed bowel is exacerbated further by the accumulation of intraluminal bacteria-derived toxins, bile acids, prostaglandins,

vasoactive intestinal polypeptide, and mucosa-derived oxygen-free radicals. With a more chronic obstruction, bacterial proliferation occurs in the lumen, further disrupting absorption, secretion, and mucosal integrity. The decrease in the absorptive capacity and increase in secretion lead to important fluid losses (enterosecretion) that can lead to dehydration if not appreciated and treated. Although the intestinal wall distal to the obstruction maintains a relatively normal function, the inability of the luminal content to reach the unobstructed small bowel and colonic absorptive surface is an important component of the overall dehydration.

## Intestinal Motility

In an attempt to propel intraluminal contents past the obstruction, intestinal contractile activity increases in the early phase of bowel obstruction, probably in large part related to the intestinal distention. Later in the course of the bowel obstruction, however, contractile activity decreases, probably secondary to a relative hypoxia of the intestinal wall and the exaggerated intramural inflammation; although the exact mechanisms have not been described adequately, this response may be similar to the changes found early after an abdominal operation, again related to inflammation of the intestinal wall.<sup>8,9</sup> Some investigators<sup>10</sup> have suggested that the alterations in intestinal motility are secondary to a disruption of the normal autonomic parasympathetic (vagal) and sympathetic splanchnic innervation, while others related these changes more to a local effect of inflammation of the intestinal wall.

The splanchnic innervation has been the focus of extensive research, and especially so in the pathogenesis of paralytic ileus. Chemical sympathectomy has been successful in ameliorating the ileus in several experimental models of ileus. Other pharmacologic approaches have focused on blocking the neural inhibitory mechanisms affecting enteric neuromuscular coordination via sympatholytics and cholinergic agonists.<sup>11,12</sup> Still other experimental approaches have been designed to prevent or inhibit the inflammatory response that accompanies the “physiologic” response to celiotomy or the abnormal inflammatory response accompanying generalized ileus.

## Circulatory Changes

Different mechanisms can lead to bowel wall ischemia. Extrinsic compression of the mesenteric arcades by adhesions, fibrosis, a mass, or a hernia defect, an axial twist of the mesentery, local chronic, serosal-based pressure on a segment of the bowel wall (eg, a fibrous band), or progressive distention in the presence of a closed-loop bowel obstruction can all cause vascular compromise or strangulation. Large bowel obstruction is especially susceptible to vascular compromise, because about 40% of people have a competent ileocecal valve, setting up a functional “closed-loop” in the presence of a distal obstruction, leading to intense, acute proximal

colonic distention; bacterial proliferation and generation of luminal gas further exacerbate the distention.

Progressive distention of the bowel lumen with a concomitant increase in intraluminal pressure results in increased transmural pressure on capillary blood flow within the bowel wall. Severe decreases in perfusion occur in simple, non-closed-loop obstruction, because the obstructed, distended bowel can decompress proximally. In contrast, the possibility of intestinal wall ischemia is a very real concern in a closed-loop small bowel obstruction and especially in large bowel obstruction when the ileocecal valve is competent, and the distended colon cannot decompress retrograde into the small bowel. The resultant increase in intraluminal pressure may compromise blood flow by exceeding venous pressure. This scenario occurs most commonly in the ascending colon where the luminal diameter and resulting wall tension are the greatest based on the law of Laplace. This difference actually makes large bowel obstruction more of a surgical emergency than small bowel obstruction. This type of bowel wall ischemia will lead to a further disruption of intestinal absorption with a relative increase in net secretion, an unregulated increase in mucosal permeability, and intramural production of reactive oxygen species by activated resident and recruited leukocytes; these reactive oxygen species cause peroxidation of the lipid components of the cellular membrane, release of cytokines and other inflammatory mediators, and systemic toxicity. With strangulation, there can also be blood loss into the infarcted bowel, which, together with the preexistent fluid loss, leads to more hemodynamic instability, further exacerbating the already compromised blood flow to the intestinal wall.

## Microbiology and Bacterial Translocation

The resident and transient flora of the upper small intestine consists mainly of gram-positive, facultative, anaerobic organisms in small concentrations, usually less than  $10^6$  colonies/mL. The bacterial count increases more distally to about  $10^8$  colonies/mL in the distal ileum; along with this increase in number of bacteria is a change of flora to primarily coliform and anaerobic organisms. In the presence of obstruction, however, a rapid proliferation of bacteria occurs proximal to the point of obstruction, consisting predominantly of fecal-type organisms. The proliferation of this fecal flora, proportional to the duration of obstruction, reaches a plateau of  $10^9$ – $10^{10}$  colonies/mL after 12–48 hours of an established obstruction. The bowel distal to the obstruction tends to maintain its usual bacterial flora until the onset of a generalized ileus, resulting only then in bacterial proliferation distal to the point of obstruction. Bacterial toxins have an important role in the mucosal response to bowel obstruction. Experiments in germ-free dogs with a mechanical bowel obstruction have shown that a net intraluminal accumulation of fluid and electrolytes does not tend to occur, and net absorption continues.

Experiments primarily in rodents have shown that bacterial translocation occurs secondary to impairment of the barrier function of the intestinal mucosa if bowel obstruction persists.

This disruption of the mucosal barrier becomes established early after the onset of bowel obstruction. The cellular response to obstruction is multifactorial. In the enterocyte, the endoplasmic reticulum dilates as early as 4 hours after onset of bowel obstruction. Mitochondrial edema, focal epithelial necrosis, intracellular swelling, and degenerative lesions in the nucleus of epithelial cells (apoptosis) have been demonstrated as early as 6–12 hours after the onset of obstruction in this experimental model.<sup>13</sup> The mucosal defense is compromised further by a decrease in perfusion of the intestinal wall. The loss of the mucosal integrity allows luminal bacteria to both translocate as well as to invade the submucosa and enter the systemic circulation via the portal venous and lymphatic systems. Several bacterial substances can be retrieved from peritoneal fluid and lymphatic channels even in the absence of perforation. In the rodent model, bacteria can be cultured from the spleen, liver, and mesenteric lymph nodes, indicating a marked increase in bacterial translocation. Concomitant with bacterial translocation, lymph fluid contains numerous bacterial proteins and lipoproteins which further disrupt normal gut function.

The demonstration of bacterial translocation in these elegant studies with rodent models led to the erroneous assumption of the existence of a similar bacterial translocation in humans. Reproducible documentation of true bacterial translocation in man is notably lacking, and existence of a true bacterial translocation seems unlikely. Several studies have unsuccessfully tried to document the presence of bacteria in intra-abdominal lymph nodes, spleen, liver, and even lymphatics. In contrast, more recent work has shown that lipopolysaccharide and other inflammatory vasoregulatory mediators, but not bacteria, can be recovered from the mesenteric lymphatics. The eventual drainage of these inflammatory substances into the systemic circulation may lead both to the systemic manifestations of sepsis and further disruption of the mucosal barrier function.

The change in the intraluminal bacteriology in simple intestinal obstruction is important clinically, because it increases markedly the risk of infective complications, especially if an intestinal resection is required or if an inadvertent enterotomy occurs with intraperitoneal spillage of “obstructed” enteric contents. In contrast, with irreversible strangulation obstruction, it is clear that a myriad of local and systemic alterations, such as systemic entry of bacterial products, activation of immunocompetent cells, release of cytokines, and increased formation of reactive oxygen intermediates, can promote the systemic inflammatory response syndrome and progress to multiple organ dysfunction with all its consequences.

## ETIOLOGY

### Adhesions

*Adhesions* may be defined as abnormal, inflammatory attachments of connective tissue between tissue surfaces. Adhesions can be so-called congenital or acquired (postinflammatory

and postoperative). Congenital or inflammatory adhesions are infrequent causes of bowel obstruction, except in selected circumstances, such as rotational disorders (malrotation) or a persistent urachus, among others. The leading cause of small bowel obstruction in Western societies is postoperative adhesions, which are responsible for 40–80% of bowel obstructions seen in most hospital surgical services. This wide variation in incidence of adhesive obstruction varies with different referral patterns, community settings, racial cultures, and countries.

Adhesion formation to some degree is nearly universal after celiotomy and starts as early as the first postoperative hours.<sup>14</sup> While the exact pathogenesis of adhesion formation remains still incompletely understood, experts in this field agree that adhesion formation is a surface event associated with some form of peritoneal injury. The inciting trauma triggers a local inflammatory response leading to activation of the complement and coagulation cascades along with exudation of fibrinogen-rich fluid; the full establishment of this fibrinous inflammatory response is present 5–7 days after the trauma of a celiotomy.<sup>15</sup> Recent findings have identified the presence of sensory nerve fibers in human peritoneal adhesions, suggesting that these structures may even be capable of conducting pain<sup>16</sup> or other neural responses.

Peritoneal healing (mesothelialization) appears to differ from the response in skin, where reepithelialization occurs from the periphery inward. In the peritoneum, operative or traumatic defects are reepithelialized by implantation of mesothelial cells in multiple areas of the defect. This mesothelialization takes place quite rapidly, and resurfacing is often complete by 2–5 days after the injury, depending on local conditions.<sup>17</sup>

Normal peritoneal healing, however, is a complex, interrelated, programmed inflammatory process. The initial response involves infiltration of the wound area with polymorphonuclear leukocytes and lymphocytes. During the ensuing 24–36 hours, circulating and local macrophages are recruited by various chemokines. By 48 hours, a fibrin scaffold overlying the defect has been established; covered by macrophages and a few mesothelial cells, these mesothelial cells then coalesce to fully mesothelialize the defect over the next 2–5 days. Fibroblasts and other mesenchymal cells populate the underlying fibrin scaffold and begin to lay down a basement membrane. By 8–10 days, a single layer of mesothelial cells resting on a continuous basement membrane has been established, and the underlying reactive matrix and inflammatory cells start to regress. This process describes the simple resurfacing of an uncomplicated peritoneal defect.

In contrast, in certain situations, adhesion formation can be considered a pathologic process in comparison to the previously described physiologic process of normal peritoneal healing. It appears that adhesions form in response to the initial fibrin gel matrix combined with the local microenvironment. This fibrin gel matrix consists of numerous types of cells, including the initial leukocytes, but also other humorally active cells such as platelets,



mast cells, and erythrocytes, in conjunction with surgical debris, nonviable tissue, foreign bodies, and possibly bacteria. The resultant spectrum of fibroinflammatory changes between physiologic mesothelial healing versus pathologic adhesion formation varies not only among individuals but is dependent also on many other conditions, such as inflammation, infection, devitalized tissue, and foreign bodies.

If the fibrin gel allows apposition of adjacent surfaces, a band or bridge may form (ie, an adhesion). This process of adhesion formation is a dynamic process, consisting predominantly of macrophages early on, but by 2–4 days, larger strands of fibrin begin to appear along with fibroblasts. By 5 days, distinct bundles of collagen are apparent, and the fibroblasts begin to form a syncytium within the matrix. These cells predominate thereafter, and eventually the fibrin matrix and cellular elements are replaced by a vascularized, granulation-type tissue containing macrophages, fibroblasts, giant cells, and a rich vascular supply. Eventually, the surface of the adhesions are covered by a mesothelial layer, but only after formation of the underlying fibrous scar leading to surface apposition and transperitoneal fibroinflammatory bands of varying severity and extent.

An important factor in the spectrum of adhesion formation that in part determines the risk of future adhesive bowel obstruction is the type of surgical procedure performed. The operations associated most frequently with adhesive bowel obstruction are those involving the structures in the inframesocolic compartment and especially in the pelvic region, such as colonic, rectal, and gynecologic procedures. Adhesive bowel obstruction may occur at any time postoperatively after a celiotomy, with reports ranging as early as within the first postoperative month to more than eight decades after the index operation. A study by Menzies and Ellis<sup>18</sup> found that about 20% of adhesive bowel obstructions occur within 30 days after the initial celiotomy, about 20% occur between 1 and 12 months postoperatively, another 20% tend to occur between 1 and 5 years postoperatively, and the remainder (~40%) occur after even 5 years. A Norwegian study of patients requiring an operation for adhesive bowel obstruction found that most episodes of recurrent bowel obstruction occurred within 5 years after the previous episode, but the risk of bowel obstruction persisted for more than 20 years after a prior episode, reaching an incidence as great as 29% at 25 years.<sup>19</sup> Therefore, a common predisposition to adhesive obstruction is the presence of a prior episode of adhesive obstruction. Numerous surgical attempts to decrease or prevent the development of postoperative adhesions have been reported and are discussed in the following text. The literature on pharmacologic prophylaxis against postoperative adhesion formation is extensive and riddled with numerous false claims of benefit. Suffice it to say that no reliable or truly effective pharmacologic agent has been developed to augment mesothelialization and prevent adhesion formation. Several proprietary barrier products of variable efficacy have been developed and are discussed in the following text.

## Hernia

Congenital, abdominal wall hernias (umbilical, epigastric, inguinal, femoral, Spigelian, obturator, sciatic, lumbar, and perineal), congenital internal hernias, or postoperative hernias (incisional, ostomy-related, or mesenteric defects after intestinal resection) with incarceration of the bowel within the hernia are the second most common cause of bowel obstruction in most series. Hernias as an etiology are more common in males than in females, primarily because of the predominance of inguinal hernias in men. In contrast, incarcerated femoral or obturator hernias are more common in women.

Approximately 5% of external hernias will require emergency operation if they are not repaired electively. These hernias are usually incisional hernias, umbilical hernias, and indirect inguinal or femoral hernias. Direct inguinal hernias incarcerate only rarely, and, because of this, the current thinking about the necessity to repair direct inguinal hernias has changed to a more conservative observational approach in the asymptomatic patient. The presence of acute incarceration should prompt emergent operative management, because 10–15% of incarcerated hernias contain necrotic bowel at exploration (Figs. 29-1 and 29-2); chronically incarcerated hernias can develop strangulation, but most chronically incarcerated hernias can be managed electively.

## Internal Hernia After Laparoscopic Gastric Bypass

Minimally invasive surgery has brought new etiologies of intestinal obstruction. The reported incidence of internal hernia after laparoscopic intestinal surgery and especially after Roux-en-Y gastric bypass (RYGB) is 0.2–3% and is much greater in incidence than with the open approach.<sup>20,21</sup> Factors contributing to the increased risk of internal hernia after a laparoscopic approach may be the relative lack of adhesion formation combined with increased small bowel mobility, marked weight loss with the associated decrease of mesenteric fat with enlargement of potential hernia openings, and failure to close appropriately all mesenteric defects. There are two or three mesenteric defects created during laparoscopic RYGB depending on retrocolic or antecolic technique<sup>22</sup> (Fig. 29-3). Petersen's defect or space is the best known site of herniation and can be created with either an antecolic or retrocolic position of the alimentary limb.<sup>23</sup> It is named after Petersen, who in 1900 described two cases of internal herniation posterior to a loop gastrojejunostomy.<sup>24</sup> Internal hernias are often difficult to diagnose; indeed, patients with internal hernias present often with nonspecific or intermittent symptoms (periumbilical pain, nausea, vomiting, anorexia, abdominal distention). Spontaneous reduction in the hernia can occur, and CT, upper GI contrast series, and plain abdominal films may be nondiagnostic.<sup>22</sup> Symptoms of intermittent bowel obstruction after laparoscopic

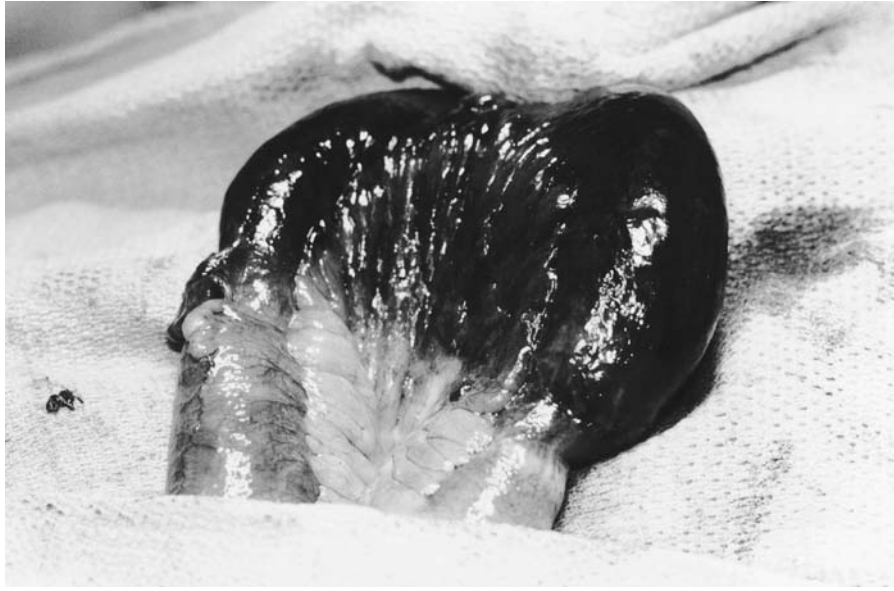

FIGURE 29-1 Gangrenous bowel from an irreversible, strangulated, incarcerated inguinal hernia.

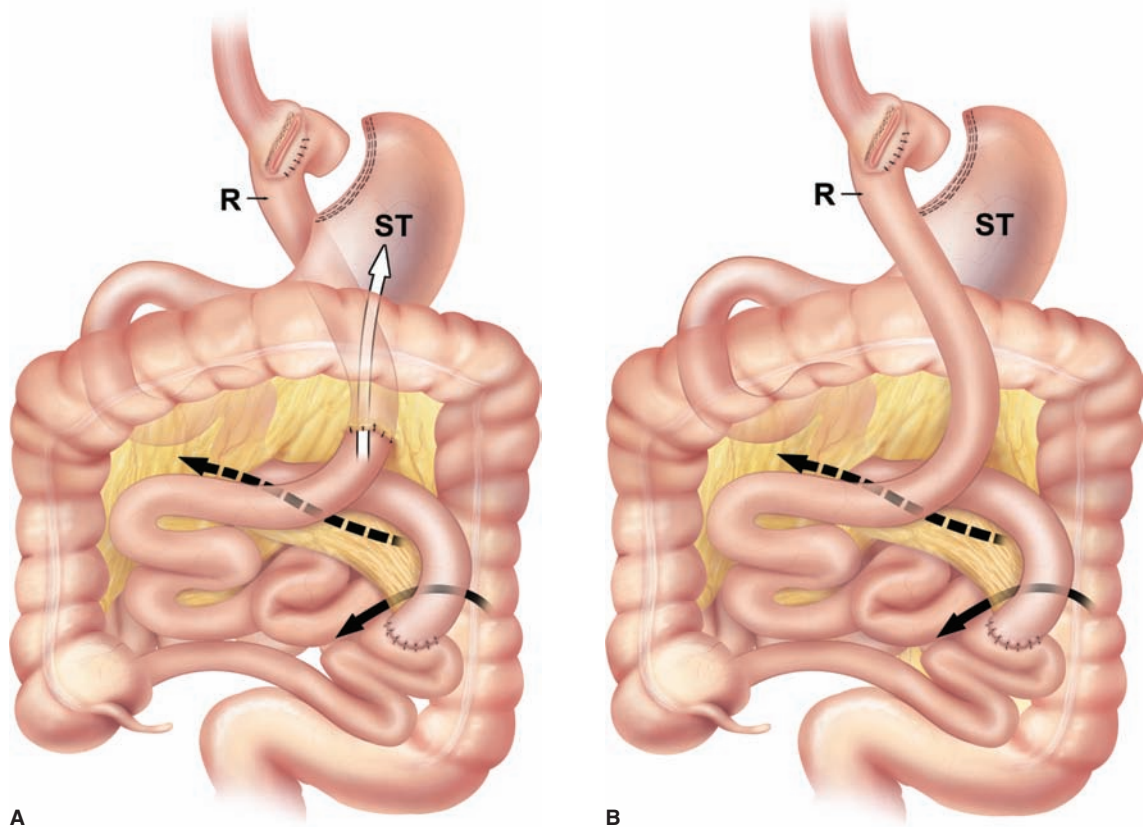


FIGURE 29-2 Umbilical hernia. Operative en bloc resection of hernia sac, umbilical skin, and irreversible strangulation obstruction.

gastric bypass should raise suspicion for occurrence of an internal hernia, especially after weight loss. The best measure to prevent these hernias is the meticulous closure of the created mesenteric defects, and suspicion of an internal hernia may itself be appropriate justification for operative exploration, especially via a diagnostic laparoscopy.

### Trocar Site Hernia

The reported incidence of trocar site herniation is 0.2–3%; the true long-term incidence, however, might even be greater.<sup>25</sup> Trocar site hernias are observed rarely with 5-mm trocars but more frequently with the use of 10-mm, 12-mm, or bigger trocars and especially with the “cutting” trocars. Closure of the fascial defect and the use of noncutting, radial expanding trocars have been recommended to decrease the risk for formation of trocar site hernias.<sup>25–27</sup> Trocar site hernias can lead to small bowel obstruction early or late after a minimal access, intra-abdominal procedure. It is also important to think of a Richter-type hernia if the patient has a history of a laparoscopic procedure and is complaining about abdominal pain in the area of the trocar site, even in the absence of (intermittent) symptoms of bowel obstruction. Richter’s hernia occurs when the antimesenteric wall of the intestine protrudes through a hernia defect but does not cause luminal obstruction. Richter’s hernias are dangerous, because reduction in the necrotic bowel wall during hernia repair can result in missed perforation and peritonitis. A Richter hernia can result in strangulation and necrosis in the absence of intestinal obstruction. Although Richter’s hernias are rare, with the widespread use of laparoscopy they have become a well-known trocar site complication.



**FIGURE 29-3** Internal hernia defects after Roux-en-Y gastric bypass (RYGB). GP, proximal gastric pouch; R, Roux limb; ST, stomach. Mesenteric defect at enteroenterostomy (*solid arrows*), transverse mesocolic defect (*open arrow*), and Peterson's hernia posterior to Roux limb mesentery (*dashed arrows*).

## Malignant Bowel Obstruction

Primary intra-abdominal neoplasms are a common cause of both large and small bowel obstruction. Colorectal, gastric, small bowel, and ovarian neoplasms are among the most frequent causes of malignant bowel obstruction, either from the primary lesion (colon and small bowel neoplasms) or from peritoneal metastases (ovarian, colonic, and gastric neoplasms). In many of these patients, bowel obstruction is associated with a high rate of recurrence and morbidity and may often be a terminal event.

Metastatic cancer can also cause bowel obstruction. The most common form of obstructing metastatic lesion is peritoneal carcinomatosis, but localized hematogenous metastases to the wall of the small intestine from melanoma and carcinoma of the breast, kidney, or lung can also cause intraperitoneal metastases that can obstruct the bowel (Fig. 29-4).

## Granulomatous Diseases and Crohn's Disease

Crohn's disease is a chronic, transmural, inflammatory disease of the GI tract that may affect any part of the alimentary tract

from the mouth to the anus. Despite often intense involvement of the bowel wall, Crohn's disease is responsible for about fewer than 5% of cases of small bowel obstruction. When true mechanical obstruction is present, the cause is usually secondary to the inflammatory process or to stricture formation. Other granulomatous diseases causing obstruction, such as tuberculosis and actinomycosis, are much less common in Western countries, but in the developing world where acquired immune deficiency syndrome (AIDS) and human immunodeficiency virus (HIV) infection are endemic, intra-abdominal tuberculosis must be entertained in the diagnosis of intestinal obstruction.

## Intussusception

Intussusception is a relatively frequent cause of bowel obstruction in infancy (in the first 2 years of life) but accounts for only 2% of bowel obstruction in the adult population.<sup>28</sup> The median age of presentation in adults with intussusception is the sixth to seventh decade. The etiology of intussusception differs greatly between adult and pediatric patients. In the vast majority of adult intussusceptions, there is a demonstrable inflammatory lesion or



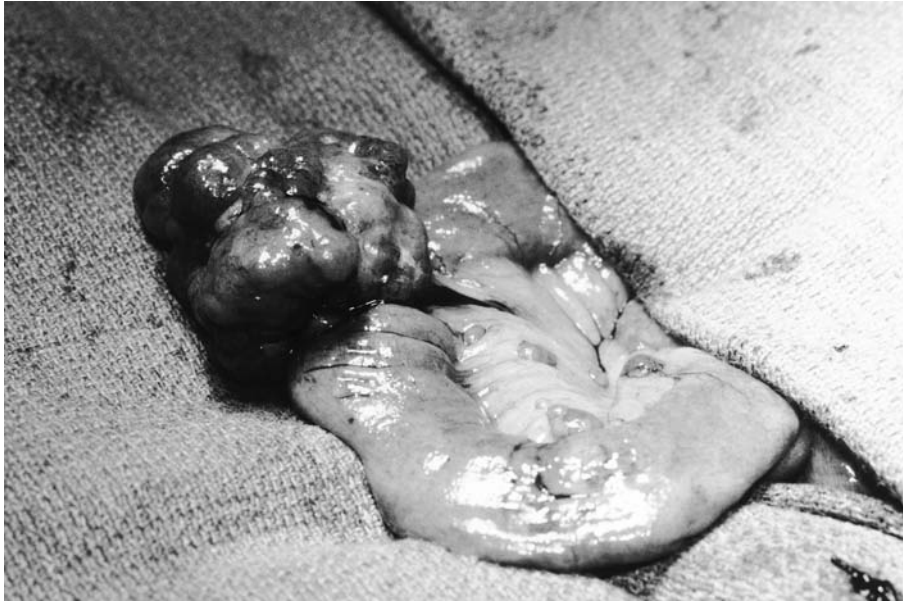

FIGURE 29-4 Renal cell carcinoma metastatic to small intestine.

a neoplasm that serves as the lead point of the intussusceptions. Neoplasms causing intussusception in adults are malignant in almost 50% of patients. Although rare in the Western Hemisphere, intussusception is one of the most common causes of bowel obstruction in central Africa for reasons as yet not fully explained.

## Volvulus

Volvulus represents an axial twist of the bowel and its mesentery. This entity is an infrequent cause of small or large bowel obstruction in the Western Hemisphere (Figs. 29-5 and 29-6). Volvulus is encountered more frequently in the geriatric

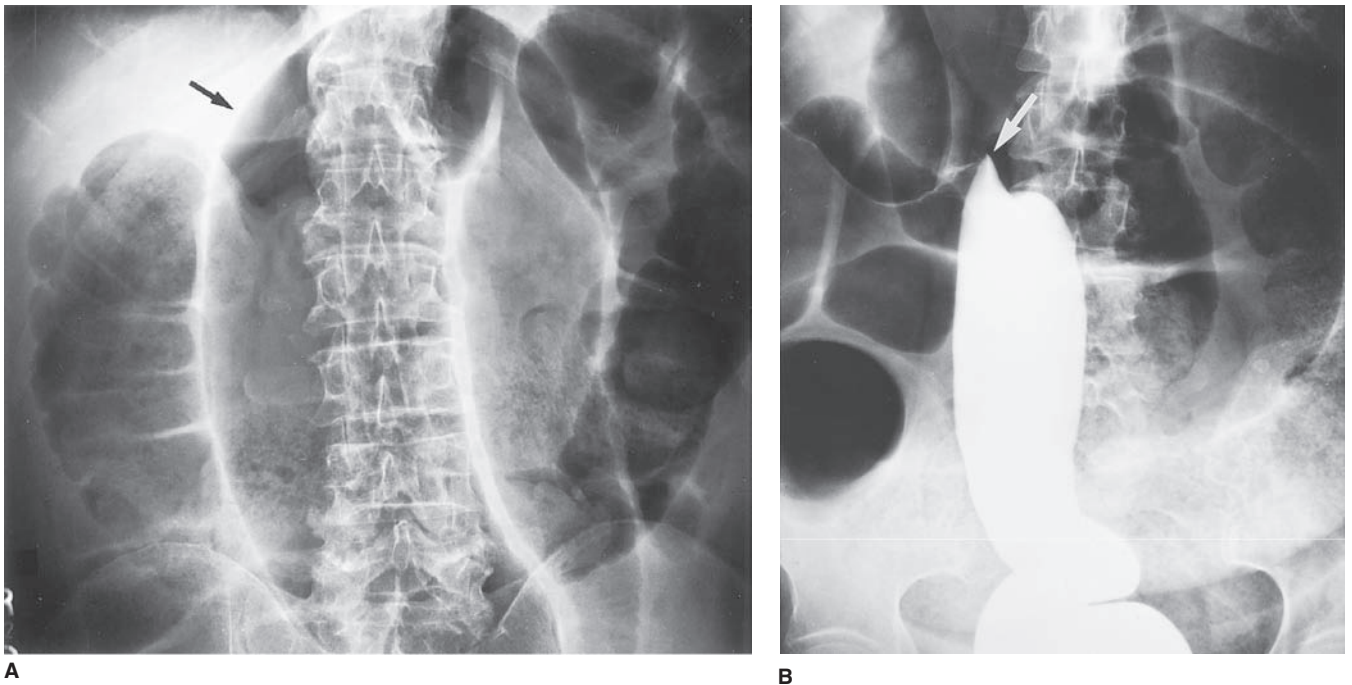
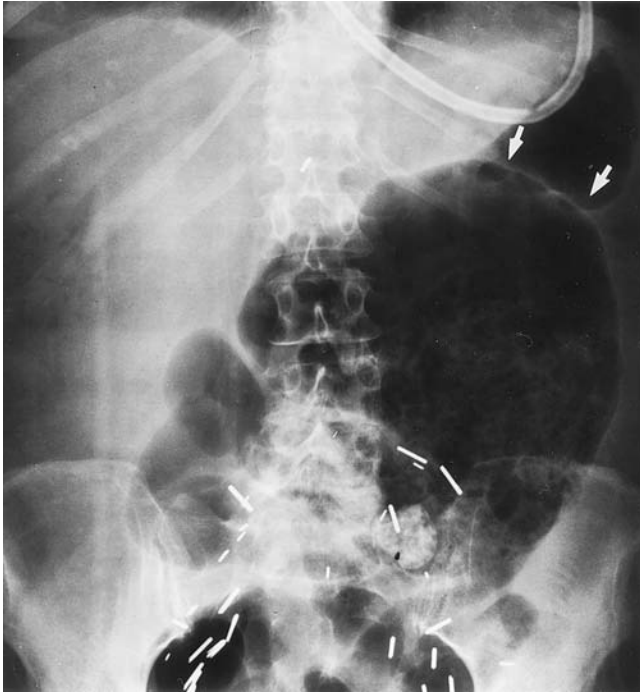

FIGURE 29-5 Sigmoid volvulus. **A.** Supine abdominal radiograph showing the dilated, volvulated segment of redundant sigmoid colon pointing toward the right upper quadrant; *arrows* show the space between the sigmoid and hepatic and splenic flexures. **B.** Contrast enema in sigmoid volvulus showing cutoff at distal site of volvulated sigmoid having a “bird-beak” appearance.



**FIGURE 29-6** Cecal volvulus. Dilated volvulated cecum pointing to left upper quadrant. Arrows indicate the cecal tip.

population, in individuals with a long history of constipation, or in institutionalized, neurologically impaired, or psychiatric patients. Colonic volvulus comprises about 1–4% of all bowel obstructions and about 10–15% of all large bowel obstructions. The volvulated segment has to be relatively mobile to allow the degree of freedom necessary to permit an axial twist of the mesentery. Either the affected segment has an especially long, narrow mesentery (eg, malrotation or cecal volvulus) and/or a lack of bowel wall fixation (floppy cecum syndrome) or one aspect of the affected segment is fixed, around which the contiguous segment can twist (eg, a deep fibrous band fixing the other end of the segment).

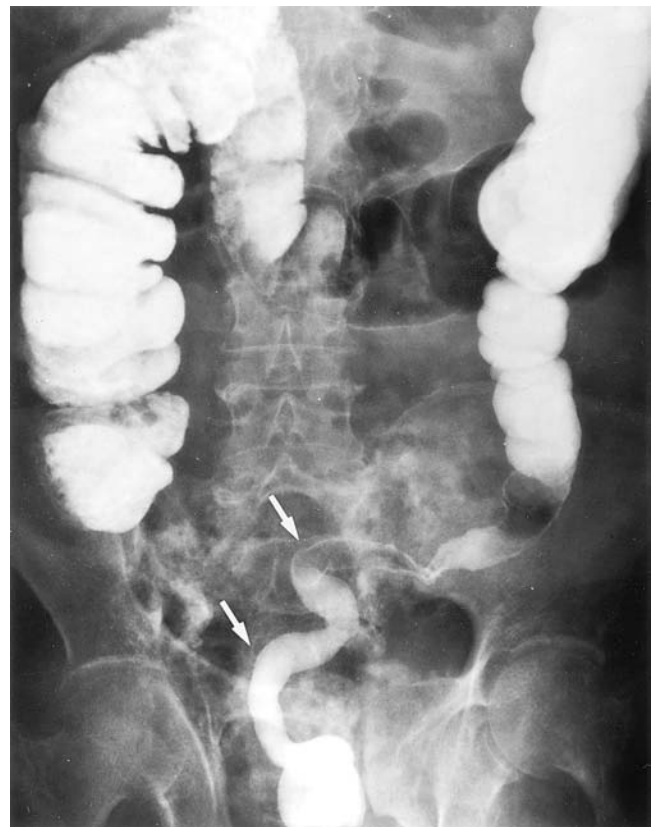Other variables also appear to play a role in the etiology of volvulus. In the Bolivian and Peruvian Andes at more than 10,000 ft above sea level, sigmoid volvulus represents 79% of all bowel obstructions. The high altitude plays a role somehow in the high incidence in this population, but the mechanism is not well understood.

Overall, sigmoid volvulus accounts for 75% of all patients with volvulus. In contrast, cecal volvulus is responsible for the majority of the remaining 25% of bowel volvulus incidences in the United States and is the most common cause of large bowel obstruction in pregnancy. The “cecal bascule” is a somewhat unique, though less common, form of cecal volvulus that occurs when the true anatomic cecum (ie, the part of the ascending colon that lies caudal to the entrance of the ileocecal valve) flops anteriorly over onto the ascending colon, obstructing the lumen. This form of cecal volvulus may be intermittent and recurrent and is often difficult to diagnose.

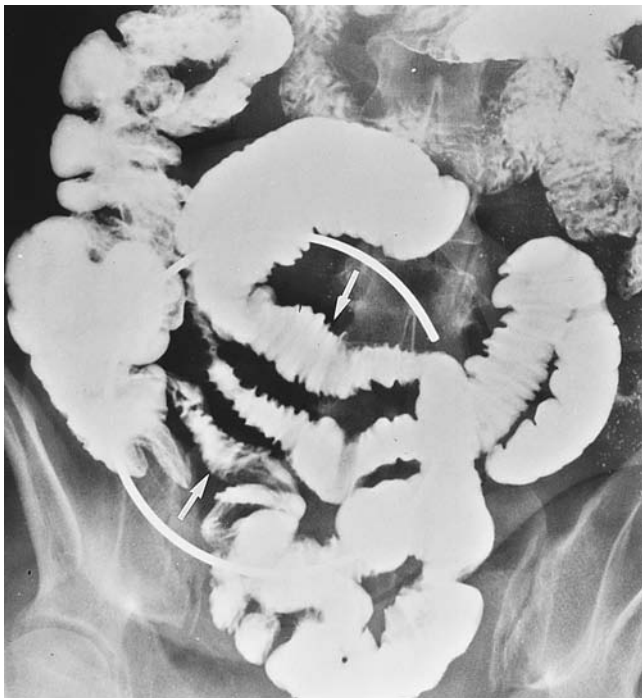Primary volvulus of the small intestine is extremely rare in the United States but is quite prevalent in central Africa, India, and the Middle East. Speculation about etiology has been related to abrupt dietary changes that occur during the religious holiday when the people celebrating Ramadan fast during the day and then consume a large meal after dark. Some investigators, however, maintain that this racial group has an exceedingly long, floppy small bowel mesentery that permits generous mobility of the small bowel.

## Other Causes

Other causes of bowel obstruction include the following: congenital lesions such as Meckel’s diverticula, duplication cysts, rotational disorders of the intestine, annular pancreas, and omphalomesenteric duct remnant; infections such as appendicitis, Meckel’s or cecal diverticulitis, the latter more common in the Asian population, and complicated diverticulitis; inflammatory conditions like starch peritonitis, intra-abdominal abscess, and localized perforations; intraluminal obstruction from stricture, gallstones, phytobezoar, swallowed foreign body, and parasitic infestation; posttraumatic lesions like mesenteric or intramural hematomas; and miscellaneous extraluminal conditions such as radiation enteropathy (Figs. 29-7 and 29-8), endometriosis, and superior mesenteric artery syndrome.



**FIGURE 29-7** Radiation changes in distal colon/rectum (arrows).



**FIGURE 29-8** Radiation enteropathy. Note the narrowed segments of ileum with much thickened bowel walls (separation between adjacent loops).

## DIAGNOSIS

The diagnosis of bowel obstruction is suspected clinically based on the presence of classic signs and symptoms and then confirmed by some form of imaging modality, such as abdominal radiography or CT. The etiology can often be pinpointed by careful history taking complemented with imaging studies.

## History and Physical Examination

The classic clinical picture of a patient suffering from bowel obstruction includes intermittent crampy abdominal pain, distention, acute obstipation, nausea, and vomiting. Abdominal pain and then distention usually precede the appearance of nausea and vomiting by several hours. The more proximal the obstruction, the earlier and more prominent are the symptoms of nausea and vomiting, while distention is usually less. In contrast, the more distal the obstruction, the more prominent the abdominal distention. Vomiting is relatively uncommon in colonic obstruction until its later stages. The abrupt onset of symptoms makes an acute obstructive cause more likely and may herald the presence of a closed-loop obstruction. The location and character of pain may be helpful in differentiating mechanical bowel obstruction from ileus. Mechanical bowel obstruction usually presents as severe, truly crampy pain localized to the midabdomen, while ileus tends to have a more diffuse and mild pain, often without the waves of colic. Both, however, are associated with nausea and vomiting.

Characteristically, the pain associated with mechanical small bowel obstruction is usually described as visceral, poorly localized, and crampy with recurrent paroxysms occurring in short (10–30 seconds) crescendo-decrescendo episodes. In contrast, in mechanical large bowel obstruction, the episodes are usually spaced farther apart in time and tend to last longer (1 or 2 minutes rather than seconds) compared to small bowel obstruction. Classically, the presence of constant or a localized pain has been regarded as a sign of strangulation. Several studies, however, have shown that these findings are neither specific nor sensitive for the detection of strangulation.

Obtaining a complete medical history is of utmost importance. The past medical history may be key in making both the diagnosis and establishing the cause of bowel obstruction. It is especially important to inquire about previous episodes of bowel obstruction, recent and distant abdominal operations, current medications, a history of chronic constipation, recent changes in the caliber of stools, a history of cancer, its stage at presentation and related treatments (operative therapy, chemotherapy, or radiation therapy), and a history of Crohn's disease.

A thorough physical examination is mandatory and should include assessment of vital signs and hydration status as part of the initial resuscitation. Thereafter, abdominal inspection, auscultation, palpation, a search for potential hernia defects of all external aspects of the abdominal wall, and a rectal examination (palpation and test for occult blood). It is important to look closely for previous surgical incisions, including inguinal incisions for previous “extraperitoneal” herniorrhaphies (recurrent hernias are common). Differential diagnosis should also include consideration given to the possibility of internal hernias or those “external” hernias not necessarily associated with an obvious “bulge,” such as obturator, femoral, or intramural Spigelian hernias.

Tachycardia, hypotension, and oliguria are signs of advanced dehydration that require aggressive resuscitation while continuing with further evaluation. Fever may be associated with an infectious cause or with strangulation. Auscultation can determine the presence, frequency, and quality of the “obstructed” bowel sounds. Mechanical bowel obstruction presents with an increase in the frequency of bowel sounds, but more specifically the high-pitched “rushes” and “groans” followed by the metallic tinkling sounds of “water dripping into a large hollow container,” indicative of dilated bowel with an air-fluid interface. In contrast, functional bowel obstruction lacks the rushes and groans but continues to have the metallic tinkling indicative of dilated bowel. Sometimes functional obstruction (ileus) may present with an absence of bowel sounds. In both mechanical and functional bowel obstruction, a succussion splash is usually present (dilated stomach or markedly dilated small bowel filled with an air-fluid interface); the presence of a succussion splash is not normal in a patient who has not eaten or ingested liquids in the previous 1–2 hours and should be regarded as an important, abnormal, and often underappreciated sign of bowel obstruction (unless the patient just recently vomited his or her gastric contents).



Abdominal palpation should reveal the presence of peritoneal signs, such as rebound, localized tenderness, and involuntary guarding that herald vascular compromise or perforation. The presence of these findings cannot be ignored. Abdominal masses should be sought and noted. A meticulous search for inguinal and femoral hernias is essential, because they can be overlooked easily. The rectal examination should rule out fecal impaction and should be evaluated for occult or macroscopic blood in the stool.

## Laboratory

There is no laboratory test sensitive and specific enough to diagnose mesenteric ischemia reliably. A spectrum of laboratory tests may, however, be helpful in determining the condition of the patient and should guide the resuscitation. A complete blood cell count and differential, electrolyte panel, blood urea nitrogen, creatinine, and urinalysis should be obtained to evaluate fluid and electrolyte imbalance and to rule out sepsis. Arterial blood pH, serum lactate concentrations, and amylase and lactic dehydrogenase activity may be useful (but not overly sensitive) tests in the evaluation of bowel obstruction, especially when trying to exclude the presence of strangulation, obstruction, or underlying bowel necrosis. An increase in serum lactate concentrations should raise the suspicion of intestinal ischemia; however, it is often a late finding.<sup>29,30</sup> D-dimer was proposed as an early marker of acute mesenteric ischemia, but it appears to be insensitive.<sup>31,32</sup> Intestinal fatty acid-binding protein (I-FABP) is a highly sensitive marker for extensive mesenteric infarction; however, it does not appear sensitive enough to detect more limited intestinal ischemia in strangulated bowel.<sup>33,34</sup> Others have suggested that serum concentrations of phosphate and isoforms of creatine phosphokinase (isoform B),<sup>35,36</sup> plasma level of ischemia-modified albumin,<sup>37</sup> and gut luminal tyrosine concentrations<sup>38</sup> may identify the presence of intestinal cell necrosis. Yet, the specificity and especially the sensitivity are not accurate enough to base a management decision solely on these values. Recently, the presence of a spectrum of findings on CT, including mesenteric edema, free peritoneal fluid, intestinal wall thickness, and the absence of fecalization of the small bowel content appear to offer additional signs of underlying strangulation obstruction.<sup>39</sup>

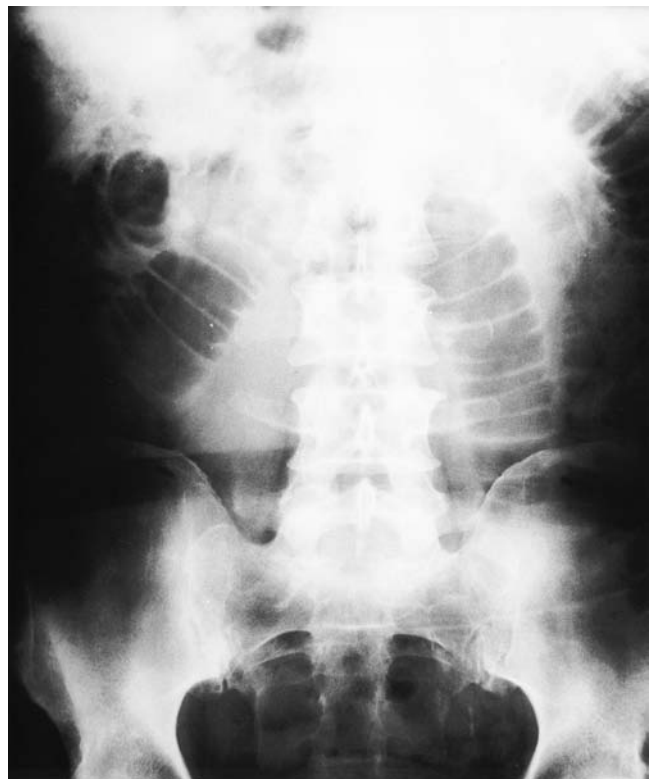## Radiologic Findings

The management of small bowel obstruction has changed little in recent decades and remains reliant heavily on excellent clinical acumen and appropriate imaging. The clinician is faced with answering the critical questions, “Is this complete obstruction and is the intestine ischemic?” Recently, the literature is replete with clinical studies examining the prognostic value of various forms of imaging in terms of predicting the need for operative management or the presence of intestinal ischemia. Most of these series have investigated the role of CT, and we will highlight these findings.

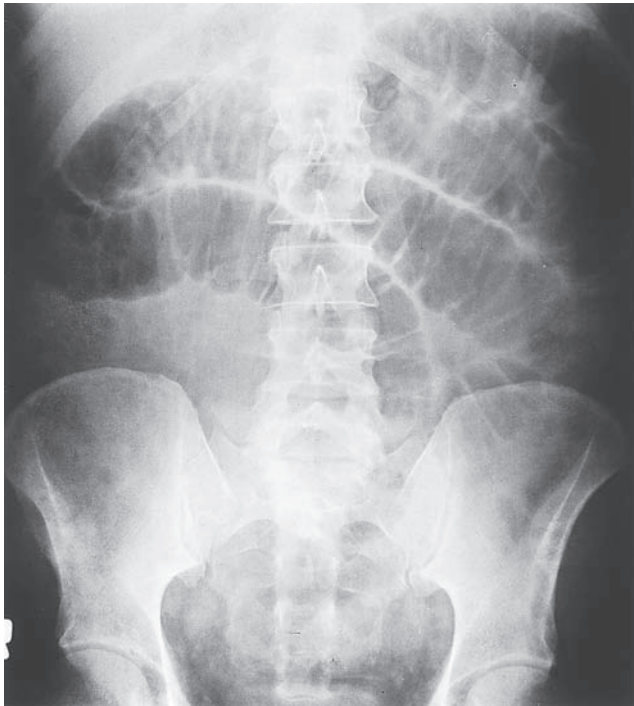
## FLAT AND UPRIGHT ABDOMINAL RADIOGRAPHS

Plain radiographs, including a chest x-ray and flat and upright films of the abdomen, remain a valuable initial imaging modality in patients with clinical small bowel obstruction. An initial chest x-ray may reveal extra-abdominal processes such as pneumonia that could be associated with an ileus rather than bowel obstruction. In addition, the presence of free air from a perforated viscus may indicate a diagnosis other than small bowel obstruction or a serious complication of small bowel obstruction requiring emergent treatment.

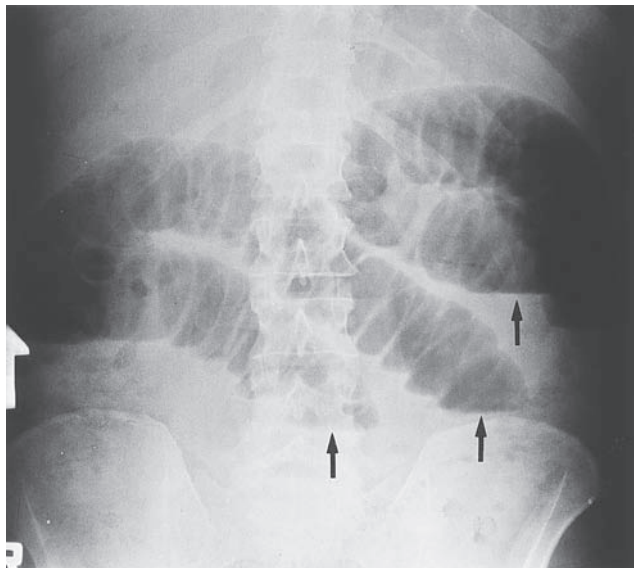
Flat and upright films of the abdomen in patients with a small bowel obstruction characteristically have multiple air-fluid levels in dilated loops of bowel and a paucity of gas in the distal (decompressed) small bowel and colon (Fig. 29-9). The location of the obstruction in the proximal or distal small intestine, however, influences greatly the findings on the plain abdominal films. A very proximal small bowel obstruction may be associated with films that demonstrate few, if any, air-fluid levels with a relatively small gastric air-fluid level resulting from a fluid-filled stomach. Conversely, a distal small bowel obstruction likely will have multiple air-fluid levels with dilated loops of small bowel stacked on one another (Figs. 29-10 and 29-11). Similarly, the pattern of bowel gas may assist in determining whether the obstruction represents a small or large bowel process. On a plain abdominal film, the small bowel lies centrally, and intestinal



**FIGURE 29-9** Supine abdominal radiograph showing an incomplete small intestinal obstruction. Note the dilated loops of small bowel.



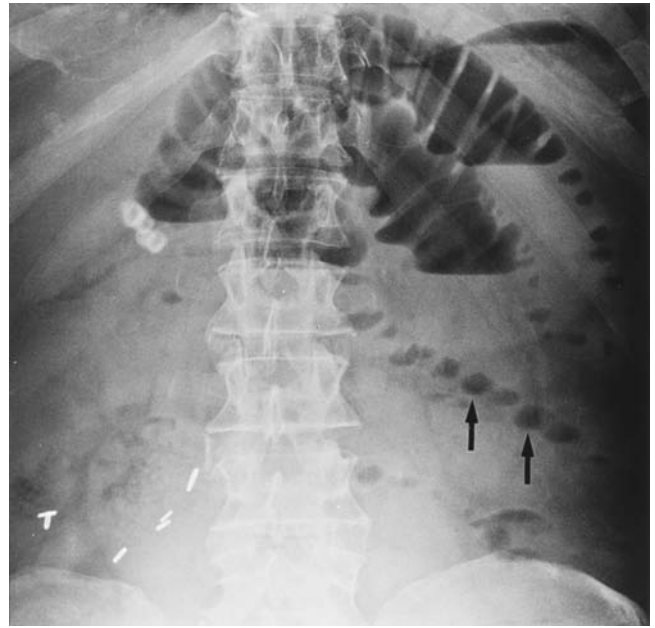
A



B

**FIGURE 29-10** Complete small bowel obstruction. **A.** Supine abdominal radiograph shows multiple loops of dilated small bowel with colonic gas. **B.** Upright radiograph shows multiple air-fluid levels in the small intestine (*arrows*).

markings from the valvulae conniventes or plicae circulares encompass the entire diameter of the bowel, whereas the large bowel lies at the periphery of the abdomen and haustral markings only partially cross the bowel. Furthermore, the appearance of the bowel gas may also give a clue as to the duration of the obstruction. So-called “fecalization” of



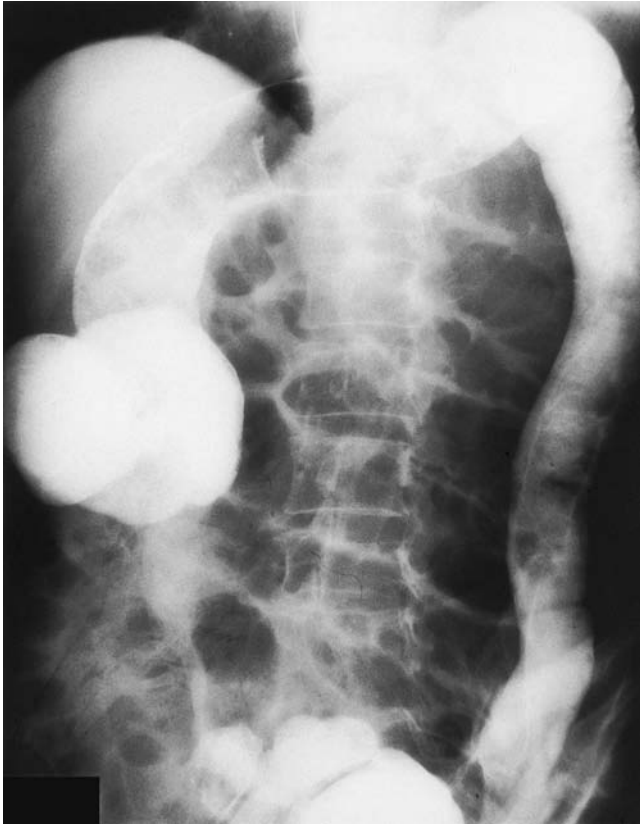
**FIGURE 29-11** Small bowel obstruction with fluid-filled loops of small bowel in left lower quadrant (*arrows*).

the small bowel content, whereby the luminal content shows less of an air-fluid level and more of an appearance of semi-solid content with pockets of gas, suggests a more chronic obstruction and may be helpful in supporting the need for operative intervention, not because of worry of strangulation but rather a chronic, established, nonresolving process.

Uncommonly, a plain film of the abdomen will contain a pathognomic sign of intestinal obstruction from gallstone ileus (a misnomer because it is a true mechanical obstruction) as is the case with pneumobilia in a patient with gallstones and no history of biliary instrumentation. Importantly, plain films of the abdomen are notoriously poor indicators of bowel involved with vascular compromise unless the devastating signs of portal venous gas and intestinal pneumatosis are evident. Closed-loop bowel obstructions are also difficult to be diagnosed on plain x-rays, because the involved bowel with a proximal and distal occlusion may be fluid filled and lack any gas. Thus, alternative imaging procedures should be contemplated in patients with any suspicion of compromised bowel.

## CONTRAST STUDIES

Though contrast studies using either dilute barium or hyperosmotic, water-soluble contrast of the small and large bowel were an integral component of the diagnostic evaluation previously, enthusiasm for these studies has waned substantially. The radiologic literature and various guidelines developed by the radiologic community support strongly the use of contrast-enhanced CT as the diagnostic imaging modality of choice.<sup>40</sup> Nonetheless, in specific clinical situations, such as in a patient with an obstructing sigmoid or rectal tumor, a radiograph with



**FIGURE 29-12** Barium enema showing complete large bowel obstruction in the ascending colon.

rectally administered contrast may provide diagnostic information that is timely, economical, and clinically important (Fig. 29-12). CT offers information concerning the extraintestinal anatomy as well as showing obstruction. On occasion, a small bowel follow-through series may be helpful in distinguishing between mucosal inflammation versus extraluminal compromise from adhesions as the etiology of bowel obstruction in a patient with Crohn's disease. This diagnostic information may alter the therapeutic approach.

Furthermore, contrast studies using water-soluble, hyperosmotic contrast have been used as a therapeutic modality in patients with intestinal obstruction. The mechanism(s) by which administration of this contrast agent may result in relief of an obstruction is not completely understood. A number of studies have examined the therapeutic benefit of contrast studies. In 1994, a study by Assalia et al found that patients receiving gastrografin had a much lesser time to their first bowel movement (6.2 vs 23.3 hours), a lesser rate of operative treatment (10 vs 21%), and lesser mean hospital stay (2.2 vs 4.4 days) when compared to those who did not receive the water-soluble contrast.<sup>41</sup> In 2002, Choi and coworkers<sup>42</sup> reported a prospective, randomized study that showed that the therapeutic use of Gastrografin not only had a role in determining the need for eventual operative management of patients with a presumed small bowel obstruction, but also appeared to decrease the need for an operation by 74%. Similarly,

Chen et al<sup>43</sup> used the findings of gastric emptying of the orally administered contrast and whether the contrast reached the colon within 8 hours to determine the eventual need for operative treatment. Recently, Abbas et al performed a meta-analysis that showed that Gastrografin did not influence the need for operative therapy but did decrease the duration of hospital stay of patients treated nonoperatively.<sup>44</sup> Alternatively, Feigin and associates could not confirm any benefit of the use of water-soluble contrast in patients with small bowel obstruction.<sup>45</sup> Thus, this topic remains unresolved.

When contrast agents are utilized, the risks of each agent must be considered carefully. The primary side effects of barium include inspissation in the obstructed large bowel (not the small bowel because the obstructed small bowel is filled with liquid). Also, barium results in severe intraperitoneal infection/barium peritonitis when extravasated in the face of small intestinal perforation. Gastrografin, if aspirated, can cause a severe pneumonitis; moreover, this contrast agent becomes diluted rapidly with an established small bowel obstruction and thereby yields little information in a distal small bowel obstruction. Finally, most surgeons agree that contrast studies are contraindicated in patients with a clear diagnosis of complete bowel obstruction and when strangulation or perforation is suspected.

## COMPUTED TOMOGRAPHY

In many centers, computed tomography (CT) has become the primary diagnostic imaging modality for the diagnosis of suspected intestinal obstruction, and, in fact, in some institutions, it has replaced plain radiographs as the initial imaging test. This increased use of CT reflects the preference of clinicians for the additional diagnostic information garnered from this examination. CT does not only provide information about the presence or absence of a luminal obstruction, but it can also define both the site of obstruction and the existence of extraluminal processes, associated inflammation, fluid collections, masses, abdominal wall or internal hernias, and free intraperitoneal fluid.

Several studies have reported a diagnostic accuracy of greater than 90% with the use of CT in intestinal obstruction.<sup>46-48</sup> In addition, some studies suggest that a CT scoring system may predict accurately the need for operative intervention. Jones et al found that a scoring system with the criteria of a dilated small bowel, identification of a transition point, ascites, complete obstruction, partial obstruction, evidence of a closed-loop obstruction, and/or free air predicted the need for operative treatment in 75% of patients.<sup>49</sup> Of particular note, O'Daly and colleagues found the association of peritoneal fluid with small bowel obstruction to be a strong predictor for the need for operative treatment.<sup>50</sup> Moreover, surgeons are interested keenly in the capability of CT to predict ischemia or strangulation of the bowel; however, the evidence for this is contradictory. In a systematic review, Mallo et al found that the sensitivity, specificity, positive predictive value, and negative predictive value of CT for predicting ischemia were 83, 92, 79, and



93%, respectively.<sup>51</sup> Conversely, Sheedy et al noted that with CT, sensitivity was 15% and specificity 94% for identifying bowel ischemia prospectively in patients with small bowel obstruction.<sup>52</sup> A recent study by Zielinski et al suggested that CT findings of free peritoneal fluid, thickened bowel, and mesenteric edema, combined with vomiting, were predictive of the need for eventual operative management, but, though relatively sensitive for ischemia, CT was not very specific.<sup>39</sup> In the face of conflicting evidence regarding the ability of CT to predict intestinal ischemia, the importance of obtaining and/or following selected clinical parameters (eg, peritonitis, worsening acidosis) of intestinal ischemia cannot be underemphasized. It is important to remember that CT is better at identifying rather than excluding the presence of ischemia.

Although the increased use of CT in patients with bowel obstruction has provided greater diagnostic information, caution must be exercised in the use of this modality in distinguishing mechanical small bowel obstruction versus ileus. In one study, up to 20% of patients with a CT diagnosis of ileus required operative intervention eventually.<sup>53</sup> Overall, the current preference for the use of CT is associated with an increased likelihood of operative intervention and decreased mortality; however, whether these associations are causal or coincidental remains unknown.<sup>54</sup>

## ULTRASONOGRAPHY

Ultrasonography (US) is used infrequently in the diagnosis of intestinal obstruction. Even though the reported specificity is 82%, sensitivity is 95%, and overall accuracy is 81%, this modality is highly operator-dependent and the results are unlikely to be reproduced consistently in many institutions. US has been reported to be useful for the early recognition of strangulation obstruction in several Japanese and European studies<sup>55,56</sup>; however, in the absence of an experienced ultrasonographer, the reliability of US remains questionable. Furthermore, US is difficult to perform in obese patients, and extensive bowel gas may obscure the pattern of intestinal obstruction.

## MAGNETIC RESONANCE ENTEROGRAPHY

Magnetic resonance enterography (MRE) has not been utilized as frequently as CT, because performance of this examination is more time consuming and requires substantial expertise in interpretation. Additionally, in general practice MRE does not have a greater diagnostic accuracy than CT. In contrast, in centers that use MRE frequently, diagnostic accuracy exceeding 90% is achievable.<sup>57,58</sup> MRE may have an advantage of distinguishing benign from malignant bowel strictures in patients with suspected malignant bowel obstruction.<sup>59</sup>

## VIDEO CAPSULE ENDOSCOPY

Video capsule endoscopy (VCE) may be a valuable diagnostic tool in patients with subacute or chronic intestinal obstruction where other imaging techniques have not revealed an etiology. VCE is particularly helpful in patients with obstruction related

to a stricture caused by inflammation or malignancy.<sup>60</sup> Overall, VCE may provide a diagnosis in nearly 40% of previously undiagnosed patients.<sup>61</sup> A major concern with the use of VCE, however, is retention or impaction of the capsule either at a stricture or in any area of severe kinking related to adhesions in a patient who otherwise may have resolution of the obstruction without an operation; the incidence of this circumstance appears infrequent, but impaction may require celiotomy.

## Detection of Ischemia

Identification of strangulation obstruction caused by ischemia of the intestine is a critical diagnosis, because the mortality associated with strangulated bowel obstruction is 9–40% compared to less than 5% in nonstrangulated intestinal obstruction.<sup>62</sup> Unfortunately, clinical and imaging parameters claimed to permit early detection and operative intervention remain unreliable and, in fact, do not lead to early diagnosis. Jancelewicz et al found that decreased bowel wall enhancement on CT, leukocytosis, and peritoneal signs were the only independent predictors of strangulation obstruction on a multiple logistic regression analysis.<sup>62</sup> Historically, acidosis, increased serum amylase activity, and increased serum lactate concentrations were also claimed to be indicators of strangulation. While abnormalities of these parameters may prove to be sensitive markers of strangulation, they generally neither lack specificity nor offer useful positive or negative predictive value. Abdominal US and pulsed-Doppler US have been reported to be useful in identifying patients with strangulation. Ogata and associates reported that an akinetic, dilated loop of bowel observed on real-time US has a high sensitivity (90%) and specificity (93%) for the recognition of strangulation; the positive predictive value was 73%. The presence of free peritoneal fluid seen on US was also sensitive for strangulation.<sup>63</sup> Further studies of the usefulness of US are needed.

## MANAGEMENT

### Small Bowel Obstruction

The initial management of patients with small bowel obstruction should focus on aggressive fluid resuscitation and nasogastric decompression of the stomach to prevent further accumulation of intestinal fluid and air; in addition, nasogastric decompression decreases the potential for aspiration and relieves vomiting. These therapies should be instituted in all patients, whether they are treated operatively or undergo a trial of nonoperative management. Blood should be analyzed for serum electrolyte concentrations, typed and screened for potential transfusion, and, when necessary, arterial blood gases should be analyzed as well.

The most important initial step in management is vigorous crystalloid fluid resuscitation. Patients with small bowel obstruction often present with profound volume losses and

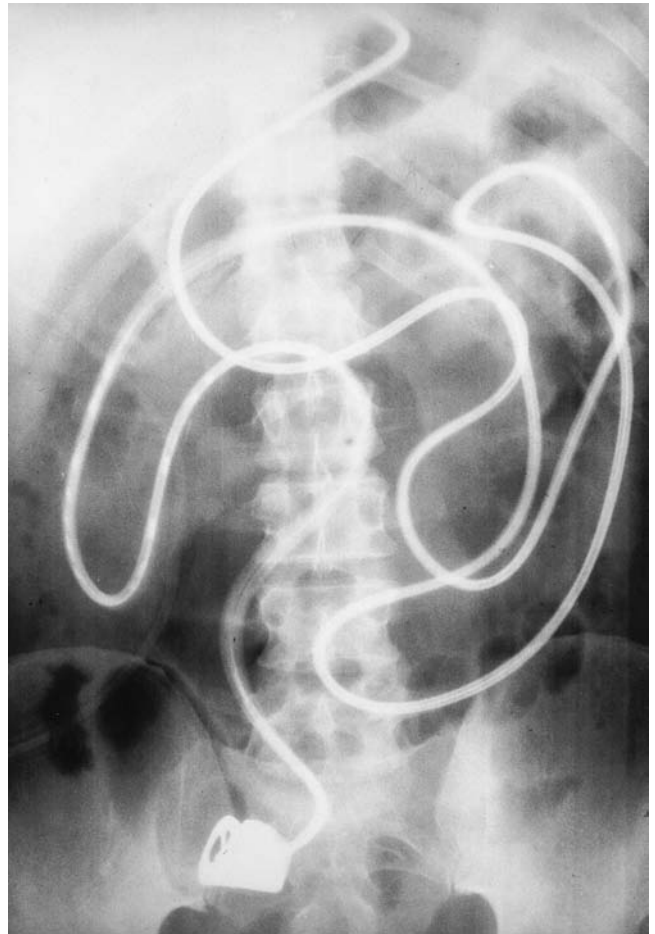
may require large amounts of isotonic crystalloid solutions, such as normal saline (0.9% NaCl) or lactated Ringer's solution with additional potassium when necessary. Resuscitation should be guided by urine output, provided the patient is hemodynamically stable and has normal renal function. Patients who are hemodynamically unstable or have impaired cardiac, pulmonary, or renal function may require monitoring of central venous or pulmonary arterial pressure to better evaluate their volume status. Colloid solutions, such as 5% albumin or hetastarch, have little or no role in the resuscitation of patients with a small bowel obstruction. Steps should also be taken to correct metabolic or electrolyte imbalances, which may be severe. Specifically, in patients who have experienced prolonged vomiting, potassium and chloride should be measured to diagnose hypokalemic, hypochloremic alkalosis and replaced appropriately. Though potassium replacement is a critical component of therapy, replenishment of this electrolyte should begin only after renal function has been established by good urine output. Volume resuscitation, electrolyte replacement, and establishment of adequate urine output are critical before operative therapy is undertaken. Broad-spectrum antibiotics should be given to patients within an hour of the incision to prophylaxis against surgical site infection, but, otherwise, antibiotics have no defined utility in the later postoperative period or in those patients initially managed nonoperatively.

Most surgeons believe that nasogastric decompression is important to prevent further intestinal distention from swallowed air and to limit aboral transit of gastric contents. In addition, nasogastric decompression also helps to prevent aspiration during vomiting and on induction of general anesthesia. Symptomatically, gastric decompression helps relieve abdominal distension and can improve ventilation in patients with respiratory compromise.

Historically, long intestinal tubes placed distal to the pylorus were used to relieve small intestinal distention under the assumption that intestinal decompression may be therapeutic if related to adhesions, because the decompressed bowel may detort and thereby relieve the mechanical obstruction (Fig. 29-13). Success rates of up to 90% have been reported in some series of patients treated with a long nasointestinal tube.<sup>64</sup> In contrast, however, most prospective and retrospective studies have failed to demonstrate the superiority of nasointestinal versus nasogastric intubation,<sup>64,65</sup> making the added expense of fluoroscopic or endoscopic placement of a nasointestinal tube unwarranted. Use of these long intestinal tubes has fallen out of favor, and they are of historic interest in the preoperative treatment of small bowel obstruction.

## Nonoperative Management

Nonoperative management of intestinal obstruction should be considered only in patients with uncomplicated intestinal obstruction in the absence of peritonitis, a progressive leukocytosis, or impaired bowel wall perfusion on imaging.



**FIGURE 29-13** Abdominal radiograph showing distal passage of a long nasointestinal decompression tube into the small bowel distal to the ligament of Treitz.

When indicated, this approach is reported to be successful in 62–85% of patients.<sup>43,66–69</sup> The rate of success is influenced likely by patient selection, type of bowel obstruction (complete versus partial), etiology (eg, adhesions, hernia, or neoplasm), and the surgeon's threshold for conversion to operative management. Patients successfully managed nonoperatively require lesser hospital stays<sup>66,67</sup> and avoid the morbidity or convalescence necessitated by an operation. Few studies have compared the long-term outcomes of patients with a small bowel obstruction treated nonoperatively versus operatively. One such study with over 4 years of follow-up reported by Landercasper and colleagues<sup>70</sup> found a recurrence rate of 29% in patients managed operatively versus a recurrence rate of 53% for patients managed nonoperatively. Even though the recurrence rates may be greater with nonoperative management, the authors point out that about half of the patients managed nonoperatively never developed a recurrent small bowel obstruction.

A recent study by Rocha et al<sup>71</sup> used the radiologist definition of “high-grade” obstruction and reported that in these patients, comparing those treated conservatively versus those

treated by operation, the conservatively treated patients had a significantly greater readmission rate at 5 years (24 vs 9%) than those treated operatively. Use of this radiologic finding may potentially extend the “indication” when criteria are met for high grade but not complete obstruction.

Absolute contraindications to nonoperative management include suspected ischemia, large bowel obstruction, closed-loop obstruction, acutely incarcerated or strangulated hernia, and perforation. In an attempt to define which patients with an uncomplicated small bowel obstruction can be successfully treated nonoperatively, Chen and colleagues<sup>43</sup> used an orally administered, water-soluble contrast agent (Urografin) to study 116 patients with small bowel obstruction. The presence of contrast material within the colonic lumen within 8 hours of oral administration had an accuracy of 93% for predicting which patients would benefit from nonoperative therapy. In their study, only 19% of patients with a small bowel transit time of more than 8 hours had resolution of their obstruction with nonoperative treatment. One of the criteria for conversion to operative treatment was the failure of contrast to reach the colon within 8 hours. Therefore, the 81% failure rate in patients in whom contrast never reached the colon within 8 hours after administration may be artificially high based on study design.

A relative contraindication to nonoperative management is complete small bowel obstruction, that is, dilated small intestine with no air in the bowel distally. In a prospective study by Fleshner and associates,<sup>67</sup> all patients with an uncomplicated small bowel obstruction underwent an initial trial of nonoperative management. They were able to manage 45% of patients successfully with a complete obstruction (by their definition), while 66% of patients with a partial obstruction were successfully managed nonoperatively, all with no mortality. These investigators, however, did not describe the incidence of intestinal ischemia at operation based on the presence or absence of complete versus partial obstruction. Another study by Fevang and colleagues<sup>66</sup> reported a 42% success rate in managing patients with a complete small bowel obstruction nonoperatively. When they compared complete and partial obstructions managed nonoperatively, there was a greater rate of bowel strangulation (10 vs 4%) and need for resection (14 vs 8%) in the group with complete obstruction at the time of operation for treatment failure. This group noted a mortality of 6% in patients with a complete obstruction initially managed nonoperatively versus 0% mortality for patients with a partial obstruction initially managed nonoperatively. Other groups have also noted a greater rate of ischemic bowel coupled with a lesser success rate in those patients with a complete obstruction managed nonoperatively.<sup>65,72</sup> These studies and the unreliability of clinical acumen to recognize strangulation obstruction accurately have led many surgeons to favor early operation for all patients with a complete small bowel obstruction,<sup>69</sup> leading to the often-quoted phrase “The sun should never rise or set on a (complete) small bowel obstruction.” If nonoperative management is attempted in a patient with complete obstruction, the decision should be made with the understanding that

there is a definite risk of overlooking an underlying strangulation obstruction,<sup>72</sup> and thus there should be a low threshold for operative intervention in patients with complete obstruction.

When patients with a small bowel obstruction are initially managed nonoperatively, vigilant attention must be paid to volume resuscitation, electrolyte homeostasis, and nasogastric decompression. Patients managed nonoperatively require the same aggressive resuscitation and realistic replacement of daily losses with an appropriate crystalloid solution and electrolyte replacement as patients who are managed operatively. Fluid replacement should take into consideration the volume and electrolyte loss in the output of the nasogastric tube, urinary output, and insensible losses. Electrolytes should be monitored frequently and corrected as necessary. Delayed correction of potassium and magnesium concentrations may lead to delayed return of bowel function and misdiagnosis of obstruction versus ileus.

Adequate proximal decompression is important to allow the bowel an opportunity to become unobstructed. This concept is accomplished by maintaining a functioning nasogastric tube. If the patient becomes progressively more distended or develops vomiting, tube placement should be evaluated and tube function confirmed by bedside evaluation. Standard nasogastric tubes should be inserted, such that the second of four marks is evident at the tip of the nares. The first mark is 40 cm from the tip of the tube, that is, the normal distance from the nares to the esophagogastric junction. Thus, if all four marks are outside the nares, the tube most likely is not in the stomach. Likewise, if no marks are visible, the tube is coiled within the stomach or is in the duodenum. On occasion, an abdominal radiograph is necessary to confirm placement. If the tube is noted on radiograph to be out of position, it should be repositioned and imaged again for proper placement. On evaluation, the tube should be connected to the suction apparatus, sumping properly (if the tube has a sump port), and should be checked for patency by flushing and aspirating water through the suction lumen. Oral intake should be minimized in the presence of a nasogastric tube, and, when allowed for patient comfort, the volume of ingested fluid should be recorded carefully to allow quantitation of gastric aspiration. In addition, the tube should never be “clamped” for prolonged periods of time, because by traversing the esophagogastric junction, the tube will lead to an incompetent lower esophagogastric sphincter and potential aspiration. Connection of the tube to a drainage bag for a brief trial is an appropriate alternative to clamping and may be used as a test to determine patient readiness for nasogastric tube removal.

## When to Convert to Operative Management

Prompt operative intervention is mandatory in patients who develop signs and symptoms suggestive of a strangulation obstruction. These parameters include fever, tachycardia,



leukocytosis, localized tenderness, continuous abdominal pain, and peritonitis. The presence of any three of these signs has an 82% predictive value for strangulation obstruction.<sup>72</sup> Similarly, the presence of any four of the above signs has a near 100% predictive value for strangulation obstruction. Obviously, patients who develop free air, signs of a closed-loop obstruction on abdominal radiograph, or gross peritonitis require emergent operative exploration. If CT demonstrates evidence of ischemia, such as pneumatosis intestinalis, bowel wall thickening, portal venous gas, generalized ascites, or nonenhancement of the bowel wall, operative intervention should be considered strongly.<sup>69</sup>

The timing of conversion to operative management in a patient with a small bowel obstruction who is not improving with nonoperative management is more controversial. Some surgeons advocate operative intervention in any patient who fails to show improvement within 48 hours of initiating therapy.<sup>65,68</sup> Others advocate a more liberal use of nonoperative therapy, citing a mean time to successful resolution of up to 4.6 days.<sup>67</sup> The authors believe that nonoperative management can be continued greater than 48 hours with the understanding that delaying inevitable operative treatment will result in a greater overall hospital stay and increased costs and may place the patient at increased risk for perioperative morbidity. It is important for the surgeon to remember that nonoperative management always carries a calculated risk of overlooking an underlying strangulation obstruction.<sup>72</sup>

## Operative Management

Once the decision has been made to pursue operative management, steps should be taken to prevent peri- and postoperative complications. Preoperative preparation includes assessing the medical fitness of the patient and, as time allows, taking steps to optimize the patient's medical status. Special consideration should be given to ensure that the patient has been resuscitated adequately, appropriate antibiotics have been given, and any electrolyte abnormalities have been addressed. Consideration should be given to the administration of beta-blockers to patients with cardiovascular comorbidities and especially to those who were on beta-blockers prior to admission.<sup>73</sup> A nasogastric tube should already be in place to decrease the risk of aspiration during the induction of anesthesia; nevertheless, a "crash," rapid-sequence induction will still be necessary to protect the airway during intubation, despite the presence of a nasogastric tube.

Several decisions must be made with regard to operative planning to provide the safest approach that will afford the best outcome for each individual patient. The choice of operative approach and incision is important to allow the surgeon adequate exposure and visibility. A laparoscopic approach should at least be considered in some patients.<sup>74</sup> When an obstruction develops in the early postoperative period, the original incision should be reopened provided extensive adhesions were not present originally. Safe entrance into the peritoneal cavity may

be best achieved by approaching this from the extremes of the previous incision rather than going directly through the mid-portion of the incision. In patients without a history of prior abdominal operation or those who are remote from their original operation, a midline celiotomy affords the best exposure to all four quadrants of the abdomen. For example, patients with upper oblique, transverse, or subcostal type incisions may have pelvic adhesions that are difficult to address from the upper abdomen, especially through a high transverse incision.

Once within the abdominal cavity, the first step is to identify the site and cause of obstruction. If the point of obstruction is not obvious, decompressed bowel distal to the obstruction can be identified and followed proximally to the point of obstruction. Care should be taken when handling the obstructed bowel at or near the point of obstruction when acutely obstructed, especially if it is fixed at an apparent site of obstruction or if it is ischemic. This region is at high risk for strangulation and infarction, making it more likely to rupture with spillage of bacteria-laden enteric contents into the abdomen. The dilated bowel proximal to the offending obstruction is often thin-walled and at increased risk for perforation if the obstruction is acute. After the offending obstruction has been corrected, a thorough exploration of all four quadrants should always be undertaken to ensure that all intestinal injuries are repaired, nonviable segments are resected, and a second site of obstruction or fixation is not overlooked; this concept is especially true for volvulated segments of small bowel where two points of fixation are often present. Sometimes obstructing bands traversing a sizeable part of the peritoneum can affect more than one loop of bowel. When a small bowel resection is necessary, intestinal continuity of the small bowel can be accomplished generally with a primary anastomosis unless there is generalized peritonitis and the edges of the remnant bowel are of questionable viability. When an intestinal anastomosis is performed, the discrepancy in bowel diameter and wall thickness between the obstructed proximal bowel and decompressed distal bowel are important factors in choosing anastomotic techniques. The surgeon may consider a side-to-side or end-to-side anastomosis in situations where massive dilation of the proximal bowel makes an end-to-end anastomosis difficult technically. In addition, a stapled anastomosis may be less safe in cases where a large discrepancy in bowel wall thickness exists or when there is bowel wall edema, because uniform approximation of the tissue for a given staple height may not be possible.

Abdominal closure may be difficult to achieve when the small bowel is massively dilated. In these cases, intraoperative intestinal decompression will facilitate closure. Techniques described for intraoperative decompression include manual retrograde decompression into the stomach (with careful handling of the obstructed bowel), intraoperative passage of a long nasointestinal tube, and, rarely, performance of a controlled enterotomy with passage of a decompressing tube; the latter technique is strongly discouraged except under very select circumstances, such as tremendous intestinal distention preventing abdominal closure or distention threatening bowel

viability. Manual retrograde decompression of luminal contents around the ligament of Treitz, through the pylorus, and into the stomach allows for aspiration through the nasogastric tube by the anesthetist.<sup>75</sup> This maneuver is the safest and quickest technique, because it allows closure of the abdominal wall while avoiding an enterotomy and excessive manipulation of the bowel. When decompressing the bowel, care must be taken to handle the inflamed and distended bowel gently, because experimental studies have demonstrated an increased rate of bacteremia after extensive manipulation of obstructed bowel.<sup>76</sup> In addition, the anesthesia team should be alerted to the maneuver to be certain that their nasogastric tube is functioning well. Although intraoperative decompression has not been shown to decrease the rate of postoperative complications or the speed of return of bowel function, it certainly does make the closure easier, faster, and safer.

Nonviable bowel needs to be identified and resected. Resection should be undertaken with caution, especially in patients with a limited length of bowel from a previous resection or those with large sections of ischemia. Adjuncts for determining bowel viability include the use of Doppler US and intravenous fluorescein. These tests are relatively subjective, should be used with caution, and are only adjuncts to sound clinical judgment. In patients who would otherwise be left with less than two-thirds of their original bowel length after resection of all bowel of questionable ischemia, consideration may be given to resecting all the grossly necrotic or obviously nonviable bowel, but preserving bowel of questionable viability and performing an end ostomy or a second-look procedure 12–24 hours later, particularly if the viability of the ends to be anastomosed is in question.

### BYPASS VERSUS RESECTION

In patients with an incurable malignant small bowel obstruction, if the offending obstruction is unable to be released or it is deemed unsafe to attempt to dissect out the point of obstruction, intestinal bypass can be performed. Bypass relieves the obstruction while reestablishing intestinal continuity and preventing a closed-loop obstruction; however, the advisability of a bypass procedure should be considered. For instance, in the presence of carcinomatosis, a bypass may prove fastest and safest, because patient survival will be short. In contrast, patients with certain chronic inflammatory diseases will remain at risk for ongoing problems (eg, Crohn's disease or tuberculosis) related to the inflammation in any "bypassed" segment and therefore such patients may be served better by resection than simple bypass.

The surgeon should at least consider an initial laparoscopic, minimal access approach in patients with uncomplicated small bowel obstruction. Laparoscopy is known to cause fewer adhesions than open laparotomy<sup>77</sup> and in that regard may be superior to laparotomy for the treatment of adhesive small bowel obstruction. Several studies have shown laparoscopy to be a safe and effective means of access for the operative treatment of small bowel obstruction.<sup>74,78–80</sup> When successful, a laparoscopic approach decreases both the duration of hospital

stay<sup>74,78,80</sup> and the complication rate.<sup>78,80</sup> Patients successfully treated laparoscopically appear to have more rapid return of bowel function.<sup>78,80</sup> These reports showing a large benefit to laparoscopic treatment for small bowel obstruction, however, need to be interpreted carefully. Many series compare patients treated laparoscopically to those who failed initial laparoscopic treatment. Those patients unable to be treated laparoscopically likely had more extensive adhesions or complicated pathology possibly requiring resection. Operative intervention in these patients would be more involved and complex whether done open or laparoscopically. One would expect these patients to have greater hospital stays, greater complication rates, and slower return of bowel function independent of the method of abdominal access. In addition, the skill and confidence level of the surgeon should weigh in the decision to approach the obstruction laparoscopically. First, if the surgeon lacks skill in using moderately advanced laparoscopic techniques, an open operation may be a better choice. Similarly, if the patient is known to have a frozen abdomen or has either a severely distended, tense abdomen with markedly distended bowel or multiple dense adhesions at the time of insertion of the laparoscope, conversion to an open procedure is wise. Initial access for creating the pneumoperitoneum in a patient with a small bowel obstruction is achieved best by a fully open approach under total visual control, but limited data support this concept.

### RECURRENT SMALL BOWEL OBSTRUCTION

Although the results of individual studies vary, between 4 and 34% of patients will experience recurrent small bowel obstruction regardless of management modality.<sup>5,66,68–70,81,82</sup> This wide range of recurrence rates likely results from variations both in the duration and quality of follow-up between studies as well as the etiology of the original bowel obstruction. Recurrent obstruction is more common in patients with multiple adhesions, matted adhesions, previous admissions for small bowel obstruction, and previous pelvic, colonic, and rectal surgery.<sup>5,70</sup>

In the past, numerous attempts have been made by surgeons to control the formation of adhesions in an effort to prevent future mechanical obstruction. A simple technique to prevent adherence of the bowel to the undersurface of the fascial incision is to interpose the omentum between the bowel and the incision. Theoretically, when adhesions from the posterior surface of the anterior abdominal wall form after omental interposition, they will involve the omentum and not the underlying bowel. Other more intricate techniques, such as the Noble plication and the Childs-Phillips transmesenteric placcation, have been described in the more distant past. These procedures involve the suturing adjacent loops of small bowel into an orderly pattern in an attempt to plicate the bowel permanently in a position that will not allow mechanical obstruction.<sup>82</sup> Although initial reports were encouraging, the Noble and Childs-Phillips procedures have multiple complications and are of historic interest only. The problems associated with plication procedures have included

prolonged operative times and high rates of enterocutaneous and enteroenteric fistula, abdominal abscess, and wound infection; moreover, the rate of recurrent obstruction is as great as 19%, questioning seriously their efficacy. Attempts to “plicate” the bowel with a long intestinal tube, so-called intraluminal plication, are also of questionable efficacy.

In some patients, it will become evident during the course of the operation that complete or adequate adhesiolysis is not possible or may risk vascular injury to a substantial segment of bowel because of the acute inflammatory nature or tenacity of the adhesions. This situation is especially common when celiotomy is deemed necessary or performed too soon after a previous intra-abdominal procedure (see the following section on early postoperative small bowel obstruction). This situation is especially common when the previous operation involved an extensive adhesiolysis. In such situations, it may be important to control any bowel injuries present, end any further dissection, and conclude the operation to prevent further bowel injury and its potential sequelae. This approach has been used by the senior author five times in 25 years of practice. This “conservative” approach may allow the acute inflammatory process to resolve or regress (often 3–6 months); should the obstruction not resolve by 6 months, the plan should be to reoperate at a time when the adhesions have matured, allowing a more controllable and much safer adhesiolysis. In some situations, the mature decision might be to provide proximal diversion with a proximal enterostomy if the obstruction has no chance for resolution (eg, due to malignancy or radiation) or if a more distal bowel repair is tenuous, or to place a tube gastrostomy for diversion and patient comfort. Pursuing a futile attempt to complete the adhesiolysis puts the patient at risk for serious bowel injury or devascularization injury necessitating resection of otherwise normal bowel with the risk of enterocutaneous fistulation or subsequent short bowel syndrome.

## ADHESION PREVENTION

Over the last 100 years, multiple approaches have been employed in an attempt to prevent the formation of unwanted postoperative adhesions. These attempts include, among others, the use of cow cecum, shark peritoneum, sea snake venom, and fish bladder, as well as multiple fluids, mechanical barriers, and gels.<sup>81</sup> The concept of separating injured surfaces mechanically to prevent adhesions is a very attractive one. The formation of fibrin bridges (and thus adhesions) may be preventable by separating injured surfaces in the postoperative interval during the critical period of healing and mesothelialization by application of an absorbable “biofilm.” Estimates of the minimum amount of time necessary for an impermeable or semipermeable barrier to prevent adhesion formation appear to be about 36 hours. Some authors have placed a Silastic sheet between two injured peritoneal surfaces; when left in place for 36 hours, no adhesions formed between these surfaces thereafter.<sup>17</sup> Others have postulated that separating the surfaces at risk for the first 5–7 days until full mesothelialization occurs would seem to

be most effective; however, the barrier should not incite its own inflammatory response and should not decrease fibrinolytic activity or suppress access to oxygen. The ideal product, therefore, should be bioabsorbable (preferably via a process such as hydrolysis), last only about 5–7 days, be easy to apply, be interposed between all injured surfaces, and not itself incite an inflammatory reaction.

The most effective method to date has been the application of a sheet of bioresorbable, hyaluronate membrane; this approach has been shown to decrease the formation of adhesions at the site of application.<sup>81,83</sup> In addition, two recent systematic reviews have demonstrated that use of this product, indeed, decreases adhesion formation at the site of application.<sup>84,85</sup> These reviews, however, both support the observation that use of a hyaluronate membrane application did not decrease the incidence of postoperative bowel obstruction nor did it decrease the need for operative intervention for intestinal obstruction. Furthermore, if the membrane is wrapped around an intestinal anastomosis, the leak rate is increased.

Initial concerns that were raised over the safety of hyaluronate barriers appear unfounded, with the exception of iron cross-lined hyaluronate that was withdrawn from the market. A prospective, randomized, controlled trial showed that hyaluronate barriers did not increase the risk of intra-abdominal abscess or pulmonary embolism<sup>83</sup>; however, in a post-hoc subgroup analysis of 289 patients in whom the hyaluronate membrane was wrapped around a fresh anastomosis, the rates of leak, fistula formation, peritonitis, abscess, and sepsis were increased. Based on these studies and assumptions, the use of hyaluronate membranes in elective abdominal surgery does decrease the amount of postoperative adhesions at the site of application but does not decrease the incidence of intestinal obstruction or the need for future reoperation for obstruction. Use of these products requires careful consideration, because they are expensive and their clinical benefit appears to be relatively low.

Other materials or substances are being developed that someday may move to the forefront of adhesion prevention. These include gel and liquid preparations such as hyaluronic acid and carboxymethylcellulose, hydrogel, fibrin sealant, and protein polymers. Other adhesion barriers include oxidized regenerated cellulose (ORC). ORC has been well studied and does help prevent adhesion formation, but its use requires a blood-free field that at times is not practical to achieve. The use of ORC, like hyaluronate membranes, has not been shown to decrease the incidence of subsequent adhesive small bowel obstruction.<sup>86</sup>

## EARLY POSTOPERATIVE SMALL BOWEL OBSTRUCTION

Early postoperative small bowel obstruction is a relatively uncommon problem but remains a very real dilemma encountered in every practice performing abdominal operations. Although the surgery literature defines early obstruction from 30 days to 6 weeks after the original operation, for the purposes



of this chapter, we will consider early intestinal obstructions as those occurring within 6 weeks of operation. Obstructions occurring after 6 weeks are managed similarly to other bowel obstructions.

It is often difficult, if not impossible, to distinguish early obstruction from postoperative ileus, but fortunately the management is usually quite similar. Patients with suspected early mechanical small bowel obstruction should be managed initially by nasogastric decompression, fluid resuscitation, and correction of any electrolyte abnormalities. After a thorough physical examination and the decision that emergent intervention is not indicated, a search for the cause of obstruction should be undertaken. CT can be helpful in determining the etiology of an obstruction but is notoriously unreliable at differentiating ileus versus partial obstruction. Obstructions caused by extrinsic bowel compression amenable to percutaneous correction, including fluid collections, abscesses, and hematomas, may be diagnosed and treated by CT-guided drainage. CT may be able to detect those causes of obstruction that will likely require operative intervention, such as internal hernia, fascial dehiscence, and uncontrolled anastomotic leak. Early CT may be warranted in patients who had a laparoscopic operation and have signs of early obstruction, because a port site hernia may be evident and would require prompt operation.

Generally, two categories of patients with early postoperative small bowel obstruction have been recognized.<sup>69</sup> The first category includes those in whom the obstruction becomes evident within 10 days of an abdominal operation. Conservative management is advised usually as long as signs and symptoms of ischemia and strangulation obstruction are not present and other remediable causes have been excluded. Patients within this time frame are not at a substantially increased risk of bowel-related complications after celiotomy, provided there are no internal hernias and, if the original operation was done laparoscopically, that port site hernias can be excluded. It is important to rule out correctable causes of extrinsic compression and reverse any electrolyte abnormalities, especially if ileus is also suspected. Strangulation obstruction, albeit rare, can occur in this group of patients, and thus a high index of suspicion must always be maintained; the etiology of a strangulation obstruction in this group is almost never related to adhesions but rather to some surgical misadventure, such as internal hernia, an overlooked segment of ischemia at the original celiotomy, bowel entrapped in the fascial closure, or an overlooked abdominal wall hernia.

The second category of patients is those presenting between 10 days and 6 weeks after operation.<sup>69</sup> Conservative management is also advised strongly whenever possible for patients in this category as well. The risk of iatrogenic bowel complications during and after reoperation so early after celiotomy increases dramatically in this group secondary to the dense adhesions often present during this period after abdominal operation. The time period from 7–10 days up until 6–12 weeks postoperatively represents the window when the greatest inflammatory reaction is present intraperitoneally. The developing adhesions are highly vascular and

friable. If the patient had no or very minimal adhesions at the time of celiotomy, reoperation is warranted; however, in a small, unpredictable group of patients without any previous adhesions and reliably so in those with dense adhesions that had required substantial adhesiolysis at the time of original celiotomy, an acute inflammatory reaction involving the peritoneal surfaces may agglutinate adjacent loops of bowel, often involving the omentum and mesenteric surfaces.

Operations performed during this period have a much greater rate of iatrogenic injury and subsequent fistula formation. Those patients not responding to conservative management during this period are best placed on parenteral nutrition until the obstruction resolves or they are more than 6–12 weeks out from their last celiotomy. At this time, the decision to reoperate is made based on several considerations. First, if the patient had relatively few adhesions at the time of celiotomy, reexploration at 6 weeks to 3 months postoperatively may be warranted. In contrast, in those patients who required an extensive adhesiolysis at the time of original celiotomy, many experienced surgeons wait for a full 6 months prior to reoperation for several reasons: (1) by 6 months, the adhesions are reliably less vascular and more mature; (2) reoperation prior to 3 months may reveal a frozen abdomen in which the obstruction may be unable to be dissected free safely; and (3) about half the time, the obstruction will resolve as the adhesions mature (see the earlier section on recurrent small bowel obstruction).

## BOWEL OBSTRUCTION AFTER ROUX-EN-Y GASTRIC BYPASS SURGERY

As with all other operations and maybe more so in the current era of laparoscopic Roux-en-Y gastric bypass (RYGB), bowel obstruction is a worrisome complication after bariatric surgery for morbid obesity. Estimates of the rate of bowel obstruction after RYGB vary within a reported range of 0.3% to greater than 9% depending on the technique used to perform the operation. The rate of bowel obstruction appears to be less after open RYGB, but there are no large prospective studies comparing laparoscopic to open procedures at this time. In a large, collected review of more than 9500 patients undergoing laparoscopic RYGB, the rate of bowel obstruction was 3.6%.<sup>87</sup> Although some controversy exists, most authors suggest that the rate of bowel obstruction is less with use of an antecolic versus a retrocolic orientation of the Roux limb for the gastric bypass.<sup>87–90</sup> Bowel obstruction after RYGB can occur secondary to a variety of etiologies; however, the four most common etiologies in decreasing order of frequency are internal hernia, adhesive obstruction, stenosis at the jejunojejunostomy, and incisional hernia.

The diagnosis of bowel obstruction after laparoscopic RYGB is more difficult than after other surgical procedures secondary to the altered GI anatomy produced by the procedure and the often less typical response of the patient with morbid obesity. After RYGB, the symptoms of bowel obstruction can be vague, and, because the most common etiology is internal hernia, the symptoms are often intermittent. Abdominal pain is the most common symptom present

in 82% of patients in one large series and, importantly, nausea and vomiting were seen in fewer than 50% of patients in this series. All three symptoms were present in only 28% of patients.<sup>89</sup> Unfortunately, imaging studies also have a lesser sensitivity for bowel obstruction in patients after RYGB, with reported sensitivities of 51, 57, and 33% for CT, UGI contrast study, and plain abdominal radiography, respectively.<sup>89</sup> When patients with unexpected GI symptoms after RYGB are assessed, a very high index of suspicion for bowel obstruction is warranted. Given the frequency of internal hernia as a cause of postoperative bowel obstruction and the low sensitivity of radiologic evaluation for bowel obstruction in patients after RYGB, a low threshold for laparoscopic exploration is warranted in patients with suspected bowel obstruction.

Internal hernia is the most common cause of bowel obstruction after RYGB. Anatomically, there are three different types of internal hernias seen after RYGB. All three types of internal hernias are transmesenteric defects created during the formation of the Roux limb and are illustrated in Fig. 29-3. The so-called Peterson hernia occurs in the infracolic compartment through the potential space between the mesentery of the Roux limb, the transverse mesocolon, and the retroperitoneum and can be seen with either an antecolic or retrocolic Roux limb. Herniation through the mesenteric defect created by the jejunojejunostomy is the second site of internal hernia observed after RYGB and can occur with both antecolic and retrocolic gastric bypass. Herniation through the mesenteric defect in the transverse mesocolon created by passage of the retrocolic Roux limb is the third type of internal hernia observed in RYGB and is only seen in retrocolic gastric bypass; this type of internal hernia was the most common type before the importance of meticulous closure of this defect was appreciated. Most authors believe that bowel obstruction after RYGB is substantially more common after laparoscopic retrocolic bypass, with reported rates of 3.2–5.1% after retrocolic and 0.3–1.7% after antecolic bypass reported in the largest series.<sup>87,90</sup> Meticulous closure of all potential hernia spaces with nonabsorbable suture at the time of RYGB is the best way to prevent internal hernia; however, care must be taken when closing the mesocolic defect, because obstruction at the mesocolic window from tight scar formation has also been reported as a cause of bowel obstruction after RYGB.<sup>91</sup> When operating on a patient with internal hernia after RYGB, careful closure of the hernia defect with nonabsorbable suture after reduction in the hernia is the treatment of choice.

## RADIATION ENTEROPATHY

The management of radiation enteropathy is often difficult and frustrating. The clinical presentation can be quite diverse with recurrent intermittent small bowel obstruction, a true, chronic, persistent partial small bowel obstruction, or chronic diarrhea/malabsorption. Operative management is often extremely challenging secondary to the dense adhesions and chronic inflammatory reaction present after radiation. These patients also tend to develop recurrent

areas of enteropathy (progression of disease) in bowel that appeared normal previously, because this ischemic disease is an ongoing and progressive chronic process. The need for operative correction with a resection and anastomosis has been reported to have a mortality rate as high as 21% in some series.<sup>82</sup> Patients with radiation enteropathy also have a high rate of anastomotic leak and fistulation after operation because of the compromised vascular supply to the bowel. These effects are magnified in patients with atherosclerosis, hyperlipidemia, or type 2 diabetes. For these reasons, a cautious, conservative approach to the patient with radiation enteropathy is warranted whenever possible.

When operative management is necessary, the surgeon must decide between resection, bypass of the affected segment, or adhesiolysis. As mentioned previously, resection has been reported to have a high mortality rate with a 36% incidence of leak after primary anastomosis.<sup>82</sup> In the same study, bypass of the affected segment had a 10% mortality and 6% leak rate. Surgeons advocating aggressive resection back to healthy bowel, however, have reported leak rates between 0 and 8% when confounding conditions (abscess, fistula, necrosis, or recurrent cancer) were absent; such an aggressive approach may require an extensive resection but often involves resection of nonfunctional bowel anyway. Worry of a short bowel syndrome is always a concern, especially because the involved bowel is usually the distal ileum.

Most surgeons approach the treatment of radiation enteropathy cautiously. In those patients with recurrent cancer and radiation enteropathy, treatment should consist of palliative bypass of the diseased segment with creation of an anastomosis in visibly normal tissue. If the obstructive process is localized, wide resection back to healthy, nonirradiated tissue (if possible) with primary anastomosis is acceptable, provided adequate absorptive area is preserved. Usually this means anastomosis from small bowel to the ascending colon, because the terminal ileum has usually been involved in the radiation field. While ideally a complete resection of the entire involved small bowel is optimal, the surgeon must consider the extent of the resection necessary as well as the anatomic segment involved. Usually, the involved small intestine is the distal ileum; major resection back to reliably normal, nonirradiated small bowel may require a total or subtotal ileal resection that carries its own nutritional complications, and a decision will need to be made concerning preservation of mildly involved but functional ileum if the only alternative is complete resection. In contrast, if the bowel is severely involved and nonfunctional, resection (despite its side effects) may be the best option. When the affected area contains dense adhesions or is stuck deep within the pelvis, bypass may be a better choice to avoid the very real concern of potential iatrogenic injury to the bowel, bladder, pelvic organs, and ureters; however, if there is a localized abscess or associated septic process, bypass is not a good option, just as with Crohn's disease, because the ischemic inflammatory process will continue. Attempts at complete lysis of adhesions alone without resection are controversial due to the risk of traumatizing the intestine with potential fistula formation. For the patient with advanced disease who

presents years after irradiation, adhesiolysis may not be a good option, especially if the bowel is matted and agglutinated. In contrast, in the case of isolated adhesive bands and the patient being early (<2 years) after irradiation, lysis alone may be warranted; much of the decision needs to be based on the quality of the involved bowel and the site of obstruction. If the bowel is thickened, woody, and strictured, resection or bypass is best.

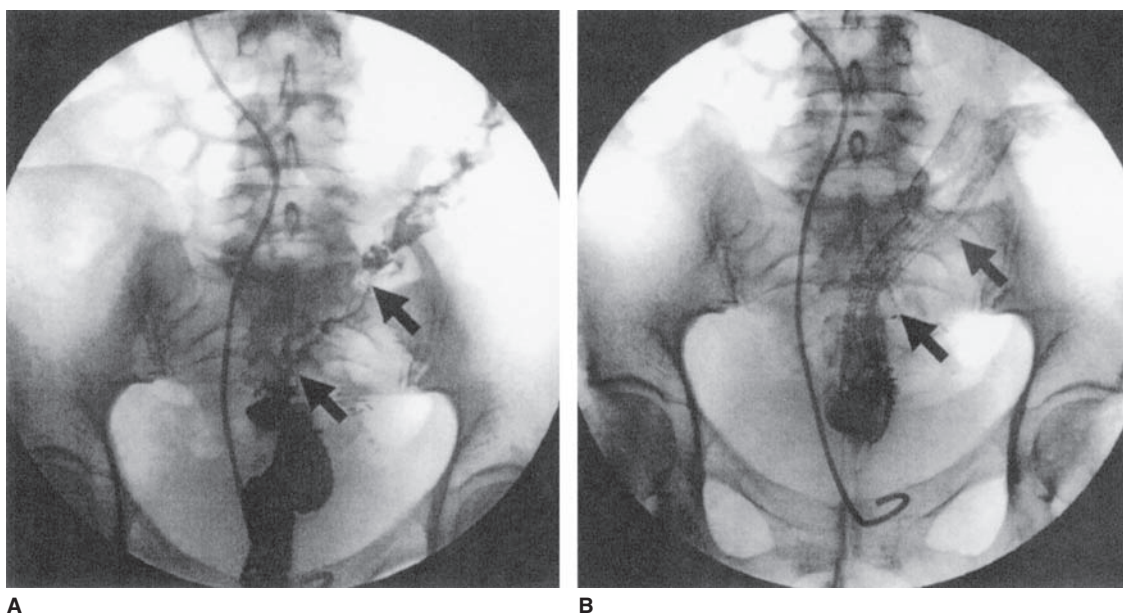
### CARCINOMATOSIS AND MALIGNANT OBSTRUCTION

Bowel obstruction in the setting of carcinomatosis often represents the terminal phase of the malignant disease. Operative management is entirely palliative and needs to be applied selectively. In the case of limited life expectancy and malignant cachexia or ascites, nonoperative palliative measures are advised, because operative intervention would be unnecessary and associated with a lesser, end-of-life, quality of life due to the convalescence required after a noncurative celiotomy. In contrast, other patients with a good performance status may have a long life expectancy, and in this case, operative bypass with the idea of permitting renewed oral intake may be indicated. Patients and their families should be counseled that the relief of their obstruction will not affect disease progression but may improve quality of life. In addition, the surgeon should remember that up to one-third of bowel obstructions presenting in the setting of carcinomatosis are due to adhesions and not to malignant obstruction.<sup>68</sup> Therefore, a short trial of conservative therapy with rehydration and nasogastric decompression is usually advisable, although many (possibly most) patients with carcinomatosis will fail this intervention.

In addition, depending on the location and extent of the malignant disease involving the GI tract, a palliative endoscopic stent placement may relieve the obstruction (Fig. 29-14).

An initial minimal access, laparoscopic approach should at least be entertained in patients with a malignant obstruction provided the access to the peritoneal cavity is safe. The least invasive approach is best for these patients, and if palliation, such as a bypass or gastrostomy tube, can be achieved laparoscopically, the patient would benefit substantially with decreased pain, possibly a shorter convalescence, and decreased duration of hospital stay, all of which are important considerations in the palliative care of patients with a limited life expectancy.

At exploration, multiple scenarios may be encountered. Some patients will have an isolated area of adhesions and require only adhesiolysis. Others will have a solitary metastasis causing either an intra- or extraluminal obstruction that can be corrected with a limited resection or bypass. If multiple areas of adhesions are present or the affected area is adherent to the abdominal wall or intra-abdominal structures in the patients with incurable malignant obstruction, bypass of the involved segment will provide symptom relief and the fewest opportunities for complication. One should consider placement of a tube gastrostomy if there is any question of the success of the operation, if impending obstruction seems imminent, or if relief of the obstruction is not possible. In the event of reobstruction, a tube gastrostomy can be used to decompress the stomach and avoid the discomfort associated with a nasogastric tube. The decision to place a palliative, decompressive, tube gastrostomy is more difficult in the presence of ascites. In this situation, a better option would be a



**FIGURE 29-14** **A.** Obstructing rectal cancer (arrows). **B.** Intraluminal self-expanding metal stent restores luminal patency. (Reproduced, with permission, from Hünnerbein M, Krause M, Moesta KT, Rau B, Schlag PM. Palliation of malignant rectal obstruction with self-expanding metal stents. *Surgery*. 2005;137:42–47.)



tube pharyngostomy.<sup>92</sup> Additionally, if histologic diagnosis of the neoplasm had been obtained previously, a repeat biopsy should be entertained to ensure that the neoplasm has histologic characteristics consistent with the original biopsy.

## REFERENCES

1. Woods JH, Erickson LW, Condon RE, Schulte WJ, Sillin LF. Postoperative ileus: a colonic problem? *Surgery*. 1978 Oct;84(4):527–533.
2. Baig MK, Wexner SD. Postoperative ileus: a review. *Dis Colon Rectum*. 2004;47(4):516–526.
3. Sajja SB, Schein M. Early postoperative small bowel obstruction. *Br J Surg*. 2004;91(6):683–691.
4. Duepre HJ, Senagore AJ, Delaney CP, Fazio VW. Does means of access affect the incidence of small bowel obstruction and ventral hernia after bowel resection? Laparoscopy versus laparotomy. *J Am Coll Surg*. 2003 Aug;197(2):177–181.
5. Miller G, Boman J, Shrier I, Gordon PH. Natural history of patients with adhesive small bowel obstruction. *Br J Surg*. 2000;87(9):1240–1247.
6. Williams SB, Greenspon J, Young HA, Orkin BA. Small bowel obstruction: conservative vs. surgical management. *Dis Colon Rectum*. 2005;48(6):1140–1146.
7. Lu RH, Chang TM, Yen MH, Tsai LM. Involvement of superoxide anion in the pathogenesis of simple mechanical intestinal obstruction. *J Surg Res*. 2003 Dec;115(2):184–190.
8. Kalf JC, Schraut WH, Simmons RL, Bauer AJ. Surgical manipulation of the gut elicits an intestinal muscularis inflammatory response resulting in postsurgical ileus. *Ann Surg*. 1998 Nov;228(5):652–663.
9. Turler A, Schnurr C, Nakao A, et al. Endogenous endotoxin participates in causing a panenteric inflammatory ileus after colonic surgery. *Ann Surg*. 2007;245(5):734–744.
10. Miedema BW, Johnson JO. Methods for decreasing postoperative gut dysmotility. *Lancet Oncol*. 2003;4(6):365–372.
11. Hallerback B, Ander S, Glise H. Effect of combined blockade of beta-adrenoceptors and acetylcholinesterase in the treatment of postoperative ileus after cholecystectomy. *Scand J Gastroenterol*. 1987;22(4):420–424.
12. Orlando E, Finelli F, Colla M, Giotto E, Terragni P, Olivero G. [A double-blind study of neostigmine versus placebo in paralytic ileus as a result of surgical interventions]. *Minerva Chir*. 1994;49(5):451–455.
13. Kabaroudis A, Papaziogas B, Koutelidakis I, Kyparissi-Kanellaki M, Kouzi-Koliakou K, Papaziogas T. Disruption of the small-intestine mucosal barrier after intestinal occlusion: a study with light and electron microscopy. *J Invest Surg*. 2003 Jan–Feb;16(1):23–28.
14. Hellebrekers BW, Trimbos-Kemper GC, Bakum EA, et al. Short-term effect of surgical trauma on rat peritoneal fibrinolytic activity and its role in adhesion formation. *Thromb Haemost*. 2000 Nov;84(5):876–881.
15. Wilson MS, Ellis H, Menzies D, Moran BJ, Parker MC, Thompson JN. A review of the management of small bowel obstruction. Members of the Surgical and Clinical Adhesions Research Study (SCAR). *Ann R Coll Surg Engl*. 1999 Sep;81(5):320–328.
16. Sulaiman H, Gabella G, Davis MC, et al. Presence and distribution of sensory nerve fibers in human peritoneal adhesions. *Ann Surg*. 2001 Aug;234(2):256–261.
17. diZerega GS, Campeau JD. Peritoneal repair and post-surgical adhesion formation. *Hum Reprod Update*. 2001 Nov–Dec;7(6):547–555.
18. Menzies D, Ellis H. Intestinal obstruction from adhesions—how big is the problem? *Ann R Coll Surg Engl*. 1990;72(1):60–63.
19. Fevang BT, Fevang J, Lie SA, Soreide O, Svanes K, Viste A. Long-term prognosis after operation for adhesive small bowel obstruction. *Ann Surg*. 2004 Aug;240(2):193–201.
20. Carmody B, DeMaria EJ, Jamal M, et al. Internal hernia after laparoscopic Roux-en-Y gastric bypass. *Surg Obes Relat Dis*. 2005 Nov–Dec;1(6): 543–548.
21. Cho M, Pinto D, Carrodegas L, et al. Frequency and management of internal hernias after laparoscopic antegastric Roux-en-Y gastric bypass without division of the small bowel mesentery or closure of mesenteric defects: review of 1400 consecutive cases. *Surg Obes Relat Dis*. 2006 Mar–Apr;2(2):87–91.
22. Steele KE, Prokopowicz GP, Magnuson T, Lidor A, Schweitzer M. Laparoscopic antecolic Roux-en-Y gastric bypass with closure of internal defects leads to fewer internal hernias than the retrocolic approach. *Surg Endosc*. 2008;22(9):2056–2061.
23. Coleman MH, Awad ZT, Pomp A, Gagner M. Laparoscopic closure of the Petersen mesenteric defect. *Obes Surg*. 2006;16(6):770–772.
24. Petersen W. Uber Darmverschluss nach der Gastroenterostomie. *Arch Klin Chir*. 1900;62:94–114.
25. Boughey JC, Nottingham JM, Walls AC. Richter's hernia in the laparoscopic era: four case reports and review of the literature. *Surg Laparosc Endosc Percutan Tech*. 2003 Feb;13(1):55–58.
26. Bhojruyl S, Payne J, Steffes B, Swanstrom L, Way LW. A randomized prospective study of radially expanding trocars in laparoscopic surgery. *J Gastrointest Surg*. 2000 Jul–Aug;4(4):392–397.
27. Johnson WH, Fecher AM, McMahon RL, Grant JP, Pryor AD. VersaStep trocar hernia rate in unclosed fascial defects in bariatric patients. *Surg Endosc*. 2006;20(10):1584–1586.
28. Begos DG, Sandor A, Modlin IM. The diagnosis and management of adult intussusception. *Am J Surg*. 1997;173(2):88–94.
29. Lange H, Jackel R. Usefulness of plasma lactate concentration in the diagnosis of acute abdominal disease. *Eur J Surg*. 1994;160(6–7):381–384.
30. Lange H, Toivola A. [Warning signals in acute abdominal disorders. Lactate is the best marker of mesenteric ischemia]. *Lakartidningen*. 1997 May 14;94(20):1893–1896.
31. Altinyollar H, Boyabatli M, Berberoglu U. D-dimer as a marker for early diagnosis of acute mesenteric ischemia. *Thromb Res*. 2006;117(4):463–467.
32. Kurt Y, Akin ML, Demirbas S, et al. D-dimer in the early diagnosis of acute mesenteric ischemia secondary to arterial occlusion in rats. *Eur Surg Res*. 2005 Jul–Aug;37(4):216–219.
33. Cronk DR, Houseworth TP, Cuadrado DG, Herbert GS, McNutt PM, Azarow KS. Intestinal fatty acid binding protein (I-FABP) for the detection of strangulated mechanical small bowel obstruction. *Curr Surg*. 2006 Sep–Oct;63(5):322–325.
34. Kanda T, Fujii H, Tani T, et al. Intestinal fatty acid-binding protein is a useful diagnostic marker for mesenteric infarction in humans. *Gastroenterology*. 1996;110(2):339–343.
35. Graeber GM, O'Neill JF, Wolf RE, Wukich DK, Cafferty PJ, Harmon JW. Elevated levels of peripheral serum creatine phosphokinase with strangulated small bowel obstruction. *Arch Surg*. 1983;118(7):837–840.
36. Mukai M, Tamaki T, Noto T, Tajima T, Nakano S, Mitomi T. A new mechanism of serum creatine phosphokinase elevation in strangulated small bowel obstruction: an experimental rat model. *J Int Med Res*. 1995 May–Jun;23(3):184–190.
37. Gunduz A, Turedi S, Mentese A, et al. Ischemia-modified albumin in the diagnosis of acute mesenteric ischemia: a preliminary study. *Am J Emerg Med*. 2008;26(2):202–205.
38. Contrin LM, Lobo SM, Navegantes LC, et al. Tyrosine: a possible marker of severe intestinal injury during ischemia. *J Surg Res*. 2009;155(2):268–272.
39. Zielinski M, Eiken P, Bannon M, et al. Small bowel obstruction—who needs an operation? A multivariate prediction model. *World J Surg*. 2010;34(5):910–919.
40. Ros PR, Huprich JE. ACR Appropriateness criteria on suspected small-bowel obstruction. *J Am Coll Radiol*. 2006;3(11):838–841.
41. Assalia A, Schein M, Kopelman D, Hirshberg A, Hashmonai M. Therapeutic effect of oral Gastrografin in adhesive, partial small-bowel obstruction: a prospective randomized trial. *Surgery*. 1994;115(4):433–437.
42. Choi HK, Chu KW, Law WL. Therapeutic value of Gastrografin in adhesive small bowel obstruction after unsuccessful conservative treatment: a prospective randomized trial. *Ann Surg*. Jul 2002;236(1):1–6.
43. Chen SC, Chang KJ, Lee PH, Wang SM, Chen KM, Lin FY. Oral Urografin in postoperative small bowel obstruction. *World J Surg*. 1999;23(10):1051–1054.
44. Abbas SM, Bissett IP, Parry BR. Meta-analysis of oral water-soluble contrast agent in the management of adhesive small bowel obstruction. *Br J Surg*. 2007;94(4):404–411.
45. Feigin E, Seror D, Szold A, et al. Water-soluble contrast material has no therapeutic effect on postoperative small-bowel obstruction: results of a prospective, randomized clinical trial. *Am J Surg*. 1996;171(2):227–229.
46. Frager D, Medwid SW, Baer JW, Mollinelli B, Friedman M. CT of small-bowel obstruction: value in establishing the diagnosis and determining the degree and cause. *AJR Am J Roentgenol*. 1994;162(1):37–41.
47. Fukuya T, Hawes DR, Lu CC, Chang PJ, Barloon TJ. CT diagnosis of small-bowel obstruction: efficacy in 60 patients. *AJR Am J Roentgenol*. 1992;158(4):765–769; discussion 771–762.
48. Megibow AJ, Balthazar EJ, Cho KC, Medwid SW, Birnbaum BA, Noz ME. Bowel obstruction: evaluation with CT. *Radiology*. 1991 Aug;180(2):313–318.

49. Jones K, Mangram AJ, Lebron RA, Nadalo L, Dunn E. Can a computed tomography scoring system predict the need for surgery in small-bowel obstruction? *Am J Surg*. 2007 Dec;194(6):780–783; discussion 783–784.
50. O'Daly BJ, Ridgway PF, Keenan N, et al. Detected peritoneal fluid in small bowel obstruction is associated with the need for surgical intervention. *Can J Surg*. 2009 Jun;52(3):201–206.
51. Mallo RD, Salem L, Lalani T, Flum DR. Computed tomography diagnosis of ischemia and complete obstruction in small bowel obstruction: a systematic review. *J Gastrointest Surg*. 2005;9(5):690–694.
52. Sheedy SP, Earnest Ft, Fletcher JG, Fidler JL, Hoskin TL. CT of small-bowel ischemia associated with obstruction in emergency department patients: diagnostic performance evaluation. *Radiology*. 2006 Dec;241(3):729–736.
53. Sebastian VA, Nebab KJ, Goldfarb MA. Intestinal obstruction and ileus: role of computed tomography scan in diagnosis and management. *Am Surg*. 2007;73(12):1210–1214.
54. Otero HJ, Erturk SM, Ochoa RE, Ondategui-Parra S, Rybicki FJ, Ros PR. Intestinal obstruction: trends in imaging utilization and their influence in its rising hospital bill. *Emerg Radiol*. 2008 Sep;15(5):317–323.
55. Cozza S, Ferrari FS, Stefani P, et al. Ileal occlusion with strangulation: importance of ultrasonography findings of the dilated loop with intraluminal fluid-fluid resulting from sedimentation. *Radiol Med*. 1996 Oct;92(4):394–397.
56. Okada T, Yoshida H, Iwai J, et al. Pulsed Doppler sonography for the diagnosis of strangulation in small bowel obstruction. *J Pediatr Surg*. 2001;36(3):430–435.
57. Beall DP, Fortman BJ, Lawler BC, Regan F. Imaging bowel obstruction: a comparison between fast magnetic resonance imaging and helical computed tomography. *Clin Radiol*. 2002;57(8):719–724.
58. Low RN, Chen SC, Barone R. Distinguishing benign from malignant bowel obstruction in patients with malignancy: findings at MR imaging. *Radiology*. 2003 Jul;228(1):157–165.
59. Fidler J. MR imaging of the small bowel. *Radiol Clin North Am*. 2007 Mar;45(2):317–331.
60. Mason M, Swain J, Matthews BD, Harold KL. Use of video capsule endoscopy in the setting of recurrent subacute small-bowel obstruction. *J Laparoendosc Adv Surg Tech A*. 2008 Oct;18(5):713–716.
61. Yang XY, Chen CX, Zhang BL, et al. Diagnostic effect of capsule endoscopy in 31 cases of subacute small bowel obstruction. *World J Gastroenterol*. 2009 May 21;15(19):2401–2405.
62. Jancelewicz T, Vu LT, Shawo AE, Yeh B, Gasper WJ, Harris HW. Predicting strangulated small bowel obstruction: an old problem revisited. *J Gastrointest Surg*. 2009;13(1):93–99.
63. Ogata M, Imai S, Hosotani R, Aoyama H, Hayashi M, Ishikawa T. Abdominal ultrasonography for the diagnosis of strangulation in small bowel obstruction. *Br J Surg*. 1994;81(3):421–424.
64. Gowen GF. Long tube decompression is successful in 90% of patients with adhesive small bowel obstruction. *Am J Surg*. 2003;185(6):512–515.
65. Brolin RE. The role of gastrointestinal tube decompression in the treatment of mechanical intestinal obstruction. *Am Surg*. 1983;49(3):131–137.
66. Fevang BT, Jensen D, Svanes K, Viste A. Early operation or conservative management of patients with small bowel obstruction? *Eur J Surg*. 2002;168(8–9):475–481.
67. Fleshner PR, Siegman MG, Slater GI, Brolin RE, Chandler JC, Aufses AH, Jr. A prospective, randomized trial of short versus long tubes in adhesive small-bowel obstruction. *Am J Surg*. 1995 Oct;170(4):366–370.
68. Pickleman J. Small bowel obstruction. In: Zinner MJ SS, Ellis H ed. *Maingot's Abdominal Operations*. 10th ed. New York, NY: McGraw-Hill; 1997:1159–1172.
69. Baerga-Varela Y. Small bowel obstruction. In: Kelly KA, Sarr MG, Hinder RA, ed. *Mayo Clinic Gastrointestinal Surgery*. Philadelphia, PA: Saunders; 2004:421–437.
70. Landercasper J, Cogbill TH, Merry WH, Stolee RT, Strutt PJ. Long-term outcome after hospitalization for small-bowel obstruction. *Arch Surg*. 1993;128(7):765–770; discussion 770–761.
71. Rocha FG, Theman TA, Matros E, Ledbetter SM, Zinner MJ, Ferzoco SJ. Nonoperative management of patients with a diagnosis of high-grade small bowel obstruction by computed tomography. *Arch Surg*. 2009;144(11):1000–1004.
72. Sarr MG, Bulkley GB, Zuidema GD. Preoperative recognition of intestinal strangulation obstruction. Prospective evaluation of diagnostic capability. *Am J Surg*. 1983;145(1):176–182.
73. Fleisher LA, Eagle KA. Clinical practice. Lowering cardiac risk in noncardiac surgery. *N Engl J Med*. 2001 Dec 6;345(23):1677–1682.
74. Leon EL, Metzger A, Tsiotos GG, Schlinkert RT, Sarr MG. Laparoscopic management of small bowel obstruction: indications and outcome. *J Gastrointest Surg*. 1998 Mar–Apr;2(2):132–140.
75. Mucha P, Jr. Small intestinal obstruction. *Surg Clin North Am*. 1987 Jun;67(3):597–620.
76. Merrett ND, Jorgenson J, Schwartz P, Hunt DR. Bacteremia associated with operative decompression of a small bowel obstruction. *J Am Coll Surg*. 1994 Jul;179(1):33–37.
77. Polymeneas G, Theodosopoulos T, Stamatiadis A, Kourias E. A comparative study of postoperative adhesion formation after laparoscopic vs open cholecystectomy. *Surg Endosc*. 2001;15(1):41–43.
78. Strickland P, Lourie DJ, Suddleson EA, Blitz JB, Stain SC. Is laparoscopy safe and effective for treatment of acute small-bowel obstruction? *Surg Endosc*. 1999;13(7):695–698.
79. Suzuki K, Umehara Y, Kimura T. Elective laparoscopy for small bowel obstruction. *Surg Laparosc Endosc Percutan Tech*. 2003 Aug;13(4):254–256.
80. Wullstein C, Gross E. Laparoscopic compared with conventional treatment of acute adhesive small bowel obstruction. *Br J Surg*. 2003;90(9):1147–1151.
81. Becker JM, Dayton MT, Fazio VW, et al. Prevention of postoperative abdominal adhesions by a sodium hyaluronate-based bioresorbable membrane: a prospective, randomized, double-blind multicenter study. *J Am Coll Surg*. 1996 Oct;183(4):297–306.
82. Tito WA, Sarr MG. Intestinal obstruction. In: Zuidema GD, ed. *Shackelford's Surgery of the Alimentary Tract*. 4th ed. Philadelphia, PA: Saunders; 1996:375–416.
83. Beck DE, Cohen Z, Fleshman JW, Kaufman HS, van Goor H, Wolff BG. A prospective, randomized, multicenter, controlled study of the safety of Sefrapilim adhesion barrier in abdominopelvic surgery of the intestine. *Dis Colon Rectum*. 2003;46(10):1310–1319.
84. Kumar S, Wong PF, Leaper DJ. Intra-peritoneal prophylactic agents for preventing adhesions and adhesive intestinal obstruction after non-gynaecological abdominal surgery. *Cochrane Database Syst Rev*. 2009(1):CD005080.
85. Zeng Q, Yu Z, You J, Zhang Q. Efficacy and safety of Sefrapilim for preventing postoperative abdominal adhesion: systematic review and meta-analysis. *World J Surg*. 2007;31(11):2125–2131; discussion 2132.
86. Al-Jaroudi D, Tulandi T. Adhesion prevention in gynecologic surgery. *Obstet Gynecol Surv*. 2004;59(5):360–367.
87. Koppman JS, Li C, Gandsas A. Small bowel obstruction after laparoscopic Roux-en-Y gastric bypass: a review of 9,527 patients. *J Am Coll Surg*. 2008;206(3):571–584.
88. Escalona A, Devaud N, Perez G, et al. Antecolic versus retrocolic alimentary limb in laparoscopic Roux-en-Y gastric bypass: a comparative study. *Surg Obes Relat Dis*. 2007 Jul–Aug;3(4):423–427.
89. Husain S, Ahmed AR, Johnson J, Boss T, O'Malley W. Small-bowel obstruction after laparoscopic Roux-en-Y gastric bypass: etiology, diagnosis, and management. *Arch Surg*. 2007;142(10):988–993.
90. Rogula T, Yenumula PR, Schauer PR. A complication of Roux-en-Y gastric bypass: intestinal obstruction. *Surg Endosc*. 2007;21(11):1914–1918.
91. Ahmed AR, Rickards G, Messing S, et al. Roux limb obstruction secondary to constriction at transverse mesocolon rent after laparoscopic Roux-en-Y gastric bypass. *Surg Obes Relat Dis*. 2009 Mar–Apr;5(2):194–198.
92. Kendrick ML, Sarr MG. Prolonged gastrointestinal decompression of the inoperable abdomen: the forgotten tube pharyngostomy. *J Am Coll Surg*. 2000 Aug;191(2):221–223.

# TUMORS OF THE SMALL INTESTINE

Craig Fischer • Barbara Lee Bass

Tumors of the small intestine, both benign and malignant, are rare. With the potential to arise from virtually every cell type within the small intestine—the epithelium, neural tissues, lymphatic and mesenchymal cells—the small bowel may also be the site of metastases from other primary tumors. The variety and uncommon nature of these tumors makes generalizations regarding their management difficult. In this chapter we review the epidemiology and clinical diagnostic and management strategies for benign and malignant neoplasms of the small bowel.

## EPIDEMIOLOGY

While the small bowel accounts for 75% of the length and 90% of the mucosal surface area of the gastrointestinal tract, fewer than 3% of gastrointestinal malignancies arise in this organ. Most of these tumors are clinically silent. Autopsy series have identified incidental small bowel tumors in 0.2–0.3% of hospital deaths—a rate 15 times the operative incidence of small bowel resections for tumors.<sup>1</sup>

Given the rare nature of these tumors, most published reports are collections of relatively small series of tumors accrued over a period of many years. Hence, interestingly, these reports differ regarding the type of small bowel tumors, the distribution of tumors, and until the advent of molecular diagnostic criteria for GIST (gastrointestinal stromal tumors), in the classification of tumors of stromal origin. Nonetheless, in most series adenocarcinoma, GIST, carcinoid tumor, and lymphoma comprise the most common malignant tumors and are approximately equally represented.<sup>2,3</sup> Small bowel tumors are more prevalent in older than in younger patients, and a recent analysis identified that over 65% of patients with small bowel adenocarcinoma were age 60 or older.<sup>3</sup> The proportion of small bowel tumors that are benign varies from 14 to 52% in different series, a disparity explained by the failure to detect the typically asymptomatic benign lesions.

There are no satisfactory explanations for the observed variation in prevalence of small bowel tumors around the world. Carcinoids are uncommon tumors in Asian series,

while GIST comprise a higher proportion of reported series in the East.<sup>4,5</sup> Men are more likely to develop small bowel neoplasms than women, with a male preponderance reported for both benign and malignant tumors.

## PATHOGENESIS

Given the length of the small bowel and its large mucosal surface, it is intriguing that it is such an uncommon site for malignancy. Unlike the adenoma-carcinoma sequence seen in the colon, a clear molecular progression sequence has not been defined in the small bowel outside the known polyposis syndromes. Only periampullary adenomas are known to be premalignant lesions with the potential to progress to adenocarcinomas. Adenomatous polyps arising elsewhere in the small bowel presumably have similar potential for malignant transformation, although the molecular traits of this transformation remain unknown. Such progression has not been definitively documented at other sites in the small bowel.

Based on theories of luminal injury defined in the colonic mucosa, several hypotheses are proposed regarding the pathogenesis of epithelial-derived small bowel tumors. Unlike the colon with its high bacterial luminal content, the lumen of the healthy small bowel is largely free of bacteria; bacterial metabolites implicated in the genetic alterations of colon carcinogenesis are absent. Transit through the small bowel is rapid—30 minutes to 2 hours—so exposure to potential toxins and metabolites is much more limited. The alkaline, mucus-rich succus entericus of the small bowel may have protective capacity and less noxious potential than the more solid contents of the colon. Enterocytes of the brush border epithelium express the enzyme benzopyrene hydroxylase, possibly protecting against mucosal damage by detoxifying the carcinogen benzopyrene. And last, high levels of luminal IgA and greater distribution of lymphoid tissue in the small intestinal epithelium and submucosa may provide an additional protective mechanism via an immune surveillance mechanism.

Bile acids and their metabolites have been implicated in the pathogenesis of small bowel adenocarcinoma.



Postcholecystectomy patients may be at greater risk for the development of small bowel malignancy. In one study of patients with small intestinal malignancy, 12% had a history of cholecystectomy, and of those with duodenal adenocarcinoma, 25% had prior cholecystectomy. However, a causative relationship between cholecystectomy and small intestinal adenocarcinoma remains unproven.

## High-Risk Population

Several heritable and inflammatory gastrointestinal conditions are associated with an increased risk for development of small bowel tumors.

### FAMILIAL ADENOMATOUS POLYPOSIS

Patients with familial adenomatous polyposis (FAP) carry a lifetime risk approaching 100% for the development of adenomatous polyps of the duodenum, and these lesions may progress to adenocarcinoma. FAP patients have a 331-fold increased risk for development of adenocarcinoma of the duodenum over the normal population,<sup>3</sup> and this is the leading cause of cancer death in patients with FAP previously treated by colectomy. These patients require regular screening esophagogastroduodenoscopy (EGD) and endoscopic or surgical excision of enlarging adenomas.

### CROHN'S DISEASE

Patients with active jejunoileitis of Crohn's disease have a 100-fold increased incidence of adenocarcinoma. Active disease in the terminal ileum is the most frequent site of malignancy.<sup>6</sup> Abdominal complaints and symptoms consistent with their primary condition may delay evaluation and diagnosis, leading to detection of tumors at advanced stages. The prognosis for patients with adenocarcinoma arising in Crohn's disease is poor.<sup>7</sup> For patients undergoing bowel-preserving procedures such as stricturoplasty, a biopsy of the site of past or active disease is advocated to look for dysplasia or in situ carcinoma. Such findings, while rare, would warrant resection rather than bowel-preserving approaches.

### CELIAC DISEASE

Celiac disease is associated with increased risk of lymphoma and is seen in up to 14% of patients.<sup>8</sup> A gluten-free diet has been postulated to decrease this risk, although this has not been substantiated by a recent study.<sup>9</sup>

### MISCELLANEOUS CONDITIONS ASSOCIATED WITH SMALL BOWEL NEOPLASMS

Patients with Peutz-Jeghers syndrome develop benign hamartomas throughout the intestinal tract. Surveillance is indicated, as these lesions are at risk of malignant transformation into adenocarcinoma.<sup>10</sup> Patients with von Recklinghausen's disease

may develop neurofibromas in the gastrointestinal tract that can undergo malignant transformation. Patients on chronic immune suppression therapy are at particular risk for small bowel malignancies, especially lymphomas and sarcomas. Transplant recipients on immunosuppression have a 45- to 100-fold increase in non-Hodgkin's lymphoma (NHL), a condition termed *posttransplant lymphoproliferative disorder* (PTLD).<sup>11</sup> PTLD accounts for 30% of all malignancies in cyclosporine-treated patients but accounts for only 12% of malignancies in patients without cyclosporine in their regimen. PTLD tends to develop rapidly, often within 12 months of transplant. Greater degrees of immunosuppression carry greater risk for development of PTLD. Human immunodeficiency virus (HIV) infection is also associated with the development of lymphoma in up to 30% of patients. Most are extranodal and the gastrointestinal tract is the involved site in 10–25% of cases. More than 90% of patients present with stage IV disease and median survival is only 6 months.

## CLINICAL PRESENTATION

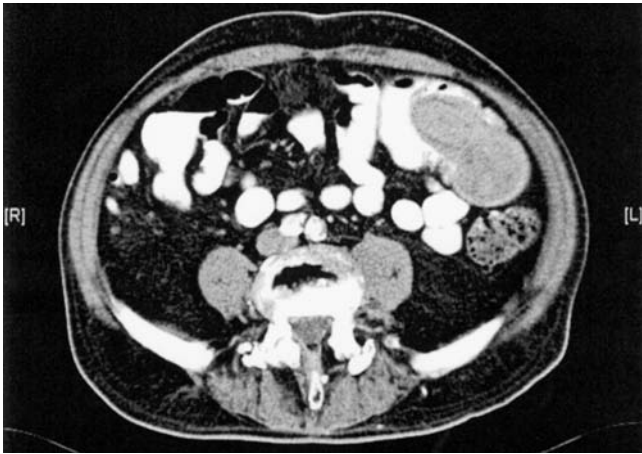
Patients with small bowel tumors present with nonspecific gastrointestinal and constitutional complaints. In hindsight, the gradual development of symptoms is usually evident. The most common symptoms include vague abdominal discomfort and cramps, gradual weight loss, anemia, nausea, and vomiting. These nonspecific complaints, coupled with the fact that most patients are older and often on medications that may also elicit these complaints, result in a high rate of misdiagnosis and delay in diagnosis. In most series, the average duration of symptoms prior to diagnosis ranges from weeks to many months. Initial evaluation to exclude more common conditions, including evaluation of the gastroduodenum, colon, and biliary tract are completed, but, when negative, further evaluation of the small bowel is delayed or deferred.

Benign lesions rarely cause abdominal pain or obstruction; rather, their presence is often heralded by acute gastrointestinal hemorrhage. Benign neoplasms may grow to a large size prior to detection and may simply be discovered incidentally on a radiological examination or at laparotomy.

## DIAGNOSIS

The diagnosis of small bowel tumors is hampered by a number of factors. In addition to the fact that these are rare tumors that produce nonspecific gastrointestinal complaints, the ability to fully image and observe the small intestine is limited. Despite the introduction of capsule endoscopy, which allows for luminal visualization of the entire small bowel mucosal surface, accurate preoperative diagnosis is in fact uncommon prior to surgery.<sup>12,13</sup>

History and physical examination are nonspecific. Abdominal mass, heme-positive stool, or signs of intestinal obstruction are usually absent. Laboratory data may demonstrate iron deficiency anemia in a minority of patients.



**FIGURE 30-1** Adenocarcinoma in the ileum is obvious as a mass in the left midabdomen.

Plain abdominal films are an appropriate initial diagnostic test, although they are rarely helpful unless the patient presents with obstructive symptoms.

After ruling out more common conditions that could elicit similar gastrointestinal and abdominal complaints with endoscopic evaluation of the gastroduodenum and colon, computed tomography (CT) of the abdomen is the appropriate initial imaging test. CT may reveal bulky tumors (Fig. 30-1) or more subtle findings suggestive of small bowel tumors, such as thickening of the small bowel wall. Thickening of the bowel wall to greater than 1.5 cm or the detection of discrete mesenteric lymph nodes or masses greater than 1.5 cm in diameter is highly suggestive of malignancy. If obstructing lesions are present, CT scan may reveal a transition zone demarcating dilated proximal bowel from decompressed distal bowel.

Tumors of the distal small bowel may cause jejunoileal or ileocolic intussusception. During intussusception, the small bowel tumor serves as the lead point to pull the small bowel into the distal small bowel or colonic lumen; the mass lesion precludes spontaneous reduction. CT findings of ileocolic or jejunoileal intussusception include the presence of concentric rings with a donut appearance involving the bowel. This sign is nearly pathognomonic for small bowel tumor. In adults, radiographic attempts to reduce an intussusception should not be made. Rather, prompt surgical exploration and resection of the nonreduced intussuscepted bowel segment with mesenteric resection should be completed without intraoperative attempts at complete reduction; rather, the intestine should be reduced gently to the palpated lead point, followed by intestinal resection and primary anastomosis. Attempts at complete reduction often lead to inadvertent enterotomy or exposure of a perforation within the intussusception.

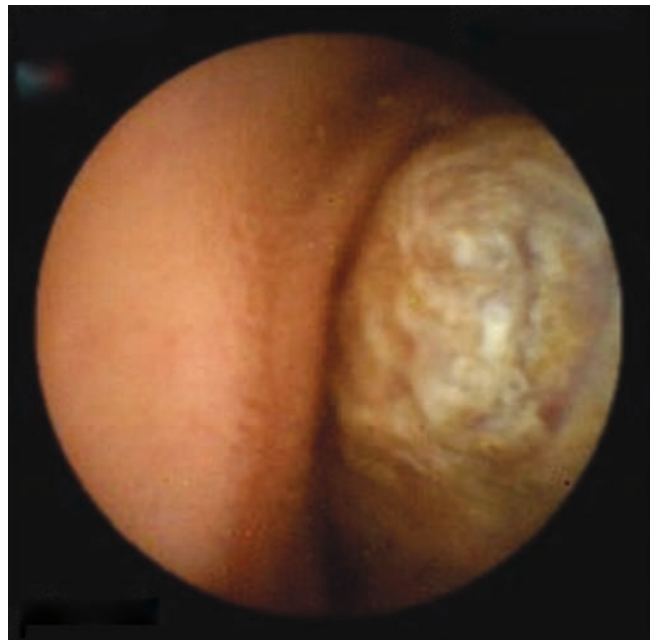
Luminal contrast radiographic studies may be used if abdominal CT imaging fails to reveal evidence of a small bowel tumor, usually an upper gastrointestinal contrast series with small bowel follow-through. A small bowel follow-through study will show an abnormality in 53–83% of cases, although direct evidence of a tumor is detected in only 30–44%.

While enteroclysis (a dynamic contrast technique using a slurry of barium and methylcellulose infused into the small bowel via a nasoduodenal tube to uniformly distend the small bowel lumen) was formerly utilized to study the mucosal surface of the small bowel lumen, this procedure has been largely replaced by video capsule endoscopy (VCE). Similarly, small bowel enteroscopy is far less commonly utilized with the advent of VCE.

For proximal jejunal lesions that cannot be visualized by routine EGD, “push” enteroscopy utilizes a pediatric colonoscope for direct examination of the lumen of the proximal 2–3 ft of small bowel.<sup>14</sup> Formerly utilized, Sonde “pull” small bowel enteroscopy, which relied on peristalsis to passively pull an enteroscope with a wide-angle lens into the distal ileum or colon, is now a procedure of only historical interest.

Intraoperative enteroscopy allows a much more complete evaluation of the small bowel. It is of value in detection of occult bleeding from the small bowel but is rarely utilized for the diagnosis of small bowel tumors, for most can usually be readily identified by careful palpation or visualization of the bowel once operation is pursued.

VCE is now widely employed in the diagnosis of small bowel tumors in patients with otherwise negative diagnostic studies. The device is an ingestible 11- × 26-mm capsule, swallowed by the patient, that contains a miniature video camera, light source, battery, and transmitter that sends images (up to 50,000 overall) to a recording device worn by the patient.<sup>15</sup> Currently the device does not have the capacity for biopsies or for precise localization of lesions, although such capability is in development. The device can be very useful in identifying lesions within the lumen of the small bowel (Fig. 30-2).



**FIGURE 30-2** Video capsule endoscopy (VCE) image of the adenocarcinoma.

The major complication of VCE is capsule retention, which is reported in 5% of cases, although the rate of requirement for surgical retrieval is less than 1%.<sup>16</sup>

While a number of small intestinal tumors are metabolically active and express hormones, somatostatin scintigraphy (octreotide scanning) is of limited use in detection of primary small bowel carcinoids or other neuroendocrine tumors. Positron emission tomography (PET) scanning also has limited utility in providing a discriminate diagnosis, as there is significant overlap between benign and malignant conditions. While diagnostic methods continue to improve, many patients with small bowel neoplasms still have initial presentation as a surgical emergency, and more than half of patients with malignant disease have metastatic spread at the time of operation.

## BENIGN TUMORS OF THE SMALL INTESTINE

Although accounting for 30–50% of primary neoplasms of the small bowel, benign tumors are poorly characterized. Half the patients with benign tumors are symptom free, and most will be diagnosed at the time of presentation with a surgical emergency such as obstruction, gastrointestinal hemorrhage, or perforation. Gastrointestinal bleeding is the most common presenting complication, presumably a consequence of spontaneous necrosis when the benign lesion outgrows the available blood supply.<sup>5</sup>

Once these lesions are diagnosed, surgical segmental intestinal resection is appropriate. While local excision via endoscopic mucosal resection or operative enterotomy with submucosal excision is feasible, it is generally not possible to grossly differentiate between benign and malignant lesions. Hence, transmural resection is preferred for indeterminate lesions. Open and laparoscopic approaches have been described.

### Brunner Gland Adenomas

Brunner gland adenomas are rare tumors of the proximal duodenum.<sup>17</sup> Originating in the Brunner glands of the duodenal submucosa that secrete alkaline bicarbonate-rich fluid and mucus, the pathogenesis of glandular hyperplasia and subsequent adenoma formation from this cell population remains unknown. Although Brunner gland adenomas have not been described to transform into carcinomas, endoscopic mucosal resection is advised to prevent complications, including acute and chronic bleeding.

### Adenomas

As in the colon, small bowel adenomas are histologically classified as tubular, tubulovillous, or villous. Most common in the periampullary region, they can develop throughout the

small bowel mucosa. Increased size correlates with malignant potential, and excision is advised when diagnosis is established, often as an incidental finding. Adenomas larger than 2 cm in diameter should be considered worrisome for malignancy. Large, periampullary duodenal adenomas may present with obstructive jaundice. In these cases ultrasound will reveal evidence of biliary obstruction, prompting upper endoscopy with endoscopic retrograde biliary and pancreatic duct evaluation (endoscopic retrograde cholangiopancreatography), which will reveal the presence of the ampullary lesion. Without these physical signs to direct the workup, duodenal adenomas are detected during evaluation of gastrointestinal blood loss or other abdominal complaints, with either contrast upper gastrointestinal series or EGD, which are equally sensitive in most series. Adenomas usually appear as intraluminal filling defects and may be pedunculated (Fig. 30-3). CT scan may differentiate adenoma from carcinoma, as carcinomas are often associated with bowel wall thickening. Endoscopic ultrasound is becoming essential in the evaluation of duodenal adenomas to evaluate depth and to determine if mucosal excision or surgical resection is more appropriate. Transduodenal local excision for small lesions is appropriate, while lesions larger than 3 cm in size have a high rate of associated malignancy and are most appropriately treated with either pancreas-sparing duodenectomy, or pancreaticoduodenectomy for larger lesions or periampullary tumors in suitable operative candidates.<sup>18</sup> Surgical series of resected ampullary adenoma report in situ or frank adenocarcinoma in 34–40%

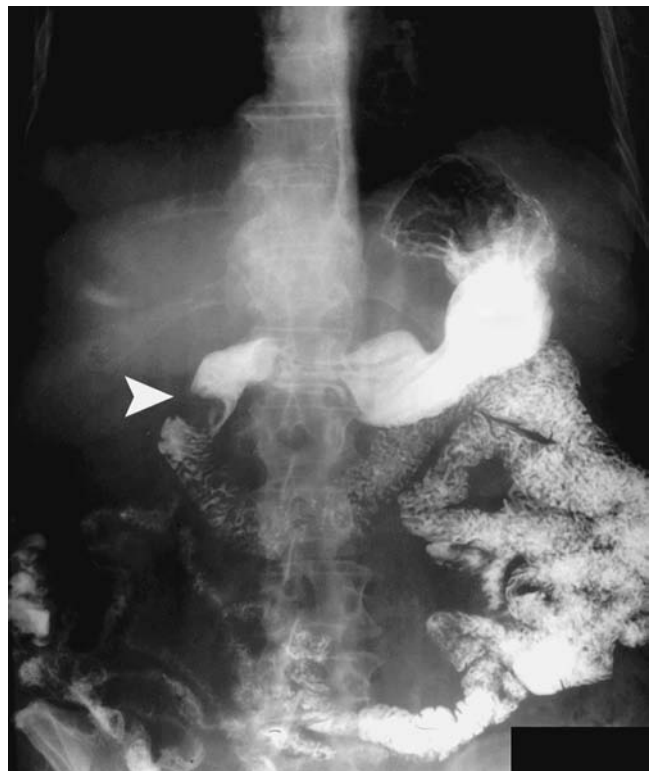

FIGURE 30-3 Filling defect in the duodenum caused by a large benign adenoma.



of patients. Local recurrence is common for periampullary adenomas treated with excision only: 40% at 10 years, 25% of which were malignant, in a recent retrospective series from the Mayo clinic. For those treated with excision only, annual surveillance with endoscopy is appropriate.<sup>19</sup>

## Lipomas

Lipomas of the gastrointestinal tract are typically identified as incidental findings on abdominal imaging. They rarely cause symptoms; although as polypoid, compressible intraluminal lesions, they may serve as lead points for intussusception. Lipomas are circumscribed lesions arising in the bowel wall appearing as fat density on CT imaging. Small tumors under 2 cm require no intervention, while larger lesions or growing lesions should be resected to rule out malignant liposarcoma.

## Hamartomas

The hamartoma is the characteristic lesion of Peutz-Jeghers syndrome, an autosomal dominant condition characterized by multiple gastrointestinal hamartomas and mucocutaneous pigmentation. The tumors are widely distributed throughout the bowel in affected individuals and in rare cases are associated with intussusception, bleeding, or obstruction. While malignant transformation has been described, this is a rare event. Given the broad distribution of the tumors, prophylactic excision is not feasible and surgical intervention is appropriate only to treat complications caused by the tumors.<sup>10</sup>

## Hemangiomas

Hemangiomas are rare congenital lesions of the small bowel. They appear to grow slowly and may become symptomatic in midlife, when acute or chronic bleeding may develop. Arising from the submucosal vascular plexuses, hemangiomas are usually solitary and not at risk for malignant transformation. Hemangiomas associated with bleeding should be locally excised or resected with a limited small bowel resection. Endoscopic sclerotherapy or angiographic embolization has also been reported as a treatment option depending on the size and position of the tumor.

## MALIGNANT NEOPLASMS

The small bowel can give rise to a number of different primary tumors and is also a site for metastasis from tumors of other origins. Primary malignancies include adenocarcinoma, GIST, carcinoid, lymphoma, and leiomyosarcoma, with rare reports of other lesions, including liposarcoma, myxoliposarcoma, and lymphangiosarcoma. Metastatic tumors may come from any other cancer, but the most common metastatic lesions are from melanoma and lymphomas.

Malignant tumors are much more likely to elicit symptoms than benign tumors, including abdominal pain, weight loss, anorexia, and acute or chronic blood loss. As a group, patients with malignant small bowel tumors present at advanced stages and have a poor prognosis.

Up to 30% of patients with small bowel malignancy develop a second primary tumor in another organ. For patients with GI carcinoid tumors, the incidence of second primaries is 50%. The second primary cancer may arise in any organ, but the most frequent second primary sites are the colorectum and breast.<sup>20,21</sup>

## ADENOCARCINOMA

### EPIDEMIOLOGY

Adenocarcinoma accounts for about 35% of small bowel tumors, making it the most common primary malignancy.<sup>7</sup> The frequency of small bowel tumors decreases along the length of the small bowel, with 80% located in the duodenum and proximal jejunum. Men are slightly more likely to develop adenocarcinoma than women. Risk factors for development of adenocarcinoma include polyposis syndromes, Crohn's disease, and celiac disease.

### CLINICAL PRESENTATION

Clinical presentation is dictated by the size and position of the tumor. Large tumors form the classic circumferential annular “apple core” constriction leading to obstruction with symptoms of anorexia, vomiting, and crampy pain (Fig. 30-4).

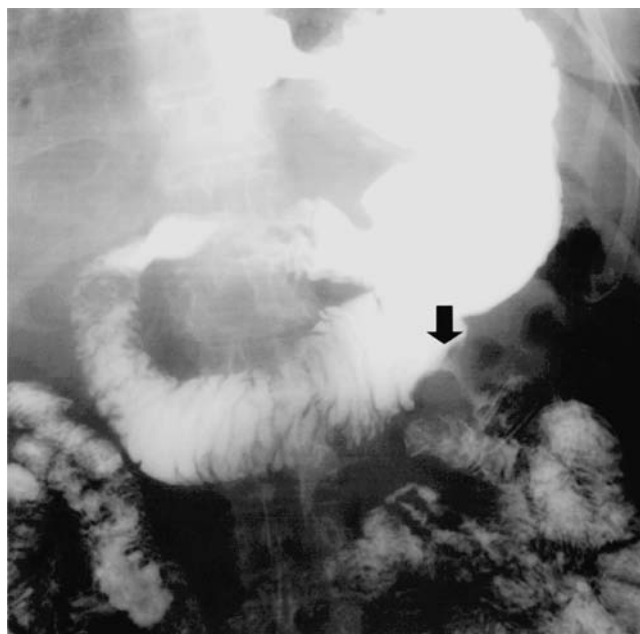

FIGURE 30-4 “Apple core” constricting adenocarcinoma of the proximal jejunum causing proximal partial bowel obstruction.

Periampullary lesions may cause biliary obstruction with secondary jaundice. In absent advanced or strategically placed lesions with obstruction, the only complaint may be vague, persistent abdominal pain.

## DIAGNOSIS

For patients with advanced lesions, plain abdominal films may show gastric distention or proximal small bowel obstruction. For the jaundiced patient, ultrasound or abdominal CT or magnetic resonance cholangiopancreatography may demonstrate the duodenal mass and site of biliary obstruction. Upper gastrointestinal contrast studies or EGD have equal diagnostic rates of 85–90%, while EGD allows diagnostic tissue biopsy. CT reveals approximately 50% of small bowel adenocarcinomas, and the appearance is that of a heterogeneous infiltrating mass. Despite diagnostic strategies, preoperative diagnosis of cancers beyond the duodenum is achieved in only 20–50% of cases.

## MANAGEMENT

Surgical resection offers the only potential cure. Many patients have intra-abdominal metastases at initial surgery, with R0 resection (ie, no gross or microscopic disease left) achieved in only 50–65% of cases. Pancreaticoduodenectomy is appropriate for proximal duodenal tumors. In the third and fourth portions of the duodenum and in the mesenteric small bowel, a segmental resection with lymphadenectomy should be performed. Palliative procedures to relieve obstruction or control hemorrhage should be completed at the time of exploration for patients with metastatic disease. Endoscopic expandable stents (Wall type) may be the best strategy to palliate proximal gastrointestinal obstruction from recurrent or metastatic disease. Gastrojejunal bypass or gastrostomy tubes may be of palliative value for decompression or nutritional support in patients with carcinomatosis or unresectable disease.

## STAGING AND PROGNOSIS

The American Joint Committee on Cancer staging system applies to small bowel adenocarcinoma.<sup>22</sup> The tumor (T) classification describes depth of invasion with T1 and T2 within the bowel wall and T3 and T4 lesions penetrating the bowel wall. The node (N) classification is defined by the presence or absence of lymph node metastases, and distant metastases are classified by M. Most patients present with stage III (lymph node involvement) or IV disease (distant metastases), which carry a poor prognosis.

The most significant prognostic factor is lymph node metastases, with poor survival linked to node-positive disease. Likely because of limited reported experience, the primary tumor features, including the degree of differentiation, do not appear to impact survival. A recent retrospective analysis showed that positive margins, extramural venous spread, positive lymph nodes, and a history of Crohn's disease are associated with poor prognosis.<sup>6</sup>

Adjuvant therapies including chemotherapy and/or radiation therapy have not demonstrated efficacy, although clinical trials are ongoing.<sup>20</sup>

## Non-Hodgkin's Lymphoma

The gastrointestinal tract is the most common extranodal site for development of non-Hodgkin's lymphoma (NHL), comprising approximately 20% of all cases of NHL. Most GI lymphomas arise in the stomach (60%), followed by the small bowel (30%), and then in the colon. Most small bowel lymphomas are distributed in the jejunum and ileum reflecting the distribution of lymphoid tissue in the bowel. Diagnostic criteria for primary GI NHL include the absence of superficial adenopathy on physical examination, absence of mediastinal adenopathy by chest imaging, normal peripheral blood cell counts, and absence of splenic or hepatic involvement. At surgery, disease must be restricted to the primary tumor with mesenteric lymph node involvement.<sup>23</sup>

The majority of cases of primary intestinal NHL are B-cell type with T-cell lymphoma comprising only 10–25%. Low-grade lymphomas derived from mucosal-associated lymphoid tissue (MALT) typically arise in the stomach in association with *Helicobacter pylori* infection. These tumors may regress with treatment of this infection.<sup>24</sup> T-cell lymphomas tend to have a worse prognosis than B-cell tumors.

## CLINICAL PRESENTATION

The majority of patients present with nonspecific abdominal complaints. Malabsorption, obstruction, or palpable mass may be present. Although rare, small intestinal lymphomas may present with perforation.

## DIAGNOSIS

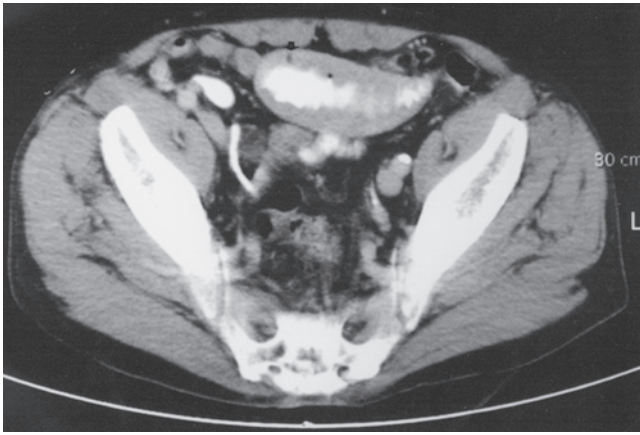
Lymphomas may grow to large size before clinical symptoms present. Most small bowel lymphomas will be demonstrable on CT scan as a mass, bowel wall thickening, displacement of adjacent organs, or luminal obstruction (Fig. 30-5). Multiple lesions are present in 10–25% of patients. Tissue diagnosis requires biopsy of the submucosal lesion by endoscopy or CT-guided biopsy.

## STAGING AND PROGNOSIS

Staging is based on site involvement as outlined in Table 30-1. Like tumors elsewhere in the small intestine, most patients present with stage III or IV disease. Fewer than 30% of patients have surgically resectable tumors and prognosis, although improving with new chemotherapy regimens, is poor.<sup>22</sup>

## TREATMENT

With no randomized series and small numbers of cases at single institutions, the optimal treatment of GI NHL remains



**FIGURE 30-5** Thickening of the bowel wall on abdominal CT scan characteristic of lymphoma.

controversial. Most agree that surgical resection of isolated small bowel lymphoma for local control and prevention of perforation and bleeding are the cornerstones of treatment. For more extensive gastrointestinal lymphoma, there is no evidence-based consensus on optimal management, although a variety of chemotherapeutic regimens have been utilized.<sup>23,24</sup>

### TABLE 30-1: STAGING FOR LYMPHOMA

Stage I	Involvement of a single lymph node region; or localized involvement of a single extralymphatic organ or site in the absence of any lymph node involvement
Stage II	Involvement of two or more lymph node regions on the same side of the diaphragm; or localized involvement of a single extralymphatic organ or site in association with regional lymph node involvement, with or without involvement of other lymph node regions on the same side of the diaphragm
Stage III	Involvement of lymph node regions on both sides of the diaphragm, which also may be accompanied by extralymphatic extension in association with adjacent lymph node involvement, or by involvement of the spleen, or both
Stage IV	Diffuse or disseminated involvement of one or more extralymphatic organs, with or without associated lymph node involvement; or isolated extralymphatic organ involvement in the absence of adjacent regional lymph node involvement, but in conjunction with disease in distant site(s); any involvement of the liver or bone marrow, or nodular involvement of the lungs

Data from American Joint Commission on Cancer. *Cancer Staging Handbook*. 6th ed. New York, NY: Springer; 2002.

## Carcinoid Tumors

Carcinoid tumors arise from the enterochromaffin cells at the base of the crypts of Lieberkühn. Enterochromaffin cells are capable of amine precursor uptake and decarboxylation (APUD) and tumors derived from these can secrete vasoactive peptides responsible for the carcinoid syndrome. Eighty percent of carcinoids arise in the gastrointestinal tract, 10% in the bronchus or lung, and others in rare sites, including the ovaries, testicles, pancreas, and kidneys. The appendix is the most common site in the GI tract for primary carcinoid tumors, followed by the small bowel. Thirty percent of GI carcinoids arise in the jejunum or ileum and have the most aggressive clinical features.

Carcinoids represent 5–35% of small bowel neoplasms; the mean age of presentation is 60 years with a slight male preponderance. Autopsy rates reveal an incidence of occult tumors approximately 2000 times that of the annual clinical incidence rate, indicating that the overwhelming majority never develop clinical findings.<sup>24,25</sup>

### CLINICAL PRESENTATION AND DIAGNOSIS

Most carcinoids grow slowly and have insidious clinical manifestations; in hindsight, symptoms may be present for 2–20 years prior to diagnosis. Carcinoid syndrome secondary to metastatic disease is the presenting sign in 40% of patients. Rarely, intestinal necrosis secondary to desmoplastic occlusion of the mesenteric vessels may develop, leading to initial presentation as a surgical emergency.

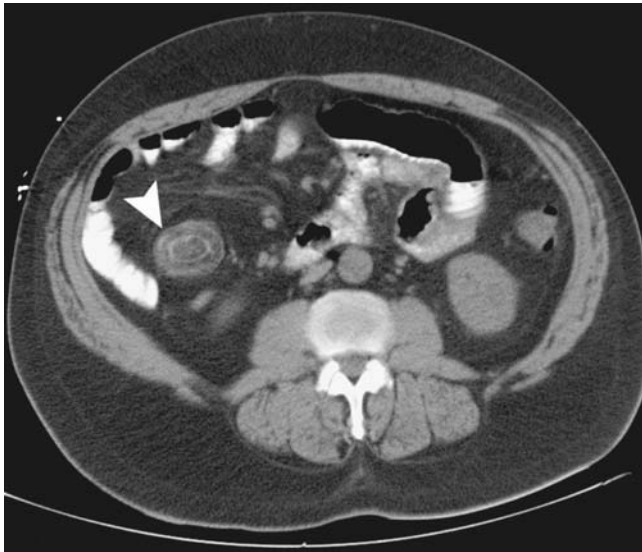
The most common presenting symptom for patients with small bowel carcinoid is abdominal pain. The polypoid lesions serve as a lead point for intussusception characterized by intermittent symptoms and signs of obstruction. Abdominal films often demonstrate a distal small bowel obstruction, and the CT findings of intussusception are distinctive, demonstrating a multilayer ringed structure in the ileocolic region (Fig. 30-6).

Appendiceal carcinoids are typically solitary lesions. However, for carcinoids arising in other areas of the gut, multiple tumors are observed in 30–40% of patients.<sup>26</sup> In addition, 30–50% of small bowel carcinoids are associated with second primary malignancies, most frequently of the breast and colon. Gastrointestinal carcinoids have the capacity to elicit a marked desmoplastic reaction in the mesentery of the small bowel. The fibrotic reaction can cause sclerosis of mesenteric vessels, leading to kinking of the bowel or intestinal ischemia and necrosis. The fibrosis affects not only peritumoral tissues, but distant tissues in the heart and lungs and is attributed to the humoral products of the tumors, although the specific factors are unknown.<sup>27,28</sup>

### STAGING AND PROGNOSIS

Appendiceal carcinoids, even at a small size, may cause appendicitis due to luminal compression; hence, early diagnosis of appendiceal carcinoid is common. In contrast, small bowel carcinoids exhibit a more aggressive phenotype and are





**FIGURE 30-6** Concentric rings in the soft tissue mass in the right lower quadrant reveal an ileocolic intussusception. An ileal carcinoid tumor was the lead point.

frequently associated with lymph node spread and hepatic metastasis at initial presentation. Tumor size is proportional to the risk for metastatic spread. For jejunoileal carcinoids smaller than 1 cm, there is a 20–30% incidence of nodal and hepatic spread. Tumors 1–2 cm in size have nodal spread in 60–80% and hepatic disease in 20%. The rate of nodal and hepatic metastasis for tumors larger than 2 cm is greater than 80% and 40–50%, respectively.<sup>25</sup> Only very small jejunoileal carcinoid tumors, those less than 1 cm, can be treated with local excision. All others should be treated with segmental bowel and mesenteric resection.<sup>29</sup>

## CARCINOID SYNDROME

Carcinoid syndrome refers to vasomotor, gastrointestinal, and cardiac manifestations induced by systemic circulation of peptides produced by carcinoid tumors. The APUD cells of carcinoid tumors can produce vasoactive products, including serotonin, histamine, kallikrein, bradykinin, and prostaglandins, although the specific mediator or mediators of the syndrome remain unknown. Carcinoid syndrome is confirmed by finding elevated 24-hour 5-hydroxyindoleacetic acid (5-HIAA) urinary excretion, the primary stable metabolite of serotonin.

Attacks are characterized by intense flushing and tachycardia. Watery diarrhea, at times explosive and associated with cramping, may occur in some patients. Attacks may be spontaneous or precipitated by stress, alcohol, a large meal, or sexual intercourse. Flushing, a 5- to 10-minute sensation of heat associated with facial and truncal erythema, is the most common finding and affects approximately 80% of patients. Diarrhea occurs in most patients and is likely related to serotonin release, as serotonin antagonists can effectively treat this symptom.

Abdominal cramps and malabsorption may occur. Cardiac manifestations are present in 60–70% of patients with advanced disease, due to tricuspid and pulmonary valve endocardial fibrosis, possibly secondary to high levels of 5-HIAA. As the disease progresses, the fibrotic plaque stiffens, leading eventually to right heart failure.

Carcinoid syndrome is due to metastatic disease in either the liver or retroperitoneum. Monoamine oxidase in the liver metabolizes serotonin to metabolites without vasomotor activity, one of the major effector hormones. Carcinoid syndrome occurs when metabolically active tumor is present in a site without portal drainage, such as a bronchial carcinoid or retroperitoneal tumor, or when hepatic metastatic tumor burden exceeds the capacity of hepatic monoamine oxidase to metabolize serotonin. Patients with gastrointestinal carcinoids that drain into the portal circulation must have metastatic disease prior to the development of the syndrome.

Management of patients with carcinoid syndrome due to metastatic hepatic tumor burden is optimized by utilization of surgical, imaging-guided interventional procedures and medical therapies. Given the relatively slow growth of carcinoid tumors, including metastatic disease, surgical debulking of extensive hepatic disease or formal hepatic resection for resectable metastases can improve symptoms and prolong life. Five- and 10-year survival for patients with residual abdominal tumor and hepatic metastases approaches 60%. While in general the initial surgery for resection of carcinoid tumor burden, including hepatic metastases, should attempt to debulk as much tumor as possible, the procedure must be planned to avoid catastrophic injuries such as those to the superior mesenteric vessels that could lead to short gut syndrome.<sup>30</sup> Hepatic artery embolization or radiofrequency ablation may be more appropriate for widespread hepatic metastases and can give marked symptomatic relief and durable tumor control.<sup>31</sup>

Medical therapy is based on somatostatin analogues (octreotide), including short- and long-acting peptides for relief of carcinoid syndrome symptoms. Carcinoid tumors express somatostatin receptors, and the somatostatin analogues inhibit vasoactive peptide release from carcinoid tumors. Palliation of symptoms is effective in 90% of patients with octreotide. Some studies have demonstrated a tumor-static or tumor reduction effect after the administration of somatostatin, although these latter findings have not been consistently reproduced. Efficacy of treatment can be documented by following excretion of the tumor marker 5-HIAA.

Chemotherapeutic agents for the treatment of metastatic carcinoid tumor include doxorubicin, 5-fluorouracil, dacarbazine, and interferon- $\alpha$ , with response rates of approximately 20%. Combination protocols most often utilize streptozotocin and 5-fluorouracil.

Preliminary reports on the use of targeted radiotherapeutics have been presented. Somatostatin analogues bind to somatostatin receptors on carcinoid tumors with high affinity. After binding is done, the ligand-receptor complex is internalized. This internalization has led to the development of “smart bombs”—radiolabeled somatostatin analogues that

theoretically deliver radiation specifically to carcinoid cells. <sup>111</sup>Indium-labeled pentetreotide demonstrated an enhanced tumor regression response compared to unlabeled analogue in one study.<sup>32</sup>

## Gastrointestinal Stromal Tumors

Although gastrointestinal stromal tumors (GIST) are the most common nonepithelial tumors of the small bowel, they are in fact rare tumors of the GI tract, representing only 0.2% of all GI tumors. Approximately 25% of GIST arise in the small bowel, with 50% gastric, 15% rectal, and 10% colonic in origin.<sup>33</sup> Men and women are equally at risk and peak incidence occurs in patients aged between 50 and 70 years. GIST tumors arise from the interstitial cell of Cajal, the pacemaker cell of the GI tract intercalated between the intramural neurons and the smooth muscle cells. The molecular diagnostic feature of GIST is the presence of activating c-kit mutations, a transmembrane receptor tyrosine kinase involved in the regulation of cellular proliferation, apoptosis, and differentiation. Over 95% of GIST express kit (CD117) mutations, a molecular marker that distinguishes them from histologically similar mesenchymal tumors of the small bowel, including leiomyomas, leiomyosarcoma, schwannomas, and others.<sup>34</sup> Retrospective molecular analysis of mesenchymal tumors has led to reclassification of up to 70% small bowel tumors as GIST that had previously been classified as a variety of mesenchymal tumors.<sup>35</sup>

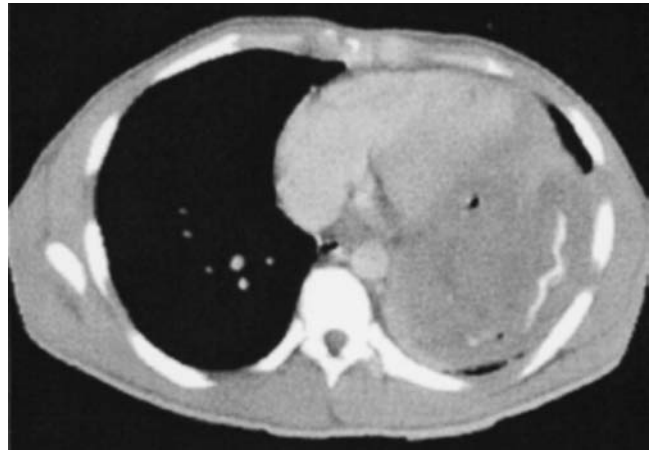GISTs are characterized by indolent clinical symptoms, including vague abdominal pain, weight loss, and occult gastrointestinal bleeding. Of all small bowel tumors, GISTs often grow to a large size prior to surgical presentation. They tend to grow insidiously as extraluminal masses from their submucosal origin in a noninvasive manner, characteristically pushing adjacent organs away from the expanding mass. Gastrointestinal hemorrhage may develop in patients with necrotic GIST in communication with the bowel lumen.

Given the propensity of GIST to grow to a large size prior to diagnosis, CT scan is most likely to be the initial positive test. A characteristic finding is the presence of a large space-occupying mass, often with evidence of central necrosis and compression of adjacent organs and calcifications (Fig. 30-7).

Regardless of size, all GIST tumors should be considered to be malignant.<sup>33</sup> Malignant potential is determined by two major criteria: tumor size and mitotic rate. Biologically aggressive tumors are large tumors with a high mitotic index, while tumors with benign features are small and exhibit a low mitotic index. Tumors are thus classified into very low- to high-risk for malignant potential, a classification that has prognostic significance.

### TREATMENT

Surgery is the primary therapeutic option with the goal being complete resection. At operation, wide local excision of the primary tumor to achieve gross negative margins with



**FIGURE 30-7** Large gastrointestinal stromal tumor (GIST) arising from the stomach in the left upper quadrant. The diaphragm and the spleen were invaded by the tumor.

incontinuity resection of adherent organs is appropriate to attain curative resection. Lymph node metastasis is rare, negating the need for wide mesenteric resection. Wedge resection of gastric lesions of amenable shape and position in the gastric wall provides equivalent outcomes to partial gastrectomy without the negative side effects of partial gastrectomy.

### MOLECULAR THERAPEUTICS AND GISTS.

Given the central role of activating mutations in the tyrosine kinases kit and more recently platelet-derived growth factor receptor alpha (PDGFRA) in the pathogenesis of GIST,<sup>34</sup> this tumor has served as a prototype for molecular therapeutic drug development. Activation of kit leads to phosphorylation of a receptor substrate protein, initiating an intracellular phosphorylation cascade leading to nuclear activation of transcription events, resulting in cell proliferation and survival. The discovery of a drug that inactivates kit with a safe therapeutic margin has revolutionized the treatment of metastatic GIST. Imatinib mesylate is a small molecule that occupies the adenosine triphosphate (ATP)-binding pocket of the kit kinase domain, blocking phosphorylation of the receptor and intracellular signaling. This binding arrests cellular proliferation and survival signaling.

Clinical use of imatinib is now routine in the management of GIST. This oral agent is well tolerated and highly effective for patients with metastatic GIST. While complete regression of tumor is rare, partial regression of disease and arrest of progression of disease can be achieved for durable intervals with continuous treatment in up to 80% of patients. Efficacy of treatment can be predicted and followed using fluorodeoxyglucose-positron emission tomography scanning; these highly biologically active tumors will become metabolically silent with imatinib therapy in those patients with responsive tumors. Emergence of resistant clones within tumors has been recognized with prolonged use of imatinib. Newer receptor

tyrosine kinase inhibitors, including sunitinib malate, have demonstrated efficacy for patients with tumor recurrence and resistance to imatinib with increased progression-free survival and overall survival.<sup>36,37</sup>

Neoadjuvant use of imatinib has been shown to result in a 70% response rate; although based on current available evidence, it is still unclear if preoperative therapy for GIST results in a clinically significant effect, leading to increased resectability or enhanced long-term survival.<sup>38</sup> The efficacy of imatinib in the adjuvant setting has been evaluated in the ACOSOG Z9001 (American College of Surgeons Clinical Oncology Group Z9001) trial, finding improved disease-free survival for patients with tumors greater than 3 cm who received imatinib. For these patients, imatinib is indicated for life. Although overall survival advantage was not achieved in this trial, adjuvant trials in North America and Europe continue.

## Metastatic Lesions to the Small Bowel

While metastases to the small bowel are rare as a group, they are in fact more common than primary small bowel neoplasms.

Metastatic spread can occur by direct invasion, hematogenous spread, or intraperitoneal seeding. Colon and pancreatic cancers are the most common primary sites for direct invasion. Hematogenous metastases spread most frequently from lung and breast carcinoma or melanoma. Peritoneal seeding may arise from any intra-abdominal malignancy including gastric, hepatic, ovarian, appendiceal, and colonic primary tumors.<sup>39</sup>

CT scan may identify metastatic lesions or reveal sites of partial or complete luminal obstruction. Metastases can be identified as bowel wall thickening or mesenteric masses. For small lesions, CT scan may be negative, while small bowel follow-through study may reveal an irregular luminal filling defect. Carcinomatosis is frequently not specifically identifiable on imaging studies, although PET-CT is useful for identification of small bowel metastases in some tumor types.

Optimal palliative management is based on clinical criteria. Segmental intestinal resection or bypass to relieve hemorrhage, obstruction, or pain is indicated except in the most terminal stages of disease. While cases of prolonged survival after intestinal resection of solitary metastases have been reported, progression of metastatic disease is more common.

Management of patients with carcinomatosis, regardless of tumor origin, remains challenging. Endoscopic luminal stents for obstructing duodenal lesions may offer short-term palliation, while intestinal bypasses and decompressive gastrostomy tubes are indicated for patients with advanced or more distal disease to enhance palliative care.

## REFERENCES

- Ciresi DL, Scholten DJ. The continuing clinical dilemma of primary tumors of the small intestine. *Am Surg.* 1995;61:698–703.
- Landis SH, Murray T, Bolden S, et al. Cancer statistics, 1999. *CA Cancer J Clin.* 1999;49:8–31.
- Howe JR, Karnell LH, Menck HR, et al. Adenocarcinoma of the small bowel: review of the National Cancer Data Base, 1985–1995. *Cancer.* 1999;86:2693–2706.
- Matsuo S, Eto T, Tsunoda T, et al. Small bowel tumors: an analysis of tumor-like lesions, benign and malignant neoplasms. *Eur J Surg Oncol.* 1994;20:47–51.
- Minardi AJ, Jr, Zibari GB, Aultman DF, et al. Small-bowel tumors. *J Am Coll Surg.* 1998;186:664–668.
- Sigel JE, Petras RE, Lashner BA, et al. Intestinal adeno-carcinoma in Crohn's disease: a report of 30 cases with a focus on coexisting dysplasia. *Am J Surg Pathol.* 1999;23:651–655.
- Abrahams NA, Halverson A, Fazio VW, et al. Adenocarcinoma of the small bowel: a study of 37 cases with emphasis on histologic prognostic factors. *Dis Colon Rectum.* 2002;45:1496–1502.
- O'Boyle CJ, Kerin MJ, Feeley K, et al. Primary small intestinal tumors: increased incidence of lymphoma and improved survival. *Ann R Coll Surg Engl.* 1998;80:332–334.
- Green PH, Fleischauer AT, Bhagat G, et al. Risk of malignancy in patients with celiac disease. *Am J Med.* 2003;115:191–195.
- Dong K, Li B. Peutz-Jeghers syndrome: case reports and update on diagnosis and treatment. *Chin J Dig Dis.* 2004; 5:160–164.
- Crump M, Gospodarowicz M, Shepherd FA. Lymphoma of the gastrointestinal tract. *Semin Oncol.* 1999;26:324–337.
- Maglinte DDT, Reyes BL. Small bowel cancer: radiologic diagnosis. *Radiol Clin North Am.* 1997;35:361–380.
- Buckley JA, Jones B, Fishman EK. Small bowel cancer; imaging features and staging. *Radiol Clin North Am.* 1997;35:381–402.
- Waye JD. Small-bowel endoscopy. *Endoscopy.* 2003;35:15–21.
- Swain P. Wireless capsule endoscopy. *Gut.* 2003;52(suppl IV): iv48–iv50.
- Cave DR. Wireless video capsule endoscopy. *Clin Perspect Gastroenterol.* 2002;5:203–207.
- Adeonigbagbe O, Lee C, Karowe M, et al. A Brunner's gland adenoma as a cause of anemia. *J Clin Gastroenterol.* 1999;29:193–196.
- Beger HG, Treitschke F, Gansange F, et al. Tumor of the ampulla of Vater. *Arch Surg.* 1999;134:526–532.
- Farnell MB, Sakorafas GH, Sarr MG, et al. Villous tumors of the duodenum: reappraisal of local vs. extended resection. *J Gastrointest Surg.* 2000;4:13–21; discussion 22–23.
- Cunningham JD, Aleali R, Aleali M, et al. Malignant small bowel neoplasms; histopathologic determinants of recurrence and survival. *Ann Surg.* 1997;225:300–306.
- Marcilla JAG, Bueno FS, Aquilar J, et al. Primary small bowel malignant tumors. *Eur J Surg Oncol.* 1994;20: 630–634.
- American Joint Committee on Cancer and TNM Committee of the International Union Against Cancer: Small intestine. In: Greene FL, Page DL, Fleming ID, et al, eds. *Handbook for the Staging of Cancer.* Philadelphia, PA: JB Lippincott; 2002:119–125.
- Cooper DL, Daria R, Salloum E. Primary gastrointestinal lymphomas. *Gastroenterologist.* 1996;4:54–64.
- Pandey M, Wadhwa MK, Patel HP, et al. Malignant lymphoma of the gastrointestinal tract. *Eur J Surg Oncol.* 1999;25:164–167.
- Memon MA, Nelson H. Gastrointestinal carcinoid tumors: current management strategies. *Dis Colon Rectum.* 1997;40:1101–1118.
- Yantiss R, Odze R, Farraye F, et al. Solitary versus multiple carcinoid tumors of the ileum: a clinical and pathological review of 68 cases. *Am J Surg Pathol.* 2003;27:811–817.
- Modlin IM, Shapiro MD, Kidd M. Carcinoid tumors and fibrosis: An association with no explanation. *Am J Gastroenterol.* 2004;99: 2466–2478.
- Sheth S, Horton K, Garland M, et al. Mesenteric neoplasms: CT appearance of primary and secondary tumors and differential diagnosis. *Radiographics.* 2003;23:457–473.
- Rothmund M, Kisker O. Surgical treatment of carcinoid tumors of the small bowel, appendix, colon and rectum. *Digestion.* 1994;55: 86–91.
- Schell S, Camp E, Caridi J, et al. Hepatic artery embolization for control of symptoms, octreotide requirements, and tumor progression in metastatic carcinoid tumors. *J Gastrointest Surg.* 2002;6:664–670.
- Roche A, Girish B, de Baerre, et al. Trans-catheter arterial chemoembolization as first-line treatment for hepatic metastases from endocrine tumors. *Eur Radiol.* 2003;13:136–140.



32. Anthony L, Woltering EA, Espenan GD, et al. Indium-111-pentetreotide prolongs survival in gastroenteropancreatic malignancies. *Semin Nucl Med.* 2002;32:123.
33. Miettinen M, Lasota J. Gastrointestinal stromal tumors—definition, clinical, histological, immunohistochemical, and molecular genetic features and differential diagnosis. *Virchows Arch.* 2001;438:1–12.
34. Heinrich MC, Corless CL, Duensing A, et al. PDGFRA activating mutations in gastrointestinal stromal tumors. *Science.* 2003;299:708–710.
35. Fletcher CD, Berman JJ, Corless C, et al. Diagnosis of gastrointestinal stromal tumors: a consensus approach. *Hum Pathol.* 2002;33:459–465.
36. Paz-Ares L, García del Muro X, Grande E, et al. Cost-effectiveness analysis of sunitinib in patients with metastatic and/or unresectable gastrointestinal stroma tumours (GIST) after progression or intolerance with imatinib. *Clin Transl Oncol.* 2008;10(12):831–839.
37. von Mehren M. New therapeutic strategies for soft tissue sarcomas. *Curr Treat Options Oncol.* 2003;4:441–451.
38. McAuliffe JC, Hunt KK, Lazar AJ, et al. A randomized, phase II study of preoperative plus postoperative imatinib in GIST: evidence of rapid radiographic response and temporal induction of tumor cell apoptosis. *Ann Surg Oncol.* 2009;16:910–919.
39. Ciplone G, Santarelli G, Quitadamo S, et al. Small bowel metastases from lung cancer. *Chir Ital.* 2004;56:639–648.

*This page intentionally left blank*

# APPENDIX, MECKEL'S, AND OTHER SMALL BOWEL DIVERTICULA

William H. Peranteau • Douglas S. Smink

## HISTORY

The first descriptions of the appendix date to the 16th century.<sup>1-3</sup> Although sketched in the anatomic notebooks of Leonardo da Vinci around 1500, the appendix was not formally described until 1524 by da Capri<sup>4</sup> and 1543 by Vesalius.<sup>5</sup> Perhaps the first description of a case of appendicitis was by Fernel in 1554,<sup>6</sup> in which a 7-year-old girl with diarrhea was treated with a large quince. Soon thereafter, she developed severe abdominal pain and died. Autopsy showed that the quince had obstructed the appendiceal lumen, resulting in appendiceal necrosis and perforation. For the next few centuries, such cases of appendicitis were typically diagnosed at autopsy.

Amyand is credited with the first appendectomy in 1736, when he operated on a boy with an enterocutaneous fistula within an inguinal hernia.<sup>7</sup> On exploration of the hernia sac, he discovered the appendix, which had been perforated by a pin resulting in a fecal fistula. As a result of his original description, an inguinal hernia containing the appendix carries Amyand's eponym to this day.<sup>8</sup> Nearly 150 years passed until Lawson Tait in London presented the first successful transabdominal appendectomy for gangrenous appendix in 1880.<sup>9</sup> Less than a decade later, in 1886, Reginald Fitz of Harvard Medical School first described the natural history of the inflamed appendix, coining the term "appendicitis."<sup>10</sup> In 1889, Charles McBurney of the Columbia College of Physicians and Surgeons in New York presented his series of cases of surgically treated appendicitis and in so doing described the anatomic landmark that now bears his name. McBurney's point is the location of maximal tenderness "very exactly between an inch and a half and two inches from the anterior spinous process of the ileum on a straight line drawn from that process to the umbilicus."<sup>11</sup> In the 1890s, Sir Frederick Treves of London Hospital advocated conservative management of acute appendicitis followed by appendectomy after the infection had subsided<sup>12</sup>; unfortunately, his youngest daughter developed perforated appendicitis and died from such treatment.

Numerous advances in the diagnosis and treatment of appendicitis have emerged in the past 125 years. Nonetheless, acute appendicitis continues to challenge surgeons to this day.

## ANATOMY

Embryologically, the appendix and cecum develop as out-pouchings of the caudal limb of the midgut loop in the 6th week of human development. By the 5th month, the appendix elongates into its vermiform shape. At birth, the appendix is located at the tip of the cecum, but, because of unequal elongation of the lateral wall of the cecum, the adult appendix typically originates from the posteromedial wall of the cecum, caudal to the ileocecal valve. The appendix averages 9 cm in length,<sup>3</sup> with its outside diameter ranging from 3 to 8 mm and its lumen ranging from 1 to 3 mm. The base of the appendix is consistently found by following the teniae coli of the colon to their confluence at the base of the cecum. The appendiceal tip, however, can vary significantly in location (Fig. 31-1). Although usually located in the right lower quadrant (RLQ) or pelvis, the tip can occasionally reside in the left lower or right upper quadrants (RUQ).

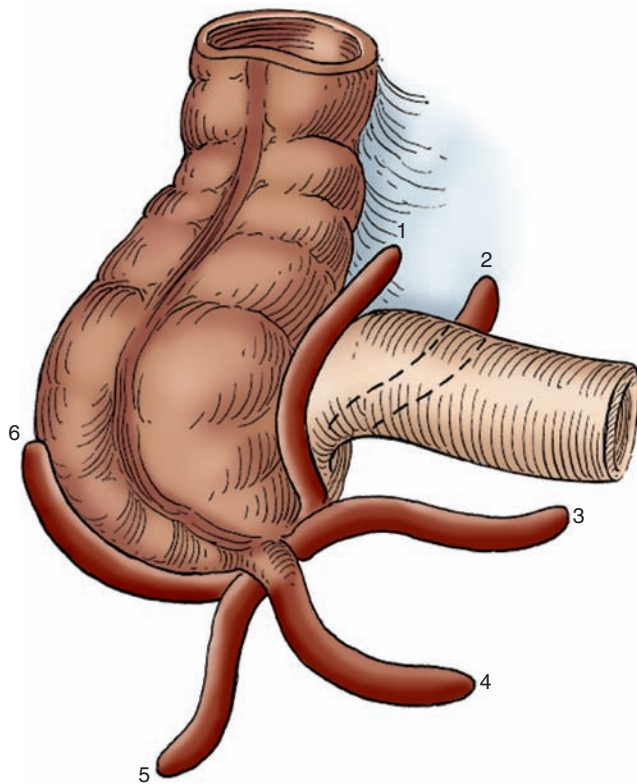
The arterial supply of the appendix comes from the appendicular branch of the ileocolic artery, which originates posterior to the terminal ileum and enters the mesoappendix near the base of the appendix (Fig. 31-2). Lymphatic drainage flows to lymph nodes along the ileocolic artery.

## ACUTE APPENDICITIS

### Epidemiology

Addiss and associates<sup>13</sup> estimated the incidence of acute appendicitis in the United States to be 11 cases per 10,000 population annually. The disease is slightly more common in



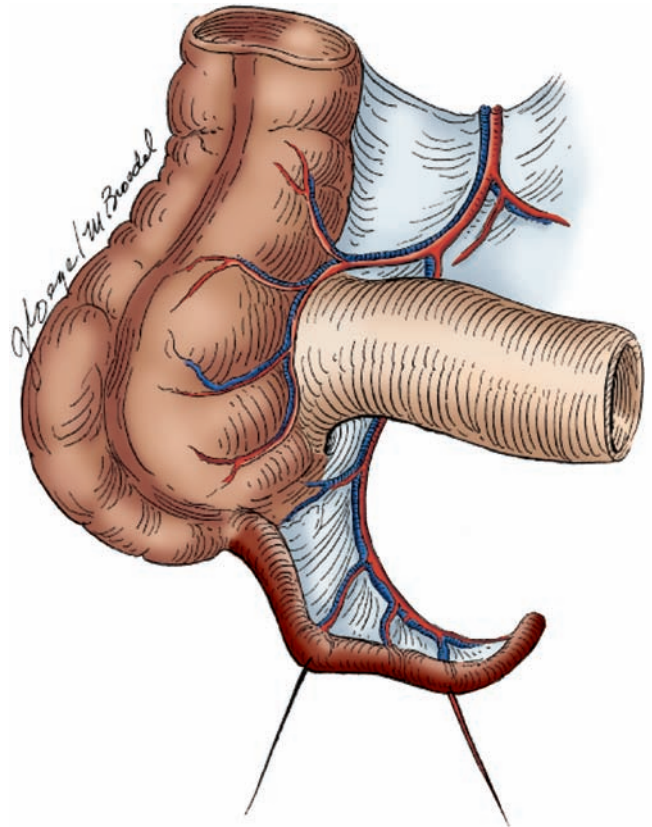


**FIGURE 31-1** Anatomic variation in the position of the appendix. (1) Preileal; (2) postileal; (3) promontoric; (4) pelvic; (5) subcecal; (6) paracolic or prececal. (Redrawn from Wakeley CP. The position on the vermiform appendix as ascertained by analysis of 10,000 cases. *J Anat.* 1933;67:277. After Waldron.)

males, with a male: female ratio of 1.4:1. In a lifetime, 8.6% of males and 6.7% of females can be expected to develop acute appendicitis. Young age is a risk factor, as nearly 70% of patients with acute appendicitis are younger than 30 years. The highest incidence of appendicitis in males is in the 10- to 14-year-old age group (27.6 cases per 10,000 population), while the highest female incidence is in the 15- to 19-year-old age group (20.5 cases per 10,000 population). Patients at extremes of age are more likely to develop perforated appendicitis. Overall, perforation was present in 19.2% of cases of acute appendicitis. This number was significantly higher, however, in patients younger than 5 and older than 65 years. Although less common in people older than 65 years, acute appendicitis in the elderly progresses to perforation more than 50% of the time.<sup>13</sup>

## Etiology and Pathophysiology

Appendicitis, diverticular disease, and colorectal carcinoma have been shown to be diseases of developed civilizations. Burkitt<sup>14</sup> found an increased incidence of appendicitis in Western countries compared to Africa, as well as in wealthy, urban communities compared to rural areas. He attributed



**FIGURE 31-2** The appendix and its arterial supply.

this to the Western diet, which is low in dietary fiber and high in refined sugars and fat, and postulated that low-fiber diets lead to less bulky bowel contents, prolonged intestinal transit time, and increased intraluminal pressure. Burkitt theorized that the combination of firm stool leading to appendiceal obstruction and increased intraluminal pressure causing bacterial translocation across the bowel wall resulted in appendicitis. In examining appendixes removed for reasons other than appendicitis, he found fecaliths to be more prevalent in Canadian (32%) than in South African (4%) adults. In a group of patients with appendicitis, fecaliths were more common in Canadians (52%) than in South Africans (23%).<sup>15</sup> He felt this was confirmation that appendiceal obstruction resulted in appendicitis. Of note, however, the majority of patients with appendicitis in his study did not have evidence of a fecalith.

Wangensteen extensively studied the structure and function of the appendix and the role of obstruction in appendicitis.<sup>16,17</sup> Based on anatomic studies, he postulated that mucosal folds and a sphincter-like orientation of muscle fibers at the appendiceal orifice make the appendix susceptible to obstruction. He proposed the following sequence of events to explain appendicitis: (1) Closed-loop obstruction is caused by a fecalith and swelling of the mucosal and submucosal lymphoid tissue at the base of the appendix; (2) intraluminal pressure rises as the appendiceal mucosa secretes fluid against the fixed

obstruction; (3) increased pressure in the appendiceal wall exceeds capillary pressure and causes mucosal ischemia; and (4) luminal bacterial overgrowth and translocation of bacteria across the appendiceal wall result in inflammation, edema, and ultimately necrosis. If the appendix is not removed, perforation can ensue.

Although appendiceal obstruction is widely accepted as the primary cause of appendicitis, evidence suggests that this may be only one of many possible etiologies. First, some patients with a fecalith have a histologically normal appendix, and the majority of patients with appendicitis show no evidence for a fecalith.<sup>15,18,19</sup> Arnbjornsson and Bengmark<sup>20</sup> studied at laparotomy the appendixes of patients with suspected appendicitis. They found the intraluminal pressure of the appendix prior to removal to be elevated in only 8 of 27 patients with nonperforated appendicitis. They found no signs of obstruction in the remaining patients with nonperforated appendicitis, as well as all patients with a normal appendix. Taken together, these studies imply that obstruction is but one of the possible etiologies of acute appendicitis.

## Presentation

Perhaps the most common surgically correctable cause of abdominal pain, the diagnosis of acute appendicitis remains difficult in many instances. Some of the signs and symptoms can be subtle to both the clinician and the patient and may not be present in all instances. Arriving at the correct diagnosis is essential, however, as a delay in diagnosis may allow progression to perforation and significantly increased morbidity and mortality. Incorrectly diagnosing a patient with appendicitis, although not catastrophic, often subjects the patient to an unnecessary operation.

The classic presentation of acute appendicitis begins with crampy, intermittent abdominal pain, thought to be due to obstruction of the appendiceal lumen. The pain may be either periumbilical or diffuse and difficult to localize. This is typically followed shortly thereafter with nausea; vomiting may or may not be present. If nausea and vomiting precede the pain, patients are likely to have another cause for their abdominal pain, such as gastroenteritis. Classically, the pain migrates to the right lower quadrant as transmural inflammation of the appendix leads to inflammation of the peritoneal lining of the right lower abdomen. This usually occurs within 12–24 hours of the onset of symptoms. The character of the pain also changes from dull and colicky to sharp and constant. Movement or Valsalva maneuver often worsens this pain, so that the patient typically desires to lie still; some patients describe pain with every bump in the car or ambulance ride to the hospital. Patients may report low-grade fever up to 101°F (38.3°C). Higher temperatures and shaking chills should again alert the surgeon to other diagnoses, including appendiceal perforation or nonappendiceal sources. When questioned, patients who have appendicitis commonly report anorexia; appendicitis is unlikely in those with a normal appetite.

The surgeon is constantly reminded that in practice, the classic presentation of acute appendicitis is not present in all patients. Patients may have none or only a few of the symptoms just described. For instance, they may not notice or recall the initial colicky pain. When the pain becomes constant, it may localize to other quadrants of the abdomen due to an alteration in appendiceal anatomy as in late pregnancy or malrotation. In patients with a retrocecal appendix, the pain may never localize until generalized peritonitis from perforated appendicitis occurs. Urinary or bowel frequency may be present due to appendiceal inflammation irritating the adjacent bladder or rectum. Because appendicitis is so common, a high index of suspicion for appendicitis is warranted in all patients with abdominal pain.

## Perforated Appendicitis

It is a commonly held belief that if left untreated, appendiceal inflammation will progress inevitably to necrosis, and ultimately to perforation. The time course of this progression varies among patients. In one study of the natural history of appendicitis, the authors questioned patients undergoing appendectomy for suspected appendicitis about their duration of symptoms.<sup>21</sup> Patients with nonperforated appendicitis reported an average of 22 hours of symptoms prior to presentation to the hospital, while patients with perforated appendicitis reported an average of 57 hours. However, 20% of cases of perforated appendicitis presented within 24 hours of the onset of symptoms; one of those patients had symptoms for only 11 hours. Although concern for perforation should be present when evaluating a patient with more than 24 hours of symptoms, the clinician must remember that perforation can develop more rapidly.

Some authors have questioned whether some perforations in acute appendicitis are attributable to delay in diagnosis after a patient seeks medical attention. Velanovich and Satava postulated a surgeon's misdiagnosis rate (the percentage of normal appendixes found at appendectomy) to be inversely related to the perforation rate (the percentage of perforated appendixes found at laparotomy).<sup>22</sup> They believed that surgeons are obliged to operate quickly when appendicitis is suspected, thus minimizing the likelihood of perforation in exchange for a higher rate of misdiagnosis. More recent studies suggest that this reasoning is flawed. Temple and colleagues showed that patients with perforated appendicitis were operated on more quickly than those with nonperforated appendicitis (6.5 vs 9 hours), but perforated patients had significantly longer prehospital symptoms (57 vs 22 hours).<sup>21</sup> These findings are confirmed by two other studies, both showing that longer duration of prehospital delay is the major contributor to perforation.<sup>23,24</sup> Perforation after presenting to surgical attention appears to be uncommon.

When acute appendicitis has progressed to appendiceal perforation, other symptoms may be present. Patients will often complain of two or more days of abdominal pain, but their duration of symptoms may be shorter, as previously

discussed. The pain usually localizes to the right lower quadrant if the perforation has been walled off by surrounding intra-abdominal structures including the omentum, but it may be diffuse if generalized peritonitis ensues. The pain may be so severe that patients do not remember the antecedent colicky pain. Patients with perforation often have rigors and high fevers to 102°F (38.9°C) or above. A history of poor oral intake and dehydration may also be present.

Most patients with perforated appendicitis present with symptoms related to the inflamed appendix itself or to a localized intraperitoneal abscess from perforation. Other more rare presentations do occur, however. These are most likely to occur in the very young and very old, who cannot express their symptoms and often present late in the course of their disease. For instance, abscesses can also form in the retroperitoneum due to perforation of a retrocecal appendix, or in the liver from hematogenous spread of infection through the portal venous system. An intraperitoneal abscess could fistulize to the skin, resulting in an enterocutaneous fistula. Pylephlebitis (septic portal vein thrombosis) presents with high fevers and jaundice and can be confused with cholangitis; it is a dreaded complication of acute appendicitis and carries a high mortality.<sup>25</sup> On occasion, patients will have bilious vomiting and obstipation due to a small bowel obstruction resulting from appendiceal perforation. Because appendicitis is so common, these rare presentations should alert the surgeon to the possibility of appendicitis.

## Diagnosis

### HISTORY AND PHYSICAL EXAMINATION

As always, the diagnosis begins with a thorough history and physical examination. The patient should be asked about the classic symptoms of appendicitis, but the surgeon should not be dissuaded by the absence of many of the symptoms. Many patients with acute appendicitis do not have a classic history. Because the differential diagnosis of appendicitis is extensive, patients should be queried about certain symptoms that may suggest an alternative diagnosis. Surgeons must also remember that a previous appendectomy does not definitively exclude the diagnosis of appendicitis, as “stump appendicitis” (appendicitis in the remaining appendiceal stump after appendectomy), although rare, has been described.<sup>26</sup>

On inspection, patients look mildly ill and may have slightly elevated temperature and pulse. They often lie still to avoid the peritoneal irritation caused by movement. The surgeon should systematically examine the entire abdomen, starting in the left upper quadrant away from the patient’s described pain. Maximal tenderness is typically in the right lower quadrant, at or near McBurney’s point, located one-third of the way from the anterior superior iliac spine to the umbilicus. This tenderness is often associated with localized muscle rigidity and signs of peritoneal inflammation, including rebound, shake, or tap tenderness. RLQ tenderness is most consistent of all signs of acute appendicitis<sup>27,28</sup>; its presence

should always raise the specter of appendicitis, even in the absence of other signs and symptoms. Because of the various anatomic locations of the appendix, however, it is possible for the tenderness to be in the right flank or right upper quadrant, the suprapubic region, or the left lower quadrant. Patients with a retrocecal or pelvic appendix may have no abdominal tenderness whatsoever. In such cases, rectal examination can be helpful to elicit right-sided pelvic tenderness.

Multiple signs can be detected on physical examination to contribute to the diagnosis of appendicitis. Rovsing’s sign, pain in the right lower quadrant on palpation of the left lower quadrant, results from localized peritoneal inflammation in the right lower quadrant. Psoas sign, pain with flexion of the leg at the right hip, can be seen with a retrocecal appendix due to inflammation adjacent to the psoas muscle. The obturator sign, pain with rotating the flexed right thigh internally, indicates inflammation adjacent to the obturator muscle in the pelvis.

In cases of perforated appendicitis, patients can look gravely ill, appearing flushed with dry mucous membranes and considerable elevations in temperature or pulse. If sepsis has developed, blood pressure can be depressed. If the perforation has been walled off by surrounding structures to create an abscess or phlegmon, a mass may be palpable in the right lower quadrant. If free intraperitoneal rupture has occurred, the patient can have signs of generalized peritonitis with diffuse rebound tenderness.

### LABORATORY STUDIES

Laboratory studies can be helpful in the diagnosis of appendicitis, but no single test is definitive. A white blood cell count (WBC) is perhaps the most useful laboratory test. Typically, the WBC is slightly elevated in nonperforated appendicitis but may be quite elevated in the presence of perforation. The clinician must remember, however, that the WBC can be normal in patients with acute appendicitis, particularly in early cases. Serial WBC measurements improve the diagnostic accuracy, with a rising value over time commonly seen in patients with appendicitis.<sup>29</sup> Urinalysis is performed to diagnose other potential causes for abdominal pain, specifically urinary tract infection and ureteral stone. Significant hematuria with colicky abdominal pain suggests ureterolithiasis, and testing directed at this diagnosis is indicated. A urinary tract infection, on the other hand, is not uncommon in patients with appendicitis. Its presence does not exclude the diagnosis of acute appendicitis, but it should be identified and treated. Although pyuria suggests urinary tract infection, it is not uncommon for the urinalysis in a patient with appendicitis to show a few white blood cells solely due to inflammation of the ureter by the adjacent appendix.

In certain patient populations, other laboratory tests are indicated. Measurement of serum liver enzymes and amylase can be helpful in diagnosing liver, gallbladder, or pancreatic disease in patients complaining of midabdominal or RUQ pain. In women of childbearing age, the urine  $\beta$ -human chorionic gonadotropin should be checked to alert the clinician



to the possibility of ectopic or concurrent pregnancy. Ectopic pregnancy is another cause of RLQ pain that demands emergent diagnosis and treatment. Concurrent pregnancy should be known before a patient with suspected appendicitis is subjected to ionizing radiation from imaging studies or to general anesthesia.

## DIAGNOSTIC SCORES

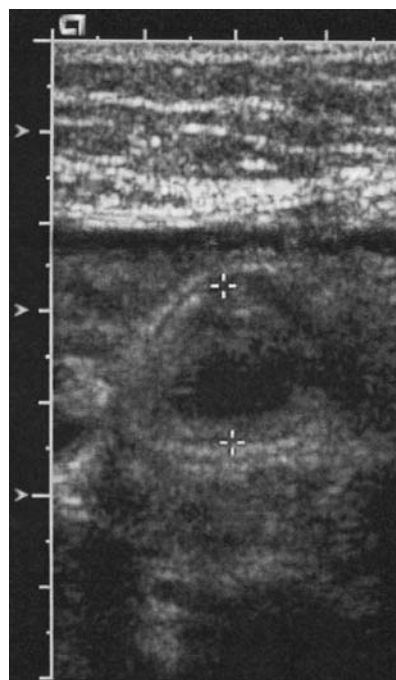
Diagnostic scoring systems have been developed in an attempt to improve the diagnostic accuracy of acute appendicitis.<sup>18,30</sup> The most prominent of those scores, developed by Alvarado,<sup>30</sup> was based on a retrospective analysis of 305 patients with abdominal pain suspicious for appendicitis. This scoring system gives points for symptoms (migration of pain, anorexia, and nausea), physical signs (RLQ tenderness, rebound tenderness, and pyrexia), and laboratory values (leukocytosis and a left shift). Although these scores can help guide clinical thinking, they do not markedly improve diagnostic accuracy.<sup>31</sup> With the recent improvement in imaging studies, these scores play a smaller role in diagnosis.

## IMAGING STUDIES

The potential imaging modalities for diagnosis of acute appendicitis include plain radiographs, ultrasound (US), and computed tomography (CT). Prior to the widespread use of modern imaging techniques, plain abdominal films were often obtained in patients with abdominal pain, and a right lower quadrant fecalith (or appendicolith) was considered pathognomonic for acute appendicitis. A number of studies question this teaching, however. Teicher and colleagues<sup>18</sup> reviewed the abdominal radiographs of 200 appendectomy patients—100 with pathologically proven appendicitis and 100 with a normal appendix. Of those with appendicitis, 10.5% had an appendicolith on x-ray, compared to 3.3% of those without appendicitis. An extensive review of appendectomy specimens at the Mayo Clinic<sup>19</sup> showed that fecaliths or appendiceal calculi were present in 9% of patients with nonperforated appendicitis and 21% of those with perforated appendicitis. Interestingly, fecaliths were also present in 7% of patients with suspected appendicitis who had a pathologically normal appendix and in 2% of patients who had an appendectomy for other reasons.

These studies show that fecaliths are not pathognomonic for appendicitis, as some patients with abdominal pain and a fecalith have a normal appendix. In addition, fecaliths are not common enough in patients with appendicitis to be used as a reliable sign. As a result, plain abdominal radiographs are neither helpful nor cost-effective and are not recommended for the diagnosis of acute appendicitis. Plain radiographs are indicated in elderly patients with severe abdominal pain, in whom a perforated viscus is included in the differential diagnosis. In this patient population, an upright chest x-ray can assess for the presence of free air.

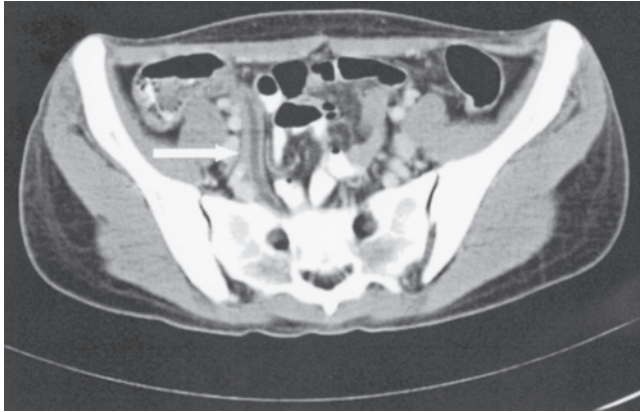
Abdominal ultrasonography is a popular imaging modality for acute appendicitis. Findings that suggest appendicitis include



**FIGURE 31-3** Appendiceal ultrasound showing distended, noncompressible appendix measuring 1.7 cm in transverse dimension (>0.6 cm is abnormal). (Used, with permission, from M. Stephen Ledbetter, MD, MPH, Brigham and Women's Hospital, Boston, MA.)

thickening of the appendiceal wall, loss of wall compressibility, increased echogenicity of the surrounding fat signifying inflammation, and loculated pericecal fluid (Fig. 31-3). The advantages of ultrasound include its widespread availability, as well as the avoidance of ionizing radiation and the side effects of intravenous contrast such as renal toxicity and allergic reactions. In addition, ultrasound (both abdominal and transvaginal) is particularly useful in assessing obstetric and gynecological causes of abdominal pain in women of childbearing age. Ultrasound is highly operator-dependent, however, and it is frequently unable to visualize the normal appendix.<sup>32</sup> A recent meta-analysis of 14 prospective studies showed ultrasound to have a sensitivity of 0.86 and a specificity of 0.81.<sup>33</sup>

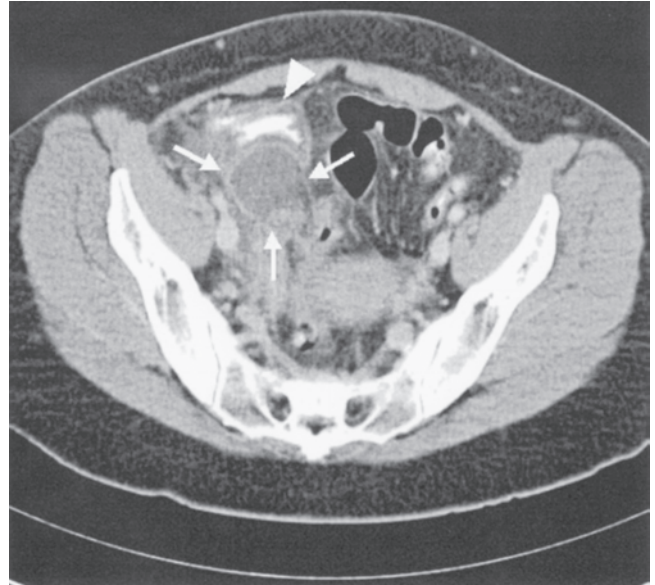
CT is yet another imaging modality for acute appendicitis. CT benefits from a high diagnostic accuracy for appendicitis<sup>33</sup> and visualization and diagnosis of many of the other causes of abdominal pain that can be confused with appendicitis. The radiographic findings of appendicitis on CT include a dilated (>6 mm), thick-walled appendix that does not fill with enteric contrast or air, as well as surrounding fat stranding to suggest inflammation (Fig. 31-4).<sup>34</sup> In a meta-analysis of 12 prospective studies, CT demonstrated a sensitivity of 0.94 and a specificity of 0.95.<sup>33</sup> CT thus has a high negative predictive value, making it particularly useful in excluding appendicitis in patients for whom the diagnosis is in doubt. Appendicitis is highly unlikely if enteric contrast fills the lumen of the appendix and no surrounding inflammation is present. The clinician must remember, however, that a CT performed early in the course of appendicitis might not show



**FIGURE 31-4** CT of acute appendicitis. The *arrow* points to an enlarged, fluid-filled appendix with wall hyperemia that does not fill with oral contrast. The paucity of intra-abdominal fat limits identification of fat stranding. (Used, with permission, from M. Stephen Ledbetter, MD, MPH, Brigham and Women's Hospital, Boston, MA.)

the typical radiographic findings. In confusing cases, it is reasonable to repeat the CT after 24 hours of observation.

A number of recent prospective studies have compared the accuracy of CT and ultrasound in imaging the appendix (Table 31-1).<sup>32,35,36</sup> Balthazar and associates<sup>35</sup> performed CT and ultrasound on 100 consecutive patients with suspected appendicitis. The sensitivity of CT was considerably higher (96% for CT, 76% for US), while the specificity was comparable (89% for CT, 91% for US), yielding a higher accuracy for CT (94 vs 83%). CT was also able to provide an alternative diagnosis in more patients and was better able to visualize abscesses or phlegmons (Fig. 31-5). Horton and colleagues<sup>36</sup> randomized patients with suspected appendicitis to either CT or ultrasound. Their findings echo those of Balthazar, with both CT and ultrasound having high specificity (100% for CT, 90% for US) but CT having significantly higher sensitivity (97 vs 76%). Yet another prospective study showed similar



**FIGURE 31-5** CT of perforated appendix. Note retrocecal abscess (*arrows*) with enhancing wall and periappendiceal fat stranding and adjacent cecal thickening (*arrowhead*). (Used, with permission, from M. Stephen Ledbetter, MD, MPH, Brigham and Women's Hospital, Boston, MA.)

results, with CT having higher sensitivity (96 vs 62%) and specificity (92 vs 71%) than ultrasound.<sup>32</sup> Again, CT was also better able to visualize other intra-abdominal pathology in the absence of appendicitis.

In a study of 100 patients evaluated by CT with rectal and intravenous contrast, Rao and coworkers<sup>37</sup> showed that CT can reduce the use of hospital resources and costs. CT changed the management of 59 patients, avoiding 13 unnecessary appendectomies and eliminating a total of 50 inpatient hospital days for observation of unexplained abdominal pain. Even factoring in the cost of the CT scans, the authors calculated a net savings of US\$447 per patient.

Taken together, these studies suggest an algorithm for evaluation of patients with suspected acute appendicitis. Patients with a history, physical examination, and laboratory studies classic for appendicitis should undergo appendectomy. In those with an evaluation suggestive but not convincing for appendicitis, further imaging is warranted. In women of childbearing age, this should begin with a pelvic ultrasound to evaluate for ovarian pathology. In other patients, transabdominal ultrasound or abdominopelvic CT should be considered, depending on study availability and expertise of the consulting radiologist. CT does have the advantage of improved accuracy in diagnosing both appendiceal and other intra-abdominal pathology. This can be supplemented with rectal contrast CT, if needed, to better visualize the appendix.<sup>32,37</sup> Patients with a CT showing nonperforated appendicitis should undergo appendectomy. In many instances, patients with a normal CT do not require hospital admission. If symptoms persist, admission to the hospital for observation, and perhaps a repeat CT scan, is warranted.

**TABLE 31-1: ACCURACY OF CT AND US FOR THE DIAGNOSIS OF ACUTE APPENDICITIS**

		Sensitivity (%)	Specificity (%)	Accuracy (%)
Balthazar et al <sup>35</sup>	CT	96	89	94
	US	76	91	83
Horton et al <sup>36</sup>	CT	97	100	98
	US	76	90	80
Wise et al <sup>32</sup>	CT	96	92	93
	US	62	71	69
Terasawa et al <sup>33</sup> (meta-analysis)	CT	94	95	N/A
	US	86	81	N/A

CT, computed tomography; N/A, not applicable; US, ultrasound.

## DIFFERENTIAL DIAGNOSIS

Because many of its signs and symptoms are nonspecific, the differential diagnosis of acute appendicitis is extensive and includes virtually all possible abdominal sources of pain, as well as some nonabdominal sources (Table 31-2). However,

**TABLE 31-2: DIFFERENTIAL DIAGNOSIS OF ACUTE APPENDICITIS**

### Gastrointestinal causes

- Cecal diverticulitis
- Sigmoid diverticulitis
- Meckel's diverticulitis
- Epiploica appendicitis
- Mesenteric adenitis
- Omental torsion
- Crohn's disease
- Cecal carcinoma
- Appendiceal neoplasm
- Lymphoma
- Typhlitis
- Small bowel obstruction
- Perforated duodenal ulcer
- Intussusception
- Acute cholecystitis
- Hepatitis
- Pancreatitis

### Infectious causes

- Infectious terminal ileitis (*Yersinia*, tuberculosis, or cytomegalovirus)
- Gastroenteritis
- Cytomegalovirus colitis

### Genitourinary causes

- Pyelonephritis or perinephric abscess
- Nephrolithiasis
- Hydronephrosis
- Urinary tract infection

### Nonabdominal causes

- Streptococcal pharyngitis*
- Lower lobe pneumonia
- Rectus muscle hematoma

### In women

- Ovarian cyst (ruptured or not ruptured)
- Corpus luteal cyst (ruptured or not ruptured)
- Ovarian torsion
- Endometriosis
- Pelvic inflammatory disease
- Tubo-ovarian abscess

### In pregnancy

- Ectopic pregnancy
- Round ligament pain
- Chorioamnionitis
- Placental abruption
- Preterm labor

some diagnoses are more likely than others in certain patient groups. For instance, in young males with a suggestive history and physical examination, acute appendicitis is the most likely cause of RLQ pain. Meckel's diverticulitis causes similar symptoms but is relatively uncommon.<sup>38</sup> Gastroenteritis is considerably more common and should be expected when nausea and vomiting precede the abdominal pain, or when diarrhea is a prominent symptom. Crohn's disease affecting the terminal ileum may resemble appendicitis in its initial presentation, but on further questioning the patient typically describes a subacute course, including fever, weight loss, and pain.

In middle-aged and older adults, other inflammatory conditions should be considered, including peptic or duodenal ulcer (with fluid tracking into the right paracolic gutter), cholecystitis, and pancreatitis. In addition, cecal or sigmoid diverticulitis can be confused with acute appendicitis. Cecal diverticulitis is quite similar in pathogenesis and presentation to appendicitis, because cecal diverticula, like the appendix, are true diverticula containing all layers of the intestinal wall. Because a redundant, floppy sigmoid colon can extend to the right side of the abdomen, patients with sigmoid diverticulitis can sometimes present with RLQ pain. Those patients typically describe a quicker progression to localized tenderness, as well as a prodrome of an alteration in bowel habits. Malignancies can present with acute RLQ pain due to perforation of a cecal carcinoma or appendicitis caused by a mass obstructing the appendiceal orifice.<sup>39</sup> These patients will also typically have guaiac-positive stools, anemia, and a history of weight loss.

In women of childbearing years, the diagnosis of RLQ pain can be even more difficult. In addition to the causes of RLQ pain mentioned for young men, young women can also have pain from obstetric and gynecological causes such as ruptured ovarian cyst or follicle, ovarian torsion, ectopic pregnancy, acute salpingitis, and tubo-ovarian abscess. A complete history including recent menstrual history, as well as pelvic examination, can be helpful in differentiating these causes of pain from acute appendicitis. Nonetheless, appendicitis can be difficult to diagnose in this patient population, and higher rates of misdiagnosis have been described in women of childbearing age.<sup>40</sup>

## SPECIAL CONSIDERATIONS

**Children.** Appendicitis most commonly affects children age 10–19, with an overall incidence of approximately 20 cases per 10,000 population annually.<sup>13</sup> Among those younger than 20, infants aged 0–4 have the lowest incidence of appendicitis (2 cases per 10,000 annually), but up to two-thirds will present with perforation.<sup>41</sup> Perforation is common because infants often present later in their disease course and because of the difficulty in obtaining an accurate history. The diagnosis is further complicated by diseases of childhood that can mimic appendicitis. For instance, mesenteric adenitis, an inflammation of the mesenteric lymph nodes secondary to



upper respiratory tract infection, can present with fever and RLQ pain. Streptococcal pharyngitis and bacterial meningitis can also present with fever, nausea, and abdominal pain. These diagnoses and others including ovarian cysts, ovarian torsion, urinary tract infection, pelvic inflammatory disease, and complications of a Meckel's diverticulum should be considered when evaluating children or adolescents for suspected appendicitis.

In children with an equivocal history and physical examination, imaging with either a CT scan or US can significantly reduce the negative appendectomy rate from 14 to 37% down to 2 to 10%.<sup>42</sup> The pertinent question is which study is preferable. As with adults, both CT and US have been shown to be highly accurate in diagnosing appendicitis in children, although CT scan is believed to have a higher specificity and sensitivity. In an early study Garcia Pena and associates compared ultrasonography and rectal contrast CT in 139 children with suspected appendicitis and found CT to be more sensitive (97% for CT, 44% for US), more specific (94% for CT, 93% for US), and more accurate (94% for CT, 76% for US).<sup>43</sup> CT correctly changed the management of 73% of patients, while ultrasound correctly changed 19%. More recent meta-analysis and reviews evaluating CT and/or ultrasound in pediatric populations found the specificity of the two imaging modalities to be similar (92–95%) but the sensitivity of ultrasound (88–90%) to be less than that of CT scan (94–95%).<sup>42,44</sup> An important determinant in the diagnostic success of ultrasound is the body mass index (BMI) of the child. The sensitivity of ultrasound has been reported by some to be 76% in children with a BMI below 25, 37% in children with a BMI greater than 25, and 82% in one study in which the patient population had a mean BMI of 17.<sup>42,45,46</sup>

The use of CT can be recommended for children with one caveat. The radiation from a CT in childhood theoretically causes a small increase in the lifetime risk of certain cancers.<sup>47</sup> Based on estimated radiation exposure from a CT scan, studies have hypothesized that a 1-year-old and 15-year-old would have a 0.18 and 0.11% lifetime risk, respectively, of fatal radiation-induced malignancy following a CT scan.<sup>42</sup> Therefore, clinicians should consider the risks and benefits of CT, and efforts should be directed toward reducing radiation dose when imaging children.<sup>48</sup> In the pediatric patients with suspected appendicitis, an algorithm starting with an ultrasound, especially in low BMI children and females, followed by CT scan if the ultrasound is equivocal may allow the maximum benefit of radiologic imaging while minimizing potential deleterious radiation effects. The use of magnetic resonance imaging (MRI) in the evaluation of children has only recently begun to be investigated. Although its ability to identify the appendix has been established, the use of MRI in the diagnosis of appendicitis in children requires further study.

**Elderly.** Although appendicitis is more common in younger age groups, it is still an important cause of abdominal pain in the elderly. Perhaps because of a diminished inflammatory response, the elderly can present with less impressive

symptoms and physical signs, longer duration of symptoms, and decreased leukocytosis compared to younger patients.<sup>49</sup> Perforation is thus more common, occurring in as many as 50% of patients older than 65.<sup>13</sup> These patients may have cardiac, pulmonary, and renal conditions, resulting in considerable morbidity and mortality from perforation. In one series, the mortality from perforated appendicitis in patients older than 80 was 21%.<sup>50</sup> These factors argue that RLQ pain in elderly patients must be aggressively investigated. Because of the multiple other possible causes of abdominal pain in this patient population (including malignancy, diverticulitis, and perforated peptic ulcer disease), prompt CT scan is advocated when the diagnosis is in question.

**Pregnancy.** The diagnosis of acute appendicitis in the pregnant patient can be particularly challenging, as nausea, anorexia, and abdominal pain may be symptoms of both appendicitis and normal pregnancy. In addition, the gravid uterus can displace the abdominal viscera, shifting the location of the appendix from the right lower quadrant. Appendicitis affects 1 in every 1400 pregnancies, an incidence similar to that of the nonpregnant female population.<sup>51</sup> It can occur in any trimester, with perhaps a slight increase in frequency during the second trimester.<sup>51,52</sup> Perforation is more common in the third trimester, however, and results from a longer duration from the onset of symptoms to operation.<sup>53</sup> The differential diagnosis of appendicitis includes not only the conditions possible in nonpregnant women but also certain conditions specific to pregnancy: ectopic pregnancy, chorioamnionitis, preterm labor, placental abruption, and round ligament pain.

In the first and early second trimesters, the presentation of appendicitis is similar to that seen in nonpregnant women. In the third trimester, women may not present with RLQ pain due to displacement of the appendix by the gravid uterus. Baer and associates performed barium enemas on normal pregnant women and found the appendix to migrate superiorly toward the right upper quadrant in later stages of pregnancy.<sup>54</sup> Their findings suggest that appendicitis should present with RUQ or flank pain in late pregnancy. Two retrospective studies contradict this, however, showing that even in the third trimester, pain and tenderness are more common in the right lower than the right upper quadrant.<sup>51,52</sup> Nonetheless, RUQ pain did predominate in some third-trimester patients with appendicitis in each study,<sup>51,52</sup> reminding the clinician that right upper quadrant and right flank symptoms could be due to appendicitis in an appendix displaced by the gravid uterus. Recent studies highlight the difficulty of assigning a clinical picture to a pregnant patient with appendicitis. Brown et al<sup>55</sup> reviewed case-control studies attempting to correlate preoperative signs and symptoms with the postoperative diagnosis of appendicitis in pregnant patients. Although patients presented with RUQ pain, RLQ pain, and fevers, only nausea, vomiting, and peritonitis were found to significantly correlate with the diagnosis of appendicitis.

Ultrasound is accurate in pregnancy<sup>56</sup> and is a useful first radiological study because it has no known adverse fetal effects.<sup>57</sup> Rectal contrast CT has also been shown to be highly

accurate in the pregnant population.<sup>58</sup> Although ionizing radiation has risks to the fetus, the radiation from a typical abdominopelvic CT is below the threshold of 5 rad at which teratogenic effects are seen.<sup>59</sup> When the diagnosis is in doubt, the risk of radiation should be weighed against the risk of spontaneous abortion from an unnecessary laparotomy or from undiagnosed appendicitis progressing to perforation. Hospital admission with close observation for progression of symptoms is a viable alternative if the risks of radiation from CT scan are deemed excessive. Additionally, MRI has been recently used to aid in the diagnosis of appendicitis in the pregnant patient when ultrasound results are equivocal. In those pregnant patients with a normal or inconclusive ultrasound, MRI is a diagnostic option, with accuracy that rivals CT; MRI has a sensitivity of 80% and specificity of 99%, compared with 85.7 and 97.4% for CT. Although MRI does not carry a risk of radiation, it does have theoretical risks of static and time-varying magnetic fields, heating effects of the radiofrequency pulses and acoustic noise generated by the spatial encoding gradients do exist. To date, however, no adverse effects of MRI on the developing fetus have been reported.<sup>60</sup>

The pregnant patient should proceed directly to appendectomy if appendicitis is suspected. A normal appendix is not an uncommon finding, as negative appendectomy has been reported in approximately one-third of cases due to the difficulty of diagnosis in this population.<sup>51,52,61</sup> Negative appendectomy should not be considered an error in diagnosis, because the risk to the fetus varies directly with the severity of appendicitis. In one series, fetal loss occurred in only 1 (3%) of 30 negative laparotomies.<sup>51</sup> Fetal mortality rises to 5% in cases of nonperforated appendicitis and increases to 20–35% when the appendix perforates.<sup>55,61</sup> These data warrant an aggressive approach to appendectomy. Early negative exploration is justified to minimize the likelihood of progression to perforation.

As laparoscopic appendectomy has become increasingly popular, it has been utilized more frequently during pregnancy.<sup>62</sup> Pregnancy can increase the complexity of the procedure, as the gravid uterus can make laparoscopic visualization difficult, particularly if the appendix is located in the pelvis. In addition, carbon dioxide insufflation of the abdomen results in fetal hypercarbia and decreased placental blood flow, the effects of which have not been completely studied.<sup>63</sup> Recent case series, however, have supported the safety of laparoscopic appendectomy in the pregnant patient. In a retrospective review of 45 cases, Lemieux et al<sup>64</sup> demonstrated that 4% of patients had a major complication (uterine perforation, intra-abdominal abscess), 4% of patients had a minor complication (cystitis, ileus), 18% delivered before 37 weeks gestation, and there was no fetal loss. There was also no difference in complications, preterm delivery, or operative time associated with performing the appendectomy during the first, second, or third trimester. A retrospective review directly comparing laparoscopic to open appendectomy in 42 pregnant women found no intra- or postoperative complications in either group and one fetal loss in both groups.<sup>65</sup> Thus, the feasibility and safety of laparoscopy during pregnancy are supported by

these studies, but larger studies are required for it to become fully accepted.

**Immunocompromise.** The immunocompromised state alters the normal response to acute infection and wound healing. Appendicitis affects all types of patients and must be considered in those who have undergone organ transplant, are receiving chemotherapy, have hematological malignancy, or are infected with the human immunodeficiency virus (HIV). The differential diagnosis of abdominal pain in this population is broad and includes hepatitis, pancreatitis (from medications or cytomegalovirus infection), acalculous cholecystitis, intra-abdominal opportunistic infections (cytomegalovirus colitis or mycobacterial ileitis), secondary malignancies (lymphoma or Kaposi's sarcoma), graft-versus-host disease, and typhlitis. This broad differential diagnosis often results in delay in diagnosis and late presentation to surgical evaluation, at which time perforation may be more likely.<sup>66,67</sup>

Appendicitis in patients with HIV and acquired immunodeficiency syndrome (AIDS) presents unique challenges. Abdominal pain is not an uncommon symptom in these patients, making differentiation between surgical and nonsurgical causes difficult. Nonetheless, immunocompromised patients with appendicitis present with symptoms similar to those of the general population,<sup>66</sup> and RLQ pain, nausea, and anorexia. Fever and WBC may not be helpful in this population, so imaging studies, particularly CT, have been supported by some authors.<sup>67</sup> There is no specific contraindication to operation in immunocompromised patients, so once diagnosed with appendicitis, appendectomy should be performed promptly.

## Treatment

### NONOPERATIVE MANAGEMENT

Appendectomy was one of the first intra-abdominal operations performed, and appendicitis has long been a surgically treated disease. Rare descriptions of nonsurgical management dot the surgical literature, however. Treves was an advocate of early nonoperative management of acute appendicitis, even prior to the advent of antibiotics.<sup>12</sup> In the postantibiotic era, Coldrey presented his retrospective series of 471 patients with appendicitis treated with antibiotics.<sup>68</sup> This treatment failed in at least 57 patients, with 48 requiring appendectomy and 9 requiring drainage of an appendiceal abscess. An early randomized controlled trial, performed by Eriksson and associates, sought to address this issue.<sup>69</sup> Their results show a high rate of recurrence of appendicitis treated nonsurgically. The authors randomized 40 adults with presumed appendicitis to appendectomy or 10 days of intravenous and oral antibiotics. Eight (40%) of the 20 patients in the antibiotic group required appendectomy within 1 year: one patient for perforation within 12 hours of randomization and another seven for recurrent appendicitis (one of whom had perforation). Based on the high rate of failure

with antibiotics alone, nonoperative management of acute appendicitis has not been recommended.

Recently, a larger randomized clinical trial evaluating antibiotic therapy versus appendectomy as the primary treatment for acute appendicitis in unselected patients was performed.<sup>70</sup> In this study 202 patients were assigned to antibiotic treatment and 167 patients to appendectomy. Treatment efficacy, defined as definite improvement without the need for surgery within a median follow-up of 1 year for the antibiotic group and confirmed appendicitis or another appropriate surgical indication at the time of the operation for the appendectomy group, was found to be similar between the antibiotic and appendectomy groups (90.8 and 89.2% respectively). In the antibiotic group, recurrent appendicitis occurred in 13.9% after a median of 1 year. A third of the recurrences occurred within 10 days and two-thirds occurred within 3 and 16 months after discharge. Minor complications were similar between the two groups while major complications, defined as the need for reoperation, abscess, bowel obstruction, wound rupture or hernia, and serious anesthesia or cardiac-related problems, were three times higher in the appendectomy group. Close evaluation of this study, however, highlights the need for further studies and caution when applying their findings to clinical practice. Specifically, only 52.5% of those allocated to the antibiotic group completed antibiotic treatment. The remaining patients were transferred to the appendectomy group based on either the patient's or surgeon's discretion. Evaluation of those patients transferred to the surgery group indicate that they had a higher WBC and elevated temperature suggesting that they may have been clinically sicker. The efficacy of the antibiotic group reported as 90.8% was based only on those that completed antibiotic therapy and thus excluded the potentially sicker patients who crossed over from the antibiotic group to the surgery group. Evaluation of efficacy based on intention-to-treat (all 202 patients originally allocated to the antibiotic group including the 47.5% that switched to surgery) results in an efficacy of 48% for the antibiotic group. These studies suggest that antibiotic treatment may be a useful first-line treatment for acute appendicitis in selected patients; however, further studies are required to determine their usefulness as the lone treatment option. Nevertheless, antibiotic treatment may be a useful temporizing measure in environments with no surgical capabilities such as in space flight and submarine travel.<sup>71</sup>

### PREOPERATIVE PREPARATION

When the decision is made to perform an appendectomy for acute appendicitis, the patient should proceed to the operating room with little delay to minimize the chance of progression to perforation. Such occurrences are rare, however, as most cases of appendiceal perforation occur prior to surgical evaluation.<sup>23,24</sup> Patients with appendicitis may be dehydrated from fever and poor oral intake, so intravenous fluids should be begun, and pulse, blood pressure, and urine output should be closely monitored. Markedly dehydrated patients may require a Foley catheter to ensure adequate urine output.

Severe electrolyte abnormalities are uncommon with non-perforated appendicitis, as vomiting and fever have typically been present for 24 hours or less but may be significant in cases of perforation. Any electrolyte deficiencies should be corrected prior to the induction of general anesthesia.

Intravenous antibiotics have been shown to reduce significantly the incidence of postoperative wound infection and intra-abdominal abscess.<sup>72</sup> Antibiotics should be administered 30 minutes prior to incision to achieve adequate tissue levels. The typical flora of the appendix resembles that of the colon and includes gram-negative aerobes (primarily *Escherichia coli*) and anaerobes (*Bacteroides* spp.). No standardized antibiotic regimen exists. Acceptable options include a second-generation cephalosporin or a combination of antibiotics directed at gram negatives and anaerobes. In nonperforated appendicitis, a single preoperative dose of cefoxitin suffices.<sup>73</sup> In cases of perforation, an extended course of at least 5 days of antibiotics is advocated.<sup>74</sup>

### OPEN VERSUS LAPAROSCOPIC APPENDECTOMY

Once the diagnosis of appendicitis is made, the surgeon must decide whether to perform an open (OA) or laparoscopic (LA) appendectomy. Numerous randomized controlled trials have compared these two methods, sometimes with conflicting results.<sup>75,76</sup> Meta-analyses and systematic reviews have combined these studies to address the controversy (Table 31-3).<sup>77-79</sup> These meta-analyses have similar findings, which can be summarized as follows: (1) OA can be performed more quickly; (2) LA patients have less postoperative pain and reduced narcotic requirements; (3) there is a trend toward reduced length of stay with LA; (4) LA patients have fewer wound infections; (5) OA patients develop fewer intra-abdominal abscesses; (6) LA patients return to work more quickly; (7) operating room and hospital costs are less with OA; and (8) societal costs may be less with LA.<sup>77-79</sup>

**TABLE 31-3: LAPAROSCOPIC VERSUS OPEN APPENDECTOMY**

Favors Laparoscopy	Favors Open
Diagnosis of other conditions	
Decreased pain and lower narcotic requirement	Shorter operating room time
Reduced length of stay	Lower operating room costs
Fewer wound infections	Fewer intra-abdominal abscesses
Quicker return to usual activities	Lower hospital costs
Lower societal cost	

Data from McCall JL, Sharples K, Jadallah F. Systemic review of randomized controlled trials comparing laparoscopic with open appendectomy: a meta-analysis. *J Am Coll Surg.* 1998; 186:545-553; and Sauerland S, Lefering R, Neugebauer EA. Laparoscopic versus open surgery for suspected appendicitis. *Cochrane Database Syst Rev.* 2004;4:CD001546.



Based on the data available, one cannot convincingly recommend either OA or LA over the other. Each method has its advantages and disadvantages that should be considered when deciding how to perform appendectomy.

One situation in which laparoscopic appendectomy may be advisable is when the diagnosis of appendicitis is in doubt. This can be particularly useful in women of childbearing age, in whom obstetric and gynecological pathology may also be likely. In this population, a normal appendix can be found in more than 40% of patients with suspected appendicitis.<sup>80</sup> Laparoscopy can thus be both diagnostic and therapeutic, and a laparotomy can be avoided if gynecologic pathology is found. The ovaries, fallopian tubes, and uterus can be examined for nonappendiceal causes of abdominal pain, including ovarian cyst or torsion, endometriosis, or pelvic inflammatory disease. Laparoscopy makes this evaluation considerably easier and less morbid for the patient. In one study, when a normal appendix was discovered, gynecological pathology was found in 73% of women explored laparoscopically but only 17% of women who had an open appendectomy.<sup>81</sup> Although diagnostic accuracy will likely improve in young women with more widespread use of CT scans, this population will continue to provide diagnostic dilemmas that may be aided by laparoscopy.

**Open Appendectomy.** If open appendectomy is chosen, the surgeon must then decide on the location and type of incision. Prior to incision, a single dose of antibiotics should be administered, typically a second-generation cephalosporin.<sup>73</sup> The patient should be reexamined after the induction of general anesthesia, which enables deep palpation of the abdomen. If a mass representing the inflamed appendix can be palpated, the incision can be centered at that location. If no appendiceal mass is detected, the incision should be centered over McBurney's point, one-third of the distance from the anterior superior iliac spine to the umbilicus. A curvilinear incision, now known as *McBurney's incision*, is made in a natural skin fold. It is important not to make the incision too medial or too lateral. An incision placed too medial opens onto the anterior rectus sheath, rather than the desired oblique muscles, while an incision placed too lateral may be lateral to the abdominal cavity.

The operation proceeds much as McBurney first described it in 1894.<sup>82</sup> The incision extends through the subcutaneous tissue, exposing the aponeurosis of the external oblique muscle, which is divided, either sharply or with electrocautery, in the direction of its fibers (Fig. 31-6). A muscle-splitting technique is typically used, in which the external oblique, internal oblique, and transversus abdominis muscles are separated along the orientation of their muscle fibers. The peritoneum is thus exposed, grasped with forceps, and opened sharply along the orientation of the incision, taking care not to injure the underlying abdominal contents. Hemostats can be placed on the peritoneum to facilitate its identification at the time of wound closure. Cloudy fluid may be encountered on entering the peritoneum. Although some advocate bacterial culture of the peritoneal fluid, studies show that this neither helps

direct the antibiotic regimen<sup>83</sup> nor reduces infectious complications.<sup>84</sup>

With a correctly placed incision, the cecum will be visible at the base of the wound. The incision should be explored with a finger in an attempt to locate the appendix. If the appendix is palpable and free from surrounding structures, it can be delivered into the incision. Frequently, the appendix is palpable, but it adheres to surrounding structures. Filmy adhesions can be divided using blunt dissection, but thicker adhesions should be divided under direct vision. To facilitate this, the cecum can be partially delivered into the incision to provide better exposure of the appendix. If necessary to improve exposure, the incision can be extended medially by partially dividing the rectus muscle or laterally by further dividing the oblique and transversus abdominis muscles. If the appendix cannot be visualized, it can be located by following the teniae coli of the cecum to the cecal base, from which the appendix invariably originates. Once located, the appendix is delivered through the incision. Grasping the mesentery with a Babcock clamp can sometimes facilitate this maneuver. Care should be taken to avoid perforation of the appendix, with spillage of pus or enteric contents into the abdomen.

The arterial supply to the appendix, which runs in the mesoappendix, is now divided between clamps and tied with 3-0 polyglactin or silk suture. This is usually performed in an antegrade fashion, from the appendiceal tip toward the base. Division of the artery to the appendiceal base is necessary to ensure that the entire appendix can be removed without leaving an excessively long appendiceal stump.

In excising the appendix, the surgeon must decide whether or not to invert the appendiceal stump. Traditionally, the appendix was ligated and divided, and its stump was inverted with a purse-string suture for the theoretical purpose of avoiding bacterial contamination of the peritoneum and subsequent adhesion formation.<sup>85,86</sup> However, recent prospective studies show no advantages to appendiceal stump inversion.<sup>87,88</sup> In one such study, 735 appendectomy patients were randomly assigned to ligation plus inversion or simple ligation of the appendiceal stump. There was no difference between the two groups in the incidence of wound infection or adhesion formation, and operating time was shorter in the simple ligation group. Inversion may also have the deleterious effect of deforming the cecal wall, which could be misinterpreted as a cecal mass on future contrast radiographs.<sup>88</sup> Furthermore, the long-standing notion that stump inversion reduces postoperative adhesions was discredited by Street and colleagues.<sup>89</sup> In their analysis, postoperative adhesions requiring operation were significantly increased in the inversion group.

To divide the appendix, the surgeon can use either suture ligation or a gastrointestinal stapler. For ligation, two hemostat clamps are placed at the base of the appendix. The clamp closest to the cecum is removed, having crushed the appendix at that site. Two heavy, absorbable sutures such as 0 chromic gut is used to doubly ligate the appendix, and the appendix is subsequently divided proximal to the second clamp. The exposed mucosa of the appendiceal stump can be cauterized to minimize the theoretical risk of postoperative mucocele, although

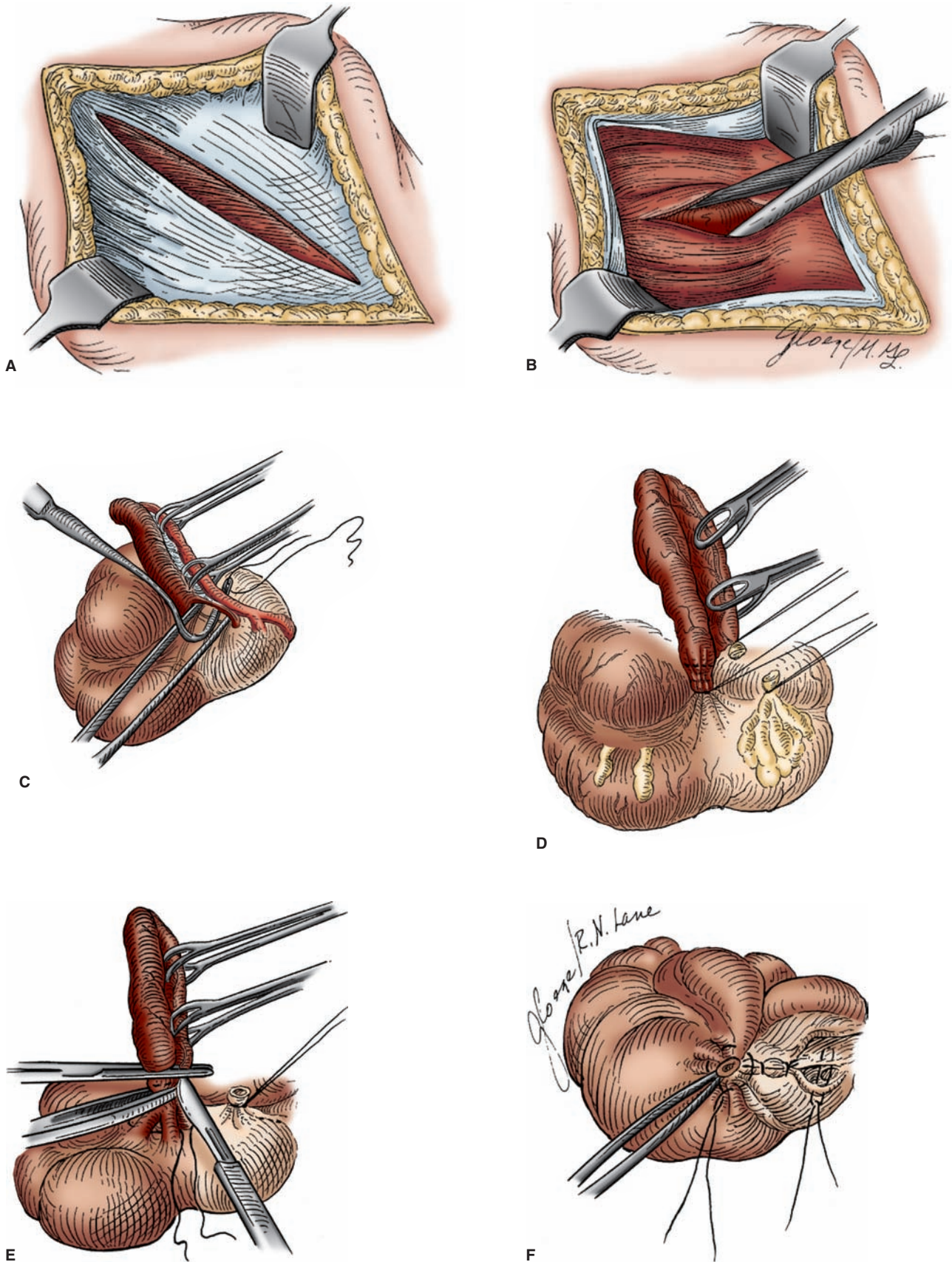


FIGURE 31-6 Open appendectomy technique.



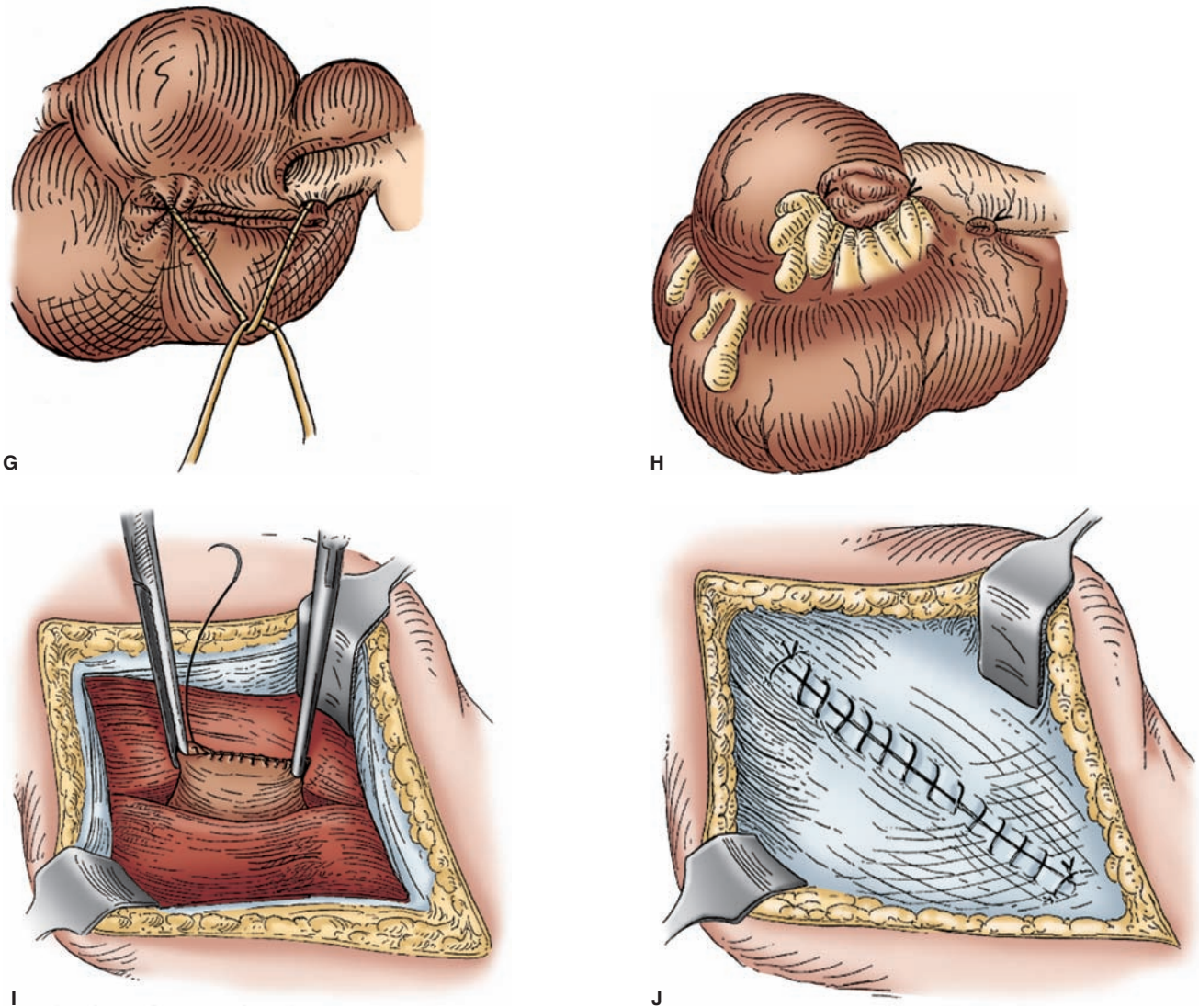


FIGURE 31-6 (Continued)

no data exist to support this. If appendiceal stump inversion is chosen, a seromuscular purse-string 3-0 silk suture is placed in the cecum around the appendiceal base after ligation but prior to division of the appendix. The purse-string suture should be placed approximately 1 cm from the base of the appendix, as placing it too close to the appendix makes stump inversion difficult. After the appendix is divided, the purse-string suture is tightened and tied while the assistant uses forceps to invaginate the appendiceal stump. Alternatively, the appendix can be divided at its base using a TA-30 stapler. Again, the stump need not be inverted, but can be if desired, using interrupted Lembert sutures with 3-0 silk suture. No matter how the appendix is divided, the residual appendiceal stump should be no longer than 3 mm to minimize the possibility of stump appendicitis in the future.<sup>26</sup>

Occasionally, inflammation at the tip of the appendix makes antegrade removal of the appendix difficult. In such cases, the appendix can be removed in a retrograde fashion.

In so doing, the appendix is divided at its base using one of the methods described previously. The mesoappendix is then divided between clamps, starting at the appendiceal base and progressing toward the tip (Fig. 31-7).

In certain cases, the appendiceal inflammation extends to the base of the appendix or beyond to the cecum. Division of the appendix through inflamed, infected tissue leaves the potential for leakage of cecal contents with a resultant abscess or fistula. Ensuring that the resection margin is grossly free of active inflammation can minimize this risk. If the base of the cecum is also inflamed but there is sufficient uninflamed cecum between the appendix and the ileocecal valve, an appendectomy with partial cecectomy can be performed using a stapling device.<sup>90</sup> Care should be taken to avoid narrowing the cecum at the ileocecal valve. If the inflammation extends to the ileocecal junction, an ileocecectomy with primary anastomosis may be necessary.



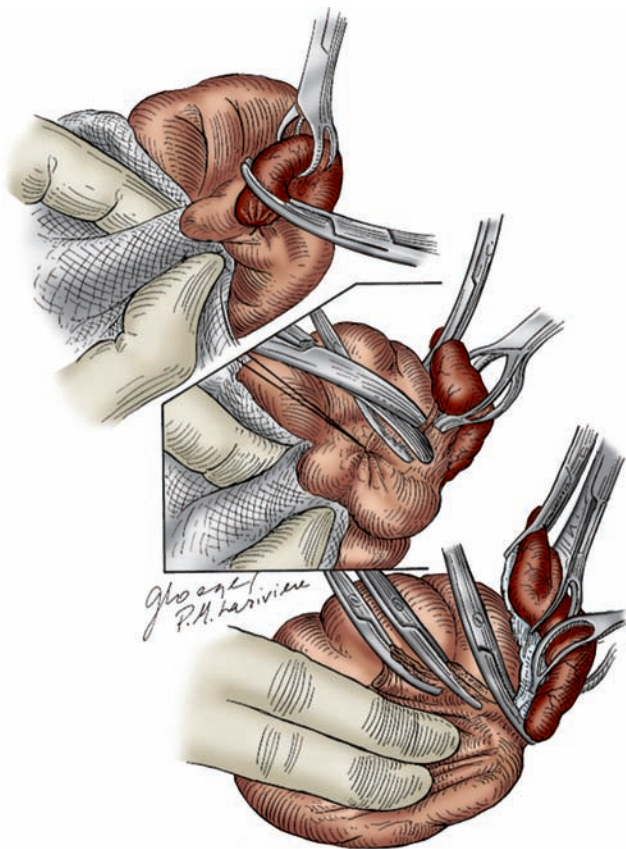


FIGURE 31-7 Retrograde dissection of the appendix.

After the appendix is removed, hemostasis is achieved and the right lower quadrant and pelvis are irrigated with warm saline. The peritoneum is closed with a continuous 0 absorbable suture; this layer provides no strength but helps to contain the abdominal contents during abdominal wall closure. The internal and external oblique muscles are then closed in succession using continuous 0 absorbable suture. To decrease postoperative narcotic requirements, the external oblique fascia can be infused with local anesthetic. Interrupted absorbable sutures are typically placed in Scarpa's fascia, and the skin can be closed with a subcuticular absorbable suture. With a preoperative dose of intravenous antibiotics and primary closure of the skin, fewer than 5% of patients with nonperforated appendicitis can be expected to develop a wound infection.<sup>91</sup>

**Laparoscopic Appendectomy.** Multiple port placements for laparoscopic appendectomy exist. The authors utilize a three-port technique, with one umbilical and one suprapubic port. Although the third port can be placed in either the left or right lower quadrant, we prefer the left lower quadrant. This follows the laparoscopic principle of triangulation, such that the port locations direct the camera and instruments toward the right lower quadrant for optimal visualization of the appendix.

The patient is positioned supine on the operating room table with the left arm tucked (Fig. 31-8). The video monitor

is placed at the patient's right side, because once pneumoperitoneum is performed, the surgeon and assistant both stand on the patient's left. A single dose of a second-generation cephalosporin is administered prophylactically. Prior to incision, a nasogastric tube and a Foley catheter are placed to decompress the stomach and urinary bladder. A Foley catheter can be avoided if a reliable patient urinates immediately prior to entering the operating room. A 1- to 2-cm vertical or transverse incision is made just inferior to the umbilicus and carried down to the midline fascia. A 12-mm trocar is placed using either Hassan or Veress technique, depending on surgeon preference. After insufflation of the abdomen and inspection through the umbilical port, a 5-mm suprapubic port is placed in the midline, taking care to avoid injury to the bladder, and another 5-mm port is placed in the left lower quadrant. These port sites typically provide excellent cosmesis postoperatively due to their small size and peripheral location on the abdomen.

A 5-mm, 30-degree laparoscope is inserted through the left lower quadrant trocar. Placing the laparoscope in the left lower quadrant allows triangulation of the appendix in the right lower quadrant by instruments placed through the two midline trocars. The surgeon operates the two dissecting instruments and the assistant operates the laparoscope. The appendix is identified at the base of the cecum, and any adhesions to surrounding structures can be lysed with a combination of blunt and sharp dissection supplemented with electrocautery. If a retrocecal appendix is encountered, division of the lateral peritoneal attachments of the cecum to the abdominal wall often improves visualization. Care must be taken to avoid underlying retroperitoneal structures, specifically the right ureter and iliac vessels. The appendix or mesoappendix can be gently grasped with a Babcock clamp placed through the suprapubic port and retracted anteriorly. A dissecting forceps placed through the umbilical port creates a window in the mesoappendix at the appendiceal base. Caution should be taken not to injure the appendiceal artery during this maneuver. As in the open procedure, the base of the appendix should be adequately dissected so that it can be divided without leaving a significant stump.<sup>26</sup> The appendix should be divided at the confluence of the appendix and cecum, or just onto the cecal wall, to avoid the possibility of stump appendicitis or mucocoele (see Fig. 31-8).

The appendix can be removed in a retrograde fashion, first dividing the appendix, followed by division of the mesoappendix. A laparoscopic gastrointestinal anastomosis (GIA) stapler is placed through the umbilical port and fired across the appendiceal base. After reloading, the stapler is again inserted through the umbilical port and placed across the mesoappendix, which is divided with firing of the stapler. Alternatively, the appendix can be secured using an Endoloop<sup>92</sup> (Ethicon, Endo-Surgery, Cincinnati, Ohio) and the mesoappendix with an Endoloop of cautery device. If desired, the appendix can be removed antegrade, by first dividing the mesoappendix prior to directing attention to the base. The appendix should be placed in a retrieval bag and removed through the umbilical port site to minimize the risk of wound infection. The operative field is inspected

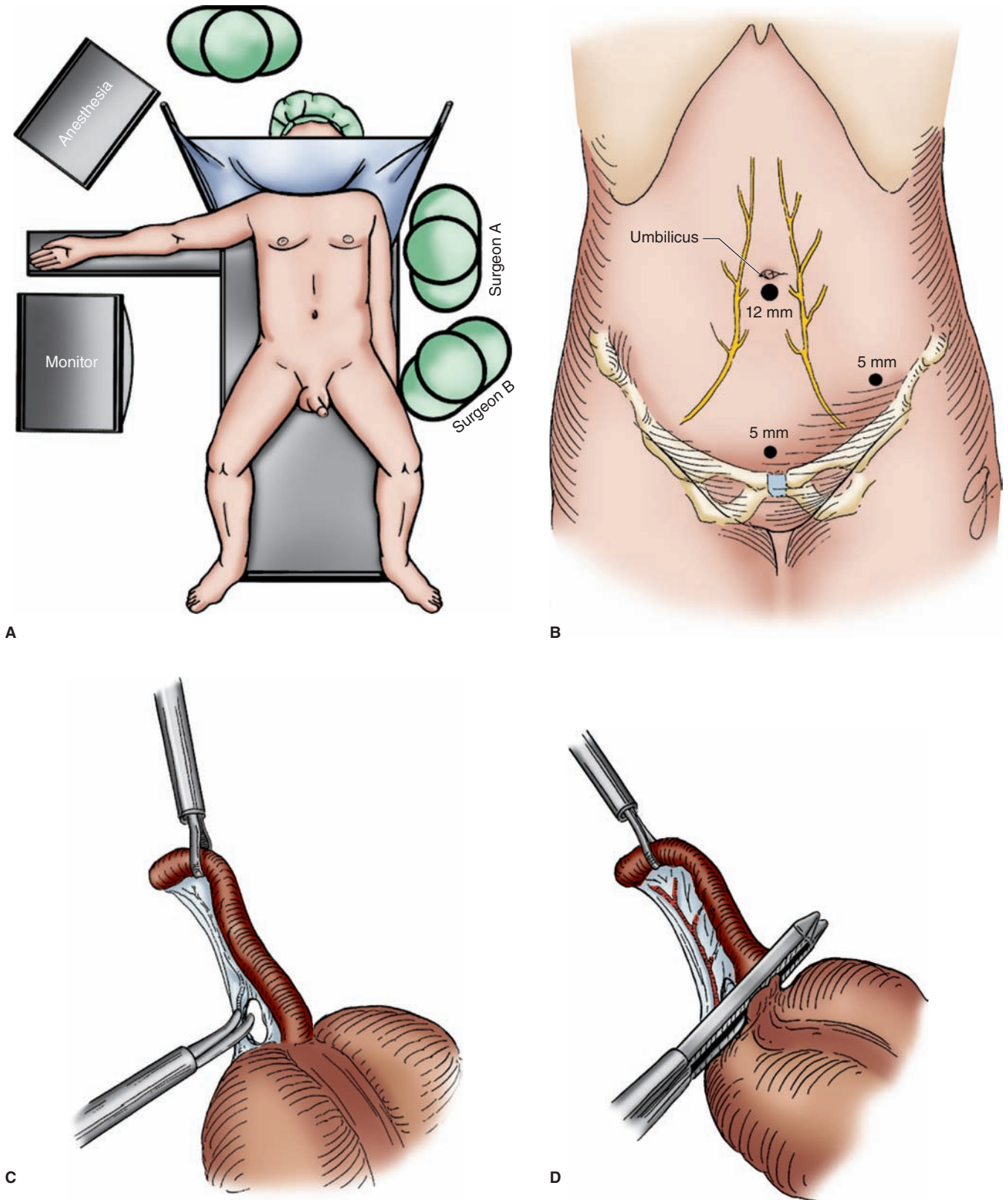


FIGURE 31-8 Laparoscopic appendectomy technique.

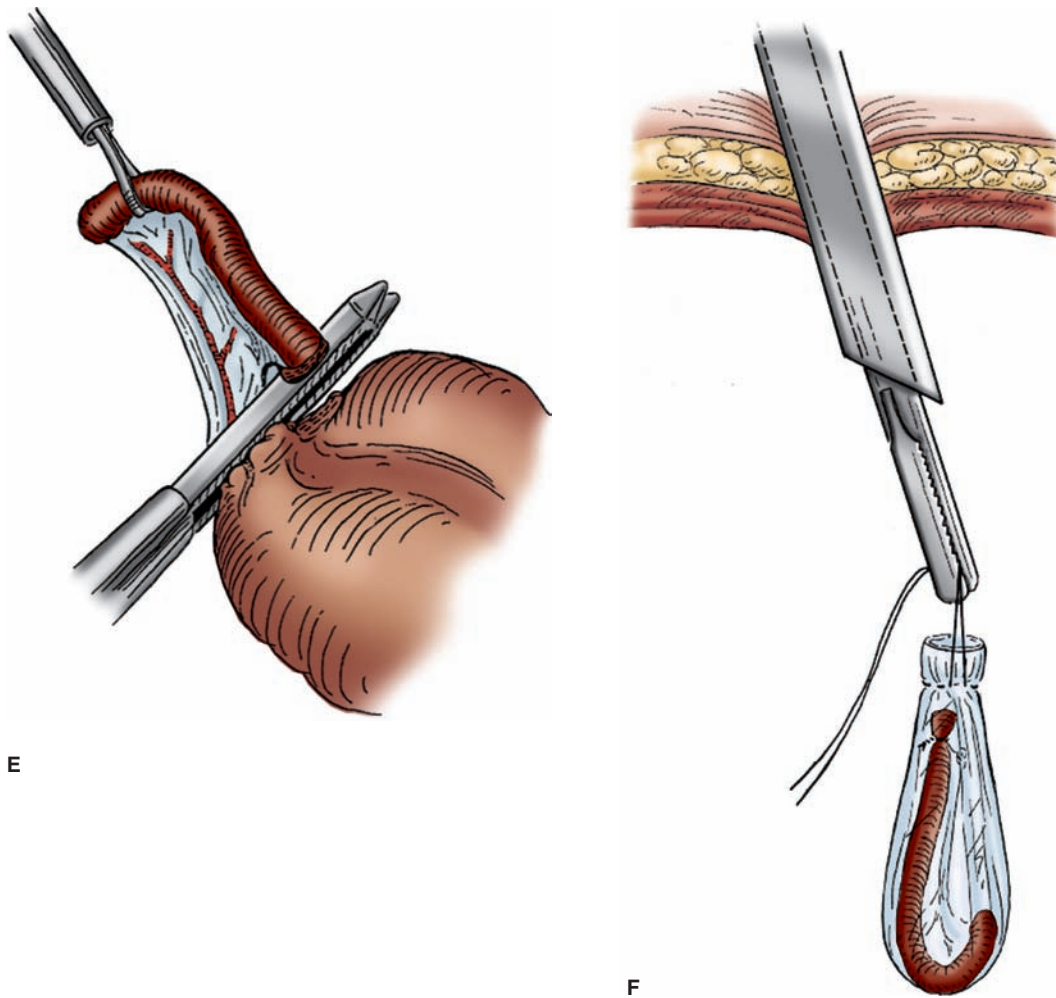


FIGURE 31-8 (Continued)

for hemostasis and can be irrigated with saline. Finally, the fascial defect at the umbilicus is closed with interrupted 0 absorbable suture, and all skin incisions are closed with fine subcuticular absorbable suture.

### Postoperative Care

Patients with nonperforated appendicitis typically require a 24- to 48-hour hospital stay. Postoperative care for both the laparoscopic and open approaches is similar. Patients can be started on a clear liquid diet immediately, and their diet can be advanced as tolerated. No postoperative doses of antibiotics are required. Patients can be discharged when they tolerate a regular diet and oral analgesics.

### Perforated Appendicitis

When appendicitis progresses to perforation, management depends on the nature of the perforation. If the perforation is contained, a solid or semisolid periappendiceal mass of

inflammatory tissue can form, referred to as a *phlegmon*. In other cases, contained perforation may result in a pus-filled abscess cavity. Finally, free perforation can occur, causing intraperitoneal dissemination of pus and fecal material. In the case of free perforation, the patient is typically quite ill and perhaps septic. Urgent laparotomy is necessary for appendectomy and irrigation and drainage of the peritoneal cavity. If the diagnosis of perforated appendicitis is known, the appendectomy can be performed through an RLQ incision, and the technique follows that previously described for open appendectomy. Sometimes patients with free perforation present with an acute abdomen and generalized peritonitis, and the decision to perform a laparotomy is made without a definitive diagnosis. In such instances, a midline incision is prudent. Once perforated appendicitis is discovered, appendectomy again proceeds as described previously. Peritoneal drains are not necessary, as they do not reduce the incidence of wound infection or abscess after appendectomy for perforated appendicitis.<sup>93,94</sup> The final operative decision is whether or not to close the incision. Because of wound infection rates ranging from 30 to 50% with primary closure of grossly contaminated



wounds, many advocate delayed primary or secondary closure.<sup>91,95</sup> However, a cost-utility analysis of contaminated appendectomy wounds showed primary closure to be the most cost-effective method of wound management.<sup>96</sup> Our technique of skin closure is interrupted permanent sutures or staples every 2 cm with loose wound packing in between. Removal of the packing in 48 hours often leaves an excellent cosmetic result with an acceptable incidence of wound infection. Patients are often continued on broad-spectrum antibiotics for 5–7 days and should remain in the hospital until afebrile and tolerating a regular diet.

If the patient does not have signs of generalized peritonitis but an abscess or phlegmon is suspected by history and physical exam, a CT scan can be particularly helpful to confirm the diagnosis. A solid, inflammatory mass in the RLQ without evidence of a fluid-filled abscess cavity suggests a phlegmon. In such instances, appendectomy can be difficult due to dense adhesions and inflammation. Ileocectomy may be necessary if the inflammation extends to the wall of the cecum. Complications such as inadvertent enterotomy, postoperative abscess, or enterocutaneous fistula may ensue. Because of these potential complications, many support an initially nonoperative approach.<sup>97–99</sup> Such an approach is only advisable if the patient is not ill appearing. Nonoperative management includes intravenous antibiotics and fluids as well as bowel rest. Patients should be closely monitored in the hospital during this time. Treatment failure, as evidenced by bowel obstruction, sepsis, or persistent pain, fever, or leukocytosis, requires immediate appendectomy. If fever, tenderness, and leukocytosis improve, diet can be slowly advanced, usually within 3–5 days. Patients are discharged home when clinical parameters have normalized. Using this approach, more than 80% of patients can be spared an appendectomy at the time of initial presentation.<sup>97,98</sup>

If imaging studies demonstrate an abscess cavity, CT- or ultrasound-guided drainage can often be performed percutaneously or transrectally.<sup>100,101</sup> Studies suggest that this approach to appendiceal abscesses results in fewer complications and shorter overall length of stay.<sup>99,102</sup> Again, following drainage the patient is closely monitored in the hospital and is placed on bowel rest with intravenous antibiotics and fluids. Advancement of diet and hospital discharge progress as clinically indicated.

## Interval Appendectomy

Treatment following initial nonoperative management of an appendiceal phlegmon or abscess is controversial. Some recommend interval appendectomy<sup>102–105</sup> (appendectomy performed approximately 6 weeks after inflammation has subsided), while others consider subsequent appendectomy unnecessary.<sup>98,106,107</sup> Factors to be considered when advising patients on interval appendectomy include a relatively low incidence of future appendicitis (8–10% and often associated with an appendicolith) and a morbidity associated with an interval appendectomy of approximately 11%.<sup>106</sup>

These factors must be weighed against the higher morbidity associated with an immediate appendectomy in the setting of acute recurrent appendicitis in the future (as high as 36% when appendicitis is associated with a phlegmon or abscess)<sup>106</sup> as well as the possibility of an ongoing appendiceal pathology, including inflammatory bowel disease and cancer.<sup>103,105,106</sup> Because it can now be performed laparoscopically on an outpatient basis with low morbidity,<sup>104,108</sup> interval appendectomy should be considered for patients who were initially treated with nonoperative management, but there is not convincing evidence to recommend this approach.

## Normal Appendix

Because of the difficulty in diagnosing appendicitis, it is not uncommon for a normal appendix to be found at appendectomy. Sometimes referred to as misdiagnosis, this can occur more than 15% of the time, with considerably higher percentages in infants, the elderly, and young women.<sup>40</sup> Negative appendectomy is to be avoided when possible, because of the risk of surgical complications and the cost associated with unnecessary surgery.<sup>109</sup> Nonetheless, in certain instances, the diagnosis is in doubt, and a noninflamed appendix is found at laparotomy or laparoscopy. The surgeon must then decide whether or not to remove the appendix. For multiple reasons, it is advisable to remove the grossly normal appendix. First, if the pain recurs and the appendix has been removed, appendicitis will no longer be a possibility and can be removed from the differential diagnosis. If the patient suffers RLQ pain in the future and the appendix has not been removed, but the patient has a classic RLQ scar, a surgeon evaluating the patient may assume a history of appendectomy and erroneously remove appendicitis from consideration. As laparoscopic appendectomy becomes more popular, this may even be true for patients with port site scars suggestive of appendectomy. Finally, there is strong evidence that a surgeon's gross assessment of the appendix can be inaccurate. In one study, 11 (26%) out of 43 appendectomy specimens described as normal by the surgeon showed acute appendicitis on pathological examination.<sup>110</sup> As a result, removal of a grossly normal appendix at the time of appendectomy is recommended.

When a normal appendix is discovered at appendectomy, it is important to search for other possible causes of the patient's symptoms. The terminal ileum can be inspected for evidence of terminal ileitis, which could be from infectious causes (*Yersinia* or tuberculosis) or Crohn's disease. In the absence of perforation, resection should not be performed for Crohn's disease and appropriate medical therapy should be initiated postoperatively. The ileum should also be evaluated for an inflamed or perforated Meckel's diverticulum, which should be excised. In females, the ovaries, fallopian tubes, and uterus should be examined for pathology as well. Evaluation of the left adnexa can be difficult through an RLQ incision, highlighting the utility of laparoscopy in female patients.

## Chronic Appendicitis

Although rare, chronic appendicitis can explain persistent abdominal pain in some patients. Patients do not present with the typical symptoms of acute appendicitis. Instead, they complain of weeks to years of RLQ pain and may have had multiple medical evaluations in the past. When queried, they may describe an initial episode with more classic symptoms of acute appendicitis, for which no treatment was delivered.<sup>111</sup> Diagnosis can be difficult, as laboratory and radiological studies are typically normal. Pathology evaluation revealing chronic inflammation confirms the diagnosis. Because the diagnosis is often uncertain preoperatively, laparoscopy can be a useful tool to allow exploration of the abdomen.<sup>112</sup>

## Asymptomatic Appendicolith

As CT scans become more widely utilized, it is likely that an increasing number of asymptomatic appendicoliths will be discovered. As discussed previously, appendicoliths are not pathognomonic for appendicitis but should only be considered in conjunction with the clinical presentation and other diagnostic studies. Lowe and associates<sup>113</sup> studied CT scans of children with suspected appendicitis and compared them to CT scans of children with abdominal trauma. Six (14%) of 44 patients with suspected appendicitis had an appendicolith but proved not to have appendicitis. In addition, 2 (3%) of the 74 trauma patients had an appendicolith on CT. These children were not followed to see if appendicitis developed later in life, but the considerable number of asymptomatic appendicoliths seen on adult abdominal radiographs suggests that many patients with an appendicolith will never develop appendicitis.<sup>18,19</sup> Based on this, appendectomy for asymptomatic appendicolith cannot be recommended.

## NEOPLASMS OF THE APPENDIX

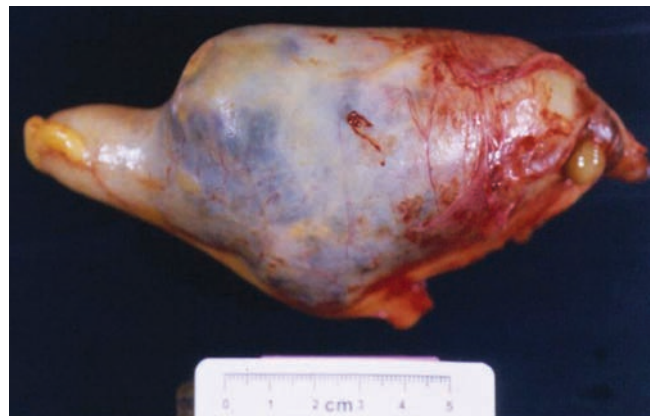Neoplasms of the appendix are rare, affecting less than 1% of appendectomies. Signs and symptoms of appendicitis prompt appendectomy in up to 50% of patients, and it is not uncommon for the patients with an appendiceal neoplasm to have acute appendicitis as well.<sup>114</sup> Patients may also present with a palpable mass, intussusception, urologic symptoms, or an incidentally discovered mass on abdominal imaging or at laparotomy for another purpose. Typically, the diagnosis is not known until laparotomy or pathologic evaluation of the appendectomy specimen, but preoperative diagnosis may become more common as imaging techniques become more widely used. Because of their common embryologic origin, the appendix and colon are susceptible to many of the same neoplastic growths. The most common appendiceal tumors include cystic neoplasms, carcinoid tumors, adenocarcinoma, and metastases. Other tumors have been reported but are extremely rare, such as lymphoma, stromal tumors (leiomyoma and leiomyosarcoma), and Kaposi's sarcoma.<sup>115</sup>

## Cystic Neoplasms and Pseudomyxoma Peritonei

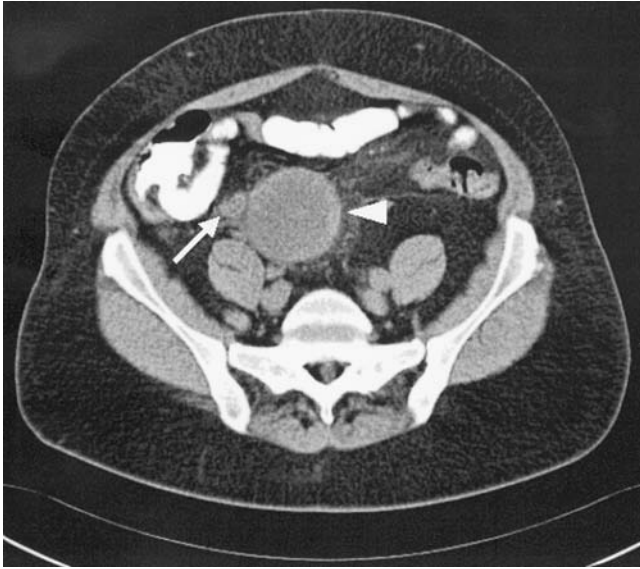Sometimes referred to as *mucoceles*, mucinous neoplasms of the appendix include a spectrum of diseases, including simple cyst, mucinous cystadenoma, mucinous cystadenocarcinoma, and pseudomyxoma peritonei. Mucocele is not a true pathologic diagnosis and instead refers to the macroscopic appearance of an appendix distended with mucus. Any of the above conditions can form a mucocele, but the more specific diagnostic term is preferable.<sup>116</sup> A simple cyst results from non-neoplastic occlusion of the appendiceal lumen, is usually less than 2 cm in diameter, and is often an incidental finding at appendectomy. In contrast, mucinous cystadenomas, benign tumors that represent the majority of “mucoceles,” can grow to 8 cm or larger (Fig. 31-9).<sup>117</sup> They typically remain asymptomatic due to slow-growing distension of the appendix and instead present incidentally as a mass on physical examination or abdominal imaging (Fig. 31-10). On plain radiograph or CT, wall calcification is characteristic.<sup>116</sup>

It is recommended that all mucinous appendiceal masses 2 cm or larger be surgically removed.<sup>117</sup> For mucinous cystadenoma, appendectomy is sufficient if the lesion does not involve the appendiceal base. Occasionally, the mass will rupture prior to or at the time of removal, but this rupture is typically contained to the right lower quadrant and is considered localized pseudomyxoma peritonei. If the mass is benign, appendectomy and removal of any residual mucin is curative.<sup>118</sup> Laparoscopic appendectomy is not currently recommended because of the possibility of malignancy and spillage of mucin-secreting cells throughout the abdomen.<sup>119</sup> Because of an association with colon and rectal carcinoma, a screening colonoscopy is recommended postoperatively.<sup>117</sup>

Mucinous cystadenocarcinoma represents the malignant form of cystic neoplasms of the appendix. In contrast to cystadenoma, patients are usually symptomatic with abdominal



**FIGURE 31-9** A 14-cm mucinous cystadenoma of the appendix. The appendiceal tip is to the left, the base to the right. (Used, with permission, from Jacqueline M. Wilson, MD, PhD, Brigham and Women's Hospital, Boston, MA.)



**FIGURE 31-10** CT axial image at the level of the terminal ileum shows a fluid-filled mass (*arrowhead*) corresponding to the mucinous cystadenoma seen in Fig 31-9. The more proximal appendix (*arrow*) is seen between the mass and cecum. (Used, with permission, from M. Stephen Ledbetter, MD, Brigham and Women's Hospital, Boston, MA.)

pain, weight loss, an abdominal mass, or signs of acute appendicitis. Increasing abdominal girth may also be present and suggests development of pseudomyxoma peritonei from perforation and peritoneal dissemination of mucin-secreting cells. Diffuse pseudomyxoma peritonei is highly predictive of malignancy; in one series, 95% of patients with pseudomyxoma had an associated mucinous cystadenocarcinoma.<sup>117</sup> The recommended treatment consists of right hemicolectomy with debulking of any gross spread of disease and removal of all mucin. It is not uncommon, however, for the diagnosis to be unknown until the time of pathologic evaluation of the appendectomy specimen. In such cases, reoperation with right hemicolectomy is recommended, as 5-year survival for mucinous cystadenocarcinoma is 75% after hemicolectomy and less than 50% after appendectomy alone.<sup>120</sup> Some referral centers advocate extensive initial resections including omentectomy, as well as repeated debulking procedures for recurrent disease.<sup>121</sup>

## Adenocarcinoma

Primary adenocarcinoma of the appendix is classified into two types: mucinous (discussed previously) and colonic. The colonic type is less common, less likely to secrete mucus, and more likely to present with acute appendicitis due to obstruction of the appendiceal lumen.<sup>116</sup> Because of similarities with colon carcinoma, appendiceal adenocarcinomas are classified as Dukes stage A, B, C, and D, with 5-year survival rates of 100, 67, 50, and 6%, respectively. The colonic type has a less favorable prognosis, with only 41% 5-year survival after

treatment, compared to 71% for the mucinous type. The optimal treatment is right hemicolectomy, and reoperation should be recommended if the diagnosis is made on pathologic evaluation of an appendectomy specimen.<sup>120</sup>

## Carcinoid Tumors

The most common neoplasm of the appendix, carcinoid tumors comprise more than 50% of all appendiceal tumors.<sup>114</sup> Among malignant tumors of the appendix, carcinoids are less aggressive and carry a much more favorable prognosis than adenocarcinomas, with 5-year survival approaching 90%.<sup>122</sup> Most appendiceal carcinoids are found incidentally at the time of appendectomy for appendicitis. However, because the majority of appendiceal carcinoids are located at the tip of the appendix, the carcinoid mass is the cause of appendicitis only 25% of the time.<sup>115</sup> Tumor size is the primary determinant of malignant potential. About 75% of carcinoids are less than 1 cm in size and 5–10% are over 2 cm. Lymph node invasion and distant metastases are exceedingly rare except in tumors over 2 cm.<sup>123</sup> Histologically, carcinoids of the appendix are categorized as goblet cell and classic carcinoid. Mortality is higher for goblet cell but is still lower than that of adenocarcinoma.<sup>122</sup>

Treatment of appendiceal carcinoids is dictated primarily by tumor size. Simple appendectomy is sufficient for tumors less than 1 cm because of the low likelihood of lymph node involvement. For masses larger than 2 cm, right hemicolectomy is recommended. Because of a concern for increased metastatic potential, some authors also advocate right hemicolectomy in young patients; in carcinoids at the appendiceal base; and when there is evidence of lymphatic invasion, lymph node involvement, spread to the mesoappendix, tumor-positive resection margins, or cellular pleomorphism with a high mitotic index.<sup>123–125</sup>

## Small Bowel Diverticula

Small bowel diverticula can be characterized according to their anatomic location (duodenal, jejunoileal, and distal ileal diverticula) or the type of diverticula (false or true diverticula). False diverticula do not contain all the layers of the bowel wall. They are acquired defects predominantly located in the duodenal and jejunoileal portions of the small bowel. These diverticula involve herniated mucosa and submucosa and typically occur at points of weakness, where blood vessels enter the mesenteric border of the small bowel. In contrast, a distal ileal (Meckel's) diverticulum is a true diverticulum containing all of the layers of the small bowel. It is a congenital anomaly resulting from the failure of the vitelline duct to obliterate and is located along the antimesenteric border of the distal ileum. Although the presence of small bowel diverticula is not uncommon, most are asymptomatic and thus not appreciated. Less than 4% of small bowel diverticula cause



symptoms, including inflammation, hemorrhage, obstruction, perforation, and malabsorption.

### DUODENAL DIVERTICULA

Duodenal diverticula (DD) account for approximately 45% of small bowel diverticula and have a reported incidence on radiologic and autopsy studies of 5–22%.<sup>126,127</sup> They are rarely multiple (12%) and are predominantly located in the medial wall of the second portion of the duodenum (88%).<sup>128</sup> When the diverticulum is located adjacent to the ampulla of Vater, as is often the case, it is known as a perivaterian or periampullary diverticulum. DD typically occur in patients aged 50–65 years and are often asymptomatic at presentation. Less than 5% of patients with DD present with symptoms, including nausea, vomiting, RUQ abdominal pain, fevers, chills, and bleeding. These presentations result from one of many potential complications, including inflammation, obstruction of the duodenum or biliary-pancreatic duct, fistula formation in the bile duct, bezoar formation inside the diverticulum, and perforation. Although it is the most unusual complication, DD perforation is the most serious and can carry a mortality of up to 20%. Perforation usually results from acute inflammation but may also result from enterolithiasis, ulceration, increased intraluminal pressure (eg, during endoscopy), abdominal trauma, gallstones, or ischemia. Perforation usually occurs posteriorly and can result in a retroperitoneal abscess and sepsis. Anterior perforation can also occur, resulting in intraperitoneal spillage or communication with the pancreas, colon, gallbladder, or aorta causing a duodenocolic fistula or acute gastrointestinal hemorrhage secondary to perforation into the aorta.<sup>126,129</sup>

The nonspecific nature of the presenting symptoms and their commonality with other gastrointestinal diseases such as pancreatitis, cholecystitis, cholangitis, and peptic ulcer disease highlight the fact that the diagnosis of a complicated DD is often one of exclusion. Radiologic studies including plain abdominal films and ultrasound may be helpful to exclude other etiologies but are not definitive. CT scan and upper endoscopy are the modalities of choice for evaluation. In the case of an inflamed diverticulum, CT may demonstrate a thickened duodenal wall and surrounding fat inflammation. If perforation has occurred, an extraluminal collection of air and fluid (predominantly retroperitoneal) may be identified. Additionally, the administration of oral contrast with a CT scan or an upper gastrointestinal swallow study may define the extent of a leak in the case of a perforation. However, it is not uncommon to be unable to identify a DD on CT scan, and additional studies may be required. Side-viewing endoscopy and endoscopic retrograde cholangiopancreatography (ERCP) are very valuable in correctly diagnosing the presence of a DD as well as potentially treating some of the associated complications. Successful endoscopic management of hemorrhage, duodenal obstruction, pancreatobiliary obstruction resulting in pancreatitis or cholangitis, and retroperitoneal abscess drainage associated with a DD have been reported.<sup>130–133</sup>

The management of DD depends on the presence or absence of symptoms and the clinical stability of the patient. Given the precarious location of a DD and the morbidity associated with resection, asymptomatic DD discovered on imaging or endoscopy for other reasons should be observed. Symptomatic DD can be managed endoscopically, nonoperatively, or with surgical exploration and resection or bypass. If inflammation with or without perforation is present, nonoperative management, including nasogastric decompression, antibiotics, serial examinations, and radiologic-guided drainage if an abscess is present, has been reported. This approach can be considered in patients with mild symptoms who are clinically stable or when CT confirms a contained leak.<sup>126,128,130,134</sup> If the patient is not a candidate for nonoperative management because of hemodynamic instability, generalized peritonitis, or persistent severe symptoms, the choice of surgical intervention depends on such factors as the location of the diverticulum and other intraoperative findings. A simple closure of the perforated diverticulum or diverticulectomy with single- or double-layer duodenal closure after Kocherizing the duodenum is the treatment of choice if there is minimal inflammation and the anatomy of the diverticulum permits. After repair, appropriate drainage tubes should be placed and the greater omentum can be used to reinforce the repair. It is imperative to avoid damaging the pancreatic and distal common bile duct during the repair, so cannulation of the ampulla of Vater either retrograde or antegrade through the cystic duct (with subsequent cholecystectomy) can be performed to help visualize the ampulla prior to dissecting the diverticulum. If there is significant inflammation at the site of the diverticulum or the diverticulum lies buried in the pancreatic head or the papilla lies deep in the diverticulum, a diversion should be performed. Diversion can be performed by either a distal gastrectomy with a Billroth-II reconstruction or a Roux-en-Y gastrojejunostomy. Again, appropriate drainage tubes are typically placed to drain the affected area. In addition to diversion and diverticulectomy, segmental duodenal resection for a perforated DD has also been reported for the rare case of a DD located in segment III or IV of the duodenum. A pancreaticoduodenectomy may also be necessary if the DD lies in close proximity to the common bile and pancreatic ducts and the inflammation is thought to be too severe for safe diversion or drainage.<sup>126,129,130</sup> If symptoms are related not to perforation of the DD but to obstruction of the pancreaticobiliary system causing cholangitis or pancreatitis, resection of the duodenum may not be required and treatment may consist of diversion of bile flow with a Roux-en-Y choledochojejunostomy and duodenojejunostomy.<sup>130,135</sup>

### JEJUNOILEAL DIVERTICULA

Least common of the small bowel diverticula, jejunoileal diverticula (JID) have an incidence of 0.002–5% based on postmortem and enteroclysis studies. Their incidence increases with age and peaks in the sixth and seventh decades of life. JID are

acquired pseudodiverticula believed to result from a jejunoileal dyskinesia causing increased intraluminal pressures and herniation of the mucosa and submucosa through the weakest site of the muscularis of the bowel wall (ie, the mesenteric border where paired blood vessels enter the bowel wall). They can be single (33%) or multiple (66%) and located in the jejunum (55–80%), ileum (15–38%), or both (5–7%).<sup>136</sup> Interestingly, patients with JID also frequently have other coexisting gastrointestinal diverticula, including those found in the colon (20–70%), duodenum (10–40%), esophagus, and stomach (2%) highlighting a potential common etiology.<sup>137–139</sup>

The diagnosis of a JID is often challenging because most patients are asymptomatic (up to 70%) or present with vague abdominal complaints. There is, in fact, no gold standard imaging technique used to diagnose a JID. Upper gastrointestinal studies with small bowel follow-through as well as traditional enteroclysis and CT enteroclysis studies are beneficial. CT, tagged red blood cell scan, or angiogram may demonstrate findings consistent with a complication of a JID such as inflammation, perforation, or bleeding. Capsule endoscopy and double-balloon endoscopy are useful in diagnosing small bowel disorders and may be of benefit in identifying JID in a nonacute setting.<sup>137,140,141</sup> Ultimately, JID are often identified on exploratory laparotomy or laparoscopy for other indications or for the evaluation of chronic or acute symptoms.<sup>137</sup>

Asymptomatic, incidentally discovered JID need not be resected. When symptomatic, patients with JID can be divided into those with acute or chronic symptoms. Forty to sixty percent of patients with a known diagnosis of JID present with chronic symptoms. These symptoms are often nonspecific and include nausea, vomiting, postprandial bloating, recurrent abdominal pain, cramping, weight loss, fatigue, and failure to thrive. Because of the vague nature of the presenting symptoms, these patients often go undiagnosed or misdiagnosed for several months (average 22 months) prior to being correctly diagnosed.<sup>136,141,142</sup> The pathophysiology of the chronic symptoms is believed to be related to either intestinal dyskinesia or bacterial overgrowth from blind loop syndrome due to stasis in the diverticular lumen. When bacterial overgrowth and a blind loop syndrome are present, the patient may develop malabsorption, steatorrhea, and megaloblastic anemia resulting from vitamin B<sub>12</sub> deficiency. Frequently, chronic symptoms from JID can be successfully managed medically. Medical management consists of a low-residue diet, antispasmodics, antacids, analgesics, and vitamin B<sub>12</sub> supplementation. Bacterial overgrowth and blind loop syndrome can be initially managed with antibiotics. If medical management fails, patients may require resection of the segment of bowel containing the diverticulum with subsequent primary anastomosis.

Approximately 10–19% of patients with JID present with acute, often emergent, symptoms resulting from a complication of the diverticulum, including gastrointestinal hemorrhage, diverticulitis with or without perforation, obstruction, fistula formation, sepsis, liver abscesses and pneumoperitoneum. The presentation and management of a patient with an acute complication of a JID depends on

the complication. Inflammation resulting in diverticulitis occurs in 2.3–6.4% of patients with JID and can present as mild abdominal pain or diffuse peritonitis associated with free perforation.<sup>136</sup> If perforation occurs in the setting of full-thickness necrosis, it can be associated with a mortality of up to 40%.<sup>136,143</sup> Traumatic and foreign body perforations of JID have also been described. If the perforation is contained within the mesentery, nonoperative management with bowel rest and antibiotics with or without percutaneous drainage can be attempted. Similarly, asymptomatic pneumoperitoneum in the setting of a known JID is not an indication for surgery and can be managed conservatively.<sup>136,144,145</sup> Lack of clinical improvement after a period of nonoperative management mandates resection of the affected segment of bowel with a primary anastomosis. Similarly, patients presenting with a more significant findings of fever, elevated WBC, peritonitis, and septic physiology require immediate laparotomy with resection of the affected segment of bowel.<sup>136</sup>

Of patients with JID, 2–4.6% present with obstruction related to adhesions, intussusception, volvulus, and extrinsic compression from a fluid-filled diverticulum or, rarely, from an enterolith formed in the diverticulum causing obstruction at the diverticulum or at the ileocecal valve. Obstruction believed to be secondary to adhesions can initially be managed conservatively. However, if nonoperative management fails, lysis of adhesions and segmental bowel resection of the JID with a primary anastomosis are required. Similarly, surgical resection is indicated for the management of obstruction resulting from intussusception, volvulus, or extrinsic compression.<sup>137</sup> Enterolith ileus associated with a JID is best managed by an initial attempt at manual lysis of the stone without an enterotomy. If not possible, the stone can be removed through an enterotomy made in a nonedematous segment of bowel. If one or multiple diverticula appear inflamed or scarred, segmental resection of the involved bowel with a primary anastomosis is mandated. However, many patients often have multiple diverticula over a long stretch of bowel, and thus, if no evidence of inflammation or scarring is present, no resection is indicated.<sup>136</sup> Approximately 3–8% of patients with JID present with bleeding complications. Hemorrhage from a JID can be slow and chronic in nature or acute and massive presenting with hemorrhagic shock. Upper and lower endoscopies are often negative, and the diagnosis is made with angiographic and radioactive red blood cell studies. Although treatment with angiographic embolization has been documented, segmental bowel resection is frequently the required treatment.<sup>136,146</sup>

## MECKEL'S DIVERTICULA

Meckel's diverticula are the most common congenital malformation of the gastrointestinal tract, occurring in approximately 1% of the population.<sup>147–149</sup> A Meckel's diverticulum is a true diverticulum containing all three layers of the intestinal wall and results from the failure of the obliteration of the omphalomesenteric duct during fetal life. It is typically

located on the antimesenteric border of the small bowel within 100 cm of the ileocecal valve. Although often lined with ileal mucosa, ectopic gastric, duodenal, colonic, and endometrial mucosa as well as pancreatic tissue, carcinoid tissue, Brunner's glands, and hepatobiliary tissue have been found in Meckel's diverticula.<sup>147</sup>

Similar to other small bowel diverticula, the majority of Meckel's diverticula are asymptomatic and discovered incidentally at the time of an operation for other indications. Recent reviews indicate that up to 84% of Meckel's diverticula found at operation were asymptomatic. A symptomatic Meckel diverticulum can present in both the pediatric and adult population; the frequency of presentation decreases with increasing age. There is a male predominance (3:1) of both symptomatic and asymptomatic Meckel's diverticula in both the pediatric and adult population.<sup>147,149</sup>

Symptomatic presentation results from one of many potential complications, including bleeding, obstruction, diverticulitis, perforation, intussusception, ulceration, and rarely the presence of malignancy (carcinoid tumor, sarcoma, stromal tumors, carcinoma, adenocarcinoma, intraductal papillary mucinous adenoma of pancreatic tissue) within the Meckel diverticulum. In the adult population the most common presentations are bleeding (38%), obstruction (34%), and diverticulitis (28%). In the pediatric population the most common presentations are obstruction (40%), bleeding (31%), and diverticulitis (29%).<sup>147,149</sup> Obstruction may result from the Meckel diverticulum serving as a lead point for intussusception or volvulus or as a result of an adhesive band to the diverticulum. Bleeding in the setting of a Meckel diverticulum is believed to result from acid secretion from ectopic gastric mucosa leading to ulceration of and subsequent bleeding from adjacent ileal mucosa.

Preoperative diagnosis of a symptomatic Meckel diverticulum can be difficult. A technetium-99m pertechnetate scan is the most common and accurate noninvasive study used to evaluate the presence of a Meckel diverticulum. The tracer used in this study is specific for ectopic gastric mucosa, and thus false-positive results may occur when a duplication cyst containing gastric mucosa is present. Moreover, a Meckel diverticulum can be missed if it does not contain ectopic gastric mucosa. Studies have found technetium-99m pertechnetate scans to be highly sensitive and specific in both the pediatric and adult populations.<sup>149-151</sup> In cases of a suspected bleeding, Meckel's diverticulum, angiography, and a tagged RBC scan may be of diagnostic value. If suspicion is high, other etiologies have been ruled out, and noninvasive diagnostic tools exhausted, exploratory laparoscopy may be required to diagnose and treat a complicated Meckel diverticulum.

Surgical resection is indicated for symptomatic Meckel's diverticula. Options for resection include a diverticulectomy or a segmental bowel resection with a primary anastomosis. A diverticulectomy can be performed if amputating the diverticulum at its base will not compromise the ileal lumen. If diverticulitis is present, the line of resection should be free of inflammation. Amputation should be performed in a transverse orientation and can utilize a surgical stapling device. The staple line can

then be oversewn with interrupted 3-0 silk Lembert sutures. Alternatively, the diverticulum can be resected between bowel clamps and the defect sutured closed in two layers, using a continuous inner layer of 3-0 Vicryl or chromic suture followed by an outer layer of 3-0 silk Lembert sutures.

In certain cases, simple diverticulectomy is not recommended. Such instances include the presence of diverticulitis or palpable ectopic tissue at the diverticular-intestinal junction.<sup>147</sup> In such cases, or if the Meckel diverticulum is associated with ischemia, perforation, or an ulcer in the adjacent intestine, a segmental ileal resection with a primary anastomosis is indicated.

The optimum management of an asymptomatic Meckel diverticulum discovered at laparotomy for a separate indication remains unclear. Some authors argue that certain asymptomatic patients are more likely to develop symptoms and thus recommend resection of an incidentally detected diverticulum in a patient who fulfills any of the following criteria: (1) younger than 50 years, (2) male sex, (3) diverticulum greater than 2 cm in length, and (4) ectopic or abnormal features within a diverticulum.<sup>147</sup> A recent review contradicts these findings, however. In this study, the risk of postoperative complications, including infection and intestinal obstruction, was significantly higher following resection than leaving the diverticulum in situ (5.3 vs 1.3%). Moreover, of the 64 patients in this study who did not undergo resection of their asymptomatic Meckel's diverticulum, no patient developed complications with long-term follow-up.<sup>148</sup> Another study found the morbidity associated with the resection of an incidental Meckel diverticulum to be higher than that associated with the resection of a symptomatic Meckel diverticulum (20 vs 13%).<sup>147</sup> Based on these studies, there is no convincing evidence to recommend resection of a Meckel diverticulum detected incidentally at laparotomy, but it should be considered in certain patient populations.

## REFERENCES

1. Meade RH. *An Introduction to the History of General Surgery*. Philadelphia, PA: Saunders; 1968.
2. Richardson RG. *The Surgeon's Tale*. New York, NY: Scribner's; 1958.
3. Williams RA, Myers P. *Pathology of the Appendix*. London, England: Chapman & Hall; 1994.
4. Da Capri JB. *Commentaria cum Amplissimus Additionibus Super Anatomia Mundini Una cum Texta Ejusdem in Pristinum et Verum Nitorem Redanto*. 528 ff. Bolonia Imp. per H. Benedictus, 1521.
5. Vesalius A. *De Humani Corporis Fabrica Liber V*. Basel, Switzerland: Johannes Oporinu; 1543.
6. Thomas CG. *Classic Description of Disease*. Springfield; 1932.
7. Amyand C. Of an inguinal rupture, with a pin in the appendix caeci, incrustrated with stone, and some observations on wounds in the guts. *Philos Trans R Soc Lond*. 1736;39:329-342.
8. Thoulfas G, Howe JR. Amyand's hernia: Appendicitis in an incarcerated hernia. *Surg Rounds*. 2004;27:515-517.
9. Tait L. Surgical treatment of typhlitis. *Birmingham Med Rev*. 1890; 27:26-34.
10. Fitz RH. Perforating inflammation of the vermiform appendix; with special reference to its early diagnosis and treatment. *Am J Med Sci*. 1886;92:321-346.
11. McBurney CM. Experience with early operative interference in cases of disease of the vermiform appendix. *NY Med J*. 1889;50:676-684.



12. Treves F. A series of cases of relapsing typhlitis treated by operation. *BMJ*. 1893;i:835–837.
13. Addiss DG, Shaffer N, Fowler BS, et al. The epidemiology of appendicitis and appendectomy in the United States. *Am J Epidemiol*. 1990;132:910–925.
14. Burkitt DP. The aetiology of appendicitis. *Br J Surg*. 1971;58:695–699.
15. Jones BA, Demetriades D, Segal I, et al. The prevalence of appendiceal fecaliths in patients with and without appendicitis. A comparative study from Canada and South Africa. *Ann Surg*. 1985;202:80–82.
16. Wangensteen OH, Buirge RE, Dennis C, et al. Studies in the etiology of acute appendicitis: the significance of the structure and function of the vermiform appendix in the genesis of appendicitis. *Ann Surg*. 1937;106:910–942.
17. Wangensteen OH, Dennis C. Experimental proof of the obstructive origin of appendicitis in man. *Ann Surg*. 1939;110:629–647.
18. Teicher I, Landa B, Cohen M, et al. Scoring system to aid in diagnoses of appendicitis. *Ann Surg*. 1983;198:753–759.
19. Nitecki S, Karmeli R, Sarr MG. Appendiceal calculi and fecaliths as indications for appendectomy. *Surg Gynecol Obstet*. 1990;171:185–188.
20. Arnbjornsson E, Bengmark S. Obstruction of the appendix lumen in relation to pathogenesis of acute appendicitis. *Acta Chir Scand*. 1983;149:789–791.
21. Temple CL, Huchcroft SA, Temple WJ. The natural history of appendicitis in adults. A prospective study. *Ann Surg*. 1995;221:278–281.
22. Velanovich V, Satava R. Balancing the normal appendectomy rate with the perforated appendicitis rate: implications for quality assurance. *Am Surg*. 1992;58:264–269.
23. Hale DA, Jaques DP, Molloy M, et al. Appendectomy. Improving care through quality improvement. *Arch Surg*. 1997;132:153–157.
24. Pittman-Waller VA, Myers JG, Stewart RM, et al. Appendicitis: why so complicated? Analysis of 5755 consecutive appendectomies. *Am Surg*. 2000;66:548–554.
25. Baril N, Wren S, Radin R, et al. The role of anticoagulation in pylephlebitis. *Am J Surg*. 1996;172:449–452.
26. Mangi AA, Berger DL. Stump appendicitis. *Am Surg*. 2000;66:739–741.
27. Wagner JM. Likelihood ratios to determine 'Does this patient have appendicitis?': Comment and clarification. *JAMA*. 1997;278:819–820.
28. Wagner JM, McKinney WP, Carpenter JL. Does this patient have appendicitis? *JAMA*. 1996;276:1589–1594.
29. Thompson MM, Underwood MJ, Dookeran KA, et al. Role of sequential leucocyte counts and C-reactive protein measurements in acute appendicitis. *Br J Surg*. 1992;79:822–824.
30. Alvarado A. A practical score for the early diagnosis of acute appendicitis. *Ann Emerg Med*. 1986;15:557–564.
31. Saidi RF, Ghasemi M. Role of Alvarado score in diagnosis and treatment of suspected acute appendicitis. *Am J Emerg Med*. 2000;18:230–231.
32. Wise SW, Labuski MR, Kasales CJ, et al. Comparative assessment of CT and sonographic techniques for appendiceal imaging. *AJR Am J Roentgenol*. 2001;176:933–941.
33. Terasawa T, Blackmore CC, Bent S, et al. Systematic review: computed tomography and ultrasonography to detect acute appendicitis in adults and adolescents. *Ann Intern Med*. 2004;141:537–546.
34. Rao PM, Rhea JT, Rattner DW, et al. Introduction of appendiceal CT: impact on negative appendectomy and appendiceal perforation rates [see comment]. *Ann Surg*. 1999;229:344–349.
35. Balthazar EJ, Birnbaum BA, Yee J, et al. Acute appendicitis: CT and US correlation in 100 patients. *Radiology*. 1994;190:31–35.
36. Horton MD, Counter SE, Florence MG, et al. A prospective trial of computed tomography and ultrasonography for diagnosing appendicitis in the atypical patient [see comment]. *Am J Surg*. 2000;179:379–381.
37. Rao PM, Rhea JT, Novelline RA, et al. Effect of computed tomography of the appendix on treatment of patients and use of hospital resources. *N Engl J Med*. 1998;338:141–146.
38. Cullen JJ, Kelly KA, Moir CR, et al. Surgical management of Meckel's diverticulum. An epidemiologic, population-based study [see comment]. *Ann Surg*. 1994;220:564–568.
39. Bizer LS. Acute appendicitis is rarely the initial presentation of cecal cancer in the elderly patient. *J Surg Oncol*. 1993;54:45–46.
40. Flum DR, Morris A, Koepsell T, et al. Has misdiagnosis of appendicitis decreased over time? A population-based analysis. *JAMA*. 2001;286:1748–1753.
41. Bratton SL, Haberkern CM, Waldhausen JH. Acute appendicitis risks of complications: age and Medicaid insurance. *Pediatrics*. 2000;106:75–78.
42. Puig S, Staudenherz A, Felder-Puig R, et al. Imaging of appendicitis in children and adolescents: useful or useless? A comparison of imaging techniques and a critical review of the current literature. *Semin Roentgenol*. 2008;43:22–28.
43. Garcia Pena BM, Mandl KD, Kraus SJ, et al. Ultrasonography and limited computed tomography in the diagnosis and management of appendicitis in children. *JAMA*. 1999;282:1041–1046.
44. Doria AS, Moineddin R, Kellenberger CJ, et al. US or CT for diagnosis of appendicitis in children and adults? A meta-analysis. *Radiology*. 2006;241:83–94.
45. Wiersma F, Sramek A, Holscher HC. US features of the normal appendix and surrounding area in children. *Radiology*. 2005;235:1018–1022.
46. Joesphson T, Stryud J, Eriksson S. Ultrasonography in acute appendicitis. Body mass index as selection factor for US examination. *Acta Radiol*. 2000;41:486–488.
47. Brenner D, Elliston C, Hall E, et al. Estimated risks of radiation-induced fatal cancer from pediatric CT. *AJR Am J Roentgenol*. 2001;176:289–296.
48. Donnelly LF, Emery KH, Brody AS, et al. Minimizing radiation dose for pediatric body applications of single detector helical CT: strategies at a large Children's Hospital. *AJR Am J Roentgenol*. 2001;176:303–306.
49. Watters JM, Blaklee JM, March RJ, et al. The influence of age on the severity of peritonitis. *Can J Surg*. 1996;39:142–146.
50. Paajanen H, Kettunen J, Kostiainen S. Emergency appendectomies in patients over 80 years. *Am Surg*. 1994;60:950–953.
51. Tamir IL, Bongard FS, Klein SR. Acute appendicitis in the pregnant patient. *Am J Surg*. 1990;160:571–575.
52. Mourad J, Elliott JB, Erickson L, et al. Appendicitis in pregnancy: new information that contradicts long-held clinical beliefs. *Am J Obstet Gynecol*. 2000;182:1027–1029.
53. To WW, Ngai CS, Ma HK. Pregnancies complicated by acute appendicitis. *Aust N Z J Surg*. 1995;65:799–803.
54. Baer JL, Reis RA, Arens RA. Appendicitis in pregnancy with changes in position and axis of the normal appendix in pregnancy. *JAMA*. 1932;98:1359–1364.
55. Brown JJS, Wilson C, Coleman S, et al. Appendicitis in pregnancy: an ongoing diagnostic dilemma. *Colorectal Dis*. 2009;11:116–122.
56. Lim HK, Bae SH, Seo GS. Diagnosis of acute appendicitis in pregnant women: value of sonography. *AJR Am J Roentgenol*. 1992;159:539–542.
57. Anonymous. ACOG Committee Opinion: guidelines for diagnostic imaging during pregnancy. *Obstet Gynecol*. 2004;104:647–651.
58. Ames Castro M, Shipp TD, Castro EE, et al. The use of helical computed tomography in pregnancy for the diagnosis of acute appendicitis. *Am J Obstet Gynecol*. 2001;184:954–957.
59. Brent RL. The effect of embryonic and fetal exposure to x-ray, microwaves, and ultrasound: counseling the pregnant and nonpregnant patient about these risks. *Semin Oncol*. 1989;16:347–368.
60. Basaran A, Basaran M. Diagnosis of acute appendicitis during pregnancy: a systemic review. *Obstet Gynecol Surv*. 2009;64:481–488.
61. Mahmoodian S. Appendicitis complicating pregnancy. *South Med J*. 1992;85:19–24.
62. Curet MJ, Allen D, Josloff RK, et al. Laparoscopy during pregnancy. *Arch Surg*. 1996;131:546–551.
63. Fatum M, Rojansky N. Laparoscopic surgery during pregnancy. *Obstet Gynecol Surv*. 2001;56:50–59.
64. Lemieux P, Rheume P, Levesque I, et al. Laparoscopic appendectomy in pregnant patients: a review of 45 cases. *Surg Endosc*. 2009;23:1701–1705.
65. Kirshtein B, Perry ZH, Avinoach E, et al. Safety of laparoscopic appendectomy during pregnancy. *World J Surg*. 2009;33:475–480.
66. Whitney TM, Macho JR, Russell TR, et al. Appendicitis in acquired immunodeficiency syndrome. *Am J Surg*. 1992;164:467–470.
67. Flum DR, Steinberg SD, Sarkis AY, et al. Appendicitis in patients with acquired immunodeficiency syndrome. *J Am Coll Surg*. 1997;184:481–486.
68. Coldrey E. Five years of conservative treatment of acute appendicitis. *J Int Coll Surg*. 1959;32:255–261.
69. Eriksson S, Tisel A, Granstrom L. Ultrasonographic findings after conservative treatment of acute appendicitis and open appendicectomy. *Acta Radiologica*. 1995;36:173–177.
70. Hansson J, Korner U, Khorram-Manesh A, et al. Randomized clinical trial of antibiotic therapy versus appendectomy as primary treatment of acute appendicitis in unselected patients. *Br J Surg*. 2009;96:473–481.
71. Campbell MR, Johnston SL 3rd, Marshburn T, et al. Nonoperative treatment of suspected appendicitis in remote medical care environments:

- implications for future spaceflight medical care. *J Am Coll Surg.* 2004;198:822–830.
72. Andersen BR, Kallehave FL, Andersen HK. Antibiotics versus placebo for prevention of postoperative infection after appendectomy. *Cochrane Database Syst Rev.* 2005;3:CD001439.
  73. Bauer T, Vennits B, Holm B, et al. Antibiotic prophylaxis in acute non-perforated appendicitis. The Danish Multicenter Study Group III. *Ann Surg.* 1989;209:307–311.
  74. Danish Multicenter Study Group. A Danish multicenter study: cefoxitin versus ampicillin + metronidazole in perforated appendicitis. *Br J Surg.* 1984;71:144–146.
  75. Frazee RC, Roberts JW, Symmonds RE, et al. A prospective randomized trial comparing open versus laparoscopic appendectomy. *Ann Surg.* 1994;219:725–728.
  76. Martin LC, Puente I, Sosa JL, et al. Open versus laparoscopic appendectomy. A prospective randomized comparison. *Ann Surg.* 1995;222:256–261.
  77. McCall JL, Sharples K, Jadallah F. Systematic review of randomized controlled trials comparing laparoscopic with open appendectomy. *Br J Surg.* 1997;84:1045–1050.
  78. Golub R, Siddiqui F, Pohl D. Laparoscopic versus open appendectomy: a metaanalysis. *J Am Coll Surg.* 1998;186:545–553.
  79. Sauerland S, Lefering R, Neugebauer EA. Laparoscopic versus open surgery for suspected appendicitis. *Cochrane Database Syst Rev.* 2004;4:CD001546.
  80. Cox MR, McCall JL, Padbury RT, et al. Laparoscopic surgery in women with a clinical diagnosis of acute appendicitis. *Med J Aust.* 1995;162:130–132.
  81. Larsson PG, Henriksson G, Olsson M, et al. Laparoscopy reduces unnecessary appendectomies and improves diagnosis in fertile women. A randomized study. *Surg Endosc.* 2001;15:200–202.
  82. McBurney CM. The incision made in the abdominal wall in cases of appendicitis, with a description of a new method of operating. *Ann Surg.* 1894;20:38–43.
  83. Mosdell DM, Morris DM, Fry DE. Peritoneal cultures and antibiotic therapy in pediatric perforated appendicitis. *Am J Surg.* 1994;167:313–316.
  84. Bilik R, Burnweit C, Shandling B. Is abdominal cavity culture of any value in appendicitis? *Am J Surg.* 1998;175:267–270.
  85. Kingsley DP. Some observations on appendectomy with particular reference to technique. *Br J Surg.* 1969;56:491–496.
  86. Arnbjörnsson E. Invagination of the appendiceal stump for the reduction of peritoneal bacterial contamination. *Curr Surg.* 1985;42:184–187.
  87. Watters DA, Walker MA, Abernethy BC. The appendix stump: should it be invaginated? *Ann R Coll Surg Eng.* 1984;66:92–93.
  88. Engstrom L, Fenyo G. Appendectomy: assessment of stump invagination versus simple ligation: a prospective, randomized trial. *Br J Surg.* 1985;72:971–972.
  89. Street D, Bodai BI, Owens LJ, et al. Simple ligation vs stump inversion in appendectomy. *Arch Surg.* 1988;123:689–690.
  90. Poole GV. Management of the difficult appendiceal stump: how I do it. *Am Surg.* 1993;59:624–625.
  91. Lemieur TP, Rodriguez JL, Jacobs DM, et al. Wound management in perforated appendicitis. *Am Surg.* 1999;65:439–443.
  92. Motson RW, Kelly MD. Simplified technique for laparoscopic appendectomy [see comment]. *ANZ J Surg.* 2002;72:294–295.
  93. Greenall MJ, Evans M, Pollock AV. Should you drain a perforated appendix? *Br J Surg.* 1978;65:880–882.
  94. Petrowsky H, Demartins N, Rousson V, et al. Evidence-based value of prophylactic drainage in gastrointestinal surgery: a systematic review and meta-analysis. *Ann Surg.* 2004;240:1074–1085.
  95. Cohn SM, Giannotti G, Ong AW, et al. Prospective randomized trial of two wound management strategies for dirty abdominal wounds. *Ann Surg.* 2001;233:409–413.
  96. Brasel KJ, Borgstrom DC, Weigelt JA. Cost-utility analysis of contaminated appendectomy wounds. *J Am Coll Surg.* 1997;184:23–30.
  97. Skoubo-Kristensen E, Hvid I. The appendiceal mass: results of conservative management. *Ann Surg.* 1982;196:584–587.
  98. Nitecki S, Assalia A, Schein M. Contemporary management of the appendiceal mass. *Br J Surg.* 1993;80:18–20.
  99. Oliak D, Yamini D, Udani VM, et al. Initial nonoperative management for periappendiceal abscess. *Dis Colon Rectum.* 2001;44:936–941.
  100. Bagi P, Dueholm S. Nonoperative management of the ultrasonically evaluated appendiceal mass. *Surgery.* 1987;101:602–605.
  101. Jeffrey RB Jr, Federle MP, Tolentino CS. Periappendiceal inflammatory masses: CT-directed management and clinical outcome in 70 patients [erratum appears in *Radiology* 1988;168:286]. *Radiology.* 1988;167:13–16.
  102. Brown CV, Abrishami M, Muller M, et al. Appendiceal abscess: immediate operation or percutaneous drainage? *Am Surg.* 2003;69:829–832.
  103. Mazziotti MV, Marley EF, Winthrop AL, et al. Histopathologic analysis of interval appendectomy specimens: support for the role of interval appendectomy. *J Pediatr Surg.* 1997;32:806–809.
  104. Freitas MS, Glick PL. Interval appendectomy for acute appendicitis. *J Pediatr Surg.* 2009;44:1056–1058.
  105. Lugo JZ, Avgerinos DV, Lefkowitz AJ, et al. Can interval appendectomy be justified following conservative treatment of perforated acute appendicitis? *J Surg Res.* 2009. [Epub]
  106. Andersson RE, Petzold MG. Nonsurgical treatment of appendiceal abscess or phlegmon: a systematic review and meta-analysis. *Ann Surg.* 2007;246:741–748.
  107. Hoffmann J, Lindhard A, Jensen HE. Appendix mass: conservative management without interval appendectomy. *Am J Surg.* 1984;148:379–382.
  108. Nguyen DB, Silen W, Hodin RA. Interval appendectomy in the laparoscopic era. *J Gastrointest Surg.* 1999;3:189–193.
  109. Flum DR, Koepsell T. The clinical and economic correlates of misdiagnosed appendicitis: nationwide analysis. *Arch Surg.* 2002;137:799–804.
  110. Grunewald B, Keating J. Should the 'normal' appendix be removed at operation for appendicitis? *J R Coll Surg Edinb.* 1993;38:158–160.
  111. Mattei P, Sola JE, Yeo CJ. Chronic and recurrent appendicitis are uncommon entities often misdiagnosed. *J Am Coll Surg.* 1994;178:385–389.
  112. Klingensmith ME, Soybel DI, Brooks DC. Laparoscopy for chronic abdominal pain. *Surg Endosc.* 1996;10:1085–1087.
  113. Lowe LH, Penney MW, Scheker LE, et al. Appendicolith revealed on CT in children with suspected appendicitis: how specific is it in the diagnosis of appendicitis? *AJR Am J Roentgenol.* 2000;175:981–984.
  114. Connor SJ, Hanna GB, Frizelle FA. Appendiceal tumors: retrospective clinicopathologic analysis of appendiceal tumors from 7,970 appendectomies. *Dis Colon Rectum.* 1998;41:75–80.
  115. Deans GT, Spence RA. Neoplastic lesions of the appendix. *Br J Surg.* 1995;82:299–306.
  116. Pickhardt PJ, Levy AD, Rohrmann CA Jr, et al. Primary neoplasms of the appendix: radiologic spectrum of disease with pathologic correlation [erratum appears in *Radiographics* 2003;23:1340]. *Radiographics.* 2003;23:645–662.
  117. Stocchi L, Wolff BG, Larson DR, et al. Surgical treatment of appendiceal mucocele. *Arch Surg.* 2003;138:585–589.
  118. Higa E, Rosai J, Pizzimbono CA, et al. Mucosal hyperplasia, mucinous cystadenoma, and mucinous metastadenocarcinoma of the appendix. A re-evaluation of appendiceal "mucocele." *Cancer.* 1973;32:1525–1541.
  119. Gonzalez Moreno S, Shmookler BM, Sugarbaker PH. Appendiceal mucocele. Contraindication to laparoscopic appendectomy. *Surg Endosc.* 1998;12:1177–1179.
  120. Nitecki SS, Wolff BG, Schlinkert R, et al. The natural history of surgically treated primary adenocarcinoma of the appendix. *Ann Surg.* 1994;219:51–57.
  121. Smith JW, Kemeny N, Caldwell C, et al. Pseudomyxoma peritonei of appendiceal origin. The Memorial Sloan-Kettering Cancer Center experience. *Cancer.* 1992;70:396–401.
  122. McCusker ME, Cote TR, Clegg LX, et al. Primary malignant neoplasms of the appendix: a population-based study from the surveillance, epidemiology and end-results program, 1973–1998. *Cancer.* 2002;94:3307–3312.
  123. Roggo A, Wood WC, Ottinger LW. Carcinoid tumors of the appendix. *Ann Surg.* 1993;217:385–390.
  124. Gouzi JL, Laigneau P, Delalande JP, et al. Indications for right hemicolectomy in carcinoid tumors of the appendix. The French Associations for Surgical Research. *Surg Gynecol Obstet.* 1993;176:543–547.
  125. Goede AC, Caplin ME, Winslet MC. Carcinoid tumour of the appendix. *Br J Surg.* 2003;90:1317–1322.
  126. Martinez-Cecilia D, Arjona-Sanchez A, Gomez-Alvarez M, et al. Conservative management of perforated duodenal diverticulum: a case report and review of the literature. *World J Gastroenterol.* 2008;14:1949–1951.
  127. Chui EJ, Shyr YM, Su CH, Wu CW, Lui WY. Diverticular disease of the small bowel. *Hepatogastroenterology.* 2000;47:181–184.
  128. Jang LC, Kim SW, Park YH, et al. Symptomatic duodenal diverticulum. *World J Surg.* 1995;19:729–733.

129. Andromanos N, Filippou D, Skandalakis P, et al. An extended retroperitoneal abscess caused by duodenal diverticulum perforation: report of a case and short review of the literature. *Am Surg.* 2007;73:85–88.
130. Schnueriger B, Vorburger SA, Banz VM, et al. Diagnosis and management of the symptomatic duodenal diverticulum: a case series and short review of the literature. *J Gastrointest Surg.* 2008; 12:1571–1576.
131. Eeckhout G, Vanstiphout J, Van Pottelbergh I, et al. Endoscopic treatment of a perforated duodenal diverticulum. *Endoscopy.* 2000;32:991–993.
132. Lee SH, Park SH, Lee JH, et al. Endoscopic diverticulotomy with an isolated-tip papillotome (Iso-Tome) in a patient with intraluminal duodenal diverticulum. *Gastrointest Endosc.* 2005;62:817–819.
133. Plath F, Brock P, Hasse N, et al. Vegetable stalk as a nidus for gallstone formation in a patient with a juxtapapillary duodenal diverticulum. *Gastrointest Endosc.* 2002;56:944–946.
134. Marhin WW, Amson BJ. Management of perforated duodenal diverticula. *Can J Surg.* 2005;48:79–80.
135. Vassilakis JS, Tzovaras G, Chrysos E, et al. Roux-Y choledochojejunostomy and duodenojejunostomy for the complicated duodenal diverticulum. *Am J Surg.* 1997;174:45–48.
136. Woods K, Williams E, Melvin W, Sharp K. Acquired jejunoileal diverticulosis and its complications: a review of the literature. *Am Surg.* 2008;74:849–854.
137. Kassahun WT, Fangmann J, Harms J, et al. Complicated small-bowel diverticulosis: a case report and review of the literature. *World J Gastroenterol.* 2007;13:2240–2242.
138. Wilcox RD, Shatney CH. Surgical significance of acquired ileal diverticulosis. *Am Surg.* 1990;56:222–225.
139. Chow DC, Babaian M, Taubin HL. Jejunoileal diverticula. *Gastroenterologist.* 1997;5:78–84.
140. Ell C, May A, Nachbar L, Cellier C, et al. Push-and-pull enteroscopy in the small bowel using the double-balloon technique: results of a prospective European multicenter study. *Endoscopy.* 2005;37:613–616.
141. Makris K, Tsiotos GG, Stafyla V, et al. Small intestinal nonmeckelian diverticulosis. *J Clin Gastroenterol.* 2009;43:201–207.
142. Tsiotos GG, Farnell MB, Ilstrup DM. Nonmeckelian jejunal or ileal diverticulosis: an analysis of 112 cases. *Surgery.* 1994;116:726–731.
143. Chendrasekhar A, Timberlake GA. Perforated jejunal diverticula: an analysis of reported cases. *Am Surg.* 1995;61:984–988.
144. Cunningham SC, Gannon CJ, Napolitano LM. Small-bowel diverticulosis. *Am J Surg.* 2005;190:37–38.
145. Dunn V, Nelson JA. Jejunal diverticulosis and chronic pneumoperitoneum. *Gastrointest Radiol.* 1979;15:165–168.
146. El-Haddawi F, Civil ID. Acquired jejuno-ileal diverticular disease: a diagnostic and management challenge. *ANZ J Surg.* 2003;73:584–589.
147. Park JJ, Wolff BG, Tollefson MK, et al. Meckel diverticulum: the Mayo Clinic experience with 1476 patients (1950–2002). *Ann Surg.* 2005;241:529–533.
148. Zani A, Eaton S, Rees CM, et al. Incidentally detected Meckel diverticulum: to resect or not to resect? *Ann Surg.* 2008;247:276–281.
149. Sagar J, Kumar V, Shah DK. Meckel's diverticulum: a systematic review. *J R Soc Med* 2006;99:501–505.
150. Kong MS, Chen CY, Tzen KY, et al. Technetium-99m pertechnetate scan for ectopic gastric mucosa in children with gastrointestinal bleeding. *J Formos Med Assoc.* 1993;92:717–720.
151. Lin S, Suhocki PV, Ludwig KA, et al. Gastrointestinal bleeding in adult patients with Meckel's diverticulum: the role of technetium 99m pertechnetate scan. *South Med J.* 2002;95:1338–1341.



*This page intentionally left blank*

# DIVERTICULAR DISEASE AND COLONIC VOLVULUS

Thang C. Nguyen • Frank A. Frizelle

Diverticular disease and colonic volvulus are common colonic conditions. Though benign in pathology, their management results in a major workload and the diseases are not without risk of major complications, including death. In this chapter we discuss the current understanding of these two pathologies.

## DIVERTICULAR DISEASE

Colonic diverticula are the most common structural abnormality of the bowel and is the fifth most costly gastrointestinal disorder in Western society.<sup>1,2</sup> An acquired condition, diverticula usually affect the sigmoid colon in Western societies, but they are also found on the right colon in countries with diets rich in fiber. The prevalence of diverticular disease has increased during the last century,<sup>3</sup> which probably reflects both an increase in detection and an aging population. Until 30 years ago, the proportion of patients requiring surgery or dying from diverticular disease was decreasing<sup>4</sup>; however, during the last 20 years, the rates of hospital admission and surgical intervention have increased, while inpatient and population mortality rates from diverticular disease have remained unchanged.<sup>5</sup>

Colonic diverticulum is an acquired condition with increased prevalence with increasing age. It affects fewer than 10% of people in their fifth decade of life, increasing to around 50–66% in their ninth decade.<sup>6</sup> Most patients with diverticulosis don't require surgery; however, complications of diverticular disease may. Such surgery can be challenging and good outcomes rely on timely and appropriate intervention.

The terminologies used include diverticulum (diverticula—plural); diverticulosis—asymptomatic diverticula; diverticulitis (simple or complicated)—diverticula with inflammation; diverticular disease—diverticula with or without inflammation.

## History

Diverticular disease was initially described by Littré in 1700 as saccular outpouchings of the colon.<sup>7</sup> Cruveilhier is credited with the first clear and detailed description of the pathogenesis of diverticulitis and complicated diverticular disease.<sup>8</sup> In

1899 Graser introduced the term “peridiverticulitis” and suggested that diverticula were caused by herniation of colonic mucosa through areas of penetration of the vasa recta. This is now well established as the pathogenesis of colonic diverticulosis.<sup>9</sup> In contrast, the mechanism for diverticulitis was not identified until 1904 by Beer.<sup>10</sup> He proposed that impacted fecal matter at the neck of the diverticulum caused inflammation and subsequent abscess and fistula formation.

Moynihan reported a case of peridiverticulitis in 1907 and underlined the difficulties in distinguishing diverticular disease from malignancy.<sup>11</sup> Telling and Gruner's classic paper describing complex diverticular disease was not published until 1917.<sup>12</sup> At this time the prevalence and pathophysiology of diverticular disease were well recognized, as were the complications, including acute diverticulitis, abscess, fistula, perforation, and obstruction.

The development of radiological imaging of the large intestine was important in establishing a diagnosis and documenting the extent of diverticular disease.<sup>13</sup> In 1914, De Quervain and Case were the first to demonstrate colonic diverticula with x-rays.<sup>14,15</sup>

## Etiology

Diverticular disease is a disease of Western populations. A number of studies have shown an increase in incidence over the last 30 years.<sup>5,16</sup> Migrant studies likewise confirm an increase in incidence when populations move to a Western country. There is a widely held view that fiber content of food is important, and that the high intraluminal pressure associated with low-fiber diets precipitated by colonic compartmentalization causes an unsustainable increase in tension within the bowel wall. This is compounded by the hyperrelaxation and altered collagen structure seen in the colon due to aging.<sup>17,18</sup> Both mechanisms ultimately lead to a loss of bowel wall integrity and the formation of diverticula. Exercise and a reduction in the intraluminal pressure associated with a high-fiber diet may be protective.<sup>19</sup>

High intraluminal pressures are generated because of colonic motility. Colonic motility is complex and not easily studied.

The most common motor patterns are tonic segmenting and rhythmic contraction. Tonic segmentation creates stationary narrow rings that appear as haustral markings. Their purpose is to slow the fecal stream and to permit water absorption and electrolyte exchange. Infrequent propulsive peristaltic contractions move fecal matter in a caudal direction; these occur around six times a day.<sup>20</sup>

The alteration in pressure caused by these movements has been implicated in the pathogenesis of colonic diverticulosis. Several groups have studied colonic motility with intraluminal manometry in humans and animals. Most studies agree that there is increased phasic pressure activity, but this relates more to the presence of symptoms rather than diverticula. The results, however, are heterogeneous, principally because of methodological differences, in particular relating to bowel preparation and pressure sensors.<sup>21</sup> It may therefore be unreasonable to draw firm conclusions from these investigations.<sup>22</sup>

More generalized alterations in colonic motility have been implicated in the pathogenesis of colonic diverticular disease. In vitro and in vivo studies, however, are conflicting. Some demonstrate an absence of slow-wave activity (favoring nonpropagating contractile activity) and some demonstrate unimpaired or increased slow-wave activity.<sup>23,24</sup> Others have demonstrated an increase in fast-wave activity, which persists after resectional surgery.<sup>25</sup> The exact relevance of these myoelectric changes remains uncertain.

Diverticulosis is a Western disease that has a striking geographic distribution. The disease is rare in rural Africa and Asia with the highest prevalence seen in the United States, Europe, and Australia.<sup>26</sup> Within a single country, the disease incidence can vary depending on ethnicity.<sup>27</sup> Urbanization can also increase diverticular disease incidence, possibly attributable to a dietary change.<sup>28,29</sup> The incidence of complicated diverticular disease also seems to be increasing.<sup>30</sup>

Diverticular disease in Asian patients is often right-sided with manifestations early in life and is often multiple. The reasons for this variation are unknown; however, it has been suggested that both diet and elastin/collagen differences may play a role.<sup>31</sup>

## Morphologic Features

Colonic diverticula are false diverticula most commonly found in the sigmoid colon (95%). The sigmoid colon is the exclusive site in about 50% and the entire colon is involved in just 5%. The muscular colonic wall is composed of both longitudinal and circular layers. The circular layer of the muscularis propria forms a continuous sheet of muscle throughout the large bowel. The longitudinal layer forms three discrete condensations called *taeniae*; one of these is adjacent to the mesentery while the other two are antimesenteric. The *taeniae* coalesce to form an enveloping muscular layer in the rectum. Much of the colonic wall is therefore devoid of longitudinal muscle and it is in these areas that diverticula form. Herniations of muscularis mucosa occur between the *taeniae*

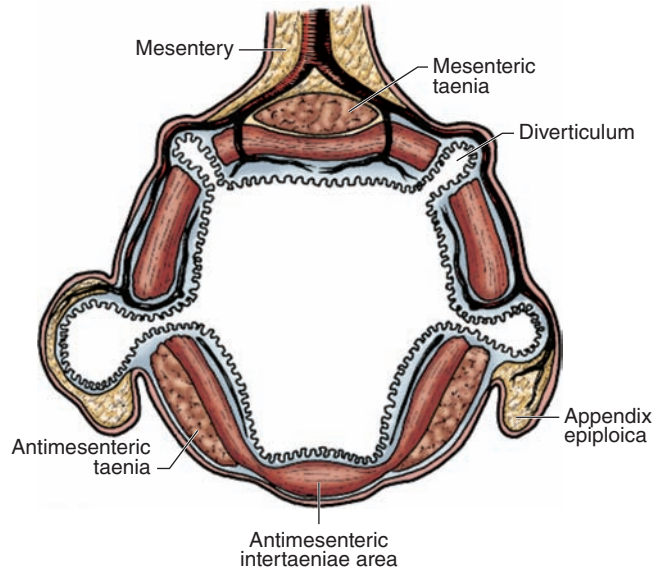


FIGURE 32-1 Relationship of diverticulum and vasa recta.

along the arteries (*vasa recta*) that penetrate the muscle wall en route to the submucosa and mucosa (Figs. 32-1 and 32-2).

Many studies have demonstrated a change in the histological structure of the muscularis propria in diverticular disease. In a classic study, Whiteway and Morson found the muscle cells to be normal with no evidence of hyperplasia or hypertrophy, but both layers were thickened. They demonstrated excessive amounts of elastin in the *taeniae* but not in the circular muscle.<sup>17</sup> Repeated intermittent distension of the colon can result in increased synthesis of connective tissue components.<sup>32</sup> It may be that the Western diet with its lower fecal load only intermittently distends the bowel wall and encourages elastin deposition.

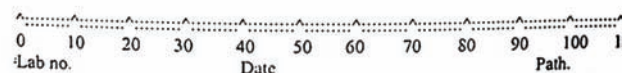
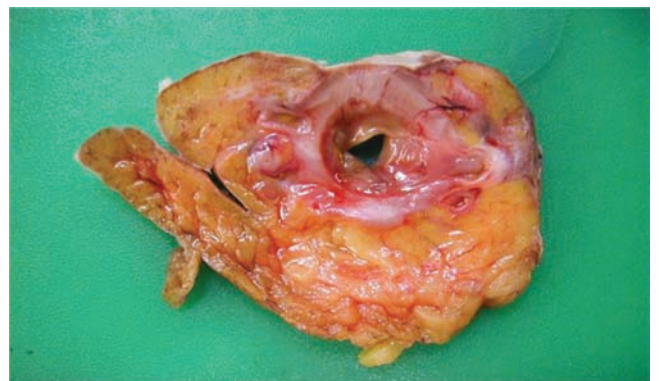

FIGURE 32-2 Cross section through the sigmoid colon containing diverticula (arrows).



The importance of collagen and elastin types in the colonic wall is increasingly being recognized. Elastin deposition, termed “elastosis,” explains the contracted and thickened appearance of the diverticulum-affected colon. The taeniae shorten, and, because of fascial linkage between the longitudinal and circular muscles, the colonic wall looks like a concertina. Thickened circular muscle folds project into the lumen causing a decrease in caliber. The mesocolon is also foreshortened, possibly as a result of chronic inflammation. Other studies have suggested that the type of collagen may be important.<sup>33</sup> One study has shown that in the bowel sections of patients with diverticulitis, there were decreased levels of mature collagen type I and increased levels of collagen type III with a resulting lower collagen I:III ratio. The expression of matrix metalloproteinase 1 was reduced significantly in the diverticulitis group.<sup>33</sup> These findings support the theory of structural changes in the colonic wall as one of the predisposing pathogenic factors for the development of diverticula (Fig. 32-3A and 32-3B).<sup>33</sup> In those with certain connective

tissue diseases, such as Marfan’s and Ehlers-Danlos syndromes, diverticular disease is a common association.

Diverticulitis always starts with a microperforation leading to peridiverticulitis. This is instigated by either a rise in intraluminal pressure and/or erosion by inspissated feces. Nonresolution of this initial injury leads to complications of diverticulitis.

## Presentation

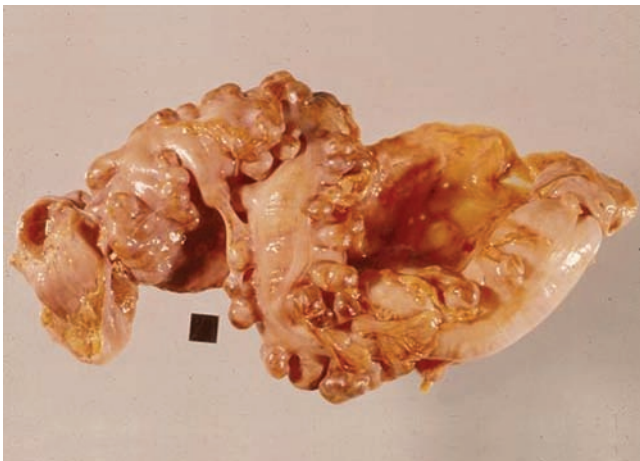Given the high incidence of diverticulosis, it is surprising that clinical manifestations are relatively infrequent. Many patients are unaware that they have colonic diverticula until they develop acute symptoms or when colonic diverticulosis may be found as an incidental finding when patients are undergoing colonic investigations. Typically an acute attack of diverticulitis begins with lower abdominal pain that then localizes to the left iliac fossa. An inflamed sigmoid colon can lie against the dome of the bladder or the cecum, mimicking a urinary tract infection or appendicitis. Fever, tachycardia, and a leukocytosis accompany the acute attack. The inflammatory response starts at the site of a blocked diverticulum, and bacterial proliferation eventually leads to abscess formation. Minor episodes may be self-limiting, but an abscess can develop and then rupture into the abdomen causing a purulent peritonitis. More rarely, feculent peritonitis occurs when a diverticulum ruptures freely into the peritoneum.<sup>34-41</sup>

Physical examination will often reveal peritonitis localized to the left iliac fossa or suprapubic area; a palpable mass is not uncommon.

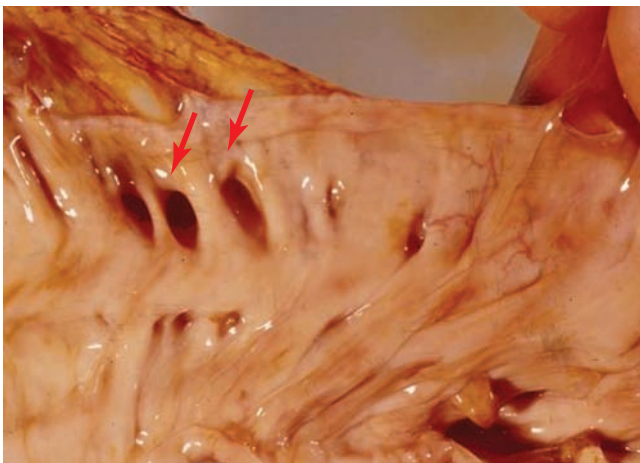
The differential diagnosis includes appendicitis, segmental ischemic colitis, colorectal cancer, inflammatory bowel disease, gastroenteritis, and irritable bowel disease.

In the absence of complications, patients with acute diverticulitis are best managed conservatively with antibiotics. Generalized rigidity suggests purulent or fecal peritonitis, and early surgery is required in this situation. Once fluid and electrolyte resuscitation has begun, an emergency laparotomy or laparoscopy with an appropriate colonic resection should be performed.

Often, diverticular disease presents in a more indolent manner with nagging left iliac fossa pain, abdominal distension, and a change in bowel habits. In the course of investigations to exclude colon cancer, diverticular disease may be discovered by barium enema, computed tomographic (CT) colonography, or colonoscopy (Figs. 32-4, 32-5A, and 32-5B). In the majority of these patients, education about the natural history of the disease with advice on dietary modification and supplementary written information will suffice. A very limited number of patients, who continue to have symptoms despite long periods of medical management, may benefit from surgery in the absence of other specific complications of the disease; however, determining who has symptoms from their diverticula and who has irritable bowel can be difficult. These patients often have persisting symptoms following surgery.



A



B

FIGURE 32-3 A. Sigmoid colon with diverticula. B. Mucosal view of colonic diverticula.

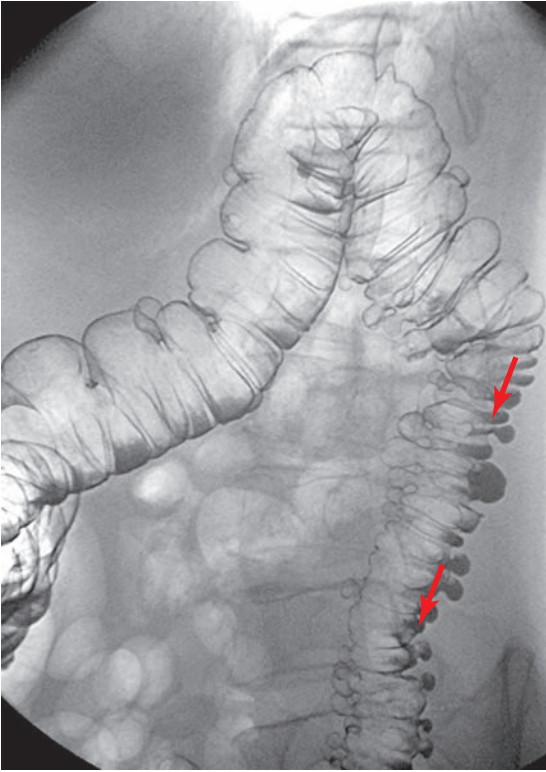


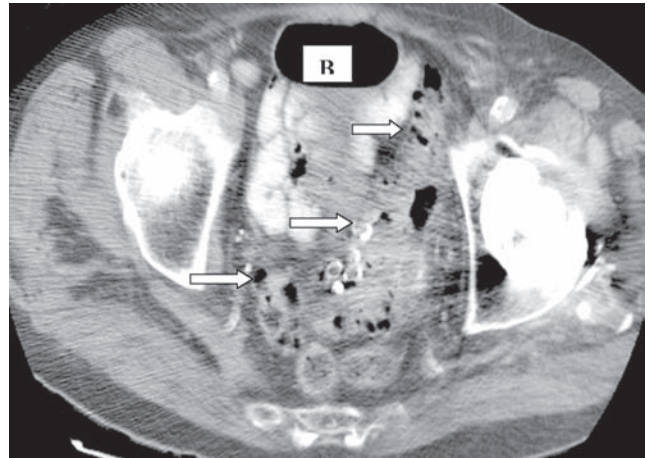
FIGURE 32-4 Left colonic diverticula on double-contrast barium enema (arrows).

## COMPLICATIONS

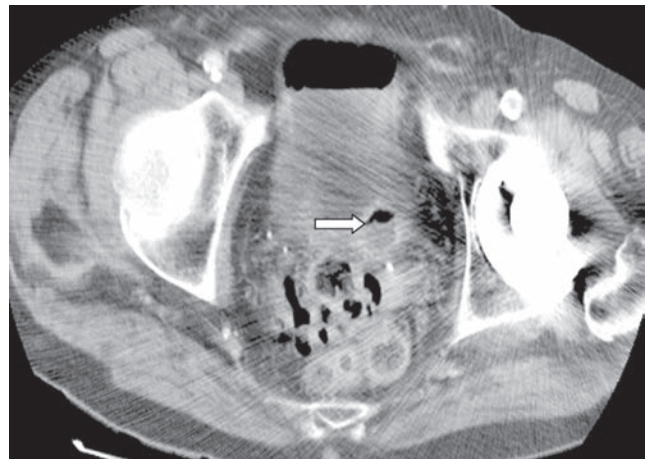
**Free Perforation.** Feculent peritonitis is usually associated with toxemia and signs of generalized peritonitis. These patients will require an immediate laparotomy, resection, and diversion. Mortality rates for emergency operations have remained unchanged at 12–36% for the last 20 years and are most often affected by the patient's underlying fitness for surgery.

**Fistula.** An inflamed segment of sigmoid colon can adhere to a number of intra-abdominal structures or to the abdominal wall. A fistula may arise spontaneously as a result of the inflammatory condition itself or as a result of surgical intervention. It is more common in males, in those with previous abdominal surgery and in immunocompromised patients. Diverticular fistulas can drain either internally or externally. Often, these fistulas are single tracts, but in about 8% of patients they are multiple. Rare sites of fistulous involvement include the ureters, other colonic segments, and stomach.

**Colocutaneous.** Occasionally a paracolic diverticular abscess will discharge spontaneously through the abdominal wall causing a colocutaneous fistula. More often, a fistula will result from incision and drainage of a pointing paracolic abscess or from a drain placed under radiological control. A fistula can arise from a leaking colonic anastomosis in patients who have undergone resection for diverticular disease.



A



B

FIGURE 32-5 CT coronal view of sigmoid diverticula.

**Colovesical.** This is the most common fistula accounting for about two-thirds of diverticular fistulae. It is more common in men because in women the uterus is interposed between the bladder and the colon. A relatively mobile sigmoid colon becomes adherent to the dome of the bladder and a communication develops. Patients present with recurrent urinary sepsis, urgency, frequency, and pneumaturia. Fecaluria is uncommon. Cystoscopy sometimes identifies an area of inflamed transitional epithelium but is more useful to exclude bladder cancer. A double-contrast enema or CT colonography provides a useful map of the anatomy and in some cases can confirm the presence of a fistula. Caution should be exercised when using barium in an acute situation to avoid peritoneal contamination.

**Coloenteric.** Small bowel can become adherent to an inflamed diverticulum-affected colon. Fistulas form when an abscess discharges through the small bowel wall. This may be asymptomatic.

**Colovaginal.** This is a particularly debilitating fistula. The patient may pass flatus and feces through the vagina and suffer

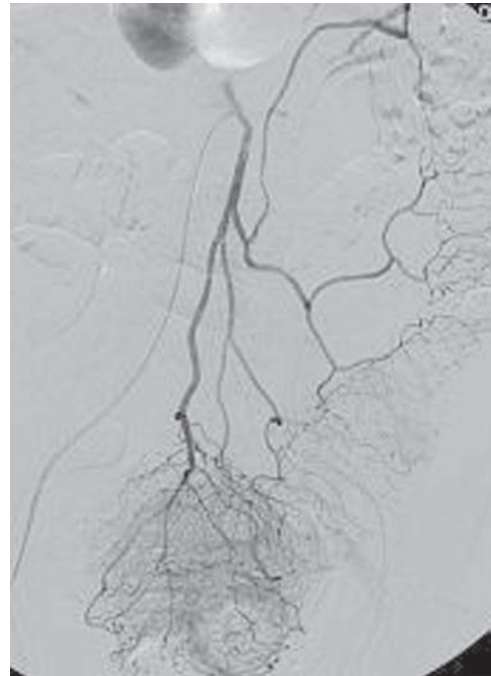


recurrent vaginal infections. Colovaginal fistulas usually only occur if a previous hysterectomy has been performed. Barium studies of both the bowel and the vagina or pelvic magnetic resonance imaging (MRI) usually can confirm the diagnosis. They are also helpful to exclude colonic malignancy as a cause; however, an examination of the vagina may also be required to exclude the rare possibility of a gynecological malignancy.

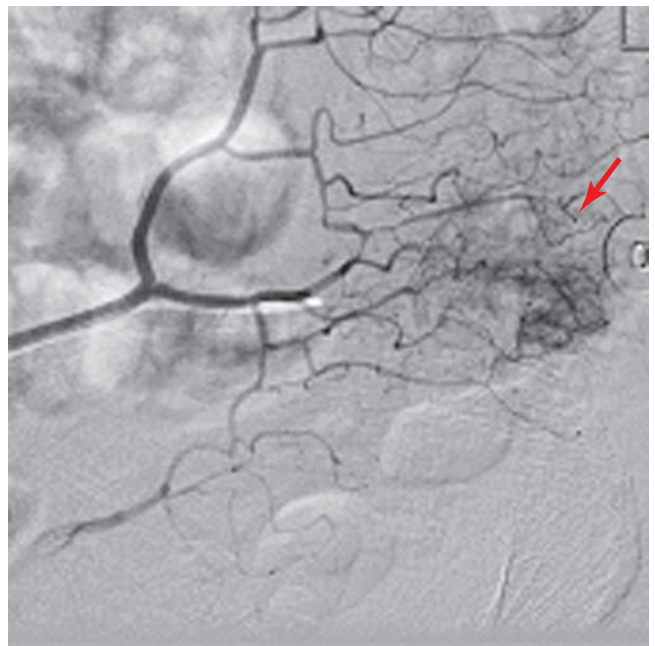
Single-stage operative resection with primary anastomosis and repair of the contiguous organ can be performed in most circumstances.<sup>42</sup> Interposition of the pedicized greater omentum between the anastomosis and the site of the fistula is a useful adjunct in preventing recurrent fistula formation.

**Bleeding.** Severe hemorrhage from diverticular disease is rare (5%).<sup>43,44</sup> However, distinguishing diverticular bleeding from other causes can be a diagnostic challenge, particularly because diverticular disease is so prevalent.<sup>45,46</sup> In elderly patients, angiodysplasia is the most common colonic cause for rectal bleeding. Taken together, bleeding from angiodysplasia and diverticula account for 90% of cases of severe lower intestinal hemorrhage. In diverticular bleeding the penetrating vasa recta that has led to the development of the diverticulum is easily eroded as it is only separated from the bowel lumen and its contents by a thin layer of mucosa. On histology there is thinning of the media and thickening of the intima of the vasa recta with rupture of the vessel usually at the dome of the diverticulum. There usually is no inflammation associated with the bleeding diverticulum.<sup>47,48</sup>

Diverticular hemorrhage presents with abrupt passage of large-volume bright or dark red blood per rectum and may be associated with lower abdominal pain probably related with colonic distension. Most diverticular bleeding occurs from left-sided diverticula except in patients of Asian ethnic origin, in whom it is more common to find the bleeding occurring on the right side.<sup>31</sup> Diverticular bleeding is more common in those on nonsteroidal anti-inflammatory drugs (NSAIDs). Colonoscopy in situations of large-volume bleeding is considered futile if not dangerous. CT angiography is now considered the most useful diagnostic test as it more readily localizes the site of bleeding should the bleeding rate exceed 0.5 mL/min. Formal mesenteric angiography to embolize the segmental vessel is then undertaken with good bleeding control and low associated complications (Fig. 32-6).<sup>49,50</sup> Failing this, other techniques to control or localize the bleeding site include vasopressin injection or methylene blue. A more sensitive test for colonic bleeding is a radio-labeled red blood cell scan or technetium-99m-labeled sulfur colloid (>0.1 mL/min), but they are poorer in localizing the bleeding site.<sup>51</sup> Colonoscopy can be used before a laparotomy or as an adjunct with the abdomen open if all else fails in a patient who continues to bleed. It is useful in an attempt to localize and control the bleeding or to minimize the amount of colonic resection. It is also important to note that in these situations a preoperative gastroscopy is mandatory to exclude an upper gastrointestinal tract (GIT) source of bleeding. Most diverticular hemorrhage ceases spontaneously (70–80%)



A

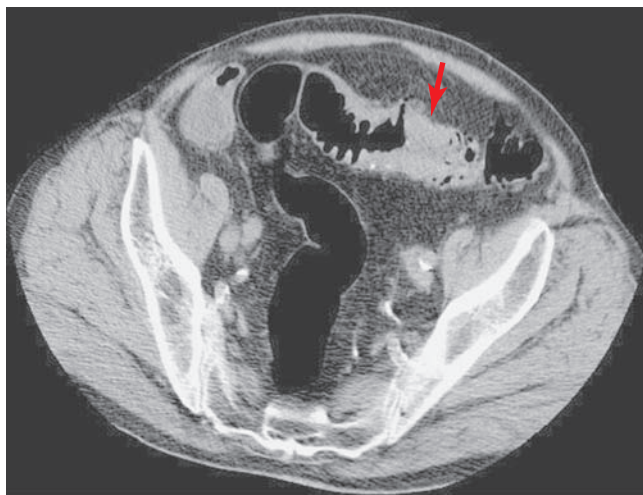


B

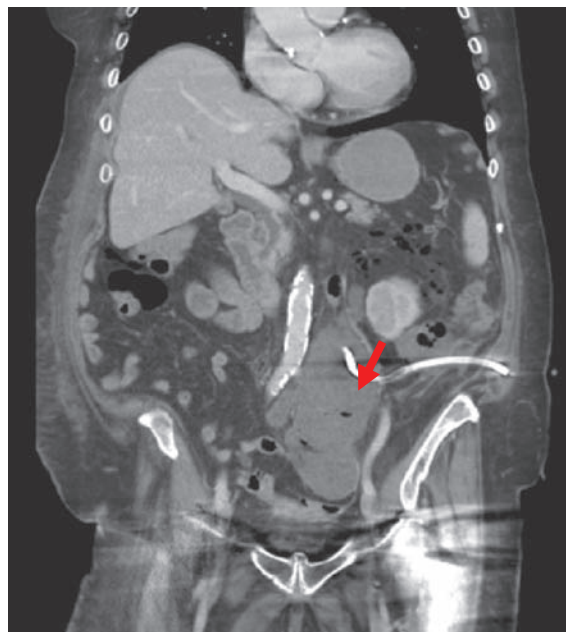**FIGURE 32-6** Formal angiography demonstrating “contrast blush”—active bleeding from sigmoid colon.

with rebleeding rates of 22–38%.<sup>44,45,52</sup> CT colonography or colonoscopy in patients who have stopped bleeding is useful to exclude malignancy particularly in those with smaller-volume bleeding, with associated suspicious symptoms or where a personal/family history of cancer is significant.





**FIGURE 32-7** CT scan of active diverticulitis with occlusion of colonic lumen secondary to inflammation (*arrow*). Differential diagnosis is a sigmoid colon malignancy.



**FIGURE 32-8** Sigmoid diverticulitis complicated by a paracolic abscess (with a percutaneous drainage tube in situ).

**Obstruction.** Obstruction due to diverticular disease accounts for 10–20% of large bowel obstructions (LBOs) in Western society. Diverticular disease causes colonic obstruction through either luminal stenosis as a result of wall edema on top of the already thick walled, fibrotic colon or extrinsic compression from an abscess (Fig. 32-7). Often the obstruction is incomplete. Small bowel obstruction can occur if a loop of small bowel becomes adherent to the inflamed sigmoid colon. The diagnosis is usually apparent from the patient's history. Radiological confirmation either by contrast enema or by CT with oral and rectal contrast should be obtained. Caution is wise in those with questionable underlying active diverticulitis particularly if complicated by localized perforation. Direct visualization and histological exclusion of malignancy are mandatory but at times difficult.

Management of colonic obstruction in this setting depends on the mode of presentation and the medical fitness of the patient. An insidious onset is characterized by pain, increasing constipation, and the passage of ribbon-like stools. The majority of patients, however, will present acutely with a classic LBO. The surgical options include a Hartmann resection and resection with primary anastomosis or rarely with a diverting loop ostomy. In those patients deemed unfit for surgery, the endoscopic or fluoroscopic deployment of a colon stent is a useful alternative procedure with a high clinical success rate.<sup>53</sup>

**Abscess.** Abscess formation is the most common complication of acute diverticulitis. It occurs when the center of the inflammatory mass or phlegmon becomes necrotic. The patient presents with worsening abdominal pain, undulating fever, leukocytosis, and raised inflammatory markers. A mass is often palpable in the left iliac fossa or suprapubic region. It may also be felt transvaginally or transrectally. The most common site for a diverticular abscess is in the sigmoid mesocolon, although a variety of unusual presentations have been

described.<sup>54</sup> A significant number of abscesses are detected radiologically on CT or ultrasound scanning. Most small (<5 cm) pericolic abscesses can be treated medically with bowel rest and antibiotics.<sup>55</sup> CT- or ultrasound-guided drainage is indicated for larger or unresolving abscesses via a transabdominal approach when accessible.<sup>41,56–58</sup> (Fig. 32-8) Alternatively, these abscesses may also be drained transanally or transvaginally depending on their location. This is successful in up to 90% and will allow subsequent observational management or a single-stage resection.<sup>58–61</sup> Factors that limit success with management include abscess that involve enteric fistulae or multilocular collections especially those containing solid feces. More recently, laparoscopic lavage and drainage have been taken up with enthusiasm by several groups with some promising results.<sup>62–65</sup>

**Giant Colonic Diverticulum.** Giant colonic diverticulum (GCD) was first described in 1946 by Bonvin and Bonte<sup>66</sup> in the French literature. The first radiological description was by Hughes and Greene in the American literature in 1953.<sup>67</sup> Various names have been used to describe GCD, including solitary air cyst, giant air cyst, giant gas cyst, encysted pneumatocoele, colonic pneumocyst, and giant diverticulum. The variety of names highlights the fact that there has been no clear definition or a single accepted name for these poorly defined lesions that present as large gas-filled cysts attached to the colon (diverticulum). GCD are rare clinical entities with just over 100 cases reported. The age at presentation is comparable to that of patients with conventional diverticular disease. Abdominal pain is the most common symptom, affecting 70% of patients, while 10% are asymptomatic. The most common physical finding is an abdominal mass, affecting 60%

of patients, while 4% have normal physical examinations. Plain abdominal radiology is usually diagnostic of GCD. Treatment is recommended early, preferably soon after presentation, because of the high complication rate. Surgical treatment may either require a diverticulectomy or segmental resection, and the outcome is usually good.<sup>68</sup>

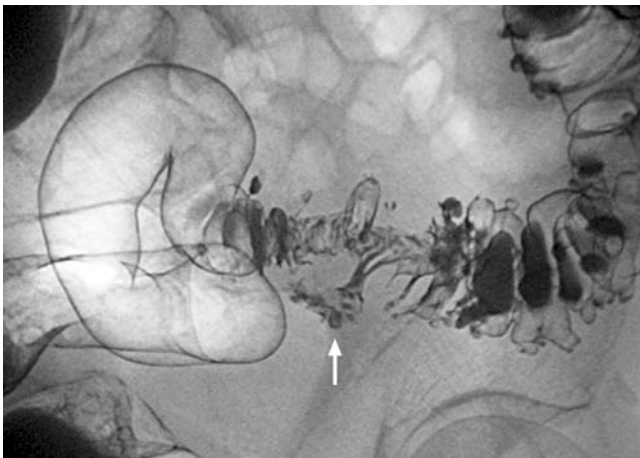
**Cancer.** There is little evidence to support an association of diverticular disease and colorectal cancer; however, a recent population-based, case-control study from Sweden identified a causal association between sigmoid diverticulitis and a long-term increased risk of left-sided colon cancer.<sup>42</sup>

## Investigations

The spiral CT scan has changed the investigation of acute diverticular disease with sensitivities of 90–95%. Although it is debatable whether CT alters disease management in minor diverticular disease, it is invaluable in excluding other causes of abdominal pain and documenting the extent of extraluminal disease. In circumstances in which access to CT is limited, a water-soluble contrast study may show mucosal thickening, edema, irregularity, and occasional extravasation of contrast (Fig. 32-9). Sensitivity is high.<sup>69</sup> Any free perforation is usually contained in an abscess cavity. Contrast enemas are particularly useful for demonstrating the presence and course of an enteric fistula. Barium should be avoided in the emergency setting, as the consequences of barium-induced peritonitis are catastrophic.

The real advantage that CT scanning affords, in addition to confirmation of the diagnosis, is to direct the treatment of complicated diverticular disease.<sup>70–72</sup> Radiologically guided drainage of diverticular abscesses is a useful adjunct to medical management, and can, if successful, avoid the requirement for emergency surgery (see Fig. 32-8).

The role of ultrasound scanning in patients suspected of having diverticular disease has been confined to the treatment



**FIGURE 32-9** Localized perforation with contrast extravasation into abscess cavity as demonstrated on double-contrast study.

and follow-up of diverticular abscess. It is highly operator-dependent, but it can be used to insert drains and to measure the response of the abscess to drainage.

It is normal practice following resolution of the first episode of diverticulitis to assess the colon for extent of disease and to exclude colorectal malignancy. This can be undertaken with colonoscopy, CT colonography, or barium enema. Care must be taken to wait for full resolution of the attack as an inflamed colon is easy to perforate; also, at times colonoscopy may be very difficult or impossible due to inflammatory adhesions. Colonoscopy generally underestimates the extent of the disease.

Other tests available that may be useful in assessing fistulous disease include MRI scans, cystoscopy, fistulogram, vaginogram, or vaginoscopy.

## Classification of Diverticulitis

The Hinchey classification is a useful grading system for diverticulitis.<sup>34</sup>

Stage I	Diverticulitis with associated pericolic abscess
Stage II	Diverticulitis associated with distant abscess (retroperitoneal or pelvic)
Stage III	Diverticulitis associated with purulent peritonitis
Stage IV	Diverticulitis associated with fecal peritonitis

More recently, the modified Hinchey classification has been proposed to further subclassify these stages. Stage 0 is clinical, mild diverticulitis without imaging information. Stage I has been subdivided into Ia that is pericolic inflammation. Stage Ib is diverticulitis associated with pericolic abscess. Stage IIa is distant abscess amenable to percutaneous drainage. Stage IIb is complex abscess with or without fistula. Stages III and IV are the same as for the original Hinchey staging.

## Management

The majority of patients with acute diverticular disease can be managed conservatively with intravenous antibiotics.<sup>73</sup> In the absence of complications, most patients will respond to a targeted course of antimicrobial therapy against predominantly gram-negative rods and anaerobes especially bacteroides species. A combination of metronidazole and ciprofloxacin or a broad-spectrum antibiotic such as meropenem or amoxicillin and clavulanate (Augmentin) is most commonly used.<sup>74</sup> There is, however, quite a variation in the treatment regime used among clinicians, and there is no specific regime that has been shown to be superior.<sup>75</sup> The decision to operate should be made at a senior level, as the actual number of patients who require resectional surgery for diverticular disease is small.<sup>76</sup> The increasing use of interventional radiology and laparoscopic surgery has impacted how diverticular disease is

currently managed. This is coupled with a trend to not perform any resectional surgery but, when necessary, to do so with a primary anastomosis in patients presenting with acute complicated diverticulitis.

## ELECTIVE SURGERY

Surgery in this setting should be reserved for patients who are medically fit with several proven attacks of acute diverticulitis or who have ongoing sequelae from complicated diverticular disease. Even then, caution should be exercised, as a significant minority of patients whose principal symptom is chronic pain will continue to be symptomatic after resectional surgery.<sup>77</sup> The patient should be fully informed of this possibility before proceeding with the surgery.

Elective resection has generally been offered to patients who have suffered two attacks of acute diverticulitis in a short period of time, but recommendations have ranged from one to four episodes.<sup>55,78,79</sup> The argument has been that this will prevent recurrent diverticulitis as well as its associated complications.<sup>81–93</sup> This is based on historical data that suggest recurrences of up to 67%, with higher morbidity (up to 60%) and mortality associated with recurrent diverticulitis particularly after two episodes.<sup>35,37,55,79,92,94–105</sup> It was also previously demonstrated that patients older than 50 years respond less well to conservative treatment following successive attacks of diverticulitis; a response rate of only about 6% was reported for the third recurrence.<sup>103</sup> In another series re-recurrence was estimated at 2% per year with the first recurrence being the most significant predictor of this.<sup>98</sup> Most often, any recurrence that occurs does so in the first 6 months after the initial attack, and recent data would suggest that it is in fact failure of resolution of the inflammation from their first episode rather than a true recurrence. Some have argued that there is a reduction in the recurrence rate of diverticulitis from 12.5 to 6%<sup>106,107</sup> with good long-term results following surgery.<sup>91,108</sup>

There is still a lack of good prospective data comparing surgical intervention with conservative management in this situation. A large population-based study recently has shown very few patients going on to have surgery after initial conservative treatment of diverticulitis.<sup>73</sup> Another group showed that successful conservatively treated complicated diseases, in particular abscesses, are not associated with further recurrence or complicated recurrences.<sup>98</sup> Recent evidence suggests that less than a quarter of patients having emergency surgery for acute diverticulitis have a previous history, and often complications arise during the first attack of diverticulitis rather than during subsequent episodes.<sup>109–111</sup> Such episodes were associated with a more benign course and responded well to nonoperative management.<sup>101,112</sup> Two groups have shown that the less severe and more readily conservatively managed complications of pericolic abscess occur in recurrent cases rather than free perforation.<sup>39,113</sup> Following elective resection, up to 25% will continue to have symptoms suggesting a coexistent pathology such as irritable bowel.<sup>6,77</sup> Up to 16% will develop recurrent diverticulitis with a small percentage requiring further surgery.<sup>107,114–118</sup> Furthermore, prophylactic colectomy

has a mortality risk of up to 4% and a covering stoma is used in up to 14%, necessitating further operation to reverse.<sup>39</sup>

Risk-reducing measures in elective surgery include weight control, routine administration of prophylactic preoperative antibiotics, and preoperative optimization of the respiratory status of the patient with chronic pulmonary disease. Attempts have been made to stratify the management of diverticular disease by pathological and radiological means.<sup>119,120</sup> In one study patients characterized as having a mild attack of diverticulitis had a 14% risk of having a recurrent episode, whereas severe forms had a risk of 39%. Ultimately, the wide spectrum of disease encountered makes dogmatic statements about intervention unreliable, and sound clinical judgment is still required to decide when to intervene.

Indications for operative intervention are different in two patient subgroups: those younger than 50 years and the immunocompromised. Data on young patients with diverticular disease are mainly retrospective. The prevalence of colonic diverticula has been estimated at between 6 and 9% in the general population 40 years of age or younger, with a male preponderance (62–100%).<sup>87,121–123</sup> Patients in this group are thought to have a more virulent course with more complicated recurrences and an aggressive policy of surgical resection has been proposed,<sup>80,87,93,95,112,123–127</sup> particularly in obese males.<sup>87,128,129</sup> Others more recently have challenged this opinion, arguing that there is no difference between the young and old population.<sup>130</sup> There were very few free perforations with recurrent attacks and certainly no increased mortality in this age group.<sup>73,97,99,122,127,131–134</sup> Whether the higher propensity for a complicated course in this age group is a true association or the presentation has been altered because of delayed diagnosis remains debatable.<sup>118,135–137</sup> Between 29 and 55% of younger patients will be readmitted to the hospital with acute diverticulitis following their initial presentation, with the majority (up to 88%) of these subsequently undergoing elective or emergency surgery.<sup>76,80,112,123,124,138</sup> A number of these patients were diagnosed at operation for another surgical condition, most often with appendicitis, and were thus often unnecessarily operated on.<sup>73,133,134</sup> It is unclear whether there is an advantage to operating after the initial acute attack of diverticulitis in this age group, especially if it is uncomplicated.

It is uncertain whether patients who are chronically immunosuppressed are more at risk of developing diverticular disease. It is thought that patients who have long-term uremia have a higher incidence of diverticulosis, possibly due to chronic constipation and generalized tissue weakness. Patients with polycystic kidney disease have a very high incidence of colonic diverticular disease.<sup>139</sup> Several groups have reported that immunocompromised patients with acute diverticulitis have a more complicated course compared to nonimmunosuppressed patients.<sup>140–142</sup> Patients who are recipients of renal transplants have a high mortality rate from acute complicated diverticular disease. In some centers, routine colonic screening of patients awaiting renal allografts is performed.<sup>143</sup>

There is limited evidence that the cessation of smoking and stopping NSAIDs will reduce the rate of recurrent attacks of diverticulitis. There is some evidence that the long-term



administration of a poorly absorbed antibiotic will have such an effect.<sup>144–148</sup>

### EMERGENT ACUTE DIVERTICULITIS WITH LOCALIZED PERITONITIS

Patients with acute diverticulitis present with localized left iliac fossa peritonitis, fever, tachycardia, and a leukocytosis. Tenderness can spread to the hypogastrium and even to the right iliac fossa. Generalized peritonitis is highly suspicious for a free diverticular perforation. Patients should be rehydrated with an intravenous infusion; in septic patients a urinary catheter is invaluable for assessing an adequate hourly urine output. Other supportive measures include oxygen therapy, adequate opioid analgesia, and antimicrobial therapy.

Early oral feeding may commence when tolerated, and a switch to oral antibiotics can be made with signs of resolution of inflammation. In the majority of patients, this conservative therapy will lead to the resolution of symptoms.

The operative rate for complicated diverticulitis overall in the past has been between 19 and 55%.<sup>79,84,94,98,99,149</sup> Complicated diverticulitis has been shown by some to be associated with high rates of recurrent complications and high rates of mortality.<sup>39,78</sup> The mortality in some reports approaches 40% especially in immunocompromised patients,<sup>39,109,150,151</sup> and similarly in those with an ASA of 3 or greater, there is a mortality rate ranging of up to 28%.<sup>35–37,39,83,85,94,109,152–154</sup>

### EMERGENT ACUTE DIVERTICULITIS WITH GENERALIZED PERITONITIS

When either an abscess or a diverticulum ruptures into the peritoneal cavity, widespread bacterial contamination ensues with resultant generalized peritonitis. Surgery is principally directed at controlling peritoneal sepsis and should be tailored to each situation. A conservative approach can be taken with elderly and medically unfit patients who are unlikely to survive surgical intervention. The combined use of appropriate antibiotic therapy and regular review is surprisingly successful in this cohort, even in the presence of a pneumoperitoneum.

In patients who are fit for surgery, a period of vigorous resuscitation and antibiotic therapy is still warranted. Even in the face of advanced peritoneal signs, a number of patients will respond to these measures and avoid the requirement for surgery. Serial clinical observation is of greatest benefit when pursuing this course. If there is no sustained improvement in 24 hours, the patient should be offered surgery.

The days of the routine three-staged procedures are gone as there is little place for nonresectional surgery in the emergent situation involving feculent peritonitis. Resection of the affected colon is associated with a lower morbidity and up to three times less mortality compared with nonresection procedures.<sup>109,155</sup> The aim of surgery is clear: to remove the source of sepsis and to toilet the abdominal cavity. More recently with the advances in laparoscopic surgery, lavage and drainage of Hinchey types 1–3 have been successfully performed. This avoids unnecessary resection surgery and its associated

morbidity and mortality, as well as stoma formation and reversal.<sup>156</sup> The apparent confusing and conflicting evidence that outcomes are better following open resection than non-resection and laparoscopic nonresection being better still than open resection still need to be resolved.

The amount of resected tissue depends on the extent of the diverticular disease. At the time of the initial acute surgery, the inflamed bowel needs to be resected. The extent of this resection depends on whether a primary anastomosis is being undertaken or a Hartmann procedure is being performed. When bowel continuity is restored after a Hartmann procedure, total sigmoid colectomy plus removing all of the diverticula-bearing colon and a rectal anastomosis has been shown to reduce the risk of recurrence by some<sup>107,115</sup> but not others.<sup>118</sup>

The decision of whether to undertake an anastomosis in the acute setting is dependent on a number of criteria: the frailty of the patient, the degree of contamination and sepsis, the preparedness of the bowel, and the experience of the surgeon. Hartmann's procedure entails resection of the sigmoid colon with formation of end colostomy and is the safest option when conditions do not favor primary anastomosis. Hartmann's resections are not without their own complications. Up to 50% of patients will never have their stoma closed, particularly the elderly.<sup>39,79,157,158</sup> There is also definite morbidity (up to 16%) and mortality (up to 4%) related to restoration of continuity.<sup>36,152,157–160</sup> Occasionally there are complications related to rectal stump dehiscence.<sup>161</sup>

Primary anastomosis can be performed in the emergency setting but only if conditions are wholly favorable.<sup>162,163</sup> Performing anastomoses in the presence of gross purulent or fecal contamination is controversial and should only be performed by experienced hands. The requirement for bowel preparation for left-sided anastomosis is equally controversial, but recent studies have cast doubt on the need for this.<sup>164</sup> Presacral drainage is often used at the end of the operation but without evidence to its effectiveness.<sup>165</sup>

### LAPAROSCOPIC SURGERY FOR DIVERTICULAR DISEASE

The widespread acceptance of laparoscopic surgery has led to its use in both benign and malignant colorectal disease. Laparoscopic surgery in colon cancer is oncologically equivalent to the open approach with better cosmesis, less analgesic usage, and shorter hospital stays.<sup>166–168</sup> In the acute situation there is growing popularity of laparoscopic exploration and drainage of Hinchey's stages I and II diverticulitis.<sup>41,56–58,169</sup> This is particularly useful in cases of misdiagnosis where diverticulitis is instead found, avoiding the need for a colectomy or stoma. Laparoscopic drainage has even been utilized in some centers for Hinchey's stages III and IV complicated diverticulitis.<sup>170</sup> Laparoscopic repair of colonoscopic perforations recently has been successful in numerous cases even with associated diverticular disease of the colon, especially when the pathology is recognized early and there is minimal contamination.<sup>171</sup>

Laparoscopic colonic resection for diverticular disease is challenging and is being increasingly utilized by specialist

centers with good results.<sup>172,173</sup> Some groups have included complicated cases, including abscesses and fistulas.<sup>174–177</sup> Published studies comparing laparoscopic and open resection of left-sided colonic diverticular disease have demonstrated benefits in terms of shorter hospital stay and convalescence despite a longer operating time.<sup>178,179</sup> Major complications as well as the length of the colon resection are generally the same when compared with the traditional open approaches.<sup>174–176</sup> Conversions to open depend on factors such as the clinician's surgical experience and the complexity of the diverticular complications involved.<sup>180</sup>

Publication bias, however, is likely to promote laparoscopic resection as being more favorable, and the true morbidity, cost, and conversion rates may differ from figures published in the medical literature. In over 1100 patients reported over the last 5 years, the postoperative complication rates range from 7.3 to 21%. Conversion rates range between 4 and 14%, operating time from 141 to 300 minutes, and return of bowel activity takes between 2 and 2.9 days.<sup>174–176,178</sup> A recent analysis of the cost of laparoscopic surgery compared with open surgery demonstrated that the total cost of the laparoscopic approach was significantly less (US\$3458 vs US\$4321;  $p < .05$ ).<sup>178</sup> Clearly this may have economic ramifications for the future.

## Summary

The prevalence of diverticular disease has increased and is continuing to do so in Western countries. The management of diverticular disease is becoming an increasing financial burden to health systems with limited resources. There is little evidence that a change in lifestyle measures can reduce the prevalence of diverticular disease. Fortunately colonic diverticula are usually asymptomatic.

The acute management of diverticulitis is usually conservative with antibiotics and bowel rest, with few patients needing emergency operations. Abscesses can be adequately treated with percutaneous drainage. When an operation is required, the quality of the surgery appears to be more important than whether the operation is undertaken open or laparoscopically. In the acute setting, the affected segment of colon should be resected. The place of elective resection is uncertain. The wide spectrum of disease encountered makes dogmatic statements about intervention unreliable, and sound clinical judgment is still required to decide when to intervene. Further prospective trials investigating recurrence rates, and in particular risk factors for recurrence, as well as the role of prophylactic surgery in the various subgroups is required.

## COLONIC VOLVULUS

A colonic volvulus occurs when a segment of colon twists around its mesentery giving rise to a partial or complete bowel obstruction. It is not just confined to humans with dogs and horses both for suffering from this disease.

## Epidemiology

Colonic volvulus occurs frequently in third-world countries such as Africa and South America, accounting for at least 50% of causes of LBO, but in developed nations it is third after cancer and diverticular disease at about 10%.<sup>181,182</sup>

In developed countries, sigmoid and cecal volvulus are the two most common forms of colonic volvulus with the former increasing in incidence with age especially in those older than 60 years. In sigmoid volvulus, there is a higher incidence in males due to their dolichomesocolic anatomy (sigmoid mesocolon is longer than wide) compared to females.<sup>181–183</sup> In cecal volvulus there is a younger age of presentation, usually around 40 years of age and particularly in women. Overall, the ratio of sigmoid to cecal volvulus is about 4:1. The other sites including the descending colon, flexures, and transverse colon are rarely involved. In developing countries the peak incidence is in males in the 40- to 60-year age group that account for up to 90%.<sup>182</sup>

## Etiology

A redundant colon that is mobile on a long mesentery is a prerequisite that predisposes to colonic volvulus. Redundancy of a colon is due to either colonic dysmotility, excessive fiber intake, or a genetic predisposition. A dynamic ileus and distal obstruction are also predisposing factors. In cecal volvulus, up to 50% will have a history of prior abdominal surgery. Volvulus in Western society is often seen in institutionalized, bed-bound elderly patients with an acquired megacolon. Mobility of the sigmoid colon is obvious with a long and narrow mesentery. In the right colon, poor fixation is often related to partial or complete malrotation of the bowel and, in the splenic flexure, volvulus occurs when there is congenital lack of fixation of the splenicocolic, gastrocolic, and phrenocolic ligaments.<sup>181,182</sup>

## Morphological Features

In colonic volvulus there is axial twisting of the bowel loops around the vascular axis, leading to a closed-loop obstruction with bowel ischemia and potential gangrene. If neglected, perforation of this bowel loop may occur. In cecal volvulus there is usually a counter-clockwise axial twisting of the cecum, ascending colon and terminal ileum around the mesenteric pedicle. Cecal bascule is a variant of the true cecal volvulus with the difference being an absence of the axial twist but rather the redundant cecum folds back transversely and upward over the ascending colon. True cecal volvulus is about nine times more common than cecal bascule. Bowel ischemia or infarction in this group can occur but is unusual.<sup>184</sup> In ileosigmoid, knotting occurs when the ileum gets caught up in the sigmoid volvulus and an ischemic process ensues in both the twisted bowel loops.

## Presentation

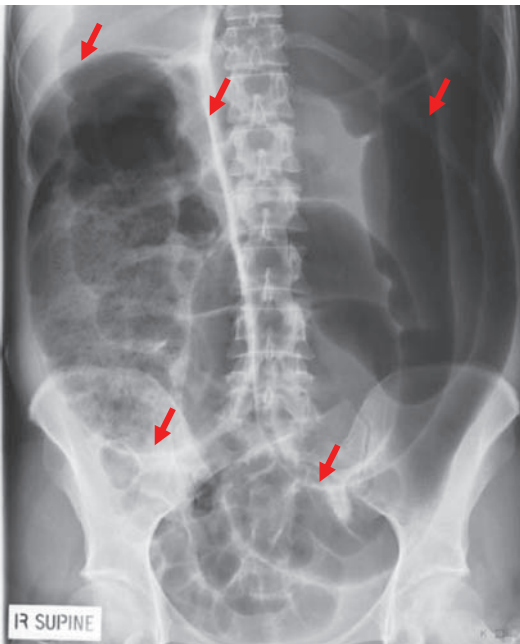
Colonic volvulus commonly presents with bowel obstruction, vomiting, obstipation, abdominal pain, and distension. About half will have symptoms suggestive of a previous attack. Clinical examination usually reveals a massively distended abdomen that is asymmetrical and tympanitic. The rectum is invariably empty. Signs of peritonitis often indicate underlying complications of perforation or gangrene.

## Complications

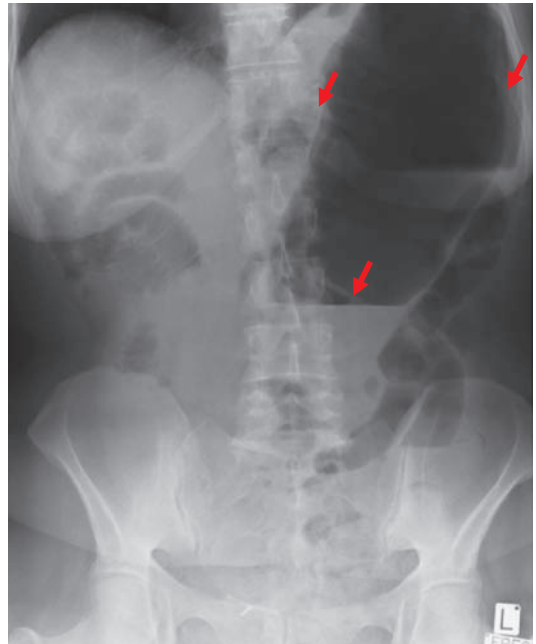
Perforation of the twisted segment of bowel (closed-loop obstruction) or bowel ischemia and infarction may occur. Secondary renal failure or multiorgan failure could arise because of third-space loss or loss from vomiting. Alternatively, this may be due to reperfusion injury after the volvulus is untwisted. Abdominal compartment syndrome is a rare complication.

## Investigations

A plain supine abdominal x-ray is usually sufficient in the diagnosis of sigmoid and cecal volvulus (Figs. 32-10 and 32-11). Up to 40% cases of cecal volvulus are in fact misdiagnosed as sigmoid volvulus. In cecal volvulus the dilated colon assumes the shape of a large coffee bean (“tear drop” or “comma” appearance) with one fluid level and the point



**FIGURE 32-10** Plain supine abdominal x-ray of sigmoid volvulus (arrows showing margins of volvulized sigmoid loop in a background of dilated proximal bowel).



**FIGURE 32-11** Cecal volvulus with proximal small bowel obstruction.

directed toward the left upper quadrant (see Fig. 32-11). There is often a lack of gas in the distal colon and up to half will have dilated small bowel as well. In sigmoid volvulus the shape is that of a “bent inner tube” with its point aimed at the right upper quadrant (see Fig. 32-10). Other features include “2 air to 1 fluid level” and a “pair of scales” whereby the fluid levels are at different horizontal levels. Dilated proximal large bowel and small bowel may be evident. Very rarely, even when present, is there free air under the hemidiaphragms due to the overwhelming amounts of colonic luminal gas that is present in the background. To confirm the diagnosis, a Gastrografin (diatrizoate meglumine) or barium enema study is performed to look for the “bird beak” sign that indicates the site of twisting of the colon. This, however, is becoming obsolete as CT scan is now readily available and commonly used to differentiate causes of abdominal pain. The “bird beak,” whirl or coffee bean signs are the most diagnostic features of volvulus on CT scan (Figs. 32-12 through 32-14).<sup>185</sup> CT scans can also be used to help exclude other diagnoses, including causes of distal bowel obstruction that may be associated with the volvulus, as well as help determine if the volvulus is complicated by ischemia or perforation.<sup>182</sup> Alternatively, a rigid or flexible sigmoidoscopy or colonoscopy can be performed. It has a higher rate of therapeutic success than an enema study in particular for the sigmoid volvulus.

## Management

In Western countries the mortality associated with colonic volvulus is high at about 20% overall and even higher when there is concomitant gangrenous colon. This is primarily



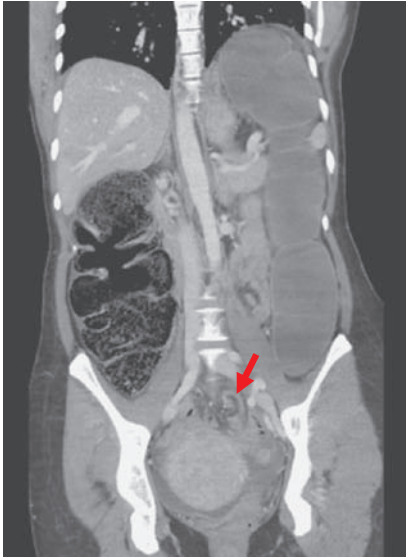


FIGURE 32-12 Coronal CT scan section. Sigmoid volvulus with the “swirl sign.”

due to the high comorbidities of this particular group of patients.<sup>183</sup>

Management of colonic volvulus should include a combination of careful resuscitation, urgent diagnosis, and decompression as soon as feasible. Of note reperfusion syndrome is a real phenomenon following detorsion of an ischemic or gangrenous bowel segment. Potential serious bacterial/toxin translocation and multiorgan failure are consequences that the treating clinician must constantly keep in check.<sup>186,187</sup>

Colonic volvulus especially involving the sigmoid colon may be decompressed by a rigid sigmoidoscope or colonoscope.

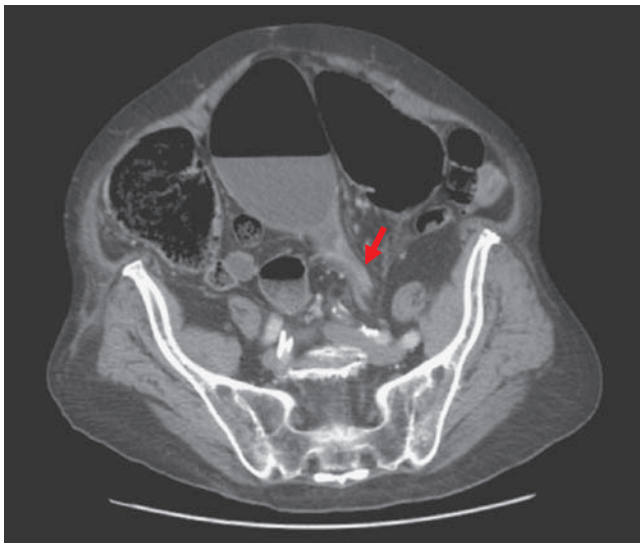


FIGURE 32-13 Transverse CT scan section showing beaking at site of sigmoid volvulus.

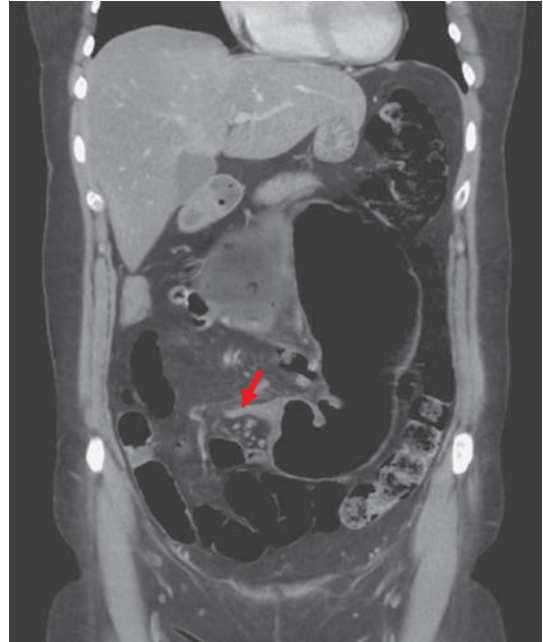

FIGURE 32-14 Cecal volvulus on transverse CT scan section with the beaking effect (*arrow*).

The latter has been shown to be more effective at decompression and with lower risk of complications.<sup>183</sup> The twisting point is often found high above the anal verge with decompression manifesting as a sudden rush of flatus and liquid feces via the anus or sigmoidoscope. The mucosa of the obstructed loop and the site of twisting should be inspected to evaluate the level of bowel ischemia. If no immediate surgery is required, a rectal tube should be placed to prevent further recurrences of the volvulus to allow the continuing decompression of the obstructed colon. For recurrent sigmoid volvulus in a patient who may withstand surgery, a sigmoid colectomy with or without anastomosis, once the bowel is adequately decompressed, is warranted. In the absence of perforation, there is no difference in outcome between a primary anastomosis and Hartmann's procedure for gangrenous disease.<sup>188</sup> The mortality of this is only slightly higher at 5.5% (primary resection and anastomosis) versus 4.2% (Hartmann's).<sup>189</sup> The recurrence rate of resectional therapies is almost zero.<sup>190</sup>

Laparotomy and detorsion with or without colopexy is a poorer alternative with similar morbidity but higher recurrences up to 40%.<sup>191</sup> Similarly, there is a high recurrence rate for mesosigmoidoplasty.<sup>189</sup> Surgery undertaken in these emergency situations had mortalities of 40% compared to 5.9% for elective operations.<sup>184</sup> In those patients who are medically at too high risk for an anesthetic, removing the rectal tube 48 hours later to allow the obstructed colon to deflate and then 24 hours of observation for recurrence before discharge is an option. Alternatively, colonoscopic-assisted placement of two colostomy tubes (percutaneous endoscopic colostomy

[PEC]) to fix the offending bowel loop to the anterior abdominal wall has recently been described in a series of 19 patients with good success and low morbidity. Only one patient had a recurrence requiring another tube colostomy to be inserted because of recurrence. Another patient died from tube dislodgement and peritonitis.<sup>192</sup> Laparoscopic colopexy, extraperitonealization of the sigmoid colon, and laparoscopic colectomies have more recently been widely used.<sup>193–195</sup> A medial to lateral approach for laparoscopic-assisted resection has been found to be advantageous.<sup>196</sup>

Cecal volvulus is more difficult to rectify via a colonoscope primarily because of an inability to reach the obstructed right colon. There is also a higher risk of perforation.<sup>197</sup> Consequently, surgery is often required. If feasible, an ileocolic resection with or without anastomosis is performed. This has the lowest recurrence rate but a high morbidity at about 30% and a mortality of up to 20%.<sup>197,198</sup> Alternatively, cecopexy may be performed but is associated with about a 20% recurrence rate. A tube cecostomy fixation (Fig. 32-15) has been advocated by some, claiming a low recurrence rate of about 2% and low morbidity, but others have shown that it has a morbidity of about 52% and mortality of 22%.<sup>197,199</sup>

## Conclusion

Colonic volvulus most commonly occurs in the sigmoid and is the third most common cause of bowel obstruction. It is readily seen on plain abdominal x-ray and CT scan. Sigmoid volvulus can often be nonoperatively decompressed before a decision is made for definitive resection that rarely leads to recurrence. Cecal volvulus often requires an operation to fix it. Delayed management of volvulus may result in perforation, leading to high rates of complications and mortality, especially in this elderly age group.

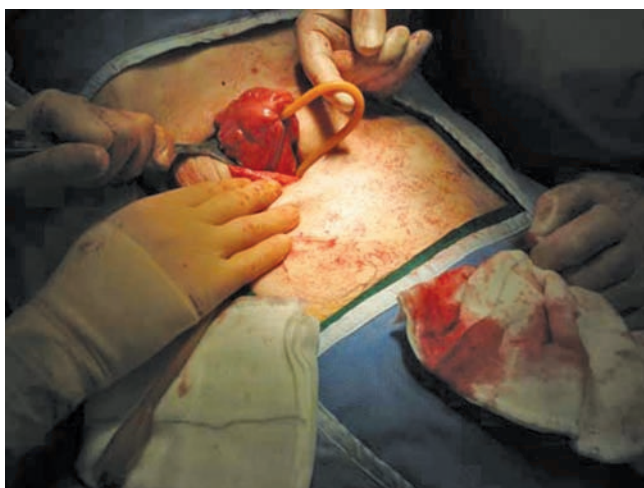

FIGURE 32-15 Cecal volvulus untwisted through lateral oblique incision and insertion of cecostomy tube (Foley catheter).

## REFERENCES

1. American Gastroenterology Association. The Burden of Gastrointestinal Diseases. Bethesda, MD. *American Gastroenterological Association* 2001.
2. Papagrigroriadis S, Debra S, Koreli A, et al. Impact of diverticular disease on hospital costs and activity. *Colorectal Dis*. 2004;6:81–84.
3. Hughes LE. Postmortem survey of diverticular disease of the colon. Diverticulosis and diverticulitis. *Gut*. 1969;10:336–344.
4. Kyle J, Davidson AI. The changing pattern of hospital admissions for diverticular disease of the colon. *Br J Surg*. 1975;62:537–541.
5. Kang JY, Hoare J, Tinto A, et al. Diverticular disease of the colon on the rise: a study of hospital admissions in England between 1989/1990 and 1999/2000. *Aliment Pharmacol Ther*. 2003;17:1189–1195.
6. Parks T. Natural history of diverticular disease of the colon. *Clin Gastroenterol*. 1975;4:53–69.
7. Litré A. 1700. Cited by: Finney JM. Diverticulitis and its surgical management. *Proc Interstate Post-Grad Med Assembly North Am*. 1928;55:57–65.
8. Cruveilhier J. *Traite d'Anatomie Pathologique Generale*. Vol. 1. Paris, France: Bailliere; 1849.
9. Graser E. Das falsche Darmdivertikel. *Arch Klin Chir*. 1899;59:638–647.
10. Beer E. Some pathological and clinical aspects of acquired (false) diverticula of the intestine. *Am J Med Sci*. 1904;128:135–145.
11. Moynihan B. The mimicry of malignant disease in the large intestine. *Edinb Med J*. 1907;21:228.
12. Telling WH, Gruner OC. Acquired diverticula, diverticulitis, and peridiverticulitis of the large intestine. *Br J Surg*. 1917;4:468–530.
13. Spriggs EI, Marxer OI. Multiple diverticula of the colon. *Lancet*. 1927;1:1067.
14. Case, JT. The roentgen demonstration of multiple diverticula of the colon. *Am J Roentgenol*. 1914;2:654.
15. De Quervain F. Zur diagnose der erworbenen dickdarmdivertikel und der sigmoiditis diverticularis. *Dtsch Z Chir*. 1914;128:67.
16. Hughes L. Postmortem survey of diverticular disease of the colon. Diverticulosis and diverticulitis. *Gut*. 1969;10:336–344.
17. Whiteway J, Morson BC. Elastosis in diverticular disease of the sigmoid colon. *Gut*. 1985;26:258–266.
18. Wess L, Eastwood MA, Wess TJ, et al. Cross linkage of collagen is increased in colonic diverticulosis. *Gut*. 1995;37:91–94.
19. Aldoori W, Giovannucci EL, Rimm EB, et al. Prospective study of physical activity and the risk of symptomatic diverticular disease in men. *Gut*. 1995;36:276–282.
20. Bassotti G, Germani U, Morelli A. Human colonic motility: physiological aspects. *Int J Colorectal Dis*. 1995;10:173–180.
21. Parks T, Connell AM. Motility studies in diverticular disease of the colon. *Gut*. 1969;10:534–542.
22. Simpson J, Scholefield JH, Spiller RC. Pathogenesis of colonic diverticula. *Br J Surg*. 2002;89:546–554.
23. Huizinga J, Waterfall WE, Stern HS. Abnormal response to cholinergic stimulation in the circular muscle layer of the human colon in diverticular disease. *Scand J Gastroenterol*. 1999;34:683–688.
24. Katschinski M, Lederer P, Ellermann A, et al. Myoelectric and manometric patterns of human rectosigmoid colon in irritable bowel syndrome and diverticulosis. *Scand J Gastroenterol*. 1990;25:761–768.
25. Parks, TG. Rectal and colonic studies after resection of the sigmoid for diverticular disease. *Gut*. 1970;11:121–125.
26. Painter NS, Burkitt DP. Diverticular disease of the colon: a deficiency disease of Western civilisation. *Br Med J*. 1971;2:450–454.
27. Kyle J, Adesola A, Tinckler L, et al. Incidence of diverticulitis. *Scand J Gastroenterol*. 1967;2:77–80.
28. Lee YS. Diverticular disease of the large bowel in Singapore: an autopsy survey. *Dis Colon Rectum*. 1986;29:330–335.
29. Walker AR, Segal I. Epidemiology of noninfective intestinal disease in various ethnic groups in South Africa. *Isr J Med Sci*. 1979;15:309–313.
30. Makela J, Kiviniemi H, Laitinen S. Prevalence of perforated sigmoid diverticulitis is increasing. *Dis Colon Rectum*. 2002;45:955–961.
31. Wong SK, Ho YH, Leong AP, Seow-Choen F. Clinical behavior of complicated right-sided and left-sided diverticulosis. *Dis Colon Rectum*. 1997;40:344–348.
32. Leung DYM, Glagov S, Mathews MB. Cyclic stretching stimulates synthesis of matrix components of arterial smooth muscle cells in vivo. *Science*. 1976;191:475–477.

33. Stumpf M, Cao W, Klinge U, et al. Increased distribution of collagen type III and reduced expression of matrix metalloproteinase 1 in patients with diverticular disease. *Int J Colorectal Dis.* 2001;16:271–275.
34. Hinchey EJ, Schaal PGH, Richards GK. Treatment of perforated diverticular disease of the colon. *Adv Surg.* 1978;12:85–109.
35. Lambert ME, Knox RA, Schofield PF, et al. Management of the septic complications of diverticular disease. *Br J Surg.* 1986;73:576–579.
36. Berry AR, Turner WH. Emergency surgery for complicated diverticular disease: a five year experience. *Dis Colon Rectum.* 1989;32:849–854.
37. Hackford AW, Schoet DJ. Surgical management of complicated diverticulitis: the Lahey Clinic experience, 1967 to 1982. *Dis Colon Rectum.* 1985;28:317–321.
38. Hart AR, Kennedy JH, Stebbings WS, et al. How frequently do large bowel diverticula perforate? An incidence and cross-sectional study. *Eur J Gastroenterol Hepatol.* 2000;12:661–666.
39. Chapman J, Davies M, Wolff B, et al. Complicated diverticulitis. Is it time to rethink the rules? *Ann Surg.* 2005;242:576–583.
40. Sher ME, Agachan F, Bortul M, et al. Laparoscopic surgery for diverticulitis. *Surg Endosc.* 1997;11:264–267.
41. Ambrosetti P, Chautems R. Long-term outcome of mesocolic and pelvic diverticular abscesses of the left colon: a prospective study of 73 cases. *Dis Colon Rectum.* 2005;48:787–791.
42. Stefansson T, Ekblom A, Sparen P, et al. Association between sigmoid diverticulitis and left-sided colon cancer; a nested, population-based, case control study. *Scand J Gastroenterol.* 2004;39:743–747.
43. McGuire HH, Jr, Haynes BW, Jr. Massive hemorrhage of diverticulosis of the colon: guidelines for therapy based on bleeding patterns observed in fifty cases. *Ann Surg.* 1972;175:847–855.
44. Zuckerman GR, Prakash C. Acute lower intestinal bleeding: part II—etiology, therapy, and outcomes. *Gastrointest Endosc.* 1999;49:228–238.
45. Peura DA, Lanza FL, Gostout CJ, et al. The American College of Gastroenterology bleeding registry: preliminary findings. *Am J Gastroenterol.* 1997;92:924–928.
46. Longstreth GF. Epidemiology and outcome of patients hospitalized with acute lower gastrointestinal hemorrhage: a population-based study. *Am J Gastroenterol.* 1997;92:419–424.
47. Bokhari M, Vernava AM, Ure T, et al. Diverticular hemorrhage in the elderly: Is it well tolerated? *Dis Colon Rectum.* 1996;39:191–195.
48. Vernava AM III, Moore BA, Longo WE, et al. Lower gastrointestinal bleeding. *Dis Colon Rectum.* 1997;40:846–858.
49. Jensen DM, Machicado GA, Jutabha R, et al. Urgent colonoscopy for the diagnosis and treatment of severe diverticular hemorrhage. *N Engl J Med.* 2000;342:78–82.
50. Gordon RL, Ahl KL, Kerlan RK, et al. Selective arterial embolization for the control of lower gastrointestinal bleeding. *Am J Surg.* 1997;174:24–28.
51. McGuire HH Jr. Bleeding colonic diverticula: a reappraisal of natural history and management. *Ann Surg.* 1994;220:653–656.
52. Potter GD, Sellin JH. Lower gastrointestinal bleeding. *Gastroenterol Clin North Am.* 1988;17:341–356.
53. Watson AJM, Shanmugam V, Mackay I, et al. Outcomes after placement of colorectal stents. *Colorectal Dis.* 2005;7:70–73.
54. Ravo B, Khan SA, Ger R, et al. Unusual extraperitoneal presentations of diverticulitis. *Am J Gastroenterol.* 1985;80:346–351.
55. Wong WD, Wexner SD, Lowry A, et al. Practice parameters for the treatment of sigmoid diverticulitis—supporting documentation. *Dis Colon Rectum.* 2000;43:289–297.
56. Saini S, Wittenburg J, Butch RJ, et al. Percutaneous drainage of diverticular abscess: an adjunct to surgical therapy. *Arch Surg.* 1986;121:1475–1478.
57. Neff CC, Van Sonneberg E, Casola G, et al. Diverticular abscesses: percutaneous drainage. *Radiology.* 1987;163:15–18.
58. Kaiser A, Jiang JK, Lake JB, et al. The management of complicated diverticulitis and the role of computed tomography. *Am J Gastroenterol.* 2005;100:910–917.
59. Schechter S, Eisenstat TE, Oliver GC, et al. Computerised tomographic scan-guided drainage of intra-abdominal abscesses: preoperative and postoperative modalities in colon and rectal surgery. *Dis Colon Rectum.* 1994;37:984–988.
60. Stabile BE, Puccio E, Van Sonnenberg E, et al. Preoperative percutaneous drainage of diverticular abscesses. *Dis Colon Rectum.* 1988;31:591–596.
61. The Standard Task Force and the American Society of Colon and Rectal Surgeons. Practice parameters for the treatment of sigmoid diverticulitis. *Dis Colon Rectum.* 2000;43:289–297.
62. Franklin ME, Jr, Jacobs M, Plasencia G, et al. Is laparoscopic surgery applicable to complicated colonic diverticular disease? *Surg Endosc.* 1997;11:1021–1025.
63. Bruce CJ, Collier JA, Murray JJ, et al. Laparoscopic resection for diverticular disease. *Dis Colon Rectum.* 1996;39:S1–S6.
64. Bergamaschi R, Arnold JP. Anastomosis level and specimen length in surgery for uncomplicated diverticulitis of the sigmoid. *Surg Endosc.* 1998;12:1149–1151.
65. Kockerling F, Schneider C, Reymond MA, et al. Laparoscopic resection of sigmoid diverticulitis. Results of a multicenter study. Laparoscopic Colorectal Surgery Study Group. *Surg Endosc.* 1999;13:567–571.
66. Bonvin P, Bonte G. Diverticules geants du sigmoïde. *Arch Mal Appar Dig Mal Nutr.* 1946;35:353.
67. Hughes WL, Greene RC. Solitary air cyst of peritoneal cavity. *Arch Surg.* 1953;67:931–936.
68. Choong CK, Frizelle FA. Giant colonic diverticulum: report of four cases and review of the literature. *Dis Colon Rectum.* 1998;41:1178–1186.
69. Smith TR, Cho KC, Morehouse HT, et al. Comparison of computed tomography and contrast enema evaluation of diverticulitis. *Dis Colon Rectum.* 1990;33:1–6.
70. Eggesbo HB, Jacobsen T, Kolmannskog F, et al. Diagnosis of acute left sided colonic diverticulitis by three radiological modalities. *Acta Radiol.* 1998;39:315–321.
71. Brengman ML, Otchy DP. Timing of computed tomography in acute diverticulitis. *Dis Colon Rectum.* 1998;41:1023–1028.
72. Poletti PA, Platon A, Rutschmann O, et al. Acute left colonic diverticulitis: can CT findings be used to predict recurrence. *Am J Roentgenol.* 2004;182:1159–1165.
73. Anaya DA, Flum DR. Risk of emergency colectomy and colostomy in patients with diverticular disease. *Arch Surg.* 2005;140:681–685.
74. Kohler L, Sauerland S, Neugebauer E. Diagnosis and treatment of diverticular disease: results of a consensus development conference. *Surg Endosc.* 1999;13:430–436.
75. Schechter S, Mulvey J, Eisenstat TE. Management of uncomplicated acute diverticulitis: results of a survey. *Dis Colon Rectum.* 1999;42:470–476.
76. Tudor RG, Farmakis N, Keighley MRB. National audit of complicated diverticular disease: analysis of index cases. *Br J Surg.* 1994;81:733–735.
77. Munson KD, Hensien MA, Jacob LN, et al. Diverticulitis. A comprehensive follow-up. *Dis Colon Rectum.* 1996;39:318–322.
78. Farmakis N, Tudor RG, Keighley MRB. The 5 year history of complicated diverticular disease. *Br J Surg.* 1994;81:733–735.
79. Makela J, Vuolio S, Kiviniemi H, et al. Natural history of diverticular disease: when to operate? *Dis Colon Rectum.* 1998;41:1523–1528.
80. Ambrosetti P, Robert JH, Witzig J-A, et al. Acute left colonic diverticulitis in young patients. *J Am Coll Surg.* 1994;179:156–160.
81. Anderson DN, Driver CP, Davidson AJ, et al. Diverticular disease in patients under 50 years of age. *J R Coll Surg Edinb.* 1997;42:102–104.
82. Kohler L, Sauerland S, Neugebauer E. Diagnosis and treatment of diverticular disease: results of a consensus development conference. *Surg Endosc.* 1999;13:430–436.
83. Elliott TB, Yego S, Irvin TT. Five-year audit of the acute complications of diverticular disease. *Br J Surg.* 1997;84:535–539.
84. Stollman NH, Raskin JB. Diagnosis and management of diverticular disease of the colon in adults. *Am J Gastroenterol.* 1999;94:3110–3121.
85. Farmakis N, Tudor RG, Keighley MR. The 5-year natural history of complicated diverticular disease. *Br J Surg.* 1997;81:733–735.
86. Wolff BG, Devine R. Surgical management of diverticulitis. *Am Surg.* 2000;66:153–157.
87. Schauer PR, Ghiatas AA, Sirinek KR, et al. Virulent diverticular disease in young obese men. *Am J Surg.* 1992;164:443–446.
88. Richards RJ, Hammit JK. Timing of prophylactic surgery in prevention of diverticulitis recurrence: a cost-effectiveness analysis. *Dig Dis Sci.* 2002;47:1903–1908.
89. Salem L, Veenstra DL, Sullivan SD, Flum DR. The timing of elective colectomy in diverticulitis: a decision analysis. *J Am Coll Surg.* 2004;199:904–912.
90. Ambrosetti P, Grosshol M, Becker C, et al. Computed tomography in acute left colonic diverticulitis. *Br J Surg.* 1997;84:532–534.
91. Moreaux J, Vons C. Elective resection for diverticular disease of the sigmoid colon. *Br J Surg.* 1990;77:1036–1038.
92. Parks TG, Connell AM. The outcome of 455 patients admitted for treatment of diverticular disease of the colon. *Br J Surg.* 1970;57:775–778.



93. Bahadursingh A, Virgo KS, Kaminski DL, et al. Spectrum of disease and outcome of complicated diverticular disease. *Am J Surg.* 2003;186:696–701.
94. Sarin S, Boulos PB. Long-term outcome of patients presenting with acute complications of diverticular disease. *Ann R Coll Surg Engl.* 1994;76:117–120.
95. Eusebio EB, Eisenberg MM. Natural history of diverticular disease of the colon in young patients. *Am J Surg.* 1973;125:308–311.
96. Almy TP, Howell DA. Medical progress: diverticular disease of the colon. *N Engl J Med.* 1980;302:324–331.
97. Biondo S, Pares D, Marti Rague J, et al. Acute colonic diverticulitis in patients under 50 years of age. *Br J Surg.* 2002;89:1137–1141.
98. Broderick-Villa GB, Collins JC, Abbas MA, et al. Hospitalization for acute diverticulitis. Does not mandate routine elective colectomy. *Arch Surg.* 2005;140:576–583.
99. Vignati PV, Welch JP, Cohen JL. Long-term management of diverticulitis in young patients. *Dis Colon Rectum.* 1995;38:627–662.
100. Larson DM, Masters SS, Spiro HM. Medical and surgical therapy in diverticular disease. A comparative study. *Gastroenterology.* 1976;71:734–737.
101. Haglund U, Helberg R. Complicated diverticular disease of the sigmoid colon: an analysis of short and long term outcome in 392 patients. *Ann Chirug et Gynaecologiae.* 1979;68:41–46.
102. Roberts P, Abel M, Rosen L, et al. Practice parameters for sigmoid diverticulitis—supporting documentation. *Dis Colon Rectum.* 1995;38:126–132.
103. Tyau ES, Prytowsky JB, Joehl RJ, et al. Acute diverticulitis: a complicated problem in the immunocompromised patient. *Arch Surg.* 1991;26:855–858.
104. Griffen WO, Jr. Management of the acute complications of diverticular disease: acute perforation of colonic diverticula. *Dis Colon Rectum.* 1976;19:293–295.
105. Colcock B. Surgical management of complicated diverticulitis. *N Engl J Med.* 1958;259:570.
106. Bell AM, Wolff BG. Progression and recurrence after resection for diverticulitis. *Semin Col Rectum.* 1990;1:99–102.
107. Benn PL, Wolff BG, Ilstrup DM. Levels of anastomosis and recurrent colonic diverticulitis. *Am J Surg.* 1986;151:269–271.
108. Penfold JCB. Management of uncomplicated diverticular disease by colonic resection in patients at St. Mark's Hospital. *Gastroenterology.* 1976;11:134–137.
109. Nagorney DM, Adson M, Pemberton JH. Sigmoid diverticulitis with perforation and generalized peritonitis. *Dis Colon Rectum.* 1985;28:71–75.
110. Killingback M. Management of perforated diverticulitis. *Surg Clin North Am.* 1983;63:97–115.
111. Almy TP, Howell DA. Diverticular disease of the colon. *N Engl J Med.* 1980;302:324–331.
112. Chautems RC, Ambrosetti P, Ludwig A, Mermillod B, Morel P, Soravia C. Long-term follow-up after first acute episode of sigmoid diverticulitis: is surgery mandatory?: a prospective study of 118 patients. *Dis Colon Rectum.* 2002;45:962–966.
113. Lorimer J. Is prophylactic resection valid as an indication for elective surgery in diverticular disease? *Can J Surg.* 1997;40:445–448.
114. Leigh JE, Judd ES, Waugh JM. Diverticulitis of the colon. Recurrence after apparently adequate segmental resection. *Am J Surg.* 1962;103:51–54.
115. Thaler K, Baig MK, Berho M. Determinants of recurrence after sigmoid resection for uncomplicated diverticulitis. *Dis Colon Rectum.* 2003;46:385–388.
116. Thorn M, Graf W, Stefansson T, et al. Clinical and functional results after elective colonic resection in 75 consecutive patients with diverticular disease. *Am J Surg.* 2002;183:7–11.
117. Wolff BG, Ready RL, MacCarty RL, et al. Influence of sigmoid resection on progression of diverticular disease of the colon. *Dis Colon Rectum.* 1984;27:645–647.
118. Andeweg C, Bleichrodt R, Goor H, et al. Incidence and risk factors of recurrence after surgery for pathology-proven diverticular disease. *World J Surg.* 2008;32:1501–1506.
119. Killingback M, Barron PE, Dent OF. Elective surgery for diverticular disease: an audit of surgical pathology and treatment. *ANZ J Surg.* 2004;74:530–536.
120. Ambrosetti P, Becker C, Terrier F. Colonic diverticulitis: impact of imaging on surgical management. A prospective study of 542 patients. *Eur Radiol.* 2002;12:114–119.
121. Marinella MA, Mustafa M. Acute diverticulitis in patients 40 years of age and younger. *Am J Emerg Med.* 2000;18:140–142.
122. Acosta JA, Grenbec ML, Doberneck RC, et al. Colonic diverticular disease in patients 40 years old or younger. *Am Surg.* 1992;58:605–607.
123. Freicschlag J, Bennion RS, Thompson JE, Jr. Complications of diverticular disease of the colon in young people. *Dis Colon Rectum.* 1986;29:639–643.
124. Chodak GW, Rangel DM, Passaro E, Jr. Colonic diverticulitis in patients under age 40: need for earlier diagnosis. *Am J Surg.* 1981;141:699–702.
125. Ambrosetti P, Robert J, Witzig JA, et al. Prognostic factors from computed tomography in acute left colonic diverticulitis. *Br J Surg.* 1992;79:117–119.
126. McConnell EJ, Tessier DJ, Wolff BG. Population-based incidence of complicated diverticular disease of the sigmoid colon based on gender and age. *Dis Colon Rectum.* 2003;46:1110–1114.
127. Simonowitz D, Paloyan D. Diverticular disease of the colon in patients under age 40 years of age. *Am J Gastroenterol.* 1977;67:69–72.
128. Dobbins C, Defontgalland D, Duthie G, et al. The relationship of obesity to the complications of diverticular disease. *Colorectal Dis.* 2006;8:37–40.
129. Rosemar AA, Rosengren U. A body mass index and diverticular disease: a 28-year follow-up study in men. *Dis Colon Rectum.* 2008;51:450–455.
130. Nelson RS, Velaso A, Mukesh BN. Management of diverticulitis in younger patients. *Dis Colon Rectum.* 2006;49:1341–1345.
131. West SD, Robinson EK, Kao LS, et al. Diverticulitis in the younger patient. *Am J Surg.* 2003;186:743–746.
132. Guzzo J, Hymen N. Diverticulitis in young patients: is resection after a single attack always warranted? *Dis Colon Rectum.* 2004;47:1187–1191.
133. Spivak H, Weinrauch S, Harvey JC, et al. Acute colonic diverticulitis in the young. *Dis Colon Rectum.* 1997;40:570–574.
134. Schweitzer J, Casilas RA, Collins JC. Acute diverticulitis in the young adult is not "virulent." *Am Surg.* 2002;68:1044–1047.
135. Koutroubakis IE, Antonio P, Tzardi M, et al. The spectrum of segmental colitis associated with diverticulosis. *Int J Colorectal Dis.* 2005;20:28–32.
136. Jani N, Finkelstein S, Blumberg D. Segmental colitis associated with diverticulosis. *Dig Dis Sci.* 2002;47:1175–1181.
137. Peppercorn MA. The overlap of inflammatory bowel disease and diverticular disease. *J Clin Gastroenterol.* 2004;38:58–510.
138. Konvolinka C. Acute diverticulitis under age forty. *Am J Surg.* 1994;167:562–565.
139. Scheff RT, Zuckerman GM, Harter H, et al. Diverticular disease in patients with chronic renal failure due to polycystic kidney disease. *Ann Intern Med.* 1980;92:202–204.
140. Church JM, Fazio VW, Braun WE, et al. Perforation of the colon in renal homograft recipients. A report of cases and a review of the literature. *Ann Surg.* 1986;203:69–76.
141. Myers WC, Harris N, Stein S, et al. Alimentary tract complications after renal transplantation. *Ann Surg.* 1979;190:535–542.
142. Sawyer OI, Garvin PJ, Codd JE, et al. Colorectal complications of renal allograft transplantation. *Arch Surg.* 1978;113:84–86.
143. McCune TR, Nylander WA, Van Buren DH, et al. Colonic screening prior to renal transplantation and its impact on post-transplant colonic complications. *Clin Transplant.* 1992;6:91–96.
144. Campbell KC, Steele RJ. Non-steroidal anti-inflammatory drugs and complicated diverticular disease: a case control study. *Br J Surg.* 1991;78:190–191.
145. Papi C, Ciaco A, Koch M, et al. Efficacy of rifaximin in the treatment of symptomatic diverticular disease of the colon. A multicentre double-blind placebo controlled trial. *Aliment Pharmacol Ther.* 1995;9:33–39.
146. Papagrigroriadis S, Macey L, Bourantas N, et al. Smoking may be associated with complications in diverticular disease. *Br J Surg.* 1999;86:923–926.
147. Latella G, Pimpo MT, Sottili S, et al. Rifaximin improves symptoms of acquired uncomplicated diverticular disease of the colon. *Int J Colorectal Dis.* 2003;18:55–62.
148. Morris CR, Harvey IM, Stebbings WSL, et al. Anti-inflammatory drugs, analgesics and the risk of perforated colonic diverticular disease. *Br J Surg.* 2003;90:1267–1272.
149. Linhardt GE, Moore RC, Mason GR. Prognostic indices in the treatment of acute diverticulitis. *Am Surg.* 1982;48:217–220.
150. Sterioff S, Orringer MB, Cameron JL. Colon perforations associated with steroid therapy. *Surgery.* 1974;75:56–58.

151. Lederman ED, Conti DJ, Lempert N, Singh TP, Lee EC. Complicated diverticulitis following renal transplantation. *Dis Colon Rectum*. 1998;41:613–618.
152. Wedell J, Banzhaf G, Chaoui R, et al. Surgical management of complicated colonic diverticulitis. *Br J Surg*. 1997;84:380–383.
153. Schwesinger WH, Page CP, Gaskill HV, 3rd, et al. Operative management of diverticular emergencies: strategies and outcomes. *Arch Surg*. 2000;135:558–562.
154. Finlay IG, Carter DC. A comparison of emergency resection and staged management in perforated diverticular disease. *Dis Colon Rectum*. 1987;30:929–933.
155. Krukowski ZH, Matheson NA. Emergency surgery for diverticular disease complicated by generalised and faecal peritonitis. *Br Med J*. 1985;290:1490–1492.
156. Krukowski ZH. Diverticular disease. In: Phillips RK, ed. *Colorectal Surgery: A Companion to Specialist Surgical Practice*. London, England: WB Saunders; 2001.
157. Belmonte C, Klav JV, Perez JJ, et al. The Hartmann procedure. First choice or last resort in diverticular disease? *Arch Surg*. 1996;131:612–617.
158. Wigmore SJ, Duthie GS, Young IE, et al. Restoration of intestinal continuity following Hartmann's procedure: the Lothian experience 1987–1992. *Br J Surg*. 1995;82:27–30.
159. Foster ME, Leaper DJ, Williamson RCN. Changing patterns in colostomy closure: the Bristol experience 1975–1982. *Br J Surg*. 1985;72:142–145.
160. Pearce NW, Scott SD, Karran SJ. Timing and method of reversal of Hartmann's procedure. *Br J Surg*. 1992;79:839–841.
161. Khoury DA, Beck DE, Opelka FG, et al. Colostomy closure. *Dis Colon Rectum*. 1996;39:605–609.
162. Biondo S, Perea MT, Rague JM, et al. One-stage procedure in non-elective surgery for diverticular disease complications. *Colorectal Dis*. 2001;3:42–45.
163. Gooszen AW, Tollenaar RAE, Geelkerken RH, et al. Prospective study of primary anastomosis following sigmoid resection for suspected acute complicated diverticular disease. *Br J Surg*. 2001;88:693–697.
164. Slim K, Vicaud E, Panis Y, et al. Meta-analysis of randomised clinical trials of colorectal surgery with or without mechanical bowel preparation. *Br J Surg*. 2004;91:1125–1130.
165. Merad F, Hay J, Fingerhut A, et al. Is prophylactic pelvic drainage useful after elective rectal or anal anastomosis? A multicenter controlled randomized trial. The French Association for Surgical Research. *Surgery*. 1999;125:529–535.
166. Veldkamp R, Kuhry E, Hop WC, et al; COlon cancer Laparoscopic or Open Resection Study Group (COLOR). Laparoscopic surgery versus open surgery for colon cancer: short-term outcomes of a randomised trial. *Lancet Oncol*. 2005;6:477–484.
167. Guillou PJ, Quirke P, Thorpe H, et al; MRC CLASICC trial group. Short-term endpoints of conventional versus laparoscopic-assisted surgery in patients with colorectal cancer (MRC CLASSIC trial): multicentre, randomised controlled trial. *Lancet*. 2005;365:1718–1726.
168. Tjandra JJ, Chan MKY. Systematic review of the short term outcome of laparoscopic resection for colon and rectosigmoid cancer. *Colorectal Dis*. 2006;8:375–388.
169. Taylor CJ, Layani L, Ghush MA, et al. Perforated diverticulitis managed by laparoscopic lavage. *Aust N Z J Surg*. 2006;76:962–965.
170. Myers E, Hurley M, O'Sullivan GC, et al. Laparoscopic peritoneal lavage for generalized peritonitis due to perforated diverticulitis. *Br J Surg*. 2008;95:97–101.
171. Hansen AJ, Anderson ML, Schlinkert RT, et al. Laparoscopic repair of colonoscopic perforations: indications and guidelines. *J Gastrointest Surg*. 2007;115:655–659.
172. Scheidbach H, Schneider C, Rose J, et al. Laparoscopic approach to treatment of sigmoid diverticulitis: changes in the spectrum of indications and results of a prospective, multicenter study on 1,545 patients. *Dis Colon Rectum*. 2004;47:1183–1888.
173. Gonzalez R, Smith CD, Mattar SG, et al. Laparoscopic vs open resection for the treatment of diverticular disease. *Surg Endosc*. 2004;18:276–280.
174. Garrett KA, Champagne BJ, Valerian BT, et al. A single training center's experience with 200 consecutive cases of diverticulitis: can all patients be approached laparoscopically? *Surg Endosc*. 2008;22:2503–2508.
175. Reissfelder C, Buhr HJ, Ritz JP. Can laparoscopically assisted sigmoid resection provide uncomplicated management even in cases of complicated diverticulitis? *Surg Endosc*. 2006;20:1055–1059.
176. Vargas HD, Ramirez RT, Hoffman GC, et al. Defining the role of laparoscopic assisted sigmoid colectomy for diverticulitis. *Dis Colon Rectum*. 2000;43:1726–1731.
177. Regan JP, Salky BA. Laparoscopic treatment of enteric fistulas. *Surg Endosc*. 2004;18(2):252–254.
178. Senagore AJ, Duepre HJ, Delaney CP, et al. Cost structure of laparoscopic and open sigmoid colectomy for diverticular disease. Similarities and differences. *Dis Colon Rectum*. 2002;45:485–490.
179. Schwander O, Farke S, Fischer F, et al. Laparoscopic colectomy for recurrent and complicated diverticulitis: a prospective study of 396 patients. *Langenbecks Arch Surg*. 2004;389:97–103.
180. Le Moine MC, Fabre JM, Vacher C, et al. Factors and consequences of conversion in laparoscopic sigmoidectomy for diverticular disease. *Br J Surg*. 2003;90(2):232–236.
181. Hiltunen KM, Syria H, Matikainen M. Colonic volvulus: diagnosis and results of treatment in 82 patients. *Eur J Surg*. 1992;158:607–611.
182. Ballantyne GH. Review of sigmoid volvulus. History and results of treatment. *Dis Colon Rectum*. 1990;33:643–646.
183. Wolfer JA, Beaton LW, Anson BJ. Volvulus of the caecum: anatomical factors in its etiology: report of a case. *Surg Gynaecol Obstet*. 1942;74:882–894.
184. Rabinovici R, Simansky DA, Kaplan O. Cecal volvulus. *Dis Colon Rectum*. 1990;33:765–769.
185. Moore CJ, Corl FM, Fishman EK. CT of cecal volvulus: unraveling the image. *AJR*. 2001;177:95–98.
186. Patel A, Kaley R, Sammartano RJ. Pathophysiology of mesenteric ischemia. *Surg Clin North Am*. 1992;72:31–41.
187. Zimmerman BJ, Granger DN. Reperfusion injury. *Surg Clin North Am*. 1992;72:65–83.
188. Wyman A, Zeiderman MR. Maintaining decompression of sigmoid volvulus. *Surg Gynecol Obstet*. 1989;169:265.
189. Peoples JB, McCafferty JC, Scher KS. Operative therapy for sigmoid volvulus: identification of risk factors affecting outcome. *Dis Colon Rectum*. 1990;33:643–646.
190. Safioleas M, Chatziconstnatinou C, Felekouras E, et al. Clinical considerations and therapeutic strategy for sigmoid volvulus in the elderly: a study of 33 cases. *World J Gastroenterol*. 2007;13:921–924.
191. Akcan A, Akyildiz H, Artis T, et al. Feasibility of single-stage resection and primary anastomosis in patients with acute noncomplicated sigmoid volvulus. *Am J Surg*. 2007;193:421–426.
192. Werrkin MG, Aufses AH. Management of volvulus of the colon. *Dis Colon Rectum*. 1978;21:40–45.
193. Bhandarkar DS, Morgan WP. Laparoscopic caecopexy for caecal volvulus. *Br J Surg*. 1995;82:323.
194. Liang JT, Lai HS, Lee PH. Elective laparoscopically assisted sigmoidectomy for the sigmoid volvulus. *Surg Endosc*. 2006;20:1772–1773.
195. Cartwright-Terry T, Phillips S, Greenslade GL, Dixon AR, et al. Laparoscopy in the management of closed loop sigmoid volvulus. *Colorectal Dis*. 2007;10:370–372.
196. Liang JT, Lai HS, Lee PH. Elective laparoscopically assisted sigmoidectomy for the sigmoid volvulus. *Surg Endosc*. 2006; 20: 1772–1773.
197. Bruusgaard C. Volvulus of the sigmoid colon and its treatment. *Surgery*. 1947;22:466–478.
198. Frizelle FA, Wolff BG. Colonic volvulus. *Adv Surg*. 1996;29:131–139.
199. Benacci J, Wolff BG. Cecostomy: therapeutic indications and results. *Dis Colon Rectum*. 1995;38:530–534.

# CROHN'S DISEASE

Fabrizio Michelassi • Roger D. Hurst  
• Alessandro Fichera

*Crohn's disease* is a chronic inflammatory condition of the gastrointestinal (GI) tract that can give rise to strictures, inflammatory masses, fistulas, abscesses, hemorrhage, and cancer. This disease commonly affects the small bowel, colon, rectum, or anus. Less commonly, it can also involve the stomach, esophagus, and mouth. Often, the disease will simultaneously affect multiple areas of the GI tract.

The cause of Crohn's disease is not known and there is no curative treatment. Current medical and surgical treatment is effective at controlling the disease, but even with optimal treatment recurrences and relapses are frequent. The combined approach of optimal medical treatment with timely and strategic surgical intervention offers the most effective management to patients affected by Crohn's disease. Crohn's disease, however, can be particularly challenging, as it has a myriad of manifestations and potential complications. Additionally, its course and response to therapy can be difficult to predict. To add to the overall complexity, there are many therapeutic options that must be tailored to each individual patient and to each site of involvement to achieve optimal outcomes.

## HISTORY

Crohn's disease was fully recognized as a specific pathological entity in 1932 when Crohn et al first identified regional enteritis as a unique clinical entity.<sup>1</sup> In retrospect, case descriptions of what appeared to be Crohn's disease date back to at least 1612, when Fabry reported on the death of a boy experiencing severe abdominal pain.<sup>2</sup> Autopsy revealed a contracted ulcerated cecum and ileum with complete bowel obstruction. In 1761, Morgagni described a case of an inflamed ileum with perforation and thickened mesentery in a young man with a history of diarrhea and fever.<sup>3,4</sup>

It is unclear how common Crohn's disease might have been before 1932, as it is likely that cases of this disease occurring in an era of limited abdominal surgery may have been mistaken for other processes such as tumor or intestinal tuberculosis. In 1913, Sir Dalziel of Glasgow, Scotland, reported in the *British Medical Journal* on 13 patients and provided what is now recognized as a classic clinical and pathologic description

of Crohn's disease.<sup>5</sup> Although not often cited, Dalziel's description predates the one by Crohn et al, and some have argued that the disease should be known by the eponym "Dalziel-Crohn disease."

After the report by Crohn et al, increased awareness of the disease led to a marked increase in reported cases in the 1930s through the 1950s. The general public's awareness of the disease increased when, in 1956, one of the most famous figures of the 20th century, President Dwight Eisenhower, was diagnosed with Crohn's disease at the terminal ileum. That same year, President Eisenhower underwent intestinal bypass surgery with the small intestine proximal to the area of disease anastomosed to the transverse colon.<sup>6</sup> Following this operation, he remained relatively free of symptoms for the remainder of his life.<sup>7</sup>

Early in the history of Crohn's disease, optimal surgical management remained disputed. Initially, many thought that the disease was one of both the bowel and the mesentery and, much like malignancies, wide excision with radical dissection of the mesentery was believed to be the best way to provide for the optimal long-term outcome.<sup>8</sup> It was also appreciated that diversion of the fecal stream was effective at decreasing active inflammation and ameliorating symptoms. Frequently performed in the 1940s and 1950s, bypass operations are now only rarely undertaken for Crohn's disease.<sup>9-11</sup> Additionally, a greater understanding of the clinical course of Crohn's disease has led to more conservative resections, as it is appreciated that wide surgical margins of normal tissue and radical resection of the mesentery are not necessary to avoid early recurrence of disease.

In spite of the increased attention given to Crohn's disease of the ileum, Crohn's colitis was not widely recognized as a form of Crohn's disease until 1960 when Lockhart-Mummery and Morson firmly established the pathologic criteria for distinguishing Crohn's disease from idiopathic ulcerative colitis.<sup>12</sup>

## EPIDEMIOLOGY

After the original description of Crohn's disease in 1932, the number of reported cases increased greatly. Today it



is estimated that the incidence of Crohn's disease in the United States is approximately four new cases per year for every 100,000 persons. This disease is chronic and patients live for many years with the ailment; thus the prevalence is much higher and is reported to be between 80 and 150 cases per 100,000 persons.<sup>13,14</sup> The incidence of Crohn's disease increased rapidly from 1930 to at least the 1980s, but the incidence of new cases now appears to have stabilized.

The United States, Canada, and Europe have the highest incidence of Crohn's disease. It is much less common in Asia, South America, and Japan. Crohn's disease is believed to be uncommon in Africa, but accurate data regarding the incidence of inflammatory bowel disease in this region of the world are lacking. The peak age for contracting Crohn's disease is between 15 and 25 years. As such, Crohn's disease typically affects young adults, yet the disease can occur at almost any age. It should be noted, however, that Crohn's disease is very rare in children younger than 6 years.<sup>15</sup>

In the United States, the incidence of Crohn's disease is highest among Caucasians, low among blacks, and lowest among Hispanics and Asians. It is three to four times more common among ethnic Jews than non-Jewish whites. It also appears to be slightly more common in women than in men, although a slight male predominance has been reported in some populations.<sup>16</sup>

Familial clusters of Crohn's disease are not uncommon, with a 6- to 10-fold increase in the risk of this disease in first-degree relatives of those affected by this disease or its sister ailment, ulcerative colitis. Although familial aggregations are common, the distribution within families does not indicate a pattern of simple mendelian inheritance.

## ETIOLOGY

The etiology of Crohn's disease is not known. Many possible causes have been the subject of both speculation and investigation.<sup>4</sup> Basic science research into the molecular biology of Crohn's disease has begun to give some better insight into the genetics of this condition, but much regarding its ultimate causes remains unclear.

It is known that Crohn's disease is an altered immune response that results in inflammation and destruction of intestinal tissues. It is not clear if this altered immune response is the result of a primary dysfunction in the gut-related immune system or whether an unknown pathological trigger induces an otherwise normal immune system to overreact. Most believe that Crohn's disease occurs in individuals with a genetic predisposition and that development of the disease is dependent on exposure to environmental triggers that start the pathological sequence that ultimately manifests as Crohn's disease.

To date, no specific primary defect in the systemic or mucosal immune system has been identified. Studies of intestinal transport mechanisms have demonstrated an increase in intestinal permeability in both Crohn's disease patients and their symptom-free first-degree relatives.<sup>17-21</sup> This has

led some to speculate that Crohn's disease is the result of an altered mucosal barrier function that allows abnormal interactions to take place between the multitude of antigenic substrates normally found in the gut lumen and the immunocompetent tissue of the submucosa.

As indicated by the observed familial aggregations and variability of risks among differing ethnic and racial groups, a genetic predisposition is very likely to have a major role in the etiology of Crohn's disease. The distribution of Crohn's disease within family aggregates is complex and defies classification with simple mendelian transmission of disease. Genetic linkage studies have identified susceptibility to Crohn's disease to the *CARD15/NOD2* gene mapped to chromosome 16q12.<sup>22,23</sup> *CARD15* is a gene product related to innate immunity and it is preferentially expressed to Paneth's cells of the ileum.<sup>24,25</sup> While the *CARD15/NOD2* gene has been linked to susceptibility to Crohn's disease, the known mutations of *CARD15* are neither necessary nor sufficient to contract this disease. Hence, it appears that the genetic relationship of *CARD15/NOD2* to Crohn's disease is complex and still poorly understood.

The suspicion that infectious agents may play a role, either directly as a primary cause of Crohn's disease or indirectly as a trigger to stimulate a defective immune system, has generated much attention. This hypothesis has always found strength in the identification of noncaseating granulomas as the characteristic histopathologic lesion found in Crohn's specimens and in the isolation of *Mycobacterium paratuberculosis* from resected Crohn's disease specimens. This finding has been far from consistent, and even sensitive preliminary chain reaction studies have been unable to provide definitive evidence for the presence of *M. paratuberculosis*-specific DNA in Crohn's disease-affected segments of the bowel. Other infectious agents have been studied and shown not to be causative agents for Crohn's disease. These include measles virus, non-pylori *Helicobacter* species, *Pseudomonas*, and *Listeria monocytogenes*.<sup>26</sup> To date, no single infectious agent has been consistently associated with Crohn's disease.

Although diet modification can ameliorate the symptoms of Crohn's disease, no dietary factor has been identified as its cause. Smoking, however, has been associated with the development of Crohn's disease, with smokers having a substantially higher risk for contracting this disease than non-smokers.<sup>27-30</sup> Additionally, smoking is known to exacerbate existing Crohn's disease and can accelerate its recurrence after resection.<sup>31,32</sup> The component of cigarette smoke that is responsible for these deleterious effects on the clinical course of Crohn's disease is not known.

## PATHOLOGY

Histopathologic examination of Crohn's disease typically demonstrates transmural inflammation characterized by multiple lymphoid aggregates in a thickened submucosa. Lymphoid aggregates may extend beyond the mucosa and can be found within the muscularis propria.<sup>33</sup> The presence of

well-formed lymphoid aggregates in an edematous fibrotic submucosa is a classic histological feature of the disease. Another sentinel microscopic feature of Crohn's disease is the presence of noncaseating granulomas. Noncaseating granulomas are a valuable diagnostic feature of Crohn's disease, but they are seen in only 50% of resected specimens and are rarely seen on endoscopic biopsies. Additionally, the presence of granulomas does not correlate with disease activity, as areas of active inflammation are no more likely to contain granulomas than areas of quiescent disease.<sup>34</sup>

The earliest gross manifestations of Crohn's disease are the development of small mucosal ulcerations called aphthous ulcers.<sup>33</sup> Aphthous ulcers appear as red spots or focal mucosal depressions and typically occur directly over submucosal lymphoid aggregates. As the inflammation progresses, the aphthous ulcers enlarge and become stellate. The enlarging ulcerations then coalesce to form longitudinal mucosal ulcerations. In Crohn's disease of the small bowel, these linear ulcerations always occur along the mesenteric aspect of the bowel lumen. Further progression leads to a serpiginous network of linear ulcerations that surround islands of edematous mucosa producing the classic "cobblestone" appearance. Mucosal ulcerations may penetrate through the submucosa to form intramural channels that can bore deeply into the bowel wall and create sinuses, abscesses, or fistulas.

The inflammation process progresses to extend through all layers of the bowel wall. The inflammation of Crohn's disease also involves the mesentery and regional lymph nodes such that the mesentery may become massively thickened. With early acute intestinal inflammation, the bowel wall is hyperemic and boggy. As the inflammation becomes chronic, fibrotic scarring develops and the bowel wall becomes thickened and leathery in texture.

## CLINICAL PRESENTATION

The clinical presentation and symptoms of Crohn's disease vary greatly depending on the segment of intestine involved<sup>35</sup> and the predominant features of the disease: stricturing, perforating, or inflammatory. In the next few paragraphs the influence of disease pattern and location is described.

### Patterns of Disease

Crohn's disease can be categorized into three general manifestations: stricturing disease, perforating disease, and inflammatory disease.<sup>36</sup> These three classes do not represent truly distinct forms of the disease; rather they are terms that are used to describe the predominant gross manifestation of the disease.<sup>37</sup> It is typical for more than one pattern to occur in the same patient or even the same segment of intestine; even so, one pattern tends to predominate in most cases. It is generally the predominant pattern of disease that determines the clinical presentation and affects the therapeutic options.

### STRICTURING PATTERN

Chronic inflammation of Crohn's disease results in the development of fibrotic scar tissue that constricts the intestinal lumen with cicatricial strictures, often referred to as "fibrostenotic lesions." Patients with a stricturing pattern of this disease generally develop partial or complete intestinal obstruction, and hence their symptoms are primarily obstructive in nature. Being the result of scar tissue, fibrostenotic strictures are not reversible with medical therapy. Once fibrostenotic areas become symptomatic, significant improvement rarely occurs and surgical intervention is often required.

### PERFORATING PATTERN

Perforating Crohn's disease is characterized by the development of sinus tracts, fistulas, and abscesses. Penetrating sinus tracts develop from deep mucosal ulcerations. These sinus tracts penetrate through the muscularis propria and give rise to abscesses or to fistulas if they penetrate into surrounding structures. The term "perforating" disease can be misleading, as free perforation with spillage of intestinal contents into the abdominal cavity is not a common phenomenon with Crohn's disease. Inflammatory response around the advancing sinus tract typically results in adhesion to surrounding structures. The sinus usually bores through the area of adhesion such that abscess formation or fistulization to other structures occurs much more often than free perforation into the abdominal cavity. Typically, perforating disease is accompanied by a degree of stricture formation, but the fistula or abscess generated by the perforating component of the disease dominates the clinical picture.

### INFLAMMATORY PATTERN

The inflammatory pattern of Crohn's disease is characterized by mucosal ulceration and bowel wall thickening. The edema that results from inflammation can lead to an adynamic segment of intestine and luminal narrowing. This pattern often gives rise to obstructive symptoms in the small intestine and diarrhea in the colon. Of the three patterns of Crohn's disease, the inflammatory pattern is much more likely to respond to medical therapy.

### Location of Disease

Crohn's disease is a panintestinal condition that may affect any area from the mouth to the anus. The most commonly affected location is the terminal ileum, and one-fifth of all patients have more than one intestinal segment affected simultaneously.

### GASTRODUODENAL AND ESOPHAGEAL CROHN'S DISEASE

Crohn's disease of the upper GI tract gives rise to symptoms of nausea, vomiting, dysphagia, or odynophagia.<sup>38</sup> Oral

Crohn's disease usually manifests with aphthous ulcers in the hard palate that may cause discomfort, especially during mastication and deglutition. Esophageal Crohn's disease is uncommon in both children and adults, but it is believed to be more frequent in children than in adult patients.<sup>39</sup> Esophageal involvement with Crohn's disease may be asymptomatic or may give rise to dysphagia or odynophagia. Esophageal Crohn's disease is associated with Crohn's disease elsewhere within the GI tract, as disease isolated to the esophagus is almost never seen. Symptomatic Crohn's disease of the stomach and duodenum is more common than disease of the esophagus, yet both locations are the least frequently involved by Crohn's disease. The symptoms are usually related to the obstructive nature of the disease with delayed gastric emptying, a sense of postprandial gastric fullness, nausea, and vomiting.

### CROHN'S DISEASE OF THE SMALL INTESTINE

Abdominal pain is the predominant symptom of small bowel Crohn's disease, as it occurs in 90% of cases.<sup>35</sup> Abdominal pain may be the result of obstructive or septic complications. Pain related to partial obstruction is mostly postprandial and crampy in nature; pain from septic complications is typically steady and associated with fevers. Other common symptoms and findings include anorexia and weight loss. Weight loss is usually related to food avoidance, but in severe cases it may be the result of malabsorption. With disease of the small intestine, patients may develop a palpable mass, usually located in the right lower quadrant, related to an abscess or phlegmon in perforating disease or a thickened loop of intestine in obstructive disease. Evidence of fistulization to the skin, urinary bladder, or vagina may also be elicited with an accurate history and physical examination.

### CROHN'S COLITIS

Crohn's involvement of the colon typically results in diarrhea that may or may not be bloody. Acute flares of Crohn's colitis are often associated with fever and abdominal pain that is often exacerbated by bowel movements. Strictureing of the colon with more advanced disease can give rise to colonic obstruction. Like Crohn's disease of the small intestine, Crohn's colitis can give rise to abscess formation and fistulas. Toxic megacolon can occur with Crohn's disease, but this severe complication is rare and less frequently seen than in ulcerative colitis.<sup>40</sup>

### PERINEAL CROHN'S DISEASE

Crohn's disease frequently affects the anal crypts and gives rise to perianal fistulas, abscesses, and anal strictures. Perineal Crohn's disease is also associated with hypertrophic perianal skin tags, fissures, and perineal scarring. Approximately 40% of patients will develop perineal manifestations of Crohn's disease.<sup>41,42</sup> Anal Crohn's disease is almost always

associated with Crohn's disease present elsewhere in the GI tract, although perianal disease can be the initial symptomatic manifestation of Crohn's disease.

### EXTRAIESTINAL CROHN'S DISEASE

In addition to the inflammation of the GI tract, a variety of extraintestinal manifestations can occur in Crohn's disease. These include ocular, dermatological, hepatobiliary, and joint disorders.<sup>43,44</sup> Such extraintestinal manifestations occur in a minority of patients, but, when present, they produce symptoms that can be more severe than those of the primary intestinal disease. Ocular manifestations of Crohn's disease include uveitis and episcleritis.<sup>45</sup> Cutaneous manifestations of Crohn's disease include erythema nodosum and pyoderma gangrenosum. Joint disorders such as ankylosing spondylitis, sacroiliitis, and seronegative polyarteritis can occur. Patients with Crohn's disease are also at risk for the development of primary sclerosing cholangitis. However, the risk for primary sclerosing cholangitis is much less in Crohn's disease patients than in patients who suffer from ulcerative colitis.

Peripheral polyarteritis, episcleritis, uveitis, and erythema nodosum typically correlate with the activity of intestinal Crohn's disease. These particular extraintestinal manifestations typically regress with complete surgical resection of the affected segment of intestine or with successful medical control of the intestinal inflammation. Pyoderma gangrenosum may also improve with treatment of primary intestinal disease, but available clinical data on this particular issue have not always been consistent. The clinical course of ankylosing spondylitis and primary sclerosing cholangitis tend to be independent of the level of disease activity within the intestine. Ankylosing spondylitis and primary sclerosing cholangitis do not improve with surgical resection of the Crohn's disease-affected bowel.

## DIAGNOSIS

The onset of Crohn's disease is often insidious and many patients will experience some symptoms for months or even years before the diagnosis is made. The diagnosis of Crohn's disease is typically made by a thorough history and physical examination along with intestinal radiography and endoscopy. There is no specific laboratory test that is diagnostic for Crohn's disease. Advanced imaging studies such as computed tomography (CT) scan or magnetic resonance imaging (MRI) can assess or detect some of the complications and manifestations of Crohn's disease,<sup>46</sup> but they are generally not useful in making the initial diagnosis of Crohn's disease.<sup>47</sup>

## History and Physical Examination

The symptoms of Crohn's disease are dependent on the location of the involved segment, the pattern and the severity of



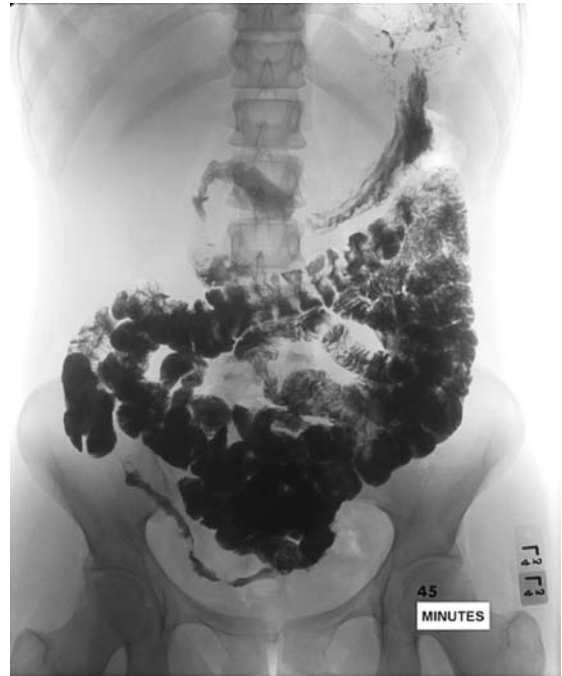disease, and the associated complications. As noted previously, in most cases the onset of disease is gradual with the most common complaints being intermittent abdominal pain, bloating, diarrhea, nausea, vomiting, weight loss, and fever.<sup>48</sup> Patients may also have symptoms related to complications of the disease, including abdominal masses, pneumaturia, perianal pain and swelling, or skin rash. In some cases the onset of symptoms can be more sudden, with patients relating a history reminiscent of acute appendicitis. In these cases, pain in the right lower quadrant may have been present only for a few hours or days. However, a brief history of symptoms such as this is atypical.

In patients suspected of having Crohn's disease, a complete physical examination should include a thorough abdominal assessment. In cases of ileal Crohn's disease, tenderness is typically present in the right lower quadrant and occasionally a palpable mass is present. The oral cavity should be examined for the presence of aphthous ulcers. The perianal area should be examined for the presence of fistulas, abscesses, or enlarged skin tags. A digital rectal examination should assess for the presence of anal strictures, fissures, and rectal mucosal ulcerations. The skin in the extremities should be examined for erythema nodosum and pyoderma gangrenosum.

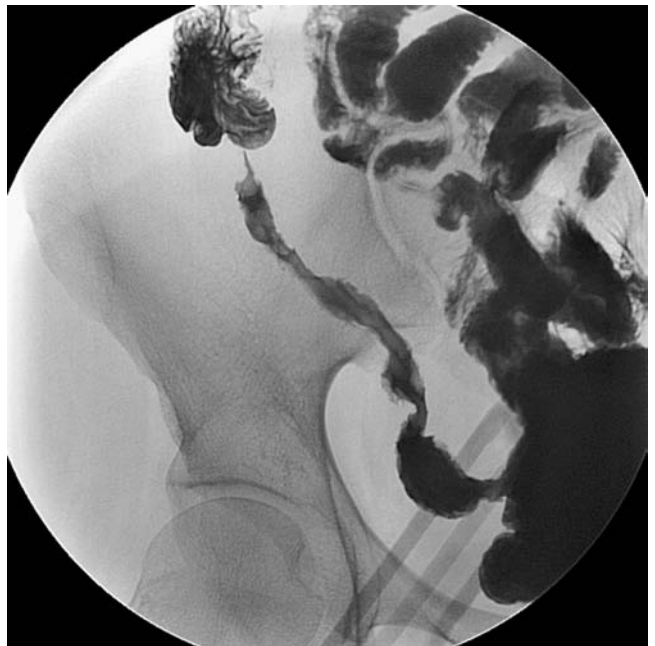## Imaging

### SMALL BOWEL RADIOGRAPHY

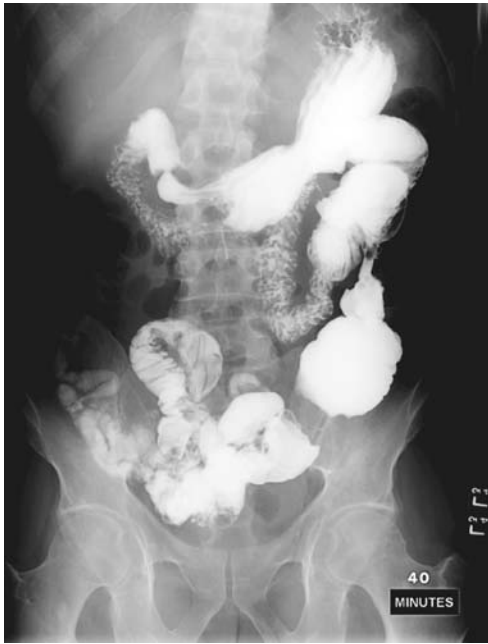Upper intestinal contrast studies, either small bowel follow-through or enteroclysis, are the best means for assessing the small bowel for Crohn's disease.<sup>49-52</sup> The radiographic abnormalities of small bowel Crohn's disease are often distinctive<sup>53</sup> (Fig. 33-1). With early Crohn's disease, mucosal granulations with ulceration and nodularity can be identified. Thickening of the mucosal folds and edema of the bowel wall itself can be demonstrated as the disease progresses. With more advanced disease, cobblestoning becomes radiographically apparent. Small bowel contrast studies can also provide information regarding enlargement of the mesentery, as well as formation of an inflammatory mass or abscess. Such findings are demonstrated by a general mass effect separating and displacing contrast-filled loops of small intestine (see Fig. 33-1; Fig. 33-2). Small bowel contrast studies can demonstrate some of the complications of Crohn's disease, including high-grade strictures and fistulas. It is important to note, however, that small bowel radiography may not identify all such lesions. For instance, many enteric fistulas including ileosigmoid and ileovesical fistulas are not typically demonstrated on contrast radiography.<sup>54,55</sup> Thus the absence of radiographic evidence for fistulization does not exclude this possibility. Additionally, small bowel studies may not demonstrate all the areas of disease with significant strictures.<sup>56</sup> While small bowel radiographs may underestimate the extent of complicated Crohn's disease, small bowel studies performed by an experienced GI radiologist are very effective as a diagnostic tool for this disease. Besides their diagnostic utility, small



**FIGURE 33-1** Small bowel radiograph demonstrating Crohn's disease of the terminal ileum. (Reprinted, with permission, from the University of Chicago General Surgery Archives.)



**FIGURE 33-2** Small bowel radiograph demonstrating Crohn's disease of the terminal ileum with high-grade strictures and ulcerations. (Reprinted, with permission, from the University of Chicago General Surgery Archives.)



**FIGURE 33-3** Small bowel radiograph demonstrating Crohn's disease with strictures in the jejunum. (Reprinted, with permission, from the University of Chicago General Surgery Archives.)

bowel radiographs can also help in assessing the extent of the disease by identifying the location and length of involved and uninvolved intestine, and by recognizing whether the disease is continuous or discontinuous with skip lesions separated by areas of normal intestine (Fig. 33-3). Experienced radiologists can also assess areas of luminal narrowing and determine if they are the result of acute inflammatory swelling or are the result of fibrostenotic scar tissue. Such a distinction provides valuable information regarding the value of medical therapy versus early surgical intervention, as inflammatory stenoses are likely to respond to medical therapy while fibrotic strictures are best treated with surgery.

## ENDOSCOPY

Upper and lower endoscopies allow for inspection of mucosal disease and provide an opportunity for a biopsy for histologic evaluation. Upper endoscopy is useful in the diagnosis of mucosal lesions of the esophagus, stomach, and duodenum; it also easily identifies strictures and grades their severity. Characteristic colonoscopic features of Crohn's disease include aphthous ulcers, longitudinal ulcerations, skip lesions often with rectal sparing, pseudopolyps, and strictures.<sup>53</sup> In many cases the terminal ileum can be entered and evaluated.

## CAPSULE ENDOSCOPY

Capsule endoscopy is a new tool in the diagnosis and evaluation of Crohn's disease.<sup>57,58</sup> With this study, a small camera

embedded within a capsule-size casing is swallowed and images from the camera are transmitted to a small electronic receiver worn by the patient. Images from the capsule endoscopy can detect subtle mucosal lesions that may not be apparent on small bowel x-rays. Prior to the capsule endoscopy, patients with suspected Crohn's disease should undergo a small bowel contrast study to exclude stricture formation, as the capsule may fail to pass through areas of narrowing and result in intestinal obstruction. The value of capsule endoscopy in the diagnosis of Crohn's disease has been recently evaluated in a prospective study from the Mayo clinic.<sup>59</sup> This study compared capsule endoscopy, CT enterography (CTE), ileocolonoscopy, and small bowel follow-through in the diagnosis of small bowel Crohn's disease in a prospective blinded trial and found that the sensitivity of capsule endoscopy was not significantly different from that of the other tests. A meta-analysis of capsule endoscopy studies comparing it to CTE suggested that the prevalence of abnormalities detected on capsule endoscopy was 38% higher than that of CTE.<sup>60</sup> However, this value was significantly higher than CTE only for the subgroup of patients with known Crohn's disease. The need for a preliminary small bowel contrast study to detect asymptomatic partial small bowel obstruction before the capsule endoscopy can be safely performed, and the lack of a clear advantage over other imaging studies limits the utility of capsule endoscopy as a first-line test in Crohn's disease and perhaps reserves this study for those cases in which there is a substantial diagnostic uncertainty.

## COMPUTED TOMOGRAPHY

Computed tomography (CT) findings of uncomplicated Crohn's disease are nonspecific, and routine CT is not necessary for the diagnosis of Crohn's disease. CT, however, is very useful in identifying the complications associated with Crohn's disease.<sup>61,62</sup> Specifically, CT can readily identify thickened and dilated intestinal loops, inflammatory masses, abscesses, and hydronephrosis resulting from retroperitoneal fibrosis and ureteral narrowing. CT scans are also the most sensitive indicator of an enterovesical fistula as suggested by the presence of air within the urinary bladder. More recently, cross-sectional imaging techniques have assumed an increasing role in the imaging of patients with Crohn's disease. Using ileoscopy and biopsy of the terminal ileum as reference to evaluate the performance characteristics of cross-sectional enterography,<sup>63</sup> CTE has been shown to have a higher sensitivity than barium small bowel follow-through.<sup>59</sup> These findings have convinced many to use CTE combined with ileocolonoscopy as a first-line test for the diagnosis and staging of Crohn's disease.<sup>59</sup> CTE exploits the high spatial resolution and speed of modern CT, using large volumes of neutral oral contrast agents to generate detailed images of the small bowel wall, lumen, and mesentery.<sup>64</sup> In addition, CTE has several potential advantages over barium studies in the identification of fistulizing disease. Unlike traditional fistulography, CTE does not suffer from superimposition of bowel loops and displays the mesentery, retroperitoneal, and abdominal wall

musculature, typically involved by fistulas. Sinus tracts and abscesses can also be readily characterized by CTE.<sup>64</sup> However, recent concerns about radiation-induced cancer arising from medically related CT<sup>65</sup> have stimulated a reassessment of the role of CTE in young Crohn's disease patients<sup>66</sup> and have encouraged the use of magnetic resonance enterography (MRE). MRE has the advantages of CTE, such as the ability to show the entire small bowel, detect transmural inflammation, grade the severity of inflammation, and detect extracolonic inflammation, but it does not require ionizing radiation. In a recent study, MRE has been shown to have similar sensitivities to CTE for detecting active small bowel inflammation, although image quality across the study cohort was better with CTE.<sup>67</sup> Therefore, MRE should be considered an alternative to CTE when radiation exposure is a concern to provide complementary information to ileocolonoscopy in the diagnosis of Crohn's disease.

## DIFFERENTIAL DIAGNOSIS

The differential diagnosis for small bowel Crohn's disease includes irritable bowel syndrome, acute appendicitis, intestinal ischemia, pelvic inflammatory disease, endometriosis, and gynecological malignancies. Other disorders that are within the differential diagnosis include radiation enteritis, *Yersinia* infections, intestinal injury from nonsteroidal anti-inflammatory agents, intestinal tuberculosis, and small bowel tumors.

Among the most important ailments to consider are small bowel malignancy and intestinal tuberculosis. In patients in whom small bowel malignancy is suspected, resection should be undertaken to make certain the diagnosis. The exclusion of intestinal tuberculosis can be difficult, as the inflammation and stricturing of the terminal ileum can occur in a manner that closely mimics Crohn's disease. The patient should be assessed for exposure to tuberculosis and screened for tuberculosis with a purified protein derivative skin test. Chest radiography should also be considered. Even when the diagnosis of Crohn's disease is certain, patients who coincidentally are found to also have latent tuberculosis should be treated in accordance with American Thoracic Society guidelines prior to the initiation of immunosuppressive therapy for management of their Crohn's disease.<sup>68</sup>

Intestinal injury from nonsteroidal anti-inflammatory drugs (NSAIDs) can result in focal enteritis with ulceration and stricture formation.<sup>69,70</sup> These manifestations can be very difficult to distinguish from Crohn's disease of the small bowel. This rare side effect from the very commonly used NSAIDs often requires resection or biopsy to confirm the diagnosis.

For Crohn's disease of the colon, the differential diagnosis includes ulcerative colitis, infectious colitis, collagenous colitis, ischemic colitis, diverticular disease, Behçet's disease, colonic neoplasm, solitary rectal ulcer syndrome, and NSAID colopathy.

The entity that is most difficult to distinguish from Crohn's colitis is ulcerative colitis. The diagnosis of ulcerative

colitis cannot be made with absolute certainty, as it is possible for Crohn's disease of the colon to reproduce all the features of ulcerative colitis. It is only when features appear that are unique to Crohn's disease that the diagnosis of Crohn's disease can be made. Such distinguishing features of Crohn's disease include small bowel involvement, perianal disease, skip lesions, transmural inflammation, fistulas, abscesses, and noncaseating granulomas. After a complete history and physical examination complemented by appropriate radiological, endoscopic, and humoral studies, Crohn's and ulcerative colitis can be distinguished with a high degree of confidence in as many as 85–90% of cases, yet in the remaining 10–15% of cases the differential diagnosis will remain indeterminate. This has major bearing on the surgical options available for such patients.

## MEDICAL MANAGEMENT

The goal of medical treatment of Crohn's disease is to provide long-lasting symptomatic relief while avoiding excessive morbidity. Crohn's disease cannot be cured by medical treatment, but it may afford long periods of disease control and avoidance of surgical intervention. Thus it is important that the surgeon have an understanding of the basics of medical therapy for Crohn's disease. Selecting the optimal medical treatment for each individual requires experience and special expertise because of the variable course of the disease, the myriad of different clinical presentations and associated complications, and the desire to optimize medical treatment for each clinical situation.

### Corticosteroids

Corticosteroids are the most effective agents for controlling acute exacerbations of Crohn's disease, but their use is limited due to the risk of serious side effects. The majority of patients with active small bowel Crohn's disease will experience clinical remission with a short course of oral prednisone given in a dose between 0.25 and 0.5 mg/kg/d.<sup>71</sup> For patients unable to take oral medications, methylprednisolone can be administered in the adult at doses of 40–60 mg given as a daily infusion.<sup>72</sup> Common side effects from corticosteroids include diabetes, osteoporosis, cataracts, osteonecrosis, myopathy, psychosis, opportunistic infections, and adrenal suppression. The risks for these side effects are related to both the dose and the duration of steroid therapy.

### 5-Aminosalicylic Acid

The aminosalicylates as a group of medications include sulfasalazine and 5-aminosalicylic acid (5-ASA) derivatives. The exact mechanism of action for these agents is not clear, but 5-ASA is thought to function through various pathways.<sup>73</sup> 5-ASA compounds inhibit leukotriene production by inhibition of



5-lipoxygenase activity. 5-ASA also inhibits the production of interleukin-1 and tumor necrosis factor (TNF). 5-ASA compounds are weak inhibitors of cyclooxygenase (COX) activity, and it is unlikely that they act through the inhibition of prostaglandin production. Aminosalicylates are effective in the treatment of mild to moderate Crohn's disease. 5-ASA given in a controlled-release preparation is also effective as maintenance therapy to prevent recurrence after a flare of disease has been effectively managed either medically or surgically.<sup>74–77</sup>

Aminosalicylates come in a variety of preparations, each designed to deliver the drug in a topical fashion to the affected segments of intestine.<sup>78</sup> For instance, Asacol (mesalamine) is 5-ASA contained within a pH-dependent resin designed to release the drug in the terminal ileum and colon where the pH is typically greater than 7.0. Pentasa (mesalamine) is 5-ASA contained within ethylcellulose-coated microgranules designed to slowly release the active compound throughout the entire small bowel and colon. Colazal (balsalazide) is 5-ASA bound to an inert carrier by an AZO bond. This bond is broken by bacterial enzymes found within the colon, releasing the active 5-ASA compound to the colonic mucosa.

It is important to emphasize that mesalamine and its derivatives should not be confused with acetylsalicylic acid (aspirin) and other NSAIDs. Unlike 5-ASA compounds, classic NSAIDs are powerful inhibitors of COX-1 and COX-2. Many clinicians have had concerns that NSAIDs may exacerbate Crohn's disease.<sup>79–81</sup> Although the basis of these concerns has been challenged,<sup>82–84</sup> it is recommended that patients with Crohn's disease avoid NSAIDs and use alternative medications when appropriate.

## Immunomodulators (Azathioprine and 6-Mercaptopurine)

Azathioprine and 6-mercaptopurine (6-MP) are immunosuppressive agents that inhibit cytotoxic T-cell and natural killer cell function. These agents are effective in treating mild to moderate Crohn's disease.<sup>72,85</sup> Azathioprine given at 2.0–2.5 mg/kg/d or 6-MP in doses of 1.0–1.5 mg/kg/d will result in a 50–60% response rate in patients with active Crohn's disease.<sup>72,86</sup> Both 6-MP and azathioprine are also effective in maintaining remission following surgery or successful medical management.<sup>75</sup>

## Infliximab

Infliximab is a chimeric mouse-human monoclonal antibody to TNF. TNF is a proinflammatory cytokine that is believed to be important in the pathophysiology of Crohn's disease. Infliximab binds to both free and membrane-bound TNF and prevents TNF from binding to its cell surface receptors.<sup>73</sup> Clinical trials have demonstrated an 80% response rate with a single dose of infliximab.<sup>87,88</sup> It is important to note that the doses and dosing intervals of infliximab must

be individualized, but a typical regimen would include 5 mg/kg of infliximab given IV at weeks 0, 2, and 6, with a dose of 5 mg/kg every 8 weeks thereafter. Because infliximab is a potent immunosuppressive agent, concerns have been raised about the risk for poor wound healing and postoperative septic complications. Current available data on the perioperative risks associated with infliximab are somewhat conflicting. Early studies have suggested that preoperative infliximab use does not appear to increase the risk for postoperative complications following abdominal surgery for Crohn's disease.<sup>89–91</sup> More recently, however, a study from the Cleveland clinic demonstrated an increased risk for infectious complications and intra-abdominal abscesses in Crohn's disease patients undergoing surgery who received infliximab.<sup>92</sup> This study also found that the presence of diverting stoma significantly decreased the risk for septic complications in patients who had been treated with infliximab.

## Other Medical Therapies

Other agents that are used with varying success in the treatment of Crohn's disease include methotrexate, metronidazole, cyclosporine, tacrolimus, and thalidomide. With the exception of metronidazole, each one of these agents requires a complete and sophisticated knowledge of appropriate dosing, side effects, and therapeutic efficacy, which is beyond the scope of this chapter. Metronidazole is indicated in the maintenance therapy of chronic perineal septic complications and in the treatment of bacterial overgrowth associated with chronic obstructive disease of the small bowel. Long-term side effects include peripheral paresthesias, which are usually transient if the drug is discontinued as soon as they are experienced.

## SURGICAL TREATMENT

Similarly to medical treatment, the goal of surgical treatment of Crohn's disease is to provide long-lasting symptomatic relief while avoiding excessive morbidity. Crohn's disease cannot be cured by surgical therapy, and thus surgery, like medical treatment, should be considered palliative. Complete extirpation of disease should not be the primary goal of surgery, as this does not produce cure and is frequently counterproductive. Rather, treatment of complications and palliation of symptoms while avoiding excessive loss of intestine should be the main aims of surgical treatment.

To avoid excessive loss of intestine, nonresectional techniques such as stricturoplasty may be required. Additionally, optimal surgical therapy may require leaving behind segments of the intestinal tract affected by mild but asymptomatic disease with resection of only the areas of severe and symptomatic Crohn's disease. The best surgical strategy for each patient with Crohn's disease takes into account the indications for surgical treatment and the natural history of the disease, with its high risk for recurrence and the need for repeated surgeries.

## Indications for Surgery

### FAILURE OF MEDICAL TREATMENT

The failure to respond to medical treatment or the inability to tolerate effective therapy are the most common indications for surgical treatment of Crohn's disease.<sup>93</sup> Some patients may respond to the initial medical therapy only to rapidly relapse with tapering of the medical treatment. For example, some patients respond well to steroid therapy but become steroid-dependent as tapering of the steroid dose results in recurrent symptoms. Because of the severe complications that are virtually inevitable with prolonged steroid treatment, surgery is warranted if the patient cannot be weaned from systemic steroids within 3–6 months. The occurrence of complications related to the medical treatment or the progression of disease while on maximal medical treatment represent additional indications for surgical treatment.

### INTESTINAL OBSTRUCTION

Partial or complete intestinal obstruction is a common indication for operation for Crohn's disease.<sup>94</sup> The clinical presentation of chronic partial small bowel obstruction is much more typical than complete obstruction. Patients with chronic partial small bowel obstruction due to Crohn's disease may experience postprandial cramps, abdominal distension, borborygmi, and weight loss. To avoid symptoms, many patients will restrict their diets to soft foods or even liquids. If partial obstruction from Crohn's disease is primarily due to acute inflammation and bowel wall thickening, initial medical therapy is warranted. If, however, the obstructive symptoms are due to high-grade fibrostenotic lesions, medical treatment will not reverse these lesions and surgery is indicated.

When complete intestinal obstruction occurs, initial conservative treatment with nasogastric decompression and intravenous hydration is warranted.<sup>34,95</sup> Intravenous steroids are also administered. This allows for decompression of acutely distended and edematous bowel and, in most cases, for resolution of the complete obstruction. Resolution of the complete obstruction should not lead the physician to attempt treating the patient with continuing medical therapy. Patients with complete obstruction who respond well to initial conservative therapy are at high risk for persistent or recurrent symptoms of obstruction and are best managed with surgery once adequate decompression is achieved. The surgery can be performed under elective and safer conditions after appropriate bowel preparation.

### FISTULAS

Intestinal fistulas occur in one-third of Crohn's disease patients.<sup>54</sup> Intestinal fistulas, however, are the primary indication for surgery in only a minority of patients. Thus the presence of an intestinal fistula is not in and of itself an indication for surgery.<sup>96,97</sup> In general, intestinal fistulas are the primary

indication for surgical treatment if they connect with the genitourinary tract, or if their drainage is cause for personal embarrassment and discomfort (enterocutaneous and enterovaginal fistulas), or if they create a bypass of such magnitude as to cause intestinal malabsorption.

Fistulas between the ileum and the urinary bladder often result in recurrent urinary tract infections, including pyelonephritis. While it is not mandatory to operate on all cases of enterovesical fistulas, surgery is warranted to avoid deterioration of renal function with recurrent infections or if symptoms persist in spite of appropriate medical therapy.

Enterocutaneous fistulas and enterovaginal fistulas often cause physical discomfort and personal embarrassment. A trial of medical therapy may be elected for enterocutaneous and enterovaginal fistulas, but most such cases will require surgery.<sup>98,99</sup>

Occasionally, an enteroenteric fistula can result in significant symptoms. Fistulas that result in functional bypass of a major intestinal segment can result in malabsorption or diarrhea. These fistulas need to be addressed surgically.

### ABSCESSSES AND INFLAMMATORY MASSES

Intra-abdominal abscesses and inflammatory masses occur less frequently than fistulas but are more often an indication for operative intervention.<sup>100</sup> Small abscesses seen on CT may warrant a trial of treatment with antibiotics, but almost all intra-abdominal abscesses will require drainage. In a vast majority of cases, Crohn's abscesses can be drained percutaneously with CT or ultrasound guidance.<sup>101–103</sup> The rare large intralooop abscesses may require open surgical drainage. Often, in such cases the abscess can be completely extirpated with the resection of the diseased segment of intestine.

Crohn's abscesses usually originate from a severely diseased segment of bowel. A Crohn's abscess that has been drained percutaneously is very likely to recur or result in an enterocutaneous fistula, and surgical resection is often advised even after successful drainage.<sup>103</sup> Inflammatory masses indicate severe disease and often harbor an unrecognized abscess.<sup>100</sup> Thus, inflammatory masses that do not readily respond to antibiotic treatment should be considered for surgical treatment.

### PERFORATION

Free perforation is a rare complication of Crohn's disease occurring in fewer than 1% of cases.<sup>104</sup> When this complication occurs, it is an obvious indication for urgent operation. The diagnosis of free perforation is made by detecting a sudden change in the patient's symptoms along with the development of the physical findings of peritonitis or the identification of free intraperitoneal air as demonstrated on plain x-rays or CT scans. The use of immunosuppressants and glucocorticosteroids can blunt many of the physical findings of acute perforation; therefore the index of suspicion for perforation must be higher in immunocompromised patients

who complain of worsening symptoms or show early signs of sepsis. Most patients, however, will demonstrate classic signs of peritonitis with rebound, rigidity, guarding, and loss of bowel sounds.

## HEMORRHAGE

Hemorrhage is an uncommon complication from Crohn's disease. Massive GI hemorrhage is rare and occurs more frequently from Crohn's colitis than in small bowel Crohn's disease.<sup>105</sup> Hemorrhage from small bowel Crohn's disease tends to be indolent with episodic or chronic bleeding requiring intermittent transfusions, but it rarely requires emergent surgery. Localization of the site of bleeding is accomplished by angiography in the presence of brisk bleeding; otherwise colonoscopy can be attempted preoperatively to localize a source of lower GI hemorrhage. Intraoperative localization can be aided by enteroscopy or colonoscopy.

When severe hemorrhage occurs in Crohn's disease, it is usually due to erosion of a single vessel by a deep ulcer or fissure. Recurrent bleeding in an area of small bowel disease is a common phenomenon, and it has been argued that even after control of hemorrhage from small bowel Crohn's disease with conservative management, elective resection of the areas of Crohn's disease should be undertaken to prevent recurrent bleeding.

Patients with Crohn's disease are also at risk for bleeding from peptic ulcer disease. This is particularly true for patients receiving corticosteroid therapy. For this reason, Crohn's disease patients who develop GI bleeding should undergo an upper endoscopy to rule out gastric or duodenal ulcers.

## CANCER OR SUSPICION OF CANCER

The presence of Crohn's disease increases the risk of adenocarcinoma of the colon and small intestine.<sup>106</sup> The diagnosis of adenocarcinoma of the small bowel is difficult because symptoms and radiographic findings of small bowel malignancy can be similar to those of the underlying Crohn's disease. Male patients and patients with long-standing disease appear to be at increased risk for small bowel adenocarcinoma.<sup>106</sup> Defunctionalized segments of bowel also seem to be at particular risk for malignancy.<sup>107</sup> For this reason, bypass surgery should be avoided for Crohn's disease of the small intestine, and defunctionalized rectal stumps should either be restored to their function or excised.

Adenocarcinoma of the small intestine should be suspected in any patient with long-standing disease whose symptoms of obstruction progress after a lengthy quiescent period. Surveillance for colonic malignancies can be undertaken by colonoscopy with random mucosal biopsy. If dysplasia is encountered, resection of the areas of Crohn's disease should be considered.<sup>108,109</sup> Areas of stricture formation within the colon should be closely examined and biopsied. Strictures that are too narrow to allow passage of the colonoscope or cannot be adequately assessed colonoscopically should be resected.

## GROWTH RETARDATION

Growth retardation occurs in a quarter of children affected by Crohn's disease. Although steroid treatment may delay growth in children, the major cause of growth retardation in Crohn's disease patients is the malnutrition associated with active intestinal disease.<sup>110,111</sup>

## Preoperative Preparation and Evaluation

A complete assessment of the GI tract is required prior to surgery. Full delineation of the extent of disease and associated complications is necessary to plan for the optimal surgical strategies.

Assessment of the small intestine can be performed with a small bowel follow-through, an enteroclysis study or a CTE. The colon and rectum are best evaluated by colonoscopy. Barium enema studies can also be used to evaluate for colonic disease, particularly in cases in which strictures do not allow passage of the colonoscope. If the patient has had a previous resection of the ileocecal valve, a contrast enema can be a useful means of evaluating the ileocolonic anastomosis and the preanastomotic segment for recurrent disease. If an abscess, fistula or inflammatory mass is suspected, a CT scan of the abdomen and pelvis with both oral and IV contrast should be obtained. CTE combined with ileocolonoscopy is used by many as a first-line test for the staging of Crohn's disease.<sup>59</sup> In patients in whom urgent surgery is required, a full evaluation of the GI tract prior to surgery may not be feasible. In these cases, evaluation of disease must be accomplished intraoperatively, and both the patient and the surgeon must be prepared for a wide variety of surgical possibilities.

As with preparation for any major operation, metabolic derangements must be treated prior to surgery. Fluid and electrolyte abnormalities must be corrected. Patients with profound anemia need to be transfused and coagulopathies must be addressed. Patients with cardiovascular or pulmonary disease should have the condition stabilized and their functional capacity optimized prior to operation. Most patients with Crohn's disease will not require preoperative parenteral nutrition, as most suffer from only a minor degree of malnutrition. There are rare cases, however, in which the nutritional status of the patient has been so severely compromised that they benefit from several weeks of bowel rest, hyperalimentation, and ongoing medical treatment before operation.

The absolute need for mechanical bowel preparation is controversial.<sup>112-114</sup> Traditionally mechanical bowel preparations have been an unquestioned standard to lessen the risks of sepsis and to allow for a safe anastomosis. Recently these advantages have been challenged.<sup>112,113</sup> Even so, it is common practice for patients undergoing intestinal resection for Crohn's disease to undergo a complete mechanical bowel preparation with either polyethylene glycol or sodium phosphate. Should the patient be unable to tolerate oral preparations, enemas can be utilized. Prophylactic broad-spectrum antibiotics are administered perioperatively,<sup>115</sup> and stress dose



steroids must be given to patients suspected of hypothalamic-pituitary-adrenal suppression. If feasible, well-contained intra-abdominal abscesses should be drained percutaneously prior to surgery. If an abdominal stoma is contemplated, the optimal site for the stoma location should be marked preoperatively. In patients in whom preoperative CT scan suggests significant inflammation in proximity to the ureters, preoperative ureteral stenting can be helpful.

Some have suggested that, to improve the safety of surgery for Crohn's disease, anti-inflammatory Crohn's medication should be either lowered or discontinued prior to elective surgery. Recent studies, however, have shown that preoperative use of steroids and antimetabolites does not appear to affect the perioperative morbidity, and hence discontinuation of these medications is not likely to result in significant benefit. Methotrexate and infliximab, on the other hand, are two medications that may be worth discontinuing at least 2 weeks and 2–3 months, respectively, prior to surgery. Laboratory studies have shown decreased wound healing with methotrexate,<sup>116</sup> and clinical data to evaluate the safety of methotrexate in patients undergoing bowel resection with anastomosis are lacking. A recent study from the Cleveland clinic has demonstrated an increased risk for infectious complications and intra-abdominal abscesses after recent treatment with infliximab.<sup>92</sup> If surgical treatment is necessary within 2 months after an infliximab infusion, consideration should be given to postpone reestablishment of the GI continuity or to protecting a newly fashioned anastomosis with a diverting stoma.

## Surgical Options

### INTESTINAL RESECTION

Intestinal resection with anastomosis or stoma formation is the most common surgical procedure performed for the treatment of Crohn's disease. Most cases of Crohn's disease require only limited resections that are generally well tolerated and do not place these patients at risk for short bowel syndrome. Cumulative clinical data including randomized studies have indicated that resection of Crohn's disease need only encompass the grossly apparent disease, as wider resections do not improve the outcome after surgery.<sup>117–120</sup> Microscopic resection margins that are grossly normal but demonstrate microscopic evidence for Crohn's activity do not result in early recurrence or other complications. Hence, intraoperative frozen section of the resection margins is not necessary.<sup>121</sup>

The extent of mesenteric dissection does not affect the long-term results either; hence the mesentery can be divided at the most advantageous level. Division of the thickened mesentery of small bowel Crohn's disease can be the most challenging aspect of the procedure. Identification and isolation of individual mesenteric vessels is not feasible with a thickened Crohn's mesentery. Although many approaches to this problem have been described, a common technique is to apply overlapping clamps on either side of the intended line of transection. The mesentery is then divided between the

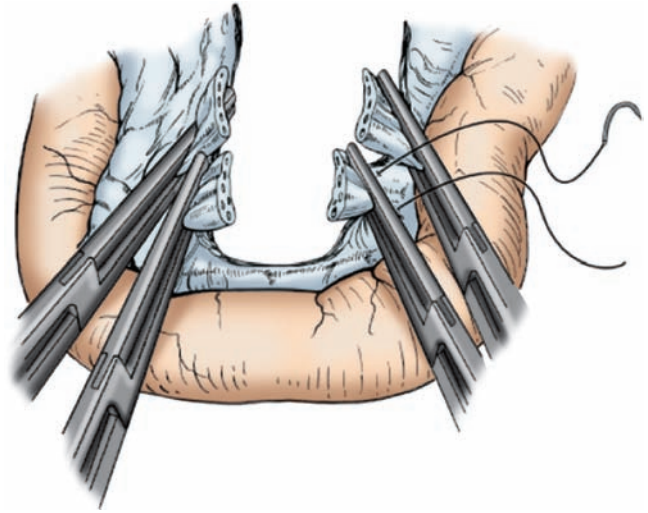


FIGURE 33-4 Technique for division of thickened Crohn's mesentery.

clamps, and the tissue contained within the clamps is suture-ligated (Fig. 33-4). In severe cases, a vascular clamp may be used at the root of the small bowel mesentery to obtain proximal control: mattress sutures may then need to be applied to the cut edge of the mesentery to control bleeding. The use of tissue welding devices such as the LigaSure device (Valleylab, Boulder, CO) can be useful for sealing vessels within the thickened mesentery. Even with these devices, mattress sutures in the mesentery are commonly needed for complete hemostasis. In spite of the difficulty dealing with the thickened and often hyperemic mesentery, resection can be performed with a low risk for postoperative hemorrhage and the risk for postoperative hemoperitoneum requiring reexploration has been reported to be less than 0.5%.<sup>93</sup>

### ANASTOMOSIS

There is no overriding consensus regarding the optimal technique for intestinal anastomosis in Crohn's disease.<sup>74,122–126</sup> It is well established that recurrent Crohn's disease after resection of terminal ileal disease is most likely to occur at the ileocolonic anastomosis or at the preanastomotic ileum. It has been proposed that large-caliber anastomoses require a longer period to stricture down to a critical diameter that becomes symptomatic. The argument is made that a longer side-to-side anastomosis may be beneficial over an end-to-end or end-to-side anastomosis.<sup>125</sup> To date, however, clinical data do not indicate a benefit for one particular intestinal configuration over another.<sup>124</sup> Intestinal anastomosis for Crohn's disease cases can be fashioned with a stapling device or may be hand-sutured. When performed under selective conditions, resection with primary anastomosis for Crohn's disease can be performed with a high degree of safety and small bowel anastomotic dehiscence rates can be kept under 1%.<sup>93</sup> In the presence of sepsis, severe scarring, malnutrition, or recent use of methotrexate or infliximab, it may be wise to protect

the anastomosis with a proximal loop stoma or to forego the anastomosis altogether and bring out an end stoma at the point of resection.

## STOMA FORMATION

Permanent stomas are required for the surgical treatment of Crohn's proctitis and occasionally required for the management of severe, unrelenting perianal disease. Temporary stomas are much more common and typically used as a means of protecting a distal anastomosis or when an anastomosis is not advisable.

If an ileostomy or colostomy is contemplated, selection of the optimal placement of the stoma should be determined preoperatively.<sup>127</sup> Proper stoma location is critical to achieve a satisfactory stoma. It is preferable to locate the ileostomy over the left or right rectus abdominis muscle on a flat area away from deep skin folds and bony prominences.<sup>128</sup> The surface of the abdomen must be evaluated in both the sitting and standing positions, as this will often demonstrate skin folds and creases not evident in the supine position. Attention must be paid to determining the level of the patient's belt line and every effort is made to place the stoma below it. Once the optimal position of the stoma has been identified, it is marked in a manner that will remain visible at the time of surgery.

Complications related to intestinal stomas are common. They include peristomal hernia, prolapse, and stricture. Peristomal hernia is the most common ostomy-related complication. It can be anticipated that approximately 25% of patients with a permanent stoma will require surgical revision of their ostomy to deal with one or more of these complications.<sup>129</sup>

## BYPASS PROCEDURES

Bypass procedures became popular in the 1940s and 1950s once physicians and surgeons realized that aggressive enterectomies did not reduce the incidence of recurrence and were fraught with the development of short gut syndrome. Initially conceived to bypass an area of stricture or obstruction, the use of bypass procedures was eventually extended to Crohn's disease complicated by septic complications. Increased experience with bypass procedures revealed that persistence of disease put patients at risk of persistent sepsis and eventually neoplastic transformation. Because of these complications, bypass procedures were supplanted by limited intestinal resection as the main surgical option in the late 1960s in all intestinal districts except the duodenum, where a simple side-to-side retrocolic gastrojejunostomy adequately relieves the obstructive symptoms. With increased experience and confidence in the performance of strictureplasty, duodenal disease is nowadays more and more commonly handled with strictureplasties.

## STRICTUREPLASTY

Strictureplasty techniques have gained popularity as a safe and effective means of treating stricturing Crohn's disease of the small intestine without resorting to lengthy resections.

Strictureplasties are best used when resection would otherwise result in loss of a lengthy segment of bowel and thus place the patient at risk for short bowel syndrome. This would include cases with long segments of stricturing disease and patients with multiple prior resections. They are also indicated when they offer a simpler alternative to resection, such as in short recurrent disease at a previous ileocolic or enteroenteric anastomosis.

It is generally accepted that the advantage conferred by a strictureplasty over a resection in the preservation of intestinal absorptive capacity is mainly due to the sparing of normal areas in between strictures that would be otherwise sacrificed. Although this is true, there is increased evidence that the acuity of the disease decreases at the site of the strictureplasty and the disease becomes quiescent.<sup>130</sup> Whether this correlates with a simultaneous restoration of absorptive function has not yet been established.

The most commonly performed strictureplasty is the Heinecke-Mikulicz strictureplasty.<sup>131-133</sup> The Heinecke-Mikulicz is named after the pyloroplasty technique from which this procedure is derived. With the Heinecke-Mikulicz strictureplasty, a longitudinal incision is made along the antimesenteric border of the stricture (Fig. 33-5). This incision should extend for 1–2 cm into the normal elastic bowel on either side of the stricture. Once the enterotomy is made, the area of the stricture should be closely examined. If there is any concern that the stricture may harbor a malignancy, a biopsy with frozen section must be obtained. Complete hemostasis should be obtained with precise application of electrocautery.

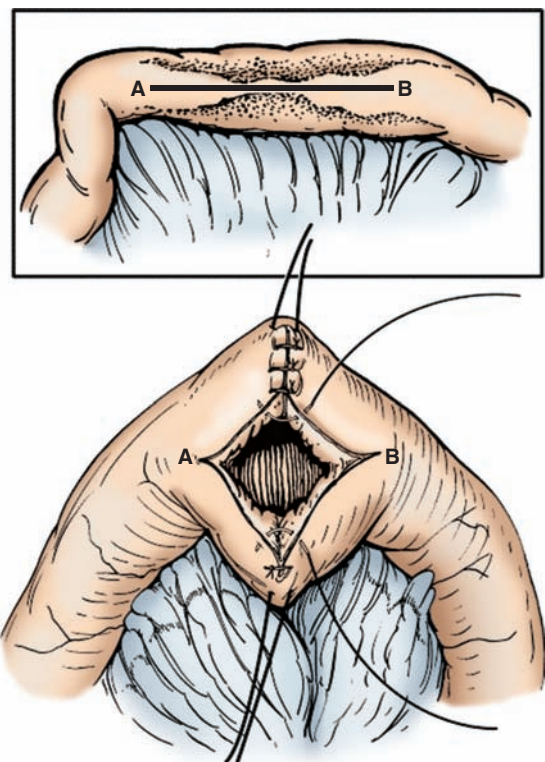


FIGURE 33-5 Heinecke-Mikulicz strictureplasty.

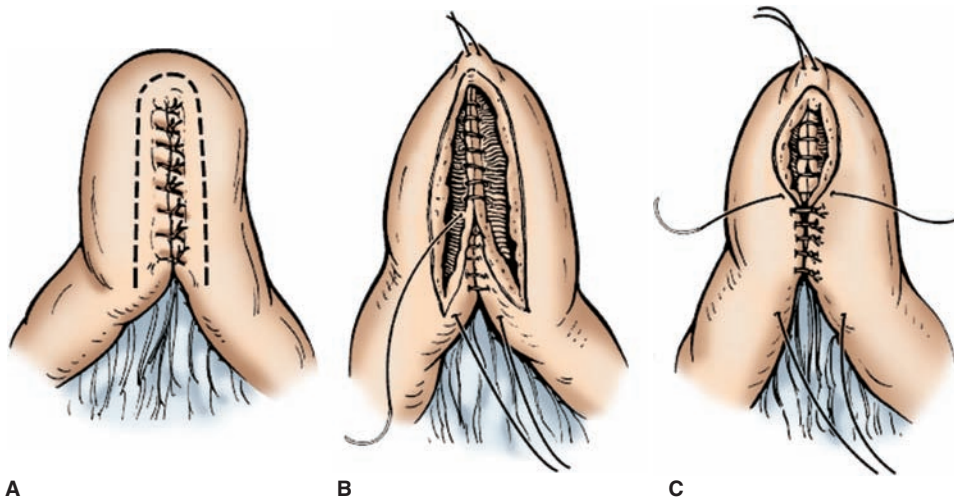


FIGURE 33-6 Finney strictureplasty.

The longitudinal enterotomy of the Heinecke-Mikulicz strictureplasty is then closed in a transverse fashion. The closure can be accomplished with either single- or double-layered sutures. The Heinecke-Mikulicz stricture technique is appropriate for short-segment strictures of 2–5 cm in length.

The Finney strictureplasty, also named for the pyloroplasty technique from which this approach is derived, can be used for strictures up to 15 cm in length.<sup>131</sup> With the Finney strictureplasty technique, the strictured segment is folded onto itself in a U-shape<sup>134</sup> (Fig. 33-6). A row of seromuscular sutures is placed between the two arms of the U, and a longitudinal U-shaped enterotomy is then made paralleling the row of sutures. The mucosal surface is examined and biopsies are taken as necessary. Hemostasis is obtained with electrocautery. Full-thickness sutures are then placed beginning at the posterior wall of the apex of the strictureplasty and then continued down to approximate the proximal and distal ends of the enterotomy. This full-thickness suture line is then continued anteriorly to close the strictureplasty. To complete the procedure, a row of seromuscular Lembert sutures is placed anteriorly. In essence, the Finney is a short side-to-side functional anastomosis. A very long Finney strictureplasty may result in a functional bypass with a large lateral diverticulum. This diverticulum, in theory, could be at risk for bacterial overgrowth and the blind loop syndrome. Fortunately, this theoretical concern has not been observed in clinical practice.

The purpose of the strictureplasty is to preserve intestinal length that otherwise would be sacrificed with resection. Those cases with long segments of stricturing disease are the ones in which nonresectional methods should be aggressively pursued. To manage such cases, multiple strictureplasties are typically required. In general, however, repeated Heinecke-Mikulicz or Finney strictureplasties should be separated from each other by at least 5 cm. Otherwise the result can be a bulky and relatively unyielding segment of intestine with considerable tension placed on each suture line.

Patients with long-segment stricturing disease and multiple strictures grouped close together are best managed with a side-to-side isoperistaltic strictureplasty, also called *Michelassi strictureplasty*.<sup>135</sup> With this technique, the segment of stricturing disease is divided at its midpoint. The proximal and distal ends are then drawn onto each other in a side-to-side fashion (Fig. 33-7). Division of some of the mesenteric vascular arcades facilitates the positioning of the two limbs over each other. The proximal and distal loops are then sutured together with a layer of interrupted seromuscular sutures. A longitudinal enterotomy is then made along both of the loops (Fig. 33-8). The intestinal ends are spatulated to provide a smoothly tailored fit to the ultimate closure of the strictureplasty. Again, this is the time to examine the mucosal surface of the intestine to detect potential areas of neoplastic transformation and control bleeding. The outer suture line is

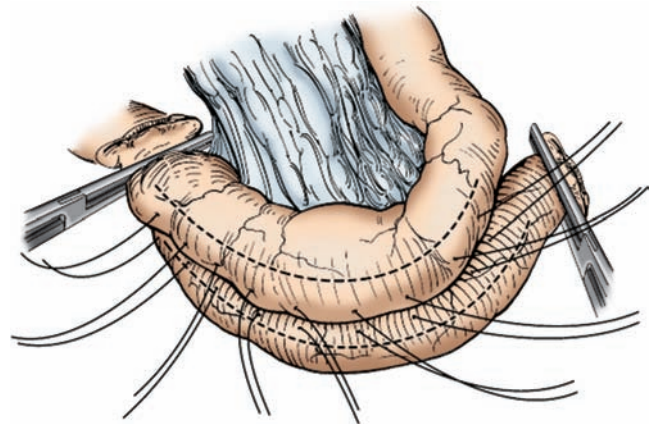
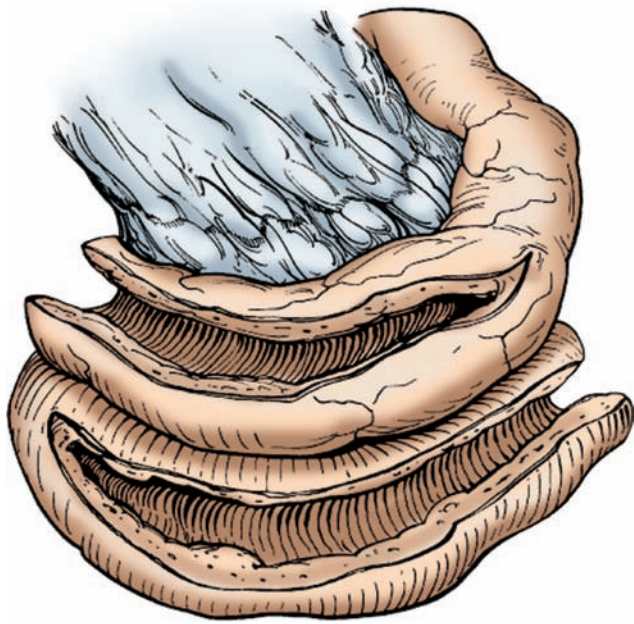


FIGURE 33-7 Isoperistaltic side-to-side strictureplasty. The segment of intestine affected by Crohn's strictures is divided and the two limbs are drawn onto each other.

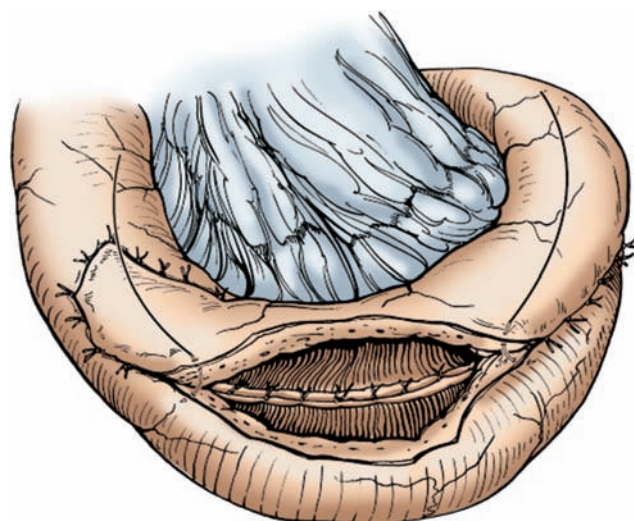




**FIGURE 33-8** Isoperistaltic side-to-side strictureplasty. Longitudinal enterotomies are made along the antimesenteric borders of the two limbs.

reinforced with an interior row of either interrupted or running full-thickness sutures. This inner suture line is continued anteriorly. The anterior closure is then reinforced with an outer layer of interrupted seromuscular sutures to complete the strictureplasty (Fig. 33-9).

Originally described in 1996, this procedure has been utilized with increasing frequency. The isoperistaltic side-to-side strictureplasty is recognized as an effective means of treating extensive small bowel Crohn's disease and provides the best



**FIGURE 33-9** Isoperistaltic side-to-side strictureplasty. The two limbs are anastomosed together in a lengthy side-to-side fashion.

option for those cases that would otherwise require extensive intestinal resection with loss of significant length of small bowel.<sup>130,133,136,137</sup>

Unlike resection, diseased segments are retained with strictureplasty and suture lines are placed in Crohn's disease-affected tissue. This has been a cause of concern regarding the risk of intestinal suture line dehiscence, long-term recurrences, and risk for malignancy. The ongoing and now substantial clinical experience with these techniques has allayed these concerns.<sup>138</sup> In appropriately selected patients, perioperative morbidity from strictureplasty appears to be similar to that of resection and primary anastomosis. Specifically, intestinal suture line dehiscence appears to be uncommon with any of the described strictureplasty techniques.<sup>139,140</sup> The most common postoperative complication directly related to strictureplasty is hemorrhage from the strictureplasty site. This has been reported to occur in up to 9% of cases. Fortunately, the GI hemorrhage following strictureplasty is typically minor and can be managed conservatively with transfusions alone. Rarely, more persistent bleeding may require intra-arterial infusion of vasopressin, but the need for reoperation to control hemorrhage after strictureplasty is very rare. It is by now also well established that strictureplasty techniques provide excellent long-term symptomatic relief that is comparable to resections with anastomosis. Although there are no controlled studies directly comparing strictureplasty to resection, multiple reports of the observed symptomatic recurrence rates after strictureplasty compare well with published recurrence rates after resection and anastomosis.<sup>133,140,141</sup>

Epidemiological studies have shown an increased risk for small bowel adenocarcinoma in Crohn's disease patients.<sup>108</sup> This risk is increased in patients with long-standing disease. It is not known if strictureplasty by virtue of its retention of diseased tissue increases this risk. At the time of the writing of this chapter, there have been only two reported cases of an adenocarcinoma developing at a site of previous small bowel strictureplasty, and it is thus believed that the risk of malignancy after strictureplasty is low.<sup>142,143</sup>

## Laparoscopy

Over the past two decades, laparoscopy has been dramatically changing all aspects of GI surgery. Specifically in colon and rectal surgery, laparoscopy has been widely used in benign disease,<sup>144,145</sup> including inflammatory bowel disease, and more recently in colon cancer.<sup>146</sup> Several single-institution small reports suggest that not only is laparoscopic surgery for Crohn's disease feasible and safe, but also it reduces length of hospitalization and recovery and allows for a smaller wound, with an overall reduction in morbidity.<sup>147-160</sup>

Most Crohn's disease patients are well suited for laparoscopy. They are usually young, otherwise healthy, and interested in undergoing an operation that involves minimal scarring, because they face the risk of multiple major abdominal operations in their lifetime. On the other hand, Crohn's disease represents a difficult arena even for the experienced open

colorectal surgeon. Many of the unique features of Crohn's disease, such as the intense inflammation and thickened mesentery, enteric fistula, inflammatory masses or abscesses, and the multiplicity of areas of intestinal involvement, have deterred many surgeons from even considering a laparoscopic approach.

Two prospective controlled studies have shown several advantages of the laparoscopic-assisted approach over the conventional approach.<sup>147,149</sup> Bemelman and colleagues compared 48 open ileocolic resections with 30 laparoscopic-assisted resections. This study showed similarly low morbidity rates in both groups but a shorter hospital stay and improved cosmetic results in favor of the laparoscopic group.<sup>149</sup> Alabaz and associates compared 48 open ileocolic resections with 26 laparoscopic-assisted resections. The patients in the laparoscopic group returned to work more quickly, had better cosmetic results, and were more likely to have improved postoperative quality of life.<sup>147</sup> A prospective randomized trial comparing open and laparoscopic-assisted resections in 60 patients undergoing elective ileocectomy for Crohn's disease not complicated by abscess formation or complex fistula showed a faster postoperative recovery of respiratory function (measured as recovery of 80% of forced respiratory volume and forced vital capacity), shorter abdominal incisions, and longer performance time in the laparoscopic-assisted group. These differences were all statistically significant. With limited follow-up, there was no difference in recurrence rate.<sup>154</sup> This paper demonstrated that in experienced hands, morbidity from the laparoscopic approach compares favorably with that of a conventional open approach. Obviously these results need to be confirmed by larger series with longer follow-up.

The indications for laparoscopic surgery for Crohn's disease should not differ from conventional open surgery as described previously. Contraindications to a laparoscopic approach include patients who are critically ill and unable to tolerate the pneumoperitoneum due to hypotension or hypercarbia, patients with extensive intra-abdominal sepsis (abscess, free perforation, or complex fistula), and difficulty in identifying the anatomy (previous surgery, obesity, or adhesions). The same variety of surgical procedures described previously can be performed laparoscopically.

After induction of general anesthesia, the patient is placed on the operating table supine or in the modified lithotomy position. Rectal irrigation with diluted iodine solution is performed, especially in patients with involvement of the rectum and sigmoid colon. An epidural catheter is usually inserted at the time of surgery. The sympathetic blockade achieved with epidural administration of local anesthetics and opioids prevents bowel distension, hence facilitating exploration of the GI tract and handling of the bowel. Depending on the procedure planned, four or five trocars are utilized, with the camera placed at the level of the umbilicus.

Every operation for Crohn's disease, whether open or laparoscopic, should start with a complete examination of the entire GI tract starting from the ligament of Treitz. The patient is placed in the reverse Trendelenburg position and right lateral decubitus with the assistant standing on

the patient's left side retracting the transverse colon into the upper quadrants and the surgeon at the right of the patient or in between the patient's legs, tracing the intestine from the ligament of Treitz all the way to the ileocolic pedicle. This maneuver is facilitated by progressively rotating the patient from the reverse Trendelenburg to a full Trendelenburg position and left lateral decubitus. In the presence of skip areas of involvement from Crohn's disease, these are marked intracorporeally with sutures in order to facilitate retrieval of the diseased segments when the specimen is exteriorized.

Laparoscopic-assisted ileocolic resection is the most commonly performed laparoscopic procedure for Crohn's disease. For laparoscopic ileocectomy, a four-trocar technique is utilized (Fig. 33-10). Trocars of 5 mm can be used exclusively, as a 5-mm, 30-degree camera offers the same resolution as larger ones and the vascular pedicles can be divided intracorporeally with 5-mm instruments. After the bowel has been evaluated in its entirety as previously described, the assistant, standing on the right of the patient or in between the patient's legs, places the ileocolic pedicle under tension with an insti-

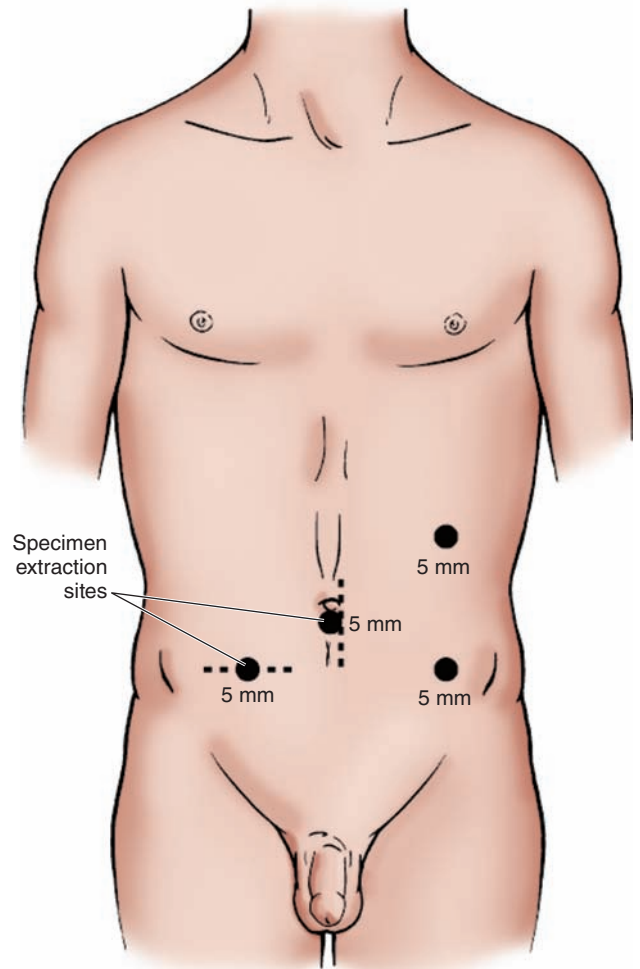
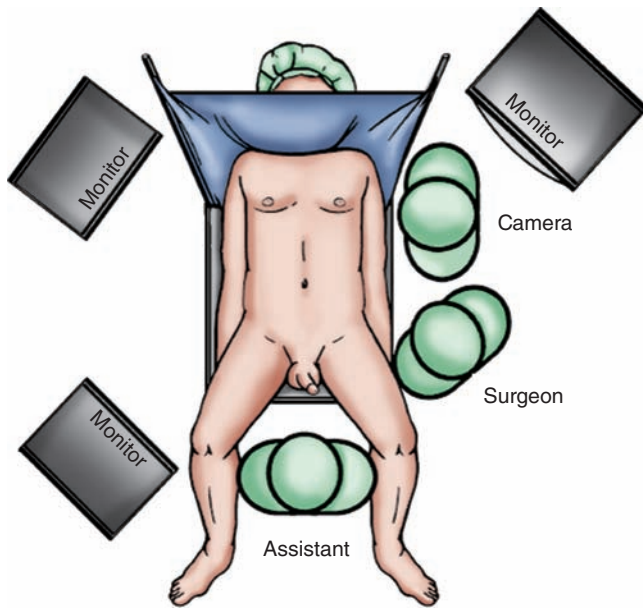


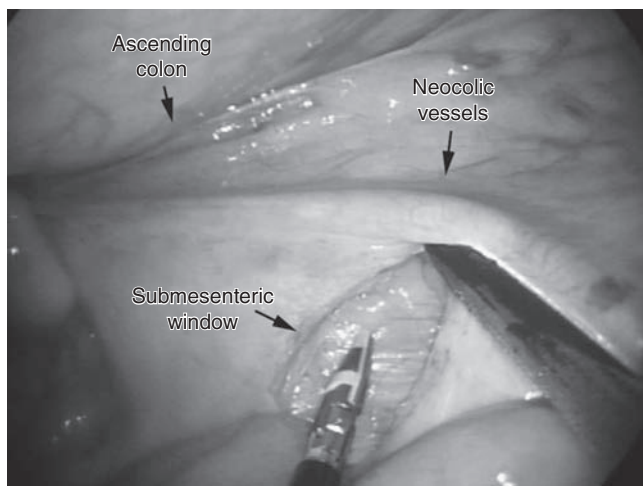
FIGURE 33-10 Port site locations for laparoscopic ileocectomy.



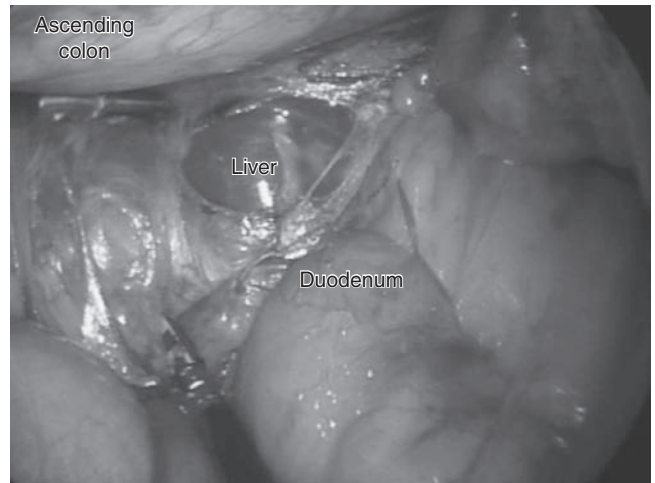


**FIGURE 33-11** Optimal position of the surgeons and assistants for laparoscopic ileocecectomy.

nal grasper placed through the right lower quadrant trocar (Fig. 33-11). The surgeon on the patient's left side dissects and divides it (Fig. 33-12). Once this is accomplished, a medial-to-lateral submesenteric mobilization of the ascending colon all the way to the hepatic flexure is completed (Fig. 33-13). When the submesenteric mobilization is completed, the lateral colonic peritoneal reflection is divided all the way to the hepatic flexure (Fig. 33-14). The terminal ileum is completely mobilized by dividing the peritoneum at the level of the pelvic rim to allow a tension-free anastomosis

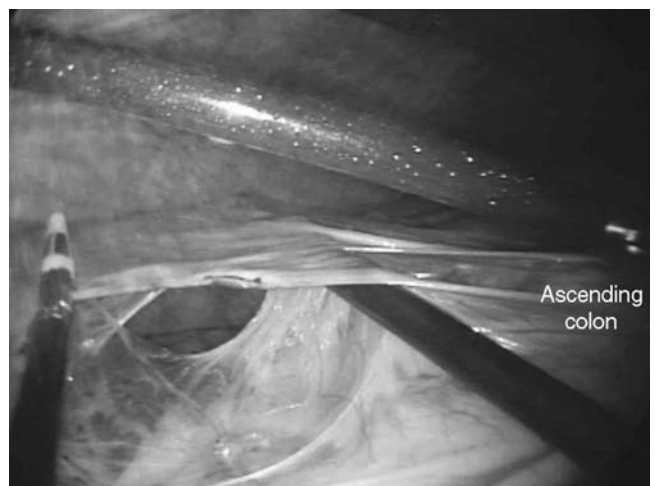


**FIGURE 33-12** Laparoscopic isolation of the ileocolic vessels. (Reprinted, with permission, from the University of Chicago General Surgery Archives.)



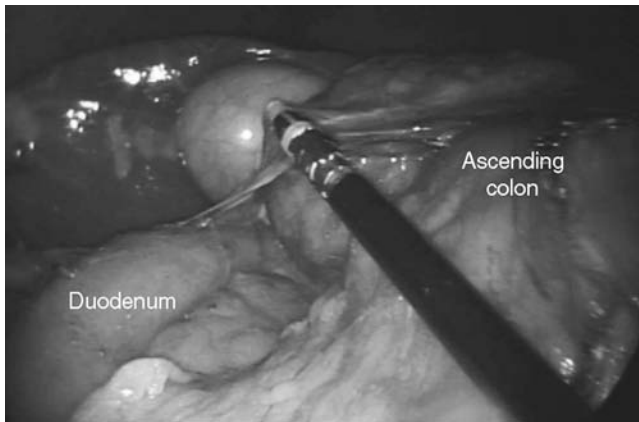
**FIGURE 33-13** Submesenteric mobilization of the ascending colon and hepatic flexure with exposure of the duodenum. (Reprinted, with permission, from the University of Chicago General Surgery Archives.)

through a small incision. It is often necessary to completely mobilize the hepatic flexure without dividing the right branch of the ileocolic vessels in order to facilitate exteriorization of the specimen (Fig. 33-15). It is imperative to make sure that the mobilization is adequate before evacuating the pneumoperitoneum and making an incision to avoid a difficult anastomosis through a small incision or the need for a larger incision to exteriorize the specimen. Should this occur, a gel port can be applied through the abdominal incision to allow for creation of the pneumoperitoneum again and further intra-abdominal dissection.



**FIGURE 33-14** Division of the lateral peritoneal attachments to the ascending colon. (Reprinted, with permission, from the University of Chicago General Surgery Archives.)





**FIGURE 33-15** Final mobilization of the hepatic flexure. (Reprinted, with permission, from the University of Chicago General Surgery Archives.)

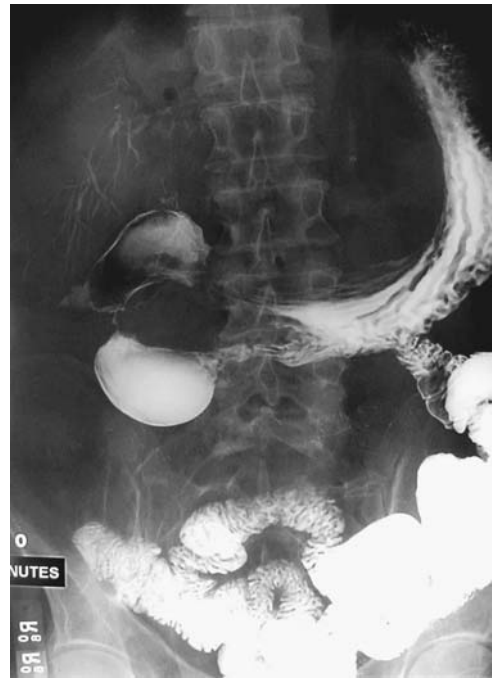Once the ileum, cecum, and ascending colon are fully mobilized, the instruments are removed. With the pneumoperitoneum still in place, the umbilical port site or the right lower quadrant port site is enlarged. The pneumoperitoneum is evacuated and the specimen is exteriorized. The ileocolonic resection is then completed by dividing the remainder of the mesentery and the bowel extracorporeally. An anastomosis is then constructed in a standard fashion.

## MANAGEMENT OF COMPLICATED CROHN'S DISEASE

### Crohn's Disease of the Duodenum

Primary Crohn's disease of the duodenum almost always manifests with stricturing disease that can be managed by strictureplasty or with bypass procedures (Fig. 33-16). Fortunately, resection of the duodenum for Crohn's disease is almost never required.<sup>161-163</sup> Perforating Crohn's disease almost never affects the duodenum. When the duodenum is involved with Crohn's fistulas, it is always the result of disease within a distal segment (typically the terminal ileum or neoterminal ileum) that fistulizes into an otherwise normal duodenum.<sup>164</sup> Yet, Crohn's disease of the duodenum can offer a particularly challenging problem due to the retroperitoneal location of the organ and its intimate proximity with the pancreas.

Stricturing disease of the duodenum is often focal and many cases can be managed with a strictureplasty.<sup>165</sup> In order to safely accomplish a strictureplasty, the duodenum must be fully mobilized with a generous Kocher maneuver. Heinecke-Mikulicz strictureplasties can be safely performed in the first, second, and proximal third portion of the duodenum. Strictures of the last portion of the duodenum are better handled with a Finney strictureplasty constructed by creating an enteroenterostomy between the fourth portion of the duodenum and the first loop of the jejunum.



**FIGURE 33-16** Upper GI study demonstrating Crohn's strictures of the duodenum. Contrast seen within the biliary ducts is due to deformity and incompetence of the ampullary sphincter secondary to the Crohn's disease. (Reprinted, with permission, from the University of Chicago General Surgery Archives.)

If the duodenal stricture is lengthy or the tissues around the stricture are too rigid or unyielding, a strictureplasty should not be performed and an intestinal bypass procedure should be undertaken. The most common bypass procedure performed for duodenal Crohn's disease is a simple side-to-side retrocolic gastrojejunostomy.<sup>121</sup> This procedure effectively relieves the symptoms of duodenal obstruction related to Crohn's strictures but carries a high risk for stomal ulcerations. To lessen the likelihood of ulcerations forming at the anastomosis, it has been recommended that a vagotomy be performed along with the gastrojejunostomy.<sup>121</sup> Because of the concerns of vagotomy-related diarrhea, a highly selective vagotomy is preferred to a truncal vagotomy. If the stricturing Crohn's disease is limited to the third or fourth portions of the duodenum, a Roux-en-Y duodenojejunostomy to the proximal duodenum is preferred to a gastrojejunostomy.<sup>164</sup> The Roux-en-Y duodenojejunostomy has the advantage of bypassing strictures and eliminates the concern regarding acid-induced marginal ulceration and the need for vagotomy.

As noted previously, when the duodenum is involved with a Crohn's fistula, it is almost always the case that the diseased segment is located distal in the GI tract and the duodenum itself is otherwise free of active Crohn's disease.<sup>164</sup> Most of these duodenal fistulas are small in caliber and asymptomatic, but larger fistulas may shunt the duodenal contents to the distal small bowel such that malabsorption and diarrhea result. In the majority of cases, duodenoenteric fistulas are identified

with preoperative small bowel radiography; however, many are discovered only at the time of surgery.<sup>166</sup> With complex fistulizing disease involving an inflammatory mass, great care at the time of surgery should be undertaken to limit the size of the duodenal defect resulting from the resection of the fistula. Most duodenal fistulas are located away from the pancreaticoduodenal margin, and thus these fistulas can be managed by resection of the primary Crohn's disease with primary closure of the duodenal defect. Larger fistulas or fistulas that are involved with a large degree of inflammation may result in a sizable duodenal defect. Such large defects may require closure with a Roux-en-Y duodenojejunostomy or with a jejunal serosal patch.<sup>166,167</sup> As noted previously, duodenal resections are almost never necessary for Crohn's disease and they should be considered the surgical option of last resort.

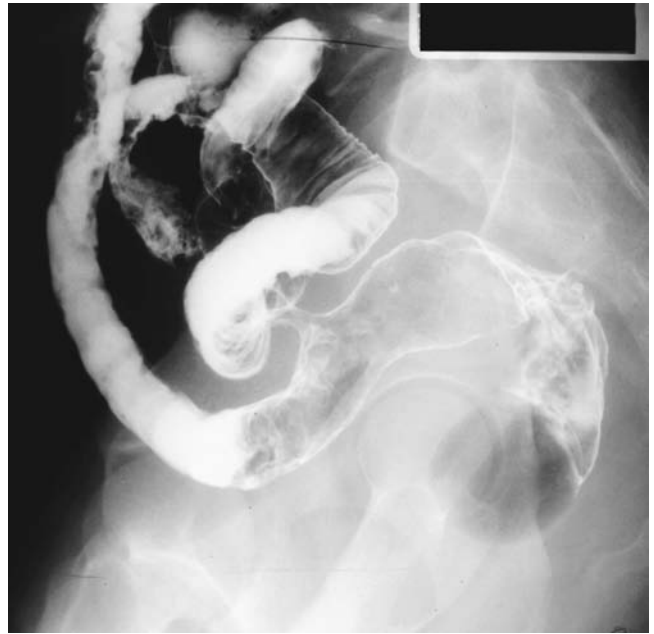## Crohn's Disease of the Small Bowel

### COMPLETE INTESTINAL OBSTRUCTION

Complete small intestinal obstruction resulting from Crohn's disease only rarely requires urgent surgical intervention, as the vascular supply to the intestinal loop is never compromised and almost all cases of complete or high-grade partial small bowel obstruction from Crohn's disease respond to conservative management. Such patients should be treated with nasogastric decompression, intravenous hydration, and steroid therapy.<sup>121</sup> This program allows for resolution of the acute episode of obstruction in a vast majority of cases. Unfortunately, most patients whose Crohn's disease is severe enough to experience an episode of complete or high-grade partial obstruction are at high risk for recurrent episodes and persistent symptoms. For this reason, elective surgery should be considered once the episode of complete obstruction has resolved. The advantage of this approach is that surgery can be performed under safer conditions when the obstruction has resolved, the bowel is not distended or edematous, and an appropriate bowel preparation has been performed. If the obstruction fails to respond to appropriate conservative treatment, surgery is required. In these situations, the surgeon needs to have a high index of suspicion for small bowel cancer as the cause of the obstruction, as obstructions from cancers do not respond to bowel decompression and steroid treatment.

### ILEOSIGMOID FISTULAS

Ileosigmoid fistula is a common complication of perforating Crohn's disease of the terminal ileum. Typically, the inflamed terminal ileum adheres to the sigmoid colon that is otherwise normal and free of primary involvement of Crohn's disease. Most ileosigmoid fistulas are small and do not produce any symptoms. Asymptomatic ileosigmoid fistulas do not in and of themselves require operative management. On the other hand, large ileosigmoid fistulas can result in bypass of the intestinal contents from the terminal ileum to the distal colon and thus give rise to debilitating diarrhea (Fig. 33-17). Such



**FIGURE 33-17** Contrast enema demonstrating large ileosigmoid fistula. (Reprinted, with permission, from the University of Chicago General Surgery Archives.)

symptomatic fistulas often fail to respond to medical therapy and should be managed surgically.

More than half of the ileosigmoid fistulas from Crohn's disease are not recognized prior to surgery.<sup>168</sup> For this reason, the surgeon should be prepared to deal with this complication in any case of Crohn's disease that involves the terminal ileum. Ileosigmoid fistulas can be managed by simple division of the fistulous adhesion and resection of the ileal disease. The defect in the sigmoid colon is then débrided and simple closure is undertaken. In this manner, 75% of ileosigmoid fistulas can be managed.<sup>55,168</sup> The remainder require resection of the sigmoid colon. Sigmoid colon resection is necessary when primary closure of the fistula is at risk for poor healing. This is the case either when the sigmoid is also involved in Crohn's disease when the fistulous opening is particularly large, or when there is extensive fibrosis extending along the sigmoid colon. Also, fistulous tracts that enter the sigmoid colon in proximity to the mesentery can be difficult to close and often require resection and primary anastomosis.

### ILEOVESICAL FISTULA

Ileovesical fistulas occur in approximately 5% of Crohn's disease patients.<sup>93</sup> Hematuria and fecaluria are virtually diagnostic of ileovesical fistula, but these symptoms are absent in one-third of cases.<sup>169</sup> Small bowel x-rays, cystograms, and cystoscopy often do not detect the fistula. Air within the bladder, as noted on CT scan, is often the best indirect evidence for the presence of an enterovesical fistula. An ileovesical fistula is an indicator of complex fistulizing disease, as most ileovesical fistulas occur along with other enteric fistulas. For example,

as many as 60% of patients with an ileovesical fistula will also have an ileosigmoid fistula.<sup>55</sup>

The necessity for surgery for ileovesical fistula is controversial. Many patients with ileovesical fistulas can be managed medically for extended periods of time without significant complications. Healing rates with medical treatment are not clearly defined, but they are probably low and most patients with ileovesical fistulas will ultimately come to surgery. Surgery is indicated when recurring urinary infections occur, particularly pyelonephritis, with concomitant potential for worsening of renal function.

Surgical treatment of ileovesical fistulas requires resection of the ileal disease with closure of the bladder defect. Most ileovesical fistulas involve the dome of the bladder, and thus débridement and primary closure can be accomplished without risk of injury to the trigone. Decompression of the bladder with an indwelling Foley catheter should be continued postoperatively until the bladder is confidently healed without leaks. A cystogram taken on postoperative day 5 is a convenient means for confirming the seal of the bladder repair and the safety of removing the Foley catheter.

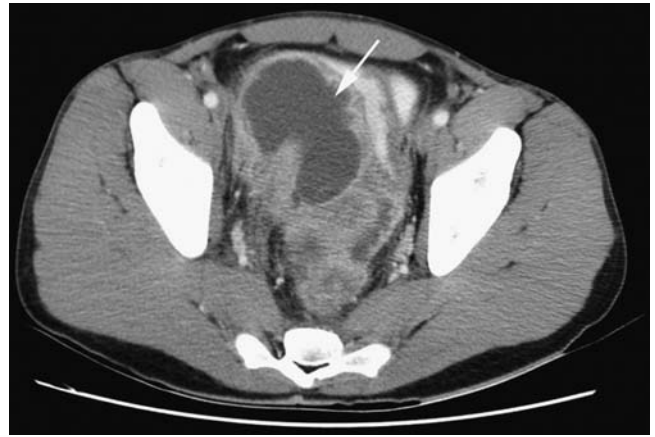### ENTEROVAGINAL AND ENTEROCUTANEOUS FISTULAS

These are rare fistulas caused by perforating small bowel disease draining through the vaginal stump in a female who has previously undergone a hysterectomy or through the abdominal wall, usually at the site of a previous scar. These fistulas often require surgical intervention because they cause physical discomfort and personal embarrassment. Surgical treatment requires resection of the small bowel disease. The vaginal cuff does not need to be closed; the chronic infection along the abdominal wall fistulous tract requires debridement and wide drainage to allow healing by secondary intention.

### ABSCESS

Intra-abdominal abscesses that result from Crohn's disease tend to follow an indolent course with modest fever, abdominal pain, and leukocytosis. Rapidly progressive and overwhelming sepsis is not typical for the clinical course of Crohn's disease–related abscesses. In fact, in up to one-third of intra-abdominal Crohn's abscesses preoperative clinical signs of localized infection are absent and the abscesses are discovered only at the time of operation. When an abscess is suspected or an abdominal mass is palpated, a CT scan should be obtained, as 50% of tender intra-abdominal masses will harbor an abscess collection within.<sup>100</sup> The CT scan can detect most chronic abscesses and can also delineate the size and location of the abscess as well as the relationship of the abscess to critical structures such as the ureters, duodenum, and the inferior vena cava (Fig. 33-18).

Most abscesses with Crohn's disease are in fact very small collections that are contained within the area of diseased intestine and its mesentery. In the case of small intraloop or intramesenteric abscesses, resection of the defective segment



**FIGURE 33-18** CT scan of the pelvis demonstrating large Crohn's abscess. (Reprinted, with permission, from the University of Chicago General Surgery Archives.)

and its mesentery often extirpates the abscess such that drains are not necessary and primary anastomosis can be performed without risk.

Large abscesses related to Crohn's disease are best managed with CT-guided percutaneous drainage.<sup>102</sup> Percutaneous drainage is often very effective at controlling the sepsis and healing the abscess cavity.<sup>101</sup> With percutaneous drainage of a Crohn's disease abscess, an enterocutaneous fistula often occurs as the abscess typically connects to a deeply penetrating sinus emanating from a segment of Crohn's disease–affected intestine. Percutaneous drainage then completes the fistulous tract from the intestine through the sinus to the abscess cavity and out the drain. Such a fistula may spontaneously close or it may persist, and the intestine may continue to be a source of sepsis. With successful drainage of the abscess, the sepsis often clears well enough that it can be tempting to try to manage the disease without subsequent surgery. Published clinical data on the optimal approach to such patients are unfortunately lacking. Even so, in the absence of Crohn's symptoms, initial nonoperative management after successful percutaneous drainage can be undertaken in carefully selected patients.<sup>103</sup> On the other hand, if drainage through the fistula continues, surgical resection of the affected segment of intestine becomes necessary.

### PERFORATION

Free perforation is a surprisingly uncommon phenomenon because the chronic progressive inflammation of Crohn's disease normally leads to adhesions with adjacent structures. Most perforations from Crohn's disease occur in the ileum and are usually proximal to a stenotic lesion.<sup>104,121</sup> The diagnosis of free perforation is made by detecting a sudden change in the patient's symptoms along with the development of the physical findings of peritonitis or the identification of free intraperitoneal air as demonstrated on plain x-rays or CT scans. Free perforation is an absolute indication for emergent laparotomy with resection of the diseased segment and exteriorization of the proximal bowel as an end ileostomy. The distal bowel end



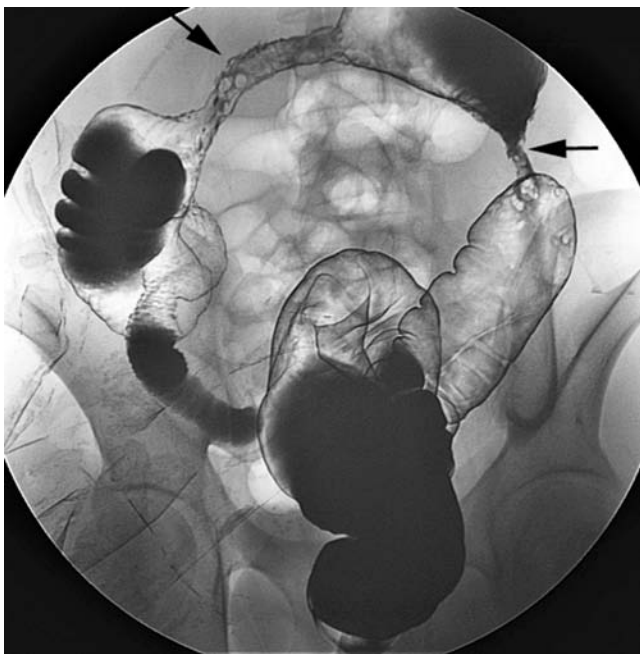
can be exteriorized as a mucous fistula or closed as a defunctionalized pouch, depending on the degree of peritoneal contamination. Creation of a primary anastomosis even with a proximal protecting loop ileostomy carries a high risk of anastomotic breakdown and should be avoided. Primary closure of the perforation should never be attempted, as sutures will not be able to approximate the edges of the perforated, edematous, and diseased bowel in a satisfactory and tension-free way and the presence of a distal intestinal stenosis or partial obstruction will cause an increase in the intraluminal pressure at the level of the local repair with subsequent dehiscence.

## HEMORRHAGE

Hemorrhage from small bowel Crohn's disease is managed by resection of the diseased portion of intestine. For patients with multiple skip areas of Crohn's disease, small bowel angiography may be attempted to localize the exact site of bleeding.<sup>105</sup> Localization with angiography may be unsuccessful if the bleeding is episodic or insufficiently brisk to be identified with angiography. In patients in whom small bowel hemorrhage stops spontaneously, the risk for rebleeding is high. Thus elective resection of active Crohn's disease after the first episode of hemorrhage should be considered.

## Crohn's Disease of the Colon

The optimal management of Crohn's disease of the colon is dependent on the distribution and the location of the disease (Fig. 33-19).



**FIGURE 33-19** Contrast enema demonstrating severe Crohn's colitis with multiple high-grade strictures. (Reprinted, with permission, from the University of Chicago General Surgery Archives.)

## CECAL DISEASE

Colonic disease limited to the cecum is almost always associated with terminal ileal disease. The terminal ileitis is the predominant component of the ileocecal disease. Terminal ileal disease with extension into the cecum behaves much like disease limited to the terminal ileum. For this pattern of disease, surgical resection should encompass the margins of gross disease with an anastomosis between the neoterminal ileum and the proximal ascending colon. Recurrence of disease at the anastomosis or at the preanastomotic ileum is common, but the risk for recurrent disease within the distal colon or the rectum is low. This pattern of disease does not imply a predisposition to more extensive colonic disease.

## RIGHT-SIDED COLITIS

Disease involving the entire right colon can occur alone but more typically occurs along with disease of the terminal ileum. Extensive involvement of the right colon as a form of ileocolonic disease is less common than the ileocecal pattern. Surgical treatment involves a standard right hemicolectomy to encompass the gross limits of the disease. An anastomosis between the ileum and the transverse colon is then fashioned. With a standard right hemicolectomy, the anastomosis may rest in proximity to the duodenum. Recurrent disease at the preanastomotic ileum may thus secondarily involve the duodenum. This phenomenon can place the patient at risk for substantial morbidity should inflammatory encasement of the duodenum or fistulization into the duodenum occur. For this reason it is advantageous to protect the duodenum by interposing omentum between the duodenum and the ileocolonic anastomosis.

## EXTENSIVE COLITIS WITH RECTAL SPARING

Extensive colitis with sparing of the rectum occurs in approximately 20% of individuals suffering from Crohn's colitis. In such cases, the rectum should be closely examined endoscopically, and, should the rectum be truly free of disease, a total abdominal colectomy with ileorectal anastomosis can be performed when fecal continence is adequate and the patient does not have extensive perineal septic complications. This procedure often results in good long-term function and enables many patients to avoid an ileostomy. Older patients or patients who have undergone an extensive small bowel resection may experience frequent and loose stools to the point that incontinence may develop after an ileorectal anastomosis. Additionally, recurrent disease within the rectum can result in significant deterioration of bowel function requiring further medical or even surgical intervention. Up to 50% of patients who undergo an ileorectal anastomosis for colonic Crohn's disease will ultimately require a proctectomy with permanent ileostomy because of poor bowel function with incontinence or recurrence of disease in the rectum.<sup>170</sup>

## PROCTOCOLITIS

Surgical management of extensive involvement of the colon and rectum requires total proctocolectomy with permanent ileostomy in almost all cases. In most instances, a total proctocolectomy can be performed in a single step. The presence of severe perianal disease, however, may require that the procedure be performed in two stages. At the first stage, the intra-abdominal colon and majority of the rectum are removed and a short rectal stump is created at the level of the levator muscles. At the same time, perineal abscesses are drained and fistulas are laid open. This first step removes the diseased colon and rectum without creating a perineal wound that may be difficult to heal in the presence of active perineal sepsis. Once the perineal sepsis is cleared and the perineum is healed, the short anorectal stump can be removed through a perineal approach. At the second stage, primary closure of the perineum can be accomplished without the high risk of persistent perineal wounds.

Restorative procedures such as an ileal pouch–anal anastomosis or continent ileostomy have traditionally not been offered to patients who have Crohn's colitis because of the recurrent nature of the disease. Even so, some of these procedures have been performed in patients whose diagnosis of Crohn's disease was not known or suspected at the time of surgery. Various reports indicate that recurrence of Crohn's disease within the pouch is common and removal of the pouch is often necessary. On the other hand, those patients who do not suffer from recurrent disease generally do well and typically experience good pouch function.

While it is commonly accepted that restorative proctocolectomy with J-pouch ileoanal anastomosis should not be undertaken for Crohn's colitis, there is a specific pattern of Crohn's disease that appears to be at low risk for problems with recurrence after an ileoanal anastomosis.<sup>171,172</sup> In cases in whom Crohn's disease is limited to the colon and rectum without any history of small bowel involvement and without any perineal manifestations, the risk for pouch failure after ileoanal anastomosis appears to be low and such patients can be considered for the ileoanal procedure. This particular pattern of Crohn's disease, however, is rare, as most patients with Crohn's proctocolitis will have some degree of small bowel involvement or perineal manifestations and thus would not be considered candidates for the ileoanal procedure.

## PROCTITIS

Crohn's inflammation limited to the rectum is unusual. Surgical management of Crohn's proctitis mandates proctectomy with permanent stoma. The need for resection of the normal proximal colon is controversial. Abdominoperineal resection with end sigmoid colostomy has been associated in some reports with a high risk for stomal complications and recurrent disease in the proximal intestine when compared to total proctocolectomy with end ileostomy. For these reasons, total proctocolectomy with ileostomy has been recommended for Crohn's disease limited to the rectum and distal colon. This

more extensive resection may be of greater value in younger patients who have no history of small bowel Crohn's disease, as it appears that colorectal Crohn's disease without small bowel involvement is unlikely to result in recurrence within the small bowel once a proctocolectomy is performed.<sup>40</sup> If the patient has undergone a prior resection for small bowel Crohn's disease, they may be at risk for high output from the ileostomy and therefore may benefit from the preservation of colonic absorptive capacity. Preservation of the colonic absorptive capacity may be beneficial also in the elderly patient. Thus these patients may be better managed with a proctectomy and end sigmoid colostomy.

Proctectomy for Crohn's disease does not require a wide excision of perirectal tissue. To avoid injury to pelvic sympathetic and parasympathetic nerves, the dissection should be undertaken close to the rectal wall. This is sometimes challenging in the presence of severe rectal mesenteric inflammatory reaction. In the absence of significant perianal disease, the perineal dissection is best carried out along the plane between the internal and external sphincters.<sup>173</sup> This intersphincteric dissection allows for a perineal closure that is associated with fewer complications and better healing than wider dissections that encompass the entire sphincter mechanism. In some patients, fistula from the perianal Crohn's disease can traverse the intersphincteric plane and a wider dissection is required in order to encompass the diseased tissue. In the presence of significant perianal disease, a staged approach, as described previously, can be utilized as an option. Occasionally, however, because of extensive rectal disease, closure of the rectal stump may be technically challenging or not feasible, forcing the surgeon to proceed with a proctectomy in the face of perianal sepsis. These dissections may need to be carried out widely and extensive loss of perianal skin and subcutaneous tissue may occur. The resultant defects are often too large for primary closure, and closure may require advanced tissue transfer techniques such as gluteal flaps, gracilis flaps, or myocutaneous rectus abdominis pedicle flaps. These closures may have to be staged as well in the presence of perineal sepsis. Large open perineal wounds may be managed temporarily or definitively with the assistance of the vacuum-assisted closure device. This device allows for rapid contracture of the wound and facilitates healing.

## SEGMENTAL COLITIS

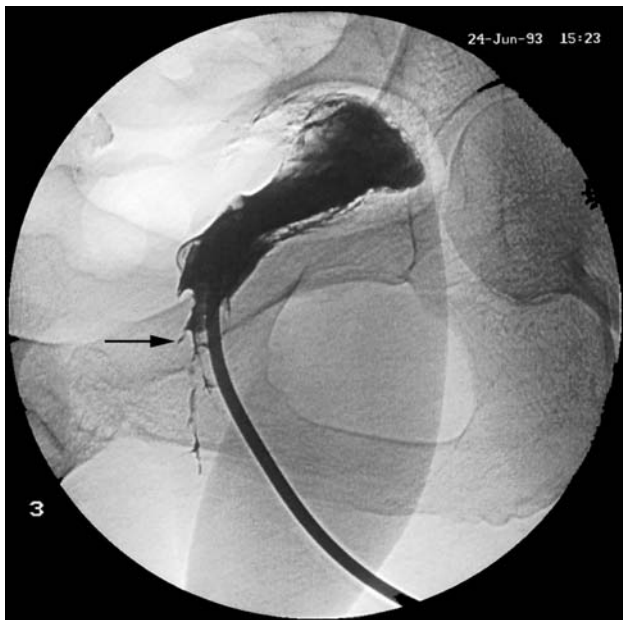
The optimal management of segmental colitis is dependent primarily on the location of the disease and secondarily on the presence and severity of concurrent perineal complications, the degree of fecal continence, and the natural history of the disease in the residual colon. Segmental involvement of the right colon should be managed by simple right hemicolectomy with ileotransverse anastomosis. For segmental disease involving the transverse colon, an extended right hemicolectomy is generally preferred to a segmental transverse colectomy. Such an approach may have a lower risk of recurrence compared to a segmental resection of the transverse colon.

Additionally, the extended right hemicolectomy avoids a colocolonic anastomosis that is associated with a higher risk for anastomotic dehiscences and strictures.

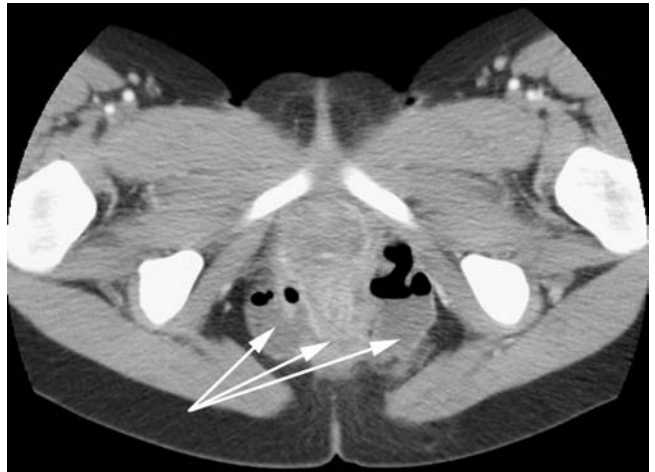
For disease in the descending or sigmoid colon, the appropriate surgery is more controversial. Presence and severity of concurrent perineal complications, the degree of fecal continence, and the natural history of the disease in the residual colon all play a role in deciding on the approach for each individual patient. Studies have indicated that segmental colonic resection with colocolonic anastomosis or even colonic strictureplasty can be performed with overall good results.<sup>174,175</sup> However, such a strategy may be at risk for early disease recurrence within the colon.<sup>40</sup> Even if the risk for recurrence is higher with segmental resection, the benefits of preserving the absorptive capacity in appropriately selected cases may outweigh the higher risk of recurrence.

### PERIANAL DISEASE

The perianal manifestations of Crohn's disease include abscesses, fistulas, fissures, anal stenosis, and hypertrophic skin tags.<sup>176,177</sup> Perianal Crohn's disease originates from inflammation within the anal crypts. This inflammation gives rise to sepsis and to fistulization (Fig. 33-20). Perianal Crohn's disease is common and occurs in one-third of the patients who suffer from intestinal Crohn's disease.<sup>42</sup> Perianal Crohn's disease is usually associated with active or quiescent disease elsewhere within the GI tract. It is controversial as to whether the activity of perianal Crohn's disease parallels that of the intestinal disease. There is also controversy over



**FIGURE 33-20** Dynamic proctogram demonstrating Crohn's fistula-in-ano. (Reprinted, with permission, from the University of Chicago General Surgery Archives.)



**FIGURE 33-21** CT scan demonstrating a large perirectal abscess secondary to Crohn's disease. (Reprinted, with permission, from the University of Chicago General Surgery Archives.)

whether medical or surgical control of the intestinal disease can ameliorate the perianal manifestations. Unlike idiopathic perianal abscesses and fistula-in-ano that occur in patients without Crohn's disease, perianal Crohn's disease tends to be recurrent, complex, and sometimes progressive.

Surgical incision and drainage are required to manage perianal abscesses (Fig. 33-21). Attempts at treating purulent collections with antibiotics alone are invariably unsuccessful. With surgical drainage of the abscess, the incision should be placed close to the anal margin. The cavity may be packed with ribbon gauze or drained with a 10–16F mushroom catheter. If a fistula tract can be identified at the time of drainage of the suppuration, a loose seton may be placed to ensure adequate drainage.

Uncomplicated submucosal or intersphincteric fistulas are best treated with an initial trial of either metronidazole or ciprofloxacin. These antibiotics are moderately effective in promoting healing of Crohn's fistulas and are associated with a low risk of complication.<sup>178,179</sup> If a low-lying submucosal or intersphincteric fistula fails to heal with antibiotic treatment, a surgical fistulotomy can be performed. These low-lying fistulas typically heal well after fistulotomy and the risk of incontinence is low.

Surgical fistulotomies and cutting setons should not be used for suprasphincteric fistulas and should also be avoided for most transsphincteric fistulas. For complex fistulas, the risk for surgical complications is higher and more aggressive medical therapy is warranted before surgery is recommended. Medical treatment for extensive Crohn's fistulas includes the use of 6-MP, azathioprine, and cyclosporine. Probably the most effective agent at promoting healing of perianal fistulas related to Crohn's disease is infliximab. With infliximab treatment, healing of complex perianal fistulas is seen in 60% of cases.<sup>180,181</sup> Recurrence of the fistula after infliximab is discontinued, however, may be high. Additionally, persistent stasis



or sepsis within the fistula tract can impede effective healing with medical treatment. To provide for adequate drainage throughout the fistula tract, many patients may benefit from placement of setons. The use of setons with infliximab therapy can improve the overall effectiveness of infliximab.<sup>182</sup> Typically the seton is placed prior to the initiation of infliximab therapy and then it is removed after the second or third dose.

Fibrin glue has been used for the treatment of Crohn's disease-related fistulas, but reported experience is limited. Success rates with this approach are low, but, given the low risk of complications, an attempt at fibrin glue may be worthwhile in selected cases.<sup>183,184</sup>

Closure of the internal opening of the fistula with a rectal advancement flap can be considered in cases of Crohn's disease.<sup>185</sup> With this approach, an incision is made at the dentate line, and a flap of mucosa and muscularis is undermined and advanced down over the internal opening of the fistula. The advancement flap is then sutured into position with absorbable sutures. Rectal advancement flaps for Crohn's disease have a low risk for anal incontinence but are associated with a high failure rate. Rectal advancement flaps are not appropriate in patients in whom the rectal mucosa is involved with Crohn's disease. In severe cases of perianal disease that do not respond to aggressive medical and surgical therapy, fecal diversion with a stoma may be necessary. Diversion of the fecal stream typically results in significant relief of local inflammation and can assist in the healing of perianal fistulas. Proctectomy is indicated when perianal disease is unrelenting or when damage to the sphincters results in debilitating incontinence.

## Recurrent Disease

Crohn's disease carries a high risk for recurrence after surgery. The actual incidence of recurrent disease depends on the defining parameters of recurrence. For example, histological evidence for recurrence can be seen in many patients within days of surgical resection.<sup>186</sup> Endoscopic evidence for recurrent Crohn's disease can be seen in over 80% of patients within 3 years.<sup>187</sup> Most cases of histological or endoscopically detected recurrences, however, do not go on to produce symptoms of Crohn's disease. For this reason, histological or endoscopic evidence of recurrent disease may be used as an end point in investigative studies but are not typically used as a guide for clinical management.<sup>188</sup>

The development of symptoms related to recurrent Crohn's disease activity is the most commonly applied definition of disease recurrence, as it is the recurrence of symptoms that has the most relevance to the patient. The onset of symptoms of recurrent Crohn's disease is often insidious and the severity of symptoms varies greatly. To create a reproducible standard for recurrence of Crohn's disease symptoms, the Crohn's Disease Activity Index (CDAI) can be applied as a means of measuring recurrent disease.<sup>189,190</sup> A CDAI of greater than 150 is generally accepted as defining clinical

recurrence. Once symptoms suggestive of recurrent disease occur, it is still necessary to carry out radiological and endoscopic tests to confirm that the symptoms are in fact related to Crohn's disease.

The clearest end point as a definition of recurrence is the need for reoperation. Dates of surgery are readily documented even in a retrospective fashion. While reoperation is the most precise definition of recurrence, even this standard does not allow for accurate and reproducible comparisons between series as some centers may submit patients to surgery earlier than other centers.

Reported crude and cumulative recurrence rates vary greatly. Symptomatic or clinical recurrence occurs in about 60% of patients at 5 years, and recurrences increase with time such that at 20 years clinical recurrence can occur in between 75 and 95% of cases.<sup>35,191,192</sup> Reports of surgical recurrence rates range from 10 to 30% at 5 years, 20 to 45% at 10 years, and 50 to 70% at 20 years.<sup>70,94,191–195</sup> Some interesting observations regarding the pattern of recurrent disease have been made. Recurrent Crohn's disease is most likely to occur in proximity to the location of the previously resected intestinal segment, typically at the anastomosis and preanastomotic bowel.<sup>94</sup> This is particularly true for terminal ileal disease. Additionally, the length of small bowel involved with recurrent disease parallels the length of disease originally resected.<sup>196,197</sup> Short-segment disease tends to recur over a short segment of the preanastomotic bowel, and lengthy disease typically is followed by lengthy recurrence. Also, to a lesser degree of concordance, stenotic disease tends to recur as stenotic disease and perforating disease tends to recur as perforating disease.<sup>197</sup>

While many factors that may influence the risk of recurrence have been studied, the cumulative literature has validated very few as true risk factors. The data are conflicting for most of the proposed predictors of recurrent Crohn's disease. Much of the clinical data examining potential risk factors are confounded by poorly defined end points and improper study design. There is, however, general consensus that cigarette smoking has a significant effect on the clinical course of Crohn's disease.<sup>30</sup> Smoking not only exacerbates existing Crohn's disease but also has been identified as a risk factor for the development of Crohn's.<sup>27,28,30</sup> What is so striking about the effect of cigarettes on Crohn's disease is that smoking has the opposite effect on what is thought to be a very similar disease, ulcerative colitis.<sup>29</sup> While smoking exacerbates Crohn's disease, it seems to lessen the activity of ulcerative colitis.

The mechanism by which smoking results in exacerbation of Crohn's disease is not known. Smoking is an independent risk factor for endoscopic, symptomatic, and surgical recurrence.<sup>31,32</sup> The risk from smoking appeared to be dose-related with heavy smokers being at higher risk. This effect is reversible, as smokers who quit smoking prior to surgery can lower their risk of recurrence to a level similar to that of nonsmokers. Because of the harmful effects on the clinical course of Crohn's disease combined with the many other clearly established health hazards caused by cigarette smoking, all patients

with Crohn's disease should be strongly counseled to quit smoking.

There is concern that NSAIDs may exacerbate the activity of both ulcerative colitis and Crohn's disease.<sup>70,80</sup> Although there are no studies that have examined the specific issue of NSAIDs and the risks for postoperative recurrence of Crohn's disease, the currently available data certainly warrant some caution and patients with Crohn's disease should be advised to avoid NSAIDs.

## POSTOPERATIVE MAINTENANCE THERAPY

The risk for recurrent disease can be lessened with postoperative maintenance therapy. The most common agents used for postoperative suppression of disease are controlled-release 5-ASA (Pentasa) and 6-MP.<sup>75-77</sup> Maintenance with 5-ASA is associated with few side effects, but up to 16 pills have to be taken daily. 6-MP is less expensive and is taken on a once-daily basis. Additionally, 6-MP may be more effective in diminishing the risk of recurrence.<sup>75</sup> 6-MP, however, is associated with potential bone marrow suppression, so that patients on 6-MP maintenance must be followed with periodic blood cell counts. The effect of these agents on the natural course of Crohn's disease is not dramatic, and many patients will go on to develop recurrence while on maintenance therapy. The largest benefit demonstrated with 6-MP in a multicenter trial showed a decrease of symptomatic recurrence from 77% with placebo to 50% with 6-MP.<sup>75</sup> The option for maintenance therapy should be considered for Crohn's disease patients, but the decision for such therapy must be individualized for each patient.

## REFERENCES

- Crohn BB, Ginsberg L, Oppenheimer GD. Regional ileitis: a pathological and clinical entity. *JAMA*. 1932;99:1323-1329.
- Fielding JF. Crohn's disease and Dalziel's syndrome. A history. *J Clin Gastroenterol*. 1988;10:279-285.
- Morgagni G. *The Seats and Causes of Disease Investigated by Anatomy*. Mount Kisco, NY: Futura Publishing; 1769.
- Kirsner JB. Etiologic concepts of inflammatory bowel disease; past, present, and future. In: Michelassi F, Milsom JW, eds. *Operative Strategies in Inflammatory Bowel Disease*. New York, NY: Springer-Verlag; 1999:3-20.
- Dalziel TK. Chronic intestinal enteritis. *Br Med J*. 1913;2:1068-1070.
- Heaton LD, Ravdin IS, Blades B, Whelan TJ. President Eisenhower's operation for regional enteritis: a footnote to history. *Ann Surg*. 1964;159:661-666.
- Hughes CW, Baugh JH, Mologne LA, et al. A review of the late General Eisenhower's operations: epilog to a footnote to history. *Ann Surg*. 1971;173:793-799.
- Bergman L, Krause U. Crohn's disease. A long-term study of the clinical course in 186 patients. *Scand J Gastroenterol*. 1977;12:937-944.
- Koudahl G, Kristensen M, Lenz K. Bypass compared with resection for ileal Crohn's disease. *Scand J Gastroenterol*. 1974;9:203-206.
- Homan WP, Dineen P. Comparison of the results of resection, bypass, and bypass with exclusion for ileocecal Crohn's disease. *Ann Surg*. 1978;187:530-535.
- Alexander-Williams J, Fielding JF, Cooke WT. A comparison of results of excision and bypass for ileal Crohn's disease. *Gut*. 1972;13:973-975.
- Lockhart-Mummery H, Morson B. Crohn's disease (regional enteritis) of the large intestine and its distinction from ulcerative colitis. *Gut*. 1960;1:87-105.
- Loftus EV, Jr. Clinical epidemiology of inflammatory bowel disease: incidence, prevalence, and environmental influences. *Gastroenterology*. 2004;126:1504-1517.
- Sandler RS, Glenn ME. Epidemiology of inflammatory bowel disease. In: Kirsner JB, ed. *Inflammatory Bowel Disease*. 5th ed. Philadelphia, PA: WB Saunders; 2000:89-112.
- Ekbohm A. The epidemiology of IBD: a lot of data but little knowledge. How shall we proceed? *Inflamm Bowel Dis*. 2004;10(suppl 1):S32-S34.
- Leong RW, Lau JY, Sung JJ. The epidemiology and phenotype of Crohn's disease in the Chinese population. *Inflamm Bowel Dis*. 2004;10:646-651.
- Hollander D, Vadheim CM, Brettholz E, et al. Increased intestinal permeability in patients with Crohn's disease and their relatives. A possible etiologic factor. *Ann Intern Med*. 1986;105:883-885.
- Wyatt J, Vogelsang H, Hubl W, et al. Intestinal permeability and the prediction of relapse in Crohn's disease. *Lancet*. 1993;341:1437-1439.
- Wyatt J, Oberhuber G, Pongratz S, et al. Increased gastric and intestinal permeability in patients with Crohn's disease. *Am J Gastroenterol*. 1997;92:1891-1896.
- Puspok A, Oberhuber G, Wyatt J, et al. Gastrointestinal permeability in Crohn's disease. *Eur J Clin Invest*. 1998;28:67-71.
- May GR, Sutherland LR, Meddings JB. Is small intestinal permeability really increased in relatives of patients with Crohn's disease? *Gastroenterology*. 1993;104:1627-1632.
- Cho JH. Advances in the genetics of inflammatory bowel disease. *Curr Gastroenterol Rep*. 2004;6:467-473.
- Cho JH. Significant role of genetics in IBD: the NOD2 gene. *Rev Gastroenterol Disord*. 2003;3(suppl 1):S18-S22.
- Gasche C, Grundtner P. Genotypes and phenotypes in Crohn's disease: do they help in clinical management? *Gut*. 2005;54:162-167.
- Grimm MC, Pavli P. NOD2 mutations and Crohn's disease: are Paneth cells and their antimicrobial peptides the link? *Gut*. 2004;53:1558-1560.
- Sartor R. Microbial influences in inflammatory bowel diseases: role in pathogenesis and clinical implications. In: Sartor R, Sandborn W, eds. *Kirsner's Inflammatory Bowel Diseases*. New York, NY: Saunders; 2004:120-137.
- Thomas GA, Rhodes J, Green JT. Inflammatory bowel disease and smoking—a review. *Am J Gastroenterol*. 1998;93:144-149.
- Cosnes J, Carbonnel F, Beaugerie L, et al. Effects of cigarette smoking on the long-term course of Crohn's disease. *Gastroenterology*. 1996;110:424-431.
- Rhodes J, Thomas GA. Smoking: good or bad for inflammatory bowel disease? *Gastroenterology*. 1994;106:807-810.
- Birrenbach T, Bocker U. Inflammatory bowel disease and smoking: a review of epidemiology, pathophysiology, and therapeutic implications. *Inflamm Bowel Dis*. 2004;10:848-859.
- Kane SV, Flicker M, Katz-Nelson F. Tobacco use is associated with accelerated clinical recurrence of Crohn's disease after surgically induced remission. *J Clin Gastroenterol*. 2005;39:32-35.
- Cottone M, Rosselli M, Orlando A, et al. Smoking habits and recurrence in Crohn's disease. *Gastroenterology*. 1994;106:643-648.
- Kleer CG, Appelman HD. Surgical pathology of Crohn's disease. *Surg Clin North Am*. 2001;81:13-30, vii.
- Block GE, Michelassi F, Tanaka M, et al. Crohn's disease. *Curr Probl Surg*. 1993;30:173-265.
- Mekhjian HS, Switz DM, Melnyk CS, et al. Clinical features and natural history of Crohn's disease. *Gastroenterology*. 1979;77(4 pt 2):898-906.
- Gasche C, Scholmerich J, Brynskov J, et al. A simple classification of Crohn's disease: report of the Working Party for the World Congresses of Gastroenterology, Vienna 1998. *Inflamm Bowel Dis*. 2000;6:8-15.
- Steinhart AH, Girgrah N, McLeod RS. Reliability of a Crohn's disease clinical classification scheme based on disease behavior. *Inflamm Bowel Dis*. 1998;4:228-234.
- Yamamoto T, Allan RN, Keighley MR. An audit of gastroduodenal Crohn disease: clinicopathologic features and management. *Scand J Gastroenterol*. 1999;34:1019-1024.
- Decker GA, Loftus EV, Jr, Pasha TM, et al. Crohn's disease of the esophagus: clinical features and outcomes. *Inflamm Bowel Dis*. 2001;7:113-119.
- Hurst RD, Melis M, Michelassi F. Surgery for Crohn's colitis. In: Bayless TM, Hanauer SB, eds. *Advanced Therapy of Inflammatory Bowel Disease*. Hamilton, Ontario, Canada: BC Decker; 2001:495-500.

41. Rankin GB, Watts HD, Melnyk CS, et al. National Cooperative Crohn's Disease Study: extraintestinal manifestations and perianal complications. *Gastroenterology*. 1979;77(4 pt 2):914-920.
42. Michelassi F, Melis M, Rubin M, et al. Surgical treatment of anorectal complications in Crohn's disease. *Surgery*. 2000;128:597-603.
43. Isaacs K. Extra-intestinal manifestations. In: Bayless TM, Hanauer SB, eds. *Advanced Therapy of Inflammatory Bowel Disease*. Hamilton, Ontario, Canada: BC Decker; 2001:267-270.
44. Loftus EV, Jr. Management of extraintestinal manifestations and other complications of inflammatory bowel disease. *Curr Gastroenterol Rep*. 2004;6:506-513.
45. Mintz R, Feller ER, Bahr RL, et al. Ocular manifestations of inflammatory bowel disease. *Inflamm Bowel Dis*. 2004;10:135-139.
46. Schreyer AG, Seitz J, Feuerbach S, et al. Modern imaging using computed tomography and magnetic resonance imaging for inflammatory bowel disease (IBD) AU1. *Inflamm Bowel Dis*. 2004;10:45-54.
47. Orel SG, Rubesin SE, Jones B, et al. Computed tomography vs. barium studies in the acutely symptomatic patient with Crohn disease. *J Comput Assist Tomogr*. 1987;11: 1009-1016.
48. Munkholm P, Binder V. Clinical features and natural history of Crohn's disease. In: Sartor R, Sandborn WJ, eds. *Kirshner's Inflammatory Bowel Diseases*, 6th ed. New York, NY: Saunders; 2004:289-300.
49. Nolan DJ. The radiological appearances of small intestinal Crohn's disease with the enteroclysis technique. *Acta Gastroenterol Belg*. 1987; 50:513-518.
50. Chernish SM, Maglinte DD, O'Connor K. Evaluation of the small intestine by enteroclysis for Crohn's disease. *Am J Gastroenterol*. 1992;87: 696-701.
51. Bernstein CN, Boulton IF, Greenberg HM, et al. A prospective randomized comparison between small bowel enteroclysis and small bowel follow-through in Crohn's disease. *Gastroenterology*. 1997;113:390-398.
52. Cirillo LC, Camera L, Della Noce M, et al. Accuracy of enteroclysis in Crohn's disease of the small bowel: a retrospective study. *Eur Radiol*. 2000;10:1894-1898.
53. Rutgeerts P, Vantrappen G, Geboes K. Endoscopy in inflammatory bowel disease. *Scand J Gastroenterol Suppl*. 1989;170:12-15; discussion 6-9.
54. Michelassi F, Stella M, Balestracci T, et al. Incidence, diagnosis, and treatment of enteric and colorectal fistulae in patients with Crohn's disease. *Ann Surg*. 1993;218:660-666.
55. Schraut WH, Chapman C, Abraham VS. Operative treatment of Crohn's ileocolitis complicated by ileosigmoid and ileovesical fistulae. *Ann Surg*. 1988;207:48-51.
56. Otterson MF, Lundeen SJ, Spinelli KS, et al. Radio-graphic underestimation of small bowel stricturing Crohn's disease: a comparison with surgical findings. *Surgery*. 2004;136:854-860.
57. Kornbluth A, Legnani P, Lewis BS. Video capsule endoscopy in inflammatory bowel disease: past, present, and future. *Inflamm Bowel Dis*. 2004;10:278-285.
58. Voderholzer WA, Beinhold J, Rogalla P, et al. Small bowel involvement in Crohn's disease: a prospective comparison of wireless capsule endoscopy and computed tomography enteroclysis. *Gut*. 2005;54:369-373.
59. Solem CA, Loftus EV, Jr, Fletcher JG, et al. Small-bowel imaging in Crohn's disease: a prospective, blinded, 4-way comparison trial. *Gastrointest Endosc*. 2008;68(2):255-266.
60. Triester SL, Leighton JA, Leontiadis GI, et al. A meta-analysis of the yield of capsule endoscopy compared to other diagnostic modalities in patients with non-stricturing small bowel Crohn's disease. *Am J Gastroenterol*. 2006;101(5):954-964.
61. Fishman EK, Wolf EJ, Jones B, et al. CT evaluation of Crohn's disease: effect on patient management. *AJR Am J Roentgenol*. 1987;148: 537-540.
62. Zalis M, Singh AK. Imaging of inflammatory bowel disease: CT and MR. *Dig Dis*. 2004;22:56-62.
63. Bodily KD, Fletcher JG, Solem CA, et al. Crohn disease: mural attenuation and thickness at contrast-enhanced CT enterography—correlation with endoscopic and histologic findings of inflammation. *Radiology*. 2006;238(2):505-516.
64. Booya F, Akram S, Fletcher JG, et al. CT enterography and fistulizing Crohn's disease: clinical benefit and radiographic findings. *Abdom Imaging*. 2009;34(4):467-475.
65. Brenner DJ, Hall EJ. Computed tomography—an increasing source of radiation exposure. *N Engl J Med*. 2007;357(22):2277-2784.
66. Peloquin JM, Pardi DS, Sandborn WJ, et al. Diagnostic ionizing radiation exposure in a population-based cohort of patients with inflammatory bowel disease. *Am J Gastroenterol*. 2008;103(8):2015-2022.
67. Siddiki HA, Fidler JL, Fletcher JG, et al. Prospective comparison of state-of-the-art MR enterography and CT enterography in small-bowel Crohn's disease. *AJR Am J Roentgenol*. 2009;193(1):113-121.
68. American Thoracic Society. Targeted tuberculin testing and treatment of latent tuberculosis infection. *MMWR Recomm Rep*. 2000;49(RR-6): 1-51.
69. Bjarnason I, Zanelli G, Smith T, et al. Nonsteroidal anti-inflammatory drug-induced intestinal inflammation in humans. *Gastroenterology*. 1987; 93:480-489.
70. Gibson GR, Whitacre EB, Ricotti CA. Colitis induced by nonsteroidal anti-inflammatory drugs. Report of four cases and review of the literature. *Arch Intern Med*. 1992;152:625-632.
71. Summers RW, Switz DM, Sessions JT, Jr, et al. National Cooperative Crohn's Disease Study: results of drug treatment. *Gastroenterology*. 1979;77(4 pt 2):847-869.
72. Hanauer SB, Stein RB. Medical therapy. In: Michelassi F, Milsom JW, eds. *Operative Strategies in Inflammatory Bowel Disease*. New York, NY: Springer-Verlag;1999:138-149.
73. Mahadevan U, Sandborn WJ. Clinical pharmacology of inflammatory bowel disease. In: Sartor R, Sandborn WJ, eds. *Kirshner's Inflammatory Bowel Diseases*. 6th ed. New York, NY: Saunders; 2004:484-502.
74. Caprilli R, Corrao G, Taddei G, et al. Prognostic factors for postoperative recurrence of Crohn's disease. Gruppo Italiano per lo Studio del Colon e del Retto (GISC). *Dis Colon Rectum*. 1996;39:335-341.
75. Hanauer SB, Korelitz BI, Rutgeerts P, et al. Postoperative maintenance of Crohn's disease remission with 6-mercaptopurine, mesalamine, or placebo: a 2-year trial. *Gastroenterology*. 2004;127:723-729.
76. Lochs H, Mayer M, Fleig WE, et al. Prophylaxis of postoperative relapse in Crohn's disease with mesalamine: European Cooperative Crohn's Disease Study VI. *Gastroenterology*. 2000;118:264-273.
77. McLeod RS, Wolff BG, Steinhart AH, et al. Prophylactic mesalamine treatment decreases postoperative recurrence of Crohn's disease. *Gastroenterology*. 1995;109:404-413.
78. Harrell LE, Hanauer SB. Mesalamine derivatives in the treatment of Crohn's disease. *Gastroenterol Clin North Am*. 2004;33:303-317, ix-x.
79. Bjarnason I, Peters TJ. Intestinal permeability, non-steroidal anti-inflammatory drug enteropathy and inflammatory bowel disease: an overview. *Gut*. 1989;30(Spec No):22-28.
80. Kaufmann HJ, Taubin HL. Nonsteroidal anti-inflammatory drugs activate quiescent inflammatory bowel disease. *Ann Intern Med*. 1987; 107:513-516.
81. Felder JB, Korelitz BI, Rajapakse R, et al. Effects of nonsteroidal anti-inflammatory drugs on inflammatory bowel disease: a case-control study. *Am J Gastroenterol*. 2000;95:1949-1954.
82. Bonner GF, Walczak M, Kitchen L, et al. Tolerance of nonsteroidal anti-inflammatory drugs in patients with inflammatory bowel disease. *Am J Gastroenterol*. 2000;95:1946-1948.
83. Bonner GF, Fakhri A, Vennamaneni SR. A long-term cohort study of non-steroidal anti-inflammatory drug use and disease activity in outpatients with inflammatory bowel disease. *Inflamm Bowel Dis*. 2004;10:751-757.
84. Forrest K, Symmons D, Foster P. Systematic review: is ingestion of paracetamol or non-steroidal anti-inflammatory drugs associated with exacerbations of inflammatory bowel disease? *Aliment Pharmacol Ther*. 2004;20:1035-1043.
85. Choi PM, Targan SR. Immunomodulator therapy in inflammatory bowel disease. *Dig Dis Sci*. 1994;39:1885-1892.
86. Pearson DC, May GR, Fick GH, Sutherland LR. Azathioprine and 6-mercaptopurine in Crohn disease. A meta-analysis. *Ann Intern Med*. 1995;123:132-142.
87. Targan SR, Hanauer SB, van Deventer SJ, et al. A short-term study of chimeric monoclonal antibody cA2 to tumor necrosis factor alpha for Crohn's disease. Crohn's Disease cA2 Study Group. *N Engl J Med*. 1997;337:1029-1035.
88. van Dullemen HM, van Deventer SJ, Hommes DW, et al. Treatment of Crohn's disease with anti-tumor necrosis factor chimeric monoclonal antibody (cA2). *Gastroenterology*. 1995;109:129-135.
89. Colombel JF, Loftus EV, Jr, Tremaine WJ, et al. Early postoperative complications are not increased in patients with Crohn's disease treated perioperatively with infliximab or immunosuppressive therapy. *Am J Gastroenterol*. 2004;99(5):878-883.



90. Marchal L, D'Haens G, Van Assche G, et al. The risk of post-operative complications associated with infliximab therapy for Crohn's disease: a controlled cohort study. *Aliment Pharmacol Ther.* 2004;19(7):749-754.
91. Kunitake H, Hodin R, Shellito PC, Sands BE, Korzenik J, Bordeianou L. Perioperative treatment with infliximab in patients with Crohn's disease and ulcerative colitis is not associated with an increased rate of post-operative complications. *J Gastrointest Surg.* 2008;12(10):1730-1736.
92. Appau KA, Fazio VW, Shen B, et al. Use of infliximab within 3 months of ileocolonic resection is associated with adverse postoperative outcomes in Crohn's patients. *J Gastrointest Surg.* 2008;12(10):1738-1744.
93. Hurst RD, Molinari M, Chung TP, et al. Prospective study of the features, indications, and surgical treatment in 513 consecutive patients affected by Crohn's disease. *Surgery.* 1997;122:661-667; discussion 7-8.
94. Michelassi F, Balestracci T, Chappell R, et al. Primary and recurrent Crohn's disease. Experience with 1379 patients. *Ann Surg.* 1991;214:230-238; discussion 8-40.
95. Cheung O, Regueiro MD. Inflammatory bowel disease emergencies. *Gastroenterol Clin North Am.* 2003;32:1269-1288.
96. Broe PJ, Bayless TM, Cameron JL. Crohn's disease: are enteroenteral fistulas an indication for surgery? *Surgery.* 1982;91:249-253.
97. Glass RE, Ritchie JK, Lennard-Jones JE, et al. Internal fistulas in Crohn's disease. *Dis Colon Rectum.* 1985;28:557-561.
98. Hawker PC, Givel JC, Keighley MR, et al. Management of enterocutaneous fistulae in Crohn's disease. *Gut.* 1983;24:284-287.
99. Heyen F, Winslet MC, Andrews H, et al. Vaginal fistulas in Crohn's disease. *Dis Colon Rectum.* 1989;32:379-383.
100. Michelassi F, Finco C, Balestracci T, et al. Incidence, diagnosis and treatment of abdominal abscesses in Crohn's patients. *Research in Surgery.* 1996;8:35-39.
101. Bernini A, Spencer MP, Wong WD, et al. Computed tomography-guided percutaneous abscess drainage in intestinal disease: factors associated with outcome. *Dis Colon Rectum.* 1997;40:1009-1013.
102. Doemeny JM, Burke DR, Meranze SG. Percutaneous drainage of abscesses in patients with Crohn's disease. *Gastrointest Radiol.* 1988;13:237-241.
103. Gervais DA, Hahn PF, O'Neill MJ, et al. Percutaneous abscess drainage in Crohn disease: technical success and short- and long-term outcomes during 14 years. *Radiology.* 2002;222:645-651.
104. Greenstein AJ, Sachar DB, Mann D, et al. Spontaneous free perforation and perforated abscess in 30 patients with Crohn's disease. *Ann Surg.* 1987;205:72-76.
105. Robert JR, Sachar DB, Greenstein AJ. Severe gastrointestinal hemorrhage in Crohn's disease. *Ann Surg.* 1991;213:207-211.
106. Ribeiro MB, Greenstein AJ, Heimann TM, et al. Adenocarcinoma of the small intestine in Crohn's disease. *Surg Gynecol Obstet.* 1991;173:343-349.
107. Greenstein AJ, Sachar D, Pucillo A, et al. Cancer in Crohn's disease after diversionary surgery. A report of seven carcinomas occurring in excluded bowel. *Am J Surg.* 1978;135:86-90.
108. Bernstein D, Rogers A. Malignancy in Crohn's disease. *Am J Gastroenterol.* 1996;91:434-440.
109. Korelitz BI, Lauwers GY, Sommers SC. Rectal mucosal dysplasia in Crohn's disease. *Gut.* 1990;31:1382-1386.
110. Kelts DG, Grand RJ, Shen G, et al. Nutritional basis of growth failure in children and adolescents with Crohn's disease. *Gastroenterology.* 1979;76:720-727.
111. Werlin SL. Growth failure in Crohn's disease: an approach to treatment. *JPN J Parenter Enteral Nutr.* 1981;5:250-253.
112. Bucher P, Mermillod B, Gervaz P, et al. Mechanical bowel preparation for elective colorectal surgery: a meta-analysis. *Arch Surg.* 2004;139:1359-1364; discussion 65.
113. Wille-Jørgensen P, Guenaga KF, Castro AA, et al. Clinical value of preoperative mechanical bowel cleansing in elective colorectal surgery: a systematic review. *Dis Colon Rectum.* 2003;46:1013-1020.
114. Bucher P, Gervaz P, Soravia C, et al. Randomized clinical trial of mechanical bowel preparation versus no preparation before elective left-sided colorectal surgery. *Br J Surg.* 2005;92:409-414.
115. Song F, Glenny AM. Antimicrobial prophylaxis in colorectal surgery: a systematic review of randomized controlled trials. *Br J Surg.* 1998;85:1232-1241.
116. Calnan J, Davies A. The effect of methotrexate (amethopterin) on wound healing: an experimental study. *Br J Cancer.* 1965;19:505-512.
117. Fazio VW, Marchetti F, Church M, et al. Effect of resection margins on the recurrence of Crohn's disease in the small bowel. A randomized controlled trial. *Ann Surg.* 1996;224:563-571; discussion 71-73.
118. Kotanagi H, Kramer K, Fazio VW, et al. Do microscopic abnormalities at resection margins correlate with increased anastomotic recurrence in Crohn's disease? Retrospective analysis of 100 cases. *Dis Colon Rectum.* 1991;34:909-916.
119. Pennington L, Hamilton SR, Bayless TM, et al. Surgical management of Crohn's disease. Influence of disease at margin of resection. *Ann Surg.* 1980;192:311-318.
120. Speranza V, Simi M, Leardi S, Del Papa M. Recurrence of Crohn's disease after resection. Are there any risk factors? *J Clin Gastroenterol.* 1986;8:640-646.
121. Aufses AH, Jr. The surgery of granulomatous inflammatory bowel disease. *Curr Probl Surg.* 1983;20:755-826.
122. Cameron JL, Hamilton SR, Coleman J, et al. Patterns of ileal recurrence in Crohn's disease. A prospective randomized study. *Ann Surg.* 1992;215:546-551; discussion 51-52.
123. Scott NA, Sue-Ling HM, Hughes LE. Anastomotic configuration does not affect recurrence of Crohn's disease after ileocolonic resection. *Int J Colorectal Dis.* 1995;10:67-69.
124. Scarpa M, Angriman I, Barollo M, et al. Role of stapled and hand-sewn anastomoses in recurrence of Crohn's disease. *Hepatogastroenterology.* 2004;51:1053-1057.
125. Munoz-Juarez M, Yamamoto T, Wolff BG, et al. Wide-lumen stapled anastomosis vs. conventional end-to-end anastomosis in the treatment of Crohn's disease. *Dis Colon Rectum.* 2001;44:20-25; discussion 5-6.
126. Tersigni R, Alessandrini L, Barreca M, et al. Does stapled functional end-to-end anastomosis affect recurrence of Crohn's disease after ileocolonic resection? *Hepatogastroenterology.* 2003;50:1422-1425.
127. Bass EM, Del Pino A, Tan A, et al. Does preoperative stoma marking and education by the enterostomal therapist affect outcome? *Dis Colon Rectum.* 1997;40:440-442.
128. Erwin-Toth P, Barrett P. Stoma marking: a primer. *Ostomy Wound Manage.* 1997;43:18-22, 4-5.
129. Ritchie JK. Ileostomy and excisional surgery for chronic inflammatory disease of the colon: a survey of one hospital region. *Gut.* 1971;12:528-540.
130. Michelassi F, Upadhyay GA. Side-to-side isoperistaltic stricturoplasty in the treatment of extensive Crohn's disease. *J Surg Res.* 2004;117:71-78.
131. Milsom JW. Stricturoplasty and mechanical dilation in strictured Crohn's disease. In: Michelassi F, Milsom JW, eds. *Operative Strategies in Inflammatory Bowel Disease.* New York, NY: Springer-Verlag; 1999:259-267.
132. Fazio VW, Galandiuk S, Jagelman DG, et al. Stricturoplasty in Crohn's disease. *Ann Surg.* 1989;210:621-625.
133. Roy P, Kumar D. Stricturoplasty. *Br J Surg.* 2004;91:1428-1437.
134. Sharif H, Alexander-Williams J. The role of stricturoplasty in Crohn's disease. *Int Surg.* 1992;77:15-18.
135. Michelassi F. Side-to-side isoperistaltic stricturoplasty for multiple Crohn's strictures. *Dis Colon Rectum.* 1996;39:345-349.
136. Tonelli F, Fedi M, Paroli GM, et al. Indications and results of side-to-side isoperistaltic stricturoplasty in Crohn's disease. *Dis Colon Rectum.* 2004;47:494-501.
137. Sampietro GM, Cristaldi M, Maconi G, et al. A prospective, longitudinal study of nonconventional stricturoplasty in Crohn's disease. *J Am Coll Surg.* 2004;199:8-20.
138. Tichansky D, Cagir B, Yoo E, et al. Stricturoplasty for Crohn's disease: meta-analysis. *Dis Colon Rectum.* 2000;43:911-919.
139. Fazio VW, Tjandra JJ, Lavery IC, et al. Long-term follow-up of stricturoplasty in Crohn's disease. *Dis Colon Rectum.* 1993;36:355-361.
140. Hurst RD, Michelassi F. Stricturoplasty for Crohn's disease: techniques and long-term results. *World J Surg.* 1998;22:359-363.
141. Spencer MP, Nelson H, Wolff BG, et al. Stricturoplasty for obstructive Crohn's disease: the Mayo experience. *Mayo Clin Proc.* 1994;69:33-36.
142. Jaskowiak NT, Michelassi F. Adenocarcinoma at a stricturoplasty site in Crohn's disease: report of a case. *Dis Colon Rectum.* 2001;44:284-287.
143. Marchetti F, Fazio VW, Ozuner G. Adenocarcinoma arising from a stricturoplasty site in Crohn's disease. Report of a case. *Dis Colon Rectum.* 1996;39:1315-1321.
144. Mavrantonis C, Wexner SD, Noguera JJ, et al. Current attitudes in laparoscopic colorectal surgery. *Surg Endosc.* 2002;16:1152-1157.

145. Talac R, Nelson H. Laparoscopic colon and rectal surgery. *Surg Oncol Clin North Am* 2000;9:1–12, v.
146. Clinical Outcomes of Surgical Therapy Study Group. A comparison of laparoscopically assisted and open colectomy for colon cancer. *N Engl J Med*. 2004;350:2050–2059.
147. Alabaz O, Iroatulam AJ, Nessim A, et al. Comparison of laparoscopically assisted and conventional ileocolic resection for Crohn's disease. *Eur J Surg*. 2000;166:213–217.
148. Bauer JJ, Harris MT, Grumbach NM, et al. Laparoscopic-assisted intestinal resection for Crohn's disease. Which patients are good candidates? *J Clin Gastroenterol*. 1996;23:44–46.
149. Bemelman WA, Slors JF, Dunker MS, et al. Laparoscopic-assisted vs. open ileocolic resection for Crohn's disease. A comparative study. *Surg Endosc*. 2000;14:721–725.
150. Benoist S, Panis Y, Beaufour A, et al. Laparoscopic ileocecal resection in Crohn's disease: a case-matched comparison with open resection. *Surg Endosc*. 2003;17:814–818.
151. Canin-Endres J, Salky B, Gattorno F, et al. Laparoscopically assisted intestinal resection in 88 patients with Crohn's disease. *Surg Endosc*. 1999;13:595–599.
152. Diamond IR, Langer JC. Laparoscopic-assisted versus open ileocolic resection for adolescent Crohn disease. *J Pediatr Gastroenterol Nutr*. 2001;33:543–547.
153. Duepre HJ, Senagore AJ, Delaney CP, et al. Advantages of laparoscopic resection for ileocecal Crohn's disease. *Dis Colon Rectum*. 2002;45:605–610.
154. Kishi D, Nezu R, Ito T, et al. Laparoscopic-assisted surgery for Crohn's disease: reduced surgical stress following ileocelectomy. *Surg Today*. 2000;30:219–222.
155. Milsom JW, Hammerhofer KA, Bohm B, et al. Prospective, randomized trial comparing laparoscopic vs. conventional surgery for refractory ileocolic Crohn's disease. *Dis Colon Rectum*. 2001;44:1–8; discussion 9.
156. Msika S, Iannelli A, Deroide G, et al. Can laparoscopy reduce hospital stay in the treatment of Crohn's disease? *Dis Colon Rectum*. 2001;44:1661–1666.
157. Reissman P, Salky BA, Pfeifer J, et al. Laparoscopic surgery in the management of inflammatory bowel disease. *Am J Surg*. 1996;171:47–50; discussion 51.
158. Tabet J, Hong D, Kim CW, et al. Laparoscopic versus open bowel resection for Crohn's disease. *Can J Gastroenterol*. 2001;15:237–242.
159. Watanabe M, Ohgami M, Teramoto T, et al. Laparoscopic ileocecal resection for Crohn's disease associated with intestinal stenosis and ileorectal fistula. *Surg Today*. 1999;29:446–448.
160. Wu JS, Birnbaum EH, Kodner IJ, et al. Laparoscopic-assisted ileocolic resections in patients with Crohn's disease: are abscesses, phlegmons, or recurrent disease contraindications? *Surgery*. 1997;122:682–688; discussion 8–9.
161. Marshak RH, Maklansky D, Kurzban JD, et al. Crohn's disease of the stomach and duodenum. *Am J Gastroenterol*. 1982;77:340–341.
162. Fitzgibbons TJ, Green G, Silberman H, et al. Management of Crohn's disease involving the duodenum, including duodenal cutaneous fistula. *Arch Surg*. 1980;115:1022–1028.
163. Harold KL, Kelly KA. Duodenal Crohn disease. *Probl Gen Surg*. 1999;16:50–57.
164. Poggioli G, Stocchi L, Laureti S, et al. Duodenal involvement of Crohn's disease: three different clinicopathologic patterns. *Dis Colon Rectum*. 1997;40:179–183.
165. Schoetz D. Gastroduodenal Crohn's disease. In: Michelassi F, Milsom JW, eds. *Operative Strategies in Inflammatory Bowel Disease*. New York, NY: Springer-Verlag; 1999:389–393.
166. Lee KK, Schraut WH. Diagnosis and treatment of duodenoenteric fistulas complicating Crohn's disease. *Arch Surg*. 1989;124:712–715.
167. Pichney LS, Fantry GT, Graham SM. Gastrocolic and duodenocolic fistulas in Crohn's disease. *J Clin Gastroenterol*. 1992;15:205–211.
168. Block GE, Schraut WH. The operative treatment of Crohn's enteritis complicated by ileosigmoid fistula. *Ann Surg*. 1982;196:356–360.
169. Gruner JS, Sehon JK, Johnson LW. Diagnosis and management of enterovesical fistulas in patients with Crohn's disease. *Am Surg*. 2002;68:714–719.
170. Lefton HB, Farmer RG, Fazio V. Ileorectal anastomosis for Crohn's disease of the colon. *Gastroenterology*. 1975;69:612–617.
171. Panis Y, Poupard B, Nemeth J, et al. Ileal pouch/anal anastomosis for Crohn's disease. *Lancet*. 1996;347:854–857.
172. Regimbeau JM, Panis Y, Pocard M, et al. Long-term results of ileal pouch-anal anastomosis for colorectal Crohn's disease. *Dis Colon Rectum*. 2001;44:769–778.
173. Berry AR, de Campos R, Lee EC. Perineal and pelvic morbidity following perimuscular excision of the rectum for inflammatory bowel disease. *Br J Surg*. 1986;73:675–677.
174. Allan A, Andrews H, Hilton CJ, et al. Segmental colonic resection is an appropriate operation for short skip lesions due to Crohn's disease in the colon. *World J Surg*. 1989;13:611–614; discussion 5–6.
175. Sanfey H, Bayless TM, Cameron JL. Crohn's disease of the colon. Is there a role for limited resection? *Am J Surg*. 1984;147:38–42.
176. Sandborn WJ, Fazio VW, Feagan BG, et al. AGA technical review on perianal Crohn's disease. *Gastroenterology*. 2003;125:1508–1530.
177. Homan WP, Tang C, Thorgjarnarson B. Anal lesions complicating Crohn disease. *Arch Surg*. 1976;111:1333–1335.
178. Bernstein LH, Frank MS, Brandt LJ, et al. Healing of perineal Crohn's disease with metronidazole. *Gastroenterology*. 1980;79:599.
179. Turunen U, Farkkila M, Seppala K. Long-term treatment of perianal or fistulous Crohn's disease with ciprofloxacin. *Scand J Gastroenterol Suppl*. 1989;24:144.
180. Present DH, Rutgeerts P, Targan S, et al. Infliximab for the treatment of fistulas in patients with Crohn's disease. *N Engl J Med*. 1999;340:1398–1405.
181. Ardizzone S, Maconi G, Colombo E, et al. Perianal fistulae following infliximab treatment: clinical and endosono-graphic outcome. *Inflamm Bowel Dis*. 2004;10:91–96.
182. Regueiro M, Mardini H. Treatment of perianal fistulizing Crohn's disease with infliximab alone or as an adjunct to exam under anesthesia with seton placement. *Inflamm Bowel Dis*. 2003;9:98–103.
183. Loungnarath R, Dietz DW, Mutch MG, et al. Fibrin glue treatment of complex anal fistulas has low success rate. *Dis Colon Rectum*. 2004;47:432–436.
184. Zmora O, Mizrahi N, Rotholtz N, et al. Fibrin glue sealing in the treatment of perineal fistulas. *Dis Colon Rectum*. 2003;46:584–589.
185. Kodner IJ, Mazor A, Shemesh EI, et al. Endorectal advancement flap repair of rectovaginal and other complicated anorectal fistulas. *Surgery*. 1993;114:682–689.
186. D'Haens GR, Geboes K, Peeters M, et al. Early lesions of recurrent Crohn's disease caused by infusion of intestinal contents in excluded ileum. *Gastroenterology*. 1998;114:262–267.
187. Rutgeerts P, Geboes K, Vantrappen G, et al. Predictability of the postoperative course of Crohn's disease. *Gastroenterology*. 1990;99:956–963.
188. McLeod RS, Wolff BG, Steinhart AH, et al. Risk and significance of endoscopic/radiological evidence of recurrent Crohn's disease. *Gastroenterology*. 1997;113:1823–1827.
189. Best WR, Becktel JM, Singleton JW, et al. Development of a Crohn's disease activity index. National Cooperative Crohn's Disease Study. *Gastroenterology*. 1976;70:439–444.
190. Best WR, Becktel JM, Singleton JW. Rederived values of the eight coefficients of the Crohn's Disease Activity Index (CDAI). *Gastroenterology*. 1979;77(4 pt 2):843–846.
191. Greenstein AJ, Sachar DB, Pasternack BS, et al. Reoperation and recurrence in Crohn's colitis and ileocolitis: crude and cumulative rates. *N Engl J Med*. 1975;293:685–690.
192. Mekhjian HS, Switz DM, Watts HD, et al. National Cooperative Crohn's Disease Study: factors determining recurrence of Crohn's disease after surgery. *Gastroenterology*. 1979;77(4 pt 2):907–913.
193. Borley NR, Mortensen NJ, Jewell DP. Preventing postoperative recurrence of Crohn's disease. *Br J Surg*. 1997;84:1493–1502.
194. Post S, Herfarth C, Bohm E, et al. The impact of disease pattern, surgical management, and individual surgeons on the risk for relaparotomy for recurrent Crohn's disease. *Ann Surg*. 1996;223:253–260.
195. Chardavoyne R, Flint GW, Pollack S, et al. Factors affecting recurrence following resection for Crohn's disease. *Dis Colon Rectum*. 1986;29:495–502.
196. D'Haens G, Baert F, Gasparaitis A, et al. Length and type of recurrent ileitis after ileal resection correlate with presurgical features in Crohn's disease. *Inflamm Bowel Dis*. 1997;3:249–253.
197. D'Haens GR, Gasparaitis AE, Hanauer SB. Duration of recurrent ileitis after ileocolonic resection correlates with pre-surgical extent of Crohn's disease. *Gut*. 1995;36:715–717.

*This page intentionally left blank*



# ULCERATIVE COLITIS

Shawn Forbes • David Messenger • Robin S. McLeod

## INTRODUCTION

*Ulcerative colitis*, one of the idiopathic inflammatory bowel diseases (IBDs), is a chronic disease that affects the mucosa of the rectum and colon. Although Hippocrates described diarrheal diseases that were colitis-like well before 360 BC, it was not until the late 1800s that ulcerative colitis was distinguished clinically from common infectious enteritis. Sir Samuel Wilks of London is credited with the first medical account of colitis. In 1859, he described a 42-year-old woman who died after several months of diarrhea and fever. Postmortem examination revealed a transmural ulcerative inflammation of the colon and terminal ileum that, while originally designated as “simple ulcerative colitis,” may in fact have been Crohn’s disease. A subsequent case report in 1875, again by Wilks and Walter Moxon, described ulceration and inflammation of the entire colon in a young woman who had succumbed to severe bloody diarrhea, and it is more likely the first detailed account of ulcerative colitis.

The landmark description of regional enteritis in the 1930s, by Crohn, Ginzburg, and Oppenheimer, led to the recognition of the existence of two IBDs: Crohn’s disease and ulcerative colitis. Although the two diseases initially appeared to have distinct pathologic features, it is now recognized that there can be significant overlap not only pathologically but also in anatomic distribution and clinical manifestations. Furthermore, there may be overlap in the underlying cause of the two diseases.

Ulcerative colitis typically manifests with periods of remission and exacerbations characterized by rectal bleeding and diarrhea. Because ulcerative colitis most commonly affects patients in their youth or early middle age, the disease can have serious long-term local and systemic consequences. The etiology remains essentially unknown, but there have been significant advances in identifying likely genetic and environmental factors that contribute to its pathogenesis. Despite this, there is no definitive medical treatment for the disease. Medical therapy can only ameliorate the inflammatory process and control symptomatic flares. Thus, surgery has an important role in the management of ulcerative colitis as it is estimated that approximately 40% of patients with ulcerative colitis will ultimately require surgery.<sup>1</sup>

Proctocolectomy or total removal of the colon and rectum has been the standard surgical treatment for ulcerative colitis. In recent years, a number of other options have become available so a permanent ileostomy is not required. Irrespective of the surgical procedure, most patients can expect to lead normal lives with a high quality of life. However, in order to achieve these outcomes, patients must be carefully assessed and selected for surgery and receive optimal perioperative care. The surgery itself can be technically challenging, and postoperative complications must be recognized and managed appropriately. All of these require that surgeons have an understanding of the epidemiology and pathophysiology of ulcerative colitis, its clinical manifestations, medical management as well as issues related to surgical technique, preoperative assessment, and postoperative care of patients.

## EPIDEMIOLOGY

Ulcerative colitis poses many challenges to the epidemiologist because the incidence of the disease is low and it is rarely fatal. Its clinical presentation can be variable and often insidious. The interval between the onset of symptoms and the diagnosis can be decades, and there are no universal diagnostic criteria.<sup>2</sup> Despite these limitations, epidemiological studies can provide valuable insight into numerous potential etiologic factors.

In the United States, IBD afflicts approximately 2–6% of the population or up to 1.5 million individuals. Although there has been a noteworthy rise in the incidence of Crohn’s disease in the United States, the incidence of ulcerative colitis has risen only slightly in recent years. As a result, the annual incidence of Crohn’s disease is nearly equal to that of ulcerative colitis.

Worldwide, there is significant variation in the incidence of ulcerative colitis and may serve as a valuable etiologic clue. It appears that there is a distinct north-to-south gradation in risk in developed countries, with the greatest incidence and prevalence occurring in countries of the northern hemisphere such as the United Kingdom, Norway, Sweden, Canada, and the United States<sup>3</sup> where the annual incidence of ulcerative colitis is about 6–12 per 100,000. In more southern countries

such as Australia, South Africa, and countries of southern Europe the annual incidence of ulcerative colitis is about two to eight per 100,000. The incidence in Asia and South America is also considerably lower.<sup>3</sup> These trends also suggest that the incidence of ulcerative colitis is highest in developed or urban regions of the world and lowest in developing regions; however, it appears that the incidence of ulcerative colitis may be leveling off in developed countries and starting to rise in the developing nations. Epidemiologic studies have also shown that the incidence of ulcerative colitis among Jewish populations is two to four times higher than that in non-Jewish populations while the age-adjusted incidence for white men is about twice that of nonwhite men and the rate for nonwhite women is actually higher than that for white women.<sup>2</sup>

Although the onset age of ulcerative colitis is bimodal and typically occurs between the ages of 15 and 40 years and again after age 60, the disease can present at any age from infancy to the elderly. In fact, nearly 5% of new cases occur after age 60. Throughout the age range, men and women are affected about equally.

## PATHOPHYSIOLOGY

Although the pathogenesis of IBD has been studied intently for the past several decades, it is only recently that there have been significant advances leading to an appreciation that genes, the environment, as well as the immune response play important roles in the development of ulcerative colitis.<sup>4</sup> The evidence now suggests that there is an inappropriate inflammatory response to intestinal bacteria in genetically susceptible individuals leading to a sustained mucosal inflammatory response that the host is unable to downregulate. Failure to attenuate this response leads to increased recruitment and activation of immune and inflammatory cells, leading to the release of proinflammatory mediators and perpetuation of inflammation and damage to intestinal tissues.

Both Crohn's disease and ulcerative colitis often affect several members of families providing strong evidence that there is a genetic basis to both diseases. However, while there appears to be a genetic predisposition among family members of patients with ulcerative colitis, a much stronger familial predisposition is seen in Crohn's disease. Furthermore, Crohn's disease and ulcerative colitis can be seen within the same family, reflected by an 80–90% concordance for the same disease category. This suggests that there are many overlapping genetic loci.

In recent genome-wide association studies in patients with ulcerative colitis, a highly significant association was observed for a common polymorphism in a region on chromosome 1q32 containing the *IL10* gene.<sup>5</sup> This family of cytokines mediate host defense against infection as well as tissue inflammation in chronic immune-mediated diseases. The other identified associations have been within the major histocompatibility complex class II region near HLA-DRA.<sup>6</sup> However, even with the identification of new genetic susceptibility loci, the identified IBD markers account for only 20%

of the heritable risk, emphasizing that there are other unidentified mutations that probably play a role in the development of ulcerative colitis.

While genetic susceptibility is important, studies in monozygotic twins have shown that the concordance between twins is only 40–60%, suggesting that environmental factors are also necessary to trigger the disease.<sup>7</sup> The likely triggers appear to be agents that affect the mucosal barrier of the bowel. There is some evidence that bacterial and viral infections are associated with IBD, although no specific species have been implicated. Similarly, nonsteroidal anti-inflammatory drugs (NSAIDs) are associated with IBD, and last, while smoking is associated with Crohn's disease, it is protective in ulcerative colitis. Diet may be an environmental factor in that it may alter the flora.

It is currently thought that loss of tolerance against indigenous enteric flora is the fundamental event in the pathogenesis of ulcerative colitis. The intestinal mucosa is continually exposed to bacteria. There are two basic components to the immune response: innate and adaptive. Innate immunity is the more basic form and is the initial response to invading pathogens.<sup>4</sup> The epithelial barrier and phagocytes within the lamina propria are the main components of innate immunity. The protective effect of innate immunity is limited because it does not have a memory, and therefore the immune response is not increased upon reinfection. It is for this reason that adaptive immunity, which is largely mediated by lymphocytes, T and B cells, that express antigen receptors on their surface, evolved. Cytokines, which are produced by T cells in response to infection, eradicate infection and also give rise to memory cells that prevent infection upon reinfection.

IBD occurs as result of the abnormal and sustained mucosal inflammatory response that the host is unable to downregulate. Recent evidence suggests that the initial response by the innate immune system is inadequate and initiates this process. The T lymphocytes, which are part of the adaptive immune response, however, appear to play a key role in the disease pathogenesis. There are various subpopulations of T cells that secrete cytokines. Once activated, there is a persistent uncontrolled inflammatory response with further recruitment of unregulated cells. A different subset of T cells is activated in ulcerative colitis compared to Crohn's disease. This subset produces interleukin 13 (IL-13) as well as interferon- $\gamma$  (IFN- $\gamma$ ), resulting in epithelial dysfunction, antibody production, and immune complex formation resulting in complement activation and mast cell degranulation. The effects of these activating events may account for distinct pathologic findings and specific disease expression.

## PATHOLOGY

### Gross Findings

Ulcerative colitis begins in the rectum above the dentate line and progresses proximally.<sup>8</sup> Involvement is classically diffuse. Rectal sparing or a patchy distribution throughout the colon

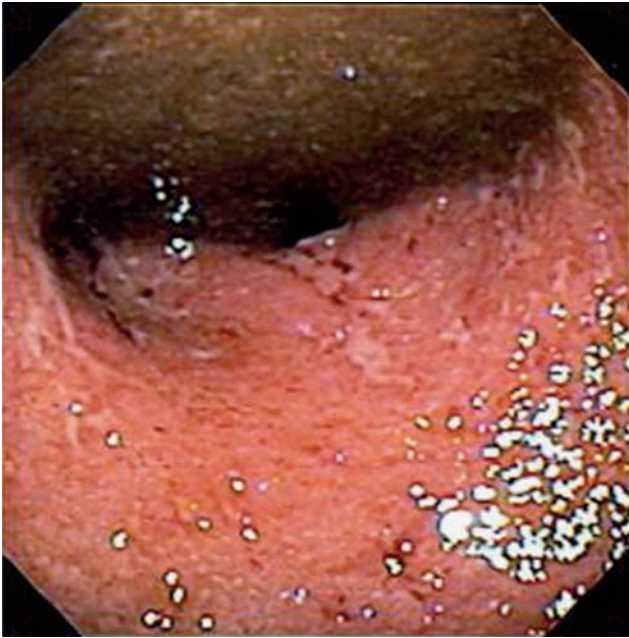


FIGURE 34-1 Endoscopic appearance of ulcerative colitis.

should lead to a suspicion of Crohn's disease. Often, the disease may be limited to the rectum at first but can progress proximally over time. Changes are typically limited to the mucosa and superficial submucosa, although full-thickness inflammation may be seen in fulminant cases and may lead to a diagnosis of indeterminate colitis in patients having surgery for severe disease. The serosa is otherwise preserved. Mucosal changes seen at endoscopy or on gross pathologic examination include edema, hyperemia, and granularity of the mucosal lining (Figs. 34-1 and 34-2). The tissues are often friable and may bleed easily with contact in the acute setting. Over time, mucosal erosions occur, coalescing to form linear ulcers

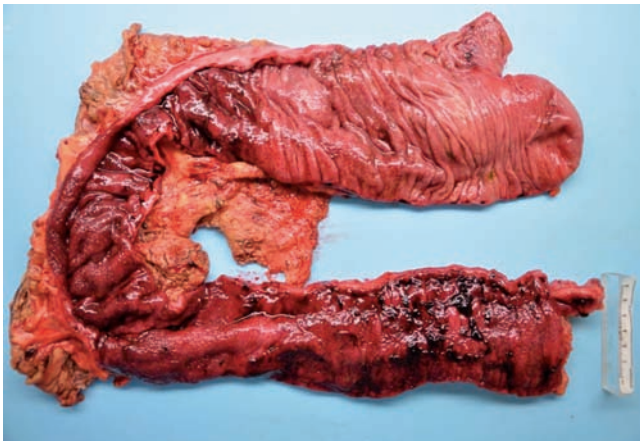


FIGURE 34-2 Colectomy specimen showing typical features of ulcerative colitis.

and leaving mucosal islands, commonly referred to as *pseudopolyps* due to their polypoid appearance. The colon will often develop a “burnt-out” appearance after long-standing disease with loss of mucosal folds (atrophy). The chronic inflammatory process may lead to shortening of the colon and loss of rectal compliance, leading to frequent bowel movements, even if no or minimal active inflammation is present. Strictureing is uncommon and, if present, should raise the suspicion of a malignancy. As many as 24% of strictures found in the setting of ulcerative colitis are malignant.<sup>9</sup>

While ulcerative colitis is limited to the colon and rectum, a phenomenon known as “backwash ileitis” has been described. This terminal ileal inflammatory change is believed to be consequent to the reflux of colonic contents into the terminal ileum through an incompetent ileocecal valve in patients with pancolitis. Endoscopically, backwash ileitis is evident by a patulous ileocecal valve and terminal ileum. The histologic appearance resembles pouchitis and the finding should not be dismissed as indicative of Crohn's disease.<sup>10</sup>

## Microscopic Findings

Crypt infiltration with neutrophils causing so-called “cryptitis” and “crypt abscesses” are pathognomonic for active ulcerative colitis. This is accompanied by diffuse chronic inflammation in the lamina propria, often with deep plasma cells, and mucosal architectural distortion (crypt branching, shortening, or atrophy). Crypt abscesses may coalesce giving rise to erosions or linear ulcers (Fig. 34-3). Undermining of adjacent mucosa by such ulcers may lead to the formation of pseudopolyps. Ulcerative colitis is classically a mucosal disease, and the transmural inflammation, stricturing fibrosis, and fissuring ulcers of Crohn's disease are not features of this disease. An exception is fulminant ulcerative colitis in which deep, sometimes fissuring, ulcers as well as transmural

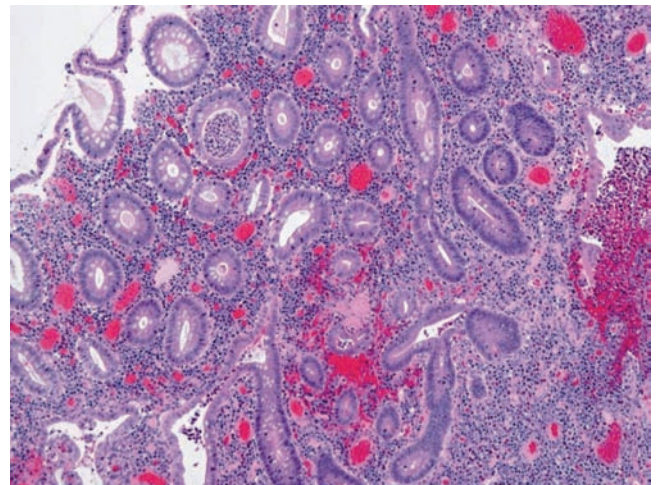


FIGURE 34-3 Histologic features of ulcerative colitis.



inflammation may be seen, sometimes leading to confusion with Crohn's disease. However, unlike in Crohn's disease, transmural inflammation is confined to areas of ulceration, and discrete transmural lymphoid aggregates and granulomas are not seen. In quiescent ulcerative colitis, cryptitis, and crypt abscess resolve, but a mild chronic inflammatory infiltrate and crypt distortion typically persist.

## CLINICAL FEATURES

The initial presentation of ulcerative colitis can vary widely from a minor disturbance in bowel function, to a rapidly progressive and fulminant course with toxicity and impending perforation. The time between onset of symptoms and diagnosis often varies with the severity of the presentation. Many patients initially have disease limited to the rectosigmoid region and present with cramping abdominal pain relieved with defecation, rectal bleeding, and diarrhea. With time, the severity of the disease may progress, with increasing involvement of the remaining colon until pancolitis results. As the disease worsens, patients often report more frequent bowel movements, 10 or more per day, tenesmus, and ongoing blood loss either as bloody stools or passage of mucus and blood alone. An acute severe episode is the initial mode of presentation in approximately 10% of patients with ulcerative colitis, with many requiring an emergent colectomy before any definitive diagnosis is made.<sup>11</sup> Fulminant colitis occurs infrequently, having decreased in incidence markedly over the past 50 years.

The most common patterns of disease are those of chronic, unrelenting symptoms or intermittent flare-ups of symptoms, interspersed between episodes of relative quiescence. Patients with chronic symptoms often become dependent on immunosuppressive therapy, or their response to medical therapies may at best be partial. Patients who have intermittent flare-ups of symptoms may have long periods where the disease is quiescent. They also may benefit from maintenance therapy.

According to the Truelove and Witt criteria, patients with severe episodes of colitis are defined as those having six or more stools per day, with one or more of the following: large

amounts of blood; fevers greater than 37.5°C, heart rates of 90 beats/min or more, anemia with hemoglobin levels less than 75% of normal, and erythrocyte sedimentation rates (ESR) of 30 mm/h or more.<sup>12</sup> Mild cases have none of these features, whereas moderate cases exhibit a less marked physiologic derangement (Table 34-1). The severity of disease may vary over time and with medical therapy. Over time, the sequelae of long-standing ulcerative colitis may show if the disease is poorly controlled. These include anemia, weight loss, and growth retardation in the young, as well as metabolic derangements.

The symptoms of ulcerative colitis are not limited to the colon. Extraintestinal manifestations of the disease may be present at initial presentation or at any time during the course of the disease.<sup>13</sup> As many as 40% of patients may have associated disease involving the eyes (uveitis and iritis), skin (pyoderma gangrenosum Fig. 34-4A and erythema nodosa), joints (arthritis, sacroiliitis), or hepatobiliary tract (primary sclerosing cholangitis [PSC]) (Fig. 34-4B). The severity of these extraintestinal manifestations of disease may coincide with the severity of the colitis. Some of these, including arthritis and skin manifestations, tend to respond to treatment or surgical extirpation of the colon. Hepatic manifestations of disease are the most common extracolonic disease site. Asymptomatic fatty infiltration of the liver seen on histologic examination is the most common extraintestinal manifestation. As many as 2–7% of patients with ulcerative colitis develop PSC. The symptoms and progression of PSC are not affected by the management of the colonic disease. Patients with progressive liver failure from PSC ultimately may require liver transplant. Affected patients are also at greater risk of developing carcinoma of the bile duct, although this may also develop de novo in patients with ulcerative colitis.

## DIAGNOSIS

### Endoscopy

The diagnosis of ulcerative colitis is usually made based on clinical symptoms confirmed by endoscopy. Barium enema

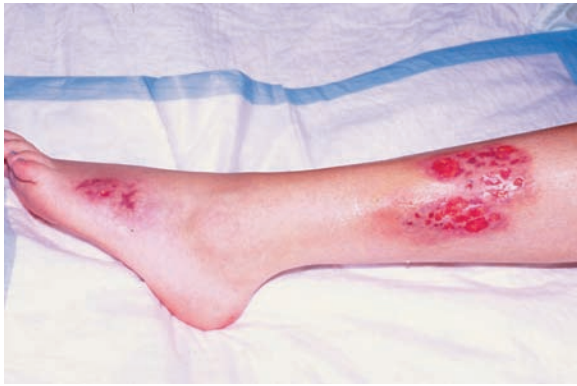

**TABLE 34-1: DISEASE ACTIVITY IN ULCERATIVE COLITIS**

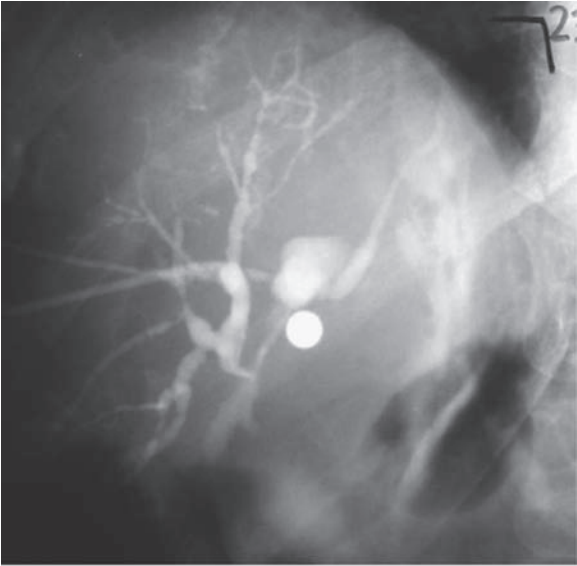
	Mild	Moderate	Severe
Bloody stools/day	<4	4 or more	≥6
Pulse	<90 beats/min	≤90 beats/min	>90 beats/min
Temperature	<37.5°C	≤37.8°C	>37.8°C
Hemoglobin	>11.5 g/dL	≥10.5 g/dL	<10.5 g/dL
ESR	<20 mm/h	≤30 mm/h	>30 mm/h
CRP	Normal	≤30 mg/L	>30 mg/L

CRP, C-reactive protein; ESR, erythrocyte sedimentation rate.

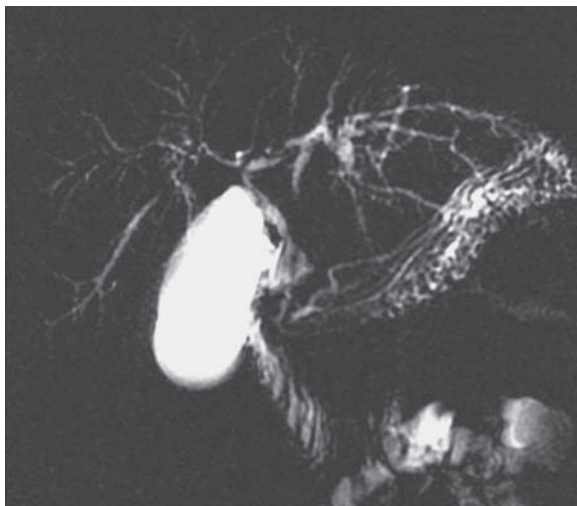
Modified from Strange EF, Travis SPL, Vermeire S, et al; for the European Crohn's and Colitis Organisation (ECCO). European evidence-based consensus on the diagnosis and management of ulcerative colitis: definitions and diagnosis. *J Crohns Colitis*. 2008;2:1–23.



A



B



C

**FIGURE 34-4** Extraintestinal manifestations of ulcerative colitis. **A.** Pyoderma gangrenosum affecting the lower limb. **B.** Primary sclerosing cholangitis—its typical appearance showing structuring of the intra- and extrahepatic biliary tract. **C.** Primary sclerosing cholangitis—MRCP appearance of primary sclerosing cholangitis.

and air contrast barium enema are no longer used to make the diagnosis because they are less sensitive in detecting early changes and assessing the severity and extent of disease.

Differentiating ulcerative colitis from Crohn's disease is especially important because the treatment differs. This is especially true for surgical management. In mild cases, there is loss of the normal vascular pattern, a granular texture and microhemorrhages when the friable mucosa is touched or wiped. When the disease is moderately active, the mucosa becomes more grossly pitted and spontaneous bleeding is often present. In severe cases, there are macroulcerations and profuse bleeding, usually accompanied by a purulent exudate (Table 34-2).

Chronic ulcerative colitis is frequently associated with the appearance of small pseudopolyps, which represent areas of regenerating mucosa in the midst of diffuse mucosal destruction. Also, the colon tends to be foreshortened and lacks distensibility. This is particularly true of the rectum and may account for increased stool frequency in the absence of acute inflammation.

In patients who have severe acute ulcerative colitis, colonoscopy is generally contraindicated because of the concern of perforation. However, flexible sigmoidoscopy should be performed to assess the disease status of the colon prior to surgery. Occasionally, the pathologic diagnosis may change to Crohn's disease postoperatively. Because generally the patient would not be a candidate for an ileal-pouch anal anastomosis (IPAA), it is important to know the status of the rectum to determine if he or she is a candidate for an ileorectal anastomosis (IRA). Postoperatively, there may be changes of disuse colitis so preoperative assessment of the rectum is preferred. In addition to endoscopy playing an important role in the diagnosis and assessment of acute ulcerative colitis, it should be performed for surveillance of cancer. Screening colonoscopy should begin 8–10 years after the onset of symptoms and be performed every 1–2 years. Four-quadrant biopsies should be taken at 10-cm intervals. A minimum of 33 biopsies should be taken. In addition, raised lesions and strictures should be biopsied. Dye spraying with methylene blue or indigo carmine dye may be helpful in identifying raised lesions. Confocal laser endomicroscopy is another technique that may be useful in identifying suspicious lesions and guide biopsies.

Typically, dysplasia is a histologic diagnosis and can only be made by histologic examination (Fig. 34-5). Raised dysplastic lesions, commonly referred to as *dysplasia-associated lesions or masses* (DALM), are significant because 25–50% have been reported to harbor cancer.<sup>14</sup> Some may appear irregular and sessile whereas others may have a typical appearance of adenomas. The area surrounding a raised lesion should be biopsied because lesions typical of adenomas without dysplasia in either the surrounding area or other areas of the colon may be treated by polypectomy provided they occur in patients in an age group when polyps typically occur and they have no other risk factors for cancer. On the other hand, sessile lesions or those having evidence of dysplasia in the surrounding area require colectomy.<sup>14</sup>

**TABLE 34-2: DIFFERENTIATION OF ULCERATIVE COLITIS AND CROHN'S DISEASE**

	Crohn's Disease	Ulcerative Colitis
Lesions (early to severe disease)	Aphthous ulcers, stellate ulcers, serpiginous "bear claw" ulcers, cobblestoning	Loss of fine vascular markings, hyperemia friable, granular mucosa, occasional large ulcers surrounded by inflamed mucosa pseudopolyps
Distribution along colon	Patchy, skip lesions with intervening areas of normal mucosa	Continuous involvement throughout affected segments, cecal patch also possible
Rectal involvement	Usually spared	Usually involved with disease spread extending proximally
Perianal involvement	Anal skin tags, fissures, complicated fistulas, abscesses	Rare, uncomplicated fissures and fistulas may be present
Ileal involvement	Involvement in most cases	Occasionally backwash ileitis in pancolitis
Fistulization	Common, including: enterocutaneous, perianal, rectovaginal, enterovesicular	Rare

Strictures are also an important finding in chronic ulcerative colitis. Benign strictures may occur, but one must always be suspicious that they are malignant in nature and should be biopsied.<sup>9</sup>

## Serologic Markers

While in most cases ulcerative colitis can be readily differentiated from Crohn's disease, this may not be true if the disease is limited to the colon. The past two decades have witnessed a growing interest in the use of serum biomarkers to aid in the diagnosis and management of patients with IBD. The two most widely studied biomarkers include atypical perinuclear antineutrophil cytoplasm antibodies (pANCA) and anti-*Saccharomyces cerevisiae* antibodies (ASCAs). Their main clinical indication appears to be in the differentiation of ulcerative colitis from Crohn's disease. Atypical pANCA is present in approximately 70% of patients with ulcerative colitis but in

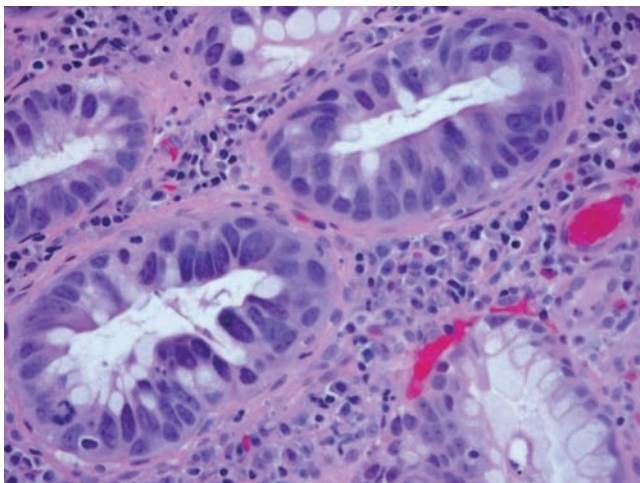


FIGURE 34-5 Histologic features of dysplasia.

only 20% of patients with Crohn's disease.<sup>15</sup> In contrast, the presence of IgG and IgA ASCAs has been demonstrated in 60–70% of patients with Crohn's disease but only 10–15% of patients with ulcerative colitis.<sup>16</sup> Combining the results of atypical pANCA and ASCA assays provides the most effective means of distinguishing ulcerative colitis from Crohn's disease, with most studies reporting a specificity of more than 90%. The pANCA<sup>+</sup>/ASCA<sup>-</sup> combination is specific for ulcerative colitis, whereas pANCA<sup>-</sup>/ASCA<sup>+</sup> is specific for Crohn's disease. However, the combined sensitivity of pANCA and ASCA is roughly 50%, which limits their use as a primary means of diagnosis.

New antiglycan (antichitobioside IgA, antilaminaribioside IgG, and antimannobioside IgG) and antimicrobial (anti-outer membrane porin C, anti-*Pseudomonas fluorescens* bacterial sequence I2, and anti-flagellin) antibodies have recently been developed. The advent of array technology has facilitated the combined study of these serologic markers, and early results suggest that they may have a greater capacity to distinguish between ulcerative colitis and Crohn's disease than the traditional combination of pANCA and ASCA.<sup>17</sup> Despite these technological advances, the role of serologic markers in current practice is limited to that of an adjunct in the clinical workup of patients with suspected IBD. Further studies are required to see if serologic markers will prove useful in predicting the course of IBD and its development in the relatives of affected individuals.

## MEDICAL MANAGEMENT

The spectrum of disease severity can range from mild to severe, and disease extent can vary from proctitis to pancolitis. Surgical involvement tends to be limited to cases where complications arise in acute severe disease, for example toxic megacolon and perforation, or chronic colitis unresponsive to medical therapy. Surgeons should have a broad understanding of the medical treatment options to help inform their decision making. The ability to discriminate between patients



requiring surgery and those that will respond to medical therapy is of paramount importance. Medical therapy should be targeted at controlling the underlying inflammatory process in order to induce remission. Prior to commencing therapy, a careful assessment of disease severity should be made, including a detailed history and physical examination in conjunction with endoscopic and radiologic findings. Treatment regimens should be based on both disease extent and severity. A tailored immunosuppressive regimen may be required to treat chronic active colitis and to maintain remission in the long term.

## Mild to Moderate Colitis

Mild to moderate colitis is often treated with 5-aminosalicylic acid (5-ASA) products. Topical application of 5-ASA or steroid products is recommended for the initial treatment of distal colitis.<sup>18</sup> Trial data suggest that 5-ASA preparations are superior to steroids with foams being better tolerated than enemas during flares of proctitis.<sup>19</sup> Disease extending to the splenic flexure warrants the addition of an oral 5-ASA agent in combination with topical therapy.<sup>20</sup> The minimum recommended duration of treatment to induce remission is 4 weeks.<sup>21</sup> For topically acting therapy, a dose of 1 g 5-ASA per day has been shown to be as effective as higher doses at achieving remission.<sup>22</sup> Typical oral maintenance doses range from 2 to 4 g/d. In more severe cases of left-sided colitis, the use of oral steroids should be considered, preferably in combination with a topical 5-ASA preparation.<sup>23</sup>

Pancolitis should initially be treated with oral 5-ASA therapy. If symptoms worsen or the disease becomes refractory to 5-ASA, oral steroids should be commenced. Most patients will respond to the addition of steroids, although a prolonged response will only be achieved in 50% after 1 year.

## Severe Colitis

Treatment of severe colitis with intravenous corticosteroids has been the mainstay of therapy for over 50 years. Optimal regimens include 400 mg of hydrocortisone per day<sup>24</sup> or 40–60 mg of methylprednisolone per day.<sup>25</sup> Infusions have been shown to be no more effective than bolus injections. Evidence suggests that 40% will achieve a complete response, although 30% will require colectomy during admission. In patients achieving a partial response to steroids, over 50% will come to colectomy in the next year and 70% within 5 years.<sup>26</sup>

If a treatment response is not observed within 3–5 days and there is no clear indication for surgery, rescue therapy with a daily cyclosporin infusion of 4 mg/kg<sup>27</sup> or a single infusion of infliximab (5 mg/kg) has been shown to be effective.<sup>28</sup> A comparison of cyclosporin and infliximab is currently the subject of a randomized controlled trial being undertaken in the United Kingdom (CONSTRUCT trial, ISRCTN 22663589). Anecdotal evidence suggests that a prolonged response to

rescue therapy can be achieved, allowing patients to avoid colectomy for several years. However, it appears that rescue therapy merely delays colectomy in the short term for the majority of patients. There may be some merit in this strategy as it allows surgery to be performed when patients are in better condition. Several case series report that tacrolimus is comparable to cyclosporin as a rescue therapy, but experience in its use is not widespread.

It is important not to overlook additional measures that can optimize patient management of severe colitis. Appropriate intravenous replacement of fluids and electrolytes is necessary to prevent dehydration and the harmful effects of electrolyte imbalance. Symptomatic anemia should also be corrected by blood transfusion. Malnutrition can be avoided by instituting feeding via the enteral or parenteral route. Enteral nutrition has been shown to be superior in reducing the rate of complications in acute colitis<sup>29</sup> although its use may be limited in the presence of ileus. A randomized controlled trial of bowel rest with parenteral nutrition has not been shown to alter outcome.<sup>30</sup> Subcutaneous heparin should be commenced on admission as severe colitis is a prothrombotic state. It is important to identify the presence of any superimposed enteric infections, namely *Clostridium difficile* and cytomegalovirus, with stool sampling or biopsy at endoscopy and then treat accordingly. There is no evidence to suggest that empirical treatment with antibiotics in severe colitis is beneficial. Agents that could potentially precipitate the effects of toxic megacolon, such as anticholinergics, anti-diarrheals, NSAIDs, and opiates, should be discontinued.

## MAINTENANCE OF REMISSION

Criteria for remission include the absence of diarrhea (less than three bowel movements per day), no visible blood in the stools, as well as no ulcerative colitis-associated intestinal or extraintestinal manifestations of disease.<sup>31</sup> First-line therapy is oral or topical 5-ASA. There is some evidence that the combination of oral and topical 5-ASA is superior to oral maintenance therapy alone.<sup>32</sup> Probiotic pathogen preparations have also shown similar clinical efficacy to standard 5-ASA preparations in maintaining remission.

In patients who are steroid-dependent or suffer with relapsing disease, azathioprine and its metabolite 6-mercaptopurine are effective at maintaining remission.<sup>33</sup> It is recommended that maintenance therapy should be continued for at least 3–5 years. Prior to commencing treatment with azathioprine, thiopurine methyltransferase levels should be checked, with monthly monitoring of the full blood count, renal and liver function thereafter. Development of leukopenia, thrombocytopenia, pancreatitis, or a gross derangement in transaminase levels are indications for the termination of treatment. In recent years, infliximab has been used increasingly as a therapeutic alternative to azathioprine. It is generally safe and well tolerated, although screening for tuberculosis is warranted prior to commencing therapy. The active colitis trials have demonstrated a rapid response with infliximab, although only 22% of patients will stay in remission without the use

of additional steroids.<sup>34</sup> Methotrexate may be considered in individual cases if infliximab is unavailable, although evidence for its use is limited to one small trial. The prolonged use of systemic steroids to maintain remission should not be encouraged because of their well-documented side effects.

## SURGICAL MANAGEMENT

### Indications for Surgery

The indications for surgery can be classified as those requiring emergent or urgent surgery and those where surgery is performed electively. Acute colitis and toxic megacolon often require urgent or emergent surgery. Massive hemorrhage and perforation are also indications for emergency surgery, but these complications are usually seen in association with acute colitis. Overall, the most common indication is failure of medical therapy. Other indications include stricture, dysplasia or cancer, and systemic complications.

### ACUTE COLITIS AND TOXIC MEGACOLON

Acute severe colitis, complicated by the presence of toxic megacolon, often requires early surgical intervention (Fig. 34-6). However, patients with acute colitis, without toxic megacolon, can be equally ill, and the risk of perforation is not closely correlated with the amount of colonic dilation. It is recommended that failure after a 24-hour trial of intensive medical therapy is an indication for urgent colectomy in patients with toxic megacolon.<sup>35</sup> The timing of surgery in patients with severe colitis who exhibit an incomplete response to medical therapy is less clear-cut. Joint involvement of gastroenterologists and surgeons at an early stage and frequent reassessment of patients is critical in making decisions about treatment as well as the timing of various interventions. It may also help

patients mentally prepare for the possibility of colectomy, especially if a trial of rescue therapy is being considered. Objective predictive indices, such as C-reactive protein (CRP) of greater than 45 mg/L and a stool frequency of eight per day on day 3, can be used to guide the timing of surgical intervention,<sup>36</sup> but they should also be interpreted in light of the clinical, radiologic, and endoscopic findings.

When toxic acute severe colitis is successfully treated non-operatively, approximately 50% of patients will require surgery within 1 year.<sup>37</sup> There are obvious advantages to attempting to settle the disease even if it means the patient will subsequently require surgery. On the other hand, acute colitis or toxic megacolon is still a life-threatening illness especially if a perforation occurs or the patient develops other septic complications. Thus, surgery should be performed immediately if there are any signs of peritonitis clinically, evidence of perforation, extreme dilation of the colon on CT scan, or if the patient fails to improve after several days of optimal medical management.

### PERFORATION

Acute perforation is an infrequent occurrence, with the risk directly related to both the extent of bowel disease and the severity of the acute attack of colitis. Although the overall risk of perforation during an attack is less than 4%, the risk may rise to about 10% if the attack is severe. Perforations occur more frequently in the presence of toxic megacolon, but it is important to remember that megacolon is not a prerequisite for the development of perforation. Thus, surgery should be considered early in patients with acute colitis who are not responding to medical treatment in order to prevent this complication because postoperative morbidity increases significantly if a perforation does occur. In the presence of a colonic perforation, subtotal colectomy with ileostomy is the procedure of choice.

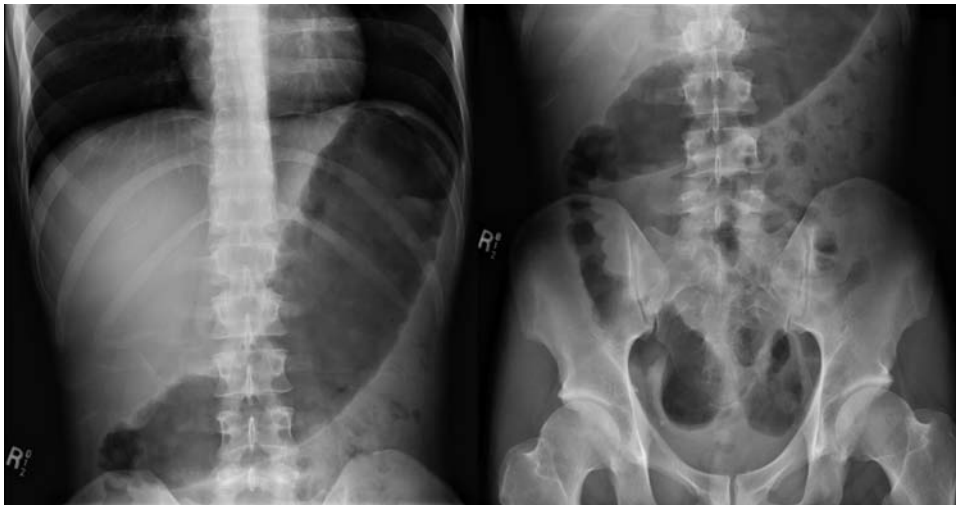

FIGURE 34-6 Toxic megacolon. Note the dilation of the transverse colon with loss of the haustral markings.

## HEMORRHAGE

Massive hemorrhage secondary to ulcerative colitis is rare, occurring in fewer than 1% of patients and accounting for about 10% of urgent colectomies performed for ulcerative colitis. Prompt surgical intervention is indicated after hemodynamic stabilization. Rarely is there one bleeding point. More often, there is diffuse bleeding from the severely inflamed mucosal surface of the bowel. Therefore, rarely is it necessary to perform a total proctocolectomy. Instead, a subtotal colectomy is usually the preferred option, because these patients tend to be very ill and a lesser operation that does not expose the patient to a potentially hazardous pelvic dissection is better tolerated. Also, preservation of the rectum allows the patient to have a reconstructive procedure in the future. With this approach, some patients may have continued bleeding from the retained rectal segment, but rarely will urgent proctectomy have to be performed. Again, it is important to emphasize that timely surgical intervention in patients with severe acute colitis should be considered because it may obviate this life-threatening complication.

## INTRACTABILITY

For most patients with ulcerative colitis, a colectomy is performed when the disease enters an intractable, chronic phase and becomes a physical and social burden to the patient. This end point is somewhat subjective and therefore requires discussion with the patient and family. Furthermore, the opinion of the gastroenterologist is equally important because he or she has usually followed the patient for a long time and has knowledge of the chronicity and severity of the symptoms as well as the response to medical therapy, whereas the surgeon is disadvantaged because he or she is seeing the patient only at one point in time. Thus, if the patient's disease is relatively settled at that time, he or she may not think that surgery is indicated when the pattern of disease has actually been characterized by frequent flare-ups or chronic symptoms.

Corticosteroids are still the mainstay of medical management of ulcerative colitis, and patients who are steroid-dependent or have quick flare-ups of the disease when the steroids are tapered should be advised to have surgery. The development of side effects of, or intolerance to, medications such as steroids, including diabetes, cataracts, and mood disorders, may also be an indication for surgery. The goal of treatment should not be preservation of the colon at all costs. Rather, the therapeutic option that will maximize the well-being, and the patient's quality of life should be chosen whether it is continuation of medical treatment or surgery. As stated previously, this is the most subjective indication for surgery and patients will vary in their preferences, and therefore it is important that they be fully informed about the risks and the outcomes that can be expected following surgery.

## DYSPLASIA AND CANCER

Colorectal cancer is the most serious long-term consequence of ulcerative colitis. The reported risk of colorectal cancer is

estimated to be 2% after 10 years, 8% after 20 years, and 18% after 30 years of the disease.<sup>38</sup>

Surveillance colonoscopy with targeted biopsies should be performed in individuals with long-standing disease. Prophylactic colectomy is not recommended. However, there are a few situations where colectomy may be performed where cancer or dysplasia is not confirmed. This includes patients with a long history of disease and multiple pseudopolyps where there is concern that it might be difficult to identify a cancer or pre-malignant lesion. Also, pseudopolyps, while benign and with no malignant potential, have been identified as a predictor of malignancy. Second, individuals who have a stricture generally should be advised to have surgery because it may be impossible to keep the rest of the colon under surveillance. Also, it may not be possible to ensure that the stricture is not malignant.

Recent studies have shown that raised lesions that have the endoscopic appearance of sporadic adenomas can be treated safely by polypectomy as long as there are no other areas of dysplasia.<sup>39</sup> However, colectomy is indicated when there is flat, high-grade dysplasia because the risk of cancer being present at the time of surgery is approximately 40%.<sup>14</sup> There is more controversy about the natural history of low-grade dysplasia. However, several studies have shown that the risk of a cancer being present at surgery may be as high as 15–20% and the risk of progression of these lesions over the next 5 years is in the similar range.<sup>40</sup> Also, because of the possibility of sampling error, repeat colonoscopy with negative biopsies may not be reassuring. Thus, most surgeons would recommend colectomy for individuals with low-grade dysplasia, the caveat being that the slides have been reviewed by an experienced GI pathologist. It is important to remember that the objective of screening is to identify and treat individuals before they develop cancer, not detect early cancer.

Because dysplasia is usually multifocal in ulcerative colitis, the entire colon and rectum should be removed. There is no role for segmental resection of dysplastic lesions or cancers.

## SURGERY FOR SYSTEMIC COMPLICATIONS

In occasional patients, surgery is indicated because of the severity of extraintestinal manifestations. However, more commonly if patients are suffering from severe extraintestinal manifestations, the intestinal disease is also active. This is often the case in patients with pyoderma gangrenosum and erythema nodosa. Others such as PSC, uveitis, and iritis are usually not improved by colectomy.

## GROWTH RETARDATION

Growth retardation may be an indication for surgery in the pediatric population. *Growth failure* is defined as a cessation of linear growth over a 6-month period or a decrease exceeding one or more standard deviations. There may be multiple causes of growth retardation, including inadequate intake, increased losses due to secretory diarrhea, and increased requirements because of associated sepsis or drug-nutrient interactions.



## Preoperative Evaluation and Management

If possible, one should try to optimize the patient's medical status and fully evaluate the gastrointestinal tract prior to undertaking surgery. This may not be possible because of the urgency of the condition or status of the underlying disease. However, even with emergency surgery, there are certain measures, such as correction of fluid and electrolyte abnormalities, administration of antibiotic and thromboembolic prophylaxis, and stoma marking that should be done. Thromboembolic prophylaxis is required because the risk of deep vein thrombosis and pulmonary embolism is increased in patients with IBD.<sup>40-42</sup> In randomized controlled trials, the risk of postoperative deep venous thrombosis, as measured by venography, may be as high as 10% even in those individuals receiving prophylaxis with unfractionated or low-molecular-weight heparin. However, the risk of symptomatic thromboembolic complications is approximately 0.5% if there is adequate prophylaxis.<sup>43</sup>

To the contrary, the need for a mechanical bowel preparation in patients undergoing colorectal resection has been challenged. A recent meta-analysis of almost 5000 patients showed that the anastomotic leak rate and surgical site infection rate were the same in patients in whom the mechanical bowel preparation was omitted compared to those who did receive a mechanical bowel preparation.<sup>44</sup>

Many patients having surgery will be on high doses of steroids or will have been on steroids for a prolonged period. Brown and Buie reviewed the literature and concluded that there is no evidence that supraphysiologic doses of corticosteroids are necessary to prevent hemodynamic instability or adrenal insufficiency in patients who have been on steroids preoperatively.<sup>45</sup> They recommended that patients should continue on the same dose of steroids throughout the perioperative period. Postoperatively steroids should be weaned slowly to avoid adrenal insufficiency, especially in individuals who have been on steroids for a prolonged period.

If possible, the nutritional status of the patient should be optimized. While there is little evidence to support a course of preoperative total parenteral nutrition (TPN), in some situations it may be worthwhile. Alternatively, if enteral feeds are tolerated, surgery may be delayed while the nutritional status of the severely malnourished patient is improved.

An ileostomy is frequently required in patients having surgery for ulcerative colitis. It may be permanent or temporary. Preoperative marking of the stoma is essential because how well the stoma functions may have a profound effect on outcome and the patient's acceptance of it. When a stoma is sited, it should be placed away from scars and creases and in a location where the patient can visualize it adequately when sitting or lying. If not, the patient may have difficulty changing the appliance. Both stoma placement and siting of incisions are extremely important in patients with ulcerative colitis. These patients will often require multiple operations, possibly require stoma revisions in the future, and may have significant weight gain or loss in the future. Thus, not only must the stoma be placed well initially but other sites, say in

the left lower quadrant, should be preserved. For this reason, midline incisions are preferred.

Serious cardiac and respiratory complications are unusual because most patients having surgery for ulcerative colitis are young. However, if there are associated medical conditions, they should be treated. Finally, patient education is an important aspect of surgical management. The patient should be prepared both physically and psychologically for surgery.

## SURGICAL OPTIONS

### Historical Perspective

Sigmoid colostomy was the first documented surgical procedure for ulcerative colitis. It was not until the 1940s when it became clear that the only definitively curative treatment of chronic ulcerative colitis is total proctocolectomy or, as a compromise, subtotal abdominal colectomy with ileostomy. However, the ileostomy was fraught with technical problems from the outset, including the optimal location of the ostomy site, surgical construction and attachment techniques, and leak proof collection pouches and skin barriers. All of these contributed to a high complication rate and patient dissatisfaction. It was not until the early 1950s when Brooke in the United Kingdom and Crile and Turnbull in the United States proposed that the ileal stoma could be immediately matured into the skin with primary mucocutaneous suturing.<sup>46,47</sup> This innovative procedure, coined the "Brooke ileostomy" (Fig. 34-7), when performed after a proctocolectomy, rapidly emerged as the surgical procedure of choice for ulcerative colitis and finally offered patients a curative operation with a reasonably manageable outcome.

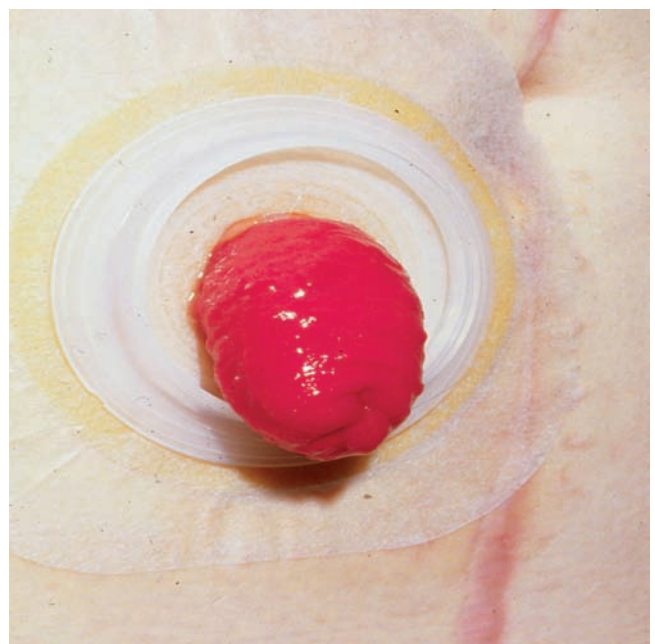


FIGURE 34-7 Ileostomy.

Perhaps the earliest attempt to promote a more functional and continent alternative to a permanent ileostomy was proposed by Stanley Aylett of the United Kingdom, who in the early 1950s began performing colectomy and IRA for ulcerative colitis.<sup>48</sup> Despite the fact that diseased mucosa remaining in the rectal segment clearly increased the risk of persistent symptoms and cancer of the rectum, he performed nearly 400 such procedures through the mid-1970s, with relatively satisfactory functional outcomes and a low cancer rate.<sup>49</sup> The next major advance in the surgical treatment of ulcerative colitis was the description of the continent ileostomy, or Kock pouch by Kock<sup>50</sup> in the late 1960s. It was his reasoning that a high-volume, low-pressure reservoir could be constructed and attached to the abdominal wall, which could be emptied using a catheter but otherwise would be continent. To make the reservoir, Kock initially described taking an isolated loop of small bowel that was divided at its antimesenteric border and folded into a U and closed side to side. However, continence was not maintained, and subsequently a valve made out of an intussuscepted segment of small bowel was interposed between the reservoir and the outlet. Patients then passed a tube through the flush stoma to empty the pouch. Patients searching for an alternative to a Brooke ileostomy enthusiastically received the Kock pouch. Although they still had a stoma, they did not have to wear an appliance. Unfortunately, the procedure is technically difficult and despite multiple technical revisions to the procedure, there is a high complication rate and need for reoperation. In addition, the patient still has a stoma, leading surgeons to seek other alternatives. Thus, in the early 1970s, Parks and Nicholls<sup>51</sup> and Utsunomiya et al<sup>52</sup> independently adopted the concept of the ileal reservoir that Kock had described and anastomosed it to the anal sphincter. Continence and stool frequency was acceptable, and the patients could evacuate via the normal route. In addition, following multiple technical changes, the procedure could be performed with relatively low morbidity, good functional results, improved quality of life, and patient satisfaction. Thus, the IPAA, ileoanal “pull-through” or restorative proctocolectomy, is currently the procedure of choice for most patients requiring surgery.

Currently, there are several options for patients requiring surgery for ulcerative colitis. Subtotal colectomy and ileostomy is often performed in patients requiring surgery urgently or emergently. The more definitive options include colectomy and IRA, total proctocolectomy and end ileostomy or Kock pouch, and IPAA. All have advantages and disadvantages, and the patient must be fully informed about the procedures, including the risks and functional results so that he or she may partake in the decision making. However, irrespective of the procedure, most patients following surgery have an improved quality of life.

## Subtotal Colectomy and Ileostomy

Subtotal colectomy and ileostomy is often performed as the first stage prior to a more definitive procedure. The most

common indication is in the emergency or urgent situation in patients with acute colitis. Even in patients with severe colitis, including those with severe bleeding, colectomy alone usually results in a dramatic clinical improvement without the morbidity associated with a potentially hazardous pelvic dissection. The inflammatory process may persist in the retained rectum, but it is usually not severe and requires no treatment or perhaps topical medical therapy. Proctocolectomy is only rarely indicated if there is profound hemorrhage from rectal ulceration. A second indication is in individuals with chronic disease who are malnourished and are on high doses of corticosteroids (the equivalent of 30 mg or more of prednisone/day). Finally, if there is uncertainty about whether the diagnosis is ulcerative colitis or Crohn's disease, by removing the colon first, a formal pathologic assessment of the specimen can be made and the rectal disease can be dealt with at a subsequent operation.

While subtotal colectomy is an excellent operation in these situations, it is not a definitive procedure, and unless there is a contraindication, proctectomy should be performed in the future as there is an ongoing risk of malignancy. A cancer may occur without symptoms until it is quite advanced. Surveillance of the rectum in the long term is usually inadequate.

## SURGICAL TECHNIQUE

After induction of general anesthesia with endotracheal intubation, patients are placed in the lithotomy position. The bladder should be catheterized. A midline incision provides wide access to the abdomen and does not compromise placement of a stoma on either side of the abdomen. Upon entering the abdomen, an exploratory laparotomy should be performed with particular attention to the terminal ileum to ensure that there is no disease because this would make one think the patient has Crohn's disease. Great care should be taken in the handling of the tissues as they may be extremely friable in severe disease or in cases of prolonged steroid use. This is especially true of the flexures where a walled off perforation may not be apparent. Mobilization usually begins with the right colon. In some patients, the flexures may be easier to mobilize owing to the shortening of the bowel seen in chronic disease. Care must be taken to protect the ureters, duodenum, and spleen. Our preference is to remove the omentum because preserving it may increase the risk of adhesional obstruction. Some surgeons preserve it, arguing that it may limit sepsis from an anastomotic leak in a subsequent IPAA.

The terminal ileum should be divided immediately proximal to the ileocecal valve to preserve bowel length if an IPAA will be performed at a later date. Our preference is to divide the colon in the distal sigmoid with preservation of the inferior mesenteric and superior rectal arteries, as it is easier to mobilize the rectum subsequently and decreases the risk of injury to the left ureter and sympathetic nerves. Perhaps the most important reason, though, is that it permits exteriorization of the rectal stump in patients with severe colitis. Breakdown of the rectal stump occurs infrequently but is the most significant complication following this procedure. In our own

series of patients, between 5 and 10% of patients experienced a blown rectal stump depending on the severity of the disease at surgery when the rectum was closed and left within the abdomen.<sup>53,54</sup> There is significant morbidity associated with a blown rectal stump, including development of a pelvic abscess or even generalized peritonitis. There are three options for handling the rectum including an exteriorized mucous fistula, closure of the rectum with exteriorization in the subcutaneous tissue, or Hartmann's procedure with placement of a 30F Foley catheter to decompress the stump. The decision about how to handle the rectal stump should be based on the severity of disease and the friability of the rectosigmoid at the time of surgery. An exteriorized mucous fistula is the safest method if the rectosigmoid is very friable but may continually drain a large volume of mucous and blood, necessitating the wearing of a second appliance. Closure of the rectum and its exteriorization in the subcutaneous tissue is often a good compromise in the presence of friable tissue, although outcomes have only been reported by a few centres.<sup>53,55,56</sup> In our own experience, one-third of patients with subcutaneous stump closure will go on to develop breakdown of the rectum with persistent drainage and possible wound infections.<sup>53</sup> However, serious intra-abdominal septic complications are avoided. The rectal stump may be stapled off in patients where the risk of a leak from the rectal stump is deemed to be small.

There is increasing evidence that laparoscopic subtotal colectomy, even in acute colitis, can be performed safely. Initially, a 12-mm port is inserted at the umbilicus, with ports then inserted in each of the four quadrants lateral to the rectus sheath. Mobilization of the colon from its peritoneal attachments is performed in much the same fashion as in the open approach. Retraction of the small bowel is facilitated by tilting of the operating table. Division of the mesocolic vessels is made close to the bowel wall and can be achieved intracorporeally with use of clips, vascular staplers, or an energy device. Mobilization of the transverse colon and division of the middle colic vessels may be difficult and tedious. Thus, the colon can be delivered through the umbilical port site, and division of the mesentery of the transverse colon can be completed extracorporeally. The terminal ileum and distal sigmoid colon can be divided using stapling devices and extracted through the umbilical site. Alternatively, the specimen can be extracted through a Pfannenstiel incision, through which a subsequent proctectomy can be performed or through the ileostomy site that may provide some additional cosmetic benefit.

Early concerns about the safety of the laparoscopic approach, particularly in cases of acute severe colitis, limited its introduction. Evidence is now emerging from specialist centers that laparoscopic subtotal colectomy is not only safe but may confer potential benefits in terms of postoperative recovery. However, many studies are limited by the inclusion of patients with noncolitic indications for colectomy. Several series have reported a reduced length of stay and time to bowel function, at the expense of an increase in operating time with the laparoscopic approach.<sup>54,57-59</sup> A few comparative observational studies have even suggested that time to

restorative proctocolectomy may be reduced by employing the laparoscopic approach to initial subtotal colectomy.<sup>60,61</sup> There are currently no randomized controlled trials comparing outcomes between the laparoscopic and open approaches, so the benefits reported in these studies should be viewed with caution in light of their inherent selection bias. Data on the late complications of laparoscopic subtotal colectomy, such as incisional herniation and small bowel obstruction, are lacking, which may reflect the fact that many of these patients go on to subsequent proctectomy within a few months of surgery.

## Colectomy and Ileorectal Anastomosis

Because ulcerative colitis almost always involves the rectum, there are limited indications for colectomy and ileorectal anastomosis (IRA). If there is sparing of the rectum, a colectomy and IRA may be preferred over IPAA because of the concern that the patient might have Crohn's rather than ulcerative colitis. However, this is an infrequent occurrence.

Patients may continue to suffer from symptoms of proctitis following surgery. They also continue to be at risk of developing dysplasia and cancer, so they require ongoing surveillance. On the other hand, the advantages to an IRA are that it avoids the risk of pelvic nerve injury and poor perineal wound healing. Generally, the procedure can be performed in one stage.

## SURGICAL TECHNIQUE

The extirpative phase of the operation is similar to that of colectomy and ileostomy. The superior hemorrhoidal vessels may be preserved if the anastomosis is performed in the distal sigmoid. More often, the anastomosis is performed at the level of the sacral promontory, and the superior hemorrhoidal vessels are divided. Our preference is to perform a hand-sewn anastomosis because usually the rectal wall is inflamed and the risk of a leak may be lower when a hand-sewn anastomosis is performed rather than a stapled anastomosis. The anastomosis may be performed either as an end-to-end or end-to-side anastomosis. Some suggest defunctioning the anastomosis with a loop ileostomy, but, in this era, if the anastomosis is that tenuous, another surgical option should be considered.

## Proctocolectomy and Ileostomy

The intestinal component of chronic ulcerative colitis is cured once the colon and rectum are removed. Therefore, total proctocolectomy with the Brooke ileostomy has historically been the operation of choice. The advantages of this procedure are the following: It can often be performed as a one-stage procedure, the disease is eliminated so patients no longer require medical therapy, and there is no longer the risk of developing a malignancy. The disadvantage is that individuals have a permanent ileostomy. Patients having surgery



for ulcerative colitis tend to be young, physically active, and single, so there may be social implications associated with a permanent stoma. While patients feel quite negatively about the prospect of having a stoma preoperatively, studies have consistently shown that most patients are accepting of an ileostomy and that their quality of life is very high postoperatively.<sup>62-64</sup> Only a very small proportion of patients have significant psychological problems dealing with the stoma.

In the modern era, total proctocolectomy is typically performed in older patients, in those with significant comorbidities or in those who are not candidates for IPAA. The latter includes patients with low rectal cancers, and those who have perianal disease, have had a prior anorectal surgery or a small bowel resection.

## SURGICAL TECHNIQUE

Total proctocolectomy can be performed either as a single-stage procedure, or in the two stages: subtotal colectomy followed by abdominoperineal resection of the rectum.

Patients are placed in the lithotomy position with the buttocks over the edge of the table. The buttocks should be taped apart and the anus sewn shut with a silk purse-string suture. A 1 L of saline bag may be placed under the sacrum to aid with exposure. The perineum should be widely prepped and draped. The vagina should be prepped to allow the surgeon to insert a finger into the vagina to guide the perineal dissection. Care should be taken to protect the peroneal nerves and avoid compression of the posterior compartments of the lower leg. Compartment syndrome after an extended period of time in lithotomy has been described. The arms should be tucked to the patient's sides and padded to protect the hands and forearms. A urinary catheter is mandatory to decompress the bladder. The use of a nasogastric tube is usually not necessary. The abdomen should be entered through a long midline incision, and the colectomy is performed as described previously. In this case, the inferior mesenteric vessels should be divided. A low ligation is preferred to minimize the likelihood of sympathetic nerve injury, unless dysplasia or a cancer was identified preoperatively.

The rectum is mobilized posteriorly in the plane between the fascia propria of the rectum and the presacral fascia posteriorly similar to that for a total mesorectal excision for rectal cancer. The plane is entered after ligating the superior hemorrhoidal/inferior mesenteric vessels. Care is taken to identify and protect the left ureter and the sympathetic nerves. The serosa covering the rectum is scored anteriorly and laterally on both sides. The dissection to the pelvic floor is carried out posteriorly first, extending laterally and then anteriorly. The dissection below the peritoneal reflection differs from that of a cancer operation in that the rectum is skeletonized of its mesorectum in order to reduce the risk of parasympathetic nerve injury. Anteriorly, the dissection is performed on the rectal side of Denonvilliers' fascia to avoid injury to the vagina or the seminal vesicles and prostate. Massive hemorrhage due to injury to the presacral or internal iliac vessels can occur during this part of the dissection, but it should be a rare event

as compared to when a more radical oncologic procedure is performed. Bleeding occurs due to misadventure when the wrong planes are entered posteriorly or laterally. Control of bleeding from the presacral veins can be particularly problematic as these vessels can retract into the sacrum and are not easily clamped or tied off. A suture ligature through the periosteum of the sacrum or a sterile tack nailed into the sacrum may be required. On rare occasions, tight packing of the pelvis with sponges may be required with removal of packs 24 to 48 hours later. Similarly, injuries to the vagina in women, or the urethra in men, are possible complications during pelvic and perineal dissection, but they occur rarely and are due to dissection in the wrong plane. Vaginal injuries can be repaired primarily whereas urethral injuries are best managed by a urologist.

Once the abdominal dissection is completed to the level of the levator muscles, the perineal dissection is performed. An intersphincteric dissection is preferred to a wide resection as performed in patients with rectal cancer unless a low-lying cancer is identified preoperatively. In so doing, the external sphincter and levator muscles are preserved. This minimizes the size of the perineal defect and decreases bleeding and wound complications. A solution of dilute epinephrine is injected into the intersphincteric plane to decrease bleeding and make the intersphincteric plane more obvious. The dissection begins posteriorly until the perineal and abdominal operators hand-touch, whereupon, guided by the abdominal operator with a hand in the pelvis posterior to the rectum, the perineal surgeon enters the pelvis just anterior to the tip of the coccyx with a pair of curved Mayo scissors. The perineal surgeon may then hook the levator muscles with a finger laterally in either direction and divide the muscles with electrocautery. Once the posterior and lateral dissection has been completed, the rectum can be brought out of the perineum to facilitate anterior dissection. Alternatively, the abdominal surgeon may direct the perineal surgeon as he or she passes scissors anteriorly between the rectum and the vagina or prostate into the abdominal cavity. Then the levator muscles may be divided laterally to complete the dissection. Once hemostasis is achieved, the pelvis is irrigated through the abdominal wound and drained through the perineal wound. A drain is placed in the pelvis through a separate incision in the abdominal wall to prevent accumulation of blood or serous fluid that may subsequently drain through the perineum. The skin may be closed or the perineum may be closed in layers, approximating the pelvic floor muscles and skin. Absorbable sutures are typically used in the skin.

An ileostomy is constructed in the right lower quadrant that has been marked preoperatively. In order to facilitate its construction, a high ligation of the ileocolic vessels may be performed. There is usually an avascular window approximately 15 cm in length between the ileocolic vessels and the superior mesenteric vessels. The mesentery of this segment of bowel can be narrowed so the bowel is supplied by a marginal artery running along its edge. The ileostomy should be brought out through the aperture so it is not under tension. The fascia and skin of the abdominal wall should then be

closed prior to maturation of the ileostomy. Also, before doing so, the mesentery can be sutured to the posterior abdominal wall to prevent an internal hernia. The ileostomy should be matured so it has a height of approximately 2 cm and it sits upright (see Fig. 43-7).

## Kock Pouch

Following total proctocolectomy, a Kock pouch or continent ileostomy may be constructed instead of a conventional ileostomy. The advantage of this operation is that it is a curative procedure that potentially offers improved quality of life because patients are continent and do not have to wear an appliance. The main disadvantage is that the procedure is technically challenging and therefore the complication rate is high. Most of the complications are valve related, and, if they do occur, patients generally require reoperation. Reported long-term failure rates are in the order of 10–40%.<sup>65–68</sup> The second disadvantage is that even though patients are continent, they still do not evacuate via the normal route and must insert a tube to empty the pouch. For both of these reasons, the Kock pouch has been rarely performed since the introduction of IPAA. The main indication now is in patients who have already undergone a total proctocolectomy and ileostomy and thus are not candidates for an IPAA. Also, individuals who have had a failed IPAA or who have anal disease may be candidates.

## SURGICAL TECHNIQUE

The Kock pouch can be constructed following extirpation of the colon and rectum as described previously or, alternatively, it can be constructed at a later date with takedown of the conventional ileostomy.

The reservoir is made from two or three limbs of small bowel. Although the initial description was that of a two-limb pouch, a three-limb pouch is usually performed now. Approximately 55 cm of terminal ileum is used to construct the continent ileostomy: a 5- to 10-cm segment for the outlet, 15-cm for the nipple valve, and 30-cm for the reservoir itself. The reservoir is constructed by suturing the three 10-cm limbs of small bowel to form the posterior wall of the reservoir. Then the 15-cm segment of small bowel is intussuscepted to form the nipple valve. The valve is maintained by stapling the intussuscepted segment with three firings of the GIA 80-mm stapler, two of those firings being on either side of the mesentery. Then the anterior wall of the reservoir is suture-closed. Because of the problems of slippage of the valve, the valve can be stabilized with several maneuvers, including a sling of fascia or soft mesh through the mesentery and around the fundus of the pouch.<sup>69–71</sup> This anchors the pouch to the posterior wall of the abdomen and provides support for the mesentery of the small bowel that forms the nipple valve. Other maneuvers include defatting the mesentery or stapling the valve to the wall of the pouch.<sup>71</sup> All of these have been used by proponents, but unfortunately valve

slippage continues to be a significant complication. Of all the maneuvers, insertion of a mesh is most effective, but it is at the expense of fistula formation from erosion of the mesh into the fundus of the pouch.

Once the pouch is completed, the outlet can be brought up through an aperture low in the abdomen and sutured to the fascia of the anterior abdominal wall. Then the stoma is matured flush with the skin. A catheter is inserted to ensure that it can be passed easily. It is usually left in situ for 2–3 weeks until the pouch has become fully adherent to the abdominal wall (Fig. 34-8).

## Ileal-Pouch Anal Anastomosis

Ileal-pouch anal anastomosis (IPAA) is the procedure of choice for most patients requiring surgery for ulcerative colitis. Its major advantage over other procedures is that the normal route of evacuation is maintained and a permanent ileostomy is avoided. The reported outcome is also satisfactory in patients who have indeterminate colitis, but Crohn's disease is generally considered a contraindication.<sup>72,73</sup> Regimbeau and colleagues reported a low failure rate of 10% in a series of 41 patients who had an IPAA constructed for Crohn's disease, but most other series report failure rates up to 50%.<sup>74</sup> Furthermore, there do not appear to be any factors that predict which patients will have a good outcome.<sup>72</sup>

Because IPAA can now be performed safely with relatively few complications, there are fewer relative contraindications. IPAA may be performed in older patients although functional results tend to worsen with age.<sup>75</sup> Thus, individuals older than 60 years should be fully informed of all options, particularly total proctocolectomy and ileostomy. While most patients dread the thought of having an ileostomy when they are considering surgical options, in reality quality of life tends to be excellent with an ileostomy and most patients adjust well to it. A decision whether to perform an IPAA should be based on the age and comorbidities of the patient as well as the status of the anal sphincter. Perianal disease is usually a contraindication because of the concern that the patient may have Crohn's disease, as well as concerns about healing. However, IPAA may be considered in selected patients provided the anal disease can be eradicated prior to performing IPAA without compromising the sphincter.<sup>76</sup>

Patients with cancer may also be considered for IPAA provided the oncologic operation is not compromised. Thus, while IPAA may be a satisfactory option for patients with colon cancer, patients with low rectal cancers or those requiring neoadjuvant or postoperative radiation generally are not candidates. Furthermore, patients who do not have a confirmed cancer in the rectum but have high-grade dysplasia also should not have IPAA because of the high probability that cancer is in fact present and it may be inadequately excised. Although there are a limited number of reports, most patients who have a pouch and have had pre- or postoperative radiation have poor functional results and often lose the pouch. Last, patients with advanced disease should probably undergo

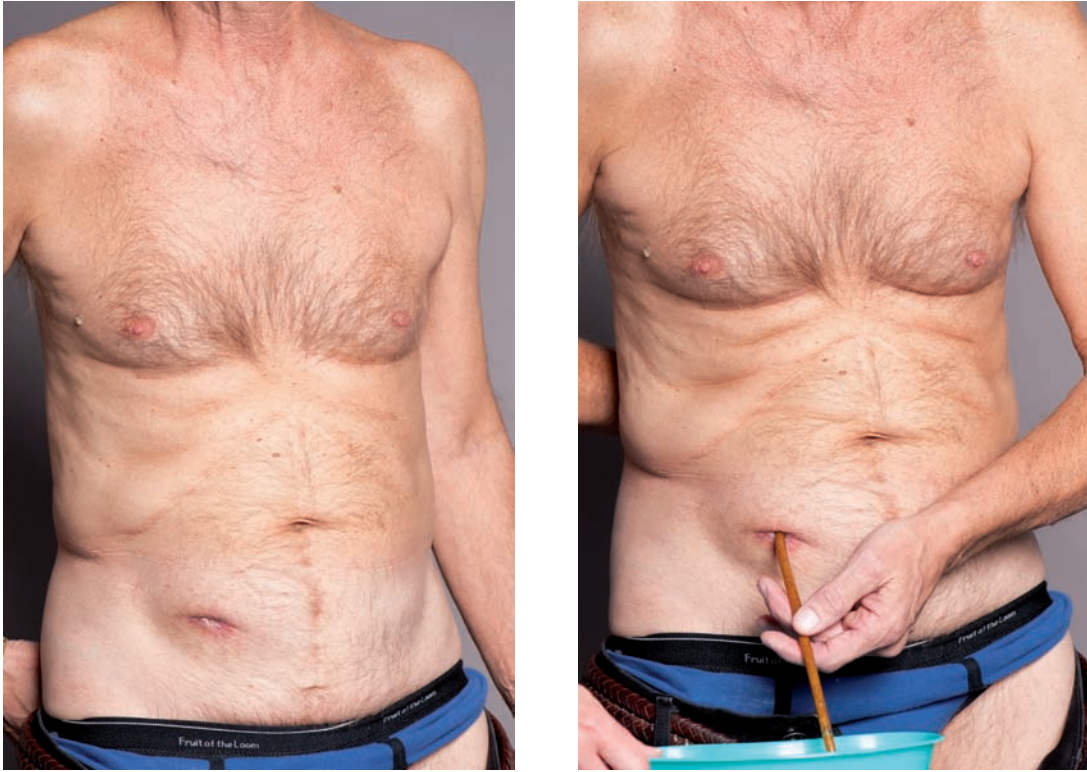

FIGURE 34-8 The stoma of a Kock pouch is made flush with the skin. A tube is inserted into the pouch to empty it.

one of the other less complicated surgical options such as subtotal colectomy or total proctocolectomy. Depending on the site of the cancer, colectomy may be a good alternative because it can be performed with low morbidity and in the future an IPAA could be considered if the patient survives.

### SURGICAL TECHNIQUE

Various modifications to IPAA have been described since it was initially introduced and there still is some variability in how the procedure is performed. First, the procedure can be performed in one, two, or three stages. A one stage operation (removal of the colon and rectum and construction of the pouch without a defunctioning ileostomy) is generally not performed because the reported ileoanal anastomotic leak rate is high. However, several authors have reported acceptable results with this surgical approach.<sup>77-79</sup> Generally, though, a one-stage procedure should not be performed by the inexperienced surgeon or in patients who are in suboptimal condition.

Two-stage procedures can be performed as colectomy, IPAA construction and a defunctioning ileostomy initially followed by closure of the ileostomy at a later date. Alternatively, a subtotal colectomy can be performed first, and at a subsequent procedure a proctectomy can be performed with construction of a pouch. Then, the defunctioning ileostomy can be omitted (two-stage procedure) or can be performed (three-stage procedure).

Our preference is to perform a two-stage procedure. In patients who require surgery urgently for acute colitis or are in suboptimal condition caused by poor nutritional status or are on more than the equivalent of 30 mg of prednisone per day, a subtotal colectomy is usually performed. At a second operation we would plan to do a proctectomy and construct the pouch without constructing an ileostomy unless there were intraoperative complications, the pelvic dissection was particularly difficult with significant blood loss, there was tension on the ileoanal anastomosis (IAA), or the IAA was incomplete. Patients who have surgery electively usually have a two-stage procedure also, but this includes proctocolectomy, pouch construction, and a defunctioning ileostomy. After 3–4 months, the ileostomy is closed after a Hypaque study has shown that the IAA and pouch are intact.

Several pouch configurations have been described, including J-, S-, and W-shaped pouches.<sup>80</sup> The J-pouch is the preferred type as it is technically easier to create and can be fashioned using a linear stapler. W-pouches are advocated because of their increased reservoir capacity, but this effect is seen only initially; long-term studies have shown no difference in bowel function between pouch types. S-pouches tend to be tedious to construct as they must be hand-sewn, but they are preferred when a hand-sewn IAA is required as they provide more length to reach the anal canal, the pouch fits through the canal easier, and the configuration allows for an end-to-end IAA.



The last area of controversy is whether the IAA should be hand-sewn or stapled.<sup>81,82</sup> Although mucosectomy and hand-sewn anastomosis was the technique described in the first descriptions, stapled anastomosis is now the preferred method. It is technically easier and quicker. Performing a hand-sewn IAA is usually more difficult, especially in obese individuals, because the pouch may be under tension. This is rarely the case if the anastomosis is stapled. Functional results also tend to be better with a stapled IAA. On the other hand, a few centimeters of rectal mucosa remain if the anastomosis is stapled and thus the disease is not eliminated. Concern has been raised over the risk of ongoing inflammation or cancer developing in the rectal remnant. In fact, even if a mucosectomy is performed, the disease is not completely eradicated and there have been a few reported cases of cancer arising after mucosectomy.<sup>83</sup> Ongoing inflammation requiring treatment is a rare occurrence.<sup>84</sup> Thus, it is our preference to perform a stapled IAA unless the patient has a cancer or dysplasia elsewhere in the colon and, if so, then perform a mucosectomy and hand-sewn IAA if it is technically possible.

### SURGICAL TECHNIQUE—OPEN IPAA

IPAA surgery can be divided into two phases: extirpative and reconstructive. The colonic and rectal dissection is performed similar to the abdominal dissection performed for total proctocolectomy. If a stapled IAA is planned, a 30-mm transverse linear cutting stapler can be used to staple off the rectum at the level of the levator muscles. The intent is to leave 1–2 cm of rectal mucosa. If a hand-sewn anastomosis is planned, the rectum can be divided at this level.

Some surgeons preserve the ileocolic vessels and divide one of the arcades to increase the length of the mesentery, but this is not necessary in our experience.<sup>85</sup> Rather, it is our preference to divide the ileocolic vessels close to their takeoff from the superior mesenteric vessels. That will add a few centimeters of length to bring the pouch down to form the IAA. The terminal ileum is divided with a linear stapler just proximal to the ileocecal valve.

The reconstructive phase of IPAA begins with full mobilization of the small bowel. If the patient had a subtotal colectomy previously, this begins with takedown of the patient's end ileostomy. The distal 1–2 cm of the ileum is resected with a linear stapler. At our center, this staple line is oversewn with 3-0 absorbable suture in a Lembert fashion, as leaks from the staple line have occurred. All adhesions between loops of small bowel are divided, and the mesentery of the small bowel is mobilized up to the level of the duodenum. If the IAA is stapled, "length" is usually not a concern, but, if a mucosectomy and hand-sewn anastomosis is performed, the small bowel mesentery must be fully mobilized back to the duodenum. Some authors have recommended scoring the peritoneum, but, if this is done, there is a risk of tearing the mesentery and vessels if there is tension on the mesentery when the small bowel is brought down to the pelvis to construct the IAA.

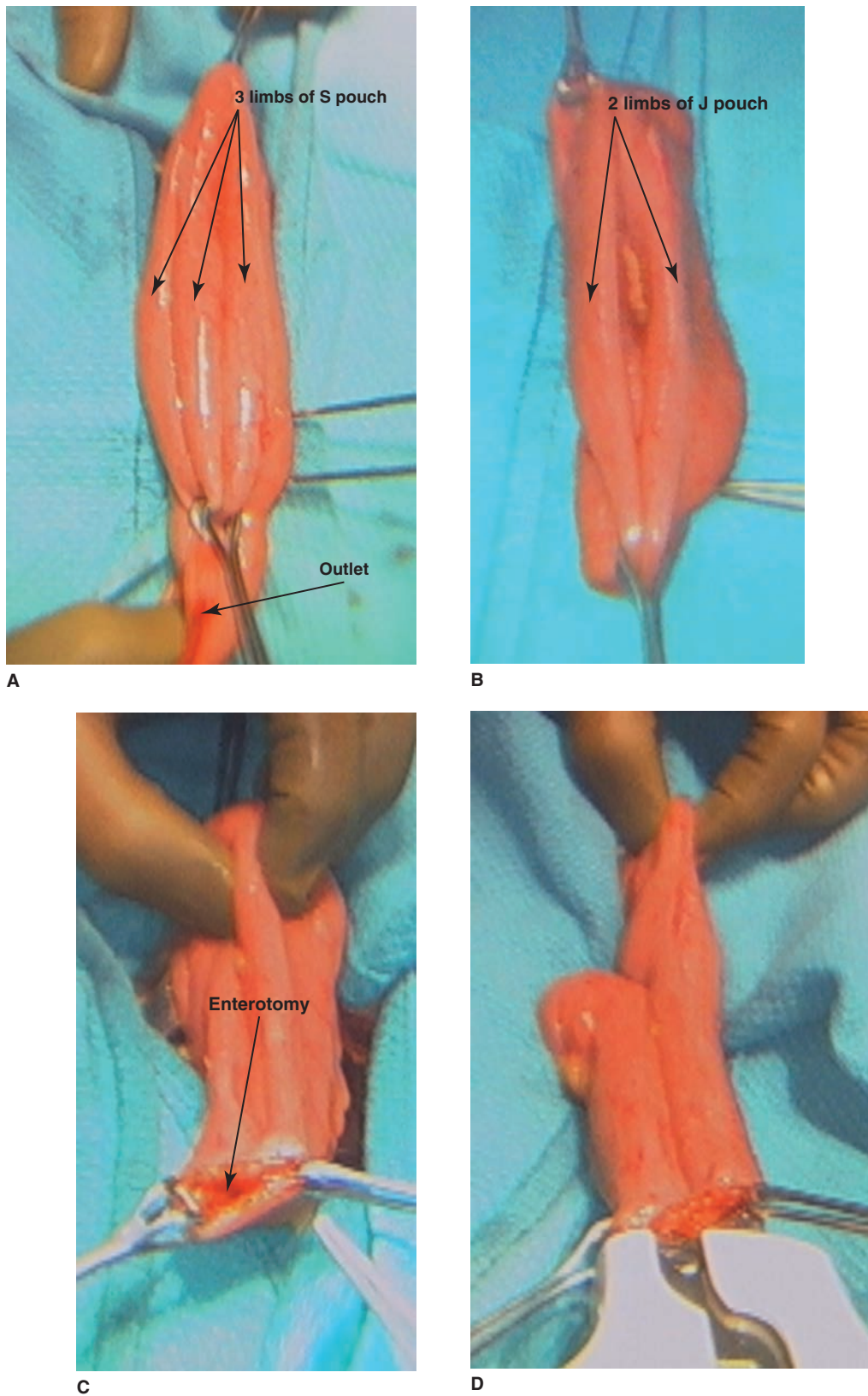
Next, the ileal pouch is fashioned (Fig. 34-9). Before doing so, the bowel should be assessed to see if it will reach

the anus. Generally, if the small bowel mesentery in the line of the superior mesenteric vessels stretches beyond the pubic symphysis, it should be adequate to perform a stapled IAA. To construct a J-pouch, the terminal ileum is folded over on itself creating two limbs approximately 15 cm long. Our preference is to orient the pouch so the mesentery lies on the right side somewhat anteriorly and the pouch lies in the hollow of the sacrum with the afferent limb of small bowel entering the pouch on the left side of the pouch. An enterotomy is made on the antimesenteric aspect of the apex of this fold, and two passes of an 80-mm linear stapler are used to create the pouch. A 2-0 polypropylene purse-string suture is placed at the enterotomy to secure the endoanal stapler anvil in place, and a double-staple IAA is constructed using a 28-mm circular stapler. The anvil in the pouch is attached, and the stapler is closed with care not to incorporate adjacent tissue, such as the vagina in women, into the staple line. The orientation of the pouch is confirmed, and the stapler is fired and removed. The proximal and distal tissue donuts are inspected for size and continuity. The pouch is then tested for a leak by advancing a 30F rectal tube into the pouch through the anus. A rectal tube is inserted and secured in place if no ileostomy is constructed and the abdomen is then closed. Otherwise, an ileostomy is brought up through an aperture in the right lower quadrant. Typically the ileostomy is constructed approximately 30 cm proximal to the pouch but varies depending on several factors, the most significant being the weight of the patient.

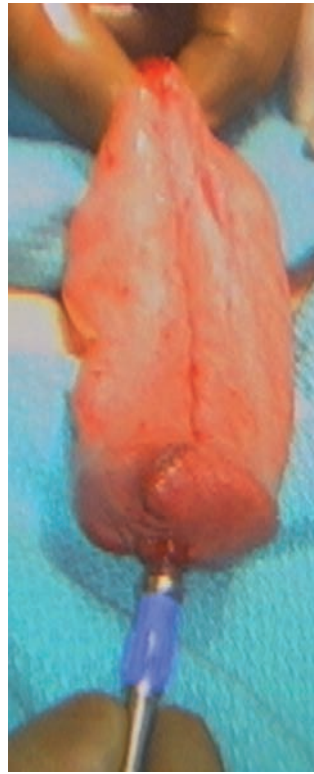If a hand-sewn anastomosis is planned preoperatively, the buttocks are taped apart to facilitate access. A Lone Star retractor (CooperSurgical, Inc., Trumbull, CT) is placed at the dentate line to draw the rectal mucosa into the anal canal. A solution of dilute epinephrine is injected submucosally, and the mucosectomy is performed with Metzenbaum scissors or electrocautery starting at the top of the dentate line. Our preference in this situation is to construct an S-shaped pouch that is performed by leaving a 1- to 2-cm outlet and then suturing three limbs of approximately 10 cm of small bowel together. A Babcock clamp is inserted through the anus to grasp the pouch, and the pouch outlet is brought through the anal canal to the anus. This can be difficult, and having two experienced surgeons, one guiding the pouch from above and the second one as the perineal operator, is advantageous during this short but critical part of the operation. Once the pouch is positioned in the pelvis, the stapled end of the S-pouch can be excised or an enterotomy at the apex of the J-pouch can be made and a hand-sewn anastomosis between the ileal pouch and the dentate line can be completed using interrupted 2-0 absorbable sutures beginning with sutures placed in the anterior, posterior, and either lateral position, and then circumferentially until the anastomosis is complete.

### SURGICAL TECHNIQUE—LAPAROSCOPIC IPAA

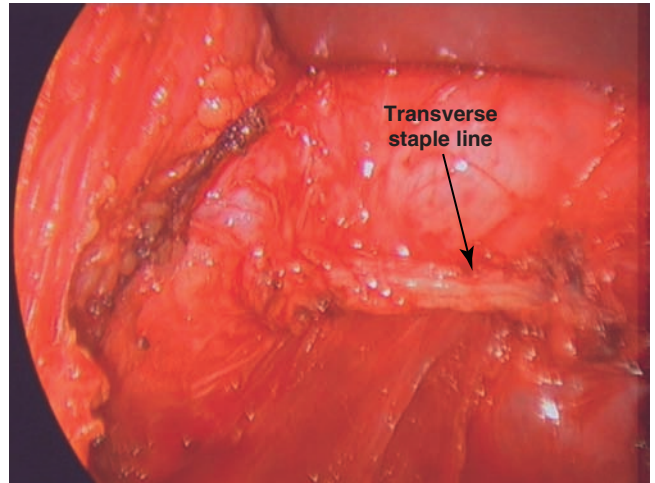
Evidence regarding outcome following laparoscopic IPAA is more widespread than for subtotal colectomy. Laparoscopic IPAA appears to confer similar short-term advantages as



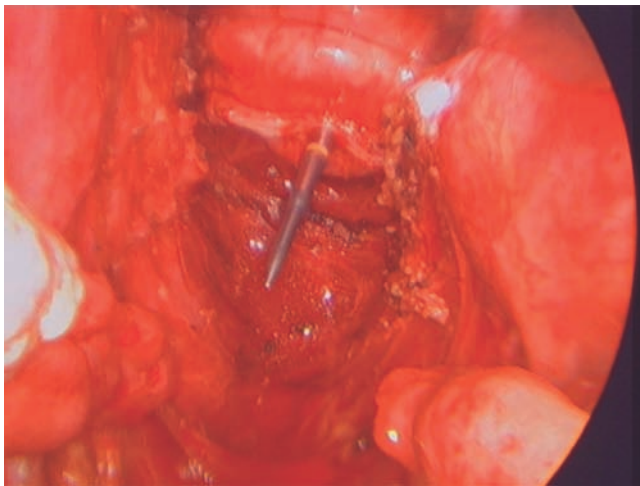
**FIGURE 34-9** **A.** S pouch is constructed from 3 limbs of small bowel each approximately 10 cm in length. The outlet should be approximately 1–2 cm in length. **B.** J pouch is constructed with 2 limbs of terminal ileum each approximately 15 cm in length. **C.** An enterotomy is made at the apex of the J pouch. **D.** Two passes of an 8 cm linear stapler is passed through the apex of the J pouch to construct the pouch.



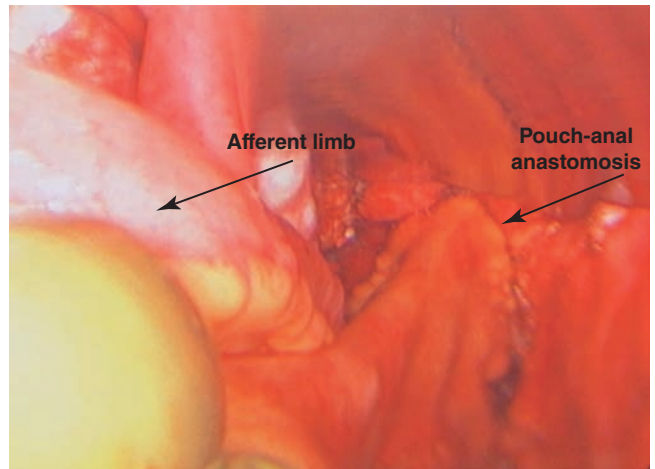
E



F



G



H

**FIGURE 34-9** **E.** The anvil of a 28-mm circular stapler is inserted into the J pouch and held in place with a purse string suture. **F.** A transverse stapler is used to staple the rectum at the top of the anorectal ring. The rectum is then divided so approximately 1–2 cm of rectum is left. **G.** The circular stapler is passed through the rectum and the anvil is opened and the center peg pierces the stapled rectum. **H.** The anastomosis is completed and then checked for an air leak. Note the afferent limb coming down into the pelvis on the lefthand side of the pouch.



laparoscopic subtotal colectomy, with a reduction in length of stay, blood loss, and return of bowel function being reported by several large case-matched series.<sup>86,87</sup> Only one randomized controlled trial has been published to date and this showed that laparoscopic proctocolectomy and ileal anal-pouch anastomosis took 77 minutes longer.<sup>88</sup> No differences in length of stay, morbidity, or long-term functional outcome were demonstrated in this trial, although higher body image and cosmesis scores were reported in the laparoscopic arm.<sup>89</sup> Laparoscopic surgery has been associated with a reduced tendency to adhesion formation,<sup>90</sup> but there are insufficient long-term follow-up data to determine whether there will be a subsequent reduction in the incidence of small bowel obstruction in patients undergoing restorative proctocolectomy. The risk of infertility in women may be decreased with the laparoscopic approach. A marked increase in operating time appears to be a universal finding as surgeons seek to overcome their learning curve with this procedure.

The colectomy is performed as described previously. The vascular supply of the colon is best divided intracorporeally. Similarly, the rectal dissection is performed in the same fashion as the open approach with dissection in the mesorectal plane above the peritoneal reflection and close to the rectal wall below it, continuing to the level of the levators. The rectum is divided at the pelvic floor, 1–2 cm above the dentate line, with a 30-mm stapler.

Our preference is to make a Pfannenstiel incision for the extraction site. If necessary, dissection of the lower rectum can also be completed through this incision. Also, it allows for better positioning of the transverse linear stapler on the rectum. The pouch is fashioned extracorporeally, and the IAA is constructed using the double-stapled technique. Care must be taken to ensure that the mesentery of the pouch is oriented correctly without any twisting. Indications for defunctioning the IPAA are the same as for the open procedure.

The technical complexity of laparoscopic subtotal colectomy and IPAA has renewed focus on the potential benefits of the hand-assisted technique. Recent studies have demonstrated that the hand-assisted technique significantly reduces operating times in restorative proctocolectomy without compromising short-term outcomes.<sup>91,92</sup> A longer incision is usually required to permit manual access, and this has raised concerns about subjecting the abdominal viscera to excessive trauma.<sup>93</sup> It is not clear whether the hand-assisted technique actually maintains the true minimally invasive characteristics of straight laparoscopic surgery, as it may provoke a more dramatic inflammatory response. Data are lacking on the long-term outcomes between the two techniques, although early reports suggest that there is no difference in the rate of incisional herniation and small bowel obstruction.<sup>94</sup> A more selective approach to the use of the hand-assisted or straight laparoscopic technique may eventually develop. For example, a troublesome colonic mobilization may be facilitated by the use of a hand port, whereas a more straightforward case could be continued using the straight laparoscopic technique.

## Complications of Surgery

### SMALL BOWEL OBSTRUCTION

Intra-abdominal adhesions develop in virtually all patients undergoing major abdominal and pelvic procedures. Although adhesions do have beneficial effects, they are also the primary cause of small bowel obstruction after abdominal surgery. Patients who have a total extirpation of the colon and rectum are at particularly high risk for the development of small bowel obstruction, possibly because of the combined abdominal and pelvic dissection, and sometimes need for multiple operations.

In patients having IPAA, the reported cumulative risk of small bowel obstruction ranges from 12 to 35% with follow-ups of 2.5–68 months.<sup>95</sup> The risk of small bowel obstruction was 8.7% at 30 days, 18.1% at 1 year, 26.7% at 5 years, and 31.4% at 10 years in our own series. However, most patients did not require reoperation. The reoperative rate was 2.7% at 1 year, 6.7% at 5 years, and 7.5% at 10 years. For patients requiring surgery, the most common sites of the obstruction were pelvic adhesions in approximately a third and the ileostomy closure site in 21%. The risk factors for developing a late small bowel obstruction were a previous diverting ileostomy and pouch reconstruction.

Because of the importance of the problem, various strategies have been tried. Beck and colleagues reported on 183 patients who had a barrier substance (Seprafilm) inserted at the time of construction of the pouch.<sup>96</sup> A significantly smaller proportion of patients in the Seprafilm group had adhesions to the abdominal wall (49 vs 94%). However, the rate of septic complication rate was significantly higher (13.5 vs 5.1%,  $p < .001$ ) when Seprafilm was placed around the anastomosis.<sup>96</sup> Subsequently, in a larger study that included over 1700 patients, these authors reported that the rate of small bowel obstruction was not decreased as a result of Seprafilm use, although significantly fewer patients required surgery for small bowel obstruction over a 5-year follow-up period (1.8 vs 3.4%,  $p < .05$ ).<sup>97</sup>

A laparoscopic approach to surgery is thought to result in decreased adhesion formation and a lower risk of subsequent small bowel obstruction. Indar et al reported on a series of patients who had undergone laparoscopic IPAA and found that the majority (68%) had no adhesions to the abdominal wall and 71% of women had no adnexal adhesions.<sup>98</sup> The long-term effect on the incidence of small bowel obstructions remains to be demonstrated.

### ILEOSTOMY COMPLICATIONS

Complications related to the ileostomy occur frequently. A wide range of complications may occur and they may occur immediately after surgery as well as later in follow-up (Table 34-3). Many can be dealt with nonoperatively. An experienced enterostomal nurse is essential to provide education to the patient and handle skin problems, including those related to irritation, allergies, and yeast infections. In addition, he

**TABLE 34-3: ILEOSTOMY COMPLICATIONS**

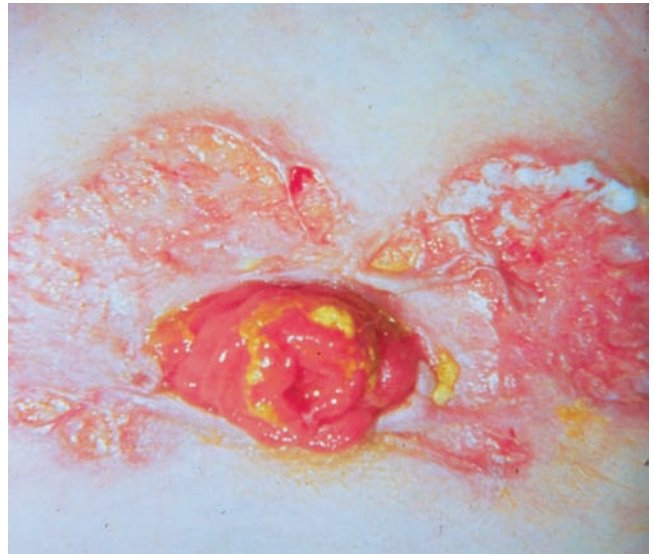
Early Complications	Late Complications
Bleeding	Skin irritation
Ischemia/necrosis	Parastomal ulcers and abscesses
Mucocutaneous separation	High ileostomy outputs
	Stricture
	Fistulas
	Retraction
	Prolapse
	Peristomal hernia

or she can advise on appliance-related problems. A well-constructed stoma is essential as quality of life is directly correlated with the function of the stoma.<sup>99</sup>

Complications are frequent occurrences in patients with loop ileostomies performed to defunction IAA. Approximately one-third of patients will experience high ileostomy outputs. In most instances, this complication can be managed with dietary modifications and antidiarrheal agents such as loperamide and/or codeine. If the outputs remain high, intravenous fluid supplements may have to be given on a regular basis until the ileostomy is closed. Feinberg and colleagues reported that approximately 20% of patients required hospital admission for dehydration.<sup>100</sup> Occasionally the ileostomy has to be closed early.

Closure of the loop ileostomy is also associated with a relatively high risk of complications, the most significant of which is an anastomotic leak.<sup>100–102</sup> Delaying closure for several months may decrease the difficulty of mobilizing the bowel and decrease the risk of complications. The high complication rate related to the ileostomy has led some surgeons to question the need for an ileostomy. However, the morbidity of a loop ileostomy must be balanced against the potential morbidity of a leak if the pouch is not protected.

Patients who have permanent ileostomies may suffer from problems such as retraction, prolapse, and parastomal hernia. Approximately 10–20% of patients will require revision of their stoma after ten to 20 years of follow-up. Parastomal hernia is caused by enlargement of the stomal aperture. It is seen more frequently in obese patients. If the patient is asymptomatic, no treatment is required. If, however, the patient has problems with retraction of the stoma, difficulty maintaining an appliance, or recurrent small bowel obstructions, surgery may be required. A number of options are available. Local repair of the hernia performed by tightening the fascia is usually unsuccessful. Thus, the recommended treatment has been resiting of the stoma to another location. However, more recently various repairs, performed either open or laparoscopically, have been described where mesh is inserted to repair the defect. Promising results have been reported although most series are small and have short follow-up. It is a difficult problem because the risk factors that led to



**FIGURE 34-10** Pyoderma gangrenosum affecting the peristomal region.

the hernia initially are usually still present and therefore the recurrence rate is high.

Peristomal ulcers and fistulas occur more commonly in Crohn's disease than in ulcerative colitis. Often, it is a signal that the patient has recurrent disease in the prestomal small bowel. Thus, if a fistula occurs in a patient who is presumed to have ulcerative colitis, one should be suspicious that the diagnosis is incorrect and the small bowel should be examined for signs of Crohn's disease. On the other hand, pyoderma gangrenosa is seen more frequently in patients with ulcerative colitis (Fig. 34-10). Because pyoderma is related to disease activity, it may occur following subtotal colectomy in patients whose rectum has been left in situ. If so, proctectomy should be performed as well as resiting of the ileostomy.

### PERINEAL COMPLICATIONS

Minor wound infections, defined as wound dehiscence of less than two cm in length, stitch abscesses, or sinus tracts have been found to occur in as many as 45% of IBD patients undergoing resection.<sup>103</sup> Major complications, including wound failures of more than 2 cm in length, perineal abscesses, or any wound complication requiring readmission or reoperation, occur in as many as 8% of IBD patients undergoing resection. Perineal wound infections and/or dehiscence leads to prolonged and/or delayed healing of the wound, and, in some cases, nonhealing.

Approximately 10–20% patients may have chronic perineal sinuses, defined as a perineal wound that fails to heal by 6 months following surgery. In many cases, it may be relatively asymptomatic and then nothing may need to be done. Management of symptomatic chronic perineal sinuses can be extremely challenging and may require repeated debridement

under anesthesia with multiple dressing changes, including the use of vacuum-assisted closure techniques and even flap closure for larger, more complicated wounds.<sup>104,105</sup>

## GENITOURINARY DYSFUNCTION

Genitourinary dysfunction is not an infrequent complication of pelvic surgery. The cause is probably multifactorial. It is likely due to both physical and psychological factors. Injury to the sympathetic and parasympathetic nerves may occur during the pelvic dissection. Several maneuvers should be performed to minimize the risk, including ligation of the inferior mesenteric vessels beyond the takeoff of the left colic vessels, ensuring that the dissection is in the plane of the fascia propria of the rectum at the sacral promontory and close dissection of the mesorectum at and below the level of the peritoneal reflection. Retrograde ejaculation is due to injury to the sympathetic nerves whereas impotence is a result of injury to the parasympathetic nerves. Both may occur temporarily or permanently and partially or totally. Referral to a urologist with appropriate urodynamic testing is indicated if dysfunction persists. The reported rates for impotence and retrograde ejaculation are less than 5%. However, most studies do not use validated instruments to assess sexual dysfunction. Davies et al reported on a cohort of 59 male patients who were assessed prospectively before and again after having IPAA using a validated instrument.<sup>106</sup> They found that male sexual function and erectile function scores remained high 12 months following surgery (mean International Index of Erectile Function score 51.7 preoperatively versus 58.3 at 12 months postoperatively). Furthermore, the prevalence of abnormal sexual function decreased from 33.3% before to 22.7% after surgery.

It is only recently female sexual function following pelvic surgery has been assessed. Bambrick and colleagues reported that women reported a significant increase in vaginal dryness, dyspareunia, pain interfering with sexual pleasure and limitation of sexual activity because of concerns of stool leakage following IPAA.<sup>107</sup> On the other hand, there was no significant change in sexual desire, frequency of sexual intercourse or satisfaction of sexual relationship. The findings are interesting although, due to the sensitive nature of the questions, the response rate was only 35% so the results may be biased. In a recent prospective study by Davies et al, approximately 70% of female patients were found to have scores indicating sexual dysfunction preoperatively using a validated instrument, the IIEF.<sup>106</sup> Postoperatively, there was a significant improvement with only 26% reporting sexual dysfunction 6 months following surgery. Improved overall physical well-being after surgery has been suggested as the reason for the improvement.

## Infertility

It is becoming more evident that female fertility is reduced following surgery for ulcerative colitis although it varies with the operative procedure. Oresland and colleagues performed hysterosalpingograms on 20 women who had had a total

proctocolectomy and found occlusion of one or both of the tubes in 18.3%.<sup>108</sup> Olsen and colleagues reported on 343 female patients followed 10–40 years following surgery for ulcerative colitis and compared them to a reference population of 1200 women in Denmark.<sup>109</sup> Surgery significantly reduced the ratio of patient to reference population fecundability (ability to conceive) to 0.20 whereas there was no significant difference in the rates following diagnosis of ulcerative colitis until the time to surgery. They also reported that 29% of women who did conceive required in vitro fertilization. Johnson and colleagues reported similar findings.<sup>110</sup> In a cohort of 147 female patients who had IPAA with a mean follow-up of 7.2 years, 38.1% reported problems with fertility compared to a Canadian national average of 8%. Furthermore, 96% of women who wished to become pregnant preoperatively were successful compared to only 55% postoperatively.

The impairment is likely due to adhesions caused by pelvic surgery. This is supported by the results of another study by Olsen and colleagues that showed that fecundity was not decreased in women having an IRA for familial polyposis.<sup>111</sup> A study in female patients suffering from ulcerative colitis showed similar results.<sup>112</sup> Colectomy and IRA likely has a minimal effect on fertility in women having surgery for ulcerative colitis because there is no pelvic dissection whereas following IPAA the tubes and ovaries are often buried behind or adherent to the pouch.

To date, there are no maneuvers that have been shown to be effective in reducing the risk of infertility. One simple maneuver is to ensure that the ovaries lie above the pouch and perhaps are tacked in this position. Application of barrier agents, although unproven, may be worthwhile. A laparoscopic approach has been shown to decrease adhesions within the abdomen, but less is known about scarring in the pelvis and whether there is less effect on fertility.

Many women who have had IPAA have not started or completed their family. Studies have reported that approximately 45% of women attempted to become pregnant following surgery, but only 56% were successful following IPAA.<sup>110</sup> Thus, women must be counseled regarding this risk preoperatively. Although infertility may be increased following total proctocolectomy or IPAA, deferring surgery until a woman has completed her family is unlikely to be a feasible option. Women who are referred for surgery typically have active disease that has become refractory to medical management. For women with active disease who require surgery, one consideration is to perform a colectomy with end ileostomy and defer IPAA because previous studies have shown that colectomy alone does not decrease fertility. While this may be acceptable to some patients, having a stoma for a prolonged period is unlikely to appeal to most women, especially young women who might be in dating relationships.

## Pregnancy and Delivery

While becoming pregnant may pose problems, most studies have shown that pregnancy following IPAA is safe and



without an associated increase in maternal or fetal morbidity or mortality.<sup>113</sup> Furthermore, there appears to be no increase in pouch-related complications or bowel obstruction during pregnancy. The concern with pregnancy is whether vaginal delivery should be recommended. Because of stool generally being semiformal in individuals with an IPAA, any degree of anal sphincter injury may lead to deterioration of functional results and, in particular, incontinence. For this reason many colorectal surgeons and obstetricians have recommended that women with an IPAA have a planned cesarean section. This is reflected by cesarean section rates of 38–78% after IPAA, which are considerably higher than the North American average of 22%.<sup>114</sup> There are multiple retrospective studies, and no data to suggest that the risk of an anal sphincter tear is increased. Some women do experience transient worsening of their functional results during pregnancy, but there are no long-term differences in functional outcomes between patients who have a vaginal delivery compared with a cesarean section. Furthermore, there are data to suggest that women who have a pregnancy and vaginal delivery following IPAA have similar long-term function compared to those who did not have a pregnancy following IPAA. The difficulty with these data is that the series are small, and therefore the true rate of sphincter injury in this group is uncertain. The counter argument to planned cesarean section is that the morbidity to both the mother and fetus with cesarean section is generally higher than that with a vaginal delivery.

## Complications Related to Colectomy and Ileorectal Anastomosis

### ANASTOMOTIC LEAK

The most significant complication following colectomy and ileorectal anastomosis (IRA) is an anastomotic leak. The reported rate is less than 5% indicating that patients who have a colectomy and IRA are highly selected.<sup>115,116</sup> The presentation can vary from a small abscess treated with antibiotics and percutaneous drainage to a free leak within the abdominal cavity with peritonitis and overwhelming sepsis. The frequent use of steroids in this population can make the diagnosis of an anastomotic leak very difficult, with only subtle symptoms present at first, although rapid deterioration can occur and thus a high index of suspicion must be maintained at all times. In the event of a serious leak, reoperation with creation of an end ileostomy and mucous fistula is necessary.

### CANCER IN THE RECTAL REMNANT

Patients who have had a colectomy and IRA continue to be at risk for cancer. Thus, surveillance of the rectum is required. The risk is increased if there was dysplasia or cancer in the resected colon, and this supports the view that colectomy and IRA is contraindicated in patients who have dysplasia or a cancer in the colon. The cumulative risk of cancer in a series of 374 patients who had been followed up to 23 years was 6%

at 20 years and 15% at 30 years.<sup>49</sup> Grundfest and colleagues reported a cumulative risk of cancer of 5% at 20 years and 12.9% at 25 years.<sup>117</sup>

## Complications Related to the Kock Pouch

### NIPPLE VALVE SLIPPAGE

Valve malfunction, in particular valve slippage, has been the most frequent complication of the Kock pouch. In fact, it has been the Achilles heel of this procedure. Despite modifications in surgical technique, this complication occurs in 20–40% of individuals.<sup>65–67</sup> Reoperation is required to repair the valve in virtually all patients.

Slippage of the valve refers to desussception of the segment of bowel, used to create the nipple valve. Intussusception of the bowel is an abnormal physiologic state, and the bowel attempts to relieve it causing desussception of the bowel and slippage of the valve. Detachment of the pouch from the abdominal wall likely precedes the actual desussception. In fact, with modifications such as a mesenteric sling, it is unusual for the valve to completely desusscept and more often the valve protrudes through the side of the pouch. This complication may occur any time after surgery but is most common in the first year after surgery. There are two characteristic manifestations: intubation of the pouch becomes difficult or impossible because of the angulation of the path of the bowel. In some instances, the patient may have to leave the catheter in continuously because reinsertion is impossible. The second symptom is incontinence, total or partial, depending on the degree of extrusion. The latter may be problematic because it is difficult for the patient to wear an appliance with the stoma being flush with the skin.

Patients suffering from valve slippage may present acutely because they are not been able to insert a catheter and empty the pouch. In these situations, sometimes a flexible scope can be used to intubate the pouch or, alternatively, an interventional radiologist may be able to insert a tube over a guide wire under fluoroscopy. As stated previously, surgery is required to definitively repair the valve. Most often, the valve can be reintussuscepted and fixed. Sometimes, however, the valve must be excised and another valve created from the afferent limb of the pouch.

### NIPPLE VALVE PROLAPSE

Prolapse or procidentia of the valve is a less frequent complication. The valve remains intact but prolapses through the stoma. It is usually the result of an excessively large fascial opening. When pressure increases in the reservoir, there is no resistance to extrusion of the valve though the fascial opening. It can be prevented by creating a snug fascial opening. However, it may occur over time as the fascial opening enlarges. It may be corrected with a skin-level procedure in which the fascia is tightened by insertion of a few sutures or insertion of

a piece of mesh. If this fails, the pouch may have to be resited at another site on the abdomen.

## FISTULIZATION

As with any gastrointestinal operation, fistulas may occur postoperatively due to inadvertent injury to the small bowel during the procedure, leaks from anastomotic suture lines, or erosion of intra-abdominal abscesses into the bowel. In addition, fistulas may arise from the nipple valve in this procedure. Most often, they arise from the fundus of the pouch at the base of the nipple valve or from the valve itself. Several factors make the fundus of the pouch a vulnerable site. First, there is often tension on this suture line because the valve is large and edematous when constructed while the reservoir has not yet dilated. Second, an anchoring suture placed between the fundus of the pouch and the abdominal wall might cut out, creating a perforation and fistula. Third, the bowel may be ischemic from passage of the stapler to maintain the valve. Finally, and probably most important, there may be erosion of the bowel in patients where a synthetic mesh has been used to stabilize the valve.<sup>67,71</sup> In fact, when mesh is inserted, valve fistulas have been reported in approximately 25% of patients so many surgeons no longer use a mesh to stabilize the valve for this reason. Although the mesh decreases the risk of valve slippage, the risk of fistulization and septic complications is increased.<sup>67</sup>

Patients may present early or late. Often, they present first with a peristomal abscess or cellulitis. Subsequently there may be drainage of fecal material. Sometimes on scoping the patient, the mesh can be visualized at the base of the valve if it has eroded through. If a mesh has been used, the fistula will not close and surgery is required. This will require takedown of the pouch, excision of the valve, and creation of a new valve using the afferent limb of small bowel.

## CANCER OF THE POUCH

Cox and colleagues have reported the only case of adenocarcinoma involving a Kock pouch 28 years following construction.<sup>118</sup> Hulten and colleagues examined and biopsied a cohort of 40 patients who had their Kock pouch for a mean duration of 30 years. There were no cases of high-grade dysplasia or cancer in any patients. This provides further evidence that cancer and dysplasia are rare events in the long term.<sup>119</sup>

## OTHER COMPLICATIONS

Volvulus of the pouch is a rare complication but has been reported.<sup>118</sup> Unfortunately, the diagnosis is usually made at laparotomy. In some instances, it may not be able to preserve the pouch.

It is likely that transient ischemia of the valve occurs frequently caused by the two to three rows of staples inserted to maintain the valve. Despite the valve and efferent conduit often appearing congested and dusky at the end of the procedure, it is unusual for this complication to occur. Ischemia and sloughing of the entire valve is a rare complication.

## Complications Related to IPAA

### LEAKS, FISTULAS, AND SEPTIC COMPLICATIONS

The most important complication of IPAA surgery is an anastomotic leak. Leaks may occur either from the IAA or from the pouch itself. They may manifest as an asymptomatic leak found on contrast studies, a perianal, pelvic, or intra-abdominal abscess or a fistula. The latter may be communications from the pouch or IAA to other intra-abdominal structures, including the vagina or the abdominal or perianal skin. Most frequently, they occur within a few days of the procedure but may also occur many months after the procedure or closure of the ileostomy.<sup>120</sup>

Anastomotic leaks are significant not only because of their frequency but because they are the most common reason for pouch excision. In those in whom the pouch is not excised, functional results may be impaired. In our series of 1554 patients, septic complications occurred in 206 (13.3%) patients, and it was identified as the reason for pouch excision in 49 (46.2%) of all pouch excisions. IAA leaks accounted for 35% of septic complications while leaks from the pouch itself accounted for 19.4%.<sup>120</sup> Gemlo and colleagues reported that perianal sepsis or pouch fistulas were the indication for pouch excision in 24% of their patients.<sup>121</sup>

The reported risk of an anastomotic leak is quite variable. Several factors may account for the variability. First, there is variability in reporting with some centers separating leaks, abscesses, and fistulas while others combining them. Second, this is a complication that has decreased significantly over time probably due to modifications in surgical technique as well as increasing experience with the procedure. Reported rates vary between 5 and 15%.<sup>120,122,123</sup>

Various patient factors may affect the leak rate, including disease activity and if the patient is on high doses of steroids. Higher leaks have also been reported in hand-sewn compared with stapled anastomosis. Ziv and colleagues analyzed 692 patients and found the rate of septic complications to be 10.5% in patients with hand-sewn anastomoses compared with 4.6% in those with stapled IPAA.<sup>81</sup> In our series, the leak rate is 13.4% in patients having a hand-sewn anastomosis compared with 7.7% in those having a stapled anastomosis.<sup>82</sup>

A leak may manifest in various ways. One should have a high degree of suspicion that there may be a leak in individuals having a pouch without a covering ileostomy who develop a low-grade fever, pelvic or suprapubic pain, and/or an ileus. In these patients, a CT scan or pouchogram should be performed immediately. It is our experience that it is unusual for patients who do not have an ileostomy to develop generalized peritonitis and require an emergency operation. More often, they can be treated with antibiotics and prolonged drainage of the pouch. If there is an intra-abdominal or pelvic abscess, percutaneous drainage should be attempted. Even patients with a covering ileostomy may develop an intra-abdominal abscess that should be drained percutaneously. Sometimes a leak is not identified, but one must always be suspicious that there was one. One must also be cautious in

closing the ileostomy of patients who had either a clinical or even a radiologic leak that appears to have healed on repeat pouchogram. Sometimes the leak may have sealed due to the pouch being defunctioned but has not healed fully, and the patient becomes symptomatic once the ileostomy is closed. In these individuals, an examination under anesthesia is warranted prior to ileostomy closure or sometimes a laparotomy depending on the degree of suspicion. However, despite these maneuvers, some patients will manifest with another leak or fistula following closure of the ileostomy.

While early on a leak most often led to excision of the pouch, now most pouches can be salvaged.<sup>124-126</sup> Various modalities can be used, including antibiotics and drainage of the pouch (if there is no covering ileostomy), delayed closure of the ileostomy, and local techniques for repair of the anastomosis and reconstruction of the pouch with a combined abdominoperineal approach. It is our preference now is to undertake a combined abdominoperineal approach in most patients as the first procedure.<sup>127</sup> It is often difficult to perform a local repair and advance the pouch in patients who had a stapled anastomosis previously. An advancement procedure is easier in patients who had a hand-sewn anastomosis, but there is more likely to be tension on the anastomosis. Also, with each attempt at repair, there is some degree of injury to the anal sphincter, and therefore, while a combined procedure is a major operation, it also may be more successful and lead to better long-term outcome. Reported rates of pouch salvage range from 70 to 80% of patients who suffer an anastomotic leak.

### POUCH-VAGINAL FISTULA

Pouch-vaginal fistula is a major complication following ileal pouch surgery. It is often more difficult to treat than other fistulas. The reported risk is in the range of 4–14%.<sup>128-130</sup> It may develop early before ileostomy closure or more commonly a few months later. The vast majority occur at the ileoanal anastomotic level. It is likely that there are two mechanisms for their development. In women having a stapled IPAA, it is possible that the posterior wall of the vagina may be incorporated into the stapled anastomosis if care is not taken. Alternatively, and probably more commonly, a pouch-vaginal fistula is due to sepsis secondary to a leak at the IAA. Some women who develop a pouch-vaginal fistula are often diagnosed, in retrospect, to have Crohn's disease. In fact, if the fistula occurs a long time following surgery or there are other anal disease or pouch abnormalities, one should be suspicious of Crohn's disease.

Multiple treatment options have been described. The most common are local advancement of the pouch and combined abdominoperineal reconstruction of the pouch. Other methods include local repair, transvaginal repair, and interposition of a gracilis muscle. The choice of operation may depend on several factors. We have found local repairs to be more difficult to perform following stapled IPAA and prefer to perform a combined abdominoperineal operation especially if the fistula is at the anastomotic site. The pouch can be brought down beyond the fistula and the anastomosis performed at

the dentate line. A local repair either performed transanally or transvaginally may be attempted in patients who had a hand-sewn anastomosis. Treatment in patients with suspected Crohn's disease may have to be dictated by the status of the pouch and whether there is other anal disease.

Unfortunately, the failure rate is higher than following repair of other IPAA fistulas, probably because of the scarring of the rectovaginal septum. Reported success rates are in the range of 60–70%.

### ANAL COMPLICATIONS

Anal complications may occur early after the operation or many years later. The most common complication is anal stenosis. Rates of 11–38% have been reported.<sup>131,132</sup> They occur more commonly after a hand-sewn anastomosis although many patients who have a stapled IPAA have a tight stricture while they are defunctioned with an ileostomy. However, in these patients, digital dilation at the time of closure of the ileostomy is usually adequate and recurrence is infrequent. Some stenoses are fibrostenotic in nature and likely occur secondary to a leak or sepsis. Tension on the anastomosis may also be a factor in their occurrence. Most strictures are mild and, because the stool is semiformal, they do not cause problems with evacuation. A small proportion may require dilation in the operating room. In the Mayo Clinic series, only one patient out of 1884 required excision of the pouch because of an anal stricture.<sup>133</sup>

In the long term, some patients may develop anal complications, especially fistulas and abscesses. One must always be suspicious that they have Crohn's disease. Abscesses should be drained. However, treatment of a fistula may be difficult. Fistulotomy should be discouraged because of the risk of incontinence even if the fistula is superficial. If the fistula is cryptoglandular in origin, it is usually not possible to perform an advancement procedure. Thus, if an abscess occurs infrequently, it may be prudent simply to treat symptomatically with antibiotics. For more symptomatic fistulas, a seton may be inserted. If the fistula is low, one might be able to use it as a cutting seton. Alternatively, one can allow the tract to epithelialize and then remove the seton. The patient may experience some minimal discharge from the fistula but not have recurrent abscesses, which is usually acceptable to most patients. Fibrin glue may be tried but has been unsuccessful in most patients in our experience.

Anal skin tags may be a problem for some patients. They may cause severe pain and irritation because of the stool frequency experienced by most patients with a pouch. As in other patients, excision of the tags should be avoided. However, if the tags are large and extremely symptomatic, they can be locally excised. If so, the patient should be warned of problems with nonhealing.

### CUFFITIS

Because most surgeons prefer to perform the IPAA without performing a mucosectomy and instead perform a stapled



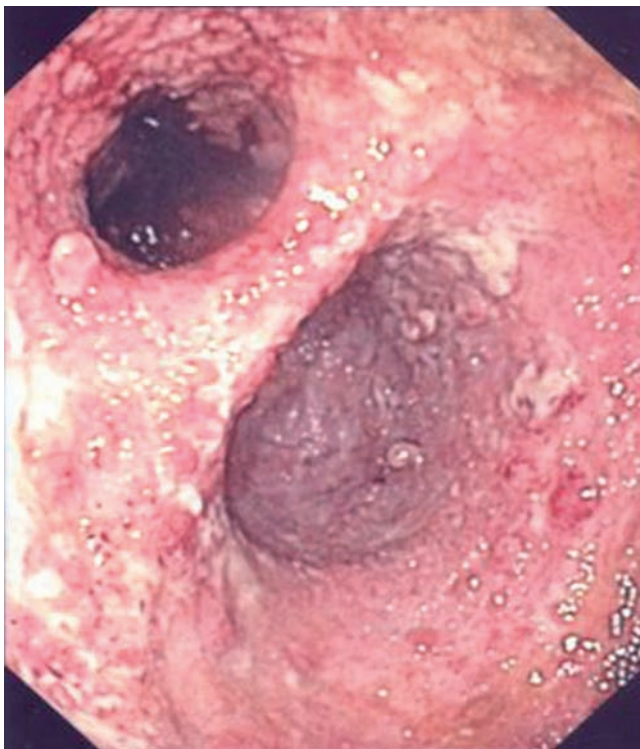
anastomosis above the dentate line, a small segment of rectal mucosa remains. Ideally, only 1–2 cm of mucosa should be left behind. Most patients will have evidence of inflammation in this segment, but, despite this, most patients are asymptomatic or may complain of a small amount of blood within the stool.<sup>84</sup> 5-ASA or steroid suppositories can be prescribed, but often they are poorly tolerated. Rarely are the symptoms severe enough to require surgery, but, if so, a mucosectomy with advancement of the pouch can be performed or alternatively a combined reconstructive procedure with mucosectomy and hand-sewn anastomosis at the dentate line. Before embarking on treatment, the pouch should be scoped to confirm the diagnosis of cuffitis and rule out pouchitis.

### POUCHITIS

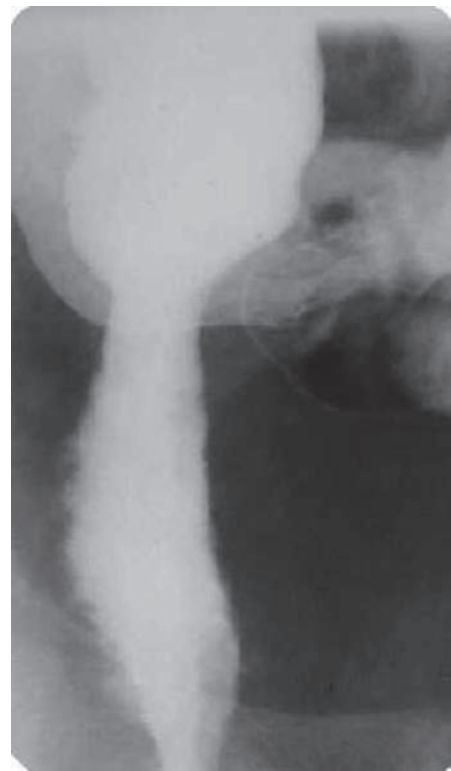Pouchitis is a nonspecific inflammation of the pouch mucosa, which is seen in patients with IPAA as well as those with a Kock pouch (Fig. 34-11).<sup>134</sup> Clinically, pouchitis manifests with a variable spectrum of clinical symptoms, including increased stool frequency, rectal bleeding, abdominal cramping, rectal urgency and tenesmus, incontinence, and low-grade fever. On endoscopy, there are inflammatory changes that usually include mucosal edema, granularity, contact bleeding, loss of the vascular pattern, hemorrhage, and superficial ulceration. It is important that on histologic examination, there is evidence of acute inflammation including neutrophil infiltration.

Patients often are labeled as having pouchitis when they have suboptimal function of the pouch. However, pouchitis is a specific diagnosis and should be based on clinical symptoms plus endoscopic and histologic changes. Svaninger and colleagues reported a cumulative risk of 34% in Kock pouch patients and 51% in IPAA patients at 5 years.<sup>135</sup> However, approximately two-thirds had only one or a few episodes of pouchitis. Sandborn reported a risk of 15% at 1 year, 36% at 5 years, and 46% at 10 years.<sup>134</sup> The etiology of pouchitis is unknown but is believed to be due to bacterial overgrowth. In addition, there may be an immune component because pouchitis rarely occurs in patients who have familial adenomatous polyposis. Other risk factors for pouchitis are anal strictures possibly leading to impaired pouch emptying. Also, patients with PSC appear to be at increased risk.<sup>136</sup> High pANCA levels appear to be associated with the development of chronic pouchitis.<sup>137</sup> In a series of 95 patients with ulcerative colitis who had IPAA, pouchitis developed in 42% of patients who were pANCA<sup>+</sup> compared with 20% pANCA<sup>-</sup> patients. Similarly 56% of patients with high pANCA levels developed chronic pouchitis compared with only 20% who were pANCA<sup>-</sup>.

Antibiotics have been the mainstay of treatment for pouchitis. There is level I evidence that metronidazole and ciprofloxacin are effective in the treatment of pouchitis.<sup>138</sup> Usually a 2-week course is instituted with response rates in the order of 75%. In most patients, the episode is short lived and rarely do patients develop recurrent episodes or chronic pouchitis.



A



B

FIGURE 34-11 Pouchitis. **A.** Endoscopic appearance. **B.** Radiologic appearance.

However, approximately 10–20% of patients may develop recurrent or chronic episodes of pouchitis. Probiotic therapy has been shown to decrease the risk of pouchitis and maintain a remission following an episode of pouchitis. Other agents including anti-inflammatory medications; steroids; immunosuppressive agents; free radical scavengers such as allopurinol, bismuth, and butyrate; and glutamine enemas have been tried with limited success.

## CANCER AND DYSPLASIA

**Dysplasia and Malignancy Affecting the Pouch Mucosa.** Creation of the pouch results in stasis, creating a new ileal environment and mucosal adaptation of the pouch mucosa that may predispose to dysplasia. Lofberg et al published the first report of a patient who developed dysplasia and aneuploidy.<sup>139</sup> Subsequently this group reported that 5 of 149 patients followed with serial biopsies were found to have dysplasia.<sup>140</sup> The median time since construction of the pouch was 54 months (5–152 months). Four patients had low-grade dysplasia and one patient had sequential transformation into multifocal high-grade dysplasia. This group classified the histology of pouches as type A, B, or C. The five cases of dysplasia were found in the seven patients with persistent severe villous atrophy (type C histology).

Despite this finding, dysplasia appears to be a rare occurrence.<sup>141</sup> There are only a few other reports in the literature. Thompson-Fawcett and colleagues examined a cohort of 116 patients considered to be at potentially high risk for developing dysplasia.<sup>142</sup> Only one patient, a woman with a 23-year history of ulcerative colitis who had a pouch performed 14 years earlier, had low-grade dysplasia on one of the eight biopsies taken.

There are a few reports of cancer arising in the pouch, but, given the number of IPAA that have been performed in the past 30 years, it is not possible to conclude that the risk of cancer is in fact increased in patients with pouches because adenocarcinoma, although rare, does occur in the small bowel of normal individuals.<sup>141</sup> However, it may be that there is a delay in the development of dysplasia, and with increasing time there may be more cases. Thus, it is difficult to make recommendations for follow-up at this time. It does appear that patients with chronic pouchitis and severe villous atrophy may be the group at highest risk and perhaps this is the group that should be followed with regular endoscopies and serial biopsies.

**Dysplasia and Malignancy Affecting the Rectal Outlet.** Given that there is an increased risk of cancer in patients with ulcerative colitis, it is reasonable to expect that there may be an increased risk of cancer in the rectal outlet. Controversy exists as to whether a mucosectomy and hand-sewn anastomosis or a double-stapled anastomosis is preferable, especially in patients known to have cancer and dysplasia elsewhere. When this procedure was first described, it was assumed that by performing a mucosectomy that all mucosal cells would be extirpated. However, in O'Connell and colleagues' report

of 29 patients who had excision of their pouches because of septic complications after mucosectomy and hand-sewn anastomosis<sup>83</sup> 14% had evidence of residual mucosa in the muscular cuff. They concluded that either mucosal cells remained following mucosectomy or there was regeneration of mucosa following mucosectomy. In either case, it is obvious that mucosectomy does not eliminate the risk of cancer.

There are nine reported cases of cancers involving the anal outlet.<sup>141</sup> In three patients a mucosectomy had been performed while the rest had a stapled anastomosis. Of note is the fact that cancer or dysplasia was present in eight of the colectomy specimens. The data on dysplasia occurring in the anal outlet are less complete. O'Riordain and colleagues from the Cleveland Clinic have reported that dysplasia developed in the residual epithelial cuff in 7 of 210 patients who had had stapled ileal pouch anal anastomoses between 1987 and 1992.<sup>143</sup> Dysplasia was high grade in one and low grade in six. Two patients had a mucosectomy performed while five were treated expectantly. In three of the seven patients, cancer or dysplasia had been present in the colectomy specimen suggesting that the dysplasia had been present at the time of surgery.

Thus, while patients with IPAA require follow-up, the method and frequency is not certain. It appears that the risk of cancer is low. Based on guidelines for surveillance of patients with ulcerative colitis who have not had surgery, a reasonable follow-up strategy would be to begin endoscopy and biopsy of the rectal outlet at 10 years and continue at 2-year intervals for individuals who have had a stapled anastomosis. For those who have had a mucosectomy and hand-sewn anastomosis, endoscopy and biopsy are not possible.

If one detects dysplasia, it is also difficult to know what to recommend. The biopsy specimens should definitely be reviewed by an experienced pathologist. Surgeons at the Cleveland Clinic have recommended performing a mucosectomy and advancement of the pouch with a hand-sewn IAA.<sup>143</sup> However, this likely does not eliminate the risk of cancer given the experience with hand-sewn anastomosis and mucosectomy. Thus, excision of the pouch would be another option and would be our recommendation. However, this is a difficult decision, and certainly the alternatives should be discussed with the patient and the patient should participate in the decision making.

## Outcome

Mortality following surgery for ulcerative colitis is low. The contemporary mortality rate for subtotal colectomy in acute severe ulcerative colitis is 0–3%,<sup>56,144</sup> but it increases dramatically when there is a colonic perforation. The mortality rate from large series of patients having IPAA is similarly low, in the range of 0–2%.<sup>145</sup> This is probably because most patients undergoing IPAA are young and free of comorbid diseases.

On the other hand, morbidity rates are high following both urgent and elective procedures. Morbidity rates of 33–66% have been reported for patients having subtotal colectomy for acute colitis with the main complications being

wound infection, ileus, small bowel obstruction, and a blown rectal stump.<sup>56,144</sup> In patients having an IPAA, complication rates are nearly as high. In a Cochrane Review, complication rates (from all causes) were as high as 53%, including both procedure-specific and general complications following pouch construction.<sup>145</sup> The rate of complications after laparoscopic IPAA were no different.

### LONG-TERM OUTCOME FOLLOWING COLECTOMY AND ILEORECTAL ANASTOMOSIS

In a small series from the Mayo Clinic, 82% of patients had a functioning ileorectal anastomosis (IRA) at 5 years.<sup>116</sup> The probability of having a functioning IRA in a series of 32 patients followed for an average of 3.5 years was 88%.<sup>146</sup> Finally, a study from the Cleveland Clinic demonstrated that 54% of patients required excision of the rectum within 20 years of construction of an IRA, most commonly for ongoing symptoms, dysplasia, or malignancy.<sup>115</sup> The same study, however, reported reasonable functional results, with patients having fewer bowel movements than matched controls who had an IPAA, but with more urgency.

### LONG-TERM OUTCOME FOLLOWING KOCK POUCH

Revisory surgery is necessary in a large proportion of patients mainly because of valve complications. Kock reported a reoperative rate of 54% in his early series of patients, but the rate decreased to 16% subsequently.<sup>147</sup> Despite the frequency of complications, most patients retain their pouch in the long term. Lepisto and Jarvinen reported a cumulative success rate of 96% at 1 year, 86% at 10 years, 77% at 15 years, and 71% at 29 years.<sup>65</sup> In this series of 96 patients, 59% had required reconstructive surgery. Nessar et al reported 10- and 20-year pouch survival rates of 87–77%.<sup>66</sup> In our own series of 194 patients, 81% of patients at 10 years and 67% at 20 years had a functioning Kock pouch.<sup>67</sup> Wasmuth and Myrvold reported a failure rate of 11.6% at 20 years.<sup>68</sup>

### LONG-TERM OUTCOME FOLLOWING IPAA

The reported failure rates are in the range of 5–10%. Many failures occur early, but there are an increased number of failures over time. In our own series of patients over 25 years, the failure rate was 6.8%.<sup>120</sup> Median time to failure was 3.5 years. The risk factors for failure included Crohn's disease and a leak from the pouch or IAA on multivariable analysis. Gemlo et al reported a failure rate of 9.9% in 253 patients having surgery at the University of Minnesota.<sup>121</sup> Poor functional results was the most common cause (28%), followed by unsuspected Crohn's disease (5%) and pelvic sepsis. Lepisto and Jarvinen reported an overall failure rate of 5.3%.<sup>65</sup> The cumulative probability of pouch failure was 1% at 1 year, 5% at 5 years, and 7% at 10 years.

Experience with the procedure is also a factor in predicting success. In our own series, the complication, reoperative and

failure rates dropped significantly over time. In the period 1981–84, the overall complication rate was 37.5%, the IAA leak rate was 30%, and the failure rate was 30%. There was a steady decrease so the respective rates in the period 1997–2000 were 10.6, 5.2, and 1.5%.<sup>148</sup> Outcome was assessed in patients undergoing an IPAA over the period 1992–1998 using population data from the province of Ontario.<sup>149</sup> Even though the surgical procedure had undergone significant modifications and been performed for more than 10 years by this time, a decrease in the complication rate as measured by readmission rate, reoperative rate, and failure rate was observed during that period. Also, outcome was significantly better in individuals having surgery in high-volume hospitals compared with medium- and low-volume hospitals.

### Quality of Life and Functional Results

Ulcerative colitis has been shown to have a significant impact on quality of life, with disease activity being one of the largest predictors of outcome.<sup>150–152</sup> In a population-based study from Norway, 328 patients with ulcerative colitis were evaluated with a Norwegian variation of the IBDQ (Inflammatory Bowel Disease Questionnaire). The frequency of disease relapse over a 5-year follow-up period was independently associated with a decrease in IBDQ scores.<sup>153</sup> Thus, it is not surprising, given that surgery eliminates the disease, that most individuals who have had surgery for ulcerative colitis have a high quality of life. In fact, one of the first studies to document this was a study by Provenzale and colleagues who compared the outcome of 22 patients with IPAA to a normal population using the Short Form 36 (SF-36).<sup>61</sup> They found that the quality of life of the individuals with IPAA was similar to that of the normal population. They also reported that the median utility for this cohort was 1.0 signifying normal health-related quality of life. Using the time trade-off technique, our group was able to show that the mean utility increased from 0.58 preoperatively to 0.98 at 1 year postoperatively in a cohort of 20 patients.<sup>62</sup>

As discussed previously in this chapter, surgeons have been innovative over the past 50 years in developing new procedures so that patients do not have to have a permanent ileostomy. In reality, most patients with conventional ileostomy have a high quality of life using the SF-36, time trade-off technique, and IBDQ; investigators have shown that not only is quality of life excellent following surgery but is similar irrespective of the procedure. Our group interviewed three cohorts of patients: 28 with conventional ileostomies, 28 with continent ileostomates, and 37 with pelvic pouches.<sup>62</sup> The mean utilities, using the time trade-off technique were not significantly different with utilities ranging from 0.87 to 0.97 with a utility of one signifying perfect health. Jimmo and Hyman studied 12 patients who had a total proctocolectomy and ileostomy and 55 who had an IPAA. Overall, 46 of 55 (83.3%) patients with an IPAA and 10 of 12 (83.3%) with a proctocolectomy and ileostomy were satisfied with the procedure. All patients completed the IBDQ, and there was no



significant difference between the two groups regarding the overall score or by category.<sup>63</sup> Using a modified version of the SF-36, Thirlby and colleagues also showed that quality of life was equal or better than norms for the general population.<sup>64</sup>

This finding seems to contradict what occurs in clinical practice; that is, most patients, given the option, choose a pelvic pouch. Several reasons may explain the discrepancy. First, patients in these studies were not randomly allocated and they may choose their preferable option. Second, there may be an aspect of patients accepting their current health status and rationalizing that it is superior to other alternatives. Finally, the most important determinant of quality of life in these patients may be physical well-being that is improved in almost all patients after all procedures. What is important about these findings is that all of the various options should be presented to patients so they may choose which procedure is most acceptable to them and their lifestyle.

Recently, there have been several studies that have shown that quality of life is similar in patients having open or laparoscopic IPAA, but cosmesis and body image is better in patients having a laparoscopic IPAA.<sup>154</sup>

Following IPAA, the average number of bowel movements is approximately six per day. In a series of over 1300 patients followed for a median of 8 years, Farouk et al reported that 85% of patients were totally continent during the day but only 52% were totally continent at night. However, frequent incontinence was reported in less than 5% of patients.<sup>155</sup> Several studies have shown that functional results deteriorate with advancing age. Also, functional results have been shown to correlate with quality of life.<sup>156</sup> Kirat et al also reported better outcomes in patients having a stapled versus a hand-sewn IAA.<sup>157</sup>

## Conclusion

Patients requiring surgery for ulcerative colitis have several options to choose from. A thorough understanding of the technical aspects of each procedure, their complications, and outcomes is essential in order to discuss the options with patients. Patients should be fully informed and they participate in the decision making. Although IPAA is the procedure of choice for most patients, they will have a good outcome with excellent quality of life irrespective of the procedure that is performed. However, to achieve such results, patients must be selected carefully and surgeons should be well versed in the technical details of the surgery as well as the pre- and post-operative care of patients and management of complications.

## REFERENCES

1. Hoie O, Wolters FL, Riis L, et al. Low colectomy rates in ulcerative colitis in an unselected European cohort followed for 10 years. *Gastroenterology*. 2007;132(2):507–515.
2. Binder V. Epidemiology of IBD during the twentieth century: an integrated view. *Best Pract Res Clin Gastroenterol*. 2004;4:463–479.
3. Andres PG, Friedman LS. Epidemiology and the natural course of inflammatory bowel disease. *Gastroenterol Clin North Am*. 1999;28:225–281.
4. Mayer L. Evolving paradigms in the pathogenesis of IBD. *J Gastroenterol*. 2010;45:9–16.
5. Silverberg MS, Cho JH, Rioux JD, et al. Ulcerative colitis-risk loci on chromosomes 1p36 and 12q15 found by genome-wide association study. *Nat Genet*. 2009;41:216–220.
6. Franke A, Balschun T, Karlsen TH, et al. Replication of signals from recent studies of Crohn's disease identifies previously unknown disease loci for ulcerative colitis. *Nat Genet*. 2008;40:713–715.
7. Danese S, Sans M, Fiocchi C. Inflammatory bowel disease: the role of environmental factors. *Autoimmun Rev*. 2004;3:394–400.
8. Finkelstein SD, Sasatomi E, Regueiro M. Pathologic features of early inflammatory bowel disease. *Gastroenterol Clin North Am*. 2002 Mar; 31(1):133–145.
9. Gumaste V, Sachar DB, Greenstein AJ. Benign and malignant colorectal strictures in ulcerative colitis. *Gut*. 1992;33(7):938–941.
10. Goldstein N, Dulai M. Contemporary morphologic definition of backwash ileitis in ulcerative colitis and features that distinguish it from Crohn disease. *Am J Clin Pathol*. 2006 Sep;126(3):365–367.
11. Langholz E, Munkholm P, Davidsen M, Binder V. Course of ulcerative colitis: analysis of changes in disease activity over years. *Gastroenterology*. 1994;107(1):3–11.
12. Truelove SC, Witts LJ. Cortisone in ulcerative colitis: final report on a therapeutic trial. *Br Med J*. 1955(ii):1041–1048.
13. Loftus EV, Jr. Management of extraintestinal manifestations and other complications of inflammatory bowel disease. *Curr Gastroenterol Rep*. 2004;6:506–513.
14. Odze R. Diagnostic problems and advances in inflammatory bowel disease. *Mod Pathol*. 2003;16:354–358.
15. Jakowski TD, Litwin CM, Hill HR. Analysis of serum antibodies in patients suspected of having inflammatory bowel disease. *Clin Vaccine Immunol*. 2006;13:655–660.
16. Bossuyt X. Serological markers in inflammatory bowel disease. *Clin Chem*. 2006;52:171–181.
17. Ferrante M, Henckaerts L, Joossens M, et al. New serological markers in inflammatory bowel disease are associated with complicated disease behaviour. *Gut*. 2007;56:1394–1403.
18. Marshall JK, Irvine EJ. Rectal corticosteroids versus alternative treatments in ulcerative colitis and pouchitis: a meta-analysis. *Gut*. 1997;40:775–781.
19. Campieri M, Gionchetti P, Belluzzi A, et al. 5-aminosalicylic acid as enemas or suppositories in distal ulcerative colitis? *J Clin Gastroenterol*. 1988;10:406–409.
20. Safdi M, DeMicco M, Sninsky C, et al. A double-blind comparison of oral versus rectal mesalamine versus combination therapy in the treatment of distal ulcerative colitis. *Am J Gastroenterol*. 1997;92:1867–1871.
21. Sutherland L, MacDonald JK. Oral 5-aminosalicylic acid for induction of remission in ulcerative colitis. *Cochrane Database Syst Rev*. 2003;CD000543.
22. Marshall JK, Irvine EJ. Putting rectal 5-aminosalicylic acid in its place: the role in distal ulcerative colitis. *Am J Gastroenterol*. 2000;95: 1628–1636.
23. Regueiro M, Loftus EV Jr, Steinhart AH, Cohen RD. Medical management of left-sided ulcerative colitis and ulcerative proctitis: critical evaluation of therapeutic trials. *Inflamm Bowel Dis*. 2006;12:979–994.
24. Meyers S, Lerer PK, Feuer EJ, Johnson JW, Janowitz HD. Predicting the outcome of corticoid therapy for acute ulcerative colitis. Results of a prospective, randomized, double blind clinical trial. *J Clin Gastroenterol*. 1987;9:50–54.
25. Turner D, Walsh C, Steinhart AH, Griffiths AM. Response to corticosteroids in severe ulcerative colitis: a systematic review of the literature and a meta-regression. *Clin Gastroenterol Hepatol*. 2007;5:103–110.
26. Bojic D, Radojicic Z, Nedeljkovic-Protic M, et al. Long-term outcome after admission for acute severe colitis in Oxford: the 1992–1993 cohort. *Inflamm Bowel Dis*. 2009;15:823–828.
27. D'Haens G, Lemmens L, Geboes K, et al. Intravenous cyclosporine versus intravenous corticosteroids as single therapy for severe attacks of ulcerative colitis. *Gastroenterology*. 2001;120:1323–1329.
28. Jarnerot G, Hertevig E, Friis-Liby I, et al. Infliximab as rescue therapy in severe to moderately severe ulcerative colitis: a randomized placebo-controlled study. *Gastroenterology*. 2005;128:1805–1811.
29. Gonzalez-Huix F, Fernandez-Banares F, Esteve-Comas M, et al. Enteral versus parenteral nutrition as adjunct therapy in ulcerative colitis. *Am J Gastroenterol*. 1993;88:227–232.

30. MacIntyre BP, Powel-Tuck J, Wood SR, et al. Controlled trial of bowel rest in the treatment of severe acute colitis. *Gut*. 1986;27:481–485.
31. Rogler G. Medical management of ulcerative colitis. *Dig Dis*. 2009;27:542–549.
32. Orchard T, Probert CS, Keshav S. Review article: maintenance therapy in patients with ulcerative colitis. *Aliment Pharmacol Ther*. 2006;24(suppl 1):17–22.
33. Timmer A, McDonald J, Macdonald J. Azathioprine and 6-mercaptopurine for maintenance of remission in ulcerative colitis. *Cochrane Database Syst Rev*. 2007:CD000478.
34. Rutgeerts P, Sandborn WJ, Feagan BG, et al. Infliximab for induction and maintenance therapy for ulcerative colitis. *N Engl J Med*. 2005;353:2462–2476.
35. Brown SR, Haboubi N, Hampton J, George B, Travis SPL. The management of acute severe colitis: ACPGBI position statement. *Colorectal Dis*. 2008;10(suppl 3):8–29.
36. Travis SPL, Farrant JM, Ricketts C, et al. Predicting outcome in severe ulcerative colitis. *Gut*. 1996;38:905–910.
37. Grant CS, Dozois RR. Toxic megacolon: ultimate fate of patients after successful medical management. *Am J Surg*. 1984;147(1):106–110.
38. Munkholm P. Review article: the incidence and prevalence of colorectal cancer in inflammatory bowel disease. *Aliment Pharmacol Ther*. 2003;18(suppl 2):1–5.
39. Ullman T, Odze R, Farraye FA. Diagnosis and management of dysplasia in patients with ulcerative colitis and Crohn's disease of the colon. *Inflamm Bowel Dis*. 2009;15:630–638.
40. Novacek G, Weltermann A, Sobala A, et al. Inflammatory bowel disease is a risk factor for recurrent venous thromboembolism. *Gastroenterology*. 2010;139(3):779–787. [Epub 2010 Jun 12].
41. Nguyen GC, Sam J. Rising prevalence of venous thromboembolism and its impact on mortality among hospitalized inflammatory bowel disease patients. *Am J Gastroenterol*. 2008;103(9):2272–2280.
42. Geerts WH, Bergqvist D, Pineo GF, et al. American College of Chest Physicians. Prevention of venous thromboembolism: American College of Chest Physicians Evidence-Based Clinical Practice Guidelines (8th Edition). *Chest*. 2008;3(6 suppl):381S–453S.
43. McLeod RS, Geerts WH, Sniderman KW, et al. Subcutaneous heparin versus low molecular weight heparin as thromboprophylaxis in patients undergoing colorectal surgery. Results of the Canadian Colorectal DVT Prophylaxis Trial. *Ann Surg*. 2001;233:438–444.
44. Slim K, Vicaut E, Launay-Savary MV, Contant C, Chipponi J. Updated systematic review and meta-analysis of randomized clinical trials on the role of mechanical bowel preparation before colorectal surgery. *Ann Surg*. 2009;249(2):203–209.
45. Brown CJ, Buie WD. Perioperative stress dose steroids: do they make a difference? *J Am Coll Surg*. 2001;193:678–685.
46. Brooke BN. The management of an ileostomy, including its complications. *Lancet*. 1952;2:102–104.
47. Crile G, Jr, Turnbull RB, Jr. The mechanism and prevention of ileostomy dysfunction. *Ann Surg*. 1954;2:102–104.
48. Aylett SO. Ileorectal anastomosis: review 1952–1968. *Proc R Soc Med*. 1971;64:967–971.
49. Baker WN, Glass RE, Ritchie JK, et al. Cancer of the rectum following colectomy and ileorectal anastomosis for ulcerative colitis. *Br J Surg*. 1978;65:862–868.
50. Kock NG. Intra-abdominal “reservoir” in patients with permanent ileostomy. Preliminary observations on a procedure resulting in fecal “continence” in five ileostomy patients. *Arch Surg*. 1969;99:223–231.
51. Parks AG, Nicholls RJ. Proctocolectomy without ileostomy for ulcerative colitis. *Br Med J*. 1978 Jul 8;2(6130):85–88.
52. Utsunomiya J, Iwama T, Imajo M, et al. Total colectomy, mucosal proctectomy, and ileoanal anastomosis. *Dis Colon Rectum*. 1980 Oct;23(7):459–466.
53. Carter FM, McLeods RS, Cohen Z. Subtotal colectomy for ulcerative colitis: complications related to rectal remnant. *Dis Colon Rectum*. 1991;34:1005–1009.
54. Messenger DE, Victor JC, O'Connor BI, MacRae HM, McLeod RS. Laparoscopic subtotal colectomy is safe in patients with active Crohn's and ulcerative colitis. *Can J Surg*. 2010;53(4):S100.
55. Ng RL, Davies AH, Grace RH, Mortensen NJ. Subcutaneous rectal stump closure after emergency subtotal colectomy. *Br J Surg*. 1992;79:701–703.
56. Randall J, Bach SP, Sarris I, et al. Complications of the retained rectum after emergency subtotal colectomy for severe ulcerative colitis. Comparison of subcutaneous vs. pelvic closure. *Colorectal Dis*. 2008;10:144–150.
57. Marcello PW, Milsom JW, Wong SK, et al. Laparoscopic total colectomy for acute colitis: a case-control study. *Dis Colon Rectum*. 2001;44:1441–1445.
58. Seshadri PA, Poulin EC, Schlachta CM, Caddeu MO, Mamazza J. Does a laparoscopic approach to total abdominal colectomy and proctocolectomy offer advantages? *Surg Endosc*. 2001;15:837–842.
59. Pokala N, Delaney CP, Senagore AJ, Brady KM, Fazio VW. Laparoscopic vs. open total colectomy: a case-matched comparative study. *Surg Endosc*. 2005;19:531–535.
60. Ouaisi M, Lefevre JH, Bretagnol F, et al. Laparoscopic 3-step restorative proctocolectomy: comparative study with open approach in 45 patients. *Surg Laparosc Endosc Percutan Tech*. 2008;18:357–362.
61. Chung TP, Fleshman JW, Birnbaum EH, et al. Laparoscopic vs. open total abdominal colectomy for severe colitis: impact on recovery and subsequent completion restorative proctocolectomy. *Dis Colon Rectum*. 2009;52:4–10.
62. McLeod RS, Churchill DN, Lock AM, Cohen Z. Quality of life of patients with ulcerative colitis preoperatively and postoperatively. *Gastroenterology*. 1991;101:593–600.
63. Jimmo B, Hyman NH. Is ileal pouch-anal anastomosis really the procedure of choice for patients with ulcerative colitis? *Dis Colon Rectum*. 1998;41:41–45.
64. Thirlby RC, Sobrino MA, Randall JB. The long-term benefit of surgery on health-related quality of life in patients with inflammatory bowel disease. *Arch Surg*. 2001;136:521–527.
65. Lepisto AH, Jarvinen HJ. Durability of Kock ileostomy. *Dis Colon Rectum*. 2003;46:925–928.
66. Nessar G, Fazio VW, Tekkis P, et al. Long-term outcome and quality of life after continent ileostomy. *Dis Colon Rectum*. 2006;49:336–344.
67. Forbes SS, Victor JC, O'Connor BI, et al. Long-term durability of the Kock continent ileostomy is high. *Dis Colon Rectum*. Submitted.
68. Wasmuth HH, Myrvold HE. Durability of ileal pouch-anal anastomosis and continent ileostomy. *Dis Colon Rectum*. 2009;52:1285–1289.
69. Bokey L, Fazio VW. The mesenteric sling technique: new method of constructing an intestinal nipple valve for the continent ileostomy. *Cleve Clin Q*. 1978;45(2):231–236.
70. Fasth S, Hulten L, Svaninger G. The Kock continent ileostomy: influence of a defunctioning ileostomy and nipple valve stapling on early and late morbidity. *Int J Colorectal Dis*. 1987;2(2):82–86.
71. Klingler PJ, Neuhauser B, Peer R, Klingler CH, Bodner E. Nipple complication caused by a mesenteric GORE-TEX sling reinforcement in a Kock ileal reservoir: report of a case. *Dis Colon Rectum*. 2001;44(1):128–130.
72. Brown CJ, Maclean AR, Cohen Z, et al. Crohn's disease and indeterminate colitis and the ileal pouch-anal anastomosis: outcomes and patterns of failure. *Dis Colon Rectum*. 2005;48(8):1542–1549.
73. Joyce MR, Fazio VW. Can ileal pouch anal anastomosis be used in Crohn's disease? *Adv Surg*. 2009;43:111–137.
74. Regimbeau JM, Panis Y, Pocard M, et al. Long-term results of ileal pouch-anal anastomosis for colorectal Crohn's disease. *Dis Colon Rectum*. 2001;44:769–778.
75. Delaney CP, Fazio VW, Remzi FH, et al. Prospective, age-related analysis of surgical results, functional outcome, and quality of life after ileal pouch-anal anastomosis. *Ann Surg*. 2003;238(2):221–228.
76. Richard CS, Cohen Z, Stern HS, McLeod RS. Outcome of the pelvic pouch procedure in patients with prior perianal disease. *Dis Colon Rectum*. 1997;40(6):647–652.
77. Sugarman HJ, Newsome HH, Decosta G, Zfass AM. Stapled ileoanal anastomosis for ulcerative colitis and familial polyposis without a temporary diverting ileostomy. *Ann Surg*. 1991;213:606–619.
78. Davies M, Hawley PR. Ten years experience of one-stage restorative proctocolectomy for ulcerative colitis. *Int J Colorectal Dis*. 2007;22(10):1255–1260.
79. Ikeuchi H, Nakano H, Uchino M, et al. Safety of one-stage restorative proctocolectomy for ulcerative colitis. *Dis Colon Rectum*. 2005;48(8):1550–1555.
80. Lovegrove RE, Heriot AG, Constantinides V, et al. Meta-analysis of short-term and long-term outcomes of J, W and S ileal reservoirs for restorative proctocolectomy. *Colorectal Dis*. 2007;9:310–320.

81. Ziv Y, Fazio VW, Church JM, et al. Stapled ileal pouch anal anastomoses are safer than handsewn anastomoses in patients with ulcerative colitis. *Am J Surg.* 1996;171:320–323.
82. Cohen Z, McLeod RS, Stephen W, et al. Continuing evolution of the pelvic pouch procedure. *Ann Surg.* 2001;216:506–512.
83. O'Connell PR, Pemberton JH, Weiland LH, et al. Does rectal mucosa regenerate after ileoanal anastomosis? *Dis Colon Rectum.* 1987;30(1):1–5.
84. Thompson-Fawcett MW, Mortensen NJ, Warren BF. "Cuffitis" and inflammatory changes in the columnar cuff, anal transitional zone and ileal reservoir after stapled pouch-anal anastomosis. *Dis Colon Rectum.* 1999;42:348–355.
85. Burnstein MJ, Schoetz DJ, Jr, Collier JA, Veidenheimer MC. Technique mesenteric lengthening in ileal reservoir-anal anastomosis. *Dis Colon Rectum.* 1987;30:883–886.
86. El-Gazzaz GS, Kiran RP, Remzi FH, et al. Outcomes for case-matched laparoscopically assisted versus open restorative proctocolectomy. *Br J Surg.* 2009;96:522–526.
87. Larson DW, Cima RR, Dozois EJ. Safety, feasibility, and short-term outcomes of laparoscopic ileal pouch-anal anastomosis: a single institution case-matched experience. *Ann Surg.* 2006;243:667–672.
88. Maatense S, Dunker MS, Slors JF. Hand-assisted laparoscopic versus open restorative proctocolectomy with ileal pouch anal anastomosis; a randomized trial. *Ann Surg.* 2004;240:984–992.
89. Polle SW, Dunker MS, Slors JF. Body image, cosmesis, quality of life, and functional outcome of hand-assisted laparoscopic versus open restorative proctocolectomy: long-term results of a randomized trial. *Surg Endosc.* 2007;21:1301–1307.
90. Gutt CN, Oniu, Schemper P. Fewer adhesions induced by laparoscopic surgery? *Surg Endosc.* 2004;18:898–906.
91. Marcello PW, Fleshman JW, Milsom JW, et al. Hand-assisted laparoscopic vs. laparoscopic colorectal surgery: a multicenter, prospective, randomized trial. *Dis Colon Rectum.* 2008;51:818–828.
92. Tsuruta M, Hasegawa H, Ishii Y, et al. Hand-assisted versus conventional laparoscopic restorative proctocolectomy for ulcerative colitis. *Surg Laparosc Percutan Tech.* 2009;19:52–56.
93. Targarona EM, Gracia E, Garriga J, et al. Prospective randomized trial comparing conventional laparoscopic colectomy with hand-assisted laparoscopic colectomy: applicability, immediate clinical outcome, inflammatory response, and cost. *Surg Endosc.* 2002;16(2):234–239.
94. Sonoda T, Pandey S, Trencheva K, Lee S, Milsom J. Long-term complications of hand-assisted versus laparoscopic colectomy. *J Am Coll Surg.* 2008;208:62–66.
95. MacLean AR, O'Connor BI, Mukraj D, et al. Risk of small bowel obstruction following ileal pouch anastomosis. *Ann Surg.* 2002;235:200–206.
96. Beck DE, Cohen Z, Fleshman JW, et al; Adhesion Study Group Steering C. A prospective, randomized, multicenter, controlled study of the safety of Seprafilm adhesion barrier in abdominopelvic surgery of the intestine. *Dis Colon Rectum.* 2003;46(10):1310–1309.
97. Fazio VW, Cohen Z, Fleshman JW, et al. Reduction in adhesive small-bowel obstruction by Seprafilm adhesion barrier after intestinal resection. *Dis Colon Rectum.* 2006;49(1):1–11.
98. Indar AA, Efron JE, Young-Fadok TM. Laparoscopic ileal pouch-anal anastomosis reduces abdominal and pelvic adhesions. *Surg Endosc.* 2009;23(1):174–177.
99. McLeod RS, Lavery IC, Leatherman JR, et al. Factors affecting quality of life with a conventional ileostomy. *World J Surg.* 1986;10:474–480.
100. Feinberg SM, McLeod RS, Cohen Z. Complications of loop ileostomy. *Am J Surg.* 1987;153:102–107.
101. Carlsen E, Bergan AB. Loop ileostomy: technical aspects and complications. *Eur J Surg.* 1999;165:140–143.
102. Hallböök O, Matthiessen P, Leinsköt, Nyström PO, Sjö Dahl R. Safety of temporary loop ileostomy. *Colorectal Dis.* 2002;4:361–364.
103. Christian CK, Kwaan MR, Betensky RA, Breen EM, Zinner MJ, Bleday R. Risk factors for perineal wound complications following abdominoperineal resection. *Dis Colon Rectum.* 2005;48:43–48.
104. Oomen JW, Spauwen PH, Bleichrodt RP, Van Goor H. Guideline proposal to reconstructive surgery for complex perineal sinus rectal fistula. *Int J Colorectal Dis.* 2007;22:225–230.
105. Schaffzin DM, Douglas JM, Stahl TJ, Smith LE. Vacuum-assisted closure of complex perineal wounds. *Dis Colon Rectum.* 2004;47:1745–1748.
106. Davies RJ, O'Connor BI, Victor C, et al. A prospective evaluation of sexual function and quality of life after ileal pouch-anal anastomosis. *Dis Colon Rectum.* 2008;51:1032–1035.
107. Bambrick M, Fazio VW, Hull TL, Purcell G. Sexual function following restorative proctocolectomy in women. *Dis Colon Rectum.* 1996;39:610–614.
108. Oresland T, Palmblad S, Ellstrom M, et al. Gynaecological and sexual function related to anatomical changes in the female pelvis after restorative proctocolectomy. *Int J Colorectal Dis.* 1994 May;9(2):77–81.
109. Olsen K, Juul S, Berndtsson I, Oresland T, Laurberg S. Ulcerative colitis: female fecundity before diagnosis, during disease, and after surgery compared with a population sample. *Gastroenterology.* 2002;122:15–19.
110. Johnson P, Richard C, Ravid A. Female infertility after ileal pouch-anal anastomosis for ulcerative colitis. *Dis Colon Rectum.* 2004;47:1119–1126.
111. Olsen KO, Juul S, Bulow S, et al. Female fecundity before and after operation for familial adenomatous polyposis. *Br J Surg.* 2003;90:227–231.
112. Mortier PE, Gambiez L, Karoui M, et al. Colectomy with ileorectal anastomosis preserves female fertility in ulcerative colitis. *Gastroenterol Clin Biol.* 2006;30:594–597.
113. Ravid A, Richard CS, Spencer LM, et al. Pregnancy, delivery, and pouch function after ileal pouch-anal anastomosis for ulcerative colitis. *Dis Colon Rectum.* 2002;45:1283–1288.
114. Johnson PM, McLeod RS. Female sexuality, fertility, pregnancy, and delivery after ileal pouch anal anastomosis for ulcerative colitis. *Semin Col Rect Surg.* 2006;17:96–101.
115. da Luz Moreira A, Kiran RP, Lavery I. Clinical outcomes of ileorectal anastomosis for ulcerative colitis. *Br J Surg.* 2010;97(1):65–69.
116. Pastore RLO, Wolff BG, Hodge D. Total abdominal colectomy and ileorectal anastomosis for inflammatory bowel disease. *Dis Colon Rectum.* 1997;40:1455–1464.
117. Grundfest SF, Fazio VW, Weiss RA, et al. The risk of cancer following colectomy and ileorectal anastomosis for extensive mucosal ulcerative colitis. *Ann Surg.* 1981;193:9–14.
118. Cox CL, Butts DR, Roberts MP, Wessels RA, Bailey HR. Development of invasive adenocarcinoma in a long-standing Kock continent ileostomy. *Dis Colon Rectum.* 1997;40:500–503.
119. Hulten L, Willen R, Nilsson O, Safarani N, Haboubi N. Mucosal assessment for dysplasia and cancer in the ileal pouch mucosa in patients operated on for ulcerative colitis: a 30-year follow-up study. *Dis Colon Rectum.* 2002;45(4):448–452.
120. Forbes SS, O'Connor BI, Victor JC, Cohen Z, McLeod RS. Sepsis is a major predictor of failure after ileal pouch-anal anastomosis. *Dis Colon Rectum.* 2009;52(12):1975–1981.
121. Gemlo BT, Wong D, Rothenberger DA, Goldberg SM. Ileal pouch-anal anastomosis: patterns of failure. *Arch Surg.* 1992;127:784–787.
122. Heuschen UO, Hinz U, Allemeyer EH, et al. Risk factors for ileoanal J pouch-related septic complications in ulcerative colitis and familial adenomatous polyposis. *Ann Surg.* 2002;235:207–216.
123. Kiran RP, da Luz Moreira A, Remzi FH, et al. Factors associated with septic complications after restorative proctocolectomy. *Ann Surg.* 2010;251(3):436–440.
124. Raval MJ, Schnitzler M, O'Connor BI, Cohen Z, McLeod RS. Improved outcome due to increased experience and individualized management of leaks after ileal pouch-anal anastomosis. *Ann Surg.* 2007;246:763–770.
125. Fazio VW, Wu JS, Lavery IC. Repeat ileal pouch-anal anastomosis to salvage septic complications of pelvic pouches: clinical outcome and quality of life assessment. *Ann Surg.* 1998;228:588–597.
126. Herbst F, Sieleznoff I, Nicholls RJ. Salvage surgery for ileal pouch outlet obstruction. *Br J Surg.* 1996;83:368–371.
127. MacLean AR, O'Connor B, Parkes R, Cohen Z, McLeod RS. Reconstructive surgery for failed ileal pouch-anal anastomosis—a viable surgical option with acceptable results. *Dis Colon Rectum.* 2002;45:880–886.
128. Wexner SD, Rothenberger DA, Jensen L, et al. Ileal pouch vaginal fistulas: Incidence, etiology, and management. *Dis Colon Rectum.* 1989;32:460–465.
129. Lee PY, Fazio VW, Church JM, et al. Vaginal fistula following restorative proctocolectomy. *Dis Colon Rectum.* 1997;40:752–759.
130. Carraro PS, Nicholls RJ, Groom J. Pouch-vaginal fistula occurring 13 years after restorative proctocolectomy. *Br J Surg.* 1992;79:716–717.
131. Rossi HL, Brand MI, Saclarides TJ. Anal complications after restorative proctocolectomy (J-pouch). *Am Surg.* 2002;7:628–630.
132. Prudhomme M, Dozois RR, Godlewski G, Mathison S, Fabbro-Perray P. Anal canal strictures after ileal pouch-anal anastomosis. *Dis Colon Rectum.* 2003;46:20–23.
133. Galandiuk S, Scott NA, Dozois RR, et al. Ileal pouch-anal anastomosis. Reoperation for pouch-related complications. *Ann Surg.* 1990;212:446–452.



134. Sandborn WJ. Pouchitis following ileal pouch-anal anastomosis: definition, pathogenesis, and treatment. *Gastroenterology*. 1994;107:1856–1860.
135. Svaninger G, Nordgren S, Oresland T, Hulten L. Incidence and characteristics of pouchitis in the Kock continent ileostomy and the pelvic pouch. *Scand J Gastroenterol*. 1993;28(8):695–700.
136. Penna C, Dozois R, Tremaine W, et al. Pouchitis after ileal pouch-anal anastomosis for ulcerative colitis occurs with increased frequency in patients with associated primary sclerosing cholangitis. *Gut*. 1996;38:234–239.
137. Fleshner PR, Vasiliaskas EA, Kam LY, et al. High level perinuclear anti-neutrophil cytoplasmic antibody (pANCA) in ulcerative colitis patients before colectomy predicts the development of chronic pouchitis after ileal pouch-anal anastomosis. *Gut*. 2001;49:671–677.
138. Sandborn WJ, McLeod RS, Jewel DP. Medical Therapy for induction and maintenance of remission in pouchitis: a systematic review. *Inflamm Bowel Dis*. 1999;5:33–39.
139. Lofberg R, Brostrom O, Karlen P, Ost A, Tribukait B. DNA aneuploidy in ulcerative colitis: reproducibility, topographic distribution, and relation to dysplasia. *Gastroenterol*. 1992;102:1149–1154.
140. Veress B, Reinholdt FP, Lindquist K, Lofberg R, Liljeqvist L. Long-term histomorphological surveillance of the pelvic ileal pouch: dysplasia developments in a subgroup of patients. *Gastroenterology*. 1995;109:1090–1097.
141. Das P, Johnson MW, Tekkis PP, Nicholls RJ. Risk of dysplasia and adenocarcinoma following restorative proctocolectomy for ulcerative colitis. *Colorectal Dis*. 2007;9:15–27.
142. Thompson-Fawcett MW, Marcus V, Redston M, Cohen Z, McLeod RS. Risk of dysplasia in long-term ileal pouches and pouches with chronic pouchitis. *Gastroenterology*. 2001;121:275–281.
143. O’Riordan MG, Fazio VW, Lavery IC, et al. Incidence and natural history of dysplasia of the anal transition zone after ileal pouch-anal anastomosis: results of a five-year to ten-year follow-up. *Dis Colon Rectum*. 2000;43:1660–1665.
144. Alves A, Panis Y, Bouhnik Y, et al. Subtotal colectomy for severe colitis: a 20-year experience of a tertiary care centre with an aggressive and early surgical policy. *J Am Coll Surg*. 2003;197:379–385.
145. Ahmed Ali U, Keus F, Heikens JT, et al. Open versus laparoscopic (assisted) ileo pouch anal anastomosis for ulcerative colitis and familial adenomatous polyposis. *Cochrane Database Syst Rev*. 2009;(1):CD006267.
146. Borjesson L, Lundstam U, oresland T, Brevinge H, Hulten L. The place for colectomy and ileorectal anastomosis: a valid option for ulcerative colitis? *Tech Coloproctol*. 2006;10(3):237–241.
147. Kock NG, Brevinge H, Philipson BM, Ojerskog B. Continent ileostomy: the present technique and long term results. *Ann Chir Gynaecol*. 1986;75:63–70.
148. McLeod RS, Cohen Z, MacRae HM, O’Connor BI, Barton P. Trends over time in patients with a pelvic pouch. *C J Surg*. 1998;41(suppl):13.
149. Kennedy ED, Rothwell DM, Cohen Z, McLeod RS. Increased experience and surgical technique lead to improved outcome after ileal pouch-anal anastomosis: a population based study. *Dis Colon Rectum*. 2006;49(7):958–965.
150. Han SW, McColl E, Barton JR, et al. Predictors of quality of life in ulcerative colitis: the importance of symptoms and illness representations. *Inflamm Bowel Dis*. 2005;11(1):24–34.
151. Janke KH, Klump B, Gregor M, Meisner C, Haeuser W. Determinants of life satisfaction in inflammatory bowel disease. *Inflamm Bowel Dis*. 2005;11(3):272–286.
152. Bernklev T, Jahnsen J, Lygren I, et al. Health-related quality of life in patients with inflammatory bowel disease measured with the short form-36: psychometric assessments and a comparison with general population norms. *Inflamm Bowel Dis*. 2005;11(10):909–918.
153. Bernklev T, Jahnsen J, Schulz T, et al. Course of disease, drug treatment and health-related quality of life in patients with inflammatory bowel disease 5 years after initial diagnosis. *Eur J Gastroenterol Hepatol*. 2005;17(10):1037–1045.
154. Dunker MS, Bemelman WA, Slors JFM, van Duijvendijk P, Gouma DJ. Functional outcome, quality of life, body image, and cosmesis in patients after laparoscopic-assisted and conventional restorative proctocolectomy. *Dis Colon Rectum*. 2001;44(12):1800–1807.
155. Farouk R, Pemberton JH, Wolff BG, et al. Functional outcomes after ileal pouch-anal anastomosis for chronic ulcerative colitis. *Ann Surg*. 2000;231:919–926.
156. Fazio VW, O’Riordan MG, Lavery IC, et al. Long-term functional outcome and quality of life after stapled restorative proctocolectomy. *Ann Surg*. 1999;230:575–586.
157. Kirat HT, Remzi FH, Kiran RP, Fazio VW. Comparison of outcomes after hand-sewn versus stapled ileal pouch-anal anastomosis in 3,109 patients. *Surgery*. 2009;146(4):723–729.

*This page intentionally left blank*

# PERSPECTIVE ON INFLAMMATORY BOWEL DISEASE

Anthony J. Senagore

Fichera et al provide a comprehensive review of the surgical approach to Crohn's disease from indications for surgery to the surgical approaches to the management of the various patterns of disease.<sup>1</sup> There are several areas that may benefit from expanded coverage so that the surgeon managing this difficult chronic disease can understand more regarding some of the current areas of controversy.

## IS CROHN'S DISEASE A LYMPHOBLITERATIVE DISEASE?

The onset of Crohn's disease has consistently been blamed on a yet to be identified alteration in mucosal immune response, possible in response to an altered susceptibility to luminal bacteria or other environmental exposures.<sup>2,3</sup> Interestingly, there has been greater recognition of the consistent histopathologic changes of mucosal exudation, submucosal edema, and extensive dilation of lacteals seen in Crohn's disease lymphatics.<sup>4</sup> These findings have correlated with animal models of lymphatic sclerosing agents leading to similar findings of inflammatory bowel disease. The inflammatory response was reduced with administration of cyclooxygenase (COX) inhibitors suggesting an arachidonic acid role. It is believed that the early lymphatic obstruction blocks the transfer of inflammatory cells to regional lymph nodes and the process of lymphoid neogenesis that produces lymphoid aggregates in the mesentery. Trapping the activated B lymphocytes in the region, coupled with an ongoing pattern of neoangiogenesis of lymphatics in the intestinal wall may be causally related to the development of the disease. Further credence is given to the theory because the virtual pathognomonic finding of fat wrapping is the result of cytokine and tumor necrosis factor (TNF) release from adjacent lymphatic tissue. This response leads to hypertrophy of fat cells in the mesentery that may be related to the common finding of thickened mesentery in patients with Crohn's disease. Although considerably more work is required to fully understand the interaction of abnormal lymph drainage and mucosal inflammation, it is

intriguing to hypothesize that early resection of the draining mesentery might be an effective surgical strategy prior to the onset of chronic disease and extensive mesenteric involvement.

## AGGRESSIVE EARLY MEDICAL THERAPY VERSUS SURGICAL THERAPY

The availability of an increasing number of biologic agents capable of creating greater immunosuppression has led to the suggestion of a so called "top-down" strategy of more aggressive medical therapy at diagnosis. This is contradistinction to the more typical "bottom-up" approach of beginning with corticosteroids or even 5-aminosalicylic acid (5-ASA) preparations and escalating only after persistent symptoms. Markowitz et al reported an almost 90% remission rate in children using a strategy of corticosteroids and 6-mercaptopurine (6-MP) as induction therapy.<sup>5</sup> Similar benefits have been described with the use of either certolizumab pegol therapy, where superior response was seen in patients with disease duration of shorter than 1 year compared to patients with longer than 5 years of disease (75 vs 52%).<sup>6</sup> A prospective trial assessing patients naive to any immunomodulator reported both an improved clinical remission rate at 52 weeks (62 vs 42%) and longer time to relapse (329 vs 174 days) with a strategy of infliximab infusion and azathioprine/6-MP compared to corticosteroids and azathioprine.<sup>7</sup> Infliximab was reserved for intractable disease that failed corticosteroids initially. Proponents of the top-down approach suggest that the benefit derives from management of a predominant Th1 immune response with excessive interferon- $\gamma$  (IFN- $\gamma$ ) secretion. This response is lost with chronicity of disease accounting for a current management within a multidisciplinary approach because there still remains a 25–40% failure rate with the top-down management approach. In addition, the ACCENT-1 trial confirmed that scheduled long-term administration of infliximab was associated with a significant reduction in the development of anti-TNF antibodies



compared to episodic therapy (1 vs 38%).<sup>7</sup> This would indicate that selection of a top-down methodology could lead to expensive long-term therapy with these agents. Therefore, reassessment for medical failure may identify patients who would benefit from a surgical intervention prior to the onset of significant impact from poorly controlled inflammation, worsening nutritional onset, or masked complications from perforation. Surgical approaches may need to be modified for patients with recent exposure to anti-TNF agents, as suggested by the authors, and may require judicious use of diverting stomas to protect anastomoses in difficult cases.

The countervailing argument to aggressive early medical therapy is aggressive surgical therapy, primarily for ileocolic disease. There is limited data available comparing quality of life and cost-effectiveness for early surgery versus top-down medical therapy. Aratari et al reported on a retrospective analysis of patients and found that “early” operated patients had prolonged clinical remission.<sup>8</sup> An interesting survey study demonstrated that gastroenterologists had a 2-fold higher desire to prevent an ileocolic resection compared to either colorectal surgeons or patients.<sup>9</sup> These data support the same potential benefit of earlier intervention in localized Crohn’s disease prior to the onset of a more problematic and difficult-to-manage inflammatory response. A current prospective randomized trial being performed in the Netherlands assessing the role of early resection of terminal ileal Crohn’s disease should provide interesting data regarding risk of complications versus restoration of quality of life. The risk and timing of recurrent disease will also be an important outcome of the study. One could see an evolving strategy of early laparoscopic resection of localized terminal ileal disease with the aggressive top-down strategy reserved for early surgical recurrences or patients with multisegment disease.

## THE ROLE OF PROPHYLACTIC MEDICAL THERAPY POSTRESECTION

As outlined by Fichera et al, surgical management is highly effective in managing complications of Crohn’s disease, including obstruction, fistula, and perforation.<sup>1</sup> Surgery is highly effective at restoring quality-of-life measures. However, current data suggest that 70–80% of patients will develop mucosal evidence of disease within 1 year postresection that is highly correlated with clinical recurrence. Approximately 25–30% of patients will develop significant recurrences requiring repeat surgical resection within 5 years and almost 70% of patients will need an additional surgical procedure by 10 years. Options for prophylaxis include probiotics. A variety of different bacteria have been assessed in probiotic formulae for Crohn’s prophylaxis further complicating assessment. However, two recent meta-analyses failed to identify a benefit associated with probiotic whether it be clinical or endoscopic recurrence.<sup>10,11</sup> Conversely, two limited trials suggested that nitroimidazole antibiotics may be beneficial in reducing clinical recurrence.<sup>12</sup> These data are limited and would require confirmatory data prior to widespread adoption. Mesalamine is probably the best evaluated anti-inflammatory agent assessed as a postresection prophylactic strategy in Crohn’s disease. The Cochrane meta-analysis reported a modest but sig-

nificant benefit for this strategy with a risk ratio of 0.76 (0.62, 0.94).<sup>13</sup> Azathioprine also enjoys a long history of evaluation and has demonstrated superiority over 5-ASA treatment albeit at an increased risk for adverse treatment events. Given these current data, a reasonable clinical strategy may be to withhold prophylaxis in patients with localized and fully resected disease and reserve prophylaxis for early recurrence or multiple prior resections. It would also be reasonable to consider prophylaxis when resection is combined with stricturoplasty.

## CONCLUSION

The ongoing work in evaluating the immunologic components of Crohn’s disease, and the related proteogenomic assessments may lead to a better understanding of the initial insult in patients with this complicated chronic disorder. The hope remains for refined and focused clinical strategies that minimize the impact of chronic illness and/or treatment-related morbidity while restoring quality of life. The authors are to be commended on an excellent clinical review of this broad topic.

## REFERENCES

1. Fichera A, Michelassi F. Surgical treatment of Crohn’s disease. *J Gastrointest Surg.* 2007;11(6):791–803.
2. Biswas A, Petnicki-Ocwieja T, Kobayashi KS. Nod2: a key regulator linking microbiota to intestinal mucosal immunity. *J Mol Med (Berl).* 2012;90(1):15–24.
3. Ng SC, Benjamin JL, McCarthy NE, Hedin CR, Koutsoumpas A, Plamondon S, Price CL, Hart AL, Kamm MA, Forbes A, Knight SC, Lindsay JO, Whelan K, Stagg AJ. Relationship between human intestinal dendritic cells, gut microbiota, and disease activity in Crohn’s disease. *Inflamm Bowel Dis.* 2011;17(10):2027–2037.
4. von der Weid P, Rainey KJ. Review article: lymphatic system and associated adipose tissue in the development of inflammatory bowel disease. *Alimentary Pharmacological Therapy.* 2010;32(6):697–711.
5. Markowitz J, Grancher K, Kohn N, Lesser M, Daum F. A multicenter trial of 6-mercaptopurine and prednisone in children with newly diagnosed Crohn’s disease. *Gastroenterology.* 2000;119(4):895–902.
6. Schreiber S, Colombel JF, Bloomfield R, Nikolaus S, Schölmerich J, Panés J, Sandborn WJ; PRECiSE 2 Study Investigators. Increased response and remission rates in short-duration Crohn’s disease with subcutaneous certolizumab pegol: an analysis of PRECiSE 2 randomized maintenance trial data. *Am J Gastroenterol.* 2010;105(7):1574–1582.
7. Hanauer SB, Feagan BG, Lichtenstein GR, Mayer LF, Schreiber S, Colombel JF, Rachmilewitz D, Wolf DC, Olson A, Bao W, Rutgeerts P, and the ACCENT I Study Group\*. Maintenance infliximab for Crohn’s disease: the ACCENT I randomised trial. *Lancet.* 2002;359: 1541–1549.
8. Aratari A, Papi C, Leandro G, Viscido A, Capurso L, Caprilli R. Early versus late surgery for ileo-caecal Crohn’s disease. *Aliment Pharmacol Ther.* 2007;26(10):1303–1312.
9. Byrne CM, Solomon MJ, Young JM, Selby W, Harrison JD. Patient preferences between surgical and medical treatment in Crohn’s disease. *Dis Colon Rectum.* 2007;50(5):586–597.
10. Doherty GA, Bennett GC, Cheifetz AS, Moss AC. Meta-analysis: targeting the intestinal microbiota in prophylaxis for post-operative Crohn’s disease. *Aliment Pharmacol Ther.* 2010;31(8):802–809.
11. Shen J, Ran HZ, Yin MH, Zhou TX, Xiao DS. Meta-analysis: the effect and adverse events of Lactobacilli versus placebo in maintenance therapy for Crohn disease. *Intern Med J.* 2009;39(2):103–109.
12. Rolfe VE, Fortun PJ, Hawkey CJ, Bath-Hextall F. Probiotics for maintenance of remission in Crohn’s disease. *Cochrane Database Syst Rev.* 2006;(4):CD004826.
13. Feller M, Huwiler K, Schoepfer A, Shang A, Furrer H, Egger M. Long-term antibiotic treatment for Crohn’s disease: systematic review and meta-analysis of placebo-controlled trials. *Clin Infect Dis.* 2010;50(4):473–480.

# PERSPECTIVE ON INFLAMMATORY BOWEL DISEASE (ULCERATIVE COLITIS AND CROHN'S DISEASE)

Patricia L. Roberts

Ulcerative colitis and Crohn's disease, collectively known as *inflammatory bowel disease* (IBD), are estimated to affect 2–6% of the population of the United States. Despite advances in medical therapy and a larger number of effective medications for treatment of this disease, up to 46% of patients with ulcerative colitis and 80% of patients with Crohn's disease ultimately require surgery.<sup>1,2</sup> While many of the operative procedures have remained the same, the approach has changed with the advent of minimally invasive surgery. Laparoscopic colorectal surgery, initially reported in the 1990s, has increased in frequency and is associated with a faster recovery, potentially less complications, better cosmesis, and a shorter length of stay.

The goals of medical therapy for IBD include controlling symptoms of the disease, inducing remission, improving quality of life, and minimizing the complications of the disease and treatment. While surgical intervention is aimed at treating both complications of IBD and intractability to medical management, the timing and role of surgical therapy has become more complex. Surgery should be aimed at optimizing quality of life and at not unnecessarily delaying the inevitable if an operation is required. Additional considerations include the role of biologic agents and the optimal timing of surgery. Furthermore, the Internet has increased access to information for patients and providers, and patients appear to be better educated about their disease and about further therapies. These additional considerations mandate close interaction and consultation with the patient and all providers, including the gastroenterologist, surgeon, primary care physician, and enterostomal nurse.

The cause of IBD remains elusive, but there is increasing evidence of a genetic predisposition to ulcerative colitis and Crohn's disease. The association is strongest in patients

with Crohn's disease where three mutations of the *NOD2/CARD15* gene affecting the short arm of chromosome 16 have been identified as being associated with the disease.<sup>3,4</sup> Mutations in the gene are found in 10–30% of patients with Crohn's disease and are associated with ileal disease, earlier age of onset, and possibly fibrostenosing characteristics. The relative risk of developing Crohn's disease in patients with such mutations is 10–40 times that of the general population.<sup>5</sup> Genetic predictors of patients who have medically refractory ulcerative colitis are also being explored.<sup>6</sup>

A major development in the treatment of IBD in the last two decades has been a number of randomized clinical trials on the use of infliximab, both for Crohn's disease and more recently for ulcerative colitis. Infliximab was shown to be effective for inflammatory disease in 1997 and for perforating disease in 1999.<sup>7,8</sup> Infliximab was subsequently shown to be effective for maintenance therapy in Crohn's disease in 2002.<sup>9</sup> More recently, it has proven effective for use in ulcerative colitis.<sup>10</sup>

The role of infliximab is best defined in patients with Crohn's disease where it has been used to treat and induce remission in patients with moderate to severe Crohn's disease. Infliximab is also effective in patients with corticosteroid-dependent disease and fistulizing disease and may decrease extraintestinal manifestations such as arthralgias and pyoderma gangrenosum. More recently, it has been suggested that infliximab be given earlier in the course of the disease and with an immunomodulator such as azathioprine. Such treatment has been termed "top-down therapy," and several studies have shown improved outcome for induction of remission and reduction in corticosteroid use.<sup>11</sup>

Additional concerns about infliximab include the impact on postoperative complications, wound healing, and the

development of infections. The data are limited with two retrospective studies showing that use of infliximab in patients with Crohn's disease within 8–12 weeks of surgery was not associated with an increased risk of postoperative complications<sup>12,13</sup> and another retrospective series showing an increase in the rate of postoperative sepsis, abscess, and hospital readmission.<sup>14</sup> For ulcerative colitis, some have suggested that a three-stage ileoanal pouch procedure with initial colectomy and ileostomy should be considered in patients with refractory ulcerative colitis on infliximab because of the increased risk of infectious complications.<sup>15</sup>

The cost of infliximab is considerable and could potentially be offset by a decrease in the rate of hospitalization and the rate of surgery for Crohn's disease. Infliximab was approved by the Food and Drug Administration (FDA) for treatment of Crohn's disease in 1998 and for treatment of ulcerative colitis in 2006. According to Centocor, 390,000 patients with IBD have been treated with infliximab since 1998.<sup>16</sup> Two studies suggested a decrease in the number of hospitalizations and operations.<sup>17,18</sup> In a retrospective single-institution study of 79 patients with Crohn's disease, 1 year after treatment with infliximab, the rate of hospitalization and gastrointestinal surgery decreased by 18% and the rate of all surgeries decreased by 66%.<sup>17</sup> An additional study that looked at fistulizing Crohn's disease found a 50% reduction in the mean number of all surgeries in patients receiving infliximab compared to the placebo group.<sup>18</sup> These studies were from single institutions, and data from the Nationwide Inpatient Sample, the largest all payer database of hospitalized patients in the United States, suggest otherwise. Data from the Nationwide Inpatient Sample was combined with census data to look at trends in population-based rates of treatment for IBD from 1998 through 2005.<sup>16</sup> These trends are most likely reflective of use of infliximab for Crohn's disease as use of infliximab was not approved by the FDA for treatment of ulcerative colitis until 2006. The rates of hospitalization for both Crohn's disease and ulcerative colitis increased by 5.1 and 3.4% per year ( $p < .001$ ) from 1998 through 2005, respectively, while the overall rate of surgery did not change.<sup>16</sup> An additional analysis of health care utilization among patients with Crohn's disease using infliximab in Manitoba, Canada also showed an increase in hospitalizations for 18–24 months after initial prescription of infliximab, which fell to the level of hospitalization of the azathioprine and steroid group at 2–5 years time.<sup>19</sup> The likelihood of surgery was still greater in the infliximab group than in the group who were treated with azathioprine and the group not prescribed these drugs for up to 36 months. Thus, although small single-institution studies show decreased hospitalizations and decreased surgeries, larger population-based studies suggest that the rate of hospitalization has actually increased and the rate of surgery has not decreased.

Because the medical therapy of ulcerative colitis and Crohn's is similar, there is less importance to distinguish between ulcerative colitis and Crohn's disease. However, distinguishing the two entities is of paramount importance in patients being considered for surgery for colitis, because

the ileoanal pouch procedure is generally not an option for patients with Crohn's colitis because of the high risk of recurrence and pouch failure in over one-third of patients with an ultimate diagnosis of Crohn's disease.

Biologics such as infliximab and adalimumab have also had an expanding role in patients with Crohn's disease–like complications following ileoanal pouch-anal anastomosis (IPAA). Such complications include antibiotic-resistant pouchitis, complex fistula of the pouch and/or small bowel, and stricturing and inflammation of the afferent limb of the pouch. There is no consensus about how to manage such patients medically, but overall goals include attempting to improve quality of life, preserving the pouch, and avoiding pouch failure. Generally, a combination of antibiotics, 5-aminosalicylic acid products, steroids, immunomodulators, and biologics such as infliximab and adalimumab has been used. While ileoanal pouch fistulizing disease is associated with a high pouch failure rate and a high rate of the need for fecal diversion, a number of studies have shown that over 50% of patients with fistulizing disease may be successfully treated with immunomodulators and biologics<sup>20–23</sup> while stricturing disease does not respond to biologics.<sup>23</sup>

Looking specifically at surgery for ulcerative colitis, since the late 1970s when the ileoanal pouch operation was described by Parks and Nicholls, the operation has become the preferred procedure of choice for the majority of patients undergoing surgery for ulcerative colitis. Excellent long-term results have been established in the majority of patients undergoing the procedure. Proctocolectomy and ileostomy remains a viable option, and quality-of-life studies have shown equivalent quality of life with the ileoanal pouch procedure, suggesting the colectomy is related to the improvement not necessarily the avoidance of a stoma. While the majority of patients do well, there are a number of ongoing concerns and complications of the procedure.

The most frequent long-term complication of the operation is the development of pouchitis, a nonspecific inflammation of the ileal pouch mucosa. Pouchitis is a clinical syndrome of increased stool frequency, rectal bleeding, abdominal cramping, blood and mucus. While many patients have an acute episode of pouchitis, a small subset of patients develops chronic pouchitis, which is a potential cause of pouch failure and poor quality of life. The cause of pouchitis remains elusive; it is disease-specific and most commonly seen in patients with ulcerative colitis and is uncommon in patients with familial adenomatous polyposis. Pouchitis has been called the "Achilles heel" of the ileoanal pouch operation, and further understanding of the etiology and ways to prevent this complication would benefit a number of patients.

Following construction, the ileoanal pouch undergoes a number of histologic changes and, with time, the metaplastic changes result in the ileal mucosa resembling colonic mucosa. These changes may also occur because of inflammation in the pouch and raise concern about the development of dysplasia and cancer in the pouch of the rectal remnant. Less than 20 cancers arising in the ileoanal pouch or transition zone have been reported with the majority of patients having cancer or



dysplasia in the original operative specimen.<sup>24</sup> As patients age, there has been increasing concern about the development of cancer or dysplasia and whether a surveillance program is justified. In a cohort of 160 patients in which over 50 % of the pouches were older than 10 years with over 1800 pouch years of surveillance, we found only one patient who had focal low-grade dysplasia of the pouch.<sup>25</sup> The most recent guidelines of the American Society of Colon and Rectal Surgeons have found insufficient evidence to endorse a surveillance program for ileoanal pouch patients.<sup>26</sup> Surveillance should be considered in higher-risk group patients, including those with dysplasia or carcinoma in the original specimen, type C ileal mucosal changes, and those with sclerosing cholangitis.<sup>24</sup> Biopsies should be obtained of the pouch and the rectal remnant (anorectal mucosa) distal to the ileoanal anastomosis.

The ileoanal pouch procedure is increasingly performed by a laparoscopic approach. Adoption rates are low across the country and data from the Nationwide Inpatient Sample suggest that less than 10% of ileoanal pouches across the United States are done laparoscopically. Retrospective case-matched comparative studies have shown a longer operative time (median 330 vs 230 minutes) but a quicker return of bowel function (2 vs 4 days) and a shorter hospital stay (7 vs 8 days) with a laparoscopic approach.<sup>27</sup> A recent meta-analysis of 10 studies with 329 patients confirmed that despite a longer operative time, patients had a lower blood loss, shorter hospital stay, and a smoother postoperative recovery compared to open surgery.<sup>28</sup> In a review of 100 laparoscopic versus 189 open ileoanal pouch procedures for ulcerative colitis, patients reported excellent body image and quality-of-life scores regardless of an open or laparoscopic approach.<sup>29</sup> Laparoscopic surgery is associated with fewer adhesions and may be associated with a lower incidence of small bowel obstruction and infertility although the data are largely speculative at present.

There are some additional considerations for the surgeon in approaching the operative management of Crohn's disease. Surgery should be planned with the caveat that there is no medical or surgical cure for the disease, the disease tends to recur, and that over the course of a lifetime patients may have a number of procedures. As such, there is no need to perform resection with wide margins and resection to grossly normal bowel is advisable. There is no role for frozen sections. Determining the extent of small bowel disease is performed intraoperatively by palpating (pinching) the mesenteric fat along the border with the bowel. With fat wrapping, the two opposing fingers cannot be well-palpated, but with normal uninvolved bowel palpation of the two opposing fingers is quite easy. My preference is to open the resected bowel in the operating room to assess the margins. Despite imaging and endoscopy preoperatively, the surgeon must be prepared to encounter "surprise" or unanticipated findings during surgery, including unsuspected abscesses or fistulas. Small bowel adenocarcinoma may be detected in patients who have long-standing stable disease with abrupt change in symptoms. Division of the mesentery can be challenging in Crohn's disease, and it is advisable to stay closer to the bowel. If bleeding occurs, the

mesentery can be resected or suture-ligated more proximally. My preference is to use various vessel sealing devices for difficult Crohn's mesenteries.

All efforts should be made to preserve bowel length as Crohn's patients may require multiple resections over the years. Strictureplasty, a technique, adopted from tuberculous strictures, is a useful technique in patients who have multiple diffuse small bowel strictures or in patients with strictures who have had prior resections. Large bowel strictures are generally not amenable to strictureplasty.

As with ulcerative colitis, a laparoscopic approach is favored for selected cases. Patients with ileocolic disease undergoing their first resection are the more ideal candidates for laparoscopic resection. A meta-analysis examined 783 patients who underwent ileocolic resection for Crohn's disease, including 338 who had a laparoscopic approach.<sup>30</sup> Operative time was longer in the laparoscopic groups, although overall costs were the same. Patients in the laparoscopic group had a shorter length of stay and shorter time to first bowel movement and resuming a diet. Although complicated Crohn's disease may be approached laparoscopically, patients who have had multiple prior procedures, have disease in multiple sites, and who have a palpable mass or phlegmon generally require an open approach.

In summary, there have been a number of changes to both the medical and surgical approach to IBD in the last decade. Biologics have afforded patients periods of remission. While laparoscopic surgery has been adopted slowly, accumulating evidence shows quicker recovery, fewer complications, less trauma, less adhesions, and potentially enhanced fertility with a minimally invasive approach.

## REFERENCES

- Hilsden RJ, Verhoef MJ, Best A, Pocobelli G. A national survey on the patterns of treatment of inflammatory bowel disease in Canada. *BMC Gastroenterol.* 2003;3:10.
- Yu AP, Cabanilla LA, Wu EQ, et al. The cost of Crohn's disease in the US and other Western countries: a systematic review. *Curr Med Res Opin.* 2008;24:319–328.
- Ogura Y, Bonen DK, Inohara N, et al. A frameshift mutation in NOD2 associated with susceptibility to Crohn's disease. *Nature.* 2001;411(6837):603–606.
- Hugot JP, Chamaillard M, Zouali H, et al. Association of NOD2 leucine-rich repeat variants with susceptibility to Crohn's disease. *Nature.* 2001;411:559–603.
- Lessage S, Zouali H, Cezard JP, et al. CARD 15/NOD2 mutational analysis and genotype-phenotype correlation in 612 patients with inflammatory bowel disease. *Am J Hum Genet.* 2002;70:845–857.
- Haritunians T, Taylor KD, Targan SR, et al. Genetic predictors of medically refractory ulcerative colitis. *Inflamm Bowel Dis.* 2010;16(11):1830–1840.
- Targan SR, Hanauer SB, van Deventer SJ, et al. a short-term study of chimeric monoclonal antibody cA2 to tumor necrosis factor alpha for Crohn's disease. Crohn's Disease cA2 Study Group. *N Engl J Med.* 1997;337:1029–1035.
- Present DH, Rutgeerts P, Targan S, et al. Infliximab for the treatment of fistulas in patients with Crohn's disease. *N Engl J Med.* 1999;240:1398–1405.
- Hanauer SB, Feagan BG, Lichtenstein GR, et al. Maintenance infliximab for Crohn's disease: the ACCENT I randomized trial. *Lancet.* 2002;359:1541–1549.

10. Rutgeerts P, Sandborn WJ, Feagan BG, et al. Infliximab for induction and maintenance therapy for ulcerative colitis. *N Engl J Med.* 2005;353:2462–2475.
11. D'Haens G, Baert F, van Assche G, et al. Early combined immunosuppression or conventional management in patients with newly diagnosed Crohn's disease: an open randomized trial. *Lancet.* 2008;371(9613):660–667.
12. Colombel JF, Loftus EV, Jr, Tremaine WJ, et al. Early postoperative complications are not increased in patients with Crohn's disease treated perioperatively with infliximab or immunosuppressive therapy. *Am J Gastroenterol.* 2004;99(5):878–883.
13. Kunitake H, Hodin R, Shellito PC, Sands BE, Korzenik J, Bordeianous L. Perioperative treatment with infliximab in patients with Crohn's disease and ulcerative colitis is not associated with an increased rate of postoperative complications. *J Gastrointest Surg.* 2008;12(10):1730–1736.
14. Appau KA, Fazio VW, Shen B, et al. Use of infliximab within 3 months of ileocolonic resection is associated with adverse postoperative outcomes in Crohn's patients. *J Gastrointest Surg.* 2008;12(10):1738–1744.
15. Selvasekar CR, Cima RR, Larson DW, et al. Effect of infliximab on short-term complications in patients undergoing operation for chronic ulcerative colitis. *J Am Coll Surg.* 2007;204(5):956–962.
16. Cannom RR, Kaiser AM, Ault GT, et al. Inflammatory bowel disease in the United States from 1998 to 2005: has infliximab affected surgical rates? *Am Surg.* 2009;75:976–980.
17. Rubenstein JH, Chong RY, Cohen RD. Infliximab decreases resource use among patients with Crohn's disease. *J Clin Gastroenterol.* 2002;35:151–156.
18. Lichtenstein GR, Yan S, Bala M, et al. Infliximab maintenance treatment reduces hospitalizations, surgeries and procedures in fistulizing Crohn's disease. *Gastroenterology.* 2005;128:862–869.
19. Nugent Z, Blanchard JF, Bernstein CN. A population-based study of health-care resource use among infliximab users. *Am J Gastroenterol.* 2010;105:2009–2016.
20. Shen B, Remzi FH, Lavery IC, et al. Administration of adalimumab in the treatment of Crohn's disease of the ileal pouch. *Aliment Pharmacol Ther.* 2009;29:519–526.
21. Ferrante M, D'Haens G, Dewit O, et al. Efficacy of infliximab in refractory pouchitis and Crohn's disease-related complications of the pouch: a Belgian case series. *Inflamm Bowel Dis.* 2010;16:243–249.
22. Viscido A, Habib FI, Kohn A, et al. Infliximab in refractory pouchitis complicated by fistulae following ileo-anal pouch for ulcerative colitis. *Aliment Pharmacol Ther.* 2003;17:1263–1271.
23. Haveran LA, Sehgal R, Poritz LS, et al. Infliximab and/or azathioprine in the treatment of Crohn's disease-like complications after IPAA. *Dis Colon Rectum.* 2011;54:15–20.
24. Das P, Johnson MW, Tekkis PP, Nicholls RJ. Risk of dysplasia and adenocarcinoma following restorative proctocolectomy for ulcerative colitis. *Colorectal Dis.* 2007;9:15–27.
25. Herline AJ, Meisinger LL, Rusin LC, et al. Is routine pouch surveillance for dysplasia indicated for ileoanal pouches. *Dis Colon Rectum.* 2003;46:156–159.
26. Cohen JL, Strong SA, Hyman NH, et al. Practice parameters for the surgical treatment of ulcerative colitis. *Dis Colon Rectum.* 2005;48:1997–2009.
27. Marcello PW, Milsom JW, Wong SK, et al. Laparoscopic restorative proctocolectomy: case-matched comparative study with open restorative proctocolectomy. *Dis Colon Rectum.* 2000;43:604–608.
28. Tilney HS, Lovegrove RE, Heriot AG, et al. Comparison of short-term outcomes of laparoscopic vs. open approaches to ileal pouch surgery. *Int J Colorectal Dis.* 2007;22:531–542.
29. Larson DW, Davies MA, Dozois EJ, et al. Sexual function, body image and quality of life after laparoscopic and open ileal pouch-anal anastomosis. *Dis Colon Rectum.* 2007;51:392–396.
30. Tilney HS, Constantinides VA, Heriot AG, et al. Comparison of laparoscopic and open ileocecal resection for Crohn's disease: a meta analysis. *Surg Endosc.* 2006;20:1036–1044.

# TUMORS OF THE COLON

Andreas M. Kaiser • David Etzioni • Robert W. Beart, Jr.

## INTRODUCTION

*Tumor* is a descriptive term for a growth or mass of cells that are independent of the physiologic function or demand of their surrounding structures. The two characteristic biological growth patterns of tumors include the ability to (1) disrespect tissue boundaries and invade other structures (*invasiveness*) and (2) gain access to blood and lymph vessels or other structures to spread tumor cells to distant locations, and allow these specially equipped cells to survive and grow new remote tumors (*metastases*). If a tumor does not have either property, it is *benign*; if a tumor can invade locally but even at a large size does not have a tendency to metastasize, it is called *semi-malignant*; and if a tumor has the ability to metastasize once a sufficient size is reached, it is a *malignant* tumor.

Colorectal lesions may be classified as either benign, potentially malignant, or malignant based on their pathological features (Table 36–1); the semimalignant variant with invasion only but no affinity to later form of metastases is not common in the colon. The overwhelming majority of colorectal tumors are of epithelial origin and arise from the mucosal surface, where they become visible descriptively as a polyp. Benign polyps include nonneoplastic polyps (eg, hyperplastic, hamartomatous, or inflammatory polyps); the potentially malignant group consists of adenomatous polyps. Once dysplastic cells in a polyp cross the boundaries of the mucosa (basement membrane and muscularis mucosae) and start to invade the submucosa and the muscularis mucosae, a true cancer (carcinoma) with the potential to metastasize is established. Tumors of nonepithelial or mesenchymal origin are comparably rare and include, among others, lipoma, lymphoma, carcinoid, and sarcoma.<sup>1–3</sup>

Colonic tumors are important for two reasons: First, they are frequent and account for both a significant mortality rate as well as high cumulative health care costs. Second, the sequence of events leading from a normal mucosa to a manifest cancer occurs through largely preventable precursor stages over the course of several years. This chapter therefore

predominantly focuses on the detection, management, and prevention of these conditions.

## EPIDEMIOLOGY

Colorectal cancer is the most common malignancy in the gastrointestinal tract. In the United States, colorectal cancer ranks fourth in terms of both gender-specific annual cancer incidence and cancer mortality (behind lung, prostate, and breast, respectively).<sup>4</sup> With an estimated 146,970 newly diagnosed cases, this disease will be responsible for an estimated 49,920 deaths or 10–15% of cancer-related deaths in the year 2009.<sup>4,5</sup> The lifetime risk of approximately 6% in our Western civilization means that 1 in 18 individuals of the general population will be affected by colorectal cancer and many more by polyps, making it an important public health issue.<sup>6</sup> Worldwide, colorectal cancer shows large geographical differences, with a crude incidence of 6.5/7.7 cases per 100,000 females/males in less developed areas as opposed to 50.9/60.8 in more developed regions.<sup>7</sup>

The colorectal cancer incidence has evolved in recent years to an overall predominance of males who represent in 51.4% of the cases.<sup>4,8</sup> Rectal cancer is more frequent in males (57.7%), while colon cancer is slightly more frequent in females, resulting in almost identical overall mortality rates for both genders.<sup>4</sup> The incidence of colorectal cancer in females is 44.8 per 100,000 and in males 61.2. Regardless of ethnicity, there is an age-dependent increase in incidence with each decade starting at age of 40 years, and the mean age at presentation is around 70–75 years.

In the period between 1975 and 2006, the Surveillance, Epidemiology and End Results (SEER) Registry of the National Cancer Institute (NCI) shows a gradual decline in all cases of colorectal cancer in the United States from 69.7 to 50.6 cases per 100,000.<sup>9</sup> However, although these numbers reflect the trend in Caucasians, the incidence of colorectal cancer in the United States for African Americans has remained at the same level of 59.3–61.5 cases per 100,000 individuals. African American males therefore now represent the ethnic subgroup with the highest risk.<sup>10,11</sup>



 **TABLE 36-1: INTRODUCTION: CLASSIFICATION OF COLON TUMORS**
**A. Epithelial Tumors of the Colon**

Type	Class	Subclassification
Benign lesions	Hyperplastic polyps	—
	Noninherited gastrointestinal polyposis syndromes	Hyperplastic polyposis
	Hamartomas	Juvenile polyps Cowden syndrome Bannayan-Riley-Ruvalcaba syndrome Cronkite-Canada syndrome
	Inflammatory polyps	—
Potentially malignant lesions/ syndromes	Adenomatous polyps	Sporadic colon cancers Hereditary colon cancers
	Hereditary adenomatous polyposis syndromes	Familial adenomatous polyposis (FAP) Attenuated familial adenomatous polyposis (AFAP)
	Noninherited gastrointestinal polyposis syndromes	Cronkite-Canada syndrome
	Inherited hamartomatous polyposis syndromes	Juvenile polyposis syndromes Peutz-Jeghers syndrome
Malignant lesions	Epithelial tumors of the colon	Sporadic colon cancers Familial colorectal cancer Hereditary nonpolyposis colon cancers (HNPCC) Familial/Hereditary polyposis coli cancers

**B. Nonepithelial Tumors of the Colon**

Type	Class
Benign lesions	Lipomas and lipomatous polyposis
Potentially malignant lesions/ syndromes	Carcinoid/neuroendocrine tumors
	Gastrointestinal stromal tumors (GIST)
	Nodular lymphoid hyperplasia of the colon
Malignant lesions	Lymphoma

**C. Secondary Tumors to the Colon**

Type	Class
Benign lesions	Endometriosis
Potentially malignant lesions/ syndromes	Leukemia
	Endometriosis transforming to cancer
Malignant lesions	Lymphoma
	Malignant melanoma
	Carcinomas from other primary sites

## RISK FACTORS, PREVENTION AND SCREENING

The specific cause of colorectal cancer is not known. However, a number of genetic and environmental risk factors have been associated with the disease.<sup>12</sup> From a practical and screening standpoint, it has been helpful to group individuals into three

risk categories (ie, average risk, increased risk, high risk) based on their presumptive genetic profile as reflected in their individual and family history.<sup>13,14</sup> The high-risk and increased-risk groups consist of patients with known hereditary syndromes or bowel diseases or patients with a personal/family history of polyps or cancer, all of which are discussed in a later section of the chapter (Table 36-2).


**TABLE 36-2: COMPARISON OF MAJOR RISK CATEGORIES**

	SCC	FAP	HNPCC	IBD
Variants		AFAP, Gardner, Turcot	Lynch I/II	Ulcerative colitis Crohn's disease
Genetics		+ Autosomal-dominant	+ Autosomal-dominant	?
Genes	Chromosomal deletions, <i>K-ras</i> , <i>DCC</i> , <i>p53</i> , <i>APC</i>	<i>APC</i>	<i>MSH2</i> , <i>MLH1</i> , <i>PMS1/2</i> , <i>MSH6</i>	?
Age of onset	>40 y Average 70–75	Polyps start after age 10–20, cancer in 100% at age 40	<50 y	Any, often young patients
Number of polyps	Variable, <10	>100	<10	Inflammatory pseudopolyps
Risk	5–6% of population	100%	>80%	Depending on age at onset, duration of disease, extent of active disease
Location	Left > right colon	Any location	Right > left colon	Active disease
Chemoprevention	NSAID? vitamins? calcium?	NSAID	?	IBD suppression?
Screening	> 50 y (45 y in African Americans)	>10–15 y Genetic counseling	>25 or 10–15 y before cancer onset in youngest family member Genetic counseling	7 y post onset, annually
Associated risks	?	Desmoids	Endometrium and other cancers	Extracolonic disease

AFAP, attenuated FAP; FAP, familial polyposis syndromes; HNPCC, hereditary nonpolyposis colon cancer; IBD, inflammatory bowel disease; NSAID, nonsteroidal anti-inflammatory drug; SCC, sporadic colon cancer.

The majority of cases, however, are sporadic colon cancers that typically arise within a polyp. Geographic and migrational studies have suggested that the Western lifestyle increases the risk for colon cancer, hence suggesting that nutritional and environmental factors may play a key role.<sup>15</sup> A large number of epidemiological studies have been undertaken to identify these individual, nutritional, lifestyle, genetic, and environmental factors that would either predispose to or prevent the development of colorectal polyps and cancer (Table 36-3).<sup>16–21</sup>

## Extrinsic Risk Factors

### DIETARY FIBER, MEAT, AND FAT

One of the characteristics of a Western diet generally has been the lack of fiber as opposed to the increased amount of meat, total fat, and animal fats.<sup>23,24</sup> In view of the known geographic differences, with the highest colorectal cancer incidence in industrialized nations,<sup>7</sup> a high-fat and low-fiber diet generally has been considered a risk factor for the development of colorectal cancer.<sup>25</sup> This concept gained support from epidemiological studies<sup>26</sup> and resulted in common recommendations of high-fiber supplements in order to increase the stool bulk, dilute toxins, and reduce the colonic transit time and thus the exposure time to fecal carcinogens.<sup>27–30</sup> More

recent prospective trials, however, have questioned the benefit of dietary fiber supplementation in that they were at best inconclusive and did not reduce the incidence of colorectal cancer.<sup>31,32</sup> On the other hand, selected fats such as *n*-3 fatty acids found in fish oils may have a protective effect,<sup>33</sup> even though a direct effect to the mucosa could not be observed.<sup>34</sup> It therefore could be concluded that the total amount of fats or fibers is of lesser importance than their quality and origin.<sup>21,23,35</sup> The protective effect of vegetables and fruits<sup>36,37</sup> may come not only from their fiber content but also from the content of antioxidative and antiproliferative agents such as isothiocyanates in cruciferous vegetables (eg, broccoli), which may enhance the expression of carcinogen-metabolizing enzymes and induce apoptosis in neoplastic cells.<sup>18,38</sup>

### CALCIUM, VITAMINS, AND MICRONUTRIENTS

Several prospective studies suggested that increased oral calcium and selenium intake may protect from colorectal polyps and cancers,<sup>39–44</sup> whereas other studies could not verify a significant benefit.<sup>45</sup> The mechanism by which calcium supplements are thought to reduce the risk of colon cancer is twofold. First, calcium can bind bile and fatty acids in the stool to insoluble complexes that are less likely to attack the colonic mucosa, and second, it can interfere directly with the mucosal cells and decrease their proliferative potential on a cellular level.<sup>26</sup>

**TABLE 36-3: RISK FACTORS ASSOCIATED WITH COLON CANCER**

Risk Factor	Comment
Geographic variation	Highest risk in Western countries and lowest in developing countries
Age	Risk increase sharply after the fifth decade
Diet	Increased with total and animal-fat diets
Physical inactivity	Increased with obesity and sedentary lifestyle
Adenoma	Risk dependent on type and size
FAP penetrance in gene carriers	100%
HNPCC penetrance in gene carriers	80%
Hamartomatous syndromes	Risk increased with Peutz-Jeghers syndrome and juvenile polyposis but not isolated juvenile polyps
Previous history of colon cancer	Increased risk for recurrent cancer
Ulcerative colitis	10-20% after 20 y
Radiation	Associated with a mucinous histology and poor prognosis
Ureterosigmoidostomy	100-500 times increased risk at or adjacent to the ureterocolonic anastomosis

FAP, familial polyposis syndromes; HNPCC, hereditary nonpolyposis colon cancer.

Data from Wu JS, Fazio VW. Colon cancer. *Dis Colon Rectum*. 2000;43(11):1473-1486.<sup>22</sup>

Several vitamins were found to have a cancer-protective effect. Vitamins A, C, and E have been shown to have antioxidant activity. Results from interventional studies, however, have remained somewhat disappointing or controversial.<sup>46,47</sup>

In a study on postmenopausal women, another correlation was found between dietary heme iron and an increased risk of proximal colon cancer, especially in conjunction with alcohol consumption, whereas intake of dietary zinc reduced the risk of both proximal and distal colon cancer.<sup>48</sup>

### ASPIRIN AND COX-2 INHIBITORS

Aspirin and other nonsteroidal anti-inflammatory drugs (NSAIDs) may interfere with the development of colorectal neoplasms by blocking the cyclooxygenase (COX)-dependent prostaglandin pathway.<sup>49</sup> The targets are the constitutive COX-1, as well as the cytokine-inducible COX-2, which has been found at increased expression levels in both polyps and cancers.<sup>50</sup> Several trials therefore have studied these agents (eg, aspirin and sulindac)

for the chemoprevention of colorectal cancer both in sporadic polyps and cancers<sup>51</sup> and in familial adenomatous polyposis (FAP).<sup>52-54</sup> In both settings, controlled studies have provided contradictory results.<sup>55</sup> Regular prophylactic medication with low-dose aspirin may reduce the risk of sporadic colorectal cancer.<sup>51,56</sup> Data from chemoprevention trials in FAP suggest that COX inhibition may delay the onset and number of adenomatous polyps, but it is not yet clear whether it is able to prevent the cancers overall or reduce their respective risk.<sup>52-54</sup> COX-2-independent mechanisms may play a role for the beneficial effect of some COX-2 inhibitors.<sup>49</sup> A major recent concern, however, has been the documented increased risk of serious cardiovascular events with the use of COX-2 inhibitors.<sup>57,58</sup>

Because data on the benefits remain conflicting, physicians must decide how to use these pharmacologic tools in the management of their patients. Based on the presumed small risks in general and the supporting data on a possible benefit, most physicians would be inclined to err on the side of a potential benefit in preventing colon polyp formation. Low doses of aspirin and calcium may be helpful in preventing polyps and cancers. However, recent concern about cardiovascular side effects and increased mortality has resulted in a withdrawal of more potent COX-2 inhibitors until further redefinition of the indications and risk groups has been accomplished.<sup>57,58</sup>

### CHOLECYSTECTOMY AND BILE ACIDS

Evidence that bile acids may act as cocarcinogens or tumor promoters comes from both experimental and epidemiological studies.<sup>59,60</sup> Bile acids can induce hyperproliferation of the intestinal mucosa via a number of intracellular mechanisms. Cholecystectomy, which alters the enterohepatic cycle of bile acids, has been associated with a moderately increased risk of proximal colon cancers.<sup>61,62</sup> It cannot be ruled out, however, that it is less the effect of the cholecystectomy than the impact of other, not yet identified factors in the lithogenic bile of such patients. A number of cofactors have been identified that may enhance or neutralize the carcinogenic effects of bile acids, for example the amount of dietary fat, fiber,<sup>26</sup> or calcium.<sup>63</sup> Calcium, in fact, binds bile acids and thus may reduce their negative impact. However, other more intrinsic mucosa-protective mechanisms of calcium supplements probably are more relevant for the demonstrated reduction of recurrent adenomatous colon polyps.

### SMOKING AND ALCOHOL CONSUMPTION

The risk of colorectal cancer is increased, even though only modestly, among long-term smokers compared with non-smokers.<sup>29,48,64,65</sup> The data suggested a dose-response relationship between pack-years of tobacco use and the development of adenomatous polyps.<sup>66-69</sup> Equally, excessive alcohol consumption has been associated with an increased risk for colon cancer.<sup>29,48,64,65</sup>



## OTHER FACTORS

An ever-increasing number of other factors are accumulating that have been attributed to an increased risk of colon cancer, for example lack of physical activity, diabetes, serum insulin levels, elevated concentrations of insulin-like growth factor 1, and low concentrations of insulin-like growth factor-binding protein 3 (IGFBP-3).<sup>70</sup> The complexity of interactions between these factors and the previously mentioned parameters, however, makes it difficult at the present time to draw conclusions that have an impact on the clinical practice.

## Intrinsic Risk Factors

### PERSONAL AND FAMILY HISTORY

There is generally little debate on whether the presence of an adenomatous pathology or chronic inflammatory bowel disease (IBD) in itself represents a risk factor for a subsequent colon cancer. In patients with a colon cancer, synchronous colorectal cancers are found in 5–10%, whereas about 10–20% of patients with a history of colorectal cancer will develop metachronous primary cancers in the large intestine. A personal history of adenomatous colonic polyps is an indicator for an increased colonic predisposition to develop subsequent adenomatous or cancerous changes.<sup>14,71–75</sup>

Compared with the general population, relatives of patients with colon cancer have a two to four times increased risk of developing the disease themselves (Table 36-4).<sup>29,76,77</sup> A similar, even though proportionally lesser, risk is observed for family members of individuals with colonic adenomatous polyps.<sup>77</sup>

**TABLE 36-4: LIFETIME RISKS OF COLORECTAL CANCER IN FIRST-DEGREE RELATIVES OF PATIENTS WITH COLON CANCER**

Population risk without risk factors	1 in 50
One relative affected	1 in 17
One first-degree relative and one second-degree relative affected	1 in 12
One relative aged <45 y affected	1 in 10
Two first-degree relatives affected	1 in 6
Dominant pedigree	1 in 2

Reproduced, with permission, from Houlston RS, Murday V, Harocopus C, Williams CB, Slack J. Screening and genetic counseling for relatives of patients with colorectal cancer in a family cancer clinic. *BMJ*. 1990;Aug 18-25:301(6748):366–368.

### INFLAMMATORY BOWEL DISEASE

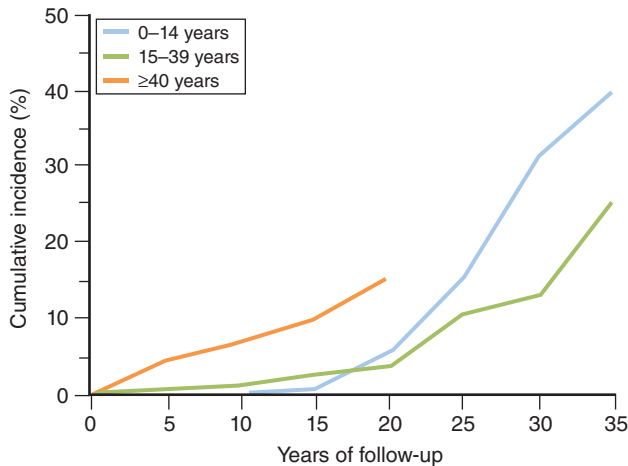
Inflammatory bowel disease (IBD) is a strong risk factor for colorectal cancer. The risk correlates with the age of onset and duration of active disease (Table 36-5 and Fig. 36-1).<sup>79,80</sup> In contrast, however, the disease activity historically was not thought to be correlated with the risk, but recent studies have challenged this view.<sup>81</sup> In ulcerative colitis, the risk of colorectal cancer increases from approximately 3% in the first decade to 10–20% in the second decade.<sup>79,80</sup> In patients with Crohn's disease with colonic involvement, the disease-associated risk for colorectal cancer is also elevated but generally to a lesser extent.<sup>82–84</sup>

**TABLE 36-5: RELATIVE RISK OF COLORECTAL CANCER AMONG PATIENTS WITH ULCERATIVE COLITIS ACCORDING TO SEX, EXTENT OF DISEASE AT DIAGNOSIS, AND AGE AT DIAGNOSIS**

Variable	Observed Cases	Person-years of Follow-up	SIR (95% CI) <sup>a</sup>
Sex			
Male	52	19,312	5.6 (4.2–7.4)
Female	39	16,268	5.9 (4.2–8.0)
Extent of disease			
Proctitis	9	11,170	1.7 (0.8–3.2)
Left-sided colitis	17	11,169	2.8 (1.6–4.4)
Pancolitis	65	13,241	14.8 (11.4–18.9)
Age at onset (y)			
0–14	13	4,220	118.3 (63.0–202.3)
15–29	21	14,047	16.5 (10.2–25.2)
30–39	15	6,892	8.2 (4.6–13.6)
40–49	16	4,119	6.1 (3.5–9.8)
50–59	11	3,294	3.4 (1.7–6.1)
≥60	15	3,008	2.2 (1.2–3.6)

<sup>a</sup> CI, confidence interval; SIR, standardized incidence ratio.

Reproduced, with permission, from Ekblom A, Helmick C, Zack M, Adami HO. Ulcerative colitis and colorectal cancer. A population-based study. *N Engl J Med*. 1990;323(18):1228–1233.<sup>79</sup>



**FIGURE 36-1** Impact of the age at diagnosis on the cumulative incidence of colorectal cancer in patients with pancolitis. Patients diagnosed with pancolitis when they were younger than 15 years are represented by solid line, when they were 15–39 years by dashed line, and when they were 40 years or older by the dotted line. (Reproduced, with permission, from Ekblom A, Helmick C, Zack M, Adami HO. Ulcerative colitis and colorectal cancer: a population-based study. *N Engl J Med.* 1990;323:1228–1233.)

## OTHER FACTORS

Less frequent risk factors for colorectal cancers may include a history of a ureterocolostomy<sup>85</sup> or previous radiation treatment.<sup>86,60</sup> The former requires the combination of fecal bacteria and urine because the microbes degrade urinary metabolites into strong carcinogens.<sup>85,87,88</sup> When colonic mucosa is used for bladder augmentation, no increased cancer risk is observed owing to the absence of bacteria. Radiation-induced colorectal cancer is little less clear, but it has been suggested that it may be associated with a mucinous histology and poor prognosis.<sup>86</sup>

## Prevention and Screening

Because symptoms are not reliable for early detection of colorectal cancer, risk-adjusted screening programs for asymptomatic individuals are important. Effective screening has to be based on an understanding of the adenoma-carcinoma sequence, which may take up to 5–10 years from the first molecular change to a clinically manifest cancer, and should reflect an individual's genetic and disease- or age-dependent risk for the development of colorectal cancer.<sup>13,14,89–91</sup> Any prevention program has to be sensitive but also practical and cost-effective in order to achieve a broad screening of the population at risk. The term “screening” is applicable only to asymptomatic people; if symptoms are present, it is not screening but diagnostic tests that are initiated. Common tools for screening include fecal occult blood tests (FOBTs), flexible sigmoidoscopies or colonoscopies, and contrast enemas or CT colonography.<sup>92</sup>

The American Cancer Society, endorsed by the major professional societies, recommends starting colorectal cancer screening in asymptomatic average-risk adults at age 50.<sup>13,14,89–91</sup> A slightly earlier screening start at age of 45 has been recommended recently for African American patients based on their statistically increased risk.<sup>11</sup> A first baseline colonoscopy is to be performed and, if no pathology is found, repeated every 10 years. In addition, an FOBT should be done at an annual basis, and any positive result should precipitate a full colonic evaluation. Every 5 years, a limited endoscopy (flexible sigmoidoscopy) or barium enema is indicated. If precursor lesions are found, they should be removed and a colonoscopy be performed after 1–3 years to detect missed (20%) or recurrent polyps.<sup>93–95</sup>

In individuals at increased risk (eg, personal/family history of polyps or cancer or African American ethnicity) or at high risk (eg, cancer syndromes or IBD), the screening has to start earlier (see Table 36-2) and has to be performed at a higher frequency.<sup>11</sup> Successful screening programs have been shown to reduce the colorectal cancer incidence by 76–90%.<sup>96</sup>

## PATHOGENESIS OF COLONIC CANCER

Carcinogenesis in the colon is a complex multistep process in which a multitude of alterations must coincide in order to transform a normal cell into a malignant cell. Several categories of genes are involved that normally are regulated in a sophisticated network to keep a tight balance between cell growth and turnover, cell death, DNA replication, and mismatch repair. Disruption of the fine balance between oncogenes, which promote cell proliferation, and tumor suppressor genes, which inhibit excessive growth, results in a growth advantage and allows malignant cells to expand.

## Colon Cancer: A Genetic Disease

All cells of even such a complex organism as a human being have DNA that is virtually identical to the DNA found in the zygotes. DNA mutations can occur either as a germline mutation or as a somatic mutation. The former may be transmitted from one to the next generation as an inherited defect. More commonly, a spontaneous mutation occurs in a non-germline cell during the growth, development, and maintenance of a tissue or organ (somatic mutation). Even in the cycle of a normally functioning cell, there is a high chance of spontaneous gene mutations, most of which will not result in a growth advantage to the harboring cell. Genesis of a cancer therefore requires several independent accidents to occur in one cell. One can assume that a normal cell will be able to detect damage to its own DNA and maintain an effective repair mechanism. However, if the cell is too severely damaged, it might rather initiate the inherent suicide program called *apoptosis*. When a cell fails to recognize or correct a DNA

damage and continues to replicate, accumulation of faulty gene products within the cell may eventually lead to a proliferative response. If that replication exceeds the growth potential of the neighboring normal cells, the mutation provides a growth advantage that will increase the state of “genetic instability” and hence lead toward a malignant cell.<sup>97</sup> Despite this potential, most mutations are silent or lethal to the cell rather than beneficial in terms of providing the cell a biologic advantage. The triggers and the step-by-step cumulative failures that lead to carcinogenesis still are relatively poorly understood.

Two types of genetic instability may occur: at the chromosome level or at the DNA level. A loss of chromosomal material, that is, a *chromosomal instability* (CIN), results when the chromosomes are not divided symmetrically during mitosis such that one daughter cell receives both copies and the other cell receives none. On an electrophoretic gel, this can be visualized as a loss of one or more bands, which is described as *loss of heterozygosity* (LOH), and has been associated with a worse prognosis of colorectal cancer.<sup>2</sup> The second form of genetic instability, at the DNA level, occurs when replication errors in repetitive short polymorphisms lead to an additional band or bands.<sup>98</sup> This phenomenon is described as *microsatellite instability* (MSI), and it has been a characteristic feature of hereditary nonpolyposis colon cancers (HNPCCs).<sup>99</sup>

During the process of cell division, DNA is duplicated, with the original DNA serving as a template for the replicated copy. DNA polymerase serves as a “proofreader” that recognizes mismatched genes, halts the DNA synthesis, removes the defective sequence, and then resynthesizes the DNA. Failure of the DNA mismatch repair system predisposes to the development of mutations within daughter cells. Enzymes that monitor newly formed DNA and correct replication errors are called *DNA mismatch repair* (MMR) systems.

Specific gene functions are lost when both copies (alleles) of a gene are inactivated. Thus, when a germline mutation occurs in a suppressor gene, only the mutation of the remaining normal allele is required for the gene’s loss of function. When both copies of the gene are normal, two mutational events are required for the gene’s loss of function. This two-hit

hypothesis may explain why inherited diseases usually manifest at an earlier age than sporadic disease.<sup>6</sup>

## The Adenoma-Carcinoma Model

After identifying several genetic alterations in colorectal specimens at various stages of their neoplastic transformation and progression, Vogelstein and colleagues in 1988 pioneered a genetic model for colorectal tumorigenesis that since has been known as the *adenoma-carcinoma sequence*<sup>3</sup> (Fig. 36-2). This multistep model described the carcinogenesis as an accumulation of genetic events, uninhibited cell growth, and proliferation and clonal development. Gene mutations and chromosomal/gene losses that were observed in sporadic colon cancer include the *APC* gene (adenoma–polyposis coli), *MMC* gene (mutated in colon cancer), *K-ras*, *DCC* (deleted in colon cancer), and *p53*.<sup>2,100,101</sup> Mutations of the *APC* gene, which is involved in the control of cell-to-cell adhesions and intercellular communication, are found in 60% of even small adenomatous polyps, as well as in carcinomas,<sup>102</sup> and therefore are believed to occur as a very early event in carcinogenesis. Mutations of *K-ras*, which under normal function plays a role in intracellular signal transduction and stimulated cell division, occur in larger adenomas and carcinomas and are thought to stimulate cell growth. Deletion of the tumor suppressor gene *DCC* may be important in the progression from a benign polyp toward a malignant condition.<sup>103</sup> Mutations of the *p53* gene, which are among the most frequent gene mutations in human cancers, are also common in invasive colon cancers but rare in adenomas, suggesting that *p53* mutations occur as a late event in the development of the invasive phenotype.<sup>104</sup> The wide range of gene mutations, inactivations, and deletions in the progression to carcinoma seem to hold the secret code for the various tumor behaviors observed in the clinical setting. It is important to note, however, that an increasing number of other genetic events have been observed and reported and that no single event seems to be equally present in all colon cancers. One therefore should caution that the described sequence is only one possible model and that the scenario may not reflect all aspects of colonic carcinogenesis.

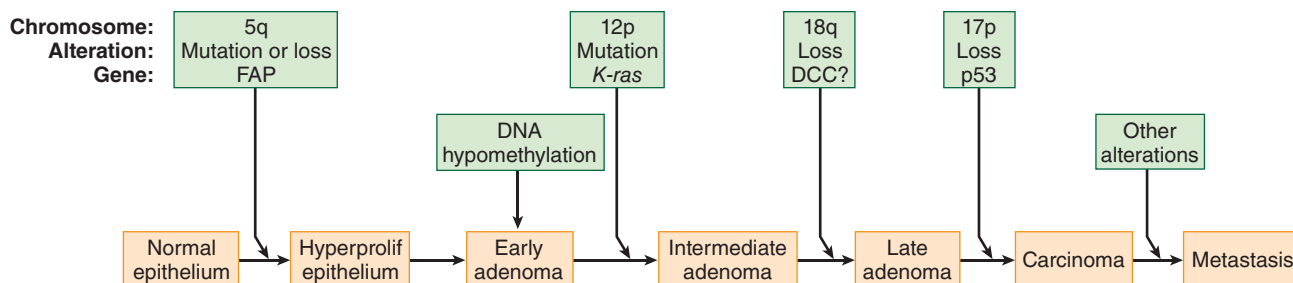


FIGURE 36-2 Genetic model for colorectal tumorigenesis (adenoma-carcinoma sequence). FAP, familial adenomatous polyposis. (Reproduced, with permission, from Fearon ER, Vogelstein B. A genetic model for colorectal tumorigenesis. *Cell*. 1990;61:759–767.)



## HEREDITARY AND NONHEREDITARY COLON TUMORS

### Nonhereditary Colon Cancer

#### SPORADIC COLON CANCER

Sporadic colon cancer, that is, colon cancer arising in individuals without a family history or an inherited predisposition, accounts for approximately 60% of all colorectal cancers and affects patients commonly older than 50 years. The risk factors associated with sporadic development of colon cancer have been discussed previously in the epidemiological section of this chapter (see Table 36-3).

#### FAMILIAL COLON CANCER

Familial colon cancer is the second most common (25–30%)<sup>6</sup> and at the same time least understood pattern of genetic colon cancer development. In affected families, colon cancer develops too frequently to be considered a sporadic colon cancer, but the pattern is not consistent with the known inherited syndromes.<sup>78</sup> An association of familial colon cancer has been found with polymorphisms, which reflect subtle genetic changes in the form of variations in the nucleotide base sequences but which do not affect protein structure.<sup>6</sup> Familial colon cancer in the Ashkenazi Jewish population probably is the result of an *APC* germline mutation on codon 1307 (I1307K). This mutation, which predisposes to sporadic mutations at distant sites of the gene and later results in structural protein abnormalities, is found in 6% of all Ashkenazi Jews and in 28% of those with both a personal and a family history of colon cancer.<sup>105</sup>

### Hereditary Colon Cancer

#### FAMILIAL ADENOMATOUS POLYPOSIS

*Familial adenomatous polyposis* (FAP) is an autosomal dominant inherited syndrome with near-complete penetrance. The offspring of affected individuals thus have a 50% risk of inheriting FAP. However, up to 20% of patients with FAP are new mutations without a family history. This condition is attributed to a truncating mutation in the germline adenomatous polyposis coli (*APC*) gene on chromosome 5q21.<sup>106</sup> Variants of the polyposis syndrome are classified as Gardner's syndrome (ie, osteomas, desmoid tumors, thyroid neoplasms, and congenital hypertrophy of the retinal pigment epithelium) and Turcot's syndrome (ie, brain tumors).

The inherited syndrome of FAP and its variants accounts for less than 1% of all colon cancers. It is characterized by greater than 100 and often several thousands of adenomatous intestinal polyps that start to develop in the late teens and early twenties and turn into cancer by age 40–45. An attenuated variant of the disease is relatively rare and is characterized by a lower number and a later onset of both the polyps and

the resulting cancer (see the following text). Nearly all FAP patients develop duodenal adenomas that are severe in 10% and account for the group's second highest cancer risk, with adenocarcinoma developing in the periampullary region in 3–10% of patients.<sup>107,108</sup> Carcinoma arising in the antrum and duodenum after colectomy is the main cause of cancer-related deaths in FAP patients.<sup>107,109,110</sup> Nonadenomatous fundic gastric polyps develop in approximately 10–30% of patients with FAP<sup>110</sup> but usually do not have a malignant potential. Ten percent of FAP patients develop desmoid tumors either intra-abdominally or on the abdominal wall, extremities, and trunk.<sup>111</sup> Histologically, desmoids are fibromatous lesions consisting of large proliferation of myofibroblasts. Even though they do not necessarily carry features of a malignant lesion, the recent literature suggests a low-grade sarcoma-like behavior. Desmoids are lethal in 10% and are the third most frequent cause for mortality of FAP patients, mainly owing to the intra-abdominal variants, which cause small bowel and ureteral obstructions.<sup>111,112</sup>

Approximately 25% of FAP patients remain without an identified *APC* mutation (*APC*-negative)<sup>112,113</sup> and, using a detailed analysis, they seem to differ in terms of lower polyp number, later age at diagnosis, and lower occurrence of extracolonic manifestations as compared with classic FAP patients.<sup>110,114</sup> This variant of FAP is known as *attenuated familial adenomatous polyposis* (AFAP).

#### HEREDITARY NONPOLYPOSIS COLON CANCERS

*Hereditary nonpolyposis colon cancer* (HNPCC), also known as *Lynch I* and *II syndromes*, is an inherited autosomal dominant disease that accounts for 3–5% of all colorectal cancers.<sup>115</sup> It is characterized by an early onset of colorectal cancers predominantly but not exclusively on the right side of the colon with synchronous and metachronous cancers. Despite its name, these cancers typically arise from colonic polyps, but a diffuse polyposis is not present. The penetrance of the HNPCC predisposition is high and results in an 80–85% lifetime risk of colorectal cancer and a 40–50% risk of endometrial cancer.<sup>17,116,117</sup> Furthermore, HNPCC patients are at increased risk of developing extracolonic malignancies, such as cancer of the small bowel, stomach, hepatobiliary tract, urinary tract, ovary, and brain. The Lynch variants describe patients with predominantly colorectal cancer at a young age (Lynch I) and those with both colorectal and extracolonic cancers (Lynch II).<sup>115</sup>

An initial observation of expansions and contractions of microsatellite DNA in the genome of colorectal tumor specimens from HNPCC patients established a link between HNPCC and the DNA MMR system.<sup>118–120</sup> In contrast to the gatekeeper concept applicable to the *APC* gene in FAP, the DNA MMR genes belong to the so-called caretakers, which, when inactivated, do not promote tumorigenesis directly but rather lead to a genetic instability that then promotes tumor growth indirectly.<sup>121</sup>

In order to facilitate the clinical diagnosis of HNPCC, the International Collaborative Group on HNPCC (ICG-HNPCC) proposed the Amsterdam Criteria in 1990.<sup>115</sup> Linkage studies in


**TABLE 36-6: AMSTERDAM CRITERIA I AND II**

Amsterdam Criteria I (1990)	Amsterdam Criteria II (1999)
At least three relatives with colorectal cancer, one of whom should be a first-degree relative of the other two.	There should be at least three relatives with HNPCC-associated cancer (colorectal cancer, cancer of the endometrium, small bowel, and ureter), one of whom should be a first-degree relative of the other two.
At least two successive generations should be affected.	At least two successive generations should be affected.
At least one colorectal cancer should be diagnosed before the age 50 y.	At least one colorectal cancer should be diagnosed before the age 50 y.
FAP should be excluded.	FAP should be excluded.
Tumors should be verified by a pathologist.	Tumors should be verified by a pathologist.
	Benign tumors, by definition, do not invade adjacent tissue borders, nor do they metastasize to distal sites. By contrast, malignant tumors have the added property of invading contiguous tissues and metastasizing to distant size.
	A polyp is defined as a mass that protrudes into the lumen of the colon. They are subdivided according to the attachment to the bowel wall (eg, sessile or pedunculated), their histologic appearance (eg, hyperplastic or adenomas), and their neoplastic potential (ie, benign or malignant).

FAP, familial polyposis syndromes; HNPCC, hereditary nonpolyposis colon cancer.

Data from Vasen HFA. Clinical diagnosis and management of hereditary colorectal cancer syndromes. *J Clin Oncol*. 2000;18(21 suppl):81S–92S.<sup>125</sup>

HNPCC families fulfilling Amsterdam Criteria I (Table 36-6) led to the discovery of the first two human MMR genes—*hMSH2* and *hMLH1*. These genes accounted for 45–86% of all classic HNPCC families.<sup>122</sup> There also was a higher risk for *hMSH2* mutation carriers to develop extracolonic cancers, in particular endometrial cancer, as compared with *hMLH1* mutation carriers.<sup>117,123</sup> Several other MMR genes have been identified in conjunction with HNPCC and include *hPMS1*, *hPMS2*, and *hMSH6*. A recent study reported that endometrial cancer represents the most common clinical manifestation of HNPCC among female *hMSH6* mutation carriers and that colorectal cancer cannot be considered an obligate requisite to

define HNPCC.<sup>124</sup> The ICG-HNPCC therefore revised the criteria (Amsterdam Criteria II), which now better weighs extracolonic manifestations (eg, endometrial, breast, small bowel, and upper renal tract cancers) as part of the family history (see Table 36-6). In addition, the less restrictive revised Bethesda Criteria (Table 36-7) were adopted to better serve patients who carry *hMSH2* or *hMLH1* gene mutations but otherwise do not fulfill the Amsterdam Criteria. Testing for MSI has become a valuable diagnostic tool to identify individuals with suspected HNPCC because 85–90% of HNPCC tumors have MSI as opposed to only 15–20% of sporadic colon cancers.<sup>99</sup>

### HAMARTOMATOUS POLYPOSIS SYNDROMES

Approximately 4% of colonic cancers are seen in the context of rare syndromes. Among these are inherited hamartomatous polyposis syndromes that are characterized by the presence of gastrointestinal hamartomatous polyps and an increased risk of gastrointestinal malignancy. Hamartomas result from a disordered differentiation during embryonic development and are characterized morphologically by disrupted representations of normal tissue components.


**TABLE 36-7: REVISED BETHESDA GUIDELINES (2002) FOR TESTING COLORECTAL TUMORS FOR MSI**

Criterion	Comment
Colorectal cancer diagnosed in a patient aged <50 y	
Presence of synchronous, metachronous colorectal cancer, or other HNPCC-associated tumor, regardless of age	Stomach, ovarian, pancreas, ureter and renal pelvis, biliary tract, and brain, sebaceous gland adenomas and keratoacanthomas, and small bowel
Colorectal cancer with MSI-high histology diagnosed in a patient aged <60 y	Tumor infiltrating lymphocytes, Crohn's-like lymphocytic reaction, mucinous/signet-ring differentiation, or medullary growth pattern
Colorectal cancer diagnosed in at least on first-degree relative with an HNPCC-related tumor diagnosed under age 50	
Colorectal cancer diagnosed in two or more first- or second-degree relatives with HNPCC-related tumors, regardless of age	

HNPCC, hereditary nonpolyposis colon cancer; MSI, microsatellite instability. Data from Umar A, Boland CR, Terdiman JP, et al. Revised Bethesda Guidelines for hereditary nonpolyposis colorectal cancer (Lynch syndrome) and microsatellite instability. *J Natl Cancer Inst*. 2004;96(4):261–268.<sup>126</sup>

**Peutz-Jeghers Syndrome.** Peutz-Jeghers syndrome is the second most common hamartomatous syndrome, occurring as an autosomal dominant condition with variable penetrance. Genetic alterations in the *LKB1/STK* (19p13) gene are responsible for approximately 50% of the cases of Peutz-Jeghers syndrome.<sup>127</sup> The syndrome is associated with hamartomatous polyps of the gastrointestinal tract and cutaneous melanin deposition. The most common location of Peutz-Jeghers polyps is in the upper gastrointestinal tract, specifically the upper jejunum. One of the most characteristic features is the melanin depositions that is seen most frequently in the perioral region or buccal mucosa but also can occur in the genital region and on the hands and the feet. While a majority of these patients remain relatively asymptomatic, some may present with abdominal pain secondary to obstruction or impending obstruction owing to an intussuscepted polyp and others with gastrointestinal bleeding. Patients with Peutz-Jeghers syndrome have a moderately increased risk in the range of 2–3% to develop gastrointestinal malignancies as well as extraintestinal malignancies.

**Juvenile Polyposis Syndrome.** Juvenile polyposis syndrome is the most common hamartomatous syndrome and is inherited as an autosomal dominant trait. The average age of onset is approximately 18 years, and there is an association with congenital birth defects in 15% of patients.<sup>128</sup> Although the diagnostic criteria for juvenile polyposis syndrome are somewhat controversial, the most commonly used criteria include three or more juvenile polyps of the colon, polyposis involving the entire gastrointestinal tract, or any number of polyps in a member of a family with a known history of juvenile polyps.<sup>129</sup>

In infancy, patients may present with acute or chronic gastrointestinal bleeding, intussusception, rectal prolapse, or a protein-losing enteropathy. In adulthood, patients commonly present with either acute or chronic gastrointestinal blood loss. Most of these patients will be found to have polyps, which are located most frequently in the rectosigmoid region.

A germline mutation in the *SMAD-4* gene (18q21) accounts for approximately 50% of the reported cases of the syndrome.<sup>130</sup> A significant risk of colorectal cancer is associated with juvenile polyposis syndrome, and should not be confused with isolated juvenile polyps because the latter have virtually no malignant potential.

**Cowden Syndrome.** Cowden's disease, first described in 1963, is known as multiple hamartoma-neoplasia syndrome. It is an autosomal dominant condition with nearly complete penetrance by age 20 that is caused by germline mutations in the *PTEN* tumor suppressor gene located at 10q22.<sup>131,132</sup> Cowden's disease is unique among the hamartomatous syndromes because polyps arise more commonly from ectodermal rather than endodermal elements. Eighty percent of patients present with tricholemmoma, a benign tumor of the hair shaft. The central nervous system is the second most

involved system, with approximately 40% of affected individuals suffering from macrocephaly. Only 35% of patients who meet the diagnostic criteria for Cowden's disease have gastrointestinal polyposis, but no increased risk of invasive gastrointestinal malignancy has been reported to date. The majority of patients with Cowden's disease suffer from benign thyroid or breast disease, on top of which adds a projected lifetime risk of 10% for thyroid cancer and of 30–50% for breast cancer.

**Bannayan-Riley-Ruvalcaba Syndrome.** Formerly known as its subentity, the Ruvalcaba-Myhre-Smith syndrome, this rare autosomal dominant condition includes two other syndromes, both of which, like Cowden's disease, are associated with genetic alterations in the *PTEN* gene on chromosome 10q23 and may be considered a variant of juvenile polyposis coli.<sup>133–135</sup> It is characterized by hamartomatous polyps of the gastrointestinal tract, macrocephaly, mental retardation, delayed psychomotor development, lipid storage myopathy, Hashimoto's thyroiditis, and hyperpigmentation of the skin of the penis. No increased risk of colorectal carcinoma, other gastrointestinal malignancies, or extraintestinal malignancy has been documented in these patients.

**Cronkite-Canada Syndrome.** Cronkite-Canada syndrome is characterized by diffuse polyposis and ectodermal abnormalities such as alopecia, onychodystrophy, and skin hyperpigmentation. The syndrome can be distinguished by the diffuse distribution of polyps throughout the entire gastrointestinal tract with exception of the esophagus, which is spared.<sup>136</sup> Symptoms include diarrhea, weight loss, nausea, vomiting, and anorexia, as well as paresthesias, seizures, and tetany related to electrolyte abnormalities. Cancer occurs in the stomach, colon, and rectum, but it remains controversial whether polyps in Cronkite-Canada syndrome possess malignant potential. As many as 15% of patients with Cronkite-Canada syndrome have a malignant tumor at the time of diagnosis.

## PATHOLOGY AND STAGING

### Polyps

*Polyp* is a descriptive clinical term for any mucosal elevation. Polyps are further categorized along several dimensions, including

1. Size
2. Character of their attachment to the bowel wall (eg, sessile or pedunculated)
3. Cellular architecture (eg, adenomas, hyperplastic, hamartomas, inflammatory) and histologic appearance (eg, tubulous, tubulovillous, villous)
4. Progression from benign to malignant behavior (eg, benign, dysplastic, cancer)



**TABLE 36-8: RISK OF INVASIVE CARCINOMA IN ADENOMATOUS POLYPS**

Polyp Size (mm)	Number	% With Invasive Carcinoma
≤5	5137	0
6–15	3581	2.2
16–25	1069	18.6
16–36	516	42.8
37–42	219	63.9
>42	677	78.9

Data from Nusko G, Mansmann U, Kirchner T, Hahn EG. Risk related surveillance following colorectal polypectomy. *Gut*. 2002;51(3):424–428.<sup>137</sup>

Most polyps are neoplastic but not necessarily malignancies. Neoplastic polyps consist of cells with the potential to acquire over time the ability to invade and to spread, that is, metastasize. *Dysplasia* is a term used to describe the intervening state between normal tissue and invasive malignancy.

### POLYP SIZE

The most immediate way in which a polyp can be described is by its size. Intuitively, polyps with a larger mass have a greater volume of neoplastic cells, and hence a higher likelihood of harboring cancer. The relationship between adenomatous polyp size and the presence of invasive malignancy was analyzed elegantly by Nusko et al (Table 36-8).<sup>137</sup>

### POLYP ATTACHMENT TO BOWEL WALL

Polyps of any size or architecture may be pedunculated, sessile, or some combination of both. The main clinical relevance of this distinction lies in the ease of endoscopic removal, with pedunculated polyps being clearly more amenable to removal without surgical intervention.<sup>138,139</sup>

It is important to note that the way in which a polyp is attached to the wall of the colorectum does not accurately predict the presence versus absence of an invasive malignancy.

Malignant polyps of the colon can be either pedunculated or sessile. The type of treatment that should be offered to a patient depends much more on the other characteristics of the polyp.

### POLYP ARCHITECTURE

Based on their histological structure, polyps can be categorized into adenomatous and nonadenomatous polyps, the latter of which consists of hyperplastic, hamartomatous, and inflammatory polyps.

**Adenomatous Polyps (Adenomas).** The most common type of polyp in the colon is the adenomatous polyp. Adenomatous polyps are categorized as tubular, tubulovillous, or villous based on the extent to which the dysplastic epithelium is organized with the normal-appearing tubular architecture.<sup>140</sup> Tubular adenomas are defined by the presence of tubules within 80% or more of the lesion; adenomas with less than 20% showing a tubular configuration are villous lesions; and the remainder is considered tubulovillous. The majority of polyps are tubular (87%), with a minority either tubulovillous (8%) or villous (5%).<sup>141</sup>

With few exceptions, the treatment for an adenomatous polyp is endoscopic polypectomy. Colorectal cancer screening programs that include colonoscopy with polypectomy have demonstrated a reduction in the incidence of colorectal cancer and colorectal cancer mortality.<sup>142</sup> It is difficult, however, to estimate the likelihood that a small adenoma will progress to a dysplastic adenoma and eventually into cancer. A number of biologic and molecular markers have been analyzed as predictors of a malignant potential, but these are not widely utilized.<sup>143</sup> Longitudinal and comparative data suggest that polyps not only progress but also may regress.<sup>144</sup> Despite these vagaries, any adenomatous polyp should be considered a premalignant lesion and be treated as such.

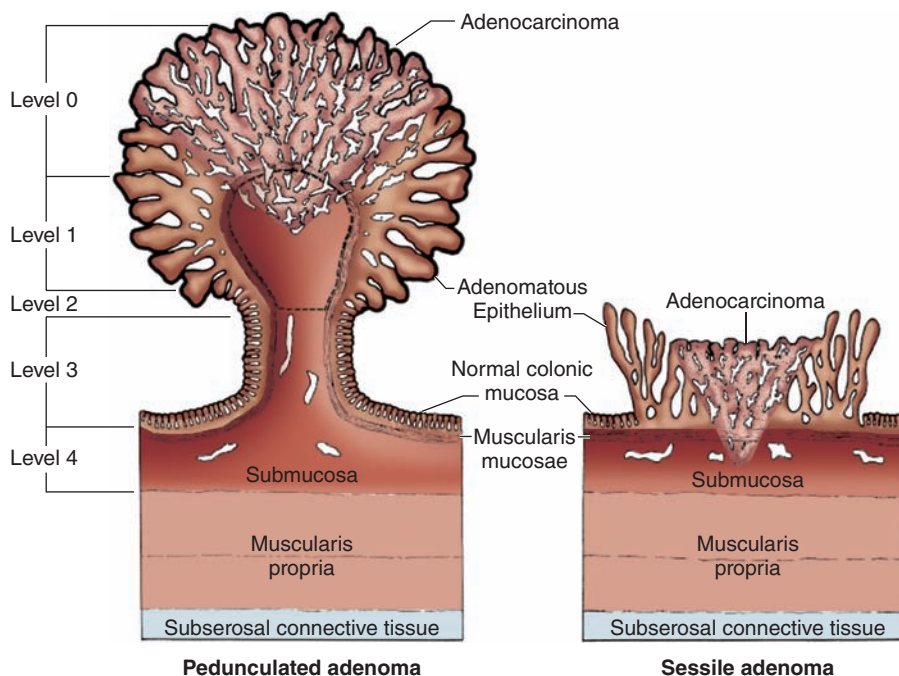
Invasive carcinoma is present in 5% of all adenomas, but the incidence correlates with the size and type of the adenoma (Table 36-9).<sup>137,145</sup>

The Haggitt classification, which defines four levels within the polyp, has evolved as a useful tool to describe the degree of cancer invasion into a pedunculated or sessile adenomatous

**TABLE 36-9: ADENOMATOUS POLYPS AND VILLOUS ADENOMA: SIZE, HISTOLOGICAL TYPE, AND PERCENT OF CARCINOMA**

Histological Type	Size		
	<1 cm	1–2 cm	>2 cm
Tubular adenoma	1% (1382)	10.2% (392)	34.7% (101)
Intermediate type	3.9% (76)	7.4% (149)	45.8% (155)
Villous adenoma	9.5% (21)	10.3% (39)	52.9% (174)

Reproduced, with permission, from Muto T, Bussey HJ, Morson BC. The evolution of cancer of the colon and rectum. *Cancer*. 1975;36(6):2251–2270.<sup>146</sup>



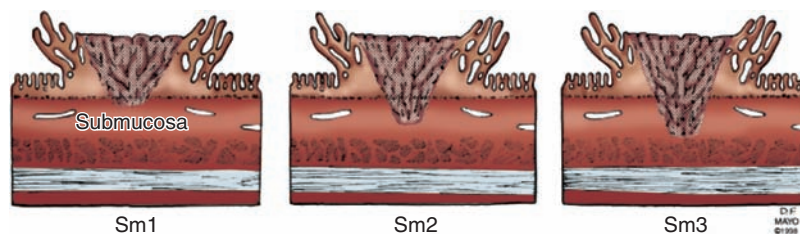
**FIGURE 36-3** Haggitt's classification of tumor invasion in pedunculated or sessile polyp. Pedunculated polyps: level 0—not invasive carcinoma; level 1—invasion to the head of the pedunculated polyp; level 2—invasion to the neck of the pedunculated polyp; level 3—invasion to the stalk of the pedunculated polyp; level 4—invasion to the base of the pedunculated polyp. Sessile polyps: All lesions are level 4. (Reproduced, with permission, from Haggitt RC, Glotzbach RE, Soffer EE, Wruble LD. Prognostic factors in colorectal carcinomas arising in adenomas: Implications for lesions removed by endoscopic polypectomy. *Gastroenterology*. 1985;89:328–336.)

polyp.<sup>147</sup> This classification forms the basis of the management of malignant polyps (Fig. 36-3). In Haggitt's levels 1, 2, and 3, the risk of lymph node metastasis in a surgical specimen is less than 1%, whereas a level 4 invasion of the stalk behaves like a sessile T1 lesion and carries a higher risk of 12–25% of having lymph node metastases. A similar, but less well-known, classification was developed in 1993 by Kudo and associates, who for prognostic purposes suggested to divide the submucosal invasion of sessile malignant lesions into three levels (Sm1, Sm2, Sm3) (Fig. 36-4).<sup>148</sup>

Flat and/or depressed adenomas are a subtype of colonic adenoma with a propensity for high-grade dysplasia in 10–41% of affected patients regardless of the small size of these lesions.<sup>149</sup> The entity was first described in Japan, where they seem to occur at a regular frequency. These lesions, which are flat or slightly raised to less than 2 mm and commonly less

than 1 cm in size, may be overlooked easily on colonoscopy and turn into a cancer before having reached a size comparable with classic cancers.<sup>149–152</sup> Recent screening studies, which took advantage of chromoendoscopy techniques, have confirmed that flat adenomas represent up to 25–36% of all polyps found in a random cohort and are present in 8–11% of the population.<sup>152,153</sup>

**Hamartomatous Polyps.** A hamartomatous polyp is composed of a spectrum of different cellular elements and is considered a nonneoplastic entity with no significant premalignant potential.<sup>154,155</sup> Several clinical syndromes manifest with a polyposis of hamartomatous polyps (Juvenile polyposis, Cowden syndrome, Bannayan-Riley-Ruvalcaba syndrome, Cronkite-Canada syndrome) and these have been discussed earlier in this chapter. These syndromes carry varying risks of



**FIGURE 36-4** Depth of submucosal invasion in sessile malignant polyps. Sm1—invasion into upper third of submucosa; Sm2—invasion into middle third of submucosa; Sm3—invasion into lower third of submucosa. (Reproduced, with permission, from Nivatvongs S. Surgical management of early colorectal cancer. *World J Surg*. 2000;24:1052–1055.)

intestinal and extraintestinal disease, and several also impose an increased likelihood of developing intestinal cancer due to immature glandular elements in the hamartomatous polyp. Stable estimates of this risk are difficult to calculate because of the relative rarity of these diseases.

**Hyperplastic Polyps.** Hyperplastic polyps are small, sessile mucosal outgrowths that display an exaggerated crypt architecture. They are usually small, with only very few (1–4%) larger than 1 cm; however, these larger polyps actually may be serrated adenomas rather than hyperplastic polyps (see the following text).<sup>156</sup> Within the colorectum, hyperplastic polyps commonly have a distal distribution pattern, predominantly in the rectum and sigmoid colon, and they have been reported in up to 75% of patients older than 60 years at autopsy.<sup>157</sup> It is not unusual to find several of these polyps in a single individual.

Histologically, hyperplastic polyps display well-formed glands and crypts that are lined by nonneoplastic epithelial cells. Because of their small size, hyperplastic polyps are generally clinically silent, but large or multiple hyperplastic polyps occasionally can be responsible for gastrointestinal symptoms.

Historically, hyperplastic polyps have been considered benign and not premalignant.<sup>156</sup> This paradigm has been increasingly questioned, beginning in 1990 with work by Longacre and Fenoglio-Preiser.<sup>158</sup> The ability of hyperplastic polyps to develop defective mismatch repair genes and foci of microsatellite unstable cancers has been documented, strengthening this concept.<sup>159</sup> Additional research has illuminated an epigenetic pathway, whereby a promoter region in the DNA of hyperplastic polyps is methylated, resulting in progression along a sequence of steps that leads to a serrated adenoma and eventually carcinoma.<sup>160</sup> The clinical significance of hyperplastic polyps and serrated adenomas is a topic of emerging importance in the field of colorectal cancer prevention.

As with adenomatous polyps, individuals who have a predisposition to developing hyperplastic polyps may be at increased risk for developing colorectal cancer. The endoscopic and radiologic appearance of the mucosal abnormalities in hyperplastic polyposis closely resembles FAP, but the syndrome is not believed to be heritable and does not have any extraintestinal manifestations. The World Health Organization (WHO) has defined criteria for this entity as follows: (1) at least five histologically diagnosed hyperplastic polyps of which two are greater than 20 mm or (2) any number of hyperplastic polyps occurring proximal to the sigmoid colon in someone who has a first-degree relative with hyperplastic polyposis, or (3) more than 30 hyperplastic polyps of any size that are distributed throughout the colon and rectum.<sup>161</sup> The risk of colorectal cancer being present or developing subsequently in a patient meeting these criteria are high in case series, but population-based studies have not yet been performed.<sup>162</sup> While prophylactic colectomy has been proposed for patients with hyperplastic polyposis, there are no consensus opinions at this time regarding the appropriateness of this

approach.<sup>163</sup> At a minimum, a program of intensive colonic surveillance is indicated.

**Inflammatory Polyps.** Inflammatory polyps are the result of reactive regenerative processes occurring in or next to a damaged epithelium. Because of the extent and chronicity of IBD, inflammatory polyps are most commonly seen in that context. The prominence of inflammatory pseudopolyps often is the result to the presence of adjacent ulcerations. Histologically, a combination of distorted crypt architecture in conjunction with granulation tissue and inflammatory infiltrates is characteristic. Even though the underlying chronic IBD represents a high risk for colorectal cancer, the inflammatory polyps as such do not carry a malignant potential. Biopsies in IBD should therefore also include the more flat-appearing areas rather than the polyps only.

## POLYP TRANSFORMATION

By definition, the neoplastic nature of an adenomatous polyp represents dysplasia. In an effort to quantify the clinical severity/importance of dysplasia, however, the degree of dysplasia is categorized and reported in three grades. This categorization is based on the histopathologic differentiation and architecture of the epithelial cells within the polyp.

Common terms for polyps include *low-grade dysplasia*, *intermediate-grade dysplasia*, and *high-grade dysplasia* (by some also referred to as *in situ [Tis] adenocarcinoma*). Once there are clear microscopic features of tumor invasion through the muscularis mucosa of the colorectum, an invasive cancer (T1 or greater) is present. This important demarcation is based on the finding that lymphatic vessels are almost never found superficial to the muscularis mucosa. The descriptive terms for invasive cancer include *well-differentiated* (grade I), *moderately differentiated* (grade II), or *poorly differentiated* (grade III) adenocarcinoma.

## MANAGEMENT OF COLORECTAL POLYPS

The overarching goal of physicians treating patients with colorectal polyps is to minimize the risks associated with invasive malignancy, while simultaneously avoiding complications of diagnosis and treatment. Colorectal cancer prevention programs are widely believed to reduce the risk of colorectal cancer mortality through endoscopic removal of premalignant lesions and the detection of invasive lesions at a point in their progression where they are asymptomatic. The efficacy of colorectal cancer prevention programs has been proven in multiple randomized and nonrandomized studies.<sup>142,164–168</sup>

The majority of colonic polyps can be removed via colonoscopy, but this may not be the case for one of two reasons. First, a polyp may not be resectable due to size, attachment to bowel wall, or other reasons related to the anatomy of the patient or polyp. In these situations, a careful assessment of the risks of surgical resection versus observational management is warranted, as 12–18% of these polyps harbor an



invasive malignancy.<sup>169–171</sup> Second, polypectomy may not be reasonable in the presence of innumerable polyps.

When invasive cancer is found in a polyp, the management is based mainly on the level of invasion and the completeness of the polypectomy. Based on Haggitt's observations (see Fig. 36-3), it has been suggested that colonic cancers invasive to Haggitt's levels 1, 2, and 3 can be adequately treated with polypectomy (2-mm margin), whereas polyps with invasion into Haggitt's level 4 should be treated like a sessile lesion.<sup>147,172</sup>

Management of sessile lesions is more controversial. If a sessile lesion cannot be snared in one intact piece with a microscopically clear margin of at least 2 mm, or if it demonstrates lymphovascular invasion or deep invasion into level Sm3 (lower third of submucosa) (see Fig. 36-4), the patient should undergo a formal oncologic resection of the colon. The approach for an adequately removed lesion with a lesser extent of invasion into the submucosa—Sm1 (invasion only into upper third of submucosa), Sm2 (invasion only into upper two-thirds of submucosa)—should be individualized based on the risk of a surgery versus the risk of lymph node metastases.<sup>172,173</sup> It is advisable in any case to tattoo the area of a suspect polyp endoscopically with India Ink for later identification of the site.

## Malignant Tumors of the Colon

The vast majority of malignant colon neoplasms are cancers (carcinoma), that is, malignant neoplasms of epithelial origin. Based on the endodermal glandular tissue origin, adenocarcinoma and its histologic variants are by far the predominant histopathology and account for 90–95% of all colorectal malignancies. The majority of this section is therefore devoted to these types of tumors, but it also briefly discusses nonepithelial tumors of the colon.

## ADENOCARCINOMA

Colorectal cancer (adenocarcinoma) is the most frequent malignancy of the gastrointestinal tract, the fourth most frequently diagnosed malignancy, and the fourth most common cause of cancer-related mortality in the world.<sup>174</sup> Squamous and adenosquamous carcinomas are exceptionally rare and are located characteristically in the rectoanal junction. The histopathologic classification of colorectal cancer as defined by the WHO is illustrated in Table 36-10.

Macroscopically, most colorectal cancers have either a polypoid or an ulcerative-infiltrating appearance, but combinations are frequent. Very rarely, colorectal cancer may have a dissolute growth pattern and resemble linitis plastica of the stomach, in which case a metastatic lesion from another primary site (eg, lobular breast cancer, stomach cancer) or a nonepithelial neoplasia (eg, lymphoma, carcinoid) would need to be ruled out.

Adenocarcinoma, the exceedingly predominant histopathology of colon cancer, has a less frequent variant of mucinous adenocarcinoma that includes signet ring cell carcinoma and accounts for approximately 10% of all colorectal cancers. Compared to nonmucinous colon cancers, mucinous carcinomas usually present at a more advanced stage and thus have an overall poorer prognosis.<sup>8,175,176</sup>

A rare variant of colorectal cancer is small cell cancer, which accounts for less than 1% of all cases and, similar to small cell cancer of the lung, and appears to be related to some degree to a neuroendocrine origin. These tumors have a high tendency to develop widespread metastasis early in the course and have an extremely poor prognosis.

The distribution of colorectal cancers among the various segments has seen a continued shift toward right-sided colon cancer.<sup>177,178</sup> An estimated 45–55% of colorectal cancers are located in the rectum (10–15%) or sigmoid colon (40%), 25–35% in the cecum or ascending colon, whereas



**TABLE 36-10: WHO HISTOPATHOLOGIC CLASSIFICATION OF COLORECTAL CANCERS AND THEIR SIGNIFICANCE**

Histopathologic Types	Pathology	Prognosis
Adenocarcinoma	90–95% of the colorectal malignancies	
Mucinous adenocarcinoma	10% of all colorectal cancers; the extracellular type is more common than the intracellular type	Controversial whether mucinous histology itself is an independent negative prognostic factor
Signet ring cell carcinoma		
Small cell carcinoma (oat cell)	<1%; histologically identical to small cell carcinoma of the lung	Extremely poor prognosis and almost all cases have lymph node, liver, and brain metastasis
Small cell adenosquamous carcinoma		
Squamous cell carcinoma		
Undifferentiated carcinoma (medullary)		

the remaining are equally distributed through the rest of the colon. The local growth pattern for colorectal cancer involves circumferential and transmural invasion of the tumor through the intestinal wall into the peritoneal cavity or surrounding organ structures. Tumor dissemination primarily occurs through access to the lymphatic vessels into the locoregional lymph nodes or through access to the blood stream as hematogenous metastasis to distant organs. The most common site of blood-borne spread is via the portal venous system to the liver; other secondary locations include the lung or, less frequently kidneys, bone, etc. In addition, tumor dissemination can occur by transperitoneal seeding and result in peritoneal carcinomatosis.<sup>179</sup> Following gravity, peritoneal seeds may accumulate in the pelvic cul-de-sac or paracolic gutters where they can grow to a considerable size (Blumer's shelf). Growth by perineural infiltration may be seen on microscopic examination and has a negative prognostic impact. About 20% of the patients have evidence of distant metastases (stage IV disease) at the time of presentation.

## STAGING OF COLON CANCER

Modern staging of colorectal cancer defines four clinical stages (I–IV) based on the TNM (tumor-node-metastasis) system, which has just recently been updated by the American Joint Committee on Cancer (AJCC) (Tables 36-11 and 36-12).<sup>8,180,181</sup> Independent parameters are (1) the depth of tumor invasion (T) into or through the layers of the intestinal wall with or without invasion of adjacent organs, (2) the number of regional lymph nodes involved (N), and (3) the presence or absence of distant metastases (M). Additional modifiers are used to reflect the method of stage determination (p for pathology, c for clinical, u for ultrasound), and y to indicate a status after neoadjuvant treatment.

Historical classifications such as Dukes and Astler-Coller are still sporadically in use but largely have been and should be abandoned.

Because the extent of tumor resection (complete vs incomplete) strongly correlates with prognosis, the AJCC released additional guidelines to reflect the extent of residual tumor after a surgical resection with the letter *R* (see Table 36-11).<sup>181</sup>

## Nonepithelial Tumors of the Colon

### BENIGN NONEPITHELIAL TUMORS

**Lipomas and Lipomatous Polyposis.** Lipomas are submucosal lesions that develop in the fifth or sixth decade of life and are more common in the large than in the small intestine. Histologically, the polyps consist of a submucosal lump of adipose tissue that is covered with a normal colonic mucosa. Whereas solitary lipomas tend to occur more frequently on the right side of the colon in the vicinity of the ileocecal valve or the ascending colon, *lipomatous polyposis* may diffusely involve the entire small and large intestine.

**TABLE 36-11: TNM STAGING OF COLON CANCER (AJCC CANCER STAGING MANUAL, 7TH ED, 2010<sup>181</sup>)**

Stage	Definition
<b>Primary tumor (T)</b>	
TX	Primary tumor cannot be assessed
T0	No evidence of primary tumor
Tis	Carcinoma in situ: intraepithelial or invasion of lamina propria
T1	Tumor invades submucosa
T2	Tumor invades muscularis propria
T3	Tumor invades through muscularis propria into the subserosa or into nonperitonealized pericolic or perirectal tissues
T4a	Tumor perforates visceral peritoneum
T4b	Tumor directly invades other organs or structures
<b>Regional lymph nodes (N)</b>	
NX	Regional lymph nodes cannot be assessed
N0	No regional lymph node metastases
N1	Metastasis in 1–3 regional lymph nodes
N1a	1 positive lymph node
N1b	2–3 positive lymph nodes
N1c	extranodal tumor deposits
N2	Metastasis in 4 or more regional lymph nodes
N2a	4–6 positive lymph nodes
N2b	≥7 positive lymph nodes
<b>Distant metastasis (M)</b>	
MX	Distant metastasis cannot be assessed
M0	No distant metastasis
M1	Distant metastasis
M1a	Metastases confined to 1 organ/site
M1b	Metastases in >1 organ/site
<b>Extent of resection</b>	
RX	Presence of residual tumor cannot be assessed
R0	No residual tumor
R1	Microscopic residual tumor
R2	Macroscopic residual tumor

TNM, tumor-node-metastasis.

Lipomas generally are asymptomatic but may be found incidentally on colonoscopy. The characteristic appearance is a smooth mass with normal overlying mucosa. The soft nature of the lipoma can be demonstrated by poking the tumor with an endoscopic instrument (“pillow test”). Asymptomatic, incidentally detected lesions should be left alone.

**TABLE 36-12: STAGING SYSTEM BY AJCC (AJCC CANCER STAGING MANUAL, 7TH ED, 2010<sup>181</sup>)**

Stage	T	N	M
0	Tis	N0	M0
I	T1	N0	M0
	T2	N0	M0
II-A	T3	N0	M0
II-B	T4a	N0	M0
II-C	T4b	N0	M0
III-A	T1–T2	N1/N1c	M0
	T1	N2a	M0
III-B	T3–T4a	N1/N1c	M0
	T2–T3	N2a	M0
	T1–T2	N2b	M0
III-C	T4a	N2a	M0
	T3–T4a	N2b	M0
	T4b	N1-N2	M0
IV-A	Any T	Any N	M1a
IV-B	Any T	Any N	M1b

AJCC, American Joint Committee on Cancer.

Occasionally, when lipomas become large enough to protrude into the lumen, they may cause symptoms such as gastrointestinal bleeding, diarrhea, intussusception, or bowel obstruction.<sup>182</sup> Endoscopic removal of such a lipoma with a snare often is possible but has a risk of hemorrhage because the fat may prevent the cautery from adequately transmitting the energy to the blood vessels in the stalk. Surgery may be required if such a complication occurs; it should therefore be considered preemptively for very large symptomatic lipomas. Alternatively, the mucosa overlying the lipoma may be opened endoscopically to allow the lipoma to spontaneously nucleate into the lumen.

### POTENTIALLY MALIGNANT NONEPITHELIAL TUMORS OF THE COLON

**Carcinoid or Neuroendocrine Tumors.** Modern nomenclature classifies carcinoids as neuroendocrine tumors, based on their neuroendocrine origin. They are characterized by subepithelial nests of epithelial-appearing cell elements. Carcinoid tumors may occur anywhere in the entire body. A recent study on 11,427 patients from the SEER database found that the gastrointestinal tract is affected in 55%, with the most frequent locations being the small intestine (44.7%), the rectum (19.6%), the appendix (16.7%), and the colon (10.6%),<sup>183</sup> a finding that contrasts with traditional reports that the appendix is the most frequent site in the gastrointestinal tract. The annual incidences for the colon and rectum were reported to be 2.0 and 4.2 cases per 100,000 people per year, the risk of metastasis proportional to the size

of the carcinoid.<sup>183</sup> Unlike most neoplasms, invasiveness of carcinoid tumors is not entirely based on histological criteria (eg, invasion of muscularis propria) but includes clinical aspects. In absence of other definite indicators for malignant behavior, carcinoids smaller than 1 cm are considered benign, lesions larger than 2 cm are likely malignant, and the gray zone in between remains undetermined or potentially malignant.<sup>184</sup> Malignant carcinoids may spread locoregionally into the lymph nodes or directly to the liver.

Patients with a gastrointestinal carcinoid tumor may be either completely asymptomatic or present with intestinal obstruction, bleeding, carcinoid syndrome, or carcinoid heart disease, that is, acquired and commonly right-sided valvular heart disease.<sup>185,186</sup> Vasoactive substances (eg, serotonin and 5-hydroxyindolacetic acid [5-HIAA]) are released from carcinoid tumors but for the most part are eliminated in a hepatic first-pass effect before reaching the systemic circulation. Carcinoid syndrome is therefore a bad prognostic sign because it does not typically develop until metastatic lesions in the liver directly release their products into the systemic circulation. Hindgut carcinoid tumors (those located in the distal transverse colon and beyond) classically do not cause carcinoid syndrome because they are less endocrinologically active.

Diagnosis of a carcinoid may be suspected clinically but can be difficult to confirm histologically short of a surgical resection because the lesions are submucosal and not commonly in reach of an endoscopic biopsy. A preoperative workup for a carcinoid tumor should include a 24-hour urine collection of 5-HIAA and a plasma chromogranin A. Both parameters can also be used for postoperative surveillance. Cross-sectional imaging and somatostatin receptor scintigraphy are tools to evaluate for systemic disease. Multicentricity and associated high rates of synchronous gastrointestinal and genitourinary malignancies warrant both an upper and lower gastrointestinal endoscopy.<sup>187</sup>

An oncologic resection should be performed in all carcinoids larger than 2 cm unless contraindicated by clinical circumstances. Tumors of smaller than 1 cm size may be managed locally, whereas the management of lesions measuring 1–2 cm remains controversial.<sup>184</sup>

**Gastrointestinal Stromal Tumors (GISTs).** GISTs are the most common mesenchymal tumors of the gastrointestinal tracts and originate from the intestinal pacemaker cells, the interstitial cells of Cajal.<sup>188</sup> Sixty percent of GISTs are found in the stomach; 29% in the small intestine; 2% in the colon, rectum, and rectovaginal septum; and 9% in the esophagus.<sup>189</sup> Symptoms are nonspecific and include pain, obstruction, bleeding, and a mass. Distinction from other mesenchymal tumors (eg, leiomyosarcoma) is important from a prognostic point of view. Tumor size and light microscopic determination of the mitotic rate (mitotic figures per  $\times$  number of high-power fields) are the most important conventional prognostic indicators.<sup>188</sup> The diagnosis of GISTs is based on morphologic features and



immunohistochemical demonstration of *c-kit* (CD117) expression. This marker is seen in almost all GISTs and is regarded as one of the key diagnostic elements, but a few otherwise characteristic tumors are found to be *c-kit* negative.<sup>190</sup> While the majority of GISTs have activating mutations of the KIT receptor tyrosine kinase, another subset of tumors show mutations in the KIT-related kinase gene platelet-derived growth factor receptor alpha (PDGFRA).<sup>191</sup> KIT and PDGFRA mutations appear to be alternative and mutually exclusive oncogenic mechanisms in GISTs.<sup>192</sup> Determination of CD117 expression is of practical importance because positivity correlates with a tumor response to treatment with imatinib (Gleevec), which inhibits KIT kinase activity. Surgical resection is the primary treatment for localized GISTs that are resectable without mutilation. Recurrent and locally advanced or metastatic tumors are treated increasingly with imatinib in a palliative, adjuvant, or neoadjuvant setting.

**Nodular Lymphoid Hyperplasia.** This condition is characterized by numerous polyps in the small and large intestine, rarely in the stomach, which consist of enlarged submucosal lymphoid follicles. Associated diseases are immune deficiencies of various origins (eg, tumors, hematoproliferative disorders, immunoglobulin A deficiency, and human immunodeficiency virus [HIV] infection), in which case recurrent infections (eg, giardiasis) appear to promote the nodular lymphoid hyperplasia. Immunocompetent patients usually are asymptomatic, and the nodular lymphoid hyperplasia is an incidental finding. Nodular lymphoid hyperplasia has been associated with an increased subsequent incidence of lymphoma (small bowel).<sup>193</sup>

## MALIGNANT NONEPITHELIAL TUMORS OF THE COLON

**Lymphoma.** Primary malignant lymphoma of the colon is uncommon and accounts for only 0.2–0.4% of all colonic malignancies and 10–15% of all primary lymphomas of the gastrointestinal tract, which themselves account for about 30% of extranodal lymphomas.<sup>194</sup> The most frequent colonic location is the cecum (70%), followed by the rectum and ascending colon. The gross appearance may be a circumferential or polypoid mass, an ulceration, or a diffuse infiltration with stricturing and bowel wall thickening.<sup>195</sup> Eighty-six percent of the lesions are solitary, but they can be multiple and diffuse in nature. The intestinal lymphomas may be subclassified into B-cell lymphomas (85%) and T-cell lymphomas (15%). Among the B-cell lymphomas, mantle cell lymphoma has a worse prognosis, whereas mucosa-associated lymphoid tissue (MALT) lymphomas have a better prognosis than other B-cell tumor types.<sup>195</sup> While surgical treatment may be indicated for some localized tumors, many authors consider medical management to be the primary treatment. It may include new approaches such as anti-infectious treatment for

MALT lymphoma or reconstitution of the patient's immune status, for example by means of antiretroviral treatment in HIV-associated B-cell lymphoma.<sup>196</sup>

Multiple lymphomatous polyposis of the gastrointestinal tract is a distinct clinicopathologic entity. This rare form of primary gastrointestinal lymphoma occurs most often in elderly patients and accounts for 9% of all gastrointestinal lymphomas.<sup>197</sup> The polyps can be widespread throughout multiple segments of the gastrointestinal tract. Histopathologic and immunohistochemical techniques are required to differentiate lymphomatous polyposis from other forms of gastrointestinal polyposis.

**Kaposi Sarcoma.** This commonly multifocal angiosarcoma has been associated with herpesvirus-8 (HHV-8) infection in conjunction with immunosuppression (eg, HIV/AIDS, chronic steroid or immunosuppressant medication, etc). The incidence in organ transplant recipients is about 0.5–0.6% but most frequently involves the skin. Extremely rarely, however, the anorectum or intestines are involved and shows characteristic bluish-purple submucosal nodules. Treatment primarily aims at improving the immune status, but chemotherapy and, rarely, radiotherapy may be indicated in patients in whom the immune status cannot be restored.<sup>198</sup>

**Smooth Muscle Tumors.** Smooth muscle tumors of the colon are rare and occur most commonly in the form of a pedunculated leiomyoma of the muscularis mucosa. Leiomyosarcomas, which consist histologically of spindle cells that resemble smooth muscle cells, are even less frequent but are characterized by an extremely aggressive and rapidly fatal growth pattern. Whenever possible, oncologic resection and adjuvant chemotherapy are the treatment of choice.<sup>199</sup>

## SECONDARY TUMORS TO THE COLON

**Endometriosis.** Endometriosis may involve the colon or rectum in approximately 15–20% and may mimic colonic carcinoma. The lesions are rarely larger than 5 cm, involve the subserosa and muscle coats, and may project into the lumen of the bowel. When endometrial tissue extends through to the colonic mucosa, biopsy may be mistaken for adenocarcinoma.

**Invasion From Extracolonic Cancers.** Locally advanced tumors from noncolonic primary cancers may directly invade the colon and cause symptoms suggestive of colon cancer (bleeding, obstruction, fistula). These tumors originate from organs in close adjacency to the colon (female organs, bladder, prostate, kidneys, pancreas, duodenum, liver).

**Metastatic Cancer.** Carcinomas from other primary sites may metastasize to the colon and occasionally mimic a primary colon cancer. Metastases originate most commonly

from lobular breast cancer, stomach cancer, ovarian cancer, malignant melanoma, and leukemia, the latter of which can be diagnosed by the hematopoietic infiltrates.

## SURGICAL ANATOMY OF THE COLON

A fundamental knowledge of the anatomy is unquestionably a key to success-oriented surgical technique aiming at the best oncological outcome and a minimized morbidity. The large intestine starts at the ileocecal junction and extends to the anus. It is about 5–6 ft (125–150 cm) long and can be divided into the cecum with the appendix, the ascending colon, the transverse colon, the descending colon, the sigmoid colon, and the rectum. Definitions of where the sigmoid colon ends and the rectum begins have not always been uniform. The best definition of the rectosigmoid junction from a functional as well as surgical viewpoint is the confluence of the teniae coli.<sup>200</sup> However, the inability to visualize this anatomic reference point endoscopically recently led the NCI and other expert committees to define the rectum for the purpose of uniformity in clinical trials as the last 12–15 cm above the anal verge as measured by rigid sigmoidoscopy.<sup>201</sup> This endoscopic definition is necessary in order to determine the appropriateness of preoperative (neoadjuvant) chemoradiation for rectal but not sigmoid cancer.<sup>201</sup> Obsolete because highly variable and therefore inaccurate definitions relate the rectosigmoid junction to the level of (1) the peritoneal reflection or (2) the sacral promontory.

The arterial and venous blood supply, as well as the lymphatics of the colon, is summarized in Fig. 36-5. The arterial blood supply to the colon comes from the superior mesenteric artery (SMA) and the inferior mesenteric artery (IMA), which communicate in a watershed area in the splenic flexure

(artery of Drummond). The rectum has additional branches from the internal iliac vessels. With a significant degree of anatomic variation, the major vascular stalks to the colonic segments consist of the ileocecal and right colic artery (last branch of the SMA), the middle colic artery (second branch of the SMA), the left colic artery (first branch of the IMA), and the superior hemorrhoidal artery (distal branch of the IMA). The venous blood supply peripherally follows the arterial branches but more centrally divides into the superior mesenteric vein and the inferior mesenteric vein, which connect at separate levels to the portal system. The lymphatic drainage starts with lymphatic follicles in the colonic submucosa, drains through the colonic muscle wall into the epicolic nodes, and continues to the paracolic lymph nodes that follow the blood vessels to the bowel, along the major arteries to the principal lymph nodes at the level of the arterial runoff from the aorta. These lymph node groups consist of the celiac, the superior mesenteric, and the inferior mesenteric groups of lymph nodes.

For a safe surgical technique, the relationship of the colon with adjacent structures, mostly in the retroperitoneum, has to be fully understood. The colon is only a partially intraperitoneal organ. Only the transverse colon and the sigmoid colon are fully peritonealized and have a free mesocolon; the ascending colon and the descending colon, including both flexures, are partially located in the retroperitoneum and therefore reside in proximity to essential anatomic structures. The structures most at risk during a right hemicolectomy include the right ureter and the duodenum; during a transverse colon resection, the SMA/SMV (and its branches) and the gastroepiploic vessels at the gastric curvature; during a takedown of the splenic flexure, the spleen, pancreas, and left kidney; and during a left colon or sigmoid resection, the left ureter, the gonadal vessels, and the hypogastric nerves.

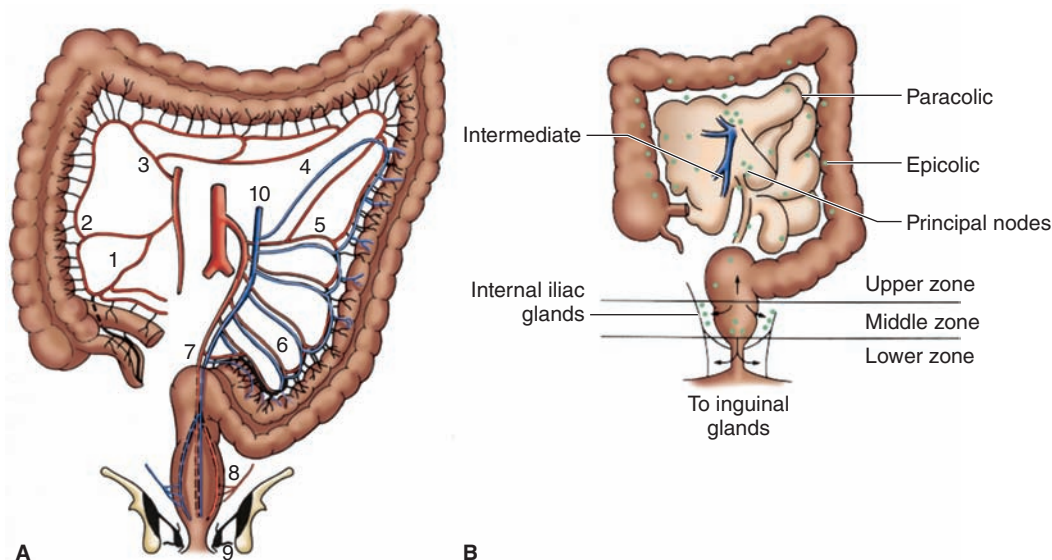


FIGURE 36-5 Anatomy of the colon. **A.** Arterial and venous supply of the colon. **B.** Lymphatic drainage of the colon.

## CLINICAL PRESENTATION OF COLORECTAL CANCER

### Symptoms and Differential Diagnosis

Colorectal cancer does not have any early signs. In fact, symptoms are often absent until a tumor has grown to a significant size. Unless a patient presents with a tumor complication (eg, bowel obstruction, bleeding, perforation, or fistula formation), symptoms mostly are subtle or uncharacteristic and vague. They may consist of unexplained weight loss, anemia and weakness from chronic blood loss, flatulence, or episodes of colicky abdominal pain. If present, these symptoms therefore always should be suspicious for a locally relatively advanced tumor stage, which is also reflected by the fact that about 20% of colorectal cancer patients at the time of their first presentation already have stage IV disease with distant metastases (Table 36-13). As the stool in the proximal colon is still liquid or at most semisolid, proximal colon tumors may grow to relatively large size before they cause an obstruction. The more distal a lesion is localized (eg, left colon or rectum), the more likely the changes in bowel habits occur. These include rectal bleeding or mucous discharge in or with the stool, sudden onset of constipation, alternating periods of diarrhea and constipation, or a decreasing diameter of the stool. Pelvic or anal pain is an ominous sign because it may occur with increasing size, perforation, or sphincter invasion of a rectal cancer.

Any large bowel obstruction, bleeding per rectum, gas or stool passage other than through the anus, or peritoneal signs should raise the index of suspicion for a colorectal malignancy until proven otherwise. Several other conditions and diseases have to be considered in the differential diagnosis. Obstructive symptoms may result from chronic diverticulitis, benign polyps, Crohn's disease, endometriosis, or a postschismic stricture. A fistula may suggest complicated diverticulitis, Crohn's disease, or tuberculosis. Bleeding per rectum may also be found in hemorrhoids and other benign anorectal conditions, diverticular disease, arteriovenous malformations, endometriosis, and proctitis or colitis. However, even if one of these benign diseases is

found on clinical evaluation, the symptoms should not be attributed automatically to them before a malignant disease of the large intestine has been ruled out.

Because symptoms are not reliable for the prevention or early detection of colorectal cancer, risk-adjusted screening programs for otherwise asymptomatic individuals (as discussed in an earlier section of the chapter) are crucial in order to achieve a reduction in cancer mortality.

Not only management planning in a situation with acute cancer complications should include strategies to alleviate symptoms and minimize the morbidity from the complication but also should provide an oncologically adequate treatment for the tumor.

### History and Physical Examination

A careful history and physical examination remain the cornerstone in all patients presenting with gastrointestinal symptoms. This review should include questions about changes in bowel habits, time of last stool and gas passage, weight loss, and a personal or family history of cancer, particularly of colorectal cancer or its precursor lesions. Awareness of possible underlying diseases and genetics that predispose to colorectal cancer is of utmost importance not only for the management of the individual patient but also for adequate counseling of potentially affected family members.

A careful physical examination follows to identify any palpable tumor masses and/or signs of tumor complication or dissemination. Apart from vital signs and temperature, the patient's general appearance may reveal evidence of cachexia, dehydration, jaundice, or lymph node enlargements. For example, enlargement of the left supraclavicular nodes may be the first but late sign of a disseminated gastrointestinal malignancy (Troisier's sign). The abdomen is examined for a palpable primary tumor, hepatomegaly (liver metastasis?), distension and/or tympanitic bowel sounds (partial or complete bowel obstruction?). Presence of peritoneal signs such as guarding with local direct and rebound tenderness or percussion tenderness may indicate a tumor perforation. A digital rectal examination and proctoscopy are mandatory to rule out involvement of the rectum or to determine the exact distance of a distal and possibly palpable tumor from the anal verge, its axial and circumferential extent, and the mobility of the tumor against surrounding structures (eg, sacrum, prostate/ vagina, anal sphincter muscle). In addition, the checking finger should assess the rectal vault for the presence of stool, blood, or melena.

A thorough general physical examination is necessary to evaluate the patient's general health status regarding the ability to tolerate a major abdominal procedure under general anesthesia. Particular attention has to be paid to patients who present with acute symptoms in an emergency setting. Prolonged fasting, nausea or vomiting, and translocation of fluids into the third space during a period of bowel obstruction or after a perforation will rapidly result in a state of malnutrition and

**TABLE 36-13: DISTRIBUTION OF SINGLE COLON PRIMARY CANCER BY STAGE**

Stage	Number	(%)
0,I	1845	(37.8)
II	1085	(22.2)
III	825	(16.9)
IV	955	(19.6)
Unspecified	168	(3.4)

Data from Passman MA, Petrelli N, Carlin A, et al. Guidelines 2000 for colon and rectal cancer surgery. *JNCI*. 2001;93(8):583-596.<sup>202</sup>



dehydration. Developing sepsis or acute and recurrent blood loss potentially aggravate these symptoms and may result in a severe volume loss. Alarming signs are a decrease in urine output, tachycardia, hypotension, elevated temperature, short-term weight loss, standing skin folds, dry oral mucosa, and acidosis. Immediate fluid and volume resuscitation has to parallel the further clinical workup and monitoring. Blood tests have to be interpreted with caution; for example dehydration may result in an artificially high hematocrit and mask a significant loss of blood.

## Investigations

Patients with symptoms suggestive of colorectal cancer should undergo a series of timely investigations with three goals: (1) to assess the large bowel regarding the primary lesion, concomitant lesions, and a potential underlying colonic disease, (2) to determine whether the tumor has metastasized, and (3) to assess the patient's operability (overall condition and comorbidities).

### COMPLETE EVALUATION OF THE LARGE INTESTINE

Irrespective of the method used, the primary goal is to document the presence of a malignant pathology and to rule out concomitant lesions in other segments of the large intestine. Both endoscopic and radiological techniques are available for evaluation of the colon and rectum, and each type of examination has inherent strengths and weaknesses.

**Rigid Proctoscopy and Flexible Sigmoidoscopy.** These first-line diagnostic tools are used mostly in the outpatient setting to accurately assess lesions in the distal colon and rectum. The two methods are rapid, widely available, and require only minimal bowel preparation (enema). However, they do not provide complete information about the rest of the colon, and therefore a complementary study is indicated before surgery. Furthermore, the flexible sigmoidoscope is notorious for giving inaccurate measurements of the level of the tumor. Determination of the rectal versus colonic location of the tumor should be done with a rigid proctoscope.

**Colonoscopy.** Colonoscopy clearly has evolved as the method of choice because of its high sensitivity in detecting tumors and its ability to take biopsies. It provides accurate information about the entire colonic mucosa (ie, polyps, synchronous cancer, colitis, melanosis, and diverticula), and it may be used to remove synchronous neoplastic polyps. Apart from determining the circumferential and longitudinal extent of a colonic lesion, colonoscopy addresses functional aspects such as active bleeding or an imminent obstruction by cauterization, laser ablation, or placement of a self-expanding metallic wall stent, hence allowing for turning an emergency situation into an elective one.

While the overall risk of colonoscopy is very low with a much less than 1% incidence of a bowel perforation, there are some limitations to the technique. There is a 25% risk of smaller lesions to escape detection, and an estimated 10% incidence that the cecum for technical reasons may not be reached. In addition, the precise position of a lesion seen on colonoscopy may not be determined adequately unless one of the two absolute landmarks (dentate line, or the carpet-like villi of the terminal ileum) is in direct proximity. Relative landmarks (eg, assessment of the endoscopic shape of the colon, liver and spleen shadow, ileocecal valve, appendiceal orifice) or the length of instrument insertion from the anal verge vary considerably and should not be used. In practical terms, however, this handicap may be overcome by India Ink tattooing of the area of a lesion for better identification during surgery or repeat endoscopy.

**Contrast Enema.** Radiographic contrast enemas alternatively can be used for a colonic evaluation. Contrast enemas are an especially valuable adjunct to colonoscopy in patients with near-obstructing colonic lesions. Furthermore, they have the advantage of more accurately visualizing the anatomic position of a colonic lesion (road map). Ideally, a barium-air double-contrast technique will be used after bowel cleansing; however, in a more acute setting, particularly if there is suspicion of a colonic perforation, administration of barium is contraindicated (risk of barium peritonitis), and instead, a water-soluble contrast material (eg, Gastrografin [diatrizoate meglumine]) should be used in a single-column technique.

The typical aspect of a colon cancer is a fixed filling defect with destruction of the mucosal pattern in an annular configuration ("apple core"), as opposed to an intact mucosal pattern in a filling defect from an extramucosal compression or from chronic diverticulitis. Although preoperative histologic confirmation of a colon cancer is preferable, an unequivocal and characteristic morphology on a barium enema or endoscopy is sufficient evidence to proceed to surgery. Contrast studies have the advantages of a better passage through even severely obstructing lesions and that they commonly reach the cecum. In addition, they are superior in visualizing diverticula or a suspected fistula between the colorectum and other pelvic organs. The major disadvantage of contrast studies is the inability to take biopsies and to detect small lesions.<sup>95</sup>

**Evolving Techniques.** CT colonography ("virtual colonoscopy")<sup>203,204</sup> and the microcapsule study have evolved in the last decade as high-tech alternatives to the two previously described methods. It should be noted that CT colonography still requires patients to undergo a bowel preparation, and that air insufflation is necessary. While there is certainly a lot of promise for both new approaches, which likely will continue to improve over time, the definite role of these techniques awaits further clarification.

Early studies suggested that CT colonography had a considerable rate of false-negative and false-positive results.<sup>204,205</sup> In a recent study of 937 patients with risk factors for colorectal

cancer, CT colonography had a sensitivity of 85% for lesions 6 mm or larger.<sup>92</sup> So far, the technology has not been approved by Medicare for screening purposes, but this may change in the future with additional validation studies. Unfortunately, incidental extracolonic findings may precipitate a large number of unwarranted tests, which add tremendous cost to the health care system. Currently, CT colonography may serve a useful purpose in patients for whom a colonoscopy is undesirable or unsuccessful.

## EVALUATION OF THE LOCAL TUMOR EXTENT AND OF METASTATIC DISSEMINATION

Traditionally, the preoperative staging for colon cancer did not mandate further imaging studies because in the majority of cases they do not change the local surgical approach. Increasingly, however, preoperative cross-sectional imaging (CT or MRI) has become the standard of care.<sup>206,207</sup> The justification for this shift is twofold. First, patients with a significant burden of liver disease (>50% liver replacement) may carry a prohibitive risk for general anesthesia and should be treated with chemotherapy either in advance of surgery or instead of it. CT scans are the most commonly used cross-sectional imaging technique in the United States and have a 90% and 95% sensitivity and specificity in detecting liver lesions larger than 1 cm.<sup>208</sup> Second, the surgeon can be alerted to evidence of advanced locoregional disease that may alter the operative plan and necessitate the involvement of other operative expertise (eg, hepatobiliary surgery, urology, gynecology, etc).

In order to rule out extrahepatic, in particular pulmonary metastases, a chest x-ray in two planes commonly is sufficient, although the yield of this test is relatively low. A CT scan of the chest may be necessary to substantiate a concern from conventional images and is only a minimal incremental burden for a patient who is already undergoing such a study of the abdomen and pelvis.

Positron emission tomography (PET) has an evolving role in the evaluation of metastatic disease. While the routine use of PET scanning in the primary management of colorectal cancer is not recommended at this time, this technology does appear to have greater sensitivity for metastatic disease.<sup>209</sup> The extent to which this greater sensitivity can be translated into an algorithmic approach to staging remains to be seen. Its greatest utility at the current time is (1) in patients where systemic disease is suspected (eg, high tumor markers) but not proven, and (2) under special circumstances where the presence of previously unknown tumor manifestations (eg, recurrence vs scar tissue, solitary vs multiple liver metastases, and presence of extrahepatic metastases) would have an impact on the treatment approach (eg, operative vs nonoperative).

## LABORATORY AND PREOPERATIVE TESTS

Preoperative laboratory tests are aimed at providing evidence for pathophysiologic effects of the tumor and ruling out

general health problems that could have an effect on the patient's general operability. A comprehensive workup includes a complete blood count, electrolytes, creatinine/blood urea nitrogen (BUN), glucose, liver function tests (alkaline phosphatase, aspartate aminotransferase [AST], alanine aminotransferase [ALT], bilirubin, total protein, albumin), and coagulation parameters (prothrombin time [PT], partial thromboplastin time [PTT], international normalized ratio [INR]). Arterial blood gas analysis and additional tests will be ordered in an emergency setting or according to the individual patient's risk assessment (eg, cardiac enzymes, etc).

Even though tumor markers such as carcinoembryonic antigen (CEA) are determined routinely, their role is limited because of the low sensitivity and specificity for colonic carcinoma and because the measured value virtually never changes the management. CEA can also be elevated in proximal gastrointestinal cancers, benign inflammatory conditions of the bowel, lung and breast cancer, and smoking. Nonetheless, CEA level determination may prove helpful in some settings, for example when the return of an elevated preoperative CEA level to normal indicates a complete tumor resection or when a postoperatively elevated level may indicate residual or recurrent disease.<sup>210</sup>

Preoperative standard evaluation includes a chest x-ray in two planes for cardiopulmonary assessment and for detection of pulmonary metastases (see previous sections). Electrocardiogram (ECG) and pulmonary function tests (forced vital capacity [FVC], forced expiratory volume in 1 second [FEV<sub>1</sub>], residual volume [RV], and diffusion capacity) are indicated in patients either older than 40 years or with a respective personal history. Specialized tests such as cardiac stress tests, echocardiogram, perfusion scintigraphy, or interventional cardiologic studies depend on the individual patient's history and risk assessment.

## TREATMENT

### Principles of Surgical Management

As a basic principle, any colorectal cancer is an indication for surgery unless widespread tumor dissemination or general contraindications from the patient's overall health status are present. Furthermore, any precursor pathology with statistical risk for cancer (eg, large sessile polyp in an otherwise healthy individual or dysplasia in a patient with ulcerative colitis) that cannot be managed nonoperatively is an indication for surgery.

The general goal for surgical management is either to achieve cure from the tumor and extension of survival or at least disease-free survival or, in the case of a precursor pathology with or without an underlying disease (eg, ulcerative colitis or FAP), to prevent the cancer and ideally to remove the risk-bearing disease. In a palliative setting, the goal is to prolong the period of symptom-free survival.

Local tumor control generally is the primary treatment objective to prevent local tumor complications, that is,

obstruction, perforation, fistula formation, bleeding, and pain. Even in the presence of distant metastases in the liver or lung, resection of the primary tumor remains a reasonable priority. Because solitary or a limited number of metastases in the liver or lung often may be treated surgically by partial organ resection or metastasectomy with a cure rate of up to 35%, their presence should not necessarily alter the surgical approach to do a curative resection at the primary site. However, if there are extensive metastases or peritoneal carcinomatosis and cancer cure is not a reasonable goal, alleviation of symptoms and prevention of impending local complications, for example by restoring the intestinal continuity, is the best palliation.

The specific surgical and oncologic strategy planning is based on a number of factors. It has to take into account the exact localization of the tumor, the tumor stage, the presence of synchronous colonic lesions or an underlying colonic disease, the risk for metachronous lesions, the patient's age and general condition, the extent of the local procedure, and the timing. Only after the extent of the operation has been defined can the method and approach to be used be discussed as to whether the procedure is only suitable for an open laparotomy approach or laparoscopy may be reasonable and beneficial.

In contrast to rectal cancer, neoadjuvant treatment (ie, preoperative chemoradiation) is not indicated in the overwhelming majority of colonic cases. In patients with resectable metastases, preoperative chemotherapy followed by a combined colon and liver resection may be an attractive alternative to a staged resection and may help in assessing the tumor response to a particular chemotherapy regimen. Only rarely is a locally very advanced lesion treated with chemotherapy in anticipation of an otherwise unresectable mass. Adjuvant (ie, postoperative) treatment is discussed in a later section.

## PREPARATION FOR SURGERY

When a patient is considered an operative candidate, several preparatory steps need to be addressed.

**Transfusion.** Most colonic operations can be performed without a blood transfusion. Blood-sparing surgical techniques have reduced the need while the threshold to transfuse has substantially increased. The indication will depend on the starting hemoglobin, the patient's age and physiologic status, a history of ischemic events (coronary, stroke, etc), and the extent of expected and real intraoperative blood loss. As a routine, it is recommended to have the patient's blood typed and screened, but to reserve crossmatching units of blood for these higher-risk situations.

While the risk of blood-borne infections is very low, there is some controversy as to the immunologic effect of blood transfusions on the overall prognosis of colorectal cancer. Because the initial report that transfusion may be associated with an increased likelihood of recurrence,<sup>211</sup> many

subsequent reports have reached conflicting conclusions. Meta-analysis studies have strongly questioned whether there is a true causal effect present.<sup>212</sup> Other factors such as extent of resection required, tumor location, and experience of the surgeon actually may be the more relevant cause for recurrence, but transfusion may be an indirect reflection of extensive disease and surgery. Furthermore, a randomized trial comparing the use of autologous versus allogenic blood in patients undergoing colorectal resections did not show any statistical difference in prognosis.<sup>213</sup>

**Bowel Cleansing.** Traditionally, bowel cleansing was considered an essential preparation to any elective colon surgery. The rationale is based on the colon being a large reservoir for numerous anaerobic and aerobic bacteria. However, recent prospective, randomized, controlled studies and meta-analyses comparing mechanical preparation versus no preparation for elective colorectal surgery have failed to demonstrate any appreciable decrease in infection rates, anastomotic leaks, or mortality rates in patients undergoing mechanical bowel preparation.<sup>214–220</sup> Contrasting with the evidence, however, the majority of colorectal surgeons still perform bowel cleansing in their patients. The indisputable advantages of a bowel preparation remain (1) the intraoperative ability to perform a colonoscopy if that were needed, and (2) the absence of a preanastomotic stool load if a primary anastomosis or the tissue quality were unexpectedly less than optimal and asked for a fecal diversion.

There are a wide variety of laxatives, washouts, and enemas available on the market for mechanical cleansing, but the products used generally are based on either polyethylene glycol (eg, GoLYTELY) or sodium phosphate (Fleet Phospho Soda), the latter of which is contraindicated in patients with renal failure and has come under more broad scrutiny in the United States. In the absence of a consensus regarding the best regimens (ie, orthograde cleansing alone or combined with retrograde enemas), the choice often is a matter of personal preference. Depending on an individual patient's constitution and the degree of obstruction, the bowel cleansing should be started 1 or even 2 days before surgery. The cathartic may result in significant fluid and electrolyte imbalances. Elderly patients, who are more prone to this adverse effect, therefore should preemptively be given intravenous fluids and electrolytes.

**Antibiotic Prophylaxis.** Perioperative administration of prophylactic antibiotics aims at reducing colonic and dermal bacterial concentrations and is considered a crucial component of colorectal procedures. The benchmark is the rate of surgical site infections in relation to the level of wound contamination. Prophylaxis has to be distinguished from therapeutic antibiotic treatment in patients who already have an established infection. Prophylaxis (ie, in patients who do not primarily suffer from an infection) should be targeted, adequately dosed, and short (ie, start within 1 hour of the incision and be limited to less than 24 hours) in order to



minimize antibiotic side effects and propagation of resistances. Coverage should include both aerobic bacteria (eg, *Staphylococcus*, *Escherichia coli*, *Klebsiella*, *Proteus*, etc) and anaerobic bacteria (eg, *Bacteroides fragilis*, *Clostridium*).

Intravenous administration of broad-spectrum antibiotics is the most common form of prophylaxis and includes several acceptable antibiotic selections: (1) single antibiotics (ertapenem, piperacillin-tazobactam); (2) combination of two antibiotics (second- or third-generation cephalosporin + metronidazole, fluoroquinolone + metronidazole, clindamycin + aminoglycoside, clindamycin + quinolone, clindamycin + aztreonam); or (3) triple combinations such as amoxicillin-clavulanic acid + metronidazole + aminoglycoside. Oral antibiotics (eg, metronidazole combined with nonabsorbable neomycin) in conjunction with a mechanical bowel preparation may yield similar results but may increase the risk of nosocomial superinfections, in particular with *Clostridium difficile*.

Special considerations according to national guidelines have to be followed for prophylaxis in patients at risk for endocarditis (eg, patients with mechanical heart valve).

**Thromboembolic Prophylaxis.** Thromboembolic prophylaxis is recommended in all patients undergoing major surgical procedures to reduce the incidence of postoperative deep venous thrombosis and pulmonary embolism. Both pharmacologic and physical prophylaxis (eg, pneumatic calf compression) have been proven to be effective,<sup>221</sup> but the use of pharmacologic prophylaxis has recently been endorsed by a task force recommendation.<sup>222</sup> Both low-dose unfractionated heparin and low-molecular-weight heparins (LMWHs) have been shown to be equally effective in reducing the incidence of postoperative thromboembolic events without resulting in significant complications.<sup>223</sup> A recent randomized study, however, showed that LMWHs have a slightly higher rate of minor bleeding events.<sup>224</sup> Based on economic analysis, the data favor the use of subcutaneous heparin as being more cost-effective than LMWHs.<sup>225</sup> It is recommended that these drugs be commenced at least 2 hours before surgery and continued postoperatively until the patient has obtained full ambulation. Intermittent pneumatic calf-compression boots are an alternative to heparin that has been demonstrated to be equally successful in preventing deep venous thrombosis and possessing the advantage of no risk of increased bleeding.<sup>226</sup> It remains to be determined whether a combination of chemical agents and pneumatic calf-compression boots for patients undergoing colonic resection will be an advantage.

Anticoagulated patients who need to take warfarin (eg, owing to a mechanical heart valve) should be switched perioperatively to intravenous heparin to allow for stopping the warfarin medication and antagonizing its effect with vitamin K. Four hours before incision, the heparin may be discontinued and resumed within 24 hours postoperatively with a stepwise increase in the dose.

**Urinary Catheters/Stents.** After induction of general anesthesia, bladder catheterization should be performed in all major cases to adequately monitor the urine output peri- and postoperatively. In selected patients with a previous history of colorectal or pelvic dissections, placement of ureteral stents allows better intraoperative identification and protection of these crucial structures. Laparoscopic colon procedures do not routinely need ureteral stents; however, selective use of lighted ureteral stents during challenging laparoscopic procedures may facilitate identification of these structures.

**Nasogastric Tube.** Placement of a nasogastric tube is not necessary on a routine basis for patients undergoing resection of the colon or rectum and should be avoided unless they present with a complete or partial bowel obstruction.<sup>227</sup>

**Preoperative Marking of Ostomy Site.** In patients who may need permanent or temporary placement of an ostomy during the surgical procedure, preoperative marking of the ideal stoma site by a stoma nurse helps to facilitate postoperative ostomy handling by the patient.

**Preemptive Pain Management.** Effective pain management is an important factor not just for patient comfort but to reduce the incidence of postoperative pulmonary complications. Preoperative placement of epidural analgesia is a very valuable strategy, which, in addition to its pain-relieving effect, promotes the earlier resumption of postoperative bowel function as a result of its suppression of sympathetic nerves. The relevant segments that need to be blocked for an abdominal incision are located at a thoracic level (T6–T12).

## Surgery

### GENERAL TECHNICAL PRINCIPLES

The objective of surgery for colonic cancer is to perform a curative resection by removing the cancerous segment of colon, the mesentery with the primary feeding vessel and the lymphatics, and any organ with direct tumor involvement. Because the lymphatics run with the arterial supply of the colon, the primary artery supplying the segment of the colon to be resected is divided at its origin. Ligation at the origin of the vessel ensures inclusion of apical nodes, which may convey prognostic significance for the patient.<sup>228</sup> While careful dissection in the right place is the mainstay of a successful surgery, the historical Turnbull no-touch technique with early vascular ligation and occlusion of the bowel with tapes to prevent embolization of tumor and improve survival has not shown any advantage.<sup>229</sup>

The length of bowel and mesentery resected is dictated by tumor location and distribution of the primary artery (Table 36-14), but a radical resection of a colonic tumor should achieve at least a 5-cm clearance at the proximal


**TABLE 36-14: STANDARD RESECTIONS OF THE COLON**

Tumor Location	Resection	Description of Extent	Major Blood Vessel	Safety Margin (cm)
Cecum	Right hemicolectomy	Terminal ileum to midtransverse colon, right flexure included	Ileocolic artery, right colic artery, right branch of mid colic artery	5
Ascending colon	Right hemicolectomy	Terminal ileum to midtransverse colon, right flexure included	Ileocolic artery, right colic artery, right branch of midcolic artery	5
Hepatic flexure	Extended right hemicolectomy	Terminal ileum to descending colon (distal to left flexure)	Ileocolic artery, right colic artery, midcolic artery	5
Transverse colon	Extended right hemicolectomy (Transverse colon resection)	Terminal ileum to descending colon (distal to left flexure) Transverse colon (including both flexures)	Ileocolic artery, right colic artery, midcolic artery Midcolic artery	5
Splenic flexure	Extended left hemicolectomy	Right flexure to rectosigmoid colon (sigmoid, beginning of rectum)	Midcolic artery, left colic artery, inferior mesenteric artery	5
Descending colon	Left hemicolectomy	Left flexure to sigmoid colon (beginning of rectum)	Inferior mesenteric artery, left branch of midcolic artery	5
Sigmoid colon	Rectosigmoid resection	Descending colon to rectum	Superior hemorrhoidal artery, inferior mesenteric artery	5

and distal margin. Extended resections for confined tumors outside of high-risk patients have not been shown to confer additional survival benefit<sup>230</sup>; however, tumors located in “border zones” should be resected with both neighboring lymphatics to encompass possible bidirectional spread. If a tumor is adherent to or invading an adjacent organ such as the kidney or small bowel, an en bloc resection should be performed where technically feasible. Because adhesions between the tumor and adjacent organ may not necessarily be inflammatory, but, because of carcinoma, mere division or “pinching” of a tumor from an adjacent organ is not an acceptable surgical technique because it may reduce the chance of cure.

When synchronous cancers are present in the colon, an extended resection or even total colectomy, with ideally only one anastomosis, should be performed. Occasionally, two separate resections (eg, right hemicolectomy and low anterior resection) with two anastomoses are preferable to preserve colon length and to avoid postcolectomy diarrhea. Cancer on the basis of an underlying pancolonic disease (eg, ulcerative colitis or FAP) requires a total proctocolectomy with either an ileoanal pull-through procedure or an ileostomy<sup>80</sup>; young patients (<50 years, with/without proven HNPCC gene constellation) presenting with tumors proximal to the sigmoid colon should be offered a total abdominal colectomy to reduce the risk of metachronous cancers and to facilitate surveillance.<sup>231</sup>

A limited wedge resection may be considered for an unfit patient or for palliative resection in those with widespread tumor. This will relieve the patient's symptoms and prevent future obstruction and bleeding from the primary tumor.

#### INTRAOPERATIVE SURGICAL TECHNIQUE

**Positioning.** For all left-sided colonic resections, it is advisable to place the patient in a modified lithotomy position, which gives access to the anus (eg, for a stapled anastomosis) and allows an assistant or the surgeon to stand between the legs for retraction or an excellent view to mobilize the splenic flexure, respectively. The same positioning obviously also can be used for all other colon resections, but a supine position usually is sufficient and faster. Laparoscopic procedures typically require the operating table to be tilted and moved to steep Trendelenburg's position; appropriate fixation and securing of the patient is therefore mandatory.

**Incision.** For an open procedure, the peritoneal cavity is most commonly entered through a midline laparotomy incision. For a proctocolectomy, we usually recommend the use of an infraumbilical incision in order to provide good exposure for the pelvic dissection. For a more proximal segmental colon resection, however, an equally short but

higher midline incision may be more convenient. In addition, a transverse incision or even a subcostal incision may give excellent exposure for a right hemicolectomy.

For a laparoscopic procedure, a first camera trocar is placed in either Veress needle or in open Hasson technique. The site should be chosen such that additional working ports can be placed along a circle with the target in the center.

**Exploration.** After the peritoneal cavity is entered (open or laparoscopically), the abdomen is explored systematically to determine the resectability of the tumor. Special attention is addressed to the presence of distant metastases in the liver, peritoneal carcinomatosis, or additional synchronous lesions throughout the large intestine. Other accessible organ systems are assessed equally, for example the gallbladder and the female reproductive organs.

**Colon Resection.** The surgical technique has been standardized for three segments: right colon, left colon, and rectosigmoid. Depending on the extent of the resection eventually needed in an individual patient, the technique for those segments may be combined (see Table 36-14). With a detailed description of the maximal resection, that is, an open total colectomy/proctocolectomy, all information about the individual steps necessary to perform any colorectal resection of lesser extent will therefore be provided.

The same steps should be achieved with laparoscopic resections; however, depending on the surgeon's preference and skills, a medial-to-lateral mobilization of the colon (ie, starting at the feeding vascular stalks before moving to the retroperitoneal attachments) supports the autoretraction of the colon throughout the critical steps.

On careful exploration of the abdomen, mobilization of the colon starts on the right side. Use of a mobile (eg, Richardson retractor) instead of a fixed (eg, Balfour or Bookwalter retractor) abdominal wall retractor in this first phase will allow a more flexible and unidirectional exposure according to rapidly changing needs. The small bowel is eviscerated from the abdomen and moved to the left. The abdominal wall is retracted to the right side while exerting countertraction on the cecum and ascending colon. A small incision is made at the exposed white line of Toldt to enter the retroperitoneum. Elevating the ascending colon from the retroperitoneal structures, the peritoneum is divided along the lateral gutter from the terminal ileum to the hepatic flexure. On the right side, the ureter is at fairly low risk and routinely falls away; however, special care is needed to avoid damage to the third part of the duodenum. The mobilization is facilitated by firm traction placed on the colon and the surgeon's left hand inserted into the retroperitoneum as a guide to divide along the peritoneal reflection. Because of the limited view around the hepatic flexure and the presence of small vessels at this level, transection of the peritoneum with cautery is often advisable.

As the right edge of the gastrocolic ligament is reached, it may be easier to complete the dissection of the hepatic flexure in retrograde direction. The abdominal wall retractor

is moved quickly into the upper end of the incision in order to pull in a cephalad direction. The lesser sac is entered far to the left in an avascular portion of the omentum, and the greater omentum is divided inferior to the gastroepiploic vessels between clamps and ligatures. While the omentum may be preserved in benign diseases, its resection with the respective colon segment is part of an oncologic resection. Dissection of the gastrocolic ligament is carried out from the left to the right. Connective tissue attachments between the antrum, duodenum, and transverse mesocolon and the hepatic flexure are divided stepwise by a combination of blunt digital tunneling and sharp dissection using both hands. Care should be taken at this point to avoid dissecting too deeply into the retroperitoneum, where large blood vessels can be encountered. Once the mobilization has been completed around the hepatic flexure, the right colon and transverse colon are attached only to their vascular supply and are ready for resection. This would be used for any standard right hemicolectomy or the first part of an extended transverse colectomy. For total colectomy, mobilization of the whole colon commonly is continued before dividing the major vessels.

At this point, the abdominal wall retractor is moved to the left side of the abdomen, and traction is placed to expose the left portion of the colon. The dissection is initiated at the level of the sigmoid, where the white line of Toldt again is incised and the retroperitoneum entered. Once the areolar tissues are identified, a small sponge is taken, and with firm pressure against the sigmoid mesentery, the retroperitoneal tissues are bluntly reflected, and the left ureter is exposed. Only after the ureter has been clearly identified and moved out of the way is incision of the peritoneum continued into the pelvis for a short distance and up to the splenic flexure along the left gutter. The colon is reflected bluntly from the retroperitoneal tissues, and with firm traction the peritoneal incision is continued. Gentle traction on the transverse and descending colon will help to lower the splenic flexure until it can be visualized fully. A hand placed in the retroperitoneum will help to mobilize the splenic flexure, and under direct vision the peritoneum over the splenic flexure can be incised. Care must be taken at this point to protect the spleen from direct or traction injury. The final attachments of the splenocolic ligament that hold the splenic flexure are clamped and divided in appropriate tissue portions. Clamping and ligating this tissue are recommended because even small vessels retracting into the left upper quadrant can be a nuisance.

After completion of the first two parts, the colon is mobilized completely from its retroperitoneal attachments from the terminal ileum to the upper rectum. Elevation of the colon allows identification of all primary feeding vessels. In order to ligate the inferior mesenteric vessels, the surgeon is on the patient's left and the colon is reflected to the left. The attachments that run over the sacral promontory and up along the left gutter are incised, and a hand is used to dissect the tissues bluntly from behind the inferior mesenteric vessels. By identifying the inferior mesenteric vessels and making the window



just under those, the hypogastric nerves going down into the pelvis are protected routinely. Sometimes, for example if there is concern about cancer in the rectum or if the patient is very obese, these structures need to be freed up more to elevate the nerves initially and later to dissect them out under direct vision. The avascular window around the origin of feeding vessels then is opened. In the case of the inferior mesenteric vessels, the left hand is placed behind the inferior mesenteric stalk, and the thumb and opposing index finger can clear a window of avascular tissue above it. Dissection of redundant adipose tissue around the vessels is carried out under direct vision, before the vessels are clamped. Before transection and ligation of the vessels, the remote location of the ureter is confirmed once more. If the ureter is not identified properly before dividing the vascular pedicle, accidental dissection of the ureter can occur and requires a repair. If unrecognized intraoperatively, the ureter injury may result in a urinoma. In difficult cases (eg, repeat operation or recurrence), it is therefore advisable to place preoperative ureteral stents to allow better identification. The whole vascular stalk may be ligated with a double ligature or a suture ligature. Individual ligation of the artery and vein is optional and has not been shown to provide an advantage. For the reason mentioned earlier, it is recommended to ligate the vessels as proximally as possible, but from an oncologic standpoint a high ligation of the IMA does not provide any advantage in comparison with a low ligation distal to the origin of the left colic artery.<sup>232,233</sup>

The vascular dissection is then continued around the colonic mesentery. The avascular tissue can be divided sharply while clamping is applied to vessels when they are encountered. The vascular anatomy of the colon is quite variable. However, if one is truly in the retroperitoneum and ligating named vessels at their origin, the colon can be taken out with as few as three to four clamps. In particular, the inferior mesenteric, middle colic, and ileocolic vessels need to be ligated. The presence of additional right and left colic vessels sometimes requires the use of five or six clamps. By taking the vessels closer to their origin, that is, before they branch off into multiple subsegments, fewer clamps are necessary and the dissection proceeds more rapidly.

Once the vessels have been ligated, the bowel may be divided by means of cutting linear stapling devices at the previously determined levels. In patients with an underlying disease (eg, ulcerative colitis or FAP), the dissection at this point would be continued as a total mesorectal excision down into the pelvis to the pelvic floor (see respective chapters). It is strongly recommended to have the specimen assessed macroscopically to verify the pathology. Tumor in the resection margin means an inadequate cancer operation requiring a re-resection. Intraoperative frozen sections of the resection margins should be requested whenever there is any doubt about the completeness of the resection.

**Reconstruction/Diversion.** After the resection has been completed, either the bowel ends can be reanastomosed or the proximal end may be brought out as an ostomy. Prerequisites for a successful anastomosis are meticulous technique,

well-vascularized and healthy appearing tissues, apposition of bowel ends without any tension, and good nutritional status of the patient with an albumin level greater than 3.0 mg/dL. Constructing an anastomosis under tension and/or with poor blood supply increases the risk of an anastomotic leak that may cause an infection and sepsis. A protective diverting ostomy does not prevent the leak as such but should diminish the life-threatening complications of an anastomotic leak. While a stapled functional end-to-end anastomosis between the ileum and the colon (ie, an enterocolonic anastomosis) is reasonable, this type of anastomosis may potentially be less desirable between two colon segments (ie, a colocolonic anastomosis) because it can result in an iatrogenic giant diverticulum that may interfere with the propulsion of formed stool or impede the performance of a surveillance colonoscopy. Performing an end-to-end anastomosis, either hand-sewn or by means of a circular stapler, will avoid these problems. An ileocolonic anastomosis in most instances can be performed in an unprepared bowel, whereas a colocolonic anastomosis on the left side traditionally requires pre- or intraoperative reduction in the stool load unless a colostomy was performed. As mentioned previously, this view has come under scrutiny.

**Drains.** Placement of drains is more often a matter of personal preference than of scientific objectiveness.<sup>234–236</sup> Most bowel anastomoses, even colocolonic anastomoses, do not need to be drained. The use of drains generally may be recommended when a pelvic dissection and anastomosis have been performed and accumulation of fluid and blood in the dependent areas around the anastomosis should be avoided. Whether prospective, but underpowered, studies are sufficient evidence to effectuate a change in this practice needs to be determined.<sup>237,238</sup>

## TECHNICAL CONSIDERATIONS

**Laparotomy Versus Laparoscopy.** Laparoscopic colon surgery has a clearly established place in the management of both benign and malignant colon diseases. In many specialized centers, it is even regarded the first-line approach unless patient-specific factors suggest otherwise. The path to a nearly unanimous endorsement of the technique at least for right-sided, left-sided, and sigmoid resections for colon cancer started in the early 1990s,<sup>239</sup> moved from palliative resections to institutional case series in curative intent, and culminated in several prospective randomized trials throughout the world,<sup>240–245</sup> the first large-scale trial being a multicenter study by the NCI.<sup>241</sup> This study, which enrolled 872 patients with stages I–III colon cancer, confirmed that there was a moderate quality-of-life benefit for the laparoscopic approach<sup>246</sup> but otherwise no difference in oncological outcome and survival between the laparoscopic and open-resection groups.<sup>241</sup> Subsequently, two large-scale European prospective multicenter trials (ie, the COLOR [COlon cancer Laparoscopic or Open Resection] trial with 1248 and the CLASICC [Conventional versus Laparoscopic-Assisted Surgery In Colorectal

Cancer] trial with 794 patients) have confirmed similar results.<sup>247,248</sup> This equality of the study results offered the unique opportunity for both opponents and proponents of the laparoscopic approach to justify their personal preference for either the open or laparoscopic technique depending on their background and skills. In contrast to one early report of a high incidence of port-site recurrences, it has become clear subsequently that with appropriate surgical technique, the incidence is in the range of 0.8–1.3% and, on a stage-by-stage comparison, not higher than wound implants after open surgery.

For the laparoscopic procedure, about three to five trocars are inserted. Lacking the tactile sensation of open procedures, tattooing of the target lesion should generally be performed prior to the surgery. The colon should be mobilized to the same extent as during open surgery, but it may be advantageous to start with the vascular pedicle rather than with the retroperitoneal attachments. The technical equipment to perform an intracorporeal resection and anastomosis is available, but it is questionable whether there is any advantage to this because at some point an incision must be made anyway to retrieve the specimen. In the laparoscopically assisted technique, the segment, once it has been mobilized to the required extent, therefore is exteriorized through a small sleeve-protected abdominal incision, and an extra-abdominal resection and anastomoses are performed. The bowels are returned into the abdomen, the fascia is closed, and the pneumoperitoneum may be reinstalled to inspect the peritoneal cavity again. To facilitate complex resections, some surgeons use hand-assisted laparoscopic surgery (HALS) to combine tactile sensation with a minimally invasive approach.

**Sentinel Lymph Node Mapping.** Although the interest in lymphatic mapping and sentinel lymph nodes has been derived from favorable experiences in breast cancer and melanoma, most recent data do not support the value of this technique for colon cancer. In particular, analysis of the recent intergroup study 0114 demonstrated a lack of correlation in an alarming 54% of the patients.<sup>249</sup> Sentinel lymph node mapping not only may be misleading and therefore not useful in the management of colorectal cancer, but there also is simply no need for this technique in colon resections because the lymphadenectomy—in contrast to breast and melanoma surgery—is not associated with any morbidity.

### SPECIAL CIRCUMSTANCES IN EMERGENCY SURGERY

Approximately 20% of patients with colon cancer present as an emergency requiring an urgent operation for a tumor-related complication (eg, bowel obstruction, perforation, or massive bleeding).<sup>250</sup> Morbidity and mortality are significantly higher than under elective conditions. Contributing factors are the lack of a mechanical bowel preparation and the patient's impaired overall status, which typically is characterized by dehydration, third spacing of fluids, anemia, a

deranged metabolism with electrolyte imbalances, and possible sepsis. The risks for wound and intra-abdominal infections and anastomotic leakages are three to six times higher.<sup>251</sup>

**Tumor Obstruction.** Sixteen percent of patients with colon cancer present with a bowel obstruction and complain of colicky abdominal pain, abdominal distension, vomiting, constipation, and, occasionally, paradoxical diarrhea. Imaging studies (abdominal x-ray or CT scan) characteristically demonstrate the features of a large or small bowel obstruction depending on how proximal in the colon the obstruction is located and whether the ileocecal valve is competent. Attention should be paid to the diameter of the cecum, which presents a risk of cecal perforation if the diameter reaches 12 cm or more. Urgent intervention is required in such circumstances to prevent cecal perforation. The most important differential diagnosis is pseudo-obstruction (Ogilvie's syndrome), which is seen as a result of various medical conditions and may mimic the features of bowel obstruction. Every patient therefore should have a rigid proctoscopy, followed by a water-soluble contrast enema, which should visualize only the colon up to the site of obstruction but not beyond the stenosis because the hyperosmolar nature of the contrast material can result in an increase in the intraluminal volume and trigger a perforation.

If the level of obstruction in the colon is proximal enough, a resection with primary enterocolonic anastomosis, for example right hemicolectomy, extended right hemicolectomy, or subtotal colectomy, may be carried out. If the tumor is located on the left side of the colon, adjustments to the surgical approach are necessary because the stool load proximal to the obstruction is of concern for a colocolonic anastomosis and because that segment of the colon could not be cleared before the operation. Synchronous lesions, which in the setting of an obstructing lesion may occur in up to 15%, may be missed and necessitate further intervention in the future. Strategies then include either (1) a subtotal colectomy, (2) an on-table lavage with segmental colon resection, intraoperative colonoscopy, and primary anastomosis, or (3) performance of a two- or even three-stage procedure instead of the elective one-stage approach. Historically, obstructed left-sided tumors were treated with a three-stage approach starting with a defunctioning loop colostomy, followed by resection and anastomosis and last by closure of the defunctioning stoma. The Hartmann procedure, the classic example among several two-stage procedures, consists of a discontinuous rectosigmoid resection with creation of a terminal colostomy and a blind rectal stump in the first stage, followed by a colostomy takedown and reanastomosis in a second operation.

More recently, there has been a trend toward attempting to relieve the acute obstruction at the tumor-bearing segment by colonoscopic insertion of a self-expanding metallic stent. Successful decompression of the prestenotic colon converts the emergency situation into an elective setting, allowing for stabilization of the patient and performance of bowel preparation. The risk of a colonic perforation during stent placement is relatively low but acceptable because an emergency

operation would be necessary anyway if the stent could not be placed successfully. Several nonrandomized, noncontrolled case series have demonstrated that colonic stenting for acute obstruction is safe and highly successful.<sup>252–255</sup> A proximal diversion hence may be avoided with this procedure.

**Tumor-Related Perforation.** Colonic perforation secondary to a tumor occurs in two different settings. Either a transmural tumor perforates itself, or the proximal colon becomes overdilated, particularly in the case of a competent ileocecal valve. Both conditions may result in diffuse fecal peritonitis with significant morbidity and mortality. In addition, the tumor perforation results in spillage of tumor cells and thus has to be considered a stage IV tumor. Surgical management is indicated in every case and requires not only addressing the site of colonic perforation but also removing the tumor in an oncologically correct fashion.<sup>250</sup> The same tactical principles described in the preceding section apply.

**Massive Colonic Bleeding.** Massive bleeding from a colonic tumor is a relatively rare complication. The general algorithms for the workup and management of lower gastrointestinal bleedings apply, but, most commonly, the bleeding site can be easily identified. If the bleeding is minor or self-limited, the standard workup can be performed. If the patient is or remains unstable and requires repeated transfusions, surgical management is indicated.

## MANAGEMENT OF ADVANCED DISEASE

**Locally Advanced Disease.** It has been estimated that approximately 15% of colonic tumors will be adherent to adjacent organs.<sup>256</sup> With locally advanced colon tumors, it is still possible to achieve cure if the surgeon is prepared to resect involved adjacent organs. Unfortunately, it is often impossible to distinguish between malignant and inflammatory adhesions, but at least 40% of these adhesions are expected to harbor malignant cells. The surgeon therefore has to consider them malignant until proven otherwise and perform an en bloc resection to achieve a tumor-free margin.<sup>257</sup>

**Operable Metastases.** At the time of presentation, 20% of patients with colorectal cancer have stage IV disease. Distant metastasis, particularly liver and lung, is a major cause of death in patients with colorectal carcinoma. However, patients with asymptomatic liver metastases may have a statistically natural life expectancy of several months up to almost 2 years without any treatment. Chemotherapy and surgical metastasectomy in selected patients may improve disease-free and overall survival substantially, resulting in a cure rate of 30%.<sup>258</sup> In the case of potentially resectable metastases, resection of the colonic primary tumor therefore should be performed in an oncologic fashion.

**Inoperable Disseminated Disease.** In patients with unresectable metastatic disease, the surgical treatment goal is to

provide palliation and to prevent predictable complications. In contrast to the oncologically defined standard resections, a limited segmental wedge resection of the colon is acceptable in this setting. In particular, tumors located in the sigmoid colon or in the cecum and ascending colon are suitable for a laparoscopic or laparoscopically assisted resection because these segments can be mobilized easily to a sufficient extent to ensure a safe anastomosis. If a tumor in a patient with metastatic disease is too advanced locally to be resected safely (eg, infiltration of other organs), palliation may be achieved by creating an internal bypass or a proximal diversion.

## POSTOPERATIVE MANAGEMENT

Postoperative fast-track management after a colorectal resection has become very straightforward and routine. The immediate postoperative monitoring of vital signs, fluids, and electrolytes, as well as adequate pain control, is not different from any other major surgery. However, there has been an increased emphasis on epidural pain management, early mobilization and regular spirometry exercises, avoidance of tubes and drains (eg, nasogastric tubes), and early resumption of oral intake no later than on the first or second postoperative day with advancement to a regular diet as tolerated. Daily assessment of the abdomen and bowel activity is crucial, including careful auscultation and palpation of the abdomen to assess bowel sounds or peritoneal signs. Unless soaking, a wound dressing may be left in place until the second postoperative day or even for 5–10 days if an occlusive transparent dressing is used. The incision has to be checked daily for the presence of induration, hematoma, redness, dehiscence, or discharge of fluids (eg, pus, hematoma, or serosanguineous fluid). Large amounts of serous fluids draining from the wound should not be mistaken for a seroma but indicate a fascial dehiscence until proven otherwise. The average length of stay after colorectal resections depends on the patient's constitution but generally is in the range between 5 and 7 days for an open standard procedure, and 2 and 5 days for a laparoscopic approach. Before discharge, further tumor treatment should have been addressed with the patient. Adjuvant chemotherapy (and rarely radiation therapy) typically are not initiated before 3–4 weeks after surgery and may be delayed if infectious complications or anastomotic leaks occur.

## Complications of Surgery

The overall perioperative mortality within 30 days of colorectal resections is between 3.5 and 6%,<sup>259</sup> with less than 2% after elective but up to 20% after emergency operations. Complications of surgery may be of a general or surgery-specific nature and can be classified based on the time of their occurrence as either early (within the first 30 days) or late (after 30 days). Intraoperative complications like injury to relevant anatomic structures such as ureters, spleen, bowel, and duodenum are related to the surgical technique, to



blurred anatomic landmarks and layers owing to the disease (eg, peritonitis or massive adhesions), or to the patient's habitus (eg, obesity). Early surgery-specific complications include bleeding, most frequently within the first few days of the resection, nonspecific infections, or infections related to an anastomotic dehiscence. Other more general complications in the early postoperative period (postoperative days 1–3) commonly are related to the cardiopulmonary system and include pulmonary problems (eg, atelectasis, pneumonia, aspiration, and pulmonary embolism) and cardiac events (eg, arrhythmia, myocardial ischemia, and dysfunction). Insufficient pain control has been recognized as an important factor promoting these conditions because it results in a poor respiratory effort by the patient and the inability to cough up sputum, leading to superficial respiration and suboptimal saturation. High fever in the 3 days therefore may be related to the development of an atelectasis rather than to an early infection.

Infectious complications usually occur after the third postoperative day and may be located either intra-abdominally, in the wound, in the urinary tract, or in the lungs. The primary workup therefore includes bacteriologic cultures and stains, blood and urine analysis, and a chest x-ray.

Abdominal complications consist of delayed return of upper and lower gastrointestinal function (also referred to as *postoperative ileus*), fascial dehiscence, and anastomotic breakdown. Clinical leaks occur in 1–2% of all colonic resections, but subclinical leaks are more frequent and may be seen incidentally on contrast studies in otherwise asymptomatic patients. A leak may present with insidious symptoms such as fever, tachycardia, abdominal distension, ileus, feces draining through a drain or the wound, or local and generalized peritonitis. Occasionally, a leak may present with sudden deterioration, generalized peritonitis, and septic shock as the result of a significant and rapid contamination of the peritoneal cavity. Owing to the heterogeneous symptoms, a leak should be suspected in any patient who is not progressing to the expected degree. Blood parameters such as white blood cell counts and C-reactive protein may be elevated but are nonspecific and difficult to distinguish from a normal postoperative reaction. After an abdominal operation, normal free air should be resorbed within 7–10 days.<sup>260</sup> The presence of substantial free subdiaphragmatic air later in the course should therefore raise the index of suspicion for an anastomotic leak.

Imaging studies to define the presence of an anastomotic leak include a water-soluble contrast enema to visualize extravasation of the contrast material and/or a CT scan with oral, intravenous, and possibly rectal contrast material. Apart from antibiotic treatment, the management of an anastomotic leak depends on its presumed extent and the clinical presentation. A patient with generalized peritonitis requires a relaparotomy after appropriate resuscitation. Depending on its location, the anastomosis either should be taken down and the ends should be exteriorized or, in more favorable conditions, resected, and a new anastomosis performed with healthy-looking bowel ends, either with or without proximal diversion. A local repair alone carries a high risk of failure but may succeed in combination with drain placement and a

proximal diverting ostomy. By the time of the reexploration, the prolonged peritonitis in some cases already may have transformed the bowel loops into rigid pipes that would not allow any mobilization for an ostomy or for a new anastomosis. In such a case, creation of a confined leak by means of a catheter enterostomy may be a desperate attempt for local control. A fecal fistula can be managed in a conservative manner if there is no evidence of generalized peritonitis or uncontrolled sepsis. Under favorable conditions, including good nutritional support and absence of a distal obstruction or disease of the involved bowel segment, the fistula may close spontaneously. The surrounding skin will need special care, and a stoma therapist will be helpful in this regard.

## Adjuvant Chemotherapy and Radiotherapy

The rationale for adjuvant chemotherapy is based on the fact that we are clearly not as successful with surgical treatment as we would like to be. 5-Fluorouracil (5-FU) was the first and most extensively evaluated drug for the treatment of colorectal cancer. Multiple studies had been completed without proof of value until Krook's study.<sup>261</sup> Subsequently, a review of 29 randomized trials concluded that adjuvant chemotherapy for colon cancer resulted in a 5% improvement in survival.<sup>262</sup> When studies using 5-FU-based regimens are analyzed, there is a 2.3–5.7% absolute improvement in 5-year overall survival. However, when just those at high risk of recurrence are treated, the improvement in survival in this group is closer to 30%. Patients with stage III colon cancer are recognized to be at high risk for recurrence, and administration of 5-FU/leucovorin (LV) for 6 months after surgery has proven to decrease recurrence and improve long-term survival.<sup>263</sup> The combination treatment of 5-FU/LV for 6 months was proven to be equivalent in efficacy to 12 months, and the addition of levamisole to 5-FU/LV did not seem to add any benefit.<sup>264</sup> Low-dose LV also was demonstrated to be equally efficacious as high-dose LV when used in combination with 5-FU. Thus the first-line standard of treatment from 1998 to 2000 was a combination of 5-FU and low-dose LV (folinic acid) given for 6 months on either a weekly schedule or 5 consecutive days every 4 weeks. At present, there is not enough evidence to recommend the routine use of adjuvant chemotherapy in stage II disease. Lenz and colleagues have demonstrated that molecular or genetic markers may better identify subgroups of patients who are likely to benefit from adjuvant chemotherapy.<sup>265,266,267</sup>

Several new agents, for example irinotecan (CPT-11)<sup>268,269</sup> and oxaliplatin,<sup>270–272</sup> have demonstrated significantly superior activity in combination with 5-FU/LV in the metastatic setting. Irinotecan/5-FU/LV (IFL)<sup>268</sup> and oxaliplatin/5-FU/LV (FOLFOX) have been entered into randomized clinical trials against 5-FU/LV in resected stage III colon cancer.<sup>273</sup> Both these studies prove that the new agents in association with 5-FU/LV were superior to 5-FU/LV alone. Because of these successes, IFL was approved as first-line chemotherapy in 2000. In 2005,

5-FU/LV with oxaliplatin (FOLFOX) was approved for adjuvant therapy and has evolved in most centers as the treatment of choice. The FOLFOX regime has been compared in a large randomized, controlled trial with IFL and irinotecan/oxaliplatin (IROX) in patients with previously untreated metastatic colorectal cancer.<sup>273</sup> This study showed significantly superior results of the FOLFOX regime for all end points. The median time to progression observed for FOLFOX was 8.7 months, response rate was 45%, and the median survival time was 19.5 months. The FOLFOX regimen had significantly lower rates of severe nausea, vomiting, diarrhea, febrile neutropenia, and dehydration. Sensory neuropathy and neutropenia were common with the regimens containing oxaliplatin.

Capecitabine (Xeloda), an oral agent designed to generate 5-FU preferentially in tumor tissue, is an exciting new development with improved convenience. A randomized phase III study comparing oral capecitabine versus intravenous 5-FU/LV concluded that capecitabine demonstrated a statistically significantly greater response rate compared with 5-FU/LV (26 vs 17%;  $p < .002$ ) and an equivalent time to progression and overall survival.<sup>274</sup> This study demonstrated that capecitabine is a suitable alternative to IV 5-FU and perhaps a replacement in the future. There are currently phase II trials being conducted on capecitabine/oxaliplatin (CAPEOX) and capecitabine/irinotecan (CAPEIRI).<sup>275–279</sup>

Two of the most fascinating targets in the treatment of colorectal cancer are the epithelial growth factor receptor (EGFR) and vascular endothelial growth factor (VEGF) blockers.<sup>280,281</sup> Agents that inhibit the EGFR or bind to VEGF have demonstrated clinical activity as single agents and in combination with chemotherapy in phases II and III clinical trials. The most promising of these agents are the monoclonal antibodies cetuximab, which blocks the binding of epithelial growth factor, and bevacizumab, which binds free VEGF.<sup>280,281</sup> However, the benefit of cetuximab is limited to patients with a tumor bearing wild-type *K-ras* while tumors bearing mutated *K-ras* do not show any response.<sup>282,283</sup> Both agents have proven benefit and seem to work best as first-line therapy for metastatic colorectal cancer. Introduction into the primary adjuvant treatment after curative resection of stages II and III tumors will remain a subject of future trials. We await future developments of these and other newer drugs and their impact in the fight against colorectal cancer.

Generally, radiotherapy does not play a primary role in the adjuvant treatment of colon cancer. However, it may be considered as a locoregional field radiation in selected locally advanced T4N0–N1 tumors.<sup>284–286</sup>

## Outcome and Prognosis

Recent years have produced a trend toward better outcome and survival in patients diagnosed with colorectal cancer. This may be related to safer and more successful surgical treatment in combination with better nonoperative and adjuvant treatments. The perioperative mortality within 30 days of elective colorectal resections is less than 2% even though it still may be

**TABLE 36-15: FIVE-YEAR SURVIVAL FOR SINGLE AND SYNCHRONOUS COLON CANCER PRIMARIES**

Stage	Single (n = 4817)	Synchronous by highest stage (n = 160)	P value <sup>a</sup>
	%	%	
0,I	83	87	NS <sup>b</sup>
II	71	67	NS
III	53	50	NS
IV	9	14	NS

<sup>a</sup> By long-rank test.

<sup>b</sup> Not significant.

Data from Passman MA, Pommier RF, Vetto JT. Synchronous colon primaries have the same prognosis as solitary colon cancers. *Dis Colon Rectum*. 1996;39(3):329–334.<sup>202</sup>

relatively high after an emergency operation, thus resulting in an overall mortality of 3.5–5.5%.<sup>259</sup> SEER data demonstrate an overall decline in colorectal cancer mortality. While the overall 5-year survival of patients with colon cancer was at 41% between 1950 and 1952, it has since increased steadily to 63.8% between 1995 and 2000. Analyzed for each stage as defined by the AJCC sixth edition system (Table 36-15) separately, 5-year survival was 93.2% for stage I, 84.7% for stage IIa, 72.2% for stage IIb, 83.4% for stage IIIa, 64.1% for stage IIIb, 44.3% for stage IIIc, and 8.1% for stage IV.<sup>8</sup> The prognosis of patients with synchronous primary colon tumors is not different from that of patients with solitary tumors if they are compared on the basis of the most advanced stage (see Table 36-15).<sup>202</sup>

## REFERENCES

- Konishi M, Kikuchi-Yanoshita R, Tanaka K, et al. Molecular nature of colon tumors in hereditary nonpolyposis colon cancer, familial polyposis, and sporadic colon cancer. *Gastroenterology*. 1996;111(2):307–317.
- Iino H, Fukayama M, Maeda Y, et al. Molecular genetics for clinical management of colorectal carcinoma. 17p, 18q, and 22q loss of heterozygosity and decreased DCC expression are correlated with the metastatic potential. *Cancer*. 1994;73(5):1324–1331.
- Vogelstein B, Fearon ER, Hamilton SR, et al. Genetic alterations during colorectal-tumor development. *N Engl J Med*. 1988;319(9):525–532.
- American Cancer Society. Cancer Facts & Figures 2009. <http://www.cancer.org/downloads/STT/500809webpdf>. Accessed November 10, 2009.
- Jemal A, Siegel R, Ward E, Hao Y, Xu J, Thun MJ. Cancer statistics, 2009. *CA Cancer J Clin*. 2009;59(4):225–249.
- Calvert PM, Frucht H. The genetics of colorectal cancer. *Ann Int Med*. 2002;137(7):603–612.
- Ferlay J, Bray F, Pisani P, Parkin DM. *GLOBOCAN 2002: Cancer Incidence, Mortality and Prevalence*. Lyon, France: IARC Press; 2004.
- O'Connell JB, Maggard MA, Ko CY. Colon cancer survival rates with the new American Joint Committee on Cancer sixth edition staging. *J Natl Cancer Inst*. 2004;96(19):1420–1425.
- Horner M, Ries L, Krapcho M, et al. *SEER Cancer Statistics Review, 1975–2006*. Bethesda, MD: National Cancer Institute; 2009.
- Chen VW, Fenoglio-Preiser CM, Wu XC, et al. Aggressiveness of colon carcinoma in blacks and whites. National Cancer Institute Black/White Cancer Survival Study Group. *Cancer Epidemiol Biomarkers Prev*. 1997;6(12):1087–1093.

11. Agrawal S, Bhupinderjit A, Bhutani MS, et al. Colorectal cancer in African Americans. *Am J Gastroenterol.* 2005;100(3):515–523; discussion 4.
12. Potter JD. Colorectal cancer: molecules and populations. *J Natl Cancer Inst.* 1999;91(11):916–932.
13. Burt RW. Colon cancer screening. *Gastroenterology.* 2000;119(3):837–853.
14. Winawer S, Fletcher R, Rex D, et al. Colorectal cancer screening and surveillance: clinical guidelines and rationale—update based on new evidence. *Gastroenterology.* 2003;124(2):544–560.
15. Wynder EL, Reddy BS, Weisburger JH. Environmental dietary factors in colorectal cancer. Some unresolved issues. *Cancer.* 1992;70(5suppl):1222–1228.
16. Schatzkin A, Kelloff G. Chemo- and dietary prevention of colorectal cancer. *Eur J Cancer.* 1995;31A(7–8):1198–1204.
17. Aarnio M, Mecklin JP, Aaltonen LA, Nystrom-Lahti M, Jarvinen HJ. Life-time risk of different cancers in hereditary non-polyposis colorectal cancer (HNPCC) syndrome. *Int J Cancer.* 1995;64(6):430–433.
18. Schernhammer ES, Feskanech D, Niu C, Dopfel R, Holmes MD, Hankinson SE. Dietary correlates of urinary 6-sulfatoxymelatonin concentrations in the Nurses' Health Study cohorts. *Am J Clin Nutr.* 2009;90(4):975–985.
19. van Duijnhoven FJB, Bueno-De-Mesquita HB, Ferrari P, et al. Fruit, vegetables, and colorectal cancer risk: the European Prospective Investigation Into Cancer and Nutrition. *Am J Clin Nutr.* 2009;89(5):1441–1452.
20. Alexander DD, Cushing CA, Lowe KA, Scurman B, Roberts MA. Meta-analysis of animal fat or animal protein intake and colorectal cancer. *Am J Clin Nutr.* 2009;89(5):1402–1409.
21. Nomura AMY, Wilkens LR, Murphy SP, et al. Association of vegetable, fruit, and grain intakes with colorectal cancer: the Multiethnic Cohort Study. *Am J Clin Nutr.* 2008;88(3):730–737.
22. Wu JS, Fazio VW. Colon cancer. *Dis Colon Rectum.* 2000;43(11):1473–1486.
23. Ghadirian P, Lacroix A, Maisonneuve P, et al. Nutritional factors and colon carcinoma: a case-control study involving French Canadians in Montreal, Quebec, Canada. *Cancer.* 1997;80(5):858–864.
24. Chao A, Thun MJ, Connell CJ, et al. Meat consumption and risk of colorectal cancer. *JAMA.* 2005;293(2):172–182.
25. Willett WC, Stampfer MJ, Colditz GA, Rosner BA, Speizer FE. Relation of meat, fat, and fiber intake to the risk of colon cancer in a prospective study among women. *N Engl J Med.* 1990;323(24):1664–1672.
26. Alberts DS, Ritenbaugh C, Story JA, et al. Randomized, double-blinded, placebo-controlled study of effect of wheat bran fiber and calcium on fecal bile acids in patients with resected adenomatous colon polyps. *J Natl Cancer Inst.* 1996;88(2):81–92.
27. Kim YI. AGA technical review: impact of dietary fiber on colon cancer occurrence. *Gastroenterology.* 2000;118(6):1235–1257.
28. Konings EJ, Goldbohm RA, Brants HA, Saris WH, van den Brandt PA. Intake of dietary folate vitamers and risk of colorectal carcinoma: results from the Netherlands Cohort Study. *Cancer.* 2002;95(7):1421–1433.
29. Lieberman DA, Prindiville S, Weiss DG, Willett W, Group VACS. Risk factors for advanced colonic neoplasia and hyperplastic polyps in asymptomatic individuals. *JAMA.* 2003;290(22):2959–2967.
30. McKeown-Eyssen GE, Bright-See E, Bruce WR, et al. A randomized trial of a low fat high fibre diet in the recurrence of colorectal polyps. Toronto Polyp Prevention Group [erratum appears in *J Clin Epidemiol.* 1995;48(2):i]. *J Clin Epidemiol.* 1994;47(5):525–536.
31. Anonymous. American Gastroenterological Association medical position statement: impact of dietary fiber on colon cancer occurrence. American College of Gastroenterology. *Gastroenterology.* 2000;118(6):1233–1234.
32. Fuchs CS, Giovannucci EL, Colditz GA, et al. Dietary fiber and the risk of colorectal cancer and adenoma in women. *N Engl J Med.* 1999;340(3):169–176.
33. Modan B. Role of diet in cancer etiology. *Cancer.* 1977;40(4 suppl):1887–1891.
34. Pot GK, Majsak-Newman G, Geelen A, et al. Fish consumption and markers of colorectal cancer risk: a multicenter randomized controlled trial. *Am J Clin Nutr.* 2009;90(2):354–361.
35. Levi F, Pasche C, La Vecchia C, Lucchini F, Franceschi S. Food groups and colorectal cancer risk. *Br J Cancer.* 1999;79(7–8):1283–1287.
36. Modan B, Barell V, Lubin F, Modan M, Greenberg RA, Graham S. Low-fiber intake as an etiologic factor in cancer of the colon. *J Natl Cancer Inst.* 1975;55(1):15–18.
37. Michels KB, Edward G, Joshipura KJ, et al. Prospective study of fruit and vegetable consumption and incidence of colon and rectal cancers [see comment][erratum appears in *J Natl Cancer Inst.* 2001 Jun 6;93(11):879]. *J Natl Cancer Inst.* 2000;92(21):1740–1752.
38. Trock B, Lanza E, Greenwald P. Dietary fiber, vegetables, and colon cancer: critical review and meta-analyses of the epidemiologic evidence. *J Natl Cancer Inst.* 1990;82(8):650–661.
39. Garland C, Shekelle RB, Barrett-Connor E, Criqui MH, Rossof AH, Paul O. Dietary vitamin D and calcium and risk of colorectal cancer: a 19-year prospective study in men. *Lancet.* 1985;1(8424):307–309.
40. Wu K, Willett WC, Fuchs CS, Colditz GA, Giovannucci EL. Calcium intake and risk of colon cancer in women and men. *J Natl Cancer Inst.* 2002;94(6):437–446.
41. Baron JA, Beach M, Mandel JS, et al. Calcium supplements for the prevention of colorectal adenomas. Calcium Polyp Prevention Study Group. *N Engl J Med.* 1999;340(2):101–107.
42. Grau MV, Baron JA, Sandler RS, et al. Vitamin D, calcium supplementation, and colorectal adenomas: results of a randomized trial. *J Natl Cancer Inst.* 2003;95(23):1765–1771.
43. Park Y, Leitzmann MF, Subar AF, Hollenbeck A, Schatzkin A. Dairy food, calcium, and risk of cancer in the NIH-AARP Diet and Health Study. *Arch Int Med.* 2009;169(4):391–401.
44. Connelly-Frost A, Poole C, Satia JA, Kupper LL, Millikan RC, Sandler RS. Selenium, folate, and colon cancer. *Nutr Cancer.* 2009;61(2):165–178.
45. Wactawski-Wende J, Kotchen JM, Anderson GL, et al. Calcium plus vitamin D supplementation and the risk of colorectal cancer [see comment] [erratum appears in *N Engl J Med.* 2006 Mar 9;354(10):1102]. *N Engl J Med.* 2006;354(7):684–696.
46. Greenberg ER, Baron JA, Tosteson TD, et al. A clinical trial of antioxidant vitamins to prevent colorectal adenoma. Polyp Prevention Study Group. *N Engl J Med.* 1994;331(3):141–147.
47. Neuhouser ML, Wassertheil-Smoller S, Thomson C, et al. Multivitamin use and risk of cancer and cardiovascular disease in the Women's Health Initiative cohorts. *Arch Int Med.* 2009;169(3):294–304.
48. Lee DH, Anderson KE, Harnack LJ, Folsom AR, Jacobs DR, Jr. Heme iron, zinc, alcohol consumption, and colon cancer: Iowa Women's Health Study. *J Natl Cancer Inst.* 2004;96(5):403–407.
49. Ferrandez A, Prescott S, Burt RW. COX-2 and colorectal cancer. *Curr Pharmaceut Des.* 2003;9(27):2229–2251.
50. Sheehan KM, Sheahan K, O'Donoghue DP, et al. The relationship between cyclooxygenase-2 expression and colorectal cancer [erratum appears in *JAMA.* 2000 Mar 15;283(11):1427]. *JAMA.* 1999;282(13):1254–1257.
51. Baron JA, Cole BF, Sandler RS, et al. A randomized trial of aspirin to prevent colorectal adenomas. *N Engl J Med.* 2003;348(10):891–899.
52. Steinbach G, Lynch PM, Phillips RK, et al. The effect of celecoxib, a cyclooxygenase-2 inhibitor, in familial adenomatous polyposis. *N Engl J Med.* 2000;342(26):1946–1952.
53. Cruz-Correa M, Hyland LM, Romans KE, Booker SV, Giardiello FM. Long-term treatment with sulindac in familial adenomatous polyposis: a prospective cohort study. *Gastroenterology.* 2002;122(3):641–645.
54. Giardiello FM, Yang VW, Hyland LM, et al. Primary chemoprevention of familial adenomatous polyposis with sulindac. *N Engl J Med.* 2002;346(14):1054–1059.
55. Burn J, Bishop DT, Mecklin J-P, et al. Effect of aspirin or resistant starch on colorectal neoplasia in the Lynch syndrome. *N Engl J Med.* 2008;359(24):2567–2578.
56. Chan AT, Ogino S, Fuchs CS. Aspirin and the risk of colorectal cancer in relation to the expression of COX-2. *N Engl J Med.* 2007;356(21):2131–2142.
57. Solomon SD, McMurray JJ, Pfeffer MA, et al. Cardiovascular risk associated with celecoxib in a clinical trial for colorectal adenoma prevention. *N Engl J Med.* 2005;352(11):1071–1080.
58. Bresalier RS, Sandler RS, Quan H, et al. Cardiovascular events associated with rofecoxib in a colorectal adenoma chemoprevention trial. *N Engl J Med.* 2005;352(11):1092–1102.
59. Rainey JB, Davies PW, Bristol JB, Williamson RC. Adaptation and carcinogenesis in defunctioned rat colon: divergent effects of faeces and bile acids. *Br J Cancer.* 1983;48(4):477–484.
60. Imray CH, Radley S, Davis A, et al. Faecal unconjugated bile acids in patients with colorectal cancer or polyps. *Gut.* 1992;33(9):1239–1245.
61. Lagergren J, Ye W, Ekblom A. Intestinal cancer after cholecystectomy: is bile involved in carcinogenesis? *Gastroenterology.* 2001;121(3):542–547.



62. Linos D, Beard CM, O'Fallon WM, Dockerty MB, Beart RW, Jr, Kurland LT. Cholecystectomy and carcinoma of the colon. *Lancet*. 1981;2(8243):379-381.
63. Reddy BS, Engle A, Simi B, Goldman M. Effect of dietary fiber on colonic bacterial enzymes and bile acids in relation to colon cancer. *Gastroenterology*. 1992;102(5):1475-1482.
64. Giovannucci E, Rimm EB, Ascherio A, Stampfer MJ, Colditz GA, Willett WC. Alcohol, low-methionine—low-folate diets, and risk of colon cancer in men. *J Natl Cancer Inst*. 1995;87(4):265-273.
65. Martinez ME, McPherson RS, Annegers JF, Levin B. Cigarette smoking and alcohol consumption as risk factors for colorectal adenomatous polyps. *J Natl Cancer Inst*. 1995;87(4):274-279.
66. Wallace K, Grau MV, Ahnen D, et al. The association of lifestyle and dietary factors with the risk for serrated polyps of the colorectum. *Cancer Epidemiol Biomarkers Prev*. 2009;18(8):2310-2317.
67. Slattery ML, Curtin K, Anderson K, et al. Associations between cigarette smoking, lifestyle factors, and microsatellite instability in colon tumors. *J Natl Cancer Inst*. 2000;92(22):1831-1836.
68. Baron JA, Sandler RS, Haile RW, Mandel JS, Mott LA, Greenberg ER. Folate intake, alcohol consumption, cigarette smoking, and risk of colorectal adenomas. *J Natl Cancer Inst*. 1998;90(1):57-62.
69. Kikendall JW, Bowen PE, Burgess MB, Magnetti C, Woodward J, Langenberg P. Cigarettes and alcohol as independent risk factors for colonic adenomas. *Gastroenterology*. 1989;97(3):660-664.
70. Giovannucci E, Pollak MN, Platz EA, et al. A prospective study of plasma insulin-like growth factor-1 and binding protein-3 and risk of colorectal neoplasia in women. *Cancer Epidemiol Biomarkers Prev*. 2000;9(4):345-349.
71. Half E, Arber N. Colon cancer: preventive agents and the present status of chemoprevention. *Expert Opin Pharmacother*. 2009;10(2):211-219.
72. Wang C, Xu C, Sun M, Luo D, Liao D-F, Cao D. Acetyl-CoA carboxylase-alpha inhibitor TOFA induces human cancer cell apoptosis. *Biochem Biophys Res Commun*. 2009;385(3):302-306.
73. Wei EK, Colditz GA, Giovannucci EL, Fuchs CS, Rosner BA. Cumulative risk of colon cancer up to age 70 years by risk factor status using data from the Nurses' Health Study. *Am J Epidemiol*. 2009;170(7):863-872.
74. Kwak EL, Chung DC. Hereditary colorectal cancer syndromes: an overview. *Clin Colorectal Cancer*. 2007;6(5):340-344.
75. Rodriguez-Bigas MA, Vasen HF, Pekka-Mecklin J, et al. Rectal cancer risk in hereditary nonpolyposis colorectal cancer after abdominal colectomy. International Collaborative Group on HNPCC. *Ann Surg*. 1997;225(2):202-207.
76. Cannon-Albright LA, Skolnick MH, Bishop DT, Lee RG, Burt RW. Common inheritance of susceptibility to colonic adenomatous polyps and associated colorectal cancers. *N Engl J Med*. 1988;319(9):533-537.
77. Winawer SJ, Zauber AG, Gerdes H, et al. Risk of colorectal cancer in the families of patients with adenomatous polyps. National Polyp Study Workgroup. *N Engl J Med*. 1996;334(2):82-87.
78. Houlston RS, Murday V, Harocopos C, Williams CB, Slack J. Screening and genetic counselling for relatives of patients with colorectal cancer in a family cancer clinic [erratum appears in *BMJ*. 1990 Sep 1;301(6749):446]. *BMJ*. 1990;301(6748):366-368.
79. Ekblom A, Helmick C, Zack M, Adami HO. Ulcerative colitis and colorectal cancer. A population-based study. *N Engl J Med*. 1990;323(18):1228-1233.
80. Kaiser AM, Beart RW, Jr. Surgical management of ulcerative colitis. *Swiss Med Wkly*. 2001;131(23-24):323-337.
81. Rutter M, Saunders B, Wilkinson K, et al. Severity of inflammation is a risk factor for colorectal neoplasia in ulcerative colitis. *Gastroenterology*. 2004;126(2):451-459.
82. Gillen CD, Walmsley RS, Prior P, Andrews HA, Allan RN. Ulcerative colitis and Crohn's disease: a comparison of the colorectal cancer risk in extensive colitis. *Gut*. 1994;35(11):1590-1592.
83. Ekblom A, Helmick C, Zack M, Adami HO. Increased risk of large-bowel cancer in Crohn's disease with colonic involvement. *Lancet*. 1990;336(8711):357-359.
84. Weedon DD, Shorter RG, Ilstrup DM, Huizenga KA, Taylor WF. Crohn's disease and cancer. *N Engl J Med*. 1973;289(21):1099-1103.
85. Azimuddin K, Khubchandani IT, Stasik JJ, Rosen L, Riether RD. Neoplasia after ureterosigmoidostomy. *Dis Colon Rectum*. 1999;42(12):1632-1638.
86. Otchy DP, Nelson H. Radiation injuries of the colon and rectum. *Surg Clin North Am*. 1993;73(5):1017-1035.
87. Husmann DA, Spence HM. Current status of tumor of the bowel following ureterosigmoidostomy: a review. *J Urol*. 1990;144(3):607-610.
88. Kalble T, Tricker AR, Mohring K, Berger MR, Geiss H, Staehler G. The role of nitrate, nitrite and N-nitrosamines in carcinogenesis of colon tumours following ureterosigmoidostomy. *Urol Res*. 1990;18(2):123-129.
89. Rim SH, Seeff L, Ahmed F, King JB, Coughlin SS. Colorectal cancer incidence in the United States, 1999-2004: an updated analysis of data from the National Program of Cancer Registries and the Surveillance, Epidemiology, and End Results Program. *Cancer*. 2009;115(9):1967-1976.
90. Mitka M. Colon cancer screening guidelines stress initial test's importance. *JAMA*. 2003;289(9):1089-1090.
91. Smith RA, Cokkinides V, Brawley OW. Cancer screening in the United States, 2009: a review of current American Cancer Society guidelines and issues in cancer screening. *CA Cancer J Clin*. 2009;59(1):27-41.
92. Regge D, Laudi C, Galatola G, et al. Diagnostic accuracy of computed tomographic colonography for the detection of advanced neoplasia in individuals at increased risk of colorectal cancer. *JAMA*. 2009;301(23):2453-2461.
93. Toma J, Paszat LF, Gunraj N, Rabeneck L. Rates of new or missed colorectal cancer after barium enema and their risk factors: a population-based study. *Am J Gastroenterol*. 2008;103(12):3142-3148.
94. Rockey DC, Paulson E, Niedzwiecki D, et al. Analysis of air contrast barium enema, computed tomographic colonography, and colonoscopy: prospective comparison. *Lancet*. 2005;365(9456):305-311.
95. Winawer SJ, Stewart ET, Zauber AG, et al. A comparison of colonoscopy and double-contrast barium enema for surveillance after polypectomy. National Polyp Study Work Group. *N Engl J Med*. 2000;342(24):1766-1772.
96. Winawer SJ, Zauber AG, Ho MN, et al. Prevention of colorectal cancer by colonoscopic polypectomy. The National Polyp Study Workgroup. *N Engl J Med*. 1993;329(27):1977-1981.
97. Gatenby RA, Vincent TL. An evolutionary model of carcinogenesis. *Cancer Res*. 2003;63(19):6212-6220.
98. Senba S, Konishi F, Okamoto T, et al. Clinicopathologic and genetic features of nonfamilial colorectal carcinomas with DNA replication errors. *Cancer*. 1998;82(2):279-285.
99. Boland CR, Thibodeau SN, Hamilton SR, et al. A National Cancer Institute Workshop on Microsatellite Instability for cancer detection and familial predisposition: development of international criteria for the determination of microsatellite instability in colorectal cancer. *Cancer Res*. 1998;58(22):5248-5257.
100. Kikuchi-Yanoshita R, Konishi M, Fukunari H, Tanaka K, Miyaki M. Loss of expression of the DCC gene during progression of colorectal carcinomas in familial adenomatous polyposis and non-familial adenomatous polyposis patients. *Cancer Res*. 1992;52(13):3801-3803.
101. Takayama T, Ohi M, Hayashi T, et al. Analysis of K-ras, APC, and beta-catenin in aberrant crypt foci in sporadic adenoma, cancer, and familial adenomatous polyposis. *Gastroenterology*. 2001;121(3):599-611.
102. Powell SM, Zilz N, Beazer-Barclay Y, et al. APC mutations occur early during colorectal tumorigenesis. *Nature*. 1992;359(6392):235-237.
103. Fearon ER, Vogelstein B. A genetic model for colorectal tumorigenesis. *Cell*. 1990;61(5):759-767.
104. Kikuchi-Yanoshita R, Konishi M, Ito S, et al. Genetic changes of both p53 alleles associated with the conversion from colorectal adenoma to early carcinoma in familial adenomatous polyposis and non-familial adenomatous polyposis patients. *Cancer Res*. 1992;52(14):3965-3971.
105. Laken SJ, Petersen GM, Gruber SB, et al. Familial colorectal cancer in Ashkenazim due to a hypermutable tract in APC. *Nature Gen*. 1997;17(1):79-83.
106. Powell SM, Petersen GM, Krush AJ, et al. Molecular diagnosis of familial adenomatous polyposis. *N Engl J Med*. 1993;329(27):1982-1987.
107. Offerhaus GJ, Giardiello FM, Krush AJ, et al. The risk of upper gastrointestinal cancer in familial adenomatous polyposis. *Gastroenterology*. 1992;102(6):1980-1982.
108. Bjork J, Akerbrant H, Iselius L, et al. Periampullary adenomas and adenocarcinomas in familial adenomatous polyposis: cumulative risks and APC gene mutations. *Gastroenterology*. 2001;121(5):1127-1135.
109. Jagelman DG, DeCosse JJ, Bussey HJ. Upper gastrointestinal cancer in familial adenomatous polyposis. *Lancet*. 1988;1(8595):1149-1151.

110. Wallace MH, Phillips RK. Upper gastrointestinal disease in patients with familial adenomatous polyposis. *Br J Surg*. 1998;85(6):742–750.
111. Gurbuz AK, Giardiello FM, Petersen GM, et al. Desmoid tumours in familial adenomatous polyposis. *Gut*. 1994;35(3):377–381.
112. Wang L, Baudhuin LM, Boardman LA, et al. MYH mutations in patients with attenuated and classic polyposis and with young-onset colorectal cancer without polyps. *Gastroenterology*. 2004;127(1):9–16.
113. Lynch HT, Smyrk T, McGinn T, et al. Attenuated familial adenomatous polyposis (AFAP). A phenotypically and genotypically distinctive variant of FAP. *Cancer*. 1995;76(12):2427–2433.
114. Heinimann K, Mullhaupt B, Weber W, et al. Phenotypic differences in familial adenomatous polyposis based on APC gene mutation status. *Gut*. 1998;43(5):675–679.
115. Lynch HT, de la Chapelle A. Hereditary colorectal cancer. *N Engl J Med*. 2003;348(10):919–932.
116. Aarnio M, Mustonen H, Mecklin JP, Jarvinen HJ. Prognosis of colorectal cancer varies in different high-risk conditions. *Ann Med*. 1998;30(1):75–80.
117. Vasen HF, Wijnen JT, Menko FH, et al. Cancer risk in families with hereditary nonpolyposis colorectal cancer diagnosed by mutation analysis [erratum appears in *Gastroenterology* 1996 Nov;111(5):1402]. *Gastroenterology*. 1996;110(4):1020–1027.
118. Thibodeau SN, Bren G, Schaid D. Microsatellite instability in cancer of the proximal colon. *Science*. 1993;260(5109):816–819.
119. Chung DC, Rustgi AK. DNA mismatch repair and cancer. *Gastroenterology*. 1995;109(5):1685–1699.
120. De Jong AE, Morreau H, Van Puijenbroek M, et al. The role of mismatch repair gene defects in the development of adenomas in patients with HNPCC. *Gastroenterology*. 2004;126(1):42–48.
121. Kinzler KW, Vogelstein B. Cancer-susceptibility genes. Gatekeepers and caretakers [see comment] *Nature*. 1997;386(6627):761.
122. Lynch HT, de la Chapelle A. Genetic susceptibility to non-polyposis colorectal cancer. *J Med Genet*. 1999;36(11):801–818.
123. Lin KM, Shashidharan M, Thorson AG, et al. Cumulative incidence of colorectal and extracolonic cancers in MLH1 and MSH2 mutation carriers of hereditary nonpolyposis colorectal cancer. *J Gastrointest Surg*. 1998;2(1):67–71.
124. Wijnen J, de Leeuw W, Vasen H, et al. Familial endometrial cancer in female carriers of MSH6 germline mutations. *Nature Gen*. 1999;23(2):142–144.
125. Vasen HF. Clinical diagnosis and management of hereditary colorectal cancer syndromes. *J Clin Oncol*. 2000;18(21 suppl):81S–92S.
126. Umar A, Boland CR, Terdiman JP, et al. Revised Bethesda Guidelines for hereditary nonpolyposis colorectal cancer (Lynch syndrome) and microsatellite instability. *J Natl Cancer Inst*. 2004;96(4):261–268.
127. Hemminki A, Tomlinson I, Markie D, et al. Localization of a susceptibility locus for Peutz-Jeghers syndrome to 19p using comparative genomic hybridization and targeted linkage analysis. *Nature Gen*. 1997;15(1):87–90.
128. Haggitt RC, Reid BJ. Hereditary gastrointestinal polyposis syndromes. *Am J Surg Pathol*. 1986;10(12):871–887.
129. Giardiello FM, Hamilton SR, Kern SE, et al. Colorectal neoplasia in juvenile polyposis or juvenile polyps. *Arch Dis Child*. 1991;66(8):971–975.
130. Howe JR, Roth S, Ringold JC, et al. Mutations in the SMAD4/DPC4 gene in juvenile polyposis. *Science*. 1998;280(5366):1086–1088.
131. Nelen MR, Padberg GW, Peeters EA, et al. Localization of the gene for Cowden disease to chromosome 10q22-23. *Nature Gen*. 1996;13(1):114–116.
132. Chi SG, Kim HJ, Park BJ, et al. Mutational abrogation of the PTEN/MMAC1 gene in gastrointestinal polyps in patients with Cowden disease. *Gastroenterology*. 1998;115(5):1084–1089.
133. Eng C. PTEN: one gene, many syndromes. *Hum Mutat*. 2003;22(3):183–198.
134. Zigman AF, Lavine JE, Jones MC, Boland CR, Carethers JM. Localization of the Bannayan-Riley-Ruvalcaba syndrome gene to chromosome 10q23. *Gastroenterology*. 1997;113(5):1433–1437.
135. Arch EM, Goodman BK, Van Wesep RA, et al. Deletion of PTEN in a patient with Bannayan-Riley-Ruvalcaba syndrome suggests allelism with Cowden disease. *Am J Med Genet*. 1997;71(4):489–493.
136. Johnson GK, Soergel KH, Hensley GT, Dodds WJ, Hogan WJ. Cronkite-Canada syndrome: gastrointestinal pathophysiology and morphology. *Gastroenterology*. 1972;63(1):140–152.
137. Nusko G, Mansmann U, Kirchner T, Hahn EG. Risk related surveillance following colorectal polypectomy. *Gut*. 2002;51(3):424–428.
138. Tolliver KA, Rex DK. Colonoscopic polypectomy. *Gastroenterol Clin North Am*. 2008;37(1):229–51, ix.
139. Wayne JD. Advanced polypectomy. *Gastrointest Endosc Clin N Am*. 2005;15(4):733–756.
140. Rubio CA, Jaramillo E, Lindblom A, Fogt F. Classification of colorectal polyps: guidelines for the endoscopist. *Endoscopy*. 2002;34(3):226–236.
141. Winawer SJ, Fletcher RH, Miller L, et al. Colorectal cancer screening: clinical guidelines and rationale. *Gastroenterology*. 1997;112(2):594–642.
142. Mandel JS, Bond JH, Church TR, et al. Reducing mortality from colorectal cancer by screening for fecal occult blood. Minnesota Colon Cancer Control Study. *N Engl J Med*. 1993;328(19):1365–1371.
143. Pilbrow SJ, Hertzog PJ, Linnane AW. The adenoma-carcinoma sequence in the colorectum—early appearance of a hierarchy of small intestinal mucin antigen (SIMA) epitopes and correlation with malignant potential. *Br J Cancer*. 1992;66(4):748–757.
144. Loeve F, Boer R, Zauber AG, et al. National Polyp Study data: evidence for regression of adenomas. *Int J Cancer*. 2004;111(4):633–639.
145. O'Brien MJ, Winawer SJ, Zauber AG, et al. The National Polyp Study. Patient and polyp characteristics associated with high-grade dysplasia in colorectal adenomas. *Gastroenterology*. 1990;98(2):371–379.
146. Muto T, Bussey HJ, Morson BC. The evolution of cancer of the colon and rectum. *Cancer*. 1975;36(6):2251–2270.
147. Haggitt RC, Glotzbach RE, Soffer EE, Wruble LD. Prognostic factors in colorectal carcinomas arising in adenomas: implications for lesions removed by endoscopic polypectomy. *Gastroenterology*. 1985;89(2):328–336.
148. Kudo S, Kashida H, Tamura T. Early colorectal cancer: flat or depressed type. *J Gastroenterol Hepatol*. 2000;15(suppl):D66–D70.
149. Muto T, Kamiya J, Sawada T, et al. Small “flat adenoma” of the large bowel with special reference to its clinicopathologic features. *Dis Colon Rectum*. 1985;28(11):847–851.
150. Adachi M, Muto T, Okinaga K, Morioka Y. Clinicopathologic features of the flat adenoma. *Dis Colon Rectum*. 1991;34(11):981–986.
151. Jaramillo E, Watanabe M, Slezak P, Rubio C. Flat neoplastic lesions of the colon and rectum detected by high-resolution video endoscopy and chromoscopy. *Gastrointest Endosc*. 1995;42(2):114–122.
152. Soetikno RM, Kaltenbach T, Rouse RV, et al. Prevalence of nonpolypoid (flat and depressed) colorectal neoplasms in asymptomatic and symptomatic adults. *JAMA*. 2008;299(9):1027–1035.
153. Rembacken BJ, Fujii T, Cairns A, et al. Flat and depressed colonic neoplasms: a prospective study of 1000 colonoscopies in the UK. *Lancet*. 2000;355(9211):1211–1214.
154. Schreibman IR, Baker M, Amos C, McGarrity TJ. The hamartomatous polyposis syndromes: a clinical and molecular review. *Am J Gastroenterol*. 2005;100(2):476–490.
155. Chan OT, Haghighi P. Hamartomatous polyps of the colon: ganglioneuromatous, stromal, and lipomatous. *Arch Pathol Lab Med*. 2006;130(10):1561–1566.
156. Williams GT, Arthur JF, Bussey HJ, Morson BC. Metaplastic polyps and polyposis of the colorectum. *Histopathology*. 1980;4(2):155–170.
157. Clark JC, Collan Y, Eide TJ, et al. Prevalence of polyps in an autopsy series from areas with varying incidence of large-bowel cancer. *Int J Cancer*. 1985;36(2):179–186.
158. Longacre TA, Fenoglio-Preiser CM. Mixed hyperplastic adenomatous polyps/serrated adenomas. A distinct form of colorectal neoplasia. *Am J Surg Pathol*. 1990;14(6):524–537.
159. Jass JR, Iino H, Ruszkiewicz A, et al. Neoplastic progression occurs through mutant pathways in hyperplastic polyposis of the colorectum. *Gut*. 2000;47(1):43–49.
160. O'Brien MJ, Yang S, Mack C, et al. Comparison of microsatellite instability, CpG island methylation phenotype, BRAF and KRAS status in serrated polyps and traditional adenomas indicates separate pathways to distinct colorectal carcinoma end points. *Am J Surg Pathol*. 2006;30(12):1491–1501.
161. Jass J, Burt R. Hyperplastic polyposis. In: Hamilton S, Aaltonen L, eds. *WHO International Classification of Tumours Pathology and Genetics of Tumours of the Digestive System*. 3rd ed. Berlin, Germany: Springer-Verlag; 2000:135–136.
162. Hyman NH, Anderson P, Blasyk H. Hyperplastic polyposis and the risk of colorectal cancer. *Dis Colon Rectum*. 2004;47(12):2101–2104.

163. Doran D, Burke JP, Hanly AM, Winter DC. Prophylactic colectomy for hyperplastic polyposis. *Ir J Med Sci.* 2009;26:26.
164. Hardcastle JD, Thomas WM, Chamberlain J, et al. Randomised, controlled trial of faecal occult blood screening for colorectal cancer. Results for first 107,349 subjects. *Lancet.* 1989;1(8648):1160–1164.
165. Kewenter J, Brevinge H, Engaras B, Haglund E, Ahren C. Results of screening, rescreening, and follow-up in a prospective randomized study for detection of colorectal cancer by fecal occult blood testing. Results for 68,308 subjects. *Scand J Gastroenterol.* 1994;29(5):468–473.
166. Kronborg O, Fenger C, Olsen J, Jorgensen OD, Sondergaard O. Randomised study of screening for colorectal cancer with faecal-occult-blood test. *Lancet.* 1996;348(9040):1467–1471.
167. Thiis-Evensen E, Hoff GS, Saur J, Langmark F, Majak BM, Vatn MH. Population-based surveillance by colonoscopy: effect on the incidence of colorectal cancer. Telemark Polyp Study I. *Scand J Gastroenterol.* 1999;34(4):414–420.
168. Winawer SJ. The achievements, impact, and future of the National Polyp Study. *Gastrointest Endosc.* 2006;64(6):975–978.
169. Alder AC, Hamilton EC, Anthony T, Sarosi GA, Jr. Cancer risk in endoscopically unresectable colon polyps. *Am J Surg.* 2006;192(5):644–648.
170. McDonald JM, Moonka R, Bell RH, Jr. Pathologic risk factors of occult malignancy in endoscopically unresectable colonic adenomas. *Am J Surg.* 1999;177(5):384–387.
171. Ross HM, Li C, Rosenthal J, Kessler J, Fogt F. Laparoscopic colon resection for polyps: a good novice case? *Dis Colon Rectum.* 2006;49(6):879–882.
172. Nivatvongs S. Surgical management of malignant colorectal polyps. *Surg Clin North Am.* 2002;82(5):959–966.
173. Nascimben R, Burgart LJ, Nivatvongs S, Larson DR. Risk of lymph node metastasis in T1 carcinoma of the colon and rectum. *Dis Colon Rectum.* 2002;45(2):200–206.
174. Parkin DM, Bray F, Ferlay J, Pisani P. Global cancer statistics, 2002. *CA Cancer J Clin.* 2005;55(2):74–108.
175. Sasaki O, Atkin WS, Jass JR. Mucinous carcinoma of the rectum. *Histopathology.* 1987;11(3):259–272.
176. Kanemitsu Y, Kato T, Hirai T, et al. Survival after curative resection for mucinous adenocarcinoma of the colorectum. *Dis Colon Rectum.* 2003;46(2):160–167.
177. Obrand DI, Gordon PH. Continued change in the distribution of colorectal carcinoma. *Br J Surg.* 1998;85(2):246–248.
178. Cheng X, Chen VW, Steele B, et al. Subsite-specific incidence rate and stage of disease in colorectal cancer by race, gender, and age group in the United States, 1992–1997. *Cancer.* 2001;92(10):2547–2554.
179. Jayne DG, Fook S, Loi C, Seow-Choen F. Peritoneal carcinomatosis from colorectal cancer. *Br J Surg.* 2002;89(12):1545–1550.
180. Compton CC, Greene FL. The staging of colorectal cancer: 2004 and beyond. *CA Cancer J Clin.* 2004;54(6):295–308.
181. Edge SB, Byrd DR, Compton CC, Fritz AG, Greene FL, Trotti A. *AJCC Cancer Staging Manual.* New York, NY: Springer; 2010.
182. Kaiser AM. Giant colonic lipoma. *Surgery.* 2009;doi:10.1016/j.surg.2008.12.016.
183. Maggard MA, O'Connell JB, Ko CY. Updated population-based review of carcinoid tumors. *Ann Surg.* 2004;240(1):117–122.
184. Kulke MH, Mayer RJ. Carcinoid tumors. *N Engl J Med.* 1999; 340(11): 858–868.
185. Pellikka PA, Tajik AJ, Khandheria BK, et al. Carcinoid heart disease. Clinical and echocardiographic spectrum in 74 patients. *Circulation.* 1993;87(4):1188–1196.
186. Fox DJ, Khattar RS. Carcinoid heart disease: presentation, diagnosis, and management. *Heart.* 2004;90(10):1224–1228.
187. Habal N, Sims C, Bilchik AJ. Gastrointestinal carcinoid tumors and second primary malignancies. *J Surg Oncol.* 2000;75(4):310–316.
188. Koh JS, Trent J, Chen L, et al. Gastrointestinal stromal tumors: overview of pathologic features, molecular biology, and therapy with imatinib mesylate. *Histol Histopathol.* 2004;19(2):565–574.
189. Ueyama T, Guo KJ, Hashimoto H, Daimaru Y, Enjoji M. A clinicopathologic and immunohistochemical study of gastrointestinal stromal tumors. *Cancer.* 1992;69(4):947–955.
190. Medeiros F, Corless CL, Duensing A, et al. KIT-negative gastrointestinal stromal tumors: proof of concept and therapeutic implications. *Am J Surg Pathol.* 2004;28(7):889–894.
191. Corless CL, Fletcher JA, Heinrich MC. Biology of gastrointestinal stromal tumors. *J Clin Oncol.* 2004;22(18):3813–3825.
192. Heinrich MC, Corless CL, Duensing A, et al. PDGFRA activating mutations in gastrointestinal stromal tumors. *Science.* 2003;299(5607): 708–710.
193. Castellano G, Moreno D, Galvao O, et al. Malignant lymphoma of jejunum with common variable hypogammaglobulinemia and diffuse nodular hyperplasia of the small intestine. A case study and literature review. *J Clin Gastroenterol.* 1992;15(2):128–135.
194. Chim CS, Shek TW, Chung LP, Liang R. Unusual abdominal tumors: case 3. Multiple lymphomatous polyposis in lymphoma of colon. *J Clin Oncol.* 2003;21(5):953–955.
195. Kohno S, Ohshima K, Yoneda S, Kodama T, Shirakusa T, Kikuchi M. Clinicopathological analysis of 143 primary malignant lymphomas in the small and large intestines based on the new WHO classification. *Histopathology.* 2003;43(2):135–143.
196. Raderer M, Pfeffel F, Pohl G, Mannhalter C, Valencak J, Chott A. Regression of colonic low grade B cell lymphoma of the mucosa-associated lymphoid tissue type after eradication of *Helicobacter pylori*. *Gut.* 2000;46(1):133–135.
197. Ruskone-Fourmestreaux A, Delmer A, Lavergne A, et al. Multiple lymphomatous polyposis of the gastrointestinal tract: prospective clinicopathologic study of 31 cases. Groupe D'etude des Lymphomes Digestifs. *Gastroenterology.* 1997;112(1):7–16.
198. Kaiser AM. *McGraw-Hill Manual Colorectal Surgery.* New York, NY: McGraw-Hill Companies; 2008.
199. Katz SC, DeMatteo RP. Gastrointestinal stromal tumors and leiomyosarcomas. *J Surg Oncol.* 2008;97(4):350–359.
200. Kaiser AM, Ortega AE. Anorectal anatomy. *Surg Clin North Am.* 2002;82(6):1125–1138.
201. Nelson H, Petrelli N, Carlin A, et al. Guidelines 2000 for colon and rectal cancer surgery. *J Natl Cancer Inst.* 2001;93(8):583–596.
202. Passman MA, Pommier RF, Vetto JT. Synchronous colon primaries have the same prognosis as solitary colon cancers. *Dis Colon Rectum.* 1996;39(3):329–334.
203. Fenlon HM, Nunes DP, Schroy PC, 3rd, Barish MA, Clarke PD, Ferrucci JT. A comparison of virtual and conventional colonoscopy for the detection of colorectal polyps. *N Engl J Med.* 1999;341(20):1496–1503.
204. Pickhardt PJ, Choi JR, Hwang I, et al. Computed tomographic virtual colonoscopy to screen for colorectal neoplasia in asymptomatic adults. *N Engl J Med.* 2003;349(23):2191–2200.
205. Spinzi G, Belloni G, Martegani A, Sangiovanni A, Del Favero C, Minoli G. Computed tomographic colonography and conventional colonoscopy for colon diseases: a prospective, blinded study. *Am J Gastroenterol.* 2001;96(2):394–400.
206. Kerner BA, Oliver GC, Eisenstat TE, Rubin RJ, Salvati EP. Is preoperative computerized tomography useful in assessing patients with colorectal carcinoma? *Dis Colon Rectum.* 1993;36(11):1050–1053.
207. Mauchley DC, Lynge DC, Langdale LA, Stelzner MG, Mock CN, Billingsley KG. Clinical utility and cost-effectiveness of routine preoperative computed tomography scanning in patients with colon cancer. *Am J Surg.* 2005;189(5):512–517; discussion 7.
208. Ward J, Naik KS, Guthrie JA, Wilson D, Robinson PJ. Hepatic lesion detection: comparison of MR imaging after the administration of superparamagnetic iron oxide with dual-phase CT by using alternative-free response receiver operating characteristic analysis. *Radiology.* 1999;210(2):459–466.
209. Johnson K, Bakhsh A, Young D, Martin TE, Jr, Arnold M. Correlating computed tomography and positron emission tomography scan with operative findings in metastatic colorectal cancer. *Dis Colon Rectum.* 2001;44(3):354–357.
210. Moertel CG, Fleming TR, Macdonald JS, Haller DG, Laurie JA, Tangen C. An evaluation of the carcinoembryonic antigen (CEA) test for monitoring patients with resected colon cancer. *JAMA.* 1993;270(8):943–947.
211. Burrows L, Tartert P. Effect of blood transfusions on colonic malignancy recurrent rate. *Lancet.* 1982;2(8299):18.
212. Vamvakas EC. Perioperative blood transfusion and cancer recurrence: meta-analysis for explanation. *Transfusion.* 1995;35(9):760–768.
213. Busch OR, Hop WC, Marquet RL, Jeekel J. Blood transfusions and local tumor recurrence in colorectal cancer. Evidence of a noncausal relationship. *Ann Surg.* 1994;220(6):791–797.



214. Santos JC, Jr., Batista J, Sirimarco MT, Guimaraes AS, Levy CE. Prospective randomized trial of mechanical bowel preparation in patients undergoing elective colorectal surgery. *Br J Surg.* 1994;81(11):1673–1676.
215. Burke P, Mealy K, Gillen P, Joyce W, Traynor O, Hyland J. Requirement for bowel preparation in colorectal surgery. *Br J Surg.* 1994;81(6):907–910.
216. Miettinen RP, Laitinen ST, Makela JT, Paakkonen ME. Bowel preparation with oral polyethylene glycol electrolyte solution vs. no preparation in elective open colorectal surgery: prospective, randomized study. *Dis Colon Rectum.* 2000;43(5):669–675; discussion 75–77.
217. Zmora O, Mahajna A, Bar-Zakai B, et al. Colon and rectal surgery without mechanical bowel preparation: a randomized prospective trial. *Ann Surg.* 2003;237(3):363–367.
218. Bucher P, Gervaz P, Soravia C, Mermillod B, Erne M, Morel P. Randomized clinical trial of mechanical bowel preparation versus no preparation before elective left-sided colorectal surgery. *Br J Surg.* 2005;92(4):409–414.
219. Guenaga KKFG, Matos D, Wille-Jorgensen P. Mechanical bowel preparation for elective colorectal surgery [update of *Cochrane Database Syst Rev.* 2005;(1):CD001544; PMID: 15674882]. *Cochrane Database Syst Rev.* 2009(1):CD001544.
220. Slim K, Vicaut E, Launay-Savary M-V, Contant C, Chipponi J. Updated systematic review and meta-analysis of randomized clinical trials on the role of mechanical bowel preparation before colorectal surgery. *Ann Surg.* 2009;249(2):203–209.
221. Ramirez JJ, Vassiliu P, Gonzalez-Ruiz C, et al. Sequential compression devices as prophylaxis for venous thromboembolism in high-risk colorectal surgery patients: reconsidering American Society of Colorectal Surgeons parameters. *Am Surg.* 2003;69(11):941–945.
222. The Standards Task Force of the American Society of Colon and Rectal Surgeons. Practice parameters for the prevention of venous thromboembolism. *Dis Colon Rectum.* 2000;43(8):1037–1047.
223. Collins R, Scrimgeour A, Yusuf S, Peto R. Reduction in fatal pulmonary embolism and venous thrombosis by perioperative administration of subcutaneous heparin. Overview of results of randomized trials in general, orthopedic, and urologic surgery. *N Engl J Med.* 1988;318(18):1162–1173.
224. McLeod RS, Geerts WH, Sniderman KW, et al. Subcutaneous heparin versus low-molecular-weight heparin as thromboprophylaxis in patients undergoing colorectal surgery: results of the Canadian colorectal DVT prophylaxis trial: a randomized, double-blind trial. *Ann Surg.* 2001;233(3):438–444.
225. Etchells E, McLeod RS, Geerts W, Barton P, Detsky AS. Economic analysis of low-dose heparin vs the low-molecular-weight heparin enoxaparin for prevention of venous thromboembolism after colorectal surgery. *Arch Int Med.* 1999;159(11):1221–1228.
226. Clagett GP, Reisch JS. Prevention of venous thromboembolism in general surgical patients. Results of meta-analysis. *Ann Surg.* 1988;208(2):227–240.
227. Wolff BG, Pemberton JH, van Heerden JA, et al. Elective colon and rectal surgery without nasogastric decompression. A prospective, randomized trial. *Ann Surg.* 1989;209(6):670–673; discussion 3–5.
228. Malassagne B, Valleur P, Serra J, et al. Relationship of apical lymph node involvement to survival in resected colon carcinoma. *Dis Colon Rectum.* 1993;36(7):645–653.
229. Wiggers T, Jeekel J, Arends JW, et al. No-touch isolation technique in colon cancer: a controlled prospective trial. *Br J Surg.* 1988;75(5):409–415.
230. Rouffet F, Hay JM, Vacher B, et al. Curative resection for left colonic carcinoma: hemicolectomy vs. segmental colectomy. A prospective, controlled, multicenter trial. French Association for Surgical Research. *Dis Colon Rectum.* 1994;37(7):651–659.
231. Natarajan N, Watson P, Silva-Lopez E, Lynch HT. Comparison of extended colectomy and limited resection in patients with Lynch syndrome. *Dis Colon Rectum.* 2010;53(1):77–82.
232. Pezim ME, Nicholls RJ. Survival after high or low ligation of the inferior mesenteric artery during curative surgery for rectal cancer. *Ann Surg.* 1984;200(6):729–733.
233. Surtees P, Ritchie JK, Phillips RK. High versus low ligation of the inferior mesenteric artery in rectal cancer. *Br J Surg.* 1990;77(6):618–621.
234. Sagar PM, Couse N, Kerin M, May J, MacFie J. Randomized trial of drainage of colorectal anastomosis. *Br J Surg.* 1993;80(6):769–771.
235. Urbach DR, Kennedy ED, Cohen MM. Colon and rectal anastomoses do not require routine drainage: a systematic review and meta-analysis. *Ann Surg.* 1999;229(2):174–180.
236. Fingerhut A, Msika S, Yahchouchi E, Merad F, Hay JM, Millat B. Neither pelvic nor abdominal drainage is needed after anastomosis in elective, uncomplicated, colorectal surgery. *Ann Surg.* 2000;231(4):613–614.
237. Yeh CY, Changchien CR, Wang JY, et al. Pelvic drainage and other risk factors for leakage after elective anterior resection in rectal cancer patients: a prospective study of 978 patients. *Ann Surg.* 2005;241(1):9–13.
238. Galandiuk S. To drain or not to drain. *Ann Surg.* 2005;241(1):14–15.
239. Kaiser AM, Corman ML. History of laparoscopy. *Surg Oncol Clin N Am.* 2001;10(3):483–492.
240. Lacy AM, Garcia-Valdecasas JC, Delgado S, et al. Laparoscopy-assisted colectomy versus open colectomy for treatment of non-metastatic colon cancer: a randomised trial. *Lancet.* 2002;359(9325):2224–2229.
241. Clinical Outcomes of Surgical Therapy Study G. A comparison of laparoscopically assisted and open colectomy for colon cancer. *N Engl J Med.* 2004;350(20):2050–2059.
242. Leung KL, Kwok SP, Lam SC, et al. Laparoscopic resection of rectosigmoid carcinoma: prospective randomised trial. *Lancet.* 2004;363(9416):1187–1192.
243. Kaiser AM, Kang JC, Chan LS, Vukasin P, Beart RW, Jr. Laparoscopic-assisted vs. open colectomy for colon cancer: a prospective randomized trial. *J Laparoendosc Adv Surg Techn A.* 2004;14(6):329–334.
244. Guillou PJ, Quirke P, Thorpe H, et al. Short-term endpoints of conventional versus laparoscopic-assisted surgery in patients with colorectal cancer (MRC CLASICC trial): multicentre, randomised controlled trial. *Lancet.* 2005;365(9472):1718–1726.
245. The Colon cancer Laparoscopic or Open Resection (COLOR) Study Group. Laparoscopic surgery versus open surgery for colon cancer: short-term outcomes of a randomised trial. *Lancet Oncol.* 2005;6(7):477–484.
246. Weeks JC, Nelson H, Gelber S, Sargent D, Schroeder G; Clinical Outcomes of Surgical Therapy Study G. Short-term quality-of-life outcomes following laparoscopic-assisted colectomy vs open colectomy for colon cancer: a randomized trial. *JAMA.* 2002;287(3):321–328.
247. Jayne DG, Guillou PJ, Thorpe H, et al. Randomized trial of laparoscopic-assisted resection of colorectal carcinoma: 3-year results of the UK MRC CLASICC Trial Group. *J Clin Oncol.* 2007;25(21):3061–3068.
248. Colon Cancer Laparoscopic or Open Resection Study G; Buunen M, Veldkamp R, Hop WC, et al. Survival after laparoscopic surgery versus open surgery for colon cancer: long-term outcome of a randomised clinical trial. *Lancet Oncol.* 2009;10(1):44–52.
249. Bertagnolli M, Miedema B, Redston M, et al. Sentinel node staging of resectable colon cancer: results of a multicenter study. *Ann Surg.* 2004;240(4):624–628; discussion 8–30.
250. Kaiser AM, Katkhouda N. Laparoscopic management of the perforated viscus. *Semin Laparosc Surg.* 2002;9(1):46–53.
251. Alves A, Panis Y, Mathieu P, et al. Postoperative mortality and morbidity in French patients undergoing colorectal surgery: results of a prospective multicenter study. *Arch Surg.* 2005;140(3):278–283.
252. Binkert CA, Ledermann H, Jost R, Saurenmann P, Decurtins M, Zollikofer CL. Acute colonic obstruction: clinical aspects and cost-effectiveness of preoperative and palliative treatment with self-expanding metallic stents—a preliminary report. *Radiology.* 1998;206(1):199–204.
253. Dauphine CE, Tan P, Beart RW, Jr, Vukasin P, Cohen H, Corman ML. Placement of self-expanding metal stents for acute malignant large-bowel obstruction: a collective review. *Ann Surg Oncol.* 2002;9(6):574–579.
254. Brehant O, Fuks D, Bartoli E, Yzet T, Verhaeghe P, Regimbeau JM. Elective (planned) colectomy in patients with colorectal obstruction after placement of a self-expanding metallic stent as a bridge to surgery: the results of a prospective study. *Colorectal Dis.* 2009;11(2):178–183.
255. Dastur JK, Forshaw MJ, Modarai B, Solkar MM, Raymond T, Parker MC. Comparison of short- and long-term outcomes following either insertion of self-expanding metallic stents or emergency surgery in malignant large bowel obstruction. *Tech Coloproctol.* 2008;12(1):51–55.
256. Sugarbaker PH, Corlew S. Influence of surgical techniques on survival in patients with colorectal cancer. *Dis Colon Rectum.* 1982;25(6):545–557.
257. Lopez MJ, Monaf WW. Role of extended resection in the initial treatment of locally advanced colorectal carcinoma. *Surgery.* 1993;113(4):365–372.
258. Geoghegan JG, Scheele J. Treatment of colorectal liver metastases. *Br J Surg.* 1999;86(2):158–169.
259. Schrag D, Cramer LD, Bach PB, Cohen AM, Warren JL, Begg CB. Influence of hospital procedure volume on outcomes following surgery for colon cancer. *JAMA.* 2000;284(23):3028–3035.

260. Tang CL, Yeong KY, Nyam DC, et al. Postoperative intra-abdominal free gas after open colorectal resection. *Dis Colon Rectum*. 2000;43(8):1116–1120.
261. Krook JE, Moertel CG, Gunderson LL, et al. Effective surgical adjuvant therapy for high-risk rectal carcinoma. *N Engl J Med*. 1991;324(11):709–715.
262. Dube S, Heyen F, Jenicek M. Adjuvant chemotherapy in colorectal carcinoma: results of a meta-analysis. *Dis Colon Rectum*. 1997;40(1):35–41.
263. O'Connell MJ, Laurie JA, Kahn M, et al. Prospectively randomized trial of postoperative adjuvant chemotherapy in patients with high-risk colon cancer. *J Clin Oncol*. 1998;16(1):295–300.
264. QUASAR Collaborative Group. Comparison of fluorouracil with additional levamisole, higher-dose folinic acid, or both, as adjuvant chemotherapy for colorectal cancer: a randomised trial. *Lancet*. 2000;355(9215):1588–1596.
265. Shirota Y, Stoehlmacher J, Brabender J, et al. ERCC1 and thymidylate synthase mRNA levels predict survival for colorectal cancer patients receiving combination oxaliplatin and fluorouracil chemotherapy. *J Clin Oncol*. 2001;19(23):4298–4304.
266. Stoehlmacher J, Park DJ, Zhang W, et al. A multivariate analysis of genomic polymorphisms: prediction of clinical outcome to 5-FU/oxaliplatin combination chemotherapy in refractory colorectal cancer. *Br J Cancer*. 2004;91(2):344–354.
267. Gordon MA, Gil J, Lu B, Zhang W, Yang D, Yun J, Schneider S, Groshen S, Iqbal S, Press OA, Rhodes K, Lenz HJ. Genomic profiling associated with recurrence in patients with rectal cancer treated with chemoradiation. *Pharmacogenomics*. 2006;7(1):67–88.
268. Saltz LB, Cox JV, Blanke C, et al. Irinotecan plus fluorouracil and leucovorin for metastatic colorectal cancer. Irinotecan Study Group. *N Engl J Med*. 2000;343(13):905–914.
269. Douillard JY, Hoff PM, Skillings JR, et al. Multicenter phase III study of uracil/tegafur and oral leucovorin versus fluorouracil and leucovorin in patients with previously untreated metastatic colorectal cancer. *J Clin Oncol*. 2002;20(17):3605–3616.
270. de Gramont A, Figer A, Seymour M, et al. Leucovorin and fluorouracil with or without oxaliplatin as first-line treatment in advanced colorectal cancer. *J Clin Oncol*. 2000;18(16):2938–2947.
271. Becouarn Y, Gamelin E, Coudert B, et al. Randomized multicenter phase II study comparing a combination of fluorouracil and folinic acid and alternating irinotecan and oxaliplatin with oxaliplatin and irinotecan in fluorouracil-pretreated metastatic colorectal cancer patients. *J Clin Oncol*. 2001;19(22):4195–4201.
272. Grothey A, Sargent D, Goldberg RM, Schmoll HJ. Survival of patients with advanced colorectal cancer improves with the availability of fluorouracil-leucovorin, irinotecan, and oxaliplatin in the course of treatment. *J Clin Oncol*. 2004;22(7):1209–1214.
273. Goldberg RM, Sargent DJ, Morton RF, et al. A randomized controlled trial of fluorouracil plus leucovorin, irinotecan, and oxaliplatin combinations in patients with previously untreated metastatic colorectal cancer. *J Clin Oncol*. 2004;22(1):23–30.
274. Van Cutsem E, Hoff PM, Harper P, et al. Oral capecitabine vs intravenous 5-fluorouracil and leucovorin: integrated efficacy data and novel analyses from two large, randomised, phase III trials. *Br J Cancer*. 2004;90(6):1190–1197.
275. Borner MM, Dietrich D, Stupp R, et al. Phase II study of capecitabine and oxaliplatin in first- and second-line treatment of advanced or metastatic colorectal cancer. *J Clin Oncol*. 2002;20(7):1759–66.
276. Scheithauer W, Kornek GV, Raderer M, et al. Randomized multicenter phase II trial of two different schedules of capecitabine plus oxaliplatin as first-line treatment in advanced colorectal cancer. *J Clin Oncol*. 2003;21(7):1307–1312.
277. Shields AF, Zalupski MM, Marshall JL, Meropol NJ. Treatment of advanced colorectal carcinoma with oxaliplatin and capecitabine: a phase II trial. *Cancer*. 2004;100(3):531–537.
278. Cassidy J, Taberero J, Twelves C, et al. XELOX (capecitabine plus oxaliplatin): active first-line therapy for patients with metastatic colorectal cancer. *J Clin Oncol*. 2004;22(11):2084–2091.
279. Bajetta E, Di Bartolomeo M, Mariani L, et al. Randomized multicenter Phase II trial of two different schedules of irinotecan combined with capecitabine as first-line treatment in metastatic colorectal carcinoma. *Cancer*. 2004;100(2):279–287.
280. Cunningham D, Humblet Y, Siena S, et al. Cetuximab monotherapy and cetuximab plus irinotecan in irinotecan-refractory metastatic colorectal cancer. *N Engl J Med*. 2004;351(4):337–345.
281. Hurwitz H, Fehrenbacher L, Novotny W, et al. Bevacizumab plus irinotecan, fluorouracil, and leucovorin for metastatic colorectal cancer. *N Engl J Med*. 2004;350(23):2335–2342.
282. Tol J, Koopman M, Cats A, et al. Chemotherapy, bevacizumab, and cetuximab in metastatic colorectal cancer. *N Engl J Med*. 2009;360(6):563–572.
283. Karapetis CS, Khambata-Ford S, Jonker DJ, et al. K-ras mutations and benefit from cetuximab in advanced colorectal cancer. *N Engl J Med*. 2008;359(17):1757–1765.
284. Amos EH, Mendenhall WM, McCarty PJ, et al. Postoperative radiotherapy for locally advanced colon cancer. *Ann Surg Oncol*. 1996;3(5):431–436.
285. Palermo JA, Richards F, Lohman KK, et al. Phase II trial of adjuvant radiation and intraperitoneal 5-fluorouracil for locally advanced colon cancer: results with 10-year follow-up. *Int J Radiat Oncol Biol Phys*. 2000;47(3):725–733.
286. Taylor WE, Donohue JH, Gunderson LL, et al. The Mayo Clinic experience with multimodality treatment of locally advanced or recurrent colon cancer. *Ann Surg Oncol*. 2002;9(2):177–185.

# LAPAROSCOPIC COLORECTAL PROCEDURES

Rajesh Pendlimari • Heidi Nelson

## INTRODUCTION

The practice of minimally invasive surgery has rapidly grown over the past two decades to the point that laparoscopic surgery has replaced open surgery for several abdominal procedures (such as cholecystectomy) and gained acceptance and implementation for many other procedures (such as colectomy).<sup>1</sup> For many surgical practices laparoscopic techniques have become common place for the patient-related advantages they offer (Table 37-1). In part, the introduction of hand-assisted laparoscopic surgery (HALS) and the early exposure of trainees to diverse laparoscopic techniques have facilitated the availability of laparoscopic surgery to more practitioners and patients.<sup>2</sup> Knowledge and experience gained from the evolving practice over the past nearly two decades has provided clarity on indications, contraindications, and technical advancements. This chapter provides a review of the principles behind the practice of laparoscopic colon and rectal surgery. It also provides a brief review of the special considerations for cancer of the colon and the rectum and focuses on providing a contemporary description of the technical approaches to laparoscopic and HALS approaches to segmental resections of the colon and the rectum, and the combined resections of the colon and rectum with creation of pelvic pouches. Finally, a perspective on NOSE (natural orifice specimen extraction), NOTES (natural orifice transluminal endoscopic surgery), and robotic surgery is offered at the conclusion of this chapter.

## PATIENT SELECTION

### Indications, Contraindications, Evaluations

With the exception of rectal cancer cases, laparoscopic surgery can be considered an option for virtually any patient with a

colon or rectal condition requiring surgery. With that said, not all patients will be ideal candidates and not all procedures can be performed by all surgeons. All surgeons must find their comfort zone with laparoscopic cases. The initiate to laparoscopy should consider limiting their early practice to right colectomies in patients who are thin and have limited risks of adhesions as well as benign disease process such as polyps or ileocolonic Crohn's strictures. Surgeons with advanced skills may be comfortable doing an entire total proctocolectomy and ileal pouch-anal anastomosis. All of these procedures have been technically described in this chapter to provide a range of procedures that are feasible. In addition to the technical range of possibilities, there is a range with respect to which patients will do well with the laparoscopic approach. As with any laparoscopic approach, for example, there would be some cases where a pneumoperitoneum is contraindicated and others where the disease or technical considerations represent contraindications. Indications and contraindications and pre- and intraoperative evaluations specific to the colon and rectal diseases and patient conditions are provided, followed by focused discussion on oncologic issues relevant to colon and rectal cancer and key points.

## INDICATIONS

The indications for laparoscopic surgery for conditions of the colon and rectum are predominantly the same as those for open surgery (Table 37-2). For inflammatory bowel disease, the list of indications includes symptomatic failure of medical therapy; dysplasia; and presence of strictures, abscess, and fistula. In acute colitis, urgent subtotal colectomy with end ileostomy may be performed initially as a part of a two- or three-stage procedure. Procedures may include strictureplasty, small bowel resection, segmental colonic resection, or proctocolectomy. For diverticulitis, the current American Society of Colon and Rectal Surgeons (ASCRS) guidelines recommend that the decision for elective resection of sigmoid after




**TABLE 37-1: ADVANTAGES OF LAPAROSCOPY**

1. Smaller incision
2. Less post-op pain
3. Shorter hospitalization
4. Improved quality of life
5. Shorter posthospital recovery
6. Better cosmetic result
7. Reduction in post-op adhesions

recovering from acute diverticulitis should be made on a case-by-case basis and recommend the laparoscopic approach in selected patients.<sup>3</sup> Large colonic polyps not amenable for resection through the endoscope may be resected through laparoscopic approach. The laparoscopic approach has been proved to produce equivalent outcomes with open resection for localized colon cancer, when oncological principles are practiced. Solitary metastatic lesion in the liver with localized tumor in the colon can also be resected laparoscopically in competent hands.

The laparoscopic approach is preferred in the repair of rectal prolapse. Resection rectopexy and mesh rectopexy both can be performed through the laparoscopic approach. Laparoscopic rectopexy has similar long-term functional outcomes and low recurrence rates.<sup>4</sup> As discussed previously, a number of technical challenges are involved in performing laparoscopic rectal cancer resection. Large multicenter trials are going on in North America and Europe to evaluate the outcomes of rectal cancer for laparoscopic approach.

## CONTRAINDICATIONS

General health conditions that would contraindicate a minimally invasive approach requiring a pneumoperitoneum typically include any severe manifestation of organ failure (Table 37-3). Patients with severe chronic obstructive pulmonary disease (COPD), reactive airway disease, or other causes of


**TABLE 37-2: INDICATIONS IN COLON AND RECTAL DISEASES**

1. Ulcerative colitis—refractory disease, dysplasia
2. Crohn's disease—refractory disease, bleeding, strictures, confined abscess, fistula
3. Diverticular disease—recurrent, noncomplicated
4. Volvulus
5. Colon polyps—not amenable to endoscopic resection
6. Carcinoma colon—localized lesions amenable to 8-cm extraction site
7. Rectal prolapse
8. Rectal cancer (in controlled trials)

respiratory compromise are usually not tolerant of the abdominal insufflation required for conducting intra-abdominal work. Patients with advanced cardiovascular disease are also typically intolerant of the pneumoperitoneum, as it can restrict the fragile dynamics of cardiac output. Finally, patients with end-organ renal failure and severe electrolyte or fluid disturbances and those with liver failure, ascites, or other sources of bleeding disorders are best served with a more controlled, open approach. At times, these conditions are not appreciated as problematic until the procedure is under way and the anesthesiologist is experiencing difficulties. Accordingly, open lines of communication between the surgeon and the anesthesiologist as well as a willingness to convert to open surgery should be the rule and not the exception.

Less absolute or relative contraindications of laparoscopy include the presence of adhesions, cardiac abnormalities, pulmonary gas exchange abnormalities, chronic liver disease, and obesity. None of these are clear-cut or absolute. For example, patients may have several abdominal scars and have undergone numerous prior procedures even near the site of the anticipated colon resection, but they may not


**TABLE 37-3: CONTRAINDICATIONS TO LAPAROSCOPY**

Absolute contraindications	<ul style="list-style-type: none"> <li>• Inability to tolerate pneumoperitoneum</li> <li>• Poor risk for general anesthesia</li> <li>• Poorly controlled coagulopathy</li> <li>• Severe systemic disease that is constant threat to life</li> <li>• Moribund patient, unlikely to survive for 24 h with/without surgery</li> </ul>
Relative contraindications	<ul style="list-style-type: none"> <li>• Multiple abdominal procedures</li> <li>• Cardiac abnormalities</li> <li>• Pulmonary gas exchange abnormalities</li> <li>• Chronic liver disease</li> <li>• Morbid obesity</li> </ul>
Contraindications in colon diseases	<ul style="list-style-type: none"> <li>• Large phlegmon or mass</li> <li>• Complex fistulizing disease</li> <li>• Tumor infiltrated into adjacent structures (T4 disease)</li> <li>• Bowel obstruction</li> <li>• Toxic dilation of the colon</li> <li>• Perforation</li> <li>• Significant adhesions</li> </ul>
Contraindications in rectal diseases	<ul style="list-style-type: none"> <li>• Large phlegmon or mass</li> <li>• Complex fistulizing disease</li> <li>• Locally infiltrative rectal cancer</li> <li>• Recurrent rectal cancer</li> <li>• Bowel obstruction</li> <li>• Toxic dilation of the colon</li> <li>• Perforation</li> <li>• Significant adhesions</li> </ul>

have prohibitive adhesions. Unless we know the patient has prohibitive adhesions, we would approach the case laparoscopically with a cautionary note to the patient that the risk of conversion may be higher than 10–15%. The same can be said for obesity. At times, managing obese patients is facilitated by laparoscopy, such as when the fat is predominantly in the abdominal wall. That being said, some obesity cases cannot be conducted using laparoscopic techniques, for example when the tools will not reach from the port to the site of the surgical resection.

A final category of absolute and relative contraindications includes those specific to the disease under treatment. For inflammatory bowel disease a large phlegmonous mass, complex or large abscess, or complex fistulizing disease are likely not suitable for the bulk of the specimen to be extracted, not to mention the challenges of mobilization. Similarly, a toxic abdomen from sepsis or fecal contamination would not be ideal for laparoscopic surgery. Massive dilation of the large or small bowel could prohibit both intra-abdominal visualization and the safe movement of instruments throughout the abdominal cavity. In cases of cancer, there is little evidence in support of tackling large fixed or recurrent tumors through small incisions. The risk-benefit ratio for large, fixed, and recurrent tumors would likely favor open surgery, although it has never been prospectively studied.

#### PREOPERATIVE EVALUATIONS UNIQUE TO LAPAROSCOPIC SURGERY

A word must be said about the workup of patients who are intended for the minimally invasive surgical approach. Although the preoperative evaluations are usually the same as for any other laparotomy approach, it is generally advised that the diagnostic tests for the disease and the treatment be as definitive and clear as possible before laparoscopic surgery. The absence of tactile information demands better preoperative assessments than historically considered necessary for open surgery. This was first realized with tumor staging. The traditional approach with open surgery was to palpate the liver at the time of laparotomy to locate metastatic tumor deposits in the abdomen, including such sites as the liver, ovaries, peritoneal cavity, omentum, or retroperitoneal lymph nodes. Current imaging with computerized tomography (CT) has improved to the point that such novel findings at surgery are rare. Surgeons may identify small superficial hepatic metastases or peritoneal tumors at the time of surgery, but this is less common than it was when laparoscopic surgery was initiated in the early 1990s.

In a similar fashion, primary tumors need to be well localized prior to surgery. For the most part this can be accomplished by combining endoscopy with tattooing for small, benign lesions, or with CT imaging for large or malignant neoplasms. Endoscopy, although usually accurate, can be misleading because there are no consistent endoluminal landmarks for identifying colonic location. Early experiences with missed lesions and wrong-site resections brought these lessons forward. For malignant lesions

it is often possible to see the mass on staging CT scan; this can be very reassuring for accurate localization. In addition to the preoperative testing, we advise that one never leave the operating room without first confirming that the target lesion has been confidently removed and identified in a specimen. Because colonoscopy can misjudge, anatomic colonic location by more than one colonic segment, this safety measure seems simple and warranted.

For benign conditions, it is equally important to localize the site of diseased bowel and understand the exact extent of disease, that is, complex versus simple fistula, contained mesenteric abscess versus poorly contained complex or perforated abscess. Of course, the size of the specimen will dictate the size of the extraction site. The larger the lesion to be extracted and the larger the incision, the less the benefit there is to the laparoscopic approach. For Crohn's disease, CT enterography may help reveal secondary sites of disease. We would also advise a complete intraoperative assessment of the small bowel in cases of Crohn's disease, especially in cases of stricturing disease.

#### INTRAOPERATIVE EVALUATIONS AND REASONS FOR CONVERSION

Conversion of laparoscopic procedure to open procedure may be required when difficulties are encountered. The reasons for conversion may include unexpected disease, significant adhesions, and inability to identify vital structures such as ureters. It is important to remember that conversion itself is not a complication, even though intraoperative complications necessitate conversion. It should not be viewed as failure but rather as an application of sound surgical judgment. It is probably safer for a surgeon to have low threshold for conversion, because the timing of conversion is critical to reduce not only overall costs but also complications. A decision to convert is best made early in the procedure, thus avoiding an increased risk of complications and reducing operative time. An early decision to convert will ensure that the rates of morbidity and mortality are maintained at acceptable levels.

For patients who are known to have frail tissues from chronic immunosuppression or other systemic conditions with adverse effects on tissues, extra caution should be taken in handling the bowel in particular but other tissues as well during the surgery. It is more difficult to judge the impact of instruments when there is an inability to use tactile information. These cases may benefit from the hand-assisted approach for that reason.

A final note should be made about the use of ureteral stents in minimally invasive cases. In general, we would not use ureteral stents for any case when they are not required in the correlating open surgery. With that said, we have a low threshold for having ureteral stents placed either preoperatively or during surgery when an inflammatory or tumor process obscures the anatomic location of the either ureter. If they are available and make a difference, the lighted ureteral stents can also be used to get a visual sense of location of the ureter.

## ONCOLOGIC ISSUES SPECIFIC TO LAPAROSCOPIC SURGERY IN COLON AND RECTAL CANCER

Because of the unique controversies that emerged with the introduction of laparoscopic colectomy for cancer, we offer here a section that specifically covers this topic for both colon cancer and rectal cancer. Soon after the introduction of the laparoscopic colectomy in 1991,<sup>1</sup> a number of concerns regarding the application of this technique in colon cancer arose, including reports of tumor wound recurrences at trocar sites and tumor extraction sites.<sup>5-7</sup> Such reports were frequent enough that national statements were issued recommending a moratorium on laparoscopic colectomy for cancer outside of clinical trials.<sup>8</sup> In response, a number of randomized clinical trials were initiated simultaneously in North America, Canada, and in Europe. At least four large prospective, randomized trials have been completed and have reported both short- and long-term outcomes. To date, 3133 patients have been studied by random allocation to laparoscopic versus open surgery and followed for cancer outcomes. These patients are reported from four international trials, including the Barcelona trial<sup>9</sup> (219 patients), the COST (Clinical Outcomes of Surgical Therapy) trial<sup>10</sup> (872 patients), the COLOR (COlon cancer Laparoscopic or Open Resection) trial<sup>11,12</sup> (1248 patients), and the CLASICC (Conventional versus Laparoscopic-Assisted Surgery In Colorectal Cancer) trial<sup>13,14</sup> (794 patients). Short-term results from all four studies confirm equivalent mortality and rates of morbidity between the laparoscopic and the open arms. They also consistently demonstrate reductions in length of hospital stay, time to first feed, and time to first bowel movement. Quality of life, although modest, has also been confirmed.

At least three of these trials, the Barcelona, COST and COLOR trials, have completed 5-year follow-up for the entire cohort of patients. It has been reassuring that these trials have not demonstrated inferiority for the laparoscopic arm with respect to overall survival or disease-free survival. A pooled analysis of all four trials examining 3-year median survival was also conducted and it confirms the same, that is, no difference in overall survival or disease-free survival between the open and laparoscopic arms.<sup>15</sup> These data have encouraged the adoption of laparoscopic colectomy for colon cancer in the absence of harm and in the presence of confirmed benefits.

The same is not true for laparoscopic rectal cancer. Indeed, although there have been several clinical trials testing the equivalence of laparoscopic colectomy in the setting of curable colon cancer, there are few studies available to examine the same question in rectal cancer. For rectal cancer, the concerns are different than they were for colon cancer. The initial concern with using laparoscopic techniques in colon cancer focused on the potential for abnormal distribution of cancer cells due to the pneumoperitoneum. It was thought that the pneumoperitoneum created a "chimney effect"<sup>16</sup> that caused a focusing of tumor cells at wound sites such as trocar sites or wound extraction sites and increased the risk of tumor implants.<sup>17</sup> There was also at least a theoretical risk that it could cause dissemination of tumor cells through abnormal patterns. This has not been borne out in colon cancer and is not considered relevant, therefore, in rectal cancer. What is considered of relevance in

rectal cancer is whether laparoscopic techniques can achieve tumor-free margins with the same rate as open surgery.<sup>18</sup> Some might argue that the pelvic dissection is facilitated by laparoscopic equipment and access to the deep pelvis with lighting and visualization superior to open surgery in some cases. This has not been proven in diverse practice settings. An additional concern is the ability to achieve distal stapling due to the limits of current instrumentation. These issues are being addressed by a prospective randomized trial conducted by the American College of Surgeons Oncology Group (ACOSOG).<sup>19</sup>

The ACOSOG Z6051 trial is a multicenter, phase III, randomized clinical trial with the primary objective that laparoscopic-assisted resection for rectal cancer is not inferior to open rectal resection, based on composite primary end point of oncologic factors that are indicative of a safe and feasible operation. The end point of this noninferiority trial is based on detailed and standardized pathologic evaluation of the specimen, including circumferential and distal margins and the completeness of the total mesorectal excision. The primary end point is a novel, surrogate end point for long-term oncologic outcome that reduces both the necessary accrual target of the trial and its time to maturation. The secondary end points include patient-related benefits (blood loss, length of stay, pain medicine utilization), 2-year local recurrence, and quality of life. The eligible criteria for the disease include T3N0M0, T1-3N1M0 adenocarcinoma of the rectum with the lower edge 12 cm or less from the anal verge and completion of 5-fluorouracil (5-FU) or capecitabine-based chemotherapy/radiotherapy in the last 4 weeks. The other patient criteria include age 18 years or greater, ECOG (Eastern Cooperative Oncology Group) performance status 2 or less, body mass index (BMI) 34 or less, no evidence of laparoscopic contraindications, no evidence of systemic disease precluding surgery, nonpregnant, nonlactating, no history of current or previous invasive pelvic malignancy, and no history of psychiatric illness. Surgeon credentialing in both laparoscopic colon and laparoscopic rectal surgery is required for participation in this study. It is based on having completed 20 laparoscopic-assisted resections each of the colon and rectum. The operative reports and the pathology reports of those cases and an unedited videotape of their laparoscopic rectal technique are reviewed by two designated investigators. This noninferiority trial is projected to enroll 650 eligible patients in the United States and Canada. The trial is sponsored by the National Cancer Institute (NCI). Further details and contact information can be obtained from the following website: <http://www.cancer.gov/clinicaltrials/ACOSOG-Z6051>.

## Key Points

1. Accurate preoperative defining of the extent of the disease is a prerequisite to make the procedure successful.
2. Preoperative tattooing of the lesion with colonoscopy will aid in the localization of the tumor during the procedure.



3. Dense adhesions or extensive disease that prevents accurate identification of the vital structures and increases the risk of complications should cause the surgeon to convert early to an open procedure.
4. Care should be taken during handling of bowel in patients particularly on high-dose steroids due to increased fragility of the tissues. Atraumatic graspers or the HALS approach should be preferred to avoid direct grasping of the colon.
5. Placement of a ureteral stent should be considered when there is difficulty in locating one or both ureters as a result of inflammation or tumor in the retroperitoneum.
6. In case of malignancy or dysplasia, it is essential to perform a complete oncological resection. This includes adequate mobilization, high vascular ligation, satisfactory lymph node harvest, and negative resection margins. Intracorporeal ligation is required to achieve high vascular ligation.

## GENERAL TECHNICAL INFORMATION

### Equipment and Instruments

Basic laparoscopic equipment is common for most of the cases and detailed in the previous chapters (Table 37-4 and Fig. 37-1). Surgeon acquaintance and comfort with the equipment is more important than the exact specifications. A 30-degree laparoscope is more useful than the 0-degree laparoscope, particularly for visualization during mobilization of the flexures and working in the pelvis. Trocars should have the ability to be sutured or have stability threads to prevent dislodgement or leakage during the case. Cautery attachment should be on the upper side of the instruments so it does not interfere with hand movements during dissection or slip off as a result of gravity and repeated hand movements. TV monitors, light source, camera unit, and CO<sub>2</sub> insufflator should be placed on readily mobile units, to allow easy positioning and provide the surgeon with better



**TABLE 37-4: COMMONLY USED LAPAROSCOPIC INSTRUMENTS**

1. Video camera unit
2. Light source
3. CO<sub>2</sub> insufflator
4. 30-degree laparoscope (5 or 10 mm)
5. Suction/irrigator
6. Cannulas (Hassan and 10/12 or 5 mm)
7. Scissors with cautery attachment
8. Babcock graspers
9. Intracorporeal vascular ligation device
10. Circular stapler for pelvic cases
11. Linear stapler (optional)
12. Automatic clip applier (optional)
13. LigaSure (optional)
14. Harmonic scalpel (optional)

ergonomics. Bowel handling graspers should be atraumatic in order to prevent serosal injury. The Babcock forceps are best applied along side the bowel, on the mesentery, or on opposing peritoneal surface. The atraumatic alligator bowel grasper can supplement the Babcock graspers while mobilizing the bowel because of its large surface area.

Although some might prefer the Veress needle for insufflating, we prefer the Hassan-type cannula and open insertion technique as they minimize the risk of injury to intra-abdominal structures. Instruments should be of sufficient length to reach up to the flexures and down into the pelvis from centrally located ports; this minimizes the need for extra ports. Total proctocolectomy and abdominal perineal resection (APR) procedures in particular require long instruments that are at least 38–40 cm. Care should be taken with the use of cutting devices (electrocautery and ultrasonic cutting devices) to minimize the risk of complications from the exposed metal components of the tools. The curved scissors allow more maneuverability, and the ability to cauterize with the curved scissors can save time.

### SPECIAL DEVICES IN COLON AND RECTAL LAPAROSCOPIC SURGERY

Several options are now available for handling the colon mesentery. The automatic clip applier can be useful for dissecting the mesenteric vessels or controlling small- to medium-size bleeding vessels. LigaSure (ValleyLab, Boulder, CO) is used to fuse tissue bundles and vessels up to 7 mm diameter using a combination of pressure and thermal energy. The Harmonic scalpel utilizes ultrasonic energy in cutting and coagulating the tissues simultaneously and offers better precision. The laparoscopic linear stapler can serve a dual purpose as it allows transection of the colon without contamination and a vascular load can be used to transect a vascular pedicle. Special maneuvers with the linear stapler aid in the preparation of J-pouch and making of side-to-side anastomosis. Circular anastomotic stapler is used for making colocolic or ileocolic anastomosis.

### PATIENT POSITION AND ROOM SETUP

Careful positioning and securing of the patient on the operating table is essential for safety of the procedure because steep inclinations of the operating table are required to assist in achieving proper exposure of the operative field. For the supine position, ankle straps ensure that steep Trendelenburg's position is tolerated and shoulder straps or bean bags can ensure that the patient does not shift side to side when the table is "air-planed" to the left or right. For synchronous cases, having the lower extremities secured in stirrups creates the same effect as ankle straps. For most cases, it is ideal to have the arms securely padded and strapped to the sides of the table. Generous padding at the elbow and neutral positioning of the wrist will minimize the risk of ulnar or median nerve injury, respectively, from pressure during long-duration surgery. A urinary catheter decompresses the bladder and a nasogastric

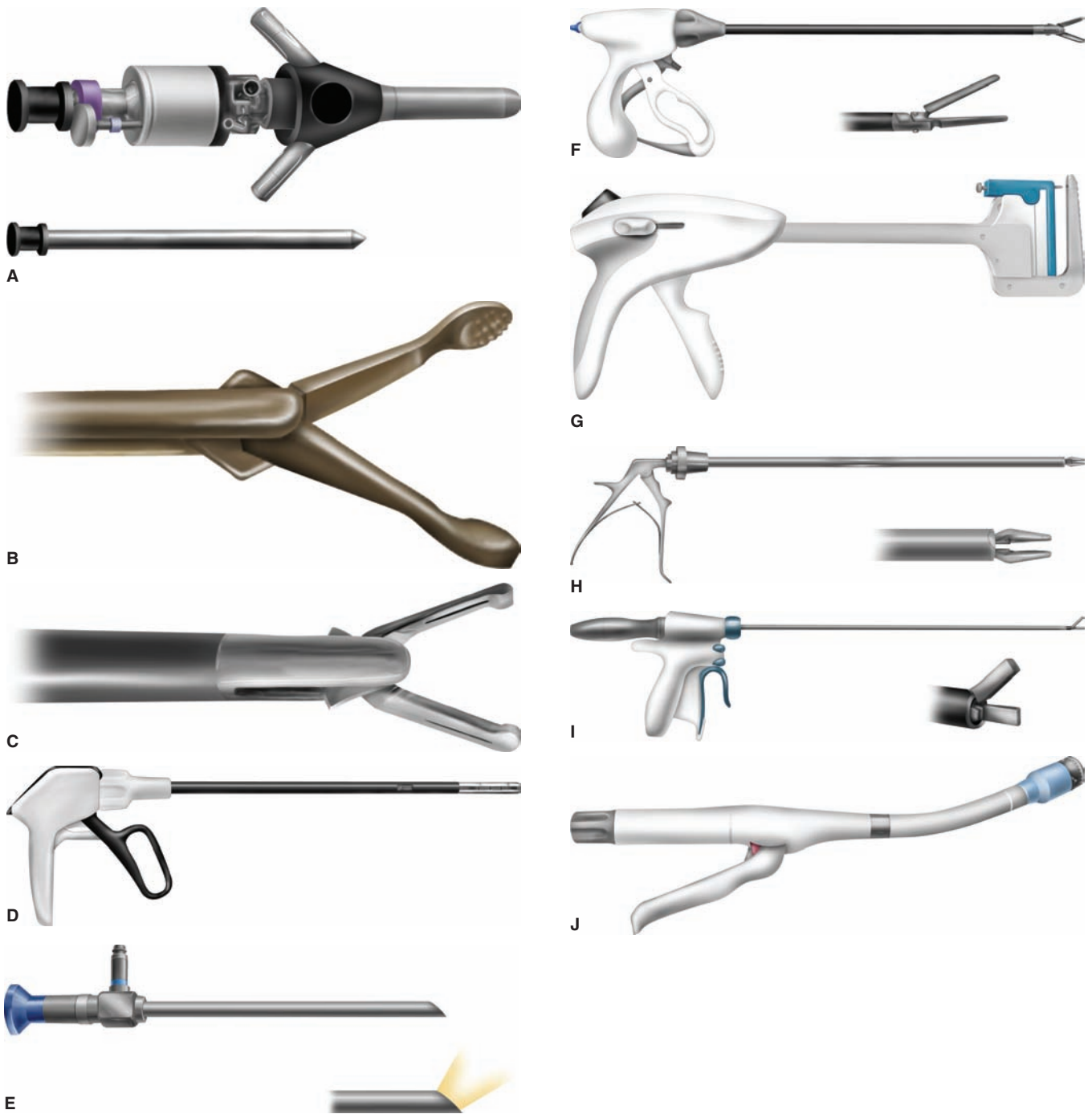
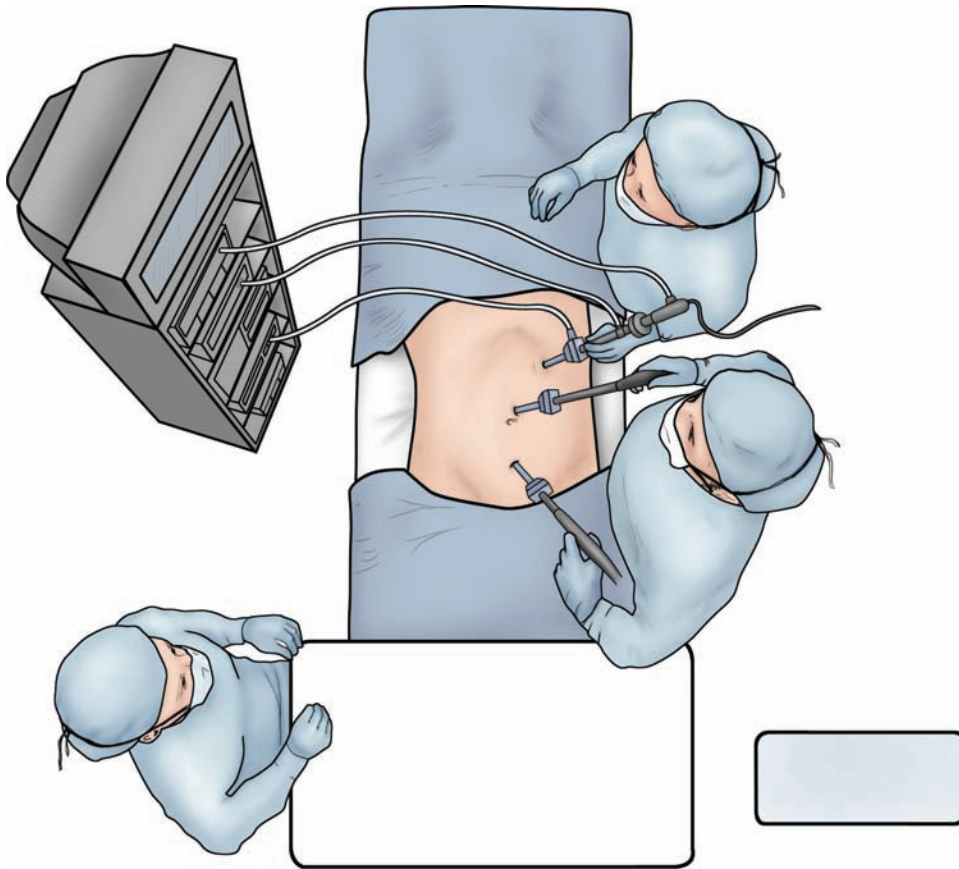


FIGURE 37-1 Laparoscopic instruments.

tube decompresses the stomach to avoid inadvertent injury and to maximize space in the abdominal cavity. The surgeon and the surgical assistant stand on the patient's side with the monitor on the opposite side to achieve consistent and in-line orientation of the field. The surgeon's eyes, hands, trocars, instrument tips, and monitor should all be directly parallel and closely aligned to minimize the difficulties associated with reverse image operating (Fig. 37-2).

#### PORT PLACEMENT TECHNIQUE

A cut-down technique is used to insert Hassan's trocar, with Hassan's cannula as the first port. Pneumoperitoneum is achieved by insufflation of carbon dioxide to 12–14 mm Hg. A 30-degree laparoscope is the preferred camera as it offers the optimal operative view. The rest of the ports are inserted under direct visual guidance.



**FIGURE 37-2** Position of equipment and the surgical team for laparoscopic right hemicolectomy. (Used with permission of Mayo Foundation for Medical Education and Research, all rights reserved.)

## WOUND CLOSURE

Trocars are removed after the pneumoperitoneum is fully released through the cannulas to avoid sucking of the bowel into the port sites and to avoid the concentration of tumor cells at the trocar sites in cancer cases. The 5-mm port sites do not require fascial closure unless there is significant enlargement of the fascia during the procedure. Port site closure should include peritoneum and fascia when they are 10 mm or greater. The lateral ports are closed under direct visualization prior to closure of midline wounds. The “Endo Close” spring-loaded suturing device can be used to close the incision. The fascia is closed with a figure-of-eight suture and an extracorporeal knot is tied. A purse-string suture is an option for closing the periumbilical site.

## Right Hemicolectomy

### STEP 1: PATIENT POSITION AND ROOM SETUP

The patient is carefully positioned supine and secured on the operating table as described previously. The surgeon and the surgical assistant stand on the patient's left side with the monitor on the right side to achieve consistent and in-line orientation of the field. The instrument table is

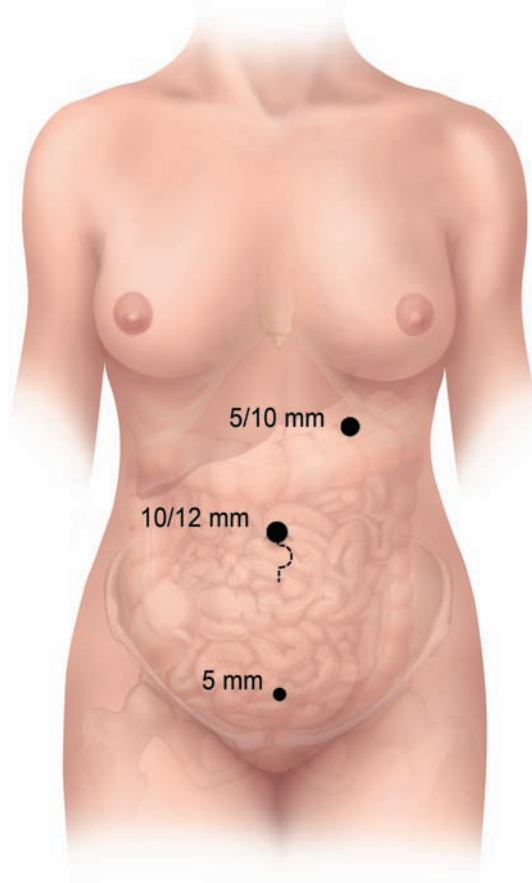
easily accommodated at the foot of the bed and the scrub nurse on the patient's right side.

### STEP 2: PORT PLACEMENT AND EXPLORATION

A 10- to 12- mm port is placed in the supraumbilical area using an open cut-down technique. A different site is preferred (typically left upper quadrant [LUQ]) when a midline scar is present and extensive adhesions are anticipated. A 30-degree camera is passed through this port, and under direct vision two 5-mm trocars are placed—one in the LUQ lateral to the epigastric vessels and 2 cm below the costal margin and the other in the suprapubic midline (Fig. 37-3). As an alternative, one can place three 10- to 12-mm trocars; this allows maximum flexibility for placement of instruments and the camera, but the more experienced surgeon may exchange one or more for 5-mm trocars.

Simple adhesions encountered at this stage should be divided. Then, an inspection of the abdominal cavity should be performed to confirm the pathology for which surgery was indicated and to exclude other pathology. The presence of a locally adherent or bulky tumor should be approached with a conversion to open surgery. The liver is carefully inspected for metastatic disease. If resectable metastases are identified, we would convert to open surgery. Some surgeons are comfortable with laparoscopic removal of hepatic metastasis





**FIGURE 37-3** Position of laparoscopic instruments for right hemicolectomy. (Used with permission of Mayo Foundation for Medical Education and Research, all rights reserved.)

or choose to address at subsequent surgery. Alligator or Babcock graspers are preferred to raise each liver lobe to view all surfaces. The peritoneal surfaces should then be inspected to exclude metastases. In cases of Crohn's disease the entire small bowel should be inspected for secondary sites of disease not detected by preoperative imaging.

### STEP 3: MOBILIZATION OF THE CECUM

The patient is placed in a steep Trendelenburg position, with the right side of the table inclined upward. The 30-degree laparoscope is deployed through the LUQ port. The pelvis is viewed to ensure that the small bowel loops can be moved up into the upper abdomen; in the absence of adhesions it is often simplest to sweep the mesentery of the bowel along with the bowel into the left upper quadrant. Right lower quadrant (RLQ) adhesions are not uncommon due to the prevalence of hysterectomy, oophorectomy, and appendectomy procedures in the general population. Presence of significant adhesions in the pelvis (eg, inability to extract terminal ileum from the pelvis) is an indication for early conversion to open procedure at this point, as full exteriorization will not be possible later.

The next step is to identify the right ureter at the pelvic brim, where it runs over the bifurcation of the common iliac

artery (Fig. 37-4). In an obese patient, the ureter is identified after opening peritoneum. It is important to be patient and wait to observe peristalsis in the ureter to avoid mistaking the psoas tendon or the gonadal vessels for the ureter. The cecum is then pushed or gently grasped with a Babcock from the supra umbilical port and elevated medially and toward the head. The peritoneum around the base of the terminal ileum and the cecum is then opened with the scissors through supraumbilical port, and correct retroperitoneal plane is entered. Using a grasper on the cut peritoneal edge and not on the bowel, the right lateral peritoneal reflection is opened along the white line of Toldt toward the hepatic flexure. Care should be taken to initially divide only the superficial layer of the peritoneum. As the dissection proceeds toward the hepatic flexure, the pneumoperitoneum helps separate the tissue planes. The plane between the colon mesentery and the Gerota fascia is then developed using a combination of blunt dissection and cautery and care must be taken to avoid dissection behind the kidney.

The peritoneum on the medial side of the terminal ileum should be incised to allow full mobilization of the cecum. Upward tension should be applied on the peritoneal fold medial to the terminal ileum, and incision is made in the superficial peritoneal layer along side the pelvic brim superior and parallel to the right iliac artery. The dissection is continued up to the level of the duodenum. Then the lateral dissection is advanced medially with care until the inferior vena cava inferiorly and duodenum superiorly. These two structures indicate the achievement of sufficient dissection.

### STEP 4: MOBILIZATION OF THE HEPATIC FLEXURE

The patient is now placed in reverse Trendelenburg's position with the right side steeply inclined upward. The laparoscope is shifted into the suprapubic port and the surgeon and the assistant trade positions. The hepatocolic ligaments are grasped just cephalad to the colon and traction placed obliquely to elevate the tissues toward the anterior abdominal wall and inferiorly. The hepatocolic ligament is divided with electrocautery scissors or an ultrasonic dissector, as preferred. Blunt dissection is then performed to separate the underlying tissue from the peritoneum. Occasionally larger vessels encountered require clips. The dissection is then continued along the gastrocolic ligament, identifying the plane between this and the transverse mesorectum, until the level of falciform ligament is reached. Care should be taken during this dissection not to damage the duodenum as the hepatic flexure is mobilized off the retroperitoneum in the right upper quadrant (RUQ) (Fig. 37-5). At this point, the whole right colon is mobilized to the midline and the right retroperitoneum is exposed, allowing visualization of the duodenum, Gerota's fascia, and the right ureter.

### STEP 5: VASCULAR DIVISION

Vascular ligation and division of the mesenteric vessels can be performed either by intra- or extracorporeal method. The surgeon and the assistant are back to original positions with the

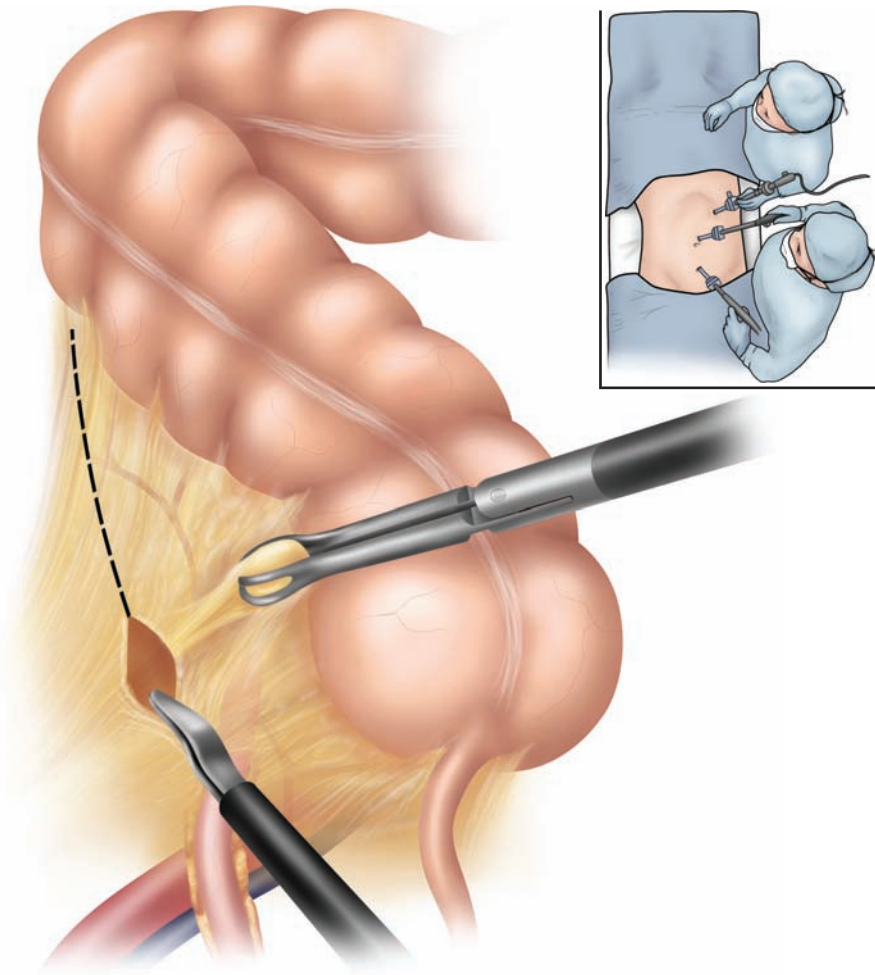


FIGURE 37-4 Mobilization of cecum. (Used with permission of Mayo Foundation for Medical Education and Research, all rights reserved.)

laparoscope placed through the LUQ port. The intracorporeal method should be used for obese patients as it is difficult to exteriorize the ileocolic pedicle. Intracorporeal ligation is preferred for the malignant diseases to ensure proximal ligation of the vessels (Fig. 37-6). Upward tension is applied on the right colon to display the ileocolic and right colic vessels, and, once mesenteric windows are created, the vessels are ligated with hemoclip, Endoloop devices (Ethicon, Cincinnati, OH), or a linear vascular stapler. It is important to visualize or palpate the junction of the ileocolic and superior mesenteric vessels to provide proximal resection of lymphatics in cancer cases without compromising blood flow to the rest of the small bowel.

#### STEP 6: EXTERIORIZATION

Once intracorporeal ligation has completed or if extracorporeal ligation has to be performed, the table is returned to a neutral position. A Babcock grasper is placed through the suprapubic port and applied to the appendix or ligament of Treves or the mesentery of the cecum. The pneumoperitoneum is vented out through the ports and the camera equipment removed. Then a small (4–6 cm) vertical incision is made for purposes of colon

exteriorization; typically it is more cephalad than caudal to the umbilicus. The wound edges are protected with a wound guard and then the bowel is exteriorized with the help of Babcock grasper left already at the level of the cecum. The right colon is exteriorized from the terminal ileum to the transverse colon (Fig. 37-7). It is generally not necessary to have divided the omentum intracorporeally as it can also be exteriorized through the incision unless it is bulky. Once the bowel is exteriorized, vascular ligation is performed in a standard manner.

#### STEP 7: ANASTOMOSIS

The mesenteric and bowel division, vascular ligation if appropriate, and anastomosis can be completed after exteriorization in an identical way to standard laparotomy. This degree of mobilization allows for a hand-sewn end-to-end anastomosis or a wide, stapled side-to-side anastomosis. Following anastomosis, the bowel is then gently returned into the abdominal cavity. Irrigation of the abdominal cavity is performed at this time. The irrigation process is conducted through the open wound and can make use of standard suction devices without the need for the laparoscopic suction

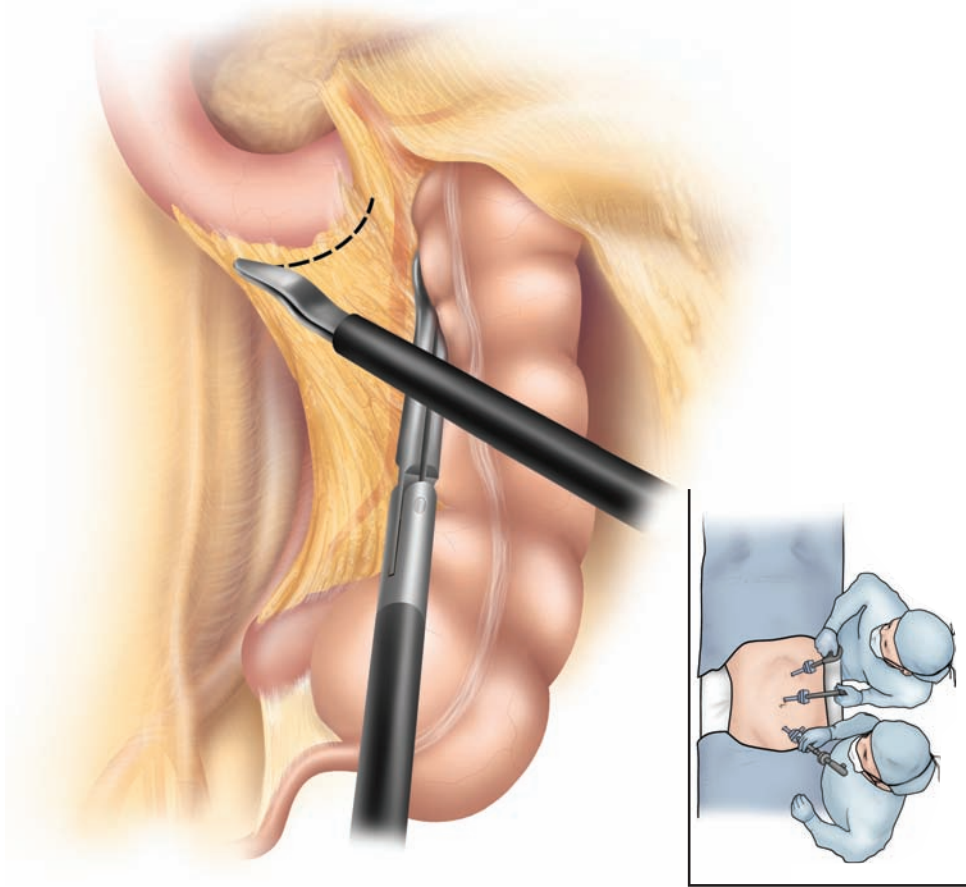


FIGURE 37-5 Mobilization of hepatic flexure. (Used with permission of Mayo Foundation for Medical Education and Research, all rights reserved.)

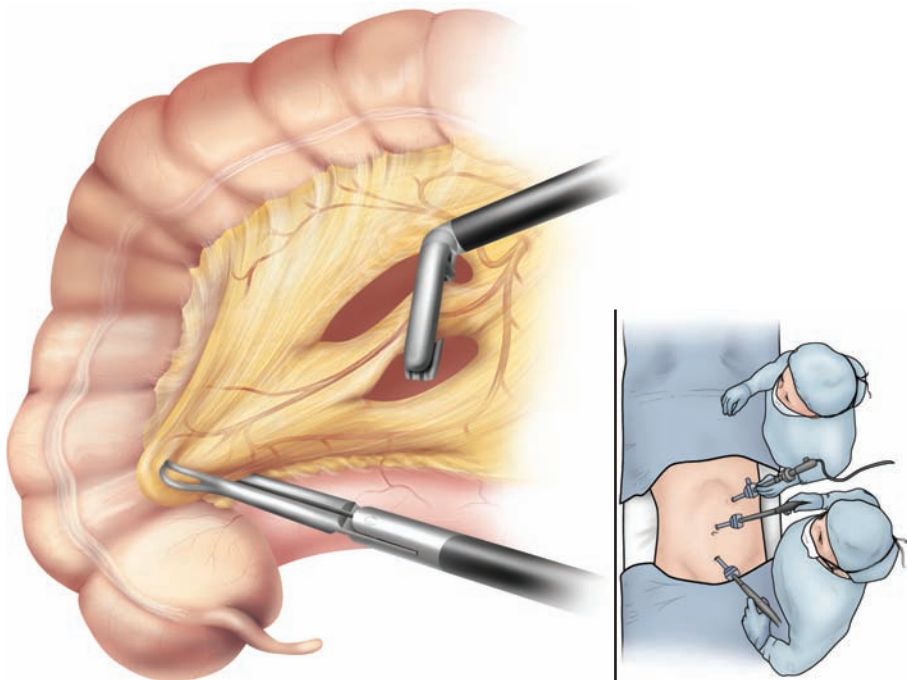


FIGURE 37-6 Intracorporeal division of vasculature of right colon. (Used with permission of Mayo Foundation for Medical Education and Research, all rights reserved.)



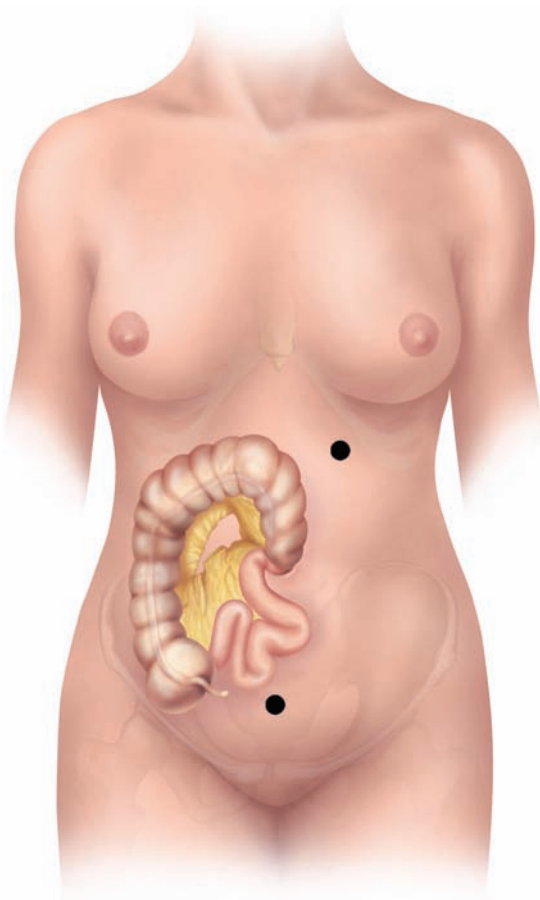


FIGURE 37-7 Exteriorization of right colon. (Used with permission of Mayo Foundation for Medical Education and Research, all rights reserved.)

irrigator equipment. The aspirate from the irrigation process is inspected to determine whether it is clear or bloody. If the aspirate is blood-stained, the abdomen may need to be reevaluated by reestablishing the pneumoperitoneum. In our experience, it is rare to have to reinspect using the pneumoperitoneum. By using Harrington-type retractor, inspection through the periumbilical incision allows for visualization of the port sites as the trocars are removed. Copious irrigation of all the wounds is then performed. The incisions are closed in two layers, fascia, and skin.

### Alternative Technique for Right Hemicolectomy

An alternative technique, in which the dissection starts from the medial aspect and extends laterally, is also practiced for right hemicolectomy. The dissection commences with the opening the peritoneum of right mesocolon. This allows for the mobilization of the colon with minimal manipulations. The right colic and ileocolic vessels are identified first and ligated using clips or vascular stapler. Then the peritoneal incision is extended superiorly toward the transverse colon, and then the dissection continues along the transverse colon inferiorly and along hepatic flexure, ascending colon and cecum medially. After the colon is freed from the peritoneal attachments on the medial side, the dissection continues along the white line of Toldt, starting from the cecum to the hepatic flexure and the transverse colon (Fig. 37-8). The right colon is

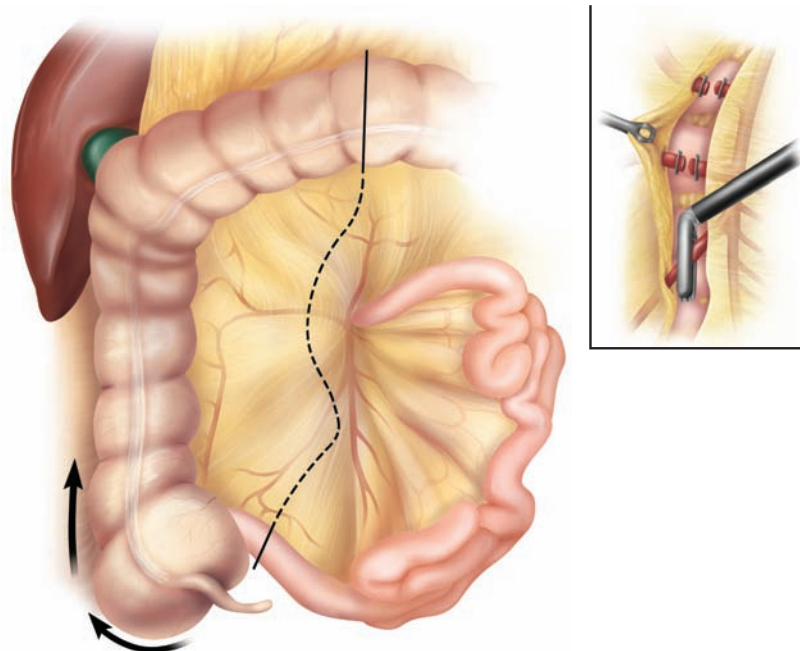


FIGURE 37-8 Alternative technique for right hemicolectomy—medial to lateral dissection. (Used with permission of Mayo Foundation for Medical Education and Research, all rights reserved.)

detached from all the attachments and it is then brought outside from the extended skin incision at the umbilicus. Then the right colon is resected extracorporeally and ileocolic anastomosis performed as described in the previously mentioned method. Although we do not practice this approach, it is gaining in popularity and seems to carry no major disadvantage.

## Left Hemicolectomy

The left hemicolectomy procedure is similar to the right colectomy, only in mirror-image reverse. One major difference is the care that must be taken around the spleen. The hand-assisted approach can facilitate management of the splenic flexure and therefore it is described as an alternative approach.

### STEP 1: PATIENT POSITION AND ROOM SETUP

Positioning and securing of the patient on the operating table is done in a similar fashion as right hemicolectomy. The surgeon and the surgical assistant stand on the right side with the monitor on the left side and parallel in-line orientation is maintained. The instrument table is accommodated at the foot of the bed and the scrub nurse on the patient's left side.

### STEP 2: PORT PLACEMENT AND EXPLORATION

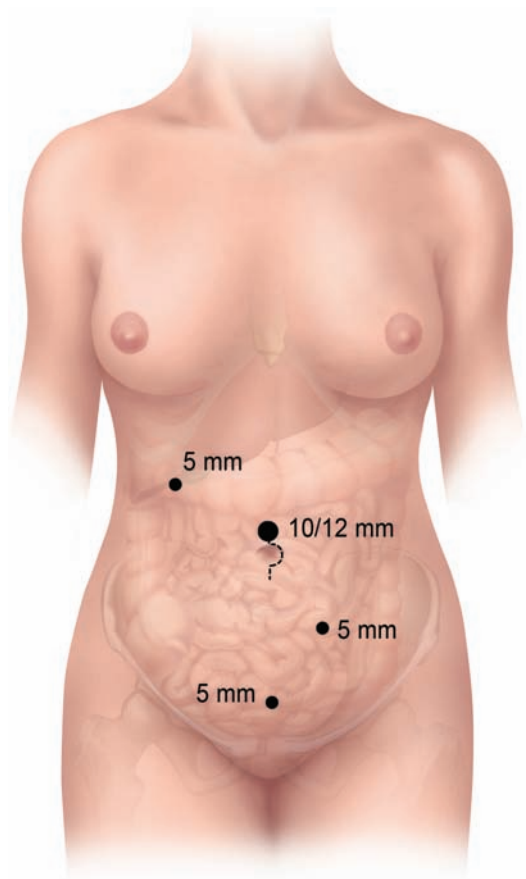
A four-port technique is used with ports in the supraumbilical area, suprapubic area, right upper quadrant, and left lower quadrant (LLQ) (Fig. 37-9). Simple adhesions encountered at this stage should be divided. Then a careful inspection should be done to confirm the pathology and any presence of additional disease. Conversion to open procedure should be made for the same conditions and indications as described for the right colectomy.

### STEP 3: MOBILIZATION OF THE LEFT COLON

The patient is placed in a steep Trendelenburg position, with the left side of the table inclined upward, and the small bowel loops are swept to the right side of the abdominal cavity using the graspers. The left ureter is identified before proceeding with the dissection. The dissection commences lateral to the proximal sigmoid colon. The peritoneum is incised and then dissected along the white line of Toldt toward the splenic flexure (Fig. 37-10). The plane is developed carefully avoiding kidney injury, between the colon mesentery and the Gerota fascia. Then the lateral dissection is advanced medially until the aorta is reached.

### STEP 4: MOBILIZATION OF THE SPLENIC FLEXURE

The patient is now placed in reverse Trendelenburg's position with the left side steeply inclined upward. The surgeon



**FIGURE 37-9** Position of laparoscopic ports for left hemicolectomy. (Used with permission of Mayo Foundation for Medical Education and Research, all rights reserved.)

standing between the legs of the patient and the assistant on the right side with in-line arrangement of camera, monitor, and the instruments provide better surgical ergonomics. The instruments are repositioned with grasper through the supraumbilical port and the cutting instrument through the left lateral port. The assistant grasps the greater omentum superior to the distal transverse colon through right lateral port and retracts upward toward the abdominal wall cranially (Fig. 37-11). With the countertraction, the surgeon incises the peritoneum and enters the lesser sac. The dissection is then advanced parallel to the transverse colon to open up the lesser sac and mobilize the transverse colon. The dissection then advanced toward the lateral dissection so that the splenic flexure is completely mobilized to the level of the umbilicus.

### STEPS 5–7: VASCULAR DIVISION, EXTERIORIZATION, AND ANASTOMOSIS

Vascular ligation and division of the mesenteric vessels are performed either by incorporeal or extracorporeal method. The colon is exteriorized through the 4- to 6-cm midline vertical incision and anastomosis is performed in a similar fashion as in right hemicolectomy.

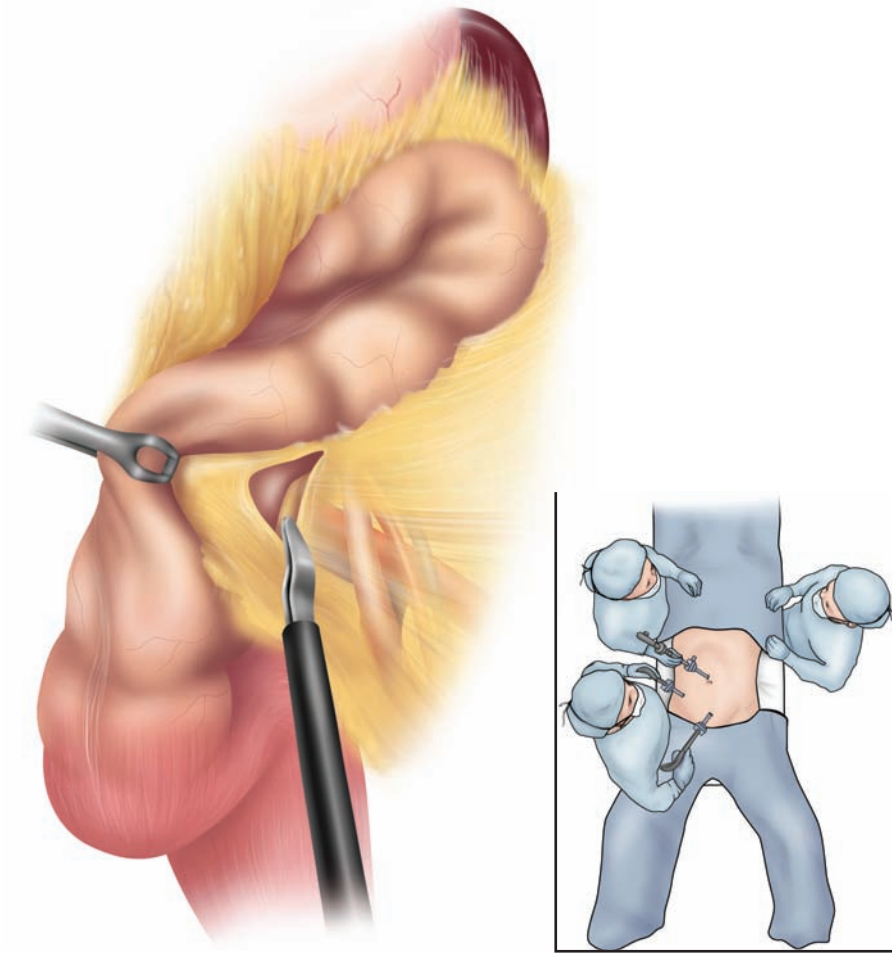


FIGURE 37-10 Mobilization of left colon. (Used with permission of Mayo Foundation for Medical Education and Research, all rights reserved.)

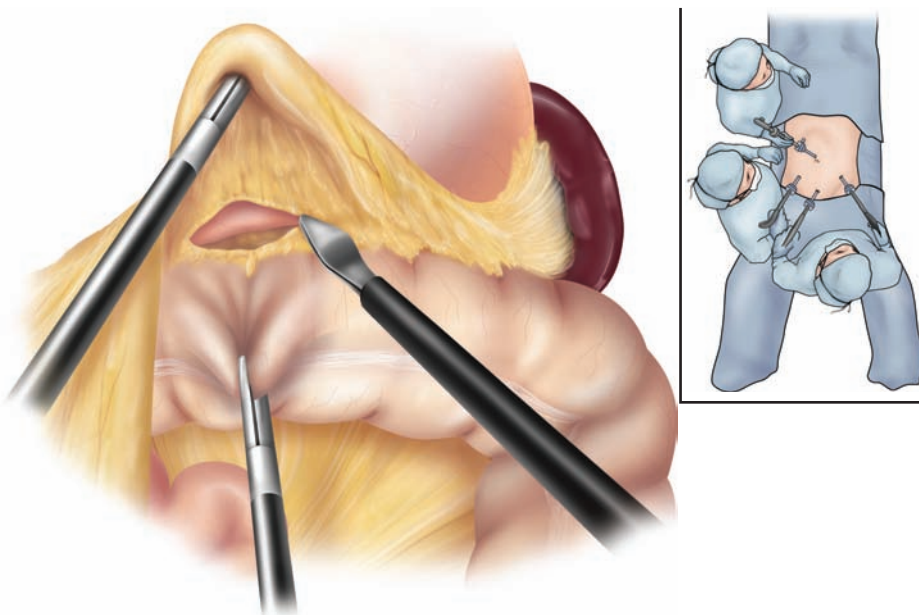


FIGURE 37-11 Mobilization of splenic flexure. (Used with permission of Mayo Foundation for Medical Education and Research, all rights reserved.)



## HAND-ASSISTED LAPAROSCOPIC SURGERY

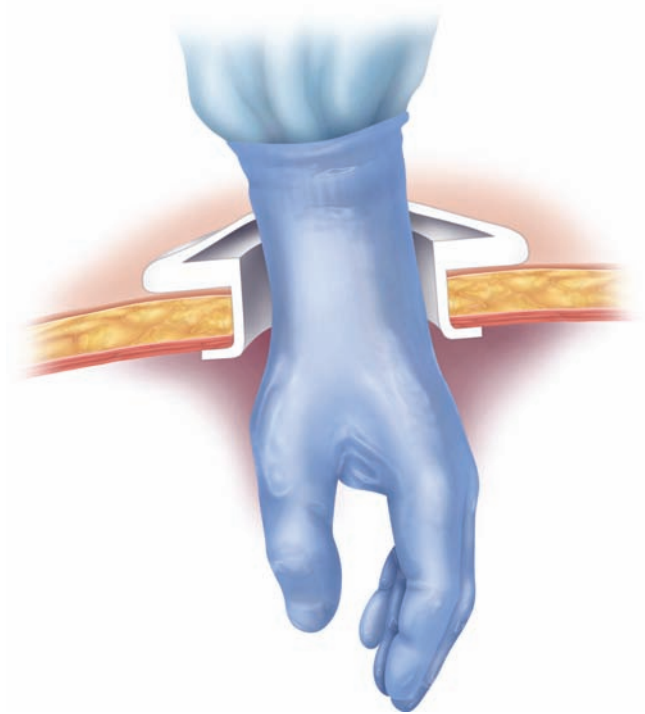
### Hand-Assisted Laparoscopic Left Hemicolectomy

#### STEP 1: PATIENT POSITION AND ROOM SETUP

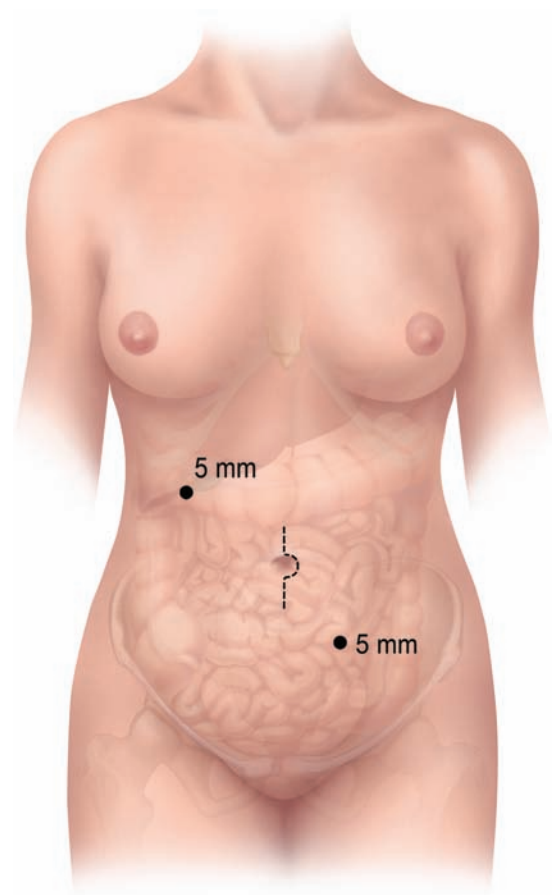
The patient is positioned and secured on the operating table in a similar fashion as for a laparoscopic-assisted procedure.

#### STEP 2: PORT PLACEMENT AND EXPLORATION

Lower midline incision is made below the umbilicus. The hand port should be placed in such a position where the nondominant hand acts like a laparoscopic retractor. The incision size should be one-half size smaller than the operator's hand size, and the incision length should remain the same through all layers of the abdomen to avoid leakage of air around the hand port (Fig. 37-12). Gelport is the new generation of multifunctional hand port that allows the usage of hand, laparoscope, and laparoscopic trocars, and maintains an airtight seal when the hand is removed. The surgeon's hand through the hand port guides the insertion of 30-degree laparoscope in the periumbilical region. A 5/10-mm port for scissors with cautery is made in the left lower quadrant under laparoscopic visualization (Fig. 37-13).



**FIGURE 37-12** Position of hand following insertion through hand port. (Used with permission of Mayo Foundation for Medical Education and Research, all rights reserved.)



**FIGURE 37-13** Position of incision for hand port and laparoscopic ports for left hemicolectomy. (Used with permission of Mayo Foundation for Medical Education and Research, all rights reserved.)

#### STEP 3: MOBILIZATION OF THE LEFT COLON AND SPLENIC FLEXURE

The traction is achieved when the hand and the colon is dissected in the similar fashion described previously for the laparoscopic hemicolectomy (Figs. 37-14 through and 37-16). A grasper can be introduced through 5-mm cannula in the right lower quadrant to achieve additional traction for adequate mobilization of the spleen.

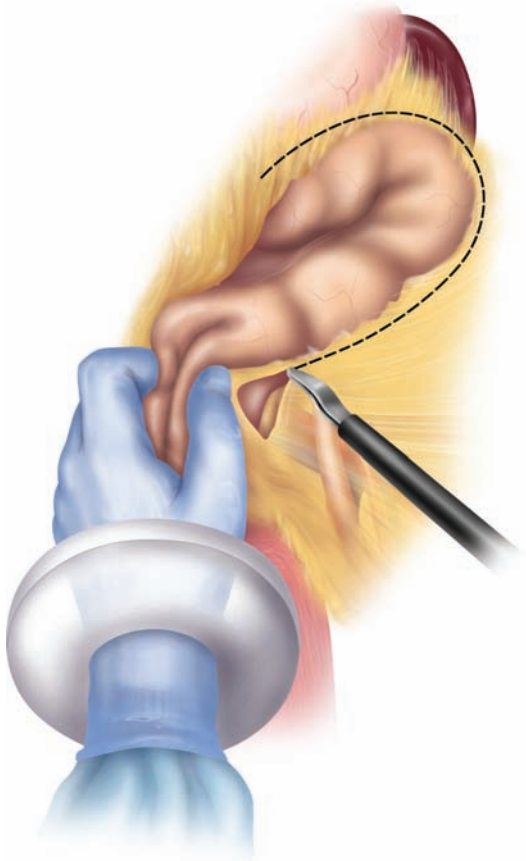
#### STEPS 4–6: VASCULAR DIVISION, EXTERIORIZATION, AND ANASTOMOSIS

Vascular ligation and division of the vessels is typically performed using intracorporeal techniques. The colon is exteriorized through the hand port and divided, and anastomosis is performed with either hand-sewn technique or standard stapled method.

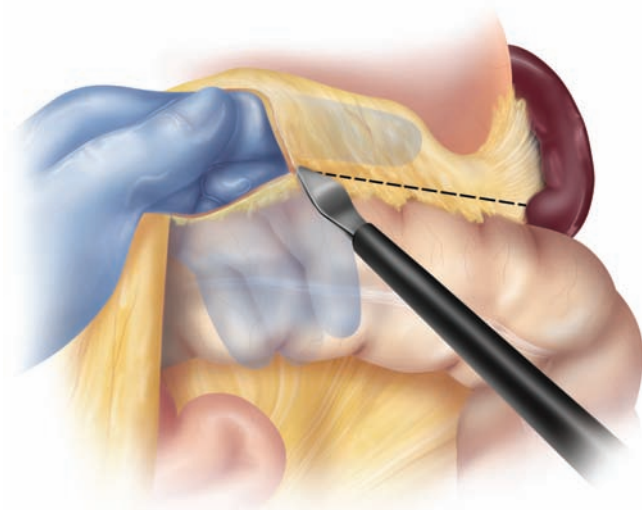
#### SIGMOID COLECTOMY:

##### STEP 1: PATIENT POSITION

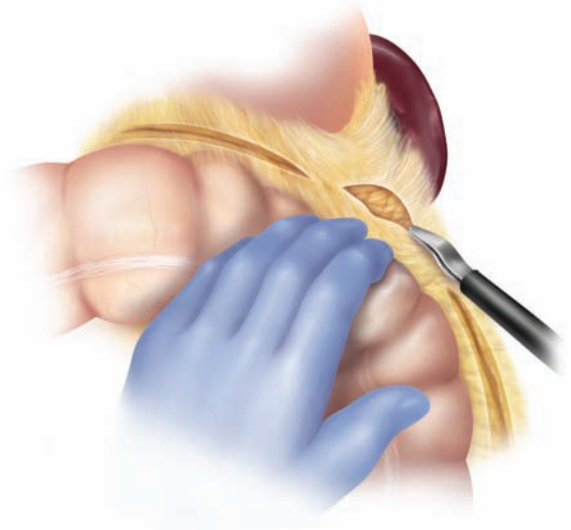
The patient is placed and secured on the operating table in modified lithotomy position same as for left hemicolectomy.



**FIGURE 37-14** Hand-assisted mobilization of left colon. (Used with permission of Mayo Foundation for Medical Education and Research, all rights reserved.)



**FIGURE 37-15** Hand-assisted mobilization of splenic flexure—omental attachments. (Used with permission of Mayo Foundation for Medical Education and Research, all rights reserved.)



**FIGURE 37-16** Hand-assisted mobilization of splenic flexure. (Used with permission of Mayo Foundation for Medical Education and Research, all rights reserved.)

The surgeon and the surgical assistant stand on the right side of the patient, and the camera, trocars, and the monitor are aligned parallel to minimize reverse image operating.

#### STEP 2: PORT PLACEMENT AND EXPLORATION

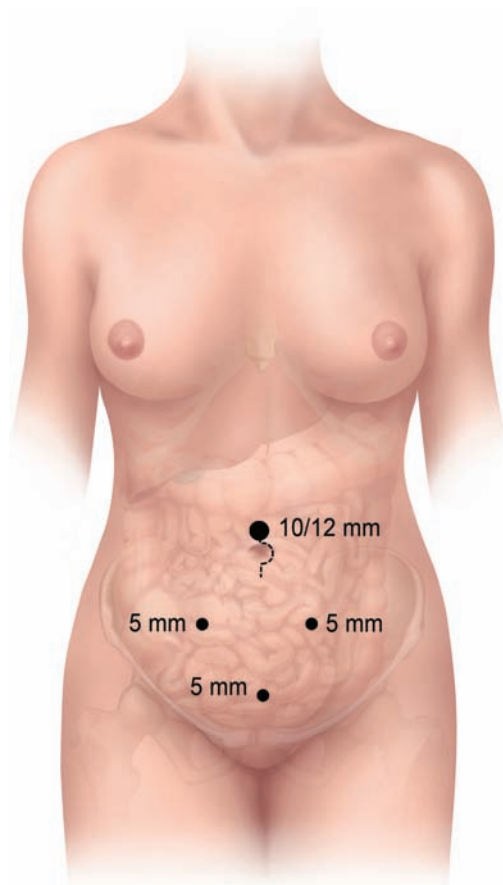
The laparoscope is inserted through the supraumbilical port and the trocars are placed under visualization in suprapubic, right, and left lower lateral positions (Fig. 37-17). The abdominal cavity should be inspected with confirmation of the indicated pathology and other pathology excluded, as previously described.

#### STEP 3: MOBILIZATION OF THE PROXIMAL SIGMOID AND DESCENDING COLON

The patient is placed in steep Trendelenburg's position with the left side of the table inclined upward. The 30-degree laparoscope is deployed through the supraumbilical port and the small bowel loops are swept to the right side. The left ureter is identified at the pelvic brim. Conversion to an open procedure is necessary if the ureter cannot be identified confidently. The ureter is swept down and away in order to avoid injury during ligation of the mesenteric vessels. The dissection commences lateral into the left ureter by incising peritoneum lateral to the sigmoid colon. The dissection continues along the white line of Toldt toward the splenic flexure in the same manner as done for left hemicolectomy. Mobilization of splenic flexure is performed as required.

#### STEP 4: MOBILIZATION OF THE DISTAL SIGMOID COLON AND UPPER RECTUM

After mobilizing the descending colon completely, the dissection is now directed caudally. With the retraction of the

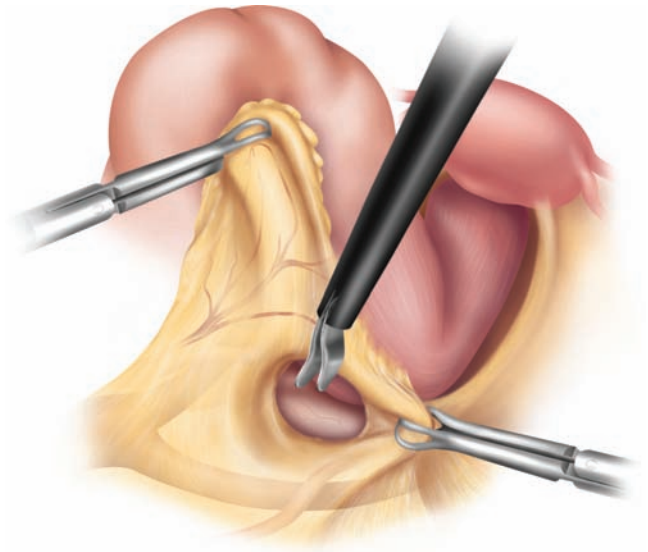


**FIGURE 37-17** Position of laparoscopic ports for sigmoid colectomy and anterior resection. (Used with permission of Mayo Foundation for Medical Education and Research, all rights reserved.)

sigmoid colon cephalad and medially, the peritoneal incision is then extended distally to the midrectum entering the presacral space. The left ureter and the iliac vessels are identified and protected throughout this part of the procedure (Fig. 37-18). The presacral space is developed by the division of the fine adhesions and care should be taken to protect hypogastric nerves by sweeping them backward toward the sacrum.

#### STEPS 5 AND 6: VASCULAR LIGATION AND EXTERIORIZATION

The sigmoid colon is elevated anteriorly and inferiorly to expose the mesenteric vessels. Then incision is made in the avascular plane on both sides of the vessels. The superior hemorrhoidal and sigmoid vessels are isolated and ligated at the level of aortic bifurcation using vascular staplers, clips, or Endoloop devices (Fig. 37-19). We ligate just distal to the takeoff of the left colic vessel. Some surgeons express a preference for ligation at the origin of the inferior mesenteric artery, proximal to the left colic branch. The sigmoid becomes more mobile after the ligation of the vascular pedicle. The upper rectum is then divided using a linear cutting stapler (Fig. 37-20).

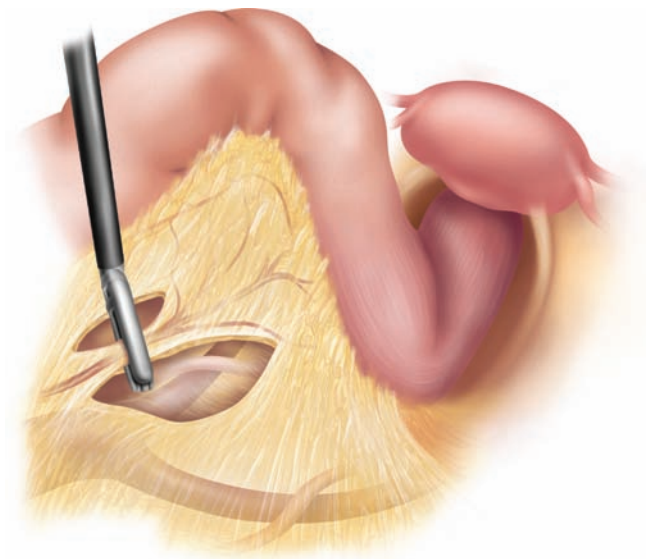


**FIGURE 37-18** Mobilization of upper rectum. (Used with permission of Mayo Foundation for Medical Education and Research, all rights reserved.)

Then the pneumoperitoneum is vented out via the laparoscopic ports. The divided sigmoid colon is brought out through the extension of the LLQ incision. The proximal colon is divided at the sigmoid and descending colon junction.

#### STEP 7: ANASTOMOSIS

A purse-string suture is inserted around the colon that is tied around the anvil of the stapler inserted into the lumen. Then the colon is returned to the abdominal cavity. The peritoneal



**FIGURE 37-19** Intracorporeal vascular division of superior hemorrhoidal and sigmoidal vessels. (Used with permission of Mayo Foundation for Medical Education and Research, all rights reserved.)



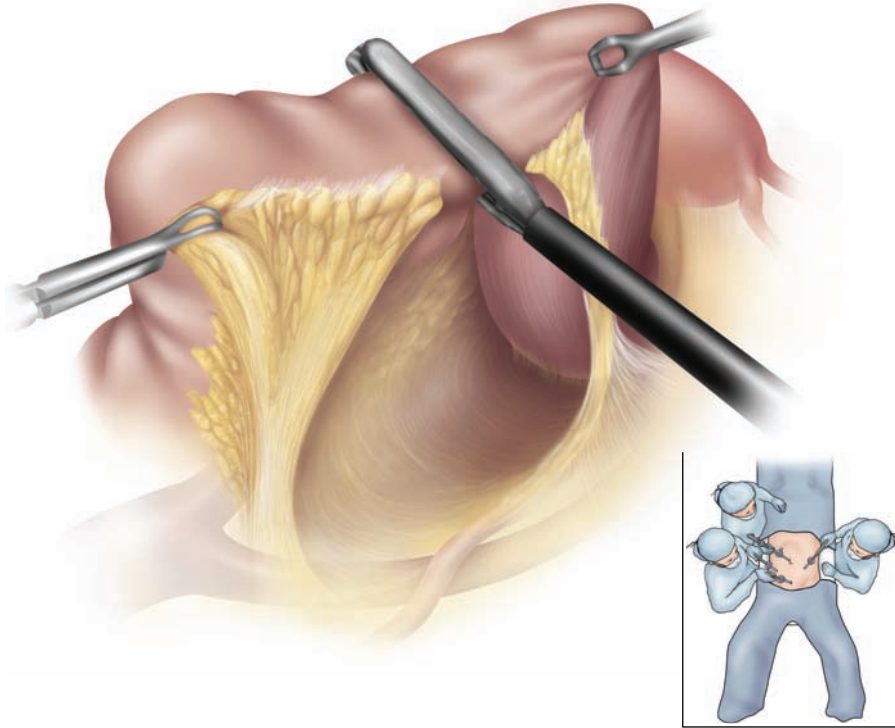


FIGURE 37-20 Division of upper rectum with linear stapler. (Used with permission of Mayo Foundation for Medical Education and Research, all rights reserved.)

cavity is irrigated and checked for blood, and the fascial defects are closed. After the reinsufflation of the abdominal cavity, the stapling device is introduced through the anus. The anvil attached to the shaft of the stapling device is advanced across the staple line under direct visualization. The anvil is attached to the gun, approximating the bowel ends, and then the device is fired. The anastomotic integrity and hemostasis can then be assessed using a proctoscope. The pneumoperitoneum is released after withdrawing cannulas under direct visualization.

The alternative approach is to perform a hand-sewn anastomosis through a small lower midline incision of 5–6 cm. After bowel exteriorization, the bowel is excised and end-to-end anastomosis is performed, taking care to ensure proper alignment of the mesentery.

## Hand-Assisted Laparoscopic Sigmoidectomy

The patient is positioned in the same way as for the laparoscopic-assisted approach. The hand port is placed in the lower midline incision in the lower abdomen 1 cm above the pubic symphysis. The incision size should be one half-size smaller than the surgeon's hand to maintain effective pneumoperitoneum. Then the surgeon's left hand in the gel port guides the placement of other trocars. A 30-degree laparoscope is placed in the supraumbilical port and cautery attached to the scissors is placed in the RLQ port. The surgeon, standing on the left side of the patient, uses the left hand to provide retraction of

the sigmoid colon while the cautery is operated with the right hand. The diseased specimen is extracted through the incision made for the hand port, and extracorporeal division of the vasculature can be performed. The anastomosis is made using the stapling device in the same manner as described previously. The pneumoperitoneum is reinstated, and the abdominal cavity is irrigated and inspected for hemostasis. Then the anastomotic site is inspected for leakage. Normal saline is placed in the abdomen and pelvis such that the anastomosis is submerged. A noncrushing clamp is placed proximal to the anastomosis and the rectum is then insufflated using a flexible sigmoidoscope. If bubbles are detected, either the anastomosis needs to be repaired at the site of the leak or the case needs proximal diversion with an ileostomy. Then the abdomen is closed after venting out the pneumoperitoneum.

## Transverse Colectomy

### STEP 1—PATIENT POSITION AND ROOM SETUP

The patient is placed and secured well on the operating table in supine or modified lithotomy position, depending on whether the pathology is closer to the right or left colon, respectively.

### STEP 2: PORT PLACEMENT AND EXPLORATION

The laparoscope is inserted through the supraumbilical port, and two cannulas are inserted in the right and left lower quadrants under direct visualization. The surgeon shifts sides

depending on the mobilization of the hepatic flexure or the splenic flexure.

### STEP 3: MOBILIZATION OF THE HEPATIC FLEXURE

Dissection and mobilization of the hepatic flexure is performed as described under right hemicolectomy.

### STEP 4: MOBILIZATION OF THE SPLENIC FLEXURE

Dissection and mobilization of the splenic flexure is performed as described under left hemicolectomy.

### STEP 5: MOBILIZATION OF THE TRANSVERSE COLON

The stomach is lifted up, and with retraction of transverse colon downward the omentum is divided. Thus transverse colon is freed from its attachments on either side.

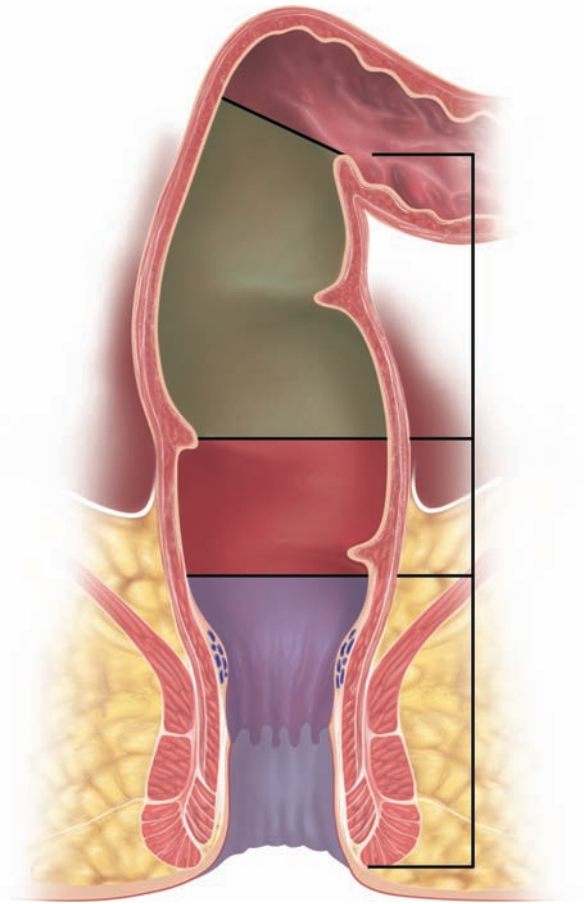
### STEPS 6–8: VASCULAR DIVISION, EXTERIORIZATION, AND ANASTOMOSIS

The vascular pedicle is divided intracorporeally, and the mobilized transverse colon is exteriorized through the extended incision in the supraumbilical area. Care should be taken around the vascular pedicle of the transverse colon. The middle colic vessels are quite short, and the vein branches easily tear and cause difficult bleeding. Too much traction on these vessels can result in disruption of venous branches and significant bleeding. The bowel is then divided and anastomosis of the free ends is done with hand-sewn technique or standard stapled technique.

## TECHNICAL PROCEDURES FOR RECTAL DISEASES

Anterior resection, or sometimes referred to as a high anterior resection, is a surgical procedure used for resection of tumors or pathology present in the proximal rectum or distal sigmoid (>12 cm from the anal verge). In contrast to the anterior resection, the low anterior resection is used to treat tumors or pathology in the mid- to distal rectum, and an ultralow anterior resection is a sphincter-preserving approach where the anal canal is spared and a coloanal anastomosis or ileal J-pouch anastomosis is performed. APR is a two-part procedure that involves an abdominal and pelvic procedure where the rectum and colon is mobilized along with a perineal procedure where the rectum and the anus are resected. With this procedure, the patient is left with a permanent colostomy. An APR is required for tumors within 1 cm of the top of the anal canal (Fig. 37-21).

Rectopexy, or repair of rectum, is typically combined with sigmoid resection but can be performed by itself for



**FIGURE 37-21** Levels of resection in rectal surgery—anterior resection, low anterior resection (LAR), coloanal, and abdominal perineal resection (APR). (Used with permission of Mayo Foundation for Medical Education and Research, all rights reserved.)

treatment of rectal prolapse. We typically perform a sigmoid resection and colorectal anastomosis; also, we secure the lateral parts of the rectum to the presacrum to generate additional fixation.

## Anterior Resection

### STEP 1: PATIENT POSITION AND ROOM SETUP

The patient is placed in modified lithotomy position or synchronous position and securely strapped to the operating table. The setup is similar to that for sigmoid colectomy.

### STEP 2: PORT PLACEMENT AND EXPLORATION

A four-port technique is used in which trocars are positioned at supraumbilical, suprapubic, and right and left lower quadrants. The abdomen is inspected to confirm the pathology and rule out metastases. Estimation of lower margins of the rectum and the pathology is crucial to decide the procedure in advance of conducting the operation.

### STEP 3: MOBILIZATION OF THE LEFT COLON AND SIGMOID COLON

The dissection of the left colon and the sigmoid colon is carried out in the similar fashion as explained in the sigmoid resection.

### STEP 4: VASCULAR LIGATION

For cancers, the vascular pedicle needs to be taken proximal, incorporating at least the superior hemorrhoidal and sigmoidal vessels. A vascular stapler, LigaSure, or a Harmonic scalpel can be utilized for intracorporeal ligation. Both ureters should be visualized and moved out of harm's way prior to vascular pedicle ligation. The left ureter courses close to the sigmoidal and hemorrhoidal vessel in the retroperitoneum above the pelvic brim. For nononcologic pathologies, vessels can be ligated at more distal locations. Extracorporeal ligation of the vessels is an alternative if adequate exposure can be obtained through the extraction site.

### STEP 5: MOBILIZATION OF THE RECTUM

After vascular ligation, the presacral space is entered to start the dissection of the rectum. The ureters should be identified to avoid injury to them. Presacral nerves are carefully protected by gently sweeping them down and away from the dissection plane. The dissection continues laterally on either side until it meets posteriorly developing a presacral plane (see Fig. 37-18). The rectum is mobilized by creating a plane anteriorly between the rectum and seminal vesicles and prostate in men and between rectum and posterior vaginal wall in women. Complete mesorectal excision along with distal and circumferential clearance is the key factor for achieving complete oncologic resection. For cancers, the level of rectum for the site of transection is marked using ink tattoo preoperatively and this is visualized at the time of the surgery with endoscopy. The level of transection is typically identified and tattooed before starting neoadjuvant chemoradiation for patients requiring it.

### STEP 6: EXCISION OF THE RECTUM AND EXTERIORIZATION

The rectum is excised at the marked position with the linear stapler gun (see Fig. 37-20) and then the specimen is extracted out through the extended incision in the supraumbilical region. Then the proximal end of the specimen is dissected extracorporeally and the remaining colon reintroduced with the anvil of the stapler gun held by the purse-string sutures.

### STEP 7: ANASTOMOSIS

The anastomosis is performed in a fashion similar to what was described for sigmoid colectomy and low anterior resection using the circular stapler. The integrity of the anastomosis is always checked prior to closing the abdomen. Conversion is

rarely needed when the anastomosis is at this high level and is typically reserved for circumstances where the tissue is of poor quality.

## Low Anterior Resection

### STEP 1: PATIENT POSITION AND ROOM SETUP

The patient is placed in the combined synchronous or modified lithotomy position and secured well on the operating table. The thighs can be kept more at the level of abdominal wall to avoid interference with the laparoscopic instruments used in the lower ports. The surgeon stands on the right side of the patient and faces toward the left lower quadrant of patient. The surgeon may have to shift to between the patient's legs if mobilization of the splenic flexure is required. The surgeon's assistant stands on the right while the scrub nurse on the left. The camera positioned to the left of patient's hips in the beginning is moved cephalad as the mobilization of the sigmoid colon and descending colon continues.

### STEP 2: PORT PLACEMENT AND EXPLORATION

A 30-degree laparoscope is introduced through the supraumbilical position. Under direct visualization, three 5-mm trocars are in suprapubic position, right lower lateral quadrant, and left lower lateral quadrant positions (see Fig. 37-17). Lower quadrant trocars are inserted lateral to the epigastric vessels.

### STEP 3: MOBILIZATION OF THE LEFT COLON

The patient is placed in the steep Trendelenburg position with the left side of the abdomen inclined upward. The peritoneum lateral to the sigmoid colon is grasped and pulled medially to expose the left peritoneal reflection, which is then opened along the white line of Toldt using cautery or scissors. The left ureter is identified at the base of the sigmoidal fossa on the medial aspect. Remaining in the correct retroperitoneal plane exposes Gerota's fascia and left ureter. Care should be taken to avoid injury to the ureter and left kidney. Depending on the need for splenic flexure mobilization, the dissection can be extended further cephalad at this moment. Mobilization of the splenic flexure is performed as described earlier in the Left Hemicolectomy section.

### STEP 4: VASCULAR PEDICLE LIGATION

By scoring the right and perirectal peritoneum on a cephalad direction, the origin of superior hemorrhoidal and sigmoidal vessels can be exposed. The window in the mesentery on either side of the vessels is identified and developed. After ensuring that both ureters are not in the field, the vascular pedicle at the level of superior hemorrhoidal and sigmoidal vessels can be divided at the level of aortic bifurcation or just below the takeoff of the left colic vessels. The vascular stapler,



Harmonic scalpel, or LigaSure can be used according to the comfort of the surgeon.

### STEP 5: MOBILIZATION OF THE RECTUM

During oncologic resection, care should be taken to avoid penetration of the mesorectal fascia. With the left side of the table inclined upward, the rectum is retracted anteriorly and right, and the left lateral dissection of the sigmoid is continued along the left lateral aspect of the rectum. The proximal aspect of the presacral space is exposed, which can be partially entered and developed. The operating table is now positioned with the right side inclined slightly upward. Retraction of the sigmoid colon and proximal rectum anteriorly, the right perirectal area is open and further retraction on the peritoneum allows for creating the presacral space. The presacral space is now developed with sharp dissection to the pelvic floor. Care should be taken to identify and protect the hypogastric nerves; they should be gently swept down toward the sacrum. The right presacral plane is opened to meet the left presacral plane. The rectum is then elevated anteriorly with sufficient traction that the presacral plane can be developed as far distally as needed to achieve at least 4 cm of distal mesorectal and 2 cm of distal bowel clearance below the tumor. It is generally necessary to work from the posterior section to the lateral section and anterior section and then again going deeper to all, repeating the steps until the dissection is carried well below the tumor. The anterior dissection should include the Denonvilliers fascia in cases of cancer. We would go above the peritoneal reflection anteriorly and take the anterior peritoneal reflection with the specimen. The lateral stalks would typically need to be divided to facilitate deep exposure of the

pelvis and mobilization of the rectum for any tumors that present below the upper rectum.

Once the dissection is carried to levators, endoscopy can confirm the optimal level of rectal and mesorectal transection.

### STEP 6: EXCISION OF THE RECTUM

The mesorectum can be divided with a LigaSure or Harmonic scalpel. A stapler is required to transect the rectum. The introduction of the stapler typically occurs through a small suprapubic incision or the hand port. The dissected rectum can be divided intracorporeally with a laparoscopic articulating linear stapler at both the ends. The resected specimen is then extracted out through the supraumbilical incision. Of note, it is also feasible to transect the distal rectum with a TA stapler, introduced through a small suprapubic incision that can be used later for specimen extraction (Fig. 37-22).

### STEP 7: ANASTOMOSIS

A purse-string suture is placed in the proximal resection margin and the anvil is tied around the margin of the colon. Then the proximal colon with the anvil is returned to the abdomen. Then the incision is closed and the pneumoperitoneum is reestablished. The circular stapler is inserted through the anus, and the anvil attached to the shaft of the stapling device is advanced across the staple line under direct visualization (Fig. 37-23). The anvil of the proximal colon is attached to the stapler, approximating the bowel ends and then the device is fired under direct visualization. Then the abdomen is irrigated with saline and hemostasis ensured. The anastomosis is checked for any leaks by filling the pelvis

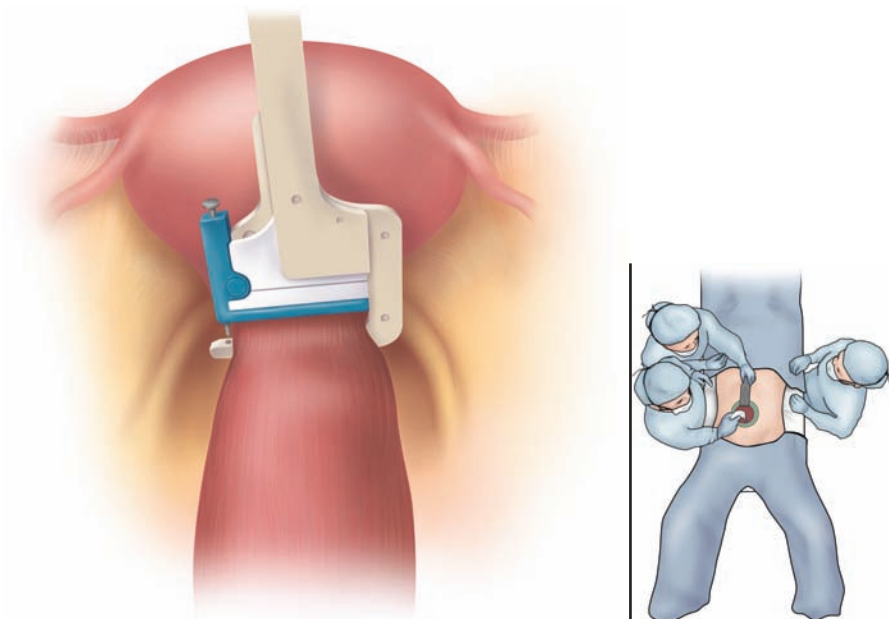
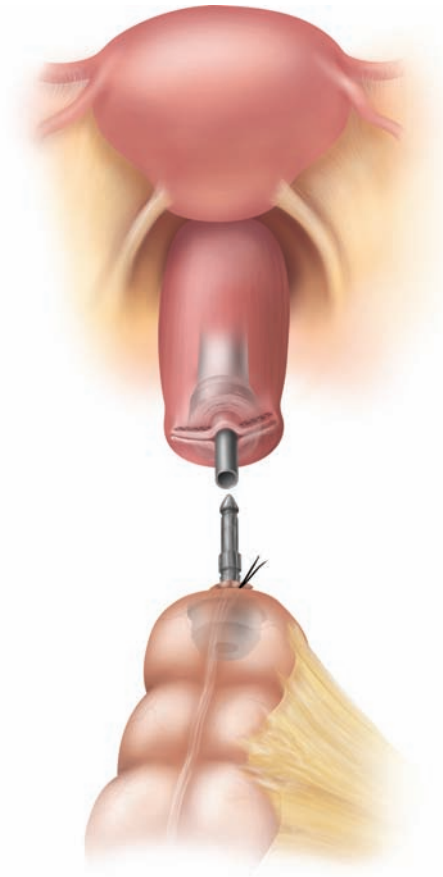


FIGURE 37-22 Division of lower rectum with transverse stapler. (Used with permission of Mayo Foundation for Medical Education and Research, all rights reserved.)



**FIGURE 37-23** Colorectal anastomosis. (Used with permission of Mayo Foundation for Medical Education and Research, all rights reserved.)

with saline, insufflating the rectum with air from the flexible scope, including the proximal colon with an alligator clamp, and observing for any air bubbles. If there is evidence of a leak, that area should be reinforced with sutures or diversion created. The pneumoperitoneum is vented out and the port sites are closed as described previously.

### Hand-Assisted Laparoscopic Low Anterior Resection

The patient is positioned in the same way as for the laparoscopic procedure. A 6- to 8-cm lower midline longitudinal incision is made to accommodate the hand port. The incision size should be a half-size smaller than the surgeon's hand to maintain effective pneumoperitoneum. Then the surgeon's left hand in the gel port guides the placement of other trocars. A 30-degree laparoscope is placed in the supraumbilical port and cautery attached to the scissors is placed in the RLQ port. The surgeon's left hand provides retraction of the sigmoid colon and the rectum to aid in the dissection. The vessels are divided intracorporeally with the help of LigaSure or vascular stapler. After a clear plane is developed around the rectum, the

rectum is divided with the linear TA stapler at the marked site. The rectosigmoid along with the mesorectum is extracted out through the incision made for the hand port. The coloanal anastomosis is performed using the circular stapling device in the same manner as detailed for the laparoscopic procedure above. Then the anastomotic site is checked for any leakage before closing of the abdomen.

## Laparoscopic Abdominal Perineal Resection

### STEP 1: PATIENT POSITION AND ROOM SETUP

Preoperative marking of the stoma site is essential to ensure proper stomal positioning and optimal postoperative care and function. The patient is placed in a modified lithotomy position and securely strapped. The surgeon stands on the right side of the patient initially during sigmoid and left colon dissection and later moves toward the patient's left side for majority of the rectal dissection. The monitor should be positioned according to the position of the surgeon. Using two monitors can alleviate the problem of repositioning the monitor during surgeon relocation.

### STEP 2: PORT PLACEMENT AND EXPLORATION

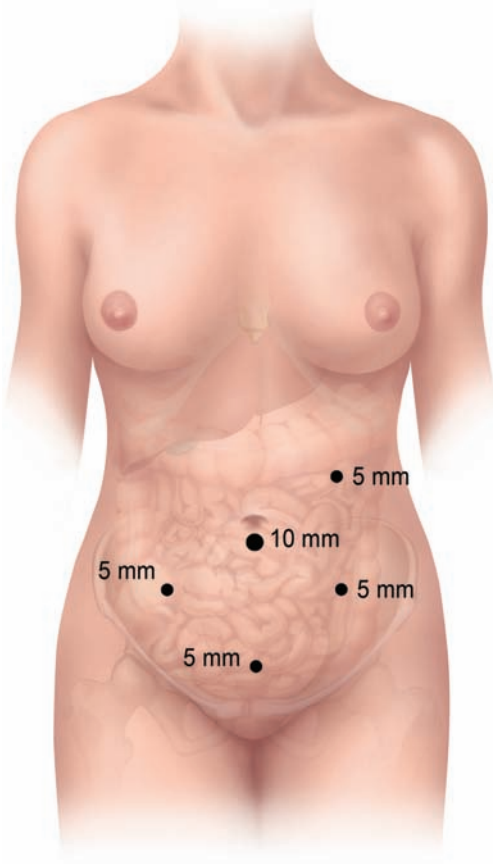
The use of five ports offers more flexibility in doing an abdominal perineal resection (APR). A 30-degree laparoscope is introduced through infraumbilical trocar. One of the trocars is introduced at the stoma site marking, while the other three trocars are inserted in the right upper, right lower, and left lower quadrants (Fig. 37-24). Using 10-mm trocars allow the surgeon to transfer the laparoscope to other ports to get better access in the procedure. Inspection of the abdomen is carried out to confirm the pathology.

### STEP 3: VASCULAR LIGATION

The origin of the superior hemorrhoidal and sigmoidal vessels can be exposed by scoring the right and perirectal peritoneum in the cephalad direction. After the window in the mesentery on either side of the vessels is developed and it is ensured that both ureters are not in the field, the vascular pedicle at the level of superior hemorrhoidal and sigmoidal vessels can be divided at the level of aortic bifurcation or just below the takeoff of the left colic vessels as described for the anterior resection.

### STEP 4: MOBILIZATION OF THE SIGMOID COLON AND THE RECTUM (ABDOMINAL PORTION)

The mobilization of the sigmoid colon and the rectum is performed as described in low anterior resection. During oncologic resection, care should be taken to avoid penetration of the rectum or the mesorectal fascia. With the left side of the table inclined upward, the rectum is retracted anteriorly and



**FIGURE 37-24** Position of laparoscopic ports for abdominal perineal resection (APR). (Used with permission of Mayo Foundation for Medical Education and Research, all rights reserved.)

right, and the left lateral dissection of the sigmoid along the white line of Toldt is continued along the left lateral aspect of the rectum. Then the left ureter should be identified at the base of the sigmoidal fossa. The proximal aspect of the presacral space is exposed, which can be partially entered and developed (see Fig. 37-18). The operating table is now positioned with the right side inclined slightly upward. Retraction of the sigmoid colon and proximal rectum anteriorly, the right perirectal area is open and further retraction on the peritoneum allows for creating the presacral space. The presacral space is now developed with sharp dissection to the pelvic floor. Care should be taken to identify and protect the hypogastric nerves; they should be gently swept down toward the sacrum and to identify the ureters. The rectum is then elevated anteriorly with sufficient traction that the presacral plane can be developed as far distally as needed to achieve at least 4 cm of distal mesorectal and 2 cm of distal bowel clearance below the tumor. It is generally necessary to work from the posterior section to the lateral section and anterior section and then again going deeper to all, repeating the steps until the dissection is carried well below the tumor. The anterior dissection should include the Denonvilliers fascia in cases of cancer.

We would go above the peritoneal reflection anteriorly and take the anterior peritoneal reflection with the specimen. The lateral stalks should be divided to facilitate deep exposure of the pelvis and mobilization of the rectum for any tumors that present below the upper rectum. Then the mesorectum is divided at the chosen level with the ultrasonic scissors. The rectal dissection is now performed anteriorly without drifting away from the mesorectal plane into the seminal vesicles and prostate or the vagina anteriorly.

#### STEP 5: PERINEAL RESECTION

The perineal dissection is performed as for conventional APR. A purse-string suture is used to close the diamond-shaped perianal incision that is created just outside the sphincter complex to include the sphincters in the specimens. The dissection of the ischial rectal fat is carried out posteriorly all the way to level of levators. Next, the anterior fat is divided in a similar fashion. Using the tip of the coccyx as a guide, a scissors is brought just anterior to the tip of the coccyx and placed into the pelvis and spread. Withdrawing the scissors in a spread position creates a common hole between the pelvis and the perineum. A finger then can be placed along the left levator and the levators divided on both the left and right sides. Hemostasis is achieved with the cautery and suture ligation as need be. The resulting defect in the pelvic floor is typically large enough that the rectum can be brought out from the abdomen and pelvis through the posterior perineal wound.

#### STEP 6: EXTERIORIZATION OF THE SPECIMEN AND WOUND CLOSURE

Anterior levators are divided on both sides along the edge of the everted rectum. Care must be taken to avoid inadvertently creating a defect in the rectum in cases of cancer. Last, the direct anterior dissection is completed and here we would avoid any excessive use of cautery in the male in particular. The urethra is quite close to the rectal dissection and it is highly sensitive to heat. A delayed urethral leak will occur if excessive heat is applied during the anterior dissection. Finally, the rectum is extracted out through the perineal wound. The perineal wound is closed in sequential layers with absorbable sutures leaving closed-suction drains either from the abdomen down to the pelvis or, if preferred, through the perineum. The drains are clamped and pneumoperitoneum can be recreated. The descending colon is inspected to ensure that it is not twisted or rotated on its mesentery as it is going to be used for the colostomy.

#### STEP 7: COLOSTOMY

The distal end of the colon is now brought to the colostomy orifice using a grasper. At least 3 cm of colon is extracted out through the skin and the colostomy is matured in a Brooke fashion by inverting the bowel wall so that the stoma is slightly raised above the skin.



## Hand-Assisted Laparoscopic Abdominal Perineal Resection

The abdominal portion of the procedure is assisted using the hand port. The sigmoid colon and the rectum are mobilized as detailed previously for the low anterior resection. The perineal resection is performed as for conventional APR.

## LAPAROSCOPIC RECTOPEXY

### Resection Rectopexy

This procedure is essentially the same as for anterior resection with the exception being the addition of presacral fixation.

#### STEP 1: PATIENT POSITION AND ROOM SETUP

The patient is placed in the modified lithotomy position and carefully positioned and strapped on the operating table. The surgeon and the assistant stand on the right side of the patient, while the monitor is placed on the patient's left side in the caudal end.

#### STEP 2: PORT POSITION AND EXPLORATION

A 30-degree laparoscope is introduced through the 10/12-mm subumbilical port. A careful inspection of the liver, small bowel, and the peritoneal surfaces is performed. Under direct visualization, three ports are made in right lower, right upper, and left lower quadrants.

#### STEP 3: VASCULAR LIGATION

The table is now positioned with left side and feet upward, and then the bowel loops are swept to the right side of the abdomen to make the operative field clear. The retroperitoneal structures are dissected to identify the sigmoidal and superior hemorrhoidal vessels and ureters. Because this procedure is indicated for benign cases, the vascular ligation can be performed more distally. The nerves should be spared and the ureters identified. The mesentery can be taken close to the bowel if surgeon attempts to preserve the vascular pedicle.

#### STEP 4: MOBILIZATION OF THE RECTOSIGMOID

The sigmoid colon is mobilized by developing a plane between the mesentery and the sigmoid colon. The rectosigmoid junction is drawn toward the patient's right side and the lateral attachments are divided. The dissection of the descending colon should be kept as minimal as possible.

#### STEP 5: MOBILIZATION OF THE RECTUM

The rectum is mobilized in the similar fashion as detailed in low anterior resection with some modifications. To minimize

chances of rectal prolapse recurrence (particularly in patients presenting with early-onset prolapse), we would dissect the rectum all the way to the levators. Although we favor transection of the lateral stalks, this should be at the discretion of surgeon and based on factors of risk of recurrence versus risk of pelvic floor dysfunction. To not divide the rectal stalk puts the patient at a higher risk of recurrent prolapse. However, to transect both rectal stalks makes the patient at least theoretically at risk for more pelvic floor dysfunction and also removes a source of blood supply (ie, the middle hemorrhoidal). We typically preserve the superior hemorrhoidal and then transect the lateral stalks, so the rectum is supplied by inferior and superior hemorrhoidal vessels.

#### STEP 6: DIVISION OF THE RECTUM AND ANASTOMOSIS

Before the proximal or distal rectum is divided, careful measurements should be made of where the two ends of the colon and rectum match up. There should be no tension on the anastomosis once it is complete, and yet there should be little to no laxity in the residual bowel as it lies in the pelvis. This will help reduce the risk of recurrent prolapse. Of note, some do not prefer to conduct a colon resection, and we would agree that if there is no redundancy in the colon and the patient suffers from fecal incontinence rather than from constipation, we might also choose not to resect the bowel. Once the level of colon and rectal transection has been determined to create a tension-free but nonlaxed anastomosis, the rectum is divided with a linear stapler. The division point of the rectum should be just below the level of the sacral promontory. The specimen is extracted through a small lower midline incision. In those cases where a hand port is performed, the specimen is readily extracted through the port site. The proximal end of the colon is divided, and the angle of the circular stapler is inserted and closed with a purse string suture. The circular stapler is inserted through the anus with the trocar brought out just in front of or behind the transverse staple line. The two parts of the stapler are coupled and the device then fired. We often place a row of seromuscular sutures around the anastomosis, especially if there is any evidence of leakage when it is tested in a saline-filled pelvis.

#### STEP 7: RECTOPEXY

Once the anastomosis is complete, the mesorectum is then attached to the sacral promontory or as one of two with two or three nonabsorbable sutures. We would incorporate the lateral edge of the rectal tissue with care being taken to find the mesorectal tissue without major vessels or nerves. We would also take care to offset the left and right sutures to avoid "crimping" or occluding the rectal lumen from this fixation process. Care should also be taken to insert the needle into some of the presacral periosteum and away from the area of the sacral nerve and internal iliac vessels.

## Laparoscopic Subtotal Colectomy With Ileorectal Anastomosis

### STEP 1: PATIENT POSITION AND ROOM SETUP

The patient is carefully placed in a modified lithotomy position and securely strapped and padded to the operating table, thus keeping the patient stable when the operating table is tilted side to side during surgery. The surgeon stands on the right or left side of the patient depending on the segment of the colon. The video monitors are adjusted according to the surgeon's position to maintain the alignment of the camera, instruments, and surgical fields. Two monitors are used for convenience because the surgeon will have to reposition at least twice. If an ileostomy is planned, the site should be identified by stomal therapists preoperatively and marked before surgery starts.

### STEP 2: PORT PLACEMENT AND EXPLORATION

A 10/12-mm port is made in the supraumbilical region and laparoscope is introduced. Under direct visual guidance, four ports are placed, one each in all four quadrants of the abdomen. A 10-mm port is placed in the right lower quadrant to allow the endoscopic stapler; the remaining ports are 5 mm in size. If camera position needs to be changed, a 5-mm port can be changed to a 10-mm cannula.

### STEP 3: MOBILIZATION OF THE COLON—LEFT COLON, SIGMOID COLON, AND RIGHT COLON

The colon is mobilized sequentially starting from splenic flexure and left colon, followed by right colon and then the sigmoid colon as previously described under individual hemicolectomies. The vessels are ligated intracorporeally and simultaneously along with the dissection of its respective segment. In case of benign pathology, the vessels can be ligated closer to the bowel and a LigaSure or other vascular transecting device can be used for most, if not all, of the vessels.

### STEP 4: EXTERIORIZATION OF THE COLON AND DIVISION OF THE VASCULATURE

The colon is confirmed free from all attachments with the help of a grasper before exteriorization of the specimen. The pneumoperitoneum is vented out and supraumbilical incision is extended for 4–6 cm inferiorly. The colon is exteriorized through this incision. Any remaining vascular pedicles can be ligated using standard open technique extracorporeally. The orientation of the ileal mesentery should be preserved to prevent torsion and small bowel internal herniation.

### STEP 5: FORMATION OF ILEORECTAL ANASTOMOSIS

An ileorectal anastomosis performed with help of the circular stapler in a fashion similar to what is described previously for

colorectal anastomosis. The tricky part of the ileorectal anastomosis is finding the optimal orientation for the small bowel and its mesentery as it comes to a lie within the pelvis. It is often difficult to get the best orientation because the ileum typically is in the right lower quadrant, not in the left lower quadrant. In some cases, it will easily work end to end for an anastomosis, but in most other cases a side ileum to end of rectum may be best to achieve a mesenteric alignment to avoid seeping. If a side of ileum to end of rectum anastomosis looks best, the stapled distal end of the small bowel can be oversewn with seromuscular sutures and a separate antimesenteric site chosen to conduct the anastomosis. In this case, the anvil of the stapler can be placed in the bowel and closed with a purse-string suture and the shaft of the stapler brought across the anus into the rectum and coupled, closed, and fired in the typical fashion.

## RESTORATIVE TOTAL PROCTOCOLECTOMY WITH ILEAL J-POUCH ANAL ANASTOMOSIS

### Laparoscopic Ileal Pouch-Anal Anastomosis

This procedure is essentially the same as the subtotal colectomy plus ultralow anterior rectal resection. The main difference here is the creation of an ileal J-pouch rather than a colon J-pouch.

### STEP 1: PATIENT POSITION AND ROOM SETUP

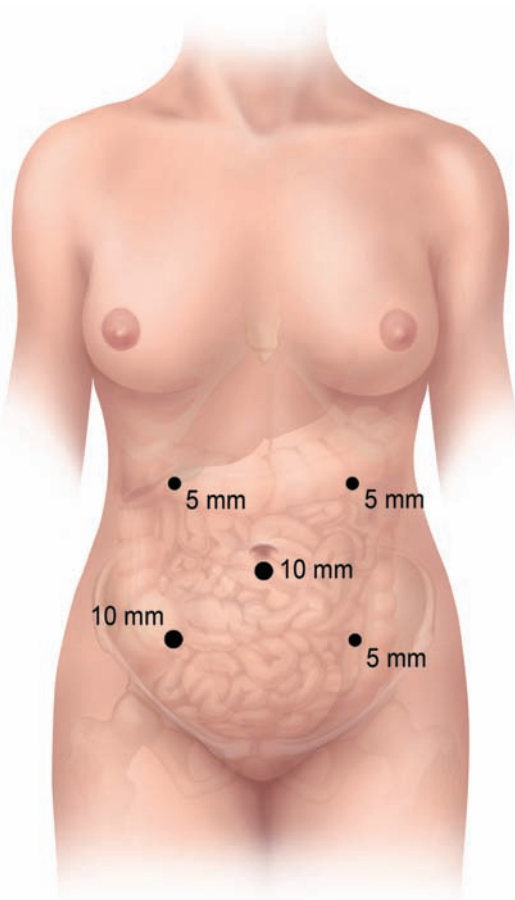
The patient is placed in modified lithotomy position and securely and safely strapped to avoid movements and injury during the procedure. The position of the surgeon should be ergonomically altered depending on the dissection of individual segment of the colon. The key to the appropriate position of the surgeon is to maintain a parallel view with the laparoscope, working instruments, and the monitors.

### STEP 2: PORT PLACEMENT AND EXPLORATION

The 30-degree laparoscope is introduced through the 10-mm trocar in the infraumbilical site. The abdomen is inspected to confirm the pathology. Under direct visual guidance, four trocars are introduced in the four quadrants (Fig. 37-25). A 10-mm trocar is inserted in the right lower quadrant while the rest of the trocars can be of 5 mm caliber. Using 10-mm trocars at all the ports will allow flexibility to the surgeon in using the laparoscope from any of the ports.

### STEP 3: COLON MOBILIZATION

The colon is mobilized sequentially starting from splenic flexure and left colon, followed by right colon and then the transverse and sigmoid colon as previously described under



**FIGURE 37-25** Position of laparoscopic ports for total proctocolectomy. (Used with permission of Mayo Foundation for Medical Education and Research, all rights reserved.)

individual hemicolectomies. We prefer to mobilize the splenic flexure early while all natural attachments are in tact. Intracorporeal vascular ligation and division is performed simultaneously with the dissection and mobilization of the colon using a vascular stapling device for larger vessels such as ileocolic and the LigaSure or similar device for smaller vessels.

#### STEP 4: RECTAL MOBILIZATION

The surgeon continues the dissection from the sigmoid colon toward the rectum. The rectum is fully mobilized to the pelvic floor as previously described in the section on ultralow anterior resection. The rectum is then divided at the pelvic floor using an Endo GIA (Covidien, Mansfield, MA) linear cutting stapler. If the stapler cannot reach the pelvic floor, the stapler can be introduced through a small suprapubic incision or the hand port incision or alternatively using a transanal approach. For the transanal approach, the anal canal is exposed using a Lone Star retractor (Lone Star Medical Products, Stafford, TX) or Gelpi retractor. Diluted epinephrine solution is then injected to raise the mucosal layer to assist in mucosectomy and to minimize bleeding. Cautery dissection starts at the dentate line and continued cephalad by lifting the mucosal layer up to the level of puborectalis, that is, the top of the anal

canal. At this point, the dissection is carried full thickness to complete the distal transection of the rectum with complete mucosal removal but with the preservation of the internal sphincter. This approach is used when the entire specimen can be removed through the anus.

#### STEP 5: EXTERIORIZATION OF COLON AND RECTUM

The infraumbilical incision is extended by 4–6 cm inferiorly after the pneumoperitoneum is vented through the cannulas. The colon is exteriorized through this incision if it has not been removed through the anus while in transanal resection. The vascular pedicles are ligated and divided using standard open technique extracorporeally unless the vessels are ligated and cut intracorporeally. The ileum at the junction with the right colon is stapled and transected.

#### STEP 6: FORMATION OF ILEAL J-POUCH–ANAL ANASTOMOSIS

The distal staple line of the ileum is oversewn with a seromuscular layer. Next, one makes sure that the blood supply and the vascular pedicle of the ileum are properly oriented without twists. Further, at this juncture one needs to make sure that the apex of the pouch can reach the level of the top of the anal canal. Lengthening of the ileum to achieve the pouch–anal anastomosis must be performed before the pouch is stapled and actually created. The mesentery of the small bowel needs to be fully mobilized all the way up to the base of the stomach near the pancreas. Vascular arcades can be ligated in order to get the pouch to reach in extreme cases, and after a period of temporary bulldog clamping has been performed to ensure good blood supply. Once the pouch is thought to reach, the “J” configuration is created using two 15-cm limbs of small bowel. Seromuscular suture helps secure the correct orientation and reinforce the staple line that is to be created. At this juncture, a small enterotomy is made in the apex of the pouch, and this allows multiple firings of the 80- to 100-mm linear stapler to create the pouch itself. Once the stapling is completed (two, at most three firings), look for and correct any defects at the intersections of the staple line and check for pouch hemostasis prior to placing the handle and the purse string in the apex.

The purse string is made in the pouch apex, and the circular stapler is placed and suture is tightened. The pouch is returned to the abdominal cavity with proper orientation and laid in the pelvis. The midline incision is closed so that the pneumoperitoneum can be restored and the anastomosis completed. The circular stapling device is inserted through the anus and the trocar advanced under direct vision across the transverse staple line or purse string at the anal level. The anvil of the stapler is then attached using a specially designed laparoscopic instrument ensuring that the pouch and its mesentery are lying in the correct orientation and not rotated. The stapler is coupled, closed, fired, and withdrawn. Removing the purse strings allows us to see if the donuts are intact. Anastomotic integrity of the pouch is checked before wound closure (Fig. 37-26).



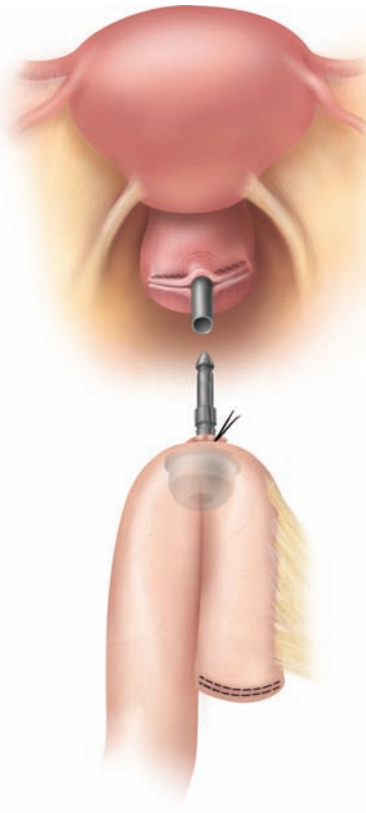


FIGURE 37-26 J-pouch–anal anastomosis. (Used with permission of Mayo Foundation for Medical Education and Research, all rights reserved.)

When a transanal approach is utilized to transect the distal end of the rectum, the pouch is delivered to the anal opening and two layers of absorbable sutures are placed. The first layer is seromuscular suturing of the pouch to the anal canal musculature, that is, an anchoring layer. The pouch is then opened and four quadrant sutures are next placed between the full thickness of the pouch and the residual anal mucosal layer. Supplemental sutures complete this layer.

#### STEP 7: FORMATION OF LOOP ILEOSTOMY

The ileum proximal to the pouch by roughly 30–50 cm is grasped and brought out to the RLQ port. A defunctioning loop ileostomy is made, ensuring that the orientation is properly defined. Pelvic drains are placed through the laparoscopic ports. The skin is then closed and the ileostomy matured.

### Hand-Assisted Ileal J-Pouch–Anal Anastomosis

The patient is placed in modified lithotomy position and securely strapped to the operating table. The hand port is placed in a lower midline incision. Three ports are made respectively at supraumbilicus, right lower, and the left upper quadrants. The surgeon may stand on the right or left of the patient; alternatively it is often convenient for the surgeon to

stand between the legs especially for takedown of flexures and the transverse colon. A 10-mm port is preferred to a 5-mm port as it allows the surgeon to use the laparoscope from any of the ports. The colonic mobilization commences at the splenic flexure. Additional assistance for the splenic mobilization can be provided with a grasper placed in the right lower quadrant. After mobilizing the splenic flexure and left colon, the surgeon shifts position to mobilize the right colon and the transverse colon. Vascular ligation and division can be performed in intra- or extracorporeal manner depending on the mobilization of the colon. The rectum can be mobilized and resected at the pelvic floor with a linear stapler or with a transverse stapler as described above. The rectum and colon are then delivered through the wound and the terminal ileum divided with the linear stapler. A J-pouch is then fashioned in the same manner as described previously and anastomosed to the anus with circular stapler inserted through the anus. If a defunctioning loop ileostomy is planned, a loop of proximal ileum is passed through the RLQ port and the ileostomy matured. Care should be taken to avoid torsion of the vascular pedicle and small bowel intussusception. Drains are placed into the pelvis through the lower quadrant port. After checking for anastomotic integrity and hemostasis is done, the hand port wound is closed in two layers as regular wound incision.

## COMPLICATIONS

Intraoperative complications including management and prevention can be seen in the following tables (Tables 37-5 to 37-7). Table 37-8 shows the advantages and disadvantages with robotics.

### TABLE 37-5: INTRAOPERATIVE COMPLICATIONS

#### Complications

Patient position related	<ul style="list-style-type: none"> <li>• Lower extremity neuropathies (peroneal nerve and compartment syndrome)</li> <li>• Upper extremity neuropathies (brachial plexus, median, and ulnar nerves)</li> <li>• Increased intra-abdominal pressure</li> </ul>
Veress needle or trocar insertion related	<ul style="list-style-type: none"> <li>• Vessel puncture and hemorrhage</li> <li>• Bowel perforation</li> </ul>
Pneumoperitoneum related	<ul style="list-style-type: none"> <li>• Increased intra-abdominal pressure</li> <li>• Hypothermia</li> <li>• Hypercarbia and acidemia</li> <li>• Insufflation with misplaced needle</li> </ul>
Technique related	<ul style="list-style-type: none"> <li>• Hemorrhage</li> <li>• Anastomotic leakage</li> <li>• Infection</li> </ul>

**TABLE 37-6: MANAGEMENT OF INTRAOPERATIVE COMPLICATIONS**

Intraoperative Complications	Management
Perforation	Laparoscopic repair, if technically feasible, or conversion to open surgery
Splenic injury	Control of capsular bleeding, electrocautery, topical hemostatic agent, conversion, and/or splenectomy
Ureteral injury	Conversion to open surgery and repair over a stent
Bladder injury	Laparoscopic repair, if feasible, or conversion
Mesenteric bleeding	Laparoscopic clip, suture control, or conversion
Anastomotic leak	Repair and/or diversion

**TABLE 37-7: PREVENTION OF INTRAOPERATIVE COMPLICATIONS**

Technique-Related Complications	Prevention
Perforation	Use atraumatic instruments; exert traction on peritoneal attachments rather than on bowel; use gentle manipulation; avoid cautery injury to well-insulated laparoscopic tools and adequate visualization of tools during the application of cautery
Splenic injury	Ensure adequate visualization when at the splenic flexure, and place gentle traction on tissues attached to the spleen
Ureteral injury	Properly identify and avoid cautery in the ureter field; use ureteral stents as necessary
Bladder injury	Use catheter decompression
Mesenteric bleeding	Create mesenteric windows in avascular plane, use of double-clip technique or suture ligation for major vessels
Anastomotic leak	Ensure proper bowel alignment, avoid tension, and check for good vascularization of proximal and distal ends, use suturing or stapling techniques, and check bleeding
Wound/trocar site infection	Proper antibiotic prophylaxis and ensure hemostasis and irrigation of trocar site
Trocar site recurrence	Protect the port site, use bag for specimen extraction, and avoid chimney effect.

**TABLE 37-8: ADVANTAGES AND DISADVANTAGES WITH ROBOTICS**

Advantages	Disadvantages
1. 3D visualization	1. High initial maintenance and cost
2. Better movement of instruments	2. Absence of tactile sensation
3. Absence of fulcrum effect	3. Long setup time for instruments
4. Less fatigue	4. Technical experience required
5. Elimination of tremor	

## LEARNING CURVE AND CREDENTIALING

Laparoscopic colectomy is different from other laparoscopic surgery as it requires working in multiple fields and different orientations. Proper training and experience along with appropriate help from the first assistant and the scrub nurse are vital in performing laparoscopic colectomy. There is a significant learning curve during which the length of each procedure may be longer and rate of conversion to open may be greater, although the incidence of complications is not altered.<sup>20</sup> It is recommended that surgeons develop their laparoscopic skills initially with simpler procedures such as appendectomy, cholecystectomy, and right colectomy before they graduate to benign complex operations and undertake cancer resections. Based on the prerequisite of 20 laparoscopic colectomies for COST trial, American Society of Colon and Rectal Surgeons (ASCRS) recommended that surgeons perform 20 laparoscopic resections before undertaking procedures for cancer. Hand-assisted laparoscopic surgery (HALS) is easily adaptable for routine and complex cases.<sup>21</sup> The steep learning curve of laparoscopic-assisted colectomy can be overcome by starting with the HALS approach.

## FUTURE CONSIDERATIONS—ROBOTICS AND NOTES

Successful telerobotic-assisted laparoscopic sigmoid and right colectomies were first reported by Weber et al<sup>22</sup> in 2002 when actual dissection and mobilization were performed with robotic assistance and a lot of progress was achieved in technological inventions and its application in various operations. D'Annibale et al reported the results of 53 robotic colorectal surgeries in 2004 and concluded that the outcomes are similar to laparoscopic surgery.<sup>23</sup> Short-term outcomes of a randomized pilot study by Baik et al comparing robotic-assisted low anterior resection and laparoscopic low anterior resection concluded the safety and feasibility of robotics (da Vinci robots [Intuitive Surgical, Inc., Sunnyvale, CA]) in colorectal surgery.<sup>24</sup>

Robotic-assisted surgery (da Vinci robots) offers many advantages over laparoscopic surgery such as 3D visualization,

increased degrees of freedom of movement, absence of fulcrum effect, reduced fatigue, and elimination of tremor and better ergonomics for surgeon.<sup>23</sup> The biggest drawback for robotics is the high cost. Minor drawbacks include the absence of tactile sensation and the lengthy time required for setup.<sup>23</sup> In the future, robotics may find its applicability in rectal operations such as total mesorectal excision, rectal rectopexy, and pelvic floor reconstruction.<sup>25</sup> With the new technological advances rapidly developing in the field of robotics, robotic-assisted surgery may replace the laparoscopic-assisted surgeries in the future.

NOSE (natural orifice specimen extraction) technique was performed in colon and rectal surgery specimen extraction through transanal and transvaginal route in the recent past and was considered a prequel to NOTES (natural orifice transluminal endoscopic surgery).<sup>26</sup>

NOTES is an interesting concept that is gaining enthusiasm. It utilizes the concept of approaching the internal viscera through natural openings such as the mouth (stomach), the anus, and the vagina. NOTES was first performed in India by Reddy and Rao in a burn patient where abdominal incision was not feasible.<sup>27</sup> Initial studies were focused mainly on animal studies.<sup>28</sup> The Natural Orifice Surgery Consortium for Assessment for Research (NOSCAR) was formed in 2005, and it identified the potential barriers in clinical practice of NOTES and set guidelines for future research and development.<sup>29</sup> Patients prefer to undergo NOTES approach over laparoscopic cholecystectomy for lack of pain (99%) and external scarring (89%).<sup>30</sup> The potential advantages of NOTES include no scars, less pain, fewer wound complications, earlier mobility,<sup>28</sup> and potential to offer therapy outside operating room (intensive care unit [ICU]).<sup>31</sup>

## REFERENCES

- Jacobs M, Verdeja JC, Goldstein HS. Minimally invasive colon resection (laparoscopic colectomy). *Surg Laparosc Endosc.* 1991;1(3):144–150.
- Hassan I, et al. Hand-assisted versus laparoscopic-assisted colorectal surgery: practice patterns and clinical outcomes in a minimally-invasive colorectal practice. *Surg Endosc.* 2008;22(3):739–743.
- Rafferty J, et al. Practice parameters for sigmoid diverticulitis. *Dis Colon Rectum.* 2006;49(7):939–944.
- Byrne CM, Smith SR, Solomon MJ, Young JM, Evers AA, Young CJ. Long-term functional outcomes after laparoscopic and open rectopexy for the treatment of rectal prolapse. *Dis Colon Rectum.* 2008;51(11):1597–1604.
- Berends FJ, Kazemier G, Bonjer HJ, Lange JF. Subcutaneous metastases after laparoscopic colectomy. *Lancet.* 1994;344(8914):58.
- Fleshman JW, et al. Early results of laparoscopic surgery for colorectal cancer. Retrospective analysis of 372 patients treated by Clinical Outcomes of Surgical Therapy (COST) Study Group. *Dis Colon Rectum.* 1996;39(10 suppl):S53–S58.
- Reilly WT, Nelson H, Schroeder G, Wieand HS, Bolton J, O'Connell MJ. Wound recurrence following conventional treatment of colorectal cancer. A rare but perhaps underestimated problem. *Dis Colon Rectum.* 1996;39(2):200–207.
- Johnstone PA, Rohde DC, Swartz SE, Fetter JE, Wexner SD. Port site recurrences after laparoscopic and thoracoscopic procedures in malignancy. *J Clin Oncol.* 1996;14(6):1950–1956.
- Lacy AM, et al. Laparoscopy-assisted colectomy versus open colectomy for treatment of non-metastatic colon cancer: a randomised trial. *Lancet.* 2002;359(9325):2224–2229.
- Clinical Outcomes of Surgical Therapy Study Group. A comparison of laparoscopically assisted and open colectomy for colon cancer. *N Engl J Med.* 2004;350(20):2050–2059.
- Buunen M, et al. Colon Cancer Laparoscopic or Open Resection Study Group. Survival after laparoscopic surgery versus open surgery for colon cancer: long-term outcome of a randomised clinical trial. *Lancet Oncol.* 2009;10(1):44–52.
- Veldkamp R, et al. COlon cancer Laparoscopic or Open Resection Study Group (COLOR). Laparoscopic surgery versus open surgery for colon cancer: short-term outcomes of a randomised trial. *Lancet Oncol.* 2005;6(7):477–484.
- Guillou PJ, et al. MRC CLASICC trial group. Short-term endpoints of conventional versus laparoscopic-assisted surgery in patients with colorectal cancer (MRC CLASICC trial): multicentre, randomised controlled trial. *Lancet.* 2005;365(9472):1718–1726.
- Jayne DG, et al. UK MRC CLASICC Trial Group. Randomized trial of laparoscopic-assisted resection of colorectal carcinoma: 3-year results of the UK MRC CLASICC Trial Group. *J Clin Oncol.* 2007;25(21):3061–3068.
- Bonjer HJ, et al. Transatlantic Laparoscopically Assisted vs Open Colectomy Trials Study Group. Laparoscopically assisted vs open colectomy for colon cancer: a meta-analysis. *Arch Surg.* 2007;142(3):298–303.
- Kazemier G, Bonjer HJ, Berends FJ, Lange JF. Port site metastases after laparoscopic colorectal surgery for cure of malignancy. *Br J Surg.* 1995;82(8):1141–2.
- Wexner SD, Cohen SM. Port site metastases after laparoscopic colorectal surgery for cure of malignancy. *Br J Surg.* 1995;82(3):295–298.
- Boller AM, Nelson H. Colon and rectal cancer: laparoscopic or open? *Clin Cancer Res.* 2007;13(22 pt 2):6894s–6896s.
- Soop M, Nelson H. Laparoscopic-assisted proctectomy for rectal cancer: on trial. *Ann Surg Oncol.* 2008;15(9):2357–2359.
- Schlachta CM, et al. Defining a learning curve for laparoscopic colorectal resections. *Dis Colon Rectum.* 2001;44(2):217–222.
- Cima RR, Pattana-arun J, Larson DW, Dozois EJ, Wolff BG, Pemberton JH. Experience with 969 minimal access colectomies: the role of hand-assisted laparoscopy in expanding minimally invasive surgery for complex colectomies. *J Am Coll Surg.* 2008;206(5):946–950; discussion 950–952.
- Weber PA, Merola S, Wasielewski A, Ballantyne GH. Telerobotic-assisted laparoscopic right and sigmoid colectomies for benign disease. *Dis Colon Rectum.* 2002;45(12):1689–1694; discussion 1695–1696.
- D'Annibale A, et al. Robotic and laparoscopic surgery for treatment of colorectal diseases. *Dis Colon Rectum.* 2004;47(12):2162–2168.
- Baik SH, et al. Robotic tumor-specific mesorectal excision of rectal cancer: short-term outcome of a pilot randomized trial. *Surg Endosc.* 2008;22(7):1601–1608.
- Whiteford MH, Swanstrom LL. Emerging technologies including robotics and natural orifice transluminal endoscopic surgery (NOTES) colorectal surgery. *J Surg Oncol.* 2007;96(8):678–683.
- Palanivelu C, Rangarajan M, Jategaonkar PA, Anand NV. An innovative technique for colorectal specimen retrieval: a new era of “natural orifice specimen extraction” (N.O.S.E). *Dis Colon Rectum.* 2008;51(7):1120–1124.
- Baron TH. Natural orifice transluminal endoscopic surgery. *Br J Surg.* 2007;94(1):1–2.
- Al-Akash M, Boyle E, Tanner WA. N.O.T.E.S.: the progression of a novel and emerging technique. *Surg Oncol.* 2009;18(2):95–103. [Epub. 2008 Dec 24]
- Rattner D, Kalloo A. ASGE/SAGES Working Group on Natural Orifice Transluminal Endoscopic Surgery. October 2005. *Surg Endosc.* 2006;20(2):329–333.
- Varadarajulu S, Tamhane A, Drelichman ER. Patient perception of natural orifice transluminal endoscopic surgery as a technique for cholecystectomy. *Gastrointest Endosc.* 2008;67(6):854–860.
- Onders RP, et al. Natural orifice transluminal endoscopic surgery (NOTES) as a diagnostic tool in the intensive care unit. *Surg Endosc.* 2007;21(4):681–683.



# PERSPECTIVE ON COLONIC NEOPLASMS

José G. Guillem • Jeannine A. Ruby

The management of colorectal cancer has progressed over the past two decades because of many advances, including those in genetics, pathology, imaging, medical oncology, radiation oncology, and surgery. Within genetics, a number of mutations have been identified that play a causative role in colon carcinogenesis and have led to developments in targeted therapies and genetic testing for familial syndromes. Currently, most patients presenting with an inherited form of colorectal neoplasm can be classified as having adenomatous (familial adenomatous polyposis [FAP], attenuated FAP [AFAP], MUTYH-associated polyposis [MAP], Lynch syndrome, and familial colorectal cancer type X [FCC X])<sup>1</sup> or hamartomatous [juvenile polyposis syndrome [JPS] and Peutz-Jeghers syndrome [PJS]) polyps. With the exception of FCC X, genetic testing can now diagnose all of the aforementioned syndromes, thereby making prophylactic risk-reducing surgery a practical option.

MAP, a recently characterized hereditary adenomatous polyposis syndrome, should be suspected in patients who have greater than 10 colorectal adenomas and have a weak or negative family history of colorectal cancer. The seemingly negative family history is due to MAP's autosomal recessive inheritance and its low (~2%) carrier frequency.<sup>2,3</sup> While the vertical transmission rate is low, the siblings of biallelic carriers have a 25% risk of being biallelic carriers.<sup>3</sup>

FCC X describes a subset of patients who meet Amsterdam criteria II (at least three relatives with colorectal, endometrial, small bowel, ureteral, or renal pelvis cancer; one a first-degree relative of the other two; at least two successive generations affected; at least one diagnosed before age 50; FAP excluded; and tumors verified by pathologic examination) but lack an identifiable mismatch repair (*MMR*) gene mutation.<sup>4</sup> Patients with FCC X have been found to have a lower incidence of colonic and extracolonic cancers than those with Lynch syndrome.<sup>5</sup> Patients with Lynch syndrome are generally recommended to undergo colonoscopy every 1–2 years, endometrial cancer screening annually, urinalysis annually, and to consider prophylactic colectomy or hysterectomy.<sup>6</sup> Patients with the apparently less virulent phenotype of

FCC X may require a less thorough approach.<sup>5,7</sup> Until more is known about the condition, patients with FCC X are recommended to undergo screening colonoscopy every 1–2 years.

Patients who meet Amsterdam criteria should be tested for *MMR* gene mutations either through immunohistochemistry (IHC) for loss of *MMR* protein expression or through molecular analysis for microsatellite instability (MSI). IHC may be the preferred test as it is less expensive, its sensitivity is comparable to MSI testing, and it allows for targeted germline testing by identifying a specific *MMR* protein loss. The routine testing of colorectal cancer patients younger than 50 years for loss of *MMR* protein expression via IHC can help identify Lynch syndrome in otherwise unsuspected cases.<sup>8</sup>

Within the field of pathology, sessile-serrated adenomas have received a lot of recent attention. They are characterized by saw-toothed crypt epithelial folds and are associated with MSI-high sporadic colorectal cancers.<sup>9</sup> These lesions are particularly interesting because the serrated tumorigenesis pathway is thought to be distinct from the traditional adenoma-carcinoma sequence.

The use of positron emission tomography with computed tomography (PET-CT) allows for both metabolic and anatomic evaluation and enhances the ability to differentiate malignant from fibrotic tissue. Currently, the National Comprehensive Cancer Network (NCCN) *Clinical Practice Guidelines in Oncology* suggest that PET-CT be considered for colorectal cancer patients with potentially resectable metastasis or with suspected recurrence based on serial carcinoembryonic antigen (CEA) elevation.<sup>10</sup> However, they do not recommend PET-CT for initial staging workup, routine surveillance, or monitoring of metastatic disease progression for colon or rectal cancer.<sup>10</sup>

The American Joint Committee on Cancer has updated the colorectal cancer TNM (tumor-node-metastasis) classification system within the past year. These changes include the subdivision of T4 lesions into T4a (penetrates visceral peritoneum) and T4b (invades or is histologically adherent to other organs or structures); the subdivision of N1 and N2 into N1a (one node), N1b (two to three nodes), N2a (four to six nodes), and

N2b (seven or more nodes); and the subdivision of M1 into M1a (single metastatic site) and M1b (multiple metastatic sites), among other changes.<sup>11</sup> It is expected that these changes will further assist clinicians in tailoring adjuvant therapy and surveillance strategies.

Targeted therapies such as cetuximab, a monoclonal antibody that inhibits epidermal growth factor receptor, and bevacizumab, a monoclonal antibody that inhibits vascular endothelial growth factor, are now available. The identification of the subset of patients who will benefit from these targeted therapies is under investigation; for example, patients bearing a tumor with a *K-ras* mutation have no improvement in progression-free or overall survival when given cetuximab.<sup>12,13</sup>

The delivery method of radiation therapy is progressing. Image-guided radiation therapy (IGRT) relies on the principle of modifying treatment based on frequent imaging during a course of radiation therapy, and intensity-modulated radiation therapy (IMRT) aims to increase dosing to the target volume and to limit dosing to surrounding normal tissue. There are few studies published on IMRT in the treatment of rectal cancer.

Following the German Rectal Cancer Trial (CAO/ARO/AIO-94) showing that neoadjuvant chemoradiation decreases local recurrence rates, neoadjuvant chemoradiation followed by total mesorectal excision and adjuvant chemotherapy is now the recommended management for patients with locally advanced rectal cancer.<sup>14</sup> With increasing pathologic complete response (pCR) rates due to evolving neoadjuvant chemoradiation regimens, investigators in Brazil have posited that radical rectal resection may be unnecessary in locally advanced rectal cancers that achieve a complete clinical response after neoadjuvant chemoradiation.<sup>15</sup> This provocative approach is currently being explored by several centers worldwide.

Another deviation in the standard treatment of rectal cancer is the proposal of using neoadjuvant chemotherapy alone followed by surgery. One recent trial gave neoadjuvant folinic acid/5-fluorouracil/oxaliplatin (FOLFOX) with bevacizumab and no radiation in 29 patients with non-T4 stages II and III rectal cancers and found a 27% pCR rate, 100% clinical regression rate, and a 100% R0 resection rate, suggesting that in carefully selected cases radiation therapy may be withheld.<sup>16</sup>

In the interest of sphincter preservation and avoidance of the morbidity and mortality associated with a radical rectal resection, the role of chemoradiation in stage I rectal tumors is under investigation. The American College of Surgeons Oncology Group (ACOSOG) Z6041 trial examines the efficacy of chemoradiation therapy and local excision in the treatment of uT2N0 rectal cancers.<sup>17</sup> Preliminary results show a 44% pCR rate, 64% tumor downstaging rate, and a 98% negative resection margin rate.<sup>18</sup> Long-term recurrence rates and survival outcomes are pending.

Since its controversial introduction in the 1990s, laparoscopic surgery for colon cancer has subsequently been shown to have similar outcomes to open surgery in large, multicenter trials,

such as the Clinical Outcomes of Surgical Therapy (COST) study group trial, the European Colon Cancer Laparoscopic or Open Resection (COLOR) trial, and the Medical Research Council Conventional versus Laparoscopic-Assisted Surgery In Colorectal Cancer (MRC CLASICC) trial.<sup>19–21</sup> In contrast, laparoscopic surgery for rectal cancer is still under investigation. Three multicenter, randomized clinical trials are currently evaluating the role of laparoscopic surgery specifically in rectal cancer: the Comparison of Open versus laparoscopic surgery for mid and low REctal cancer After Neoadjuvant chemoradiotherapy (COREAN) trial (closed to accrual), the COLOR II trial (accruing), and the ACOSOG Z6051 trial (accruing).<sup>22–24</sup>

Surgeons have turned to robotic surgery to overcome some of the technical challenges of performing conventional laparoscopic surgery within the pelvis. A recent series of 64 stages I–III rectal cancer patients treated with robotic-assisted total mesorectal excision found that the approach allowed for an adequate oncologic resection, and acceptable 3-year overall (96.2%) and disease-free (73.7%) survival rates after a mean follow-up of 20.2 months.<sup>25</sup> Long-term studies of rectal cancer patients treated with robotic surgery remain to be performed.

Undoubtedly, the management of patients afflicted with colorectal cancer will evolve as advances continue to be made in the multiple disciplines that contribute to the diagnosis and treatment of colorectal cancer.

## REFERENCES

- Steinhagen E, Markowitz AJ, Guillem JG. How to manage a patient with multiple adenomatous polyps. *Surg Oncol Clin N Am*. 2010 Oct;19(4):711–723.
- Croitoru ME, Cleary SP, Di Nicola N, et al. Association between biallelic and monoallelic germline MYH gene mutations and colorectal cancer risk. *J Natl Cancer Inst*. 2004 Nov 3;96(21):1631–1634.
- Lubbe SJ, Di Bernardo MC, Chandler IP, Houlston RS. Clinical implications of the colorectal cancer risk associated with MUTYH mutation. *J Clin Oncol*. 2009 Aug 20;27(24):3975–3980.
- Vasen HF, Watson P, Mecklin JP, Lynch HT. New clinical criteria for hereditary nonpolyposis colorectal cancer (HNPCC, Lynch syndrome) proposed by the International Collaborative group on HNPCC. *Gastroenterology*. 1999;116(6):1453–1456.
- Lindor NM, Rabe K, Petersen GM, et al. Lower cancer incidence in Amsterdam-I criteria families without mismatch repair deficiency: familial colorectal cancer type X. *JAMA*. 2005 Apr 27;293(16):1979–1985.
- Lindor NM, Petersen GM, Hadley DW, et al. Recommendations for the care of individuals with an inherited predisposition to Lynch syndrome: a systematic review. *JAMA*. 2006 Sep 27;296(12):1507–1517.
- Vasen HF, Abdirahman M, Brohet R, et al. One to 2-year surveillance intervals reduce risk of colorectal cancer in families with Lynch syndrome. *Gastroenterology*. 2010 Jun;138(7):2300–2306.
- Lee-Kong SA, Markowitz AJ, Glogowski E, et al. Prospective immunohistochemical analysis of primary colorectal cancers for loss of mismatch repair protein expression. *Clin Colorectal Cancer*. 2010 Oct 1;9(4):255–259.
- Leggett B, Whitehall V. Role of the serrated pathway in colorectal cancer pathogenesis. *Gastroenterology*. 2010;138(6):2088–2100.
- Cited with permission from *The NCCN 1.2011 Colon Cancer/1.2011 Rectal Cancer Clinical Practice Guidelines in Oncology*. National Comprehensive Cancer Network; 2010. Available at: <http://www.nccn.org>. Accessed July 26, 2010. To view the most recent and complete version of the guideline, go online to [www.nccn.org](http://www.nccn.org).
- AJCC Cancer Staging Manual*. 7th ed. New York, NY: Springer; 2010.

12. Karapetis CS, Khambata-Ford S, Jonker DJ, et al. K-ras mutations and benefit from cetuximab in advanced colorectal cancer. *N Engl J Med.* 2008 Oct 23;359(17):1757–1765.
13. Lievre A, Bachet JB, Boige V, et al. KRAS mutations as an independent prognostic factor in patients with advanced colorectal cancer treated with cetuximab. *J Clin Oncol.* 2008 Jan 20;26(3):374–379.
14. Sauer R, Becker H, Hohenberger W, et al. Preoperative versus postoperative chemoradiotherapy for rectal cancer. *New Engl J Med.* 2004;351(17):1731–1740.
15. Habr-Gama A, Perez RO, Proscurshim I, et al. Patterns of failure and survival for nonoperative treatment of stage c0 distal rectal cancer following neoadjuvant chemoradiation therapy. *J Gastrointest Surg.* 2006;10(10):1319–1328; discussion 1328.
16. Schrag D, Weiser M, Goodman K, et al. Neoadjuvant FOLFOX-bev, without radiation, for locally advanced rectal cancer [abstr 3511]. *J Clin Oncol.* 2010;28(suppl):15s.
17. Ota DM, Nelson H. Local excision of rectal cancer revisited: ACOSOG protocol Z6041. *Ann Surg Oncol.* 2007;14(2):271.
18. Garcia-Aguilar J, Shi Q, Thomas C, Jr, et al. A phase II trial of neoadjuvant chemoradiation and local excision for T2N0 rectal cancer: preliminary results of the ACOSOG Z6041 trial. *Ann Surg Oncol.* 2012;19(2):384–391.
19. Fleshman J, Sargent DJ, Green E, et al. Laparoscopic colectomy for cancer is not inferior to open surgery based on 5-year data from the COST Study Group trial. *Ann Surg.* 2007 Oct;246(4):655–662; discussion 662–654.
20. Buunen M, Veldkamp R, Hop WCJ, et al. Survival after laparoscopic surgery versus open surgery for colon cancer: long-term outcome of a randomised clinical trial. *Lancet Oncol.* 2009;10(1):44–52.
21. Jayne DG, Thorpe HC, Copeland J, Quirke P, Brown JM, Guillou PJ. Five-year follow-up of the Medical Research Council CLASICC trial of laparoscopically assisted versus open surgery for colorectal cancer. *Br J Surg.* 2010;97(11):1638–1645.
22. Kang SB, Park JW, Jeong SY, et al. Open versus laparoscopic surgery for mid or low rectal cancer after neoadjuvant chemoradiotherapy (COREAN trial): short-term outcomes of an open-label randomised controlled trial. *Lancet Oncol.* 2010;11(7):637–645.
23. Buunen M, Bonjer HJ, Hop WC, et al. COLOR II. A randomized clinical trial comparing laparoscopic and open surgery for rectal cancer. *Dan Med Bull.* 2009 May;56(2):89–91.
24. Soop M, Nelson H. Laparoscopic-assisted proctectomy for rectal cancer: on trial. *Ann Surg Oncol.* 2008;15(9):2357–2359.
25. Baek JH, McKenzie S, Garcia-Aguilar J, Pigazzi A. Oncologic outcomes of robotic-assisted total mesorectal excision for the treatment of rectal cancer. *Ann Surg.* 2010;251(5):882–886.



# PERSPECTIVE ON COLONIC NEOPLASMS

David J. Schoetz, Jr.

Colon tumors remain one of the more common reasons for abdominal surgery. Adenocarcinoma of the colon is still the most common histology requiring operative intervention. Other types of malignant tumors and benign lesions make up a distinct minority of colonic neoplastic indications for operation.

The etiology of colorectal cancer remains elusive. Dietary factors, including macro- and micronutrients, have maintained a central importance in theories of the etiology of colon cancer. High dietary fiber, once felt to be protective, has more recently been demonstrated in a large prospective study to not prevent colorectal cancer.<sup>1</sup> Conversely, the breakdown products of cooked meat have clearly been implicated in the development of colorectal cancer.<sup>2</sup> Because rigid control of the constituents of diet over time is highly unlikely and even strict vegetarians have developed colorectal cancer, it is not likely that lifelong dietary manipulation will substantially alter the natural history of this disease.

Screening for colorectal cancer is clearly effective in reducing the overall mortality from colorectal cancer, presumably by discovery of tumors at an earlier and thus more curable stage. In this respect, it is an ideal disease for directed screening, because the precancerous phase is long and removal of the precancerous lesion is preventive of cancer. The incidence of colorectal cancer has been in a slow decline over the past 10–15 years, due in part to increased application of screening programs in the population as a whole.<sup>3</sup>

Because of noncompliance of the American population with Hemoccult testing programs or, in fact, any other procedures that require interacting with stool (such as stool DNA analysis), intermittent anatomic evaluation of the entire colon and rectum by some means has become the preferred manner of colorectal cancer screening. Practically, total colonoscopy has become the most common screening procedure, beginning at age 50 in normal-risk individuals. Alternatively, flexible sigmoidoscopy and air contrast barium enema are recommended at 5-year intervals; they are perceived by patients and primary care physicians to be more uncomfortable because of the lack of conscious sedation when compared to colonoscopy.

Radiographic screening with three-dimensional software for interpretation of cross-sectional images is popularly known as “virtual colonoscopy,” a misnomer leading to misunderstandings about the procedure. Individuals undergoing computed tomographic (CT) colonography must mechanically cleanse the colon and then have air (or carbon dioxide) insufflation prior to imaging. Positive findings necessitate referral for optical colonoscopy. There are certain circumstances in which diagnostic CT imaging is indicated; comorbidities that preclude conscious sedation, refusal on the part of the patient to undergo colonoscopy or prior failed attempt(s) and obstruction preventing proximal passage of the instrument are all reasonable indications for CT colonography.

It must be stressed that no method of screening is infallible. Furthermore, there are some individuals who do not have any identifiable factors that would indicate surveillance at an earlier age or with greater frequency who develop colorectal cancer.

Among identifiable risk factors suggesting the need for surveillance beginning at an earlier age than 50 years, family history of cancer is the most common and arguably the most significant factor. Identification of individuals at risk for genetic syndromes begins with accurate history taking from the patient as well as construction of the family pedigree. In the current era of “endoscopy-on-demand” programs, the responsibility for identifying patients and families who would potentially benefit from genetic screening and more aggressive endoscopic surveillance shifts to the primary caregivers and ancillary personnel, because the endoscopists often do not know the patient or participate in the decision to perform endoscopy.

Ultimately, the genetics of all colorectal cancers will be elucidated, perhaps resulting in the development of reliable blood testing to replace screening tests that are expensive, resource intensive, and have some associated risk. At present, the variations of familial adenomatous polyposis (FAP) with mutations of the *APC* gene as well as the multiple mismatch repair (*MMR*) genes involved in the basic phenotype of hereditary nonpolyposis colon cancer (HNPCC) represent a minority of all colon cancer patients. Attenuated FAP,

a mutation of the *APC* gene, exhibits a different phenotype than classic FAP characterized by fewer polyps and later age of onset. More recently, the recessive *MYH* genes, with an attenuated FAP phenotype but a different genetic transmission, have been added to the better-known genetic syndromes.<sup>4</sup> As more of the genetic associations are elucidated, the molecular basis of sporadic colorectal cancers will become evident.

Preoperative localization of colonic neoplasms should be a priority in order to plan operative strategy. In some instances, colonoscopy to the cecum, traversing the lesion to exclude the presence of synchronous pathology that requires coincident attention, is not possible. In the elective situation, other strategies may be employed to visualize the proximal colon. Water-soluble contrast enema may be able to outline the colon above a lesion that does not allow the passage of a colonoscope; this requires communication with the radiologist to avoid excessive pressure and overinflation of the colon with a risk of perforation. As mentioned previously, CT colonography may be used to visualize the colon but has the limitation of not being able to cleanse the colon because of the obstruction. In the instances in which complete colonic evaluation is not accomplished preoperatively, the performance of intraoperative colonoscopy using carbon dioxide rather than air for insufflation to minimize the duration of colonic distention has been suggested. This requires on-table lavage to allow detailed mucosal inspection and is probably impractical in many instances of operation for obstruction. As a result, individuals undergoing urgent operation precluding preoperative colonic inspection should be evaluated by colonoscopy sooner in the postoperative period with the expectation that there will be discovery of the occasional synchronous neoplasm.

Preoperative marking of tumor location by the colonoscopist, most often by submucosal injection of India Ink, has become quite popular; this has been driven primarily by the relative loss of tactile sensory capability for the surgeon with the advent of laparoscopic colon resection. It is not unusual for the endoscopist to misinterpret the position of the tip and thus the tumor, leading in some instances to resection of the wrong segment of colon. This is obviated by India Ink marking.

Mechanical cleansing of the colon has recently been deemphasized as a necessary part of the routine preparation of a patient for colon resection.<sup>5</sup> While there is no evidence to support an increased risk of anastomotic or infectious complications for elective colon resections in stool-filled bowel, some find this situation aesthetically displeasing and prefer a colon without formed stool upon which to work. In fact, patients have often had some form of amended bowel cleaning by not eating solids for a day or more, taking some laxative and/or using a disposable enema. This is particularly true for left-sided lesions.

In some instances, the degree of obstruction of the colon is such that preoperative preparation of the colon is not possible. Under these circumstances the options are to (1) perform a subtotal colectomy with anastomosis of the ileum to the colon distal to the lesion; (2) resect the lesion and perform on-table lavage with primary anastomosis; and (3) perform

a staged procedure with resection and stoma. A more recent option is the placement by the endoscopist of an expandable metallic stent to relieve the acute obstruction and allow mechanical cleansing of the colon followed by an elective resection in the near future.<sup>6</sup>

Since the introduction of laparoscopic colon resection in the early 1990s, there has been a relative explosion of this technology. Data from the American Board of Colon and Rectal Surgery reflected utilization of laparoscopy for colon surgery beginning with resident case logs in 1994.<sup>7</sup> By continuing to record and analyze resident case lists from colorectal training programs, the percentage of abdominal colorectal resections performed laparoscopically increased from 3.6% in 1994 to 24.3% in 2005.<sup>8</sup> Analysis of the relative penetration of pathology indicating operation suggests that the application of laparoscopy for cancer somewhat awaited the publication of the multi-institutional trials outlined in Chap. 37. This fundamental change in the approach to colon surgery represents an enormous challenge for the education of residents and practicing surgeons alike.

Laparoscopic surgery represents an alternative means of accomplishing well-established operative procedures. These new skills must be incorporated into the new curriculum of teaching and learning technical surgery. Fortunately, laparoscopic skills lend themselves to the use of simulation technologies that have been designed, validated, and implemented. The Fundamentals of Laparoscopic Surgery (FLS) program, developed by the Society of American Gastrointestinal and Endoscopic Surgeons (SAGES), is a combination of a didactic curriculum combined with skill assessment using box trainers, trained observers, and validated end points for evaluation of distinct psychomotor and cognitive skills necessary for basic laparoscopy.<sup>9</sup> All general surgery residents must have successfully completed the FLS program by graduation from residency. By extension, because all colon and rectal residents are fully trained general surgeons, they will also be FLS-certified.

Computer-based simulation is developing at a rapid pace and may well evolve into procedure-specific training devices. Credentialing of practicing surgeons will probably incorporate simulation exercises for competency determination in the future; perhaps there will also be review of videotapes of specific procedures by hospital credentialing committees or even the surgical boards for both primary certification and part IV of maintenance of certification.

As abdominal access shifts increasingly to laparoscopy, open surgical skills will atrophy, if they are developed at all, during general surgical residency. Volumes of some procedures are already a challenge, pushing many general surgery graduates into subspecialty training after completion of a standard 5-year residency program. Furthermore, the learning curve differs among individual surgeons; marketing pressures and financial incentives may push marginally capable surgeons to do procedures for which they are not yet prepared for safe independent performance.

The growth of laparoscopy has not all been fueled by randomized prospective data demonstrating its superiority over

open surgery. Proposed advantages such as shorter length of stay, less postoperative pain and more rapid return to work must be counterbalanced by longer operative times and greater procedural expense. Some of the enthusiasm among patients and referring physicians is stimulated and amplified by misunderstandings of the true benefits of the 'minimally invasive' approach. There are absolute and relative contraindications to performance of laparoscopic resection outlined in Table 37-3. These criteria must be scrupulously applied to patients seeking laparoscopic surgery.

As a general rule, the same procedural endpoints must be able to be accomplished by laparoscopic techniques; nowhere is this more evident than with cancer surgery. Oncologic results of laparoscopic colon resection for cancer must at least equal those obtained by traditional open surgery. Adequacy of mesenteric lymph node resection has gained considerable traction as a surrogate for quality surgery. Survival is dependent on numbers of lymph nodes harvested, with survival increasing with more resected nodes.<sup>10</sup> Numbers of nodes removed are a quality measure in addition to the time-honored outcomes of overall cure and disease-free survival.

Technical horizons awaiting scientific scrutiny are robotics as applied to colorectal surgery, single-port access surgery, and NOTES (natural orifice transluminal endoscopic surgery). While each of these techniques may find a place in the future, at present they must all be considered experimental in nature. Development of these expensive technologies should not be at the primary direction of market-driven forces; rather, there

should be a concerted effort to develop and test new techniques, with at least proof of equivalence, before allowing them to permeate practice.

## REFERENCES

1. Fuchs CS, Giovannucci EL, Colditz GA, et al. Dietary Fiber and the risk of colorectal cancer and adenoma in women. *N Engl J Med.* 1999;340:169–176.
2. Zheng W, Lee SA. Well-done meat intake, heterocyclic amine exposure, and cancer risk. *Nutr Cancer.* 2009;61:437–446.
3. Jemal A, Siegel R, Ward E, et al. Cancer statistics, 2009. *CA Cancer J Clin.* 2009;59:250–263.
4. Tops CMJ, Wijnen JT, Hes FJ. Introduction to molecular and clinical genetics of colorectal cancer syndromes. *Best Pract Res Clin Gastroenterol.* 2009;23:127–146.
5. Slim K, Vicaut E, Launay-Savary MV, et al. Updated systematic review and meta-analysis of randomized clinical trials on the role of mechanical bowel preparation before colorectal surgery. *Ann Surg.* 2009;249:203–209.
6. Tilney HS, Lovegrove RE, Purkayasth P, et al. Comparison of colonic stenting and open surgery for malignant large bowel obstruction. *Surg Endosc.* 2007;21:225–233.
7. Schoetz DJ. Colon and rectal surgery. A true subspecialty. *Dis Colon Rectum.* 1998;41:1–10.
8. Schoetz DJ. Evolving practice patterns in colon and rectal surgery. *J Am Coll Surg.* 2006;203:322–327.
9. Tsuda S, Scott D, Doyle J, Jones DB. Surgical skills training and simulation. *Curr Probl Surg.* 2009;46:266–370.
10. Chang GJ, Rodriguez-Bigas MA, Skibber JM, Moyer VA. Lymph node evaluation and survival after curative resection of colon cancer: systemic review. *J Natl Cancer Inst.* 2007;99:433–441.



VI

# RECTUM AND ANUS

*This page intentionally left blank*

# BENIGN DISORDERS OF THE ANORECTUM (PELVIC FLOOR, FISSURES, HEMORRHOIDS, AND FISTULAS)

Anne Y. Lin • James W. Fleshman, Jr.

Benign diseases of the anorectum range from relatively simple disorders such as hemorrhoids and fissures to extremely complex problems associated with pelvic floor abnormalities.

## ANATOMY

The beginning of any evaluation of anorectal problems is the examination; therefore clinicians need to understand the anatomy. The normal anatomic relationships of the rectum and pelvis are important in understanding pelvic floor abnormalities and anorectal pathology. The rectum normally lies attached to its mesorectum within the curve of the sacrum with limited mobility. The junction of the rectosigmoid is most consistently found at the sacral promontory and descends only 2 or 3 cm during a Valsalva maneuver. The rectum exits the pelvis anteriorly surrounded by a sling of muscle from the pubis through a slit in the pelvic floor. The sling is created by the horseshoe-shaped puborectalis muscle that circles around behind the rectum and reinserts on the pubis anteriorly. Contraction of the muscle pulls the rectum forward, creating a more acute angle at the anal outlet. The anal canal itself measures 3–4 cm and is a funnel-shaped extension of the pelvic floor musculature. The pressure generated by this voluntary muscle prevents egress of rectal contents. The internal sphincter muscle is a continuation of the thickened circular muscle of the rectum. As such, it is an autonomic muscle and has no voluntary control.

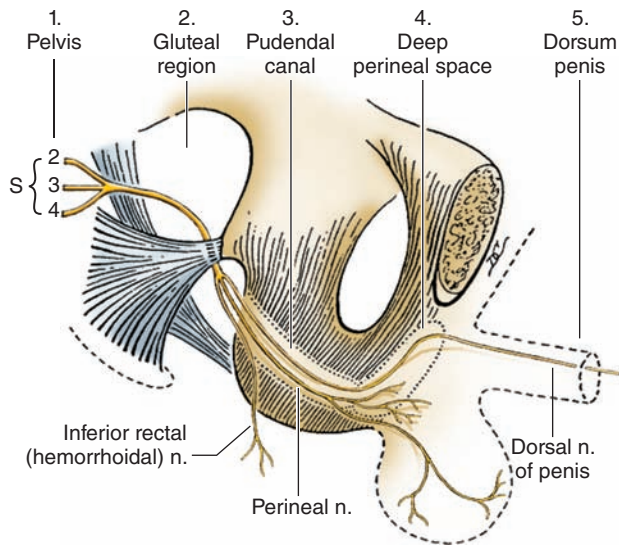
The anorectum receives both sympathetic and parasympathetic nerves. The sympathetic nerves originate from thoracolumbar segments and unite below the inferior mesenteric artery to form the inferior mesenteric plexus. These fibers

then descend to the superior hypogastric plexus located just inferior to the aortic bifurcation. These purely sympathetic fibers bifurcate and descend as the hypogastric nerves. Parasympathetic fibers from S2, S3, and S4 (the Nervi erigentes) join the hypogastric nerves anterolateral to the rectum to form the inferior hypogastric plexuses. Mixed fibers from the plexuses innervate the prostate, rectum, bladder, penis, and internal anal sphincter. These autonomic plexuses of the pelvic nerves run around the lateral aspect of the pelvic rim to enter the prostate and seminal vesicles anteriorly. The sympathetic innervation of the internal sphincter is motor, while the parasympathetic innervation is inhibitory. Injury to the pelvic autonomic nerves during pelvic surgery may result in bladder dysfunction, impotence, or both.

The innervation of the voluntary muscles of the pelvic floor is via direct fibers from S2, S3, and S4 in the pelvis from the sacrum (Fig. 39-1). The nerves of the external sphincter are derived from S2, S3, and S4 nerve roots from the sacral plexus and they arrive at the external sphincter via the pudendal nerve around the ischial spine at Alcock's canal. The uterus and vagina are closely approximated to the anterior surface of the rectum but not attached. There is no ligamentous suspension of the rectum or the uterus at the lower aspect of the pelvis. The slit-like defect in the pelvic floor through which the rectum passes also provides an outlet for the vagina and the urinary bladder.

The alimentary tract terminates at the anus, which provides continence of flatus and feces. It is useful to consider the anus and surrounding structures as a single unit, the anorectum (Fig. 39-2). The anorectum includes the perianal skin, the anal canal, the anal sphincters, and the distal rectum. The three main anatomic points of reference are the anal verge,





**FIGURE 39-1** Diagram of the pudendal nerve. Note the five regions in which it runs and the three divisions into which it divides. (Reproduced, with permission, from Anderson JE. *Grant's Atlas of Anatomy*. 8th ed. Baltimore, MD: Williams & Wilkins; 1983.)

the dentate line, and the anorectal ring. The distal external boundary of the anal canal is the anal verge, which is also the junction between the anal and perianal skin. Anal epithelium (anoderm) is devoid of the hair follicles, sebaceous glands, and apocrine glands that are present in the perianal skin, a fact worth remembering when attempting to distinguish between hidradenitis (inflammation of the apocrine glands in the perianal skin) and cryptoglandular anal disease.

The cephalad border of the anal canal is a true mucocutaneous junction, the dentate line. This union of the embryonic ectoderm with the endodermal gut resides approximately 1.0–1.5 cm above the anal verge. In a transitional zone of 6–12 mm in length, the columnar epithelium of the rectum changes to cuboidal epithelium that joins the squamous epithelium at the dentate line.

The upper border of the anal sphincteric complex is the anorectal ring. It may be palpated by digital examination about 1.0–1.5 cm above the dentate line. Anatomists consider the anal canal to begin at the dentate line and end at the anal verge. However, most surgeons consider the anal canal to start at the anorectal ring and terminate at the anal verge. This latter definition of the anal canal is used throughout this chapter.

Just above the dentate line, the rectal mucosa forms 8–14 longitudinal folds known as the *rectal columns*. Between each two columns at the dentate line is a small pocket termed an *anal crypt*. Small, rudimentary anal glands open into some, but not all, of these anal crypts. The glands may extend through the internal sphincter as far as the intersphincteric plane, but they do not extend into the external sphincter.

Below the dentate line, cutaneous sensations of heat, cold, touch, and pain are conveyed by afferent fibers in the

inferior rectal nerves. Cephalad to the dentate line, poorly defined dull sensations, elicited when the mucosa is pinched or internal hemorrhoids are ligated, are probably carried by parasympathetic fibers.

The superior rectal artery, the terminal branch of the inferior mesenteric artery, descends to the upper rectum where it divides into lateral branches. Subsequent smaller divisions penetrate the rectal wall. The middle rectal arteries arise from the internal iliac arteries and supply the distal rectum and upper anal canal. The inferior rectal arteries, branches from the internal pudendal arteries, cross the ischioanal fossae to supply the anal sphincters (Fig. 39-3).

There are two paths for venous blood return from the anorectum. Above the dentate line, venous blood flows into the portal system through the superior rectal vein and inferior mesenteric vein. Below the dentate line, the external hemorrhoidal plexus drains into the internal iliac vein via the middle rectal vein or via the pudendal vein, which receives blood from the inferior rectal vein.

## FECAL INCONTINENCE

### Pathophysiology

Mechanical disruption is usually due to obstetric injury, trauma, or fistula disease in which the external muscle is divided or damaged (Table 39-1). Neurogenic incontinence is due to stretching of the pudendal nerves during prolonged labor, descent of the perineum and nerve stretch during straining at stool or rectal prolapse, or systemic disease such as multiple sclerosis, scleroderma, or spinal cord injury. Idiopathic incontinence is due to medical disease such as diarrhea in a patient with limited rectal capacity, irritable bowel syndrome, or sedatives that cause poor sensation in the anal canal in patients with no evidence of neurogenic or mechanical incontinence.

The normal continence mechanism has several components. Rectal capacitance and compliance are essential. The rectum normally holds between 200 and 250 mL. It distends readily with filling and has limited muscular activity intrinsically. The internal anal sphincter provides 80% of the resting anal sphincter pressure that provides the resistance to gas and mucus at the anal canal. The sampling reflex is a function of rectal distension causing internal anal sphincter relaxation via an intramural reflex to the internal sphincter. The rectal contents can then be sensed in the sensory nerve-rich transitional zone and anoderm to discriminate the true nature of the rectal contents. This sampling reflex occurs frequently throughout the day to provide continence and also serves to initiate the defecation process. The voluntary external sphincter muscle contraction in response to this sampling reflex provides the final active component of fecal continence. The subconscious voluntary contraction of the external sphincter, puborectalis, and pelvic floor muscles provide complete control of rectal contents. The pelvic floor muscles maintain continual activity, even during sleep, to provide fecal continence. This also

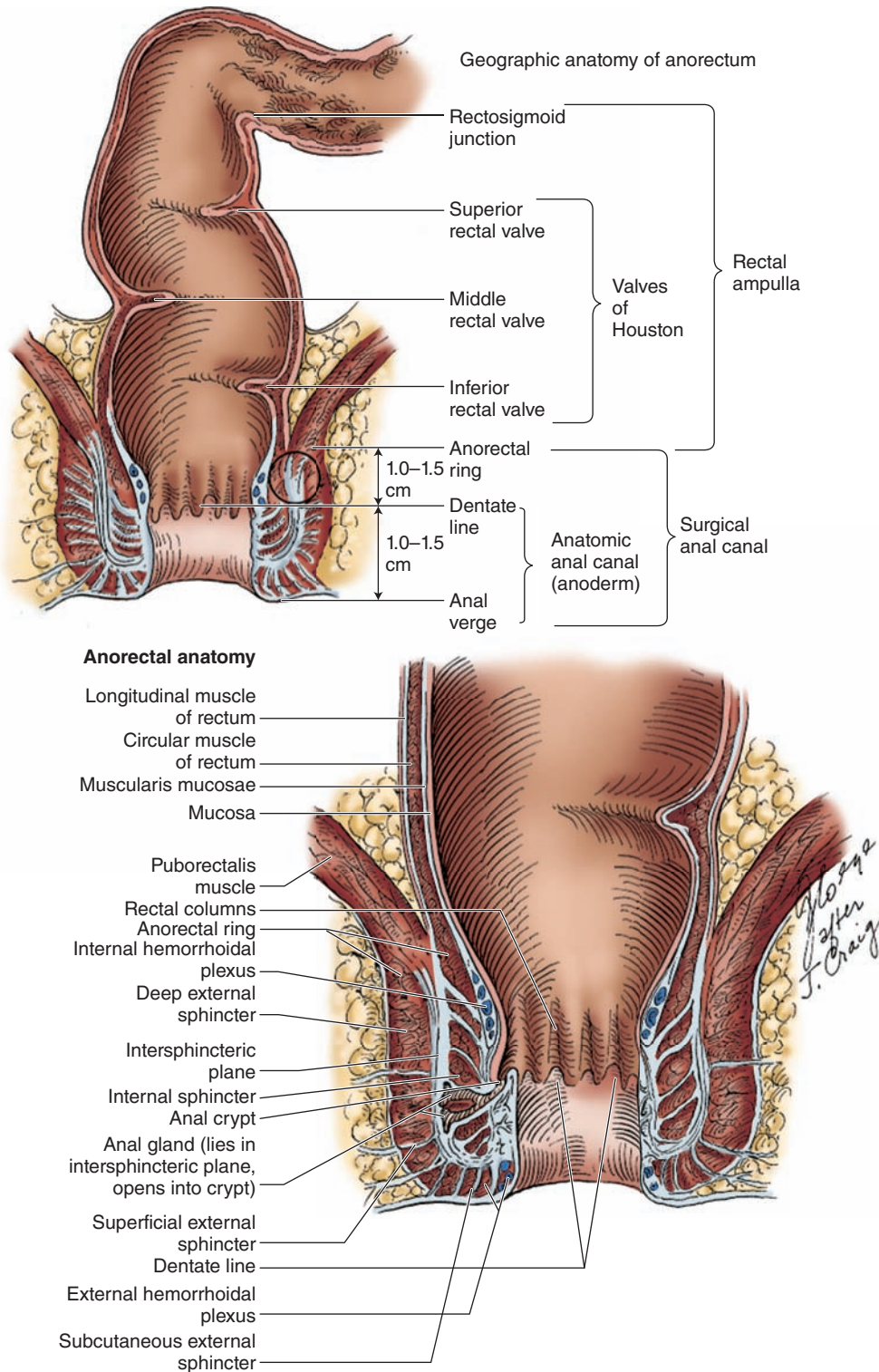
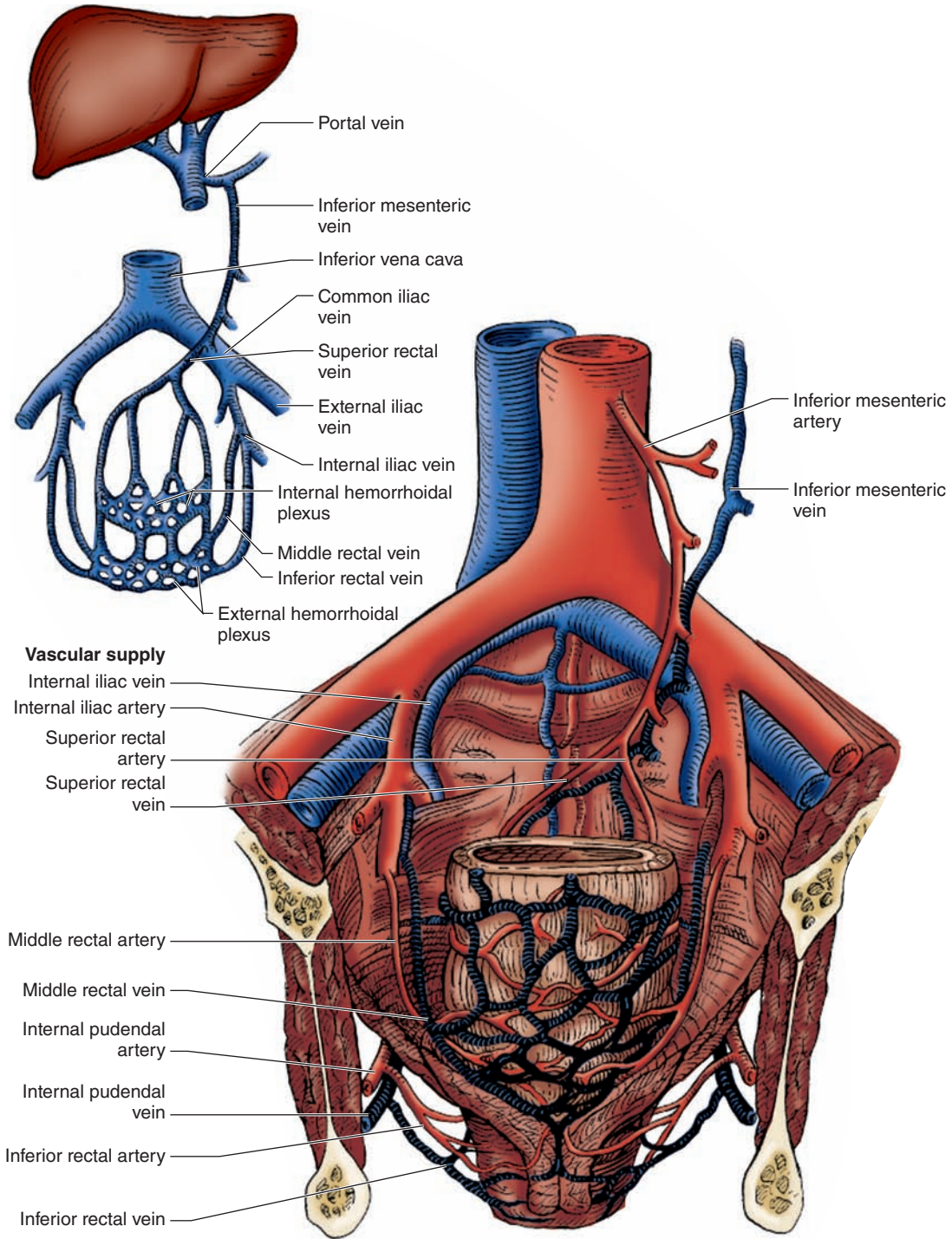


FIGURE 39-2 Anatomy of the anus and rectum: geographic anatomy of the anorectum and anorectal anatomy. (Redrawn, with permission, from Fry RD, Kodner IJ. Anorectal diseases. *Clin Symp*. 1985;37(6):2–32. Copyright 1985, Academy of Medical Sciences. Originally illustrated by John Craig, MD.)



**FIGURE 39-3** Vascular supply of the anus and rectum. Blood returns from the anus via two routes. Below the dentate line, the external hemorrhoidal plexus drains into the inferior vena cava via inferior pudendal veins. Above the dentate line, the internal hemorrhoidal plexus drains into the portal system via the superior rectal vein. (Redrawn, with permission, from Fry RD, Kodner IJ. Anorectal diseases. *Clin Symp.* 1985;37(6):2–32. Copyright 1985, Academy of Medical Sciences. Originally illustrated by John Craig, MD.)



**TABLE 39-1: FECAL INCONTINENCE ETIOLOGY**

Mechanical	Neurogenic	Idiopathic
Obstetric injury	Pudendal nerve stretch	No clear etiology
Fistula disease	Strain	Medical illness
Trauma	Prolonged labor	Irradiation
Iatrogenic	Trauma	Irritable bowel syndrome
Systemic disease		Multiple sclerosis, diabetes mellitus, scleroderma
Diarrheal states		

seems to be a learned response because infants and children require 1–2 years to achieve control.

*Fecal incontinence* is defined as the inability to control the passage of gas, liquid, or stool until a socially acceptable time or place for evacuation. The frequency of incontinence may vary, and the loss of control may involve solid stool, liquid stool, or gas only. Frequent episodes of incontinence to gas alone may be as incapacitating as infrequent episodes of solid stool. Evaluation of fecal incontinence should include assessment of severity as well as impact of disease. The American Society of Colon and Rectal Surgeons has validated a fecal incontinence severity index and a fecal incontinence quality-of-life index to help standardize the assessment of fecal incontinence.<sup>1–3</sup>

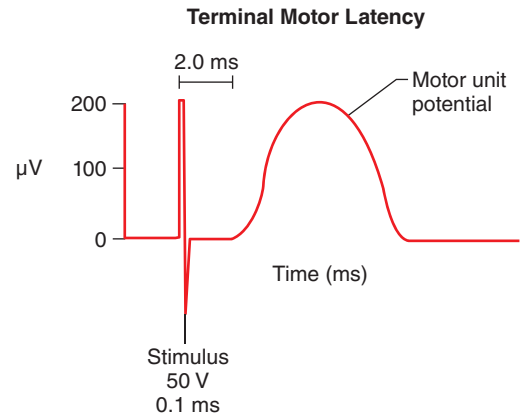
## Diagnosis and Evaluation

A problem-focused history as well as physical examination should be performed. History should include information on gastrointestinal or neurologic disorders, obstetrics, and previous anorectal surgery. On physical examination, a thin perineal body with scarring between the vagina and the anal canal and a poor squeeze on command may indicate a sphincter problem. In the setting of an anterior sphincter injury, it is essential to evaluate for the presence of a rectovaginal fistula.

Anal manometry is useful to document reduced resting and squeeze pressures as well as sphincter length in individual sphincter quadrants. Normal resting pressure is at least 40 mm Hg. Normal squeeze pressure is 80 mm Hg, which is usually double the resting pressure. Sphincter length is greater than 3 cm. Normal sensation should allow detection of a balloon inflated with 10–20 mL of air in the distal rectum. Maximal tolerable volume is at least 100 mL of air-filled balloon distention.

## ELECTROMYOGRAPHY

Pudendal nerve terminal motor latency (PNTML) determination measures the conduction velocity of the nerve



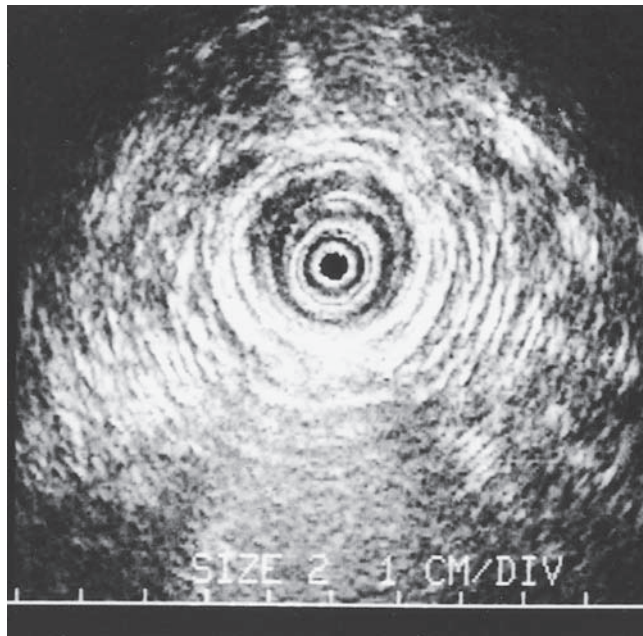
**FIGURE 39-4** Normal tracing of pudendal nerve terminal motor latency (PNTML). (Reproduced, with permission, from Fleshman JW, Kodner IJ, Fry RD. Anal incontinence. In: Zuidema GD, ed. *Shackelford's Surgery of the Alimentary Tract*. 3rd ed, Vol. 1. Philadelphia, PA: WB Saunders; 1991:349–361.)

action potential through the terminal 4 cm of the pudendal nerve between Alcock's canal and the external sphincter (Fig. 39-4). A delay in conduction reflects injury to the fast-conducting fibers of the nerve. This injury usually is the result of stretch, direct trauma, or systemic disease. The normal terminal motor latency is  $2.0 \pm 0.2$  milliseconds. A delay in conduction velocity greater than this indicates nerve injury. Measurement of the PNTML has been shown to be clinically less useful than originally thought. The defect in the nerve must be fairly advanced to see a change in conduction and is therefore somewhat inaccurate for assessing minor defects. Single-fiber or concentric needle electromyography (EMG) is most accurate but not very useful clinically due to pain during the test.

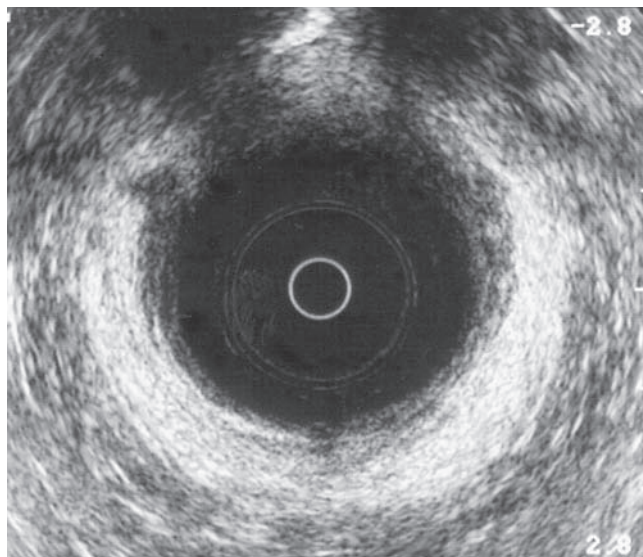
## TRANSRECTAL ULTRASOUND

The most sensitive method for documenting sphincter injury may be the anal ultrasound using a 360-degree rotating 10-MHz transducer covered with an anal cap and inserted into the anal canal. The focal length of the anal probe is approximately 1–2 cm and allows evaluation of the anal sphincter muscles in three dimensions as the probe is withdrawn from the rectum (Fig. 39-5). The ultrasound can detect scarring at the site of an injury, as well as rectovaginal fistula. The presence of a sphincter defect alone, however, may not correlate with fecal incontinence. Figure 39-6 shows an algorithm for the evaluation and management of fecal incontinence using these diagnostic techniques.

High-resolution magnetic resonance imaging (MRI) with an endoanal coil is a diagnostic modality that can detect sphincter defects similarly to endoanal ultrasound. Endoanal coil MRI may also show sphincter atrophy or thinning not detectable by endoanal ultrasound that may be useful for predicting success of surgical repair.<sup>4</sup> Focused pelvic floor MRI with a surface coil and dynamic MRI are being evaluated as methods of evaluating fecal incontinence.<sup>5,6</sup>



A



B

**FIGURE 39-5** **A.** Transrectal ultrasound of a normal male sphincter reveals internal and external sphincter muscles. An anal cap covers the 7.5- or 10-MHz rotating transducer of the Bruel and Kjaer ultrasound probe. The innermost dark layer is the mucosa of the anal canal. **B.** Image of anterior sphincter defect in a female patient with anal incontinence due to obstetric injury. (Part B reproduced, with permission, from Fleshman JW. Anorectal motor physiology and pathophysiology. *Surg Clin North Am.* 1993;73:1256.)

## Treatment

Therapy depends on severity of symptoms. For milder forms of fecal incontinence, an improvement in symptoms may occur with dietary changes such as increased

fiber intake or antidiarrheal agents. A bowel regimen with high fiber, suppositories, and enemas every morning may be appropriate in patients with incontinence that cannot be repaired because of comorbidities or other confounding factors.

## MUSCLE SENSORY RETRAINING OR BIOFEEDBACK

Operant conditioning using surface EMG, manometric, and balloon sensation techniques may be helpful in patients who do not respond to dietary changes.<sup>7</sup> Biofeedback may improve symptoms in patients with a mechanical sphincter defect before repair or who have persistent or recurrent symptoms after sphincter repair. Improvement in symptoms is reported in 64–89% of patients.<sup>8</sup> Prediction of the subset of patients who may benefit from biofeedback is difficult, but in general those with poor pudendal nerve function or complete disruption of the anal sphincter have less benefit. A trained physical therapist or anal physiotherapist experienced with anal and pelvic floor treatment is critical to the degree of success achieved.

## ANAL SPHINCTER RECONSTRUCTION

Anal sphincter repair can be performed successfully in most patients who have an isolated mechanical sphincter defect. A complete bowel preparation is highly recommended. The ends of the obstetrically injured sphincter are identified in the anterior perineum and either overlapped and sutured “pants over vest” or reefed in the midline to reconstruct the circular muscle (Fig. 39-7). Control of solid and liquid stool will be adequate in 90% of patients after this type of repair. However, complete continence is usually only achieved in 75% of patients and the long-term results may even be less satisfactory.<sup>9</sup> Leakage of liquid, mucus, and gas may continue to affect patients after repair. Improvement in squeeze pressures has been shown to correlate best with functional outcome.<sup>10</sup> The presence of at least one normal pudendal nerve is important for functional improvement after sphincter reconstruction. Complications of wound infection, fistula formation, and breakdown of the sphincter repair may be reduced by leaving a drain in the perineal body after the repair. A repeat procedure is equally successful in patients in whom the sphincter repair is noted to be disrupted by endoanal ultrasound.<sup>11,12</sup>

## OTHER TREATMENTS AND NEW MODALITIES

Sacral nerve stimulation using implanted electrodes at the S2–4 foramen has been found to be of benefit for patients with fecal incontinence.<sup>13–16</sup> Complications requiring removal of the device seem to be uncommon. Rarely, infection and pain at the site can be encountered. This technique is now approved

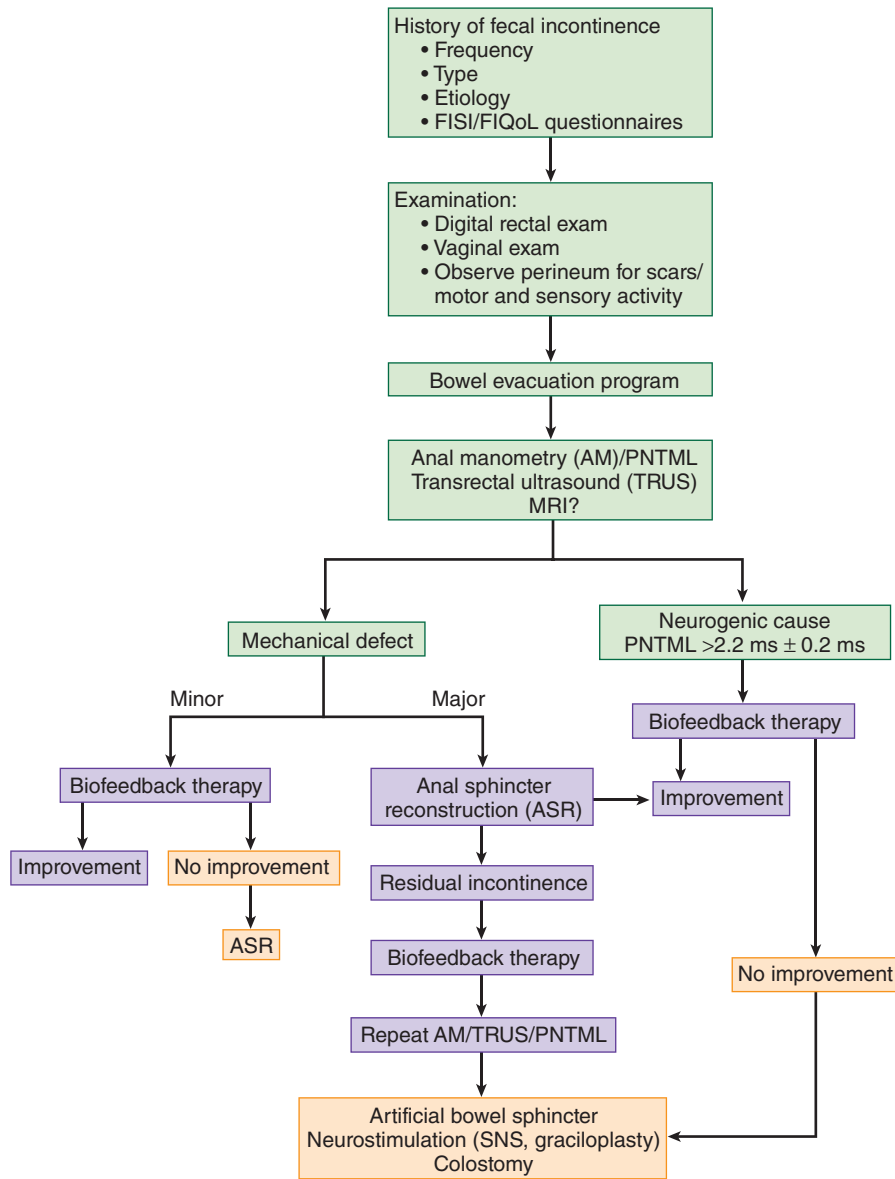


FIGURE 39-6 Algorithm for evaluation and management of anal incontinence. PNTML, pudendal nerve terminal motor latency; SNS, sacral nerve stimulation.

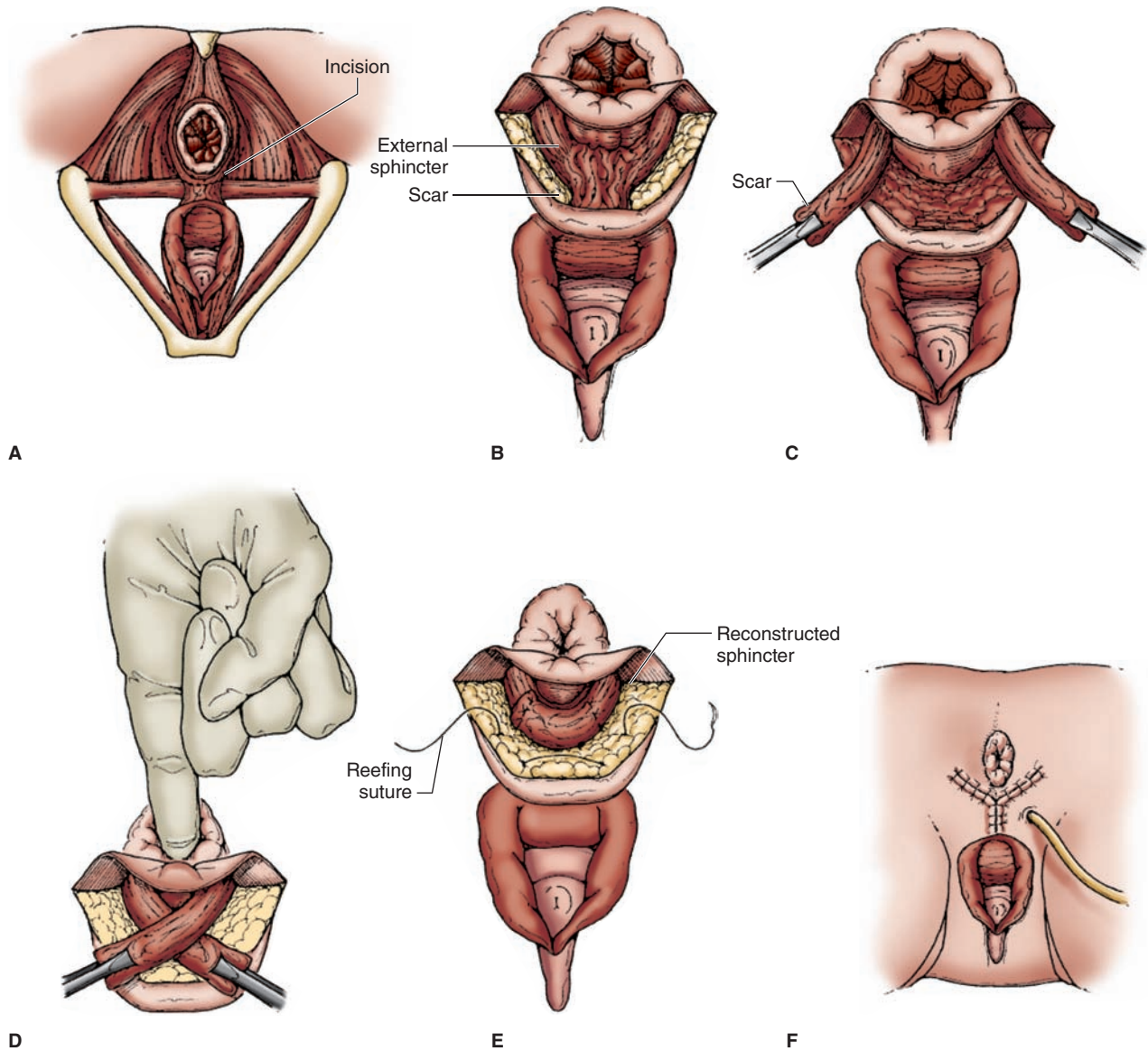
in the United States for fecal incontinence. The mechanism of action is not fully delineated but may be due to the lift of the pelvic floor provided by levator ani continual contraction. Placement of the electrodes can be performed as an outpatient under local anesthesia.

For patients with a severely damaged sphincter, dynamic graciloplasty or implantation of a neurostimulator that provides constant activity into a muscle transferred to the anal canal may be appropriate, but it has been discontinued in the United States.<sup>17</sup> Alternatively, an artificial sphincter of silicone with water-filled circum-anal cuff, called *artifi-*

*cial bowel sphincter*, may be implanted. Although the rate of explantation secondary to infection remains high, this technique can provide improvement in fecal continence. This technique has been removed from the market.<sup>18,19</sup>

When all other treatments fail, or if a patient desires, a stoma may be appropriate. Attention should be directed preoperatively to correct siting of the stoma to prevent pouching difficulties. Quality-of-life measures show that patients are generally satisfied. In a series from St. Mark's hospital, 83% of patients with a permanent colostomy reported improvement in lifestyle.<sup>20</sup>





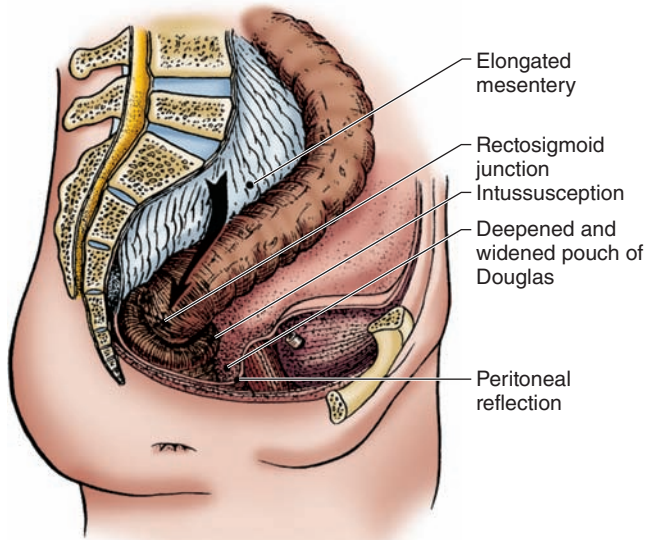
**FIGURE 39-7** Anal sphincter overlapping muscle repair. **A.** Anterior incision and perineal view of muscles. **B.** Rectal flap is created and sphincter muscles are isolated. **C.** Muscle flaps are fully mobilized. **D.** Muscle flaps are overlapped around a 15-mm rubber dilator or fingertip. **E.** Muscle flaps are sutured in place and the perineal body repaired. **F.** A drain is placed behind the vaginal wall and the wall closed. (Reproduced, with permission, from Fleshman JW, Fry RD, Kodner IJ. Anal incontinence. In: Zuidema GO, ed. *Shackelford's Surgery of the Alimentary Tract*. 3rd ed, Vol. 1. Philadelphia, PA: WB Saunders; 1991:349–361.)

## RECTAL PROLAPSE AND INTERNAL INTUSSUSCEPTION

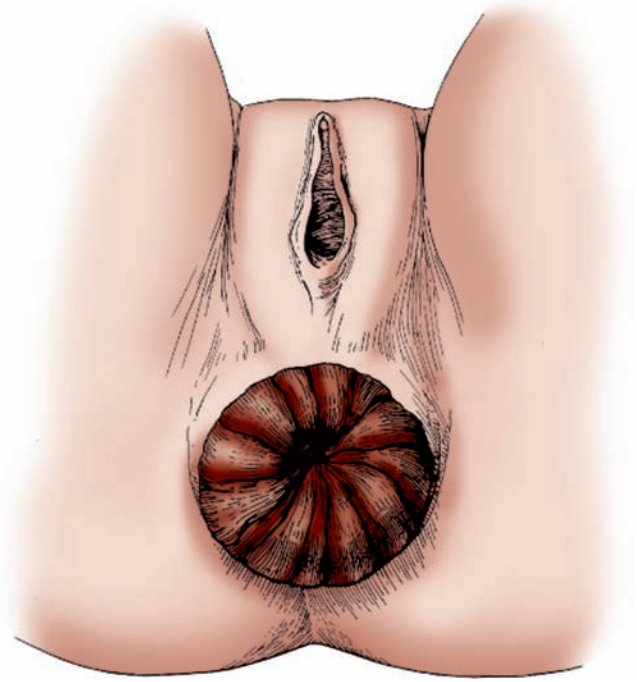
### Pathophysiology

The true etiology of rectal prolapse and intussusception is unknown. The mechanism is influenced by three components: (1) The rectum and rectosigmoid junction have increased mobility off the sacrum; (2) descent of the rectosigmoid junction into the pelvis allows a funnel-shaped intussusception

into the rectum as the rectum attempts to expel itself; and (3) poor relaxation of the pelvic floor and external sphincter mechanism occurs during straining (Fig. 39-8). Persistent straining against this outlet obstruction may lead to descent of the perineum, expulsion of the rectum, and true rectal prolapse. This sequence of events from progression of internal intussusception (funnel formation) to full rectal prolapse is supported anecdotally. Consequences of rectal prolapse include anal canal injury from stretch of the internal sphincter during rectal prolapse and/or injury to the pudendal nerve during descent of the perineum. The classic defecographic



**FIGURE 39-8** Rectum with internal intussusception. (Reproduced, with permission, from Hoffman MJ, Kodner IJ, Fry RD. Internal intussusception of the rectum: diagnosis and surgical management. *Dis Colon Rectum*. 1984;27:435.)



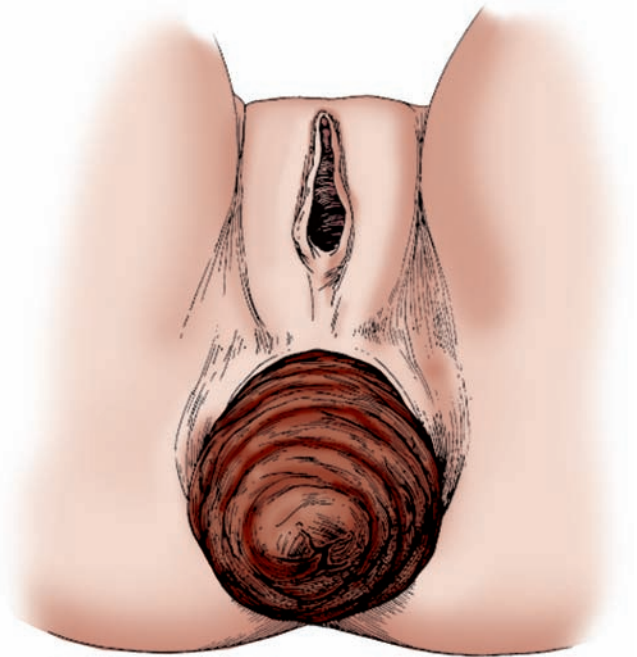
**A**

picture of rectal prolapse and severe intussusception is a funnel that descends into the deep pelvis as the rectosigmoid junction descends. A ball valve obstruction occurs at the level of the anal canal before it is pushed through to the outside.

A distal mucosal prolapse is occasionally mistaken for full rectal prolapse. The typical appearance of a mucosal prolapse is that of mucosa separated by radial lines around the anus (Fig. 39-9A). Concentric rings of mucosa are seen in true rectal prolapse (Fig. 39-9B). Defecography is helpful to distinguish between these two entities, as they are treated differently.

## Diagnosis and Evaluation

Signs and symptoms of rectal prolapse include rectal pressure and pain, incomplete evacuation, outlet obstruction, and constipation causing prolonged straining. Mucus discharge and bleeding from the fully prolapsed tissue may also be present. Examination most often reveals concentric rings of rectal tissue with a patulous anal canal, poor voluntary tone, and a very mobile rectum within the vault. Proctosigmoidoscopy reveals descent of tissue during straining and occasionally an ulcer on the anterior wall (caused by ischemia at the lead point of the intussusception). Defecography reveals extreme mobility of the rectum from its point of fixation to the sacrum, redundancy of the mesorectum, and funnel formation as the rectum prepares to descend through the anal canal opening at the pelvic floor. Defecography is most useful in cases that cannot be visualized in an office setting. Thickened barium simulates stool and cinedefecography allows visualization



**B**

**FIGURE 39-9** **A.** Radial folds of mucosal prolapse. **B.** Concentric rings of full-thickness rectal prolapse. (Redrawn, with permission, from Fry RD, Kodner IJ. Anorectal diseases. *Clin Symp*. 1985;37(6):2–32. Copyright 1985, Academy of Medical Sciences. Originally illustrated by John Craig, MD.)


**TABLE 39-2: DEFECOGRAPHY GRADING SYSTEM<sup>a</sup>**

Grade	Description
N	Rectum remains fixed to sacrum, sphincter relaxes, and rectum empties
1	Nonrelaxation of puborectalis
2	Mild intussusception or mobility from sacrum
3	Moderate intussusceptions
4	Severe intussusceptions
5	Prolapse
R	Rectocele

<sup>a</sup> Lateral view on videofluoroscopy unit of patient in sitting position, passing thickened barium.

Reproduced, with permission, from Kodner IJ, Fry RD, Fleshman JW. Rectal prolapse and other pelvic floor abnormalities. *Surg Annu.* 1992;24:157–190.

of the defecating process; this is particularly helpful in cases in which mucosal prolapse is suspected and the intent is to rule out full rectal prolapse. Triple-contrast cinedefecography (rectum, vagina, and small bowel and bladder as needed) also helps delineate complex pelvic floor abnormalities. This technique is gradually being replaced, or at least supplemented, by dynamic MRI and three-dimensional (3D) ultrasound of the pelvic floor.

A grading system of intussusception has been developed to assist one in planning management (Table 39-2). Mild to moderate intussusception with some mobility, some funnel formation, and descent of the rectum can usually be treated conservatively. However, grade 4 intussusception with severe outlet obstruction may require operative resection of the redundant rectum or rectopexy to secure the rectum to the sacrum.<sup>21</sup> The most appropriate setting for operative treatment of internal intussusception is the patient who has developed moderate incontinence from the intussusception and straining or the patient who has severe bleeding from the solitary rectal ulcer at the tip of the funnel.

Anal manometry can be useful to document the preoperative function of the sphincter if there is not an obvious patulous anal canal on examination. PNTMLs provide objective evidence of pudendal nerve injury and allow some prediction of continued recovery after repair.

## Management

**Rectal Prolapse.** There are numerous techniques for management of rectal prolapse; over 100 procedures have been described. The four basic types of procedures include rectopexy, low anterior resection, perineal proctectomy, and anal encirclement procedures.<sup>22</sup>

Rectopexy relies on foreign material or sutures to attach the rectum to the sacrum. The rectum is mobilized down to

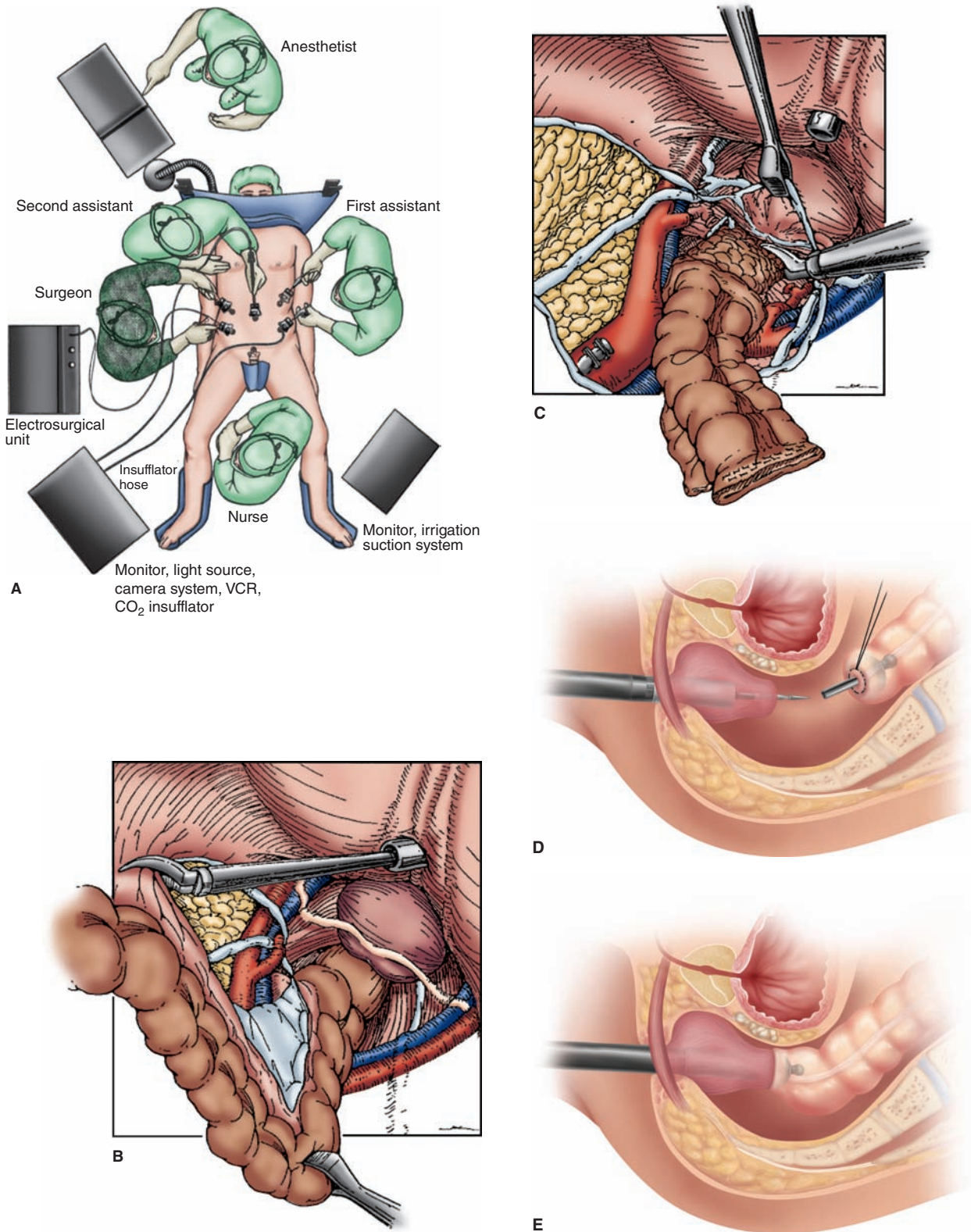
the pelvic floor, and the rectum is stretched out of the pelvis to fit into the curve of the sacrum. For patients who report constipation preoperatively, the redundant sigmoid colon and rectum may be removed. The low anterior resection technique uses the standard technique for removal of the middle and upper portions of the rectum and redundant sigmoid colon. The left colon is reattached to the upper or middle third of the rectum by using either a double-staple or hand-sewn technique (Fig. 39-10). The rectum is mobilized to the level of the pelvic floor circumferentially, but preserving the anterolateral ligaments carrying the middle rectal arteries and splanchnic nerves. The left colon and rectum (now in continuity) are returned to the curve of the sacrum. The incidence of fecal incontinence may be higher after this procedure because the rectal capacitance is reduced. As well, postoperative evacuation difficulties may be noted if the anterolateral ligaments have been divided. Preoperative anal physiological testing may assist in the selection of patients who are candidates for low anterior resection (ie, no evidence of sphincter injury or dysfunction).

Suture rectopexy with or without sigmoid resection in patients with constipation-associated rectal prolapse have low recurrence rates in well-selected patients. Laparoscopic rectopexy is a reasonable alternative that may be associated with fewer complications and a shorter hospital stay.<sup>23,24</sup> A technique of anterior Prolene mesh rectopexy has been described by D'Hoore, which only mobilizes the anterior rectum to the anal canal and suspends the rectum with the mesh with sutures placed along the anterior rectum at the level of the rectovaginal septum and attached to the sacral promontory. The redundant cul-de-sac is excised and the peritoneum is closed over the mesh along its length.<sup>25</sup>

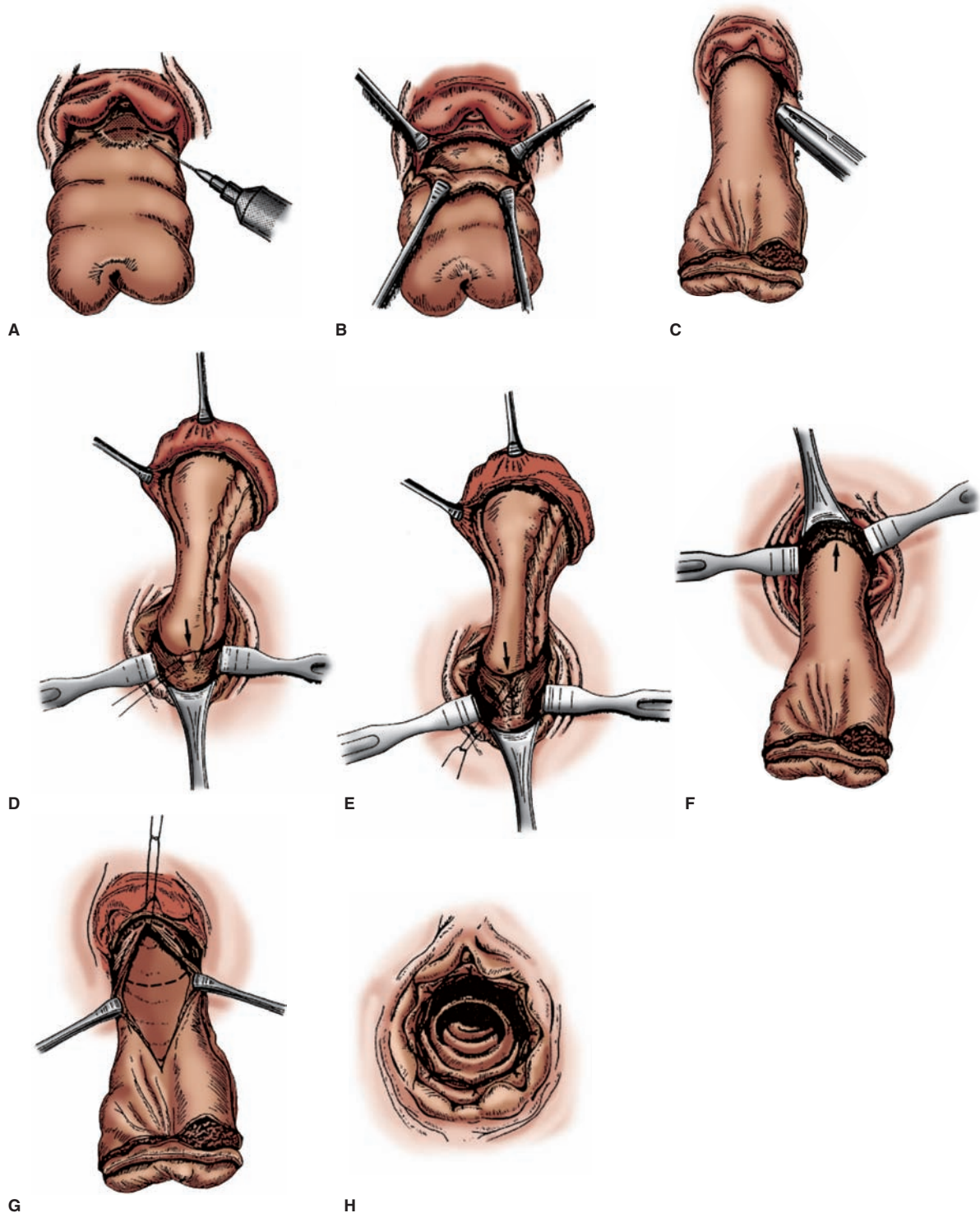
The use of a perineal proctectomy with anterior and posterior reefing of the sphincter muscle has become more popular for the treatment of rectal prolapse in the elderly patient with full rectal prolapse and comorbidities. This is a revival of the Altemeier perineal resection technique. The entire prolapsing rectum and redundant sigmoid are removed through a perineal approach beginning at the top of the transitional zone columns (Fig. 39-11). The left colon or proximal sigmoid is sutured to the transitional zone 1–2 cm above the dentate line. The external anal sphincter and pelvic floor muscles can be reefed in the anterior and posterior midline to restore anal tone in patients with incontinence as described by Prasad et al.<sup>26</sup> The incidence of recurrent prolapse is approximately 10% in patients with good sphincter function. Even though the operation is generally recommended for elderly patients, it may be appropriate for patients of all ages with severe compromise of sphincter tone and pronounced procidentia. This procedure is not technically possible in patients who have mucosal prolapse alone or patients with high rectal prolapse and an intact anal canal and normal sphincter.

Anal encirclement procedures have been mostly replaced by the perineal proctectomy. The anal encirclement procedure using synthetic material such as nylon mesh should be limited to the extremely debilitated patient or the elderly





**FIGURE 39-10** Laparoscopic low anterior resection with colorectal anastomosis—double-staple technique. **A.** Laparoscopic positioning of the patient and surgeon. The patient is secured to the table in modified lithotomy position. The operating surgeon stands to the right of the patient. Trocar placement is based on use of hand-assisting devices and surgeon preference. **B.** Lateral approach to mobilization and dissection of the sigmoid colon and identification of the left ureter. **C.** Laparoscopic mobilization and dissection of the rectum down to the lateral ligaments. **D.** Intracorporeal colorectal anastomosis: a descending colon purse-string suture is tied around the shaft of the anvil. This can also be performed extracorporeally with a hand-assisting device or via a small incision. **E.** Completed anastomosis with stapler still in place.



**FIGURE 39-11** Perineal proctectomy. **A.** Patient in the prone jackknife position. After gentle traction is applied on the rectal wall, a diluted epinephrine solution is injected into the outer layer of the prolapsed rectal wall. **B.** A circular incision is made through the full thickness of the outer layer of the prolapsed segment just proximal to the everted dentate line. **C.** The rectal prolapse has been completely unfolded. The mesenteric vessels are carefully ligated close to the bowel wall. **D.** The rectum is elevated anteriorly to expose the presacral space. A posterior rectopexy is performed (*arrow*) by approximating the seromuscular layers of the bowel wall to the coccygeal fascia above the levator ani muscles. **E.** The levator ani muscles are approximated posteriorly (*arrow*). This repair pushes the bowel anteriorly to help recreate the anorectal angle. **F.** One or two sutures are used to approximate the levators anterior to the rectum to reinforce the pelvic floor. **G.** The prolapse is amputated and the colon is sutured to the dentate line in a circumferential fashion (*dotted line*). **H.** Completed anastomosis. (Reproduced, with permission, from Prasad ML, Pearl RK, Abcarian H, Orsay CP, Nelson RL. Perineal proctectomy, posterior rectopexy, and postanal levator repair for the treatment of rectal prolapse. *Dis Colon Rectum.* 1986;29:547.)



patient who cannot withstand perineal proctectomy. It can be effectively performed under local anesthesia in patients with prohibitive surgical risks and decreased life expectancy.

## Internal Intussusception of the Rectum

The treatment of internal intussusception of the rectum is primarily conservative with use of a high-fiber diet. High doses of psyllium may prevent formation of the funnel and outlet obstruction with normalization of bowel function. Patients with pelvic floor outlet obstruction (nonrelaxation of the puborectalis) may benefit from biofeedback. In patients without pelvic floor outlet obstruction and with severe symptoms from the intussusception (ie. bleeding or incontinence), an operation may be considered. A low anterior resection or rectopexy is appropriate for these patients depending on whether they have constipation or incontinence, respectively. The treatment of a bleeding solitary rectal ulcer by low anterior resection sometimes requires an ultralow anterior resection and coloanal anastomosis in the setting of an extremely thickened anterior rectal wall that overwhelms even the thickest staple height. Perineal proctectomy is not recommended because the sphincter mechanism is intact and resection of redundant rectum will be extremely difficult in patients with an incomplete prolapse. Tests that are obtained prior to operation for internal intussusception include colonic transit times to document normal colonic transit, defecography that shows the level of the funnel formation within the rectum, and a balloon expulsion test to eliminate pelvic floor outlet obstruction as a cause of the intussusception.

The use of transanal stapling (STARR [(stapled transanal rectal resection)] or Transtar) procedures has become popular in Europe. Patient selection is important as those with other abnormalities such as enteroceles, larger rectoceles, or nonrelaxation of the puborectalis were found not to have good response after the STARR procedure.<sup>27</sup> Complications include bleeding, perineal pain, recurrence, or incontinence. In a trial comparing STARR versus biofeedback, the STARR procedure was found to be more effective in improving symptoms of obstructed defecation. It may be performed in unhealthy individuals under local by a properly trained individual after failure of biofeedback.<sup>28</sup>

## PELVIC FLOOR OUTLET OBSTRUCTION AND SOLITARY RECTAL ULCER SYNDROME

### Pathophysiology

The presenting complaints of patients with pelvic floor outlet obstruction usually include some form of constipation and straining. Defecation is a learned process and pelvic floor outlet obstruction may be either a change in the defecating mechanism or a failure to learn the appropriate series of events

to allow normal function. The muscle of the pelvic floor is completely normal, but the function and control are abnormal. There may be a psychologic influence in this syndrome because patients who have been sexually abused or have been psychologically traumatized may develop this outlet obstruction. The need to dominate and control has also been documented in these patients. The syndrome results from obstruction of the anal canal due to anterior displacement of the puborectalis muscle and contraction of the pelvic floor and external sphincter during straining to defecate. Attempts to defecate against a closed pelvic floor result in chronic funnel formation of the rectum and descent of the anterior rectal wall into the anal canal. This chronic trauma and ischemia may lead to the formation of an ulcer on the anterior wall of the rectum. The stimulus to defecate is often neglected. The end result is an uncoordinated effort at defecation with pelvic floor obstruction of the outlet, even as the rectum begins to distend and the autonomic muscles begin to relax.

It is possible that pelvic floor outlet obstruction is etiologically related to rectal prolapse and intussusception. However, no long-term studies have provided conclusive evidence. Patients may also present with megarectum from outlet obstruction, fecal incontinence due to nerve injury from chronic straining, or severe mucosal prolapse or hemorrhoids.

The solitary rectal ulcer is assumed to be due to ischemia of an isolated portion of the anterior rectal wall, approximately 10 cm above the anal verge, which prolapses partially into the anal canal and becomes ischemic during prolonged straining. The healing process may occasionally incorporate mucosal glands beneath the new mucosal surface and form a localized area of colitis cystica profunda. These entrapped glands continue to produce mucus and are occasionally mistaken for an early neoplasm of the rectum.

### Diagnosis and Evaluation

Patients with pelvic floor outlet obstruction may complain of a number of problems that include constipation and straining at defecation, the need for digital maneuvers to evacuate the rectum, bleeding, mucosal prolapse, and hemorrhoids. They occasionally present with chronic pain of the anal canal and symptoms of severe spasm of the anal canal and pelvic floor. In the past this was classified as anismus, proctalgia fugax, or levator ani syndrome. Digital rectal examination may reveal paradoxical motion (tightening instead of relaxing) of the puborectalis muscle during attempts to push the finger out of the rectum. Defecography generally shows a persistent puborectalis impression on the posterior rectum as the patient attempts to evacuate the rectal contents. Defecography tends to overdiagnose the problem of nonrelaxing puborectalis. This may be due to an unnatural setting in a cold radiology suite or possible patient embarrassment. The presence of nonrelaxing puborectalis muscle must therefore be confirmed using some other technique. The method best suited to our practice has been to have the patient expel a 60-mL air-filled soft latex balloon while sitting in a private bathroom. This simple



technique of expulsion of the balloon within the confines of a private bathroom seems to be adequate.<sup>29</sup> Surface EMG is also useful in the diagnosis and treatment of nonrelaxing puborectalis muscle, as it documents decreased pelvic floor electrical activity during proper straining techniques and an increase during paradoxical contraction. Colonic transit study will demonstrate accumulation of all of the administered radiopaque markers within the rectum after an elapsed period adequate for clearance (>7 days). An algorithm used to deal with pelvic floor disorders is shown in Fig. 39-12.

## Treatment and Management

The initial steps in the treatment of outlet obstruction problems include high doses of fiber and establishment of a normal bowel routine. Outpatient biofeedback using surface EMG, balloon expulsion, sensation techniques, and a simulated stool are also effective in severe cases of nonrelaxing puborectalis muscle.<sup>30</sup> Psychological counseling

and relaxation techniques may be of help in patients who have a psychological component to their problem.

## RECTOCELE, ENTEROCELE, AND COMPLEX PELVIC FLOOR ABNORMALITIES

Outpouching or bulging of the rectum into the vagina (rectocele) can be seen on defecography in patients with pelvic floor disorders. These findings, however, can also be found in patients without any pelvic or bowel complaints. Surgical repair does not always lead to resolution of symptoms. No predictors of successful outcome of surgery are universally accepted from various studies examining characteristics on defecography and symptomatology. Surgical technique is the surgeon's preference and can be performed via a transanal, transvaginal, or perineal approach to bolster, plect, and reconstruct the muscle in the rectovaginal

**Symptoms:** Constipation, straining, digital maneuvers, rectal pressure

**Tests:** Colonic transit, defecography, balloon expulsion, proctosigmoidoscopy

### Results:

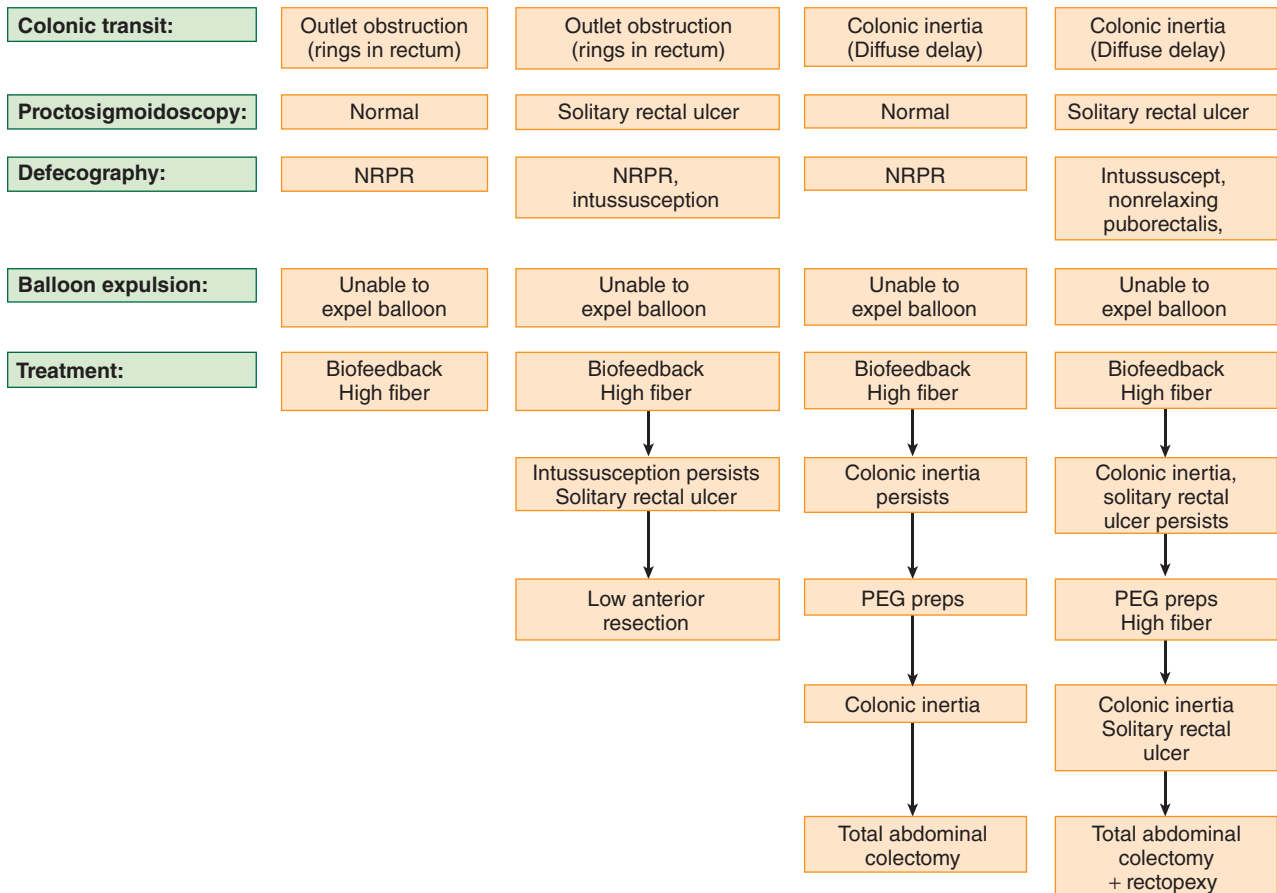


FIGURE 39-12 Algorithm for diagnosis and treatment of pelvic floor outlet obstruction. NRPR, nonrelaxing puborectalis.

septum. Fortunately, the majority of patients improve with medical management.<sup>31,32</sup> Rectoceles occurring in patients with rectal prolapse generally resolve after repair of the prolapse as long as the rectum is mobilized all along the rectovaginal septum.

Enteroceles or bulging of small bowel into the recto-genital area can also be detected on defecography. This is a common finding in patients who are status post hysterectomy, in patients with symptoms of obstructive defecation, or in asymptomatic patients. An enterocele can be repaired transabdominally in conjunction with operative management of other pelvic floor abnormalities by reefing or excising and reclosing the redundant pelvic peritoneum to prevent herniation of small bowel into the pelvic floor.

Pelvic floor disorders may also involve bladder or gynecological complaints. A multidisciplinary team approach for evaluation and operative management of complex pelvic floor abnormalities may include a urogynecologist for bladder or vaginal suspension in addition to rectopexy/resection, and pelvic floor suspension. Dynamic MRI may be a useful modality for the diagnosis of some of these challenging pelvic floor cases.<sup>33</sup> High-resolution 3D endovaginal and endorectal ultrasonographies are increasingly being used for evaluation of pelvic floor disorders.<sup>34,35</sup>

## HEMORRHOIDS

Current theories about the development of hemorrhoids consider the nature of anal “cushions.” Such cushions are aggregations of blood vessels (arterioles, venules, and arteriolar-venular communications), smooth muscle, and elastic connective tissue in the submucosa that normally reside in the left lateral, right posterolateral, and right anterolateral anal canal.<sup>36</sup> Smaller discrete secondary cushions may reside between the main cushions. Hemorrhoids are likely the result of a sliding downward of these anal cushions. Hemorrhoids provide tissue to close the anal canal during rest. It appears that the disintegration of the anchoring and supporting connective tissue and the terminal fibers of the longitudinal muscle above the hemorrhoids allows these structures to slide distally.

### Classification

Anal skin tags are discrete folds of skin located at the anal verge. These may be the end result of resolved thrombosed external hemorrhoids or, more rarely, may be associated with inflammatory bowel disease. Internal hemorrhoids reside above the dentate line and are covered by transitional and columnar epithelium (Fig. 39-13). First-degree internal hemorrhoids cause painless bleeding with defecation. Second-degree hemorrhoids protrude through the anal canal at the time of defecation but spontaneously reduce. Third-degree internal hemorrhoids protrude and bleed with defecation, but they must be manually reduced. Fourth-degree internal

hemorrhoids are permanently fixed below the dentate line and cannot be manually reduced.

External hemorrhoids consist of the dilated vascular plexus located below the dentate line and are covered by squamous epithelium. Mixed hemorrhoids are composed of elements of both internal and external hemorrhoids.

### Evaluation of Internal Hemorrhoids

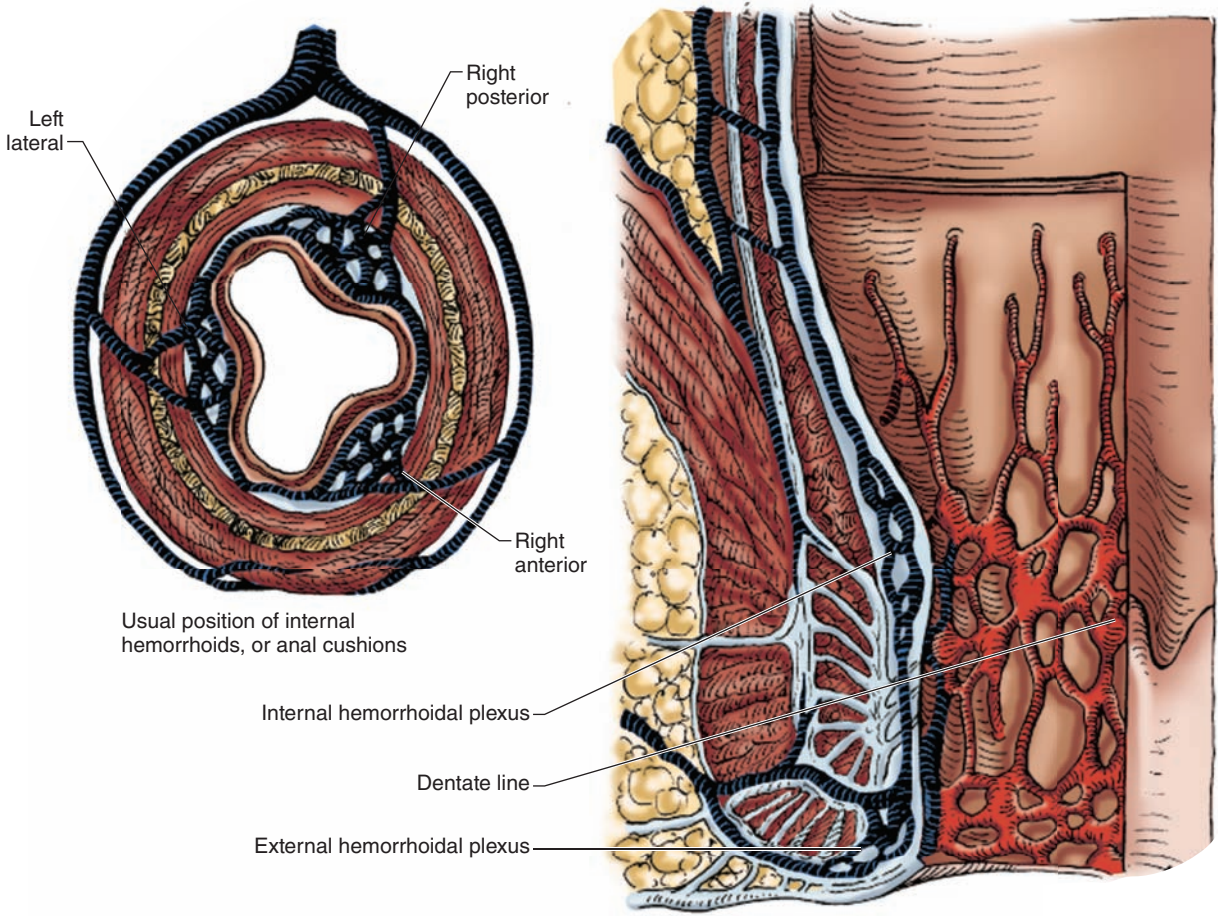
Even though internal hemorrhoids are the most common source of rectal bleeding, it is imperative that other causes be excluded. Because internal hemorrhoids cannot be detected by digital examination, diagnosis can only be made by anoscopy. It is mandatory that colonoscopy be performed in high-risk patients to exclude other sources of bleeding, such as carcinoma or proctitis (eg, for patients aged >40 years and those with a personal or family history of colorectal neoplasia or a change in bowel habits).

### Treatment

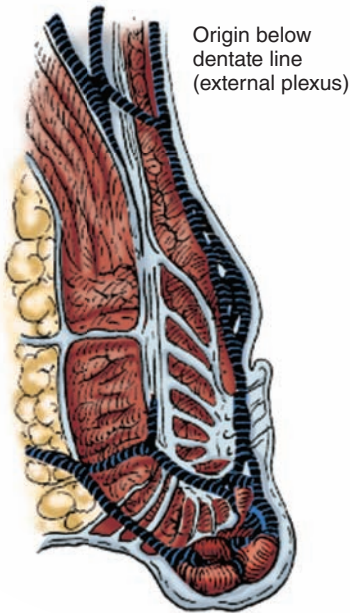
Regulation of diet and avoidance of prolonged straining at the time of defecation comprise the initial treatment of mild symptoms of bleeding and protrusion. Increasing the fiber content of the diet to at least 25–35 g daily with raw vegetables, fruits, whole-grain cereals, and hydrophilic bulk-forming agents can reduce and often alleviate all symptoms. If bleeding and protrusion persist, however, the hemorrhoids should be treated surgically.

Elastic ligation of the friable redundant hemorrhoidal tissue is quite satisfactory for first-, second- and third-degree hemorrhoids. The procedure is quite simple. The hemorrhoid is visualized with the aid of an anoscope and grasped with forceps. The redundant tissue is pulled into a double-sleeved cylinder on which there are two latex bands. The bands are discharged from the cylinder, and the hemorrhoidal bundle is ligated (Fig. 39-14).

Certain precautions, however, must be taken with this form of treatment. The ligatures must be placed at least 1–2 cm above the dentate line to avoid extreme discomfort. Ideally, the ligatures should be placed at the top of the hemorrhoidal cushion. About 25% of patients experience mild, dull anorectal discomfort lasting for 2–3 days following the procedure. Mild analgesics and warm baths are usually sufficient to relieve the discomfort. In about 1% of patients, brisk bleeding that may require suture ligation occurs when the necrotic tissue sloughs off at 7–10 days. About 2% of patients treated with ligation of the internal hemorrhoid develop thrombosis of an external hemorrhoid, which may cause considerable discomfort. Necrotizing pelvic or perineal sepsis is rare and almost always associated with immune compromise but must be immediately recognized in the setting of increased pain, fever, or urinary dysfunction. Treatment requires immediate examination under anesthesia for debridement of all necrotic tissue, intravenous antibiotics, and observation

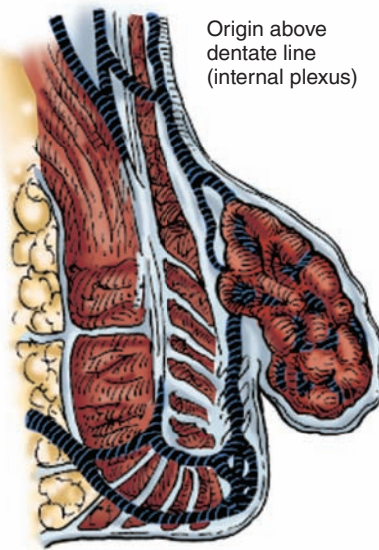


**Types of hemorrhoids**



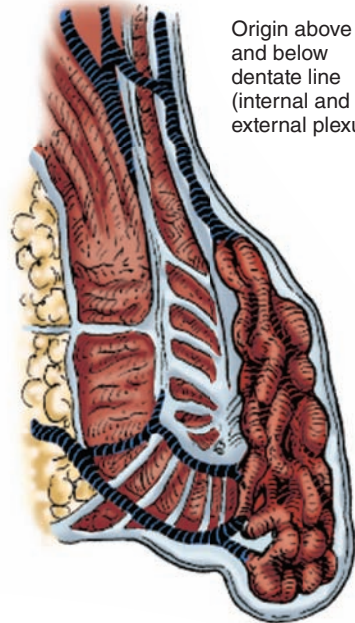
Origin below dentate line (external plexus)

External hemorrhoid



Origin above dentate line (internal plexus)

Internal hemorrhoid



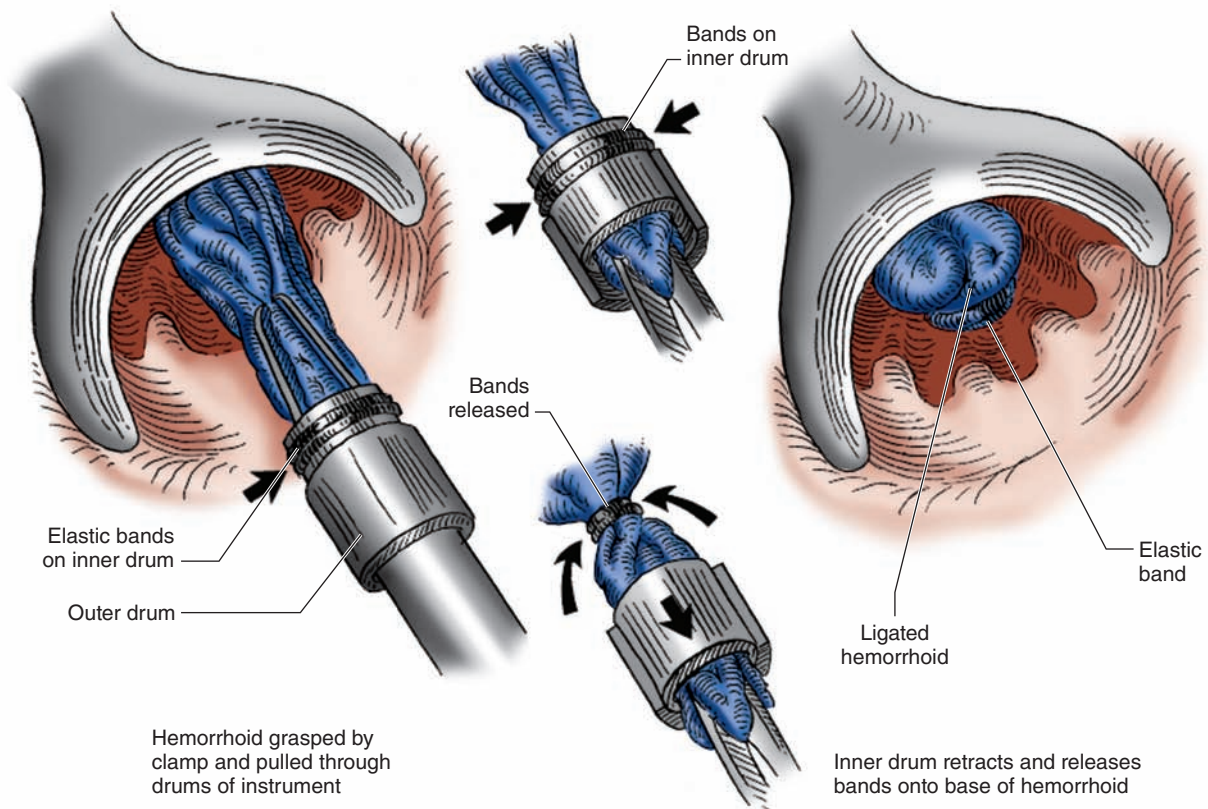
Origin above and below dentate line (internal and external plexus)

Mixed hemorrhoid

**FIGURE 39-13** Location and types of hemorrhoids. (Redrawn, with permission, from Fry RD, Kodner IJ. Anorectal diseases. *Clin Symp.* 1985;37(6):2-32. Copyright 1985, Academy of Medical Sciences. Originally illustrated by John Craig, MD.)



## Elastic ligation technique



**FIGURE 39-14** Elastic ligation technique. (Redrawn, with permission, from Fry RD, Kodner IJ. Anorectal diseases. *Clin Symp*. 1985;37(6):2–32. Copyright 1985, Academy of Medical Sciences. Originally illustrated by John Craig, MD.)

in the intensive care unit. Patients with poorly functioning neutrophils or reduced numbers of white blood cells for any reason should be treated with another method or at least warned of and observed for the occurrence of this potentially life-threatening complication.

Hemorrhoidal ligation is an office procedure, and no special preparation is required. Patients with a bleeding diathesis or with portal hypertension are not good candidates for ligation. Usually only one hemorrhoid is ligated on the first treatment visit. Ligations can be performed every 2–4 weeks until all symptoms of bleeding or prolapse are alleviated. The second ligation can be multiple if the first treatment is well tolerated. Other minimally invasive procedures such as infrared coagulation, diathermy coagulation, and ultrasound-guided vascular pedicle ligation achieve the same result with variable success and need for effort.

Although diet, bowel regulation, or elastic ligation will alleviate most symptoms of internal hemorrhoids, occasionally further surgical treatment may be needed. Excisional hemorrhoidectomy is indicated for large, mixed (combined internal/external) hemorrhoids that are not amenable to ligation because the ligature would have to incorporate pain-sensitive tissue at or below the dentate line.

Circular stapled hemorrhoidectomy is a newer technique indicated for the elective treatment of circumferential third- and fourth-degree hemorrhoids that are not permanently prolapsed due to scar.<sup>37</sup> This involves placing a purse-string suture incorporating the mucosa of the anal canal with a stapled circumferential mucosectomy at a level 4–5 cm above the dentate line. This can be performed under regional anesthesia with minimal morbidity in experienced hands. Potential complications include bleeding if the staple line is incomplete, pain if the staple line is too close to the dentate line, rectovaginal fistula if the purse string captures the rectovaginal septum, complete closure of the rectum if the stapler and purse string are malpositioned, and return of symptoms if the purse string is incomplete.

Occasionally, the internal hemorrhoidal tissue may be incarcerated outside the anal canal, resulting in spasm of the anal sphincter, massive local edema, and severe pain. In such circumstances, the edematous tissue may be injected with a local anesthetic containing epinephrine. Dissipation of the edema by manual compression then can be achieved, allowing reduction in the prolapsed tissue. Observation and use of stool softeners with tub soaks usually allow the acute episode to resolve without an operation because the hemorrhoidal

vessels have been naturally thrombosed. The thrombosed internal hemorrhoids will sclerose and may not require surgery. If symptoms persist or recur, a three-quadrant hemorrhoidectomy may then be necessary. If necrotic tissue is present at the time of acute thrombosis, emergent excisional hemorrhoidectomy is necessary. Care should be taken to preserve the anoderm. The patient should be kept in the hospital after the procedure until the pain is minimal and until spontaneous voiding is possible and to ensure resolution of any potential infection.

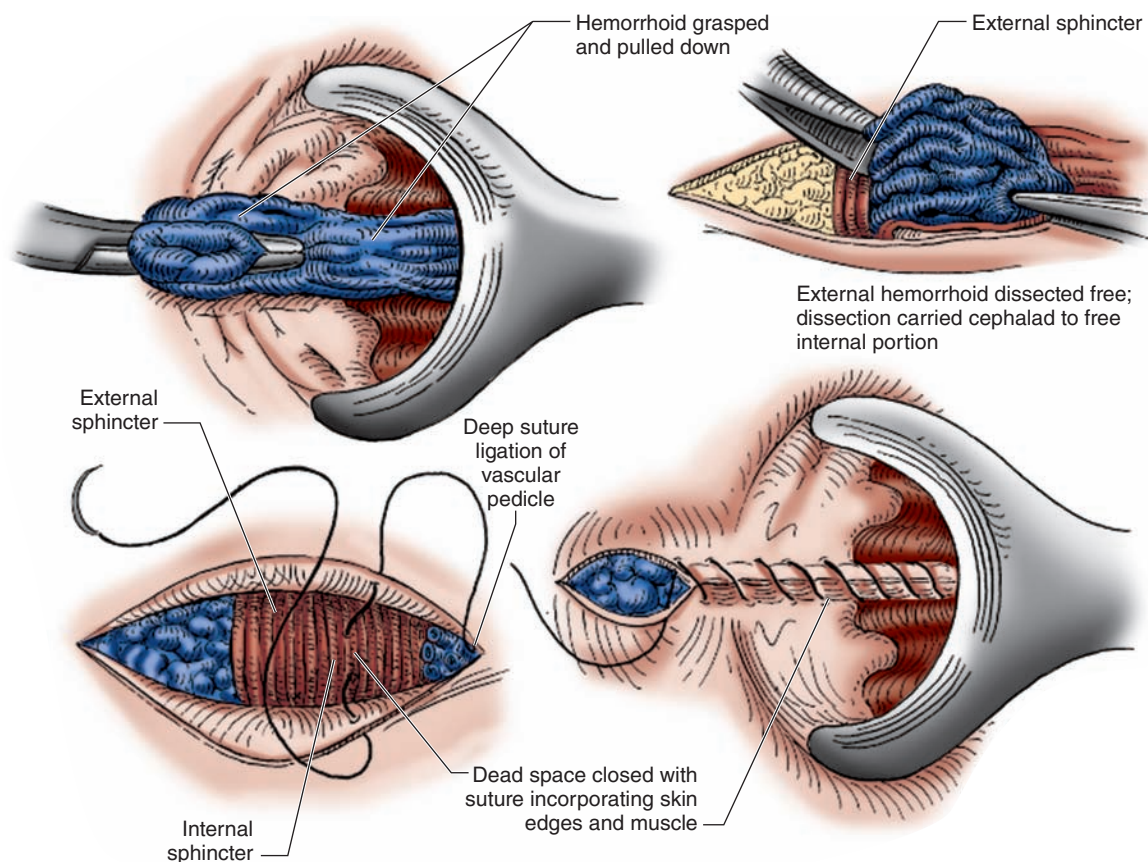
### MIXED HEMORRHOIDS

The mucosal component of mixed hemorrhoids occasionally can be treated by elastic ligation. Large symptomatic, non-reducing mixed hemorrhoids generally are treated by excisional hemorrhoidectomy. The patient is placed in the prone flexed position under local anesthesia using a perianal field block with 0.25% bupivacaine with or without epinephrine. The apex of the vascular pedicle is ligated first with a 3-0 chromic catgut suture. An elliptical excision incorporates the external and

internal hemorrhoids from the perianal skin to the anorectal ring. The hemorrhoidal tissue is sharply dissected from the underlying internal sphincter (Fig. 39-15). The entire wound is then closed by running the apex chromic catgut suture to the distal perianal skin edge. The largest hemorrhoid is excised first, with care taken not to excise excessive tissue that may result in a stricture. If there is any concern of leaving an adequate anal aperture covered by normal anoderm, it is best to modify a planned three-quadrant hemorrhoidectomy and instead perform a two-quadrant hemorrhoidectomy and band the remaining internal component.

### THROMBOSED EXTERNAL HEMORRHOIDS

The external venous plexus is located at the anal verge and encircles the anal canal. A segmental thrombus is confined to the anoderm and perianal skin and does not extend above the dentate line. The problem presents as a painful perianal mass. The overlying skin may be stretched to 2 cm or more. Pain usually peaks within 48 hours and generally becomes minimal after the fourth day. If untreated, the thrombus is absorbed



**FIGURE 39-15** Excision technique for mixed hemorrhoids. (Redrawn, with permission, from Fry RD, Kodner IJ. Anorectal diseases. *Clin Symp*. 1985;37(6):2-32. Copyright 1985, Academy of Medical Sciences. Originally illustrated by John Craig, MD.)

within a few weeks. The pressure of the underlying clot will occasionally cause the adjacent skin to become necrotic, and the clot will be extruded through the area of necrosis. This is noted by the patient as rectal bleeding followed by relief of the anal pain. A partially extruded clot can be removed in the office to provide relief.

Treatment of thrombosed hemorrhoids is aimed at relief of the pain. If symptoms are minimal, mild analgesics, sitz baths, proper anal hygiene, and bulk-producing agents will suffice. However, if pain is severe, excision of the thrombosed hemorrhoid may be beneficial. Because numerous vessels usually are involved, it is necessary to excise the entire mass along with the overlying skin and subcutaneous tissue. The wound is left open without packing. Postoperative care consists of mild analgesics and warm sitz baths or showers.

## ANAL FISSURE

An anal fissure is a split in the anoderm over the hypertrophied band of internal sphincter at the anal verge (Fig. 39-16). The fissure is almost always located close to the midline of the anal canal; in men, 95% are near the posterior midline and 5% near the anterior midline, whereas in women, about 80% will be located posteriorly and 20% anteriorly. The precise cause of an anal fissure has yet to be determined. However, fissures probably are related to tearing of the anoderm at the time of defecation. The increased anal canal pressure that accompanies an anal fissure is associated with ischemia in the area of the fissure and prevents healing, as spasm recurs with each bowel movement.<sup>38</sup> An anal ulcer is the chronic form of an anal fissure with heaped-up edges, sentinel skin tag, and occasionally hypertrophied anal papilla.

## Clinical Features and Diagnosis

Most fissures are superficial and heal rapidly with no specific treatment. Occasionally, the fissure may extend deeply through the anoderm to expose the fibers of the internal sphincter. Surprisingly, secondary infection rarely occurs.

Fissures that are aberrantly located may be caused by previous anal operations that result in scarring, stenosis, and loss of anoderm. Individuals with chronic diarrhea may develop anal stenosis associated with a fissure. Crohn's disease often is complicated by anal fissures, which may be a primary manifestation of the disease. These fissures usually are associated with the shiny anal skin tags typical of anal Crohn's disease and may lie laterally instead of close to the midline of the anus.

Patients with anal fissures usually complain of anal pain accompanying and following defecation. Bright red bleeding may accompany a bowel movement, although it is usually minimal. A slight discharge also may be present.

An anal fissure is detected by gently separating the buttocks to reveal the lower edge of the fissure at the anal verge,

where a sentinel tag also may be seen. A soft touch of a cotton swab to this area will elicit the pain and help with the diagnosis. A deep gluteal cleft or tight spasm of the sphincter may sometimes obscure the fissure, and, if the patient can tolerate, examination with a small anoscope may be required.

Anal sphincter hypertonicity and an increase in ultraslow waves on anal manometry characterize typical anal fissures.

## Treatment

Dietary recommendations and prescription of bulking agents to promote soft stools are beneficial, and warm tub soaks may provide comfort. The majority of acute fissures will heal with conservative management. The use of 2% nifedipine ointment applied to the anoderm outside the anal verge relaxes the sphincter and dilates local vessels to promote healing. Most of the remainder of acute fissures will heal with this added therapy.<sup>39</sup>

The injection of 20–25 units of botulinum A toxin into both edges of an anal ulcer and directly into the internal sphincter muscle at the ulcer base (total of 75–1000 units) is a simple procedure that has had some mixed success in healing anal fissures.<sup>40</sup> It can be done with local anesthesia as an outpatient procedure, with delay of symptomatic relief by approximately 1 week. The paralysis of the internal sphincter reverses in several months, but the fissure may recur. Repeat treatments can be performed if the initial response was adequate, but it is expensive with at best modest healing rates.

Surgical treatment may be required for deep, chronic fissures associated with a sentinel skin tag, hypertrophied anal papilla, and exposed internal sphincter. Excellent results can be achieved if the internal sphincter is divided laterally rather than in the midline. Furthermore, lateral sphincterotomy is not associated with keyhole deformity. Only the thickened band of the internal sphincter is divided (ie, partial sphincterotomy), which limits the amount of internal sphincter transection and reduces the potential for fecal incontinence.

Sphincterotomy can be performed under local anesthesia, using either an open or closed technique (Fig. 39-17). The open technique consists of radial incision of the anoderm over the intersphincteric groove and limited division of the internal sphincter only up to the proximal extent of the fissure under direct vision. The closed method entails dividing the internal sphincter by a subcutaneous approach. Both techniques may be used in the outpatient setting and afford rapid pain relief. Approximately 98% of fissures heal following sphincterotomy. However, there is a small incidence of fecal incontinence following the procedure, so careful patient selection is mandatory. Elderly patients with decreased anorectal sensation are generally not ideal candidates for internal sphincterotomy because of this risk. Consideration should be given to a diamond skin advancement flap to cover the ulcer bed in women. This flap requires isolation of a postage stamp-sized island of skin based on a subcutaneous fat pedicle from the inner aspect of the buttock posteriorly or the perineum anteriorly. The ulcer is excised leaving a defect in the size of the flap. The flap is advanced to



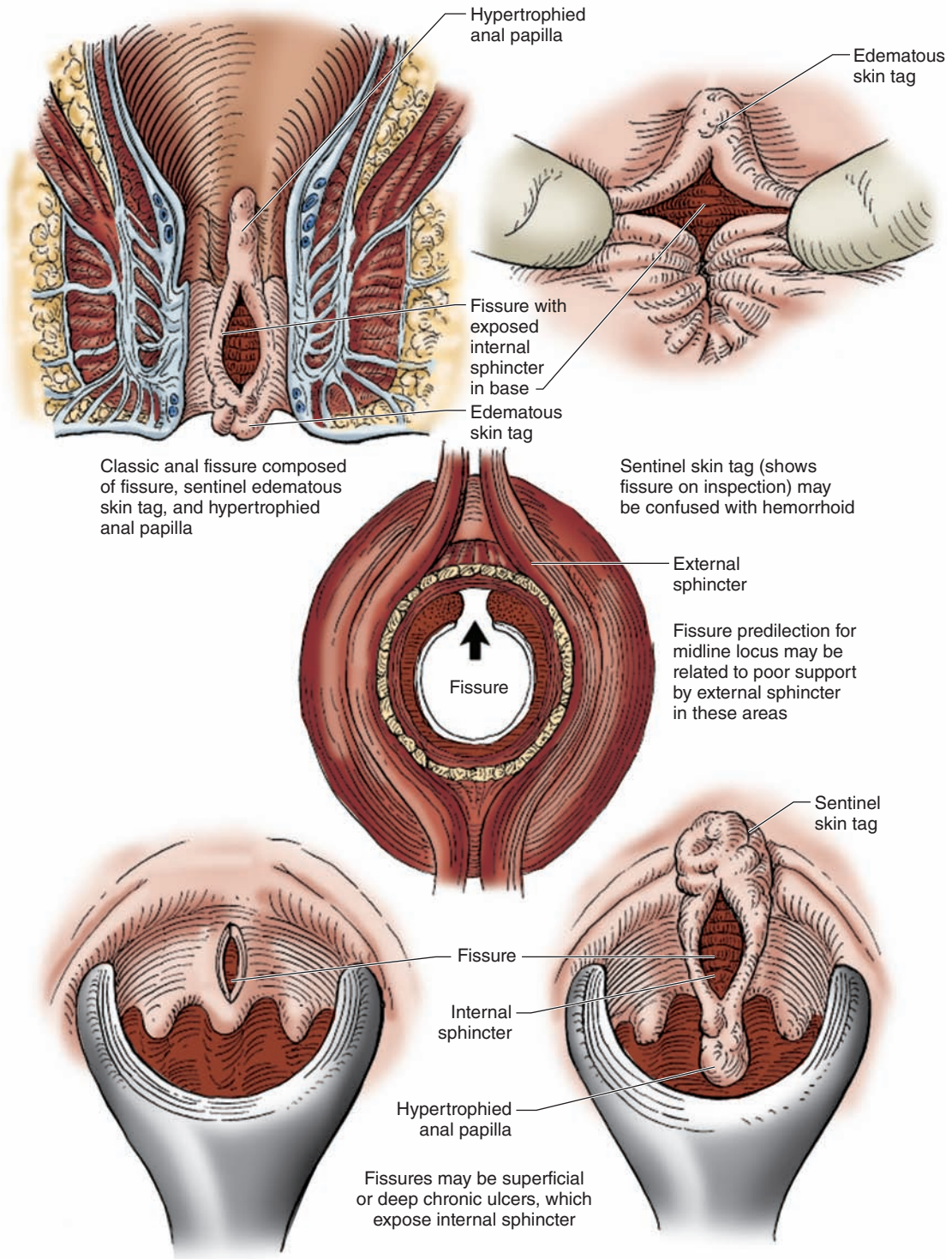


FIGURE 39-16 Anal fissure. (Redrawn, with permission, from Fry RD, Kodner IJ. Anorectal diseases. *Clin Symp.* 1985;37(6):2-32. Copyright 1985, Academy of Medical Sciences. Originally illustrated by John Craig, MD.)

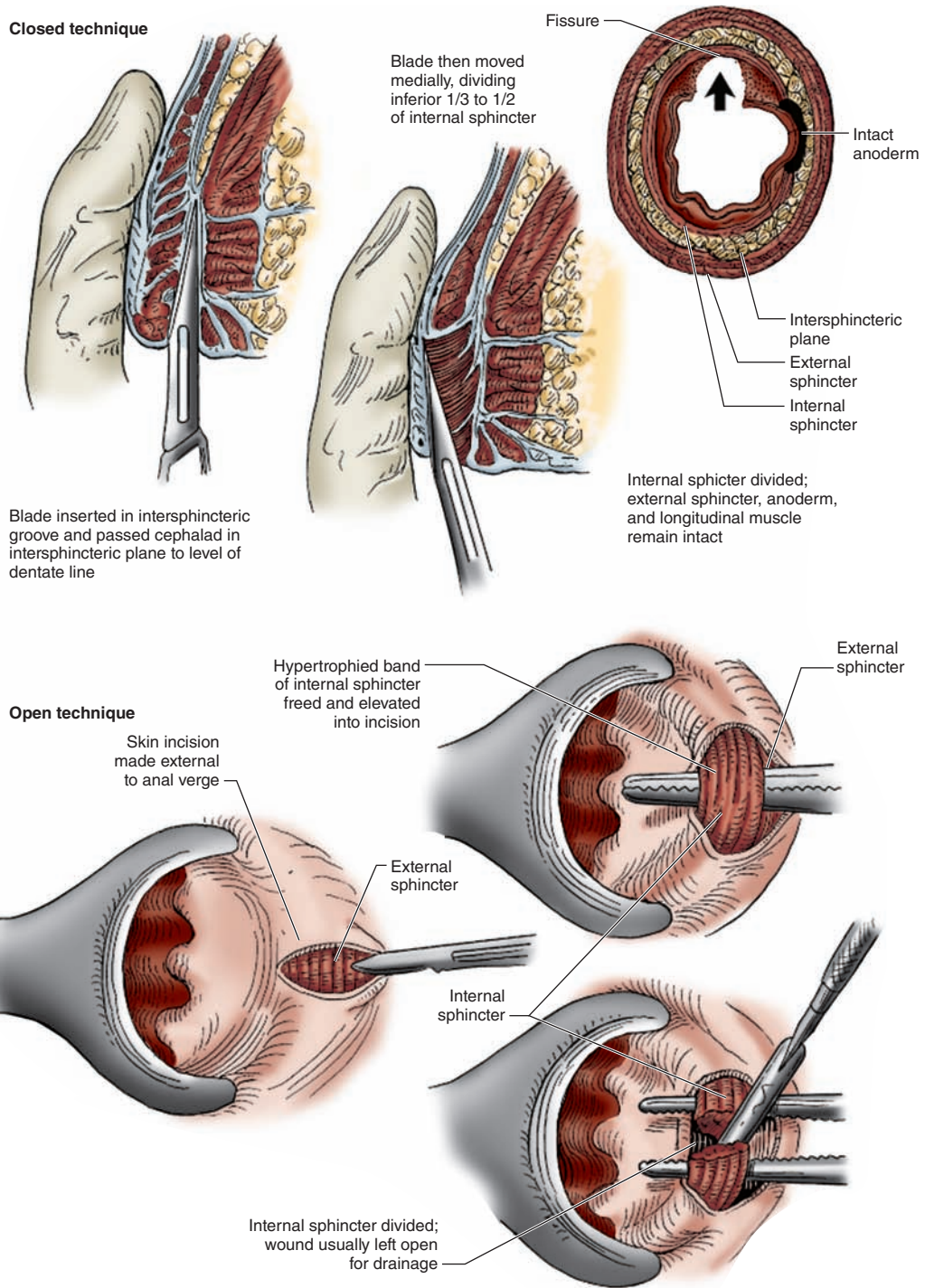
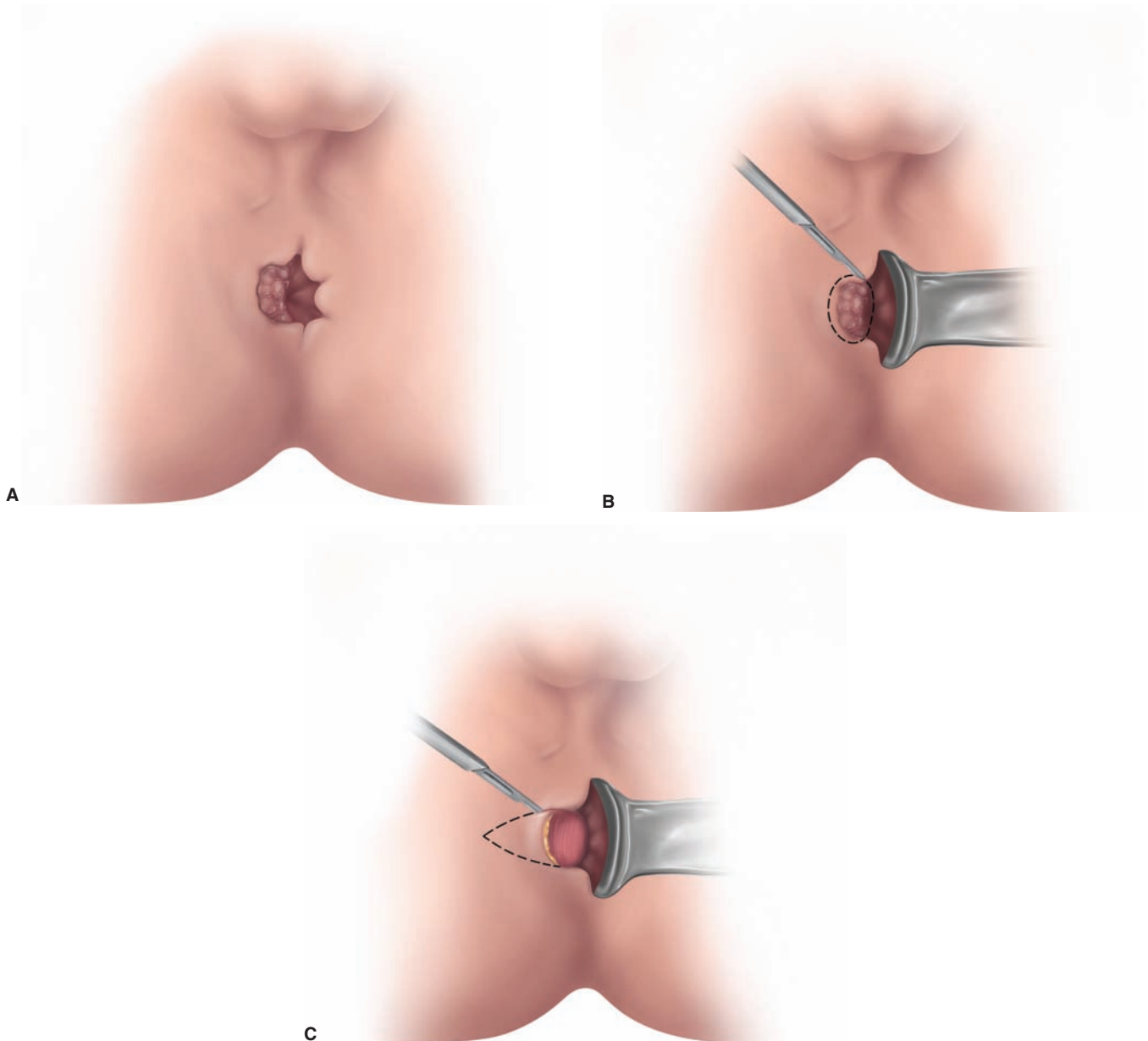


FIGURE 39-17 Lateral internal sphincterotomy. (Redrawn, with permission, from Fry RD, Kodner IJ. Anorectal diseases. *Clin Symp.* 1985;37(6):2-32. Copyright 1985, Academy of Medical Sciences. Originally illustrated by John Craig, MD.)



**FIGURE 39-18** Excision of mucosal ulcer and flap design. (Redrawn, with permission, from Caplin DA, Kodner IJ. Repair of anal stricture and mucosal ectropion by simple flap procedures. *Dis Colon Rectum*. 1986;29:92–94.)

the open area in the anoderm and secured to the freshly cut mucosal edges (Figs. 39-18 and 39-19).

## ANORECTAL ABSCESS AND ANAL FISTULA

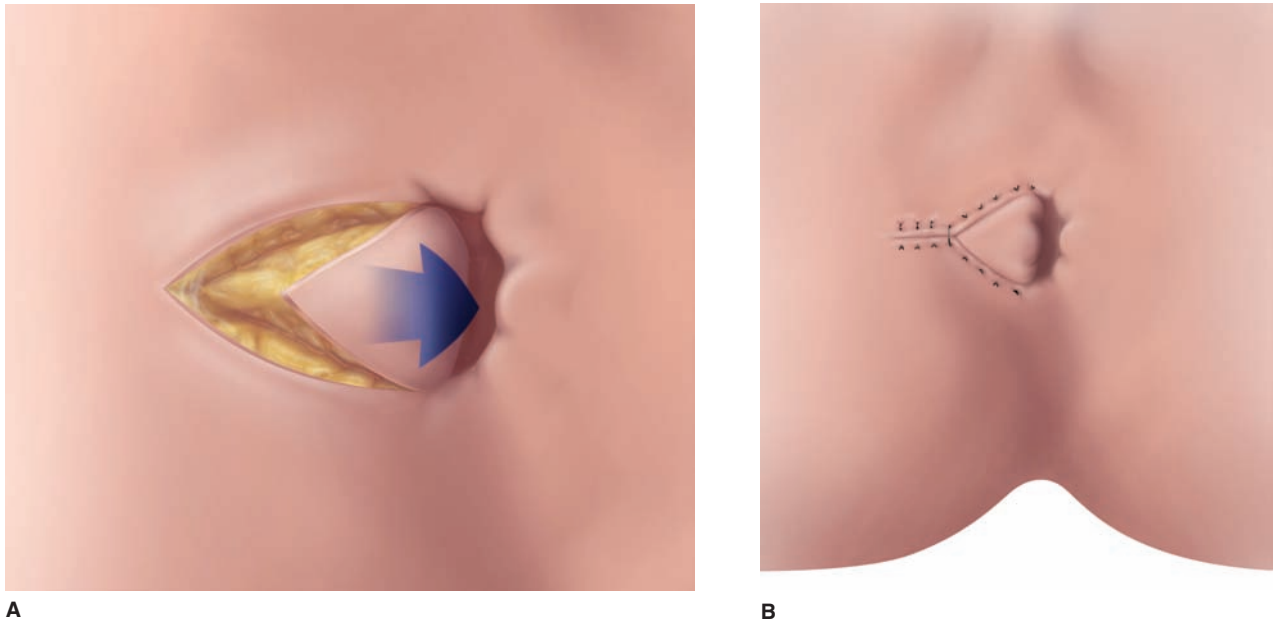
### Diagnosis and Classification

More than 95% of all anorectal abscesses are caused by infections arising in the anal glands that communicate with the anal crypts (cryptoglandular disease). The acute phase

of the infection causes an anorectal abscess, while the chronic stage is recognized as an anal fistula. The anal glands lie in the intersphincteric space between the internal and external anal sphincters. Inflammation of an anal gland leads to the formation of a local abscess in the intersphincteric plane. The clinical presentation, natural history, and proper treatment of anorectal abscess and fistula are understood easily if it is recognized that the disease originates as an intersphincteric abscess.

As the abscess enlarges, it escapes the confines of the intersphincteric plane and spreads in one of several possible directions (Fig. 39-20). The most common of all anorectal abscesses is a perianal abscess, which presents as a tender,





**FIGURE 39-19** Flap mobilization. (Redrawn, with permission, from Caplin DA, Kodner IJ. Repair of anal stricture and mucosal ectropion by simple flap procedures. *Dis Colon Rectum*. 1986;29:92–94.)

erythematous bulge at the anal verge. An ischio-rectal abscess is formed when a growing intersphincteric abscess penetrates the skeletal muscle of the external sphincter below the level of the puborectalis and expands into the fat of the ischio-rectal fossa. These abscesses can become quite large, because the levator ani (the upper border of the ischio-rectal fossa) slopes upward. Thus an ischio-rectal abscess may be palpated as a bulge above the puborectalis, although it actually lies below the levator ani musculature. In contrast to the perianal abscess, this abscess seldom presents as a visible bulge because of the large potential space in the ischio-rectal fossa. Thus the abscess preferentially expands upward rather than protruding through the skin of the buttock. Rarely, an intersphincteric abscess may expand upward between the circular internal sphincter and the external sphincter, forming a supralevator abscess.

## Treatment

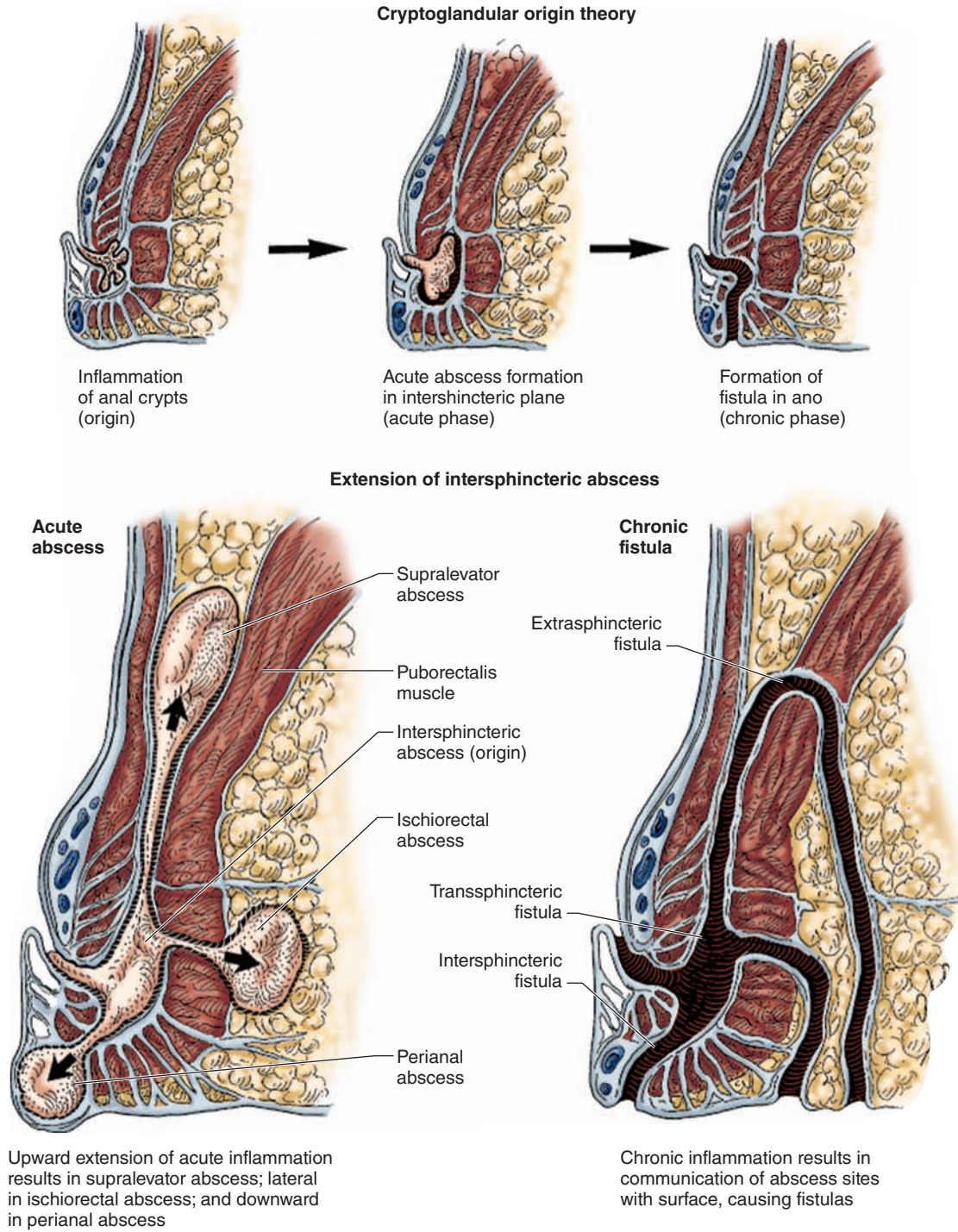
Perianal abscesses should be drained immediately, before wide fluctuance or cellulitis develops. Antibiotics are not indicated and should be used only in the presence of extensive cellulitis, valvular heart disease, diabetes, or compromised immunity. If the diagnosis is suspected but not readily evident, examination under regional anesthesia should be performed.

With adequate regional anesthesia, the abscess can be detected and localized by digital examination. An intersphincteric abscess is treated definitively by performing an internal sphincterotomy over the length of the abscess cavity, which serves to unroof and drain the abscess. However, if the infection

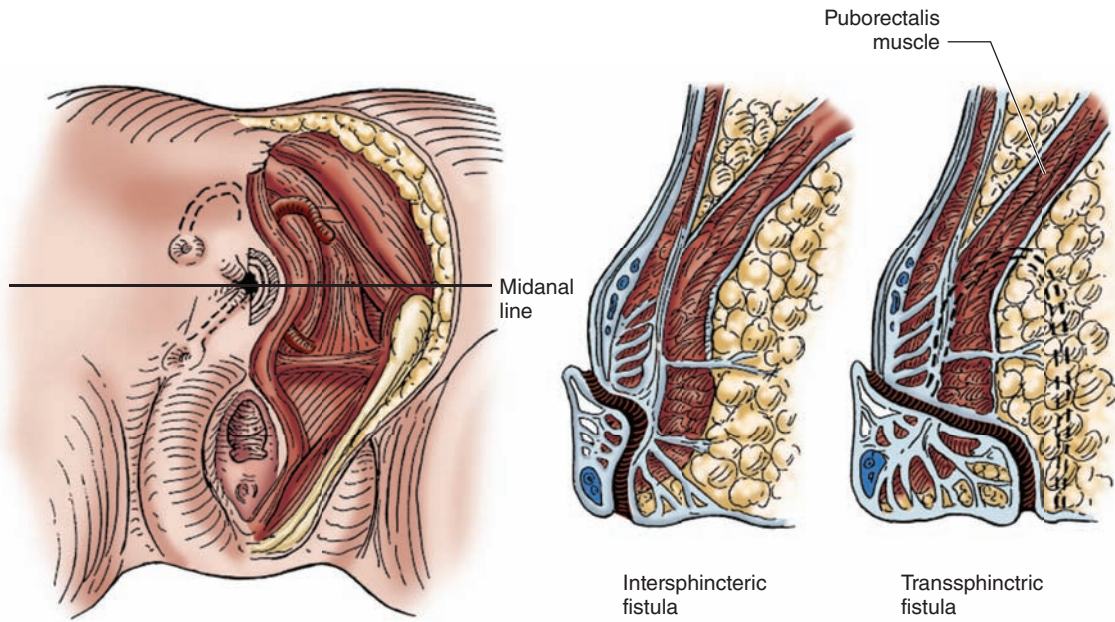
has developed into a perianal or an ischio-rectal abscess, adequate drainage of the abscess cavity first must be done by making a cruciate incision in the skin overlying the abscess as close to the anal canal as possible, or excising a small disc of overlying skin to permit complete evacuation of the contents of the abscess cavity. Incision and drainage alone will result in complete resolution of the infection in about half of patients. In the other half, an anal fistula occurs, which consists of a chronically infected tract with an internal opening located in a crypt at the level of the dentate line and an external opening located at the drainage site of the earlier abscess.

The appropriate treatment for an anal fistula is dependent on the anatomy and the location of the fistula tract. Good-sall's rule states that if the anus is bisected by a line in the frontal plane, an external opening anterior to the line (within 2 cm of the anal verge) will connect to an internal opening by a short, direct fistula tract (Fig. 39-21). However, if the external opening is located posterior to this imaginary line or anteriorly but outside 2 cm from the anal verge, the fistula tract follows a curved course to the crypt in the posterior midline. This rule, while useful, is not infallible.

Occasionally, an external opening located more than 2 cm from the anal verge anterior to the imaginary bisecting line connects to an internal opening in the posterior midline. Because of its shape, this fistula is usually called a *horseshoe fistula*. Horseshoe fistulas usually have an internal opening in the posterior midline of the anus and may extend anteriorly and laterally to both ischio-rectal spaces by way of the deep space. The posterior opening is incised into the postanal space to deal with the primary cause. The anterior extensions of the horseshoe tracts then can be drained by a secondary



**FIGURE 39-20** Anorectal abscess and fistula-in-ano cryptoglandular origin theory. (Redrawn, with permission, from Fry RD, Kodner IJ. Anorectal diseases. *Clin Symp.* 1985;37(6):2-32. Copyright 1985, Academy of Medical Sciences. Originally illustrated by John Craig, MD.)

**Goodsall's rule**

Fistulas with external openings anterior to midanal line connected to internal opening by short, straight tract. Posterior external openings follow curved course to internal opening in posterior midline

Surgical management of intersphincteric and low (below puborectalis) transsphincteric fistulas involves unroofing tract. Only internal sphincterotomy in first case; internal sphincterotomy involving portion of external sphincter in latter case. Division of puborectalis muscle results in incontinence, so high fistulas are not treated by sphincterotomy

**FIGURE 39-21** Surgical management of fistula-in-ano. (Redrawn, with permission, from Fry RD, Kodner IJ. Anorectal diseases. *Clin Symp.* 1985;37(6):2–32. Copyright 1985, Academy of Medical Sciences. Originally illustrated by John Craig, MD.)

opening, avoiding a long skin incision that would unroof the entire tract (Fig. 39-22). This is the Hanley procedure for a horseshoe abscess/fistula.

If a perianal abscess develops into a fistula and the fistula tract involves a small portion of the sphincter muscle, the condition can be treated by simple fistulotomy, which divides a portion of the internal sphincter and unroofs the tract entirely.

An anorectal fistula that persists after drainage of an ischiorectal fossa abscess usually is a transsphincteric fistula, because the tract crosses the lower portion of the external sphincter. The fistulotomy required to unroof this tract results in division of a portion of the internal sphincter as well as a portion of the lower external sphincter. If the tract lies below the posterior midline puborectalis, the external sphincter usually can be divided at the site of the fistula tract without loss of continence. However, the puborectalis must not be divided, or incontinence will invariably ensue.

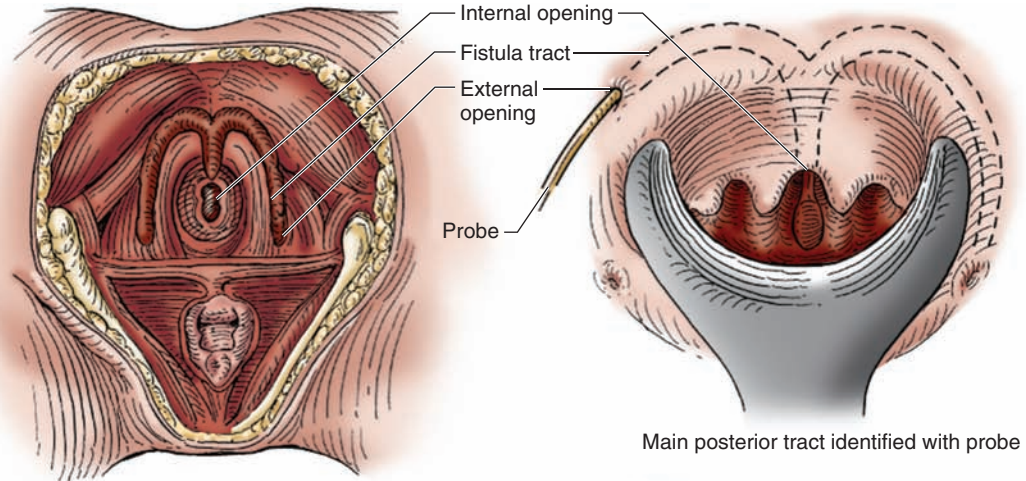
The external anal sphincter is much less prominent in the anterior midline. Thus fistulotomy as treatment for an anterior midline anal fistula is associated with an increased risk of anal incontinence, particularly in women. Consequently, treatment of such fistulas often involves eradicating the internal opening of the fistula at the level of the dentate line by

advancing a flap of rectal mucosa. It is important to ensure adequate drainage of the fistula through the external opening until the suture line of the advancement flap is well healed; otherwise an abscess can reform and disrupt the suture line, causing a recurrence of the fistula (Fig. 39-23). Injection of Fibrin glue and insertion of collagen plugs into the fistula tract is also an alternative with minimal morbidity and mixed success.<sup>41,42</sup> A newer technique involving ligation of the intersphincteric fistula tract (LIFT) has also been described with minimal morbidity and mixed success.<sup>43,44</sup> A dissection in the intersphincteric plane to the level of the fistula with double-suture ligation and partial excision of the intersphincteric portion of the tract will result in healing of approximately 50% of fistulas treated this way. Minimal damage to the sphincter mechanism and anal canal allows other treatments to be used if the technique fails.

Repair of rectovaginal fistulas after obstetric injury can also be performed in the same manner as the sliding advancement flap.<sup>45,46</sup> It is important to perform preoperative testing to evaluate for an associated external sphincter defect that may need to be repaired at the time of the advancement flap.

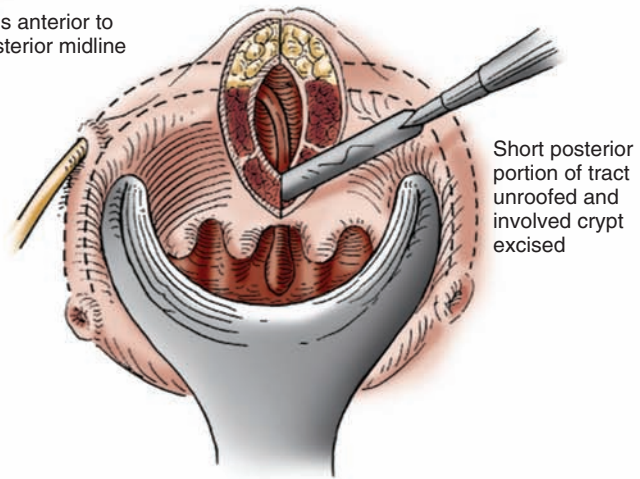
Although most anorectal abscesses originate in the anal crypts, other disease entities must be considered if the pathology appears atypical. Crohn's disease should be suspected if



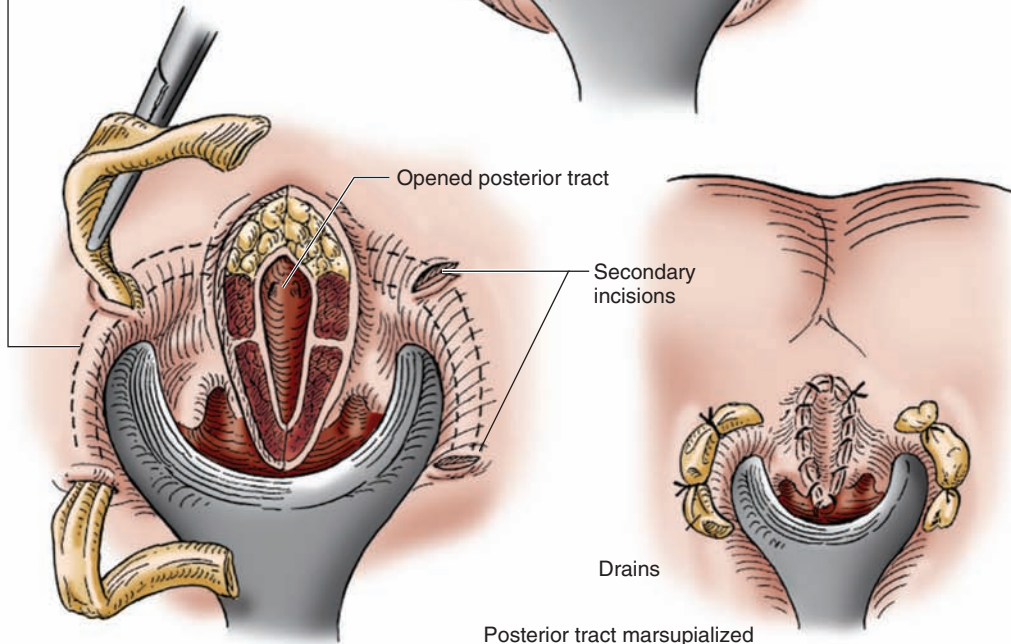


Main posterior tract identified with probe

Horseshoe fistula with external openings anterior to midanal line and internal opening in posterior midline

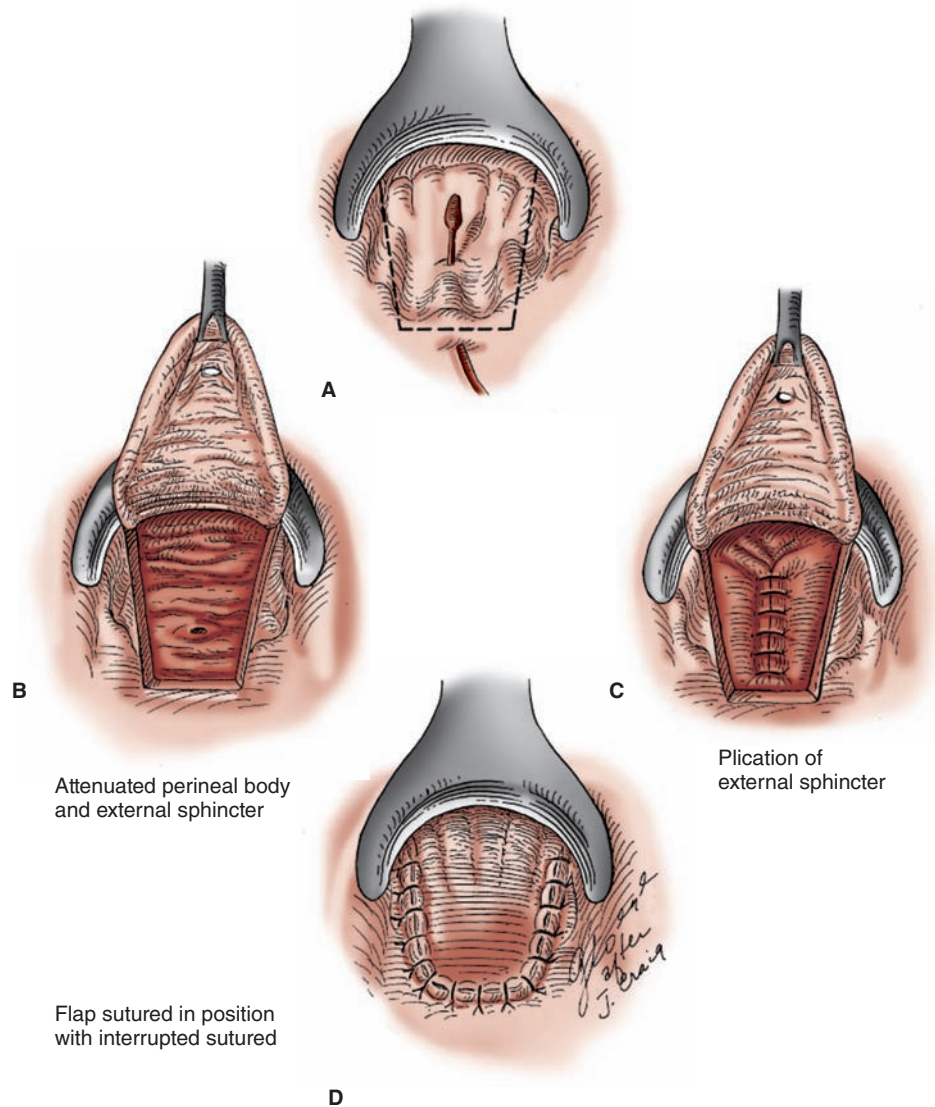


Anterior extensions curetted and drained via Penrose drains through secondary incisions along tracts, avoiding along incision



Posterior tract marsupialized

FIGURE 39-22 Surgical management of horseshoe fistula. (Redrawn, with permission, from Fry RD, Kodner IJ. Anorectal diseases. *Clin Symp.* 1985;37(6):2-32. Copyright 1985, Academy of Medical Sciences. Originally illustrated by John Craig, MD.)



**FIGURE 39-23** Endorectal advancement flap repair of complex anal-perineal or low rectal-perineal fistula. (Redrawn, with permission, from Kodner IJ, et al. Endorectal advancement flap repair of rectovaginal and other complicated anorectal fistulas. *Surgery*. 1993;114:682–690.)

there are numerous complex fistula tracts associated with edematous skin tags, or if there is inflammation of the rectal mucosa. Tuberculosis is now a rare cause of anal abscesses and fistulas but has recently been observed in immigrants to America. Hidradenitis suppurativa also may mimic cryptoglandular suppurative disease. Close examination, however, will reveal that the disease arises from the perianal skin and not the anal crypts. Actinomycosis should be suspected if typical sulfur-like granules are seen in the abscess cavity or fistula tract. Pilonidal disease sometimes can be confused with a posterior perianal abscess, but careful examination should reveal that there is no communication with the anus. Hair obtained from the abscess cavity when the pilonidal abscess is drained will indicate the true nature of the disease.

## SEXUALLY TRANSMITTED ANAL DISEASE

During recent years there has been a profound change in the prevalence and types of sexually transmitted diseases. Genital-anal, oral-anal, and other anal-based practices among homosexual or bisexual men and among women who engage in anal receptive intercourse account for the transmission of most of these diseases.

The recognition of the acquired immunodeficiency syndrome (AIDS) has led to public concern over the transmission of the causative agent, the human immunodeficiency virus (HIV). The incidence of other venereal diseases appears to be increasing. Although a detailed discussion of

these infections is beyond the scope of this textbook, the surgeon will often be consulted for evaluation of complications of these diseases.<sup>47</sup>

## Human Papillomavirus

Human papillomavirus (HPV) is the etiological agent causing venereal warts. These lesions are most common in homosexual men and can have a varied appearance, including (1) discrete warts: papillary or acuminate white lesions, usually occurring singly or in clusters at or below the dentate line; (2) circumferential wart ring lesions located at the dentate line and encompassing 60–100% of the anal canal; and (3) flat white epithelium: pale areas of smooth opaque epithelium that often extend cephalad to the dentate line. These latter lesions may be detected more easily by using a colposcope to magnify the anal canal. A high prevalence of histologically confirmed dysplasia in these internal lesions can be detected in asymptomatic homosexual men. Dysplasia was found in 70% of HIV-seronegative men and 85% and 90% of nonimmunosuppressed and immunosuppressed HIV-seropositive men, respectively. Biopsy of the lesions was necessary for detection, because it could not be predicted by the gross appearance of the warts.

The association of dysplasia with HPV is now well recognized. There are at least 60 different HPV types. Types 6 and 11 are associated with warts and low-grade dysplasia. Types 16 and 18 have been found in cervical cancer and high-grade cervical dysplasia, and type 16 has been found in high-grade anal dysplasia and invasive cancers. HPV types 31, 33, and 35 are thought to pose an intermediate cancer risk.

While it is clear that HPV is implicated in the pathogenesis of anal cancer in homosexual men, the rates of progression from dysplasia to cancer in the anal canal are unknown. It is likely that the progression rate is low, but further study is needed for documentation.

Anal intraepithelial neoplasia (AIN) is believed to be a precursor of anal neoplasm. Low-grade anal squamous intraepithelial lesion (LSIL) is equivalent to AIN grade I and high-grade anal squamous intraepithelial lesion (HSIL) is equivalent to AIN grade II or III. AIN III is defined as nuclear abnormalities that have penetrated through the full thickness of the epithelium. AIN III may be found in the pathology specimen after surgery for an unrelated problem such as hemorrhoids. One can apply acetic acid to the perianal area to visualize the lesions. The technique of anal mapping using biopsies at 1-cm intervals starting at the dentate line around the anus may also be used. Depending on the size and location of the lesion around the anus, the appropriate therapy for AIN is ablation of the lesions, either by excision, electrocautery, or laser. Medical options include topical 5-fluorouracil (5-FU) cream or imiquimod. Wide local excision may result in morbidity including anal stenosis or incontinence. Despite treatment of AIN, it is not known if treatment will reduce cancer risk. Thus, patients

should be followed closely, especially those with immunocompromise.<sup>48</sup>

## Chlamydial Infections

Chlamydial infections are now the most common sexually transmitted disease in the United States and they account for increasing numbers of cases of proctitis in patients who practice receptive anal intercourse. There are 15 recognized immunotypes of *Chlamydia trachomatis*, but for practical purposes it should be recognized that there are lymphogranulomatous causing lymphogranuloma venereum (LGV) and nonlymphogranulomatous (non-LGV) types. The non-LGV organisms are a common cause of urethritis, epididymitis, and pelvic inflammatory disease. At least half of the genital infections previously diagnosed as “nonspecific” or “nongonococcal” are caused by non-LGV *Chlamydia*. Chlamydial proctitis may coexist with other rectal infections, especially gonorrhea. Several serotypes are responsible for proctitis, and serotypes L1, L2, and L3 are responsible for lymphogranuloma venereum. The pathogen is introduced by either genital-anal or oral-anal intercourse. The non-LGV organisms are obligate intracellular parasites that can penetrate only columnar or transitional epithelium. The LGV organisms also can penetrate mononuclear cells, which may account for the prominent lymphadenopathy in patients with lymphogranuloma venereum.

Infection may be asymptomatic or may consist of nonspecific symptoms such as anal pain, pruritus, purulent discharge, and bleeding. More severe forms of infection, especially severe proctitis, usually indicate the presence of one of the LGV serotypes. Perianal fistulas and rectovaginal fistulas may develop, with untreated cases progressing to severe rectal stricture. Two weeks after the initial symptoms, inguinal lymphadenopathy becomes predominant and the inguinal nodes may fuse together in a large mass.

The organism is an obligate intracellular organism, and rectal cultures are usually inconclusive. A biopsy of the rectal mucosa is probably the most commonly used method to confirm the diagnosis. The diagnosis of chlamydial infections used to be difficult because satisfactory culture techniques were not widely available. Diagnosis usually required the detection of rising antibody titers. The organism, however, now can be identified by using tissue culture techniques or DNA probes.

Chlamydial infections should be treated as soon as the diagnosis is suspected. The recommended treatment for non-LGV chlamydial infection is doxycycline or, alternatively, erythromycin for 7–14 days. LGV chlamydial infection should be treated with tetracycline and sulfonamides for a minimum of 21 days.

As with all acute STDs, sexual abstinence until eradication is complete as well as education, testing, and treatment of sexual partners, when appropriate, is recommended.



## Herpes Simplex Virus

Anorectal herpes is usually caused by the type 2 herpes simplex virus (HSV-2), although the HSV-1 virus is responsible for approximately 10% of anal infections. Patients who have been previously infected have virus-specific antibodies. The first symptoms of infection are perianal pruritus or paresthesia, followed by intense anal pain. Small vesicles surrounded by red areolas may appear. These vesicles subsequently rupture, leaving small ulcers that appear on the perianal skin, in the anal canal, or even on the rectal mucosa. Fever and malaise are frequently present. The ulcerated lesions may become secondarily infected, with increased pain and discharge. The lesions usually heal in about 2 weeks. Unfortunately, a chronic relapsing course is common, although recurrent lesions are usually much less painful.

Scrapings from the base of a ruptured vesicle can be stained to show typical intranuclear inclusion bodies, but the diagnosis is most expeditiously made by viral HSV culture.

There is no known cure for herpes. Primary or initial infections are treated with oral acyclovir, famciclovir, or valacyclovir for 7–10 days.<sup>49</sup> Acyclovir should be taken at the onset of recurrent symptoms, which may reduce the formation of new vesicles. Chronic suppressive therapy or self-initiation of antiviral treatment with recurrent episodes may be helpful in patients with more than six recurrences per year. AIDS patients with perianal herpes resistant to acyclovir may benefit from two newer compounds, foscarnet or vidarabine.<sup>50</sup>

Patients are contagious while the lesions are present and should abstain from sexual activity until all lesions are completely healed. Even after the lesions have completely healed, a condom should be used during sexual intercourse.

## Gonorrhea

Anorectal infections caused by the bacterium *Neisseria gonorrhoeae* are common in the male homosexual population and frequently accompany other venereal diseases. Over half of homosexual men seen in screening clinics have been found to be infected, with the rectum being the only site infected in about half of cases. The majority of these infections are asymptomatic.<sup>51</sup>

Symptoms vary from none to intense anorectal pain and tenesmus accompanied by a viscid, yellow anal discharge. Anoscopy may reveal anusitis or distal proctitis. Diagnosis is confirmed by obtaining cultures from the rectal discharge or mucosa, or more recently by DNA probes.

Treatment should be initiated if the disease is suspected. Untreated rectal gonorrhea can lead to septic arthritis, endocarditis, perihepatitis, and meningitis, as well as infection of sexual partners. Several drugs (penicillin, tetracycline, ampicillin, and spectinomycin) may be used for treatment, although increasing numbers of resistant strains are being recognized. Cultures should be repeated after treatment is completed, because antibiotic therapy may fail in as many

as one-third of the patients. All sexual contacts also must be treated. All patients with confirmed rectal gonorrhea should have a serologic test for syphilis 3 months after treatment is completed.

## Syphilis

The classic lesion of primary syphilis is a chancre on the genitalia, but in homosexual males the chancre usually presents in the anal canal or at the anal verge.<sup>52</sup> These ulcerated lesions may mimic an anal fissure, but an aberrant location of the lesion (eg, lateral anus instead of midline) should arouse suspicion. Classic descriptions indicate that the syphilitic chancre is a painless lesion, but anal chancres may be extremely painful. The causative organism is the spirochete, *Treponema pallidum*, which may occasionally cause severe proctitis without an accompanying chancre. Inguinal adenopathy is common.

Early syphilis can be diagnosed by examining scrapings from the base of the chancre with dark-field microscopy; these lesions teem with spirochetes that can be seen as corkscrew-shaped motile fluorescent yellowish-green organisms. Serology is also very helpful in establishing the diagnosis. In untreated primary syphilis, the Venereal Disease Research Laboratory assay is reactive in about 75% of cases, in early latent syphilis about 95%, and in the secondary state it is 100% reactive. The fluorescent treponemal antibody absorption test usually becomes positive about 4–6 weeks after the initial infection. Rapid plasma reagin and darkfield microscopy are the appropriate tests for suspected early syphilis.

The second stage of anal syphilis appears 6–8 weeks after the chancre has healed in untreated patients. It may present as condyloma latum, a pale-brown or flesh-colored flat verrucous lesion, or as a mucocutaneous rash. All three serologic tests for syphilis will be positive at this stage. Skin lesions are highly contagious.

Benzathine penicillin G is the treatment of choice for syphilis. Alternative treatments include doxycycline, tetracycline, or erythromycin. Patients with syphilis must abstain from sexual contact until treatment is complete. All sexual contacts within the preceding 90 days should be prophylactically treated.

## REFERENCES

1. Rockwood TH, et al. Patient and surgeon ranking of the severity of symptoms associated with fecal incontinence: the fecal incontinence severity index. *Dis Colon Rectum*. 1999;42(12):1525–1532.
2. Rockwood TH, et al. Fecal Incontinence Quality of Life Scale: quality of life instrument for patients with fecal incontinence. *Dis Colon Rectum*. 2000;43(1):9–16; discussion 16–7.
3. Tjandra JJ, et al. Practice parameters for the treatment of fecal incontinence. *Dis Colon Rectum*. 2007;50(10):1497–1507.
4. Rociu E, et al. Fecal incontinence: endoanal US versus endoanal MR imaging. *Radiology*. 1999;212(2):453–458.
5. Terra MP, et al. MRI in evaluating atrophy of the external anal sphincter in patients with fecal incontinence. *AJR Am J Roentgenol*. 2006;187(4):991–999.

6. Rentsch M, et al. Dynamic magnetic resonance imaging defecography: a diagnostic alternative in the assessment of pelvic floor disorders in proctology. *Dis Colon Rectum*. 2001;44(7):999–1007.
7. Solomon MJ, et al. Randomized, controlled trial of biofeedback with anal manometry, transanal ultrasound, or pelvic floor retraining with digital guidance alone in the treatment of mild to moderate fecal incontinence. *Dis Colon Rectum*. 2003;46(6):703–710.
8. Heymen S, et al. Biofeedback treatment of fecal incontinence: a critical review. *Dis Colon Rectum*. 2001;44(5):728–736.
9. Halverson AL, Hull TL. Long-term outcome of overlapping anal sphincter repair. *Dis Colon Rectum*. 2002;45(3):345–348.
10. Ha HT, et al. Manometric squeeze pressure difference parallels functional outcome after overlapping sphincter reconstruction. *Dis Colon Rectum*. 2001;44(5):655–660.
11. Giordano P, et al. Previous sphincter repair does not affect the outcome of repeat repair. *Dis Colon Rectum*. 2002;45(5):635–640.
12. Vaizey CJ, et al. Long-term results of repeat anterior anal sphincter repair. *Dis Colon Rectum*. 2004;47(6):858–863.
13. Matzel KE, Stadelmaier U, Hohenberger W. Innovations in fecal incontinence: sacral nerve stimulation. *Dis Colon Rectum*. 2004;47(10):1720–1728.
14. Govaert B, et al. Factors associated with percutaneous nerve evaluation and permanent sacral nerve modulation outcome in patients with fecal incontinence. *Dis Colon Rectum*. 2009;52(10):1688–1694.
15. Tjandra JJ, et al. Sacral nerve stimulation is more effective than optimal medical therapy for severe fecal incontinence: a randomized, controlled study. *Dis Colon Rectum*. 2008;51(5):494–502.
16. Wexner SD, et al. Sacral nerve stimulation for fecal incontinence: results of a 120-patient prospective multicenter study. *Ann Surg*. 2010;251(3):441–449.
17. Edden Y, Wexner SD. Therapeutic devices for fecal incontinence: dynamic graciloplasty, artificial bowel sphincter and sacral nerve stimulation. *Expert Rev Med Devices*. 2009;6(3):307–312.
18. Wong WD, et al. The safety and efficacy of the artificial bowel sphincter for fecal incontinence: results from a multicenter cohort study. *Dis Colon Rectum*. 2002;45(9):1139–1153.
19. Wexner SD, et al. Factors associated with failure of the artificial bowel sphincter: a study of over 50 cases from Cleveland Clinic Florida. *Dis Colon Rectum*. 2009;52(9):1550–1557.
20. Norton C, Burch J, Kamm MA. Patients' views of a colostomy for fecal incontinence. *Dis Colon Rectum*. 2005;48(5):1062–1069.
21. Kodner IJ, Fry RD, Fleshman JW. Rectal prolapse and other pelvic floor abnormalities. *Surg Ann*. 1992;24(pt 2):157–190.
22. Kim DS, et al. Complete rectal prolapse: evolution of management and results. *Dis Colon Rectum*. 1999;42(4):460–466; discussion 466–469.
23. Byrne CM, et al. Long-term functional outcomes after laparoscopic and open rectopexy for the treatment of rectal prolapse. *Dis Colon Rectum*. 2008;51(11):1597–1604.
24. Tou S, et al. Surgery for complete rectal prolapse in adults. *Cochrane Database Syst Rev*. 2008;(4):CD001758.
25. D'Hoore A, Penninckx F. Laparoscopic ventral recto(colpo)pexy for rectal prolapse: surgical technique and outcome for 109 patients. *Surg Endosc*. 2006;20(12):1919–1923.
26. Prasad ML, Pearl R, Abcarian H, Orsay CP, Nelson RL. Perineal proctectomy, posterior rectopexy, and postanal levator repair for the treatment of rectal prolapse. *Dis Colon Rectum*. 1986;29(9):547–552.
27. Gagliardi G, et al. Results, outcome predictors, and complications after stapled transanal rectal resection for obstructed defecation. *Dis Colon Rectum*. 2008;51(2):186–195; discussion 195.
28. Lehur PA, et al. Outcomes of stapled transanal rectal resection vs. biofeedback for the treatment of outlet obstruction associated with rectal intussusception and rectocele: a multicenter, randomized, controlled trial. *Dis Colon Rectum*. 2008;51(11):1611–1618.
29. Fleshman JW, et al. Balloon expulsion test facilitates diagnosis of pelvic floor outlet obstruction due to nonrelaxing puborectalis muscle. *Dis Colon Rectum*. 1992;35(11):1019–1025.
30. Fleshman JW, et al. Outpatient protocol for biofeedback therapy of pelvic floor outlet obstruction. *Dis Colon Rectum*. 1992;35(1):1–7.
31. Goei R. Anorectal function in patients with defecation disorders and asymptomatic subjects: evaluation with defecography. *Radiology*. 1990;174(1):121–123.
32. Selvaggi F, et al. Evaluation of normal subjects by defecographic technique. *Dis Colon Rectum*. 1990;33(8):698–702.
33. Lienemann A, Fischer T. Functional imaging of the pelvic floor. *Eur J Radiol*. 2003;47(2):117–122.
34. Santoro GA, et al. High-resolution three-dimensional endovaginal ultrasonography in the assessment of pelvic floor anatomy: a preliminary study. *Int Urogynecol J Pelvic Floor Dysfunct*. 2009;20(10):1213–1222.
35. Santoro GA. *Benign Anorectal Diseases: Diagnosis With Endoanal and Endorectal Ultrasound and New Treatment Options*. Trento, Italy: Springer-Verlag Italia; 2006.
36. Haas PA, Fox TA, Jr, Haas GP. The pathogenesis of hemorrhoids. *Dis Colon Rectum*. 1984;27(7):442–450.
37. Sutherland LM, et al. A systematic review of stapled hemorrhoidectomy. *Arch Surg*. 2002;137(12):1395–1406; discussion 1407.
38. Schouten WR, et al. Ischaemic nature of anal fissure. *Br J Surg*. 1996;83(1):63–65.
39. Orsay C, et al. Practice parameters for the management of anal fissures (revised). *Dis Colon Rectum*. 2004;47(12):2003–2007.
40. East WH. One hundred cases of anal fissure treated with botulin toxin: early and long-term results. *Dis Colon Rectum*. 1997;40(9):1029–1032.
41. Lindsey I, et al. A randomized, controlled trial of fibrin glue vs. conventional treatment for anal fistula. *Dis Colon Rectum*. 2002;45(12):1608–1615.
42. Loungnarath R, et al. Fibrin glue treatment of complex anal fistulas has low success rate. *Dis Colon Rectum*. 2004;47(4):432–436.
43. Rojanasakul A. LIFT procedure: a simplified technique for fistula-in-ano. *Tech Coloproctol*. 2009;13(3):237–240.
44. Rojanasakul A, et al. Total anal sphincter saving technique for fistula-in-ano; the ligation of intersphincteric fistula tract. *J Med Assoc Thai*. 2007;90(3):581–586.
45. Kodner IJ, et al. Endorectal advancement flap repair of rectovaginal and other complicated anorectal fistulas. *Surgery*. 1993;114(4):682–689; discussion 689–690.
46. Sonoda T, et al. Outcomes of primary repair of anorectal and rectovaginal fistulas using the endorectal advancement flap. *Dis Colon Rectum*. 2002;45(12):1622–1628.
47. Knapp J. In: M.A. Morse SA, Thompson SE, eds. *Sexually Transmitted Diseases*. ed. Philadelphia, PA: JB Lippincott; 1990.
48. Abbasakoor F, Boulos PB. Anal intraepithelial neoplasia. *Br J Surg*. 2005;92(3):277–290.
49. Corey L, et al. Evaluation of new anti-infective drugs for the treatment of genital infections due to herpes simplex virus. Infectious Diseases Society of America and the Food and Drug Administration. *Clin Infect Dis*. 1992;15(suppl 1):S99–S107.
50. Apoola A, Radcliffe K. Antiviral treatment of genital herpes. *Int J STD AIDS*. 2004;15(7):429–433.
51. Janda WM, et al. Prevalence and site-pathogen studies of *Neisseria meningitidis* and *N gonorrhoeae* in homosexual men. *JAMA*. 1980;244(18):2060–2064.
52. Golden MR, Marra CM, Holmes KK. Update on syphilis: resurgence of an old problem. *JAMA*. 2003;290(11):1510–1514.

# CANCER OF THE RECTUM

Joel Goldberg • Ronald Bleday

## INCIDENCE

At the beginning of the 21st century, rectal cancer continues to be a significant medical and social problem. Currently, there are approximately 149,000 cases of colorectal cancer diagnosed in the United States each year. Adenocarcinoma of the rectum accounts for nearly 30% of these cancers. This translates into 41,000 new diagnoses of rectal cancer each year and greater than 10,000 deaths attributable to this disease within the same time period.<sup>1</sup>

## HISTORY

The history of modern rectal cancer resection dates back to 1884, when Czérny described the first abdominoperineal resection (APR). In 1885, Kraske pioneered the transsacral approach of rectal resection and anastomosis. In 1908, Miles improved on the APR by understanding that there was a “zone of upward spread.”<sup>2</sup> He emphasized the importance of performing a wide perineal excision. Furthermore, he advocated removal of the rectum with a high ligation of the superior hemorrhoidal artery as well as excision of the abdominal attachments of the rectum and the iliac lymph nodes. Despite the improvements in oncologic resection, operative mortality in Miles’ first series exceeded 42%. Over the next 80 years through the late 1980s, mortality and morbidity for rectal cancer surgery improved markedly in pace with improvements in intra-, peri-, and postoperative care. Unfortunately, there were few, if any, advancements in oncologic techniques during this period. Then, in the late 1980s, William Heald described and began popularizing total mesorectal excision (TME) for carcinoma of the rectum.<sup>3</sup> In this technique he advocates using sharp dissection to perform the complete excision of the mesorectum and its associated lymphatics along the subtle fascial planes that encompass the rectum. Moreover, Heald described a “zone of downward spread” within the mesorectum that requires complete excision in order to reduce local recurrence. Finally, local excision of small rectal cancers has been used for a 100 years in selected patients. More recently, local excision is being combined with neoadjuvant and adjuvant chemoradiotherapy to maximize local control with a minimally invasive approach.

## ETIOLOGY AND RISK FACTORS

In Western industrialized nations the average lifetime risk for an individual to develop colorectal cancer is approximately 6%. This risk increases two- to fourfold if the patient has a personal history of a first-degree relative with colorectal cancer. Inflammatory bowel disease (IBD) is another risk factor. In the first 10 years after the initial diagnosis of ulcerative colitis (UC), the incidence of colorectal cancer ranges from 2 to 5%; however, this risk increases 1% for each year of disease thereafter. Pancolitis is associated with both an earlier and an increased risk for colorectal cancer when compared to left-sided colitis alone. For all patients with UC, the cumulative risk for colorectal cancer at 25 years is 25%. Screening the colon yearly starting at 10 years after the diagnosis with colonoscopy and multiple biopsies in four quadrants every 10 cm from the cecum to the distal rectum is used to predict when a patient is at risk for developing colorectal cancer. If high-grade dysplasia is detected in any of the biopsies, the patient needs to have a total proctocolectomy. Some practitioners advocate a surgical resection for low-grade dysplasia as well, whereas some are willing to repeat a colonoscopy with multiple biopsies. If low-grade dysplasia is found on the second short-interval colonoscopy, total proctocolectomy is indicated. Ultimately, the most effective method for preventing colon cancer in patients with UC is to remove the colon once any type of dysplasia has been identified. Crohn’s colitis is associated with a similar increased risk for colorectal cancer. This is often not appreciated by clinicians because patients with severe Crohn’s colitis often undergo proctocolectomy before their long-term risk becomes an issue.

Genetic risk factors also have been implicated in the development of colorectal cancer. One is familial adenomatous polyposis (FAP), an autosomal dominant syndrome with 100% risk of developing colorectal cancer. The abnormality is caused by a defect in the *APC* gene located on chromosome 5q21. Patients with FAP develop hundreds or thousands of adenomas by their 20s, and colorectal cancer develops in all patients by age 50 years if untreated. Extraintestinal manifestations of this genetic defect include desmoid tumors, periampullary masses, osteomas, and medulloblastomas. A second genetic abnormality associated with the development of colorectal cancer is related to defects in the mismatch repair genes *MSH2* and



*MLH1*. Mismatch repair genes affect the repair of DNA replication errors and spontaneous base repair loss and contribute to hereditary nonpolyposis colorectal cancer (HNPCC) that is also known as *Lynch syndrome*. Despite the name, these cancers arise from adenomas and may account for 5% of all colorectal malignancies. In this autosomal dominant syndrome, cancers occur more often on the right side of the colon. Despite developing at a younger age, there is a better prognosis with these cancers when compared with age-matched controls with a non-HNPCC colorectal cancer. In theory, a patient with HNPCC living to age 80 years would have an 80% risk for developing colorectal cancer; additionally, there is a risk of endometrial cancer (40%), gastric cancer (20%), biliary tract cancer (18%), urinary tract cancer (10%), and ovarian cancer (10%). Family members should be screened initially at age 20 years with colonoscopy for the presence of polyps or colon cancer. After age 40 years, colonoscopies should be performed yearly. If a polyp or cancer is detected, a total abdominal colectomy with an ileorectal anastomosis is recommended. Urine cytology to rule out dysplastic cells in the genitourinary tract (which is at risk for transitional cell carcinoma) is recommended. Women should get regular transvaginal pelvic ultrasounds and CA-125 levels. Any affected woman who has finished childbearing and requires a colectomy should give strong consideration to a prophylactic total abdominal hysterectomy and bilateral salpingo-oophorectomy.

Dietary fats, especially red-meat fats, have been implicated as a risk factor for colon and rectal cancer.<sup>4</sup> People who consume less than 15% of their diet as fat have a lower incidence

of colorectal cancer, whereas those who take in 20% of their diet as fat, either as unsaturated animal fat or as highly saturated vegetable oils, have an increased risk of colorectal malignancy.

In the past few decades, several studies have linked alcohol consumption and tobacco use with an increased risk of colorectal neoplasia. Moreover, there appears to be a synergistic effect with an even greater increased risk of adenomatous polyps in people who are both smokers and drinkers.<sup>5</sup>

## POLYPS

The concept that colorectal cancers develop from polyps, or the “adenoma-to-carcinoma sequence,” was first described by Dukes in 1926. The majority of patients with rectal cancer have no inherited component; instead, there is an initiating genetic mutation, such as of an oncogene like *ras*, that leads to abnormal cell growth. Subsequently, mutations resulting in inactivation of tumor suppressor genes, such as *p53*, allow for progression to cancer.

The time course for polyp development and transformation to cancer is thought to be 5–10 years. Most adenomas remain benign; however, histologic type, polyp size, and evidence of dysplasia are associated with transformation. Data from the National Polyp Study and St. Mark’s Hospital show that approximately 75–85% of adenomas are tubular, 8–15% are tubulovillous, and 5–10% are villous. Tubular adenomas usually form a stalk, whereas villous adenomas have a broad base (Fig. 40-1). Villous histology is associated with an

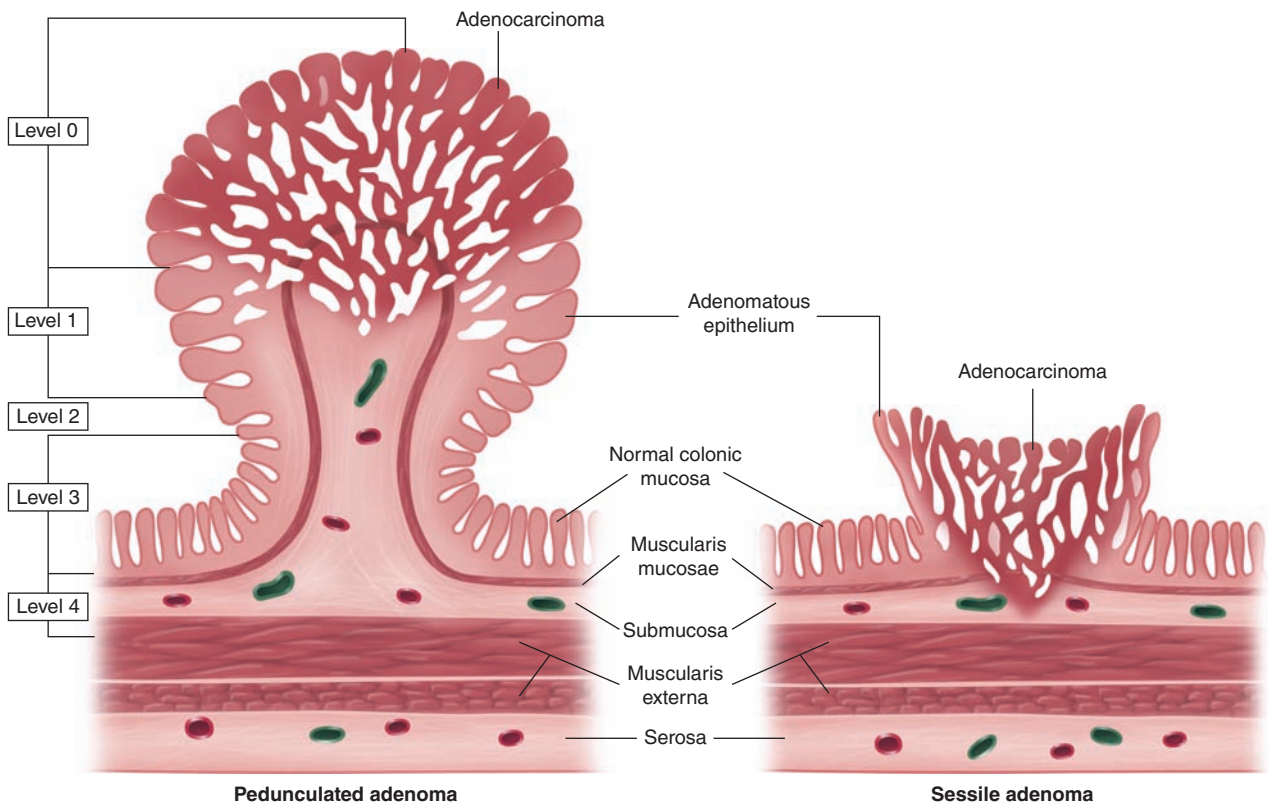


FIGURE 40-1 Haggitt classification of a pedunculated and sessile polyp, each of which contains an invasive cancer.

increased risk of cancer development. Only 1% of polyps less than 1 cm in diameter show evidence of malignant transformation, whereas 50% of polyps greater than 2 cm in diameter harbor areas of carcinoma.

Clinically, it is important to diagnose the type, size, and number of polyps to risk-stratify patients for treatment and future surveillance. Endoscopic treatment likely reduces or eliminates the risk of colorectal cancer in patients. Rigid sigmoidoscopy and flexible sigmoidoscopy are all that are necessary to screen the rectum. Sigmoidoscopic screening should be followed by a complete colonoscopy if biopsy of a small rectal or sigmoid polyp shows adenomatous changes. Colonoscopic screening as the first study is indicated in high-risk populations. Autopsy studies have reported that adenomas are present in 20–60% of patients with a colorectal cancer, and synchronous cancers are found in 3–9% of patients. In patients who cannot undergo a preoperative colonoscopy, either a virtual colonoscopy or barium enema should be performed. If both procedures are contraindicated in these patients, colonoscopic evaluation should be performed 3 months after resection.

Treatment of the malignant rectal polyp is becoming more common with the increase in colonoscopic screening and the early diagnosis of small distal rectal cancers. Surgical treatment in part depends on the morphology of the polyp and the histologic evaluation of the resected lesion. Pedunculated malignant polyps are classified by Haggitt according to the depth of invasion of the cancer within the head of the polyp and stalk<sup>6</sup> (see Fig. 40-1). Malignant polyps completely resected with greater than 2-mm margins and without stalk invasion are considered adequately treated with colonoscopic removal, provided there are no poor prognostic histologic features; tumors with poor differentiation or lymphatic or venous invasion are associated with an increased incidence of involved lymph nodes.<sup>7</sup>

## ANATOMY

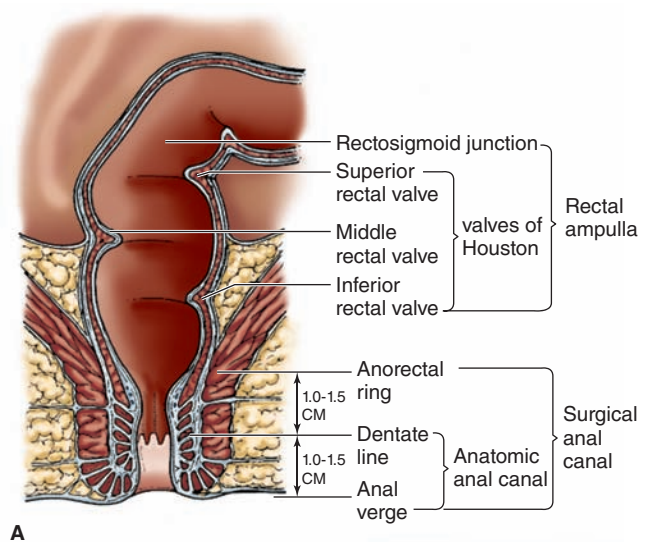
### Anatomic Landmarks

The type of therapy offered to a patient with rectal cancer depends not only on the stage of the tumor but also on its location within the pelvis and its relation to the anal sphincters. Compared with colon cancer, knowledge and appreciation of anatomic landmarks are critical in determining resectability and sphincter preservation.

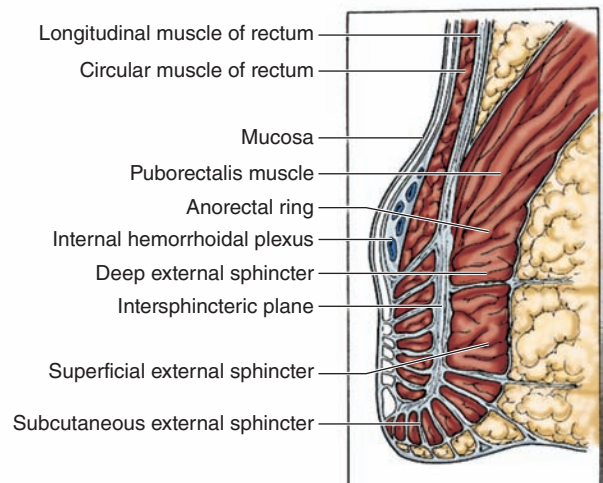
The rectum, usually 15–20 cm in length, extends from the rectosigmoid junction, marked by fusion of the taenia coli into a completely circumferential muscular layer, to the anal canal. The rectum transitions from being intraperitoneal to being completely extraperitoneal 10–12 cm from the anus and the root of the sigmoid mesentery is approximately 19 cm from the anal verge on rigid sigmoidoscopy.<sup>8</sup> The rectum is “fixed” posteriorly and laterally by Waldeyer’s fascia and the lateral stalks, respectively. In the male patient, the anterior rectum is fixed to Denonvilliers’ fascia, a fold of two layers of peritoneum that separates the rectum from

the posterior prostate and seminal vesicles. In the female patient, the peritoneal cavity descends to the pouch of Douglas, with its most dependent point being adjacent to the cervix anteriorly and midrectum posteriorly.<sup>9</sup> When seen endoscopically, the rectum has three valves of Houston, the middle of which corresponds to the anterior peritoneal reflection (Fig. 40-2A).

While many surgical descriptions for rectal cancer refer to the distance of the lesion from the anal verge or the *dentate line*, a more accurate description for distal (palpable lesions) is the distance above the anorectal ring as palpated by the examining surgeon. For nonpalpable lesions, we use a rigid sigmoidoscope to localize the lesion and then ascertain the distance from the anal verge to the mass. At the muscular level, the anal canal starts at the top of the “high-pressure zone” that is at the proximal aspect of the anorectal ring, a muscular structure consisting of the internal sphincter, external sphincter,



A



B

FIGURE 40-2 Anatomic landmarks of the rectum and anus.

and puborectalis (Figs. 40-2A and 40-2B). The high-pressure zone descends beyond the dentate line to the junction of the anal mucosa and the perianal skin; this junction is often referred to as the *anal verge*. In order to achieve an adequate distal margin ( $\geq 2$  cm) with sphincter preservation, the lower border of a tumor must be located high enough above the top of the anorectal ring. If curative resection compromises perfect function of the sphincter apparatus, or if an adequate distal margin cannot be obtained while preserving the anorectal ring, an APR with a permanent colostomy should be constructed. Although a patient may assume that a colostomy indicates a hopelessly incurable cancer, we must emphasize that the colostomy is necessary because of the anatomic location, not necessarily the severity of the rectal cancer.

## Vascular Supply

Arteriography demonstrates extensive intramural anastomoses between the superior, middle, and inferior rectal arteries. The superior rectal artery originates from the inferior mesenteric artery and descends in the mesorectum to supply the upper and middle rectum (Fig. 40-3). The inferior rectal arteries, branches of the internal pudendal arteries,

enter posterolaterally and provide blood supply to the anal sphincters and epithelium. The middle rectal artery, often depicted in anatomic drawings as a large and significant artery branching off the internal iliac artery on each side, is seldom greater than 1 mm in diameter.<sup>10</sup> In one study, the middle rectal artery was observed in only 22% of cadaver specimens.<sup>9</sup> When actually present, the middle rectal artery is located near the lateral rectal stalks. These stalks are primarily nerves but have been confused previously with arterial supply.

The superior rectal vein drains the upper and middle thirds of the rectum and empties into the portal system via the inferior mesenteric vein. The middle rectal veins drain the lower rectum and upper anal canal into the internal iliac veins. The inferior rectal veins drain the lower anal canal, emptying into the internal iliac veins via the pudendal veins. Because the venous systems communicate, low rectal cancers may spread via the portal and systemic circulations.

## Lymphatic Drainage

Local recurrence after resection is common and can occur with and without distant metastatic disease. Rectal cancer

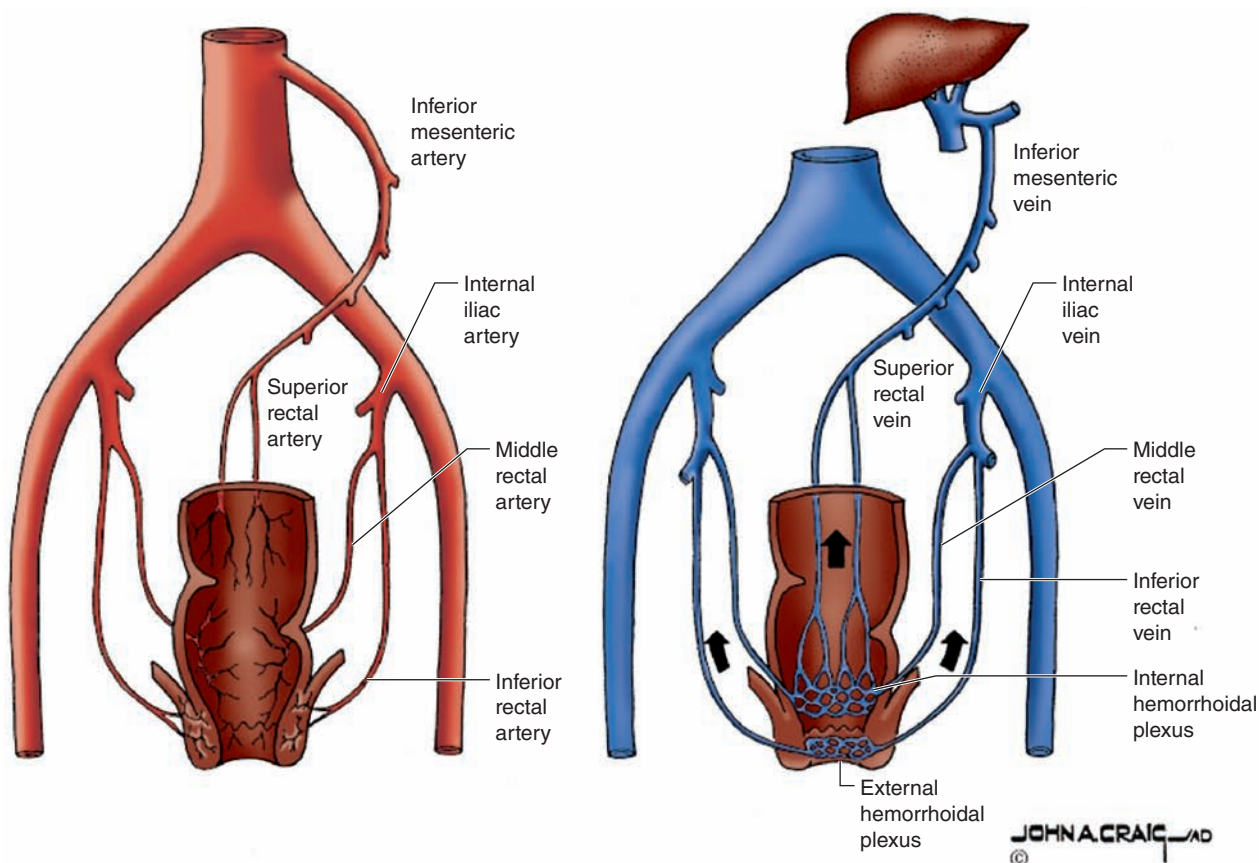
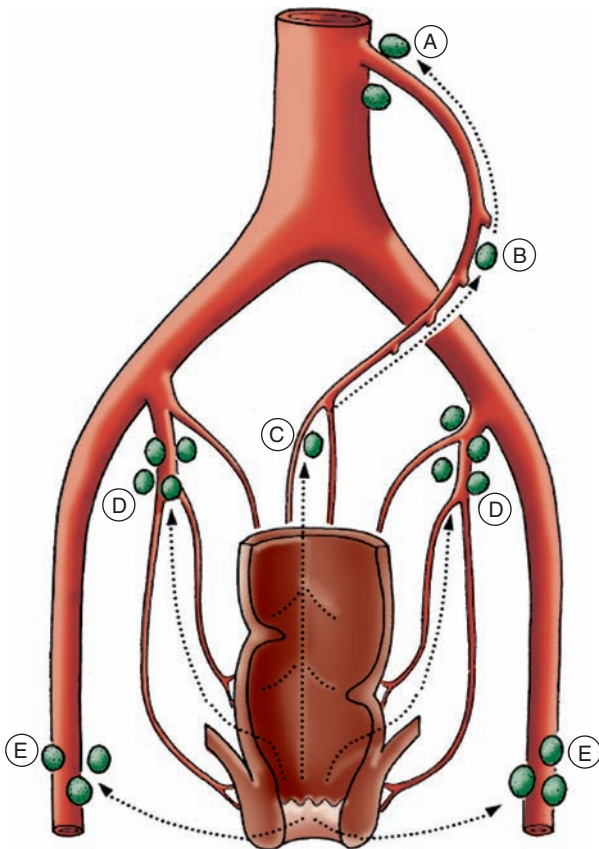


FIGURE 40-3 Vasculature of the rectum and anus. **A.** Arterial supply. **B.** Venous drainage.

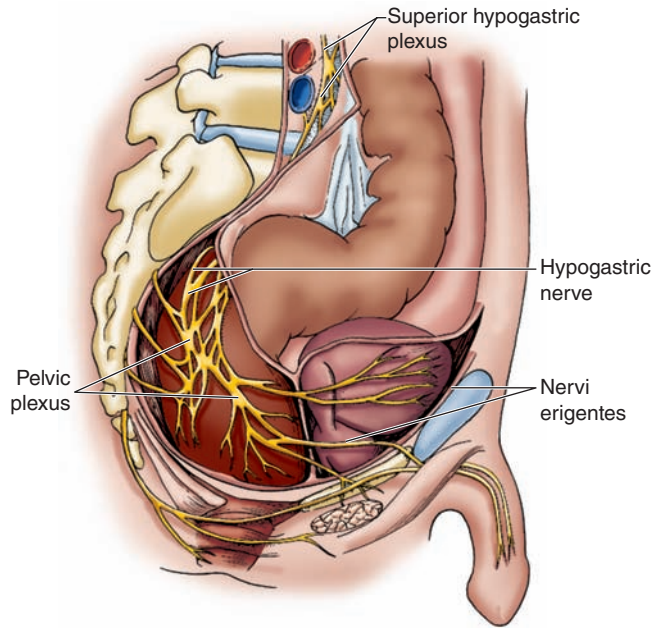


can spread locally via lymphatics that follow cranially along the superior hemorrhoidal vessels. This “zone of upward spread” was described initially by Miles in his landmark paper describing the APR. Heald has described a “zone of downward spread” within the mesorectum<sup>3</sup>; this zone can encompass as much as 4 cm beyond the distal mucosal edge of the tumor.<sup>11,12</sup> Although some surgeons and pathologists describe tumor within this zone of downward spread as tumor implants, others believe that these implants are replaced nodes. Appreciation of the zones of upward and downward spread has influenced the extent of dissection surgeons now perform for curative resection of rectal cancers.

Lymph from the upper and middle rectum drains into the inferior mesenteric nodes (Fig. 40-4). Lymph from the lower rectum may drain into the inferior mesenteric system or into the network along the middle and inferior rectal arteries, posteriorly along the middle sacral artery, and anteriorly through the channels to the retrovesical or rectovaginal septum, to the iliac nodes, and ultimately, to the periaortic nodes. In a Japanese study, the obturator nodes, external to the hypogastric nerve plexus, were found to be involved with cancer in 8% of tumors located in the distal rectum, whereas these nodes were rarely, if ever, involved with proximal tumors.<sup>13</sup> Lymphatics



**FIGURE 40-4** Lymphatic drainage of the rectum and anus. **A.** Nodes at the origin of the inferior mesenteric artery. **B.** Nodes at the origin of sigmoid branches. **C.** Sacral nodes. **D.** Internal iliac nodes. **E.** Inguinal nodes.



**FIGURE 40-5** Nerve supply of pelvic organs.

from the anal canal above the dentate line usually drain via the superior rectal lymphatics to the inferior mesenteric lymph nodes and laterally to the obturator and internal iliac nodes. Below the dentate line, lymph drains primarily to the inguinal nodes but may empty into the inferior or superior rectal lymph nodes.

## Innervation

The pelvic autonomic nerves consist of the paired hypogastric (sympathetic), sacral (parasympathetic), and inferior hypogastric nerves (Fig. 40-5). Sympathetic nerves originate from L1–L3, form the inferior mesenteric plexus, travel through the superior hypogastric plexus, and descend as the hypogastric nerves to the pelvic plexus. The parasympathetic nerves, or nervi erigentes, arise from S2–S4 and join the hypogastric nerves anterior and lateral to the rectum to form the pelvic plexus and ultimately the periprostatic plexus. The inferior hypogastric nerve plexus arises from interlacing sympathetic and parasympathetic nerve fibers and forms a fenestrated rhomboid plate on the lateral pelvic sidewall. Fibers from this plexus innervate the rectum as well as the bladder, ureter, prostate, seminal vesicles, membranous urethra, and corpora cavernosa. Therefore, injury to these autonomic nerves can lead to impotence, bladder dysfunction, and loss of normal defecatory mechanisms.

## Fascial Planes

The walls and floor of the pelvis are covered by the endopelvic, or parietal, fascia (Fig. 40-6). The fascia propria, an

extension of the endopelvic fascia, encloses the rectum and its mesorectal fat, lymphatics, and vascular supply as a single unit; forms the lateral stalks of the rectum; and connects to the parietal fascia on the pelvic sidewall. The presacral fascia is the parietal fascia that covers the sacrum and coccyx, presacral plexus, pelvic autonomic nerves, and the middle sacral artery. Posteriorly, a thickening of this fascia, called *Waldeyer's fascia*, is the anteroinferior fascial reflection from the presacral fascia at the level of S4. Anteriorly, *Denonvilliers' fascia* separates the anterior rectal wall from the prostate and seminal vesicles in the male and is thought to be an entrapped extension of the peritoneum.<sup>14</sup>

## DIAGNOSIS AND EVALUATION

The preoperative evaluation is critically important to treat the cancer optimally and achieve sphincter preservation. With this information, surgeons must individualize the treatment and care of each patient.

## History

The patient with rectal cancer usually presents to the surgeon after a definitive endoscopic diagnosis. The patient's initial

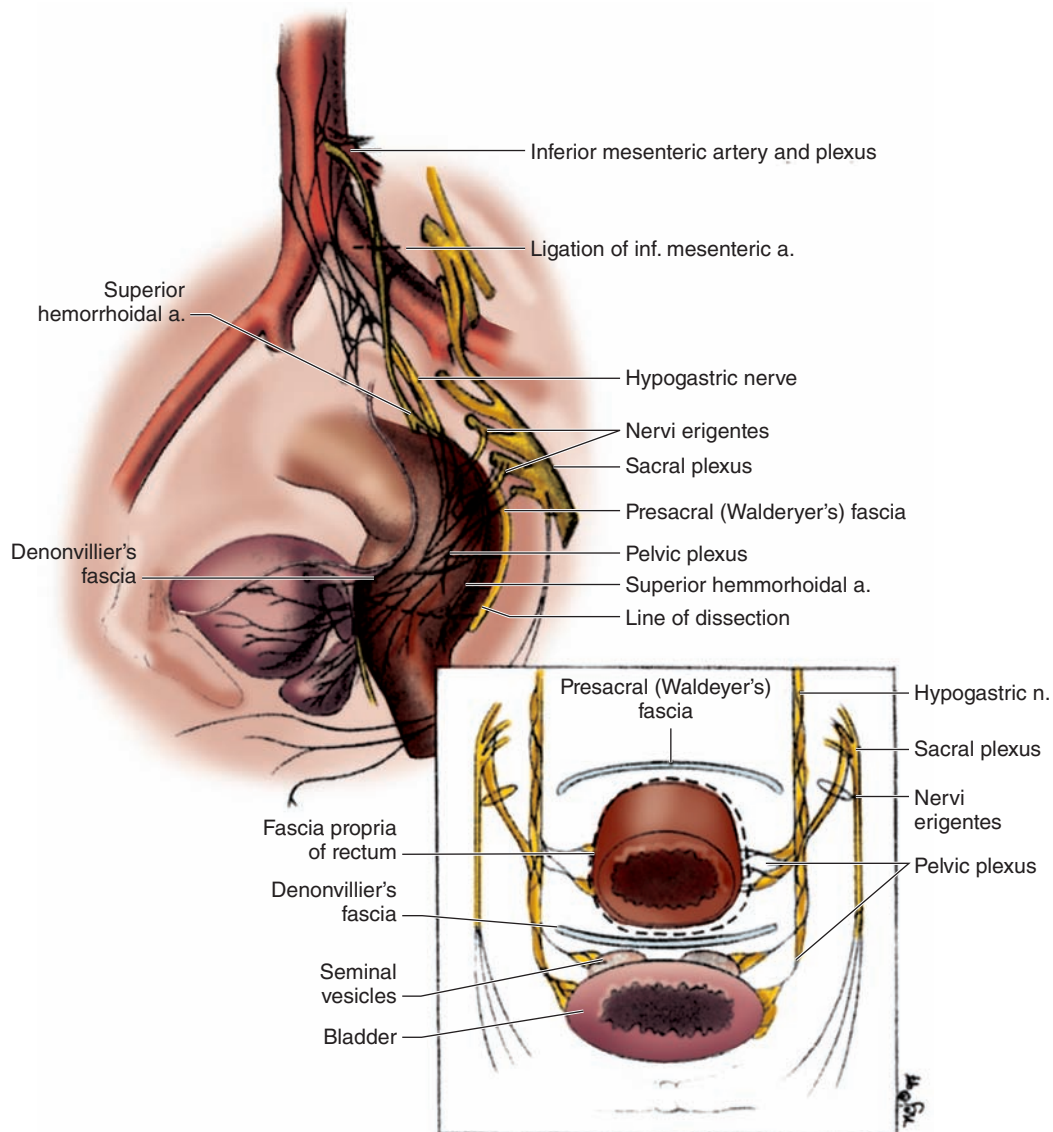


FIGURE 40-6 Fascial planes. (Used, with permission, from Michelassi F, Milsom JW, eds. *Operative Strategies in Inflammatory Bowel Disease*. New York, NY: Springer-Verlag; 1999.)

complaint may include rectal bleeding, a change in bowel habits or stool caliber, rectal pain, a sense of rectal “fullness,” weight loss, nausea, vomiting, fatigue, or anorexia; however, many patients are completely asymptomatic. Specific symptoms may assist the surgeon in deciding on the optimal approach to therapy. Tenesmus, the constant sensation of needing to move one’s bowels, usually is indicative of a large and possibly fixed stage II or III cancer. Pain with defecation suggests involvement of the anal sphincters; cancers growing directly into the anal sphincter usually are not amenable to sphincter-sparing procedures. Information pertaining to anal sphincter function is invaluable when one is contemplating a low anastomosis. If patients are incontinent, they are better served with an ostomy. Preoperative sexual function is important to know because one must discuss the risks of the procedure and possible diminution of sexual function postoperatively.

A comprehensive medical history should be aimed at identifying other medical conditions, such as cardiopulmonary, renal, and nutrition, that may require additional evaluation before surgical intervention and allow appropriate risk stratification. For patients with a cardiac history or symptoms, a stress test and cardiology evaluation are indicated.

Family history or factors predisposing the patient to rectal cancer, such as FAP, HNPCC, and IBD, are important to take into account as one plans the operative procedure.

## Physical Examination

A careful and accurate digital rectal examination (DRE) is critical in determining the clinical stage and any plans for neoadjuvant therapy. DRE of a palpable lesion allows for the assessment of tumor size, mobility and fixation, anterior or posterior location, relationship to the sphincter mechanism and top of the anorectal ring, and distance from the anal verge.

Rigid proctoscopy is also essential to the evaluation of patients with rectal cancer because it demonstrates the proximal and distal levels of the mass from anal verge; extent of circumferential involvement; orientation within the lumen; and relationship to the vagina, prostate, or peritoneal reflection. All this information aids in determining the feasibility of local excision. Rigid proctoscopy also allows one to obtain an adequate tissue biopsy. Flexible sigmoidoscopy is not used routinely because the flexibility of the instrument can give a false distance between the tumor and the dentate line. Furthermore, a mass will often be described as being a sigmoid or rectosigmoid tumor on flexible colonoscopy, and, when the patient is evaluated in the office with rigid sigmoidoscopy, the lesion is often found to be much lower and in fact is often a true rectal cancer that qualifies for neoadjuvant chemoradiotherapy. Hence, rigid sigmoidoscopy is mandatory for all distal left sided lesions.

A complete colonoscopy to the cecum is essential to rule out synchronous cancers, which occur 2–8% of the time. We

prefer colonoscopy over virtual colonoscopy so that we may not only diagnose but also excise any amenable polyps.

Women should undergo a complete pelvic examination in order to determine vaginal invasion or spread to the ovaries. Men should be evaluated for extension into the prostate or bladder.

## Preoperative Staging

Following the initial history, DRE, and rigid proctoscopy, additional preoperative staging studies can help to determine the appropriate treatment for each patient, whether radical resection or local excision is warranted, and whether preoperative chemoradiation is recommended. Accurate preoperative staging is gaining increasing importance as combined-modality therapy and sphincter-preserving surgical approaches are considered.

Abdominal and pelvic computed tomographic (CT) scans can demonstrate regional tumor extension, lymphatic and distant metastases, and tumor-related complications such as perforation or fistula formation. Its accuracy in determining the depth of invasion, however, is less than that of endorectal ultrasound (ERUS) or specialized magnetic resonance imaging (MRI). Pelvic CT scan therefore is not recommended as the only modality for evaluation of a patient’s primary tumor. For example, the sensitivity of CT scan for detecting distant metastasis is higher (75–87%) than that for detecting perirectal nodal involvement (45%) or the depth of transmural invasion (70%). If a node is seen on CT scan, it should be presumed to be malignant because benign adenopathy is not normally seen around the rectum.

Intravenous contrast material at the time of a CT scan is important to assess the liver for metastatic disease, as well as to evaluate the size and function of the kidneys. Ureteral involvement by the tumor can be assessed and allows for planning of ureteral stent placement preoperatively.

All patients should undergo a chest x-ray or chest CT scan to exclude pulmonary metastases. Although useful information for assessing long-term prognosis, the extra information obtained from a chest CT scan often does not influence the decisions that need to be made to treat the local/regional disease.

## LABORATORY STUDIES

Complete blood count and electrolytes often are obtained. Liver enzymes may be normal in the setting of small hepatic metastases and are not a reliable marker for liver involvement.

Guidelines published by the American Society for Clinical Oncology (ASCO) recommend that serum carcinoembryonic antigen (CEA) levels be obtained preoperatively in patients with rectal cancer to aid in staging, surgical treatment planning, and assessment of prognosis. Although neither



sensitive nor specific enough to serve as a screening method for the detection of colorectal cancer, preoperative CEA levels greater than 5 ng/mL signify a worse prognosis, stage for stage, than those with lower levels. Additionally, elevated preoperative CEA levels that do not normalize following surgical resection imply the presence of persistent disease and the need for further evaluation. Furthermore, CEA is most helpful in identifying recurrent disease with an overall sensitivity rate of 70–80%.

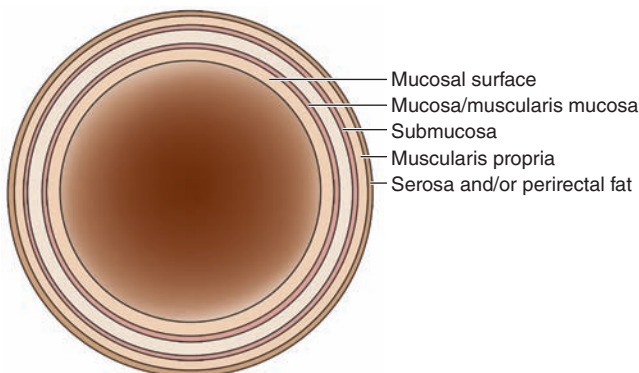
## ENDOLUMINAL ULTRASOUND

Compared with CT scanning, transrectal endoluminal or endoscopic ultrasound (TRUS) permits a more accurate characterization of the primary tumor and the status of the perirectal lymph nodes. Localized cancers involving only the mucosa and submucosa usually can be distinguished from tumors that penetrate the muscularis propria or extend through the rectal wall into the perirectal fat.

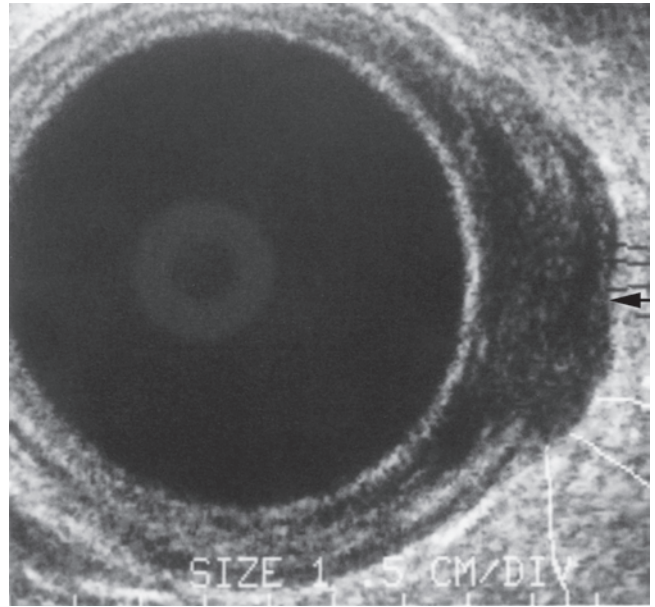
ERUS is an office-based procedure that is well tolerated and can be performed by the surgeon for preoperative planning. Figure 40-7 shows the schematic layers seen in TRUS.

**T Stage.** Several studies comparing the accuracy of TRUS with CT scan and MRI suggest that TRUS is superior for T staging of rectal cancer. The range of the accuracy of TRUS is 80–95% compared with 65–75% for CT scan, 75–85% for MRI, and 62% for DRE. In one review, the accuracy of TRUS was greatest (95%) in distinguishing whether a tumor was confined to the rectal wall (T1, T2) versus invading into the perirectal fat (T3 or greater) and less able to distinguish accurately T1 from T2 cancers.<sup>15</sup> Figure 40-8 demonstrates a uT2 lesion. Additionally, in patients who have received prior radiation, the accuracy decreases owing to edema and fibrosis.

Despite these data, there is considerable interobserver variability and a significant learning curve associated with



**FIGURE 40-7** Schematic of transrectal endoluminal ultrasonography illustrates the five layers seen on ultrasound.



**FIGURE 40-8** Transrectal endoluminal ultrasonography of a uT2 lesion. The *arrow* indicates the intact serosa.

performing TRUS. For these reasons, TRUS understages more frequently than overstages the primary rectal tumor. However, TRUS understages the cancer less often than CT scan (15 vs 39%). A modified TNM (tumor-node-metastasis) classification for rectal cancer has been proposed based on TRUS-derived T stage (Table 40-1).

**N Stage.** TRUS is less useful in predicting the status of perirectal lymph nodes. In a number of comparative studies, the accuracy of TRUS (70–75%) was similar to that of CT scan (55–65%) and MRI (60–65%). The accuracy of nodal staging with TRUS requires the nodes to be larger than 5 mm. The contribution of TRUS-guided fine-needle aspiration (FNA) biopsy to N-staging accuracy for rectal cancer is controversial.

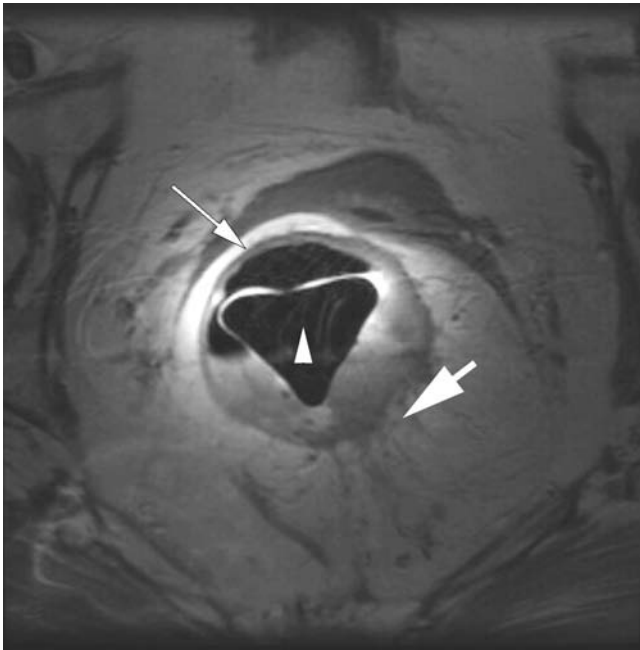
### TABLE 40-1: ENDOSCOPIC ULTRASOUND STAGING OF RECTAL TUMORS

uT1	Invasion confined to the mucosa and submucosa
uT2	Penetration of the muscularis propria but not through to the mesorectal fat
uT3	Invasion into the perirectal fat
uT4	Invasion into the adjacent organ
uN0	No enlargement of lymph nodes
uN1	Perirectal lymph nodes enlarged

## MAGNETIC RESONANCE IMAGING

Endorectal coil magnetic resonance imaging (ecMRI) and surface coil MRI are becoming more useful in the pretreatment evaluation of patients with rectal cancer. MRI offers some advantages compared with TRUS: It permits a larger field of view, it may be less operator- and technique-dependent, and it allows study of stenotic tumors that may not be even amenable to DRE.<sup>16</sup> Figure 40-9 illustrates a T<sub>3</sub> lesion. Like TRUS, ecMRI or phased-array MRI can discriminate small-volume nodal disease and subtle transmural invasion. These specialized MRI techniques can identify involved perirectal nodes on the basis of characteristics other than size, with reported accuracy rates of up to 95%. Another advantage over TRUS is identification of foci not only within the mesorectum but also outside the mesorectal fascia, such as the pelvic sidewall. We currently prefer phased-array MRI for staging of rectal cancers because it provides equal accuracy in staging compared to ecMRI but without the intrarectal coil.

Double-contrast MRI may permit more accurate T staging of rectal cancer by allowing better distinction between normal rectal wall, mucosa, muscularis, and perirectal tissues. In one report, the specificity and sensitivity of ecMRI with combined intravenous and endorectal contrast material to predict infiltration of the anal sphincter were 100 and 90%, respectively. However, N staging was not improved with this approach.



**FIGURE 40-9** Endorectal MRI of a T<sub>3</sub> lesion. *Arrowhead* indicates the site of the endorectal coil. *Large arrow* demonstrates finger-like projections of carcinoma invading into the mesorectal fat. *Small arrow* points to the anterior rectal wall. (Used with permission from Koensraad J. Mortele, MD, Beth Israel Deaconess Medical Center, Boston, MA.)

Phased-array surface coil MRI also may be beneficial in predicting the likelihood of a tumor-free resection margin by visualizing tumor involvement of the mesorectal fascia. If confirmed in other series, preoperative MRI may prove useful in selecting patients at high risk of local recurrence for therapy prior to resection.

## POSITRON EMISSION TOMOGRAPHY

Fluorine-18 fluorodeoxyglucose–positron emission tomography (FDG-PET) is effective in assessing the extent of pathologic response of primary rectal cancer to preoperative chemoradiation and may predict long-term outcome.<sup>17</sup> Additionally, it has an accuracy of 87% for detecting recurrence of rectal cancer after surgical resection and full-dose external-beam radiation therapy.<sup>18</sup> While PET scans are positive in 90% of primary and recurrent tumors and in distant metastatic disease, they are relatively inaccurate for nodal metastases. Rectal cancer rarely metastasizes to the bones or to the brain, and without symptoms these two areas are not included routinely in surveillance imaging. They will, however, light up on PET scan. Current guidelines recommend that PET scans not be used routinely in the standard workup of a rectal cancer.

## TNM STAGING

The purpose of staging any cancer is to describe the anatomic extent of the lesion. Staging by clinical examination, radiology, and pathology aids in planning treatment, evaluating response to treatment, comparing the results of various treatment regimens, and determining prognosis. Currently, the most widely accepted staging system for rectal cancer in the United States is the TNM classification system.

In 1987, the American Joint Committee on Cancer (AJCC) and the International Union Against Cancer (IUC) introduced the TNM staging system for colorectal cancer; this system was updated in 2010 (Tables 40-2 and 40-3). The TNM staging system is based on depth of tumor invasion as well as presence of lymph node or distant metastases. In stage I disease, the tumor may invade into the muscularis propria. In stage II disease, the tumor invades completely through this layer into the perirectal fat (T<sub>3</sub>) or adjacent organs (T<sub>4</sub>). Any lymph node metastasis represents stage III disease, and metastatic spread denotes stage IV disease. Depth of invasion (T stage) of the primary tumor is an important prognostic variable as increasing depth of invasion is correlated with an increasing chance of lymph node metastases. For instance, early-stage cancers extending into the muscularis mucosa (T<sub>1</sub>) will have a 10–13% incidence of metastasizing to perirectal lymph nodes.<sup>19,20</sup> In 805 pathology specimens Sitzler noted that 5.7% of T<sub>1</sub> lesions, 19.6% of T<sub>2</sub> lesions, 65.7% of T<sub>3</sub> lesions, and 78.8% of T<sub>4</sub> lesions had lymph node metastases.<sup>21</sup>

Generally, the biologic behavior of rectal cancer cannot be predicted by its location or size although there is a general

**TABLE 40-2: TNM CLASSIFICATION OF RECTAL CANCER**

Stage	Definition
<b>Primary tumor (T)</b>	
TX	Primary tumor cannot be assessed
T0	No evidence of primary tumor
Tis	Carcinoma in situ: intraepithelial or invasion of lamina propria
T1	Tumor invades submucosa
T2	Tumor invades muscularis propria
T3	Tumor invades through muscularis propria into the subserosa or into nonperitonealized pericolic or perirectal tissues
T4a	Tumor perforates visceral peritoneum
T4b	Tumor directly invades other organs or structures
<b>Regional lymph nodes (N)</b>	
NX	Regional lymph nodes cannot be assessed
N0	No regional lymph node metastases
N1	Metastasis in 1–3 regional lymph nodes
N1a	Metastasis in 1 regional lymph node
N1b	Metastasis in 2–3 regional lymph nodes
N1c	Tumor deposit(s) in the subserosa, mesentery, or nonperitonealized pericolic or perirectal tissues without regional nodal metastasis
N2	Metastasis in 4 or more regional lymph nodes
N2a	Metastasis in 4–6 regional lymph nodes
N2b	Metastasis in 7 or more regional lymph nodes
<b>Distant metastasis (M)</b>	
M0	No distant metastasis
M1	Distant metastasis
M1a	Metastasis confined to one organ or site (for example, liver, lung, ovary, nonregional node)
M1b	Metastases in more than one organ/site or the peritoneum

consensus among experts that the more distal cancers have a poorer outcome when compared stage for stage with more proximal lesions. Poorly differentiated cancers have a worse long-term prognosis than well- or moderately differentiated tumors. Other factors that portend a poor prognosis include direct tumor extension into adjacent structures (T4 lesions); lymph node metastases; lymphatic, vascular, or perineural invasion; and bowel obstruction.

## PRINCIPLES OF TREATMENT

Surgical resection is the cornerstone of curative therapy. Following a potentially curative resection, the 5-year survival rate varies according to disease extent<sup>22,23</sup> (Table 40-4). However, these survival figures may improve with the increased use of adjuvant therapy.

Surgical and oncologic management varies greatly depending on the stage and location of the tumor within the

rectum. Superficially invasive, small cancers may be managed effectively with local excision. However, most patients have more deeply invasive tumors that require major surgery, such as low anterior resection (LAR) or abdominoperineal resection (APR). Yet others present with locally advanced tumors adherent to adjoining structures such as the sacrum, pelvic sidewall, vagina, uterus, cervix, prostate, or bladder, requiring an even more extensive operation.

After establishing the diagnosis and completing the staging workup, a decision is made whether to pursue immediate resection or administer preoperative chemoradiotherapy. For patients with stage II and III rectal cancer the authors advocate for combined preoperative chemoradiotherapy. The authors recommend this for all stage II and III patients with tumors located in the distal two-third of the rectum. For patients with rectal cancer in the proximal one-third of the rectum, the authors use preoperative chemoradiotherapy on a case by case basis depending on the size and bulkiness of the tumor as well as the patient's medical and surgical history.

## Bowel Preparation

The high bacterial load in the intestinal tract requires preoperative bowel decontamination to reduce the incidence of infectious complications. Prior to the routine use of mechanical bowel preparation and preoperative antibiotics, the reported rate of infection following colorectal surgery was 60%.<sup>24</sup> A standard bowel preparation includes a clear-liquid diet 1–3 days prior to surgery, laxatives and/or enemas, and gastrointestinal tract irrigation with a solution of polyethylene glycol electrolyte lavage (GoLYTELY) or saline cathartics. In two separate surveys of North American colorectal surgeons, almost two-thirds preferred the polyethylene glycol electrolyte solutions because of the reliability of the cleansing results.<sup>25,26</sup> Certain preparations are contraindicated in patients with certain medical conditions. For example, patients with elevated creatinine or congestive heart failure should avoid the magnesium citrate preparation, whereas patients with gastroparesis should not take GoLYTELY.

Studies have shown that mechanical bowel preparation provides little, if any, additional benefit to reducing the perioperative infection rate. However, we still recommend to our patients that a mechanical bowel preparation be performed in large part because it allows for easier manipulation of the colon and rectum with both open and laparoscopic surgery.<sup>27</sup>

Oral antibiotics are also used to further decrease the incidence of postoperative infectious complications. Although mechanical cleansing decreases the total volume of stool in the colon, it does not affect the concentration of bacteria per milliliter of effluent. The most commonly used regimen is the Nichols/Condon preparation: neomycin 1 g and erythromycin base 1 g, both non-absorbable antibiotics, by mouth at 1:00 pm, 2:00 pm, and 10:00 pm on the day prior to surgery. Many surgeons substitute metronidazole 500 mg for the erythromycin base because it is active against a greater percentage of gastrointestinal anaerobes.



 **TABLE 40-3: ANATOMIC STAGE/PROGNOSTIC GROUPS**

Stage	T	N	M	Dukes*	MAC*
0	Tis	N0	M0	-	-
I	T1	N0	M0	A	A
	T2	N0	M0	A	B1
II-A	T3	N0	M0	B	B2
II-B	T4a	N0	M0	B	B2
II-C	T4b	N0	M0	B	B3
III-A	T1–T2	N1/N1c	M0	C	C1
	T1	N2a	M0	C	C1
III-B	T3–T4a	N1/N1c	M0	C	C2
	T2–T3	N2a	M0	C	C1/C2
	T1–T2	N2b	M0	C	C1
III-C	T4a	N2a	M0	C	C2
	T3–T4a	N2b	M0	C	C2
	T4b	N1–N2	M0	C	C3
IV-A	Any T	Any N	M1a	-	-
IV-B	Any T	Any N	M1b	-	-

NOTE: cTNM is the clinical classification, pTNM is the pathologic classification. They prefix is used for those cancers that are classified after neoadjuvant pretreatment (for example, ypTNM). Patients who have a complete pathologic response are ypT0N0cM0 that may be similar to Stage Group 0 or I. The r prefix is to be used for those cancers that have recurred after a disease-free interval (rTNM).

\* Dukes B is a composite of better (T3 N0 M0) and worse (T4 N0 M0) prognostic groups, as is Dukes C (any TN1 M0 and Any T N2 M0). MAC is the modified Astler-Coller classification.

Instead of an oral antibiotic preparation most surgeons use perioperative systemic antibiotics. A typical choice to cover both aerobic and anaerobic intestinal bacteria is cefazolin and metronidazole administered intravenously just prior to the skin incision. A second dose of cefazolin is administered 4 hours into the case. Postoperative antibiotic prophylaxis usually is continued for 24 hours, although the perioperative dose is more critical. Some surgeons do “double” prophylaxis with oral and systemic antibiotics in all surgeries below the peritoneal reflection. Currently it is our practice to just use intravenous systemic antibiotics.


Perioperative systemic antibiotic coverage is broadened in patients with high-risk cardiac lesions such as prosthetic heart valves, a previous history of endocarditis, or a surgically constructed systemic-pulmonary shunt and with intermediate-risk cardiac lesions such as mitral valve prolapse, valvular heart disease, or idiopathic hypertrophic subaortic stenosis. Intravenous ampicillin 2 g and gentamycin 1.5 mg/kg are administered 30–60 minutes before the procedure, and ampicillin is repeated once 6 hours postoperatively in place

of cefazolin; metronidazole is administered as usual. Vancomycin is substituted for ampicillin if the patient is allergic to penicillin or cephalosporin.

## Goals of Surgery for Rectal Cancer

The primary goal of surgical treatment for rectal cancer is complete eradication of the primary tumor along with the adjacent mesorectal tissue and the superior hemorrhoidal artery pedicle. Although reestablishment of bowel continuity at the time of surgery has become routine, cancer removal should not be compromised in an attempt to avoid a permanent colostomy.

For tumors located in the extraperitoneal rectum, resection margins are limited by the bony confines of the pelvis and the proximity of the bladder, prostate, and seminal vesicles in men and vagina in women. Although locoregional recurrence may be inevitable, local recurrence, cure, mortality, anastomotic leaks, and colostomy rates after rectal cancer surgery are related to surgical technique as well as to the experience and volume of the individual surgeon and institution.

 **TABLE 40-4: SURVIVAL RATES**

Stage I	80–90%
Stage II	62–76%
Stage III	30–40%
Stage IV	4–7%

## Resection Margins

### DISTAL MARGINS

The optimal distal resection margin for surgically treated rectal cancer remains controversial. Although the first line of

rectal cancer spread is upward along the lymphatics, tumors below the peritoneal reflection can spread distally via intra- or extramural lymphatic and vascular routes.

The use of APR for low rectal cancers traditionally has been based on the need for a 5-cm distal margin of normal tissue. However, in retrospective studies, margins as short as 1 cm have not been associated with an increased risk of local recurrence.<sup>28–30</sup> Distal intramural spread usually is limited to within 2.0 cm of the tumor unless the lesion is poorly differentiated or widely metastatic. Data from a randomized, prospective trial conducted by the National Surgical Adjuvant Breast and Bowel Project demonstrated no significant differences in survival or local recurrence when comparing distal rectal margins of less than 2, 2–2.9, and greater than 3 cm.<sup>28</sup> Therefore, a 2-cm distal margin is acceptable for resection of rectal carcinoma, although a 5-cm proximal margin is still recommended.<sup>31</sup>

## RADIAL MARGINS

The importance of obtaining an adequate circumferential or radial margin has been appreciated more in the last decade. In fact, the circumferential radial margin (CRM) is more critical than the proximal or distal margin for local control. Tumor involvement of the circumferential margin has been shown to be an independent predictor of both local recurrence and survival. The Norwegian Rectal Cancer group reported on circumferential resection margins with 29-month median follow-up in 686 patients who had curative intent LAR with TME alone (no adjuvant radiotherapy) for rectal adenocarcinoma. The Norwegian group found that the overall local recurrence rate was 7% (22% with positive CRM and 5% with a negative CRM). Moreover, 40% of patients with a positive CRM developed distant metastases whereas only 12% of those with negative CRM developed distant disease.<sup>32</sup> In this study a positive CRM clearly affected survival. In another report of 90 patients undergoing resection for rectal cancer, when the radial margins were histologically positive, the hazard ratio (HR) for local recurrence was 12.2, and the HR for death was 3.2 when compared with those with clear

circumferential margins. Furthermore, the length of mesorectum beyond the primary tumor that needs to be removed is thought to be between 3 and 5 cm because tumor implants usually are seen no further than 4 cm from the distal edge of the tumor within the mesorectum.<sup>6,12</sup> Therefore, in proximal rectal cancers, distal mesorectal excision 5 cm below the lower border of the tumor should be the goal.

## LOCAL EXCISION

### Oncologic Results

A number of retrospective studies of local excision since the 1970s have demonstrated a local recurrence rate of 7–33% and survival rates of 57–87%. Many of these reviews are limited, small, single-institution studies, often combining patients with tumors of different depths, including T3 lesions, positive margins, or who underwent different forms of local therapy, such as fulguration and snare cauterization. Despite these limitations, many of these studies have demonstrated that local excision for superficial tumors with negative margins may provide similar survival and local control but without the morbidity of the APR. Major risk factors for local recurrence include positive surgical margins, transmural extension, and poorly differentiated histology. These retrospective studies suggest that local excision of selected distal rectal adenocarcinomas may provide adequate oncologic control at considerably less morbidity than APR.

Several prospective studies have been published (Table 40-5). In a study from the M.D. Anderson Cancer Center, 46 patients underwent transanal excision of small distal rectal cancer followed by postoperative radiation treatment.<sup>33</sup> Patients with T3 lesions also were given chemotherapy. For patients with negative margins, there was only a 6.5% local recurrence rate (all were T3 tumors) with a 93% overall 3-year survival. Local treatments combined with radiation provided similar oncologic control for T1 or T2 small distal rectal adenocarcinomas as compared with APR.



**TABLE 40-5: RECURRENCE RATES AFTER LOCAL EXCISION AND ADJUVANT THERAPY**

	Patients (n)	Treatment	Follow-Up (mo)	Local Recurrence	Survival
Ota et al <sup>33</sup>	46	LE and post-op XRT and 5-FU for T2, T3	36 (median)	6.5% (3/46) All T3s	Overall 3-y 93%
Bleday et al <sup>34</sup>	48	LE, post-op XRT and 5-FU for T2, T3	41 (mean)	8% (4/48)	Disease-specific 96%
Steele et al <sup>35</sup>	110	LE, post-op XRT and 5-FU for T2	48 (mean)	T—5.1% (3/59)	Overall 6-y 85%; disease-specific
Greenberg et al <sup>36</sup>	110	Same as Steele	85	T2—13.7% (7/51)	Overall 10-y T1 84% T2 66%

5-FU, 5-fluorouracil; LE, local excision; post-op, postoperative; XRT, radiation therapy.

From the New England Deaconess Hospital in Boston, patients with small distal cancers (<4 cm in diameter and <10 cm from the dentate line) with no evidence of metastatic disease were entered in a prospective study.<sup>34</sup> Patients with T1 lesions were observed after local excision. Patients with T2 lesions treated with local excision were given postoperative chemoradiation. Several patients were found to have T3 lesions and all were recommended further radical surgery. Those who refused had adjuvant chemoradiation therapy and were followed. All patients were followed every 3 months for 2 years and then every 6 months for 5 years. The local recurrence rate in this study was 8%, and the cancer-specific mortality rate was 4%. Risk factors associated with recurrence were T3 cancers or lymphatic invasion. Surgery alone was adequate for T1 lesions, and surgery combined with chemoradiation was appropriate for T2 lesions excised with negative margins. Radical resection was and still is appropriate for tumors with positive margins after local excision or for T3 cancers. Patients with lymphovenous invasion deserve further therapy, although that therapy was not defined.

In his initial report Steele and colleagues published the only large multicenter prospective trial of local excision (CALGB 8984 [Cancer and Leukemia Group B]).<sup>35</sup> Patients were eligible for the study if their cancer was within 10 cm of the dentate line and was less than 4 cm and involved less than 40% of the luminal circumference. All patients preoperatively were thought to have N0M0 disease, as determined clinically and by CT scan. All study patients had negative margins. T1 lesions had no further treatment, and T2 lesions were treated with chemoradiation. After 6 years of follow-up, the overall survival (OS) and the disease-free survival (DFS) were 85 and 78%, respectively. DFS was 84 and 71% for T1 and T2 lesions, respectively. Seven patients recurred with local disease only and underwent APR with a 70% salvage rate. This approach was no worse than that of radical resection. Longer-term follow-up (median 7.1 years) of CALGB 8984 revealed that 10-year overall survival rates were 84% for T1 lesions and 66% for T2 lesions. DFS was reported at 75% in T1 patients and 64% in those with a T2 lesion. Furthermore, local and distant recurrence rates were 8 and 5% versus 18 and 12% in T1 and T2 lesions, respectively. The longer-term follow-up of CALGB 8984 showed that the rates of local recurrence, OS, and DFS didn't change significantly for T1 lesions, but that there was a significant decrease in OS and DFS in the T2 lesions even though these patients received adjuvant therapy. It is clear that local excision is indicated for appropriately selected patients and that local excision with adjuvant therapy should be used more judiciously especially in medically fit patients.<sup>36</sup>

## Patient Selection and Choice of Operation

Preoperative staging, primarily with ERUS or MRI, is most helpful in identifying appropriate patients for a local excision. Criteria for consideration for local excision are listed in



**TABLE 40-6: CHARACTERISTICS OF TUMORS AMENABLE TO LOCAL EXCISION**

T1N0 or T2N0 lesion
<4 cm in diameter
<40% circumference of the lumen
<10 cm from dentate line
Well- to moderately differentiated histology
No evidence of lymphatic or vascular invasion on biopsy
Patients with extensive metastatic disease and poor prognosis who require local control
Adjuvant treatment for patients with lymphatic invasion, T1 with poor prognosis features, T2 lesions

Table 40-6. Patients with T3 or N1 disease are inappropriate for local excision. Given the low probability of microscopic nodal disease in T1 lesions, these patients are the best candidates for local excision. T3 and T4 lesions have a high probability of nodal involvement and therefore should be treated with radical resection. Controversy remains over the best therapy for T2 lesions. Most colorectal surgeons still believe that radical surgery with anLAR or APR remains the standard for T2 lesions. However, local excision combined with postoperative chemoradiation achieves similar rates of survival but not necessarily similar rates of DFS. In patients with a T2 lesion who undergo treatment with local excision and adjuvant chemoradiation, those who have a recurrence ultimately require a salvage APR for cure. The American College of Surgeons Oncology Cooperative group has just finished enrolling patients in a trial examining the benefit of preoperative chemoradiotherapy followed by local excision for appropriately staged T2N0Mx distal rectal adenocarcinoma. Preliminary results have just been reported and there was a 44% pathologic complete response rate, 64% pathologic downstaging rate, 5% had ypT3 tumors and 1–2% positive radial margin rate. These preliminary results show that there is excellent pathologic complete response and downstaging as well as good surgical outcomes with nearly all margins being negative. The ultimate efficacy of this technique will depend on long-term oncologic outcomes which are still pending at the time of this publication.<sup>37</sup> If the long-term oncologic outcomes are satisfactory, this approach of accurate staging and then the application of neoadjuvant therapy, followed by a local excision for small T2N0 lesions, may be the new paradigm for this subset of rectal cancer patients.

Tumors less than 3 cm from the dentate line but not invading the sphincters usually can be resected via a transanal procedure. Tumors 5 cm from the dentate line may need a transcoccygeal approach or transanal endoscopic microsurgery (TEM). Tumors 7–10 cm from the dentate line require TEM or should be considered for an LAR. Clearly, tumors tethered to the mesorectum or pelvic floor on physical examination, suggesting transmural involvement, are not amenable to local excision. Patients with such lesions should undergo preoperative radiation followed by a radical resection.



Patients considered medically unfit for a major resection are good candidates for local treatment of most small, mobile tumors, including T2 and T3 lesions, accepting a higher rate of local recurrence. In these circumstances, adjuvant chemoradiation is advocated, and close follow-up is mandatory.

After local excision, if the pathology is unfavorable, the patient should be counseled to have further therapy, including chemoradiation therapy and either an LAR or APR with TME. Local excision in these circumstances can be considered an open biopsy and not the definitive therapy.

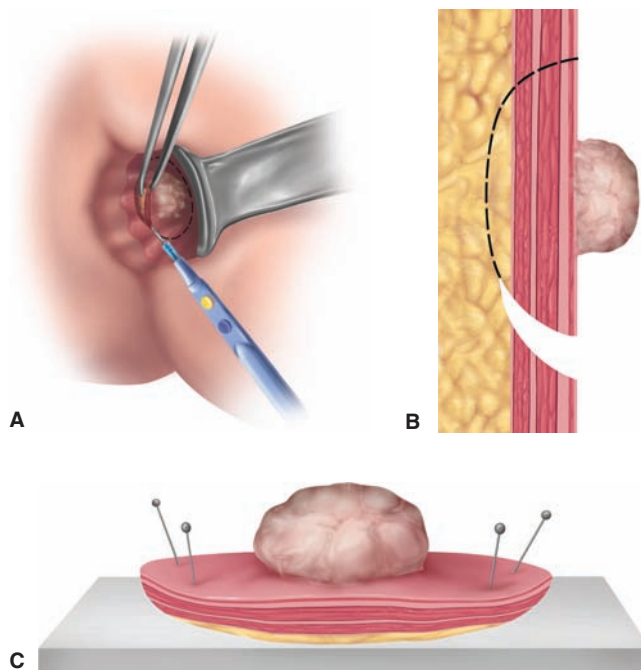
## Technique

There are four approaches to local excision: transsphincteric, transanal, transcoccygeal, and TEM. The transsphincteric technique, however, leads to significant dysfunction of the anal sphincters with subsequent moderate to severe fecal incontinence. Therefore, the transanal, transcoccygeal, and TEM approaches are the preferred techniques.

## Transanal Excision

The majority of small distal rectal cancers can be excised locally via a transanal excision. Tumors amenable to this approach usually range from 6–8 cm above the anal verge which is the same as 3–4 cm above the anorectal ring.

Prior to the procedure, all patients should receive a full mechanical and antibiotic bowel preparation. Pre- and perioperative medications are similar to those administered for radical resection. Most patients are placed in the prone jack-knife position, and the buttocks are taped apart. For lesions that are directly posterior, the lithotomy position can be used. The surgeon wears a fiberoptic headlight. A pudendal nerve block using 0.5% Marcaine (bupivacaine) with 1:100,000 units of epinephrine is administered to relax the sphincters and facilitate postoperative pain control. A Lone Star retractor (CooperSurgical, Inc., Trumbull, CT) can be used to expose the dentate line. A Pratt bivalve retractor (Pilling-Weck Instruments, Ft. Washington, PA), a Fansler operating speculum (HaydenMedical, Inc., Santa Clarita, CA) or Parks anal retractor (CS Surgical, Inc., Slidell, LA) is inserted to dilate the anus and expose the lesion. Once the tumor is viewed adequately, traction sutures using 2-0 Vicryl (Ethicon, Somerville, NJ) are placed 2 cm proximal to the tumor. The circumferential dissection line is outlined on the mucosa using the cautery with a pinpoint Bovie tip approximately 1 cm from the border of the tumor; careful attention should be paid to maintaining a wide proximal margin. If an adequate view of the lesion cannot be obtained initially, serial traction sutures starting distally are used to prolapse the lesion into the field. Additional local anesthetic is injected submucosally circumferentially along the Bovie markings to provide hemostasis. Starting proximally and proceeding circumferentially, a full-thickness incision of bowel wall is made down to perirectal fat using the cautery along the previously marked mucosa (Fig. 40-10). Once fat is reached, the dissection is made through the fat to undercut the



**FIGURE 40-10** Approach to transanal excision of a rectal tumor. **A.** A 1- to 2-cm margin is marked circumferentially with Bovie electrocautery on the rectal mucosa. **B.** Full-thickness excision down to perirectal fat is performed. **C.** The specimen is oriented for the pathologist. (Reprinted, with permission, from Bleday R. Local excision of rectal cancer. *World J Surg.* 1997;21:706–714.)

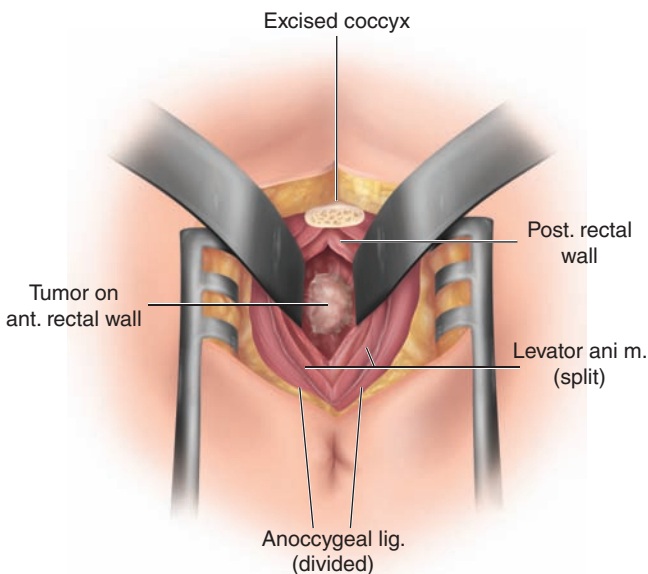
specimen. Anteriorly in a female patient, one must not injure the posterior wall of the vagina. In a male patient, one must avoid the prostate. Once the specimen is free, carefully maintain and mark the orientation for the pathologist (eg, proximal, anterior, left, right). Irrigate and check for hemostasis. After excision, the defect in the bowel wall is closed transversely with full-thickness bites using interrupted 3-0 Vicryl sutures. One stitch is placed in the center of the incision. One-half is closed, followed by the other. A rigid sigmoidoscope is inserted to visualize the suture line and to ensure patency of the rectal lumen. The patient then is placed supine. A pad is applied to the rectal area and secured with mesh rectal shorts. A pack in the anal canal or rectum is not used. These procedures can be done either as an outpatient or with a short stay. Potential complications include urinary retention, urinary tract infections, fecal impaction, infections in the perirectal and ischioirectal spaces, and delayed hemorrhage. The incidence of these complications is quite low; mortality in most series is zero.

## Transcoccygeal Excision

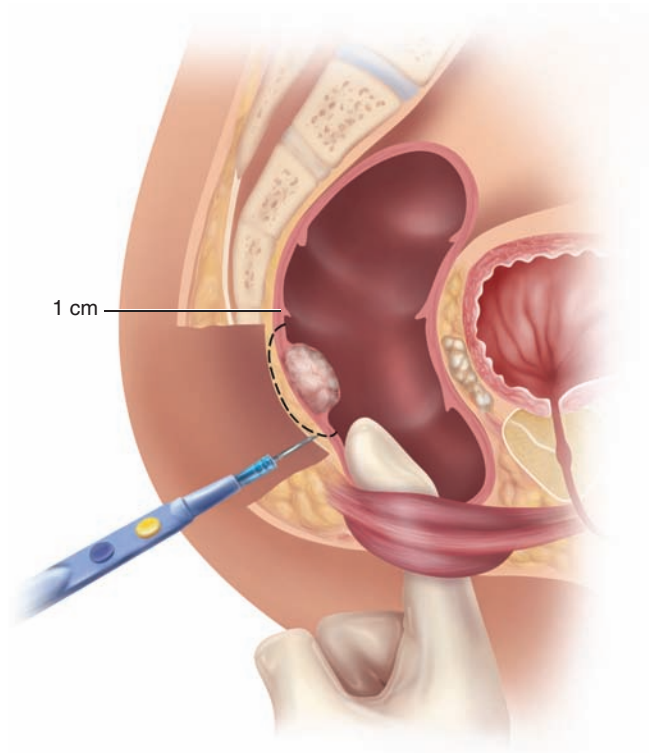
Originally popularized by Kraske, the transcoccygeal excision is used for larger or more proximal lesions within the middle or distal third of the rectum. Bleday et al reported that the average distance of the distal margin of an appropriate tumor

that was selected for the posterior or Kraske approach was approximately 4.8 cm from the dentate line.<sup>34</sup> This approach is useful for lesions on the posterior wall of the rectum but can be used for anterior lesions.

Patients undergo similar bowel preparation and thrombosis precautions as the transanal excision patients. The patient is placed in the prone jackknife position. The buttocks are taped apart for better exposure, but at closure the tape is released to facilitate approximation of the subcutaneous tissues and skin. After prepping the skin, the rectum is irrigated with a Betadine (povidone/iodine) solution. The incision is made in the intergluteal fold over the sacrum and coccyx down to the upper border of the posterior aspect of the external sphincter. After division of the skin and subcutaneous tissues, one encounters the coccyx and anal coccygeal ligament. In order to obtain optimal exposure, the coccyx is removed by cauterizing its attachments, including the anal coccygeal ligament, from each side and from its lower edge and then proceeding with the dissection on its undersurface. A cutting wire is used to transect the sacral coccygeal joint. With removal of the coccyx, bleeding from an extension of the middle sacral artery is controlled with electrocautery. The levator ani muscles are separated in the midline, exposing a membrane that is just outside the mesorectal fat. Once this membrane is divided, the rectum can be completely mobilized within the intraperitoneal pelvis. For anterior lesions, a posterior proctotomy is made; the anterior rectum is approached under direct vision, with removal of the tumor along with a 1-cm margin (Fig. 40-11). For posterior-based lesions, after complete mobilization of the mesorectum, the distal margin of the tumor



**FIGURE 40-11** Kraske approach to an anterior lesion. The coccyx is excised, the levator is split in the midline, and the rectum is mobilized. The posterior rectal wall is opened to expose an anterior lesion. (Reprinted, with permission, from Bleday R. Local excision of rectal cancer. *World J Surg.* 1997;21:706–714.)



**FIGURE 40-12** Kraske approach to a posterior lesion. After the rectum has been exposed, the surgeon may palpate the distal margin of the tumor. The tumor is excised with a 1-cm margin. (Reprinted, with permission, from Bleday R. Local excision of rectal cancer. *World J Surg.* 1997;21:706–714.)

can be palpated via a rectal examination; the mesorectum and rectum are transected approximately 1 cm distal to the tumor (Fig. 40-12). The tumor is excised with a 1-cm margin of normal tissue. The advantage of the posterior approach is that the immediate mesorectal tissue adjacent to the tumor is removed along with perirectal nodes. After removal, the specimen is oriented for the pathologist. The incision is closed in a transverse manner using an absorbable suture such as 3-0 Vicryl or 3-0 PDS (Ethicon, Somerville, NJ). After closure of the rectum, an air test is performed by insufflating the rectum with air and filling the operative field with sterile saline. After all air leaks are controlled, the levator ani musculature is reapproximated and the anal coccygeal ligament is reattached to the sacrum, followed by closure of the subcutaneous tissues and skin.

One of the most troubling complications of the transcoccygeal excision is a fecal fistula extending from the rectum to the posterior incision. The incidence of this complication ranges from 5 to 20%.<sup>35</sup> These fistulas usually heal after temporary fecal diversion.

## Transanal Endoscopic Microsurgery

The transanal endoscopic microsurgery (TEM) technique was first described by Gerhard Buess of Tübingen, Germany

in 1980. It is especially useful for small benign and malignant lesions in the mid and proximal rectum that are too high for a traditional transanal excision. This technique is widely used in Europe but over the years has been underused in North America until recently. It is gradually becoming standard practice for early mid to upper rectal lesions. The specialized instrumentation includes a 4-cm Wolf operating proctoscope (Richard Wolf Company, Frankfurt am Main, Germany) in lengths of 12 and 20 cm with a flat or beveled end. The operating proctoscope is equipped with a binocular microscope and videoscope attachment for viewing on a standard laparoscopy tower. A CO<sub>2</sub> insufflator and long operating surgical instruments are needed as well. The surgeon must be trained in the technique, which follows the same principles as transanal excision described earlier using the pinpoint tip on the Bovie electrocautery. Preoperative localization in the office with a rigid sigmoidoscope is essential so that the patient can be appropriately positioned. The patient is positioned using a beanbag and fixation to the table with tape, which allows the patient to be rotated laterally during the procedure. For an anterior lesion, the patient is placed in the prone jack-knife position. For a posterior lesion, the patient is placed in a modified lithotomy position. For lateral lesions, the patient can be placed on the appropriate side so that the lesion is at the inferior quadrant of the visual field. After the patient is appropriately positioned, the operating proctoscope is fixed to the table with a rigid support arm and a glass faceplate. The faceplate is equipped with two operating ports and a suction port. The rectum is distended with carbon dioxide anywhere from 15- to 26-cm water pressure so that the tumor can be visualized and the resection and closure of the rectum can be completed. After full-thickness excision of the lesion is completed, the defect is endoscopically closed with interrupted 3-0 PDS figure-of-eight sutures. If unable, the defect may be left open as in a standard transanal excision. The one caveat, however, is that extreme care must be taken to identify the peritoneal reflection, especially anteriorly. If dissection carries into the peritoneal cavity, the defect must be closed. If we enter the peritoneal cavity, after we close the defect, our practice is to observe these patients in hospital until they are passing flatus. In selected patients, temporary diversion is needed after entering the peritoneal cavity. Furthermore, patients in whom TEM is contemplated should be made aware that because of technical considerations (proctoscope won't fit or pass and/or poor visualization or entry into the peritoneal cavity), an LAR may need to be performed. This is especially true in patients with a known malignancy.

Unfortunately, the literature describing oncologic outcomes for TEM resection of early-stage rectal adenocarcinoma is mainly single institution, small series, and with short-term follow-up. Most of these studies make a comparison with radical surgery (LAR, APR) but never make a direct comparison with transanal resection. For the most part, the comparison of TEM to traditional transanal excision is made with historical data alone. This is in part because very distal lesions near the sphincter are difficult to excise with the TEM and a traditional transanal excision is easier, whereas the more

proximal lesions are not amenable to a traditional approach and a TEM is more likely to succeed in removing these lesions per rectum. Hence, only a small number of tumors that are above 8 cm and below 10 cm from the anal verge could ever be enrolled in a trial to make a direct comparison. To answer this question, a multicenter randomized trial comparing TEM to traditional transanal excision for early-stage rectal cancer with and without adjuvant radiotherapy needs to be performed. To date this trial has not been done.

TEM resection of low-risk T1 rectal adenocarcinoma results in a 0–11% local recurrence rate whereas local recurrence for T2 lesions without adjuvant therapy is approximately 19–35%. When T2 and T3 lesions are treated with adjuvant or neoadjuvant therapy and TEM resection, the local recurrence rates decrease to 14 and 3%, respectively. One caveat is that all of these studies have short-term follow-up with the longest being 4 years. Indirect comparisons of local excision with TEM for T1 lesions have similar local recurrence rates (7–18% TAE vs 0–11% TEM), and as a result the decision to perform traditional transanal excision versus TEM should depend on the location of the tumor and the individual surgeon's expertise. Local recurrence rates without chemoradiotherapy for either TEM or transanal excision, on the other hand, are not satisfactory. Local recurrence rates for T2 lesions excised by TEM range from 19 to 35% versus 26 to 47% for traditional transanal excision (see Table 12-2) In either case, the results are not adequate, and as a result medically fit patients with T2 lesions should not have either a TEM or a transanal excision without the addition of radiotherapy.

In summary, the results of TEM resection are as good as or better than traditional transanal resection for early rectal cancer. When deciding whether to utilize transanal excision or TEM, the surgeon should remember that TEM offers better visualization, almost complete intact excision, and access to lesions that are higher in the rectum and otherwise would need radical surgery. Cataldo's group from the University of Vermont has shown that TEM resection resulted in intact nonfragmented excision 94% of the time whereas transanal excision only accomplished intact nonfragmented excision 65% of the time ( $p < .001$ ) and tumor-free margins were 98% with TEM versus 78% with TAE when resecting a rectal cancer ( $p = .03$ ). Furthermore, they showed a nonstatistically significant trend to lower recurrence rates (22% for TAE and 3% for TEM).<sup>38</sup>

## LOW ANTERIOR RESECTION WITH TOTAL MESORECTAL EXCISION

### Oncologic Results

Local failures most often result from inadequate surgical clearance of the radial margin. The concept of total mesorectal excision (TME) proposed by Heald et al has been shown to improve both disease-free and overall survival.<sup>3</sup> TME in conjunction with an LAR or APR involves precise dissection

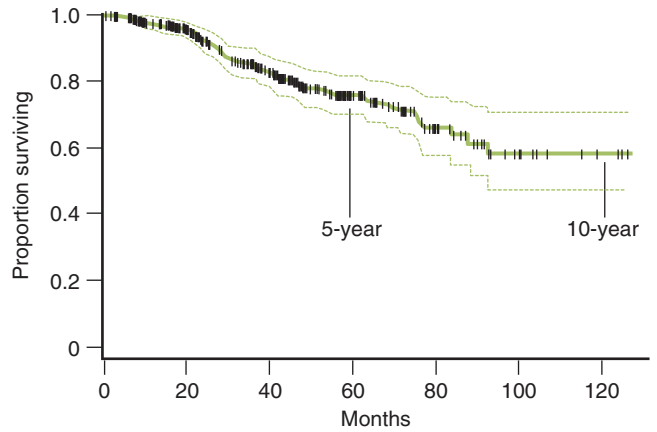


and removal of the entire rectal mesentery, including that distal to the tumor, as an intact unit. Unlike conventional blunt dissection, which may leave residual mesorectum in the pelvis, TME involves sharp dissection under direct vision in the avascular, areolar plane between the fascia propria of the rectum, which encompasses the mesorectum, and the parietal fascia overlying the pelvic wall structures. This procedure emphasizes autonomic nerve preservation (ANP) and complete hemostasis and avoids violation of the mesorectal envelope. This results in a characteristic bilobed, smooth, glistening surface of the excised mesorectum.

Because rectal cancer spread appears to be limited to the mesorectal envelope, its total removal should encompass virtually every tumor satellite, thus improving the likelihood of local control. The excellent results with TME may be attributed to improved lateral clearance with removal of potential tumor deposits in the mesentery and decreased risk of tumor spillage from a disrupted mesentery.<sup>39</sup> The completeness of the mesorectal excision influences local control, even if the surgical margins are uninvolved. In one report, both local (11.4 vs 5.5%) and distant recurrence rates (19.2 vs 12.2%) were higher in patients with an incomplete, as compared with a complete or nearly complete, mesorectal resection. These favorable results have led some to question the need for routine postoperative radiation in patients undergoing complete resection of rectal cancer with TME. However, the Dutch neoadjuvant trial that randomly assigned 1861 patients with resectable rectal cancer to TME alone or a short course of preoperative radiation (5 Gy daily for 5 days, in the “Swedish style”) followed by TME demonstrated a significantly decreased rate of local recurrence 8.2 versus 2.4% at 2 years.<sup>40</sup>

Of greatest importance is that improved local control appears to result in better overall survival. In one of the earliest reports, Heald et al noted a local recurrence rate of 3.6% and a survival rate of 86% after 9 years of follow-up.<sup>41</sup> In 1994, the Norwegian Rectal Cancer Group was founded to improve the surgical standard by implementing TME on a national level and to evaluate the results; courses were arranged to teach surgeons the technique of TME. Optimized TME reduced the rate of local recurrence (6% TME vs 12% non-TME) and increased overall survival (73% TME vs 60% non-TME) within 2 years.<sup>42</sup> This led to a strategic change in both Norway and the United States to initiate quality assessment in the surgical treatment of rectal cancer.

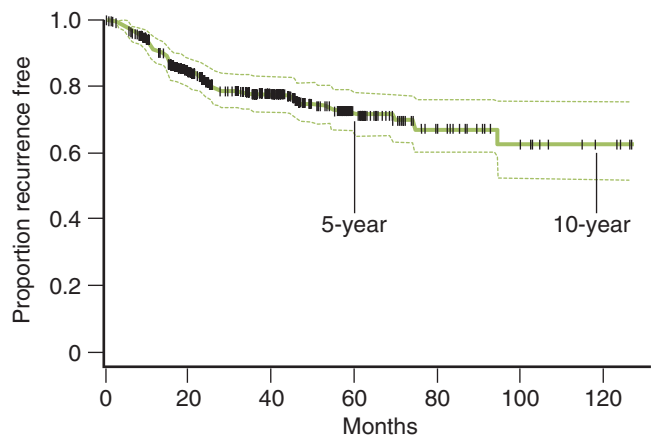
Guillem et al recently demonstrated an improved overall and disease-free survival in patients with T3 or N1 tumors who underwent TME after preoperative combined-modality therapy.<sup>43</sup> With a median follow-up of 44 months, the estimated 10-year overall survival was 58% (Fig. 40-13) and 10-year recurrence-free survival was 62% (Fig. 40-14). On multivariate analysis, pathologic response greater than 95%, lack of lymphovascular invasion and/or perineural invasion (PNI), and lack of postoperative positive lymph nodes were significantly associated with improved overall and disease-free survival.



**FIGURE 40-13** Five- and 10-year overall survival with 95% confidence intervals of rectal cancer patients following preoperative combined modality therapy and total mesorectal excision. (Used, with permission, from Guillem JG, Chessin DB, Cohen AM, et al. Long-term oncologic outcome following preoperative combined modality therapy and total mesorectal excision of locally advanced rectal cancer. *Ann Surg.* 2005;241:829–838.)

## Lateral Nodal Dissection

Despite the advent of TME and the addition of neoadjuvant chemoradiotherapy to the treatment of patients with rectal cancer, there is still a risk of local pelvic recurrence and the appearance of distant metastatic disease. Lateral nodal spread, especially in distal rectal cancers, is one possible culprit for treatment failures in rectal cancer. It is well established that distal rectal adenocarcinomas have a worse prognosis than



**FIGURE 40-14** Five- and 10-year recurrence-free survival with 95% confidence intervals of rectal cancer patients following preoperative combined-modality therapy and total mesorectal excision (TME). (Used, with permission, from Guillem JG, Chessin DB, Cohen AM, et al. Long-term oncologic outcome following preoperative combined modality therapy and total mesorectal excision of locally advanced rectal cancer. *Ann Surg.* 2005;241:829–838.)

more proximally based lesions. Most surgeons attribute this to three factors: (1) Distal tumors require a more difficult low dissection in a narrow pelvis; (2) there are probably biologic differences in tumors with the low-lying tumors probably having a poorer biology; and (3) the more distal tumors have a predilection to more complex lymphatic channels and the possibility of lateral spread into the systemic circulation as well as the portal circulation. Takahashi et al performed a retrospective analysis of 764 patients over a 20-year period (1975–1995) who underwent a curative three-space dissection. The three spaces are defined as follows: (1) The inner space is encircled by the visceral pelvic fascia posteriorly and Denonvilliers' fascia anteriorly, and laterally the three spaces unite near the pelvic nerve plexus; (2) the intermediate space is defined by the parietal pelvic fascia posteriorly and the internal iliac arteries and branches laterally and anteriorly; and (3) the outer space is lateral to the internal iliac arteries. Takahashi found that 66 of 764 patients (8.6%) had lateral nodal spread of their rectal cancer. More importantly, 16.4% of the low-lying rectal cancers had their lower margins less than 5 cm above the dentate line. Lateral nodal spread is outside the traditional TME resection plane but can be encompassed by a three-space lateral nodal dissection in appropriate patients. When this was achieved, they had a 42.4% 5-year survival in their subgroup of patients who had lateral spread and a curative three-space dissection.<sup>44</sup>

A comparative study of Japanese and Dutch patients examined local recurrence in Dutch patients who received TME-alone versus TME-plus preoperative radiotherapy and Japanese patients who were treated with TME-plus lateral nodal dissection (LAR or APR). Most Japanese patients did not receive neoadjuvant therapy. Local recurrence, lateral pelvic recurrence, and presacral recurrence rates were analyzed and are shown in Table 40-7.

In summary, both TME with radiotherapy and lateral nodal dissection without radiotherapy result in excellent local control and have improved local control over TME alone. The conclusion is that the radiotherapy sterilizes the lateral space that has microscopic tumor extension beyond the traditional TME resection plane.<sup>45</sup> The major caveat is that patients who have TME alone have much better postoperative sexual and urinary function than those who have TME-plus lateral nodal dissection.<sup>46</sup>

**TABLE 40-7: ANALYSIS OF LOCAL, LATERAL PELVIC, AND PRESACRAL RECURRENCE RATES**

	TME Alone (%)	TME + RT (%)	TME + Lateral Dissection (%)
Local recurrence	12.1	5.8	6.9
Lateral pelvic recurrence	2.7	0.8	2.2
Presacral recurrence	3.2	3.7	0.6

## Quality of Life

Quality of life has improved with TME and ANP. Conventional rectal surgery is associated with a significant incidence of impotence, retrograde ejaculation, and urinary incontinence, presumably owing to damage to the pelvic autonomic parasympathetic and sympathetic nerves by blunt dissection.<sup>47</sup> Postoperative impotence, retrograde ejaculation, or both are observed in 25–75% of conventionally treated patients compared with only 10–29% of patients after TME with its careful nerve-sparing dissection.<sup>47</sup>

Erectile capacity and normal ejaculation may be preserved in most male patients, especially those 60 years of age or younger. In one retrospective study of patients undergoing TME with ANP, 86% of male patients younger than 60 years and 67% of those 60 years or older were able both to engage in postoperative sexual intercourse and to achieve orgasm.<sup>47</sup> In female patients, sexual activity was maintained in 86%, sexual arousal with vaginal lubrication in 98%, and the ability to achieve orgasm in 91%. With the advent of pelvic dissections that preserve autonomic nerves, postoperative sexual dysfunction rates have been reduced from greater than 50% to 10–28%.<sup>47</sup>

Isolated urinary dysfunction is uncommon with preservation of the pelvic autonomic nerves. In a prospective study of rectal cancer patients undergoing TME with ANP, only 2 of 35 had difficulty with bladder emptying and possessed evidence of bladder denervation on postoperative studies.

Some studies, however, have demonstrated impaired quality of life owing to LAR with TME in part because of a temporary loop ileostomy or preoperative radiotherapy. Yet cost-utility analysis estimates that improved survival outweighs impaired quality of life.<sup>48</sup>

## Technique of Total Mesorectal Excision

Prior to the procedure, all patients receive a full mechanical and antibiotic bowel preparation. The patient's abdomen is marked preoperatively by the enterostomal therapy nurse for potential stoma sites. An epidural catheter is placed by the anesthesia team for postoperative pain control. Sequential compression devices are applied to the lower extremities before general anesthesia is induced for deep vein thrombosis (DVT) prophylaxis. One dose of 5000 units of heparin is administered subcutaneously. Cefazolin and metronidazole are infused. After anesthesia is induced, the patient is brought down on the table so that the buttocks are at the edge; a gel pad placed under the buttocks facilitates access to the anus. The patient is placed in a modified lithotomy position using Allen or Yellow Fin stirrups (Fig. 40-15). The hips are minimally flexed and abducted. The feet are positioned flat in the stirrups; an imaginary line is visualized keeping the ankle, knee, and contralateral shoulder in a straight line. Care is paid to having no pressure on the peroneal nerve or bony prominences; a hand should be able to be placed easily between

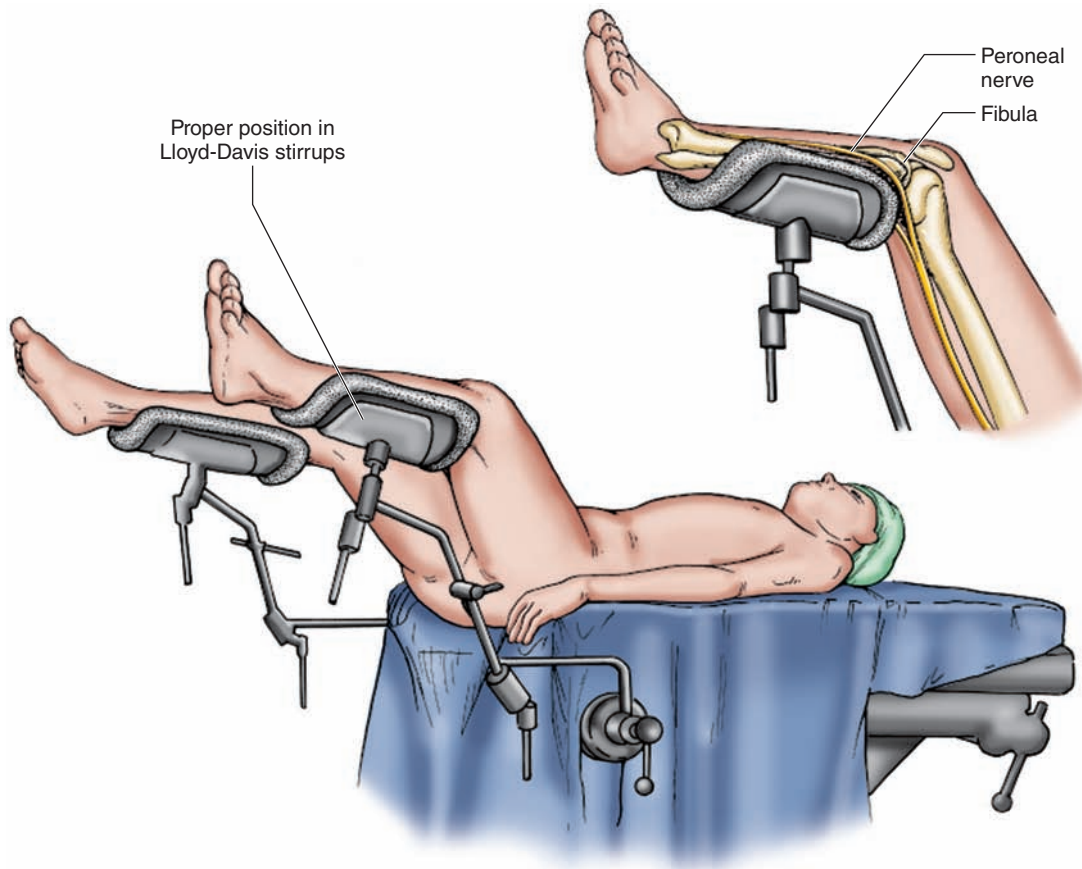


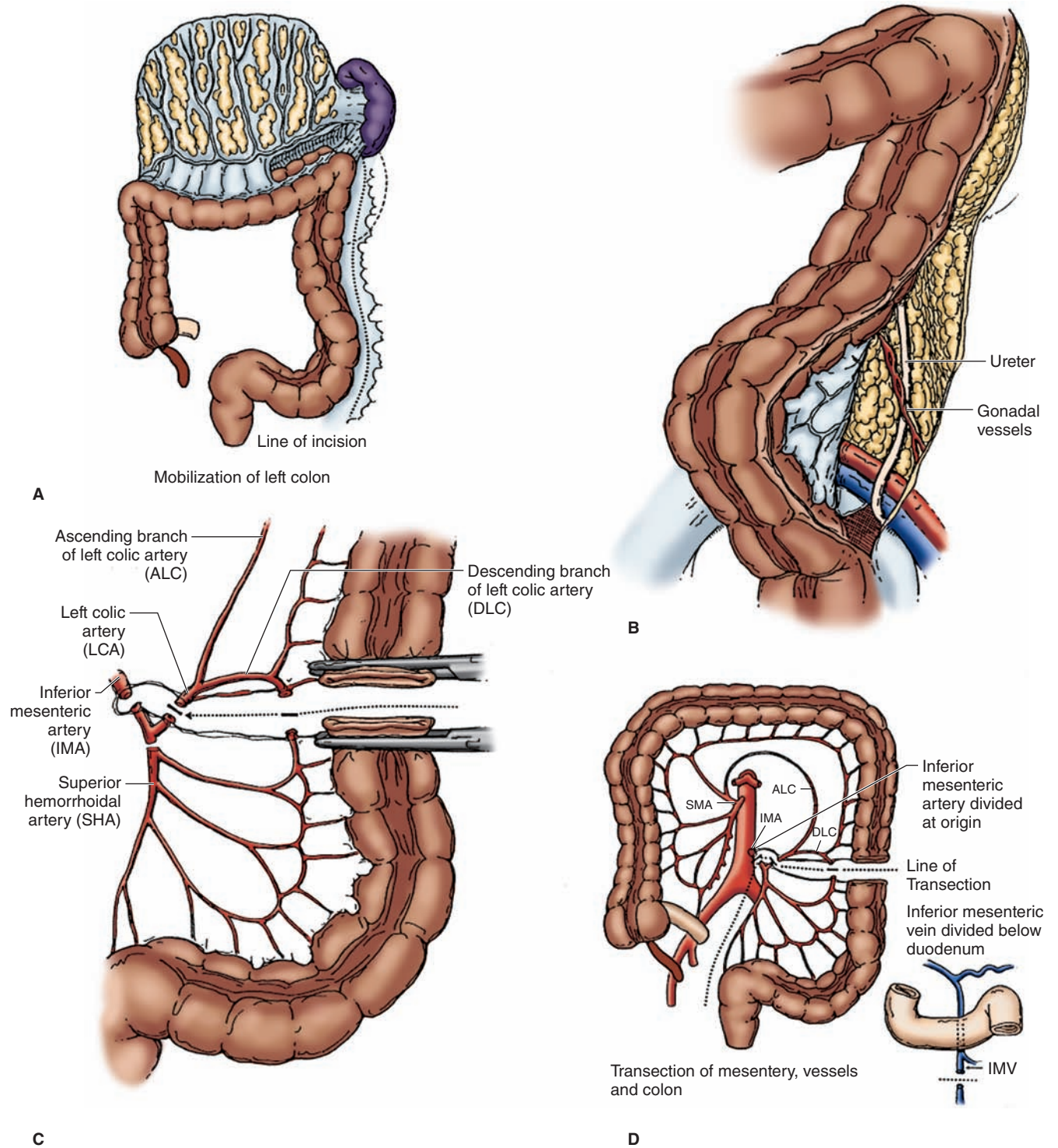
FIGURE 40-15 Position of patient for surgical treatment of rectal cancer allows access to both the abdomen and the perineum.

the posterolateral aspect of each lower leg and its respective stirrup. If the patient has had previous pelvic surgery or evidence of hydronephrosis on CT scan, consider bilateral ureteral stent placement. A Foley catheter is placed and is draped over one leg. A nasogastric tube is inserted by the anesthesia team. A DRE is performed. If there is any question regarding the distal or proximal limits of the tumor, rigid proctoscopy may be performed at this time. Preoperatively, the lesion may have been marked by an injection of India Ink. The surgeon should wear a headlight to help with visualization in the lower pelvis. Most surgeons stand on the patient's left, which allows them to operate more efficiently with their right hand in the lower pelvis. A low midline incision is made between the umbilicus and the pubis, keeping in mind potential stoma sites; cephalad extension may be necessary to mobilize the splenic flexure. The abdomen is explored to search for metastatic disease in the liver or peritoneal surfaces. The rectum is palpated to assess the primary mass. The colon is palpated for any synchronous lesions.

The abdominal self-retractor is set up. The patient is placed in slight Trendelenburg's position. The sigmoid is mobilized laterally by scoring the white line of Toldt (Fig. 40-16A). The

left ureter is identified by several ways: visualizing it cross over the bifurcation of the common iliac artery, palpating the external iliac artery and pinching the tissue above it, locating it at the level where the sigmoid turns, or incising the peritoneum over the psoas muscle and finding the ureter on the medial aspect of the peritoneum (Fig. 40-16B). If it is clear that much length will be necessary for reconstruction, the splenic flexure is mobilized. Tension on the colon should be gentle but firm; too much traction on the colon or omentum can cause splenic injury. The transverse colon is freed from the omentum by sharp dissection along the avascular plane between the two structures. The bowel is packed into the upper abdomen. The sigmoid is held up in the air at the junction between the descending colon and sigmoid. Both sides of the mesentery are scored from this point down to the sacral promontory. The right ureter is identified. The colon usually is divided at the sigmoid-descending colon junction using a linear stapler (or may be divided between two bowel clamps, which would require a hand-sewn anastomosis). The sigmoidal vessels are isolated and divided using large Kelly clamps, two proximally and one distally. Metzenbaum scissors are used to divide the vessels. The vessels are doubly





**FIGURE 40-16** Mobilization of the left colon. **A.** Incision line around the left colon. **B.** Left colon reflected medially, exposing the ureter and gonadal vessels. **C.** Superior hemorrhoidal artery is divided close to the aorta to result in a high arterial ligation. The arcade of Riolan is preserved, and the left colon and mesentery are divided at the junction of the descending and sigmoid colon. **D.** Proximal ligation of the inferior mesenteric vein adds extra mobility.

ligated. The colon is packed cephalad, out of the field. The superior hemorrhoidal artery is then divided at the junction with the left colic artery (Fig. 40-16C). A more proximal ligation of the inferior mesenteric vessel can also be performed if extra length on the colon is needed, but it is not necessary to ligate the IMA flush with the aorta for oncologic reasons. One usually suture-ligates the superior hemorrhoidal vessels so as to ensure hemostasis.

After dividing the superior hemorrhoidal artery, it is important to find the proper plane of dissection at the sacral promontory. One first locates the sympathetic nerves along the pelvic brim. The rectum is retracted anteriorly. Electrocautery with a long Bovie tip is used to develop the loose areolar plane of avascular issue posteriorly (Fig 40-17B). The nerves are visualized and kept posterior to the plane of resection. The presacral fascia is incised down to Waldeyer's fascia, and the dissection is carried inferiorly to the coccyx. The St. Mark's abdominal retractor facilitates the deep pelvic dissection.

The anterior and lateral dissections are then started after the posterior dissection has been partially completed. The peritoneum is incised on each side and then across the anterior midline to meet at the deepest point in the cul-de-sac, the groove between the rectum and the anterior structures (uterus/vagina in women, seminal vesicles in men) (Fig. 40-17A). The mesorectum is separated from the pelvic sidewall using the cautery to divide the thin areolar tissue that is found when one is dissecting in the proper plane. The dissection is carried down anterolaterally to the lateral ligaments or "stalks" (Fig. 40-17C). Only 25% of patients have distinct branches of the middle rectal vessels in these ligaments. They can be divided flush with the pelvic sidewall, but care should be taken to preserve the hypogastric plexus that lies on the pelvic sidewall just lateral to the seminal vesicles in men or just lateral to the cardinal ligaments in women. Preservation of the plexus helps with avoiding postoperative potency or urinary problems, and resection of the plexus is rarely helpful for oncologic reasons. Throughout the lateral dissection, one should be aware of the nerves and vessels along the pelvic sidewall. Too lateral a dissection causes bleeding from the pelvic sidewall.

Anteriorly, the planes are less distinct, and the fat of the mesorectum is thin. The vaginal wall or seminal vesicles are elevated anteriorly using the lipped St. Mark's retractor while the surgeon places posterior traction on the rectum. In the male patient, the dissection is continued through or anterior to Denonvilliers' fascia (Fig. 40-17D). This fascia is often two layers of a thin membrane. When performing a cancer resection, one should take both layers of this membranous fascia off the seminal vesicles and upper prostate if possible.

## POINT OF TRANSECTION

For middle to low rectal cancers, TME involves removing the entire mesorectum with its enveloping fascia as an intact unit. For tumors in the upper rectum (>10 cm from the anal verge), TME is extended to 5–6 cm below the level

of the tumor, dividing the rectum and mesorectum at the same level. A number of pathologic studies demonstrate that tumor spread within the mesorectum rarely extends beyond 4 cm distal to the caudal edge of the tumor; usually most nodes or mesorectal implants are within 3 cm of the distal edge of the tumor.<sup>6,12</sup> However, multiple studies have shown that a 2-cm margin is adequate on the mucosa. Fewer than 2–4% of tumors will have mucosal or submucosal spread beyond 2 cm distally. Rigid sigmoidoscopy may be used to identify the appropriate site for transection if the cancer is not palpable, especially after neoadjuvant therapy.

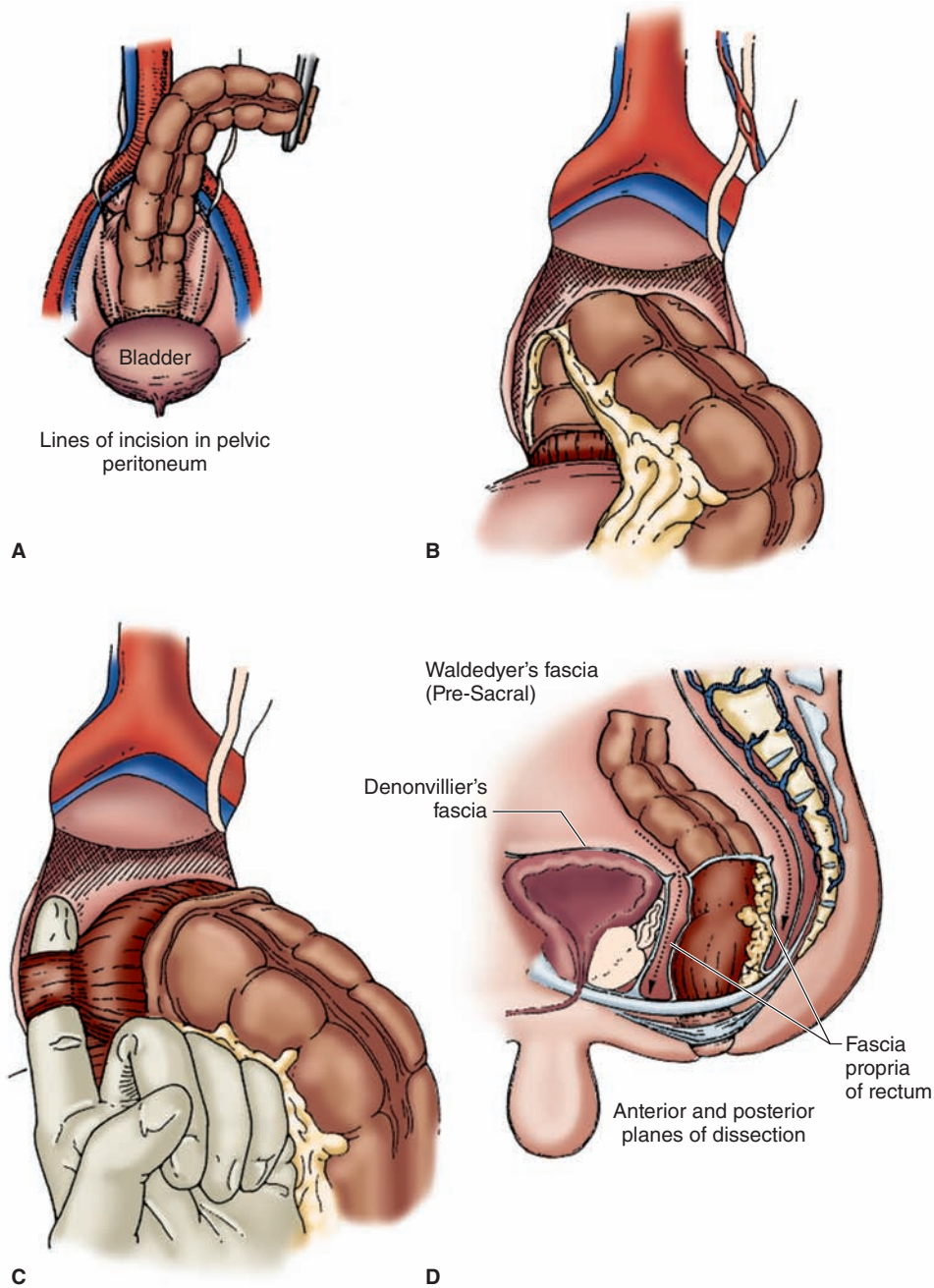
Once the rectum has been mobilized, a tumor measured at 5 cm by rigid proctoscopy often may be moved to 8 cm from the dentate line, a distance that permits an adequate resection margin and sphincter preservation (Fig. 40-18).

When the distal extent of the tumor and the site of transection have been established, electrocautery is used to dissect the mesorectal fat away from the rectum. Vessels require ligation with 2-0 Vicryl ties. It is important to keep the dissection of the mesorectum perpendicular to the site of transection. "Coning in" as one divides the mesorectum prior to transection should be avoided.

Once the bowel has been cleared of mesorectal fat, a 30-, 45-, or 60-mm TA linear stapler is used to staple the rectum (Fig. 40-19A). This is the first staple line in the "double-stapling technique." The bowel is clamped just proximal to this point. A no. 10 blade on a long handle is used to transect the bowel. The specimen is handed off the field.

## RECONSTRUCTION: DOUBLE-STAPLING TECHNIQUE

The proximal colon is unpacked, and the length required for a tension-free anastomosis is determined. If more colon is needed, the splenic flexure is mobilized further. This may require an extension of the incision cephalad. Proximal ligation of the inferior mesenteric vein also adds extra mobility (see Fig. 40-16D). The proximal bowel is cleaned by resecting residual fat and small vessels approximately 1 cm proximal to the staple line. The staple line is excised with Bovie electrocautery. Sizers may be inserted to select an end-to-end anastomosis (EEA) stapler diameter (25, 29, or 31 mm). A circular stapler is then chosen. The anvil is placed within the opened bowel. A 3-0 Prolene is used to take full-thickness, 1- to 2-mm bites to fashion a purse-string stitch around the anvil. The purse-string suture is tied gently but firmly around the shaft so that the shaft is completely encircled by bowel (Fig. 40-19C). If there are any gaps, an additional 3-0 Prolene suture can be used to take another full-thickness bite, and this suture may be tied around the shaft as well. The serosa of the bowel is cleaned further of fat and small vessels within 1 cm of the shaft of the anvil to optimize bowel-to-bowel contact when the circular stapler is applied. One can also perform a similar placement of the anvil on the antimesenteric side of the colon for a side-to-end anastomosis. The optimal placement of the anvil in this case is such that only a small blind end of colon remains distal to the anastomosis (1–5 cm).



**FIGURE 40-17** Mobilization of the rectum. **A.** Peritoneal incision of the pelvis. **B.** Rectum reflected anteriorly and posterior avascular plane entered between the presacral fascia of Waldeyer and the fascia propria of the rectum. **C.** Division of lateral stalks. **D.** Projected line of dissection in pelvis through Waldeyer's and Denonvilliers' fascia.

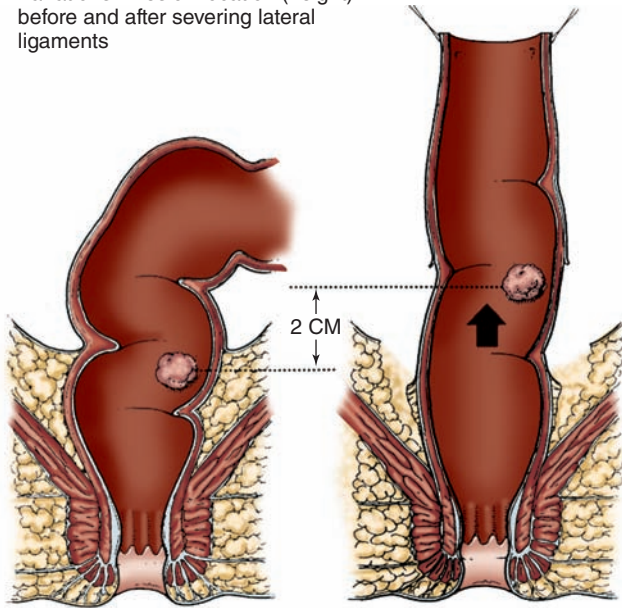
Attention then is turned to the pelvis, which is irrigated and inspected for hemostasis. This is one's truly last opportunity to inspect this area because one's exposure will be compromised once the anastomosis is completed.

One member of the team then stands between the patient's legs. The circular stapler tip is coated with lubricant on the outside of the stapler; we do not place lubricant on the staples

themselves. The tip is retracted fully. A rectal examination is performed, and the anus is dilated gently with two to three fingers in order to accommodate the stapler. The circular stapler is inserted gently following the curve of the rectum—initially straight in and then the stapler is tilted posteriorly. Using close communication with the surgeon overlooking the abdomen, the assistant positions the circular stapler tip so

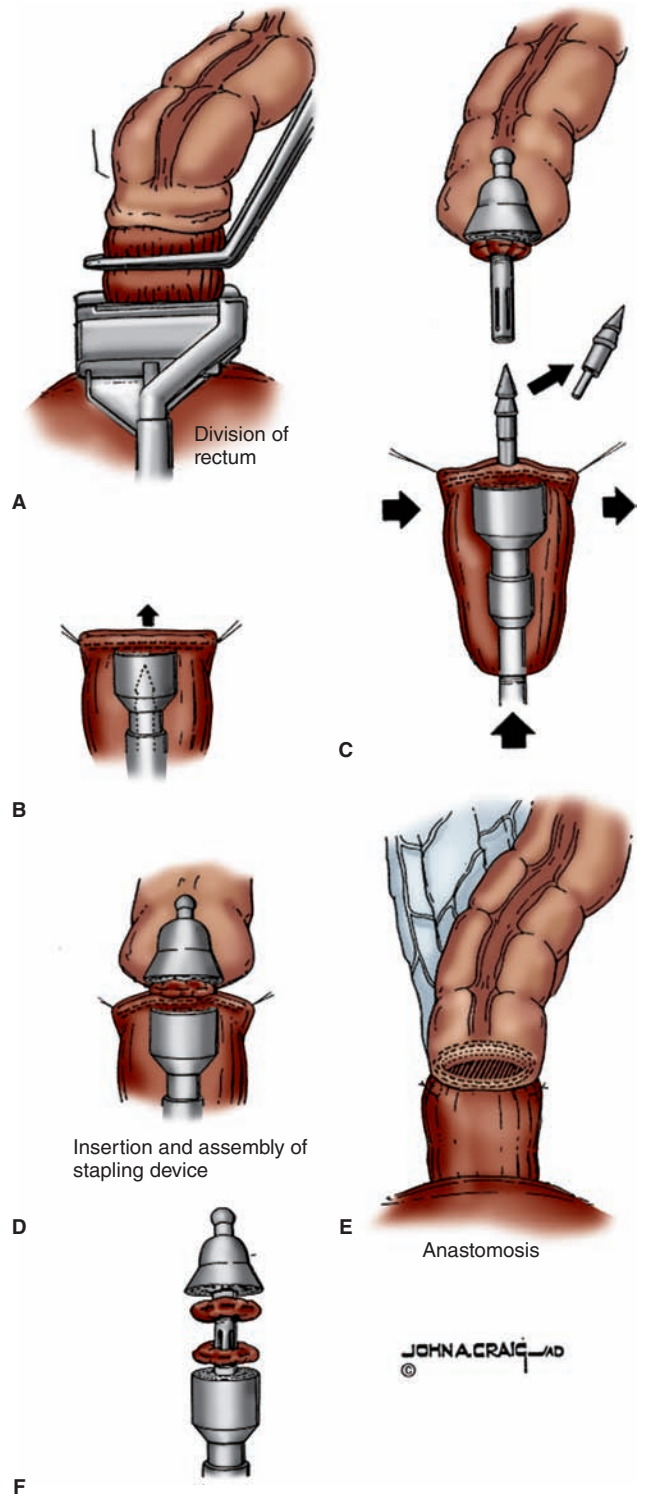


Variations in lesion location (height) before and after severing lateral ligaments



**FIGURE 40-18** Tumor position relative to the dentate line after mobilization of the rectum. This may permit a sphincter-preserving resection.

that the trocar will exit either 2–3 mm anterior or posterior (we elect to do this posteriorly in women in order to avoid the vaginal wall) to the staple line (Fig. 40-19B). The trocar is advanced slowly; the bowel continues to be adjusted as necessary. When the trocar protrudes through the bowel wall, be sure that the trocar is fully advanced so that its bottom is visualized (see Fig. 40-19C). The trocar is removed. Ensuring that the proximal bowel is not twisted and that the remaining bowel, mesentery, and epiploicae are held away, the anvil is brought down gently to the stapler and connected. The colon is inspected again to verify that no adjacent tissue is entrapped. The stapler is closed slowly until both pieces of colon are fully approximated (Fig. 40-19D). The stapler is fired, opened slightly, and gently removed as directed according to the type of stapler. This is the second staple line in the double-staple technique (Fig. 40-19E). The stapler is opened, and the tissues from the proximal and distal bowel are inspected to make sure that the two rings of tissue, or “donuts,” are intact (Fig. 40-19F). If they are not intact, additional sutures are placed if a visible gap is apparent. All anastomoses are checked for integrity. The surgeon fills the pelvis with saline and clamps the bowel proximal to the anastomosis gently with the hands; the assistant introduces a rigid sigmoidoscope through the rectum and insufflates air. If bubbles cannot be detected, one can be confident that the anastomosis is intact. If bubbles are detected, additional sutures are placed in suspected areas, and a diverting loop ileostomy is constructed. If the anastomosis is disrupted completely, it must be refashioned.



**FIGURE 40-19** Colorectal anastomosis: double-staple technique. **A.** Transection of the distal rectum with a linear stapler. **B.** Stapling instrument introduced through rectum. **C.** Descending colon purse-string suture is tied around shaft of anvil. After the trocar of the circular stapler penetrates behind the staple line, the trocar is removed before reconnecting the anvil to the shaft. **D.** The circular stapler is reconnected, reapproximated, and fired. **E.** The anastomosis is complete. **F.** The proximal and distal staple lines are examined for intact inner “donuts.”

## DIVERTING LOOP ILEOSTOMY

A diverting loop ileostomy should be considered in any low anastomoses (<5 cm) from the dentate line, which are associated with anastomotic leak rates of up to 17%. Other risk factors for anastomotic breakdown include a history of radiation, perioperative steroid use, malnutrition, elderly women with a thin rectovaginal septum, or elderly patients undergoing preoperative combined-modality therapy with planned postoperative chemotherapy. Additionally, if there is any question regarding the integrity of the anastomosis, an ileostomy should be created.

Ileostomies can be closed within 8 weeks but often are left in place until the patient completes adjuvant chemotherapy. A Gastrografin (diatrizoate meglumine) enema is used to check the patency and integrity of the anastomosis prior to takedown of the anastomosis.

## DRAIN PLACEMENT

Most surgeons continue to advocate routine use of drains after pelvic anastomoses. One prospective, randomized trial of 100 patients to receive either no drains or closed-suction drains demonstrated that the presence or absence of a drain did not influence the rate of morbidity and mortality. Although there is no evidence for the use of drains when an anastomosis has been made outside the pelvis, pelvic drainage may be important after anterior resection. We recommend placing a drain in extremely low resections, especially where the anastomosis was hand sewn or in patients who undergo an APR. For all other resections, placement of a drain may be determined on a case-by-case basis.

## CLOSURE

We prefer to close the abdominal fascia with a looped no. 0 PDS suture starting at the cephalad and caudad ends and to run the suture toward the middle. The deep dermal layer is closed with 3-0 Vicryl. The skin is closed with either staples or a 4-0 Vicryl subcuticular suture followed by benzoin and Steri-Strips. A 4 × 8 gauze dressing is applied and covered with Tegaderm (3M, St. Paul, MN).

## Postoperative Care

The nasogastric tube is removed at the end of the procedure or on postoperative day 1, and the patient can drink sips of clear liquids. The diet is advanced to low residue after flatus is passed. Cefazolin and metronidazole are continued for 24 hours postoperatively. Heparin is administered subcutaneously at a dose of 5000 units BID or TID depending on the patient's weight. Low-molecular-weight heparin also can be used in appropriate doses. Sequential compression devices are worn by the patient unless the patient is ambulating well. Most patients ambulate on postoperative day 1. The Foley catheter is kept in place for 3–5 days. If an epidural has been

used for postoperative pain control, it is usually left in place until the patient is started on oral pain medication when he or she is tolerating clear liquids well.

## Coloanal Anastomosis

Anastomoses at or just above the anorectal ring often result in increased frequency of stool, incontinence or soilage, and impaired quality of life owing to an insufficient reservoir. Diet restrictions and time after surgery usually will improve these symptoms, but two alternative techniques of reconstruction address these postoperative problems and often allow for improved function to be attained more quickly.

## COLONIC POUCH

A 6-cm limb of sigmoid or descending colon is folded, and the apex is brought down to reach the rectal stump without tension. The splenic flexure may require additional mobilization. A colotomy is made at the apex with Bovie electrocautery, and a no. 75 GIA linear cutter is used to staple the pouch on itself to create a common lumen. A second fire of the stapler may be necessary. This pouch now serves as the neorectum. A double-stapled anastomosis as described or a hand-sewn anastomosis then is performed. A diverting loop ileostomy is used routinely for these ultralow anastomoses.

Multiple prospective, randomized studies have demonstrated superior function of a coloanal J-pouch over a straight coloanal anastomosis, especially in the first 6 months after ileostomy takedown.

## TRANSVERSE COLOPLASTY

When the pelvis is too narrow for a J-pouch or the length of the pouch is inadequate, a transverse coloplasty may be fashioned. This is performed by placing the anvil of a 29- or 33-mm circular stapler into the cut end of the sigmoid as described under the section Low Anterior Resection. The colon should be mobilized to the level of the middle colic vessels. Beginning 2 cm proximal to the anvil, a 7- to 8-cm longitudinal colotomy is made. This colotomy then is closed transversely. The anastomosis is completed as described under Low Anterior Resection. A diverting loop ileostomy is created.

## ABDOMINOPERINEAL RESECTION

Traditionally, distal rectal cancers have been treated with an abdominoperineal resection (APR), as first described by Miles, who noted high failure rates after local excision.<sup>2</sup> This procedure involves the en bloc resection of the tumor as well as the surrounding lymph nodes and the anal sphincters, resulting in a permanent colostomy.

The APR, although quite successful for early rectal cancers (stage I) in terms of survival, is associated with significant morbidity of 61% and mortality ranging from 0 to 6.3%.<sup>49</sup>

Urinary complications can be as high as 50% and perineal wound infections 16%. In addition to these perioperative problems, significant long-term morbidity is associated with a permanent colostomy. In a patient survey, 66% of patients complained of significant leaks from their stoma appliance, 67% experienced sexual dysfunction, and only 40% of patients working preoperatively ultimately returned to work.<sup>50</sup> There is also a significant change in body image when compared with sphincter-saving procedures. The 5-year survival rates following an APR range from 78 to 100% for stage I, 45 to 73% for stage II, and 22 to 66% for stage III disease.<sup>51</sup> Despite radical resection, 20% recur locally. Variations in recurrence rates depend on location of the tumor within the rectum, changes in surgical technique, and the addition of adjuvant therapy.

For patients with cancers that involve the sphincter apparatus or for those who are incontinent of feces, an APR is performed to remove the rectal specimen.

## Technique

The patient is marked preoperatively by the enterostomal nurse for a permanent colostomy. Please see the section Low Anterior Resection With Total Mesorectal Excision for details regarding additional preoperative care, positioning, incision, and rectal mobilization. The dissection proceeds down to the striated muscles of the levator ani; one can confirm muscle contraction by using electrocautery. Once this level is reached, the perineal excision field can begin either by the surgeon or by a second team. The two-team approach saves time.

## Perineal Dissection

The anus is closed with a no. 0 silk suture in a purse-string fashion (Fig. 40-20B). A marking pen is used to draw an ellipse 2 cm outside the superficial external sphincter and extending from the perineal body anteriorly, coccyx posteriorly, and ischial tuberosities laterally. The incision is made with a no. 10 blade and carried down through the dermis into ischioanal fat (Fig. 40-20C). Two Gelpi retractors are placed at 45 degrees to the anus in order to facilitate deep dissection. The dissection is carried deep outside the external sphincter toward the tip of the coccyx, keeping in mind the planes of dissection (Figs. 40-20A and 40-20E). The anococcygeal ligament is palpated just anterior to the tip of the coccyx, and the palpating finger meets the fingers of a team member working from the abdominal field (Fig. 40-20D). A pair of large scissors is used to poke through the ligament; the scissors are fully spread and, while wide open, are pulled straight back. Hooking the index and middle fingers under the levator muscles and transecting with electrocautery frees the rectum laterally (Figs. 40-20F and 40-20G).

The anterior surface is dissected last (Figs. 40-20H and 40-20I). The rectum is delivered through the perineal opening. An assistant retracts the skin and subcutaneous tissue

anteriorly with an army-navy retractor. Care is taken to keep the posterior wall of the vagina or the prostate anterior to the plane of dissection. The surgeon cups the hand around the rectum with traction posteriorly and inferiorly and uses cautery between the rectum and the anterior structures, often reassessing the plane of transection. Once freed circumferentially, the specimen is passed off the field.

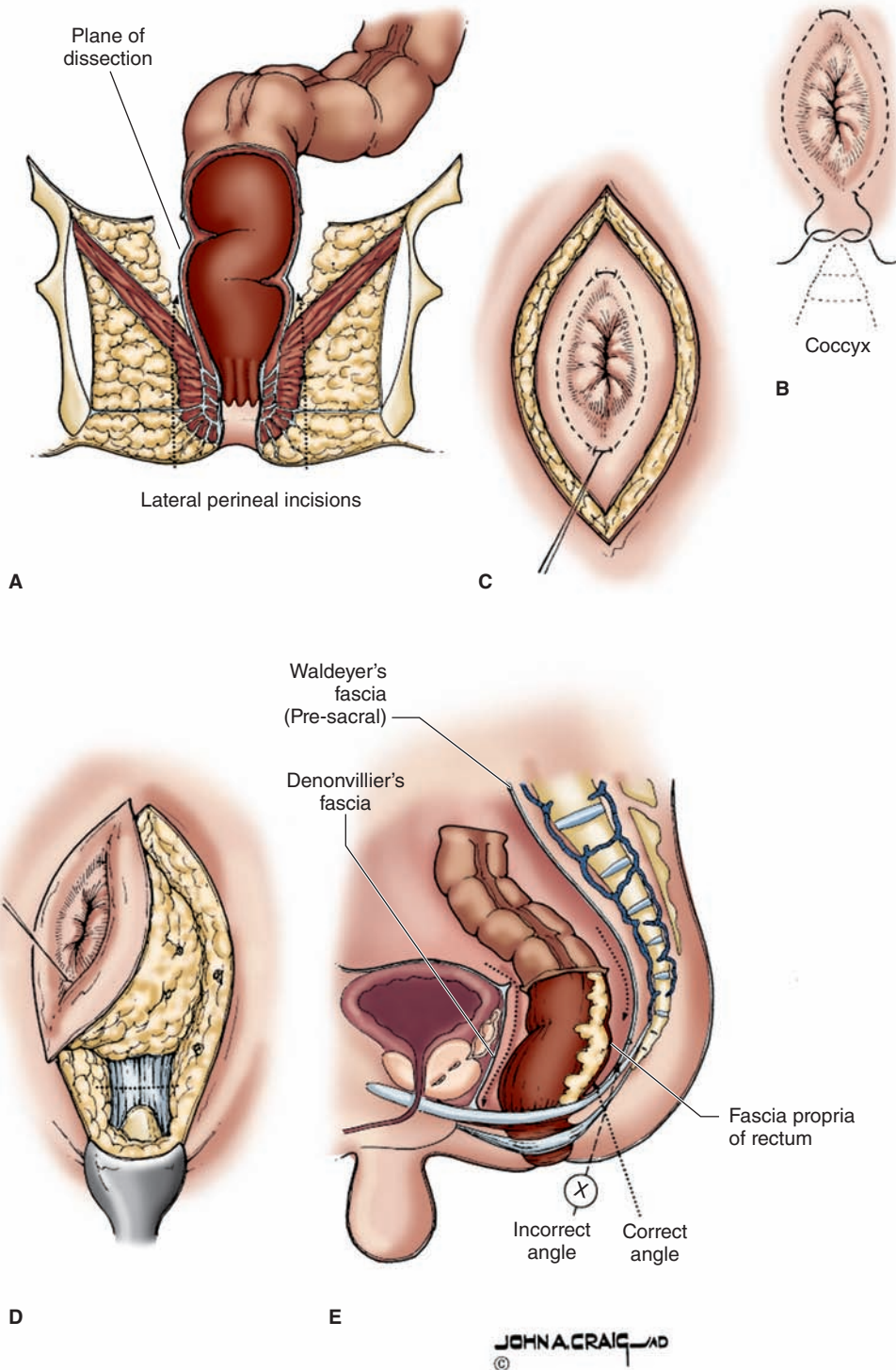
The pelvic floor is irrigated and checked carefully for hemostasis. A tongue of omentum or omental pedicle flap may be used to cover the pelvis to prevent the small bowel from dropping deep into the pelvis if radiation is contemplated. Omentum also helps healing, especially in an irradiated perineum or when patients also have undergone prostate or vaginal resections. The descending colon is further mobilized in order to exit the skin without tension. The colostomy site is prepared similar to the diverting loop ileostomy as described under Low Anterior Resection. The colon is drawn through the colostomy site using a Babcock clamp, but it is not matured until the midline incision is closed.

Two no. 10 Jackson-Pratt drains are placed in the pelvis and are brought anteriorly out through the abdominal wall and secured to the skin using 3-0 nylon suture (Fig. 40-20J). The abdomen is closed as described under Low Anterior Resection. The colostomy is matured using interrupted 3-0 Vicryl suture.

If using a two-team approach, the perineal wound can be closed after the pelvis has been irrigated and hemostasis achieved. Two layers of interrupted 2-0 Vicryl suture are used to approximate the subcutaneous tissue. One layer of 3-0 Vicryl in a vertical mattress fashion is used to approximate the skin. Because this area is often radiated, multiple layers decrease the risk of the wound breakdown extending into the pelvis.

Initially the APR was performed utilizing an anterior approach and then flipping the patient for the perineal component. In this way, APR was done by completing the abdominal mobilization of the rectum to the levators circumferentially and then creating a colostomy and closing the abdomen and flipping the patient to complete the perineal portion of the operation. In most institutions two teams work simultaneously (as described previously) and two instrument tables are used with separate counts and often requiring additional OR support staff to assist. All of this increases utilization in order to save operative time. More recently, attention has reverted to the traditional anterior and posterior approach to the APR. In fact, there are recent data that support a better oncologic outcome using an anterior and posterior approach as described previously. This is known as the *cylindrical technique*. West et al reported more tissue excised in all pathologic resections and better margins from the muscularis to all resection margins. These results translated into a lower rate of positive circumferential resection margin with APE 14.8 versus 40.6% for traditional APR and a decrease in intraoperative perforations 22.8 to 3.7%, respectively.<sup>52</sup> In our experience we have also found better short-term outcomes with lower perineal wound infections and improved perineal healing.





**FIGURE 40-20** Perineal dissection: two team synchronous approach. **A.** Projected lines of pelvic floor resection in the vertical plane. **B.** Anal closure. **C.** Perineal incision. **D.** Incision line anterior to coccyx through anococcygeal ligament through which scissors are used to gain entrance to the pelvis. **E.** Planes of pelvic dissection and posterior plane of entry into pelvis through the pelvic floor. **F.** Projected lines of pelvic floor transection. **G.** Lateral transection of levator ani muscle. **H.** Anterior transection of rectourethralis, puborectalis, and pubococcygeus. **I.** Completion of anterior dissection and removal of rectum through perineal wound. **J.** Pelvic floor closed with two drains in place.

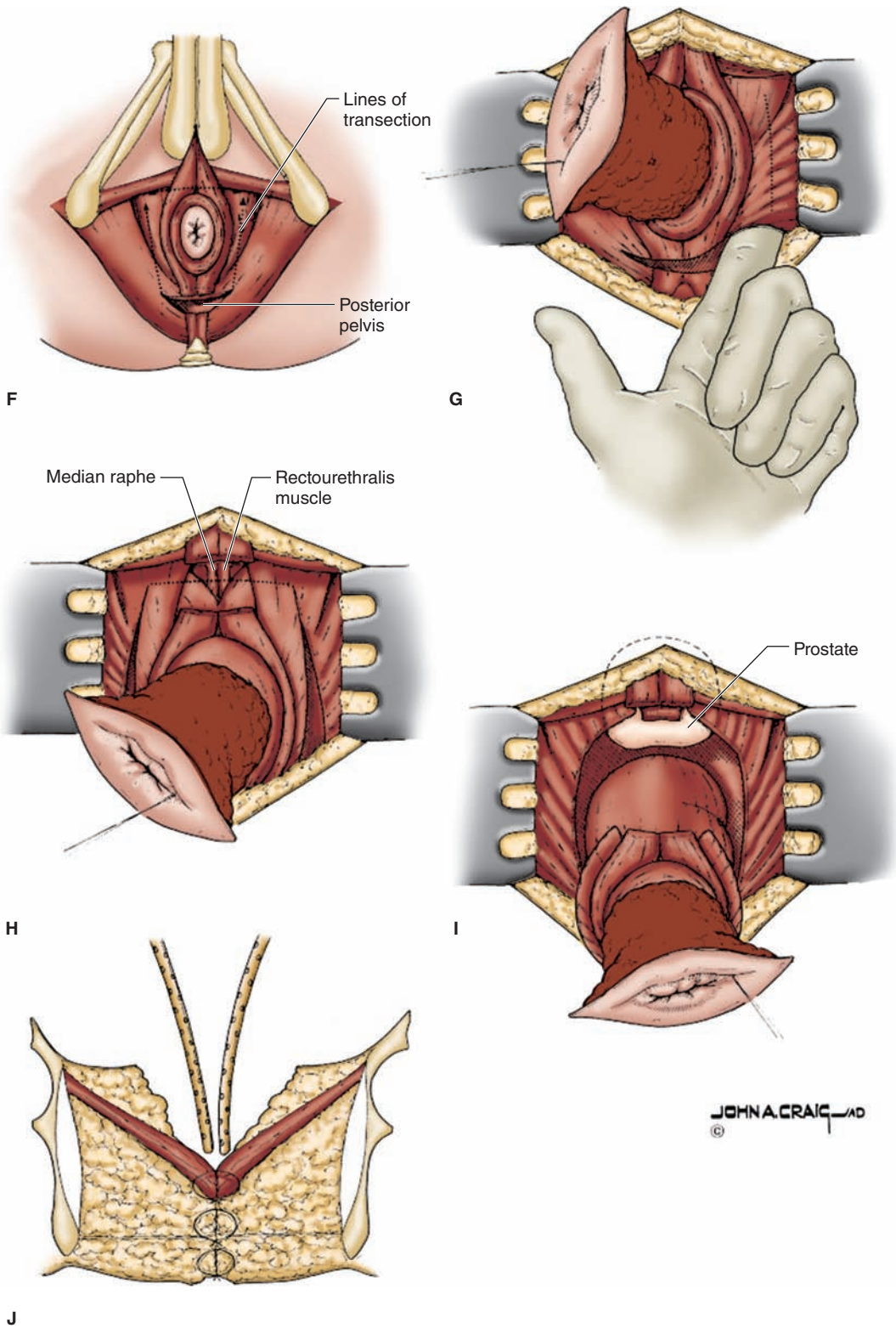


FIGURE 40-20 (Continued)

## Postoperative Care

Postoperative care is similar to that described under Low Anterior Resection. The patient is not allowed to sit for 5 days but may only recline and ambulate. Thereafter, the patient may sit on a soft pillow; we do not advocate using a “donut” because perineum is not supported. The perineum is cleaned daily with dilute hydrogen peroxide. The Foley catheter remains in place for 3–5 days.

## Complications

Perineal wound complications are common following APR and occur in up to 25% of patients. While most of these wound complications are minor, some may require operative débridement. We demonstrated previously that preoperative radiation and primary closure were not associated with an increased incidence of wound complications compared with nonirradiated patients following APR for rectal cancer.<sup>53</sup>

Stoma complications include ischemia, retraction, hernia, stenosis, and prolapse. The construction of a good colostomy will provide a patient with a superb quality of life after APR. Early education in the immediate postoperative period allows the patient to adjust to life with a stoma. The stoma shrinks to its final size approximately 3 weeks postoperatively when the edema has subsided. An end colostomy may be irrigated to establish regularity of bowel movements and further improve the patient’s quality of life. The operative mortality for APRs is less than 2%.

## EN BLOC EXCISION WITH RECTUM

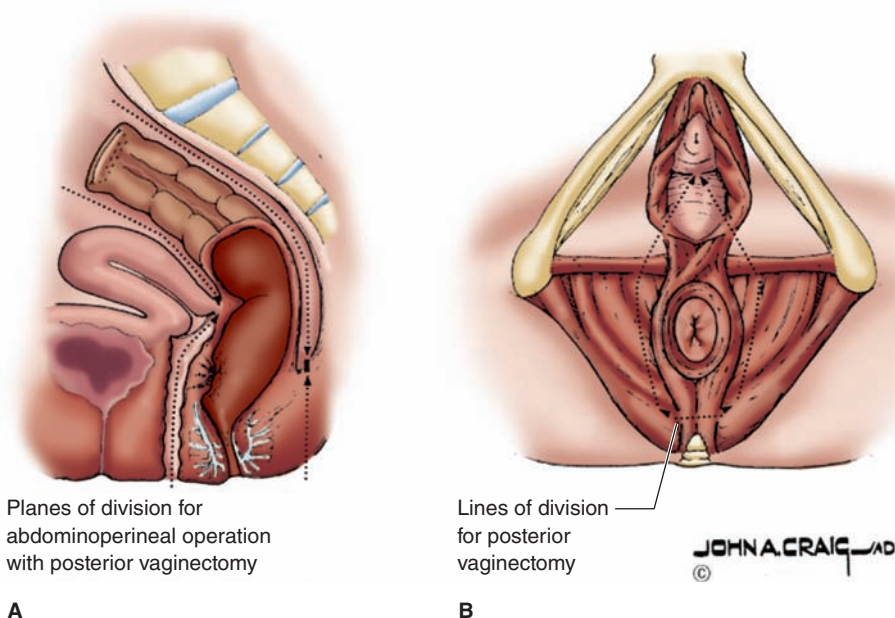
### Posterior Vaginectomy

Partial vaginectomy is indicated for locally advanced low rectal cancers involving the vagina. One study demonstrated a 5-year survival of 46% and a median survival of 44 months, with most favorable results from negative surgical margins and node-negative disease.<sup>54</sup>

If the patient undergoes an APR, the posterior wall of the vagina is removed as the anterior margin of the resection (Fig. 40-21). After completing the posterior and lateral dissections, the rectum is delivered through the perineum. The anterior aspect of the perineal incision includes the posterior introitus and is extended around the posterior third to half of the vagina only to avoid denervation of the urethra. To achieve hemostasis during the procedure, one can place interrupted 2-0 absorbable full-thickness sutures through the vagina from either side, starting at the apex of the incision, and tie the sutures as the specimen is being excised.

If the patient undergoes an LAR with a coloanal anastomosis, the partial vaginectomy may be performed through the abdominal approach. The involved area of the vagina is resected with a 1-cm margin and kept en bloc with the rectum. Subsequent closure of the vagina is completed by initially placing Allis clamps on the vaginal edges and then taking full-thickness bites with 2-0 Vicryl sutures in a figure-of-eight fashion.

Before abdominal closure, we recommend placing an omental flap around the vaginal cuff to prevent breakdown of the vaginal suture line. If a coloanal anastomosis is in place, we would position the omentum between the vaginal and the coloanal suture lines.



**FIGURE 40-21** Posterior vaginectomy with APR. **A.** Line of dissection, including posterior wall of vagina for low anterior rectal cancer. **B.** Lines of transection, including posterior wall of vagina.



## Prostatectomy

In locally advanced rectal cancer in which there appears to be possible involvement of the prostate, urethra, bladder, or ureterovesicular junction on CT scan of the abdomen and pelvis, an MRI of the pelvis should be obtained. Urology consult should be made because one must be prepared for radical prostatectomy and/or cystectomy with ileal conduit diversion. A prostatectomy en bloc with rectal resection is an alternative to total pelvic exenteration in patients whose rectal cancer is fixed only to the prostate. The reasons for involving urology are in part due to the vascularity of the prostate. In addition, one should be concerned about constructing any genitourinary anastomosis (eg, between bladder and urethra) in the presence of previous radiation and a rectal anastomosis. Attention should be paid to potential for autonomic nerve deficit if proximity and effacement of the neurovascular bundle are evident on MRI.

## Pelvic Exenteration

Total pelvic exenteration is an alternative for patients with locally advanced rectal cancer in which the tumor is contiguous with adjacent organs, such as the prostate or bladder (Fig. 40-22). Long-term survival rates range from 20 to

70% and are improved in younger patients with no lymph node metastases.<sup>55</sup> Local recurrence rates range from 3 to 8%. An argument against performing total pelvic exenteration is the considerable morbidity (20–40%) and 0–20% mortality associated with this procedure. The most common complications are infection, small bowel obstruction, and problems with urinary diversion.

## Prophylactic Bilateral Oophorectomy

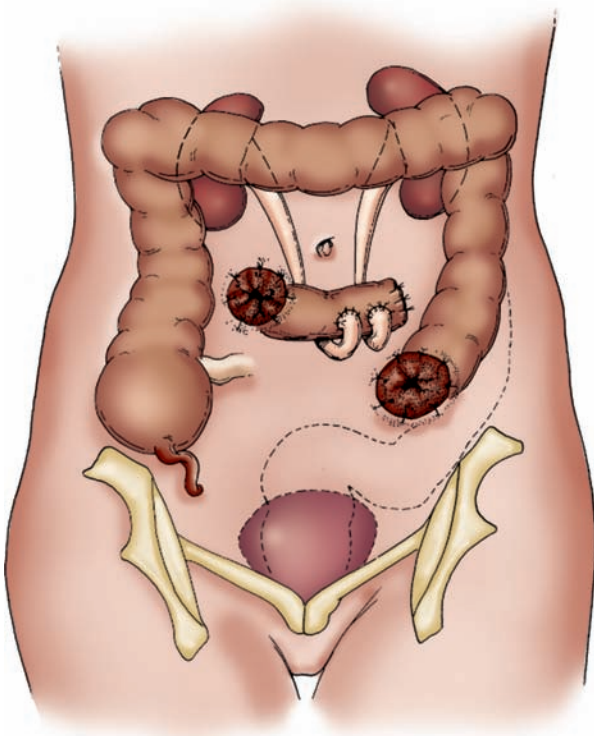
Carcinoma of the rectum metastasizes readily to the ovaries, and prophylactic oophorectomy during rectal resection may diminish the morbidity of carcinoma of the rectum in women. Additionally, the incidence of ovarian cancer in women with a history of colorectal cancer is roughly five times the incidence in women without such a history. Although prophylactic bilateral oophorectomy does not significantly affect survival, the prevention of primary ovarian cancer in postmenopausal women is considered to be the main benefit of this procedure. We discuss this with our postmenopausal patients and offer this to them at the time of operation.

## PALLIATIVE RESECTION IN STAGE IV DISEASE

Palliative resection of the primary colorectal tumor in stage IV rectal cancer depends on the degree of symptoms present. In patients who are symptomatic from bleeding, localized perforation and obstruction, there are several management options that can relieve the symptoms of the primary tumor:

1. Permanent diversion followed by chemotherapy ( $\pm$  radiotherapy depending on local symptoms)
2. Palliative resection with a permanent colostomy followed by chemotherapy (radiotherapy is not needed if the primary is successfully resected in the stage IV patient)
3. Palliative resection with restoration of GI continuity followed by chemotherapy (once again, radiotherapy is not needed if the primary is successfully resected in the stage IV patient)

In the symptomatic patient it is our practice to offer upfront surgical resection/diversion and additional therapy using one of the above three options. The surgical procedure depends on the performance status and the intraoperative findings at the time of exploration. In patients with distant spread to solid organs alone, it is our inclination to perform resection of the primary with restoration of GI continuity. In patients with significant peritoneal and pelvic carcinomatosis, we will offer either resection with end colostomy or just a diversion depending on the degree of pelvic peritoneal carcinomatosis. In the patient with a large burden of disease, it is better to just divert the patient and start chemotherapy and the offer palliative radiotherapy if the bulky primary continues to bleed or causes pain from infiltration of the sacral nerve roots.



**FIGURE 40-22** Pelvic exenteration. (Redrawn, with permission, from Craig JA, Kodner IJ, Fry RD, et al. Colon, rectum and anus. In: Schwartz DI, ed. *Principles of Surgery*. 6th ed. New York, NY: McGraw-Hill; 1993:1296.)

On the other hand, resection in the asymptomatic patient with incurable stage IV disease is controversial. Resections for rectal cancer often have significant morbidity and measurable mortality but at the same time offer the best palliation of local symptoms. Moreover, in the last decade chemotherapy regimens have significantly extended the life expectancy of patients with colorectal cancer. The advent and widespread use of the FOLFOX (5-fluorouracil [5-FU], leucovorin, and oxaliplatin) and FOLFIRI (folinic acid, fluorouracil, and irinotecan) chemotherapy regimens have extended the median life expectancy of patients with stage IV disease from approximately 8 months to nearly 2 years (see Chap. 36). Many patients live much longer than this. Hence, it is our opinion that upfront palliative resection is warranted in the medically fit patient with a low burden of distant but traditionally incurable disease. In those who have significant distant disease, we prefer systemic therapy with restaging after several courses of chemotherapy.

In the medically fit patient with a good performance status that has substantial improvement in the metastatic burden, we will once again offer palliative resection. The choice of operation (see above choices) depends on the intraoperative findings. This approach has never been studied prospectively and the sparse literature is based solely on retrospective reviews. Despite this, patients who have had asymptomatic primary tumors resected have a substantial survival advantage over those who were never resected. Ruo et al showed that those who were resected versus the nonresected had a prolonged median survival of 16 versus 9 months and a 2-year survival of 25 versus 6% with both measures reaching statistical significance.<sup>56</sup>

## LAPAROSCOPIC SURGERY

Minimally invasive laparoscopically assisted surgery was first considered in 1990 for patients undergoing colectomy for cancer. The technical feasibility of performing laparoscopic TME was demonstrated in several prospective studies. Preservation of the autonomic nerves is also possible during laparoscopic TME. Early results confirmed complete resection of the mesorectum with intact visceral fascia in all patients.<sup>57</sup> Because Nelson and other showed equivalent outcome, quality of life, and survival in laparoscopic surgery for colon cancer, there has been renewed interest in laparoscopic LAR for rectal cancer.<sup>58</sup> Currently a randomized prospective trial is ongoing in the United States. The Conventional versus Laparoscopic-Assisted Surgery In Colorectal Cancer (CLASSIC) trial group from the United Kingdom published the results of their randomized comparison of laparoscopic versus open LAR for rectal cancer in 794 patients (526 lap vs 268 open) with a median follow-up of 36.8 months and equivalent numbers of patients receiving chemoradiotherapy. The overall survival (open 66.7 vs lap 74.6%) and disease-free survival (open 70.4 vs lap 70.9%) were similar in both groups and were without statistical significance. The overall local recurrence rates were 7% in open resection and 7.8% in the laparoscopic group. Even though the laparoscopic group had a higher positive circumferential resection margin (CRM),

there was no difference in local recurrence at 3-year follow-up. This increased positive CRM is certainly concerning with only 3-year follow-up and longer-term follow-up is certainly needed to ensure that this is not significant.<sup>59,60</sup> In addition to increased positive CRM, the above CLASSIC trial reported overall worse sexual function in men (not women) undergoing laparoscopic rectal cancer resection.<sup>61</sup> Both a positive CRM and worse sexual function are major potential complications, and, as a result, laparoscopic surgery for rectal cancer should still be limited to ongoing trials (especially in male patients) until long-term data show at least equivalent recurrence and complication rates. This is especially true because the same CLASSIC trial measured quality-of-life outcome for these patients and there was no difference between laparoscopic resection and open surgery.

## OTHER TREATMENT OPTIONS

Besides surgical resection for rectal cancer, there are other options for patients who may not be candidates for surgery owing to their comorbidities, extent of disease, or preference. Endocavitary radiation may be delivered at doses of 50 cGy for palliation and for curative intent. Performed as an outpatient and well tolerated by patients, endocavitary radiation is delivered with sedation and local perineal block.

Electrocoagulation may be used via a transanal approach after administering general anesthesia and placing the patient in the lithotomy position. The rectal lesion and a 1-cm margin are fulgurated. Recurrence rates approach 50–80%; therefore patients may require repeat treatments.

Cryotherapy, another alternative modality, results in a large amount of foul-smelling discharge. Photodynamic therapy has limited availability. Laser vaporization using neodymium:yttrium-aluminum-garnet laser provides palliation but is associated with a 14% recurrence rate and is costly.

## COMPLICATIONS

Complications of surgical management of rectal cancer may include those common to any major intra-abdominal operation, such as infection, bleeding, wound problems, deep venous thrombosis/pulmonary embolism, myocardial infarction, pneumonia, and renal failure. There are, however, several complications that are related to rectal cancer. There is a 50% incidence of impotence in men following resection for rectal cancer. Therefore, it is critical to discuss this situation with the patient before the resection and to record the preoperative status of his sexual function. If a man is impotent after surgery, it is advisable to wait 1 year before undergoing implantation of a penile prosthetic device. This delay is recommended not only to ensure that the malignancy has been cleared but also to allow the patient sufficient time to overcome psychological impediments such as a change in body image from pelvic surgery or from a colostomy. Women may also suffer from impaired sexual function, especially if the vagina is distorted during the rectal resection.

A possible permanent colostomy is often not preferred by patients. Its placement, however, must be explained in a way that the patient understands that he or she may be left with this if reconstruction is not technically possible.

Anastomotic leak, which occurs in up to 20% of patients, can be avoided by constructing the anastomosis with well-vascularized tissue without tension. Interestingly, young, muscular men have a higher incidence of anastomotic leaks, which may result from the technical challenge of operating in a narrow pelvis or from strong sphincters that may stress the anastomosis. The latter may be addressed by dilating the anal sphincter in the operating room at the end of the procedure. Anastomotic leaks usually present between 4 and 7 days postoperatively. Symptoms may include fever, tachycardia, arrhythmias, tachypnea, enterocutaneous fistula, or diffuse peritonitis. When a leak is suspected, the patient should be made NPO and blood should be sent for a complete blood count, electrolytes, and type and cross-match. An upright chest x-ray will diagnose pneumoperitoneum. Abdominal series may demonstrate extraluminal air. CT scan of the abdomen and pelvis with water-soluble contrast material may demonstrate abscess formation, extraluminal air, and the actual leak. Barium should be avoided because leakage of barium creates a destructive peritonitis. A leak may be managed with intravenous antibiotics and bowel rest in a patient without peritonitis. An abscess may be drained percutaneously. An enterocutaneous fistula may be treated with total parenteral nutrition and local wound care. If a large leak is demonstrated or the patient experiences peritonitis, exploratory laparotomy with diverting ileostomy or colostomy should be performed. The anastomosis is rarely taken down and should not be reconstructed in the presence of sepsis.

Massive venous bleeding from the presacral space may result intraoperatively from lateral dissection onto the pelvic sidewall or sacrum. Ligation of the iliac vessels is discouraged and may be hazardous. If massive bleeding is encountered, a surgical metal “tack” may be driven into the sacrum to compress the venous space. Additionally, the pelvis may be packed for 24–48 hours, at which time the patient is returned to the operating room for pack removal and closure.

Urinary dysfunction may occur after rectal resection. Many men have coexisting prostatic hypertrophy. Because low rectal dissection approaches the membranous urethra, Foley catheters usually are kept in place for 5 days. Patients may be discharged with indwelling catheters, especially if they have undergone partial prostatectomies or seminal vesiculectomies. Women may experience urinary incontinence if the anterior aspect of the vagina, which contains the neurologic control of the urethra, is transected.

## OBSTRUCTING, METASTATIC, AND RECURRENT RECTAL CANCER

### Obstructing Cancer of the Rectum

For obstructing cancers of the rectum, a loop ileostomy, performed as an open or a laparoscopic procedure, is constructed

for diversion. Usually, the tumor is staged as a T3 or N1 lesion; the patient is treated with neoadjuvant chemoradiation and considered for subsequent surgical resection.

### Metastatic Rectal Cancer

The management of hepatic and pulmonary metastases is not described in this chapter (see Chap. 36). Nonetheless, if a patient presents with incurable metastatic disease and life expectancy is greater than 6 months, it is reasonable to consider a palliative rectal resection. If the rectal lesion is staged as T3 or N1, we recommend neoadjuvant chemoradiation because this addresses both the primary lesion and the metastasis and may provide some palliation of obstruction, bleeding, or pain. Other options include rectal stents or laser destruction of the tumor to maintain an adequate lumen. It is important to understand the patient, his or her desires, and general state of health when recommending treatment at this stage of cancer.

### Recurrent Rectal Cancer

Local recurrence of rectal adenocarcinoma is seen in up to 30% of patients. Although recurrence may be seen at the distal margin of the anastomosis, most develop from residual cancer on the pelvic wall. The time course for recurrences to present through the anastomosis is approximately 18 months. By their nature, these tumors are fixed to the pelvic wall and surrounding viscera. They cause significant symptoms, such as intractable pelvic pain, bleeding, cramping or constipation, urinary tract dysfunction, and chronic pelvic sepsis.

When patients present with these symptoms or with a rising CEA level, a workup including CT scan of the abdomen and pelvis, ERUS, MRI of the pelvis, and PET scan may be helpful. A careful pelvic examination is mandatory. A biopsy, either via sigmoidoscopy or CT-guided, should be used to confirm the diagnosis pathologically. If external radiation has not been used before, it should be considered. The surgeon should review the imaging studies and determine which organs are involved, such as the vagina, uterus, prostate, bladder, sacrum, and small intestine, which will require en bloc resection. Urology consult should be obtained if there is any question of prostate or bladder involvement; ureteral stents should be placed preoperatively. Removal of the rectum and urinary bladder with surrounding lymphatic tissue results in a permanent colostomy and ileal conduit.

### INTRAOPERATIVE RADIATION THERAPY

Intraoperative radiation therapy (IORT) may be considered in patients with pelvic sidewall recurrence. This is performed in an operating room–radiation therapy suite. Resection with negative microscopic margins and absence of vascular invasion independently predicts improved local control and survival after resection and IORT.<sup>62</sup> The major morbidities of IORT include peripheral neuropathy and ureteral stenosis.



## PALLIATION

These tumors are difficult to palliate, let alone cure. Surgical resection combined with aggressive multimodality therapy is advocated to avert the morbidity of pelvic disease and to prolong survival in a subset of patients, with survival rates up to 30%.<sup>63</sup> Most patients, however, will not be offered curative surgery on the basis of comorbidities, poor performance status, distant metastases, or locally unresectable disease on preoperative imaging. These patients may be offered palliative intervention. Miner and colleagues demonstrated that in patients who underwent surgery with palliative intent, improvement was noted in 40% with bleeding, 70% with obstruction, and 20% with pain.<sup>64</sup> When considering the effective use of surgery for these patients, decision making is complex because one must balance palliation of symptoms, comorbidities, and patient desires and goals. Seeking the input of a multidisciplinary treatment group, including medical oncologists and radiation oncologists, is invaluable.

## CHEMORADIATION

Patients with rectal cancer who undergo surgery with intention to cure and without evidence of gross disease postoperatively may still develop local recurrence or distant metastases. Up to 10% of patients who undergo TME with tumor-free radial and distal margins may develop local failure. The goal of adjuvant therapy is to eliminate the micrometastatic disease present at the time of surgery.

## Adjuvant Chemoradiation

In 1990, the National Institutes of Health consensus statement concluded that “combined postoperative chemotherapy and radiotherapy improves local control and survival in stages II and III patients and is recommended.” Most of the information regarding chemotherapy for colorectal cancer comes from trials of colon cancer rather than for rectal cancer. The NSABP C-04 (National Surgical Adjuvant Breast and Bowel Project C-04) trial studied stages II and III colon cancer patients and demonstrated that 5-fluorouracil (5-FU) and leucovorin treatment had a significantly better 5-year survival rate (74 vs 69%) compared with 5-FU and levamisole.<sup>65</sup>

Several trials have suggested a benefit for adjuvant chemoradiation for rectal cancer in patients with resected stage II or III cancers. The GITSG (Gastrointestinal Tumor Study Group) trial demonstrated that combined chemoradiation resulted in an improvement in overall survival as well as a decrease in local recurrence.<sup>66</sup> The NCCTG (North Central Cancer Treatment Group) trial demonstrated that the addition of chemotherapy to radiation reduced both local recurrence (13 vs 25%) and distant metastases (28 vs 46%) and improved survival.<sup>67</sup>

Radiation therapy used alone as adjuvant therapy may improve local recurrence and survival rates. A theoretical reason to use postoperative radiation therapy is that more

appropriate patient selection can be achieved because pathologic staging is performed prior to radiation. Disadvantages include radiating the neorectum and small bowel and a lower tendency of patients to complete their radiation. While none of the trials in the 1980s and 1990s demonstrated increased survival, one study did show a decrease in local recurrence.

## Neoadjuvant Chemoradiation

There are a number of potential advantages for using neoadjuvant chemoradiation. They include the ability to deliver higher doses of chemotherapy with radiation. Another advantage is not only to downstage the tumor, which has been noted in 60–80% of patients, but also to achieve a pathologic complete response, which occurs in 15–30% of patients. The ability to “shrink” the tumor facilitates surgical resection, thereby allowing one to achieve negative margins and perform a sphincter-preserving operation in patients who otherwise would require an APR. Additional advantages include radiating tissues with a greater oxygen supply, not radiating the anastomosis, and decreased likelihood of developing radiation enteritis because small bowel is less likely to enter the pelvis. Finally, patients are more likely to complete the course of radiation therapy because it precedes their surgical resection.

The Dutch Colorectal Cancer Group demonstrated a significantly decreased rate of local recurrence at 2 years in patients who received preoperative radiotherapy (20 Gy over 5 days) followed by TME compared with TME alone (2.4 vs 8%).<sup>39</sup> The Swedish trial was the first and only study to demonstrate a survival benefit (58%) for stage III rectal cancer patients receiving preoperative radiation (short course of 5 Gy over 5 days) followed by surgery compared with patients who underwent surgery alone (48%).<sup>68</sup> The Swedish trial also demonstrated a decreased rate of local recurrence in the radiation-treated group (11%) compared with 27% in the surgery-alone group. Furthermore, a meta-analysis concluded that preoperative radiation therapy plus surgery compared with surgery alone significantly reduced the 5-year overall mortality rate, cancer-related mortality rate, and local recurrence rate.<sup>69</sup>

In the German Rectal Cancer Trial published in the *New England Journal of Medicine*, Sauer et al randomly assigned patients with clinical stage II or III rectal cancer to preoperative (421 patients) or postoperative (402 patients) chemoradiotherapy based on a concurrent long course of radiotherapy (5040 cGy delivered in fractions of 180 cGy per day, 5 days per week) and 5-FU (120-hour continuous intravenous infusion during the first and fifth weeks).<sup>70</sup> Six weeks later, TME was performed, followed by four cycles of 5-FU 1 month postoperatively. Despite the preponderance of distal tumors in the preoperative chemoradiation group, there was no difference in overall survival or disease-free survival at 4 years. On the other hand, patients receiving preoperative chemoradiotherapy had a 6% local recurrence rate as compared to a 13% local recurrence rate in those receiving postoperative chemoradiotherapy. Moreover, the group treated with

preoperative chemoradiotherapy had a higher incidence of sphincter preservation and lower treatment-related toxicities (27 vs 40%). Differences in local recurrence, sphincter preservation, and treatment toxicities were all statistically significant. A Polish rectal cancer trial from 2004 compared preoperative short-course radiotherapy (5 days of 5 Gy) versus conventional radiotherapy (28 fractions of 1.8 Gy for a total of 50.4 Gy) to ascertain whether there was a difference in sphincter preservation. The surgical resection was based on the tumor status at the time of surgery not before the radiotherapy. This allowed for the surgical decision to be made after tumor shrinkage for patients who received the longer course of radiotherapy. Between 1999 and 2002 the study enrolled 316 patients. Tumor shrinkage was on average 1.9 cm greater in the long-course group and this was statistically significant. However, sphincter preservation in the short-course group was 61% and in the long-course group 58%. In other words, whether the patient received short- or long-course radiotherapy, it did not impact sphincter preservation.<sup>71</sup> There was also no difference in survival, local control or late complications. Furthermore, this Polish trial reported no differences in anorectal or sexual function between the short- or long-course radiotherapy.<sup>72</sup> A French group in conjunction with the EORTC (European Organisation for Research and Treatment of Cancer) group studied “the addition of chemotherapy to preoperative radiotherapy and the use of postoperative chemotherapy in the treatment of rectal cancer.” Patients with clinical stage T3 or T4 rectal adenocarcinoma were randomized to four groups: preoperative radiotherapy, preoperative chemoradiotherapy, preoperative radiotherapy with postoperative chemotherapy, and preoperative chemoradiotherapy with postoperative chemotherapy. The primary end point of this study, which enrolled 1011 patients, was overall survival. The main secondary end point was local recurrence. The results showed that there was no difference in overall survival between the groups that received

chemotherapy preoperatively or those that received it postoperatively. There was, however, a difference in local recurrence. In the patients who received pre-op, post-op, or pre-op and post-op chemotherapy, the local recurrence rates were 8.7, 9.6, and 7.6%, respectively whereas the radiotherapy-alone group had a local recurrence rate of 17.1%. This was statistically significant and it suggests that there is a benefit to local control by adding preoperative chemotherapy to the regimen. It is not clear whether the addition of postoperative chemotherapy to a patient who has already received preoperative chemotherapy with the radiation treatment has any survival benefit.<sup>73</sup>

Our current practice is to recommend preoperative staging with ERUS or MRI to all patients with rectal adenocarcinoma and then to offer chemoradiation to medically fit patients with curative intent who have T3-T4 or N-positive rectal carcinoma. Some patients with bulky T2 lesions near the sphincters should also be considered for neoadjuvant chemoradiotherapy in order to improve sphincter preservation (Table 40-8). Neoadjuvant therapy then is followed by TME with APR or TME with an end-to-side or colonic J-pouch reconstruction. Postoperatively, patients who have had involved lymph nodes either by preoperative staging or on the final pathology report are encouraged to have additional postoperative chemotherapy. Postoperative chemotherapy in node-negative patients or patients who have had a complete response is determined on a case by case basis.

## SURVEILLANCE

After curative resection, long-term follow-up includes routine screening for rectal recurrence and metachronous colorectal neoplasms. Between 60 and 84% of recurrences are seen in the first 24 months and 90% within 48 months. Median time to recurrence is 11–22 months. Local recurrence rates



**TABLE 40-8: CURRENT RECOMMENDATIONS FOR CHEMORADIATION IN RECTAL CANCER PATIENTS AFTER RADICAL RESECTION**

Stage I	No adjuvant therapy
Stage II or III	Neoadjuvant chemoradiation
Low/midlesion	5-FU–based chemotherapy or other investigational agents with XRT (180 cGy 5 d/wk × 30 treatments) Rest for 4–8 wk Total mesorectal excision Rest for 4 wk Chemotherapy in appropriate patients for 4–6 mo
High lesion	Pre- or post-op chemoradiation therapy Total mesorectal excision
Stage IV	LAR or APR for palliation/prevention of obstruction or bleeding Adjuvant chemotherapy 5-FU + leucovorin ± irinotecan or oxaliplatin with individualized XRT

APR, abdominoperineal resection; 5-FU, 5-fluorouracil; LAR, low anterior resection; XRT, radiation therapy.

range between 4 and 50%. Survival rates vary according to stage (see Table 40-4). Median survival after recurrences are detected is 40 months.

Patients are seen postoperatively at 2 weeks and then every 3 months for 2 years. At each visit, the patient undergoes DRE and sigmoidoscopy, and a CEA level is obtained. As per the National Comprehensive Cancer Network (NCCN) guidelines we recommend at 1 year postresection, a colonoscopy and abdominopelvic CT. Either a chest CT or chest x-ray is also performed. A CT scan is performed annually until 3 years postoperatively. Colonoscopy frequency is determined by the findings at 1 year. If there are no polyps and no recurrence, the follow-up interval can be lengthened. After 2 years, patients continue to be followed every 6 months with CEA levels and physical examinations until 5 years after the surgery. At 5 years, if the patient has had no recurrence, he or she may be followed yearly with clinic visits and may undergo colonoscopy every 3 to 5 years. Of course, closer observation is indicated for patients at high risk for subsequent cancer formation, such as patients with IBD, polyposis syndromes, or a strong family history of colorectal cancer.

## REFERENCES

- Jemal A, Murray T, Samuels A, et al. Cancer statistics, 2003. *CA Cancer J Clin.* 2003;53:5.
- Miles WE. A method of performing abdominoperineal excision for carcinoma of the rectum and the terminal portion of the pelvic colon. *Cancer.* 1908;2:1812.
- Heald RJ, Moran BJ, Ryall RD, et al. Rectal cancer: the Basingstoke experience of total mesorectal excision, 1978–1997. *Arch Surg.* 1998;133:894–899.
- Wei EK, Giovannucci E, Wu K, et al. Comparison of risk factors for colon and rectal cancer. *Int J Cancer.* 2004;108:433–442.
- Martínez ME, McPherson RS, Annegers JF, Levin B. Cigarette smoking and alcohol consumption as risk factors for colorectal adenomatous polyps. *J Natl Cancer Inst.* 1995;87:274–279.
- Haggitt RC, Glotzbach RE, Soffer EE, et al. Prognostic factors in colorectal carcinomas arising in adenomas: implications for lesions removed by endoscopic polypectomy. *Gastroenterology.* 1985;89:328–336.
- Masaki T, Muto T. Predictive value of histology at the invasive margin in the prognosis of early invasive colorectal carcinoma. *J Gastroenterol.* 2000;35:195–200.
- Memon S, Keating JP, Cooke HS, Dennett ER. A study into external rectal anatomy: improving patient selection for radiotherapy for rectal cancer. *Dis Colon Rectum.* 2009;52(1):87–90.
- Sato K, Sato T. The vascular and neuronal composition of the lateral ligament of the rectum and the rectosacral fascia. *Surg Radiol Anat.* 1991;13:17–22.
- Jones OM, Smeulders N, Wiseman O, et al. Lateral ligaments of the rectum: an anatomical study. *Br J Surg.* 1999;86:487–489.
- Scott N, Jackson P, al-Jaberi T, et al. Total mesorectal excision and local recurrence: a study of tumour spread in the mesorectum distal to rectal cancer. *Br J Surg.* 1995;82:1031–1033.
- Hida J, Yasutomi M, Maruyama T, et al. Lymph node metastases detected in the mesorectum distal to carcinoma of the rectum by the clearing method: justification of total mesorectal excision. *J Am Coll Surg.* 1997;184:584.
- Ueno H, Yamauchi C, Hase K, et al. Clinicopathological study of intrapelvic cancer spread to the iliac area in lower rectal adenocarcinoma by serial sectioning. *Br J Surg.* 1999;86:1532–1537.
- Enker WE, Kafka NJ, Martz J. Planes of sharp pelvic dissection for primary, locally advanced, or recurrent rectal cancer. *Semin Surg Oncol.* 2000;18:199–206.
- García-Aguilar J, Pollack J, Lee SK, et al. Accuracy of endorectal ultrasonography in preoperative staging of rectal tumors. *Dis Colon Rectum.* 2002;45:10–15.
- Orrom WJ, Wong WD, Rothenberger DA, et al. Endorectal ultrasound in the preoperative staging of rectal tumors: a learning experience. *Dis Colon Rectum.* 1990;33:654–659.
- Guillem JG, Moore HG, Akhurst T, et al. Sequential preoperative fluorodeoxyglucose-positron emission tomography assessment of response to preoperative chemoradiation: a means for determining long-term outcomes of rectal cancer. *J Am Coll Surg.* 2004;199:1–7.
- Moore HG, Akhurst T, Larson SM, et al. A case-controlled study of 18-fluorodeoxyglucose positron emission tomography in the detection of pelvic recurrence in previously irradiated rectal cancer patients. *J Am Coll Surg.* 2003;197:22–28.
- Morson BC, Whiteway JE, Jones EA, et al. Histopathology and prognosis of malignant colorectal polyps treated by endoscopic polypectomy. *Gut.* 1984;25:437–444.
- Nascimbeni R, Burgart LJ, Nivatvongs S, Larson DR. Risk of lymph node metastasis in T1 carcinoma of the colon and rectum. *Dis Colon Rectum.* 2002;45(2):200–206.
- Sitzler PJ, Seow-Choen F, Ho YH, Leong AP. Lymph node involvement and tumor depth in rectal cancers: an analysis of 805 patients. *Dis Colon Rectum.* 1997;40(12):1472–1476.
- Jessup JM, Stewart AK, Menck HR. The National Cancer Data Base report on patterns of care for adenocarcinoma of the rectum, 1985–1995. *Cancer.* 1998;83:2408.
- Willett CG, Lewandowski K, Donnelly S, et al. Are there patients with stage I rectal carcinoma at risk for failure after abdominoperineal resection? *Cancer.* 1992;69:1651–1655.
- Clarke JS, Condon RE, Bartlett JG, et al. Preoperative oral antibiotics reduce septic complications of colon operations: results of prospective, randomized, double-blind clinical study. *Ann Surg.* 1977;186:251–259.
- Solla JA, Rothenberger DA. Preoperative bowel preparation: a survey of colon and rectal surgeons. *Dis Colon Rectum.* 1990;33:154–159.
- Nichols RL, Smith JW, Garcia RY, et al. Current practices of preoperative bowel preparation among North American colorectal surgeons. *Clin Infect Dis.* 1997;24:609–619.
- Smink, Vicout E, Launay-Savary MV, Contant C, Chipponi J. Updated systematic review and meta-analysis of randomized clinical trials on the role of mechanical bowel preparation before colorectal surgery. *Ann Surg.* 2009;249(2):203–209.
- Wolmark N, Fisher B. An analysis of survival and treatment failure following abdominoperineal and sphincter-saving resection in Dukes' B and C rectal carcinoma: a report of the NSABP clinical trials. National Surgical Adjuvant Breast and Bowel Project. *Ann Surg.* 1986;204:480–489.
- Vernava AM, 3rd, Moran M, Rothenberger DA, et al. A prospective evaluation of distal margins in carcinoma of the rectum. *Surg Gynecol Obstet.* 1992;175:333–336.
- Moore HG, Riedel E, Minsky BD, et al. Adequacy of 1-cm distal margin after restorative rectal cancer resection with sharp mesorectal excision and preoperative combined-modality therapy. *Ann Surg Oncol.* 2003;10:80–85.
- Nelson H, Petrelli N, Carlin A, et al. Guidelines 2000 for colon and rectal cancer surgery. *J Natl Cancer Inst.* 2001;93:583–596.
- Wibe A, et al. *BJS* 2002;89:327–344.
- Ota DM, Skibber J, Rich TA. M.D. Anderson Cancer Center experience with local excision and multimodality therapy for rectal cancer. *Surg Oncol Clin N Am.* 1992;1:147–152.
- Bleday R, Breen E, Jessup JM, et al. Prospective evaluation of local excision for small rectal cancers. *Dis Colon Rectum.* 1997;40:388–392.
- Steele GD, Herndon JE, Bleday R, et al. Sphincter-sparing treatment of distal rectal adenocarcinoma. *Ann Surg Oncol.* 1999;6:433–441.
- Greenberg JA, Shibata D, Herndon JE, Steele, Jr. GD, Mayer R, Bleday R. Local excision of distal rectal cancer: an update on CALGB 8984. *Dis Colon Rectum.* 2008;51(8):1185–1191.
- García-Aguilar J, Shi Q, Thomas CR Jr, et al. A phase II Trial of Neoadjuvant Chemoradiation and Local Excision for T2N0 Rectal Cancer: preliminary results of the ACOSOG Z6041 trial. *ANN Surg Oncol.* 2012;19:384–391.
- Moore JS, Cataldo PA, Osler T, Hyman NH. Transanal endoscopic microsurgery is more effective than traditional transanal excision for resection of rectal masses. *Dis Colon Rectum.* 2008;51(7):1026–1030; discussion 1030–1031. [Epub 2008 May 15]
- Guillem JG. Ultra-low anterior resection and coloanal pouch reconstruction for carcinoma of the distal rectum. *World J Surg.* 1997;21:721–727.
- Kapiteijn E, Marijnen CA, Nagtegaal ID, et al. Preoperative radiotherapy combined with total mesorectal excision for resectable rectal cancer. *N Engl J Med.* 2001;345:638–646.



41. Heald RJ, Husband EM, Ryall RD. The mesorectum in rectal cancer surgery: the clue to pelvic recurrence? *Br J Surg*. 1982;69:613–616.
42. Wibe A, Eriksen MT, Syse A, et al. Total mesorectal excision for rectal cancer: what can be achieved by a national audit? *Colorectal Dis*. 2003;5:471–477.
43. Guillem JG, Chessin DB, Cohen AM, et al. Long-term oncologic outcome following preoperative combined modality therapy and total mesorectal excision of locally advanced rectal cancer. *Ann Surg*. 2005;241:829–838.
44. Takahashi T, Ueno M, Azekura K, Ohta H. Lateral node dissection and total mesorectal excision for rectal cancer. *Dis Colon Rectum*. 2000;43:S59–S68.
45. Kusters M, Beets GL, van de Velde CJ, et al. A comparison between the treatment of low rectal cancer in Japan and the Netherlands, focusing on the patterns of local recurrence. *Ann Surg*. 2009;249(2):229–235.
46. Akasu T, Sugihara K, Moriya Y. Male urinary and sexual functions after mesorectal excision alone or in combination with extended lateral pelvic lymph node dissection for rectal cancer. *Ann Surg Oncol*. 2009;16(10):2779–2786. [Epub 2009 Jul 21]
47. Havenga K, Enker WE, McDermott K, et al. Male and female sexual and urinary function after total mesorectal excision with autonomic nerve preservation for carcinoma of the rectum. *J Am Coll Surg*. 1996;182:495–502.
48. Van Den Brink M, Van Den Hout WB, Stiggelbout AM, et al. Cost-utility analysis of preoperative radiotherapy in patients with rectal cancer undergoing total mesorectal excision: a study of the Dutch Colorectal Cancer Group. *J Clin Oncol*. 2004;22:244–253.
49. Rothenberger DA, Wong WD. Abdominoperineal resection for adenocarcinoma of the low rectum. *World J Surg*. 1992;16:478–485.
50. Williams NS, Johnston D. The quality of life after rectal excision for low rectal cancer. *Br J Surg*. 1983;70:460–462.
51. Enker WE, Havenga K, Polyak T, et al. Abdominoperineal resection via total mesorectal excision and autonomic nerve preservation for low rectal cancer. *World J Surg*. 1997;21:715–720.
52. West NP, Finan PJ, Anderin C, Lindholm J, Holm T, Quirke P. Evidence of the oncologic superiority of cylindrical abdominoperineal excision for low rectal cancer. *J Clin Oncol*. 2008;26(21):3517–3522. [Epub 2008 Jun 9]
53. Christian CK, Kwaan MR, Betensky RA, et al. Risk factors for perineal wound complications following abdominoperineal resection. *Dis Colon Rectum*. 2005;48:43–48.
54. Ruo L, Paty PB, Minsky BD, et al. Results after rectal cancer resection with in-continuity partial vaginectomy and total mesorectal excision. *Ann Surg Oncol*. 2003;10:664–668.
55. Law WL, Chu KW, Choi HK. Total pelvic exenteration for locally advanced rectal cancer. *J Am Coll Surg*. 2000;190:78–83.
56. Ruo L, Gougoutas C, Paty PB, Guillem JG, Cohen AM, Wong WD. Elective bowel resection for incurable stage IV colorectal cancer: prognostic variables for asymptomatic patients. *J Am Coll Surg*. 2003;196:722–728.
57. Weiser MR, Milsom JW. Laparoscopic total mesorectal excision with autonomic nerve preservation. *Semin Surg Oncol*. 2000;19:396–403.
58. Clinical Outcomes of Surgical Therapy Study Group. A comparison of laparoscopically assisted and open colectomy for colon cancer. *N Engl J Med*. 2004;350(20):2050–2059.
59. Jayne DG, Guillou PJ, Thorpe H, et al. Randomised trial of laparoscopic-assisted resection of colorectal carcinoma: 3-year results of the UK MRC CLASICC Trial Group. *J Clin Oncol*. 2007;25:3061–3068.
60. Guillou PJ, Quirke P, Thorpe H, et al; MRC CLASICC trial group. Short-term endpoints of conventional versus laparoscopic-assisted surgery in patients with colorectal cancer (MRC CLASICC trial): multicentre, randomised controlled trial. *Lancet*. 2005;365(9472):1718–1726.
61. Jayne DG, Brown JM, Thorpe H, Walker J, Quirke P, Guillou PJ. Bladder and sexual function following resection for rectal cancer in a randomized clinical trial of laparoscopic versus open technique. *Br J Surg*. 2005;92:1124–1132.
62. Shoup M, Guillem JG, Alektiar KM, et al. Predictors of survival in recurrent rectal cancer after resection and intraoperative radiotherapy. *Dis Colon Rectum*. 2002;45:585–592.
63. Salo JC, Paty PB, Guillem J, et al. Surgical salvage of recurrent rectal carcinoma after curative resection: a 10-year experience. *Ann Surg Oncol*. 1999;6:171–177.
64. Miner TJ, Jaques DP, Paty PB, et al. Symptom control in patients with locally recurrent rectal cancer. *Ann Surg Oncol*. 2003;10:72–79.
65. Wolmark N, Rockette H, Mamounas E, et al. Clinical trial to assess the relative efficacy of fluorouracil and leucovorin, fluorouracil, and levamisole, and fluorouracil, leucovorin, and levamisole in patients with Dukes' B and C carcinoma of the colon: Results from the National Surgical Adjuvant Breast and Bowel Project C-04. *J Clin Oncol*. 1999;17:3553–3559.
66. Gastrointestinal Tumor Study Group. Prolongation of the disease-free interval in surgically treated rectal carcinoma. *N Engl J Med*. 1985;312:1465–1472.
67. Krook JE, Moertel CG, Gunderson LL, et al. Effective surgical adjuvant therapy for high-risk rectal carcinoma. *N Engl J Med*. 1991;324:709–715.
68. Swedish Rectal Cancer Trial. Improved survival with preoperative radiotherapy in resectable rectal cancer. *N Engl J Med*. 1997;336:980–987.
69. Camma C, Guinta M, Fiorica F, et al. Preoperative radiotherapy for resectable rectal cancer: a meta-analysis. *JAMA*. 2000;284:1008–1015.
70. Sauer R, Becker H, Hohenberger W, et al. Preoperative versus postoperative chemoradiotherapy for rectal cancer. *N Engl J Med*. 2004;351:1731–1740.
71. Bujko K, Nowacki MP, Nasierowska-Guttmejer A, et al. Sphincter preservation following preoperative radiotherapy for rectal cancer: report of a randomised trial comparing short-term radiotherapy vs. conventionally fractionated radiochemotherapy. *Radiother Oncol*. 2004;72:15–24.
72. Pietrzak L, Bujko K, Nowacki MP, et al; Polish Colorectal Study Group. Quality of life, anorectal and sexual functions after preoperative radiotherapy for rectal cancer: report of a randomised trial. *Radiother Oncol*. 2007;84(3):217–225. [Epub 2007 Aug 10]
73. Bosset JF, Collette L, Calais G, et al; EORTC Radiotherapy Group Trial 22921. Chemotherapy with preoperative radiotherapy in rectal cancer. *N Engl J Med*. 2006;355(11):1114–1123.

*This page intentionally left blank*

# PERSPECTIVE ON RECTAL AND ANAL CANCER

Julio Garcia-Aguilar

## CANCER OF THE RECTUM

### Introduction

For many years the treatment of rectal cancer has involved removal of the rectum and the mesorectal envelope through a laparotomy, an operation commonly known as *total mesorectal excision* (TME).<sup>1</sup> For surgeons performing this procedure, the main surgical consideration was whether to preserve the sphincter and restore continuity of the bowel or remove the entire rectum and anal canal leaving the patient with a permanent colostomy. In recent years, an improved understanding of the biology of rectal cancer and the causes of local recurrence,<sup>2,3</sup> coupled with advances in imaging,<sup>4</sup> surgical techniques,<sup>5,6</sup> and the use of radiation and systemic chemotherapy<sup>7</sup> have expanded the available surgical options. Selection between the different surgical therapies is based predominately on the stage and location of the tumor. Other factors such as patient age, overall health, functional status, and personal wishes and expectations also need to be taken into consideration when deciding on an appropriate surgical approach.

### Patient Evaluation

Treatment decisions in patients with rectal cancer can be influenced by the presence of synchronous tumors, by the locoregional extension of the disease, and by the presence of distant metastasis. Therefore, every patient should undergo a complete evaluation before outlining a treatment plan.

A complete colonoscopy is important to exclude synchronous polyps and cancers, but locoregional staging is essential to guide the initial therapy. A digital rectal examination (DRE) provides useful information because the mobility of the tumor in relation to the rectal wall is an indication of the depth of tumor invasion. The DRE is particularly useful in assessing the relationship of the tumor to the levator muscle and the external anal sphincter, and deciding between the different treatment options. A proctoscopic examination

is the best method to assess the distance of the tumor from the anal verge, the only anatomical landmark that can be seen simultaneously with the distance marks of the rigid scope.

In addition to a thorough clinical examination, every rectal cancer patient should undergo adequate local and regional staging with the help of the best available imaging technology.<sup>4</sup> Endorectal ultrasound (ERUS) is a useful technique for staging early rectal cancer as it provides detailed images of the different layers of the rectal wall and demonstrates the disruption of those layers by the tumor. Magnetic resonance imaging (MRI) is most useful for staging locally advanced rectal cancer because it provides a broader view of the pelvis and the best images of the fascia propria of the rectum. The new-generation computed tomography (CT) scanners also provide high-resolution cross-sectional images of the rectum, the mesorectum, and surrounding pelvic structures, and can be used for the locoregional staging of rectal cancers when high-quality MRI is not available. A chest x-ray and a CT scan of the abdomen and pelvis are also commonly included in any patient assessment to diagnose metastatic disease. Occasionally, other tests such as a triple-phase CT of the liver or a positron emission tomography-CT (PET-CT) may be necessary to confirm the diagnosis of liver or pulmonary metastasis.

### Choosing the Surgical Approach

At the completion of the evaluation, the surgeon must decide whether the patient requires a TME or can be treated with a local form of therapy, such as local excision (LE). To make the right choice, the surgeon should take into consideration both the location and characteristics of the tumor and the overall status of the patient.

#### LOCAL EXCISION

Patients with early-stage rectal cancer, that is, tumors localized to the bowel wall that have not penetrated beyond the muscularis propria and do not involve the mesorectal lymph nodes, can potentially be treated with LE, thus avoiding some



of the mortality, morbidity, and functional consequences of removing the entire rectum.<sup>8</sup> Local excision of low rectal cancers can be performed by a conventional transanal excision (TAE) or by transanal endoscopic microsurgery (TEM), an operation that uses a special operating proctoscope, endoscopic imaging, and long surgical instruments similar to those used for laparoscopy.<sup>9</sup> The oncologic outcomes are similar with both LE techniques for tumors of the same stage and location.<sup>10</sup> However, the advantage of TEM is that it permits the use of LE in tumors located in the mid and upper rectum, which would otherwise be out of reach using TAE. But this advantage is relative as LE should only be considered for patients with early-stage distal rectal cancers in whom a TME would otherwise require a coloanal anastomosis or an abdominoperineal resection (APR) of the rectum.

The initial decision to perform LE should be based on clinical staging and imaging studies; only patients with small mobile tumors, localized to the rectal wall and without mesorectal nodes suspicious for lymph node metastasis according to optimal imaging, should be considered for LE.<sup>8</sup> However, the decision to accept LE as the only treatment should be based on the pathologic examination of the LE specimen. For fit and healthy patients treated with curative intent, LE as the only form of therapy should only be offered for distal T1N0 rectal cancers with favorable histologic features (well or moderately differentiated, without lymphovascular invasion, mucinous component, or signet ring cells) and negative resection margins. Patients with positive margins or tumors with unfavorable histologic features should be offered a TME. Patients found to have T2 tumors after an LE should be offered a TME because the 5-year survival rate after LE as the only form of therapy for T2 tumors is lower compared to TME.<sup>11</sup> Two prospective phase II trials have suggested that postoperative radiation and chemotherapy decrease the risk of local recurrence after LE for T2 rectal cancer provided the surgical margins are negative and the mesorectum is free of nodes in preoperative imaging staging.<sup>12,13</sup>

Patients with clinically staged T2N0 tumors, that is, those with a complete break of the submucosa but no penetration into the perirectal fat and without evidence of mesorectal nodes in ERUS imaging, deserve special consideration. While still potentially resectable for cure with LE, these tumors carry a significant risk of occult nodal metastasis, and, if confirmed to be T2 tumors on histopathologic examination, they are associated with a high rate of local recurrence when they are treated with LE alone. Therefore, chemoradiation (CRT) before LE has been explored as an option for patients with distal uT2uN0 rectal cancer interested in an organ preservation approach.<sup>8</sup> The ACOSOG Z6041 (American College of Surgeons Oncology Group Z6041) trial investigated the efficacy of CRT before LE in this subset of rectal cancer patients, but the long-term oncologic outcomes for these patients are not available yet, and therefore CRT before LE for ultrasound-staged T2N0 tumors should still be considered an experimental treatment.<sup>14</sup>

## TOTAL MESORECTAL EXCISION

The majority of rectal cancer patients with tumors that have penetrated the muscularis propria or metastasized to the

mesorectal lymph nodes require the removal of the rectum and the mesorectal envelope. This operation should be performed by sharp dissection within the areolar space between the fascia propria of the rectum and the presacral fascia. A blunt dissection increases the risks of tearing the mesorectum potentially leaving nests of cancer cells behind or causing bleeding from inadvertent tearing of the presacral veins. The risks of injuring the hypogastric nerves or the branches of the pelvic plexuses are also considerably reduced if they are visualized and protected during a sharp mesorectal excision along well-defined anatomical planes. Rectal perforation with the associated risks of pelvic infection, tumor cell spillage, and compromised sphincter preservation are also less likely when the dissection is performed outside the fascia propria of the rectum. The importance of performing a sharp mesorectal excision has been highlighted by a number of pathologic audits that have linked the completeness of the mesorectal excision to the risk of local and distant tumor recurrence.<sup>3</sup>

The need to remove the entire mesorectum for tumors located in the upper rectum has been a matter of controversy for years. There is now conclusive evidence that rectal cancers rarely spread distally in the mesorectum beyond 5 cm, measured from the lower end of the tumor.<sup>15</sup> Therefore, for tumors located in the upper rectum, the mesorectum can be safely transected transversely, without coning, approximately 5 cm distal to the lower margin of the tumor. This operation is often called *tumor-specific mesorectal excision*. For tumors located in the mid or lower rectum, a 5-cm mesorectal clearance requires a complete TME.<sup>16</sup>

The mesorectum tapers distally as the rectum approaches the levator hiatus and ends slightly above the level of the anorectal ring. Distal to that point, the muscularis propria of the rectum is in contact with the levator muscle. For most mid and distal rectal cancers, the rectum is transected below the end of the mesorectum and the intestinal continuity is reestablished by a double-stapling technique. Whenever possible, a colonic J-pouch or a side-to-end anastomosis should be performed to provide some reservoir capacity and reduce, at least temporarily, the urgency and frequency associated with the sphincter-saving procedure. For patients with tumors located close to the anorectal ring, the surgeon must decide whether removal of the tumor with a negative margin is compatible with sphincter preservation or requires an APR of the rectum. For many years the decision between these two surgical options was based primarily on the possibility of obtaining a negative distal resection margin in the bowel wall. While a 2-cm margin of normal rectal wall distal to the tumor is desirable, a margin as short as 1 cm does not seem to increase the risk of recurrence, particularly in patients treated with neoadjuvant CRT.<sup>17</sup> In recent years surgeons have learned that in most patients with very distal rectal cancers, the need for an APR of the rectum is due to the inability to obtain a negative circumferential resection margin rather than a negative distal margin. In general, an APR of the rectum becomes necessary when a distal rectal cancer has penetrated beyond the muscularis propria and infiltrates the levator muscle or the external anal sphincter. In these patients, the dissection in the intersphincteric plane in an attempt to preserve the sphincter will

result in a positive circumferential resection margin with the consequent risk of local tumor recurrence. Tumor fixation on DRE is a good indicator of tumor infiltration of the levator muscle or the external anal sphincter, but high-resolution MRI and CT scans that provide axial, sagittal, and coronal views can demonstrate the relationship of the tumor to the levator muscle and the external anal sphincter with a high degree of accuracy.

Historically, an APR of the rectum has been associated with higher local recurrence rates compared to the sphincter-saving procedures.<sup>18</sup> This difference has been attributed in part to the higher rate of positive circumferential resection margins associated with the APR in tumors that infiltrate the levator muscle or the external anal sphincter.<sup>19</sup> When the pelvic dissection is carried out distally to the level of the levator hiatus or beyond and the upper portion of the levator muscle is not removed, the risk of leaving tumor behind is very high. Therefore, when performing an APR for rectal cancer that infiltrates the levators or the external sphincter, the mesorectal dissection should stop at the upper level of the levators. During the perineal dissection, the levators should be divided at the apex of the ischioanal fossa where they insert in the white line of the obturator fascia. This operation, known as a *cylindrical APR*, has been shown to decrease the risk of local recurrence compared to conventional APR.<sup>20</sup> Some surgeons prefer to perform the perineal portion of the APR with the patient in the prone-jackknife position because it provides better visualization of all anatomical structures, improved ergonomics, and better use of assistants.

Some patients with low rectal cancers that do not infiltrate the levator muscle or the external sphincter but are too close to the pelvic floor to perform a double-stapling technique are still potential candidates for a sphincter-saving procedure with a hand-sewn coloanal anastomosis. In this procedure the dissection of the portion of the rectum distal to the tumor is performed through the anus. This transanal approach provides simultaneous visualization of the distal end of the tumor and the anatomical landmarks in the anal canal, in particular the dentate line and the anal verge. A circular incision is made in the rectal wall at least 1 cm below the level of the tumor. This incision is carried through the mucosa, submucosa, and muscularis propria/internal sphincter until the intersphincteric space is reached. The transanal dissection is carried out in the intersphincteric space separating the distal rectum from the levator muscle posteriorly and laterally and from the urethra and the prostate or vagina anteriorly, provided that the intersphincteric space is free of tumor. This transanal dissection of the distal portion of the rectum can be performed before or after the transabdominal mesorectal dissection. If the mesorectal dissection has been performed from the pelvis first, the transanal dissection is continued until the rectum is totally mobilized. When the transanal approach is the first step of the operation, the lumen of the distal rectum is closed with interrupted sutures and the patient is repositioned to perform the abdominal and pelvic aspects of the operation. Either way, once the specimen is removed, the distal end of the colon is anastomosed to the anal canal

with interrupted absorbable stitches. Patients with distal rectal cancer treated with a TME and a sphincter-saving procedure should receive a loop ileostomy because of the high risk of anastomotic leak.

### MINIMALLY INVASIVE TME

In most centers a TME is performed through a midline or low transverse laparotomy. However, many surgeons use minimally invasive techniques for the treatment of rectal cancer because of the potential gains of a faster recovery and improved short-term quality-of-life outcomes.

The length of the incision in rectal cancer surgery is dictated by the need to mobilize the left colon and take down the splenic flexure rather than by the mesorectal dissection. Therefore, dividing the inferior mesenteric artery and vein, taking down the splenic flexure, and mobilizing the left colon laparoscopically or with the help of a hand-assisted device, help reduce the length of the incision even if the mesorectal dissection is performed open through a low midline or low transverse incision. A laparoscopic or robotic mesorectal dissection reduces the size of the abdominal incision even further and expedites recovery without compromising the quality of the operation or the oncologic outcomes compared to open mesorectal dissection.<sup>21,22</sup>

For a laparoscopic TME, the patient is placed in a modified lithotomy position with the legs in stirrups and the hips fully extended. The patient needs to be well secured to the operating table to avoid sliding when the table is placed in steep Trendelenburg's position and/or lateral rotation. Once the pneumoperitoneum is created by either a Veress needle in the left upper quadrant or by placing the Hasson trocar in the periumbilical area, additional trocars are placed in the right upper, right lower, and left lower quadrants. Once the peritoneum is inspected and the presence of peritoneal carcinomatosis excluded, the operation begins by identifying the inferior mesenteric artery and its branches at the root of the left colon mesentery. A space is developed underneath the superior rectal vessels, and, once the left ureter is identified, the vessels are divided with a stapling device, between vascular clips, or with a bipolar energy device. Care has to be taken to avoid injuring the hypogastric plexus that lies close to the aorta. Next, the inferior mesenteric vein is dissected and divided close to the ligament of Treitz. The mesentery of the sigmoid and descending colon is lifted from the retroperitoneal structures by blunt dissection, from the inferior border of the pancreas to the pelvic inlet. The lateral attachments of the colon to the parietal peritoneum along the line of Told are divided from the pelvic inlet to the splenic flexure. Finally, the splenic flexure is completely mobilized after separating the omentum from the left side of the transverse colon. Some surgeons routinely take down the splenic flexure and mobilize the entire left colon in every patient undergoing a sphincter-saving TME for rectal cancer to ensure a tension-free anastomosis using the end of the descending colon. The blood supply of the left colon is never an issue provided the left branch of the middle colic vessels and the marginal vessels are preserved.

Once the colon is completely mobilized, the mesorectal dissection starts by applying traction anteriorly from the stump of the superior rectal vessels to open the areolar space behind the fascia propria of the rectum at the level of the promontory. The hypogastric nerves, clearly identified at this level in their course toward the pelvic sidewalls, should be carefully separated from the fascia propria of the rectum and brushed posteriorly and laterally. The peritoneum is opened on both sides of the rectum all the way to the cul-de-sac, and the rectum is lifted from the concavity of the sacrum by sharply dividing the areolar attachments of the fascia propria of the rectum to the presacral fascia. The lateral stalks are divided next using electrocautery, although harmonic scalpel or bipolar coagulation can also be used. The anterior dissection to separate the rectum from the urogenital organs is performed last. The anterior dissection can be performed in different planes, depending on the location of the tumor. For anterior tumors the dissection should be carried in front of Denonvilliers' fascia to avoid dissecting into the tumor. For other tumors, the dissection can be safely performed behind Denonvilliers' fascia.

The laparoscopic TME is a technically demanding procedure because of the two-dimensional visualization, the use of long and rigid instruments, the difficulty handling the rectum and providing traction and countertraction during the dissection, and the unnatural position for the surgeon. Consequently conversion rates for laparoscopic TME in prospective randomized trials have been high.<sup>21</sup> The robotic da Vinci (Intuitive Surgical, Inc., Sunnyvale, CA) platform eliminates some of these difficulties by providing tridimensional visualization, articulating instruments that resemble the human wrist, improved scale of motion, enhanced surgeon control of camera and instruments, and improved ergonomics. A number of retrospective case series have reported that a robotic TME is safe and provides similar outcomes compared to open or laparoscopic TME.<sup>23</sup> However, the changes in patient position needed to take advantage of the gravity required to keep the small bowel away from the area of dissection represents a handicap to the use of the robot because it requires more than one docking of the instruments to the patient. Therefore, most surgeons perform a hybrid procedure with laparoscopic control of the vessels, mobilization of the left colon, and takedown of the splenic flexure and robotic mesorectal dissection. Robotic techniques are still evolving, and with new instrumentation and improved trocar placement it may be possible to perform the entire operation without the need to reposition the patient.

## Use of Neoadjuvant CRT

Another important consideration for patients with rectal cancer is the use of neoadjuvant CRT to improve local tumor control. Information accumulated over several decades has proven that for patients with locally advanced rectal cancer the use of pelvic radiation with or without chemotherapy decreases the risk of local recurrence. For many years, pelvic radiation was given after surgery for patients with tumors found at surgery to penetrate the perirectal fat or involve the regional lymph nodes.<sup>24</sup> With recent advances in imaging techniques that can

accurately stage tumors before surgery, patients diagnosed with locally advanced rectal cancer now receive pelvic radiation, usually associated with sensitizing chemotherapy, prior to surgery. Indeed there is now conclusive evidence suggesting that the use of neoadjuvant CRT is more effective for local tumor control and safer than adjuvant CRT.<sup>25</sup>

Current guidelines in the United States recommend that all patients with clinical stage II or III rectal cancers should be treated with 5 weeks of hyperfractionated radiation and sensitizing chemotherapy, followed by TME 6–8 weeks later, and postoperative adjuvant chemotherapy.<sup>26</sup> In Europe, where most rectal cancer patients are staged with phased-array MRI, patients are stratified into three different risk groups according to the penetration of the tumor into the mesorectum and its relationship to the fascia propria of the rectum.<sup>27</sup> Patients with early rectal cancer are treated with TME alone. Patients with T3 or node-positive rectal cancer that is not close to the fascia propria of the rectum are treated by short course radiation (5 cGy/d for 5 consecutive days) followed by TME 1 week later. Patients with locally advanced tumors that are close to or reach the fascia propria of the rectum are treated with hyperfractionated radiation and sensitizing chemotherapy followed by TME, or extended surgery as needed to achieve an R0 resection, 6 weeks after completion of the CRT.

## Patients With Metastatic Disease

Almost one-third of rectal cancer patients present with distant metastasis at the time of diagnosis. The treatment options in these patients are multiple and need to be individualized according to the local-regional stage and the symptoms of the primary tumor, the extent and potential resectability of the metastatic disease and the comorbid conditions, and performance status of the patient. Treatment decisions in these patients require a multidisciplinary approach with input from several medical and surgical specialists.

Patients with distant metastases that are resectable or borderline resectable at the time of diagnosis often require multimodality therapy, including systemic chemotherapy, neoadjuvant CRT of the primary tumor, and surgery for the primary and the metastatic disease. The sequence and timing of these interventions need to be individualized according to the tumor and the patient, but also according to the response of the tumor to the different treatments. Asymptomatic patients should be treated initially with systemic chemotherapy with reevaluation after 2 months to assess tumor response and plan the surgery for both the primary tumor and the distant metastasis. Depending on the tumor response, some patients benefit from additional cycles of chemotherapy. Patients with locally advanced primary rectal cancers that approach the circumferential resection margin and have a high risk for local recurrence often need short-course radiation (5 Gy/d for 5 days) or CRT before surgery.

Fit and otherwise healthy patients may be candidates for synchronous resections of the primary tumor and the distant metastasis, particularly if the rectal resection can be performed laparoscopically. However synchronous resections are associated with high morbidity and some patients are better treated by



staged resections. If the decision is to perform staged resections, the primary tumor should be treated first because the inability to achieve a curative resection for the rectal primary, or the finding of unexpected peritoneal disease at the time of the first procedure, may impact the treatment plan for the distant metastasis.

A number of rectal cancer patients with resectable metastasis present with obstructive symptoms, rectal bleeding, or rectal pain at the time of diagnosis. While patients with severe symptoms may require an intervention such as tumor resection, diverting stoma, stenting, or even electrocoagulation, many of them experience a significant symptomatic improvement after a few weeks of CRT. Once the CRT is completed, patients can be treated with systemic chemotherapy.

In the past, asymptomatic patients with unresectable metastasis were offered surgery to treat or prevent debilitating complications related to the primary tumor such as obstruction, bleeding, or perforation. But multiple studies have proven that the proportion of these patients requiring an operation to treat complications is relatively small. Therefore asymptomatic patients with unresectable metastasis should also be treated initially with systemic chemotherapy. The treatment of the primary tumor will depend on the response to the chemotherapy and the development of symptoms. Patients with unresectable distant metastasis and symptoms either at diagnosis or after systemic chemotherapy may require local palliative interventions. These palliative procedures may include resection, diverting stoma, stenting, tumor ablation by laser or electrocautery, or even CRT, depending on the type and severity of the symptoms, the size of the tumor, the performance status, the comorbid conditions, and life expectancy of the patient.

## CANCER OF THE ANUS

In the last three decades of the 20th century, anal cancer changed from being a disease primarily treated by surgery to a disease treated with chemotherapy and radiation. These changes resulted in improved patient survival and quality of life. However, they have been paralleled by a dramatic increase in the incidence of anal cancer due primarily to the AIDS epidemics.

The surgeon still plays a pivotal role in the management of patients with anal cancer at different levels. The surgeon can play a role in the primary prevention of anal cancer by diagnosing and treating precancerous conditions, diagnosing and directing the initial therapy, following the patient to assess the tumor response to the multimodality therapy, and diagnosing and treating the recurrences. Therefore surgeons should be familiar with all aspects of the disease, from the etiology and pathogenesis to the treatment of advanced disease. All of these aspects are well covered in Chap. 42.

The term *cancer of the anus* includes a number of different neoplasms with different etiology, pathogenesis, treatment, and prognosis that have in common only their anatomical locations. Therefore a precise understanding of the embryology, anatomy, and histopathology of the anal region is essential. The anal canal extends from the anorectal ring, represented by the impromptu of the puborectalis in the distal rectal wall, to the anal verge, which corresponds to the palpable groove created by the distal

end of the internal anal sphincter. Outside the anal verge is the anal margin, which corresponds to a circular area of skin extending 5 cm from the anal verge around the anus. Tumors with their center located in the anal canal are considered cancers of the anal canal, but in some cases the classification of an adenocarcinoma as rectal or anal, or a squamous cell carcinoma as originating in the anal canal or in the anal margin, may be difficult. However, this distinction may be relatively irrelevant, because an adenocarcinoma invading the distal rectum and anal canal should be treated as a distal rectal cancer with neoadjuvant CRT and APR of the rectum and anal canal, while a squamous cell carcinoma of the anal margin extending to the anal canal should be treated primarily with CRT.

As emphasized in Chap. 42, the anal canal is a complex embryologic region where different types of epithelia overlap over a significant distance. For example, squamous epithelium could be found several centimeters within the rectum. Therefore it is not unusual to find a squamous cell carcinoma located entirely within the distal rectum. In addition, there are cases of squamous cell carcinoma located exclusively in the mesorectal lymph nodes secondarily invading the rectum without conclusive evidence of a primary tumor in the anal canal per se. These considerations are important, because tumors in the anorectal region should be treated according to their histology. In other words, a squamous cell carcinoma of the distal rectum should be treated as a squamous cell carcinoma of the anal canal.

One of the most controversial issues in the management of patients with anal cancer is primary prevention by diagnosing and treating precancerous conditions. As described in Chap. 42, a number of institutions are now performing anal Pap smear in high-risk patients groups. Patients with positive Pap smear are often referred to surgeons for high-resolution anoscopy. These procedures are only performed at a handful of institutions and the data are still limited, but the diagnosis and ablation of areas of high-grade squamous intraepithelial lesions (H-SIL) seems to reduce the risk of invasive squamous cell carcinoma of the anus in high-risk patients. The true effectiveness of this intervention, measured as the number of cancers prevented and the complications caused, is still to be proven. It is likely that the recently introduced prophylactic and therapeutic vaccine will prevent anal cancer with less discomfort and potential complications than the surgical or ablative therapies.

Shortly after the introduction of multimodality therapy as definitive therapy, patients were typically followed for 6–8 weeks after the completion of the CRT. A biopsy of the tumor bed was performed, and an APR of the rectum was recommended if the biopsy was positive. However, these premature biopsies led to many unnecessary permanent colostomies. As a result patients are now followed clinically with DRE and anoscopy, and biopsies are reserved for patients with persistent or recurrent palpable, visible, or symptomatic lesions. In most institutions follow-up examinations are performed at 3–4 months for the first 3 years and every 6 months for 2 additional years. The benefit of using ultrasound in the follow-up has not proven to be effective.

Not every patient with squamous cell carcinoma of the anus responds to multimodal therapy, and 20–30% of tumors will never disappear completely or will relapse after an apparent

initial complete response. Surgery is the best treatment for patients who have failed multimodality therapy, but only 30% of those who have a surgical resection survive 5 years.<sup>28–34</sup> A radical resection with negative resection margins is the main prognostic factor and the only hope for cure in these patients, and therefore every effort should be made to diagnose recurrences early when they are still resectable and to plan the operation adequately to remove the entire tumor en block with negative margins. An APR in patients with anal cancer, particularly in those with squamous cell carcinoma of the anus who have failed multimodality treatment, usually requires a wider skin excision and complete removal of the ischioanal fat and the levator muscle. These patients are therefore at a greater risk of infection and dehiscence of the perineal wound with the consequent morbidity. Therefore many of these patients benefit from a reconstruction of the perineum using either a rectus muscle flap or unilateral or bilateral gluteal flaps. In some patients salvage surgery requires extensive exenterative procedures with more complex reconstructions involving multiple specialists.<sup>30–34</sup>

## Acknowledgment

The author thanks Nicola Solomon, PhD, for assistance in writing and editing the manuscript.

## REFERENCES

- Heald RJ, Husband EM, Ryall RD. The mesorectum in rectal cancer surgery—the clue to pelvic recurrence? *Br J Surg*. 1982;69(10):613–616.
- Quirke P, Durdey P, Dixon MF, Williams NS. Local recurrence of rectal adenocarcinoma due to inadequate surgical resection. Histopathological study of lateral tumour spread and surgical excision. *Lancet*. 1986;2(8514):996–999.
- Nagtegaal ID, Marijnen CA, Kranenbarg EK, van de Velde CJ, van Krieken JH; Pathology Review Committee; Cooperative Clinical Investigators. Circumferential margin involvement is still an important predictor of local recurrence in rectal carcinoma: not one millimeter but two millimeters is the limit. *Am J Surg Pathol*. 2002;26(3):350–357.
- Evans J, Patel U, Brown G. Rectal cancer: primary staging and assessment after chemoradiotherapy. *Semin Radiat Oncol*. 2011;21(3):169–177.
- MacFarlane JK, Ryall RD, Heald RJ. Mesorectal excision for rectal cancer. *Lancet*. 1993;341(8843):457–460.
- West NP, Finan PJ, Anderin C, et al. Evidence of the oncologic superiority of cylindrical abdominoperineal excision for low rectal cancer. *J Clin Oncol*. 2008;26(21):3517–3522.
- Minsky BD, Röedel C, Valentini V. Combined modality therapy for rectal cancer. *Cancer J*. 2010;16(3):253–261.
- Garcia-Aguilar J, Holt A. Optimal management of small rectal cancers: TAE, TEM, or TME? *Surg Oncol Clin N Am*. 2010;19(4):743–760.
- Cataldo PA. Transanal endoscopic microsurgery. *Surg Clin North Am*. 2006;86(4):915–925.
- Christoforidis D, Cho HM, Dixon MR, et al. Transanal endoscopic microsurgery versus conventional transanal excision for patients with early rectal cancer. *Ann Surg*. 2009;249(5):776–782.
- You YN, Baxter NN, Stewart A, Nelson H. Is the increasing rate of local excision for stage I rectal cancer in the United States justified? A nationwide cohort study from the National Cancer Database. *Ann Surg*. 2007;245(5):726–733.
- Russell AH, Harris J, Rosenberg PJ, et al. Anal sphincter conservation for patients with adenocarcinoma of the distal rectum: long-term results of radiation therapy oncology group protocol 89-02. *Int J Radiat Oncol Biol Phys*. 2000;46(2):313–322.
- Greenberg JA, Shibata D, Herndon JE, 2nd, et al. Local excision of distal rectal cancer: an update of cancer and leukemia group B 8984. *Dis Colon Rectum*. 2008;51(8):1185–1191;discussion 1191–1194.
- Garcia-Aguilar J, Shi Q, Thomas, CR, et al. A phase II trial of neoadjuvant chemoradiation and local excision for T2N0 rectal cancer: preliminary results of the ACOSOG Z6041 trial. *Ann Surg Oncol*. 2012;19(2):384–391. [Epub 2011, Jul 14]
- Reynolds JV, Joyce WP, Dolan J, Sheahan K, Hyland JM. Pathological evidence in support of total mesorectal excision in the management of rectal cancer. *Br J Surg*. 1996;83:1112–1115.
- Lopez-Kostner F, Lavery IC, Hool GR, Rybicki LA, Fazio VW. Total mesorectal excision is not necessary for cancers of the upper rectum. *Surgery*. 1998;124(4):612–617; discussion 617–618.
- Guillem J, Chessin DB, Shia J, et al. Prospective pathologic analysis using whole-mount sections of rectal cancer following preoperative combined modality therapy: implications for sphincter preservation. *Ann Surg*. 2007;245(1):88–93.
- Nagtegaal ID, van de Velde CJ, Marijnen CA, van Krieken JH, Quirke P; Dutch Colorectal Cancer Group; Pathology Review Committee. Low rectal cancer: a call for a change of approach in abdominoperineal resection. *J Clin Oncol*. 2005;23(36):9257–9264.
- How P, Shihab O, Tekkis P, et al. A systematic review of cancer related patient outcomes after anterior resection and abdominoperineal excision for rectal cancer in the total mesorectal excision era. *Surg Oncol*. 2011;20(4):e149–e55. [Epub 2011;May 31]
- Marr R, Birbeck K, Garvican J, et al. The modern abdominoperineal excision: the next challenge after total mesorectal excision. *Ann Surg*. 2005;242:74–82.
- Jayne DG, Thorpe HC, Copeland J, et al. Five-year follow-up of the Medical Research Council CLASICC trial of laparoscopically assisted versus open surgery for colorectal cancer. *Br J Surg*. 2010;97(11):1638–1645.
- Kang SB, Park JW, Jeong SY, et al. Open versus laparoscopic surgery for mid or low rectal cancer after neoadjuvant chemoradiotherapy (COREAN trial): short-term outcomes of an open-label randomised controlled trial. *Lancet Oncol*. 2010;11(7):637–645.
- Baek JH, McKenzie S, Garcia-Aguilar J, Pigazzi A. Oncologic outcomes of robotic-assisted total mesorectal excision for the treatment of rectal cancer. *Ann Surg*. 2010;251(5):882–886.
- NIH Consensus Conference. Adjuvant therapy for patients with colon and rectal cancer. *JAMA*. 1990;264:1444–1450.
- Sauer R, Becker H, Hohenberger W, et al. Preoperative versus postoperative chemoradiotherapy for rectal cancer. *N Engl J Med*. 2004; 351(17):1731–1740.
- Engstrom PF, Arnoletti JP, Benson AB, 3rd, et al; National Comprehensive Cancer Network. NCCN Clinical Practice Guidelines in Oncology: rectal cancer. *J Natl Compr Canc Netw*. 2009;7(8):838–81.
- Valentini, V, Aristei C, Glimelius B, et al; Scientific Committee. European Multidisciplinary Rectal Cancer Management: 2nd European Rectal Cancer Consensus Conference (EURECA-CC2). *Radiother Oncol*. 2009; 92(2):148–163.
- Weis SE, Vecino I, Pogoda JM, et al. Prevalence of anal intraepithelial neoplasia defined by anal cytology screening and high-resolution anoscopy in a primary care population of HIV-infected men and women. *Dis Colon Rectum*. 2011;54(4):433–441.
- Berry JM, Palefsky JM, Jay N, et al. Performance characteristics of anal cytology and human papillomavirus testing in patients with high-resolution anoscopy-guided biopsy of high-grade anal intraepithelial neoplasia. *Dis Colon Rectum*. 2009;52(2):239–247.
- Butler CE, Gündeslioglu AO, Rodriguez-Bigas MA. Outcomes of immediate vertical rectus abdominis myocutaneous flap reconstruction for irradiated abdominoperineal resection defects. *Am Coll Surg*. 2008; 206(4):694–703.
- Sunesen KG, Buntzen S, Tei T, et al. Perineal healing and survival after anal cancer salvage surgery: 10-year experience with primary perineal reconstruction using the vertical rectus abdominis myocutaneous (VRAM) flap. *Ann Surg Oncol*. 2009;16(1):68–77.
- Lefevre JH, Parc Y, Kernéis S, et al. Abdomino-perineal resection for anal cancer: impact of a vertical rectus abdominis myocutaneous flap on survival, recurrence, morbidity, and wound healing. *Ann Surg*. 2009;250(5):707–711.
- Haapamäki MM, Pihlgren V, Lundberg O, Sandzén B, Rutegård J. Physical performance and quality of life after extended abdominoperineal excision of rectum and reconstruction of the pelvic floor with gluteus maximus flap. *Dis Colon Rectum*. 2011;54(1):101–106.
- Di Mauro D, D'Hoore A, Penninckx F, et al. V-Y Bilateral gluteus maximus myocutaneous advancement flap in the reconstruction of large perineal defects after resection of pelvic malignancies. *Colorectal Dis*. 2009;11(5):508–512.

# PERSPECTIVE ON RECTAL CANCER

Mark Welton

## INTRODUCTION

Dr Goldberg and Dr Bleday have admirably summarized the current literature regarding the diagnosis, evaluation, and treatment of rectal cancer. In broad strokes, I agree with what they say and wish primarily to highlight a few important issues.

## ANATOMIC LANDMARKS

In the description of the anatomy, the authors emphasize their preference for the anorectal ring as the anatomic landmark when evaluating the level of the tumor. Yet in other sections of the chapter, the anal verge and the dentate line are mentioned as the distal landmark rather than the anorectal ring. This is consistent with the confusion that exists in colorectal and general surgery and confounds and confuses recommendations made for approaching rectal tumors. I personally prefer the dentate line because it is a clear tissue transition not altered by patient body habitus. Consider, for example, a lesion at 5 cm from the anal verge. Heavyset patients may have a longer distance from the anal verge to the dentate line (4 cm), leaving the lesion quite close to the dentate line (1 cm above). In contrast, the distance from anal verge to the dentate may be very short in thin patients (1 cm), and the lesion may actually reside relatively high in the rectum (4 cm above the dentate line). This variability holds true for the other landmark mentioned, the anorectal ring. The muscular funnel that comprises the anal sphincters may be long in young muscular patients and shorter in others. These variations lead to unclear recommendations as to how to approach lesions at various heights. The literature would benefit from a standardization of landmarks so that authors and clinicians attempting to follow the recommendations in articles could compare outcomes across studies.

## PREOPERATIVE ASSESSMENT

I agree with the authors' recommendation for a CT scan of the chest, abdomen, and pelvis in the preoperative evaluation of

patients with rectal cancer and would add that a preoperative PET scan adds value when used selectively to assess abnormalities identified on CT scans. This approach is preferred to the routine use of PET scans as it is more cost-effective. It is better than a follow-up CT in 3 months after surgery in that it allows for earlier identification and treatment of metastatic and may obviate the need for surgical intervention.

## TNM STAGING

The 7th edition of the American Joint Committee on Cancer (AJCC) TNM (tumor-node-metastasis) staging system published in 2010 developed new classifications of stages II and III tumors following the recommendations of the Hindgut Taskforce.<sup>1,2</sup> As noted by the authors, the tumors are evaluated about depth of tumor invasion (T), nodal involvement (N), and distant metastases (M). Stage 0 tumors are T0 or Tis, N0 and M0. Stage I is T1 or T2, N0, M0. Stage II is T3 or T4, N0, M0. Stage III is Any T stage, N1 or N2, and M0. Stage IV is Any T stage, Any N stage, and M1. Stages II and III can be subdivided and these subdivisions were modified in the 7th edition based on the Surveillance, Epidemiology, and End Results (SEER) and the National Cancer Data Base (NCDB) data. Traditionally stage II was divided into IIA and IIB, T3, N0, M0, and T4, N0, M0, respectively. Stage III was separated into three stages: IIIA (T1 or T2, N1, M1); IIIB (T3 or T4, N1, M0); and IIIC (Any T, N2, M0). T4bN0 is associated with poorer survival and is now classified as IIC (previously IIB). In contrast, the following three tumors appear to have somewhat better survivals upgrading their classifications to IIIB, T1 or T2, N2a, T1 or T2, N2b and T3, N2a. Finally, T4b, N1a and T4b, N1b are IIIC (previously IIIB). These reclassifications are important for prognostication and treatment planning.

## PERIOPERATIVE MANAGEMENT

*Perioperative management* is an arena in which data appear to drive practice less rigorously than in other realms in



surgery despite the push to practice evidence-based, outcomes-driven medicine. A case in point is the issue of bowel preparation. The authors note despite the lack of evidence supporting oral mechanical bowel preparation and evidence from Cochrane reviews and a meta-analysis from Pineda et al that oral mechanical bowel preparation may be harmful, it is still their preference to mechanically bowel-prepare their patients prior to surgery.<sup>3,4</sup> They are not alone in this practice. Nearly 99% of colorectal surgeons surveyed in 2003 did the same.<sup>5</sup> Unfortunately, this survey predates the larger discussion and simply reinforces the need to educate the practicing physicians. We abandoned routine oral mechanical bowel preparation at our institution over 3 years ago because there are no data to support its routine use. We have continued oral mechanical bowel preparation when intraoperative colonoscopy is planned for tumor localization or clearing of the proximal bowel. Oral mechanical bowel preparation is associated with increased anastomotic leaks and wound complications in many series. This may result from dehydration, increased intraoperative fluid requirements (secondary to the dehydration), decreased core temperature (secondary to rehydration), and overresuscitation leading to edematous bowel. We have not noted any negative impact on bowel handling on either open or laparoscopic cases as suggested by the authors. Many other centers have abandoned routine oral mechanical bowel preparation based on the literature for all cases and simply perform one or two preoperative enemas to clear the distal bowel of feces to allow passage of a stapler. Others have eliminated bowel preparation for all right-sided lesions. The issue is far from settled as highlighted by a debate at the SSAT in 2009 when the presentation to eliminate oral mechanical bowel preparation won the debate unanimously and yet not one individual out of 250 attending did agree to change their practice based on the data. A large multicenter North American trial is still desired.

Wound infection rates are impacted by factors other than oral mechanical bowel preparation. The Surgical Care Improvement Project (SCIP) has outlined recommendations that have been adopted by the Centers of Medicare and Medicaid Services (CMS) and the Centers for Disease Control (CDC) as performance measures. These recommendations emphasize appropriate timing of antibiotic delivery, within 60 minutes of incision, discontinuation of antibiotics within 24 hours (although there are no data to support more than one preoperative dose with appropriate intraoperative redosing as needed),<sup>6</sup> appropriate hair removal, maintenance of normothermia, and “early” removal of urinary catheters.<sup>7-11</sup> In teaching hospitals the discontinuation of antibiotics proved to be a challenge. Therefore we moved to a single dose of ertapenem when appropriate as it provides a 24-hour coverage obviating the need for any postoperative “prophylaxis.” The timing of urinary catheter removal has not been well studied in the colorectal population, and colorectal pelvic cases are explicitly exempted from the urinary catheter removal performance measure.

## LOCAL EXCISION

The authors provide an excellent discussion of the controversies surrounding local excision of rectal cancers as would be expected, given Dr Bleday's leading role in defining patient populations appropriately treated in this fashion. Articles by You and others highlight the potential risks and benefits of transanal excision.<sup>12-16</sup> It appears T1 lesions within 5 cm of the dentate line with favorable histology and clear margins seem appropriately treated in this fashion. Whether T2 lesions may be treated in this fashion if they meet the aforementioned criteria and are treated with either preoperative combined modality therapy (chemotherapy plus radiation therapy) or postoperative therapy remains unclear. The potential for decreased operative morbidity and mortality with local excision is clear. Recently the presumed functional benefit and improved quality of life (QOL) associated with transanal excision were questioned when local excision was compared to low anterior resection (LAR).

It is clear that appropriate patient selection and adherence to preoperative selection criteria are critical, and ultimately this is an individual decision made after lengthy informed discussions with the patient and the patient's family. Unfortunately the current selection criteria are still lacking an ability to predict who will fail locally or with distant disease, and we await biologic markers. However, even with improved markers, questions will remain regarding treatment of primary rectal tumors by local excision in attempts to preserve gastrointestinal continuity. For instance, in a patient with markers that predict a high likelihood of early metastasis, does the method of removing the primary rectal tumor impact development of systemic disease and overall survival? Are local excision and early chemotherapy to treat microscopic disease preferable to a large operation because of the potential for immunosuppression associated with a more invasive procedure?

As with any other operative approach, surgical technique (and most likely surgeon volume and possibly hospital volume) plays a role. This is clear in total mesorectal excision (TME), and it seems reasonable to assume that it would be true for local excision approaches, whether TEM or transanal excision. This issue is at the heart of the dilemma in that surgeons often feel that their personal experience is not equal to that published in large series where technique and selection may be harder to define.

The authors give a nice description of transcoccygeal surgery. I have not had the opportunity to use this approach feeling the morbidity of a transsacral colcutaneous fistula outweighs the potential benefits. Selected patients with significant comorbidities and increasing operative risk might be candidates for this approach. My practice has been to proceed with an LAR or abdominoperineal resection (APR) instead of the transcoccygeal approach.

## QUALITY OF LIFE

Quality of life (QOL) is a much-understudied subject in the treatment of rectal cancer. We are just starting to accumulate

data to help us answer how best to treat these patients with a focus on long-term QOL issues. QOL impacts our decisions to perform lateral lymph node dissections, provide pelvic radiation therapy, create a colonic J-pouch, and pursue palliative procedures. The experience in North America with lateral pelvic node dissection, as highlighted by the authors, suggests that the complications associated with the procedure outweigh potential benefits. However, a true comparison of TME plus lateral pelvic node dissection versus TME plus pelvic irradiation in the treatment of patients with rectal cancer with a focus on local failure, overall survival, and QOL is lacking.

Pelvic radiation for the treatment of rectal cancer is standard of care for T3 or T4 lesions and Any T with nodal disease. However, there is clearly room to define the functional impact of radiation therapy on the function of the residual rectum. Many patients suffer frequent bowel movements after resection of the rectum with clustering of their movements (LAR syndrome). Radiation therapy negatively impacts the reservoir function of the rectum, leaving some to question the routine use of radiation after a well-performed TME.

Colonic J-pouches favorably impact the frequency of bowel movements in the first year. The pouch does not appear to be associated with significant long-term benefit and many patients have difficulty evacuating the pouches, leaving some to question the advisability of creating a pouch for short-term benefit. One note of caution, the authors state that they select either sigmoid or descending colon to create the pouch. In Western cultures the surgeon needs to be sure that the sigmoid is healthy and not involved with diverticular disease that would limit distensibility of the pouch.

Palliation of the primary rectal lesion in a patient with established distant disease is a challenging problem that is best approached with a multispecialty team, often a tumor board. We have chosen to be aggressive in our treatment of metastatic disease in the well-selected patient, believing the metastatic disease presents the biggest challenge to overall survival. In a patient with an asymptomatic primary, we have offered chemotherapy to treat the metastatic disease looking for a tumor response. In those patients where a response is seen, we may proceed with chemoradiation therapy of the primary if indicated by imaging studies. If the metastatic disease does not progress during this time interval, we may then proceed with resection of the primary with simultaneous resection of the metastatic disease, especially if we are able to achieve these goals laparoscopically with the assistance of an experienced laparoscopic liver surgeon. We may also proceed with resection of the primary alone or metastatic disease in staged procedures. We are ever vigilant regarding the primary tumor and local invasion of surrounding structures, believing the pain associated with local invasion a significant issue that we control poorly. If the primary appears to be encroaching on the sidewalls, we offer resection for palliation.

We have been aggressive, as have the authors, with locally advanced primary or recurrent disease believing posterior exenteration, pelvic exenteration, and exenteration including sacrectomy to be the best methods to control the tumor and associated symptoms in those with locally advanced disease.

Finally, whenever possible, we have preferred stenting of the primary rectal tumor in the patient with advanced metastatic disease to fecal diversion as it avoids a stoma and the morbidity of surgery with associated time loss due to hospitalization and recovery.

## TECHNIQUE

The description of TME is excellent, and the importance of this technique cannot be understated. Pathologic assessment of the specimen and evaluation of the adequacy of mesorectal excision has been shown to predict 5-year survival.<sup>17</sup>

I do not perform oral mechanical bowel preparation routinely, reserving that for cases in which I anticipate intraoperative colonoscopy might be necessary to localize a lesion. I provide one dose of ertapenem and no postoperative prophylactic antibiotics because no data support its use. Unless contraindicated, 5000 units of subcutaneous heparin and sequential compression stockings are used routinely. All vessels are taken with an electro-surgical device unless there is difficulty with hemorrhage. No drains are placed routinely as no data support this practice and increased complications are seen with routine usage.<sup>18,19</sup>

## POSTOPERATIVE CARE

*Postoperative care* is another arena in which major advances and challenges to the traditional dogma await young investigators. One example is “early refeeding.” Experience in laparoscopic surgery started to challenge our beliefs; 80–90% of patients tolerated liquids within 24 hours of laparoscopic procedures.<sup>20,21</sup> This practice was expanded to the open patient population. A meta-analysis found a statistically significant decrease in infection rates and lengths of stay and increased rates of vomiting.<sup>22</sup> A Cochrane review suggested that early refeeding is safe and may reduce post-operative complications.<sup>23</sup> We have practiced a patient-controlled diet for 18 years offering on postoperative day 1 a postsurgical diet (tea, coffee, chicken broth, toast, crackers, juice, English muffin, bagel). This is followed by a regular diet of choice (diabetic, etc.) emphasizing chicken, fish, rice, bread, pasta, and potatoes. The patient is encouraged to eat what sounds good and small meals (six per day) and avoid rich foods and foods that have “always made [them] sick.”

## REFERENCES

1. Edge SB, Byrd DR, Compton CC, Fritz AG, Green FL, Trotti A. *AJCC Staging Manual*. 7th ed. New York, NY: Springer; 2010.
2. Gunderson LL, Jessup JM, Sargent DJ, et al. Revised TN categorization for colon cancer based on national survival outcomes data. *J Clin Oncol*. 2009;28:264–271.
3. Guenaga KK, Matos D, Wille-Jørgensen P. Mechanical bowel preparation for elective colorectal surgery. *Cochrane Database Syst Rev*. 2009;(1):CD001544.

4. Pineda CE, Shelton AA, Hernandez-Boussard T, Morton JM, Welton ML. Mechanical bowel preparation in intestinal surgery: a meta-analysis and review of the literature. *J Gastrointest Surg.* 2008;12(11):2037–2044. [Epub 2008 Jul 12]
5. Zmora O, Wexner SD, Hajjar L, et al. Trends in preparation for colorectal surgery: survey of members of the American Society of Colon and Rectal Surgeons. *Am Surg.* 2003;69:150–154.
6. Dipiro JT, Cheung RP, Bowden TA, Jr, Mansberger JA. Single dose antibiotic prophylaxis of surgical wound infections. *Am J Surg.* 1986;152(5):552–559.
7. Song F, Glenny A. Antimicrobial prophylaxis in colorectal surgery: a systematic review of randomized controlled trials. *Br J Surg.* 1998;85:1232–1241.
8. Bratzler DW, Houck PM. Antimicrobial prophylaxis for surgery: an advisory statement from the National Surgical Infection Prevention Project. *Clin Infect Dis.* 2004;38:1706–1715.
9. Nelson RL, Glenny AM, Song F. Antimicrobial prophylaxis for colorectal surgery. *Cochrane Database Syst Rev.* 2009;1:CD001181.
10. Bratzler DW, Hunt DR. The surgical infection prevention and surgical care improvement projects: national initiative to improve outcomes for patients having surgery. *Clin Infect Dis.* 2006;43:322–330.
11. Fry DE. Surgical site infections and the surgical care improvement project (SCIP): evolution of national quality measures. *Surg Infect.* 2008;9:579–584.
12. You YN, Baxter NN, Steward A, et al. Is the increasing rate of local excision for stage I rectal cancer in the United States justified? A nationwide cohort study from the National Cancer Database. *Ann Surg.* 2007;245(7):726–733.
13. Ptok H, Marusch F, Meyer F, et al. Oncological outcome of local vs radical resection of low risk pT1 cancer. *Arch Surg.* 2007;142(7):649–656.
14. Garcia-Aguilar J, Mellgre A, Sirivongs P, et al. Local excision of rectal cancer without adjuvant therapy. *Ann Surg.* 2000;231(3):345–351.
15. Pary PH, Nash GM, Baron P, et al. Long-term results of local excision for rectal cancer. *Ann Surg.* 2002;236(4):522–530.
16. Varma MG, Rogers SJ, Schrock TR, Welton ML. Local excision of rectal carcinoma. *Arch Surg.* 1999;134(8):863–867.
17. Nagtegaal ID, van de Velde CJ, van der Worp E, Kapiteijn E, Quirke P, van Krieken JH. Macroscopic evaluation of rectal cancer resection specimens: clinical significance of the pathologist in quality control. *J Clin Oncol.* 2002;20(7):1729–1734.
18. Urbach DR, Kennedy ED, Cohen MM. Colon and rectal anastomoses do not require routine drainage: a systematic review and meta-analysis. *Ann Surg.* 1999;229(2):174–180.
19. Petrowsky H, Demartines N, Rousson V, Clavien PA. Evidence-based value of prophylactic drainage in gastrointestinal surgery: a systematic review and meta-analysis. *Ann Surg.* 2002;240(6):1074–1084.
20. Phillips Eh, Franklin M, Carroll BJ, et al. Laparoscopic colectomy. *Ann Surg.* 1992;216:703–707.
21. Jacobs M, Verdeja GD, Goldstein DS. Minimally invasive colon resection (laparoscopic colectomy). *Surg Laparosc Endosc.* 1991;1:144–150.
22. Lewis Sj, Egger M, Sylvester PA. Early enteric feeding versus nil by mouth after gastrointestinal surgery: systematic review and meta-analysis of controlled trials. *BMJ.* 2001;323:1–5.
23. Andersen HK, Lewis SJ, Thomas S. Early enteral nutrition within 24h of colorectal surgery versus later commencement of feeding for postoperative complications. *Cochrane Database Syst Rev.* 2009;CD004080.



# CANCER OF THE ANUS

Joshua I. S. Bleier • Najjia N. Mahmoud • Robert D. Fry

Cancers of the anus are rare problems with diverse histology. While squamous cell carcinoma (SCC) of the anal canal remains by far the most common of these neoplasms and the main focus of this chapter, the anus may also harbor tumors such as adenocarcinoma, melanoma, and basal cell carcinoma. The treatment of anal cancer has undergone dramatic changes in the past 30 years. Multimodality treatment consisting of radiation and chemotherapy has replaced abdominoperineal resection or wide local excision as the mainstay of therapy. Five-year survival rates now exceed 80% and radical surgery is reserved for cancers of the anal canal that do not respond to chemoradiation or that subsequently recur locally. Our understanding of the etiology and epidemiology of anal SCC and its precursor lesions has also profoundly changed in the past few decades, yielding new initiatives in both therapy and prevention that may further alter the future treatment of this disease. The importance of the surgeon's role in the detection and diagnosis of anal cancer remains undiminished. The surgeon is the clinician most likely to diagnose the disease, delegate treatment, and provide follow-up care. Anal cancer is clearly a disease that benefits from multidisciplinary intervention. Because of this, the treatment of anal cancer serves as a paradigm for the multimodality treatment of cancer.

## ANAL CANAL ANATOMY AND HISTOLOGY

The anal canal extends from the top of the anorectal ring (a palpable convergence of the internal sphincter, deep external sphincter, and puborectalis muscle) to the anal verge (the junction of the anal canal and the hair-bearing keratinized skin of the perineum). The lining of the anal canal is comprised of columnar cells, transitional epithelium, and non-hair bearing squamous epithelium. Tumors distal or beyond the verge have been historically been termed anal margin tumors (Fig. 42-1A).

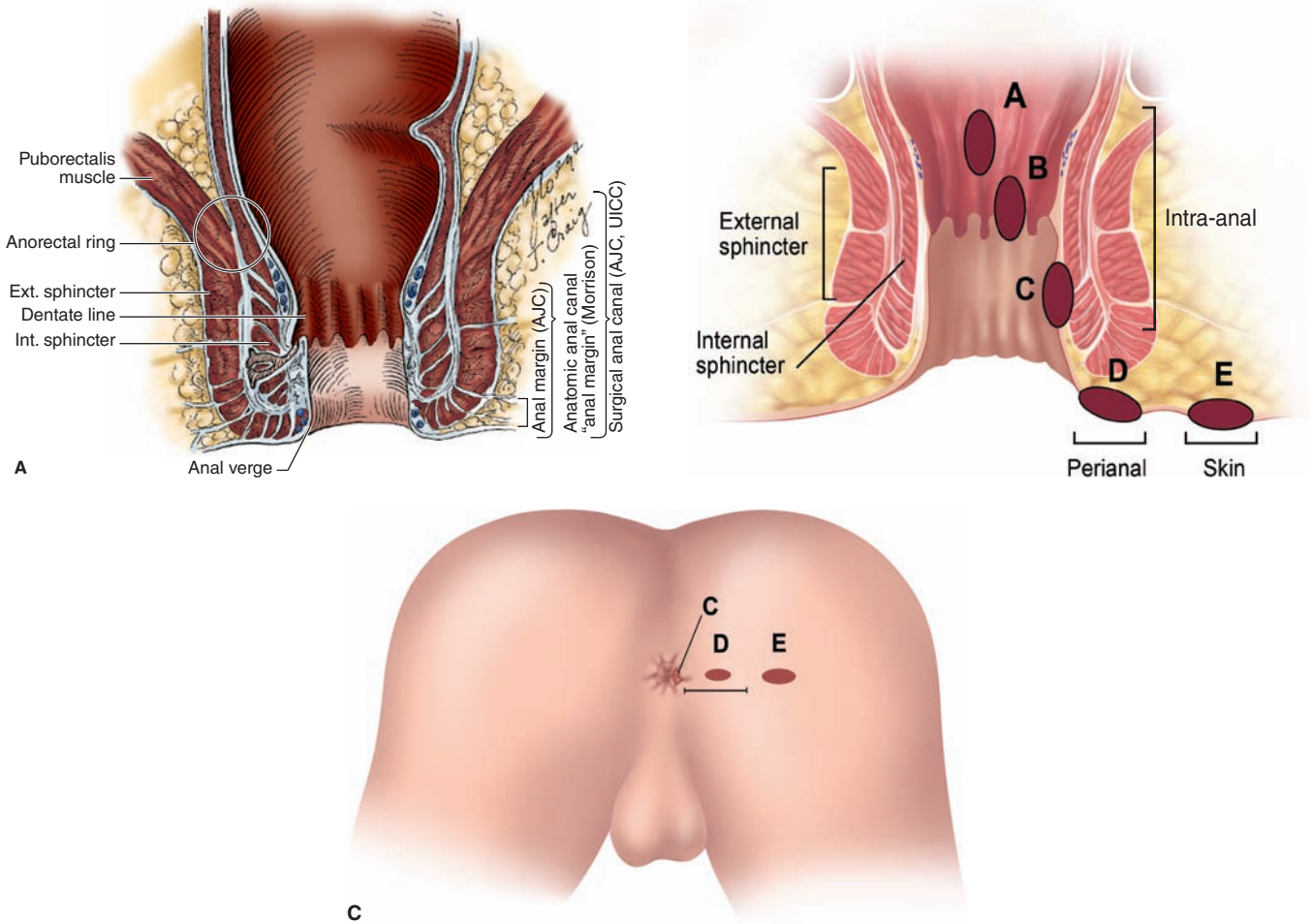
The anal transition zone, or transformation zone (ATZ) is a unique anatomic region, which has a variable histologic

makeup. It is a 1- to 2-cm region which begins at the dentate line and extends proximally. This zone, similar to the transformation zone of the cervix, contains a transitional epithelium containing columnar cells with variable amounts of squamous metaplasia. These metaplastic cells may be found as high as 6–10 cm proximal to the dentate line. This may, in part, explain the existence of rare “intra-anal” SCCs that have been found in the mid-low rectum. Tumors arising in the anal canal above and within the ATZ are typically nonkeratinizing SCCs. Those originating below this level are generally keratinizing.<sup>1</sup>

Because of the complex gross and histologic anatomy of this region, classification of anal neoplasms has been confusing and inconsistent. According to the World Health Organization (WHO) classification, anal canal lesions consist of squamous cell (cloacogenic) variants, including keratinizing, nonkeratinizing, and basaloid tumors. Other anal canal neoplasms include adenocarcinoma, carcinoid, lymphoma, and melanoma.<sup>2</sup> Anal margin tumors include SCC, giant condylooma (verrucous carcinoma), and basal cell carcinoma.<sup>2</sup>

A more current *clinical* classification scheme is more progressively in use which is more broadly understood by all practitioners who may treat patients with anal pathology.<sup>3</sup> This classification divides the area into three anatomic regions: intra-anal, perianal, and skin (Figs. 42-1B and C). Intra-anal lesions are contained fully within the anal canal and cannot be seen on external view. Lesions may be made partially visible with gentle distraction of the area. Perianal lesions are fully visible, and lie within a 5-cm radius of the anal opening. Skin lesions lie outside this 5-cm radius. Henceforth in this chapter, we will use the updated terms to refer to the location of these tumors.

The dentate line provides an anatomic reference point for lymphatic drainage of the anal canal and margin. Above the dentate line, drainage is primarily via the superior rectal lymphatics to the inferior mesenteric nodes and laterally along the middle and inferior rectal vessels to the internal iliac nodal basin. Lesions distal to the dentate line drain to the inguinal and femoral lymphatics. Tumors in the ATZ may follow both lymphatic routes. Patients with unexplained inguinal lymphadenopathy should undergo a careful examination of the anal canal.



**FIGURE 42-1** **A.** Anatomy of the anal canal and margin, classic description. Modern Classification system of anal cancers. **B.** Coronal section. *a-c:* intra-anal (anal canal) lesions. **C.** Perianal view. *d:* perianal (anal margin) lesion; *e:* skin lesions.

## ANAL SQUAMOUS CELL CARCINOMA

### Incidence and Epidemiology

In the last two decades of the twentieth century, the incidence of anal cancer nearly doubled; in the year 2000 approximately 3400 new cases were reported in the United States. During the ensuing 9 years, this figure has risen even faster—in 2009, it is estimated that there will be 5290 new cases, reflecting a trend that mirrors increases in human immunodeficiency virus (HIV) infection.<sup>4-7</sup> Although this number represents only 1–2% of all large bowel cancers, the rise in incidence underscores a significant and serious change in the epidemiology of the problem.<sup>5</sup> Squamous cell cancers of the anus are thought to have a viral etiology that is similar to that of cervical cancer. There is much evidence to suggest that high-risk sexual activity in the era of the HIV is responsible for the potentiation of the viruses that cause anal SCC and that the rise in incidence is directly linked to this phenomenon.

Until the past decade, the highest rates of anal SCC were described in women with numbers increasing after 30 years of age to plateau at an incidence of 5.0/100,000 after age 85.<sup>8</sup> The ratio of females to males affected was approximately 2:1.<sup>9</sup> However, in the past decade men under the age of 45 who have sex with men have constituted the group with both the greatest number of reported cases as well as the greatest increase in disease incidence. Currently in the United States, anal cancer occurs more frequently in males than in females.<sup>9</sup>

Considered as a group, men who practice anoreceptive intercourse have an incidence of anal SCC of 35/100,000—a rate identical to that of cervical cancer prior to routine cervical cytological screening.<sup>9</sup> Although not yet listed as an acquired immunodeficiency syndrome (AIDS)-defining illness like cervical cancer, an argument may be made that anal SCC should have similar emphasis. The United States AIDS-Cancer registry is a survey that linked AIDS-related cancer registries in 11 states or metropolitan areas for the period of time between 1995 and 1998 and included over 309,000 HIV-infected

patients.<sup>10</sup> The relative risk of SCC-type anogenital cancers in this population was much higher than that of the general population. The relative risks for cervical, vulvar or vaginal, and penile cancers were 5.4, 5.8, and 3.7, respectively, while the risk for anal cancer in women was 6.8 and for men 37.9.<sup>10</sup> Subset analysis of affected individuals revealed that those less than 30 years of age, compared to the healthy, HIV-negative, human papillomavirus- (HPV) negative population, had dramatically elevated relative risks of anal cancer of 134 for women and 162.7 for men. Analyzing the data by HIV exposure history showed that homosexual contact resulted in the highest relative risk of anal SCC, with other categories such as intravenous (IV) drug abuse, heterosexual contact among women, and blood transfusion somewhat less.<sup>11</sup>

## Etiology, Pathogenesis, and Risk Factors

### HUMAN PAPILLOMAVIRUS

HPV is a double-stranded papova DNA virus with a predilection for mucoepithelial tissues. More than 100 HPV strains have been identified, but only approximately 30 have been isolated in cancers of the anogenital region.<sup>12</sup> The majority of those exposed clear the virus, however, chronic HPV infection results in either anogenital warts (*condyloma acuminata*) or squamous intraepithelial lesions (SILs).<sup>12</sup> Condylomata are generally associated with HPV 6 and 11 and their subtypes and consist of fleshy growths that harbor and generate infectious viruses and have virtually no malignant potential.<sup>12</sup>

It is estimated that between 10 and 40% of HIV-positive males who have sex with males (MSM) will develop chronic infection with HPV strains with malignant potential. The most commonly isolated oncogenic HPV viruses are HPV 16, 18, 31, 33, and 35, which are strongly associated with invasive cancer and are commonly found in both anal and cervical cancer.<sup>13</sup> In a case-control study of 388 patients with anal cancer from Denmark and Sweden, 88% of anal cancers harbored HPV DNA.<sup>14</sup>

HPV infection is the most common sexually transmitted viral disease. Transmission is not prevented by safer-sex practices. These oncogenic viruses may lead to premalignant changes and uncontrolled cellular proliferation, via integration in host-cell genome and loss of cell-cycle regulation.<sup>15</sup>

### HUMAN IMMUNODEFICIENCY VIRUS INFECTION

There is an increased incidence of both anal SCC as well as its precursor lesion, high-grade squamous intraepithelial lesion (HSIL) in patients with HIV infection. Progression to high-grade dysplasia is accelerated in patients with a low CD4 count (<200).<sup>16</sup> Data collected in case-control studies among homosexual men and heterosexual women with high-risk behaviors show a direct correlation between HIV seropositivity, HPV prevalence, and anal cancer and its precursors. Anal

HPV infection is found in nearly 92% of HIV-positive MSM compared to 66% in HIV-negative MSM. Early epidemiologic evidence among homosexual men in the San Francisco Bay area documents a dramatic rise in anal SCC between 1973 and 1999, when the relative risk increased from 3.7 to 20.6.<sup>17</sup> Similar studies conducted in New York city between the years 1979 and 1985 show a 10-fold increase in anal SCC in men 20–49 years of age that coincided with the explosion of HIV in this population.<sup>18</sup>

Since the advent of highly active antiretroviral therapy (HAART), morbidity and mortality in the HIV population have decreased dramatically, both due to opportunistic infections and malignancies. Thus, it might be hypothesized that the incidence of HPV-related diseases and anal SCC would decrease in this group. However the opposite appears to be true; increasing incidence of anal cancer in the HIV-positive population in the HAART era have been shown by multiple groups. A report by Piketty et al using the French Hospital database on HIV<sup>19</sup> showed an increase in incidence, especially in the MSM population. In another recent publication, a Surveillance, Epidemiology and End Results (SEER)-based analysis showed that over the period from 1992 to 2003, anal cancer was the only malignancy increasing in incidence among HIV-positive individuals in the United States.<sup>20</sup>

However, HPV, HSIL, and anal cancer do not seem to be phenomena linked exclusively to homosexual men. Similar findings occur in HIV-infected male heterosexual IV drug users who deny anal-receptive sex. In this cohort, a high rate of HPV infection coincides with an elevated rate of HSIL as well as anal cancer.<sup>21</sup> Heterosexual women who are HIV-positive or have progressed to AIDS have high rates of HSIL as well.<sup>10</sup> When HIV-positive and HIV-negative cohorts (both male and female) with similar HPV risk factors are compared, the rates of both HSIL and anal cancer are dramatically increased in the HIV-positive groups.<sup>10,11,18,22</sup>

Although this trend includes both men and women with HIV, HIV-positive MSM is the highest risk group with an incidence of anal cancer higher than 78/100,000 person years.<sup>23</sup>

### SMOKING

Cigarette smoking is a well-known risk factor for anal SCC that is independent of sexual practices. The risk increases two- to fivefold over that of the general population.<sup>18,24</sup> It is speculated based on data demonstrating an increased incidence in premenopausal women of 5.6 with a 6.7% linear increase per pack-year, that smoking may have some antiestrogenic effect permissive for the disease in the estrogen-sensitive tissues of the anal canal.<sup>25</sup> This hypothesis is supported by the finding that no-risk increase was demonstrated by this study in either postmenopausal female or male smokers.

### CHRONIC INFLAMMATION

At one time, benign anorectal conditions such as hemorrhoids, fissures, and fistulas were thought to predispose to



the development of SCC. The etiology or common mechanism was presumed to be prolonged exposure of the anal epithelium to chronic inflammatory conditions. Patients with inflammatory bowel disease were believed to be at increased risk, particularly when anal fistulas were present. In 1994, Frisch examined this issue in a large population and found no evidence to support a causal relationship between benign anorectal conditions and anal cancer up to 13 years after resolution of the benign condition.<sup>26</sup> In another large population study, Frisch and Johansen identified 9602 Danish patients with a diagnosis of either Crohn's disease or ulcerative colitis with a mean follow-up of 10 years.<sup>27</sup> Only two patients developed anal SCC during this time. Both patients had the disease longer than 15 years. Although long-term irritable bowel disease patients may be at slightly increased risk of anal SCC, short- and mid-term risk is not significantly different from that of the general population.<sup>27</sup>

## Anal Intraepithelial Neoplasia or Squamous Intraepithelial Neoplasia

### DIAGNOSIS AND TREATMENT

Anal intraepithelial neoplasia (AIN) is widely believed to be the precursor lesion for SCC of the anus. The terms carcinoma in situ (CIS), Bowen's disease, AIN, anal dysplasia, and squamous intraepithelial lesion (SIL) have all been used to refer to the same spectrum of pathology; nomenclature varies by pathologist. There is a growing effort to make this pathological definition more uniform, and prognostically, lesions can be divided into normal, low-grade squamous epithelial lesions (LSILs), HSIL, and invasive cancer.<sup>3</sup> In the United States, the Bethesda criteria for anal intraepithelial lesions (AIN) lists two dominant categories—HSIL and LSIL.<sup>13</sup> In the European literature, HSIL is known as AIN 3, whereas LSIL consists of AIN 1 and 2.<sup>13</sup>

The incidence of anal cancer among HIV-positive homosexual men is 75–80/100,000 (a rate of 0.8/100,000 in the general population), more than twice the incidence of cervical cancer in women (35/100,000) prior to the introduction of routine cervical Pap smear cytology evaluations.<sup>10,17</sup> Because of the dramatic reduction in cervical cancer (8/100,000 currently) attributed to the detection of dysplasia, it is widely believed that the same result could be seen in high-risk anal cancer populations if similar detection and ablation methods are used.

Previously, wide local excision had been the treatment of choice for HSIL (Bowen's disease). It was assumed, based on anecdotal evidence that a percentage of patients with HSIL progresses to invasive cancer. This led to attempts to surgically clear patients of the disease.

A 1999 survey of the practice patterns of members of the American Society of Colon and Rectal Surgeons revealed that 86–95% of surgeons treated HSIL with wide local excision.<sup>28</sup> A distinction was made between microscopic disease and other manifestations. Most HSIL found incidentally in hemorrhoidectomy specimens were considered

microscopic asymptomatic disease and simply followed without re-excision (74%).<sup>28</sup> This survey coincided with other investigations highlighting the multifocal nature of HSIL and the difficulty presented by wide local excision under these circumstances. In one review of 34 patients undergoing wide local excision for macroscopically evident HSIL, 19 had positive margins at the time of initial resection, and 12 of the 19 had recurrent HSIL within 1 year.<sup>29</sup> Even with a microscopically complete initial resection, 2 of 15 patients eventually developed HSIL. Although none of these individuals subsequently developed anal cancer, five developed significant surgical complications of resection including anal stenosis and incontinence.<sup>29</sup>

More structured techniques using mapping biopsies, intraoperative frozen section and selective wide-local excision yielded excellent results and long-term control, however recurrent disease still occurred.<sup>30</sup>

The true incidence of HSIL and its resultant progression to invasive SCC are not clearly known, however the rapid increase in incidence of SIL and anal SCC in clearly high-risk populations, combined with the potential morbidity of a radical surgical approach have led many to adopt a policy of either very specific ablative therapy or close and frequent observation.

Anal screening (Pap smear) was first described in the 1990s as a direct corollary of the cervical Pap smear, and has since been promoted as a diagnostic and screening tool in high-risk populations.<sup>31</sup> However, evidence demonstrating a resulting decrease in the incidence of anal cancer similar to that of cervical cancer has not been forthcoming. Still, only a very short time has passed since the institution of the technique. The use of anal cytology as a screening technique has not gained the recognition afforded cervical Pap smears. Lack of recognition by clinicians of the increased incidence of anal cancer, limitation of the problem to high-risk populations, lack of knowledge of techniques, cost, and a dearth of supporting outcomes data may all conspire to limit the use of the technique. Ongoing outcome studies may clarify the role of anal Pap smear for high-risk patients.

In the early 1990s high-resolution anoscopy (HRA) was developed at the University of California, San Francisco (UCSF). Like anal Pap cytologies, HRA is a direct application of the technology for cervical intraepithelial detection and ablation to anal dysplasia. The technique can be done in either the office, or for more extensive disease, in the operating room.

After obtaining a Pap smear, a digital rectal examination is performed followed by placement of a cotton swab covered in gauze soaked in 3% acetic acid. The swab is held in place for 1 minute after which an anoscope is inserted, permitting examination of the anal canal by a colposcope providing 6- to 25-times magnification. Special attention is directed to the area surrounding the ATZ. Applying acetic acid causes these often unapparent lesions to become opaque or "acetowhite." Lugol's iodine solution is then placed in the anal canal to further highlight these areas. HSILs fail to take up Lugol's, rendering the area yellow to tan, whereas normal tissue or

LSILs stain dark brown or black.<sup>31</sup> This approach, combined with the magnification, allows visualization of vascular changes such as punctate appearance, mosaicism, and atypical vessels characteristic of dysplastic change.<sup>31</sup> Suspicious lesions are then destroyed by electrocautery.

Pineda et al published a retrospective review of 246 patients being treated for HSIL with HRA and targeted ablation over a 10-year period. In this group, 81% of patients had extensive, or circumferential lesions, and 79% were immunocompromised due to HIV. Recurrent HSIL occurred after ablation in 57% at an average of 19 months of follow-up, but only 25% of those patients required surgery. In this high-risk group, under careful surveillance, 1.2% of patients progressed to invasive cancer.<sup>32</sup> This series represent the largest report of patients followed with HRA and targeted surgical ablation. It is especially notable for a much lower rate of progression to invasive cancers compared to other studies detailing expectant management *without* the use of HRA surveillance, where progression to invasive cancer ranges from 8.5 to 13%.<sup>33,34</sup>

HRA may provide objective evidence of the presence of disease that office examination alone does not. Whether ablative therapies should follow documentation of HSIL by any method remains unknown and controversial. There have been no randomized controlled trials to date which can clearly characterize the appropriate approach for this group. Slow progression from HSIL to invasive cancer, heterogeneity in follow-up, and lack of broad expertise in surveillance techniques make these studies impractical to perform. Nevertheless, it is clear that special attention needs to be paid to these highest-risk groups.

## HUMAN PAPILLOMAVIRUS VACCINES

Both prophylactic and therapeutic vaccines to HPV have completed Phase III trials targeting cervical cancer, testing both types of vaccine in high-risk populations.<sup>13,35</sup> Prophylactic or preventive vaccines are typically made from structural viral proteins, while therapeutic vaccines are made from the early viral replication proteins E6 and E7. In 2006, the Food and Drug Administration (FDA) granted approval to the first vaccine designed to prevent cervical cancer. Gardasil (Merck & Co., Inc, Whitehouse Station, NJ) is a recombinant vaccine against HPV types 6, 11, 16, and 18. It is currently approved for use in females, 9–26 years of age and requires a series of three injections over a 6-month period. A total of 21,000 patients in four randomized trials demonstrated a dramatic, nearly 100% prevention rate in genital warts, and vulvar, vaginal, and cervical precancerous lesions caused by the serotypes against which the vaccine is directed. The vaccine is only effective, however, in patients not previously exposed to the viruses included in the vaccine, and it confers no protection against viruses not covered by the vaccine. Scattered reports of adverse side effects to Gardasil have been reported, including syncope, headache, and anaphylaxis raising some concern regarding its use. However, the significance of these events is yet to be determined.

A recent double-blind placebo-controlled randomized clinical trial (RCT) involving over 4000 HPV genotype-naïve males showed that the quadrivalent vaccine was 86% effective in preventing persistent HPV infection, and 90% effective against genotype-specific condyloma.<sup>35</sup> Although the potential usefulness of this vaccine can be extrapolated, further studies in high-risk population will be needed to determine efficacy and effects on SIL and cancer prevention.

Cervarix (GSK) is a bivalent vaccine targeted against HPV 16 and 18. It has been licensed for use in females as young as 10 years of age. No registration for treatment indications in males has been sought.<sup>35</sup>

Other studies have combined aerosolized delivery mechanisms with intramuscular injections to maximize antibody titers against the virus. Although the practicality of prevention of dysplasia and cancer by vaccines is unclear at this time, results from these studies may clarify the situation in the near future.

Stressgen Biotechnologies, Inc. has developed a therapeutic vaccine for anal HSIL that has completed Phase II clinical trials in HIV-negative patients.<sup>13</sup> The vaccine is a recombinant fusion protein called HspE7. The immune response generated by the vaccine seems to be CD8 dependent alone—CD4 cells do not seem to be involved. Of those patients receiving 500 µg doses, 76% showed regression of their HSIL to LSIL, one of the primary endpoints of the study. Approximately 7 months elapsed before the first complete responses began to appear. Even so, results seem durable with 86% of this group remaining in remission at 15 months. Although the study samples are small and this approach has yet to be validated in HIV-positive immunocompromised patients, early evidence supports an optimistic outlook for the field of HPV therapeutic vaccines.<sup>13</sup>

## Pathology, Diagnosis, and Staging of Anal Squamous Cell Cancer

### PATHOLOGY

Nearly 80% of anal canal tumors are either SCCs or histologic variants of SCC. The great variation in terminology results from the histologically diverse microscopic anatomy and the fact that many tumors, especially in the anal transition zone, have a mixed histologic appearance, including squamous, basaloid, and rarely glandular elements. The WHO designates all squamous carcinoma variants in this location as “cloacogenic.”<sup>2</sup> Tumors of the distal anal canal (anal), and particularly of the anal margin (perianal), are generally comprised predominantly of squamous cells, with fewer basaloid and no glandular characteristics.<sup>36</sup> The more distal in the anal canal the squamous tumor arises, generally the more likely it is to contain keratinizing cells. Tumors of the proximal anal canal and ATZ are usually composed of nonkeratinizing cells.<sup>36</sup> It is important to note that the difference in the cellular characteristics of these anal canal cancers does not result in a different mode of treatment. There are

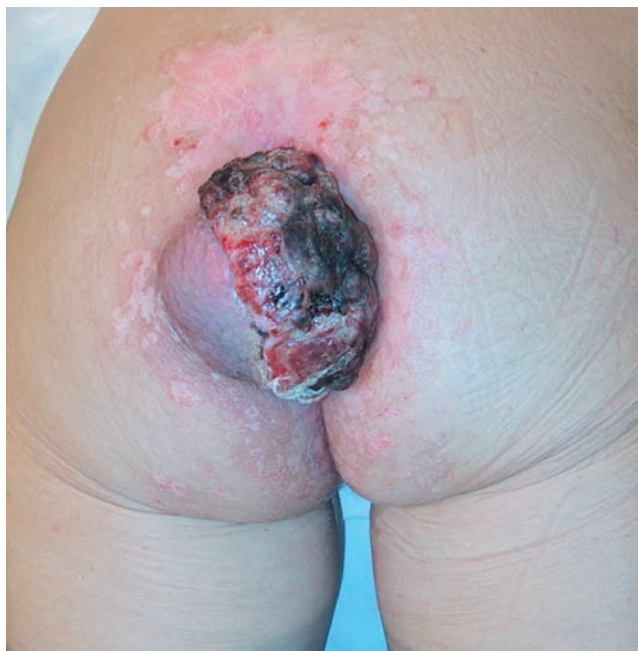no data to suggest differences in outcome between squamous and basaloid histologic types in anal canal cancers. Perianal (anal margin) tumors, however, are typically treated like skin cancers, by local excision.

The treatment of anal cancer has undergone major changes within the past 30 years. Currently chemotherapy and radiation are usually the sole treatment for patients with this disease. Prior to 1974, the standard of care was either wide local excision if the tumor was judged to be superficial, or abdominoperineal resection (APR) for tumors invading the sphincter. Outcomes were poor, with overall survival rates after APR ranging from 30–70%, depending on tumor grade, stage, and size.<sup>8</sup> The local recurrence rate after wide resection or APR was reported to be 25–35% with a 100% local recurrence rate for tumors invading through the submucosa in a series from Singh and associates at Roswell Park Memorial Institute.<sup>37</sup> Perineal or pelvic recurrence occurs in 50–70% of patients undergoing APR, with less than 10% dying of distant disseminated disease.<sup>9</sup> In 1974, Norman Nigro at Wayne State University used radiation and fluoropyrimidines in anal canal cancer as a way to reduce local recurrence following APR.<sup>38</sup> He observed that often there was no residual cancer in the resected specimen. Thus began an exciting and revolutionary time in the treatment of this disease that resulted in a radical shift in treatment.

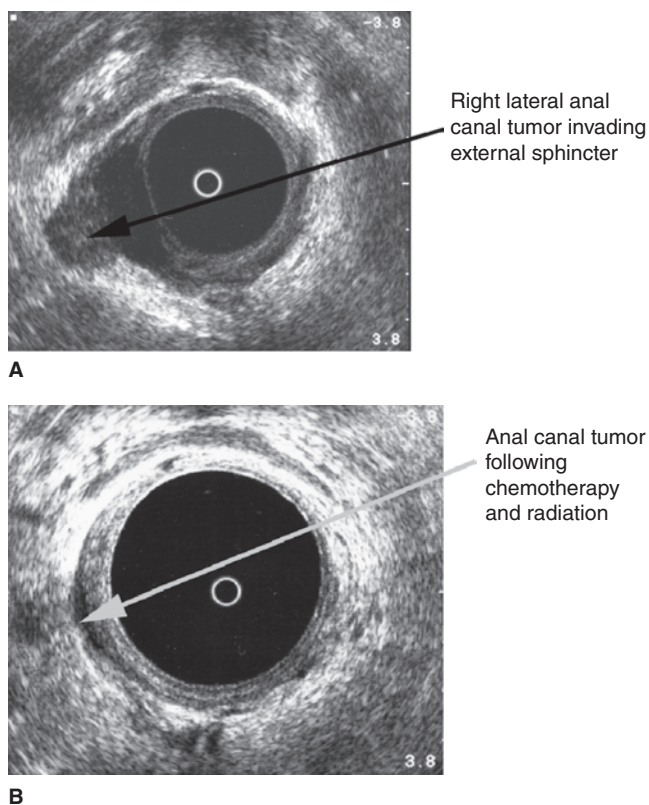
## DIAGNOSIS AND STAGING

Over 50% of patients present with a complaint of rectal bleeding. Delays in diagnosis are common because the tumor is often mistaken by both patients and physicians for benign conditions such as hemorrhoids or fissures (Fig. 42-2). Pain, tenesmus, and pruritus may be present. The initial physical examination should include a digital rectal examination, proctoscopy, and inspection of the inguinal lymph nodes. A biopsy of the anal mass is necessary to confirm the diagnosis. Inguinal masses should be aspirated with a fine needle for diagnosis and staging. Because the current nonoperative approach to anal cancer management is highly effective, excisional biopsy of suspected anal SCCs and inguinal node dissection for adenopathy should generally be avoided. The staging process includes CT of the chest, abdomen, and pelvis, and a transanal ultrasound to assess depth of invasion and aid in establishing the size of the tumor (Figs. 42-3A and B). In addition, the use of positron emission tomography (PET)/CT is becoming more standard in the pretreatment staging. This allows for anatomic and metabolic correlation of primary tumor as well as sensitive assessment for inguinal or distant nodal metastases. Importantly, post-therapy response to PET is predictive of long-term outcomes.<sup>39</sup>

The IUCC staging system for anal cancer was updated in 1997 and adopted by the AJCC<sup>7</sup> (Table 42-1). In contrast to staging parameters for other gastrointestinal (GI) lesions, it is based on size rather than depth of invasion. Anal margin tumors are staged and treated the same as skin cancers (Fig. 42-4).



**FIGURE 42-2** Large, fungating anal squamous cell carcinoma (SCC). (Used, with permission, from Charles Friel, MD.)



**FIGURE 42-3** **A.** Endoanal ultrasound of a squamous cell carcinoma (SCC) of the anal canal invading the anal sphincters prior to chemoradiation. **B.** The patient shown 4 months after 4500 Gy radiation, cisplatin, and 5-fluorouracil. The patient has had a complete clinical response to therapy.



**TABLE 42-1: AJCC STAGING SYSTEM FOR ANAL (CANAL) CARCINOMA**

### Primary Tumor (T)

- TX: Primary tumor cannot be assessed  
 T0: No evidence of primary tumor  
 Tis: Carcinoma in situ  
 T1: Tumor 2 cm or less in greatest dimension  
 T2: Tumor more than 2 cm but no more than 5 cm in greatest dimension  
 T3: Tumor more than 5 cm in greatest dimension  
 T4: Tumor of any size that invades adjacent organ(s) (eg, vagina, urethra, or bladder<sup>a</sup>)

### Regional Lymph Nodes (N)

- NX: Regional lymph nodes cannot be assessed  
 N0: No regional lymph node metastasis  
 N1: Metastasis in perirectal lymph node(s)  
 N2: Metastasis in unilateral internal iliac and/or inguinal lymph node(s)  
 N3: Metastasis in perirectal and inguinal lymph nodes and/or bilateral internal iliac and/or inguinal lymph nodes

### Distant Metastasis (M)

- MX: Distant metastasis cannot be assessed  
 M0: No distant metastasis  
 M1: Distant metastasis

### Stage Groupings

- Stage 0:  
 Tis, N0, M0  
 Stage I:  
 T1, N0, M0  
 Stage II:  
 T2, N0, M0  
 T3, N0, M0  
 Stage IIIA:  
 T1, N1, M0  
 T2, N1, M0  
 T3, N1, M0  
 T4, N0, M0  
 Stage IIIB:  
 T4, N1, M0  
 Any T, N2, M0  
 Any T, N3, M0  
 Stage IV:  
 Any T, any N, M1

<sup>a</sup>Direct invasion of the rectal wall, perirectal skin, subcutaneous tissue, or the sphincter muscle(s) is not classified as T4.

Adapted, with permission, from American Joint Committee on Cancer. *AJCC Cancer Staging Manual*. 6th ed. New York, NY: Springer; 2002:125–130.

A number of reviews in the literature prior to and during the introduction of chemoradiotherapy for anal SCC document the strong correlation between tumor size, lymphatic spread, and prognosis.<sup>40</sup> In a 1984 report from the M.D. Anderson Cancer Center, 132 patients treated by APR for anal SCC were studied. For patients with tumors 1–2 cm

in size, survival was 78%; 3- to 5-cm tumors had survival of 55%; and patients with tumors greater than 6 cm experienced survival of only 40%.<sup>40</sup> Other reviews suggest that survival for large tumors is considerably worse, at less than 20%, and that generally overall survival is diminished when tumor size is greater than 5 cm, whether the tumor is treated by excision or chemoradiotherapy.<sup>41–44</sup> Recently, analysis of the completed Radiation Treatment Oncology Group (RTOG) 98-11, which represents the largest prospective trial database showed that pretreatment tumor size greater than 5 cm predicted colostomy requirement.<sup>45</sup>

The presence of regional nodal metastases is a poor prognostic indicator regardless of treatment modality. Although survival in the face of nodal metastases has improved significantly with the use of chemoradiation, patients who present with metastatic disease have a significant survival disadvantage.<sup>40,41</sup> Prior to the routine use of chemoradiotherapy, a report in which surgery was done with and without preoperative radiation demonstrated a 5-year survival rate of 44% for node-positive patients compared to 74% for node-negative patients.<sup>40</sup> Other studies confirm comparatively poor survival for patients with nodal metastases.<sup>41</sup>

## Surgical Management

Operative therapy for anal SCC has largely been supplanted by chemoradiation and is now the exception rather than the rule. Historically, the failure rate for APR has depended rather predictably on the size of the primary tumor. This procedure was often accompanied by prophylactic inguinal node dissection, but the morbidity and lack of efficacy caused inguinal lymphadenectomy to be abandoned. Failure rates for APR range from 40 to 70%, with local failure rates of 40% and median survival time after recurrence of only 1 year.<sup>8</sup>

Although chemotherapy and radiation have been shown to result in higher disease-free survival rates, when chemoradiotherapy is refused or contraindicated, there may still be a role for local excision in some cases of anal canal carcinoma. A retrospective analysis of local excision at the University of Minnesota revealed a direct correlation between survival and tumor size. For tumors greater than 2.5 cm, 5-year survival rates were 60%.<sup>46</sup> Although the sample size was small, the authors advocated local resection with curative intent for small (<1 cm) well-differentiated tumors confined to the submucosa.<sup>46</sup> Corman and Haggitt reported a similar experience, with all tumors confined to the submucosa being cured by local excision or APR, and those invading more deeply suffering eventual local recurrence.<sup>47</sup> Longo and colleagues recorded a 62% failure rate in stage I–III tumors undergoing solely local excision, in which all patients with stage II and III tumors recurred.<sup>48</sup> Tumor accessibility, full-thickness excision, depth of invasion, and negative margins seem imperative technical considerations when considering local resection. Even so, very few candidates are suitable for this approach.

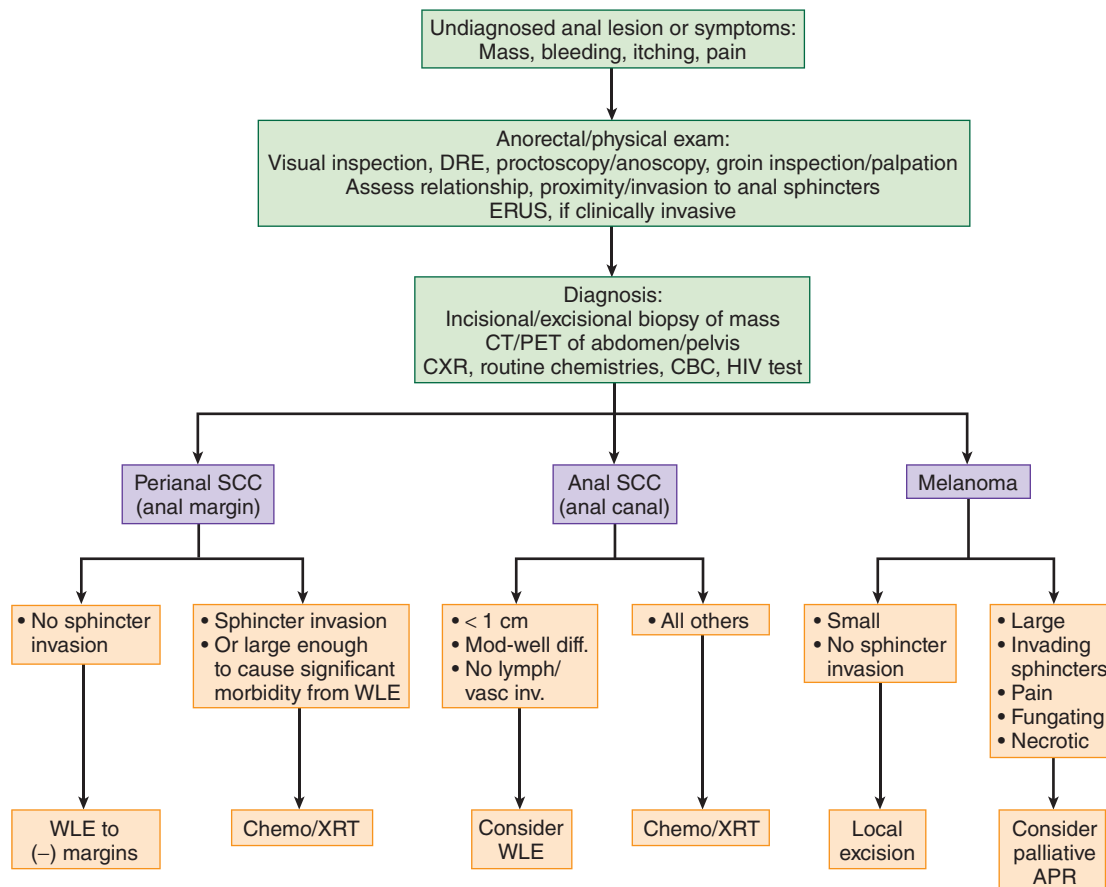


FIGURE 42-4 Basic treatment algorithm for most common anal neoplasms.

## Chemoradiation

The treatment of anal (canal) carcinoma has changed radically since the late 1970s, with the advent of chemoradiation protocols. In 1974 Norman Nigro defined a treatment protocol involving the administration of 5-fluorouracil (5-FU), mitomycin-C, and preoperative radiation to shrink anal canal tumors.<sup>38</sup> Fluoropyrimidines were known at the time to enhance the effect of radiation, and there was some evidence that mitomycin had an antineoplastic effect on squamous cell tumors. Nigro's protocol was neoadjuvant, and the radiation (30 Gy total) was given in 15 sessions over a 3-week period. The 5-FU was administered at a dose of 1000 mg/m<sup>2</sup>/d, for 4 days starting on the first day of radiation therapy, as a continuous infusion. It was then repeated on days 29 through 32. Mitomycin-C (15 mg/m<sup>2</sup>) was administered as a single dose on treatment day one.<sup>38</sup> Of the three patients in the initial report, two underwent APR 6 weeks after treatment. The third refused surgery and remained disease-free. No evidence of tumor was found in the specimens of the two patients who underwent surgery.<sup>38</sup>

Following the dramatic results reported by Nigro's group, others followed suit, treating patients with both radiation alone and with multimodality therapy followed by surgical

excision. In 1983, Michaelson and associates at Memorial Sloan-Kettering Cancer Center (MSKCC) reported that 52% of patients treated with both chemotherapy and radiation had a complete pathological response, and another 22% had only microscopic disease at operation.<sup>49</sup> All of these patients had undergone APR or wide local excision following treatment. After Nigro's 1974 publication, a number of other investigators examined the effects of multimodality therapy. Most used 5-FU and mitomycin-C as the chemotherapeutic regimen, although several made dose and infusion modifications, and nearly all increased the radiation dose. Maximal doses were in the range of 50 Gy. Because of such variability among therapies, meta-analysis is difficult. However, direct comparison between studies is useful.<sup>38</sup>

Preliminary studies done by Nigro and others set the stage for prospective Phase II studies. Among these, Martenson and colleagues reported on an Eastern Cooperative Oncology Group (ECOG) study of 50 patients receiving 40 Gy of radiation with a 10–13 Gy boost to the tumor.<sup>50</sup> Bolus 5-FU and mitomycin-C was given during radiation, and biopsy of the tumor or tumor site was performed 6–8 weeks later. APR was performed if the biopsy was positive. Of 46 patients completing treatment, 34 (74%) had a complete response and 11 had a partial response.<sup>50</sup> Eighty

**TABLE 42-2: RANDOMIZED PHASE III TRIALS OF RADIATION AND CHEMOTHERAPY FOR ANAL (CANAL) CANCER**

	Study Arms	Radiation Dose	Chemotherapy	Number of Eligible Patients	Stoma-Free Survival	Local Failure Rate	Overall Survival
EORTC <sup>50</sup>	Radiation alone	45 Gy + 15–20 Gy boost if CR/PR	None	103	22%	69%	56%
	Radiation + 5-FU/Mit-C	45 Gy + 15–20 Gy boost if CR/PR	5-FU, Mit-C	103	41% ( $p = .002$ )	42% ( $p = .02$ )	56% NSS
UKCCCR <sup>49</sup>	Radiation alone	45 Gy + 15–20 Gy boost if CR/PR	None	285	N/A	59%	58% (3 y)
		45 Gy + 15–20 Gy boost if CR/PR	5-FU, Mit-C	145	59%	36% ( $p < .0001$ )	65% (3 y) NSS
		45 Gy	5-FU	145	59%	36%	67%
RTOG/ECOG <sup>51</sup>	Radiation + 5-FU	45 Gy	5-FU	145	59%	36%	67%
	Radiation + 5-FU/Mit-C	45 Gy	5-FU, Mit-C	146	71% ( $p = .0019$ )	18% ( $p = .0001$ )	76% ( $p = .18$ )

CR/PR, complete response or partial response; 5-FU, 5-fluorouracil; Mit-C, mitomycin-C; NSS, not statistically significant; N/A, not available. Modified, with permission, from Chawla AK, Willett CG. Squamous cell carcinoma of the anal canal and anal margin. *Hematol Oncol Clin North Am.* 2001;15:321–344.

percent had no locoregional recurrence and 58% were disease-free at 7 years.<sup>50</sup>

The RTOG and ECOG reported on an intergroup trial of 79 patients treated with combined radiation and chemotherapy in 1989. The radiation dose was 40.8 Gy and only 8 patients had evidence of disease requiring APR at the completion of therapy. At 3 years, overall survival and local control rates were 73% and 71%, respectively.<sup>51</sup>

Further series from MSKCC supported the ECOG and intergroup study. Forty-two patients were treated with a total dose of 30 Gy and the 5-FU/mitomycin-C combination.<sup>52</sup> Eighteen patients had positive biopsy results after treatment but only half of these had local recurrence on follow-up. The 5 year disease-free survival rate was 82%.<sup>52</sup>

In all of these small Phase II trials, disease-free survival, colostomy-free survival, and local disease control compared very favorably to the standard surgical approach. However, the toxicities encountered were significant. In the ECOG study, 37% of patients suffered severe toxicities including severe neutropenia, moist desquamation of the perianal skin, and diarrhea.<sup>50</sup> Treatment toxicities like these gave rise to questions regarding the necessity of chemotherapy in anal cancer in spite of its early promise. Concurrent studies examined the role of radiation alone, often in doses substantially higher than those used with chemotherapy. At the Institute Curie, 183 patients receiving a dose between 60 and 65 Gy showed a 59% 5-year survival rate with a local control rate of 69%.<sup>53</sup> A similar 5-year survival rate of 61% was demonstrated in a review of 147 patients from the Hospital Tenon.<sup>43</sup> Local control in this study was 71%. Complications of higher-dose radiation included anal ulceration and stenosis requiring surgery in 5–15% of cases.

In the late 1990s three Phase III trials reported direct comparisons between radiation alone and radiation with concurrent chemotherapy (Table 42-2). In 1996, the United Kingdom Coordinating Committee on Cancer Research (UKCCCR) published the largest prospective randomized study of chemotherapy and radiation versus radiation alone.<sup>54</sup> The trial enrolled 585 patients, assigning them to either combined therapy or radiation, and then assessed them at 6 weeks. Poor responders were offered APR while those responding well received boost radiotherapy and reassessment. Those patients receiving only radiation had a local failure rate of 59%, whereas those with multimodality therapy recorded a 36% local failure rate with a mean follow-up time of 42 months. Although the early morbidity of combination therapy was higher than that with radiation alone (including two deaths from sepsis), the late morbidity rate was the same. Both the local failure rate as well as the number of patients requiring salvage surgery was halved compared to radiation alone. In all, 29/174 patients who had received combined therapy with a boost required salvage APR, compared to 72/188 who had received radiation alone. Although the local failure rate for radiation alone was higher, overall survival between the groups was not statistically significant (58% radiation vs 65% chemoradiation at 3 years).<sup>54</sup>

The results of the European Organization for Research and Treatment of Cancer (EORTC) supported those of the UKCCCR trial.<sup>55</sup> Patients with locally advanced (T3–T4) cancers were randomized to radiation alone (45 Gy plus a boost of 15–20 Gy) versus combination therapy with 5-FU/mitomycin-C. With the addition of chemotherapy, the local failure rate dropped from 69% to 42% and colostomy-free



survival increased from 22% to 41%. Early and late complication rates were similar except for anal ulcers, which were slightly increased in the combined group. As in the UKCCCR trial, although local control and colostomy-free survival rates were much improved over that of radiation alone, the rate of distant spread was unchanged. Overall survival between the two groups in this study was 56% at 5 years.<sup>55</sup>

In 1996, Flam and colleagues explored further the role of mitomycin-C as a radiation sensitizing agent in a phase III RTOG/ECOG trial.<sup>56</sup> Three hundred ten patients were enrolled and randomized to receive either radiation/5-FU or radiation/5-FU and mitomycin-C. They concluded that although the addition of mitomycin-C produced slightly greater toxicity, at 4 years the disease-free survival was higher (73% vs 51%;  $p = .0003$ ) and the colostomy rate was lower (9% vs 22%;  $p = .002$ ). While the 5-FU/mitomycin-C/radiation group had a good overall survival of 76%, this was not statistically different from that of the comparison group at 67% ( $p = .18$ ). However, the role of mitomycin-C was validated.<sup>56</sup>

The RTOG/ECOG study also examined the ability to salvage patients with residual cancer in their post-treatment biopsy with additional chemotherapy and radiation. Of the 24 patients on the trial eligible to undergo salvage, 12 were rendered free of disease with a 9-Gy boost, 5-FU, and cisplatin (100 mg/m<sup>2</sup>).<sup>56</sup> It has been suggested that the patients who underwent salvage chemoradiotherapy in this trial may have been free of disease secondary to radiation-induced apoptosis if the period prior to biopsy had been extended. It is unclear whether cisplatin was actually responsible for the results, but interest in the agent was sparked, given the treatment-limiting toxicities of mitomycin-C. Cisplatin is well known as a radiation sensitizer and effective agent in the treatment of SCC in other areas such as cervix, head and neck, and esophagus. There have been two Phase II trials of high-dose radiation and 5-FU in combination with cisplatin for anal canal cancer. These studies showed complete response rates of 70–95% with reduced toxicity compared to mitomycin-C.<sup>50,57</sup>

RTOG 98-11 was a Phase III study designed to directly compare the efficacy of cisplatin-based therapy to the standard mitomycin-based regimen, in the setting of large SCC primaries (T2 or larger), a group known to have decreased response to chemoradiotherapy. The authors hypothesized that induction chemotherapy with fluorouracil and cisplatin would shrink the primary tumor, and render subsequent concurrent chemoradiotherapy more effective. Primary outcome measure was 5-year disease-free survival, while secondary end points were overall survival, time to relapse, and colostomy rate. After a median follow-up of 2.51 years, as compared to standard (mitomycin) therapy, the cisplatin group showed decreased 5-year disease-free survival (54 vs 60%), worse 5-year overall-survival (70 vs 75%), higher 5-year local recurrence and distant metastasis rates (33 and 19% vs 25 and 15%), respectively. Colostomy rates were *significantly* better in the mitomycin group (10 vs 19%,  $p = .02$ ).<sup>58</sup>

Based on these data, the authors conclude that cisplatin-based therapy failed to achieve improved disease-free survival compared to a standard mitomycin-based regimen, and in fact, worsened colostomy rates.<sup>58</sup> Currently, at the University of Pennsylvania, a mitomycin-based regimen, without induction, is the standard treatment.

Treatment for anal cancer does not differ in the HIV-positive population. Combined chemotherapy and radiation is the best approach to this disease in the setting of HIV/AIDS. Studies have consistently documented responses to standard therapy that equal those in the HIV-negative population.<sup>10,17</sup>

Thus, for any stage of invasive SCC of the anal canal, the primary mode of treatment should be chemoradiotherapy with a 5-FU/mitomycin-based regimen and external beam radiotherapy. Surgery is reserved for in situ (wide local excision), residual or recurrent disease (APR).

## Newer Modalities for Radiotherapy

The above series of randomized trials firmly established concurrent chemoradiotherapy with 5-FU and mitomycin-C as standard of care for anal cancer. This approach has resulted in very effective disease control (5-year overall survival 50–61% and 5-year colostomy-free survival from 76 to 78%).<sup>54–56,58</sup> The tradeoff, however is that this sphincter-sparing approach has significant toxicity. The EORTC trial and UKCCCR trial reported significant acute dermatologic toxicity on 49–76% of patients, and acute GI toxicity in 33–45%.<sup>54,55</sup>

The technique of intensity-modulated radiation therapy (IMRT) is a new way to plan and deliver conformal radiation. Using advanced imaging and computer-guided techniques, radiation dosage can be delivered with higher accuracy to target tissue while sparing normal nearby tissues. A multicenter US group conducted a prospective cohort study using concurrent 5-FU/mitomycin C and IMRT techniques on 53 patients with SCC of the anus.<sup>59</sup> Outcomes showed a favorable toxicity profile when compared with classic controls, as exemplified by the outcomes of the RTOG 98-11 (Table 42-3).<sup>58</sup> There was decreased dermatologic toxicity (grade 3, 38 vs 78%, and no grade 4), and fewer patients needed breaks in treatment; in addition 57% of patients requiring breaks left for less than or equal to 4 days of treatment. GI toxicity was similarly decreased with only 15.1% experiencing grade 3 toxicity compared to 34% in the RTOG trial.<sup>58</sup>

Cancer response rates were similar in this study compared to controls; there was a 92.5% complete response (CR), with failures associated with advanced stage, although not statistically so. Survival rates were also comparable, with 18-month colostomy-free survival, and overall survival at 83.7 and 93.4%, respectively.

Further randomized trials need to be conducted to validate standard concurrent chemoradiotherapy with IMRT techniques; however at the University of Pennsylvania we use conformal radiation techniques as standard therapy.



TABLE 42-3: RECENT TRIALS OF CHEMORADIATION FOR ANAL (CANAL) CANCER

Study	N	Stage	Follow-Up (Months)	Chemotherapy	Radiation	CR	Stoma-free Survival	Local Control	Survival
Klass 1999 <sup>46</sup>	12	T1–4	48	5-FU, Mit-C	35–45 Gy	N/A	N/A	N/A	57% <sup>a</sup>
Faynsod 2000 <sup>62</sup>	30	Stage I–IV	40	5-FU, Mit-C	45–55 Gy	94%	N/A	64%	74% <sup>a</sup>
Mitchell 2001 <sup>63</sup>	49	Stage I–IIIB	9.8 y	5-FU, Mit-C or CIS for tumors >3 cm (n = 26)	45–60 + 10–15 Gy boost	T1–2 74% T3—433%	81%	85%	Stage I <sup>a</sup> 62% Stage II 68% Stage IIIA 100% Stage IIIB 70%
Kapp 2001 <sup>64</sup>	39	T1–4, N0–2, MO	31	31 5-FU, Mit-C for tumors >3 cm (n = 28)	Split-dose 50.4 with 6 Gy brachytherapy	80%	73%	76%	76% <sup>b</sup>
Peiffert 2001 <sup>65</sup>	80	>4 cm and/or LN+	29	5-FU, CIS	45 Gy + 15–20 Gy boost	67%	73% (3 y)	84% (3 y)	86% <sup>c</sup>
Ajani 2008 <sup>58</sup>	341	T2–T4	2.5 y	5-FU, Mit-C vs 5-FU, CIS	45–59 Gy		90% 81%	75% (5 y)	75% (5 y) 70% 67%

CR, complete response; 5-FU, 5-fluorouracil; Mit-C, mitomycin-C; CIS, cisplatin; LN, lymph node; N/A, not available.

<sup>a</sup>5-year overall survival.

<sup>b</sup>5-year disease-specific survival.

<sup>c</sup>3-year overall survival.

Modified, with permission, from Chawla AK, Willett CG. Squamous cell carcinoma of the anal canal and anal margin. *Hematol Oncol Clin North Am.* 2001;15:321–344.

## Treatment of Inguinal Nodal Metastases

Palpable inguinal lymph nodes (LN) should be biopsied or evaluated by fine-needle aspiration (FNA) at the onset of treatment for staging. Several reviews have confirmed the poor prognostic outlook conferred by inguinal LN metastases. In 1970, Stearns and Quan reviewed the MSKCC experience with anal canal cancer and noted that only 14% of patients with synchronous nodal metastases survived for 5 years.<sup>60</sup> Similarly, O'Brien and colleagues reported in 1982 that none of the 52% of patients presenting with synchronous LN involvement survived more than 3 years after diagnosis.<sup>61</sup> Both Stearns and O'Brien observed independently that patients presenting with metachronous LN metastases had better survival following therapeutic inguinal lymph node dissection. In the MSKCC review, 75% of patients survived longer than 5 years after groin dissection.

The use of radiation on the inguinal lymph nodes, both prophylactically and for treatment, was explored by Papillon.<sup>66</sup> In 1974, he reported on 19 patients with synchronous inguinal nodal involvement who underwent groin irradiation for disease control. Eleven of the 19 had no evidence of disease at 3 years. Cummings and associates treated nodal disease in a similar fashion and showed that 87% of patients had good disease control or cure without groin dissection.<sup>67</sup>

With the use of radiation fields expanded to include inguinal, internal, and external iliac nodes, the current treatment paradigm is to treat inguinal nodal metastases with chemotherapy and radiation concurrently with the primary tumor. Metachronous lymph node involvement is treated with salvage chemotherapy and radiation if dose limits have not been exceeded, as well as groin dissection if warranted.

## Recurrent Disease and Salvage Therapy

The goal of early detection of local post-treatment recurrence is to prevent lymphatic spread of disease and maximize salvage. Most clinicians advocate a thorough physical examination including a digital rectal examination and anoscopy every 3–4 months for at least 2 years. An additional strategy involves the use of endoanal ultrasound (EAUS) inspection. At the Hospital of the University of Pennsylvania, the current protocol is EAUS every 4 months for 3 years, followed by every 6 months for 2 years. Suspicious tissue or lymph nodes are biopsied with the aid of ultrasound guidance.

There is some evidence that local regression of disease following radiation therapy can occur up to 6–9 months following chemoradiation. Routine biopsy of the anal canal

following treatment is no longer recommended within this time period. Rousseau and associates advise allowing the anal canal to heal completely, reserving biopsy for nonhealing ulcers and recurrent or enlarging anal canal masses after a period of at least 6 months following therapy.<sup>68</sup> After this point, any disease detected is residual and salvage therapy is warranted.

In spite of success with nonoperative anal (canal) cancer management, depending on the stage of disease, 10–30% of patients will recur, most locally. The treatment of recurrent or persistent disease is APR with negative margins. In a retrospective analysis of salvage therapy for recurrent disease following chemotherapy with radiation, Allal and colleagues found that APR results in a 53% actuarial 5-year survival rate versus 28% in those who did not receive additional treatment.<sup>69</sup> Pocard and colleagues' data from St. Antoine University Hospital examined salvage APR in 21 patients who had either residual disease after sphincter conservation or recurrence. The group found an actuarial 5-year survival benefit of 30%.<sup>70</sup> Factors resulting in failure were lymphadenopathy, positive margins, and distant disease. Longo and associates compared salvage with chemoradiation versus APR and found that only 27% of patients treated with additional combined therapy survived long term, whereas 57% of those in the APR group did<sup>71</sup> (Table 42-4).<sup>44,72,73</sup> Similarly, a recent retrospective review from the University of Toronto looked at a cohort of 40 patients who underwent surgical salvage after failure of chemoradiotherapy and found an overall survival of 41 months, with 5-year overall- and disease-free survival 39 and 30%, respectively.<sup>74</sup>

Patients with recurrence die of locoregional complications including ureteral obstruction, perineal sepsis and necrosis, bowel obstruction, and venous thrombosis. Contraindications for salvage surgery include medical debilitation, known distant metastases, invasion of the pelvic sidewalls, and obvious inguinal lymphadenopathy. The preoperative assessment should include a chest x-ray and an MRI or CT scan of the abdomen and pelvis. A multidisciplinary approach is appropriate for local invasion of resectable structures such as the urinary bladder, cervix, vagina,

or the sacrum. A team including urologists, neurosurgeons, orthopedic surgeons, and plastic surgeons may be required. Recurrences close to the pelvic sidewall may be indistinguishable intraoperatively from fibrosis and scarring from prior radiation or surgery. An intraoperative frozen section may be useful if one is considering placing afterloading catheters or delivering intraoperative brachytherapy to these areas. The role and long-term outcomes of brachytherapy as a treatment adjunct for salvage surgery has not yet been validated.

The complications of salvage pelvic surgery may be severe and debilitating and include perineal wound dehiscence and necrosis. Tissue coverage in previously irradiated fields improves wound healing and many consider it essential for postextenteration reconstruction. Pedicle and rotational flaps may be fashioned from the gluteus, gracilis, or rectus abdominis muscles.

There is little published regarding long-term follow-up in patients salvaged with radiation or chemoradiation following local excision of anal cancer. Patients who undergo primary excision for anal canal carcinoma do so for a number of reasons, usually inadvertently, including polypectomy, hemorrhoidectomy, or excisional biopsy, as well as local excision with intent to cure. Although it is unclear at this point whether further treatment for completely excised, early-stage lesions is appropriate, patients with positive margins, or those with tumors harboring vascular or lymphatic invasion with poorly differentiated characteristics are candidates for further therapy. A retrospective analysis from MSKCC in 1999 reviewed 14 patients who received postoperative chemoradiation (either 30 or 45–50 Gy) after local excision.<sup>75</sup> Actuarial 5-year local control rates were 93% with no difference between outcomes in the higher- and lower-dose groups. Longo and associates published the largest single retrospective analysis of outcomes in 1994, reviewing chemoradiation following local excision.<sup>48</sup> The overall local control rate at 5 years was 79% in 109 patients receiving a median dose of 42 Gy. Stratification of the data by stage revealed a 90% local control rate with stage I, 54% with stage II, and 100% with stage III (6/6 patients).<sup>48</sup> There have been no prospective



**TABLE 42-4: ABDOMINOPERINEAL RESECTION AFTER FAILURE OF RADIATION (WITH OR WITHOUT CHEMOTHERAPY) FOR ANAL CANCER**

Review	Number of Patients	Median Follow-Up (Months)	Alive (%)	5-Year Survival Rate (%)
Zelnick 1992 <sup>44</sup>	9	20	<10	—
Tanum 1993 <sup>72</sup>	9	36	67	—
Lasser 1993	14	36	50	—
Ellenhorn 1994 <sup>73</sup>	38	47	—	44
Longo 1994 <sup>48</sup>	11	25	18	—
Hill 1996	11	25	18	—
Pocard 1989 <sup>70</sup>	21	40	48	33

Data from Cummings BJ, Keane TJ, Hawkins NV, et al. Treatment of perianal carcinoma by radiation (RT) or radiation plus chemotherapy (RTCT). *Int J Radiat Oncol Biol Phys*. 1986;12:170.



studies comparing local excision alone versus chemoradiation for T1 favorable-histology tumors.

More recently, a multicenter group from France looked at their experience with adjuvant treatment of very early anal (canal) tumors. Of 62 patients with either Tis or T1 anal SCC, 26 had undergone primary excision followed by adjuvant radiation as compared to 43 patients treated with definitive radiation alone. Local recurrence rates were higher for the former group (3/23 vs 3/43). Local control was obtained in all six local failures via APR. Long-term survival was no different.<sup>76</sup> There are no data to clearly show superiority of local excision of anal SCC over definitive chemoradiation. However, current studies suggest that tumors that are incompletely excised, those with poor histologic characteristics, and those that are stage II and above are candidates for chemoradiation following excision.<sup>68,71,75</sup> As with primary therapy, giving chemotherapy (principally infusional 5-FU with mitomycin-C or cisplatin) seems to promote effective local control at lower radiation doses.

Anal (canal) carcinoma metastasizes in 10–20% of patients late in the course of disease and prognosis is exceedingly poor.<sup>9</sup> Liver and lung metastases predominate and cisplatin-based chemotherapy is the only strategy shown to be somewhat effective.<sup>68</sup>

## PERIANAL (ANAL MARGIN) CANCER

Squamous cell carcinoma of the perianal area is at least five times less common than anal (canal) carcinoma, and for the most part, is treated by primary surgical excision similarly to skin cancers. These tumors arise on the perianal skin beyond the anal verge. They are usually well- or moderately differentiated keratinized SCCs and generally have a favorable prognosis.<sup>9</sup> Metastases are late and rare, and recurrences are typically locoregional. Symptoms include pain, bleeding, itching, and palpable mass. In a study from Denmark, Jensen and associates noted a 6-month median duration of symptoms prior to diagnosis, with an erroneous initial diagnosis made in 29% of cases.<sup>6</sup> Because these tumors are fairly slow growing and uncommon, they are frequently mistaken for hemorrhoids or other benign conditions at initial presentation.

Diagnosis is often suspected by the experienced clinician on inspection, but biopsy prior to definitive treatment is imperative. If the lesion is small, excisional biopsy can be accomplished with adequate margins (1 cm). If the tumor is larger, a small incisional biopsy allows accurate classification of the tumor and appropriate preoperative counseling.

Metastases to the inguinal lymph nodes occur in 15–25% of patients. The rate of nodal metastases is directly proportional to the size of the tumor. Papillon and Chassard reported that for tumors less than 2 cm in size, the rate of nodal metastasis was 0%, for those 2–5 cm 24%, and for those greater than 5 cm 67%.<sup>77</sup> Cummings and colleagues found that those with tumors less than 5 cm in size had 0% nodal metastases, whereas metastases occurred in 25% of those with tumors 5 cm or larger.<sup>67</sup>

## Surgery

Although surgical excision (either local excision or APR, depending on location) is considered the standard of care for perianal (anal margin) tumors, outcome data for this rare neoplasm are primarily retrospective. In most studies, overall and disease-specific survival is considered for all stages together and subgroup analysis for large numbers of patients is not available. Unfortunately, evaluation of local recurrence data is similarly limited by the small numbers of patients affected; however, in general a trend toward increased recurrence in larger tumors is apparent.<sup>78</sup>

Surgical treatment of the primary perianal tumor is accomplished by wide local excision with 1-cm margins. At MSKCC, Greenall and associates reported a series of 51 patients with perianal squamous cell carcinoma (anal margin).<sup>42</sup> Five-year survival was 88%, although local recurrence was 46%. Local recurrences were amenable to re-excision. Inguinal nodal dissection was employed for metachronous inguinal nodal metastases. Thirteen patients in this series underwent APR as initial treatment. The local recurrence rates for these patients were identical to those of the local excision group. Tumor size was the most important factor for local control and survival (Fig. 42-5). In 1979, Cleveland

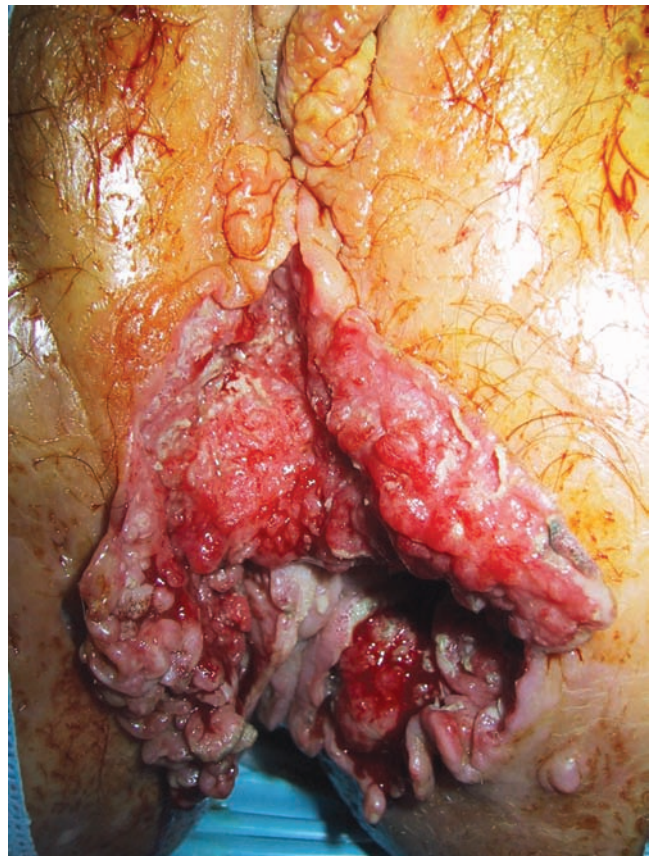


FIGURE 42-5 Deeply ulcerating anal margin tumor. (Used, with permission, from Charles Friel, MD.)

clinic reviewed their experience with surgery for anal margin tumors over a 20-year period.<sup>79</sup> Eight patients were identified for whom follow-up was available. A disease-specific survival rate of 70% was noted after 8 years, with a local recurrence rate of 30%. At the University of Chicago, a 19% local recurrence rate was noted in 16 patients undergoing surgical therapy alone.<sup>80</sup> Two of 11 patients recurred following local excision, and 1 of 3 recurred after APR. Of 27 patients with either stage I perianal (anal margin) cancer or carcinoma in situ treated at the Mayo Clinic between 1950 and 1970, 5-year survival rates were 100%, although local recurrence rates were unavailable.<sup>81</sup>

After surgery alone (local excision or APR), the overall survival rate for all stages is 60–90% with a local recurrence rate of approximately 30%. Survival rates after surgery for recurrence are unknown.<sup>9,78</sup>

## Radiotherapy

The optimal treatment of perianal (anal margin) tumors is dependent on location. Significant challenges and functional problems may result when the anal sphincters are present within the boundaries of optimal surgery. If adequate excision compromises the sphincters, APR is an option. However, many surgeons and oncologists would advocate a more conservative approach and use radiotherapy. Cummings and associates demonstrated local control rates of 100% for anal margin tumors less than 5 cm in size with a dose of 50 Gy over 4 weeks.<sup>67</sup> Local control rates were inversely proportional to the size of the tumor. For those tumors 5–10 cm, 70% local control was achieved, but for tumors greater than 10 cm, only 40% sustained a durable response. Similar results were reported by Papillon and Chassard at Centre Leon Berard in France.<sup>77</sup> In this review, a 78% overall survival rate was achieved using external beam radiation (40 Gy cobalt 60 source) with a perineal field. Again, those with tumors greater than 5 cm in size fared considerably worse, with overall survival rates less than 50%.<sup>77</sup>

There have been numerous retrospective reviews of the response of perianal (anal margin) tumors to radiation in the past 40 years documenting stage-specific local recurrence rates, disease-specific survival rates, and overall survival rates. Overall, local control rates of 52–87% are typical, with 5-year overall survival rates ranging from 52 to 90%.<sup>78</sup> T1 and T2 tumors have better local control rates with overall and disease-specific survival rates ranging from 82 to 100%.<sup>78</sup>

It is difficult to evaluate the sphincter preservation rate from these reviews. Small numbers and retrospective design limits direct comparison of this technique to surgery alone. There are no prospective studies comparing surgery alone to radiotherapy. Although the addition of chemotherapy (5-FU and mitomycin-C or cisplatin) seems logical, there are few data to support that approach. The rationale for these agents is extrapolated from the prospective trials of chemoradiation in the setting of anal (canal) carcinoma. Even so,

it is reasonable to believe that primary radiotherapy with or without chemotherapy for perianal (anal margin) tumors in close proximity to the anal sphincters, where adequate excision may compromise function, will result in both sphincter preservation and good local control. It is also reasonable to expect that surgical salvage for recurrence after primary radiotherapy is a possibility, with rates of local control of approximately 50%. Long-term disease-specific survival following this scenario is unknown.

## LESS COMMON ANAL NEOPLASMS: ANAL MELANOMA

Melanoma of the anus and rectum is a rare malignancy accounting for less than 1% of all colorectal and anal neoplasms.<sup>82</sup> The majority of GI melanomas are metastases; autopsy studies have shown GI metastases in up to 30% of patients with extraintestinal primaries.<sup>83</sup> Primary GI melanoma predominantly affects the anorectum and esophagus. Although there is a female predominance, with an almost 1:2 ratio, there is evidence that the median age of affected males is significantly less (57 vs 71 years).<sup>79</sup> Cagir and colleagues examined the epidemiology and demographics of anorectal melanoma using the Surveillance, Epidemiology and End Results (SEER) database. These investigators note a recent emergence of a bimodal age distribution of anorectal melanoma for all patients, with males occupying the younger aspect of the curve. Survival rates were slightly better in this group (63 vs 51% at 1 year and 41 vs 27% at 2 years;  $p < .01$ ).<sup>84</sup> The most common symptoms include bleeding, itching, the presence of a mass, pain, tenesmus, or changes in bowel habits. Like anal SCC, misidentification of the tumor as a hemorrhoid is a common mistake. Diagnosis is frequently made following hemorrhoidectomy or local excision of the perianal mass. The tumor can appear small and polypoid, or large and ulcerating. About 30% of these tumors are amelanotic and unpigmented making immediate recognition of the problem difficult.<sup>82</sup> On pathology, 70% of lesions show some evidence of melanin production either grossly or microscopically.<sup>82</sup> Commonly, anal melanoma arises at the mucocutaneous junction. Occasionally, the lesion arises more proximally, within the rectal mucosa. Although the origin of these tumors is speculative, they are believed to arise in areas of heterotopic anal canal epithelium in the rectum, or to start from proximal microscopic mucosal spread from a small lesion located more distally.<sup>82</sup>

## Staging and Prognosis

Like melanoma of the skin, anorectal melanoma is staged by depth or thickness of the lesion. Lymphatic metastases can occur in the inguinal, mesorectal, and internal iliac nodal distribution. Mesorectal lymph node metastases are found in 40–60% of patients at initial presentation and inguinal

adenopathy is present in at least 20% of patients.<sup>85,86</sup> Distant spread occurs to the bone, lung, and liver.

Regardless of stage, 5-year survival rates for patients diagnosed with anorectal melanoma are very poor, averaging about 6%. The median survival time following diagnosis is 12–18 months.<sup>82</sup>

## Surgery

In recent years, local excision has replaced APR for the treatment of anal melanoma. A 64-year review, concluding in 1995, of the anorectal melanoma experience at MSKCC demonstrated a trend toward increased survival for patients with localized, node-negative disease, and for those that were resectable, the authors advocated radical surgery.<sup>86</sup> A more recent report of the last 20 years of the MSKCC experience showed no disease-specific or overall survival for any surgical approach.<sup>87</sup> Other outcomes data comparing local recurrence rates and survival are similar, and do not demonstrate a survival difference between the two approaches; therefore the preservation of fecal continence is a priority when possible. A number of retrospective series published from 1990 to 2003 reviewing institutional experience with local excision and APR found that 5-year survival rates range from 0 to 29% for those undergoing wide local excision, and from 0 to 26% for those undergoing APR. Most authors now recommend wide local excision with negative margins for those patients without anal sphincter involvement.<sup>82</sup>

Even though survival differences are minimal between local and radical approaches, local recurrence rates may be higher after local excision. A study from the M.D. Anderson Cancer Center found that recurrence after local excision was significantly higher than recurrence after APR (58 vs 29%), and that median survival times were the same (~19 months for both groups).<sup>88</sup> Patients with local recurrence in this study developed synchronous regional and distant disease. Roumen in the Netherlands also reported an increased rate of local recurrence with local excision, but no overall survival disadvantage.<sup>89</sup>

Inguinal lymph node dissection in anorectal melanoma is usually reserved for those with clinically positive nodes and is a palliative intervention. Prophylactic nodal dissection does not seem to provide a survival benefit and there currently is no clear indication for it. The role of sentinel lymph node mapping in this disease is not clear. The benefits of the technique are now well established in cutaneous melanoma, but it has not been investigated in anorectal melanoma and is not currently routinely performed.

## Adjuvant Therapy

High-dose interferon- $\alpha$  (IFN- $\alpha$ ) is currently used in the treatment of cutaneous melanoma. It confers a survival benefit in this group, improving disease-free survival rates.<sup>82</sup> However,

there are no data demonstrating its efficacy in anorectal melanoma, and current reports of adjuvant chemotherapy in this setting are anecdotal. In fact, two large meta-analyses show no consistent benefit from the use of IFN- $\alpha$ .<sup>90,91</sup>

Aggressive multidrug chemotherapeutic regimens show some potential efficacy, but toxicities with these approaches are considerable.<sup>92,93</sup> Temozolomide, whose metabolite is dacarbazine has shown efficacy against cutaneous melanoma,<sup>94</sup> and is being investigated for use in anal melanoma. Innovative new approaches, guided by molecular targets are also under investigation,<sup>95</sup> but currently, there is no data to guide effective adjuvant chemotherapy.

External beam irradiation for symptomatic pelvic and local recurrences and metachronous inguinal nodal disease has been incorporated into the palliative treatment of anorectal melanoma, but again, no data are available to assess overall efficacy. It seems reasonable, however, to extrapolate treatment paradigms from cutaneous melanoma to anorectal melanoma in stage IV disease.

The surgical treatment of anorectal melanoma has changed over time, evolving from radical to local excision. No survival benefit is conferred by APR in most studies, and in most reviews survival is quite poor in spite of surgical excision, with median survival less than 20 months from the time of diagnosis. Although adjuvant chemotherapy is shown to be effective in cutaneous melanoma, lack of data hinders acceptance of this therapy in anorectal melanoma.

## ANAL ADENOCARCINOMA

Anal adenocarcinomas are uncommon, comprising 10% of all anal (canal) carcinomas.<sup>82</sup> Symptoms of bleeding, pain, and change in bowel habits are nonspecific and similar to other anal canal and distal rectal neoplasms. Anal adenocarcinomas may occasionally arise from chronic anal fistulas.

Although outcomes data are few, anal adenocarcinoma has a poor prognosis when compared to rectal cancers or anal SCC. In small series, 5-year survival rates range from 64% to less than 5%.<sup>96,97</sup> These neoplasms have a high rate of both local and distant failure.<sup>97</sup>

Treatment is similar to therapy for adenocarcinoma of the rectum. Neoadjuvant chemoradiation followed by surgical excision is recommended. Postoperative adjuvant chemotherapy may be prudent, as it is in rectal adenocarcinoma, to reduce the risk of distant spread.

## PAGET'S DISEASE

Paget's disease was first described in 1874 by Sir James Paget, who reported 15 cases involving the nipple.<sup>98</sup> To date, less than 200 cases of perianal Paget's have been documented in the literature since Darier and Couillaud reported the first case in 1893.<sup>98</sup>

Paget's has a female predominance (1.5:1) with a median presentation age of 65 years.<sup>99</sup> The disease is usually



present for an extended period of time prior to diagnosis because the symptoms are nonspecific and often mistaken for a benign dermatitis. Paget's occurs in apocrine, hair-bearing areas. Erythematous, pruritic, scaling plaques with well-defined serpiginous borders are a typical feature of the disease. These lesions may also appear ulcerated and crusty with a serous discharge. The disease can be found in both the anal canal and margin.<sup>82,98</sup> Histologically, Paget's disease is defined by the presence of large intraepidermal anaplastic tumor cells lying separately or in small clusters. Perianal Paget's cells are foamy and vacuolar in appearance and stain light blue with hematoxylin and eosin. They are positive for periodic acid-Schiff, mucicarmine, Alcian blue, and cytokeratin 7.<sup>82</sup>

The pathogenesis of Paget's disease is still somewhat unclear. Because it can be associated with the presence of rectal adenocarcinoma, it is speculated that Paget's represents a downward extension of the tumor or that a "neoplastic milieu" may create an environment hospitable to the presence of multiple GI primary tumors. Another hypothesis holds that it is a primary tumor of the apocrine glandular elements of the distal anal canal and margin. Others have suggested that Paget's may arise from a neoplastic pluripotent epidermis basal cell.<sup>82</sup>

Perianal Paget's is associated with an underlying visceral malignancy in 20–86% of cases.<sup>82,98,99</sup> Colorectal adenocarcinoma is the most common synchronous tumor, but urogenital, breast, and bile duct carcinomas have also been reported. Screening for other malignancies is imperative. A colonoscopy and prostate examination are basic preventive and diagnostic tests that can be helpful. Some authors recommend computed tomography of the abdomen and pelvis as well.<sup>98</sup>

Complete excision is the treatment for Paget's disease. The extent of the disease is usually determined by taking circumferential biopsies of the anal canal and margin. After the disease is *mapped*, wide local excision is performed. Often, the procedure creates large defects that may require skin grafts or flaps (rotational, island, or myocutaneous). Because excision to negative margins is critical to cure, techniques to ensure this may be required. Surgeons may obtain frozen sections of the margins of the specimen in the operating room prior to reconstruction. Others prefer to cover the wound with saline-soaked gauze, admit the patient to the hospital, and await permanent pathology results for up to 2–3 days prior to reconstruction. If a large flap reconstruction is placed in the anal canal, some recommend diversion with a colostomy or ileostomy at the time of the perineal excision.

Recurrence rates as high as 61% have been reported following excision of perianal Paget's disease.<sup>100</sup> Re-excision is the usual recommendation, although in cases in whom underlying rectal or anal adenocarcinoma exist, radiation followed by APR is advisable. Although recurrence rates are high, the prognosis of Paget's limited to the perianal area with no concomitant neoplasm is very good.<sup>82</sup> Because of the association with additional visceral neoplasms, continued surveillance is

required for patients with perianal Paget's disease. Physical examination, including a prostate and pelvic examination, and periodic colonoscopy are probably prudent. Biopsies of new lesions at the edges of the flap or graft may reveal residual disease. Local excision of these recurrences and continued surveillance is required.

## BUSCHKE-LÖWENSTEIN TUMORS

Buschke-Löwenstein tumors are also referred to as giant condylomas and were first described in 1925 by Buschke and Löwenstein as "carcinoma-like condylomata acuminata."<sup>101</sup> They are rare entities belonging to a wider group of lesions called verrucous carcinomas, which include oral and cutaneous fungating condylomata. The key feature of giant condyloma that differentiates it from benign anal condyloma is the presence of local invasion.

Although the natural history of these lesions is poorly understood, the etiology is assumed to be similar to that of condyloma.<sup>101</sup> Human papillomavirus (HPV) has been isolated from the tumors. Histologically, the lesions are benign in appearance and do not invade the basement membrane as carcinomas do. Instead, they destroy surrounding tissue by expansion rather than direct invasion (Fig. 42-6). The tumor does not metastasize. Deaths from untreated Buschke-Löwenstein tumors have occurred following deep invasion into unresectable pelvic structures followed by superinfection and recurrent sepsis. The overall mortality rate from this rare entity is 20%.<sup>102</sup>

The literature consists almost entirely of case reports,<sup>103</sup> thus, there are no consistent treatment guidelines. Primary treatment consists of surgical resection to clear margins.<sup>102</sup> However, adequate surgery may be impossible when the tumor deeply invades the pelvis. There have been several case reports demonstrating the efficacy of intralesional injection of interferon- $\alpha$  2b.<sup>101</sup> At least three reported cases of deeply infiltrating giant condylomata have completely responded to

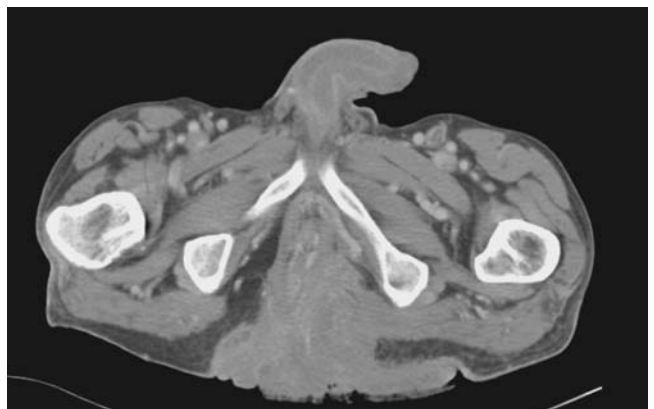


FIGURE 42-6 Buschke-Löwenstein tumor. Local invasion of pelvis, rectum, anal sphincters, and gluteus muscles.

long-term therapy, including one patient who would have required hemipelvectomy with limb amputation to achieve negative margins. Interferon- $\alpha$  2b may be a good alternative or supplement to radical resection in select cases. Long-term outcomes are not available.

## GASTROINTESTINAL STROMAL TUMORS

Gastrointestinal stromal tumors (GISTs) are of mesenchymal origin, believed to be derived from the interstitial cells of Cajal. Immunohistochemical analysis shows the majority to be positive for CD34 and CD117 (*c-kit*). The vast majority of GISTs affect the stomach and small bowel; only 5% of GISTs affect the anorectum, and purely anal GIST comprise only 2–8% of these.<sup>104</sup> Because there are so few, most reports consider anal and rectal GISTs together for analysis.

Current assessment of prognosis for GIST is based on certain clinicopathologic features; tumor size greater than 5 cm, and mitoses greater than 5/high-power field (HPF) predict malignant behavior and decreased survival. Other factors such as pleomorphism, tumor necrosis, and infiltration of muscularis propria and symptoms are indicative of more aggressive behavior, but effects on survival are less clear.<sup>104,105</sup>

Due to the exceeding rarity of this tumor, few data-driven recommendations can be given but extrapolation from management of rectal GISTs demonstrates that surgical excision is recommended for all tumors. Smaller tumors (<2 cm) may be excised locally, while larger, or more locally invasive tumor may require APR for an R0 resection. Local recurrence is common after limited resection, up to 60% in one series,<sup>104</sup> while radical resection yielded 100% recurrence-free survival. Anecdotally, salvage APR for local recurrence after limited excision may yield affective long-term disease control. However, there is no data available to show that extent of surgery can affect overall survival.

While adjuvant therapy with molecularly targeted tyrosine kinase inhibitors like imatinib (Gleevec) and sunitinib (Sutent) for advanced or metastatic disease is becoming standard of care for most GISTs, however there is no data yet to support or extrapolate its use in anal GISTs.

## KAPOSI'S SARCOMA

Although Kaposi's sarcoma (KS) is the most common malignancy in AIDS, the incidence of anorectal KS is still quite small in this population. Current HAART treatment makes this number continue to fall.<sup>106</sup> Anal KS usually presents as pedunculated or round purplish-red anal lesions that can easily be mistaken for prolapsing hemorrhoidal tissue. Treatment is primarily medical, with chemotherapy directed at the tumor, as well as appropriate antiretroviral therapy. Use of external beam radiation has also been described for cutaneous anal lesions.<sup>107</sup>

## REFERENCES

- Fenger C. The anal transitional zone. *Acta Pathol Microbiol Immunol Scand Suppl.* 1987;289:1–42.
- World Health Organization. Anal cancer. In: *World Health Organization International Statistical Classification of Diseases and Related Health Problems.* 10th ed; 2003.
- Welton ML, Varma ML. Anal cancer. In: Wolff BG, Fleshman JW, Beck DE, Pemberton JH, Wexner SD, eds. *The ASCRS Textbook of Colon and Rectal Surgery.* New York, NY: Springer; 2007:482.
- Greenlee RT, Murray T, Bolden S, Wingo PA. Cancer statistics, 2000. *CA Cancer J Clin.* 2000;50(1):7–33.
- Jemal A, Thomas A, Murray T, Thun M. Cancer statistics, 2002. *CA Cancer J Clin.* 2002;52(1):23–47.
- Jensen SL, Hagen K, Harling H, Shokouh-Amiri MH, Nielsen OV. Long-term prognosis after radical treatment for squamous-cell carcinoma of the anal canal and anal margin. *Dis Colon Rectum.* 1988;31(4):273–278.
- Jemal A, Siegel R, Ward E, Hao Y, Xu J, Thun MJ. Cancer statistics, 2009. *CA Cancer J Clin.* 2009;59:225–249.
- Chawla AK, Willett CG. Squamous cell carcinoma of the anal canal and anal margin. *Hematol Oncol Clin North Am.* 2001;15(2):321–344, vi.
- Gervasoni JE, Jr, Wanebo HJ. Cancers of the anal canal and anal margin. *Invest.* 2003;21(3):452–464.
- Klencke BJ, Palefsky JM. Anal cancer: an HIV-associated cancer. *Hematol Oncol Clin North Am.* 2003;17(3):859–872.
- Goedert JJ, Cote TR, Virgo P, et al. Spectrum of AIDS-associated malignant disorders. *Lancet.* 1998;351(9119):1833–1839.
- Palefsky JM. Anal squamous intraepithelial lesions in human immunodeficiency virus-positive men and women. *Semin Oncol.* 2000;27(4):471–479.
- Stanley M. Genital human papillomavirus infections—current and prospective therapies. *J Natl Cancer Inst Monogr.* 2003;31:117–124.
- Frisch M, Glimelius B, van den Brule AJ, et al. Sexually transmitted infection as a cause of anal cancer. *N Engl J Med.* 1997;337(19):1350–1358.
- Bosch FX, Lorincz A, Munoz N, Meijer CJ, Shah KV. The causal relation between human papillomavirus and cervical cancer. *J Clin Pathol.* 2002;55(4):244–265.
- Abbasakoor F, Boulos PB. Anal intraepithelial neoplasia. *Br J Surg.* 2005;92(3):277–290.
- Berry JM, Palefsky JM, Welton ML. Anal cancer and its precursors in HIV-positive patients: perspectives and management. *Surg Oncol Clin N Am.* 2004;13(2):355–373.
- Ryan DP, Compton CC, Mayer RJ. Carcinoma of the anal canal. *N Engl J Med.* 2000;342(11):792–800.
- Piketty C, Selinger-Leneman H, Grabar S, et al. Marked increase in the incidence of invasive anal cancer among HIV-infected patients despite treatment with combination antiretroviral therapy. *AIDS.* 2008;22(10):1203–1211.
- Patel P, Hanson DL, Sullivan PS, et al. Incidence of types of cancer among HIV-infected persons compared with the general population in the United States, 1992–2003. *Ann Intern Med.* 2008;148(10):728–736.
- Frisch M, Biggar RJ, Engels EA, Goedert JJ, AIDS-Cancer Match Registry Study Group. Association of cancer with AIDS-related immunosuppression in adults. *JAMA.* 2001;285(13):1736–1745.
- Goedert JJ. The epidemiology of acquired immunodeficiency syndrome malignancies. *Semin Oncol.* 2000;27(4):390–401.
- Palefsky J. Human papillomavirus-related disease in people with HIV. *Curr Opin HIV AIDS.* 2009;4(1):52–56.
- Stephenson J. Health agencies update: anal cancer screening. *JAMA.* 2000;283(23):3060.
- Frisch M, Glimelius B, Wohlfahrt J, Adami HO, Melbye M. Tobacco smoking as a risk factor in anal carcinoma: an antiestrogenic mechanism? *J Natl Cancer Inst.* 1999;91(8):708–715.
- Frisch M, Olsen JH, Bautz A, Melbye M. Benign anal lesions and the risk of anal cancer. *N Engl J Med.* 1994;331(5):300–302.
- Frisch M, Johansen C. Anal carcinoma in inflammatory bowel disease. *Br J Cancer.* 2000;83(1):89–90.
- Cleary RK, Schaldenbrand JD, Fowler JJ, Schuler JM, Lampman RM. Treatment options for perianal Bowen's disease: survey of American Society of Colon and Rectal Surgeons Members. *Am Surg.* 2000;66(7):686–688.
- Brown SR, Skinner P, Tidy J, Smith JH, Sharp F, Hosie KB. Outcome after surgical resection for high-grade anal intraepithelial neoplasia (Bowen's disease). *Br J Surg.* 1999;86(8):1063–1066.

30. Margenthaler JA, Dietz DW, Mutch MG, Birnbaum EH, Kodner JJ, Fleshman JW. Outcomes, risk of other malignancies, and need for formal mapping procedures in patients with perianal Bowen's disease. *Dis Colon Rectum*. 2004;47(10):1655–1660; discussion 1660–1661.
31. Chang GJ, Berry JM, Jay N, Palefsky JM, Welton ML. Surgical treatment of high-grade anal squamous intraepithelial lesions: a prospective study. *Dis Colon Rectum*. 2002;45(4):453–458.
32. Pineda CE, Berry JM, Jay N, Palefsky JM, Welton ML. High-resolution anoscopy targeted surgical destruction of anal high-grade squamous intraepithelial lesions: a ten-year experience. *Dis Colon Rectum*. 2008;51(6):829–835; discussion 835–837.
33. Scholefield JH, Castle MT, Watson NF. Malignant transformation of high-grade anal intraepithelial neoplasia. *Br J Surg*. 2005;92(9):1133–1136.
34. Watson AJ, Smith BB, Whitehead MR, Sykes PH, Frizelle FA. Malignant progression of anal intra-epithelial neoplasia. *ANZ J Surg*. 2006;76(8):715–717.
35. Duclos P. Human papillomavirus vaccines: WHO position paper. *Biologicals*. 2009;37(5):338–344. Epub 2009 Jun 13.
36. Moore HG, Guillem JG. Anal neoplasms. *Surg Clin North Am*. 2002;82(6):1233–1251.
37. Singh R, Nime F, Mittelman A. Malignant epithelial tumors of the anal canal. *Cancer*. 1981;48(2):411–415.
38. Nigro ND, Vaitkevicius VK, Considine B, Jr. Combined therapy for cancer of the anal canal: a preliminary report. 1974. *Dis Colon Rectum*. 1993;36(7):709–711.
39. Grigsby PW. FDG-PET/CT: new horizons in anal cancer. *Gastroenterol Clin Biol*. 2009;33(5):456–458.
40. Frost DB, Richards PC, Montague ED, Giacco GG, Martin RG. Epidermoid cancer of the anorectum. *Cancer*. 1984;53(6):1285–1293.
41. Boman BM, Moertel CG, O'Connell MJ, et al. Carcinoma of the anal canal. A clinical and pathologic study of 188 cases. *Cancer*. 1984;54(1):114–125.
42. Greenall MJ, Quan SH, Stearns MW, Urmacher C, DeCosse JJ. Epidermoid cancer of the anal margin. Pathologic features, treatment, and clinical results. *Am J Surg*. 1985;149(1):95–101.
43. Touboul E, Schlienger M, Buffat L, et al. Conservative versus nonconservative treatment of epidermoid carcinoma of the anal canal for tumors longer than or equal to 5 centimeters. A retrospective comparison. *Cancer*. 1995;75(3):786–793.
44. Zelnick RS, Haas PA, Ajlouni M, Szilagyi E, Fox TA, Jr. Results of abdominoperineal resections for failures after combination chemotherapy and radiation therapy for anal canal cancers. *Dis Colon Rectum*. 1992;35(6):574–577; discussion 577–578.
45. Ajani JA, Winter KA, Gunderson LL, et al. US intergroup anal carcinoma trial: tumor diameter predicts for colostomy. *J Clin Oncol*. 2009;27(7):1116–1121.
46. Klas JV, Rothenberger DA, Wong WD, Madoff RD. Malignant tumors of the anal canal: the spectrum of disease, treatment, and outcomes. *Cancer*. 1999;85(8):1686–1693.
47. Corman ML, Haggitt RC. Carcinoma of the anal canal. *Surg Gynecol Obstet*. 1977;145(5):674–676.
48. Longo WE, Vernava AM, 3rd, Wade TP, Coplin MA, Virgo KS, Johnson FE. Recurrent squamous cell carcinoma of the anal canal. Predictors of initial treatment failure and results of salvage therapy. *Ann Surg*. 1994;220(1):40–49.
49. Michaelson RA, Magill GB, Quan SH, Leaming RH, Nikrui M, Stearns MW. Preoperative chemotherapy and radiation therapy in the management of anal epidermoid carcinoma. *Cancer*. 1983;51(3):390–395.
50. Martenson JA, Lipsitz SR, Wagner H, Jr, et al. Initial results of a phase II trial of high dose radiation therapy, 5-fluorouracil, and cisplatin for patients with anal cancer (E4292): an Eastern Cooperative Oncology Group study. *Int J Radiat Oncol Biol Phys*. 1996;35(4):745–749.
51. Sischy B, Doggett RL, Krall JM, et al. Definitive irradiation and chemotherapy for radiosensitization in management of anal carcinoma: interim report on Radiation Therapy Oncology Group study no. 8314. *J Natl Cancer Inst*. 1989;81(11):850–856.
52. Miller EJ, Quan SH, Thaler HT. Treatment of squamous cell carcinoma of the anal canal. *Cancer*. 1991;67(8):2038–2041.
53. Salmon RJ, Fenton J, Asselain B, et al. Treatment of epidermoid anal canal cancer. *Am J Surg*. 1984;147(1):43–48.
54. Epidermoid anal cancer: results from the UKCCCR randomised trial of radiotherapy alone versus radiotherapy, 5-fluorouracil, and mitomycin. UKCCCR Anal Cancer Trial Working Party. UK Co-ordinating Committee on Cancer Research. *Lancet*. 1996;348(9034):1049–1054.
55. Bartelink H, Roelofsens F, Eschwege F, et al. Concomitant radiotherapy and chemotherapy is superior to radiotherapy alone in the treatment of locally advanced anal cancer: results of a phase III randomized trial of the European Organization for Research and Treatment of Cancer Radiotherapy and Gastrointestinal Cooperative Groups. *J Clin Oncol*. 1997;15(5):2040–2049.
56. Flam M, John M, Pajak TF, et al. Role of mitomycin in combination with fluorouracil and radiotherapy, and of salvage chemoradiation in the definitive nonsurgical treatment of epidermoid carcinoma of the anal canal: results of a phase III randomized intergroup study. *J Clin Oncol*. 1996;14(9):2527–2539.
57. Doci R, Zucali R, La Monica G, et al. Primary chemoradiation therapy with fluorouracil and cisplatin for cancer of the anus: results in 35 consecutive patients. *J Clin Oncol*. 1996;14(12):3121–3125.
58. Ajani JA, Winter KA, Gunderson LL, et al. Fluorouracil, mitomycin, and radiotherapy vs fluorouracil, cisplatin, and radiotherapy for carcinoma of the anal canal: a randomized controlled trial. *JAMA*. 2008;299(16):1914–1921.
59. Salama JK, Mell LK, Schomas DA, et al. Concurrent chemotherapy and intensity-modulated radiation therapy for anal canal cancer patients: a multicenter experience. *J Clin Oncol*. 2007;25(29):4581–4586.
60. Stearns MW, Jr, Quan SH. Epidermoid carcinoma of the anorectum. *Surg Gynecol Obstet*. 1970;131(5):953–957.
61. O'Brien PH, Jenrette JM, Wallace KM, Metcalf JS. Epidermoid carcinoma of the anus. *Surg Gynecol Obstet*. 1982;155(5):745–751.
62. Faysod M, Vargas HI, Tolmos J, et al. Patterns of recurrence in anal canal carcinoma. *Arch Surg*. 2000;135(9):1090–1093; discussion 1094–1095.
63. Mitchell SE, Mendenhall WM, Zlotecki RA, Carroll RR. Squamous cell carcinoma of the anal canal. *Int J Radiat Oncol Biol Phys*. 2001;49(4):1007–1013.
64. Kapp KS, Geyer E, Gebhart FH, et al. Experience with split-course external beam irradiation +/- chemotherapy and integrated Ir-192 high-dose-rate brachytherapy in the treatment of primary carcinomas of the anal canal. *Int J Radiat Oncol Biol Phys*. 2001;49(4):997–1005.
65. Peiffert D, Giovannini M, Ducreux M, et al. High-dose radiation therapy and neoadjuvant plus concomitant chemotherapy with 5-fluorouracil and cisplatin in patients with locally advanced squamous-cell anal canal cancer: final results of a phase II study. *Ann Oncol*. 2001;12(3):397–404.
66. Papillon J. Radiation therapy in the management of epidermoid carcinoma of the anal region. *Dis Colon Rectum*. 1974;17(2):181–187.
67. Cummings BJ, Thomas GM, Keane TJ, Harwood AR, Rider WD. Primary radiation therapy in the treatment of anal canal carcinoma. *Dis Colon Rectum*. 1982;25(8):778–782.
68. Rousseau DL, Jr, Petrelli NJ, Kahlenberg MS. Overview of anal cancer for the surgeon. *Surg Oncol Clin N Am*. 2004;13(2):249–262.
69. Allal AS, Laurencet FM, Reymond MA, Kurtz JM, Marti MC. Effectiveness of surgical salvage therapy for patients with locally uncontrolled anal carcinoma after sphincter-conserving treatment. *Cancer*. 1999;86(3):405–409.
70. Pocard M, Turet E, Nugent K, Dehni N, Parc R. Results of salvage abdominoperineal resection for anal cancer after radiotherapy. *Dis Colon Rectum*. 1998;41(12):1488–1493.
71. Longo WE, Vernava AM, 3rd, Wade TP, Coplin MA, Virgo KS, Johnson FE. Rare anal canal cancers in the U.S. veteran: patterns of disease and results of treatment. *Am Surg*. 1995;61(6):495–500.
72. Tanum G. Treatment of relapsing anal carcinoma. *Acta Oncol*. 1993;32(1):33–35.
73. Ellenhorn JD, Enker WE, Quan SH. Salvage abdominoperineal resection following combined chemotherapy and radiotherapy for epidermoid carcinoma of the anus. *Ann Surg Oncol*. 1994;1(2):105–110.
74. Schiller DE, Cummings BJ, Rai S, et al. Outcomes of salvage surgery for squamous cell carcinoma of the anal canal. *Ann Surg Oncol*. 2007;14(10):2780–2789.
75. Hu K, Minsky BD, Cohen AM, et al. 30 Gy may be an adequate dose in patients with anal cancer treated with excisional biopsy followed by combined-modality therapy. *J Surg Oncol*. 1999;70(2):71–77.
76. Ortholan C, Ramaioli A, Peiffert D, et al. Anal canal carcinoma: early-stage tumors < or = 10 mm (T1 or Tis): therapeutic options and original pattern of local failure after radiotherapy. *Int J Radiat Oncol Biol Phys*. 2005;62(2):479–485.



77. Papillon J, Chassard JL. Respective roles of radiotherapy and surgery in the management of epidermoid carcinoma of the anal margin. Series of 57 patients. *Dis Colon Rectum*. 1992;35(5):422–429.
78. Newlin HE, Zlotecki RA, Morris CG, Hochwald SN, Riggs CE, Mendenhall WM. Squamous cell carcinoma of the anal margin. *J Surg Oncol*. 2004;86(2):55–62; discussion 63.
79. Al-Jurf AS, Turnbull RP, Fazio VW. Local treatment of squamous cell carcinoma of the anus. *Surg Gynecol Obstet*. 1979;148(4):576–578.
80. Schraut WH, Wang CH, Dawson PJ, Block GE. Depth of invasion, location, and size of cancer of the anus dictate operative treatment. *Cancer*. 1983;51(7):1291–1296.
81. Beahrs OH, Wilson SM. Carcinoma of the anus. *Ann Surg*. 1976;184(4):422–428.
82. Billingsley KG, Stern LE, Lowy AM, Kahlenberg MS, Thomas CR, Jr. Uncommon anal neoplasms. *Surg Oncol Clin N Am*. 2004;13(2):375–388.
83. Tessier DJ, McConnell EJ, Young-Fadok T, Wolff BG. Melanoma metastatic to the colon: case series and review of the literature with outcome analysis. *Dis Colon Rectum*. 2003;46(4):441–447.
84. Cagir B, Whiteford MH, Topham A, Rakinic J, Fry RD. Changing epidemiology of anorectal melanoma. *Dis Colon Rectum*. 1999;42(9):1203–1208.
85. Goldman S, Glimelius B, Pahlman L. Anorectal malignant melanoma in Sweden. Report of 49 patients. *Dis Colon Rectum*. 1990;33(10):874–877.
86. Brady MS, Kavolius JP, Quan SH. Anorectal melanoma. A 64-year experience at Memorial Sloan-Kettering Cancer Center. *Dis Colon Rectum*. 1995;38(2):146–151.
87. Yeh JJ, Shia J, Hwu WJ, et al. The role of abdominoperineal resection as surgical therapy for anorectal melanoma. *Ann Surg*. 2006;244(6):1012–1017.
88. Ross M, Pezzi C, Pezzi T, Meurer D, Hickey R, Balch C. Patterns of failure in anorectal melanoma. A guide to surgical therapy. *Arch Surg*. 1990;125(3):313–316.
89. Roumen RM. Anorectal melanoma in The Netherlands: a report of 63 patients. *Eur J Surg Oncol*. 1996;22(6):598–601.
90. Bullard KM, Tuttle TM, Rothenberger DA, et al. Surgical therapy for anorectal melanoma. *J Am Coll Surg*. 2003;196(2):206–211.
91. Lens MB, Dawes M. Interferon alfa therapy for malignant melanoma: a systematic review of randomized controlled trials. *J Clin Oncol*. 2002;20(7):1818–1825.
92. Kawano N, Tashiro M, Taguchi M, et al. Combined treatment with dacarbazine, nimustine, cisplatin, and tamoxifen plus interferon-beta in a patient with advanced anorectal malignant melanoma. *Nippon Shokakibyo Gakkai Zasshi*. 2008;105(11):1627–1633.
93. Eton O, Legha SS, Bedikian AY, et al. Sequential biochemotherapy versus chemotherapy for metastatic melanoma: results from a phase III randomized trial. *J Clin Oncol*. 2002;20(8):2045–2052.
94. Spiro T, Liu L, Gerson S. New cytotoxic agents for the treatment of metastatic malignant melanoma: temozolomide and related alkylating agents in combination with guanine analogues to abrogate drug resistance. *Forum (Genova)*. 2000;10(3):274–285.
95. Quintas-Cardama A, Lazar AJ, Woodman SE, et al. Complete response of stage IV anal mucosal melanoma expressing KIT Val560Asp to the multikinase inhibitor sorafenib. *Nat Clin Pract Oncol*. 2008;5(12):737–740.
96. Jensen SL, Shokouh-Amiri MH, Hagen K, Harling H, Nielsen OV. Adenocarcinoma of the anal ducts. A series of 21 cases. *Dis Colon Rectum*. 1988;31(4):268–272.
97. Papagikos M, Crane CH, Skibber J, et al. Chemoradiation for adenocarcinoma of the anus. *Int J Radiat Oncol Biol Phys*. 2003;55(3):669–678.
98. Delaunoy T, Neczyporenko F, Duttman R, Deprez C, da Costa PM, de Koster E. Perianal Paget's disease: case report and review of the literature. *Acta Gastroenterol Belg*. 2004;67(2):228–231.
99. Amin R. Perianal Paget's disease. *Br J Radiol*. 1999;72(858):610–612.
100. Sarmiento JM, Wolff BG, Burgart LJ, Frizelle FA, Ilstrup DM. Paget's disease of the perianal region—an aggressive disease? *Dis Colon Rectum*. 1997;40(10):1187–1194.
101. Geusau A, Heinz-Peer G, Volc-Platzer B, Stingl G, Kirnbauer R. Regression of deeply infiltrating giant condyloma (Buschke-Lowenstein tumor) following long-term intralesional interferon alfa therapy. *Arch Dermatol*. 2000;136(6):707–710.
102. Chu QD, Vezeridis MP, Libbey NP, Wanebo HJ. Giant condyloma acuminatum (Buschke-Lowenstein tumor) of the anorectal and perianal regions. Analysis of 42 cases. *Dis Colon Rectum*. 1994;37(9):950–957.
103. Renzi A, Giordano P, Renzi G, Landolfi V, Del Genio A, Weiss EG. Buschke-Lowenstein tumor successful treatment by surgical excision alone: a case report. *Surg Innov*. 2006;13(1):69–72.
104. Tan GY, Chong CK, Eu KW, Tan PH. Gastrointestinal stromal tumor of the anus. *Tech Coloproctol*. 2003;7(3):169–172.
105. Nigri GR, Dente M, Valabrega S, et al. Gastrointestinal stromal tumor of the anal canal: an unusual presentation. *World J Surg Oncol*. 2007;5:20.
106. Frisch M, Smith E, Grulich A, Johansen C. Cancer in a population-based cohort of men and women in registered homosexual partnerships. *Am J Epidemiol*. 2003;157(11):966–972.
107. Yuhan R, Orsay C, DelPino A, et al. Anorectal disease in HIV-infected patients. *Dis Colon Rectum*. 1998;41(11):1367–1370.

*This page intentionally left blank*



# LIVER



*This page intentionally left blank*

# HEPATIC ABSCESS AND CYSTIC DISEASE OF THE LIVER

Kathleen K. Christians • Henry A. Pitt

## INTRODUCTION

The differential diagnosis of cystic lesions of the liver includes bilomas, abscesses, parasitic disease, simple cysts, polycystic liver disease (PCLD), biliary cystadenoma, and cystadenocarcinoma.<sup>1</sup> The disease spectrum includes infectious, traumatic, congenital, and neoplastic hepatic lesions that are relatively uncommon. While significant improvements have been made in the diagnosis, treatment, and outcome of many of these cystic hepatic lesions, controversy continues regarding the best treatment option. Many classification systems exist for these lesions; however, the one used in this chapter is presented in Table 43-1.

## PYOGENIC LIVER ABSCESS

The first description of a hepatic abscess is credited to Hippocrates in the year 4000 BC. Ochsner's classic 1938 paper<sup>2</sup> described this disease as one that occurred in young males with pylephlebitis, usually due to appendicitis, and resulting in liver abscess. At that time, pyogenic liver abscesses carried a case-fatality rate of 77%<sup>2</sup> and open surgical drainage remained the treatment of choice for many years. In 1953, McFadzean and associates<sup>3</sup> in Hong Kong advocated closed aspiration and antibiotics for treatment of solitary pyogenic liver abscess; however, this treatment did not gain widespread acceptance until imaging advancements in the 1980s allowed for precise localization and a percutaneous approach to treatment. In recent decades, the predominant etiology of pyogenic liver abscess has changed from pylephlebitis to a biliary origin, and more recent reports from Asia and the United States have noted an increase in incidence of cryptogenic liver abscesses. Fortunately, advanced imaging techniques and improved therapeutic modalities have decreased the case-fatality rate for this disease to 6–26%.<sup>4,5</sup>

## Etiology

Kupffer cells act as a filter for the clearance of microorganisms in the liver. These organisms reach the liver through the bloodstream, biliary tree, or direct extension. Abscesses occur when normal hepatic clearance mechanisms fail or the system is overwhelmed. Parenchymal necrosis and hematoma secondary to trauma, obstructive biliary processes, ischemia, and malignancy also promote invasion of microorganisms.

In order to appropriately treat the abscess, source control is required. Six distinct categories have been identified as potential sources: (1) bile ducts, causing ascending cholangitis; (2) portal vein, causing pylephlebitis from appendicitis or diverticulitis; (3) direct extension from a contiguous disease; (4) trauma due to blunt or penetrating injuries; (5) hepatic artery due to septicemia; and (6) cryptogenic<sup>6,7</sup> (Fig. 43-1).

Biliary disease accounts for 35–40% of all pyogenic liver abscesses, and 40% of pyogenic liver abscesses of biliary origin are related to an underlying malignancy.<sup>6</sup> Obstruction of the biliary tree is the norm, and cholangitis is present in up to one-half of these patients.<sup>8</sup> Intrahepatic stones and related biliary stricture are predominant in Eastern series whereas malignant biliary obstruction is more common in the West.<sup>7</sup> Any manipulation of the biliary tree—namely cholangiography, percutaneous transhepatic stents, endoscopic stent placement, and biliary-enteric anastomoses—also predispose patients to cholangitis and pyogenic liver abscess. Malignancy contributes to poor nutrition and immunosuppression, potentiating the whole process.

Intestinal pathology is responsible for 20% of all pyogenic liver abscesses. Transient bacteremia due to bacterial translocation or frank gastrointestinal perforation causes overwhelming numbers of microorganisms to spread via the portal venous system to the liver. In the preantibiotic era, 43% of Ochsner's 622 patients seeded the liver through the portal vein, and appendicitis was the most common source (34%).<sup>2</sup> Today, appendicitis accounts for only 2% of


**TABLE 43-1: CLASSIFICATION OF CYSTIC HEPATIC LESIONS**

- I. Infectious hepatic cysts
  - A. Pyogenic liver abscess
  - B. Amebic liver abscess
  - C. Hydatid liver cysts
- II. Congenital hepatic cysts
  - A. Simple cysts
  - B. Polycystic liver disease
- III. Neoplastic hepatic cysts
  - A. Cystadenoma
  - B. Cystadenocarcinoma
- IV. Traumatic hepatic cysts

all pyogenic liver abscesses. Diverticulitis, perforated colon cancers, and abscesses elsewhere in the abdomen and pelvis remain common causes of pyogenic liver abscesses. Primary and metastatic liver tumors may also become colonized with enteric flora.

Contiguous extension of gangrenous cholecystitis, perforated ulcers, and subphrenic abscesses is also a reported source for pyogenic liver abscess. In addition, liver trauma causes parenchymal necrosis and clot, which creates an ideal milieu for the seeding and proliferation of microorganisms and subsequent abscess formation. Ablative procedures for tumors can create this same environment. Microorganisms

can then seed these areas of necrosis through intraoperative contamination, biliary-enteric anastomoses, external drains involving the biliary tree, or percutaneous drains placed near the site of trauma or ablation.

Arterial embolization of bacteria via the hepatic artery causes approximately 12% of pyogenic liver abscesses. Intravenous drug abuse accounts for most of these cases, but hepatic artery chemoembolization and umbilical artery catheterization have also been cited. Arterial embolization can also occur from distant infection in the heart, lungs, kidneys, bones, ears, and teeth.<sup>9</sup>

Cryptogenic abscesses occur in 10–45% of patients, depending on the aggressiveness of investigation used to define the source.<sup>9,10</sup> Patients with cryptogenic abscesses usually have comorbidities such as diabetes, immunosuppression, or malignancy. Abscesses in these patients tend to be solitary and usually contain a single anaerobe.

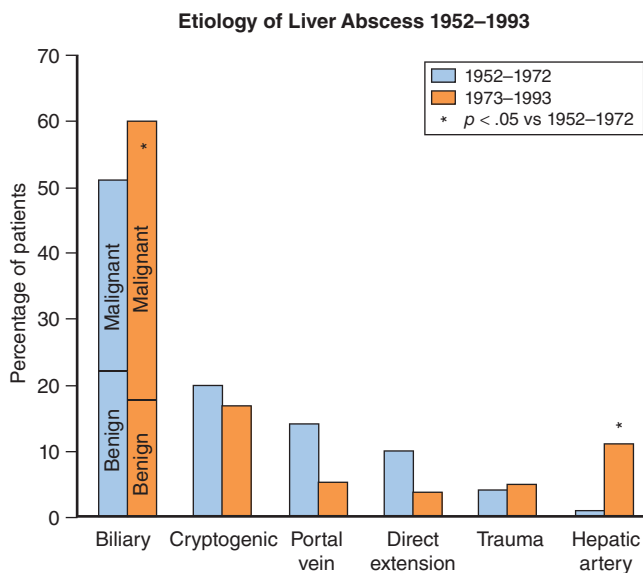
## Incidence

Pyogenic liver abscess affected 5–13 patients per 100,000 admissions before 1970 and accounts for approximately 15 cases per 100,000 admissions today. Seeto and Rocky<sup>11</sup> reported an incidence nearly twofold that of earlier reports (22 per 100,000). This rising incidence is attributed to a more aggressive management approach to hepatobiliary and pancreatic cancers as well as major improvements in diagnostic imaging.<sup>7,12</sup>

## Predisposing Factors

Pyogenic liver abscesses occur more frequently in adults with comorbid conditions, including diabetes mellitus, cirrhosis, pancreatitis, inflammatory bowel disease, pyelonephritis, and peptic ulcer disease. Solid-organ cancers as well as lymphoma and leukemia are present in 17–36% of patients with liver abscesses.<sup>9</sup> Branum and associates reported an increased incidence in patients with underlying malignancy and immunosuppression.<sup>13</sup> Civardi and colleagues<sup>14</sup> as well as Lambiasi and coworkers<sup>15</sup> have reported series of patients with liver abscesses and underlying acquired immune deficiency. The combination of chemotherapy and steroid use is thought to be responsible in these cases.

In addition to comorbidities, age plays a role in the development of pyogenic liver abscess. The age of pyogenic liver abscess patients has increased since 1938. This disease has now become one of the middle-aged and elderly with a reported mean age of 47–65 years. Older patients are more likely to have a biliary etiology or underlying malignancy, whereas younger patients are more likely to be alcoholic males with a cryptogenic origin. Polymicrobial or anaerobic infections with multidrug-resistant organisms, a pleural effusion, inappropriate initial antibiotic selection, and a greater severity of illness on admission occur more frequently in older patients.



**FIGURE 43-1** Comparison of etiology of pyogenic liver abscesses treated during 1952–1972 and 1973–1993 at the Johns Hopkins Hospital. (Reproduced, with permission, from Huang CJ, Pitt HA, Lipsett PA, et al. Pyogenic hepatic abscess: changing trends over 42 years. *Ann Surg.* 1996;223:600–609.)



Underlying malignancy is more prevalent in older patients and is a risk factor for developing anaerobic infections. Age and an APACHE II (Acute Physiology and Chronic Health Evaluation II) score of greater than 15 on admission are risk factors for case fatality in older patients. The case-fatality rate in older patients is related to host conditions, rather than characteristics of the abscess itself. Clinicians should apply an aggressive approach for older patients exhibiting a poor response to primary treatment, particularly in those with a greater severity of illness on admission.<sup>16</sup>

In children, pyogenic liver abscesses tend to occur in the setting of host-defense abnormalities or immune disorders. Complement deficiencies, chronic granulomatous disease, leukemia, and other malignancies place these children at increased risk for liver abscess. Hepatic abscesses are also seen in sickle cell anemia, congenital hepatic fibrosis, PCLD, and after liver transplant (Table 43-2).<sup>9</sup>

### Pathology

The source of the liver abscess is predictive of the number, location, and size of the abscess affecting a given patient. In general, portal, traumatic, and cryptogenic hepatic abscesses are solitary and large, while biliary and arterial abscesses are multiple and small. Huang and associates<sup>7</sup> reported that 63% of patients had abscesses involving the right lobe, 14% had abscesses involving the left lobe, and 22% had bilobar disease. The number of bilateral and multiple abscesses have increased as more patients present with a biliary etiology. Bilateral disease may be seen in 90% of patients with an arterial or biliary source. In contrast, those with intra-abdominal infections frequently present with right lobe abscesses due to preferential flow from the superior mesenteric vein. Fungal abscesses are usually multiple, bilateral, and miliary.<sup>9</sup>

**TABLE 43-2: PREDISPOSING FACTORS FOR PYOGENIC LIVER ABSCESSSES**

Children	Adults
Chronic granulomatous disease	Diabetes mellitus
Complement deficiencies	Cirrhosis
Leukemia	Chronic pancreatitis
Malignancy	Peptic ulcer disease
Sickle cell anemia	Inflammatory bowel disease
Polycystic liver disease	Jaundice
Congenital hepatic fibrosis	Pyelonephritis
Posttransplant liver failure	Malignancy
Necrotizing enterocolitis	Leukemia and lymphoma
Chemotherapy and steroid therapy	Chemotherapy and steroid therapy
Acquired immunodeficiency syndrome	Acquired immunodeficiency syndrome

### Bacteriology

Diagnostic confirmation of a pyogenic liver abscess involves aspiration of the abscess itself and obtaining blood cultures that are positive. Abscess cultures are positive for growth in the majority (80–97%), whereas blood cultures are positive in only 50–60% of cases.<sup>11,14</sup> *Escherichia coli*, *Klebsiella* species, enterococci, and *Pseudomonas* species are the most common aerobic organisms cultured in recent series, whereas *Bacteroides* species, anaerobic streptococci, and *Fusobacterium* species are the most common anaerobes.<sup>12</sup> Huang and colleagues<sup>7</sup> cited the increased use of indwelling biliary stents as the cause of an increasing incidence of *Klebsiella*, streptococcal, staphylococcal, and pseudomonadal species in liver abscesses. They also noted the presence of fungi in 22% of cultures taken between 1973 and 1993 compared to only 1% between 1952 and 1972. Broad-spectrum antibiotic use in the treatment of cholangitis was thought to be the causative factor. *Candida* fungal abscesses are also found in cancer patients who have undergone cytotoxic chemotherapy. *Mycobacterium tuberculosis* is a common infecting organism in the acquired immune deficiency syndrome<sup>8</sup> (Table 43-3).

The species of microorganism found in a hepatic abscess is related to the source. The biliary tree gives rise to abscesses predominantly composed of *E. coli* and *Klebsiella*. *E. coli*, enterococci, and anaerobes are the main organisms

**TABLE 43-3: ORGANISMS ISOLATED FROM PYOGENIC LIVER ABSCESSSES**

Category of Organism	% of Patients
Gram-negative aerobes	50–70
<i>Escherichia coli</i>	35–45
<i>Klebsiella</i>	18
<i>Proteus</i>	10
<i>Enterobacter</i>	15
<i>Serratia</i>	Rare
<i>Morganella</i>	Rare
<i>Acinetobacter</i>	Rare
Gram-positive aerobes	55
Streptococcal species	20
<i>Enterococcus faecalis</i>	10
β-Streptococci	5
α-Streptococci	5
Staphylococcal species	15
Anaerobes	40–50
<i>Bacteroides</i> species	24
<i>Bacteroides fragilis</i>	15
<i>Fusobacterium</i>	10
<i>Peptostreptococcus</i>	10
<i>Clostridium</i>	5
<i>Actinomyces</i>	Rare
Fungal	26
Sterile	7

recovered from abscesses related to the intestinal tract. Anaerobes are the usual microorganisms found in cryptogenic liver abscesses in Western countries. Negative cultures may relate to poor anaerobic culture technique or the use of broad-spectrum antibiotics prior to abscess drainage. In series where careful attention is paid to anaerobic organism recovery, anaerobes may be detected in 10–17%, most often *B. fragilis*.<sup>17</sup> If suspected bacterial cultures are repeatedly negative, amebic and parasitic organisms must be considered because they are difficult to identify by routine staining and culture techniques.<sup>9</sup>

*Klebsiella pneumoniae* is the number one pathogen found in pyogenic liver abscesses in Taiwan and Korea and usually occurs in a monobacterial as opposed to mixed bacterial setting. Investigation into the K antigen serotype revealed that the K1 serotype accounts for 60% of *K. pneumoniae* strains causing liver abscess in these countries. The reason why liver abscess caused by K1 serotype *K. pneumoniae* strains has been emerging has not been elucidated. In contrast, this particular serotype is rarely found in clinical isolates from Western countries. In Taiwan and Korea, the average age to develop a *K. pneumoniae* liver abscess is 55–60 years. These abscesses are twice as likely to be diagnosed in men than in women and are much more likely to be cryptogenic in origin (64%). Diabetes is a known risk factor for developing *K. pneumoniae* liver abscess and is a significant risk factor for embolic complications, especially endophthalmitis.<sup>17,18</sup>

## Diagnosis

The clinical presentation of pyogenic liver abscess is usually subacute and nonspecific, leading to delays in presentation, diagnosis, and treatment. In Seeto and Rocky's review<sup>11</sup> of 142 patients with pyogenic liver abscesses, the classic triad of fever, jaundice, and right upper quadrant (RUQ) tenderness was present in fewer than 10% of patients overall.

## Clinical Presentation

Most patients have fever (92%) and 50% have abdominal pain, but only half have pain in the right upper quadrant. Diarrhea occurs in less than 10% of patients. The liver may be tender (65%) and enlarged (48%), and the patient may appear jaundiced (54%). Other nonspecific complaints include malaise, anorexia, and nausea. If the diaphragm is involved, pleuritic chest pain, cough, or dyspnea may occur. If the abscess ruptures, peritonitis and sepsis may be presenting features<sup>7,8,11</sup> (Table 43-4).

## Laboratory Evaluation

Leukocytosis is present in 70–90%, an elevated alkaline phosphatase in 80%, and an elevated bilirubin and transaminases in 50–67% of patients. Anemia, hypoalbuminemia,



**TABLE 43-4: SYMPTOMS, SIGNS, AND LABORATORY DATA OF PYOGENIC LIVER ABSCESSES**

	% of Pyogenic Abscesses
<b>Symptom</b>	
Fever	83
Weight loss	60
Pain	55
Nausea and vomiting	50
Malaise	50
Chills	37
Anorexia	34
Cough or pleurisy	30
Pruritus	17
Diarrhea	12
<b>Sign</b>	
Right upper quadrant tenderness	52
Hepatomegaly	40
Jaundice	31
Right upper quadrant mass	25
Ascites	25
Pleural effusion or rub	20
<b>Laboratory data</b>	
Increased alkaline phosphatase	87
WBC count >10,000/mm <sup>3</sup>	71
Albumin <3 g/dL	55
Hematocrit <36%	53
Bilirubin >2 mg/dL	24

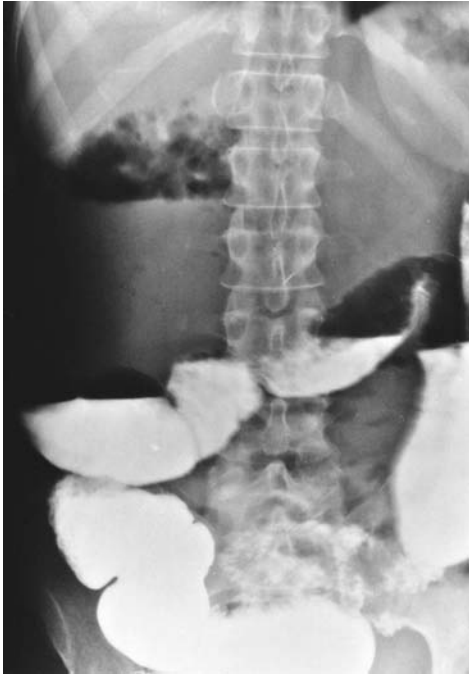
WBC, white blood (cell) count.

and prolonged prothrombin time are seen in 60–75% of patients.<sup>7,8,11,12</sup>

## Radiology

Plain films such as chest radiographs are abnormal in 50% of patients. Findings may include an elevated right hemidiaphragm, a right pleural effusion, and/or right lower lobe atelectasis. Abdominal films may show hepatomegaly, air-fluid levels in the presence of gas-forming organisms, or portal venous gas if pylephlebitis is the source (Fig. 43-2). Ultrasound (US) will distinguish solid from cystic lesions and is cost-effective and portable. US is 80–95% sensitive but has limited utility in the morbidly obese and in lesions that are located under the ribs or located in an inhomogeneous liver.

Computed tomography (CT) is more sensitive (95–100%) than US in detecting hepatic abscesses. On CT examination, an abscess is of lower attenuation than the surrounding liver, and the wall of the abscess may enhance with intravenous

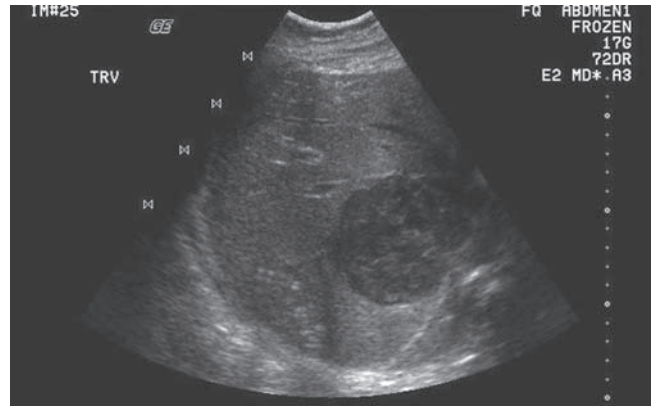


**FIGURE 43-2** Plain film of a barium enema performed on a patient with a large gas-filled abscess located in the right hepatic lobe. (Reproduced, with permission, from Pitt HA. Liver abscess. In: Zuidema GD, Tureotte JG, eds *Shackelford's Surgery of the Alimentary Tract*. 3rd ed. Philadelphia, PA: WB Saunders; 1991:444.)

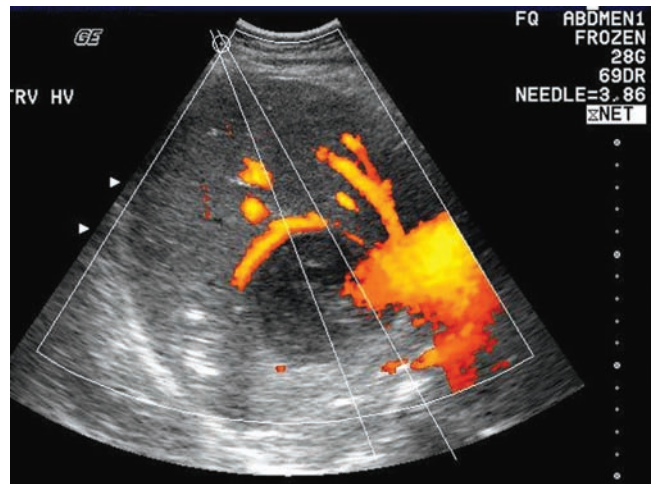
contrast administration. Lesions are detectable to around 0.5 cm with CT and are not limited by shadowing from ribs or air. CT and US may be used to evaluate and potentially treat the source of infection by percutaneous drainage (Figs. 43-3A and B; Figs. 43-4A through 4-4C). Radionuclide scanning with technetium 99m ( $^{99m}\text{Tc}$ ) is no longer used and has been completely replaced by CT and US. On the other hand, cholangiography, usually through an indwelling biliary stent, may visualize the abscess (Fig. 43-5).

## Treatment

The appropriate treatment for pyogenic liver abscesses requires treatment of the abscess itself and concomitant treatment of the source. Drainage of a pyogenic abscess is essential for cure in most cases. Although antibiotics alone may be curative, patients sustain higher risk of failure and complications such as abscess rupture. Percutaneous transhepatic drainage is relatively low-risk and successful treatment method for both polymicrobial liver abscesses and *K. pneumoniae* liver abscesses.<sup>17</sup> Steps in management include antibiotic administration, radiologic confirmation by US or CT, and drainage. Exceptions to this strategy include multiple small abscesses and miliary fungal abscesses. These abscesses are treated with intravenous antibiotics and antifungals respectively, without a drainage procedure.



**A**



**B**

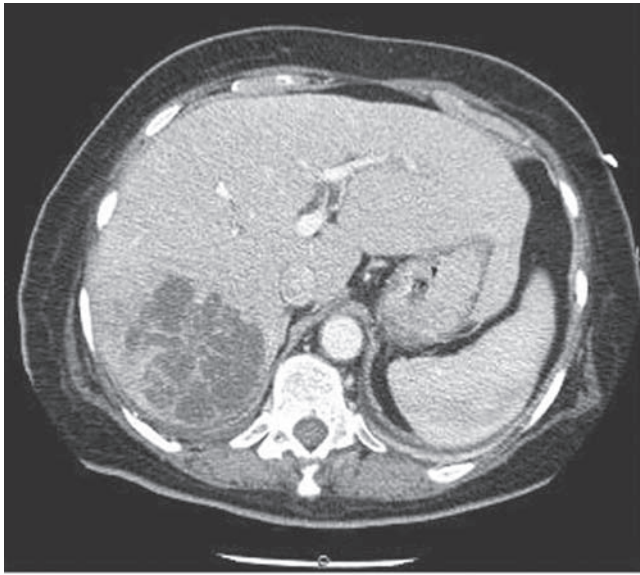
**FIGURE 43-3** **A.** Abdominal ultrasound demonstrating a pyogenic liver abscess. The lesion appears as a low-density collection with small internal echos. **B.** Duplex ultrasound of pyogenic liver abscess with intervening portal vessels blocking safe access to percutaneous drainage.

## ANTIBIOTICS

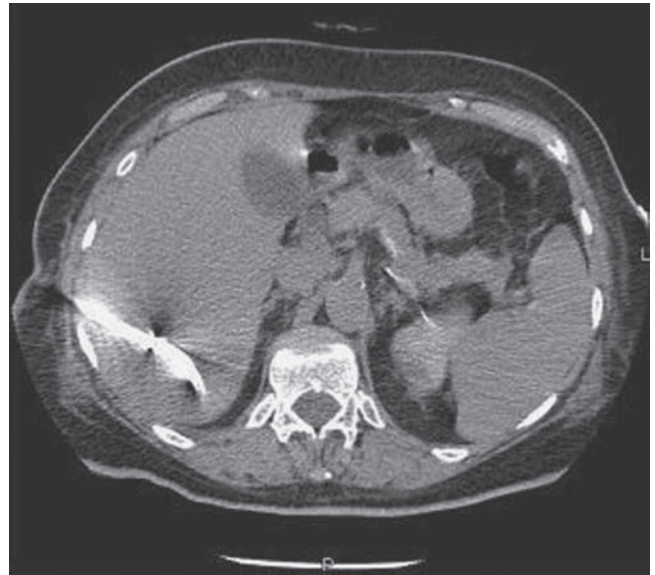
After confirmatory imaging with US or CT, abscesses are aspirated, blood cultures are drawn, and broad-spectrum intravenous antibiotics are administered until sensitivities allow a more selective antibiotic choice. Serologic testing should also be performed if an amebic abscess is suspected.<sup>8</sup>

Classic antibiotic regimens include an aminoglycoside, clindamycin, and either ampicillin or vancomycin. Fluoroquinolones can replace aminoglycosides, and metronidazole can be used instead of clindamycin, especially if an amebic source is suspected. Single-agent therapy with ticarcillin-clavulanate, imipenem-cilastatin, or piperacillin-tazobactam is also acceptable.<sup>12</sup> Treatment used to be given for 4–6 weeks; however, many studies now document success with only 2 weeks of antibiotic therapy.<sup>9</sup> Empiric antibiotics should include anaerobic coverage in

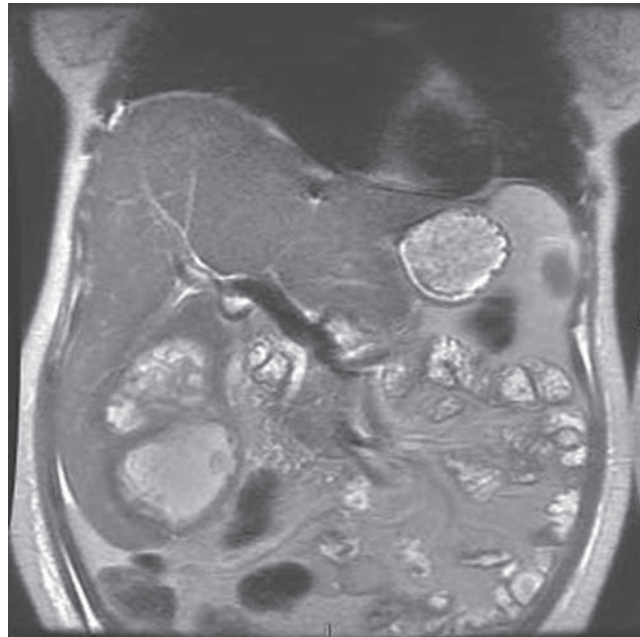




A



B



C

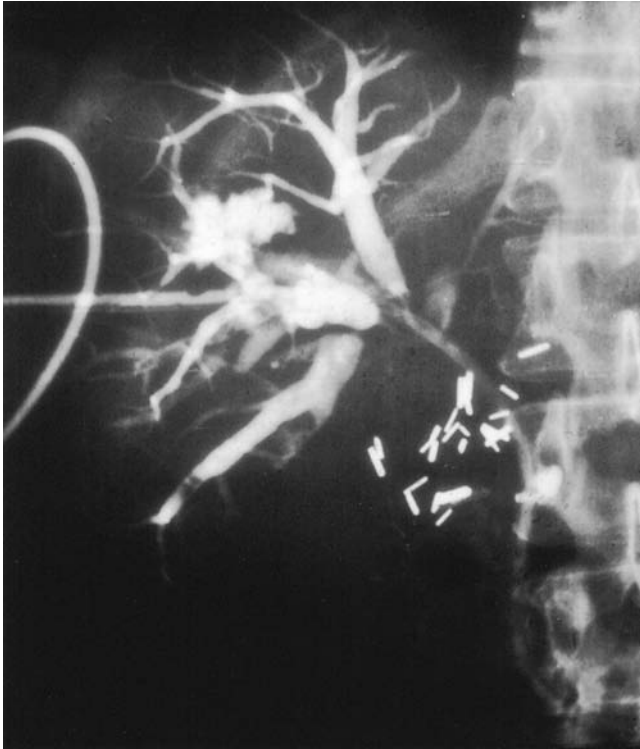**FIGURE 43-4** **A.** Abdominal CT demonstrating a large, low-density pyogenic abscess. **B.** Percutaneous drainage of posterior liver abscess. **C.** MRI of liver abscesses.

older pyogenic liver abscess patients, particularly in the setting of malignancy.<sup>16</sup>

*K. pneumoniae* is intrinsically resistant to ampicillin. Metronidazole is ineffective against aerobic organisms, and regimens containing first-generation cephalosporins have been shown to be inferior in treatment of *K. pneumoniae* liver abscess. A combination of an aminoglycoside and either an extended spectrum  $\beta$ -lactam, such as piperacillin, or second- or

third-generation cephalosporin is preferred for patients with *K. pneumoniae* liver abscess.<sup>17</sup>

In the setting of multiple abscesses of less than 1.5 cm and no concurrent surgical disease, patients may be treated with IV antibiotics alone. However, multiple small abscesses frequently imply biliary tract disease and may require biliary drainage for source control. Similarly, fungal abscesses are miliary in nature and not amenable to percutaneous or surgical drainage.



**FIGURE 43-5** Cholangiogram via a transhepatic stent in a patient with biliary obstruction secondary to recurrent gastric cancer. It shows a communicating liver abscess.

## ANTIFUNGALS

Candidal liver abscess is a rare disease reported most commonly in patients with hematologic malignancies during periods of neutropenia resolution. Most of the candidal liver abscesses in patients with hematologic malignancies are a manifestation of disseminated candidiasis and have high mortality rates. They can also be acquired by fungemia from the portal vein or an ascending retrograde infection from the biliary tree. In patients with hematologic malignancies, the yield of positive culture is often less than 50% with the diagnosis usually based on microscopic examination or histopathology from deep tissues. Higher doses of amphotericin B (2–9 g) are recommended by most experts because a cumulative dose of less than 2 g correlated with residual lesions at autopsy. Cases of hepatosplenic candidiasis have been successfully treated with fluconazole. Symptoms improved at 3–8 weeks, but resolution of the lesions on CT scan was noted after at least 1 month of fluconazole.<sup>19</sup>

*Candida glabrata* often has reduced susceptibility to both azoles and amphotericin B, and opinions on best therapy are divided. Both *C. Krusei* and *C. glabrata* appear susceptible to caspofungin, and this agent appears to be a good alternative. Although fungemia due to *C. glabrata* has been treated successfully with fluconazole (6 mg/kg/d), many experts prefer amphotericin B deoxycholate (>0.7 mg/kg/d). On the basis of pharmacokinetics predictions, fluconazole (12 mg/kg/d; 800 mg/d for the 70-kg patient) may be a suitable alternative, particularly in less critically ill patients.<sup>20</sup>

## ASPIRATION AND PERCUTANEOUS CATHETER DRAINAGE

Needle aspiration and percutaneous catheter drainage of liver abscesses have similar mortality rates; however, recurrence rates and the requirement for surgical intervention may be greater in those who undergo aspiration alone.<sup>11</sup> Needle aspiration is less invasive, less expensive, and avoids all of the complications associated with catheter care. Giorgio and colleagues<sup>21</sup> reported a series of 115 patients with a 98.3% success rate for needle aspiration, no mortality, and no procedure-related morbidity. A randomized controlled trial by Rajak et al<sup>22</sup> in 1998 compared percutaneous needle aspiration to catheter drainage and also found no major complications and no deaths. They did, however, report only 60% success with needle aspiration versus a 100% success rate with catheter drainage.<sup>22</sup> The highest rate of recurrence (15%) occurred in patients with biliary tract disease and obstructive lesions, whereas the recurrence rate with cryptogenic abscesses was less than 2%. This observation suggests that the underlying lesion should influence the type of therapy chosen.<sup>11</sup>

Patients in whom percutaneous drainage is not appropriate include those with (1) multiple large abscesses; (2) a known intra-abdominal source that requires surgery; (3) an abscess of unknown etiology; (4) ascites; and (5) abscesses that would require transpleural drainage.<sup>6</sup> An example of a patient managed by percutaneous drainage is provided in Figs. 43-6A through 43-6D.

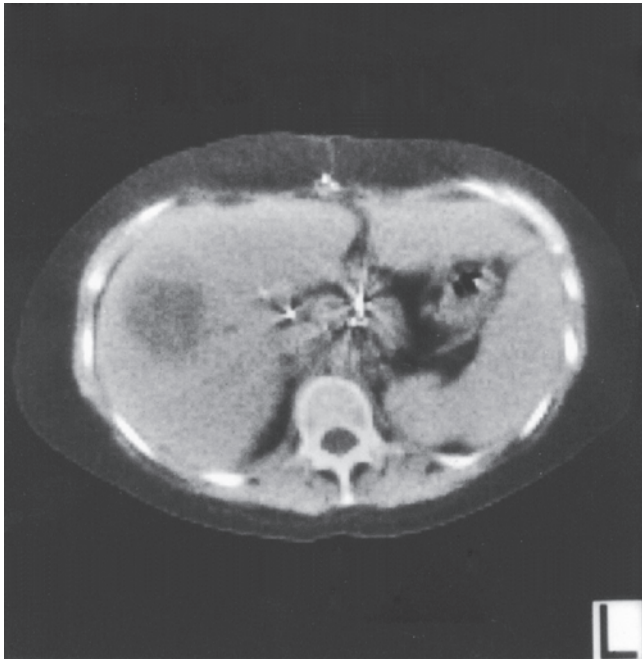
## SURGICAL DRAINAGE

Surgical drainage was the widely accepted treatment for liver abscesses for many years following Ochsner's 1938 report.<sup>2</sup> Abscesses were drained extraperitoneally via a 12th rib resection to avoid contamination of the peritoneal cavity. With the advent of systemic antibiotics, transperitoneal surgical exploration also was considered a safe surgical approach. The transperitoneal approach advantages include the ability to: (1) treat the inciting pathology in the remainder of the abdomen/pelvis; (2) gain access and exposure of the entire liver for evaluation and treatment; and (3) access the biliary tree for cholangiography and bile duct exploration.

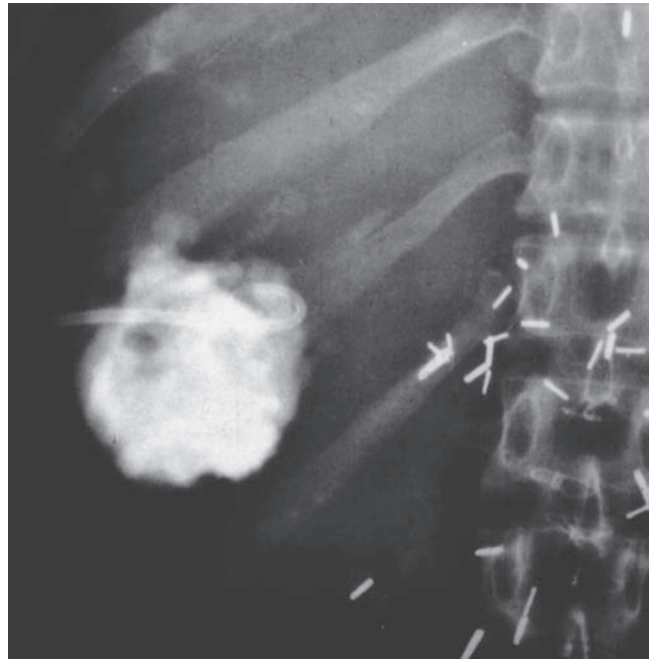
Since the 1980s, treatment has shifted to a less invasive approach using percutaneous needle aspiration or catheter drainage to treat pyogenic abscesses. Surgical drainage is currently reserved for patients who have failed nonoperative therapy, those who need surgical treatment of the underlying source, those with multiple macroscopic abscesses, those on steroids, or those with concomitant ascites.<sup>7</sup>

## Complications

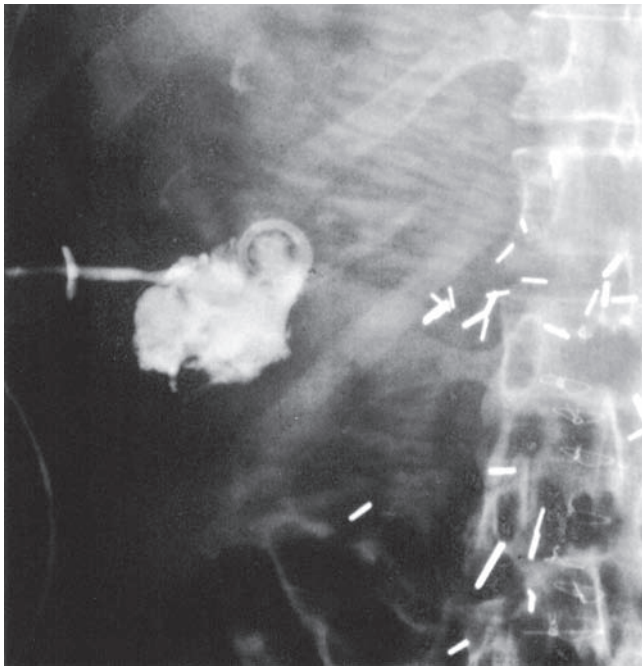Up to 40% of patients develop complications from pyogenic liver abscesses, with the most common being generalized sepsis. In addition to sepsis, morbidity can include pleural effusions,



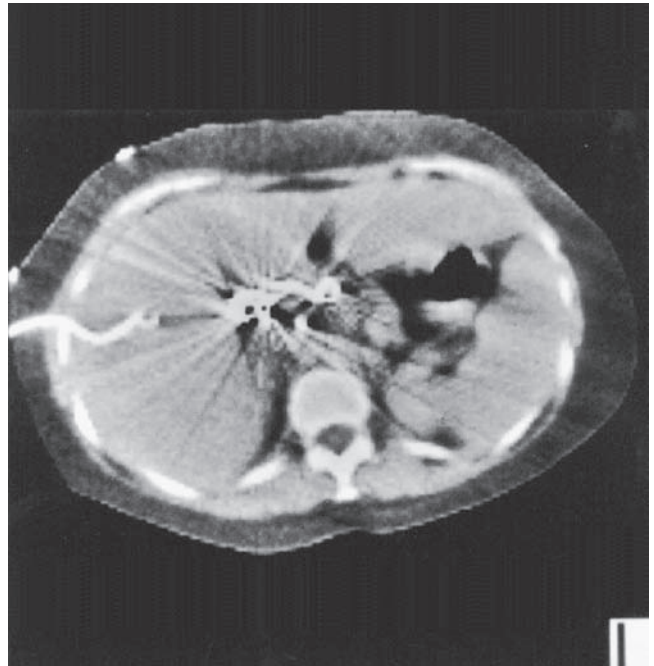
A



B



C



D

**FIGURE 43-6** **A.** CT demonstrating a pyogenic abscess in the right hepatic lobe. **B.** Contrast injected into the abscess cavity through a percutaneously placed drainage catheter. **C.** Sinogram performed 2 weeks later revealing a decrease in the size of the abscess cavity. **D.** CT after 4 weeks demonstrating complete resolution of the abscess. (Reproduced, with permission, from Pitt HA. Liver abscess. In: Zuidema GD, Tureotte JG, eds. *Shackelford's Surgery of the Alimentary Tract*. 3rd ed. Philadelphia, PA: WB Saunders; 1991:444.)



empyema, and pneumonia. Abscesses may also rupture intraperitoneally, which is frequently fatal. Usually, however, the abscess does not rupture but develops a controlled leak, resulting in a perihepatic abscess. Pyogenic abscesses may also cause hemobilia and hepatic vein thrombosis.<sup>9</sup>

Bacteremia is extremely common (95%) in *K. pneumoniae* liver abscess as opposed to other types of pyogenic liver abscesses (50%). As a result, end-organ seeding and distant abscesses are common. Extrahepatic abscesses occur in 7–12% of patient with *K. pneumoniae* liver abscesses with the most commonly reported organ being the eye. Endophthalmitis occurs in to 6–61% of cases and commonly occurs after liver abscess drainage. Disseminated intravascular coagulation (DIC), septic pulmonary emboli, and acute renal failure are also well-accepted complications of *K. pneumoniae* liver abscess.<sup>17</sup>

## Outcome

Between the 1950s and 1990, mortality rates varied from as low as 11% to as high as 88%.<sup>6</sup> High mortality rates came from delay or failure to diagnose the abscess, failure to detect smaller intrahepatic abscesses, ineffective surgical drainage, lack of source control, associated malignancy, immune insufficiency, or other major comorbid conditions. No general consensus has been reached regarding risk factors due to the variability of the patient population being studied (Table 43-5).

The prognosis for *K. pneumoniae* is better than that for other pyogenic liver abscesses regarding mortality (6–17%) and disease relapse. Prognosticators for mortality in *K. pneumoniae* liver abscess include abscess more than 5 cm, concomitant sepsis, intrahepatic gas formation, APACHE III score of more than 40, delayed/inadequate abscess drainage, use of antimicrobials alone, thrombocytopenia, and diabetes.<sup>17</sup> The main concern in this type of liver abscess is no longer mortality but catastrophic disability due to irreversible ocular or neurological complications. The *K. pneumoniae* genotype K1 is an emerging pathogen capable of causing septic ocular or central nervous system (CNS) complications from pyogenic liver abscess independent of host underlying diseases.<sup>18</sup> The outcome for

patients who develop endophthalmitis is grim because despite rapid intervention, visual acuity outcome is poor.<sup>17</sup>

## AMEBIC LIVER ABSCESS

Amebic liver abscess is caused by the parasitic protozoan *Entamoeba histolytica*. The disease was described in association with blood and mucus diarrheal stools in the fifth century BC by Hippocrates and other practitioners. In 1890, Sir William Osier described the first North American case when, after an attack of dysentery while in Panama, a physician's stool and abscess fluid were both found to contain amebae. Councilman and LaFleur of Johns Hopkins Hospital went on to detail the pathogenic role of amebae and coined the terms "amebic dysentery" and "amebic liver abscess" in 1891.<sup>23</sup> Amebic liver abscess is the most common extraintestinal form of invasive amebiasis and an estimated 100,000 people succumb to this disease each year.<sup>24</sup>

## Etiology

Two species of ameba infect humans. *Entamoeba dispar* is associated with an asymptomatic carrier state and not with disease. *E. histolytica* is responsible for all forms of invasive disease. The life cycle involves cysts, invasive trophozoites, and fecally contaminated food or water to initiate the infection.<sup>25,26</sup> Fecal-oral transmission occurs; the cyst passes through the stomach into the intestine unscathed, and pancreatic enzymes start to digest the outer cyst wall. The trophozoite is then released into the intestine and multiplies there. Normally, no invasion occurs, and the patient develops amebic dysentery or becomes an asymptomatic carrier. In a small number of cases, the trophozoite invades through the intestinal mucosa, travels through the mesenteric lymphatics and veins, and begins to accumulate in the hepatic parenchyma, forming an abscess cavity. Liquefied hepatic parenchyma with blood and debris gives a characteristic "anchovy paste" appearance to the abscess.<sup>12</sup>

## Incidence

Worldwide, an estimated 500 million people are carriers of *E. histolytica* or *E. dispar*, 50 million people have active disease and 50,000–100,000 die annually. The vast majority of these infections are acquired in the developing world. Amebiasis is common in Africa, Indochina, and Central and South America. Up to 5% of diarrheal illness in Mexico is due to *Entamoeba* disease.<sup>25</sup> The overall prevalence in the United States is 4% per year. High-risk groups in the United States include sexually active homosexual men, immigrants, tourists who travel to endemic areas, institutionalized people, and those with human immunodeficiency virus (HIV).<sup>27</sup> Children also have been known to infect entire families. Amebiasis follows a bimodal age distribution. One peak is

**TABLE 43-5: FACTORS ASSOCIATED WITH A POOR OUTCOME IN PATIENTS WITH PYOGENIC LIVER ABSCESSSES**

Age >70 y	WBC count >20,000/mm <sup>3</sup>
Diabetes mellitus	Increasing bilirubin
Associated malignancy	Increasing SGOT
Biliary etiology	Albumin <2 g/dL
Multiple abscesses	Aerobic abscess
Septicemia	Significant complication
Polymicrobial bacteremia	

SGOT, serum glutamic oxaloacetic transaminase; WBC, white blood (cell) count.

at age 2–3 years, with a case-fatality rate of 20%, and the second peak is at over the age of 40 years, with a case-fatality rate of 70%.<sup>25</sup> Those living in developing countries have a greater risk and an earlier age of infection than those in developed regions. Low socioeconomic status and unsanitary conditions are significant independent risk factors for infection.<sup>27</sup> Amebic liver abscess is 10 times as common in men as in women and is a rare disease in children.<sup>26</sup>

## Pathology

Roughly 90% of people who become infected with *E. histolytica* are asymptotically colonized, and factors that control the invasiveness of this organism are not completely understood. *E. histolytica* cysts can last for days in a dried state at temperatures of 30°C. These cysts are resistant to the effects of gastric acid pH but become stimulated to form trophozoites in the alkaline pH of the bowel. Trophozoites are found in the colon and in the feces of humans and mammals. Humans become reservoirs, and transmission occurs by ingesting food and water contaminated with amebic cysts, or occasionally through person-to-person contact. Incubation takes 1–4 weeks. Left untreated, asymptomatic individuals may shed cysts for many years.

Invasive amebiasis can include anything from amebic dysentery to metastatic abscesses. The most common form of the invasive disease is colitis. The majority (70–80%) of patients experience a gradual onset of symptoms with worsening diarrhea, abdominal pain, weight loss, and stools containing blood and mucus. Trophozoites invade and induce apoptosis in colonic mucosa, resulting in “buttonhole” ulcers with undermined edges. Trophozoites are actually found in the edge of the ulcers.

The most common extraintestinal site of amebiasis is the liver, occurring in 1–7% of children and 50% of adults (usually males) with invasive disease.<sup>25</sup> Trophozoites reach the liver through the portal system, causing focal necrosis of hepatocytes and multiple microabscesses that coalesce into a single abscess. The central cavity of the lesion contains a homogenous thick liquid that is typically red-brown and yellow in color and similar to anchovy paste in consistency.<sup>28</sup>

## Diagnosis

The definitive diagnosis of amebic liver abscess is by detection of *E. histolytica* trophozoites in the pus and by finding serum antibodies to the ameba.<sup>28</sup> The differential diagnosis should include pyogenic liver abscess, necrotic adenoma, and echinococcal cyst.

### CLINICAL PRESENTATION

Ninety percent of amebic liver abscesses occur in young adult males. The presentation may be acute, with fever and RUQ

pain, or subacute, with weight loss and, less frequently, fever and abdominal pain. The usual case of amebic liver abscess does not present with concurrent colitis, but patients may have had dysentery within the last year. Alcohol abuse is common.<sup>29</sup> Eighty percent of patients with amebic liver abscess present with symptoms that develop within 2–4 weeks, including fever, cough, and a dull aching pain in the RUQ or epigastrium. Diaphragmatic involvement causes right-sided pleural pain or pain referred to the shoulder. Gastrointestinal symptoms of nausea, vomiting, abdominal cramping, abdominal distention, diarrhea, and constipation occur in 10–35%. Hepatomegaly with point tenderness over the liver or subcostal region is common<sup>26</sup> (Table 43-6). In contrast to pyogenic liver abscesses, amebic liver abscesses are more likely to occur in males younger than 50 years who have immigrated or traveled to a country where the disease is endemic. The patient will also not be jaundiced or have biliary disease or diabetes mellitus<sup>26</sup> (Table 43-7).

### LABORATORY EVALUATION

Patients may present with a mild to moderate elevation of the white blood cell count and anemia. Acutely, alkaline



**TABLE 43-6: SYMPTOMS, SIGNS, AND LABORATORY DATA OF AMEBIC LIVER ABSCESSES**

	% of Amebic Abscesses
<b>Symptom</b>	
Pain	90
Fever	87
Nausea and vomiting	85
Anorexia	50
Weight loss	45
Malaise	25
Diarrhea	25
Cough or pleurisy	25
Pruritus	<1
<b>Sign</b>	
Hepatomegaly	85
Right upper quadrant tenderness	84
Pleural effusion or rub	40
Right upper quadrant mass	12
Ascites	10
Jaundice	5
<b>Laboratory data</b>	
Increased alkaline phosphatase	80
WBC count >10,000/mm <sup>3</sup>	70
Hematocrit <36%	49
Albumin <3 g/dL	44
Bilirubin >2 mg/dL	10

WBC, white blood (cell) count.

**TABLE 43-7: DISTINGUISHING CLINICAL CHARACTERISTICS OF PATIENTS WITH HEPATIC ABSCESSSES**

Amebic	Pyogenic
Age <50 y	Age >50 y
Male:female ratio 10:1	Male:female ratio 1:1
Hispanic descent	No ethnic predisposition
Recent travel to endemic area	Malignancy
Pulmonary dysfunction	High fevers
Abdominal pain	Pruritus
Diarrhea	Jaundice
Abdominal tenderness	Septic shock
Hepatomegaly	Palpable mass

phosphatase will be normal and alanine aminotransferase levels will be elevated. The opposite is true in patients with chronic disease.<sup>26</sup> Jaundice is rare. Because amebic abscesses involve destruction of liver parenchyma and are often larger than pyogenic liver abscesses, patients may have an elevated prothrombin time.<sup>9</sup> If colitis is present, wet mount preps of stool samples contain trophozoites 30% of the time in one sample and 70% of the time if three samples are tested. Liver abscesses are associated with positive stool samples in 40–50% of cases.<sup>25</sup>

## RADIOLOGY

Chest radiographs are abnormal in two-thirds of patients with amebic liver abscess and frequently show pleural effusion, infiltrates, or an elevated hemidiaphragm.<sup>9</sup> Ultrasound, CT, and magnetic resonance imaging (MRI) are all excellent methods for detecting amebic liver abscesses but are nonspecific.<sup>26</sup>

In 75–80% of cases, only a single abscess is present and located in the right lobe. Ten percent are in the left lobe and the rest are multiple. Six percent may present as a caudate lobe abscess. Only 40% have typical sonographic features of amebic liver abscess, and serial scanning shows no change in the ultrasound features despite adequate treatment. The mean time to resolution is 7 months, and 70% have findings that persist for more than 6 months. Eventually, resolution may be complete or result in a small residual cystic cavity that resembles a simple cyst of the liver.<sup>30</sup>

## SEROLOGY

Serum antibodies are positive in 85% of patients with invasive colitis and 99% with liver abscesses.<sup>31</sup> Countries with a high prevalence of amebiasis also have a high prevalence of positive serologies in asymptomatic individuals. Therefore serologies help exclude the diagnosis only in appropriately chosen populations. Patients with *E. dispar* infection will have negative serologies. Biopsies of the edge of an ulcer or the wall of an abscess reveal trophozoites with periodic acid-Schiff stain.<sup>25</sup>

## DIAGNOSTIC ASPIRATION

Serologic data are usually available within 24–48 hours; therefore the need to aspirate a suspected amebic abscess is questionable. Diagnostic aspirations are usually done when amebic serologies are negative and a pyogenic cause needs to be ruled out. The fluid of an amebic abscess is odorless, and Gram stain and cultures are negative. Amebae are recovered in 33–90% of aspirates, and wall scrapings increase the yield.

The diagnosis of invasive amebiasis is most commonly attempted by a combination of stool testing for ova and parasites (O&P) and serologic testing, possibly coupled with colonoscopy and biopsy of intestinal lesions or drainage of liver abscesses. Numerous studies have demonstrated the inadequacies of microscopic examination for *E. histolytica* for the diagnosis of both amebic colitis and liver abscess. Antigen detection or polymerase chain reaction (PCR) to detect *E. histolytica* in the stool is a better approach than O&P but requires fresh or frozen stool specimens (vs preserved), and PCR is impractical in the developing world. The detection of amebic markers in the sera of patients with amebic colitis and liver abscess remains only a research tool at the present time.<sup>27</sup>

## Treatment

Since the introduction of metronidazole in the 1960s, surgical drainage of amebic liver abscesses has become virtually unnecessary. Drainage procedures, regardless of the approach, are reserved for those cases in which the diagnosis is questionable or when complications occur.

## ANTIBIOTICS

Noninvasive infections can be treated with paromomycin. Nitroimidazoles, especially metronidazole, are the mainstays of treatment for invasive amebiasis. Nitroimidazoles with longer half-lives (secnidazole, tinidazole, and ornidazole) are better tolerated and can be given for shorter periods, but these are not available in the United States.<sup>26</sup> Metronidazole reaches high concentrations in the liver, stomach, intestine, and kidneys. This antibiotic crosses the placenta and blood-brain barrier and is contraindicated in the first trimester of pregnancy. The drug is also excreted in milk; thus breastfeeding should be discontinued during use. Serious side effects are rare. Positive responses to metronidazole should be seen by the third day of treatment. At 5 days, an 85% cure rate is achieved, and this response may be increased to 95% by 10 days. Approximately 5–15% of patients with amebic liver abscess may be resistant to metronidazole.<sup>30</sup> Parasites persist in the intestine in up to 40–60% of patients who get a nitroimidazole; thus nitroimidazole treatment should be followed with paromomycin or diloxanide furoate to cure luminal infection or risk relapse from residual infection in the intestine.<sup>26</sup>

In summary, amebic liver abscess is usually managed by the administration of metronidazole or tinidazole, followed



by treatment with a luminal amoebicide (paromomycin or diloxanide furoate).<sup>24</sup>

### THERAPEUTIC ASPIRATION

Blessmann and colleagues<sup>32</sup> reported a prospective, randomized trial of patients with amebic abscesses that were treated with metronidazole alone or with US-guided aspiration of the fluid plus medication. Fever, RUQ pain, liver tenderness, and laboratory studies such as erythrocyte sedimentation rate, white blood cell count, hemoglobin, C-reactive protein, and abscess size were obtained on admission and daily thereafter. Abscess aspiration resulted in improved liver tenderness within the first 3 days, but no other difference was demonstrable between the two groups. The authors concluded that this minor benefit was insufficient to justify routine needle aspiration. They advocated drug treatment alone for uncomplicated abscesses with a diameter up to 10 cm and located in the right lobe of the liver.

Therapeutic aspiration may occasionally be required as an adjunct to antiparasitic treatment. Drainage should be considered in patients who have no clinical response to drug therapy within 5–7 days or those with a high risk of abscess rupture defined as having a cavity diameter of greater than 5 cm or lesions located in the left lobe.<sup>33</sup> A 2009 Cochrane Review<sup>34</sup> attempted to lay to rest the controversy surrounding percutaneous needle aspiration of uncomplicated amebic liver abscesses. The authors found that percutaneous needle aspiration did not help patients with uncomplicated amebic liver abscess. Benefits were observed in resolution time of pain and tenderness, but no additional benefit was found with percutaneous needle aspiration plus metronidazole versus metronidazole alone for uncomplicated amebic liver abscesses in hastening clinical and radiologic resolution.<sup>34</sup> Bacterial coinfection of amebic liver abscess has been observed; therefore addition of antibiotics, drainage, or a combination of both, to nitroimidazole therapy may be necessary.<sup>26</sup>

### DRAINAGE

Percutaneous or surgical drainage should be reserved for cases in which the diagnosis of amebic liver abscess is in question or when complications occur.

**Percutaneous.** Image-guided percutaneous catheter drainage has replaced surgical intervention as the procedure of choice for decreasing the size of an abscess. Percutaneous drainage remains most useful for treating pulmonary, peritoneal, and pericardial complications. The high viscosity of amebic abscess fluid, however, requires a large-diameter catheter for adequate drainage, and this may cause more discomfort for the patient. Secondary infections related to the indwelling catheter are always a risk of this intervention.<sup>9</sup>

**Surgical.** Surgical drainage of amebic liver abscesses has largely been replaced by antibiotic therapy. The most common

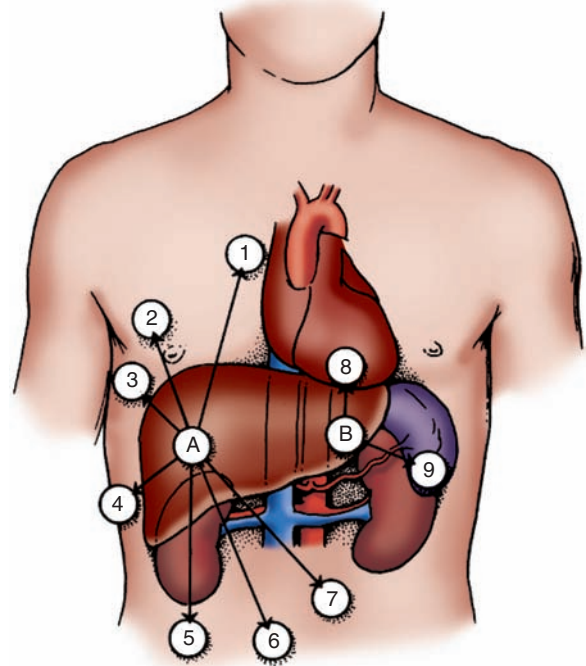
indication for surgical intervention is to manage abscesses that have failed to respond to more conservative therapy. Laparotomy is indicated for life-threatening hemorrhage that may or may not be related to abscess rupture, or when the amebic abscess erodes into a neighboring viscus and control of the involved viscus is necessary. Sepsis due to a secondarily infected amebic abscess also warrants operative intervention if percutaneous treatment fails.<sup>9</sup>

### COMPLICATIONS

Complications from amebic abscesses occur secondary to rupture of the abscess into the peritoneum, pleural cavity, or pericardium (Fig. 43-7). Extrahepatic sites also have been described in the lungs, brain, skin, and genitourinary tract, presumably from hematogenous spread.<sup>26</sup> Ruptured amebic liver abscesses occur in 2–17% of patients and are associated with mortality rates between 12 and 50%.<sup>30</sup>

Peritonitis associated with amebiasis is due to rupture in the majority (78%) and less commonly secondary to necrotizing or perforated amebic colitis (22%). The liver abscess usually adheres to the diaphragm and the anterior abdominal wall, or the omentum and bowel tend to wall it off. Rupture into the colon or stomach also may occur. Free rupture into the peritoneal cavity is uncommon and occurs in moribund patients or those with poor nutrition.<sup>30</sup>

Thoracic amebiasis (empyema, bronchohepatic fistulas, and pleuropulmonary abscess) is the most common complication, followed by pericardial amebiasis (acute pericarditis with



**FIGURE 43-7** Paths of extension of amebic liver abscesses located within (A) the right hepatic lobe (labels 1–7) and (B) the left hepatic lobe (8, 9).

tamponade).<sup>25</sup> Transdiaphragmatic involvement manifests as dyspnea and dry cough. On examination, right basilar crackles and a pleural rub may be heard. Plain films show atelectasis and blunting of the costophrenic angle. If the abscess ruptures into the pleural cavity, it usually occurs suddenly, collapsing the lung, filling up the pleural space, and whiting out the lung on chest x-ray. Treatment requires drainage of the pleural cavity with tube thoracostomy. If the abscess ruptures into the bronchi, this complication causes sudden onset of coughing with expectoration of copious brown sputum. Surgical intervention is not required, as the abscess is usually walled off from the pleural and peritoneal cavities. Postural drainage, bronchodilators, and antiamebic drugs may suffice.

Left lobe abscesses are more likely to involve the pericardium. Complications range from asymptomatic effusions, to cardiac tamponade, to intrapericardial rupture. If pericardial thickening or effusion is noted on imaging, some experts believe that this is an indication for aspiration of a left lobe liver abscess. When tamponade develops, aspiration of the

pericardium, drainage of the liver abscess, and antiamebic drugs are indicated.<sup>30</sup> Cerebral amebiasis is seen in up to 8% of autopsies. These patients are severely ill from sepsis and may experience seizures.<sup>25</sup>

## Outcome

The majority of patients with amebic liver abscess defervesce within 3–4 days of treatment<sup>29</sup>; however, if left untreated, amebic liver abscesses are often fatal. Mortality rates of 0–18% are reported, with higher rates occurring secondary to a delay in diagnosis, or when secondary bacterial infection or complications (abscess rupture) occur. Independent risk factors for mortality include serum bilirubin greater than 3.5 mg/dL, encephalopathy, hypoalbuminemia defined as less than 2.0 g/dL, and the presence of multiple abscess cavities.<sup>35</sup> Abscess aspiration is a risk factor for secondary bacterial infection; however in recent reports, secondary bacterial infection rates have decreased from 10–20% to 0–4% (Table 43-8).

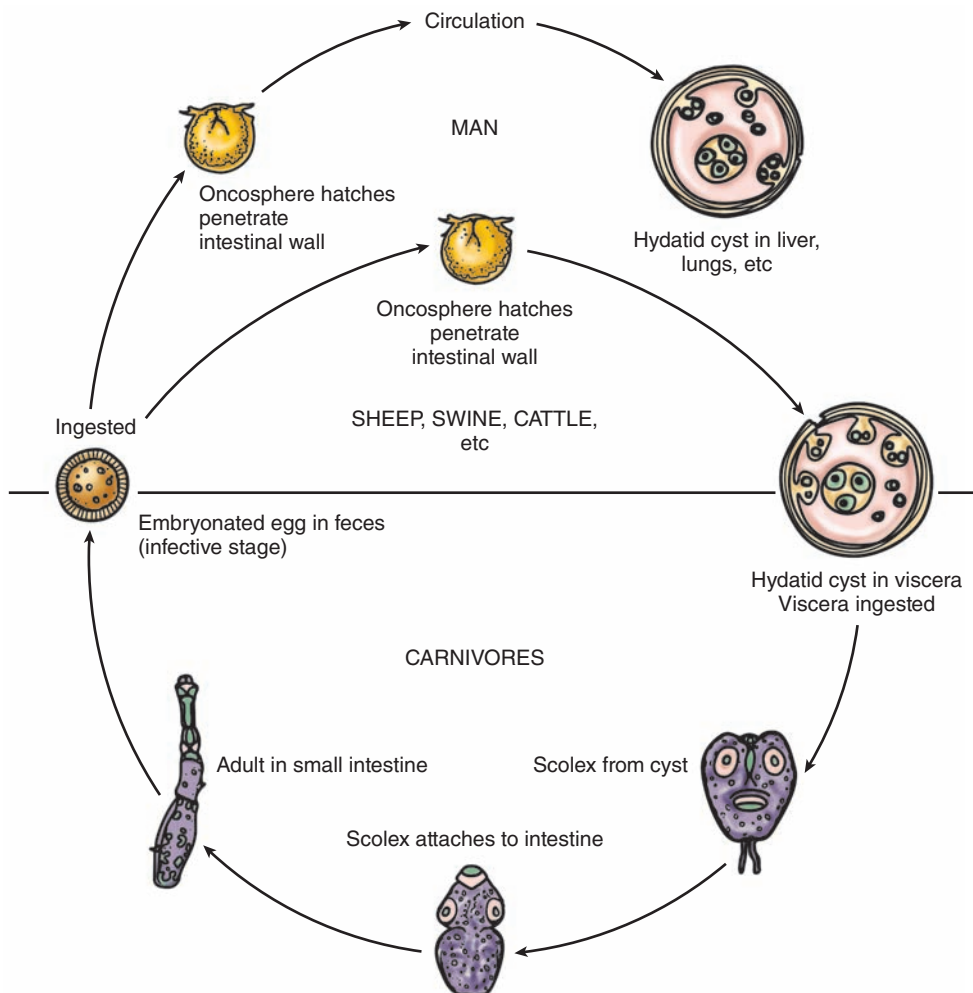


FIGURE 43-8 Life cycle of *Echinococcus granulosus*. (Modified from Melvin DM et al. *Common Blood and Tissue Parasites of Man*. Life Cycle Charts. Atlanta, Georgia: Center for Disease Control, 1979.)

## HYDATID LIVER CYST

Echinococcosis (hydatid disease) is a zoonosis caused by the larval stage of *Echinococcus granulosus* (also known as *Taenia echinococcus*). Humans are accidental intermediate hosts, whereas animals can be both intermediate and definitive hosts. The two main types of hydatid disease are caused by *E. granulosus* and *E. multilocularis*. The former is commonly seen in the Mediterranean, South America, the Middle East, Australia, and New Zealand, and is the most common type of hydatid disease in humans.<sup>36</sup> In humans, 50–75% of the cysts occur in the liver, 25% are located in the lungs, and 5–10% distribute along the arterial system. Infection with echinococcal organisms is the most common cause of liver cysts in the world.<sup>37</sup>

### Etiology

The life cycle of *E. granulosus* has two hosts. The definitive host is usually a dog or some other carnivore. The adult worm of the parasite lives in the proximal small bowel of the definitive host attached by hooklets to the mucosa. Eggs are released into the host's intestine and excreted in the feces. Sheep are the most common intermediate host, and these animals ingest the ovum while grazing. The ovum loses the protective chitinous layer and is digested in the duodenum. The released hexacanth embryo (oncosphere) passes through the intestinal wall into the portal circulation and develops into cysts within the liver. The definitive host eats the viscera of the intermediate host to complete the cycle (Fig. 43-8).

Humans may become intermediate hosts through contact with the definitive host (usually a dog) or by ingestion of contaminated water or vegetables. Once in the liver, cysts grow to 1 cm in the first 6 months and 2–3 cm annually thereafter. Once the parasite passes through the intestinal wall into the portal venous or lymphatic system, the liver is the first line of defense and thus is the most frequently involved organ.

### Incidence

The incidence of hydatid liver cysts in the United States is approximately 200 cases per year, with an increased frequency

in immigrant populations. Hydatid liver disease affects all age groups, both sexes equally, and no predisposing pathologic conditions are associated with infection. Public education about the life cycle and transmission of the disease has helped decrease the incidence. Washing hands after contact with canines, eliminating the consumption of vegetables grown at ground level from the diet, and stopping the practice of feeding entrails of slaughtered animals to dogs have all aided in decreasing the incidence of the disease.<sup>9</sup>

### Pathology

Hydatid liver cysts tend to expand slowly and without symptoms and are thus frequently very large on presentation. Single lesions are noted in 75% and are predominantly located within the right lobe (80%).<sup>36</sup> Even though the lesion is single, half contain daughter cysts and are multilocular.

The typical hydatid cyst has a three-layer wall surrounding a fluid cavity. The outer layer is the pericyst, a thin, indistinct fibrous tissue layer representing an adventitial reaction to the parasitic infection. The pericyst acts as a mechanical support for the hydatid cyst and is the metabolic interface between the host and the parasite. As the cyst grows, bile ducts and blood vessels stretch and become incorporated within this structure. This explains the biliary and hemorrhagic complications of cyst growth and difficulties with resection. Over time, the pericyst calcifies.<sup>9</sup>

The outer layer of the cyst itself is the ectocyst or laminated membrane and is bluish-white, gelatinous, and about 0.5 cm thick. This membrane is a cuticular chitinous structure without nuclei and acts as a barrier for bacteria and an ultrafilter for protein molecules.

The inner layer or endocyst is the germinal membrane, responsible for the production of clear hydatid fluid, the ectocyst, brood capsules, scoleces, and daughter cysts. The endocyst is 10–25  $\mu\text{m}$  thick and attached tenuously to the laminated membrane. The absorptive function of the inner layer is important for cyst nutrition. The inner layer also has a proliferative function producing the ectocyst and scoleces.<sup>38</sup> This germinal layer forms small cellular masses that give rise to brood capsules, in which future worm heads develop. They enlarge and develop into invaginated protoscoleces with four suckers and a double row of hooks—a protoscolex. The protoscolex fully differentiates and matures attached by a pedicle to the capsule wall. Brood capsules and freed protoscoleces are released into the fluid of the original cyst and together with calcareous bodies, form hydatid sand.

Hydatid sand is made up of around 400,000 scoleces per milliliter of fluid. The protoscolex can differentiate in two directions. In the definitive host, the scolex becomes an adult tapeworm. In the intermediate host, including humans, each of the released protoscoleces is capable of differentiating into a new hydatid cyst. Development of brood capsules from the germinal layer indicates complete biologic development of the cyst, which occurs after 6 months of growth.



**TABLE 43-8: FACTORS ASSOCIATED WITH A POOR OUTCOME IN PATIENTS WITH AMEBIC LIVER ABSCESSSES**

Increased age
Increased bilirubin level
Pulmonary involvement
Rupture or extension
Late presentation



Daughter cyst formation is a defense reaction. Hydatid cysts in humans are long-standing, large, and liable to injury. Any injury may cause daughter cyst formation. Daughter cysts are replicas of the mother cyst, and their size and number are variable. In uncomplicated cysts, the cyst cavity is filled with sterile, colorless, antigenic fluid containing salt, enzymes, proteins, and toxic substances.<sup>38</sup> The formation of daughter cysts is called *endogenic vesiculation*.

Ectogenic vesiculation occurs when a small rupture or defect in the laminated membrane occurs and the germinal layer passes through and creates a satellite hydatid cyst. This process is uncommon in *E. granulosus* but is characteristic for the larval stage of *E. multilocularis*. Because the liver parenchyma in humans cannot sequester *E. multilocularis* and the process of ectogenic vesiculation is fulminant, multiple vesicles are formed in all directions. The infected parenchyma has a multilocular appearance, and the center becomes necrotic, spongy, and filled with a gelatinous fluid similar to that of a mucoid liver carcinoma. Hepatic insufficiency is common and the disease is often lethal.<sup>38</sup>

## Diagnosis

The diagnosis of uncomplicated hydatid liver cyst depends on the index of clinical suspicion. Most uncomplicated cysts are asymptomatic. Symptoms may arise due to a toxic reaction from the presence of the parasite or local mechanical effects.

### CLINICAL PRESENTATION

The clinical features of hydatid liver disease depend on the site, size, stage of development, whether the cyst is alive or dead, and whether the cyst is infected.<sup>38</sup> Pain in the RUQ or epigastrium is the most common symptom, whereas hepatomegaly and a palpable mass are the most common signs. Nonspecific fever, fatigue, nausea, and dyspepsia may also be present<sup>39</sup> (Table 43-9). Approximately one-third of patients will have eosinophilia, and only 20% will present with jaundice and hyperbilirubinemia.

### SEROLOGY

No single biochemical test definitively establishes the diagnosis. The Casoni and Weinberg tests are no longer used owing to their low sensitivities. Determination of specific antigens and immune complexes of the cyst with enzyme-linked immunosorbent assay (ELISA) give a positive result in more than 90% of patients. Specific IgE antibodies are demonstrated with ELISA and radioallergosorbent test (RAST) if active disease is present. The arc 5 antibody test involves precipitation during immunoelectrophoresis of the blood of patients with the antigen. Positivity for this test is 91%. Sbihi and colleagues<sup>40</sup> reported that purified fractions enriched in antigens 5 and B and glycoproteins from hydatid fluid yielded a sensitivity of 95% with a specificity of 100%.

**TABLE 43-9: SYMPTOMS, SIGNS, AND LABORATORY DATA OF HYDATID LIVER CYSTS**

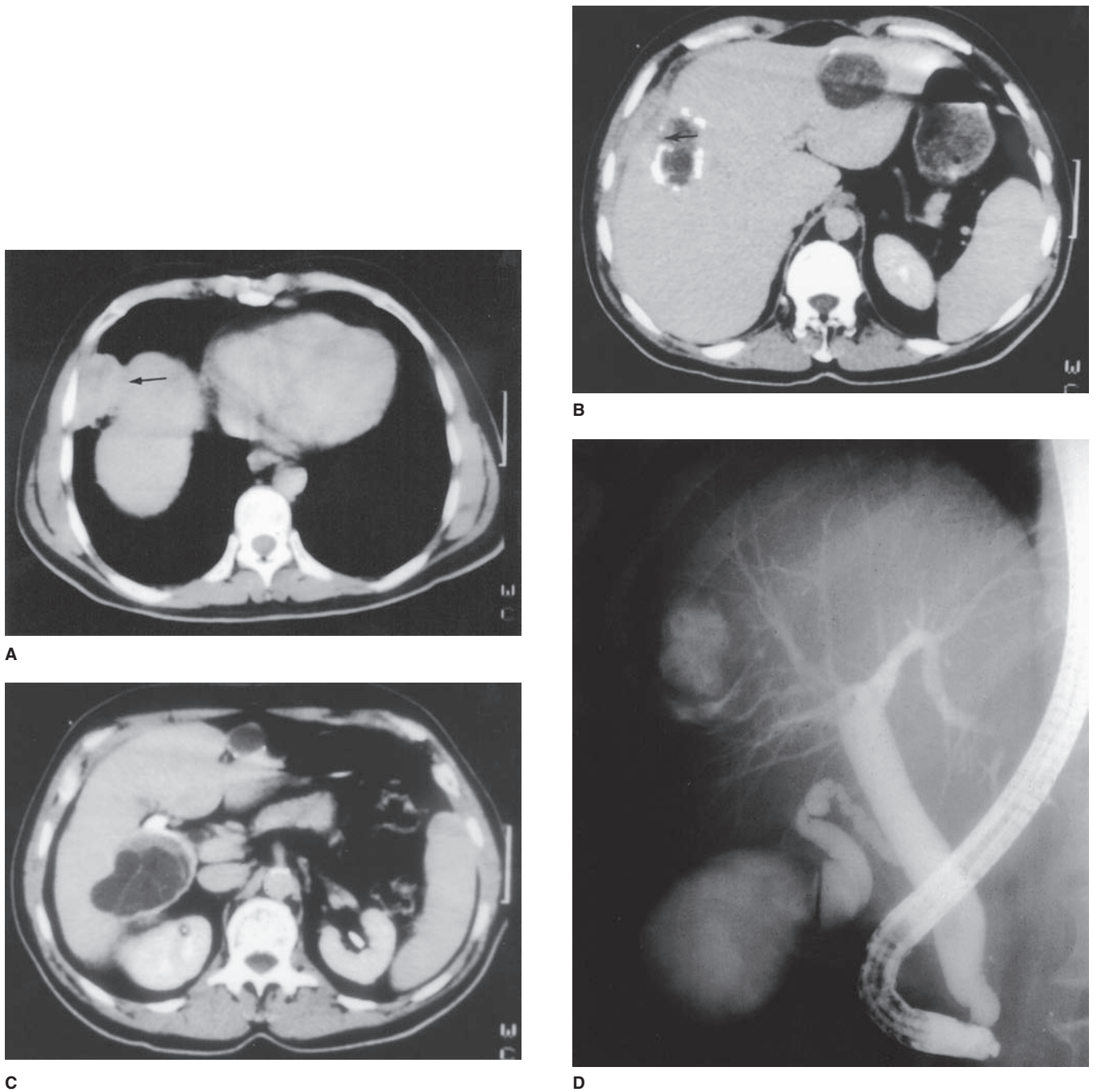
	% of Hydatid Cysts
<b>Symptom</b>	
Asymptomatic	75
Abdominal pain	20
Dyspepsia	13
Fever and chills	8
Jaundice	6
<b>Sign</b>	
Right upper quadrant mass	70
Right upper quadrant tenderness	20
<b>Laboratory data</b>	
Eosinophilia	35
Bilirubin >2 mg/dL	20
WBC count <10,000/mm <sup>3</sup>	10

WBC, white blood (cell) count.

### RADIOLOGY

Chest radiographs may show an elevated diaphragm and concentric calcifications in the cyst wall, but they are of limited value. Ultrasound and CT are considered the first choice for imaging (Figs. 43-9A through 43-9D). Classic findings of hydatid cysts are calcified thick walls, often with daughter cysts.<sup>41</sup> Ultrasound defines the internal structure, number, and location of the cysts and the presence of complications. The specificity of ultrasound in hydatid disease is around 90%.<sup>39</sup> The classification proposed by Gharbi and associates<sup>42</sup> provides a morphologic description. Type I has a pure fluid collection. Type II has a fluid collection with a split wall (floating membrane). Type III reveals a fluid collection with septa (honeycomb image). Type IV has heterogeneous echographic patterns and type V has reflecting thick walls. Differential imaging characteristics of hepatic cysts is presented in Table 43-10.

CT gives similar information to ultrasound, but more specific information about the location and depth of the cyst within the liver. Daughter cysts and exogenous cysts are also clearly visualized, and cyst volume can be estimated. CT is imperative for operative management, especially when a laparoscopic approach is used.<sup>39</sup> MRI provides structural details of the hydatid cyst, but adds little more than ultrasound or CT, and is more expensive. Endoscopic retrograde cholangiopancreatography (ERCP) may show communication between the cysts and bile ducts and can be used to drain the biliary tree before surgery. The routine use of ERCP is advocated by some to completely define the bile duct anatomy and to visualize any clinically silent connections between the bile ducts and cysts.<sup>41</sup>



**FIGURE 43-9** **A.** CT scan demonstrating rupture of hydatid cyst through the diaphragm (*arrow*) into the pleural space. **B.** CT scan in the same patient demonstrating a heavily calcified hydatid cyst (*arrow*) with diaphragmatic penetration and a lightly calcified cyst on the left. **C.** CT scan in the same patient showing a third calcified cyst near the gallbladder fossa and a small superficial fourth cyst on the left. **D.** Endoscopic retrograde cholangiopancreatography (ERCP) in the same patient demonstrating biliary communication in the cyst that also penetrates the diaphragm.

## Treatment

Most echinococcal cysts are asymptomatic on presentation, but potential complications such as pulmonary infection, cholangitis, rupture, and anaphylaxis give good reason to consider treatment for all. Medical, surgical, and percutaneous

approaches may be part of the treatment armamentarium.<sup>41</sup> Small cysts (<4 cm) located deep in the parenchyma of the liver, if uncomplicated, can be managed conservatively.<sup>39</sup> Basic principles include (1) eradication of the parasite within the cyst, (2) protection of the host against spillage of scoleces, and (3) management of complications.<sup>41</sup>



TABLE 43-10: DIFFERENTIAL IMAGING AND CHARACTER OF HEPATIC CYSTS

	Pyogenic	Amebic	Hydatid	Congenital	Cystadenoma
Number	Single or multiple	One or few	Usually single	Single or multiple	Single with loculations
Wall thickness	Thick	Thick	Thick	Thin	Variable
Wall character	Uniform or multiloculated	Usually uniform	Uniform, daughter cysts; 50% calcified	Uniform	Septations common may be irregular
Cyst contents	Usually pus with blood	Red-brown; like anchovy paste	Clear or bilious; gelatinous	Usually clear water density	Usually green-brown mucinous

## ANTIHELMINTICS

Medical therapy for echinococcosis is limited to the benzimidazoles (mebendazole and albendazole) and used alone is only 30% successful. Albendazole is readily absorbed from the intestine and metabolized by the liver to an active form. Mebendazole is poorly absorbed and is inactivated by the liver. Albendazole is thus the drug of choice for medical therapy. Greater success rates may be seen in extrahepatic manifestations of the disease and with the alveolar form caused by *E. multilocularis*. Given for at least 3 months preoperatively, albendazole reduces the recurrence rate when cyst spillage, partial cyst removal, or biliary rupture has occurred. Duration of therapy in these instances is at least 1 month.<sup>41</sup>

## PERCUTANEOUS ASPIRATION AND DRAINAGE

Surgical dictum has stated that percutaneous puncture of a hydatid cyst is a dangerous and contraindicated activity. It was believed that the risk of anaphylaxis, communication with the biliary tree, and spillage outweighed any potential advantages. In 1983, Fornage<sup>43</sup> challenged this axiom and reported an accidental puncture of a hydatid cyst by US that had no clinical consequences. Many successful reports followed thereafter.<sup>38,44</sup> The most frequently used protoscolicidal agents for percutaneous treatment are 15–20% saline, 95% ethanol, a combination of 30% saline and 95% ethanol, and mebendazole solution. PAIR technique stands for *p*uncture of the cyst wall, *a*spirations of cyst content, *i*njection, and *r*e-aspiration of a scolecoidal agent. PAIR involves initial puncture of the cyst under ultrasound or CT guidance, aspiration of cyst content, injection of contrast material to opacify the cyst, infusion of scolecoidal drug, followed by povidone-iodine infusion. The catheter stays clamped for 30 minutes, and then povidone-iodine is infused again. The catheter is preserved for drainage. Except in the case of povidone-iodine infusion, aspiration can be followed by sclerotherapy or infusion of alcohol or a scolecoidal such as albendazole. Recently, a modified PAIR technique was created to introduce concomitant evacuation of cyst contents while infusing scolecoidal agent via a specially designed coaxial catheter system. The simultaneous aspiration/infusion process allows almost complete washout of cyst content, reducing chances of

any scoleces surviving, and the maintenance of the intracystic pressure minimizes risk of biliary fistula formation.<sup>45</sup> The PAIR technique has been combined with albendazole therapy with 70% success rates and a low rate of recurrence. In 1997 Filice and Brunetti<sup>46</sup> reported a series of 163 patients with 231 cysts treated percutaneously. No complications were reported and long-term results were good.

Indications for percutaneous treatment of liver hydatid cysts include types I and II cysts; types III and IV cysts with drainable material; suspected fluid collections; infected hydatid cysts; inoperable patients; pregnant women; and patients with multiple, disseminated, or symptomatic cysts. Contraindications include subgroups of types III and IV (hydatid cysts with heterogeneous echo pattern), ruptured liver cysts into the biliary system or peritoneum, cysts inaccessible to puncture, and children younger than 3 years. Type V cysts are not eligible for any intervention other than simple follow-up. Recurrence rates vary between 0 and 4%. Overall complication rates in percutaneous drainage range from 15 to 40%. Major complications (anaphylactic shock) are rare (0.1–0.2%). Minor complications (urticaria, itching, hypotension, fever, infection, fistula, rupture into the biliary system) range from 10 to 30%. Cyst-biliary complications after PAIR and caused by cyst decompression can be handled endoscopically or by cyanoacrylate infusion. Cholangiography or ERCP is recommended before any attempt for percutaneous drainage to inject contrast material and make any communication visible. Overall mortality rates are as low as 0.1%.<sup>45</sup>

Despite these reports, percutaneous treatment is not benign. Spillage, anaphylaxis, and recurrence can be life threatening. Complete aspiration of all cyst contents, especially multivesicular disease, is difficult, and complete sterilization with protoscolicidal agents is uncertain. If the protoscolicidal agent enters the biliary tree, serious damage also can occur within the liver. Exogenous vesiculation may also go undiscovered. Long-term results are unknown.<sup>38</sup>

## SURGERY

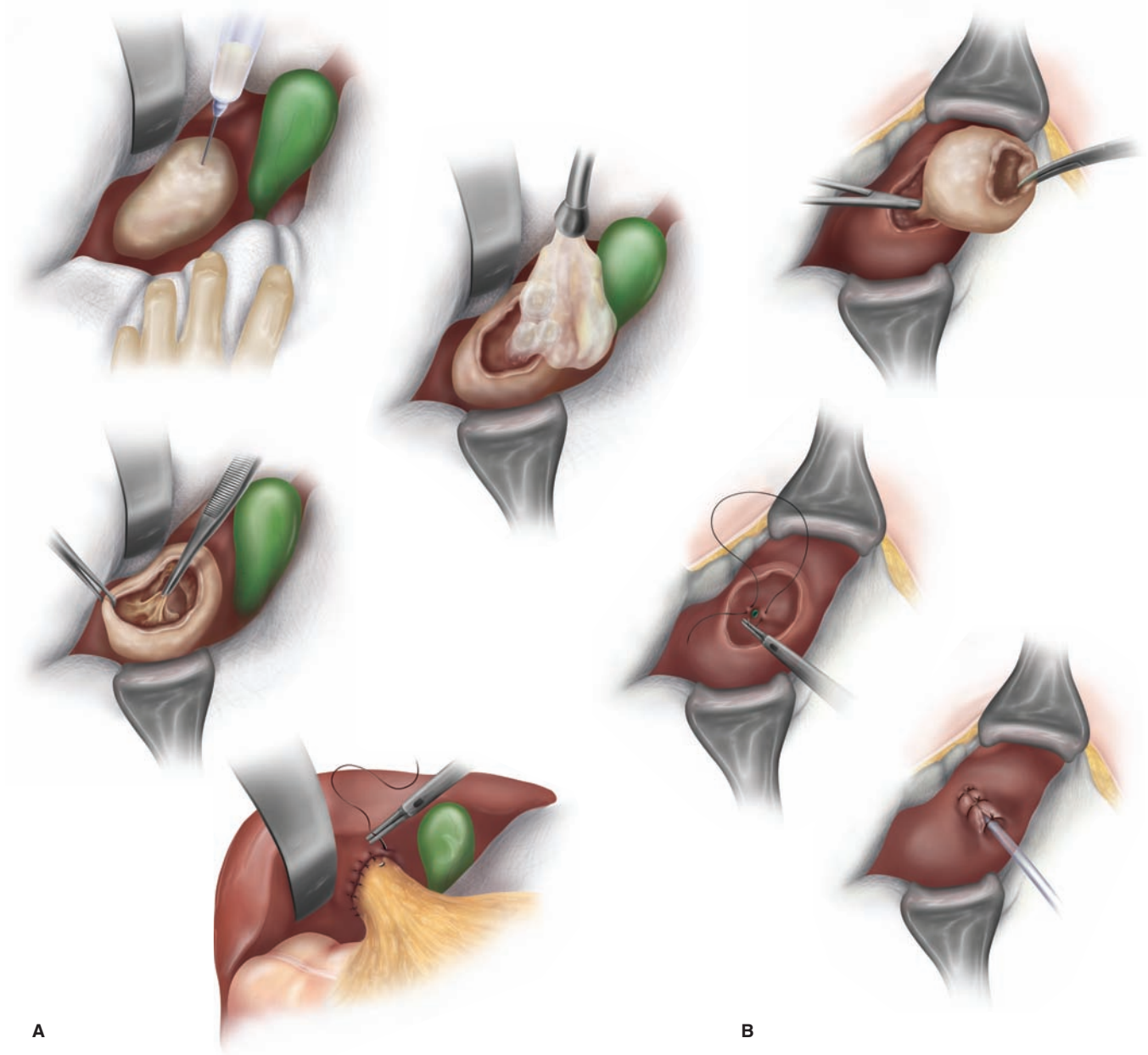Surgery remains the treatment of choice for uncomplicated hydatid disease of the liver, although there is much debate about the most appropriate surgical technique that can offer



total extirpation of the parasites with minimal postoperative complications.<sup>45</sup> The objectives of surgical treatment are to (1) inactivate the scoleces, (2) prevent spillage of cyst contents, (3) eliminate all viable elements of the cyst, and (4) manage the residual cyst cavity. The surgical procedure varies from a radical resective open approach (pericystectomy or hepatic resection) to a conservative approach (drainage or obliteration of the cavity or both) that can potentially even be done laparoscopically<sup>39</sup> (Fig. 43-10). One of the most important end points of hydatid cyst surgery may be recurrence. Dissemination

of protoscolices-rich fluid during surgery and incomplete removal of the germinative membrane from the cyst cavity is a major cause of recurrence (8.5–25%) of postoperative cases.<sup>47</sup>

**Scolicidal Agents.** Early on, surgical management of hydatid cysts via cyst evacuation resulted in a high rate of peritoneal implantation. This problem prompted the use of scolicidal agents for injection into the cyst and for use in the surrounding peritoneum. Formalin, hypertonic saline, chlorhexidine, cetrimide, hydrogen peroxide, polyvinylpyrrolidone-iodine,



**FIGURE 43-10** **A.** Open-cyst evacuation demonstrating cyst aspiration (*upper left*), removal of daughter cysts (*upper right*), resection of active cyst lining (*lower left*), and packing with omentum (*lower right*). **B.** Pericystectomy demonstrating removal of a calcified pericyst (*top right*), closure of a small bile duct (*middle left*), and closure of the cavity over a drain (*lower right*). (Reproduced, with permission, from Cameron JL, Sandove C. *Atlas of Surgery*. Philadelphia, PA: BC Decker; 1990:215–221.)

silver nitrate, and ethyl alcohol are among some of the many agents that have been used.<sup>39,41,45</sup> However, formalin caused sclerosing cholangitis when it entered the biliary tract. Hypertonic saline has to be used carefully to avoid biliary injection and hypernatremia. The safety of the other agents in the biliary tree has not been established. No agent should be injected pre-evacuation due to high intracyst pressure. The World Health Organization (WHO) regards the use of scolicalidal agents for intraoperative killing of infectious material as questionable, as there is no agent that is both effective and safe. According to WHO, ethanol (70–95%), hypertonic saline (15–20%), and cetrimide solution (0.5%) are deemed substances with relatively low risk.<sup>47</sup> Recently, chlorhexidine gluconate 0.04% (Chx-Glu) was found to be nontoxic, without harmful effects on the biliary tract, and is not affected by dilution in the cyst fluid. In addition, Chx-Glu is commonly available, easily prepared, inexpensive, and was 100% effective on protoscolec and germinative membrane, and may become the preferred scolicalidal in the future.<sup>47</sup>

**Open-Cyst Evacuation.** The safest surgical approach is open-cyst evacuation. Peripherally located cysts are the most easily treated, and either abdominal or flank approaches may be used depending on cyst location. Before opening the cyst, the field is lined with hypertonic (20%) saline-soaked gauze to guard against spillage. The cyst is then opened, and the contents are aspirated with a suction device that is capable of generating high negative pressures. The cyst is then opened completely, and any remaining debris is meticulously cleared. The cavity may then be irrigated with a scolicalidal agent.<sup>41</sup> Recurrence rate of this procedure is 10–30%.<sup>45</sup>

**Laparoscopic Cyst Evacuation.** Peripherally located echinococcal hepatic cysts may be safely managed by laparoscopic cyst evacuation.<sup>48</sup> The lesions best suited for this approach are situated anteriorly and do not have thick calcified walls. A right lateral approach also works for cysts in segments VI and VII. A trocar (11 mm) is inserted just above the cyst, and 10% povidone-iodine-soaked sponges are placed as the scolicalidal agent. The cyst is aspirated with a 14-gauge needle. The endocyst then shrinks back from the wall and rests at the bottom of the cyst. The 11-mm trocar is then exchanged for an 18-mm trocar, and the germinal membrane is aspirated. The laparoscopic camera is inserted directly into the cyst to explore for residual daughter cysts or biliary fistulae. The remaining cavity is irrigated with 20% saline solution, and the cyst wall is excised. The cavity may be plugged with omentum or closed over a closed-suction drain.<sup>48</sup>

The most difficult part of the laparoscopic approach is the initial cyst puncture and aspiration of the cyst fluid. Indications for laparoscopic excision of liver echinococcosis have changed over the years. Currently, the only excluding criteria for laparoscopic intervention include deep intraparenchymal cysts or posteriorly situated cysts, more than three cysts, and cysts with thick and calcified walls. Postoperative morbidity ranges from 8 to 25% and mortality in most series is 0%

with recurrence rates of 0–9% (vs 12–63% morbidity, 0–3% mortality, and 0–30% recurrence in open series). Major complications (ie, anaphylaxis) are, however, more common in laparoscopic interventions as a result of peritoneal spillage during debridement and removal of cyst contents. Major drawbacks to the comparison of laparoscopic versus open procedures include the small studies, lack of randomization, and bias related to careful selection of laparoscopic candidates.<sup>45</sup>

**Pericystectomy.** Pericystectomy involves complete resection of the cyst wall without entering the cyst cavity. This procedure is done through a plane outside of the pericyst or along the cyst wall itself. Preoperative localization of the bile ducts and vascular system is imperative. If a bile duct connection is suspected, preoperative ERCP should be obtained. Intraoperative ultrasound should be used. Pericystectomy decreases the risk of spillage of cyst contents into the peritoneal cavity and also lowers the risk of recurrence. The disadvantage to this approach is the potential for bleeding and/or damage to bile ducts in proximity to the cyst wall.<sup>41</sup> Gunay and associates<sup>37</sup> reported 0% recurrence rates, a lower incidence of biliary fistulae, and shorter hospitalization compared with more conservative procedures. The procedure also precludes management of the cavity and facilitates detection of recurrence.

**Liver Resection/Transplantation.** Some experts have argued that formal resection for benign disease is excessive and unnecessary, whereas others have stressed that resection is very safe. Multiple cysts within proximity to a major blood supply or to each other, or a cyst in a relatively safe location (ie, segments II/III) are candidates for resection provided a complete resection can be achieved. *E. multilocularis* infection may also lead to fulminant hepatic failure from sclerosing cholangitis, biliary sclerosis, or Budd-Chiari syndrome, and in these rare cases orthotopic liver transplant may be necessary.<sup>41</sup> Among these various treatment options, criteria for uncomplicated and complicated patients are presented in Table 43-11. A recent study also discovered lymphatic spread of larval *E. multilocularis* from the liver to regional lymph nodes and suggests the routine removal of regional nodes to reduce the risk of persistent infection.<sup>49</sup>

## Complications

Complications from hydatid cysts are seen in one-third of patients. Most commonly, the cyst ruptures internally or externally, followed by secondary infection, anaphylactic shock, and liver replacement, in order of decreasing frequency.<sup>37</sup> Viable hydatid cysts are space-occupying lesions with a tendency to grow. In confined areas such as the CNS, even small cysts can cause severe symptoms. In less confined areas, symptoms depend on the site and size of the cyst. Symptoms result from direct pressure or distortion of neighboring structures or viscera. Compressive atrophy of the surrounding hepatocytes and

**TABLE 43-11: TREATMENT OPTIONS FOR HYDATID LIVER CYSTS**

Uncomplicated Patients	
Percutaneous or Laparoscopic Evacuation	Open Evacuation or Resection
Gharbi type I or II	Gharbi type IV or V
Anterior cysts	Posterior cysts
Peripheral cysts	Central cysts
One to three cysts	More than three cysts
Small cysts	Large cysts
No or minimal calcification	Heavy calcification
Complicated Patients	
Percutaneous or Laparoscopic Evacuation	Open Evacuation or Resection
Infected cysts meeting above criteria	Infected cysts meeting above criteria
Biliary communication—not indicated	Biliary communication—indicated
Pulmonary communication—not indicated	Pulmonary communication—indicated
Peritoneal rupture—not indicated	Peritoneal rupture—indicated

fibrosis occurs, and these cysts may grow to such an enormous size that they replace an entire lobe.

As the cysts enlarge, they may also rupture. If rupture of only the endocyst occurs, the content is retained within the pericyst. A communicating rupture is a rupture into the biliary or bronchial tree.<sup>38</sup> Hydatid liver cysts cause compression of the biliary system leading to decubitus lesions and biliary communication in up to 80% of cases. This communication may be very difficult to find and result in biliary leakage/fistulae postoperatively. Bile leakage is the main source of cavity-related complications in conservative surgery. If not properly drained, this may result in abscess or bile peritonitis. If drained effectively, an external biliary fistula may develop. From 12 to 33.3% with biliary fistulae require biliary drainage postoperatively and rates are higher in conservative versus radical surgery. The complication rates for radical surgery range from 17 to 20%. Retention cysts in conservative surgery may lead to misdiagnosis of early recurrence and result in unnecessary operations.<sup>50</sup>

A free rupture occurs when hydatid contents rupture throughout the peritoneal, pleural, or pericardial cavity. Acute symptomatic rupture into the peritoneal cavity occurs in 1–4% of patients and may precipitate anaphylactic shock.<sup>38</sup>

## Outcome

Medical therapy alone results in recurrence rates of 70–80% and is not recommended. Medical treatment is used in combination with a drainage procedure or in patients who are not surgical candidates. Uncomplicated cases that undergo open surgical, laparoscopic, and percutaneous drainage have recurrence rates around 10%. Early local recurrence and cavity-related complications are the main problems affecting the success of the surgical management of hydatid liver disease. These problems are rare for complete resections due to complete removal of the cyst wall containing the germinal epithelium and daughter cyst. Conservative operations are easier and safer but are associated with a high incidence of local recurrence (10%) and cavity-related complications (37%). Older cysts have an increased risk of exogenic daughter cyst formation, which is an important risk factor for early local recurrence. Another important risk factor for early local recurrence, especially in conservative surgery, is pre- and intraoperative undetected satellite cysts that exist around pericysts or exogenic vesiculations. Because the disease is endemic to many locations, the potential for reinfection remains, so long-term serologic and imaging studies are necessary. Rupture into the pleural or peritoneal cavity portends a recurrence rate of up to 25%.<sup>41</sup>

Uncomplicated cases undergoing elective procedures such as laparoscopic or percutaneous cyst aspiration should have morbidity rates between 15 and 30% and essentially no mortality. In patients with complicated disease that requires open evacuation, pericystectomy, or resection, morbidity is as high as 50%; however, mortality should still remain less than 5%. Septic shock, peritoneal rupture, and comorbid conditions (ie, malnutrition) play a major role in increasing mortality rates.

## CONGENITAL LIVER CYSTS

### Simple

The incidence of simple hepatic cysts in 1695 patients referred for abdominal or pelvic ultrasound was 2.5% with a sharp increase noted at the age of over 60 years.<sup>51</sup> In a separate European study<sup>52</sup> of more than 26,000 patients undergoing upper abdominal ultrasound, simple cysts were found in 2.8%, and most (>92%) were over the age of 40. The female to male ratio was 1.5:1.

Solitary benign cysts are believed to be congenital and thought to arise from abnormal development of intrahepatic bile ducts in utero. The aberrant ducts enlarge slowly and may result in symptoms later in life. In a study from the Mayo Clinic<sup>53</sup> from 1907 through 1971, only 24% of simple cysts were symptomatic, and they usually became symptomatic in the fourth or fifth decade of life. Abdominal pain and mass were noted most frequently and were present in

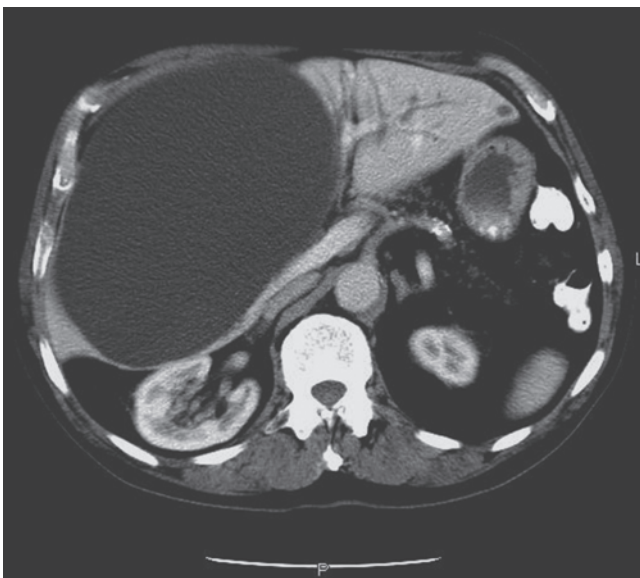


more than 50%. Less commonly, symptoms were related to mass effect, resulting in nausea, vomiting, early satiety, and jaundice. Physical examination revealed hepatomegaly or a palpable abdominal mass. Laboratory values should be normal, but occasionally hyperbilirubinemia may be seen. Simple solitary cysts are bluish in color, and contain clear, straw-colored fluid. Echinococcal disease should be ruled out by serology.<sup>54</sup>

Ultrasound is the most accurate imaging modality, with greater than 90% sensitivity and specificity. On ultrasound, the cysts appear as anechoic masses with smooth margins and thin, imperceptible walls. Ultrasound also differentiates between cystic and solid lesions and can assess for intra- and extrahepatic biliary dilation in the jaundiced patient. CT imaging reveals nonenhancing, fluid (water) density lesions with a thin, uniform wall (Fig. 43-11). On MRI, simple cysts are well-circumscribed lesions that are hypointense on T1-weighted images and hyperintense on T2-weighted images.<sup>52</sup>

Most simple cysts are found incidentally and are asymptomatic, and 80–95% remain asymptomatic. In the setting of symptoms, percutaneous aspiration can aid in diagnosis but is associated with 100% recurrence within a 2-year period. If sclerosants are added, a 17% recurrence rate can be achieved.<sup>54</sup>

Success of surgical treatment for cystic liver disease is judged by relief of symptoms rather than by complete disappearance of the cystic lesion on imaging studies. Once the benign nature of the cyst is established, a permanent internal cyst “drain” is the mainstay of surgical therapy and complete cyst excision is not necessary.<sup>55</sup> If the cyst protrudes from the liver and no biliary connection is demonstrated, the



**FIGURE 43-11** CT demonstrating a large simple cyst compressing the hepatic veins and inferior vena cava and abutting the left portal venous system.

### TABLE 43-12: TREATMENT OPTIONS FOR CONGENITAL LIVER CYSTS

- I. Simple cysts
  - A. Aspiration with sclerosis
  - B. Open surgery
    1. Partial excision
    2. Complete excision
  - C. Laparoscopic surgery
    1. Partial excision
    2. Complete excision
- II. Polycystic liver disease
  - A. Aspiration with sclerosis
  - B. Open surgery
    1. Partial unroofing
    2. Unroofing with resection
    3. Liver transplant

accessible wall on the liver surface may be excised and the remaining cyst lining allowed to drain freely into the peritoneal cavity. If the cyst has a biliary connection, suspicion should be high that the lesion is a biliary cystadenoma rather than a simple cyst. In general, cyst excision or unroofing and resection have a 0–20% recurrence rate and a mortality rate of 0–5% (Table 43-12).<sup>54</sup>

Unroofing the cyst by a laparoscopic approach can also be done with an overall success rate of more than 90% and a 10% rate of symptomatic cyst recurrence. Proponents of the laparoscopic approach report excellent exposure, less postoperative pain, and success rates similar to those of cases done open.<sup>54</sup> Gamblin et al reported the largest series of laparoscopic liver resections for cystic lesions that included 51 patients. The authors routinely left the back wall of the cyst behind and untreated. Patients experienced minimal postoperative pain, short hospital stays (median 2 days, range 1–11) resolution of symptoms (pain resolved in all), had a low recurrence rate (2 of 51 required reoperation), and no 90-day mortalities. Median follow-up was 13 months. A growing body of literature supports the equivalency of many laparoscopic and open procedures regarding outcomes and advantages in avoiding a laparotomy, especially in benign disease. These authors proposed minimally invasive cyst excision as the standard of care for management of these benign hepatic cysts.<sup>56</sup>

## Polycystic

Polycystic liver disease (PCLD) is an autosomal dominant disorder, often found in association with polycystic renal disease (40%).<sup>57</sup> PCLD is the most frequent extrarenal manifestation of autosomal dominant polycystic kidney disease. It also exists in an autosomal dominant pattern that is not associated with polycystic renal disease, but may have cysts that develop in other organs in addition to the kidneys.

Cysts in PCLD are epithelial-lined growths arising from biliary epithelium that usually do not communicate with the biliary tree. The majority of patients are asymptomatic and do not require treatment. Their prognosis is directly related to the severity of the accompanying renal disease.<sup>58</sup>

If PCLD becomes symptomatic, it is usually secondary to hepatomegaly. Symptoms may include abdominal fullness, distention and pain, or bowel and biliary obstruction. Complications such as bleeding, infection, rupture, portal hypertension, and Budd-Chiari syndrome have been reported, but they are rare. Malignant transformation has been reported, but it infrequently occurs. Hepatic function is typically preserved, so progression to liver failure is uncommon.<sup>58</sup>

Routine imaging of cysts in PCLD is similar to that of simple cysts. Unenhanced CTs show multiple, homogenous, hypoattenuating lesions with a regular outline (Fig. 43-12). Contrast-enhanced CT images have no cyst wall or enhancement of cyst contents. MRI demonstrates very low-signal intensity on T1-weighted images and does not enhance after administration of gadolinium. Because the cyst content is purely fluid and homogeneous, high-signal intensity is demonstrated on T2-weighted images.<sup>57</sup>

Development of symptoms in PCLD is most often due to hepatomegaly, and therefore treatment needs to result in a reduction in liver size. Percutaneous aspiration with sclerotherapy may be used in those who are not surgical candidates or in lesions that are not surgically accessible, but long-term results of this approach are poor.

If a small number of large cysts exist, laparoscopic unroofing with the aid of intraoperative ultrasound may be successful. Deeper cysts may be accessed and unroofed through the back wall of more superficially located cysts. However, because the rigid architecture is found in PCLD, unroofing alone may not be enough to provide hepatic collapse and relief of symptoms. In addition, if too many cysts are unroofed, the peritoneum's

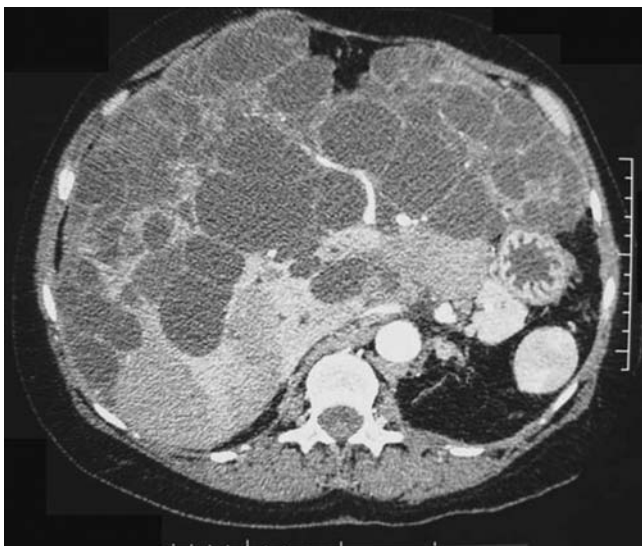

FIGURE 43-12 CT demonstrating polycystic liver disease (PCLD).

absorptive capacity may be exceeded and cause ascites. Unroofing is not useful in patients with a large number of smaller cysts because it cannot be adequately performed.

A combination of cyst unroofing and liver resection may achieve the best results in terms of reducing liver volume. Resection should include the most cysts with the least loss of hepatic function. Morbidity for this approach is greater, but long-term results are improved. Orthotopic liver transplant is occasionally indicated if symptoms are disabling or hepatic function is compromised. If patients have associated renal failure, the liver transplant may be combined with renal transplant.<sup>58</sup>

## NEOPLASTIC CYSTS

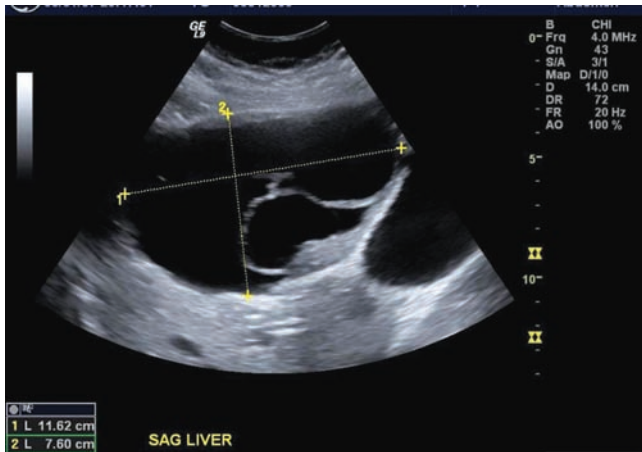
Neoplastic cysts are acquired cysts that occur less commonly than simple cysts, usually in females, in the fifth decade of life. Their etiology is unknown. Cystic neoplasms are frequently large, resulting in abdominal discomfort and a palpable mass on examination. Cystic neoplasms appear as multiloculated lesions with papillary projections inside the cyst cavity. Invasion of the surrounding tissue suggests malignancy, as does the presence of a predominantly solid (vs cystic) component. Ten percent of neoplastic cysts are malignant. Definitive diagnosis requires intraoperative biopsy of the cyst wall. Incomplete resection will result in nearly 100% recurrence.<sup>54</sup>

Laboratory investigation is normal in most, although some patients present with elevated liver enzymes. Serum alpha-fetoprotein (AFP) and carcinoembryonic antigen (CEA) levels are usually normal. In some patients, CA 19-9 has been found to be elevated fivefold. In general, hemorrhagic cyst fluid suggests cystadenocarcinoma, whereas bilious or mucinous fluid suggests cystadenoma.<sup>59</sup>

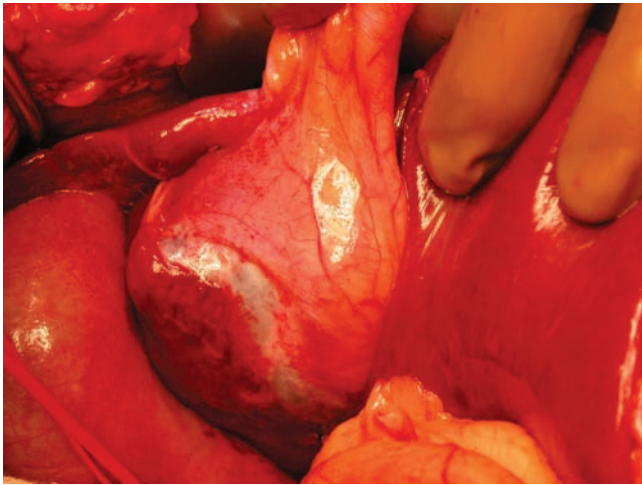
## Cystadenoma

Cystadenomas comprise less than 5% of all intrahepatic cysts of biliary origin.<sup>60</sup> Hepatobiliary cystadenoma with mesenchymal stroma occurs exclusively in young and middle-aged women and has potential to transform into cystadenocarcinoma. In contrast, hepatobiliary cystadenoma without mesenchymal stroma occurs in both sexes equally, at a mean age of 50, and has no clear association with cystadenocarcinoma.<sup>59</sup> These tumors are lined with columnar epithelium and frequently have papillary infoldings<sup>60</sup> (Fig. 43-13, negative path). If symptoms are present, they may include abdominal pain (60–80%), jaundice, cholangitis, fullness, or bloating.<sup>1</sup>

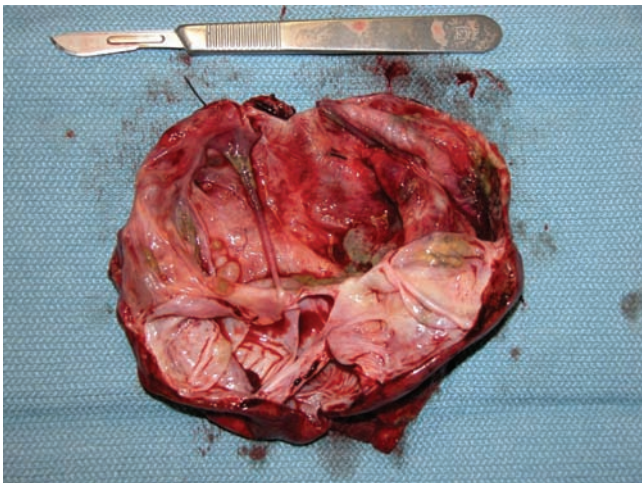
Cystadenomas have a septated, multilocular appearance on US and CT (see Figs. 43-13A through 43-13C).<sup>54</sup> CT will reveal well-demarcated cystic lesions, usually with internal septations; the walls are rarely calcified, and the presence of polypoid protrusions or wall excrescences should trigger the concern for cystadenocarcinoma.<sup>1</sup> MRI shows typical



A



B



C

**FIGURE 43-13** A. Ultrasound demonstrating a septated cystic liver tumor. B. Intraoperative photograph of segment 4 liver cystadenoma. C. Gross photograph of liver cystadenoma after enucleation.

features for a fluid-containing loculated mass with homogeneous low-signal intensity on T1-weighted images and homogeneous high-signal intensity on T2-weighted images. However, signal intensity of mucinous fluids varies depending on protein concentration. On T1-weighted images, the signal intensity may change from hypointense to hyperintense as protein concentration increases. On T2-weighted images signal intensity of mucinous fluids can decrease from hyperintense to highly hypointense with increasing protein concentration and viscosity. Blood products also have different signal characteristics on MRI. The distinction between cystadenoma and cystadenocarcinoma remains difficult on the basis of imaging findings alone as the presence/absence of septae, mural nodules, and papillary projections are variable between lesions. Magnetic resonance cholangiopancreatography (MRCP) does, however, appear helpful in evaluating the relationship of the lesion to bile ducts.<sup>61</sup> ERCP will usually demonstrate communication with the biliary tree, often at the proximal left hepatic duct.

Serum CEA and CA 19-9 levels are usually within normal ranges and cannot be considered as significant parameters to discriminate between malignant and benign liver tumors.<sup>61</sup> The diagnosis of intrahepatic biliary cystadenoma can be suggested on the basis of cyst fluid analysis (CFA), but this relies on adequate sampling and correlation with clinical and radiologic findings. CA 19-9 and CEA have been shown to be elevated in intrahepatic biliary cystadenoma and normal in simple cysts. Immunohistochemical analysis of intrahepatic biliary cystadenoma has shown the presence of CA 19-9 and CEA in the epithelium; however, the premalignant progression is based on the histologic presence of intestinal metaplasia characterized by the presence of numerous goblet cells. This has led to the recommendation that patients with suspected intrahepatic biliary cystadenoma based on CFA should undergo cyst wall sampling to determine whether a premalignant (intestinal metaplasia + atypia) or malignant diagnosis requiring resection exists.<sup>62</sup> Other authors, however, believe that percutaneous biopsy for preoperative diagnosis rarely produces a definitive diagnosis and the risk of peritoneal dissemination in the case of malignancy is prohibitive.

Neoplastic cysts with no signs of malignancy may be enucleated. This technique requires removal of the entire cyst, the cyst's surrounding wall, and a small rim of liver parenchyma.<sup>54</sup> Formal hepatic resection also is an appropriate treatment. Aspiration, sclerosis, marsupialization, and internal drainage must be avoided. Inadequate excision leads to recurrence in all cases<sup>60</sup> (Table 43-13).

### Cystadenocarcinoma

Devaney and colleagues<sup>63</sup> divided cystadenocarcinoma (Fig. 43-14, positive path) into three subtypes: (1) cystadenocarcinoma with mesenchymal stroma arising from cystadenoma with mesenchymal stroma, occurring exclusively in females and following a relatively indolent course; (2)



### TABLE 43-13: TREATMENT OPTIONS FOR NEOPLASTIC LIVER CYSTS

- I. Cystadenoma
  - A. Enucleation
  - B. Hepatic resection
- II. Cystadenocarcinoma
  - A. Hepatic resection
  - B. Palliative unroofing

cystadenocarcinoma without mesenchymal stroma not associated with cystadenoma, occurring in males and following an extremely aggressive course; and (3) cystadenocarcinoma without mesenchymal stroma, occurring in females and with a poorly understood clinical course.<sup>64</sup> Resection is the only appropriate treatment for malignant biliary cystadenocarcinoma.<sup>54</sup> With complete resection, the clinical course for cystadenocarcinoma is better than that for hepatocellular carcinoma or cholangiocarcinoma.<sup>64</sup> In the rare patient with a symptomatic cystadenocarcinoma with peritoneal metastasis, palliative unroofing of the cyst may be indicated.

## TRAUMATIC CYSTS

In recent years, the management of hepatic trauma has undergone major changes. The frequent use of dual-phase CT imaging to assess patients with abdominal trauma has resulted in the detection of even the most minor of liver injuries. In the hemodynamically unstable patient, damage control laparotomy—the control of bleeding and contamination with packing off of the abdomen to postpone definitive treatment—has gained popularity, while formal anatomic hepatic resection has fallen out of favor. More and more

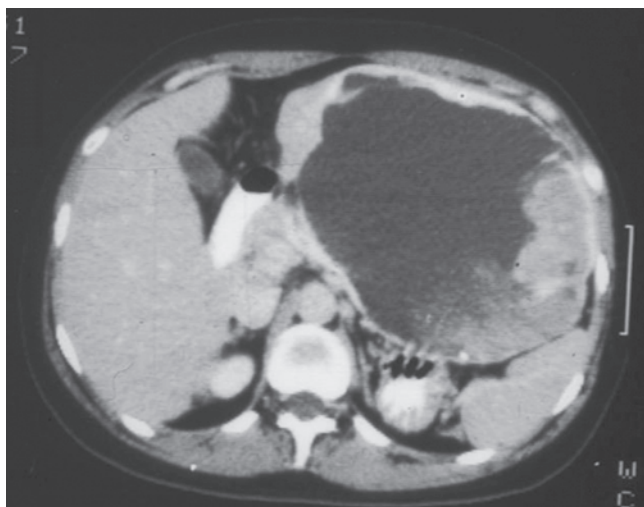
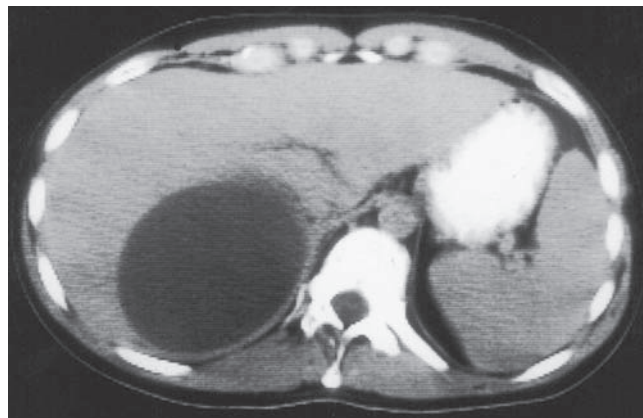


FIGURE 43-14 CT scan demonstrating a cystadenocarcinoma.

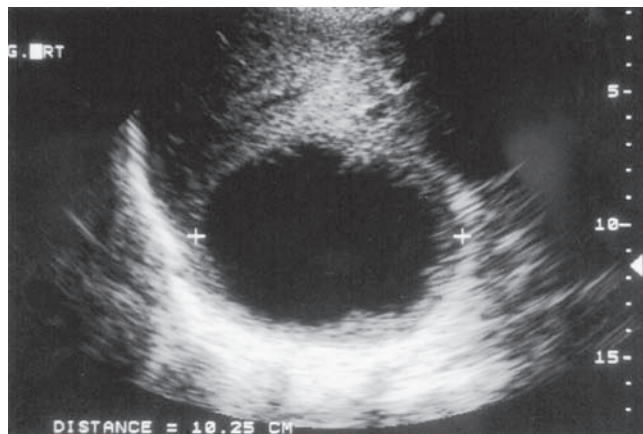
American Association for the Surgery of Trauma grades IV and V liver injuries are also being managed nonoperatively. Mortality rates have fallen to 7–12%,<sup>65</sup> but a different set of management problems is being created. One such problem is the traumatic cyst.

Traumatic cysts are acquired cysts that occur from continued bile leakage from an injured intrahepatic bile duct after abdominal trauma. When an injured biliary structure continues to leak into a hematoma cavity, a cyst containing bile and blood may form.<sup>54</sup> These cysts lack a true epithelial lining and are considered pseudocysts (Fig. 43-15). Some traumatic cysts may resolve spontaneously,<sup>58</sup> while others may grow until compressive symptoms are caused. Presentation is typically delayed, and abdominal pain or fullness may occur months or sometimes years after the trauma.<sup>54</sup>

Because of the proximity of the right hepatic artery to the cystic duct, this artery is vulnerable to injury when the critical view of safety is not achieved during laparoscopic cholecystectomy. Combined injury to the bile duct and hepatic artery during laparoscopic cholecystectomy may result in development of intrahepatic abscess, recurrent cholangitis with



A



B

FIGURE 43-15 A. CT scan demonstrating a traumatic hepatic cyst 4 months after blunt liver trauma. B. Ultrasound in the same patient demonstrating a thickened cyst wall.

secondary biliary cirrhosis or ischemic necrosis, and atrophy of the liver.<sup>66</sup> The incidence of liver necrosis with or without abscess is reported as high as 75% in patients with combined biliary and arterial injury.<sup>67</sup> Patients with bile duct injuries after cholecystectomy should be evaluated for concomitant hepatic arterial injury and will frequently require hepatic resection to treat secondary biliary cirrhosis. An intact portal circulation is mandatory for oxygenation of the hepatic parenchyma when the hepatic artery has been injured; therefore portal blood flow must also be examined in any case of combined bile duct and hepatic artery injury following cholecystectomy. These combined portal and arterial injuries in the setting of bile duct injury tend to present earlier and often require formal hepatectomy.<sup>68</sup>

## TREATMENT

Treatment is reserved for those who are symptomatic. Options include aspiration, unroofing, and excision. Bile leaks must be sought and controlled.<sup>58</sup> Small bilomas may be observed, whereas larger collections usually require percutaneous drainage at the time of diagnosis. Once the cavity is collapsed, spontaneous closure of the fistula is the rule.

## REFERENCES

1. Thomas KT, Welch D, Trueblood A, et al. Effective treatment of biliary cystadenoma. *Ann Surg.* 2005;241(5): 769–775.
2. Ochsner A. Pyogenic abscess of the liver. *Am J Surg.* 1938;40:292.
3. McFadzean AJS, Chang EPS, Wong CC. Solitary pyogenic abscess of the liver treated by closed aspiration and antibiotics: a report of 14 consecutive cases with recovery. *Br J Surg.* 1953;41:141–152.
4. Lok KH, Li KF, Li KK, Szeto ML. Pyogenic liver abscess: clinical profile, microbiological characteristics, and management in a Hong Kong hospital. *J Microbiol Immunol Infect.* 2008;41:483–490.
5. Chen SC, Huang CC, Tsai SJ, et al. Severity of disease as main predictor of mortality in patients with pyogenic liver abscess. *Am J Surg.* 2009;198(2):164–172. [Epub 2009 Mar 6]
6. Pitt HA. Surgical management of hepatic abscesses. *World J Surg.* 1990; 14:498–504.
7. Huang CJ, Pitt HA, Lipsett PA, et al. Pyogenic hepatic abscess: changing trends over 42 years. *Ann Surg.* 1996;223:600–609.
8. Pope IM, Poston GJ. Pyogenic liver abscess. In: Blumgart LH, Fong Y, eds. *Surgery of the Liver and Biliary Tract.* 3rd ed. London, England: WB Saunders; 2001:1135–1145.
9. Barnes S, Lillemo K. Liver abscess and hydatid cyst disease. In: Zinner M, Schwartz S, Ellis H, Ashley S, McFadden D, eds. *Maingor's Abdominal Operations.* 10th ed. Stamford, CT: Appleton & Lange; 1997:1513–1545.
10. Chu KM, Fan ST, Lai ECS, et al. Pyogenic liver abscess: an audit of experience over the past decade. *Arch Surg.* 1996;131:148–152.
11. Seeto RK, Rocky DC. Pyogenic liver abscess: Changes in etiology, management, and outcome. *Medicine.* 1996;75:99–113.
12. Leslie DB, Dunn DL. Hepatic abscess. In: Cameron J, ed. *Current Surgical Therapy.* 8th ed. Philadelphia, PA: Elsevier Mosby; 2004:298–303.
13. Branum GD, Tyson GS, Branum MA, et al. Hepatic abscess: changes in etiology, diagnosis and management. *Ann Surg.* 1990;212:655–662.
14. Civardi G, Filice C, Caremani M, et al. Hepatic abscesses in immunocompromised patients: ultrasonically guided percutaneous drainage. *Gastrointest Radial.* 1992;175:17–23.
15. Lambiase RE, Deyoe L, Cronan JJ, Dorfman GS. Percutaneous drainage of 335 consecutive abscesses: results of primary drainage with 1-year follow-up. *Radiology.* 1992;184:167–179.
16. Chen SC, Lee YT, Yen CH, et al. Pyogenic liver abscess in the elderly: clinical features, outcomes and prognostic features. *Age Ageing.* 2009; 38:271–276.
17. Lederman ER, Crum NF. Pyogenic liver abscess with a focus on *Klebsiella pneumoniae* as a primary pathogen: an emerging disease with unique clinical characteristics. *Am J Gastroenterol.* 2005;100:322–331.
18. Kim JK, Chung DR, Wie SH, et al. Risk factor analysis of invasive liver abscess caused by the K1 serotype *Klebsiella pneumoniae*. *Eur J Clin Microbiol Infect Dis.* 2009;28:109–111.
19. Lai CH, Chen HP, Chen TL. Candidal liver abscesses and cholecystitis in a 37-year-old patient without underlying malignancy. *World J Gastroenterol.* 2005;11(11):1725–1727.
20. Pappas PG, Rex JH, Sobel JD, et al. Guidelines for treatment of candidiasis. *Clin Infect Dis.* 2004;38:161–189.
21. Giorgio A, Tarantino L, Mariniello N, et al. Pyogenic liver abscess: 13 years of experience in percutaneous needle aspiration with US guidance. *Radiology.* 1995;195:122–124.
22. Rajak CL, Gupta S, Jain S, et al. Percutaneous treatment of liver abscesses: needle aspiration versus catheter drainage. *Am J Roentgenol.* 1998;170:1035–1039.
23. Martinez Baez M. Historical introduction. In: Martinez-Palomo A, ed. *Amebiasis. Human Parasitic Diseases, Vol. 2.* Amsterdam, Holland: Elsevier; 1986:1–9.
24. Santi-Rocca J, Rigotherier MC, Guillen N. Host-microbe interactions and defense mechanisms in the development of amoebic liver abscesses. *Clin Microbiol Rev.* 2009;22(1):65–75.
25. Yost J. Amebiasis. *Pediatr Rev.* 2002;23:293–294.
26. Haque R, Huston CD, Hughes M, et al. Current concepts: amebiasis. *N Engl J Med.* 2003;48:1565–1573.
27. Tanyuksel M, Petri WA. Laboratory diagnosis of amebiasis. *Clin Microbiol Rev.* 2003;16:713–729.
28. Salles JM, Moraes LM, Salles MC. Hepatic amebiasis. *Braz J Infect Dis.* 2003;7:96–110.
29. Petri WA, Jr, Singh U. Diagnosis and management of amebiasis. *Clin Infect Dis.* 1999;29:1117–1125.
30. Thomas PG, Ravindra KV. Amebiasis and biliary infection. In: Blumgart LH, Fong Y, eds. *Surgery of the Liver and Biliary Tract.* 3rd ed. London, England: WB Saunders; 2001:1147–1165.
31. Haque R, Mollah NU, Ali IK, et al. Diagnosis of amebic liver abscess and intestinal infection with the TechLab *Entamoeba histolytica* II antigen detection and antibody tests. *J Clin Microbiol.* 2000;38:3235–3239.
32. Blessmann J, Binh HD, Hung DM, Tannich E, Burchard G. Treatment of amebic liver abscess with metronidazole alone or in combination with ultrasound-guided needle aspiration: a comparative, prospective and randomized study. *Trop Med Int Health.* 2003;8:1030–1034.
33. Weinke T, Grobusch MP, Buthoff W. Amebic liver abscess—rare need for percutaneous treatment modalities. *Eur J Med Res.* 2002;7:25–29.
34. Chavez-Tapia NC, Hernandez-Calleros J, Tellez-Avia FI, et al. Image-guided percutaneous procedure plus metronidazole versus metronidazole alone for uncomplicated amoebic liver abscess. *Cochrane Database Syst Rev.* 2009;21(1):CD004886.
35. Sharma MP, Dasarthy S, Verma N, et al. Prognostic markers in amebic liver abscess: a prospective study. *Am J Gastroenterol.* 1996;91:2584–2588.
36. Pedrosa I, Saiz A, Arrazola J, et al. Hydatid disease: Radiologic and pathologic features and complications. *Radiographics.* 2000;20:795–817.
37. Gunay, K, Taviloglu K, Berber E, et al. Traumatic rupture of hydatid cysts: a 12-year experience from an endemic region. *J Trauma.* 1999;46: 164–167.
38. Milicevic MN. Hydatid disease. In: Blumgart LH, Fong Y, eds. *Surgery of the Liver and Biliary Tract.* 3rd ed. London, England: WB Saunders; 2001:1167–1204.
39. Sayek I, Onat D. Diagnosis and treatment of uncomplicated hydatid cyst of the liver. *World J Surg.* 2001;25:21–27.
40. Sbihi Y, Janssen D, Osuna A. Serologic recognition of hydatid cyst antigens using different purification methods. *Diagn Microbiol Infect Dis.* 1996;24:205.
41. Goldblatt M, Pitt H. Hepatic echinococcosis. In: Cameron J, ed. *Current Surgical Therapy.* 8th ed. Philadelphia, PA: Elsevier Mosby; 2004: 306–311.
42. Gharbi HA, Hassine W, Brauner MW, et al. Ultrasound examination of hydatid liver. *Radiology.* 1981;139:459.

43. Fornage B. [Fortuitous diagnosis by fine needle puncture under real-time ultrasound control of an atypical hydatid cyst of the liver.] *J Radiol.* 1983;64:643–645.
44. Khuroo MS, Wani NA, Javid G, et al. Percutaneous drainage compared with surgery for hepatic hydatid cysts. *N Engl J Med.* 1997;337:881–887.
45. Filippou D, Tselepis D, Filippou G, et al. Advances in liver echinococcosis: diagnosis and treatment. *Clin Gastroenterol Hepatol.* 2007;5:152–159.
46. Filice C, Brunetti E. Use of PAIR in human cystic echinococcosis. *Acta Trop.* 1997;64:95–107.
47. Topcu O, Sumer Z, Tuncer E, Aydin C, Koyuncu A. Efficacy of chlorhexidine gluconate during surgery for hydatid cyst. *World J Surg.* 2009;33(6):1274–1280.
48. Ertem M, Karahasanoglu T, Yavuz N, et al. Laparoscopically treated liver hydatid cysts. *Arch Surg.* 2002;137:1170.
49. Buttenschoen K, Kern P, Reuter S, Reuter S. Hepatic infestation of *Echinococcus multilocularis* with extension to regional lymph nodes. *Langenbecks Arch Surg.* 2009;394(4):699–704.
50. Yuksel O, Akyurek N, Sahin T, et al. Efficacy of radical surgery in preventing early local recurrence and cavity-related complications in hydatid liver disease. *J Gastrointest Surg.* 2008;12:483–489.
51. Gaines PA, Sampson MA. The prevalence and characterization of simple hepatic cysts by ultrasound examination. *Br J Radiol.* 1989;62:335–337.
52. Caremani M, Vincenti A, Benci A et al. Echographic epidemiology of non-parasitic hepatic cysts. *J Clin Ultra sound.* 1993;21:115–118.
53. Sanfelippo PM, Beahrs OH, Weiland LH. Cystic disease of the liver. *Ann Surg.* 1974;179:922–925.
54. Cowles RA, Mulholland MW. Solitary hepatic cysts. *J Am Coll Surg.* 2000;191:311–321.
55. Schacter P, Sorin V, Avni Y, et al. The role of laparoscopic ultrasound in the minimally invasive management of symptomatic hepatic cysts. *Surg Endosc.* 2001;15:364–367.
56. Gamblin TC, Holloway SE, Heckman JT, Geller DA. Laparoscopic resection of benign hepatic cysts: a new standard. *J Am Coll Surg.* 2008;207:731–736.
57. Mortelet KJ, Ros PR. Cystic focal liver lesions in the adult: differential CT and MR imaging features. *Radiographics.* 2001;21:895–910.
58. Knauer E, Sweeney JF. Cystic disease of the liver. In: Cameron J, ed. *Current Surgical Therapy.* 8th ed. Philadelphia, PA: Elsevier Mosby; 2004:303–306.
59. Maruyama S, Hirayama C, Yamamoto S, et al. Hepatobiliary cystadenoma with mesenchymal stroma in a patient with chronic hepatitis C. *J Gastroenterol.* 2003;38:593–597.
60. Tsiftsis D, Christodoulakis M, DeBree E, et al. Primary intrahepatic biliary cystadenomatous tumors. *J Surg Oncol.* 1997;64:341–346.
61. Lewin M, Mourra N, Honigman I, et al. Assessment of MRI and MRCP in diagnosis of biliary cystadenoma and cystadenocarcinoma. *Eur Radiol.* 2006;16:407–413.
62. Koffron A, Rao S, Ferrario M, et al. Intrahepatic biliary cystadenoma: role of cyst fluid analysis and surgical management in the laparoscopic era. *Surgery.* 2004;136:926–936.
63. Devaney K, Goodman ZD, Ishak KG. Hepatobiliary cystadenoma and cystadenocarcinoma: a light microscopic and immunohistochemical study of 70 patients. *Am J Surg Pathol.* 1994;18:1078–1091.
64. Akiyoshi T, Yamaguchi K, Chijiwa K, Tanaka M. Cystadenocarcinoma of the liver without mesenchymal stroma: possible progression from a benign cystic lesion suspected by follow-up imagings. *J Gastroenterol.* 2003;38:588–592.
65. Pachter HL, Spencer FC, Hofstetter SR, et al. Significant trends in the treatment of hepatic trauma: experience in 411 injuries. *Ann Surg.* 1992;215:492–502.
66. Felekouras E, Megas T, Michail O, et al. Emergency liver resection for combined biliary and vascular injury following laparoscopic cholecystectomy: case report and review of the literature. *South Med J.* 2007;100(3):317–320.
67. Gupta N, Solomon H, Fairchild R, et al. Management and outcome of patients with combined bile duct and hepatic artery injuries. *Arch Surg.* 1998;133:176–181.
68. Frilling A, Li J, Weber F, et al. Major bile duct injuries after laparoscopic cholecystectomy: a tertiary center experience. *J Gastrointest Surg.* 2004;8:679–685.



# BENIGN AND MALIGNANT PRIMARY LIVER NEOPLASMS

Clifford S. Cho • Yuman Fong

## BENIGN LIVER TUMORS

### Introduction

Benign tumors of the liver include hepatic hemangioma, hepatocellular adenoma, focal nodular hyperplasia (FNH), and other less common lesions arising from hepatic epithelial or mesenchymal tissues (Table 44-1). Benign tumors of the liver may be found in up to 20% of the population,<sup>1</sup> and are more than twice as common as malignant lesions. As a consequence of increased availability and utilization of abdominal computed tomography (CT) and magnetic resonance imaging (MRI), they are now being diagnosed with increasing frequency. Hemangiomas and FNH have an entirely benign natural history and therefore do not warrant resection; adenomas carry a risk of growth, hemorrhage, or malignant transformation and should be treated operatively. Correct identification of these lesions is therefore imperative, and establishment of a definitive diagnosis is often the primary challenge in managing this group of patients.

Diagnostic uncertainty is common, and has been reported to be the indication for operation in as many as 40% of patients undergoing resection.<sup>2,3</sup> Contemporary clinical, laboratory, and radiographic studies are often incapable of definitively distinguishing benign from malignant liver lesions. Symptoms, physical examination findings, and liver function tests are nonspecific. Tumor markers are normal in many patients with malignancy, and therefore should not be relied upon to identify a benign process. Hepatic ultrasonography is commonly employed, but often nonspecific. Currently, the most accurate radiographic modalities are CT and MRI. These are often complementary tests, and are usually diagnostic for hemangioma. MRI is becoming the diagnostic test of choice, with recent studies demonstrating an accuracy of 85–95%.<sup>4</sup> CT and MRI have traditionally been less helpful in distinguishing adenoma from FNH,<sup>3,5</sup> but recent advances in MRI contrast agents selectively excreted by hepatocytes suggest that use of such agents may permit reasonable differentiation of FNH, which retains contrast enhancement on delayed imaging, from adenoma, which

does not.<sup>6</sup> Table 44-2 presents the MRI and CT characteristics of the more common benign lesions.

A liver biopsy may be indicated when noninvasive tests are not diagnostic. The precise indications for preoperative liver biopsy remain controversial; in our practice, liver biopsy is generally reserved for cases in which diagnostic uncertainty persists after a thorough clinical and radiographic evaluation. Biopsy may be performed by percutaneous or laparoscopic fine-needle aspiration (FNA) or core needle biopsy. The diagnostic accuracy of liver biopsy may be as low as 40%; therefore, the potential benefits of biopsy must be balanced against the risk of iatrogenic bleeding and the potential for tumor seeding of the peritoneal cavity if the lesion is malignant.<sup>7,8</sup> In a recent study from the Memorial Sloan-Kettering Cancer Center (MSKCC), 30 of 68 patients (44%) who underwent resection of a benign liver tumor had a preoperative percutaneous biopsy, but the preoperative biopsy provided the correct diagnosis in only 11 of the 30 cases (37%).<sup>9</sup>

Indications for resection of benign tumors include diagnostic uncertainty with a suspicion of malignancy, severe mass-related symptoms due to lesion size, and in the case of hepatic adenoma, the risk of hemorrhage, rupture, or malignant degeneration. The decision to resect is based on patient history, the radiographic appearance of the tumor, and the surgeon's clinical judgment. Because of the predominance of hemangioma, the majority of patients with benign liver tumors may be safely observed.<sup>2,9</sup> The safety of nonoperative management of asymptomatic patients with FNH or hemangioma was illustrated in a large study in which 388 patients diagnosed with either hemangioma or FNH by thorough radiographic evaluation were followed with observation alone.<sup>2</sup> After a median follow-up of 32 months, 87% of patients demonstrated complete stability in their tumor size, and no patients developed tumor rupture. Figure 44-1 presents a flow diagram of our basic management approach for presumed benign tumors of the liver.

When surgical resection is indicated, a variety of approaches can be considered. These approaches include open or laparoscopic resection or enucleation. When malignancy cannot be excluded, resection should be performed with a margin of

**TABLE 44-1: BENIGN TUMORS OF THE LIVER**

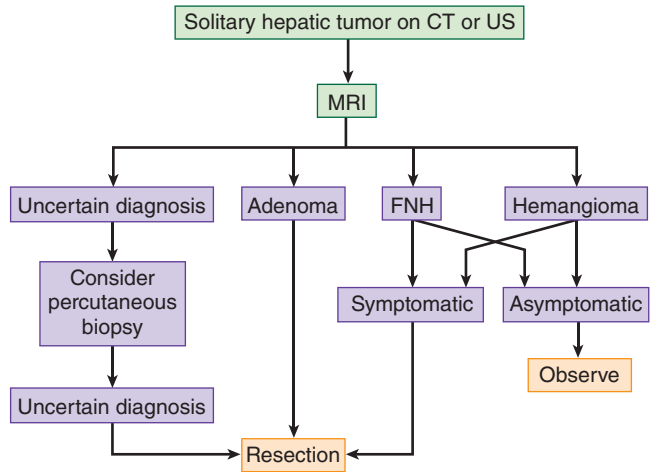
Epithelial tumors	Hepatocellular	Focal nodular hyperplasia
		Hepatocellular adenoma
		Nodular regenerative hyperplasia
Mesenchymal tumors	Bile duct	Bile duct adenoma
	Blood vessel	Bile duct cystadenoma
		Hemangioma
Others	Adipose	Lipoma
	Muscle	Leiomyoma
		Abscess
		Focal fatty infiltration

normal surrounding parenchyma. Resection is also necessary when the tumor lies deep within the liver, as enucleation is generally not feasible in this circumstance. Enucleation for benign tumors is often appropriate, and is our preferred approach for tumors known to be hemangioma.<sup>10</sup> Laparoscopic resection is appropriate for selected patients with benign tumors, with retrospective studies verifying the safety of laparoscopic subsegmental, segmental, and lobar resections.<sup>11,12</sup>

### Hemangioma

#### EPIDEMIOLOGY AND ETIOLOGY

Hemangiomas are the most common benign tumors of the liver; autopsy series suggest that they may be present in up to 7% of the population.<sup>13</sup> Their pathogenesis is unknown. Hemangiomas of the liver may be associated



**FIGURE 44-1** Treatment algorithm for patient presenting with presumed solitary benign tumor of the liver.

with hemangiomas of other organs, and may be multifocal within the liver.<sup>14</sup> Recent data suggest that there is no difference in the incidence of liver hemangioma between men and women, and sex hormones do not appear to play a role in the growth of these lesions.<sup>15,16</sup> An updated review from MSKCC of 115 patients with liver hemangioma found that 35% of the patients were male.<sup>10</sup> A recent case-control study found no association between liver hemangioma and the patient’s reproductive history or use of oral contraceptives.<sup>15</sup>

#### PATHOLOGY

The typical cavernous hemangioma is a red-blue, soft, spongy mass that usually measures between 1 and 2 cm in diameter. When these lesions are greater than 4 cm in size, they are

**TABLE 44-2: RADIOGRAPHIC FEATURES OF BENIGN TUMORS OF THE LIVER**

	Triphasic Contrast-Enhanced CT			MRI		
	Precontrast	Arterial Phase	Delayed Phase	T1	T2	Delayed Sequence
Hemangioma	Well-defined hypodensity	Peripheral nodular enhancement	Centripetal enhancement	Hypointense	Hyperintense	Centripetal enhancement
Focal nodular hyperplasia	Well-defined hypo/isodensity	Homogeneous enhancement	Increased scar uptake	Hypo/isointense	Isointense with possible increased scar signal	Retains gadobenate dimeglumine contrast enhancement
Hepatocellular adenoma	Isodensity; fat, hemorrhage or necrosis may be present	Homogeneous enhancement	Possible prolonged hyperdense enhancement	Mixed, may be hyperintense	Mixed, may be hyperintense	Does not retain gadobenate dimeglumine contrast enhancement

referred to as giant hemangiomas. Histologically, these lesions are sharply defined but not encapsulated, and are made up of large, cavernous vascular spaces partly or completely filled with blood separated by minimal connective tissue stroma. The amount of stromal tissue is variable, and some lesions may exhibit extensive areas of necrosis and fibrosis. Thrombosis is common, and dystrophic calcification may be present within the lesion.

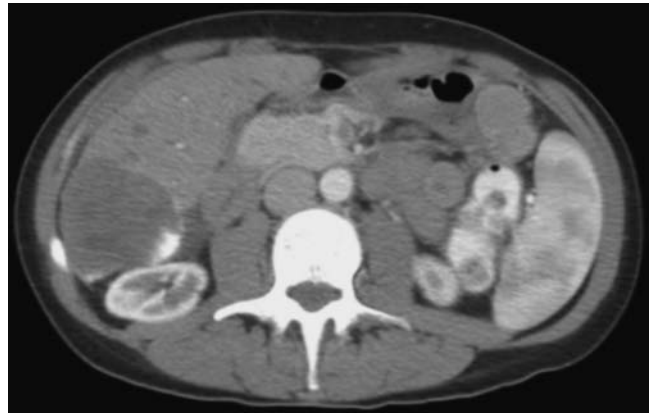
The microscopic interface between a hemangioma and the surrounding liver parenchyma is one that has been well described, and may influence the ease with which they can be enucleated.<sup>17,18</sup> Zimmermann has described four distinct patterns of tumor-parenchymal interface: (1) a fibrous interface characterized by relatively avascular capsule-like fibrous lamellae, (2) an interdigitating interface characterized by a mixture of parenchymal and hemangioma components without a capsule-like interface, (3) a compression interface characterized by direct apposition between hemangioma and parenchyma, and (4) an irregular or spongy interface characterized by a highly irregular border with numerous parenchymal foci interspersed between dilated blood channels.<sup>18</sup> The fibrous interface is the most common interface in large hemangiomas, and the presence of this capsule-like avascular fibrous interface facilitates operative enucleation of these lesions.

## DIAGNOSIS

Although cavernous hemangioma can be diagnosed by biopsy, percutaneous biopsies should be performed with caution because of their risk of hemorrhage and their suboptimal diagnostic accuracy. In a recent study from MSKCC, 8 of 55 patients (15%) resected for hemangioma underwent preoperative percutaneous biopsy.<sup>10</sup> The diagnosis of hemangioma was established by biopsy in only three of 13 patients (23%).

The diagnosis of hemangioma is most often rendered through the use of high-quality CT and MRI. Noncontrast CT images will reveal a well-defined hypodense mass that may contain areas of calcification or central scarring. Contrast-enhanced images using arterial and portal venous phase series will usually demonstrate a typical pattern of peripheral nodular enhancement (Fig. 44-2).<sup>19,20</sup> In a study of 38 patients with 50 liver hemangiomas, five specific CT criteria were found to be diagnostic of hemangioma: (1) a low-density lesion on an unenhanced scan, (2) early peripheral contrast enhancement, (3) progressive centripetal opacification from the periphery toward the center, (4) a delay of at least 3 minutes before total opacification, and (5) an eventual isodense appearance. In this study, 38 of the 50 lesions (76%) demonstrated all five criteria, and the presence of criteria 4 and 5 plus any other two criteria was considered diagnostic.<sup>20</sup>

When hemangioma is clinically suspected but CT fails to confirm the diagnosis, MRI should be performed. Hemangiomas typically exhibit hypointense signal intensity compared with the surrounding liver tissue on T1-weighted imaging, and hyperintense signal intensity on T2-weighted imaging. The pattern of gadolinium enhancement is similar to that



**FIGURE 44-2** Arterial phase computed tomographic appearance of hepatic hemangioma of the right hemiliver. Note the nodular peripheral contrast enhancement.

seen on contrast-enhanced CT imaging. MRI may be more sensitive than CT in detecting subtle enhancement, and recent studies have demonstrated that MRI has a diagnostic accuracy as high as 96% for hepatic hemangioma.<sup>4,21</sup>

Several other radiographic tests are available for the diagnosis of liver hemangioma, but are generally not indicated. Because of the accuracy of CT and MRI, Tc-99m-labeled red blood cell scans are infrequently necessary. However, in circumstances where both CT and MRI are not diagnostic, this test may be helpful and is certainly superior to ultrasound or even biopsy.<sup>22</sup> Use of positron emission tomography (PET) has also been described in the diagnosis of hepatic and peripheral hemangiomas.<sup>10,23</sup> Limited available data suggest that hemangiomas are not <sup>18</sup>F-fluorodeoxyglucose (FDG)-avid, suggesting that PET may be helpful in differentiating hemangioma from metabolically active malignancies.

## TREATMENT

Most patients with hepatic hemangiomas should be managed nonoperatively. The natural history of these lesions is usually one of stability. Only rarely do patients develop symptoms attributable to hemangioma, and the onset of spontaneous rupture is reportable. Only 30 reports of spontaneous intra-abdominal rupture of hepatic hemangiomas have been cited in the literature.<sup>24</sup> Size alone should not be used as a criterion for resection, as recent reports have demonstrated that even large lesions may be safely managed nonoperatively.<sup>2,25</sup> In a recent study from the Netherlands, 38 of 49 patients discovered to have hepatic hemangiomas were followed nonoperatively. In this study, the median diameter of nonoperatively managed lesions was 6 cm. The median follow-up was 52 months, during which time no patient experienced a complication or developed symptoms attributable to the lesion.<sup>25</sup>

Three criteria we use as indications for resection of hemangioma are the presence of severe symptoms, an inability to confidently exclude malignancy, and the development of



complications. Controversy persists as to whether resection is advisable for symptom relief. Bismuth's group reported that 7 of 14 patients (50%) who underwent treatment of hemangioma for symptom relief had persistent symptoms following treatment, prompting them to advise caution against resection.<sup>26</sup> However, it should be noted that 6 of the 14 patients treated for symptomatic hemangioma underwent embolization or hepatic arterial ligation rather than surgical excision; of the seven patients with persistence of symptoms, five were from the embolization or ligation group. Data from MSKCC and others suggest that between 75 and 96% of carefully selected patients who undergo resection or enucleation for symptoms will have relief,<sup>9,10,14,27,28</sup> but it is imperative that these patients be carefully selected. Other pancreaticobiliary and upper gastrointestinal (GI) causes for the symptoms must be investigated, and the symptoms should be carefully matched to the size and nature of the hemangioma. Lesion size appears to be associated with the likelihood of symptoms. The median lesion size among patients resected for symptoms at MSKCC was 14 cm. In our experience, hemangiomas less than 4 cm in size are almost exclusively asymptomatic, and symptomatic lesions tend to be larger within the right hemiliver than within the left.<sup>10</sup>

Another indication for surgical resection of hepatic hemangioma is the development of tumor-related complications. As noted above, intra-abdominal hemorrhage is extremely uncommon, but when it does occur, it should be considered a life-threatening emergency treated with a combination of angiography with embolization and surgery. Intratumoral bleeding has been reported as a complication of hemangioma, and is often thought to be associated with the development of symptoms. Although this complication is not life threatening, onset of symptoms will often lead to diagnosis of the lesion and eventual surgical evaluation. Kasabach-Merritt syndrome is another complication of large hemangiomas characterized by thrombocytopenia and consumptive coagulopathy.<sup>30</sup> Its pathophysiology is thought to involve activation of the clotting cascade by platelets trapped within the hemangioma. Controversy exists as to the most appropriate intervention for this condition. Recommended treatments have included immunosuppressive agents, radiation, surgical resection, and even transplantation.<sup>29,30</sup>

When surgical intervention is indicated, both resection and enucleation have been advocated. Multiple studies have documented that the majority of cases are treated by enucleation.<sup>10,27,31</sup> In a recent study from MSKCC, enucleation was performed for 31 of 52 patients (60%) undergoing operative treatment for hemangioma.<sup>10</sup> We believe that this technique decreases both operative time and operative blood loss. In a recent analysis of 52 patients undergoing surgical resection of hemangioma, enucleation was associated with a lower rate of postoperative complications and a similar rate of transfusion.<sup>31</sup> Hepatic hemangioma is suited for enucleation because of its benign nature and the fibrous cleavage plane that often exists between the hemangioma and the surrounding hepatic parenchyma.

The technique for enucleation of hepatic hemangiomas has previously been described in detail.<sup>10,32</sup> In general, hepatic inflow control is initially achieved by use of the Pringle maneuver. The hepatic artery ipsilateral to the tumor is identified and dissected proximally to the level of the proper hepatic artery. For large lesions of the right or left hemiliver, ligation of the ipsilateral artery can result in some shrinkage in tumor size. Smaller lesions do not require arterial ligation and may be adequately devascularized with a more selective ligation of distal branch vessels. Once arterial inflow has been controlled, a small hepatotomy should be performed a few millimeters from the edge of the hemangioma. Division of this parenchyma will allow entry into the compressed sheath of liver tissue that usually defines the border between hemangioma and normal parenchyma. Gentle dissection within this sheath is usually possible, and small blood vessels or bile ducts encountered during parenchymal transaction can be easily controlled with clips or suture ligatures.

## Focal Nodular Hyperplasia

### EPIDEMIOLOGY AND ETIOLOGY

Focal nodular hyperplasia (FNH) presents as a nodule composed of benign-appearing hepatocytes within a liver that is otherwise histologically normal.<sup>33</sup> The second most common benign tumor of the liver, FNH typically presents as a solitary lesion and is often discovered incidentally. It occurs most commonly in young women, with a female-to-male ratio of 8:1. The average age of patients at the time of diagnosis is 35 years.<sup>34</sup>

The pathogenesis of this lesion is not well understood, but thought to be a reactive process to a vascular injury or malformation. The presence of large arteries within a central fibrous scar and the absence of portal venous structures are characteristic of FNH. Some have postulated that this abnormal vascular anatomy results in chronic malperfusion and secondary hyperplasia of the surrounding hepatocytes.<sup>35</sup> Controversy exists as to whether this lesion, or its natural history, is associated with the use of oral contraceptives.<sup>36,37</sup> Contemporary data suggest that neither the presence, size, nor number of lesions is influenced by the use of oral contraceptives. In an analysis of 216 women with FNH, oral contraceptive use and pregnancy were not associated with lesion growth.<sup>38</sup> During follow-up, only four lesions (2%) increased in size, and none of the 12 patients who became pregnant experienced growth or complications related to their lesion.

### PATHOLOGY

FNH grossly appears as a discrete pale mass with lobulations and abundant septae. A thin capsule often surrounds the tumor, which is usually free of necrosis or hemorrhage. A central scar is characteristic of FNH. More than one central scar may be apparent, and dilated blood vessels are often

evident within the scar. These dilated vessels represent the large central arteries that are typical of this lesion.

Technically, FNH is not a neoplastic process, but a hyperplastic one. FNH is categorized into typical and atypical types. Typical, or classic FNH, is characterized by a central stellate fibrous region that contains abnormal arteries but not portal veins, and is multinodular with nearly normal-appearing hepatocytes and mildly proliferative bile ducts.<sup>37</sup> These bile ducts are generally located at the junction of the abnormal hepatocytes and fibrous regions. Atypical FNH are histologically classified as FNH, but do not exhibit one of the classic features of typical FNH; for example, they may lack a central scar, or may harbor a portal vein within the central vascular region. These atypical lesions have been further divided into three subtypes: (1) telangiectatic; (2) FNH with cytologic atypia; and (3) mixed hyperplastic or adenomatous FNH.<sup>34,37</sup>

## DIAGNOSIS

FNH does not require surgical resection; therefore, it is critical to differentiate this lesion from other hypervascular lesions such as hepatocellular adenoma, hepatocellular carcinoma, and various metastatic lesions. Radiographic imaging is the current mainstay for diagnosis; however, percutaneous biopsy may be warranted in situations where radiographic diagnosis is not definitive.

Increased availability and recent improvements in contrast administration and image detection have resulted in increased utilization and accuracy of CT imaging for the diagnosis of FNH. The typical FNH will appear as a well-demarcated hypointense lesion on noncontrast images. In the arterial phase, the lesion will become uniformly hyperattenuating because of the homogenous enhancement of the entire lesion with the exception of the central scar. This pattern is similar to that of hemangioma; however, within an FNH, the enhancement is uniform throughout the lesion rather than from the periphery. In the portal phase, the lesion will become more isointense, and the central scar may show enhancement as a result of gradual diffusion of the contrast material into the fibrous scar.<sup>39</sup>

Currently, the most sensitive test for the diagnosis of FNH is MRI with gadolinium enhancement, which has reported

sensitivity and specificity rates of about 75 and 98%, respectively.<sup>6,37,40</sup> In general, FNH is hypointense on T1-weighted images, and slightly hyperintense on T2-weighted images. Similar to CT findings, FNH will show brisk and homogenous enhancement with gadolinium. During later phases, the central scar will enhance and may even become hyperintense as contrast washes out of the lesion (Fig. 44-3). Other tissue-specific contrast agents have been recently investigated.<sup>37</sup> These agents are specific for Kupffer cells and hepatocytes and may further increase the ability to identify FNH with MRI.<sup>6</sup>

When imaging studies are equivocal, percutaneous biopsy may permit diagnosis of FNH in a majority of cases.<sup>37</sup> In one study, a histologic diagnosis of FNH was made by percutaneous biopsy in 58% of lesions with nondiagnostic radiographic imaging characteristics.<sup>41</sup> The typical FNH can be diagnosed with core biopsy when benign-appearing hepatocytes, a prominent arterial supply, absence of a portal vein, and peripheral bile duct hyperplasia are observed histologically.

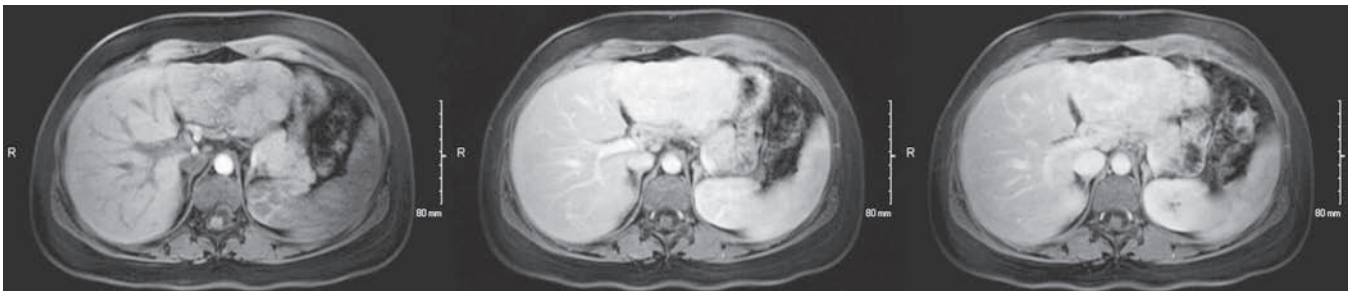## TREATMENT

When the diagnosis of FNH is confirmed, treatment should be nonoperative in the vast majority of patients. FNH is not a neoplastic process, and cannot be considered premalignant. As noted above, growth of these lesions is uncommon, and does not clearly appear to be related to the use of oral contraceptives or pregnancy.<sup>38</sup> Therefore, resection should not be recommended as a prophylactic measure against tumor enlargement and rupture. Patients have on rare occasion been reported to present with symptoms attributable to FNH.<sup>9,42</sup> After careful diagnostic review, resection in such a setting may be warranted for highly selected cases. Subsegmental resections are generally preferable for FNH, and minimally invasive approaches should be considered.

## Hepatocellular Adenoma

### EPIDEMIOLOGY AND ETIOLOGY

Like FNH, hepatocellular adenoma also occurs predominantly in young women; however, unlike FNH, it is a neoplastic process that is clearly associated with the use of oral contraceptive



**FIGURE 44-3** MRI appearance of a large left lateral section focal nodular hyperplasia. Note the gradual contrast washout from the lesion and enhancement of the central scar on delayed sequences.

pills (OCPs), as well as with type 1 glycogen storage disease and diabetes.<sup>43</sup> Hepatocellular adenoma was rarely reported before the introduction of oral contraception, and is believed to be four times more common in women who use OCPs compared with those who do not.<sup>43</sup> The risk of developing hepatocellular adenoma is proportional to the duration of OCP use; patients who have used OCPs for more than 9 years have a risk of developing hepatocellular adenoma that is 25 times that of the general population. Complications from hepatocellular adenoma have also been associated with the use of OCPs. A review of 237 patients found that those taking OCPs presented with larger tumors (97% >5 cm vs 75% >5 cm) and were more likely to present with tumor rupture or hemorrhage than those not taking OCPs (65 vs 25%).<sup>44</sup>

A majority of hepatocellular adenomas will be symptomatic at presentation, and complications associated with these lesions include tumor growth, rupture with intraperitoneal hemorrhage, and malignant transformation. The risk of rupture and intraperitoneal hemorrhage may be as high as 30–50%.<sup>45,46</sup> In a review of 54 patients with hepatocellular adenoma, 21 patients (39%) were diagnosed after the onset of hemorrhage into the tumor or peritoneal cavity, and only four patients (7%) had the lesion discovered incidentally.<sup>47</sup> In a recent multicenter retrospective analysis of 124 patients with hepatocellular adenoma, tumor rupture was reported in 31 cases (25%), and the risk of rupture was associated with increasing tumor size, recent OCP use, or hormonal replacement therapy (within 6 months). Average tumor size for nonruptured adenoma in this series was 7.2 cm, compared with 10.5 cm for ruptured adenoma.<sup>48</sup> When hemorrhage does occur, intra-abdominal blood may be observed in up to 60% of patients. Hepatocellular adenoma should be considered a premalignant condition. Published reports of patients who have been followed with serial radiographic studies have described the development of hepatocellular carcinoma within previous hepatocellular adenoma.<sup>45,46,49</sup> In these studies, an increase in the serum alpha-fetoprotein (AFP) level was found to be an indicator of malignant transformation.<sup>45,46,49</sup> In the aforementioned multicenter analysis of 124 patients with hepatocellular adenoma, malignancy was detected in 5 cases (4%).<sup>48</sup>

## **PATHOLOGY**

Hepatocellular adenomas present as solitary lesions in approximately 75% of cases. Multiple adenomas are common in patients with glycogen storage disease or hepatic adenomatosis. Adenomas may vary from 1 cm to greater than 20 cm in size. Grossly, adenomas are sharply demarcated from the normal parenchyma and appear light in color. Unlike FNH, hemorrhage is commonly evident on gross examination.

Microscopically, adenomas consist of cords of cells that closely resemble normal hepatocytes; indeed, histologic differentiation between adenoma and normal liver tissue can be difficult. However, adenoma cells are larger than normal hepatocytes and may contain large amounts of glycogen and lipid.<sup>50</sup> Adenomas are devoid of bile ducts, and this key

histologic feature helps to distinguish hepatocellular adenoma from FNH on biopsy. Hepatocytes within an adenoma are separated by dilated sinusoids that represent the arterial blood supply of the lesion which, like FNH, typically lacks a portal venous supply. Adenomas characteristically have little fibrous connective tissue support and generally lack a tumor capsule.

## **DIAGNOSIS**

The most important diagnosis to exclude in the evaluation of hepatocellular adenoma is FNH, as their treatments are radically different. Hepatocellular adenomas are often first detected by ultrasonography during evaluation for right upper quadrant abdominal symptoms.<sup>50</sup> Adenomas are typically hyperechoic on ultrasound, which may be a result of their high lipid content. Other findings may include significant heterogeneity due to intratumoral hemorrhage, or calcifications due to hemorrhage and necrosis. These findings may identify the lesion, but are not specific enough to diagnose hepatocellular adenoma.

Multiphasic CT is more specific than ultrasonography for adenoma.<sup>51</sup> Nonenhanced images may identify areas of fat or hemorrhage that are typical of adenoma. The majority of adenomas will appear sharply demarcated and are hypo- or isoattenuating. Areas of old hemorrhage and necrosis will appear as discrete foci of hypoattenuation on nonenhanced imaging. Arterial phase contrast images may show some degree of peripheral enhancement due to the larger peripheral feeding vessels. However, approximately 80% of cases will show rapid homogenous enhancement.<sup>50</sup> Unlike FNH, contrast enhancement in adenoma usually does not persist due to a component of arteriovenous shunting (Fig. 44-4).

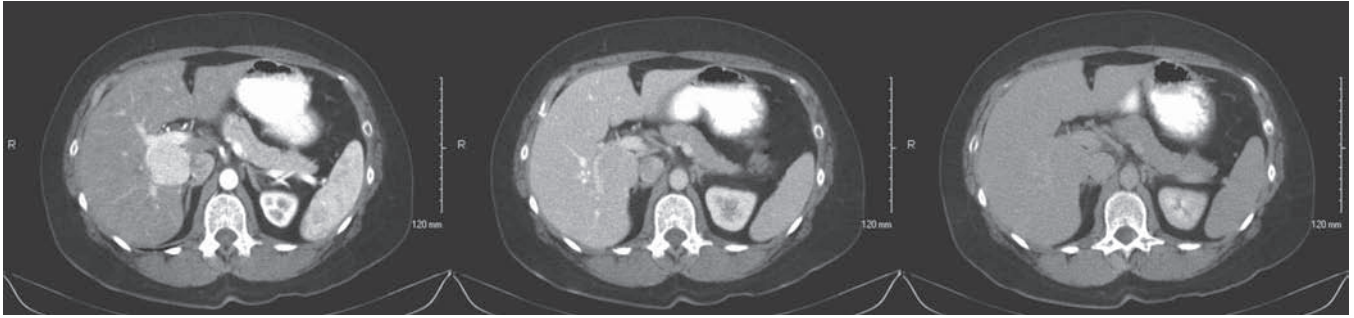
Findings on MR imaging have been reported to be more variable than those of CT.<sup>50,52,53</sup> Adenomas have been described as hyperintense, isointense, and hypointense on T1-weighted imaging.<sup>52,53</sup> Heterogeneity is again common, with regions of increased signal intensity occurring due to fat, hemorrhage, and necrosis. Inconsistency is also reported for T2-weighted imaging, but the majority of adenomas will be hyperintense relative to the liver on T2 imaging.<sup>53</sup> Dynamic gadolinium-enhanced MRI may also be used to demonstrate early arterial enhancement. Since adenomas have a scarcity of Kupffer cells, Kupffer cell-specific agents will result in decreased signal intensity on T2-weighted imaging.<sup>53</sup>

If diagnostic uncertainty persists after a thorough imaging evaluation, percutaneous biopsy should be considered, especially if the possibility of FNH remains within the differential diagnosis. Percutaneous FNA and core biopsy have been shown to be accurate in the diagnosis of hepatocellular adenoma.<sup>43</sup> As noted earlier, the absence of bile ducts within the lesion is one of the critical elements that differentiates FNH from hepatocellular adenoma.

## **TREATMENT**

In general, patients with any size hepatocellular adenoma should undergo surgical therapy in order to prevent the risk of tumor growth and rupture, and to prevent the risk





**FIGURE 44-4** Computed tomographic appearance of hepatic adenoma of the right hemiliver. Note the rapid homogenous contrast enhancement seen on arterial phase images and rapid contrast washout seen on delayed images.

of malignant degeneration. Some have recommended initial discontinuation of OCP use with follow-up imaging to assess for evidence of regression.<sup>9</sup> This approach may be reasonable in selected patients, but it must be emphasized that regression is unpredictable, and continued growth, rupture, and malignant transformation even after discontinuation of OCPs have been reported.<sup>43–45</sup>

## Miscellaneous Benign Tumors

### NODULAR REGENERATIVE HYPERPLASIA

Nodular regenerative hyperplasia is an uncommon lesion associated with conditions of chronic liver disease. Cirrhosis and portal hypertension may be present in up to 50% of cases.<sup>54</sup> Radiographically, these lesions appear similar to FNH; however, portal venous phase images may show almost complete contrast washout, rendering these lesions almost imperceptible.<sup>36</sup> Given the rarity of this entity, their natural history is poorly understood, but tumor growth and rupture are extremely rare. Percutaneous biopsy can be obtained to confirm the diagnosis of nodular regenerative hyperplasia, which should be managed nonoperatively.

### PELIOSIS HEPATITIS

Hepatic peliosis is an uncommon disorder histologically characterized by multiple, small, blood-filled sinuses. Peliosis occurs most commonly in immunocompromised transplant recipients, AIDS patients, and patients on long-term corticosteroid therapy.<sup>55,56</sup> Radiographically, they present as diffuse hypodense areas distributed throughout the liver. CT and MRI will typically show enhancement on early phase images, and may progress from central to peripheral enhancement on delayed imaging.<sup>57</sup> Rupture with intraperitoneal hemorrhage has been reported from this condition.<sup>58,59</sup> The optimal treatment for bleeding from this lesion has been angiographic embolization. As this is a diffuse condition of the liver resulting from identifiable causes, ultimate treatment should be directed toward the specific etiology.

### BILE DUCT ADENOMA

Bile duct adenomas are benign lesions that appear as small and well-demarcated white subcapsular lesions ranging from several millimeters to 1 or 2 cm in maximal dimension. These are typically diagnosed incidentally at the time of operation. Pathologically, these appear as well-differentiated bile ductular structures surrounded by a fibrous stroma. These lesions are typically asymptomatic and appear to be entirely benign.<sup>60,61</sup>

## MALIGNANT LIVER TUMORS

### Introduction

Malignant tumors of the liver may arise from the hepatocyte, the bile duct epithelium, and the endothelial cells within the liver. The most common primary liver malignancy is hepatocellular carcinoma (HCC), which represents the most common solid organ cancer worldwide. As a group, malignant tumors of the liver present major diagnostic and therapeutic challenges. Although surgery can be potentially curative, most hepatobiliary cancers are discovered at a stage too advanced to permit complete resection.

Over the last two decades, considerable advances have been made in the diagnosis and treatment of these tumors. Enhancements in imaging have permitted earlier detection and more accurate staging of disease. The morbidity associated with surgical resection has decreased, and improving short- and long-term results are now being achieved with extensive but rational resections. Contemporary surgical therapy is guided by improved imaging techniques and a better understanding of disease biology. Furthermore, novel palliative treatments such as radiotherapy and ablative techniques have extended the limits of tumor eradication and treatment.

### Hepatocellular Carcinoma

The therapeutic challenge of HCC arises from three factors. First, it is usually associated with cirrhosis, which limits the

range of treatment options and increases the morbidity of any given therapy. Second, HCC is usually asymptomatic at early stages, during which it has a great propensity for intravascular or intrabiliary extension; as a result, HCC typically presents at an advanced stage with consequently few effective therapeutic options. Third, HCC has been resistant to most conventional forms of cytotoxic chemotherapy, limiting the array of nonoperative forms of treatment.

## EPIDEMIOLOGY AND ETIOLOGY

There are nearly 500,000 new cases of HCC diagnosed yearly (Table 44-3).<sup>62</sup> The incidence of HCC increases with age, and is four to eight times more common in males than in females. HCC is strongly associated with chronic liver injury; therefore, its geographic distribution closely mirrors that of viral hepatitis. The etiologic association between hepatitis B (HBV) infection and HCC is well established. A landmark study examined the relationship between HBV infection and HCC among 22,707 male subjects in Taiwan, 15.2% of whom were chronic HBV carriers as evidenced by detection of HB<sub>s</sub>Ag in their serum. Of the 116 cases of HCC that developed during a mean follow-up period of 7 years, 113 occurred in patients positive for HB<sub>s</sub>Ag. This study demonstrated that HCC was related not simply to a history of HBV infection but to the chronic carrier state, and that the relative risk of developing HCC was 200-fold greater in individuals with evidence of HBV infection compared with uninfected individuals.<sup>63</sup>

The hepatitis C virus (HCV) has also been associated with HCC. Antibodies to HCV have been found in as many as 76% of patients with HCC in Japan, Italy, and Spain<sup>64</sup> and

in 36% in the United States.<sup>65</sup> Unlike HBV-associated HCC, which rarely occurs before the development of cirrhosis, HCV-associated HCC does not necessarily arise in the setting of advanced liver disease. Additionally, the incidence of HCC in chronic carriers of HCV is estimated to be as high as 5% per year, compared with 0.5% per year for HBV carriers.<sup>66</sup>

Chemical carcinogens have also been linked to HCC. Nitrites, hydrocarbons, solvents, organochlorine pesticides, primary metals, and polychlorinated biphenyls have been implicated in development of HCC.<sup>67</sup> Colloidal thorium dioxide (Thorotrast), which emits high level  $\alpha$ ,  $\beta$ , and  $\gamma$  radiation and was used as an angiographic agent in the 1930s, has been linked to angiosarcoma, cholangiocarcinoma, and HCC. Of all the chemicals linked to the development of HCC, the most important is ethanol. Alcohol abuse has been associated with the development of HCC, in addition to carcinomas of the larynx, mouth, and esophagus. Ethanol is believed to produce HCC through the development of hepatic cirrhosis or as a cocarcinogen with other agents such as HBV, HCV, hepatotoxins, and tobacco<sup>68-73</sup> rather than through any direct effect on hepatocytes.

Aflatoxins produced by the fungi *Aspergillus flavus* and *Aspergillus parasiticus* have also been linked to HCC. These are fungi that grow on grains, peanuts, and other food products, and are the most common cause of food spoilage in the tropics. These fungi produce aflatoxins designated B<sub>1</sub>, B<sub>2</sub>, G<sub>1</sub>, and G<sub>2</sub>. Aflatoxin B<sub>1</sub> is the most hepatotoxic, and chronic exposure to these mycotoxins can promote HCC.<sup>74</sup>

Congenital conditions may also lead to the development of HCC. Genetic diseases such as hemochromatosis, Wilson's disease, hereditary tyrosinemia, type 1 glycogen storage disease, hepatic porphyria of both intermittent and cutanea tarda types, familial polyposis coli, ataxia telangiectasia, familial cholestatic cirrhosis, biliary atresia, congenital hepatic fibrosis, neurofibromatosis, situs inversus, fetal alcohol syndrome,  $\alpha$ -antitrypsin deficiency, and Budd-Chiari syndrome<sup>75</sup> have all been linked to a higher incidence of HCC. Ultimately, the unifying etiology of HCC for these conditions is chronic liver injury and inflammation.

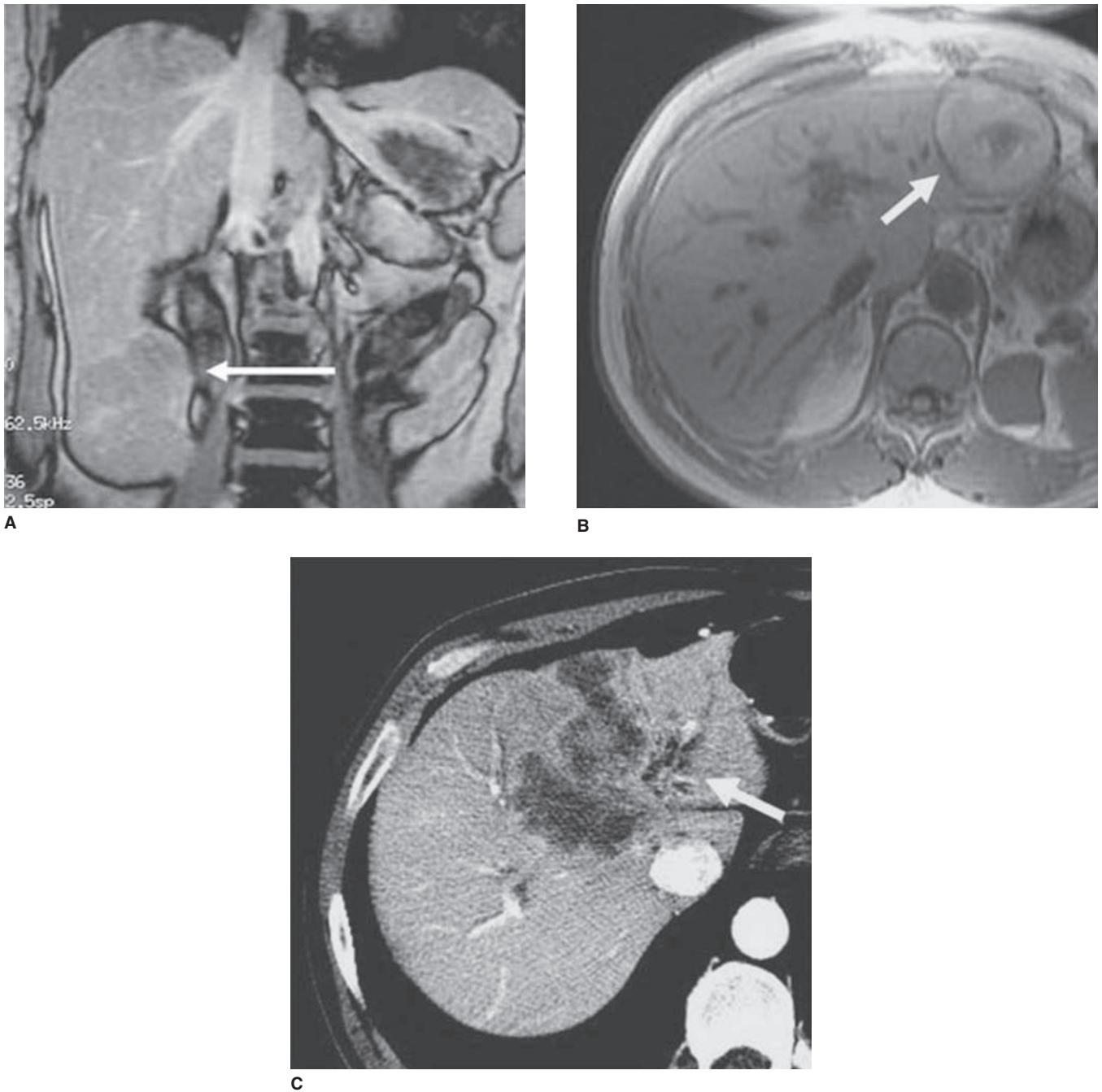


**TABLE 44-3: FACTORS ASSOCIATED WITH THE DEVELOPMENT OF HCC**

Infection	Hepatitis B virus Hepatitis C virus
Cirrhosis	Laennec's (alcohol-induced) Autoimmune hepatitis Primary biliary cirrhosis
Environmental	Aflatoxins <i>N</i> -nitrosylated compounds Pyrrolizidine alkaloids Thorotrast
Metabolic disorders	Alpha 1-antitrypsin deficiency Citruinemia Familial cholestatic cirrhosis Galactosemia Hemochromatosis Hereditary tyrosinemia Porphyria cutanea tarda Type 1 and 3 glycogen storage disease Wilson's disease

## PATHOLOGY

HCC has been histologically graded as well differentiated, moderately differentiated, and poorly differentiated. The well-differentiated variety may be difficult to distinguish from a regenerating nodule on biopsy. HCC can also be classified into three distinct patterns of growth that are associated with resectability and therefore have a significant influence on long-term outcome (Fig. 44-5). The hanging type is attached to the normal liver by a small vascular stalk, even when tumors are large. Because of this anatomic configuration, these are easily excised with minimal loss of functional hepatic parenchyma. The pushing type is generally well demarcated and often encapsulated by a fibrous capsule. These displace rather than infiltrate normal vasculature and typically do not invade the major vessels. Even when large, they are often resectable. Finally, the infiltrative type has a very indistinct tumor-to-liver interface,



**FIGURE 44-5** Growth patterns of hepatocellular carcinoma. **A.** “Hanging” type. MRI demonstrating a mass (*arrow*) that is attached by a stalk to the right lobe of the liver. **B.** “Pushing” type. These are generally encapsulated, well-circumscribed tumors (*arrow*). **C.** “Infiltrating/invading” type. This lesion has diffusely infiltrated the entire left two-thirds of the liver. Note the left biliary ductal dilation (*arrow*).

and tends to have a much greater degree of vascular infiltration and invasion even when the tumor is relatively small. Because of the indistinct interface, resection of infiltrative-type HCC is occasionally complicated by positive margins. The practical nature of this gross pathologic classification scheme is reinforced by the distinctive radiologic appearance of these three

different growth patterns on imaging and the resulting ability to categorize HCC preoperatively.<sup>76</sup>

An important pathologic determination involves the distinct appearance and clinical behavior of the fibrolamellar variant of HCC (Table 44-4). On gross and radiologic inspection, fibrolamellar HCC is generally well demarcated,




**TABLE 44-4: COMPARISON OF STANDARD HCC WITH FIBROLAMELLAR VARIANT HCC**

Characteristic	HCC	Fibrolamellar HCC
Male:Female	4:1–8:1	1:01
Median age	55	25
Tumor morphology	Invasive	Well-circumscribed
Resectability	<25%	50–75%
Cirrhosis	90%	5%
AFP elevation	80%	5%
HBV positivity	65%	5%

often encapsulated, and contains a central fibrotic area that can sometimes make differentiation of fibrolamellar HCC and FNH difficult. This variant generally occurs in young patients without underlying cirrhosis.<sup>77</sup> AFP, which is commonly elevated in usual cases of HCC, is not elevated in fibrolamellar HCC. Other serum markers that are often elevated in fibrolamellar HCC include neurotensin and vitamin B<sub>12</sub>-binding protein.<sup>78</sup> The fibrolamellar variant of HCC is associated with prolonged survival compared with typical HCC, which is likely due to the well-demarcated nature of their tumors and the greater range in treatment options for patients without underlying cirrhosis.<sup>79</sup>

## CLINICAL PRESENTATION

Despite the fact that they are generally slow-growing tumors, most cases of HCC present at an advanced stage that is no longer amenable to potentially curative therapies. Because the liver is relatively hidden behind the right costal cartilages, tumors can reach a substantial size before becoming palpable. Furthermore, the large functional reserve of the liver generally masks any small impairment resulting from local parenchymal disturbances by tumor. Small HCC tumors are usually therefore asymptomatic, and are discovered by screening programs<sup>80–82</sup> or incidentally during imaging performed for other abdominal conditions.

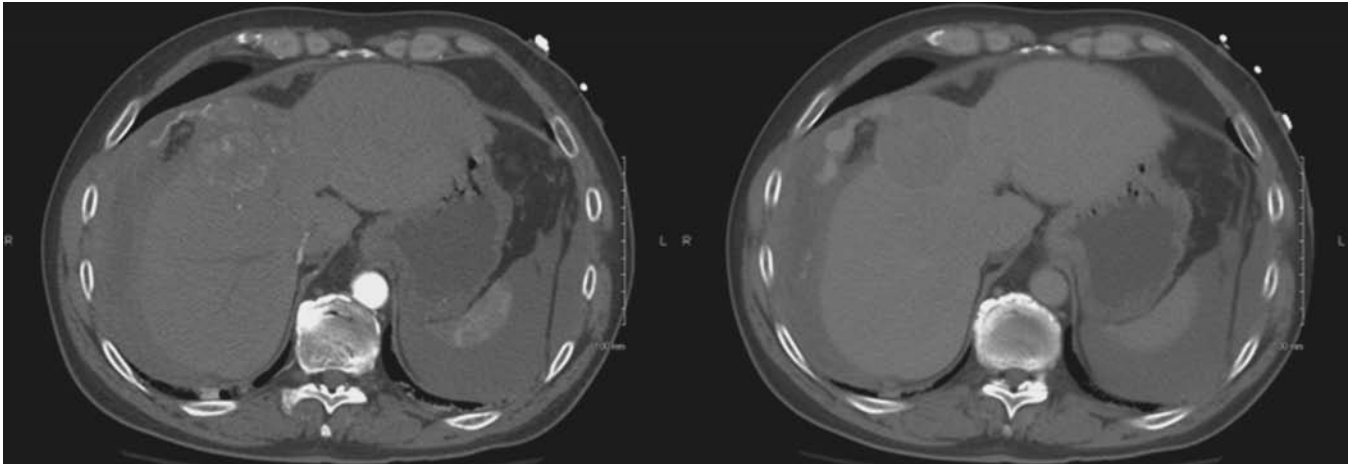
As a result, the majority of HCC cases present with local symptoms resulting from large tumor mass. Patients usually complain of a dull and vague right upper quadrant pain that is sometimes attributable to the shoulder. Hepatomegaly is a frequent accompanying finding. The liver edge is often hard and irregular because of both the tumor and the usual accompanying cirrhosis. A vascular bruit can be heard over the liver in about 25% of cases.<sup>83</sup> General symptoms of malignancy, including anorexia, nausea, lethargy, and weight loss, are common. The most common clinical presentation is the triad of right upper quadrant pain, a palpable mass, and weight loss.<sup>84–86</sup> Central necrosis of large tumors can lead to fever, and HCC can occasionally present as pyrexia of unknown origin. For the majority of patients,

the presentation of HCC will also be the first presentation of their underlying cirrhosis. In one study population in which 90% of patients were eventually found to have cirrhosis, fewer than 10% of patients were thought at first evaluation for HCC to have chronic liver disease on the basis of their history and clinical examination.<sup>85</sup>

Hepatic decompensation is another common presentation for HCC, with patients seeking medical attention as a result of symptoms of liver failure like ascites, jaundice, or encephalopathy. This acute decompensation of liver function is usually a consequence of replacement of functional parenchyma by tumor in a patient with previously compensated cirrhosis. HCC also has a great propensity for vascular invasion and intravascular growth; hepatic failure can also result from portal vein occlusion secondary to intravascular tumor thrombus.<sup>87–89</sup> A rare cause of liver failure is Budd-Chiari syndrome resulting from direct invasion and occlusion of the hepatic vein and inferior vena cava by tumor and tumor thrombus. Gastrointestinal hemorrhage often complicates the clinical course of patients with HCC and is the presenting finding in 10% of cases.<sup>89</sup> In approximately half of these cases, bleeding is from esophageal varices<sup>89</sup> that can result from portal hypertension due to cirrhosis alone or cirrhosis with the added contribution of intraportal tumor thrombus. Patients with bleeding esophageal varices have an extraordinarily poor prognosis, with a median survival measurable in weeks.<sup>88</sup> In one study, nearly a quarter of patients with HCC died of massive variceal hemorrhage.<sup>87</sup> Gastrointestinal bleeding can also occur from other causes, such as a benign peptic ulcer or direct invasion of the alimentary tract by tumor.<sup>89</sup> The most dramatic presentation of HCC is tumor rupture, which is the initial presenting event in 2–5% of HCC patients (Fig. 44-6). Symptoms of tumor rupture include acute abdominal pain and swelling, and signs include abdominal distension, guarding, rebound tenderness, and ileus. Patients also commonly have signs of hemodynamic instability or overt hypovolemic shock. Diagnosis is confirmed by findings of tumor mass and peritoneal blood through imaging, laparotomy, or paracentesis.<sup>90–94</sup>

Up to half of HCC patients initially present with jaundice, which is most commonly due to hepatic insufficiency.<sup>84,95–97</sup> On rare occasions (fewer than 10% of jaundiced patients), jaundice associated with HCC is a result of biliary obstruction by extraluminal or intraluminal tumor or tumor-induced hemobilia.<sup>84,98–102</sup> In the clinical evaluation of jaundice for patients with HCC, it is critically important to distinguish hepatocellular failure from obstruction. The former etiology usually indicates that the patient is beyond any therapy, while the latter can often be treated with effective palliation and possible cure.<sup>99,101,103–107</sup>

In rare cases (<5%), HCC can present with paraneoplastic syndromes attributable to hormonal or immune effects of tumor.<sup>108</sup> The most important of these are hypoglycemia, erythrocytosis, hypercalcemia, and hypercholesterolemia. Porphyria cutanea tarda, virilization and feminization syndromes, carcinoid syndrome, hypertrophic osteoarthropathy, hyperthyroidism, and osteoporosis can also occur.<sup>109–111</sup>



**FIGURE 44-6** Computed tomographic appearance of ruptured hepatocellular carcinoma. Note the acute extravasation of contrast seen on early arterial phase images with pooling of blood seen on delayed images.

## DIAGNOSIS

For patients with suspected HCC, the aims of diagnostic investigations are (1) verification of diagnosis; (2) determination of extent of disease; and (3) estimation of functional liver reserve.

**Verification of Diagnosis.** Diagnosis of HCC can usually be established noninvasively with a combination of history, physical examination, imaging, and laboratory blood tests. There is little diagnostic doubt in a patient with a liver mass consistent with a HCC on CT or MRI and a serum AFP greater than 500 ng/dL. This combination of findings is diagnostic, and treatment can be initiated without the need for a tissue diagnosis. The presence of cirrhosis or hepatitis infection (as documented by presence of HB<sub>s</sub>Ag or HCV in the blood) serves to further confirm the diagnosis.

In the patient with a space-occupying lesion on ultrasonography or CT with a nondiagnostic AFP level, the role of percutaneous needle biopsy has been debated. There is little doubt that needle biopsy can be diagnostic for HCC; however, iatrogenic complications of biopsy are not infrequent. Hemorrhage or tumor rupture can occur, and there is also a risk of tumor spillage and seeding of the needle biopsy tract.<sup>112</sup> In cases of potentially resectable HCC where the diagnostic certainty is high, we typically proceed to surgical exploration without a biopsy. Indeed, in this clinical scenario, the histologic appearance of the non-neoplastic liver may have a greater impact on surgical planning; if the presence of advanced cirrhosis will preclude safe resection, we will biopsy the nontumoral liver for histologic evaluation.

In patients with nondiagnostic AFP who are not surgical candidates (and therefore not candidates for curative therapy), tumor biopsy is performed for those who may be candidates for palliative therapy. In such cases, fine-needle aspirate for cytologic evaluation has been shown to yield a higher percentage of correct diagnoses compared with microhistology of core needle biopsy specimens (86 vs 66%).<sup>113</sup> Patients who are not

candidates for palliative therapy do not need a definitive diagnosis, and biopsy is discouraged for this cohort.

**Extent of Disease Evaluation.** The two issues that must be resolved by the extent of disease evaluation are (1) whether the disease is isolated to the liver, and (2) whether the distribution of tumor within the liver is amenable to surgical resection. The most common sites of HCC metastases include lung, peritoneum, adrenal, and bone. Chest radiography is therefore mandatory. Cross-sectional imaging such as CT or MRI of the abdomen and pelvis should be scrutinized for peritoneal and adrenal sites of disease. Many centers consider bone scans to be mandatory prior to liver resection; this should certainly be performed for patients with pain that could be attributable to bony metastases. The presence of extrahepatic disease gravely alters the prognosis, as it eliminates the potentially curative treatment option of hepatectomy.

The extent of liver involvement is usually determined by CT. In the evaluation of HCC, cross-sectional imaging is used to determine the number and distribution of liver tumors and to identify radiographic evidence of vascular invasion. In this regard, triple phase (noncontrast, arterial phase, and portal phase) CT images should be obtained. HCC tumors are generally highly vascular; however, some tumors may become isodense with the surrounding liver on contrast-enhanced images, and some tumors are only visible during the noncontrast-enhanced phase. HCC has a great propensity for vascular invasion and extension, and tumor thrombus in the portal vein, hepatic vein, or vena cava is not unusual. Scans should therefore be scrutinized for evidence of vascular invasion, since therapy and prognosis can be significantly altered by the presence of such findings. If vascular invasion is suspected but not proven by CT, Doppler ultrasonography or MRI is indicated.

At some centers, hepatic angiography is a standard component of the diagnostic evaluation of HCC.<sup>114,115</sup> Some have even advocated routine use of lipiodol injected angiographically to

further delineate hepatic extent of disease.<sup>116</sup> This lipid is preferentially retained in HCC because of its particle size. There is no doubt that these angiographic methods are highly sensitive in detecting the presence of tumor. However, with current helical CT or MRI, the incremental yield of this invasive diagnostic modality is minor. We rely on angiography for select circumstances in which small tumors are suspected but not visible by conventional cross-sectional imaging (eg, a patient with a very high AFP level with only minimal disease seen on CT).

**Determination of Functional Liver Reserve.** Various liver function tests, alone or in combination, have been touted as useful for predicting risks of liver resection and other treatments for HCC. Various single serum measures of liver function have been suggested to be useful predictors of perioperative outcome, including serum bilirubin<sup>117</sup> and serum alanine aminotransferase (ALT).<sup>118</sup> A doubling of bilirubin has been suggested as a contraindication for liver resection.<sup>119</sup> Others have used a platelet count less than 50,000, or a prolonged prothrombin time greater than 4 seconds over control, to be relative contraindications for hepatic resection.<sup>119</sup> Most investigators have not relied on a single parameter, but use a combination of clinical and biochemical parameters to gauge safety of hepatectomy and other liver-directed treatments. The most clinically useful system is the Child-Turcotte-Pugh (Child) classification, which is a point scoring system for evaluation of liver function based on serum bilirubin, coagulation profile, serum albumin, presence or absence of ascites and encephalopathy, and nutritional status (Table 44-5).<sup>120,121</sup> Functionally, well-compensated cirrhosis is classified as Child classification grade A; decompensating cirrhosis is grade B; decompensated cirrhosis is grade C. Generally, partial hepatectomy is offered only to patients who are Child A and the most favorable class B patients.<sup>122</sup> In general, class C patients are only offered supportive care, since even nonsurgical ablative methods such as transarterial embolization are associated with procedure-related mortality in one-third of patients.<sup>123</sup>

Many sophisticated dynamic measures of liver function have also been used in attempts to quantitate hepatic function. Investigators have used the elimination of certain dyes that are exclusively cleared by the liver, such as bromosulphthalein or

indocyanine green, as measures of hepatic function. Galactose clearance and [<sup>14</sup>C] aminopyrine clearance have also been used to evaluate the metabolic capacity of the liver. Of these, the most commonly utilized evaluations in clinical practice are indocyanine green retention at 15 minutes<sup>124</sup> and the [<sup>14</sup>C] aminopyrine breath test,<sup>125</sup> although controversy still exists concerning their utility.<sup>126</sup> We do not use these tests on a routine basis in our care of patients with HCC, and have found clinical Child-Turcotte-Pugh classification sufficiently discriminatory for selecting patients for therapies.

Another relatively simple test that may be predictive of perioperative outcome, and which we use on occasion, is hepatic venous wedge pressure. By passing a venous catheter through the vena cava into the hepatic vein, the hepatic venous pressure can be directly ascertained. With balloon occlusion of the hepatic vein, the hepatic venous wedge pressure, which is a reflection of portal pressure, can be determined. These measurements have been touted as useful in segregating Child-Turcotte-Pugh B patients who may have favorable results from resection versus those likely to have major complications.<sup>127</sup>

## POTENTIALLY CURATIVE TREATMENT

Therapies for HCC can be separated into resection, ablation, radiation therapy, systemic chemotherapy or immunotherapy, and supportive care. Resectional therapy represents the only potentially curative option. We will begin with a discussion of these, particularly emphasizing recent advances and comparison of partial hepatectomy with total hepatectomy or liver transplantation.

**Partial Hepatectomy.** Partial hepatectomy represents the most common procedure for HCC performed with curative intent (Table 44-6). The liver is normally a very resilient organ with remarkable regenerative capacity. In a noncirrhotic liver, routine recovery can be expected even after resection of over two-thirds of functional parenchyma.<sup>128</sup> In the United States, nearly half of the patients with HCC will have no associated cirrhosis.<sup>129</sup> Operative mortality at most major centers is generally less than 5%, and very extensive procedures are justified by the low risk and the potential for long-term survival and cure. Resection is associated with a 5-year survival estimate of nearly 40% (Fig. 44-7).<sup>126-130</sup> For patients without cirrhosis, partial hepatectomy is a relatively safe procedure, and is the treatment of choice for HCC.

In contrast, most cases of HCC worldwide are associated with cirrhosis. The associated cirrhosis greatly increases the risk of partial hepatectomy. This increase in risk is partly a result of intraoperative factors. These patients will usually have rigid and hard hepatic parenchyma and established varices that are difficult to manipulate and prone to hemorrhage. Additionally, these patients will have thrombocytopenia and coagulation defects that further exacerbate their risk of bleeding. Postoperatively, the liver may not regenerate, resulting in liver failure. Furthermore, postoperative exaggeration of portal hypertension may lead to ascites and variceal bleeding. It is understandable; therefore, that resection is associated with

**TABLE 44-5: CHILD-TURCOTTE-PUGH GRADING SYSTEM FOR CIRRHOSIS**

Criterion	1 Point	2 Points	3 Points
Bilirubin (mg/dL)	<2.0	2.0–2.9	>2.9
INR	<1.7	1.7–2.3	>2.3
Albumin (g/dL)	>3.5	2.8–3.4	<2.8
Ascites	Absent	Mild	Moderate–severe
Encephalopathy	Absent	Mild (grade 1–2)	Moderate–severe (grade 3–4)

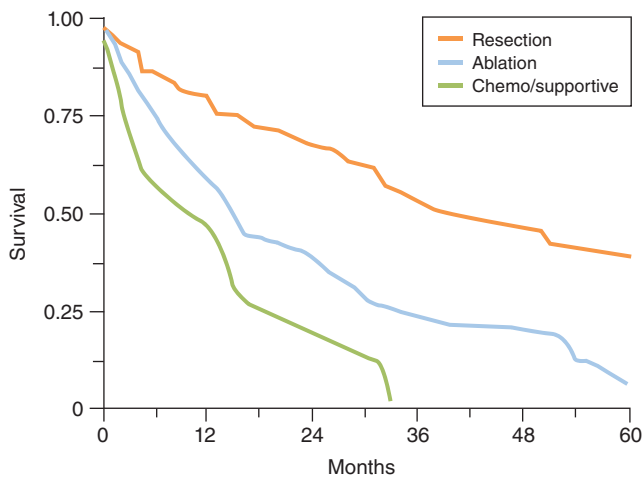
Child-Turcotte-Pugh class A: 5–6 points; B: 7–9 points; C: 10–15 points.



**TABLE 44-6: OUTCOMES AFTER LIVER RESECTION FOR HCC**

Author/Year	n	Operative Mortality	Survival 1-y	Survival 5-y	Survival 10-y	Comments
Okuda et al/1984 <sup>269</sup>	98	NR	62%	—	—	—
Nagao et al/1987 <sup>142</sup>	94	19%	58%	20%	—	—
Kanematsu et al/1988 <sup>270</sup>	107	NR	83%	26%	—	—
Yamanaka et al/1990 <sup>271</sup>	295	NR	76%	31%	—	—
Ringe et al/1991 <sup>272</sup>	131	NR	68%	54%	—	—
Sasaki et al/1992 <sup>273</sup>	186	NR	—	44%	—	Cirrhotics
	57	NR	—	68%	—	Noncirrhotics
Nagasue et al/1993 <sup>134</sup>	229	7%	80%	26%	19%	—
Takenaka et al/1994 <sup>274</sup>	229	1%	89%	76%	—	<70 y old
	39	5%	87%	52%	0	>70 y old
Suenaga et al/1994 <sup>275</sup>	134	NR	100%	68%	—	—
Bismuth et al/1995 <sup>276</sup>	68	NR	74%	40%	26%	Noncirrhotics
Lai et al/1995 <sup>277</sup>	343	5%	60%	24%	—	1987–1991
Vauthey et al/1995 <sup>130</sup>	106	6%	—	41%	—	—
Takenaka et al/1996 <sup>278</sup>	280	2%	88%	50%	—	—
Fong et al/1999 <sup>129</sup>	154	5%	80%	39%	—	67% cirrhosis
Poon RT et al/2001 <sup>279</sup>	230	NR	—	37%	—	—
Belghiti et al/2002 <sup>280</sup>	328	6%	81%	37%	13%	50% cirrhosis
Esnaola et al/2003 <sup>281</sup>	586	5%	—	36%	14%	47% cirrhosis
Ng et al/2005 <sup>282</sup>	404	2%	88%	58%	—	HCC <5 cm
	380	3%	74%	39%	—	HCC >5 cm
Cho et al/2008 <sup>135</sup>	184	5%	—	38%	—	35% cirrhosis

NR, not reported.



**FIGURE 44-7** Survival curve for 154 patients undergoing hepatectomy for hepatocellular carcinoma at Memorial Sloan-Kettering Cancer Center. (Used with permission from Fong Y, et al. An analysis of 412 cases of hepatocellular carcinoma at a Western center. *Ann Surg.* 1999;229[6]:792.)

increased morbidity and mortality in these patients. Even for a cirrhotic patient with well-compensated liver function, we are reluctant to remove more than 20–25% functional parenchyma.<sup>126,136–139</sup> Until recently, even at centers with a low mortality for partial hepatectomy in the noncirrhotic population, partial hepatectomy for patients with cirrhosis was associated with a 10% mortality or more.<sup>134,140–144</sup> This explains the nihilistic view adopted by some for this disease, and explains the interest in treating this disease by total hepatectomy and liver transplantation. Nevertheless, even in this period of time, cirrhotic patients who survive the operation have a 5-year survival of approximately 30%.<sup>137–141</sup> Over the last decade, a number of series have demonstrated increasing safety of partial hepatectomy in cirrhotic patients. Due to improvements in patient selection, surgical technique, and perioperative support, the mortality at most major centers treating HCC has been reduced to less than 5%.<sup>129,131,132,135</sup>

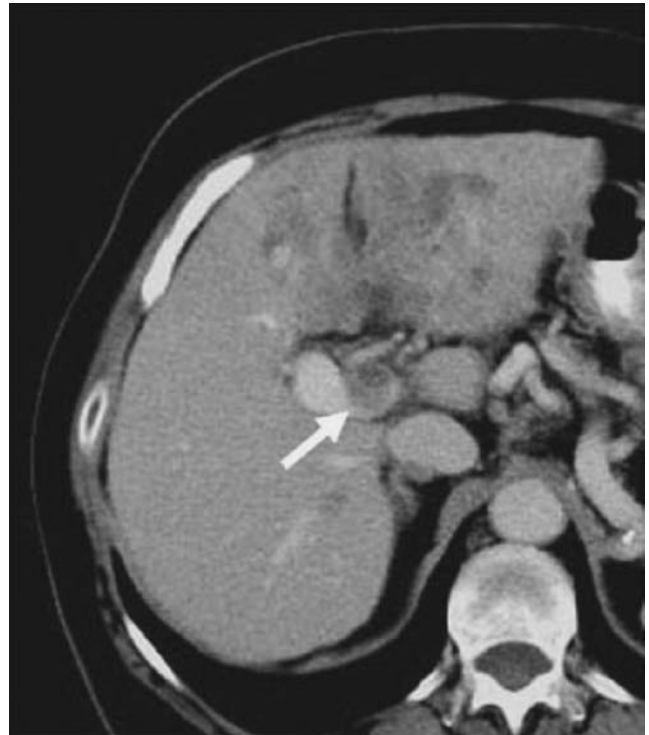Patient selection for surgery is primarily driven by hepatic function. As discussed above, the most commonly used clinical selection criteria for a patient’s fitness for surgery relies on the Child-Turcotte-Pugh score. Few surgeons are willing to perform hepatic resection for patients with Child C cirrhosis. Most surgeons will only consider resection for patients with class A liver functional reserve and the best class B patients.

The major changes in operative conduct that have improved perioperative outcome include the willingness to use inflow occlusion during resection and the willingness to accept nonanatomic resection. Temporary occlusion of the hepatic artery and portal vein during liver resection by clamping the gastrohepatic ligament has been a useful technique for reducing blood loss during hepatectomy for patients without cirrhosis.<sup>145</sup> In the past, surgeons have been reluctant to use such inflow occlusion (the Pringle maneuver) in cirrhotic patients because of fears that cirrhotic parenchyma will not tolerate even transient ischemia. Recent studies have indicated that the reluctance to use this technique is largely unfounded, and that the cirrhotic liver can tolerate a Pringle maneuver for well over 30 minutes.<sup>146,147</sup> The most important change in operative technique has been the willingness to use limited, nonanatomic resections. For patients without cirrhosis, most major centers adhere to the anatomic boundaries of the various segments during liver resection for cancer. Hemihepatectomies, sectionectomies, and segmentectomies are preferred over wedge and other nonanatomic resections because limited resections are more likely to result in a positive microscopic margin.<sup>148</sup> In the cirrhotic liver, however, a smaller resection margin is acceptable if it will reduce the chance of postoperative liver failure. The smallest resection that will remove all gross tumors is generally used at most centers.

As the safety of resections has improved, increasing experience in the treatment of HCC has resulted in long-term results that allow for the analysis of prognostic factors. Many factors that in years past were thought to be contraindications to surgical resection have not been substantiated by these data. It is now clear that multiple lesions do not preclude surgical resection.<sup>132,134,135,138</sup> Presentation with intraductal tumor and obstructive jaundice does not preclude long-term survival after surgical resection. Therefore, it is very important in a patient who presents with HCC and jaundice to distinguish biliary obstruction from hepatic insufficiency as the cause for the jaundice. Synchronous direct invasion of adjacent organs such as the diaphragm by HCC is also not an absolute contraindication to resectional surgery.<sup>149,150</sup>

One cohort with a particularly poor prognosis is comprised of those with major intravascular extension of tumor (Fig. 44-8). Even though tumor thrombus can be treated with liver resection and thrombus extraction, the risk of disseminated disease is extremely high.<sup>151</sup> If the tumor thrombus involves the vena cava or main portal vein, liver resections accompanied by venous tumor thrombectomies are unlikely to yield long-term survival.

A number of staging systems have been proposed for purposes of postoperative risk stratification.<sup>152-158</sup> In a recent analysis of the MSKCC experience, the median disease-specific survival of 184 patients with HCC treated with partial hepatectomy was 54 months. Incorporating the prognostically informative variables of patient age, operative blood loss, microscopic resection margin status, presence of satellite lesions, presence of vascular invasion, tumor size, and AFP,

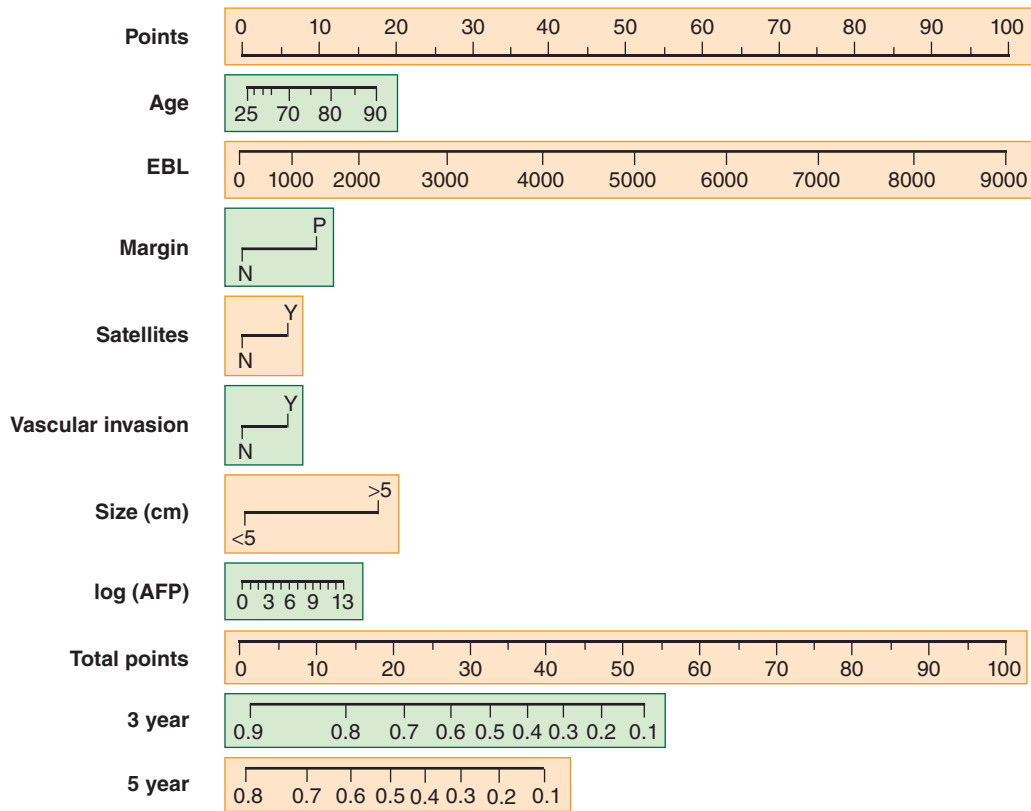


**FIGURE 44-8** Vascular invasion of hepatocellular carcinoma. These tumors have propensity for intravascular extension. Note the tumor thrombus in the portal vein (*arrow*).

we developed a nomogram that appears to permit far more accurate prediction of individual recurrence-free and overall survival outcomes than is permissible using conventional staging systems (Fig. 44-9).<sup>155</sup>

**Neoadjuvant Therapy.** Many groups have attempted to treat HCC with local or systemic therapies prior to surgical resection. The rationale for such neoadjuvant therapies is that (1) large primary tumors may be sufficiently reduced in bulk to make resection safer, and (2) local and systemic microscopic disease may be reduced or eradicated to improve long-term outcomes. In this regard, methods that have been employed to achieve these goals include transarterial chemoembolization,<sup>159,160</sup> combined chemotherapy (doxorubicin and 5-fluorouracil) and radiation therapy (2100 cGy), a combination of hepatic artery ligation, hepatic artery infusion of chemotherapeutic agents, radioimmunotherapy, and fractionated regional radiotherapy,<sup>161</sup> and transarterial yttrium 90 microspheres.<sup>162,163</sup>

In a French study, preoperative administration of lipiodol/doxorubicin-based transarterial chemoembolization (TACE) prior to partial hepatectomy in 49 patients resulted in tumor downstaging in 42% and total tumoral necrosis in 50%, with five patients being converted from unresectable to resectable disease. A trend toward improved survival was observed among patients demonstrating a partial or complete response



**FIGURE 44-9** Prognostic nomogram for prediction of overall survival following resection of hepatocellular carcinoma. The individual patient's values are located on each variable axis and a line is drawn upward to determine the number of points received for each variable. A line is drawn downward from the sum of these numbers on the "Total Points" axis to obtain the likelihood of 3-year and 5-year survival. (Used with permission from Cho CS, Gonen M, Shia J, et al. A novel prognostic nomogram is more accurate than conventional staging systems for predicting survival after resection of hepatocellular carcinoma. *J Am Coll Surg.* 2008;206[2]:288.)

to neoadjuvant TACE compared with those demonstrating no response or those not undergoing resection alone, suggesting that response to preoperative therapy may enhance proper selection of patients for operative intervention.<sup>164</sup> Another investigative form of preoperative treatment is immunoembolization. In a comparison of 39 patients treated with neoadjuvant transarterial immunoembolization using the immunogenic *Streptococcus pyogenes* preparation OK-432 versus neoadjuvant TACE, enhanced tumoral necrosis was observed among patients treated with transarterial immunoembolization. Two- and 3-year disease-free survival after resection were 85 and 51% after transarterial immunoembolization and 56 and 47% after TACE, respectively.<sup>165</sup> In a randomized analysis of 91 patients with HCC assigned to resection alone versus neoadjuvant chemoembolization or immunoembolization followed by resection, overall survival was 18 months after resection alone versus 36.3 months after neoadjuvant therapy followed by resection.<sup>166</sup> Although these strategies are promising, their analyses have involved relatively small numbers of patients, and the use of neoadjuvant therapy remains investigative.

An alternative neoadjuvant strategy to improve outcomes after resection that has been adopted more widely is preoperative portal vein embolization (PVE). Embolization

of the portal vein nourishing the portion of liver in which the tumor resides results in compensatory hypertrophy of the contralateral hemiliver. Single-institution analyses have identified improved postoperative mortality and morbidity among patients treated with preoperative PVE with no compromise in oncologic outcomes.<sup>167-169</sup>

**Adjuvant Therapy.** Approximately one-third of patients can expect to remain durably free of disease after partial hepatectomy for HCC; the fact that the majority of patients will recur indicates the prevalence of microscopic residual disease at the time of liver resection.<sup>170,171</sup> This has motivated keen interest in developing effective adjuvant therapy directed at microscopic residual disease.

In a Chinese study, 61 patients with resected HCC were randomized to no further therapy or postoperative hepatic infusion of lipiodol and cisplatin with systemic epirubicin. Interestingly, patients receiving adjuvant therapy appeared to have a higher extrahepatic recurrence rate and worse outcomes.<sup>172</sup> Another study of 57 patients with resected HCC randomized to hepatic arterial infusional and systemic epirubicin versus no further treatment demonstrated no differences in overall and disease-free survival.<sup>173</sup>



Although TACE is used extensively for the treatment of unresectable disease, randomized studies have not supported the use of this modality in the adjuvant setting. Indeed, three studies have demonstrated worse survival for those treated after resection with chemoembolization.<sup>174-176</sup> There have been two positive randomized trials of adjuvant therapy after resection for HCC. The first involves the use of the retinoid-derivative polyphenolic acid, which had been shown to inhibit hepatocarcinogenesis in rodents.<sup>177</sup> In a study randomizing patients after curative resection or percutaneous ethanol injection for HCC to polyphenolic acid or placebo, significantly higher numbers of patients receiving placebo developed additional HCC. This compound is not currently available in the United States, but these data encourage further study of this and other retinoid derivatives in adjuvant treatment for HCC and in chemoprevention of patients at high risk for development of HCC. Another positive adjuvant study involved the use of radioembolization employing transarterial delivery of <sup>131</sup>I-lipiodol. This compound has demonstrated significant activity against small HCC, but problems with dosimetry have limited its use for patients with bulky unresectable disease. In a prospective, randomized study, 21 patients who received 50 mCi of transarterial <sup>131</sup>I-lipiodol within 6 weeks of liver resection were compared with 22 patients receiving no adjuvant therapy. Three-year survival rates for the treated group and the control group were 85 and 46%, respectively.<sup>178</sup> These findings await larger multicenter studies to confirm long-term survival improvement and to demonstrate the feasibility of delivering radioembolization in other centers.

Until recently, no systemic chemotherapy regimen had demonstrated efficacy for HCC. However, a large prospective multicenter randomized trial involving 602 patients confirmed a survival advantage associated with the use of the multikinase inhibitor sorafenib for patients with advanced unresectable HCC.<sup>179</sup> Median survival and time to radiographic progression were 10.7 and 5.5 months, respectively, in the sorafenib group compared with 7.9 and 2.8 months, respectively in the placebo control group. Whether sorafenib may offer benefit in an adjuvant setting for patients having undergone resection of HCC is presently under investigation.

**Total Hepatectomy and Liver Transplantation.** From a theoretical standpoint, total hepatectomy with liver transplantation is the most attractive therapeutic option for HCC (Table 44-7). This treatment allows for tumor resection with the widest possible margins, and permits removal of diseased and tumorigenic parenchyma that may contain microscopic metastatic disease and be predisposed to the formation of additional primary tumors. Initial experience with liver transplantation for HCC was disappointing. Several studies demonstrated that large tumors, multiple tumors, and the presence of microscopic and/or macroscopic vascular invasion were associated with poor outcomes.<sup>180-183</sup> Indeed, early comparative analyses did not uniformly identify improved outcomes associated with transplantation as compared to resection. A landmark study defining the appropriate role for transplantation described 3-year post-transplant survival estimates of 85% for highly selected patients with small tumor burden.<sup>184</sup>

 **TABLE 44-7: OUTCOMES AFTER LIVER TRANSPLANTATION FOR HCC**

Author/Year	n	Operative Mortality	Survival 1-y	Survival 3-y	Survival 5-y
O'Grady et al/1988 <sup>283</sup>	50	23%	40%	—	—
Ringe et al/1989 <sup>284</sup>	52	15%	—	37%	—
Yokoyama et al/1990 <sup>182</sup>	80	13%	64%	45%	45%
Iwatsuki et al/1991 <sup>285</sup>	71	NR	—	43%	—
Pichlmayr et al/1992 <sup>286</sup>	87	24%	—	—	20%
Bismuth et al/1993 <sup>123</sup>	60	5%	—	49%	—
Selby et al/1995 <sup>181</sup>	105	NR	66%	39%	36%
Pichlmayr et al/1995 <sup>287</sup>	36	18%	57%	31%	27%
Schwartz et al/1995 <sup>288</sup>	57	0%	72%	57%	—
Mazzaferro et al/1996 <sup>184</sup>	48	5%	—	—	75% (4 y)
Llovet et al/1998 <sup>289</sup>	58	14%	84%	74%	74%
Hemming et al/2001 <sup>290</sup>	112	13%	78%	63%	57%
Yao et al 2001 <sup>291</sup>	70	NR	91%	—	72%
Duffy et al/2007 <sup>292</sup>	467	NR	82%	65%	52%
Sotiropoulos et al/2007 <sup>293</sup>	100	14%	76%	—	60%
Marelli et al/2008 <sup>294</sup>	100	16%	74%	62%	45%
Onaca et al/2009 <sup>295</sup>	587	NR	85%	74%	68%
Halazun et al/2009 <sup>296</sup>	150	3%	85%	68%	60%

NR, not reported.

This work motivated the introduction of the so-called “Milan criteria” (single tumors  $\leq 5$  cm in maximal dimension or no more than three tumors each  $\leq 3$  cm in maximal dimension), which have been adopted by the United Network of Organ Sharing (UNOS) as a system of selecting HCC patients eligible for liver transplantation. As a result of these defined criteria, there is also accumulating experience with the use of neoadjuvant locoregional therapies such as TACE and percutaneous ablation as means to downstage patients to meet transplantation eligibility.<sup>185–187</sup>

Attempts to compare partial hepatectomy and liver transplantation for HCC have been challenging because of the fundamental differences in patient populations selected for each treatment modality. Patients selected for partial hepatectomy generally have good liver function and can have tumors of enormous size.<sup>188–190</sup> Partial hepatectomy for patients with small tumors also results in very favorable outcomes. For a patient with a tumor that is less than 5 cm in size, the 5-year overall survival is 45–57%.<sup>129,191,192</sup> In light of organ shortages and costs of liver transplantation, partial hepatectomy should be regarded as the curative treatment of choice for patients without cirrhosis or with Child’s A classification cirrhosis. Indeed, survival outcomes after partial hepatectomy among patients with preserved hepatic function with HCC meeting Milan criteria are comparable to those observed after transplantation.<sup>193</sup> For patients with severe liver dysfunction, total hepatectomy and transplantation is the better option and may indeed be the only viable option.

**Palliative Therapy.** The majority of patients presenting with HCC will not have disease amenable to potentially curative surgical intervention. The presence of underlying liver disease often renders them not treatable by partial hepatectomy, and most patients present with disease burden beyond accepted eligibility criteria for total hepatectomy and orthotopic liver transplantation. If the disease is nevertheless completely or largely confined to the liver, local tumor ablative therapies (including percutaneous ethanol injection, radiofrequency ablation, and cryoablation) and embolization (chemoembolization or radioembolization) can result in reasonable local control of disease. Two randomized trials comparing chemoembolization to symptom control have demonstrated a significant survival benefit associated with the use of palliative chemoembolization.<sup>194,195</sup> Nonrandomized studies have suggested that a similar survival benefit may be expected with the use of radiofrequency ablation for properly selected cases.<sup>196</sup> As outlined earlier, systemic sorafenib has also been associated with an incremental survival benefit for patients with unresectable HCC.<sup>179</sup>

## Intrahepatic Cholangiocarcinoma

### EPIDEMIOLOGY AND ETIOLOGY

Cancers of the bile duct are uncommon, with approximately 4000 cases diagnosed in the United States annually.<sup>197</sup> Bile

duct carcinoma may occur anywhere along the biliary tree, and is commonly divided into distal, proximal, and intrahepatic varieties. It is a disease of the elderly, with the majority of patients diagnosed older than 65 years of age, and the peak incidence occurs in the eighth decade of life.<sup>198</sup> In the absence of therapeutic intervention, bile duct cancers are rapidly fatal, and the majority of patients will die within a year of diagnosis. Death usually results from hepatic failure or biliary sepsis.<sup>197,199,200</sup> Long-term survival is highly dependent on the efficacy of surgical therapy. Indeed, it has been shown that location within the biliary tree has no impact on survival, provided that complete resection is achieved.<sup>201</sup> However, it is more likely that a patient with distal bile duct cancer can be resected with curative intent, which explains the relatively favorable prognosis of distal tumors.

Conditions resulting in chronic biliary inflammation have been associated with an increased incidence of cholangiocarcinomas. These conditions include primary sclerosing cholangitis, choledochal cysts, and chronic biliary infections.

**Primary Sclerosing Cholangitis.** In Western nations, the disease most often associated with development of cholangiocarcinoma is primary sclerosing cholangitis (PSC). This is an autoimmune disease characterized by inflammation of the periductal tissues. In advanced cases, it is characterized by multifocal strictures of the intrahepatic and extrahepatic bile ducts.<sup>185–187</sup> The majority (70–80%) of patients with PSC also have associated inflammatory bowel disease, typically in the form of ulcerative colitis.<sup>185</sup> In a longitudinal study of patients with PSC, 8% of patients developed clinically apparent cholangiocarcinoma over a 5-year period.<sup>185</sup> Indeed, a high incidence (30–40%) of occult cholangiocarcinoma has been found in autopsy or explant specimens from patients with PSC.<sup>202,203</sup> Cholangiocarcinoma presenting in patients with PSC is often multifocal and prone to recurrence, and typically not amenable to treatment by partial hepatectomy. Liver transplantation is often the only effective treatment for these patients, not only because of the likelihood of multifocal cancer, but also because of the baseline hepatic insufficiency that often results from the underlying inflammatory disease.<sup>204,205</sup>

**Choledochal Cysts or Caroli’s Disease.** The increased risk of cholangiocarcinoma in patients with congenital cystic disease of the biliary tree is well recognized.<sup>206,207</sup> The reason for the malignant transformation is thought to be related to chronic inflammation and bacterial contamination within areas of cystic dilatation.<sup>206,208–210</sup> Early excision of the choledochal cyst significantly reduces the risk of cancer.<sup>206,208</sup> Fifteen percent to 20% of adult patients with unexcised choledochal cysts, or cysts previously treated with bypass, will be found to harbor cholangiocarcinoma.<sup>206,208</sup>

**Pyogenic Cholangiohepatitis and Other Hepatic Infections.** In Asia, chronic infections of the liver can predispose patients to the development of cholangiocarcinoma. Pyogenic cholangiohepatitis or oriental cholangiohepatitis

results from chronic portal bacteremia and portal phlebitis, which gives rise to intrahepatic pigment stone formation. This hepatolithiasis then leads to recurrent episodes of cholangitis and biliary stricture formation.<sup>211,212</sup> Those who do not succumb to sepsis will have an estimated 10% risk of developing cholangiocarcinoma.<sup>212</sup> In southeast Asia, biliary parasites (*Clonorchis sinensis*, *Opisthorchis viverrini*) are also associated with an increased risk of cholangiocarcinoma.<sup>213</sup> In areas where these parasites are endemic, the incidence of cholangiocarcinoma is as high as 87 per 100,000.<sup>213</sup>

**Environmental Toxins.** Several radionuclides and chemical carcinogens, including thorium, radon, nitrosamines, dioxin, and asbestos, have also been implicated in the genesis of cholangiocarcinomas.

### PATHOLOGY AND CLASSIFICATION

Cholangiocarcinoma can arise anywhere within the biliary tree. Approximately 10% of cholangiocarcinoma cases arise within the intrahepatic bile ducts.<sup>214–217</sup> Extrahepatic cholangiocarcinomas are more common and can occur along the entire length of the extrahepatic biliary system from the confluence of the hepatic ducts to the ampulla. Some have classified these extrahepatic tumor into proximal (hilar), mid, and distal bile duct tumors. We agree with the convention of dividing cholangiocarcinomas into intrahepatic, perihilar, and distal subgroups, thus eliminating the mid-duct group.<sup>218</sup>

Peripheral or intrahepatic cholangiocarcinoma is diagnosed in 1000–2000 patients in the United States annually.<sup>219</sup> Clinical presentation is similar to that for HCC, with the most common symptoms being right upper quadrant pain, epigastric pain, and weight loss.<sup>214,219</sup> In fact, difficulty can be encountered in distinguishing peripheral cholangiocarcinomas from HCC or metastatic tumors from unknown origin. Jaundice occurs in only 24% of patients with peripheral cholangiocarcinoma compared with 71% of patients with hilar tumors.<sup>219</sup> Because the tumor is usually asymptomatic in early stages, most patients have advanced disease at presentation. On cross-sectional imaging by CT or MRI, peripheral cholangiocarcinoma is often confused with HCC or metastatic tumor from unknown primary. Unlike HCC, AFP levels will be normal. Search for alternative primary cancers that may have produced liver metastases will not be fruitful. A solitary lesion not associated with the gallbladder, in a patient with no cirrhosis and no other primary cancer, and with a normal serum AFP, should raise suspicion of a peripheral cholangiocarcinoma. Intrahepatic metastases and tumor growth along the biliary tract frequently occur, and can make it even more difficult to distinguish these tumors from metastatic disease originating from a distant site.

The segregation of extrahepatic cholangiocarcinomas into perihilar and distal subtypes is practical for purposes of operative planning. Tumors that are proximal to the cystic duct–common duct junction typically require a liver resection for extirpation; these represent approximately 40–60% of cases of cholangiocarcinoma, and include the hilar

cholangiocarcinomas or so-called “Klatskin tumors.”<sup>200,201,218–221</sup> Tumors that are distal to the cystic duct typically require pancreaticoduodenectomy for extirpation. Fewer than 10% of patients will present with multifocal or diffuse involvement of the biliary tree.<sup>222</sup>

Lymph node metastases are common with peripheral cholangiocarcinoma, and the assessment of hilar lymph node appears to provide useful prognostic information.<sup>223,224</sup> The (primary) tumor, (regional lymph) node, (remote) metastases (TNM) staging of intrahepatic or peripheral cholangiocarcinoma is the same as that for HCC.

### TREATMENT

**Partial Hepatectomy.** Whenever possible, surgical resection is the treatment of choice. In a series of 42 patients with intrahepatic cholangiocarcinoma, survival was indistinguishable from that of 70 patients with hilar cholangiocarcinomas.<sup>225</sup> Median survival was 12 months, and no patient survived more than 42 months. Others have reported more favorable results. In a series of 20 patients with peripheral cholangiocarcinoma undergoing surgery over a 10-year period, median survival was 21 months.<sup>214</sup> Four patients lived more than 3 years, and a single patient was alive 5 years after resection. In our own report of 32 cases of resected peripheral cholangiocarcinoma, median survival was 59 months with an actuarial 5-year survival of 42%. Vascular invasion and intrahepatic satellite lesions were predictors of worse survival ( $p < .05$ ).<sup>214</sup> In a recent update of the MSKCC experience, the median disease-specific survival for 82 patients with intrahepatic cholangiocarcinoma treated with surgical resection was 36 months. This stands in contrast to a median disease-specific survival of only 9 months for patients with disease not amenable to partial hepatectomy; unfortunately, only a third of patients with intrahepatic cholangiocarcinoma evaluated at MSKCC were ultimately found to have resectable disease. The presence of multiple tumors, tumors greater than or equal to 5 cm, and nodal metastases was found to be associated with worse survival after resection on multivariate analysis.<sup>224</sup>

**Total Hepatectomy and Liver Transplantation.** Historically, outcomes after liver transplantation for patients with cholangiocarcinoma have been suboptimal; in 1991, an actuarial 5-year survival rate of 17% was reported for 109 intrahepatic and extrahepatic cholangiocarcinoma patients transplanted at various centers throughout the world. In this series, there were no significant differences in recurrence rates for hilar and peripheral tumors.<sup>226</sup> More recently, encouraging outcomes have been observed with the use of liver transplantation for selected patients with hilar cholangiocarcinoma following a course of neoadjuvant chemoradiation.<sup>227,228</sup> The Mayo Clinic has utilized a protocol of external beam radiation therapy, chemosensitizing 5-FU, and capecitabine chemotherapy followed by staging laparotomy and, for patients without evidence of hilar nodal or distant metastases, liver transplantation for patients with unresectable hilar cholangiocarcinoma or hilar cholangiocarcinoma arising in a setting of primary



sclerosing cholangitis.<sup>229,230</sup> Estimated actuarial 5-year survival of patients completing this therapy was 82%, which compared favorably to the 21% 5-year survival observed among a cohort of 26 patients with hilar cholangiocarcinoma who underwent conventional surgical resection at the same institution. Whether this promising strategy could be applied for patients with peripheral cholangiocarcinoma remains unknown.

**Chemotherapy.** Data for chemotherapy or radiation in treatment of this disease is not encouraging. Response rates with 5-fluorouracil (5-FU) and 5-FU-based systemic chemotherapy regimens have been generally poor.<sup>231</sup> A 5% complete response and 46% partial response for the treatment of peripheral cholangiocarcinoma was reported with a regimen of initial whole-liver irradiation to 2100 cGy in seven fractions, doxorubicin, cisplatin, and <sup>131</sup>I anticarcinoembryonic antigen (CEA) antibody. Although the median survival was 14 months from diagnosis and 10 months from treatment, no patient survived more than 2 years from the onset of diagnosis.<sup>232</sup> A recent phase II clinical trial examining the use of hepatic arterial floxuridine and dexamethasone for patients with unresectable intrahepatic cholangiocarcinoma and HCC identified a radiographic response rate of 47.1% with 2-year survival estimates of 67%, suggesting that liver-directed chemotherapeutic regimens may hold some palliative promise for patients with unresectable intrahepatic cholangiocarcinoma.<sup>233</sup>

## Other Primary Malignancies of the Liver

### HEPATOBLASTOMA

Hepatoblastoma affects approximately 1 in 100,000 children and is the most common primary malignant liver tumor in children.<sup>234,235</sup> It is usually diagnosed before the age of 3 years, with a 2:1 male predominance. Patients usually present with abdominal swelling,<sup>234,235</sup> and the serum AFP is elevated in over 75% of cases. CT scans will reveal a vascular mass that is often (50%) speckled with calcifications.<sup>236</sup> Overall long-term survival varies between 15 and 37%.<sup>236–239</sup> Poor prognosis is associated with unresectable tumors and tumors demonstrating aneuploidy and anaplastic characteristics.<sup>237,240,241</sup>

Complete resection is possible in 50–65% of children with hepatoblastoma, and is associated with cure rates between 30 and 70%.<sup>240,241</sup> Unlike adult primary liver tumors, chemotherapy may produce a response in a significant number of patients with hepatoblastoma. Preoperative chemotherapy has been used with some success in converting unresectable tumors to resectability.<sup>242,243</sup> Adjuvant chemotherapy has also been used following resection of hepatoblastoma. In one report, 20% of 24 patients with hepatoblastoma were relapse-free 8–42 months after surgical resection coupled with adjuvant vincristine, doxorubicin, 5-FU, and cyclophosphamide.<sup>244</sup> Radiation therapy has been used in the treatment of unresectable hepatoblastomas, but its utility is yet to be proven.<sup>242,245</sup> Orthotopic liver transplantation should be considered for children with unresectable hepatoblastoma if the tumor does not become

resectable after preoperative chemotherapy. In a report of 18 patients undergoing liver transplantation for unresectable hepatoblastoma, tumors recurred in six patients, but five have survived disease-free for more than 2 years with actuarial survival rates of approximately 50%.<sup>226</sup>

### ANGIOSARCOMA

These malignant mesenchymal tumors of the liver are also referred to as hemangiosarcomas. Approximately 25 cases occur in the United States each year.<sup>246</sup> Peak incidence is in the sixth and seventh decades, with 85% of cases occurring in males.<sup>247</sup> Presenting symptoms are as for any liver tumor, and most commonly include abdominal pain, abdominal swelling (usually due to hepatomegaly), liver failure, nausea, anorexia, emesis, and jaundice. These malignant tumors have been associated with exposure to Thorotrast, arsenic, or vinyl chloride.

Angiosarcomas are aggressive neoplasms; partial hepatectomy can result in long-term survival, but most patients present with advanced tumors not amenable to complete resection. Distant metastases are found at initial presentation in half of patients. Most patients die within 6 months of diagnosis. Even with resectable tumors, few patients survive more than 1–3 years after complete resection due to the onset of metastatic disease. Results of radiation therapy and chemotherapy or both have been disappointing.<sup>247</sup> Results of orthotopic liver transplantation for treatment of angiosarcoma have also been poor, with disease recurrences reported in 9 of 14 transplant patients with tumors classified as either angiosarcoma or epithelioid tissue sarcomas. The 2-year survival rate was 15%, with no patient surviving more than 28 months after transplantation.<sup>226</sup>

The liver can occasionally be the primary site for rhabdomyosarcoma,<sup>248</sup> although this is more common in children than adults. Hepatic metastases from a gastrointestinal or uterine primary need to be ruled out before the diagnosis of primary leiomyosarcoma of the liver can be made. Surgical resection is the treatment of choice for these primary hepatic sarcomas,<sup>248</sup> and unresectable disease typically portends an unfavorable prognosis. Undifferentiated sarcomas of the liver are very rare and usually occur in children between the ages of 6 and 15 years.<sup>249,250</sup> Most undifferentiated sarcomas of the liver present at an advanced stage, when surgical resection is not possible. These patients rapidly succumb to their disease, as they are generally not responsive to radiotherapy or chemotherapy.<sup>250</sup>

### EPITHELIOID HEMANGIOENDOTHELIOMA

Epithelioid hemangioendothelioma is another malignant soft tissue tumor of endothelial cell origin.<sup>246,248,251</sup> Factor VII immunohistochemical staining differentiates hemangioendothelioma from other nonvascular tumors. Unlike infantile hemangioendothelioma, which is benign, the adult variety is malignant and highly aggressive. Average age at presentation is 50 years. Afflicted patients usually present with nonspecific

complaints that include pain and an abdominal mass. In contrast to angiosarcoma, there is a female predominance (63% of patients).<sup>248</sup> Vinyl chloride exposure has also been implicated as a possible etiology of epithelioid hemangioendothelioma in some patients.<sup>251</sup>

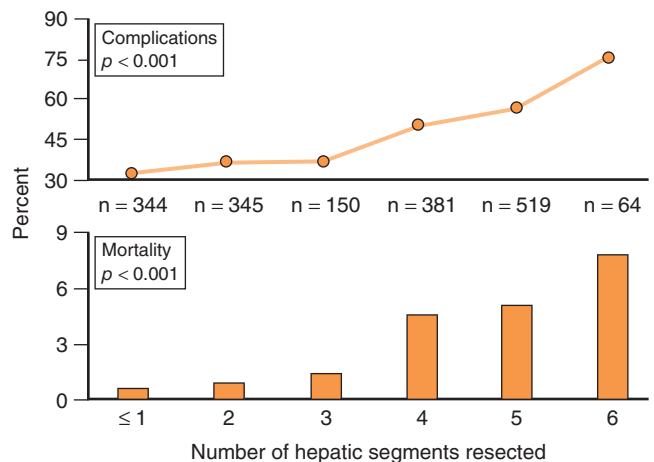
Radical surgery has been advocated for cases of resectable epithelioid hemangioendothelioma.<sup>246</sup> Unfortunately, these tumors are almost always diffuse and multifocal, and therefore unlikely to be cured by partial hepatectomy. Percutaneous biopsy is undertaken when this diagnosis is suspected. Intraoperative frozen section analysis is not typically helpful, as special immunostaining is often needed for definitive diagnosis. Patients with hemangioendotheliomas should be considered for total hepatectomy and liver transplantation. In a series of patients who underwent orthotopic liver transplantation for epithelioid hemangioendothelioma, 7 of 21 patients developed disease recurrence.<sup>226</sup> The actuarial survival rate was 82% at 2 years and 43% at 5 years.

## Technical Considerations in Hepatic Resection

The past two decades have seen a dramatic improvement in perioperative outcome after hepatic resection. High-volume centers now routinely report operative mortality rates of less than 5%, and often as low as 2–3%.<sup>129,232–234</sup> A recent review of over 1800 resections from MSKCC also documented a significant improvement in blood loss, transfusion requirements, and postoperative length of stay in patients undergoing hepatic resection over a 10-year time period.<sup>254</sup> There is no single factor solely responsible for this reduction in morbidity and mortality; better patient selection, the evolution of hepatobiliary surgery as an area of specialization, advances in anesthetic technique, and optimization of operative technique have all contributed to these improved results.

A better appreciation of the segmental nature of hepatic anatomy has resulted in an increasing use of anatomically based resections and, more importantly, an increased use of parenchymal-sparing segmental resections. In a study from MSKCC, the number of hepatic segments resected was a strong predictor of outcome and, along with operative blood loss, was an independent predictor of both the morbidity and mortality of hepatic resection.<sup>234,255</sup> As the number of resected segments increased, there was an almost linear rise in the rate of complications and postoperative mortality (Fig. 44-10). We have observed a significant increase in the proportion of segmental resections performed over the last decade, resulting in a decline in the number of segments resected. Both of these factors correlated closely with the observed reduction in mortality and the overall improvement in perioperative outcome.

Data from this and other studies suggest that measures aimed at preserving hepatic parenchyma without compromising the oncologic integrity of the resection have a significant influence on operative morbidity and mortality. In selected



**FIGURE 44-10** Perioperative complications and mortality stratified by the number of hepatic segments resected. (Used with permission from Jarnagin WR, Gonen M, Fong Y, et al. Improvement in perioperative outcome after hepatic resection: analysis of 1803 consecutive cases over the past decade. *Ann Surg.* 2002;236(4):402.)

patients, parenchymal-sparing segmental resections offer the same benefit as more extensive lobar resections with less risk. The use of segmental resections allows a complete but less extensive resection to be performed in patients with limited disease, and permits greater flexibility for those with more extensive disease or decreased hepatic functional reserve. Additionally, anatomically based segmental resections have been shown to be superior to nonanatomic wedge resections with respect to blood loss and tumor clearance.<sup>256–258</sup>

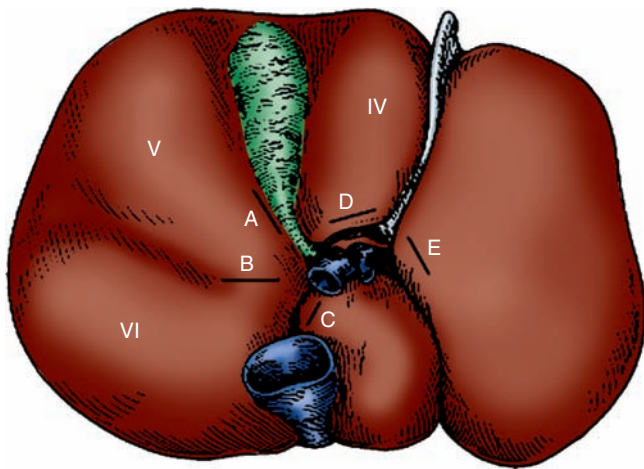
For major hepatic resections, we typically begin by establishing control of the vascular inflow. Several different techniques for vascular inflow control during hepatic resection have been described.<sup>259</sup> In the 1950s, the technique of extrahepatic portal dissection and transection, prior to parenchymal division, became a common practice.<sup>260</sup> This technique consists of individual dissection and ligation of the ipsilateral hepatic artery and portal vein within the hilus of the liver. This extrahepatic technique is still commonly employed today, with division of the inflow being performed with the use of stapling devices or suture ligation.<sup>261,262</sup> Some have noted, however, that this extrahepatic method for inflow control is time consuming, and can result in inadvertent injury to aberrant vascular or biliary structures.<sup>257</sup>

The technique of intrahepatic vascular inflow control was first reported by Couinaud and Launois.<sup>259,263,264</sup> This technique is based on the anatomic observation that the structures of the portal triad enter the liver together as a pedicle, carrying the enveloping Glisson's capsule with them into the hepatic parenchyma. Thus, within the liver, all three structures of the porta are contained within a very strong and well-formed sheath (pedicle), which can be isolated and divided *en masse* within the liver. No such well-characterized sheath exists outside the liver; therefore, the extrahepatic portal structures are

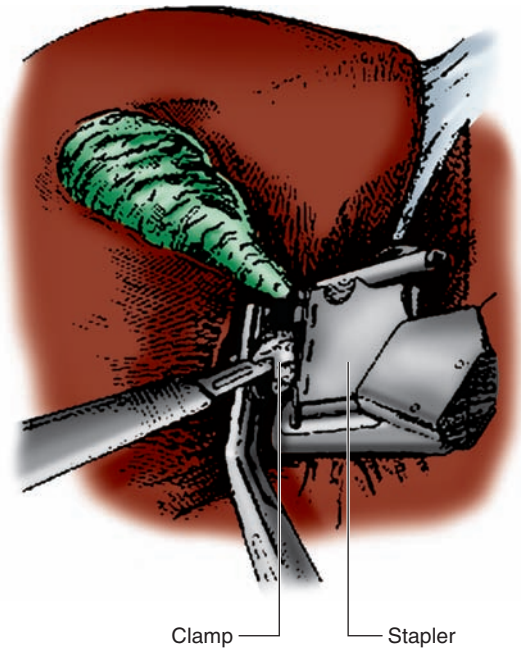
isolated and divided individually. The technique of pedicle ligation is ideally suited for right-sided tumors situated away from the hilus and requiring a right hemihepatectomy. For tumors close to the hilus, pedicle ligation may compromise the resection margin and is therefore inappropriate. For major left hemihepatectomies, pedicle ligation may be used but extrahepatic control is typically employed, as the longer extrahepatic course of the left hepatic inflow allows for relatively easy extrahepatic dissection.

Two different methods have been reported for intrahepatic ligation of the portal pedicle during hepatic hemihepatectomy.<sup>263,264</sup> These methods differ with respect to the direction from which the pedicle is approached, and the sequence for division of the parenchyma and the pedicle. In the posterior approach (or hepatotomy method), hepatotomies are created both anterior and posterior to the hilum on the side of resection (Fig. 44-11). A clamp or other instrument is used to isolate the pedicle sheath, and the pedicle is then transected with a vascular stapler prior to division of the hepatic parenchyma (Fig. 44-12). In the anterior approach (or transection method), the hepatic parenchyma is initially divided along the line of the main hepatic fissure under Pringle inflow occlusion until the pedicle is identified. Once identified, the pedicle is isolated from within the liver and divided. Regardless of approach, both techniques obviate the need for extrahepatic dissection within the hilus of the liver.

With either approach, the technique of pedicle ligation for right hemihepatectomy first involves mobilization of the right liver off the inferior vena cava. Initial division of the lowermost retrohepatic veins draining the caudate process is essential. Failure to do this can result in tearing of these veins during pedicle isolation.<sup>265</sup> Once the liver has been mobilized, the gallbladder is removed and the hilar plate lowered. A hepatotomy is created anterior to the hilum, extending from the right side of the gallbladder fossa. A second parallel incision



**FIGURE 44-11** Hepatotomy placement for pedicle ligation. **A** and **C**. Right hepatectomy. **A** and **B**. Right anterior sectorectomy. **B** and **C**. Right posterior sectorectomy. **D** and **E**. Left hepatectomy.



**FIGURE 44-12** Placement of stapling device after isolation of the right portal pedicle.

is made in the caudate process just posterior to the hilum. The hepatic parenchyma is further dissected and a finger or clamp passed to connect the two hepatotomies to encircle the portal pedicle with a tape or vessel loop. With traction, the right and left main pedicles can be exteriorized. After confirming adequate and appropriate isolation with clamping, the pedicle is divided with either an Endo GIA (Covidien, Mansfield, MA) or TA stapler (Ethicon Surgical, Cincinnati, OH).<sup>257</sup> This technique may also be used for segmental resections, as further dissection of the hepatic parenchyma after initial isolation of the main pedicle permits isolation of pedicle branches to individual hepatic sections or segments.

Once inflow control has been achieved, control of the hepatic venous outflow is undertaken; this may again be achieved intrahepatically during parenchymal transection, or outside of the liver. In general, we prefer to obtain extrahepatic control except for bulky tumors that involve the junction of the hepatic vein with the inferior vena cava, in which case hepatic vascular isolation may be appropriate. In almost all cases, with satisfactory control of central venous pressure and careful dissection of the major veins, extrahepatic outflow control can be achieved.

Once the vascular inflow and outflow have been controlled, the liver parenchyma may be transected with any variety of techniques or instruments. Our preferred approach is to crush the parenchyma with a clamp to expose the intrahepatic bile ducts and vessels, which are then individually ligated and divided. Over the past decade, a number of devices have been described for parenchymal transection. The ultrasonic dissector, water-jet dissector, harmonic scalpel, stapling devices, and most recently radiofrequency coagulators have all been used for parenchymal transection.



The majority of reports regarding the use of these instruments are descriptive, and little data exist to suggest that one technique is better than another with respect to intraoperative blood loss.<sup>32,257,266-268</sup> In the setting of cirrhosis and significant steatosis, the crushing technique for parenchymal transection is probably not ideal because the liver tissue tends to fracture and small vascular or biliary structures are more easily torn. In these situations, the use of noncrushing instruments such as the harmonic scalpel, which simultaneously coapt and coagulate, may be beneficial.

## REFERENCES

- Karhunen PJ. Benign hepatic tumours and tumour like conditions in men. *J Clin Pathol.* 1986;39(2):183-188.
- Weimann A, Ringe B, Klempnauer J, et al. Benign liver tumors: differential diagnosis and indications for surgery. *World J Surg.* 1997;21(9):983-990.
- Whitney WS, Herfkens RJ, Jeffrey RB, et al. Dynamic breath-hold multiplanar spoiled gradient-recalled MR imaging with gadolinium enhancement for differentiating hepatic hemangiomas from malignancies at 1.5 T. *Radiology.* 1993;189(3):863-870.
- Mitchell DG, Saini S, Weinreb J, et al. Hepatic metastases and cavernous hemangiomas: distinction with standard- and triple-dose gadoteridol-enhanced MR imaging. *Radiology.* 1994;193(1):49-57.
- Soyer P, Gueye C, Somville E, et al. MR diagnosis of hepatic metastases from neuroendocrine tumors versus hemangiomas: relative merits of dynamic gadolinium chelate-enhanced gradient-recalled echo and unenhanced spin-echo images. *AJR Am J Roentgenol.* 1995;165(6):1407-1413.
- Grazioli L, Morana G, Kirchin MA, et al. Accurate differentiation of focal nodular hyperplasia from hepatic adenoma at gadobenate dimeglumine-enhanced MR imaging: a prospective study. *Radiology.* 2005;236(1):166-177.
- Abdelli N, Bouche O, Thieffn G, et al. Subcutaneous seeding on the tract of percutaneous cytologic puncture with a fine needle of a hepatic metastasis from colonic adenocarcinoma. *Gastroenterol Clin Biol.* 1994;18(6-7):652-656.
- Vergara V, Garripoli A, Marucci MM, et al. Colon cancer seeding after percutaneous fine needle aspiration of liver metastasis. *J Hepatol.* 1993;18(3):276-278.
- Charny CK, Jarnagin WR, Schwartz LH, et al. Management of 155 patients with benign liver tumours. *Br J Surg.* 2001;88(6):808-813.
- Yoon SS, Charny CK, Fong Y, et al. Diagnosis, management, and outcomes of 115 patients with hepatic hemangioma. *J Am Coll Surg.* 2003;197(3):392-402.
- Descottes B, Glineur D, Lachachi F, et al. Laparoscopic liver resection of benign liver tumors. *Surg Endosc.* 2003;17(1):23-30.
- Rogula T, Gagner M. Current status of the laparoscopic approach to liver resection. *J Long Term Eff Med Implants.* 2004;14(1):23-31.
- Ishak KG, Rabin L. Benign tumors of the liver. *Med Clin North Am.* 1975;59(4):995-1013.
- Metry DW, Hawrot A, Altman C, et al. Association of solitary, segmental hemangiomas of the skin with visceral hemangiomas. *Arch Dermatol.* 2004;140(5):591-596.
- Gemer O, Moscovici O, Ben Horin CL, et al. Oral contraceptives and liver hemangioma: a case-control study. *Acta Obstet Gynecol Scand.* 2004;83(12):1199-1201.
- Reddy KR, Kligerman S, Levi J, et al. Benign and solid tumors of the liver: relationship to sex, age, size of tumors, and outcome. *Am Surg.* 2001;67(2):173-178.
- Zimmermann A, Baer HU. Fibrous tumor-liver interface in large hepatic neoplasms: its significance for tumor resection and enucleation. *Liver Transpl Surg.* 1996;2(3):192-199.
- Zimmermann A. Tumors of the liver: pathological aspects. In: Blumgart LH, Fong Y, eds. *Surgery of the Liver and Biliary Tract.* 3rd ed. New York, NY: W.B. Saunders Co.;2003;1343-1396.
- Quinn SF, Benjamin GG. Hepatic cavernous hemangiomas: simple diagnostic sign with dynamic bolus CT. *Radiology.* 1992;182(2):545-548.
- Ashida C, Fishman EK, Zerhouni EA, et al. Computed tomography of hepatic cavernous hemangioma. *J Comput Assist Tomogr.* 1987;11(3):455-460.
- Itai Y, Ohtomo K, Furui S, et al. Noninvasive diagnosis of small cavernous hemangioma of the liver: advantage of MRI. *AJR Am J Roentgenol.* 1985;145(6):1195-1199.
- Tsai CC, Yen TC, Tzen KY. The value of Tc-99m red blood cell SPECT in differentiating giant cavernous hemangioma of the liver from other liver solid masses. *Clin Nucl Med.* 2002;27(8):578-581.
- Hatayama K, Watanabe H, Ahmed AR, et al. Evaluation of hemangioma by positron emission tomography: role in a multimodality approach. *J Comput Assist Tomogr.* 2003;27(1):70-77.
- Cappellani A, Zanghi A, Di Vita M, et al. Spontaneous rupture of a giant hemangioma of the liver. *Ann Ital Chir.* 2000;71(3):379-383.
- Terkivatan T, Vrijland WW, Den Hoed PT, et al. Size of lesion is not a criterion for resection during management of giant liver haemangioma. *Br J Surg.* 2002;89(10):1240-1244.
- Farges O, Daradkeh S, Bismuth H. Cavernous hemangiomas of the liver: are there any indications for resection? *World J Surg.* 1995;19(1):19-24.
- Kammula US, Buell JF, Labow DM, et al. Surgical management of benign tumors of the liver. *Int J Gastrointest Cancer.* 2001;30(3):141-146.
- Fioole B, Kokke M, Van Hillegersberg R, et al. Adequate symptom relief justifies hepatic resection for benign disease. *BMC Surg.* 2005;5(1):7.
- Hall GW. Kasabach-Merritt syndrome: pathogenesis and management. *Br J Haematol.* 2001;112(4):851-862.
- Hochwald SN, Blumgart LH. Giant hepatic hemangioma with Kasabach-Merritt syndrome: is the appropriate treatment enucleation or liver transplantation? *HPB Surg.* 2000;11(6):413-419.
- Lerner SM, Hiatt JR, Salamandra J, et al. Giant cavernous liver hemangiomas: effect of operative approach on outcome. *Arch Surg.* 2004;139(8):818-821.
- Baer HU, Dennison AR, Mouton W, et al. Enucleation of giant hemangiomas of the liver. Technical and pathologic aspects of a neglected procedure. *Ann Surg.* 1992;216(6):673-676.
- Terminology of nodular hepatocellular lesions. International Working Party. *Hepatology.* 1995;22(3):983-993.
- Nguyen BN, Flejow JF, Terris B, et al. Focal nodular hyperplasia of the liver: a comprehensive pathologic study of 305 lesions and recognition of new histologic forms. *Am J Surg Pathol.* 1999;23(12):1441-1454.
- Bioulac-Sage P, Balabaud C, Wanless IR. Diagnosis of focal nodular hyperplasia: not so easy. *Am J Surg Pathol.* 2001;25(10):1322-1325.
- Gibbs JF, Litwin AM, Kahlenberg MS. Contemporary management of benign liver tumors. *Surg Clin North Am.* 2004;84(2):463-480.
- Hussain SM, Terkivatan T, Zondervan PE, et al. Focal nodular hyperplasia: findings at state-of-the-art MR imaging, US, CT, and pathologic analysis. *Radiographics.* 2004;24(1):3-17.
- Mathieu D, Koberer H, Cherqui D, et al. Oral contraceptive intake in women with focal nodular hyperplasia of the liver. *Lancet.* 1998;352(9141):1679-1680.
- Mortele KJ, Praet M, Van Vlierberghe H, et al. CT and MR imaging findings in focal nodular hyperplasia of the liver: radiologic-pathologic correlation. *AJR Am J Roentgenol.* 2000;175(3):687-692.
- Mortele KJ, Praet M, Van Vlierberghe H, et al. Focal nodular hyperplasia of the liver: detection and characterization with plain and dynamic-enhanced MRI. *Abdom Imaging.* 2002;27(6):700-707.
- Fabre A, Audet P, Vilgrain V, et al. Histologic scoring of liver biopsy in focal nodular hyperplasia with atypical presentation. *Hepatology.* 2002;35(2):414-420.
- Herman P, Pugliese V, Machado MA, et al. Hepatic adenoma and focal nodular hyperplasia: differential diagnosis and treatment. *World J Surg.* 2000;24(3):372-376.
- Shortell CK, Schwartz SI. Hepatic adenoma and focal nodular hyperplasia. *Surg Gynecol Obstet.* 1991;173(5):426-431.
- Klatskin G. Hepatic tumors: possible relationship to use of oral contraceptives. *Gastroenterology.* 1977;73(2):386-394.
- Gyoffry EJ, Bredfeldt JE, Black WC. Transformation of hepatic cell adenoma to hepatocellular carcinoma due to oral contraceptive use. *Ann Intern Med.* 1989;110(6):489-490.
- Foster JH, Berman MM. The malignant transformation of liver cell adenomas. *Arch Surg.* 1994;129(7):712-717.
- Foster JH. Primary benign solid tumors of the liver. *Am J Surg.* 1977;133(4):536-541.

48. Deneve JL, Pawlik TM, Cunningham S, et al. Liver cell adenoma: a multicenter analysis of risk factors for rupture and malignancy. *Ann Surg Oncol.* 2009;16(3):640–648.
49. Gordon SC, Reddy KR, Livingstone AS, et al. Resolution of a contraceptive-steroid-induced hepatic adenoma with subsequent evolution into hepatocellular carcinoma. *Ann Intern Med.* 1986;105(4):547–549.
50. Grazioli L, Federle MP, Brancatelli G, et al. Hepatic adenomas: imaging and pathologic findings. *Radiographics.* 2001;21(4):877–892.
51. Ichikawa T, Federle MP, Grazioli L, et al. Hepatocellular adenoma: multiphasic CT and histopathologic findings in 25 patients. *Radiology.* 2000;214(3):861–868.
52. Gabata T, Matsui O, Kadoya M, et al. MR imaging of hepatic adenoma. *AJR Am J Roentgenol.* 1990;155(5):1009–1011.
53. Arrive L, Flejou JF, Vilgrain V, et al. Hepatic adenoma: MR findings in 51 pathologically proved lesions. *Radiology.* 1994;193(2):507–512.
54. Trenschel GM, Schubert A, Dries V, et al. Nodular regenerative hyperplasia of the liver: case report of a 13-year-old girl and review of the literature. *Pediatr Radiol.* 2000;30(1):64–68.
55. Ishak KG. Hepatic lesions caused by anabolic and contraceptive steroids. *Semin Liver Dis.* 1981;1(2):116–128.
56. Relman DA, Falkow S, LeBoit PE, et al. The organism causing bacillary angiomatosis, peliosis hepatis, and fever and bacteremia in immunocompromised patients. *N Engl J Med.* 1991;324(21):1514.
57. Ferrozzi F, Tognini G, Zuccoli G, et al. Peliosis hepatis with pseudotumoral and hemorrhagic evolution: CT and MR findings. *Abdom Imaging.* 2001;26(2):197–199.
58. Wang SY, Ruggles S, Vade A, et al. Hepatic rupture caused by peliosis hepatis. *J Pediatr Surg.* 2001;36(9):1456–1459.
59. Omori H, Asahi H, Irinoda T, et al. Peliosis hepatis during postpartum period: successful embolization of hepatic artery. *J Gastroenterol.* 2004;39(2):168–171.
60. Cho CS, Fong Y. Biliary tract tumors. In: Yeo C, ed. *Shackelford's Surgery of the Alimentary Tract.* 6th ed. Philadelphia, PA: W.B. Saunders, Co.;2007:1519–1536.
61. Zimmerman A. Tumors of the bile duct: pathologic aspects. In: Blumgart LH, Fong Y, eds. *Surgery of the Liver and Biliary Tract.* 3rd ed. New York, NY: W.B. Saunders, Co.;2003:953–976.
62. Colombo M. Malignant neoplasms of the liver. In: Schiff L, Schiff ER, eds. *Diseases of the Liver.* 9th ed. Philadelphia, PA: J.B. Lippincott Co.; 1993:1377–1404.
63. Beasley RP, Hwang LY. Epidemiology of hepatocellular carcinoma. In: Vyas GH, Dienstag JL, Hoofnagle JH, eds. *Viral Hepatitis and Liver Disease.* New York, NY: Grune & Stratton; 1984:209–224.
64. Simonetti RG. Prevalence of antibodies to hepatitis C virus in hepatocellular carcinoma. *Lancet.* 1989;2(8675):1338.
65. Hasan F, Jeffers LJ, DeMedina M, et al. Hepatitis C-associated hepatocellular carcinoma. *Hepatology.* 1990;12(3 pt 1):589–591.
66. Di Bisceglie AM. Hepatitis C and hepatocellular carcinoma. *Semin Liver Dis.* 1995;15(1):64–69.
67. Forman D. Ames, the Ames test and the causes of cancer. *Br Med J.* 1991;303(6800):428–429.
68. Austin H, Delzell E, Grufferman S, et al. A case-control study of hepatocellular carcinoma and the hepatitis B virus, cigarette smoking and alcohol consumption. *Cancer Research.* 1986;46(2):962–966.
69. Naccarato R, Farinati F. Hepatocellular carcinoma, alcohol and cirrhosis: facts and hypothesis. *Dig Dis Sci.* 1991;36(8):1137–1142.
70. Nalpas B, Pol S, Theopot V, et al. Hepatocellular carcinoma in alcoholics. *Alcohol.* 1995;12(2):117–120.
71. Saunderson J, Latt W. Epidemiology of alcoholic liver disease. *Baillieres Clin Gastroenterol.* 1993;7(3):555–579.
72. Schiff ER. Hepatitis C and alcohol. *Hepatology.* 1997;26(3 suppl 1):S39–S42.
73. Trichopoulos D, Day NE, Kaklamani E, et al. Hepatitis B virus, tobacco smoking and ethanol consumption in the etiology of hepatocellular carcinoma. *Int J Cancer.* 1987;39(1):45–49.
74. Yu SZ. Primary prevention of hepatocellular carcinoma. *J Gastroenterol Hepatol.* 1995;10(6):674–682.
75. Leong ASY, Liew CT. Epidemiology, risk factors, etiology, premalignant lesions and carcinogenesis. In: Leong ASY, Liew CT, Lau JWY, Johnson PJ, eds. *Hepatocellular Carcinoma, Diagnosis, Investigation and Management.* London, UK: Arnold; 1999:1–17.
76. Woodall CE, Scoggins CR, Loehle J, et al. Hepatic imaging characteristics predict overall survival in hepatocellular carcinoma. *Ann Surg Oncol.* 2007;14(10):2824–2830.
77. Stipa F, Yoon SS, Liau KH, et al. Outcome of patients with fibrolamellar hepatocellular carcinoma. *Cancer.* 2006;106(6):1331–1338.
78. Collier NA, Bloom SR, Hodgson HJF, et al. Neurotensin secretion by fibrolamellar carcinoma of the liver. *Lancet.* 1984;1(8376):538–540.
79. Craig JR. Fibrolamellar carcinoma: clinical and pathological features. In: Okuda K, Tabor E, eds. *Liver Cancer.* New York, NY: Churchill Livingstone; 1999:255–262.
80. Heyward W, Lanier A, McMahon B, et al. Early detection of primary hepatocellular carcinoma. *J Am Med Assoc.* 1985;254(21):791–794.
81. Johnson PJ, Leung N, Cheng P, et al. "Hepatoma-specific" alpha-fetoprotein may permit preclinical diagnosis of malignant change in patients with chronic liver disease. *Br J Cancer.* 1997;75(2):236–240.
82. Lok AS, Lai CL. alpha-Fetoprotein monitoring in Chinese patients with chronic hepatitis B virus infection: role in early detection of hepatocellular carcinoma. *Hepatology.* 1989;9(1):110–115.
83. Sherman H, Hardison J. The importance of a coexistent hepatic rub and bruit. *JAMA.* 1979;241(14):1495.
84. Ihde DC, Sherlock P, Winawer SJ, et al. Clinical manifestations of hepatoma. A review of 6 years experience at a cancer hospital. *Am J Med.* 1974;56(1):83–91.
85. Lai CL, Wu PC, Chan GC, et al. Clinical features of hepatocellular carcinoma: review of 211 patients in Hong Kong. *Cancer.* 1981;47(11):2746–2755.
86. Shiu W, Dewar G, Leung N, et al. Hepatocellular carcinoma in Hong Kong: clinical study on 340 cases. *Oncology.* 1990;47(3):241–245.
87. Ho J, Wu PC, Kung TM. An autopsy study of hepatocellular carcinoma in Hong Kong. *Pathology.* 1981;13(3):409–415.
88. Ng WD, Chan YT, Ho KK, Kong CK. Injection sclerotherapy for bleeding esophageal varices in cirrhotic patients with hepatocellular carcinoma. *Gastrointest Endosc.* 1989;35(1):69–70.
89. Yeo W, Sung JY, Ward SC, et al. A prospective study of upper gastrointestinal haemorrhage in patients with hepatocellular carcinoma. *Digestive Disease Sciences.* 1995;40(12):2516–2520.
90. Dewar GA, Griffin SM, Ku KW, et al. Management of bleeding liver tumours in Hong Kong. *Br J Surg.* 1991;78(4):463–466.
91. Chearani O, Plengvanit U, Asavanichi C, et al. Spontaneous rupture of primary hepatoma: report of 63 cases with particular reference to the pathogenesis and rationale treatment by hepatic artery ligation. *Cancer.* 1983;51(8):1532–1536.
92. Chen MF, Hwang TL, Jeng LB, et al. Surgical treatment for spontaneous rupture of hepatocellular carcinoma. *Surg Gynecol Obstet.* 1988;167(2):99–102.
93. Kew MC, Dos Santos HA, Sherlock S. Diagnosis of primary liver cancer of the liver. *Br Med J.* 1971;4(5784):408–411.
94. Nagasue N, Inokuchi K. Spontaneous and traumatic rupture of hepatoma. *Br J Surg.* 1979;66(4):248–250.
95. Edmondson HA, Steiner PE. Primary carcinoma of the liver: a study of 100 cases among 48,900 necropsies. *Cancer.* 1954;7(3):462–503.
96. Kappel DA, Miller DR. Primary hepatic carcinoma. A review of thirty-seven patients. *Am J Surg.* 1972;124(6):798–802.
97. Kew MC, Geddes EW. Hepatocellular carcinoma in rural southern African Blacks. *Medicine.* 1982;61(2):98–108.
98. Kojiro M, Kawabata K, Kawano Y, et al. Hepatocellular carcinoma presenting as intrabiliary duct tumor growth. A clinicopathologic study of 24 cases. *Cancer.* 1982;49(10):2144–2147.
99. Lai EC, Ng IO, Ng MM, et al. Long-term results of resection for large hepatocellular carcinoma: a multivariate analysis of clinicopathological features. *Hepatology.* 1990;11(5):815–818.
100. Lau WY, Leung KL, Leung TW, et al. Obstructive jaundice secondary to hepatocellular carcinoma. *Surg Oncol.* 1995;4(6):303–308.
101. Lee NW, Wong KP, Siu KF, Wong J. Cholangiography in hepatocellular carcinoma with obstructive jaundice. *Clinical Radiology.* 1984;35(119):123.
102. Okuda K. Clinical aspects of hepatocellular carcinoma—analysis of 134 cases. In: Okuda K, Peters F, eds. *Hepatocellular Carcinoma.* New York, NY: Wiley; 1976:387–436.
103. Roslyn JJ, Kuchenbecker S, Longmire WP, et al. Floating tumor debris. A cause of intermittent biliary obstruction. *Arch Surg.* 1984;119(11):1312–1315.

104. Afroudakis A, Bhuta SM, Ranganath KA, et al. Obstructive jaundice caused by hepatocellular carcinoma. Report of three cases. *Digestive Diseases*. 1978;23(7):609–617.
105. Lau WY, Leow CK, Li AKC. A logical approach to hepatocellular carcinoma presenting with jaundice. *Ann Surg*. 1997;225(3):281–285.
106. van Sonnenberg E, Ferucci J. Bile duct obstruction in hepatocellular carcinoma (hepatoma)—clinical and cholangiographical characteristics. Report of 6 cases and review of the literature. *Radiology*. 1979;130(1):7–13.
107. Wu CS, Wu SS, Chen PC, et al. Cholangiography of icteric type hepatoma. *Am J Gastroenterol*. 1994;89(5):774–777.
108. Kew MC, Dusheiko GM. Paraneoplastic manifestations of hepatocellular carcinoma. In: Berk PD, Chalmers TC, eds. *Frontiers Liver and Disease*. New York, NY: Thieme-Stratton; 1981:305–319.
109. Helzberg JH, McPhee MS, Zarling EJ, Lukert BP. Hepatocellular carcinoma: an unusual course with hyperthyroidism and inappropriate thyroid-stimulating hormone production. *Gastroenterology*. 1985;88(1 pt 1):181–184.
110. McFrazee AJ, Yeung RRT. Further observations on hypoglycaemia in hepatocellular carcinoma. *Am J Med*. 1969;47(2):220–235.
111. Shapiro E, Bell GI, Polonsky K, et al. Tumor hypoglycemia: relationship to high molecular weight insulin-like growth factor II. *J Clin Invest*. 1990;85(5):1672–1679.
112. Lau JWY, Leow CK. Surgical management (including liver transplantation). In: Leong ASY, Leiw CT, Lau JWY, Johnson PJ, eds. *Hepatocellular Carcinoma. Diagnosis, Investigation and Management*. London, UK: Arnold; 1999:147–172.
113. Caturelli E, Biscaglia M, Fusilli S, et al. Cytological versus microhistological diagnosis of hepatocellular carcinoma: comparative accuracies in the same fine-needle biopsy specimen. *Dig Dis Sci*. 1996;41(12):2326–2331.
114. Voyles CR, Bowley NJ, Allison DJ, et al. Carcinoma of the proximal extrahepatic biliary tree radiologic assessment and therapeutic alternatives. *Ann Surg*. 1983;197(2):188–194.
115. Williamson BW, Blumgart LH, Mckellar NJ. Management of tumors of the liver. Combined use of arteriography and venography in the assessment of respectability, especially in hilar tumours. *Am J Surg*. 1980;139(2):210–215.
116. Lau WY, Arnold M, Leung NW, et al. Hepatic intraarterial lipiodol ultrasound guided biopsy in the management of hepatocellular carcinoma. *Surg Oncol*. 1993;2(2):119–124.
117. Hasegawa H, Yamazaki S, Makuuchi M, et al. Hepatectomies pour hepatocarcinome sur goë cirrhotique: schémas desionnels et principes de reanimation peri-operatoire. Experience de 204 cas. *Journal de Chirurgie*. 1987;124(8–9):425–431.
118. Noun R, Jagot P, Farges O, et al. High preoperative serum alanine transferase levels: effect on the risk of liver resection in child grade A cirrhotic patients. *World J Surg*. 1997;21(4):390–395.
119. Lau WY, Lai EC. Hepatocellular carcinoma-current management and recent advances. *Hepatobiliary Pancreat Dis Int*. 2008;7(3):237–257.
120. Child CG, Turcotte JG. Surgery and portal hypertension. In: Child CG, ed. *The liver and portal hypertension*. Philadelphia, PA: W.B. Saunders; 1964:50–62.
121. Pugh RN, Murray-Lyon IM, Dawson JL, et al. Transection of the oesophagus for bleeding oesophageal varices. *Br J Surg*. 1973;60(8):646–649.
122. Franco D, Borgonovo G. Liver resection in cirrhosis of the liver. In: Blumgart LH, Fong Y, eds. *Surgery of the Liver and Biliary Tract*. 3rd ed. New York, NY: W.B. Saunders, Co.; 2003:1725–1742.
123. Bismuth H, Chiche L, Adam R, et al. Liver resection versus transplantation for hepatocellular carcinoma in cirrhotic patients. *Ann Surg*. 1993;218(2):145–151.
124. Hemming AW, Scudamore CH, Shackleton CR, et al. Indocyanine green clearance as a predictor of successful hepatic resection in cirrhotic patients. *Am J Surg*. 1992;163(5):515–518.
125. Gill RA, Goodman MW, Golfus GR, et al. Aminopyrine breath test predicts surgical risk for patients with liver disease. *Ann Surg*. 1983;198(6):701–704.
126. Takenaka K, Kanematsu T, Fukuzawa K, et al. Can hepatic failure after surgery for hepatocellular carcinoma in cirrhotic patients be prevented? *World J Surg*. 1990;14(1):123–127.
127. Bruix J, Castells A, Bosch J, et al. Surgical resection of hepatocellular carcinoma in cirrhotic patients: prognostic value of preoperative portal pressure. *Gastroenterology*. 1996;111(4):1018–1022.
128. Bismuth H, Houssin D, Mazmanian G. Postoperative liver insufficiency: prevention and management. *World J Surg*. 1983;7(4):505–510.
129. Fong Y, Sun RL, Jarnagin W, Blumgart LH. An analysis of 412 cases of hepatocellular carcinoma at a Western center. *Ann Surg*. 1999;229(6):790–799.
130. Vauthey JN, Klimstra D, Blumgart LH. A simplified staging system for hepatocellular carcinomas. *Gastroenterology*. 1995;108(2):617–618.
131. Nathan H, Schulick RD, Choti MA, et al. Predictors of survival after resection of early hepatocellular carcinoma. *Ann Surg*. 2009;249(5):799–805.
132. Cha C, Fong Y, Jarnagin WR, et al. Predictors and patterns of recurrence after resection of hepatocellular carcinoma. *J Am Coll Surg*. 2003;197(5):753–758.
133. Tsuzuki T, Sugioika A, Ueda M, et al. Hepatic resection for hepatocellular carcinoma. *Surgery*. 1990;107(5):511–520.
134. Nagasue N, Kohno H, Chang YC, et al. Liver resection for hepatocellular carcinoma. Results of 229 consecutive patients during 11 years. *Ann Surg*. 1993;217(4):375–384.
135. Cho CS, Gonen M, Shia J, et al. A novel prognostic nomogram is more accurate than conventional staging systems for predicting survival after resection of hepatocellular carcinoma. *J Am Coll Surg*. 2008;206(2):281–291.
136. Nagasue N, Yukaya H, Ogawa Y, et al. Human liver regeneration after major hepatic resection. A study of normal liver and livers with chronic hepatitis and cirrhosis. *Ann Surg*. 1987;206(1):30–39.
137. Vauthey JN, Klimstra D, Franceschi D, et al. Factors affecting long-term outcome after hepatic resection for hepatocellular carcinoma. *Am J Surg*. 1995;169(January):28–35.
138. Ho MC, Huang GT, Tsang YM, et al. Liver resection improves the survival of patients with multiple hepatocellular carcinomas. *Ann Surg Oncol*. 2009;16(4):848–855.
139. Tanabe G, Sakamoto M, Akazawa K, et al. Intraoperative risk factors associated with hepatic resection. *Br J Surg*. 1995;82(9):1262–1265.
140. Kanematsu T, Takenaka K, Matsumata T, et al. Limited hepatic resection effective for selected cirrhotic patients with primary liver cancer. *Ann Surg*. 1984;199(1):51–56.
141. The Liver Study Group of Japan. Primary liver cancer in Japan. *Cancer*. 1980;45(10):2663–2669.
142. Nagao T, Goto S, Kawano N, et al. Hepatic resection for hepatocellular carcinoma: clinical features and long-term prognosis. *Ann Surg*. 1987;205(1):33–40.
143. Capussotti L, Borgonovo G, Bouzari H, et al. Results of major hepatectomy for large primary liver cancer in patients with cirrhosis. *Br J Surg*. 1994;81(3):427–431.
144. Fuster J, Garcia-Valdecasas JC, Grande L, et al. Hepatocellular carcinoma and cirrhosis—results of surgical treatment in a European series. *Ann Surg*. 1996;223(3):297–302.
145. Melendez JA, Arslan V, Fischer ME, et al. Perioperative outcomes of major hepatic resections under low central venous pressure anesthesia: blood loss, blood transfusion, and the risk of postoperative renal dysfunction. *J Am Coll Surg*. 1998;187(6):620–625.
146. Kim YI, Nakashima K, Tada I, et al. Prolonged normothermic ischaemia of human cirrhotic liver during hepatectomy: a preliminary report. *Br J Surg*. 1993;80(12):1566–1570.
147. Man K, Fan ST, Ng IO, et al. Prospective evaluation of Pringle maneuver in hepatectomy for liver tumors by a randomized study. *Ann Surg*. 1997;226(6):704–711.
148. DeMatteo RP, Palese C, Jarnagin WJ, et al. Segmental resection superior to wedge resection for colorectal liver metastases. *J Gastrointest Surg*. 2000;4(2):178–184.
149. Lau WY, Leung KL, Leung TW, et al. Resection of hepatocellular carcinoma with diaphragmatic invasion. *Surg Oncol*. 1995;82(2):264–266.
150. Sitzmann JV, Abrams R. Improved survival for hepatocellular cancer with combination surgery and multimodality treatment. *Ann Surg*. 1993;217(2):149–154.
151. Yamanaka N, Okamoto E, Fujihara S, et al. Do the tumor cells of hepatocellular carcinomas dislodge into the portal venous system during hepatic resection? *Cancer*. 1992;70(9):2263–2267.
152. Farinati F, Rinaldi M, Gianni S, et al. How should patients with hepatocellular carcinoma be staged? Validation of a new prognostic system. *Cancer*. 2000;89(11):2266–2273.
153. Zhao WH, Ma ZM, Zhou XR, et al. Prediction of recurrence and prognosis in patients with hepatocellular carcinoma after resection by use of CLIP score. *World J Gastroenterol*. 2002;8(2):237–242.



154. Bruix J, Llovet JM. Prognostic assessment and evaluation of the benefits of treatment. *J Clin Gastroenterol.* 2002;35(5 suppl 2):S138–S142.
155. Levy I, Sherman M, The Liver Cancer Study Group of the University of Toronto. Staging of hepatocellular carcinoma: assessment of the CLIP, Okuda, and Child-Pugh staging systems in a cohort of 257 patients in Toronto. *Gut.* 2002;50(6):881–885.
156. Rabe C, Lenz M, Schmitz V, et al. An independent evaluation of modern prognostic scores in a central European cohort of 120 patients with hepatocellular carcinoma. *Eur J Gastroenterol Hepatol.* 2003;15(12):1305–1315.
157. Ramacciato G, Mercantini P, Cautero N, et al. Prognostic evaluation of the new American Joint Committee on Cancer/International Union Against Cancer staging system for hepatocellular carcinoma: analysis of 112 cirrhotic patients resected for hepatocellular carcinoma. *Ann Surg Oncol.* 2005;12(4):289–297.
158. Marrero JA, Fontana RJ, Barrat A, et al. Prognosis of hepatocellular carcinoma: comparison of 7 staging systems in an American cohort. *Hepatology.* 2005;41(4):707–716.
159. Fan J, Tang ZY, Yu YQ, et al. Improved survival with resection after transcatheter arterial chemoembolization (TACE) for unresectable hepatocellular carcinoma. *Dig Surg.* 1998;15(6):674–678.
160. Harada T, Matsuo K, Inoue T. Is preoperative hepatic arterial chemoembolization safe and effective for hepatocellular carcinoma? *Ann Surg.* 1996;224(1):4–9.
161. Tang ZY, Yu YQ, Zhou XD, et al. Treatment of unresectable primary liver cancer: with reference to cytoreduction and sequential resection. *World J Surg.* 1995;19(1):47–52.
162. Lau WY, Ho S, Leung TW, et al. Selective internal radiation therapy for nonresectable hepatocellular carcinoma with intraarterial infusion of 90 yttrium microspheres. *Int J Radiat Oncol Biol Phys.* 1998;40(3):583–592.
163. Riaz A, Kulik L, Lewandowski RJ, et al. Radiologic-pathologic correlation of hepatocellular carcinoma treated with internal radiation using yttrium-90 microspheres. *Hepatology.* 2009;49(4):1185–1193.
164. Majno PE, Adam R, Bismuth H, et al. Influence of preoperative transarterial lipiodol chemoembolization on resection and transplantation for hepatocellular carcinoma in patients with cirrhosis. *Ann Surg.* 1997;226(6):688–701.
165. Yoshida T, Sakon M, Umehita K, et al. Appraisal of transarterial immunoembolization for hepatocellular carcinoma: a clinicopathologic study. *J Clin Gastroenterol.* 2001;32(1):59–65.
166. Lygidakis NJ, Tsiliakos S. Multidisciplinary management of hepatocellular carcinoma. *Hepatogastroenterology.* 1996 Nov;43(12):1611–1619.
167. Borzutzky CA, Turbner EH. The predictive value of hepatic artery perfusion scintigraphy. *J Nucl Med.* 1985;26(10):1153–1156.
168. Palavecino M, Chun YS, Madoff DC, et al. Major hepatic resection for hepatocellular carcinoma with or without portal vein embolization: perioperative outcome and survival. *Surgery.* 2009;145(4):399–405.
169. Seo DD, Lee HC, Jang MK, et al. Preoperative portal vein embolization and surgical resection in patients with hepatocellular carcinoma and small future liver remnant volume: comparison with transarterial chemoembolization. *Ann Surg Oncol.* 2007;14(12):3501–3509.
170. Okuda K, Ohtsuki T, Obata H, et al. Natural history of hepatocellular carcinoma and prognosis in relation to treatment. *Cancer.* 1985;56(4):918–928.
171. Friedman M. Primary hepatocellular cancer: present results and future prospects. *Int J Radiat Oncol Biol Phys.* 1983;9(12):1841–1850.
172. Lai EC, Choi TK, Tong SW, et al. Treatment of unresectable hepatocellular carcinoma: results of a randomised controlled trial. *World J Surg.* 1986;10(3):501–509.
173. Carr BI, Zajko A, Bron K, et al. Phase II study of Spherex (degradable starch microspheres) injected into the hepatic artery in conjunction with doxorubicin and cisplatin in the treatment of advanced-stage hepatocellular carcinoma: interim analysis. *Semin Oncol.* 1997;24(2 suppl 6):S6.
174. Izumi R, Shimizu K, Iyobe T, et al. Postoperative adjuvant arterial infusion of lipiodol containing anticancer drugs in patients with hepatocellular carcinoma. *Hepatology.* 1994;20(2):295–301.
175. Lai EC, Lo CM, Fan ST, et al. Postoperative adjuvant chemotherapy after curative resection of hepatocellular carcinoma: a randomized controlled trial. *Arch Surg.* 1998;133(2):183–188.
176. Wu CC, Ho YZ, Ho WL, et al. Preoperative transcatheter arterial chemoembolization for resectable large hepatocellular carcinoma. A reappraisal. *Br J Surg.* 1995;82(1):122–126.
177. Muto Y, Moriawaki H, Ninomiya M, et al. Prevention of second primary tumors by an acyclic retinoid, polyphenolic acid, in patients with hepatocellular carcinoma. *N Engl J Med.* 1996;334(24):1561–1567.
178. Lau WY, Leung TW, Ho SK, et al. Adjuvant intra-arterial iodine-131-labelled lipiodol for resectable hepatocellular carcinoma: a prospective randomized trial. *Lancet.* 1999;353(9155):797–801.
179. Llovet JM, Ricci S, Mazzaferro V, et al. Sorafenib in advanced hepatocellular carcinoma. *N Engl J Med.* 2008;359(4):378–390.
180. Ringe B, Hanack U, Schulze FP. Liver transplantation for tumors. In: Blumgart LH, Fong Y, eds. *Surgery of the Liver and Biliary Tract.* 3rd ed. New York, NY: W.B. Saunders, Co.; 2003:2097–2106.
181. Selby R, Kadry Z, Carr B, et al. Liver transplantation for hepatocellular carcinoma. *World J Surg.* 1995;19(1):53–58.
182. Yokoyama I, Todo S, Iwatsuki S, Starzl TE. Liver transplantation in the treatment of primary liver cancer. *Hepatogastroenterology.* 1990;37(2):188–193.
183. Haug CE, Jenkins RL, Rohrer RJ, et al. Liver transplantation for primary hepatic cancer. *Transplantation.* 1992;53(2):376–382.
184. Mazzaferro V, Regalia E, Doci R, et al. Liver transplantation for the treatment of small hepatocellular carcinomas in patients with cirrhosis. *N Engl J Med.* 1996;334(11):693–699.
185. Graziadei IW, Sandmueller H, Waldenberger P, et al. Chemoembolization followed by liver transplantation for hepatocellular carcinoma impedes tumor progression while on the waiting list and leads to excellent outcome. *Liver Transpl.* 2003;9(6):557–563.
186. Millonig G, Graziadei IW, Freund MC, et al. Response to preoperative chemoembolization correlates with outcome after liver transplantation in patients with hepatocellular carcinoma. *Liver Transpl.* 2007;13(2):272–279.
187. Yao FY, Kerland RK Jr, Hirose R, et al. Excellent outcome following down-staging of hepatocellular carcinoma prior to liver transplantation: an intention-to-treat analysis. *Hepatology.* 2008;48(3):819–827.
188. Yang LY, Fang F, Ou DP, et al. Solitary large hepatocellular carcinoma: a specific subtype of hepatocellular carcinoma with good outcome after hepatic resection. *Ann Surg.* 2009;249(1):118–123.
189. Liao KH, Ruo L, Shia J, et al. Outcome of partial hepatectomy for large (>10 cm) hepatocellular carcinoma. *Cancer.* 2005;104(9):1948–1955.
190. Pawlik TM, Poon RT, Abdalla EK, et al. Critical appraisal of the clinical and pathologic predictors of survival after resection of large hepatocellular carcinoma. *Arch Surg.* 2005;140(5):450–457.
191. Livraghi T, Bolondi L, Buscarini L, et al. No treatment, resection and ethanol injection in hepatocellular carcinoma: a retrospective analysis of survival in 391 patients with cirrhosis. Italian Cooperative HCC Study Group. *J Hepatol.* 1995;22(5):522–526.
192. Nonami T, Harada A, Kurokawa T, et al. Hepatic resection for hepatocellular carcinoma. *Am J Surg.* 1997;173(4):288–291.
193. Cha CH, Ruo L, Fong Y, et al. Resection of hepatocellular carcinoma in patients otherwise eligible for liver transplantation. *Ann Surg.* 2003;238(3):315–321.
194. Lo CM, Ngan H, Tso WK, et al. Randomized controlled trial of transarterial lipiodol chemoembolization for unresectable hepatocellular carcinoma. *Hepatology.* 2002;35(5):1164–1171.
195. Llovet JM, Real MI, Montana X, et al. Arterial embolisation or chemoembolisation versus symptomatic treatment in patients with unresectable hepatocellular carcinoma: a randomized controlled trial. *Lancet.* 2002;359(9319):1734–1739.
196. Chok KS, Ng KK, Poon RT, et al. Comparable survival in patients with unresectable hepatocellular carcinoma treated by radiofrequency ablation or transarterial chemoembolization. *Arch Surg.* 2006;141(12):1231–1236.
197. Kuwayti K, Baggenstoss AH, Stauffer MH, Priestly JI. Carcinoma of the major intrahepatic and extrahepatic bile ducts exclusive of the papilla of Vater. *Surg Gynecol Obstet.* 1957;104(3):357–366.
198. Carriaga MT, Henson DE. Liver, gallbladder, extrahepatic bile ducts, and pancreas. *Cancer.* 1995;75(suppl 1):S171–S190.
199. Okuda K, Kubo Y, Okazaki N, et al. Clinical aspects of intrahepatic bile duct carcinoma including hilar carcinoma. A study of 57 autopsy proven cases. *Cancer.* 1977;39(1):232–246.
200. Burke EC, Jarnagin WR, Hochwald SN, et al. Hilar Cholangiocarcinoma: patterns of spread, the importance of hepatic resection for curative operation, and a presurgical clinical staging system. *Ann Surg.* 1998;228(3):385–394.

201. Nagorney DM, Donohue JH, Farnell MB, et al. Outcomes after curative resections of cholangiocarcinoma. *Arch Surg.* 1993;128(8):871-879.
202. Broome U, Olsson R, Loof L, et al. Natural history and prognostic factors in 305 Swedish patients with primary sclerosing cholangitis. *Gut.* 1996;38(4):610-615.
203. Pitt HA, Nakeeb A, Abrams RA, et al. Perihilar cholangiocarcinoma. Postoperative radiotherapy does not improve survival. *Ann Surg.* 1995;221(6):788-798.
204. LaRusso NF, Shneider BL, Black D, et al. Primary sclerosing cholangitis: summary of a workshop. *Hepatology.* 2006;44(3):746-764.
205. Cho CS, Dayton MT, Thompson JS, et al. Proctocolectomy-ileal pouch-anal anastomosis for ulcerative colitis after liver transplantation for primary sclerosing cholangitis: a multi-institutional analysis. *J Gastrointest Surg.* 2008;12(7):1221-1226.
206. Vogt DP. Current management of cholangiocarcinoma. *Oncology.* 1988;2(6):37-44, 54.
207. Hewitt PM, Krige JE, Bornman PC, et al. Choledochal cyst in pregnancy; a therapeutic dilemma. *J Am Coll Surg.* 1995;181(3):237-240.
208. Becker CD, Glartli A, Maibach R, et al. Percutaneous palliation of malignant obstructive jaundice with the Wallstent endoprosthesis: follow-up and reintervention in patients with hilar and non-hilar obstruction. *J Vasc Inter Radiol.* 1993;4(5):597-604.
209. Jeng KS, Ohta I, Yang FS, et al. Coexisting sharp ductal angulation with intrahepatic biliary strictures in right hepatolithiasis. *Arch Surg.* 1994;129(10):1097-1102.
210. Tanaka K, Ikoma A, Hamada N, et al. Biliary tract cancer accompanied by anomalous junction of pancreaticobiliary ductal system in adults. *Am J Surg.* 1998;175(3):218-220.
211. Chu KM, Lo CM, Liu CL, Fan ST. Malignancy associated with hepatolithiasis. *Hepato-Gastroenterology.* 1997;44(14):352-357.
212. Kubo S, Kinoshita H, Hirohashi K, Hamba H. Hepatolithiasis associated with cholangiocarcinoma. *World J Surg.* 1995;19(4):637-641.
213. Watanapa P. Cholangiocarcinoma in patients with opisthorchiasis. *Br J Surg.* 1996;83(8):1062-1064.
214. Harrison LE, Fong Y, Klimstra DS, et al. Surgical treatment of 32 patients with peripheral intrahepatic cholangiocarcinoma. *Br J Surg.* 1998;85(8):1068-1070.
215. Berdah SV, Delpero JR, Garcia S, et al. A western surgical experience of peripheral cholangiocarcinoma. *Br J Surg.* 1996;83(11):1517-1521.
216. Chu KM, Lai EC, al-Hadeedi SY, et al. Intrahepatic cholangiocarcinoma. *World J Surg.* 1997;21(3):301-306.
217. Severini A, Bellomi M, Cozzi G, et al. Lymphomatous involvement of intrahepatic and extrahepatic biliary ducts. PTC and ERCP findings. *Acta Radiol Diagn.* 1981;22(2):159-163.
218. Nakeeb A, Pitt HA, Sohn TA, et al. Cholangiocarcinoma: a spectrum of intrahepatic perihilar, and distal tumors. *Ann Surg.* 1996;224(4):463-475.
219. Chen MF, Jan YY, Wang CS, et al. Clinical experience in 20 hepatic resections for peripheral cholangiocarcinoma. *Cancer.* 1989;64(11):2226-2232.
220. Tompkins RK, Thomas D, Wile A, Longmire WP. Prognostic factors in bile duct carcinoma. Analysis of 96 cases. *Ann Surg.* 1981;194(4):447-457.
221. Fong Y, Blumgart LH, Lin E, et al. Outcome of treatment for distal bile duct cancer. *Br J Surg.* 1996;83(12):1712-1715.
222. Saunders K, Longmire W, Jr., Tompkins R, et al. Diffuse bile duct tumors: guidelines for management. *Am Surg.* 1991;57(12):816-820.
223. Tamandi D, Kaczirek K, Gruenberger B, et al. Lymph node ratio after curative surgery for intrahepatic cholangiocarcinoma. *Br J Surg.* 2009;96(8):919-925.
224. Endo I, Gonen M, Yopp AC, et al. Intrahepatic cholangiocarcinoma: rising frequency, improved survival, and determinants of outcome after resection. *Ann Surg.* 2008; 248(1):84-96.
225. Altae MY, Johnson PJ, Farrant JM, Williams R. Etiologic and clinical characteristics of peripheral and hilar cholangiocarcinoma. *Cancer.* 1991;68(9):2051-2055.
226. Penn I. Hepatic transplantation for primary and metastatic cancers of the liver. *Surgery.* 1991;110(4):726-735.
227. Sudan D, DeRoover A, Cinnakotla S, et al. Radiochemotherapy and transplantation allow long-term survival for nonresectable hilar cholangiocarcinoma. *Am J Transplant.* 2002;2(8):774-779.
228. DeVreede I, Steers JL, Burch PA, et al. Prolonged disease-free survival after orthotopic liver transplantation plus adjuvant chemoradiation for cholangiocarcinoma. *Liver Transpl.* 2000;6(3):317-319.
229. Rea DJ, Heimbach JK, Rosen CB. Liver transplantation with neoadjuvant chemoradiation is more effective than resection for hilar cholangiocarcinoma. *Ann Surg.* 2005;242(3):451-458.
230. Rosen CB, Heimbach JK, Gores GJ. Surgery for cholangiocarcinoma: the role of liver transplantation. *HPB.* 2008;10(3):186-189.
231. Todoroki T. Chemotherapy for bile duct carcinoma in the light of adjuvant chemotherapy to surgery. *Hepatogastroenterology.* 2000; 47(33):644-649.
232. Stillwagon GB, Order SE, Haulk T, et al. Variable low dose rate irradiation (131I-anti-CEA) and integrated low dose chemotherapy in the treatment of nonresectable primary intrahepatic cholangiocarcinoma. *Int J Radiat Oncol Biol Phys.* 1991;21(6):1601-1605.
233. Jarnagin WR, Schwartz LH, Gultekin DH, et al. Regional chemotherapy for unresectable primary liver cancer: results of a phase II clinical trial and assessment of DCE-MRI as a biomarker of survival. *Ann Oncol.* 2009;20(9):1589-1595.
234. Halpern E, Kun LE, Constine LS, et al. *Pediatric Radiation Oncology.* New York, NY: Raven Press; 1989:280.
235. Stocker JT, Ishak KG. Hepatoblastoma. In: Okuda K, Ihak KG, eds. *Neoplasms of the Liver.* New York, NY: Springer-Verlag; 1987.
236. Lack EE, Neave C, Vawter GE. Hepatoblastoma. A clinical and pathologic study of 54 cases. *Am J Surg Pathol.* 1982;6(8):693-705.
237. Mahour GH, Wogu GU, Siegel SE, Isaacs H. Improved survival in infants and children with primary malignant liver tumors. *Am J Surg.* 1983;146(2):236-240.
238. Weinberg AG, Finegold MJ. Primary hepatic tumors of childhood. *Hum Pathol.* 1983;14(6):512-537.
239. Schmidt D, Harms D, Lang W. Primary malignant tumors in childhood. *Virchows Archiv A Pathol Anat Histopathol.* 1985;407(4):387-405.
240. Stevens WR, Johnson CD, Stephens DH, Nagorney DM. Fibrolamellar hepatocellular carcinoma: stage at presentation and results of aggressive surgical management. *AJR Am J Roentgenol.* 1995;164:1153.
241. Hata Y, Ishizu H, Ohmori K, et al. Flow cytometric analysis of the nuclear DNA content of hepatoblastoma. *Cancer.* 1991;68(12):2566-2570.
242. Filler RM, Ehrlich PF, Greenberg ML, Babyn PS. Preoperative chemotherapy in hepatoblastoma. *Surgery.* 1991;110(4):591-596.
243. Ninane J, Perilongo G, Stalens JP, et al. Effectiveness and toxicity of cisplatin and doxorubicin (PLADO) in childhood hepatoblastoma and hepatocellular carcinoma: a SIOP pilot study. *J Med Ped Oncol.* 1991;19(3):199-203.
244. Evans AE, Land VJ, Newton WA, et al. Combination chemotherapy (vincristine, adriamycin, cyclophosphamide, and 5-fluorouracil) in the treatment of children with malignant hepatoma. *Cancer.* 1982;50(5):821-826.
245. Habrand JL, Pritchard J. Role of radiotherapy in hepatoblastoma and hepatocellular carcinoma in children and adolescents: results of a survey conducted by the SIOP Liver Tumour Study Group. *J Med Ped Oncol.* 1991;19(3):208.
246. Weiss SW, Enzinger FM. Epithelioid hemangioendothelioma: a vascular tumor often mistaken for a carcinoma. *Cancer.* 1982;50(5):970-981.
247. Mark L, Delorme F, Creech JL, et al. Clinical and morphological features of hepatic angiosarcoma in vinyl chloride workers. *Cancer.* 1976;37(1):149-163.
248. Ishak KG, Sesterhenn IA, Goodman ZD, et al. Epithelioid hemangioendothelioma of the liver: a clinicopathologic and follow-up study of 32 cases. *Hum Pathol.* 1984;15(9):839-852.
249. Leuschner I, Schmidt D, Harms D. Undifferentiated sarcoma of the liver in childhood: morphology, flow cytometry, and literature review. *Hum Pathol.* 1990;21(1):68-76.
250. Stocker JT, Ishak KG. Undifferentiated (embryonal) sarcoma of the liver: report of 31 cases. *Cancer.* 1978;42(1):336-348.
251. Shin MS, Carpenter JT, Jr., Ho KJ. Epithelioid hemangioendothelioma: CT manifestations and possible linkage to vinyl chloride exposure. *J Comput Assist Tomogr.* 1991 May;15(3):505-507.
252. Scheele J, Stang R, Altendorf-Hofmann A, Paul M. Resection of colorectal liver metastases. *World J Surg.* 1995;19:59-71.
253. Gayowski TJ, Iwatsuki S, Madariaga JR, et al. Experience in hepatic resection for metastatic colorectal cancer: analysis of clinical and pathologic risk factors. *Surgery.* 1994;116:703-711.
254. Jarnagin WR, Gonen M, Fong Y, et al. Improvement in perioperative outcome after hepatic resection: analysis of 1,803 consecutive cases over the past decade. *Ann Surg.* 2002;236(4):397-406.

255. Gold JS, Are C, Kornprat P, et al. Increased use of parenchymal-sparing surgery for bilateral liver metastases from colorectal cancer is associated with improved mortality without change in oncologic outcome: trends in treatment over time in 440 patients. *Ann Surg.* 2008;247(1):109–117.
256. Billingsley KG, Jarnagin WR, Fong Y, Blumgart LH. Segment-oriented hepatic resection in the management of malignant neoplasms of the liver. *J Am Coll Surg.* 1998;187(5):471–481.
257. DeMatteo RP, Fong Y, Jarnagin WR, Blumgart LH. Recent advances in hepatic resection. *Semin Surg Oncol.* 2000;19(2):200–207.
258. DeMatteo RP, Palese C, Jarnagin WR, et al. Anatomic segmental hepatic resection is superior to wedge resection as an oncologic operation for colorectal liver metastases. *J Gastrointest Surg.* 2000;4(2):178–184.
259. Couinaud CM. A simplified method for controlled left hepatectomy. *Surgery.* 1985;97(3):358–361.
260. Foster JH. History of liver surgery. *Arch Surg.* 1991;126(3):381–387.
261. McEntee GP, Nagorney DM. Use of vascular staplers in major hepatic resections. *Br J Surg.* 1991;78(1):40–41.
262. Fong Y, Blumgart LH. Useful stapling techniques in liver surgery. *J Am Coll Surg.* 1997;185(1):93–100.
263. Launois B, Jamieson GG. The importance of Glisson's capsule and its sheath in the intrahepatic approach to resection of the liver. *Surg Gynecol Obstet.* 1992;174(1):7–10.
264. Launois B, Jamieson GG. The posterior intrahepatic approach for hepatectomy or removal of segments of the liver. *Surg Gynecol Obstet.* 1992;174(2):155–158.
265. Blumgart LH, Jarnagin W, Fong Y. Liver resection for benign disease and for liver and biliary tumors. In: Blumgart LH, Fong Y, eds. *Surgery of the Liver and Biliary Tract.* 3rd ed. New York, NY: W.B. Saunders, Co.; 2003:1639–1714.
266. Yamamoto J, Kosuge T, Shimada K, et al. Repeat liver resection for recurrent colorectal liver metastases. *Am J Surg.* 1999;178(4):275–281.
267. Hodgson WJ, Morgan J, Byrne D, et al. Hepatic resections for primary and metastatic tumors using the ultrasonic surgical dissector. *Am J Surg.* 1992;163(2):246–250.
268. Rau HG, Buttler ER, Baretton G, et al. Jet-cutting supported by high frequency current: new technique for hepatic surgery. *World J Surg.* 1997;21(3):254–259.
269. Okuda K, Obata H, Nakajima Y, et al. Prognosis of primary hepatocellular carcinoma. *Hepatology.* 1984;4(1 suppl):3S–6S.
270. Kanematsu T, Matsumata T, Takenaka K, et al. Clinical management of recurrent hepatocellular carcinoma after primary resection. *Br J Surg.* 1988;75(3):203–206.
271. Yamanaka N, Okamoto E, Toyosaka A, et al. Prognostic factors after hepatectomy for hepatocellular carcinoma. A univariate and multivariate analysis. *Cancer.* 1990;65(5):1104–1110.
272. Ringe B, Pichlmayr R, Wittekind C, Tusch G. Surgical treatment of hepatocellular carcinoma: experience with liver resection and transplantation in 198 patients. *World J Surg.* 1991;15(2):270–285.
273. Sasaki Y, Imaoka S, Masutani S, et al. Influence of coexisting cirrhosis on long-term prognosis after surgery in patients with hepatocellular carcinoma. *Surgery.* 1992;112(3):515–521.
274. Takenaka K, Shimada M, Higahi H, et al. Liver resection for hepatocellular carcinoma in the elderly. *Arch Surg.* 1994;129(8):846–850.
275. Suenaga M, Sugiura H, Kokuba Y, et al. Repeated hepatic resection for recurrent hepatocellular carcinoma in eighteen cases. *Surgery.* 1994;115(4):452–457.
276. Bismuth H, Chiche L, Castaing D. Surgical treatment of hepatocellular carcinomas in noncirrhotic liver: experience with 68 liver resections. *World J Surg.* 1995;19(1):35–41.
277. Lai EC, Fan ST, Lo CM, et al. Hepatic resection for hepatocellular carcinoma. An audit of 343 patients. *Ann Surg.* 1995;221(3):291–298.
278. Takenaka K, Kawahara N, Yamamoto K, et al. Results of 280 liver resections for hepatocellular carcinoma. *Arch Surg.* 1996;131(1):71–76.
279. Poon RT, Ng IO, Fan ST, et al. Clinicopathologic features of long-term survivors and disease-free survivors after resection of hepatocellular carcinoma: a study of a prospective cohort. *J Clin Oncol.* 2001;19(12):3037–3044.
280. Belghiti J, Regimbeau JM, Durand F, et al. Resection of hepatocellular carcinoma: a European experience on 328 cases. *HepatoGastroenterology.* 2002;49(43):41–46.
281. Esnaola N, Mirza N, Lauwers GY, et al. Comparison of clinicopathologic characteristics and outcomes after resection in patients with hepatocellular carcinoma treated in the United States, France, and Japan. *Ann Surg.* 2003;238(5):711–719.
282. Ng KK, Vauthey JN, Pawlik TM, et al. Is hepatic resection for large or multinodular hepatocellular carcinoma justified? Results from a multi-institutional database. *Ann Surg Oncol.* 2005;12(5):364–373.
283. O'Grady JG, Polson RJ, Rolles K, et al. Liver transplantation for malignant disease. *Ann Surg.* 1988;207(4):373–379.
284. Ringe B, Wittekind C, Bechstein WO, et al. The role of liver transplantation in hepatobiliary malignancy: a retrospective analysis of 95 patients with particular regard to tumor stage and recurrence. *Ann Surg.* 1989;209(1):88–98.
285. Iwatsuki S, Starzl TE, Sheahan DG, et al. Hepatic resection versus transplantation for hepatocellular carcinoma. *Ann Surg.* 1991;214(3):221–229.
286. Pichlmayr R, Weimann A, Steinhoff G, Ringe B. Liver transplantation for hepatocellular carcinoma: clinical results and future aspects. *Cancer Chemother Pharmacol.* 1992;21(suppl 1):S157–S161.
287. Pichlmayr R, Weimann A, Oldhafer KJ, et al. Role of liver transplantation in the treatment of unresectable liver cancer. *World J Surg.* 1995;19(6):807–813.
288. Schwartz ME, Sung M, Mor E, et al. A multidisciplinary approach to hepatocellular carcinoma in patients with cirrhosis. *J Am Coll Surg.* 1995;180(5):596–603.
289. Llovet JM, Bruix J, Fuster J, et al. Liver transplantation for small hepatocellular carcinoma: the tumor-node-metastasis classification does not have prognostic power. *Hepatology.* 1998;27(6):1572–1577.
290. Hemming AW, Cattral MS, Reed AI, et al. Liver transplantation for hepatocellular carcinoma. *Ann Surg.* 2001;233(5):652–659.
291. Yao FY, Ferrell L, Mass NM, et al. Liver transplantation for hepatocellular carcinoma: expansion of the tumor size limits does not adversely impact survival. *Hepatology.* 2001;33(6):1394–1403.
292. Duffy JP, Vardanian A, Benjamin E, et al. Liver transplantation criteria for hepatocellular carcinoma should be expanded: a 22-year experience with 467 patients at UCLA. *Ann Surg.* 2007;246(3):502–509.
293. Sotiropoulos GC, Lang H, Nadalin S, et al. Liver transplantation for hepatocellular carcinoma: University Hospital Essen experience and metaanalysis of prognostic factors. *J Am Coll Surg.* 2007;205(5):661–675.
294. Marelli L, Grasso A, Plequezuolo M, et al. Tumour size and differentiation in predicting recurrence of hepatocellular carcinoma after liver transplantation: external validation of a new prognostic score. *Ann Surg Oncol.* 2008;15(12):3503–3511.
295. Onaca N, David GL, Jennings LW, et al. Improved results of transplantation for hepatocellular carcinoma: a report from the international registry of hepatic tumors in liver transplantation. *Liver Transpl.* 2009;15(6):574–580.
296. Halazun KJ, Hardy MA, Rana AA, et al. Negative impact of neutrophil-lymphocyte ratio on outcome after liver transplantation for hepatocellular carcinoma. *Ann Surg.* 2009;150(1):141–151.



*This page intentionally left blank*

# HEPATIC COLORECTAL METASTASES: RESECTION, PUMPS, AND ABLATION

Michael A. Choti

## INTRODUCTION

Colorectal cancer (CRC) is the third most commonly diagnosed cancer in the United States.<sup>1</sup> In spite of an increasing emphasis on screening and prevention of this disease, more than 140,000 new cases will have been diagnosed in 2010, comprising approximately 10% of new cancer diagnoses. Although mortality from this disease has improved over the past two decades, more than 40% of patients with colorectal cancer eventually die of their cancer.<sup>1,2</sup> Among those patients with advanced disease, more than half will develop liver metastases, more than any other organ, and many will have disease recognizably confined to this organ. Specifically, approximately 20–40% of patients with metastatic CRC have liver-only metastases at the time of presentation or recurrence, accounting for about 30,000 patients per year in the United States.<sup>3,4</sup>

While not supported by randomized trials, a preponderance of uncontrolled studies have demonstrated that complete resection in patients with liver metastases is associated with dramatically improved survival compared with patients not undergoing surgical therapy. Advances in imaging technology, surgical techniques, and systemic chemotherapy have brought steady improvements in long-term outcome in patients undergoing resection, with 5-year overall survival exceeding 50%. In addition, other surgically delivered locoregional strategies offer promising directions in improving outcomes in these patients, including ablation, and intra-arterial chemotherapy. Herein, an overview is provided of the important clinical issues relating to the surgical management of patients with colorectal liver metastases.

## PREOPERATIVE EVALUATION OF THE PATIENT WITH HEPATIC METASTASES

The extent of evaluation and staging of a patient with hepatic metastases should be determined based on the available

treatment options. In patients for whom further treatment is not being considered, either due to comorbid conditions or patient choice, an extensive evaluation for the extent of disease may be unjustified. In patients for whom only non-curative systemic chemotherapy is being considered, an evaluation should establish a baseline to facilitate monitoring of the response to treatment at all sites. In those who are or may become candidates for local therapy directed to the liver, it is important to exclude the presence of extrahepatic disease, particularly in the majority of these patients who are asymptomatic from their liver disease.

When evaluating the patient for extrahepatic disease, computed tomography (CT) is the imaging modality used most frequently. Abdominal CT can detect other intra-abdominal disease, while chest CT is most sensitive for identifying pulmonary metastases, detecting 95% of lesions greater than 1 cm in diameter.<sup>5–7</sup> While controversial, chest CT should be strongly considered prior to resection of liver metastases, even in patients with a normal chest x-ray.<sup>6</sup> The ability of CT imaging to detect extrahepatic disease within the abdominal cavity or pelvis is lower, with a sensitivity reported between 22 and 41%.<sup>8,9</sup> Similarly, magnetic resonance imaging (MRI) can be useful in evaluating evidence of extrahepatic disease.<sup>8</sup> In addition, MRI may be useful to characterize indeterminate liver lesions. While most consider a high-quality contrast CT sufficient, some have suggested MRI may be the most sensitive for preoperative staging.<sup>10</sup>

One of the most informative imaging modalities for the assessment of metastatic sites is whole body positron emission tomography (PET). Unlike standard cross-sectional imaging, PET provides functional information related to metabolic activity. Although a number of positron-emitting radiopharmaceuticals have been developed,<sup>18F</sup>-fluorodeoxyglucose (FDG) PET is the most widely used in oncology.<sup>11</sup> When administered intravenously, <sup>18F</sup>-FDG is taken up and accumulated in metabolically active cells. Malignant tissue with relatively increased uptake can be seen as areas of increased signal relative to the surrounding less metabolically active normal tissue.

A wide spectrum of malignancies may be successfully staged by FDG-PET, including colorectal, lung, and breast cancer.<sup>12</sup> PET has been reported to have a sensitivity as high as 92–100%, with a specificity of 85–100%.<sup>13</sup> In patients with colorectal liver metastases in whom resection is planned, preoperative FDG-PET appears to be especially useful to exclude extrahepatic disease.<sup>14,15</sup> Recent studies report identifying such additional disease which alters the patient management in up to 25% of the patients.<sup>15,16</sup> Accordingly, FDG-PET is recommended by the National Comprehensive Cancer Network as a routine component of the preoperative evaluation in patient being considered for surgical therapy for liver metastases from CRC.<sup>6</sup>

When considering any local therapy of the liver, it is particularly important to carefully evaluate the extent of intrahepatic disease and determine the location of metastases relative to major vascular pedicles within the liver. Multiple bilobar metastases as well as involvement of hilar structures or the presence of periportal or celiac nodal disease may preclude resection. Not infrequently, patients who are considered preoperatively to be candidates for resection are found at operation to be unresectable because of previously unrecognized additional hepatic lesions. High-quality contrast-enhanced cross-sectional imaging is imperative for an adequate assessment of the liver prior to surgery. In addition, advanced postacquisition imaging techniques—such as three-dimensional reconstruction, volume-rendering, and digital subtraction angiography—may improve the ability to view the relationship of metastases to vital structures and determine resectability.

The goal of the preoperative evaluation is to identify the best candidates for resection and exclude those who will be found at operation to have unresectable disease, thereby obviating unnecessary laparotomy in the latter group. In one report from Johns Hopkins, the non-therapeutic laparotomy rate decreased from 15% in the 1990s to approximately 5% in the more recent years.<sup>17</sup>

## INTRAOPERATIVE ASSESSMENT: IOUS AND LAPAROSCOPY

Intraoperative exploration and evaluation of the extent of disease within the abdominal cavity and liver is critical prior to proceeding with surgical resection. The abdominal cavity, including peritoneal surfaces and pelvis should be inspected and palpated if accessible to rule out extrahepatic disease or locoregional recurrence. Special attention should be paid to porta hepatis and periportal nodal region.<sup>18,19</sup> Nodal involvement in the periportal area is associated with a significantly poorer long-term outcome.<sup>18,20</sup> It probably represents a manifestation of disseminated disease and should preclude curative resection in most cases.

Bimanual and bidigital palpation of the liver is then carried out. In most cases, metastases from CRC are firmer than the surrounding liver and palpable. In some patients, however, a fibrotic or fatty liver, sometimes related to the use of preoperative chemotherapy, may reduce the ability to palpate

small metastases. In some cases, an indentation or dimple on the capsule of the liver can provide a clue of the presence of a small metastasis below the surface, particularly in patients following a significant response to chemotherapy.

Intraoperative ultrasonography (IOUS) is the most sensitive modality currently available for detecting otherwise occult liver metastases. Even in the era of high-quality preoperative imaging, IOUS sensitivity is reported to be superior to other imaging modalities.<sup>21,22</sup> The sensitivity of IOUS to detect additional lesions depends on multiple factors, including the quality and timing of the preoperative imaging, associated liver disease, and tumor echogenicity.<sup>22–24</sup> In one study, van Vledder et al demonstrated in 213 patients undergoing surgical exploration for CRC liver metastases between 1998 and 2009, IOUS alone detected additional tumors in 10% of patients. Detection rate was found to be higher in those patients with multiple metastases (>3) and those in whom the index known lesions were hypochoic<sup>22</sup> (Fig. 45-1). Moreover, they found patients with isoechoic index lesions were associated with significantly higher rate of early intrahepatic recurrence, a surrogate for missed lesions.

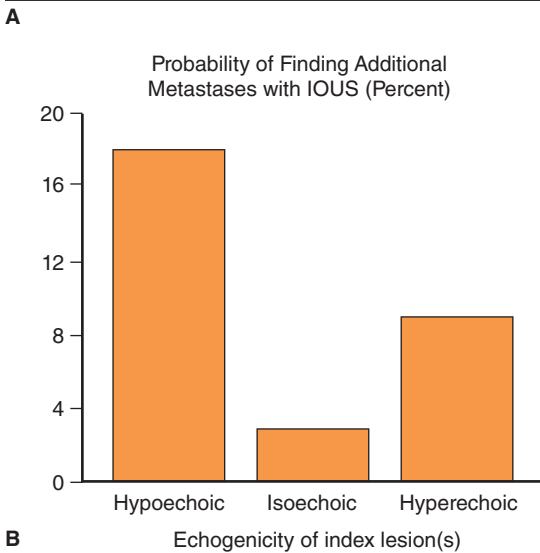
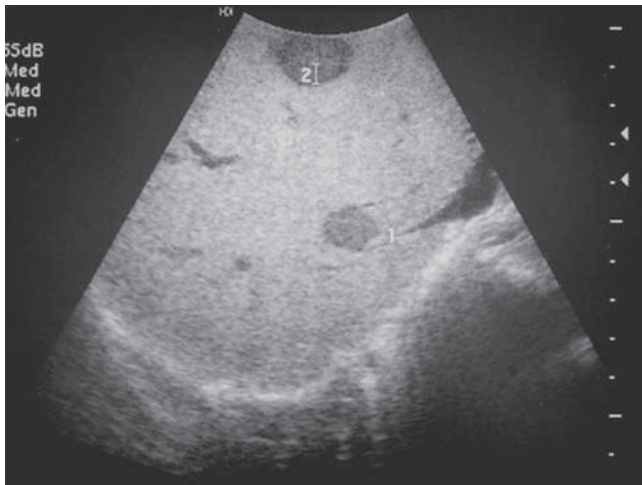By improving the capability of detecting clinically occult metastases, patients with multiple unresectable metastases may be spared unnecessary hepatic resection. IOUS may also contribute to improved survival by helping to detect and excise or ablate otherwise occult residual disease. Moreover, IOUS facilitates the careful examination of intrahepatic vascular structures and their relationship to the hepatic tumors, often facilitating safer resections with more adequate resection margins.<sup>25–27</sup>

Laparoscopic evaluation of the liver and abdominal cavity just prior to laparotomy has been used in a variety of gastrointestinal malignancies.<sup>28–30</sup> This approach is used to potentially identify additional patients who have unresectable disease, reducing the number of patients unnecessarily undergoing full surgical exploration. With recent refinements in laparoscopic ultrasonographic devices, intraoperative hepatic ultrasonography can now compliment visual laparoscopic assessment.<sup>29,31</sup> Laparoscopic staging for potentially resectable hepatic colorectal metastases is more controversial and less frequently used. First, non-therapeutic laparotomy rates are lower in this disease than in most other gastrointestinal cancers, resulting in less potential benefit. Yet some continue to recommend it, particularly among those at higher risk.<sup>32,33</sup> In one report of 103 consecutive patients evaluated with potentially resectable disease, laparoscopy identified 14 of 26 patients with unresectable disease, 10 of whom were spared an unnecessary laparotomy.<sup>33</sup> Despite such enthusiastic initial reports, the role of laparoscopy prior to surgical exploration for patients with isolated hepatic metastases remains to be defined.

## SURGICAL RESECTION

Hepatic resection is acknowledged as the most effective therapy for patients with colorectal metastases confined to the liver. A more accurate understanding of liver structure, based on functional segmental anatomy, as well as advances





**FIGURE 45-1** Intraoperative ultrasonography for the operative assessment of hepatic colorectal metastases. **A.** Image of a metastasis detected intraoperatively. **B.** Sensitivity of IOUS depends on the echogenicity of the known (index) lesions. (van Vledder MG, Pawlik TM, Munireddy S, Hamper U, de Jong MC, Choti MA. Factors determining the sensitivity of intraoperative ultrasonography in detecting colorectal liver metastases in the modern era. *Ann Surg Oncol.* 2010 Oct;17[10]:2756–2763.)

in operative technique and postoperative care, has resulted in the capability to perform even major hepatectomy with very low morbidity and mortality. Thus, the goal of surgery should be complete removal of all metastatic disease. Several issues should be addressed when considering hepatic resection for our patients: (1) How do we select patients for resection? (2) What surgical techniques are recommended? (3) What are the long-term outcomes and prognostic factors? (4) How can we expand the role of liver resection to those with disease that is initially considered to be unresectable? and (5) What is the role of adjuvant or neoadjuvant chemotherapy for patients undergoing hepatic resection?

## Selecting Patients for Surgical Resection

Indications for surgical resection of hepatic colorectal metastases have undergone a major shift in the last decade. Previously, hepatectomy was not recommended in patients who had more than three or four metastases, hilar adenopathy, metastases within 1 cm of major vessels such as the vena cava or main hepatic veins, or extrahepatic disease. More recent studies demonstrate, however, that patients with these clinicopathologic factors can achieve long-term survival following hepatic resection and therefore should not be excluded from surgical consideration.<sup>34–37</sup> Specifically, a small number of metastases<sup>38–40</sup> and wide margin status are no longer considered necessary for defining resectability.<sup>41,42</sup> Similarly, contiguous extension to adjacent anatomical structures and local or regional recurrence at the site of the primary colorectal cancer are not contraindications to resection. An increasing number of studies also indicate that although survival may be reduced in patients with extrahepatic or periportal lymph node metastases, complete resection of these sites in conjunction with resection of hepatic metastases can result in long-term survival.<sup>18,43–47</sup>

Data such as these have led to a shift in the definition of resectability from criteria based on the characteristics of the metastases (tumor number, size, etc.) to new criteria based on whether a macroscopic and microscopic complete (R0) resection of the liver disease, can be achieved. Currently, hepatic colorectal metastases should be defined as resectable when it is anticipated that (1) all disease can be completely resected, (2) two adjacent liver segments can be spared, (3) adequate vascular inflow and outflow and biliary drainage can be preserved, and (4) the volume of the liver remaining after resection is sufficient.

The health and function of the nontumor bearing liver is clearly one of the most important factors impacting resectability and outcomes following liver resection. In patients undergoing surgery for hepatic metastases, cirrhosis is rarely present. However, increasing use of prolonged preoperative chemotherapy can result in significant steatosis, steatohepatitis, and sinusoidal dilatation. In some situations, these pathologic changes can be associated with increased postoperative morbidity. Assessment of hepatic functional reserve is important when deciding whether resection should be pursued. Staging the extent of hepatic dysfunction using the functional Child-Pugh and model for end-stage liver disease (MELD) classification system may be helpful.<sup>48</sup> Thrombocytopenia can be useful to estimate the extent of portal hypertension. Measurement of the indocyanine green retention rate can also provide an estimate of underlying liver function.<sup>49</sup> Although this test is used in some centers, it is not employed with great frequency in most cases. Imaging techniques may shed light on the extent of cirrhosis in some cases. Specifically, CT scan or MRI can identify loss of liver volume or hepatic contour changes indicative of more extensive cirrhosis; visualization of portal vein collaterals, splenomegaly, or ascites can indicate more advanced disease.

The size of the remnant volume considered safe varies with the condition of the hepatic parenchyma. In healthy livers, a

remnant liver volume greater than 20–25% of the estimated total liver volume is considered adequate.<sup>50,51</sup> In contrast, patients with cirrhosis need a greater remnant liver volume (>40%) in order to avoid postoperative liver failure. CT or MRI can now provide an accurate, reproducible method for preoperatively measuring the volume of the future liver remnant.<sup>52</sup> In cases where major hepatectomy is planned and there is concern regarding insufficient liver volume, these patients should be considered for ipsilateral portal vein embolization (PVE) to induce hypertrophy of the contralateral liver lobe.<sup>51</sup> PVE has been shown to increase the size of the future liver remnant. However, no strong evidence to date has clearly demonstrated improved outcomes following PVE compared to no PVE, particularly in the non-cirrhotic patient. Likely, the selective use of PVE may enable the performance of an extended hepatectomy in a subset of patients who otherwise would not have been candidates for safe resection.

In addition to tumor- and liver-related factors, patient comorbidities also need to be considered. Patients with an increased American Society of Anesthesiology (ASA) score have been shown to have a significantly higher morbidity and mortality as compared to those patients with an ASA of 1.<sup>48,53</sup> These patients with higher ASA scores reflect more underlying cardiac disease, renal insufficiency, and other conditions which place this patient population at greater risk for postoperative complications.

## Techniques for Liver Resection

Whether for removal of colorectal metastases or other indications, the objective of a liver resection is to remove the involved portion of liver with an acceptable surgical margin and preserve sufficient hepatic reserve. Major hepatic resections can be divided into left and right hepatectomy (or hemihepatectomy) or extended hepatectomy, depending on the number of liver segments removed.<sup>54</sup> All or part of the caudate lobe can be included as part of a major liver resection or can be resected separately. When performing major hepatic resection, the vascular structures supplying the liver being removed are typically isolated extrahepatically prior to parenchymal dissection. The relevant portal pedicle can be secured at the hilum, either as a group within the intrahepatic hilum or by individual isolation of the portal vein and hepatic artery.<sup>55,56</sup> Selective extrahepatic ligation of inflow allows for the demarcation of the portion of the liver to be removed.

Minor resections can be either nonanatomic wedge resections or segmental resections. Wedge resections typically make no attempt at isolating vascular structures supplying the area being removed and are generally reserved for small peripheral lesions. When such resections are being performed for colorectal metastases, care must be taken to achieve an adequate resection margin as wedge resections are more often associated with positive or close margins.<sup>56</sup> Hepatic segmentectomy can be considered an anatomic minor resection. Such resections can be of a single segment or multiple adjacent segments (bisegmentectomy, sectorec-

tomy, or sectionectomy) in one or both hemilivers. Provided adequate tumor margins are achieved, segmental resections have the advantage of preserving hepatic parenchyma compared to major liver resections. Intrahepatic anatomic landmarks visualized with intraoperative ultrasonography can be used to plan segmental resections and vascular pedicles are typically controlled within the liver substance. Temporary total inflow occlusion (Pringle maneuver) can be helpful during these types of resections.

A variety of techniques have been described for the division of the liver parenchyma.<sup>26,57–60</sup> The traditional method utilizes blunt parenchymal dissection either manually, or with a crushing clamp. Vascular and biliary structures are identified within the liver and ligated or clipped. Other dissection techniques utilize devices such as the ultrasonic Cavitron or a saline jet irrigator to divide the liver by disrupting the parenchyma. Newer devices use saline-enhanced radiofrequency energy to achieve coagulative necrosis of the liver substance to achieve hemostasis during or before the dissection.<sup>58,59</sup> Other devices thermally precoagulate the resection plane to achieve complete hemostasis prior to transection.<sup>60</sup> Surgical stapling devices have also greatly improved the ease in which liver resection can be performed.<sup>61</sup> In addition to facilitating division of the extrahepatic vascular pedicles, staplers can be used to divide larger pedicles within the liver parenchyma. The superiority of any one single method has not been established and the choice of technique should be determined by the individual surgeon's expertise.

## Results of Liver Resection for Colorectal Metastases

Perioperative mortality of liver resection for colorectal metastases has markedly decreased in recent years, approximating 1% in most recent reported series.<sup>62–68</sup> In experienced hands, even major hepatic resections, which are performed in about half of these cases, result in perioperative mortalities of less than 3%.<sup>62,64,65</sup> The recommendation is that major liver resection be performed at centers and by surgeons with more than occasional experience with such procedures. One study analyzing the short-term outcome for liver resections in the state of Maryland indicated a clear relationship between hospital procedure volume and perioperative mortality.<sup>65</sup> Among 606 patients, the in-hospital mortality was 1.5% in the high-volume hospitals (defined as more than 15 resections per year) compared to a 9.6% mortality in centers performing less than eight resections per year. Although operative mortality should be uncommon, significant complications have been reported in 15–30% of patients.<sup>64,67,69,70</sup> The morbidity associated specifically with liver resection includes hemorrhage, perihepatic abscess, bile leak and/or fistula, pleural effusion, and hepatic failure.

The long-term survival reported following hepatic resection with curative intent for metastatic colorectal cancer has improved significantly in the last decade. While older series report 5-year survival rates of 25–40%,<sup>69,71,72</sup> more contemporary series report

**TABLE 45-1: LARGEST SERIES REPORTING SHORT- AND LONG TERM OUTCOMES AFTER CURATIVE INTENT SURGICAL THERAPY FOR COLORECTAL LIVER METASTASES**

Authors (Year Published)	Number of Patients Included	Mortality	Morbidity	5-Year Disease- free Survival	5-Year Overall Survival
Nordlinger et al (1992) <sup>76</sup>	1568	2%	23%	15%	28%
Fong et al (1999) <sup>63</sup>	1001	3%	31%	—	37%
Malik et al (2007) <sup>68</sup>	700	3%	30%	31%	45%
de Jong et al (2009) <sup>77</sup>	1669	—	—	30%	47%
House et al (2010) <sup>75</sup>	1600	2%	44%	27–33%	37–51%

5-year survival in excess of 50%.<sup>62,73–75</sup> Recent large multi-institutional collective series demonstrate trends in improved long-term outcome.<sup>63,68,76,77</sup> (Table 45-1).

### Prognostic Factors Following Resection for Colorectal Metastases

Although surgical resection results in prolonged survival and perhaps cure in some patients, the majority eventually develop recurrent disease. For this reason, many authors have attempted to identify factors that might improve patient selection, thereby improving the long-term outcome of those resected.<sup>78,79</sup>

Pathologic features of the primary tumor appear to correlate with long-term outcome following liver resection. Both nodal status and histologic grade of the primary tumor are associated with poorer outcome following liver resection in several reported series.<sup>62,63,72</sup> Features of the hepatic metastatic disease, including the number, size, and location of the metastases, correlate with prognosis in many series.<sup>62,63,73,75</sup> Fong et al report that the number and size of metastases, as well as the preoperative carcinoembryonic antigen (CEA) and disease-free interval each independently correlated with survival by multivariate analysis.<sup>33</sup> Although these data suggest that the prognosis appears worse in patients with an increased number of metastases, long-term survival can be achieved, at least in selected patients, with resection of even four or more metastatic lesions. There are insufficient data to allow a definitive threshold to be established at present.<sup>78</sup>

Technical factors at the time of surgery can also impact on the prognosis. These are of particular significance as they are often under the control of the surgeon. A positive histologic surgical resection margin has been found to be associated with poor long-term survival and higher risk of local recurrence.<sup>41,62,80</sup> The optimal width of the negative surgical margin, however, remains controversial. Some investigators have reported an improved survival when clearance margins were 1 cm or greater<sup>72</sup> while others have shown no differences, provided the margin is grossly negative.<sup>41,81</sup> In recent reports, some have challenged the need even for microscopically negative margins, particularly following

preoperative chemotherapy.<sup>42</sup> The type of resection performed (wedge resection, segmentectomy, or hemihepatectomy) and the technique of parenchymal dissection do not appear to affect long-term recurrence rates, independent of margin status.<sup>62,63,75</sup>

### Liver Resection in the Presence of Extrahepatic Colorectal Metastases

Extrahepatic disease, even when limited and resectable is generally acknowledged to be associated with worse prognosis following liver resection of colorectal metastases, with many in the past considering this a contraindication to surgery.<sup>63,71</sup> However, reduced surgical morbidity as well as the development of more effective systemic chemotherapy regimens have prompted many to recommend resection of all disease when possible, including extrahepatic sites.<sup>45,47</sup> Certainly, local extension to adjacent structures and locoregional recurrence should not be considered true extrahepatic disease and are not contraindication to surgery if complete resection is possible. In contrast, offering hepatic resection in the presence of extrahepatic metastases is somewhat more controversial. The lungs are the second most frequent site of metastatic disease, accounting for approximately 20% of those with metastases from colorectal cancer, and about 5–10% of patients who present with metastatic disease will have both liver and lung metastases. In the past, multiple studies have reported favorable long-term survival rates after resection of localized lung-only disease.<sup>82,83</sup> More recently, however, several centers have reported their results for patients undergoing combined lung and liver resection.<sup>84,85</sup> These studies have reported 5-year survival rates in excess of 30%. Prognosis following resection of pulmonary and liver metastasis does not appear to be affected by synchronous versus metachronous presentation. Several studies have reported no significant difference in survival between patients who present with simultaneous versus synchronous disease.<sup>86</sup> Patients with multiple pulmonary metastases (>3) have a significantly higher risk for disease-specific death compared with other patients.

Perihepatic lymph nodes are felt to be “metastases from metastases” and are generally associated with a poor outcome.



Until recently, many considered such nodal involvement an absolute contraindication to hepatic resection.<sup>87</sup> However, more recent studies have reported long-term survival in some patients with such nodal metastases and have concluded that this patient population may still benefit from hepatic resection.<sup>18,47,88,89</sup>

Metastatic spread to the peritoneal surfaces can occur in 15–20% of patients with advanced colorectal cancer and is not uncommonly seen in those with liver metastases. Although usually a particularly ominous indicator of poor prognosis, some centers have reported success with cytoreductive surgery and intraperitoneal chemotherapy.<sup>90</sup> Surgical therapy of combined liver and peritoneal metastases has been advocated by some.<sup>91</sup> However, concomitant peritoneal disease should be considered a contraindication for resection of liver metastases.

Elias et al<sup>92</sup> reported that the 5-year survival rate following hepatectomy for colorectal liver metastasis and simultaneous resection of extrahepatic disease with curative intent was 29%, including selected cases with pulmonary, nodal, and peritoneal metastasis. Patients with peritoneal disease or extrahepatic disease at multiple sites were found to have worse survival rate than patients with single-site extrahepatic disease.<sup>92</sup> In contrast, multiple studies have shown that patients with only pulmonary metastases have the most favorable outcome following liver and lung resection.<sup>82,83</sup>

While preoperative factors may be generally instructive, these factors should not be used to exclude patients from surgical consideration. Patients with one or multiple negative prognostic factors can still derive a significant survival advantage from hepatic resection of their colorectal metastases. However, the presence of disseminated extrahepatic disease, probably including periportal nodal disease or lack of control of the locoregional primary disease, is generally considered a contraindication to resection with curative intent. In patients with metastatic disease confined to the liver in whom surgical resection can completely and safely remove all evident disease with negative margins, surgical resection should be advocated.

## ROLE OF SYSTEMIC CHEMOTHERAPY IN PATIENTS UNDERGOING SURGICAL THERAPY OF LIVER METASTASES

Current combination chemotherapy regimens incorporating oxaliplatin or irinotecan in addition to 5-fluorouracil (5-FU) and leucovorin (LV) or capecitabine have produced response rates in excess of 40%.<sup>93–95</sup> The addition of biologic agents such as those targeting epithelial and vascular endothelial growth factor pathways has been shown to further improve response rates and increase survival in the metastatic setting.<sup>96,97</sup> The impressive results of these regimens have led to much enthusiasm for their use in combination with hepatic resection.

Optimal integration of chemotherapy and surgical therapy of liver metastases is an important and controversial topic.

While extensive randomized controlled trials have shown the benefit of postoperative adjuvant chemotherapy in locoregional colon cancer,<sup>98–100</sup> the role of chemotherapy combined with potentially curative resection of liver metastases is less well studied. Specifically, integration of chemotherapy may include (1) postoperative adjuvant therapy in the resected patient, (2) neoadjuvant or perioperative chemotherapy in the patient with initially resectable disease, and (3) preoperative chemotherapy in the initially unresectable patient in order to achieve a conversion to a resectable state.

## Postoperative Adjuvant Chemotherapy

It has been known for decades that adjuvant chemotherapy improves disease-free and overall survival in earlier-stage colon cancer.<sup>99,100</sup> In stage III patients, the risk of relapse with surgery alone is reduced by 40% with 5-FU-based adjuvant therapy, and the risk of death is reduced by 30%.<sup>99</sup> The addition of oxaliplatin to infusion 5-FU/LV (FOLFOX regimen) significantly improves disease-free survival.<sup>98</sup> However, the role of adjuvant chemotherapy is not as clearly defined after potentially curative resection of liver metastases (stage IV with no evidence of disease). Given that these patients have overall higher risk of recurrence than stage III patients, the rationale for use of adjuvant therapy in this setting is clear, yet few studies have evaluated whether chemotherapy improves outcomes following liver resection. Two European randomized trials closed early because of slow accrual. A pooled analysis of these included 278 patients who had undergone complete resection of the primary tumor and up to four liver or lung metastases and randomized patients to receive either six cycles of bolus 5-FU/LV or surgery alone.<sup>101</sup> There was a trend toward improved 5-year progression-free survival with chemotherapy compared with surgery alone, but the results did not reach statistical significance. Portier et al reported a French trial of 173 patients who were randomized to 6 months of postoperative bolus 5-FU/LV versus observation following R0 resection.<sup>102</sup> The 5-year disease-free survival was 34% for patients in the chemotherapy group and 27% for patients in the surgery-alone group (OR 0.66,  $p = .028$ ). There was a trend toward increased 5-year overall survival with chemotherapy (51 vs 41% with surgery alone), but this difference did not reach statistical significance. These trials were conducted with bolus 5-FU/LV, the standard regimen at the time; the benefit of more effective postoperative oxaliplatin-based regimens such as FOLFOX as well as with biologic therapies has yet to be determined.

Intrahepatic infusional chemotherapy also has been proposed as adjuvant therapy following liver resection, based in part on the high risk of intrahepatic recurrence and the ability of regional chemotherapy to deliver higher drug concentrations within the liver. Several studies have examined the role of adjuvant hepatic artery infusion (HAI) using 5-FU or floxuridine (FUDR) with or without systemic chemotherapy.<sup>103</sup> This therapy was compared with either observation or systemic chemotherapy with bolus 5-FU/LV. Two small

trials demonstrated some benefit for HAI over this systemic chemotherapy alone.<sup>105</sup> Although some improved efficacy was observed in these studies as well as phase II studies, comparisons with newer, more active systemic regimens in randomized trials are lacking.<sup>104</sup> In addition, the toxicity and technical aspects of implanting and maintaining a hepatic arterial pump have limited its applicability in practice. One recent cooperative trial in the United States closed early after failing to accrue many patients, and the current role for adjuvant therapy using regional infusion chemotherapy in this disease is limited outside of a clinical trial.

### Perioperative Chemotherapy in the Initially Resectable Patient

The use of preoperative chemotherapy for patients with initially resectable hepatic metastases has generated significant controversy. Several arguments have been made in favor of preoperative chemotherapy (Table 45-2). First, it provides some time for biologically aggressive disease to declare itself, potentially avoiding unnecessary surgery. Second, determination of response in the macroscopic disease provides prognostic information<sup>105-108</sup> as well as potentially allowing for modification of the postoperative therapy based on response. Finally, neoadjuvant chemotherapy may allow a smaller resection or increase the possibility of an R0 resection. Achieving negative margins is important when resecting for curative intent and the rate of positive surgical margins may be lower with preoperative systemic chemotherapy than with immediate resection.<sup>42</sup>

While theoretically appealing, the use of preoperative chemotherapy in an initially resectable patient may have some disadvantages (Table 45-2). Some consider it important to offer the surgical therapy first in order to avoid a lost opportunity. If neoadjuvant therapy fails to stabilize the

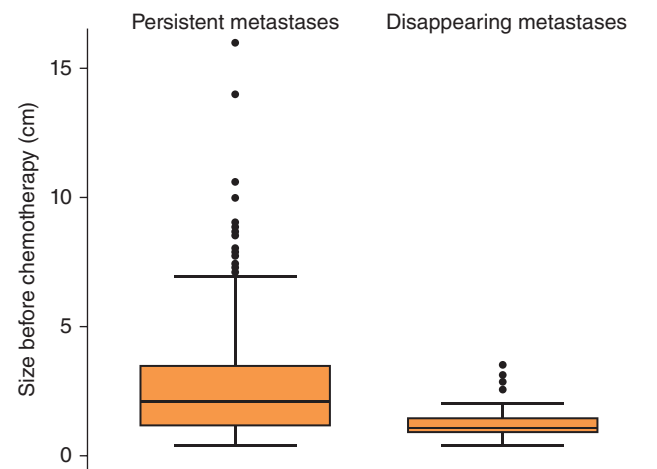
disease, it may progress to an unresectable status. This situation is rare, however, with most series reporting less than 10% occurrence. In addition, patients in this group may have less to gain from aggressive surgical therapy given the poor prognosis that early progression may indicate.<sup>106</sup> Another disadvantage of preoperative chemotherapy is the risk of chemotherapy-associated liver injury, which could increase the morbidity of surgery.<sup>109-112</sup> Seen in two forms, vascular sinusoidal dilatation and fatty liver changes (steatosis or steatohepatitis), hepatotoxicity can be limited with shorter duration of chemotherapy.

Another potential disadvantage of neoadjuvant chemotherapy is related to the complete radiologic response that can be observed in some lesions. In one study, van Vledder et al found 23% of patients receiving preoperative chemotherapy had at least one disappearing liver metastases.<sup>113</sup> This finding was more common in small lesions, in patients with multiple metastases, and in those with longer chemotherapy duration (Fig. 45-2). Only approximately one-half were found at the time of surgery and, when not identified, the majority of these were not treated. In most cases local recurrence developed in these sites. Similarly, Benoist et al, reported the presence of residual disease at the site of a radiologic complete response in 82%.<sup>114</sup> Thus, if the hepatic lesions are rendered so small that the surgeon can no longer find them, perhaps the patient may have been done a disservice by preoperative chemotherapy.

The impact of perioperative chemotherapy in conjunction with liver resection was reported in a randomized, multi-institution trial sponsored by the European Organization for Research and Treatment of Cancer (EORTC 40983).<sup>115</sup> In this study, 364 chemo-naïve patients with up to four colorectal liver metastases (median of 1) were randomized

**TABLE 45-2: NEOADJUVANT CHEMOTHERAPY PRIOR TO HEPATECTOMY IN THE INITIALLY RESECTABLE PATIENT WITH COLORECTAL LIVER METASTASES**

Potential Advantages	Potential Disadvantages
1. Allows time for other sites to declare themselves	1. Tumors may progress to unresectable status
2. Allows for earlier therapy of occult micrometastatic disease	2. Split regimen may have detrimental effect
3. Allows for in vivo gauge of chemoresponsiveness, facilitating postoperative chemotherapy planning	3. Chemotherapy-associated hepatotoxicity
4. Response may allow for smaller resection	4. Potential for increased postoperative complications
5. Response is a prognostic factor	5. Response may hinder finding all sites of metastatic disease



**FIGURE 45-2** Comparison of the size of metastases prior to chemotherapy among those that radiologically disappeared versus those that remained visible following chemotherapy. (van Vledder MG, de Jong MC, Pawlik TM, Schulick RD, Diaz LA, Choti MA. Disappearing colorectal liver metastases after chemotherapy: should we be concerned? *J Gastrointest Surg*. 2010 Nov;14[11]:1691-1700.)

to either perioperative chemotherapy with six cycles of FOLFOX before surgery and six cycles after surgery, or to surgery alone. Difference in 3-year progression-free survival between groups was 7.3% in randomized patients ( $p = .058$ ), 8.1% in eligible patients ( $p = .041$ ), and 9.2% in patients successfully undergoing resection ( $p = .025$ ). There were no differences in perioperative mortality between the treatment groups, but postoperative complications occurred significantly more often in those who received neoadjuvant therapy (25 vs 16%), including increased risk of biliary fistula and intra-abdominal infection. These findings support a role for chemotherapy in patients undergoing liver resection, although the benefit was perhaps less than may be expected based on the benefit seen with chemotherapy in stage III disease. Overall survival was not significant, so it is unclear whether perioperative FOLFOX actually contributes to cure or simply delays recurrence. Furthermore, the trial was not designed to test the value of preoperative versus postoperative chemotherapy and did not definitively answer the important question about the optimal sequencing of chemotherapy around curative liver resection.

## Converting Unresectable to Resectable Disease With Preoperative Chemotherapy

The prospect of converting initially unresectable metastases to resectable disease has become more attainable with improved response rates from modern systemic regimens. Combination chemotherapy, including FOLFOX and FOLFIRI, achieves radiologic response rates of approximately 50%.<sup>97,116</sup> More aggressive regimens (eg, FOLFOXIRI) as well as the addition of targeted therapies increase response rates even further.<sup>117–119</sup>

The goal of tumor downsizing with a chemotherapeutic response is to be able to remove the gross residual disease of all original sites of disease. Liver metastases located near major vascular pedicles which need to be salvaged are ideal candidates (Fig. 45-3). Currently, it is estimated that approximately one-fourth of patients with liver metastases are initially resectable and conversion from unresectable to resectable disease through tumor downsizing can be achieved in approximately 20% of those initially considered unresectable.<sup>120,121</sup>

Outcomes following liver resection in initially unresectable patients following chemotherapy response appear similar to initially resectable patients. In one report, 5- and 10-year overall survival rates were 33% and 23%, respectively in initially unresectable patients who subsequently underwent resection.<sup>120</sup> In a more recent study, unresectable patients with liver-only disease were randomized to either FOLFOX or FOLFIRI in combination with cetuximab.<sup>122</sup> Complete resection was achieved in 34% overall and was comparable in both groups.

Strategies for tumor downsizing and resection need to be further refined. We still do not know what circumstances

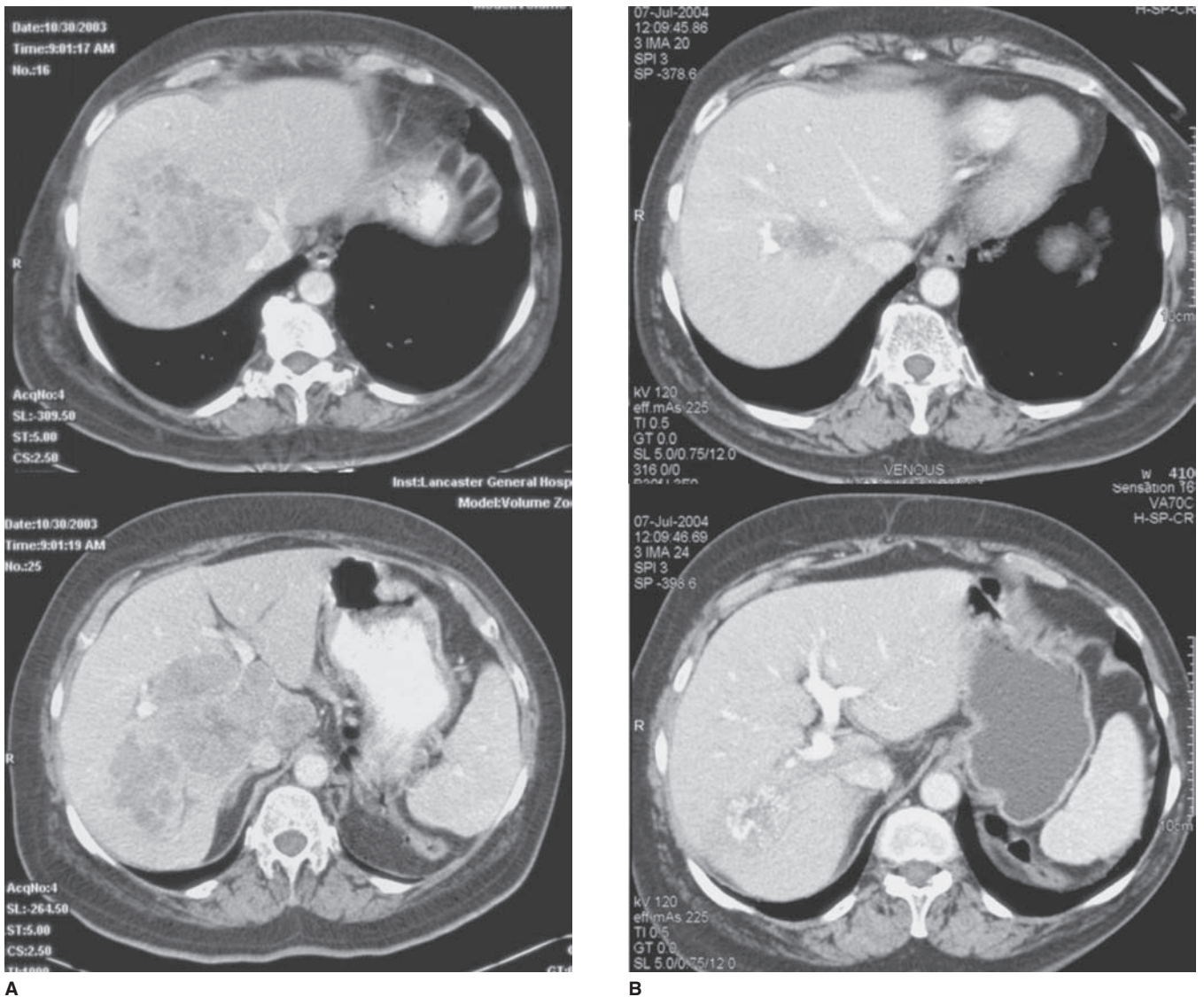
indicate optimally converted patients. For example, it is unclear whether all areas where the tumor initially existed should be resected. Furthermore, it is still unclear what role ablation might play in such a setting. The optimal duration of preoperative chemotherapy in this setting also remains uncertain. For example, should patients be treated until disease is resectable or to a maximal response? It is likely that residual visible disease is of benefit in identifying all initial sites that need to be resected to prevent recurrent disease. Similarly, it is unclear how to manage disease in the case of complete radiologic response. Should patients undergo surgery at that time or wait until some disease becomes radiologically evident?

## ABLATIVE THERAPIES

Although surgical resection may afford the best potential for cure in patients with hepatic metastases, many patients may not be candidates for surgical resection for a variety of reasons. Novel methods for local ablation have been developed with a goal of increasing the number of patients eligible for local, potentially curative therapy. The early experiences with metastasis ablation have been primarily with hepatic cryosurgery. This technique relies on the destruction of a defined area within the liver by freeze or thawing, using probes cooled by liquid nitrogen to subzero temperatures. Placement and monitoring of the freezing process is monitored with ultrasound. More recently, radiofrequency ablation (RFA) has been applied for the treatment of liver tumors in much the same manner as cryotherapy. With this technique, a needle-probe is inserted within the selected tumor under image guidance and electric current is employed to generate heat, resulting in interstitial thermal destruction. RFA can be performed laparoscopically or percutaneously, as well as via open laparotomy. Advantages of RFA over cryotherapy include the smaller probe and fewer related complications. For these reasons, RFA has replaced cryotherapy as the preferred method of interstitial ablation in many centers. While most studies report outcomes of RFA for treatment of colorectal metastases, newer ablative approaches are being used with increasing frequency. These include microwave ablation and nonthermal irreversible electroporation. While potentially promising, these newer ablative modalities await larger controlled reports to determine their role in therapy of hepatic colorectal metastases.

When performing ablation of colorectal metastases, RFA in particular, careful planning of the zone of destruction is necessary to achieve complete necrosis of the target lesion.<sup>123</sup> In some cases when using an expandable multielectrode RFA needle of sufficient size, complete ablation can be achieved with a single application, deploying the electrode from the center of the tumor. In cases of larger lesions, multiple overlapping applications may be required.<sup>124</sup> Tumor size as well as location can preclude effective ablation with curative intent. Tumor sizes larger than 3 cm are associated with an increased incidence of local recurrence.<sup>125</sup> Similarly, tumors near major





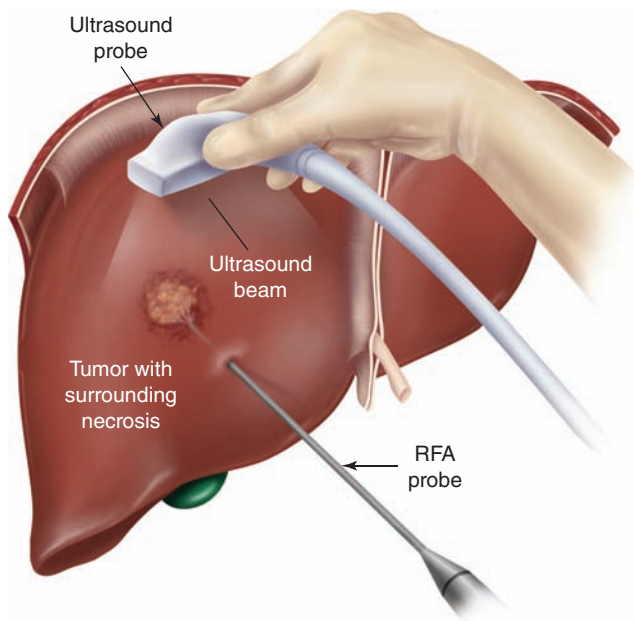
**FIGURE 45-3** Computed tomographic images in a patient with metastatic colorectal cancer. **A.** Bulky liver-only disease in patient initially considered unresectable. **B.** Converted to resectable status following response to preoperative systemic chemotherapy (FOLFOX with bevacizumab).

vascular structures such as the vena cava are more difficult to achieve long-term local control with ablation.

Once the target tumor is identified with theIOUS transducer during a surgical ablation, the RFA electrode needle is inserted under ultrasound guidance (Fig. 45-4). Optimally, the electrode is advanced in a track parallel and within the plane of the transducer, so the entire path of the needle can be visualized. Monitoring during thermal ablation can be performed using a variety of methods. Some RFA devices have the capacity to measure tissue temperatures with thermistors located at the tips of the electrodes. Alternatively, tissue impedance and current can be monitored during treatment. The ablation zone is visualized by ultrasound during treatment. Typically, local miniscule gas bubble formation results in hyperechogenicity within the treated tissue.

The optimal method for evaluating the efficacy of RFA treatment using imaging modalities is not well defined. The presence of residual viable tumor tissue after RFA can be detected using contrast-enhanced CT or MRI.<sup>126,127</sup> However, as with other ablative approaches, interpretation of these images can be difficult at times, as a hypoattenuating lesion may persist for months to years despite complete tumor destruction. In most cases, a local recurrence is characterized by an increase in the lesion size on serial scans, or evidence of new areas of contrast enhancement. FDG-PET may be useful in assessing recurrent disease provided it is acquired after the postablation inflammation has subsided, typically after 3 months.<sup>127</sup>

Unlike hepatic resection where long-term efficacy is relatively established, evidence of the benefit of ablation for treatment



**FIGURE 45-4** Operative radiofrequency ablation under IOUS guidance.

of hepatic colorectal metastases has been limited and inconsistent.<sup>123</sup> There are no published randomized controlled trials examining its use in this disease so the data are largely based on single-arm, retrospective, and prospective studies.

Local recurrence rates published in the literature range from less than 10% to as high as 40–50%.<sup>73,123,128,129</sup> Data on the survival benefit of RFA have been similarly contradictory. Some studies have reported 5-year survival of less than 20% following RFA whereas other studies have reported 5-year survival rates in the range of 40% or more.<sup>123</sup> In addition, several studies have attempted to compare outcome of resection versus ablation, most demonstrating RFA to be associated with a worse disease-free and overall survival compared with resection. One must realize, however, that important prognostic and treatment-related variables differ between the two cohorts when compared retrospectively. In a review of RFA for colorectal cancer by the American Society of Clinical Oncology (ASCO), the authors recognized a scarcity of quality evidence and emphasized a compelling need for more clinical trials to determine the efficacy and utility of RFA in these patients.<sup>123</sup>

## REGIONAL CHEMOTHERAPY: HEPATIC ARTERIAL INFUSION

Chemotherapy delivered systemically to treat hepatic metastases may be limited by the incapability to deliver high concentrations of drug to tumor cells without systemic toxicity. This provides the rationale for regional chemotherapy. The normal liver derives its blood supply from both the hepatic arterial and portal venous vessels. Macroscopic

hepatic tumors, however, derive most of their afferent blood supply from the hepatic artery.<sup>130</sup> Directing a high-dose infusion of chemotherapy into the hepatic artery therefore increases the concentration of drug to which the tumor is exposed, proportional to the hepatic parenchyma, as well as to the body as a whole, and should thereby improve the therapeutic index.<sup>131</sup> Drugs such as fluorodeoxyuridine (FUDR), an active metabolite of 5-FU, which are rapidly metabolized within the liver on the first pass, are the most commonly used regional chemotherapeutic agents.<sup>132</sup>

While evidence regarding the role of HAI therapy was summarized earlier, several older randomized trials have compared the results of continuous HAI chemotherapy alone to systemic chemotherapy in patients with unresectable liver metastases.<sup>133–135</sup> Most reported increased response rates compared to systemic therapy but survival benefit was inconsistent, in part because of inadequate sample sizes, crossover study designs, or inadequately administered systemic chemotherapy.

In 2003, Kerr et al reported a European trial randomizing 290 patients to systemic versus HAI 5-FU.<sup>136</sup> While the study was criticized for the technique and study design, the median overall survival was no different between treatment groups. In another randomized multi-institutional trial, Kemeny et al reported a higher response rate with HAI FUDR with dexamethasone (47%) compared to the systemic group receiving 5-FU/LV (24%), along with an improved overall survival in the HAI group (24.4 vs 20 months,  $p = .003$ ).<sup>103</sup> As with HAI therapy in the adjuvant setting, limited level 1 evidence exists comparing regional infusion chemotherapy to current combination systemic regimens. While response rates are high with this approach, even following tumor progression on systemic therapies, the biliary toxicity and technical aspects of implanting and maintaining an hepatic arterial pump have limited its applicability in current practice beyond few centers with experience in this approach.

## SUMMARY

Surgical therapies for hepatic colorectal metastases have been shown to be increasingly safe and effective resulting in more frequent and aggressive application of this local approach. Preoperative and intraoperative assessment and planning are important to achieve safe and complete resection of all evident disease. Current methods for increasing the ability to offer liver resection include preoperative chemotherapy, staged resection, preoperative portal vein embolization, and ablative strategies. Perioperative chemotherapy may play a role in the optimal treatment of initially resectable disease, but the sequencing of chemotherapy and surgery remains unclear.

In the near future, we are likely to see expanding use of local therapies of hepatic metastases, particularly as systemic chemotherapy improves. Minimally invasive approaches for resection, including laparoscopic resection, will likely be increasingly utilized, as well as other nonextirpative techniques. However, until the role of cytoreduction or incomplete local therapies is defined, complete, curative-intent therapy must be advocated.

## REFERENCES

- Jemal A, Siegel R, Xu J, Ward E. Cancer statistics. *CA Cancer J Clin*. 2010 Sep–Oct;60(5):277–300.
- Edwards BK, Howe HL, Ries LA, et al. Annual report to the nation on the status of cancer, 1973–1999, featuring implications of age and aging on U.S. cancer burden. *Cancer*. 2002 May 15;94(10):2766–2792.
- Ohlsson B, Palsson B. Follow-up after colorectal cancer surgery. *Acta Oncol*. 2003;42(8):816–826.
- Weiss L, Grundmann E, Torhorst J, et al. Haematogenous metastatic patterns in colonic carcinoma: an analysis of 1541 necropsies. *J Pathol*. 1986 Nov;150(3):195–203.
- Kang MC, Kang CH, Lee HJ, Goo JM, Kim YT, Kim JH. Accuracy of 16-channel multi-detector row chest computed tomography with thin sections in the detection of metastatic pulmonary nodules. *Eur J Cardiothorac Surg*. 2008 Mar;33(3):473–479.
- Engstrom PF, Arnoletti JB, Benson AB, 3rd, et al. NCCN Clinical Practice Guidelines in Oncology: colon cancer. *J Natl Compr Canc Netw*. 2009 Sep;7(8):778–831.
- Engstrom PF, Arnoletti JB, Benson AB, 3rd, et al. NCCN Clinical Practice Guidelines in Oncology: rectal cancer. *J Natl Compr Canc Netw*. 2009 Sep;7(8):838–881.
- Dobos N, Rubesin SE. Radiologic imaging modalities in the diagnosis and management of colorectal cancer. *Hematol Oncol Clin North Am*. 2002 Aug;16(4):875–895.
- Gonzalez-Moreno S, Gonzalez-Bayon L, Ortega-Perez G, Gonzalez-Hernando C. Imaging of peritoneal carcinomatosis. *Cancer J*. 2009 May–Jun;15(3):184–189.
- Nielke MC, Bipat S, Stoker J. Diagnostic imaging of colorectal liver metastases with CT, MR imaging, FDG PET, and/or FDG PET/CT: a meta-analysis of prospective studies including patients who have not previously undergone treatment. *Radiology*. 2010 Dec;257(3):674–684.
- Patel CN, Goldstone AR, Chowdhury FU, Scarsbrook AF. FDG PET/CT in oncology: “raising the bar”. *Clin Radiol*. 2010 Jul;65(7):522–535.
- Poeppel TD, Krause BJ, Heusner TA, Boy C, Bockisch A, Antoch G. PET/CT for the staging and follow-up of patients with malignancies. *Eur J Radiol*. 2009 Jun;70(3):382–392.
- Floriani I, Torri V, Rulli E, et al. Performance of imaging modalities in diagnosis of liver metastases from colorectal cancer: a systematic review and meta-analysis. *J Magn Reson Imaging*. 2010;31(1):19–31.
- Joyce DL, Wahl RL, Patel PV, Schulick RD, Gearhart SL, Choti MA. Preoperative positron emission tomography to evaluate potentially resectable hepatic colorectal metastases. *Arch Surg*. 2006 Dec;141(12):1220–1226; discussion 1227.
- Selznor M, Hany TF, Wildbrett P, McCormack L, Kadry Z, Clavien PA. Does the novel PET/CT imaging modality impact on the treatment of patients with metastatic colorectal cancer of the liver? *Ann Surg*. 2004 Dec;240(6):1027–1034; discussion 1035–1026.
- Wiering B, Krabbe PF, Jager GJ, Oyen WJ, Ruers TJ. The impact of fluor-18-deoxyglucose-positron emission tomography in the management of colorectal liver metastases. *Cancer*. 2005 Dec 15;104(12):2658–2670.
- Pawlik TM, Assumpcao L, Vossen JA, et al. Trends in nontherapeutic laparotomy rates in patients undergoing surgical therapy for hepatic colorectal metastases. *Ann Surg Oncol*. 2009 Feb;16(2):371–378.
- Jaeck D. The significance of hepatic pedicle lymph nodes metastases in surgical management of colorectal liver metastases and of other liver malignancies. *Ann Surg Oncol*. 2003 Nov;10(9):1007–1011.
- Grobmyer SR, Wang L, Gonen M, et al. Perihepatic lymph node assessment in patients undergoing partial hepatectomy for malignancy. *Ann Surg*. 2006 Aug;244(2):260–264.
- Laurent C, Sa Cunha A, Rullier E, Smith D, Rullier A, Saric J. Impact of microscopic hepatic lymph node involvement on survival after resection of colorectal liver metastasis. *J Am Coll Surg*. 2004 Jun;198(6):884–891.
- Wildi SM, Gubler C, Hany T, et al. Intraoperative sonography in patients with colorectal cancer and resectable liver metastases on preoperative FDG-PET-CT. *J Clin Ultrasound*. 2008 Jan;36(1):20–26.
- van Vledder MG, Pawlik TM, Munireddy S, Hamper U, de Jong MC, Choti MA. Factors determining the sensitivity of intraoperative ultrasonography in detecting colorectal liver metastases in the modern era. *Ann Surg Oncol*. 2010 Oct;17(10):2756–2763.
- van Vledder MG, Torbenson MS, Pawlik TM, et al. The effect of steatosis on echogenicity of colorectal liver metastases on intraoperative ultrasonography. *Arch Surg*. 2010 Jul;145(7):661–667.
- Choti MA, Kaloma F, de Oliveira ML, et al. Patient variability in intraoperative ultrasonographic characteristics of colorectal liver metastases. *Arch Surg*. 2008 Jan;143(1):29–34; discussion 35.
- Torzilli G, Del Fabbro D, Palmisano A, et al. Surgical strategy for liver tumors located at the hepato-caval confluence. *Ann Ital Chir*. 2006 Jul–Aug;77(4):323–328.
- Poon RT. Recent advances in techniques of liver resection. *Surg Technol Int*. 2004;13:71–77.
- Patel NA, Roh MS. Utility of intraoperative liver ultrasound. *Surg Clin North Am*. 2004 Apr;84(2):513–524.
- Hur H, Lee HH, Jung H, Song KY, Jeon HM, Park CH. Predicting factors of unexpected peritoneal seeding in locally advanced gastric cancer: indications for staging laparoscopy. *J Surg Oncol*. 2010 Dec 1;102(7):753–757.
- Muntean V, Mihailov A, Iancu C, et al. Staging laparoscopy in gastric cancer. Accuracy and impact on therapy. *J Gastrointest Liver Dis*. 2009 Jun;18(2):189–195.
- Hariharan D, Constantinides VA, Froeling FE, Tekkis PP, Kocher HM. The role of laparoscopy and laparoscopic ultrasound in the preoperative staging of pancreatico-biliary cancers—a meta-analysis. *Eur J Surg Oncol*. 2010 Oct;36(10):941–948.
- Samee A, Moorthy K, Jaipersad T, et al. Evaluation of the role of laparoscopic ultrasonography in the staging of oesophago-gastric cancers. *Surg Endosc*. 2009 Sep;23(9):2061–2065.
- Pilkington SA, Rees M, Peppercorn D, John TG. Laparoscopic staging in selected patients with colorectal liver metastases as a prelude to liver resection. *HPB (Oxford)*. 2007;9(1):58–63.
- Jarnagin WR, Conlon K, Bodniewicz J, et al. A clinical scoring system predicts the yield of diagnostic laparoscopy in patients with potentially resectable hepatic colorectal metastases. *Cancer*. 2001 Mar 15;91(6):1121–1128.
- Charnsangavej C, Clary B, Fong Y, Grothey A, Pawlik TM, Choti MA. Selection of patients for resection of hepatic colorectal metastases: expert consensus statement. *Ann Surg Oncol*. 2006 Oct;13(10):1261–1268.
- Pawlik TM, Choti MA. Shifting from clinical to biologic indicators of prognosis after resection of hepatic colorectal metastases. *Curr Oncol Rep*. 2007 May;9(3):193–201.
- Pawlik TM, Schulick RD, Choti MA. Expanding criteria for resectability of colorectal liver metastases. *Oncologist*. 2008 Jan;13(1):51–64.
- Lupinacci R, Penna C, Nordlinger B. Hepatectomy for resectable colorectal cancer metastases—indicators of prognosis, definition of resectability, techniques and outcomes. *Surg Oncol Clin N Am*. 2007 Jul;16(3):493–506, vii–viii.
- Altendorf-Hofmann A, Scheele J. A critical review of the major indicators of prognosis after resection of hepatic metastases from colorectal carcinoma. *Surg Oncol Clin N Am*. 2003 Jan;12(1):165–192, xi.
- Kokudo N, Imamura H, Sugawara Y, et al. Surgery for multiple hepatic colorectal metastases. *J Hepatobiliary Pancreat Surg*. 2004;11(2):84–91.
- Weber SM, Jarnagin WR, DeMatteo RP, Blumgart LH, Fong Y. Survival after resection of multiple hepatic colorectal metastases. *Ann Surg Oncol*. 2000 Oct;7(9):643–650.
- Pawlik TM, Scoggins CR, Zorzi D, et al. Effect of surgical margin status on survival and site of recurrence after hepatic resection for colorectal metastases. *Ann Surg*. 2005 May;241(5):715–722, discussion 722–714.
- de Haas RJ, Wicherts DA, Flores E, Azoulay D, Castaing D, Adam R. R1 resection by necessity for colorectal liver metastases: is it still a contraindication to surgery? *Ann Surg*. 2008 Oct;248(4):626–637.
- Elias DM, Ouellet JF. Incidence, distribution, and significance of hilar lymph node metastases in hepatic colorectal metastases. *Surg Oncol Clin N Am*. 2003 Jan;12(1):221–229.
- Byam J, Reuter NP, Woodall CE, Scoggins CR, McMasters KM, Martin RC. Should hepatic metastatic colorectal cancer patients with extrahepatic disease undergo liver resection/ablation? *Ann Surg Oncol*. 2009 Nov;16(11):3064–3069.
- Carpizo DR, Are C, Jarnagin W, et al. Liver resection for metastatic colorectal cancer in patients with concurrent extrahepatic disease: results in 127 patients treated at a single center. *Ann Surg Oncol*. 2009 Aug;16(8):2138–2146.



46. de Haas RJ, Wicherts DA, Adam R. Resection of colorectal liver metastases with extrahepatic disease. *Dig Surg*. 2008;25(6):461–466.
47. Elias D, Liberale G, Vernerey D, et al. Hepatic and extrahepatic colorectal metastases: when resectable, their localization does not matter, but their total number has a prognostic effect. *Ann Surg Oncol*. 2005 Nov;12(11):900–909.
48. Schroeder RA, Marroquin CE, Bute BP, Khuri S, Henderson WG, Kuo PC. Predictive indices of morbidity and mortality after liver resection. *Ann Surg*. 2006 Mar;243(3):373–379.
49. Komori H, Beppu T, Baba Y, et al. Histological liver injury and surgical outcome after FOLFOX followed by a hepatectomy for colorectal liver metastases in Japanese patients. *Int J Clin Oncol*. 2010 Jun;15(3):263–270.
50. Kishi Y, Abdalla EK, Chun YS, et al. Three hundred and one consecutive extended right hepatectomies: evaluation of outcome based on systematic liver volumetry. *Ann Surg*. 2009 Aug 27;145(1):9–19.
51. Abulkhir A, Limongelli P, Healey AJ, et al. Preoperative portal vein embolization for major liver resection: a meta-analysis. *Ann Surg*. 2008 Jan;247(1):49–57.
52. Vauthey JN, Chaoui A, Do KA, et al. Standardized measurement of the future liver remnant prior to extended liver resection: methodology and clinical associations. *Surgery*. 2000 May;127(5):512–519.
53. Aloia TA, Fahy BN, Fischer CP, et al. Predicting poor outcome following hepatectomy: analysis of 2313 hepatectomies in the NSQIP database. *HPB (Oxford)*. 2009 Sep;11(6):510–515.
54. Celinski SA, Gamblin TC. Hepatic resection nomenclature and techniques. *Surg Clin North Am*. 2010 Aug;90(4):737–748.
55. Couinaud CM. A simplified method for controlled left hepatectomy. *Surgery*. 1985 Mar;97(3):358–361.
56. DeMatteo RP, Palese C, Jarnagin WR, Sun RL, Blumgart LH, Fong Y. Anatomic segmental hepatic resection is superior to wedge resection as an oncologic operation for colorectal liver metastases. *J Gastrointest Surg*. 2000 Mar–Apr;4(2):178–184.
57. Pamecha V, Gurusamy KS, Sharma D, Davidson BR. Techniques for liver parenchymal transection: a meta-analysis of randomized controlled trials. *HPB (Oxford)*. 2009 Jun;11(4):275–281.
58. Sugo H, Mikami Y, Matsumoto F, et al. Hepatic resection using the harmonic scalpel. *Surg Today*. 2000;30(10):959–962.
59. Geller DA, Tsung A, Maheshwari V, Rutstein LA, Fung JJ, Marsh JW. Hepatic resection in 170 patients using saline-cooled radiofrequency coagulation. *HPB (Oxford)*. 2005;7(3):208–213.
60. Pai M, Jiao LR, Khorsandi S, Canelo R, Spalding DR, Habib NA. Liver resection with bipolar radiofrequency device: Habib 4X. *HPB (Oxford)*. 2008;10(4):256–260.
61. Schemmer P, Friess H, Hinz U, et al. Stapler hepatectomy is a safe dissection technique: analysis of 300 patients. *World J Surg*. 2006 Mar;30(3):419–430.
62. Choti MA, Sitzmann JV, Tiburi MF, et al. Trends in long-term survival following liver resection for hepatic colorectal metastases. *Ann Surg*. 2002 Jun;235(6):759–766.
63. Fong Y, Fortner J, Sun RL, Brennan MF, Blumgart LH. Clinical score for predicting recurrence after hepatic resection for metastatic colorectal cancer: analysis of 1001 consecutive cases. *Ann Surg*. 1999 Sep;230(3):309–318; discussion 318–321.
64. Vauthey JN, Pawlik TM, Abdalla EK, et al. Is extended hepatectomy for hepatobiliary malignancy justified? *Ann Surg*. 2004 May;239(5):722–730; discussion 730–722.
65. Choti MA, Bowman HM, Pitt HA, et al. Should hepatic resections be performed at high-volume referral centers? *J Gastrointest Surg*. 1998 Jan–Feb;2(1):11–20.
66. de Liguori Carino N, van Leeuwen BL, Ghaneh P, Wu A, Audisio RA, Poston GJ. Liver resection for colorectal liver metastases in older patients. *Crit Rev Oncol Hematol*. 2008 Sep;67(3):273–278.
67. Farid SG, Aldouri A, Morris-Stiff G, et al. Correlation between postoperative infective complications and long-term outcomes after hepatic resection for colorectal liver metastasis. *Ann Surg*. 2010 Jan;251(1):91–100.
68. Malik HZ, Prasad KR, Halazun KJ, et al. Preoperative prognostic score for predicting survival after hepatic resection for colorectal liver metastases. *Ann Surg*. 2007 Nov;246(5):806–814.
69. Rosen CB, Nagorney DM, Taswell HF, et al. Perioperative blood transfusion and determinants of survival after liver resection for metastatic colorectal carcinoma. *Ann Surg*. 1992 Oct;216(4):493–504; discussion 504–495.
70. Adam R, Frilling A, Elias D, et al. Liver resection of colorectal metastases in elderly patients. *Br J Surg*. 2010 Mar;97(3):366–376.
71. Scheele J, Stangl R, Altendorf-Hofmann A. Hepatic metastases from colorectal carcinoma: impact of surgical resection on the natural history. *Br J Surg*. 1990 Nov;77(11):1241–1246.
72. Hughes KS, Rosenstein RB, Songhorabodi S, et al. Resection of the liver for colorectal carcinoma metastases. A multi-institutional study of long-term survivors. *Dis Colon Rectum*. 1988 Jan;31(1):1–4.
73. Abdalla EK, Vauthey JN, Ellis LM, et al. Recurrence and outcomes following hepatic resection, radiofrequency ablation, and combined resection/ablation for colorectal liver metastases. *Ann Surg*. 2004 Jun;239(6):818–825; discussion 825–817.
74. de Haas RJ, Wicherts DA, Salloum C, et al. Long-term outcomes after hepatic resection for colorectal metastases in young patients. *Cancer*. 2010 Feb 1;116(3):647–658.
75. House MG, Ito H, Gonen M, et al. Survival after hepatic resection for metastatic colorectal cancer: trends in outcomes for 1,600 patients during two decades at a single institution. *J Am Coll Surg*. 2010 May;210(5):744–752, 752–745.
76. Nordlinger B, Guiguet M, Vaillant JC, et al. Surgical resection of colorectal carcinoma metastases to the liver. A prognostic scoring system to improve case selection, based on 1568 patients. Association Francaise de Chirurgie. *Cancer*. 1996 Apr 1;77(7):1254–1262.
77. de Jong MC, Pulitano C, Ribero D, et al. Rates and patterns of recurrence following curative intent surgery for colorectal liver metastasis: an international multi-institutional analysis of 1669 patients. *Ann Surg*. 2009 Sep;250(3):440–448.
78. Bilchik AJ, Poston G, Adam R, Choti MA. Prognostic variables for resection of colorectal cancer hepatic metastases: an evolving paradigm. *J Clin Oncol*. 2008 Nov 20;26(33):5320–5321.
79. Gayowski TJ, Iwatsuki S, Madariaga JR, et al. Experience in hepatic resection for metastatic colorectal cancer: analysis of clinical and pathologic risk factors. *Surgery*. 1994 Oct;116(4):703–710; discussion 710–701.
80. Are C, Gonen M, Zazzali K, et al. The impact of margins on outcome after hepatic resection for colorectal metastasis. *Ann Surg*. 2007 Aug;246(2):295–300.
81. Nuzzo G, Giuliani F, Ardito F, et al. Influence of surgical margin on type of recurrence after liver resection for colorectal metastases: a single-center experience. *Surgery*. 2008 Mar;143(3):384–393.
82. Inoue M, Ohta M, Iuchi K, et al. Benefits of surgery for patients with pulmonary metastases from colorectal carcinoma. *Ann Thorac Surg*. 2004 Jul;78(1):238–244.
83. Sakamoto T, Tsubota N, Iwanaga K, Yuki T, Matsuoka H, Yoshimura M. Pulmonary resection for metastases from colorectal cancer. *Chest*. 2001 Apr;119(4):1069–1072.
84. Headrick JR, Miller DL, Nagorney DM, et al. Surgical treatment of hepatic and pulmonary metastases from colon cancer. *Ann Thorac Surg*. 2001 Mar;71(3):975–979; discussion 979–980.
85. Neeff H, Horth W, Makowiec F, et al. Outcome after resection of hepatic and pulmonary metastases of colorectal cancer. *J Gastrointest Surg*. 2009 Oct;13(10):1813–1820.
86. Mineo TC, Ambrogi V, Tonini G, et al. Long-term results after resection of simultaneous and sequential lung and liver metastases from colorectal carcinoma. *J Am Coll Surg*. 2003 Sep;197(3):386–391.
87. Iwatsuki S, Dvorchik I, Madariaga JR, et al. Hepatic resection for metastatic colorectal adenocarcinoma: a proposal of a prognostic scoring system. *J Am Coll Surg*. 1999 Sep;189(3):291–299.
88. Viana EF, Herman P, Siqueira SC, et al. Lymphadenectomy in colorectal cancer liver metastases resection: incidence of hilar lymph nodes micro-metastasis. *J Surg Oncol*. 2009 Dec 1;100(7):534–537.
89. Bennett JJ, Schmidt CR, Klimstra DS, et al. Perihepatic lymph node micrometastases impact outcome after partial hepatectomy for colorectal metastases. *Ann Surg Oncol*. 2008 Apr;15(4):1130–1136.
90. Yan TD, Morris DL. Cytoreductive surgery and perioperative intraperitoneal chemotherapy for isolated colorectal peritoneal carcinomatosis: experimental therapy or standard of care? *Ann Surg*. 2008 Nov;248(5):829–835.
91. Chua TC, Yan TD, Zhao J, Morris DL. Peritoneal carcinomatosis and liver metastases from colorectal cancer treated with cytoreductive surgery perioperative intraperitoneal chemotherapy and liver resection. *Eur J Surg Oncol*. 2009 Dec;35(12):1299–1305.

92. Elias D, Ouellet JF, Bellon N, Pignon JP, Pocard M, Lasser P. Extrahepatic disease does not contraindicate hepatectomy for colorectal liver metastases. *Br J Surg*. 2003 May;90(5):567–574.
93. de Gramont A, Figer A, Seymour M, et al. Leucovorin and fluorouracil with or without oxaliplatin as first-line treatment in advanced colorectal cancer. *J Clin Oncol*. 2000 Aug;18(16):2938–2947.
94. Cunningham D, Pyrhonen S, James RD, et al. Randomised trial of irinotecan plus supportive care versus supportive care alone after fluorouracil failure for patients with metastatic colorectal cancer. *Lancet*. 1998 Oct 31;352(9138):1413–1418.
95. Douillard JY, Cunningham D, Roth AD, et al. Irinotecan combined with fluorouracil compared with fluorouracil alone as first-line treatment for metastatic colorectal cancer: a multicentre randomised trial. *Lancet*. 2000 Mar 25;355(9209):1041–1047.
96. Hurwitz H, Fehrenbacher L, Novotny W, et al. Bevacizumab plus irinotecan, fluorouracil, and leucovorin for metastatic colorectal cancer. *N Engl J Med*. 2004 Jun 3;350(23):2335–2342.
97. Van Cutsem E, Kohne CH, Hitre E, et al. Cetuximab and chemotherapy as initial treatment for metastatic colorectal cancer. *N Engl J Med*. 2009 Apr 2;360(14):1408–1417.
98. Andre T, Boni C, Navarro M, et al. Improved overall survival with oxaliplatin, fluorouracil, and leucovorin as adjuvant treatment in stage II or III colon cancer in the MOSAIC trial. *J Clin Oncol*. 2009 Jul 1;27(19):3109–3116.
99. O'Connell MJ, Laurie JA, Kahn M, et al. Prospectively randomized trial of postoperative adjuvant chemotherapy in patients with high-risk colon cancer. *J Clin Oncol*. 1998 Jan;16(1):295–300.
100. Goldberg RM, Sargent DJ, Morton RF, et al. A randomized controlled trial of fluorouracil plus leucovorin, irinotecan, and oxaliplatin combinations in patients with previously untreated metastatic colorectal cancer. *J Clin Oncol*. 2004 Jan 1;22(1):23–30.
101. Mitry E, Fields AL, Bleiberg H, et al. Adjuvant chemotherapy after potentially curative resection of metastases from colorectal cancer: a pooled analysis of two randomized trials. *J Clin Oncol*. 2008 Oct 20;26(30):4906–4911.
102. Portier G, Elias D, Bouche O, et al. Multicenter randomized trial of adjuvant fluorouracil and folinic acid compared with surgery alone after resection of colorectal liver metastases: FFCD ACHBTH AURC 9002 trial. *J Clin Oncol*. 2006 Nov 1;24(31):4976–4982.
103. Kemeny NE, Niedzwiecki D, Hollis DR, et al. Hepatic arterial infusion versus systemic therapy for hepatic metastases from colorectal cancer: a randomized trial of efficacy, quality of life, and molecular markers (CALGB 9481). *J Clin Oncol*. 2006 Mar 20;24(9):1395–1403.
104. Kemeny N, Capanu M, D'Angelica M, et al. Phase I trial of adjuvant hepatic arterial infusion (HAI) with floxuridine (FUDR) and dexamethasone plus systemic oxaliplatin, 5-fluorouracil and leucovorin in patients with resected liver metastases from colorectal cancer. *Ann Oncol*. 2009 Jul;20(7):1236–1241.
105. Allen PJ, Kemeny N, Jarnagin W, DeMatteo R, Blumgart L, Fong Y. Importance of response to neoadjuvant chemotherapy in patients undergoing resection of synchronous colorectal liver metastases. *J Gastrointest Surg*. 2003 Jan;7(1):109–115; discussion 116–107.
106. Adam R, Pascal G, Castaing D, et al. Tumor progression while on chemotherapy: a contraindication to liver resection for multiple colorectal metastases? *Ann Surg*. 2004 Dec;240(6):1052–1061; discussion 1061–1054.
107. Chun YS, Vauthey JN, Boonsirikamchai P, et al. Association of computed tomography morphologic criteria with pathologic response and survival in patients treated with bevacizumab for colorectal liver metastases. *JAMA*. 2009 Dec 2;302(21):2338–2344.
108. Blazer DG, 3rd, Kishi Y, Maru DM, et al. Pathologic response to preoperative chemotherapy: a new outcome end point after resection of hepatic colorectal metastases. *J Clin Oncol*. 2008 Nov 20;26(33):5344–5351.
109. Tamandl D, Klinger M, Eipeldauer S, et al. Sinusoidal obstruction syndrome impairs long-term outcome of colorectal liver metastases treated with resection after neoadjuvant chemotherapy. *Ann Surg Oncol*. 2011 Feb;18(2):421–430.
110. Pawlik TM, Olino K, Gleisner AL, Torbenson M, Schulick R, Choti MA. Preoperative chemotherapy for colorectal liver metastases: impact on hepatic histology and postoperative outcome. *J Gastrointest Surg*. 2007 Jul;11(7):860–868.
111. Zorzi D, Laurent A, Pawlik TM, Lauwers GY, Vauthey JN, Abdalla EK. Chemotherapy-associated hepatotoxicity and surgery for colorectal liver metastases. *Br J Surg*. 2007 Mar;94(3):274–286.
112. Fernandez FG, Ritter J, Goodwin JW, Linehan DC, Hawkins WG, Strasberg SM. Effect of steatohepatitis associated with irinotecan or oxaliplatin pretreatment on resectability of hepatic colorectal metastases. *J Am Coll Surg*. 2005 Jun;200(6):845–853.
113. van Vledder MG, de Jong MC, Pawlik TM, Schulick RD, Diaz LA, Choti MA. Disappearing colorectal liver metastases after chemotherapy: should we be concerned? *J Gastrointest Surg*. 2010 Nov;14(11):1691–1700.
114. Benoist S, Brouquet A, Penna C, et al. Complete response of colorectal liver metastases after chemotherapy: does it mean cure? *J Clin Oncol*. 2006 Aug 20;24(24):3939–3945.
115. Nordlinger B, Sorbye H, Glimelius B, et al. Perioperative chemotherapy with FOLFOX4 and surgery versus surgery alone for resectable liver metastases from colorectal cancer (EORTC Intergroup trial 40983): a randomised controlled trial. *Lancet*. 2008 Mar 22;371(9617):1007–1016.
116. Tournigand C, Andre T, Achille E, et al. FOLFIRI followed by FOLF-FOX6 or the reverse sequence in advanced colorectal cancer: a randomized GERCOR study. *J Clin Oncol*. 2004 Jan 15;22(2):229–237.
117. Kopetz S, Hoff PM, Morris JS, et al. Phase II trial of infusional fluorouracil, irinotecan, and bevacizumab for metastatic colorectal cancer: efficacy and circulating angiogenic biomarkers associated with therapeutic resistance. *J Clin Oncol*. 2010 Jan 20;28(3):453–459.
118. Taberero J, Van Cutsem E, Diaz-Rubio E, et al. Phase II trial of cetuximab in combination with fluorouracil, leucovorin, and oxaliplatin in the first-line treatment of metastatic colorectal cancer. *J Clin Oncol*. 2007 Nov 20;25(33):5225–5232.
119. Masi G, Loupakis F, Pollina L, et al. Long-term outcome of initially unresectable metastatic colorectal cancer patients treated with 5-fluorouracil/leucovorin, oxaliplatin, and irinotecan (FOLFOXIRI) followed by radical surgery of metastases. *Ann Surg*. 2009 Mar;249(3):420–425.
120. Adam R, Delvart V, Pascal G, et al. Rescue surgery for unresectable colorectal liver metastases downstaged by chemotherapy: a model to predict long-term survival. *Ann Surg*. 2004 Oct;240(4):644–657; discussion 657–648.
121. Folprecht G, Grothey A, Alberts S, Raab HR, Kohne CH. Neoadjuvant treatment of unresectable colorectal liver metastases: correlation between tumour response and resection rates. *Ann Oncol*. 2005 Aug;16(8):1311–1319.
122. Folprecht G, Gruenberger T, Bechstein WO, et al. Tumour response and secondary resectability of colorectal liver metastases following neoadjuvant chemotherapy with cetuximab: the CELIM randomised phase 2 trial. *Lancet Oncol*. 2010 Jan;11(1):38–47.
123. Wong SL, Mangu PB, Choti MA, et al. American Society of Clinical Oncology 2009 clinical evidence review on radiofrequency ablation of hepatic metastases from colorectal cancer. *J Clin Oncol*. 2010 Jan 20;28(3):493–508.
124. Gillams AR, Lees WR. Radiofrequency ablation of colorectal liver metastases. *Abdom Imaging*. 2005 Jul–Aug;30(4):419–426.
125. van Duijnhoven FH, Jansen MC, Junggeburst JM, et al. Factors influencing the local failure rate of radiofrequency ablation of colorectal liver metastases. *Ann Surg Oncol*. 2006 May;13(5):651–658.
126. Schraml C, Clasen S, Schwenzer NF, et al. Diagnostic performance of contrast-enhanced computed tomography in the immediate assessment of radiofrequency ablation success in colorectal liver metastases. *Abdom Imaging*. 2008 Nov–Dec;33(6):643–651.
127. Kuehl H, Antoch G, Stergar H, et al. Comparison of FDG-PET, PET/CT and MRI for follow-up of colorectal liver metastases treated with radiofrequency ablation: initial results. *Eur J Radiol*. 2008 Aug;67(2):362–371.
128. Gleisner AL, Choti MA, Assumpcao L, Nathan H, Schulick RD, Pawlik TM. Colorectal liver metastases: recurrence and survival following hepatic resection, radiofrequency ablation, and combined resection-radiofrequency ablation. *Arch Surg*. 2008 Dec;143(12):1204–1212.
129. Ruers TJ, Joosten JJ, Wiering B, et al. Comparison between local ablative therapy and chemotherapy for non-resectable colorectal liver metastases: a prospective study. *Ann Surg Oncol*. 2007 Mar;14(3):1161–1169.
130. Ackerman NB, Hodgson WB. Vascular patterns of liver tumors and their consequences for different therapeutic approaches. *Recent Results Cancer Res*. 1986;100:248–255.
131. Ensminger WD, Gyves JW. Clinical pharmacology of hepatic arterial chemotherapy. *Semin Oncol*. 1983 Jun;10(2):176–182.

132. Kemeny NE. Regional chemotherapy of colorectal cancer. *Eur J Cancer*. 1995 Jul-Aug;31A(7-8):1271-1276.
133. Kemeny N, Daly J, Reichman B, Geller N, Botet J, Oderman P. Intrahepatic or systemic infusion of fluorodeoxyuridine in patients with liver metastases from colorectal carcinoma. A randomized trial. *Ann Intern Med*. 1987 Oct;107(4):459-465.
134. Chang AE, Schneider PD, Sugarbaker PH, Simpson C, Culnane M, Steinberg SM. A prospective randomized trial of regional versus systemic continuous 5-fluorodeoxyuridine chemotherapy in the treatment of colorectal liver metastases. *Ann Surg*. 1987 Dec;206(6):685-693.
135. Hohn DC, Stagg RJ, Friedman MA, et al. A randomized trial of continuous intravenous versus hepatic intraarterial floxuridine in patients with colorectal cancer metastatic to the liver: the Northern California Oncology Group trial. *J Clin Oncol*. 1989 Nov;7(11):1646-1654.
136. Kerr DJ, McArdle CS, Ledermann J, et al. Intrahepatic arterial versus intravenous fluorouracil and folinic acid for colorectal cancer liver metastases: a multicentre randomised trial. *Lancet*. 2003 Feb 1; 361(9355):368-373.



# PERSPECTIVE ON LIVER SURGERY

Steven A. Curley

Interest and experience with surgical treatment of the liver has expanded dramatically over the past two decades. The size of the pool of surgeons who routinely perform liver-directed surgery has also increased. These changes and expansion have been fueled by improved description, understanding, and study of segmental liver anatomy and the numerous potential variations in hepatic arterial, portal venous, hepatic venous, and bile duct anatomy. A key example is the description of segmental hepatic anatomy by Couinaud with an appreciation of the vascular anatomy and associations with the eight segments of the liver (Fig. 46A-1).

As with many other types of potentially complex surgical procedures, operations on the liver now occur more commonly because of enhanced safety. Procedures and techniques have evolved to minimize blood loss which reduces the morbidity related to transfusion of multiple units of blood. Hepatobiliary surgeons can be as idiosyncratic as any other group of surgical specialists; each individual surgeon has his or her own favorite technique or techniques for hepatic transection. The number of possible techniques to perform liver transection safely has grown based on the interest from medical device manufacturers to produce novel equipment to permit liver parenchymal transection while minimizing blood loss. It is not unusual for there to be an array of equipment in the operating room of the modern hepatobiliary surgeon with the goal being to perform the operation with maximum safety and improved patient outcome.

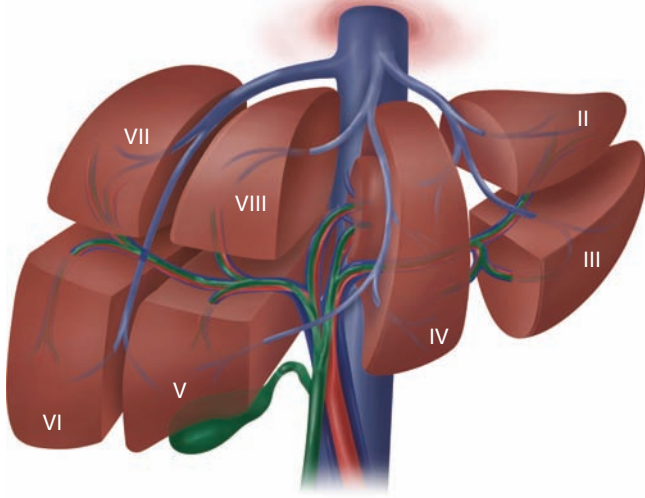
The liver is unusual in the human body as it has a dual blood supply, the portal vein and the hepatic artery. It has been known for almost a 100 years that occlusion of the portal vein and hepatic artery during operation on the liver, be it for a traumatic injury to the liver or for elective resection of a portion of the liver, can reduce blood loss. Advances in our understanding using this technique have led to the realization that inflow occlusion of the hepatic blood supply can be performed safely for carefully controlled periods even in patients with cirrhotic livers. Furthermore, intermittent occlusion followed by brief periods of reperfusion of the liver will increase the total time of inflow occlusion that can be achieved while still successfully limiting blood loss and reducing the risk for ischemic liver injury.

## HEPATIC ABSCESS AND CYSTIC DISEASE OF THE LIVER

Despite an ever expanding selection of antibiotic agents, pyogenic liver abscess is as common a problem today as it was in the preceding century. If anything, treatment of pyogenic liver abscess with antibiotic therapy is more difficult and has been complicated by the indiscriminate use of antibiotics over the past several decades. Iatrogenic etiologies of liver abscess may have also been increased by the more invasive and aggressive approaches to benign and malignant pancreatic and biliary tract diseases. Endoscopic retrograde cholangiopancreatography, placement of internal stents, or percutaneous placement of external stents in patients with biliary obstruction can increase the likelihood of the development of a pyogenic liver abscess. Furthermore, immunocompromised patients, such as those receiving cytotoxic chemotherapy for malignant disease, are at increased risk to develop hepatic abscess. The primary treatment approach continues to be medical antibiotic therapy and percutaneous interventional radiology aspiration or drainage of abscesses when possible. However, there is still an occasional role for surgical drainage of a complex or multiloculated abscess.

Amebic liver abscess is an extremely common problem worldwide. It should not be forgotten in patients treated in the United States because of the number of people who travel to high-risk areas or who have immigrated to the United States from endemic regions. This is particularly true in the southern, southwestern, and western United States. The diagnosis of amebic liver abscess should be entertained in patients with imaging evidence of a hepatic abscess and an appropriate history and risk group. Treatment is generally medical therapy with occasional need for aspiration or percutaneous drainage.

An echinococcal or hydatid cyst of the liver is an extremely common cause of cystic liver disease worldwide. It is critical to consider this in the differential diagnosis of a patient with a liver cyst because aspiration and spillage of the cyst contents can produce an anaphylactic reaction and spread of the scolices throughout the peritoneal cavity. This diagnosis should



**FIGURE 46A-1** The junctional division of the liver and the segments according to Couinaud's nomenclature.

be considered in individuals living in high-risk areas of the world, and once again, may arise in immunocompromised individuals. Management of small cysts involves medical therapy with benzimidazoles. However, this is rarely successful alone, and treatment of larger lesions may also require very careful percutaneous aspiration of all cyst contents followed by installation of the cyst cavity with protoscolicidal agents. Surgical treatment still has a primary role in management of hydatid cysts of the liver and may include resection of the area of the liver bearing the cyst or complete drainage of the cyst while preventing spillage of cyst contents.

Simple liver cysts are diagnosed frequently in patients who are undergoing upper abdominal ultrasound or axial body imaging for some other diagnostic purpose. It is particularly common in patients with malignant disease during staging to be referred to a hepatobiliary surgeon with a finding of cystic lesions in the liver. The question arises from many oncologists as to whether or not these are worrisome and a concern for metastatic disease is often raised. Asymptomatic simple cysts essentially are a radiographic finding and do not require any therapeutic intervention. In the unusual case of giant cysts that are causing pain or compression on adjacent structures, either an open or laparoscopic unroofing of the cyst can be performed as long as there is no connection to the biliary tract. A laparoscopic approach is my preferred treatment for patients with symptomatic simple cysts of the liver as the recovery time is rapid and the symptom relief rate without recurrence of symptoms exceeds 95%. If a biliary tract connection is recognized, concern must be raised for a possible biliary cystadenoma or cystadenocarcinoma. Most of the cystic neoplasms are benign, but complete resection of both benign and malignant neoplastic cysts of the liver is mandatory to prevent a local recurrence of disease. Cystadenoma or cystadenocarcinoma should be suggested if aspiration of a cyst reveals either bile-stained or mucinous fluid.

## BENIGN AND MALIGNANT PRIMARY LIVER NEOPLASMS

Similar to asymptomatic simple cysts of the liver, patients with solid benign tumors of the liver are often referred to hepatobiliary surgeons after either a transcutaneous ultrasound or an axial body imaging technique reveals a single or multiple solid lesions. Cavernous hemangiomas, hepatocellular adenomas, and focal nodular hyperplasia may be found in almost one in five patients undergoing a liver imaging technique. It is not uncommon for an individual patient to have more than one type of benign hepatic tumor. Like asymptomatic simple cysts, hemangiomas and focal nodular hyperplasia of the liver are usually only radiographic findings and not associated with symptoms. In those unusual situations where these lesions are large or symptomatic, surgical resection with either an open or laparoscopic approach is indicated. Parenthetically, a significant proportion of early laparoscopic resections were performed for benign solid tumors of the liver that may have not required any type of resection. A benign solid or cystic neoplasm of the liver in an area that is technically feasible to resect with a laparoscopic approach is not an indication for a resection if the lesion is asymptomatic. Hepatic adenomas can grow in size over time and have been associated with two potentially catastrophic outcomes, rupture of the lesion with intraperitoneal hemorrhage or transformation into malignant hepatocellular carcinoma (HCC). Taking female patients off oral contraceptives or other forms of estrogen replacement therapy may lead to reduction in the size of hepatic adenomas, but most hepatobiliary surgeons agree that lesions larger than 4–5 cm should be treated with surgical resection.

HCC is one of the most common solid tumors worldwide. There are estimates that anywhere between ½ and 1 million new patients are diagnosed annually worldwide with this particularly lethal malignancy. Most cases of HCC are associated with concomitant liver injury or established cirrhosis. The chronic liver injury can arise from a number of environmental or hereditary causes, but the most common etiologic agents are chronic hepatitis B and/or C infection and alcohol abuse. The presence of cirrhosis may limit the role of the hepatobiliary surgeon even in patients with reasonably early-stage disease. Surgical treatment is still considered the gold standard in therapy for HCC but only a small minority of patients are candidates for surgical treatment approaches. These treatments include orthotopic liver transplantation based on defined patient-inclusion criteria, resection in patients with adequate functional hepatic reserve remaining after an anatomic or non-anatomic liver resection, and thermal ablation techniques in patients with small lesions but cirrhosis too severe to permit resection. As pointed out in the chapter by Cho and Fong, the 5-year survival rates after resection for HCC have ranged from approximately 20 to 75%. In orthotopic liver transplant series that accrued patients after proper patient selection criteria were established the 5-year survival rates vary from 45 to 75%.

Unfortunately, in most large treatment centers that see a large volume of HCC patients, less than 10% are candidates for surgical treatment. The reasons for exclusion from surgical

treatment may include presentation with advanced-stage or metastatic disease, major vascular invasion by tumor, paucity of organs for transplantation, and severity of cirrhosis too great to permit surgical treatment. There have been numerous types of regional and systemic therapies used to treat HCC in patients who are not candidates for surgical treatment. This is a highly resistant and aggressive disease and sadly very few patients who are not candidates for surgical treatment survive more than 2 years, much less having a chance at 5-year survival. Worldwide, the overall mortality rate for HCC in all patients exceeds 94%, so it is clear that better screening programs to diagnose patients at an earlier stage of disease would be highly desirable. It is not clear if such screening programs would be cost effective but this will become an issue due to the increased incidence of this disease in both modern and less developed regions of the world. Similarly, programs aimed at prevention of disease are crucial. Hepatitis B vaccinations have made an impact on the incidence of this cancer in portions of the world where chronic hepatitis B infection is hyperendemic. There is no vaccine for hepatitis C and this virus is supplanting hepatitis B virus as the most common cause of HCC worldwide. Education and prevention are important factors, but clearly better treatments are also needed for this lethal disease. Currently the oral agent sorafenib, a multiple tyrosine kinase inhibitor, has become a standard therapy for patients with advanced and unresectable HCC. However, use of sorafenib enhances survival by an average of less than 3 months, so more effective therapeutic agents for patients with advanced disease must be sought and developed.

Cholangiocarcinomas may arise from the extrahepatic bile ducts, the intrahepatic bile ducts, or the gallbladder. As with HCC, complete surgical resection of cholangiocarcinoma offers the patient the best opportunity for long-term survival. For extrahepatic bile duct cancer and gallbladder cancer, identifying the association of tumors in the bile ducts with key vascular, lymphatic, and hepatic structures is critical to optimize the resection. An excellent example is the importance of caudate resection in patients with hilar cholangiocarcinoma as direct extension of these cancers along small bile ducts directly into the caudate is a common site of failure in patients undergoing a resection that does not include the caudate. Resection of regional lymph nodes is recommended in patients with gallbladder cancer and cholangiocarcinoma and is important for staging. It is not clear that adjuvant therapy significantly improves the long-term outcome of patients but some small studies of systemic chemotherapy or chemoradiation therapy have suggested improved local disease control and possibly an improved median disease-free survival time. Cholangiocarcinomas generally arise in patients with no evidence of cirrhosis or concomitant risk factors for the development of chronic liver injury so major liver resection can be performed more frequently in this patient population. Discussion in the surgical literature has ranged widely regarding the volume of liver that must be resected as part of an operation for cholangiocarcinoma, particularly for gallbladder cancer or hilar cholangiocarcinoma. My general philosophy and data from our experience indicates that major extended hepatectomy should

only be performed if this is the procedure that is required to permit complete resection of the tumor with negative resection margins. As previously noted, resection of the caudate is important as a component of the resection of patients with hilar cholangiocarcinoma, but the volume of other liver that must be resected should be based on leaving as much normal, non-malignant liver as possible after the resection.

## HEPATIC COLORECTAL METASTASES: RESECTION, PUMPS, AND ABLATION

HCC is the most common reason for hepatic resection or surgical treatment of malignant liver tumors in parts of the world where chronic hepatitis B and C virus infections are common. In most western countries, surgical resection of colorectal cancer liver metastases is a primary focus of many hepatobiliary surgeons. Following the report in the late 1980s of a retrospective analysis of tumor registry data, it was recognized that patients undergoing hepatic resection of colorectal metastases can achieve long-term disease-free and overall survival. While there has not been, and likely never will be a randomized prospective controlled clinical trial comparing resection of colorectal cancer liver metastases with nonsurgical treatment, it is accepted by both the surgical and medical oncology communities that properly selected patients should be considered for surgical treatment of their colorectal cancer liver metastases. Like cholangiocarcinoma, most patients with colorectal cancer liver metastases have relatively normal liver function. This being said, it has been recognized in the last decade that patients with steatohepatitis, caused either by obesity and dietary excesses or iatrogenically by the extensive and prolonged use of neoadjuvant chemotherapy that causes hepatic inflammation, can increase the risk of complications and even mortality related to liver failure after major hepatic resection. Many hepatobiliary surgeons prefer to proceed directly with resection of colorectal cancer liver metastases if the patient has technically resectable disease and an adequate functional hepatic volume remaining after the operation. Others advocate for the use of short courses of neoadjuvant therapy to assess the biological response in the tumors to potentially effective systemic agents. Ultimately, hepatobiliary surgeons will operate on some colorectal cancer patients who have received extensive systemic therapy. It has now been recognized that patients who initially present with clearly unresectable disease but who have a dramatic response to systemic therapy may be considered candidates for resection and can achieve 5-year survival rates in excess of 35% following operation. Ongoing clinical trials internationally will be important to understand the role of neoadjuvant and adjuvant therapy after surgical resection of colorectal cancer liver metastases. Surgeons and patients should be encouraged to enter these trials to provide much needed information on optimal multidisciplinary treatment of stage IV colorectal cancer.

The early retrospective studies indicated that approximately one-third of patients treated with surgical resection achieved a 5-year overall survival. Improved patient selection, routine use



of intraoperative ultrasonography to detect small lesions not found on preoperative imaging studies, and improved surgical techniques have produced 5-year survival rates of almost 60% in more recent studies. Additionally, we now know that even a small tumor-free resection margin can be associated with improved patient outcomes, so aggressive surgical approaches should be considered even in tumor that is near major central portal or hepatic venous structures. The routine but selective use of preoperative portal vein embolization (PVE) to induce compensatory hypertrophy in the future liver remnant has also improved the ability to perform major extended hepatectomies safely. The compensatory hypertrophy that occurs after PVE is rapid and most patients can undergo an operation 4–6 weeks after PVE. We, and other surgical groups, have also been aggressive about applying staged hepatic resections in properly selected patients. Performing a two-stage liver resection with or without PVE is associated with long-term survival in over one-third of the treated patients. It is important to recognize that discussing such an aggressive surgical approach is considered reasonable and rational because the 5-year survival rate in patients with unresectable colorectal cancer liver metastases treated with active chemotherapeutic drugs continues to be 5% or less. Furthermore, the surgical mortality rate in high volume centers is less than 3%.

As noted previously, intraoperative ultrasonography is critical for the hepatobiliary surgery performing resection for colorectal cancer, or for other solid tumor liver metastases. Despite improvements in axial body imaging, I still find additional small tumors not seen on preoperative imaging studies in up to 10% of patients undergoing resection. These lesions may be in area of the liver that is planned to be resected or may be on the contralateral side of the liver requiring wedge resection, staged resection, or concomitant thermal ablation of the additional small tumors. I routinely map the location of major intrahepatic portal and hepatic venous structures. This allows the safe application of linear vascular staplers in patients with nonsteatotic or noncirrhotic livers. I also use ultrasonic dissection devices combined with saline-enhanced cautery devices to perform a safe and relatively bloodless liver transection. Inflow occlusion can be applied judiciously, but many patients require no inflow occlusion when using vascular stapling and other liver transection techniques. I am not an advocate for any specific technique as being superior, I am a firm believer that all surgeons should be well versed in use of equipment available for safe hepatic transection and should use techniques with which they are comfortable and confident in their results.

Prior to 2000, there were a paucity of active systemic chemotherapeutic agents in the United States to treat stage IV colorectal cancer. In the 1980s and 1990s, surgical placement of hepatic artery infusion (HAI) pumps was a treatment that was often considered in patients with stage IV colorectal cancer confined to the liver that was not resectable. Unfortunately, regional chemotherapy, while associated with increased rates of measurable partial response, was not associated with an improved long-term survival rate. Additionally, there were toxicities peculiar to HAI chemotherapy, including chemical hepatitis and biliary sclerosis. There have been trials published supporting the use of

adjuvant HAI chemotherapy which may reduce the likelihood of recurrence of disease in the liver after liver resection, but this approach has not gained general acceptance. Currently, HAI therapy is performed at few centers in the country and should be considered only as part of a clinical trial.

Tumor ablation techniques continue to evolve. Radiofrequency ablation (RFA) has been applied to treat unresectable HCC as well as unresectable liver metastases from colon and other types of solid malignancies. In my mind it would not be appropriate to consider a trial that would randomize patients with resectable colorectal cancer to resection versus thermal tumor ablation. Well-trained hepatobiliary surgeons can perform resection with low-morbidity and mortality rates and even the most meticulous application of thermal tumor destruction techniques such as RFA, laser tumor ablation, or microwave tumor ablation are associated with incomplete tumor destruction in as few as 5% and as many as 20% of patients. Nonetheless, thermal ablation has permitted treatment of patients with otherwise unresectable disease and we have learned how to apply to it appropriately in patients. The risk of incomplete tumor destruction is much higher in tumors larger than 4 cm in diameter or in lesions that abut major vascular structures. Tumors that are near major hilar structures should not be treated with thermal ablation techniques unless some special circumstance allows installation and infusion of cooled solutions into the biliary system to prevent bile duct injury. This is somewhat extreme and while technically feasible, should not be considered routinely and should be performed only as part of clinical trials in the hands of experienced practitioners. I do commonly perform concomitant RFA of small contralateral tumors in patients undergoing right or left hepatectomy or extended right or left hepatectomy. This must be applied judiciously as a surrounding zone of normal hepatic parenchyma will be destroyed by the ablation technique and consideration must always be given to the amount of liver volume that will remain following a combined resection and ablation procedure.

## SUMMARY

Surgeons should understand the role and timing of application of surgical treatment for localized hepatic infections. Similarly, patients are often referred after a benign tumor of the liver is encountered during some type of imaging study. These generally do not require surgical treatment but certain lesions, particularly hepatic adenomas, do require close follow-up evaluation and symptomatic or large lesions can be treated by either laparoscopic or open surgical resection. The surgical treatment of primary and metastatic solid tumors that are confined to the liver will continue to have an important role. This remains the gold standard for treatment for these patients and offers the best opportunity for long-term disease-free and overall survival. We must continue to take the lead in investigation of neoadjuvant and adjuvant multidisciplinary approaches in both primary and metastatic hepatic malignancies in an attempt to improve further the outcomes for our patients.

# PERSPECTIVE ON LIVER SURGERY

Richard S. Swanson

## RESECTION OF COLORECTAL CANCER METASTATIC TO THE LIVER

Chapter 45 expertly describes the preoperative evaluation, patient selection, integration of chemotherapy, and results of resection for colorectal cancer (CRC) metastatic to the liver. Below are comments about the technique of resection.

Most liver resections can be done with a right subcostal incision extended vertically in the midline to the xyphoid process. Patients prefer this incision to the rooftop or “Chevron” incision that rarely is needed. Inspection and palpation should exclude extrahepatic disease and assess intrahepatic disease. At this point, intraoperative ultrasound (IOUS) should be performed to determine the size and location of all tumor nodules. IOUS can help plan the resection to maximize the chance of obtaining a negative margin. With no contraindication to resection, the appropriate resection can be performed. Resections depend on the segments that need to be removed. A diagram of Couinaud’s segments is in Fig. 46B-1.

The nomenclature for resections depends on the segments removed as summarized in Table 46B-1. Right hepatectomy is the most common major liver resection and it is described in detail below.

### Right Hepatectomy

The right side of the liver is mobilized by dividing the right triangular ligament and the anterior and posterior leaflets of the right coronary ligament. The inferior vena cava (IVC) is exposed and small branches from the liver to the IVC are ligated and divided to facilitate exposure and avoid tearing. At this point, attention is focused on the porta hepatis for the hepatoduodenal dissection.

The gallbladder is removed and the bile duct is traced to the liver. The hepatic artery is identified and the right hepatic artery (RHA) isolated, usually anterior to the hepatic duct but occasionally posterior to the hepatic duct. The RHA is ligated and divided, carefully protecting the main and left

hepatic arteries. The right hepatic duct is divided and the hepatic duct can be lifted anteriorly to the left to expose the portal vein (Fig. 46B-2). The junction of left and right portal vein (RPV) is exposed cautiously and a vessel loop is placed around the RPV. It is preferable to ligate and divide the RPV with sutures or a vascular stapler that ligates and cuts. At this point, inflow control is achieved and the liver will quickly demarcate such that the right liver will discolor. It now is reasonable to maximize outflow control.

An alternative method to achieve inflow control is to isolate and ligate the right portal pedicle intrahepatically. This can be done by incising the capsule in segments four and six and placing a finger around the pedicle in the liver. IOUS can monitor this technique. A vascular stapler can be applied to control the inflow.

The liver is rotated anteriorly and to the left. Small veins emptying directly from the liver into the IVC are ligated and divided. This might require suture ligation of the veins at the IVC as these branches are quite short. The surgeon should work from caudad to cephalad to secure these branches; usually there are about four pairs. A broad fibrous band of tissue extends from the IVC to the liver just caudad to the right hepatic vein (RHV). This tissue has small veins in it or next to it. There can be a larger accessory RHV in or next to this tissue. This band needs to be divided to expose the RHV (Fig. 46B-3).

Careful sharp and blunt dissection usually can isolate the RHV outside the liver such that it can be divided with clamps or a vascular stapler. The vascular stapler with 2.5-mm staples works well; clamps and Prolene sutures occasionally slip or tear producing significant bleeding. With inflow and outflow control, the parenchyma is transected to obtain a 1-cm margin. If the central venous pressure (CVP) is kept low, then backbleeding will be minimized. To minimize the risk of air embolism when the CVP is low during transection, the patient should be kept in a Trendelenberg position. There are several methods for parenchymal transection. The standard technique is “finger fracture” that requires fracturing the parenchyma with the index finger and thumb to define vessels and bile ducts. The vessels and ducts are ligated or clipped and the liver is expeditiously transected (Fig. 46B-4). Variations of the finger fracture technique

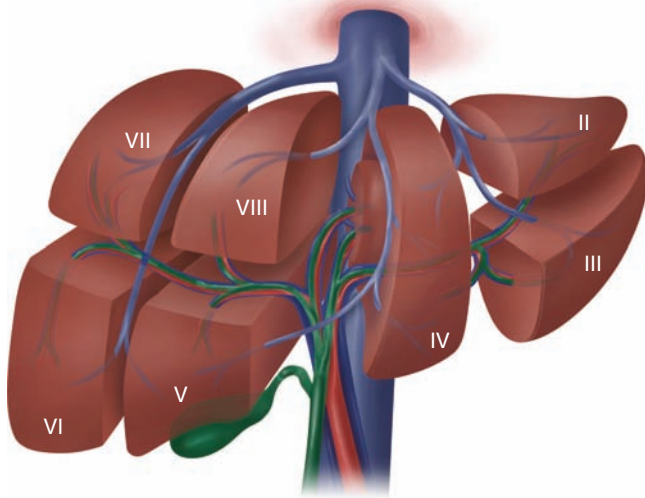


FIGURE 46B-1 The functional division of the liver and the segments according to Couinaud's nomenclature.

use a Kelly clamp, closed scissors, or a metal suction device. The key is to use a method that works well for the surgical team such that one surgeon can do the fracturing while another surgeon secures the vessels. During this maneuver, bleeding can be minimized by occluding inflow at the porta hepatis as a Pringle maneuver with clamping for 10–15 minutes with 2–5 minutes of unclamping. This maneuver can be repeated until the liver has been divided. A normal liver without steatohepatitis should tolerate 45 minutes of normothermic ischemia.

Other devices have been designed to divide the parenchyma. These include the ultrasonic dissector, the water jet dissector, the saline-linked radiofrequency (RF) dissecting sealer, the bipolar vessel sealing device, and the harmonic scalpel. Each device has its proponents. Some use these devices to meticulously and slowly divide the complete parenchyma of the liver, suturing, tying, or clipping vessels or ducts. Others use these devices to divide a portion of the parenchyma; when they are deep in the parenchyma and when the margin is not

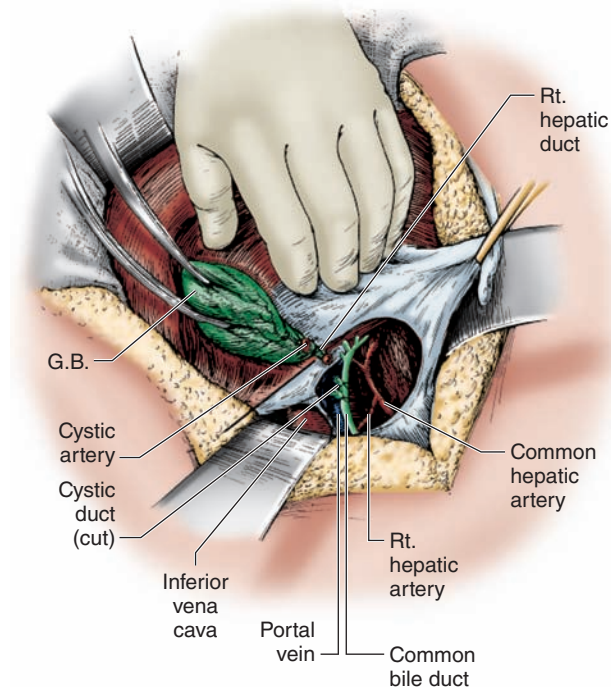


FIGURE 46B-2 Hepatoduodenal dissection.

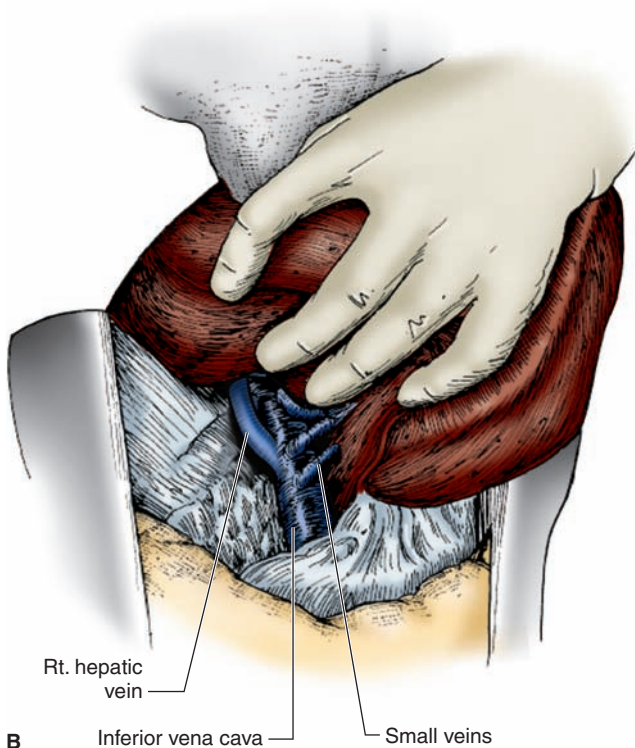
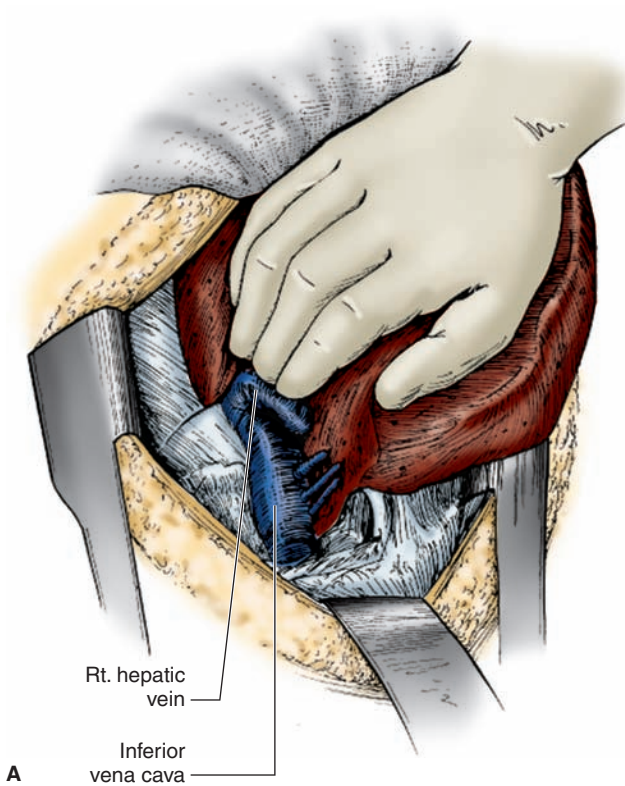
an issue, these surgeons switch to a finger fracture technique to finish the dissection. To expedite deep parenchymal division, many will use vascular staplers. Vascular staplers control vessels efficiently and they can be used for parenchymal transection. To perform transection of the right liver can require over 15 vascular stapler cartridges. The parenchymal transection can be performed in less than 10 minutes without the need for a Pringle maneuver. The staplers can rip vessels if not guided appropriately. The firm metal blade of the stapler should be introduced carefully; there should be no force required to introduce the stapler. The obvious argument against staplers is cost. If the stapler companies would reduce the costs of the staplers, many surgeons would use multiple loads of the vascular stapler to divide the liver. If two experienced surgeons use finger fracture, the cost of transection is small and the resection can be performed with little blood loss. If a liver surgeon performs finger fracture with an inexperienced resident, the time for transection and the blood loss can be considerable. The RF resection device (such as the Habib) ablates liver tissue that then can be cut with a knife or a bipolar cautery device. The problem with these devices are twofold: (1) cost—one RF resection device can cost as much as 30 or more stapler cartridges; and (2) vessels less than 5 mm in diameter can be ablated but larger vessels can bleed significantly from the holes of the electrodes. The RF resection devices are very effective for peripheral nonanatomic wedge resections and left lateral liver resections. Theoretically, the radiofrequency ablation (RFA) can treat microscopic tumor cells at the margin. The first



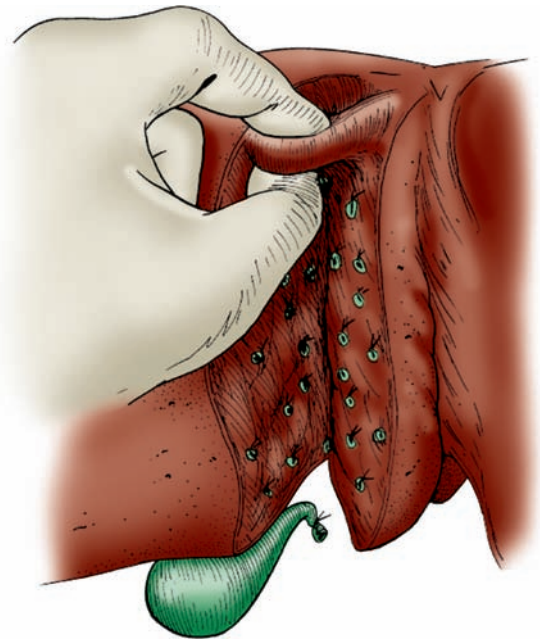
TABLE 46B-1: DEFINITIONS OF LIVER RESECTION

Definition	Couinaud's Segments Removed
Right hepatectomy	V, VI, VII, VIII
Left hepatectomy	II, III, IV
Right trisegmentectomy (right lobectomy)	IV, V, VI, VII, VIII
Left trisegmentectomy	II, III, IV, V, VIII
Left lateral liver resection (left lobectomy)	II, III





**FIGURE 46B-3** A and B. Retrohepatic dissection to achieve control of hepatic veins.



**FIGURE 46B-4** Finger fracture technique. Posterosuperior intraparenchymal dissection of the RHV.

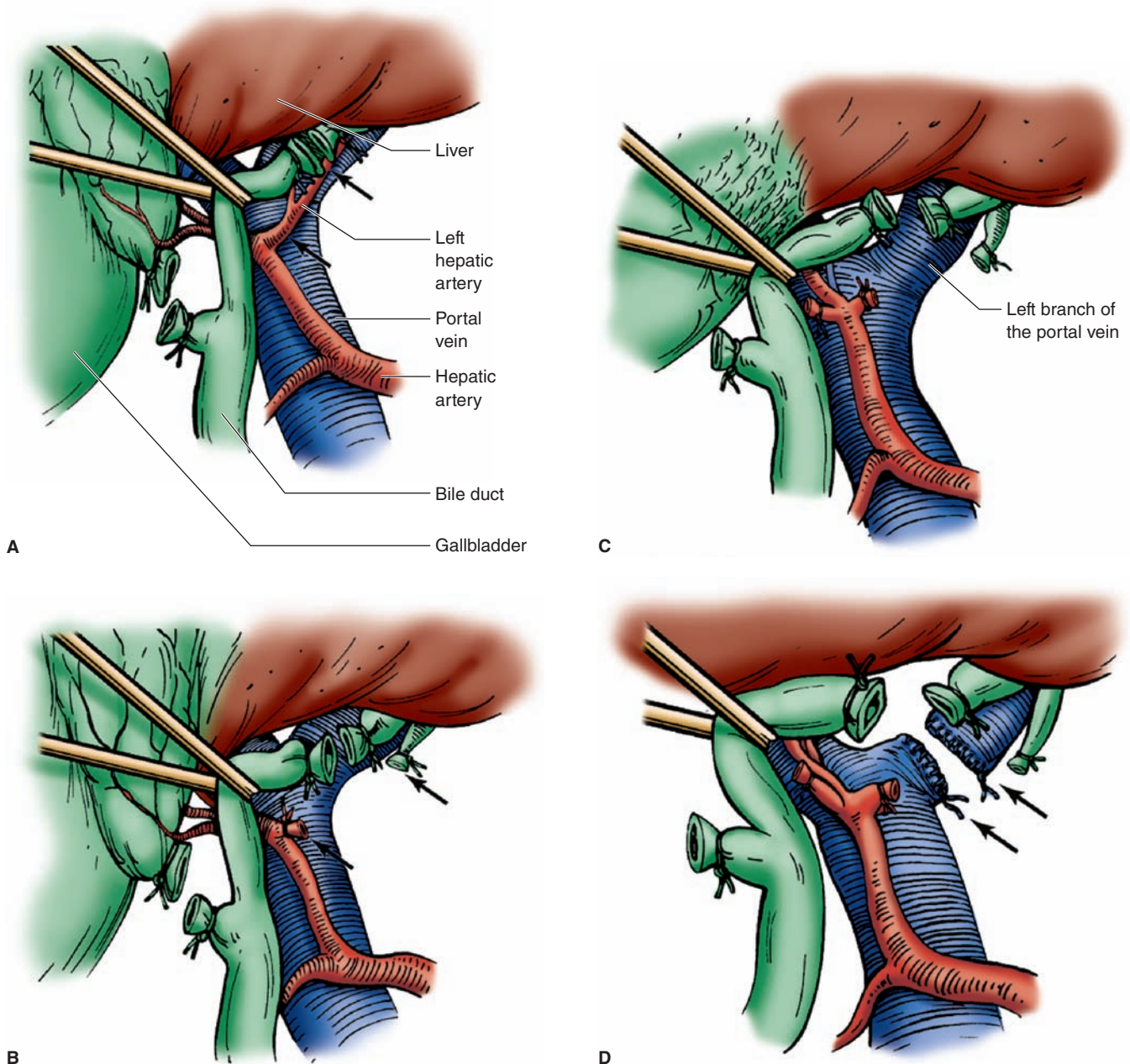
laparoscopic liver resection with a RF resection device was done at the Brigham and Women's Hospital (BWH),<sup>1</sup> but now most laparoscopic liver resections at the BWH are done with the staplers or a variation of the finger fracture method.

The above operation can be performed with a laparoscope either as a complete laparoscopic procedure or as a hand-assisted laparoscopic liver resection.<sup>2,3</sup> Multiple methods of parenchymal transection can be performed laparoscopically. The vascular staplers work well with the use of a handport. A reason to use staplers to transect the liver during open liver resection is to become familiar with this technique for laparoscopic resection. The intra-abdominal pressure with pneumoperitoneum can tamponade some of the smaller venous bleeding. This nuisance bleeding can be controlled with the Argon Beam Coagulator, topical sealants, or with sutures as necessary. The Argon Beam Coagulator should be used with caution as a venous embolus with Argon does not dissipate as quickly as carbon dioxide. Draining the right upper quadrant usually is done for several days if there is concern about a possible bile leak.

Patients should be discharged in 4–5 days. Blood transfusions should be avoided, if possible, as the survival rate decreases after liver resection if transfusion is used.

## Left Hepatectomy

Left hepatectomy essentially is the mirror image to right hepatectomy. A hilar dissection controls inflow (Fig. 46B-5). If the caudate lobe needs to be removed, it can be freed from the IVC facilitating isolation of the left hepatic vein (LHV). A stapler can be used to divide it. Alternatively, the parenchyma



**FIGURE 46B-5** Hilar dissection in left hepatectomy. **A.** Division of cystic duct and left hepatic duct; **B.** Division of left hepatic artery; **C.** Exposure of left portal vein; **D.** Division of left portal vein.

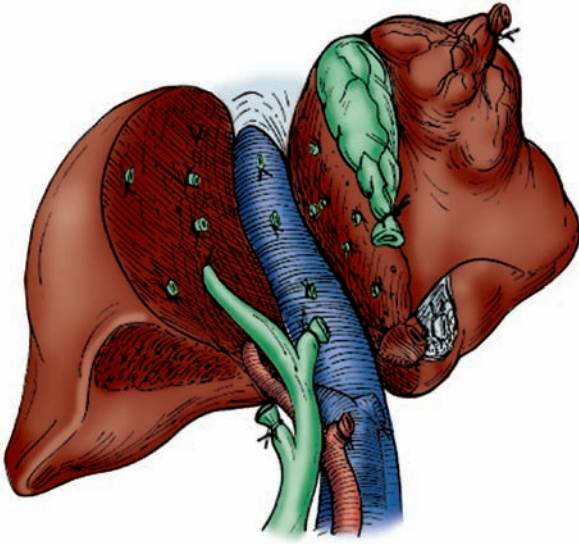
can be divided and the LHV can be secured during the parenchymal dissection (Fig. 46B-6).

## PUMPS FOR TREATMENT OF COLORECTAL METASTASES TO THE LIVER

Administering chemotherapy directly into the hepatic artery via a catheter introduced through the femoral artery has been practiced for over 30 years. Toward the end of the 1970s, a totally self-contained implantable pump was

developed that allowed continuous arterial infusion of chemotherapy via a catheter placed in the gastroduodenal artery at the junction of the hepatic artery. The rationale for HAI chemotherapy takes advantage of the observation that CRC metastases in the liver derive the majority of their blood supply from the hepatic artery, not the portal vein.<sup>4</sup> Further, the drug most commonly used for HAI, fluorodeoxyuridine (FUDR), has over 95% uptake in the liver on first pass as compared to 5-fluorouracil (5-FU) that has less than 50% uptake on first pass.<sup>5</sup> This major difference allows HAI with FUDR at 100–400 times the concentration of systemic 5-FU.





**FIGURE 46B-6** Completed transection of the parenchyma in left hepatectomy.

Randomized studies evaluating HAI with FUDR versus systemic 5-FU conducted in the 1980s showed response rates of 30–50% with HAI FUDR but did not conclusively demonstrate a survival benefit with this technique.<sup>5–10</sup> Thus, the appropriate role for this treatment continues to be debated. The literature is clear that the frequency and severity of complications decrease with increasing experience of the surgeon. These complications include pump malfunction, pocket problems, catheter occlusion or dislodgement, and arterial complications (hemorrhage, thrombosis, or perfusion problems).<sup>10</sup> Currently, the indications for HAI chemotherapy are twofold: (1) for the treatment of unresectable liver-only metastases from CRC; and (2) as an adjunct after the resection of CRC metastatic to the liver. Both indications are controversial. With no definitive randomized study showing a clear benefit to HAI chemotherapy, a multi-institutional trial of HAI with FUDR versus systemic 5-FU-based chemotherapy was conducted in the 1990s. The HAI chemotherapy group had about a 3-month median survival time advantage over the systemic therapy group.<sup>11</sup> However, this trial was criticized by many medical oncologists because (1) the survival time advantage was considered too short to argue for pump implantation; and (2) newer systemic agents provide longer survival times than the systemic regimen used in this trial. A single-institution randomized trial showed a survival advantage at 2 years with HAI chemotherapy after liver resection versus no HAI chemotherapy.<sup>12</sup> This trial was criticized because there was not a significant long-term survival advantage in the HAI group. At the moment, HAI chemotherapy is not widely used principally because most oncologists are not comfortable managing pump chemotherapy and they feel systemic chemotherapy is adequate.

The technique of pump implantation requires insertion of a catheter into the gastroduodenal artery with the tip

close to the junction with the hepatic artery. The pump is placed in the subcutaneous space on the abdominal wall. The gallbladder is removed to obviate chemical cholecystitis. Potential arterial branches from the hepatic artery to the stomach or duodenum are interrupted to avoid chemical duodenitis or gastritis.

## ABLATION OF COLORECTAL METASTASES TO THE LIVER

RFA is a treatment that destroys tumors in situ by protein denaturation and thermal coagulation. It has been used to treat tumors since the early 1900. Beer used RF coagulation through a cystoscope to treat bladder tumors in 1908. Cushing used RFA to treat intracranial tumors in 1926. In 1990, two groups independently used ultrasound to guide RFA treatment of liver tumors. RFA uses alternating current with a frequency between 10 kHz and 900 MHz. Tissue adjacent to the electrode dies from the heat generated in the tissue by RF energy; the electrode itself does not become hot but it delivers RF energy that causes mechanical friction in the tissue that leads to thermal ablation.<sup>13</sup>

Resection is the best treatment for CRC metastatic to the liver. RFA is used as an alternative to resection when (1) comorbid disease precludes resection, or (2) anatomical considerations preclude resection. Examples of the latter indication principally are twofold. First, if a discrete number of metastases are located in different segments such that resection of the lesions would result in inadequate residual liver volume, then RFA would be reasonable. Second, if several lesions in one-half of the liver can be removed with an ipsilateral hepatectomy but a lesion deep in the contralateral half of the liver cannot be removed, an ipsilateral hepatectomy with RFA of the lesion in the contralateral liver would be appropriate.

RFA can be performed percutaneously in an imaging suite with computed tomography (CT) scan or ultrasound guidance, or in the operating room either open or laparoscopically with ultrasound guidance. Complication rates associated with RFA in one large review and one single-institution study were 7 and 2.4%, respectively.<sup>14,15</sup> The reported procedure-related mortality rate is 0.5% (10 deaths in 1931 patients).<sup>14</sup> Complications are more frequent in those undergoing open RFA versus percutaneous RFA. Complications include abscess, biloma, bile duct injury, pleural effusion, and pain.<sup>16,17</sup>

Some claim that RFA for solitary CRC metastases is associated with infrequent local recurrences. The M.D. Anderson group recently examined this issue. With a median follow-up time of 31 months, they found a 37% local recurrence rate for RFA treatment of solitary metastases as compared to a 5% local recurrence for resection ( $p = .0001$ ).<sup>18</sup> The subset with smaller tumors—less than 3 cm in diameter—had a 31% local recurrence rate with RFA compared to 3% with resection. Clearly, RFA of CRC metastases to the liver is not equivalent to resection; RFA should be considered investigational or—at best—an inferior, second-choice treatment.



## BENIGN AND MALIGNANT PRIMARY TUMORS

Cho and Fong appropriately state that imaging modalities should differentiate hemangiomas, focal nodular hyperplasia (FNH), adenomas, and cancers. When it is difficult to confirm the diagnosis of a benign (or malignant) tumor,<sup>19–23</sup> a biopsy can be considered; however, as the authors state, liver biopsies of suspected tumors notoriously are inaccurate, and complications such as bleeding and spread of tumor can occur. The inadequate accuracy and bleeding complications of liver biopsy particularly become relevant when attempting to distinguish the atypical FNH that does not need resection from the adenoma that does.

### Focal Nodular Hyperplasia

FNH is the second most common solid tumor or the most common nonvascular benign tumor of the liver. It possibly comes from a polyclonal hyperplastic response to locally altered blood flow.<sup>24</sup> Resection infrequently is necessary to diagnose or treat pain. Pain usually is from a source other than the FNH; thus, a search for other causes is mandatory. If pain is from the FNH, the FNH usually is large but a small FNH can cause pain.

### Hepatocellular Adenomas

Hepatocellular adenomas (HCAs) typically occur in young females who are taking oral contraceptive pills (OCPs). The initial management is to stop the OCP which should shrink the tumor. This action both confirms diagnosis and treats the tumor. In general, all adenomas greater than 5 cm or symptomatic should be resected. But this approach generates questions that cannot be answered adequately because the natural history of adenomas is not well known. These questions include:

If an adenoma shrinks to less than 5 cm with cessation of the OCP, can it safely be observed? Probably, but adenomas less than 5 cm can bleed or transform into hepatocellular carcinomas (HCCs).<sup>25</sup>

Will small adenomas cause trouble during pregnancy? Probably not. Dokmak et al reported 11 patients followed through pregnancy with no problems.<sup>26</sup> But adenomas less than 5 cm can bleed and transform,<sup>25</sup> and pregnancy is associated with a significant increase in estrogen that stimulates the growth of adenomas. It probably is reasonable to monitor a pregnant patient with a small adenoma by using ultrasound of the liver during pregnancy.

Does adenomatosis of the liver (defined by most as >10 adenomas) demand a liver transplant? The literature certainly is not clear about this issue. The Mayo Clinic used a definition of adenomatosis to be more than three tumors and they recommended observing adenomas less than 3 cm in diameter

and resecting adenomas greater than 5 cm.<sup>27</sup> Others have reported selective transplantation for adenomatosis.<sup>28</sup>

Can small adenomas be treated by percutaneous RFA? The literature does not have adequate information to answer this question.

### Regenerative Nodular Hyperplasia

These tumors do not need treatment but they are becoming an increasing clinical problem because they are associated with chemotherapy given before resection of CRC metastatic to the liver. Wicherts et al found regenerative nodular hyperplasia in 22% who had six cycles of preoperative chemotherapy containing oxaliplatin. Distinguishing these tumors from other tumors becomes an issue, and these tumors are associated with an increase in postoperative hepatic morbidity (50 vs 29%).<sup>29</sup>

### Hepatocellular Carcinoma

The best treatment of HCC is resection but the cirrhosis generally associated with HCC makes resection difficult. As Cho and Fong note, it is difficult to use preoperative information to determine whether or not a minimally cirrhotic liver can tolerate resection. In selected cases, preoperative portal vein embolization (PVE) might demonstrate whether or not a chronically damaged liver has the ability to grow. If 4–6 weeks after PVE the future liver remnant does not grow, then liver resection probably would not be tolerated. At this point, this strategy is speculation at best.

After resection, RFA is a second choice for treatment of HCC. Ideally, HCC should be resected with a healthy negative margin, but this approach can be difficult from a bleeding standpoint as well as from a liver function standpoint. To minimize bleeding and theoretically optimize tumor control as well as liver function, it is reasonable to use a RF resection device to ablate a plane of liver tissue at the edge of the tumor. Theoretically, this should kill microscopic tumor at the margin, and minimize bleeding during resection.

## HEPATIC ABSCESSSES AND CYSTIC DISEASES OF THE LIVER

Chapter 43 expertly discusses hepatic abscesses and cystic diseases of the liver. Given the advances in laparoscopy, the management of cystic diseases of the liver particularly has evolved. Patients with large liver cysts who have symptoms typically have pain. A search for other causes of pain is reasonable as most liver cysts do not cause pain. If pain appears to be due to a large liver cyst, then a magnetic resonance imaging (MRI) with magnetic resonance cholangiopancreatography (MRCP)

is reasonable specifically to examine the cyst lining and any possible communication with the biliary tree. If the lining does not have nodularity and there is no obvious communication with the biliary tree, then laparoscopy with aspiration of the cyst contents followed by generous laparoscopic resection of protruding cyst wall can provide significant tissue for frozen section analysis. While awaiting frozen section analysis, the remainder of the cyst lining can be examined and biopsied if there is any concerning tissue. If frozen section reveals a simple cyst, then the remaining lining can be cauterized to minimize recurrence of the cyst. If frozen section reveals cystadenoma, then the remaining epithelium should be removed. If it technically is not possible to remove the epithelium laparoscopically, then open resection should be considered. An alternative is to cauterize laparoscopically the remaining epithelium in the cyst. This should kill any residual cystadenoma which should prevent cystadenocarcinoma from occurring. We have used this approach selectively although there are no long-term large series demonstrating the efficacy of this strategy. If frozen section reveals cystadenocarcinoma, then formal resection to obtain negative margins—either by open or laparoscopic technique—should be performed.

## REFERENCES

- Clancy TE, Swanson RS. Laparoscopic radiofrequency-assisted liver resection (LRR): a report of two cases. *Digestive Disease and Sciences*. 2005;50:2259–2262.
- Gigot JF, Glineur D, Azagra JS, et al. Laparoscopic liver resection for malignant liver tumors: preliminary results of a multicenter European study. *Ann Surg*. 2002;236:90–97.
- Buell J, Koffron A, Thomas M, Rudich S, Abecassis M, Woodle E. Laparoscopic liver resection. *J Am Coll Surg*. 2005;200:472–480.
- Ridge JA, Bading JR, Gelbard AS, et al. Perfusion of colorectal hepatic metastases: relative distribution of flow from the hepatic artery and portal vein. *Cancer*. 1987;59:1547.
- Ensminger WD, Rosowsky A, Raso V, et al. A clinical-pharmacological evaluation of hepatic arterial infusions of 5-fluoro-2'-deoxyuridine and 5-fluorouracil. *Cancer Res*. 1978;38:3784–3789.
- Chang AE, Schneider PD, Sugarbaker PH, et al. A prospective randomized trial of regional versus systemic continuous fluorodeoxyuridine chemotherapy in the treatment of colorectal liver metastases. *Ann Surg*. 1987;206:685–693.
- Hohn DC, Stagg RJ, Friedman MA, et al. A randomized trial of continuous intravenous versus hepatic intraarterial floxuridine in patients with colorectal cancer metastatic to the liver: the Northern California oncology group trial. *J Clin Oncol*. 1989;7:1646–1654.
- Kemeny N, Daly J, Reichman B, et al. Intrahepatic or systemic infusion of fluorodeoxyuridine in patients with liver metastases from colorectal carcinoma. *Ann Intern Med*. 1987;107:459–465.
- Martin JK, O'Connell MJ, Wieand HS, et al. Intra-arterial floxuridine vs systemic fluorouracil for hepatic metastases from colorectal cancer. *Arch Surg*. 1990;125:1022–1027.
- Allen PJ, Nissan A, Picon AI, et al. Technical complications and durability of hepatic artery infusion pumps for unresectable colorectal liver metastases: an institutional experience of 544 consecutive cases. *J Am Coll Surg*. 2005;201:57–65.
- Kemeny NE, Niedzwiecki D, Hollis DR, et al. Hepatic arterial infusion versus systemic therapy for hepatic metastases from colorectal cancer: a randomized trial of efficacy, quality of life, and molecular markers (CALGB 9481). *J Clin Oncology*. 2006;24:1395–1403.
- Kemeny N, Huang Y, Cohen AM, et al. Hepatic arterial infusion of chemotherapy after resection of hepatic metastases from colorectal cancer. *N Engl J Med*. 1999;228:756–762.
- Decadt B, Siriwardena AK. Radiofrequency ablation of liver tumors: systematic review. *Lancet Oncol*. 2004;5:550–560.
- Mulier S, Mulier P, Ni Y, et al. Complications of radiofrequency coagulation of liver tumours. *Br J Surg*. 2002;89:1206–1222.
- Curley SA, Francesco I, Delrio P, et al. Radiofrequency ablation of unresectable primary and metastatic hepatic malignancies. *Ann Surg*. 1999;230:1–7.
- Scudamore CH, Shung IL, Patterson EJ, et al. Radiofrequency ablation followed by resection of malignant liver tumors. *Am J Surg*. 1999;177:411–417.
- Abdalla EK, Vauthey JN, Ellis LM, et al. Recurrence and outcomes following hepatic resection, radiofrequency ablation, and combined resection/ablation for colorectal liver metastases. *Ann Surg*. 2004;239:818–825.
- Aloia TA, Vauthey J-N, Loyer EM, et al. Solitary colorectal liver metastasis: resection determines outcome. In press. *Arch Surg*. 2006;141:460–466.
- Adam R, Akpınar E, Johann M, et al. Place of cryosurgery in the treatment of malignant liver tumors. *Ann Surg*. 1997;225:39–50.
- Onik G, Rubinsky B, Zemel R, et al. Ultrasound-guided hepatic cryosurgery in the treatment of colorectal metastatic colon carcinoma. Preliminary results. *Cancer*. 1991;67:901–907.
- Weaver ML, Atkinson D, Zemel R. Hepatic cryosurgery in treating colorectal metastases. *Cancer*. 1995;76:210–214.
- Seifert JK, Morris DL. Prognostic factors after cryotherapy for hepatic metastases from colorectal cancer. *Ann Surg*. 1998;228:201–208.
- Yan TD, Padang R, Morris DL. Longterm results and prognostic indicators after cryotherapy and hepatic arterial chemotherapy with or without resection for colorectal liver metastases in 224 patients: Longterm survival can be achieved in patients with multiple bilateral liver metastases. *J Am Coll Surg*. 2006;202:100–111.
- Maillette de Buy, Weinniger L, Terpstra V, Beurs V. *Digestive Surgery*. 2010;27:24–31.
- Foster J, Berman M. The malignant transformation of liver cell adenomas. *Arch Surg*. 1994;129:712–717.
- Dokmak S, Paradis V, Vilgrain V, et al. A single-center surgical experience of 122 patients with single and multiple hepatocellular adenomas. *Gastroenterology*. 2009;137:1698–1705.
- Ribeiro A, Burgart LJ, Nagorney DM, Gores GJ. Management of liver adenomatosis: results with a conservative surgical approach. *Liver Transplantation and Surgery*. 1998;4:388–398.
- Chiche L, Dao J, Salame E. Liver adenomatosis: reappraisal, diagnosis, and surgical management: eight new cases and a review of the literature. *Ann Surg*. 2000;231:74–81.
- Wichert DA, de Haas RJ, Sebagh M, et al. Regenerative nodular hyperplasia related to chemotherapy. *Ann Surg Oncology*. 2011;18:659–669.

*This page intentionally left blank*



# PORTAL HYPERTENSION

*J. Michael Henderson*

Portal hypertension is present when portal venous pressure exceeds 10 mm Hg. This chapter addresses the causes, evaluation, and treatment options for patients with portal hypertension. While the emphasis is on surgical aspects, this group of patients requires a multidisciplinary approach and surgical therapy must inevitably be viewed in this context. The major clinical presentations that will be addressed are variceal bleeding, ascites, end-stage liver disease, and the pulmonary syndromes. Whatever the presentation of portal hypertension, be it an incidental finding or one of the above clinical presentations, it demands full investigation. In the United States, the etiology is most commonly cirrhosis, but other etiologies such as prehepatic portal or splenic vein thrombosis or other intraparenchymal liver disease such as schistosomiasis or hepatic fibrosis should be considered. Definition of the cause is important as prognosis depends on the underlying liver disease, and a full evaluation to allow development of a treatment plan for variceal bleeding, ascites, or end-stage liver disease is paramount at initial presentation. The focus of this chapter is on emphasizing the role of a multidisciplinary team approach to managing patients with portal hypertension.

## HISTORY

Portal hypertension was recognized by the Greeks<sup>1,2</sup>, was highlighted by Shakespeare in his character of Falstaff, and has played a role through much of history. The evolution of the treatment of portal hypertension was driven by surgeons until the 1980s. Nicolai Eck, a Russian Army surgeon, performed an end-to-side portacaval shunt in 1883 in an animal model. Pavlov, the great Russian physiologist, conducted animal studies that showed the detrimental effect of diverting portal flow, describing meat intoxication (encephalopathy) and liver failure. Vidal, a French surgeon is credited with performing the first portal systemic shunt in a human in 1903. Morison and Talma operated on patients with portal hypertension with procedures such as omentopexy and splenic transposition, but

their failure to recognize cirrhosis as the cause of portal hypertension led to poor results.

In the 1940s, Whipple and the Columbia Presbyterian group in New York initiated an era of success for portal decompression.<sup>3</sup> The next 40 years saw many refinements to decompressive shunts, Drapanas with mesocaval shunts,<sup>4</sup> Warren and Inochuchi with selective variceal decompression,<sup>5,6</sup> and Sarfeh with partial shunts.<sup>7</sup> This era saw many randomized trials documenting efficacy of shunts.

Endoscopic therapy was the next major advance in managing variceal bleeding, being first done by surgeons with rigid esophagoscopes.<sup>8</sup> In the 1980s, three surgeons, Johnston, Terblanche,<sup>9</sup> and Paquet,<sup>10</sup> bridged the gap from rigid to flexible variceal sclerotherapy. Another surgeon, Steigmann,<sup>11</sup> moved the field forward by introducing variceal band ligation.

Over the last three decades, the more recent advances have been made by nonsurgeons. A better understanding of the pathophysiology, the ability to better evaluate liver diseases, the introduction of pharmacologic therapy, development of the radiologic shunt, and coming of age of liver transplantation are the main contributors to this progress. Lebrec and his colleagues in the 1980s introduced beta-blockers to reduce portal hypertension,<sup>12</sup> and this has become the primary treatment for reducing the risk of an initial variceal bleed and first-line treatment for those who have bled. Transjugular intrahepatic portosystemic shunt (TIPS), pioneered by Rösch,<sup>13</sup> has led to shunts being more safely placed by the radiologist than the surgeon with lower early morbidity and mortality.

However, two surgeons, Starzl<sup>14</sup> and Calne,<sup>15</sup> revolutionized the whole field of hepatology with their persistence in developing liver transplantation through the 1960s to 1980s, and bringing it to a clinical reality. Transplantation has not only offered a treatment for patients with end-stage liver disease and portal hypertension, but has also opened the doors to further investigation.

It is around this history of portal hypertension that many of the investigative and treatment options discussed in this chapter are built.

## PATHOPHYSIOLOGY

The pathophysiology of portal hypertension<sup>16,17</sup> has been clarified over the past two decades in animal models documenting the sequential changes in the splanchnic and systemic circulations. The sequence of events is as follows:

- Block to portal flow leads to increased portal pressure.
- Splanchnic vascular bed response.
  - (a) Initial increased vasoconstrictor and decreased vasodilator response increases intrahepatic resistance.
  - (b) Secondly, the vasodilator response dominates, with increase in splanchnic inflow.
- Collaterals develop between the portal circulation and the systemic circulation.
- Plasma volume expansion occurs with the development of a systemic hyperdynamic circulation.

The splanchnic vascular response leads to increased flow in the gut and thus major clinical manifestations of collaterals in multiple locations: at the umbilicus, in the retroperitoneum, hemorrhoidal, and at the gastroesophageal junction.

The systemic hemodynamic changes result in cardiac outputs in the 10–15 L/min range, systolic blood pressures in the 100–110 range, and a low calculated total systemic vascular resistance. These changes have significant management implications for fluid resuscitation and patient management. It is important for the managing physician to understand these pathophysiologic changes and their impact on patient care.

## COMPLICATIONS

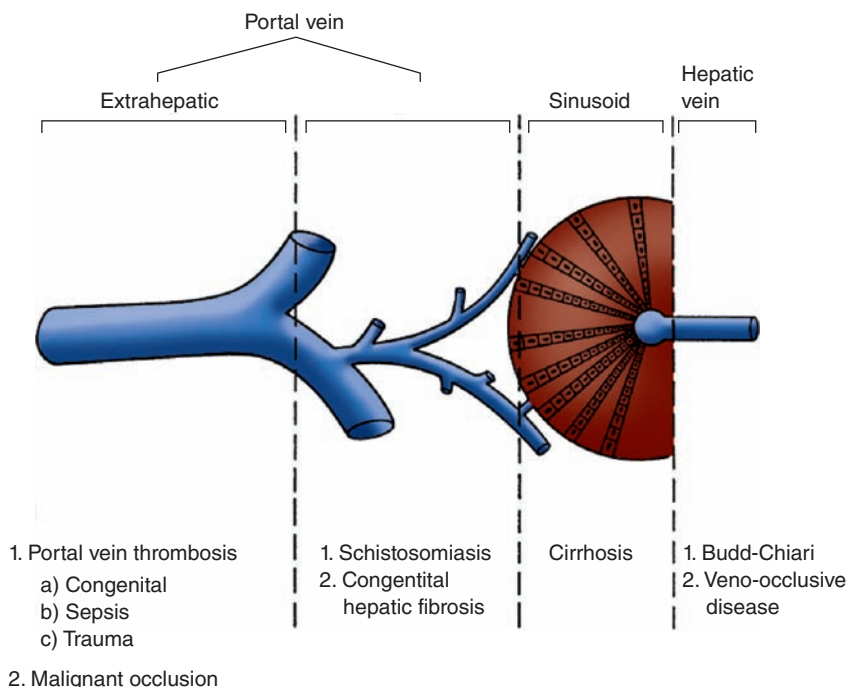
The major complications of portal hypertension are as follows:

- Variceal bleeding
- Ascites
- End-stage liver disease
- Hepatopulmonary syndromes

This chapter will address the etiology, evaluation methods, specific therapies, and overall treatment strategies for each of these complications. An important distinction in patients with portal hypertension is between those with ascites and encephalopathy, which are markers of advanced liver disease, and patients with variceal bleeding, which may occur in patients with a normal liver (portal vein thrombosis) or early in the course of cirrhosis. The implication of this is that the range of treatment options is considerably broader for variceal bleeding than it is for patients with ascites and encephalopathy.

## ETIOLOGY

Figure 47-1 illustrates the wide range of etiologies for portal hypertension.<sup>18</sup> In the United States and Europe, approximately 90% of patients with portal hypertension have cirrhosis, with a small percentage having portal vein thrombosis (PVT) or hepatic fibrosis. The latter are important to differentiate because they have normal liver function and a much better prognosis. Worldwide, schistosomiasis is an important etiology



**FIGURE 47-1** Sites for obstruction in portal hypertension. In the United States and Europe, most patients have a sinusoidal block secondary to cirrhosis. Other causes must be considered.

of portal hypertension, occurring mainly in the Middle and Far East and South America. It is characterized by fibrosis of the terminal portal venules, and in the absence of concurrent hepatitis, these patients have normal liver function.

Cirrhosis covers a broad spectrum of disease by etiology and severity. Alcoholic liver disease and hepatitis are the most common etiologies, with other causes, such as the cholestatic liver diseases of primary biliary cirrhosis (PBC) and primary sclerosing cholangitis (PSC), and the metabolic liver diseases such as hemochromatosis, Wilson's disease, and  $\alpha$ 1-antitrypsin deficiency, contributing a small percentage. Whatever may be the etiology of the cirrhosis, full evaluation of activity and stage of the disease is an important part of initial patient evaluation. Different etiologies may have different natural histories which is important in developing a treatment plan.

## EVALUATION

The evaluation of patients with portal hypertension has the following essential components, and should be done at initial presentation:

- Assessment of the liver disease
- Assessment of the portal circulation
- Upper gastrointestinal (GI) endoscopy

Liver evaluation<sup>19,20</sup> is based on clinical findings and laboratory studies. Jaundice, ascites, encephalopathy, and malnutrition define a patient with end-stage liver disease. Some patients with variceal bleeding do not show these clinical signs and have well-preserved liver function. Laboratory tests add objectivity, the most useful indicators being serum bilirubin, albumin, prothrombin time, and creatinine. The two main scoring systems for liver disease severity are the Child-Pugh score<sup>19</sup> (Table 47-1) and the Model for End-stage Liver Disease (MELD) score<sup>20</sup> (Equation 47-1). Specific serologic markers may be useful in defining etiology for viral hepatitis, or for some of the metabolic diseases with antimitochondrial antibody, iron studies,  $\alpha$ 1-antitrypsin, or ceruloplasmin levels. In addition, alpha-fetoprotein (AFP) should be measured in all such patients as a screening test for hepatoma.

**TABLE 47-1: CHILD-PUGH SCORE**

Parameter	1 Point	2 Points	3 Points
Serum bilirubin (mg/dL)	<2	2–3	>3
Albumin (g/dL)	>3.5	2.8–3.5	<2.8
Prothrombin time ( $\uparrow$ S)	1–3	4–6	>6
Ascites	None	Slight	Moderate
Encephalopathy	None	1–2	3–4

Grades: A, 5–6 points  
B, 7–9 points  
C, 10–15 points

Equation 47-1

MELD Score

$$\text{Score} = 0.957 \times \log_e \text{creatinine (mg/dL)} + 0.378 \times \log_e \text{bilirubin (mg/dL)} + 1.120 \log_e \text{INR}$$

When a patient has portal hypertension, usually shown by varices, a cause must be found. If clinical and laboratory studies do not fit, imaging and a liver biopsy may be indicated. Quantitative liver testing with studies such as indocyanine green clearance, galactose elimination capacity, and monoethylglycine xylidide (MEGX) formation are advocated by some, but have not proved to be clinically useful.

Imaging is initially with ultrasound to show overall liver morphology and potentially to pick up focal lesions suggestive of hepatoma. Contrast-enhanced computed tomography (CT) scan or magnetic resonance imaging (MRI) may be required for morphologic assessment. Liver biopsy may be required to confirm that some patients do have underlying cirrhosis, and in cases of focal lesions, to differentiate hepatocellular carcinoma from regenerative nodules. In the latter case a biopsy of the uninvolved liver is performed as well as the focal lesion to assess for cirrhosis.

Vascular anatomy is evaluated with imaging modalities of escalating complexity depending on information required for management.<sup>21–23</sup> Doppler ultrasound can assess the hepatic artery, portal and hepatic veins and this may be all that is required. Documenting size, directional flow, velocities, and wave-form patterns of the portal and hepatic veins is a standard procedure. Tributaries to the portal vein—the superior mesenteric and splenic veins, and large collaterals such as the coronary and umbilical vein may also be readily defined. The most important information that the clinician needs to know is the patency (or thrombosis) of the portal vein. Hepatic artery patency, course, and resistive index can be assessed with Doppler ultrasound.

The next level of complexity for evaluating the liver circulation is with CT scan or MRI. These two modalities may be combined with CT or MR angiography (MRA). The speed of scanners, new contrast-enhancing agents, and the increasingly advanced software for data reconstruction allow sophisticated imaging of the liver's arterial and venous anatomy. These methods have improved preoperative planning for living donor liver transplantation and liver resection.

Finally, angiography still plays a role for direct pressure measurement and clarification when the prior modalities are unclear. Portal pressure is measured indirectly from the hepatic veins by measuring wedged and free hepatic vein pressures, with the difference being the hepatic venous pressure gradient (HVPG).<sup>24</sup> This is done using a balloon occlusion technique akin to a Swan-Ganz catheter measurement in the pulmonary circulation. Normal HVPG is 6–8 mm Hg, and in cirrhosis it will be greater than 10 mm Hg. There has been resurgence of interest in HPV to measure response to pharmacologic therapy. Direct portal pressure measurement also can be done by the transjugular, transhepatic route. This method, useful in



the acute situation particularly when combined with TIPS, is not used for repeated measurements.

Upper GI endoscopy is used to assess varices. All patients with cirrhosis should have an upper endoscopy. This recommendation is based on epidemiologic studies that have shown the following:

- Thirty percent of patients with cirrhosis develop portal hypertension.
- Thirty percent of patients with portal hypertension will bleed from varices within 2 years.
- The rate of development of varices in patients with cirrhosis is approximately 8% per year.

Endoscopy should focus on the presence of varices; the size, extent, and tortuosity; and the presence or absence of red color signs. Large varices with red color signs are at greater risk of bleeding. In patients with cirrhosis and upper GI bleeding, endoscopy may be both diagnostic and therapeutic with banding. Following an acute variceal bleed, the extent of varices should be assessed after stabilization. Grading systems for varices have been developed and validated by the Japanese<sup>25</sup> and Italians.<sup>26</sup> Finally, the gastric mucosa should be evaluated for evidence of portal hypertensive gastropathy with congestion and cobble stoning.<sup>27</sup> Gastric varices may also be seen, with isolated gastric varices being more problematic than gastric varices in continuity with esophageal varices.<sup>28</sup>

## MANAGEMENT OF VARICEAL BLEEDING

Figure 47-2 illustrates a management algorithm for variceal bleeding that requires a multidisciplinary team, and may vary from center to center depending on available expertise. The team should have a predetermined, step-wise management plan for patients with variceal bleeding. This algorithm will form the basis for further discussion of patients.

The following therapies are available for treating variceal bleeding:

- Pharmacotherapy
- Endoscopic therapy
- Decompressive shunts—radiologic or surgical
- Devascularization operations
- Liver transplantation

Pharmacologic therapy plays a role in preventing the initial bleed, managing the acute variceal bleed, and as first-line treatment in preventing rebleeding.

Noncardioselective beta-blockers (Inderal [propranolol hydrochloride] or nadolol) were shown by Lebrec and his colleagues in the early 1980s to reduce portal hypertension.<sup>12</sup> Patients with moderate- to large-size varices should be placed on one of these drugs for prophylaxis prior to their first bleed. Not all patients tolerate beta-blockers or are responsive to them, with a noncompliance or fallout rate of about 20%. The target for treatment is greater than 20% or

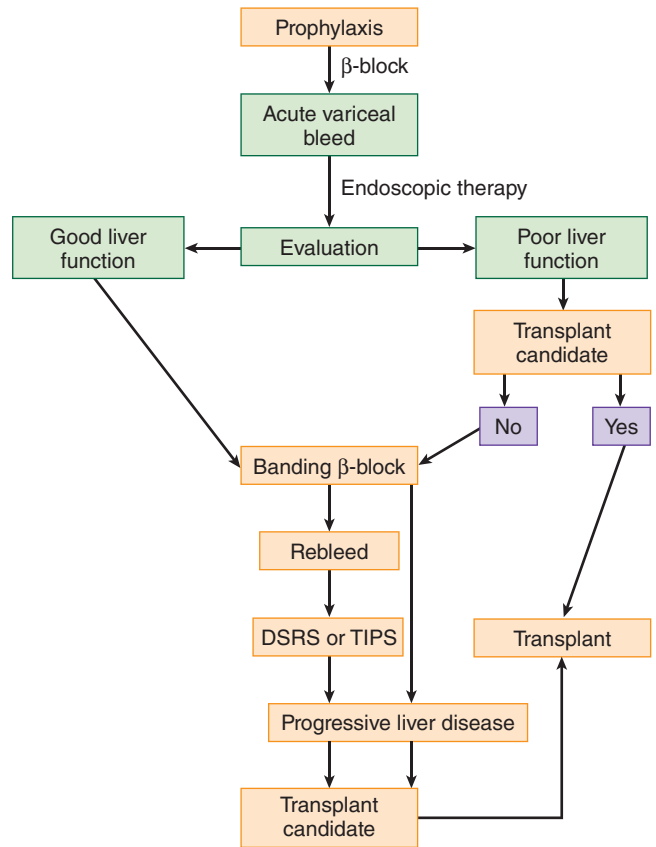


FIGURE 47-2 Algorithm for management of patients with variceal bleeding.

less than 12 mm Hg reduction in HVPG. If this is achieved, patients will not bleed.<sup>29</sup>

Propranolol or nadolol are used as initial therapy to prevent rebleeding, with the same caveats for tolerance, response rates, and targets for therapy. Many other pharmacologic agents have been evaluated such as long-acting nitrates, serotonin antagonists, and calcium channel blockers. None of these have been shown to be as efficacious as the beta-blockers, and while combination therapy has been beneficial in some studies, it has been limited by side effects.<sup>29,30</sup>

Pharmacologic therapy for acute variceal bleeding was initially with vasopressin. It has been largely replaced by terlipressin, or somatostatin or one of its analogs. These drugs effectively reduce portal pressure in the patient with acute variceal bleeding.

## Endoscopic Therapy

The current standard for endoscopic therapy for esophageal varices is endoscopic banding.<sup>11</sup> This has largely replaced endoscopic sclerotherapy because it has fewer side effects, obliterates varices faster, and can be easily applied. Multiband ligators can be fitted on the end of the endoscope and allow the firing of six to eight bands in a spiral fashion onto columns of

varices. The varix is sucked into the end of the applicator, and the band fired around its base. The bands will slough off in 5–7 days with less ulceration over the varices than induced by sclerotherapy, and hence a lower initial rebleeding rate. Endoscopic banding can be used in the patient with acute variceal bleeding if the bleeding varix can be identified. A course of banding—usually two to three sessions—is then applied over the next month to 6 weeks in an attempt to obliterate the varices at the gastroesophageal junction. Occasionally, endoscopic sclerotherapy with injection of a sclerosing solution may be a useful adjunct to complete the obliteration of smaller varices that cannot be banded.

Many prospective, randomized controlled trials have documented better control of bleeding with endoscopic banding than sclerotherapy, with lower morbidity. However, the mortality was not significantly different between banded and sclerosed patients in these trials.<sup>31</sup>

From a practical point of view, patients with an acute variceal bleed should have their bleeding controlled with an endoscopic session, have their varices obliterated with a course of banding, and be placed on a noncardioselective beta-blocker for long-term management. This constitutes first-line treatment.

## Decompressive Shunts

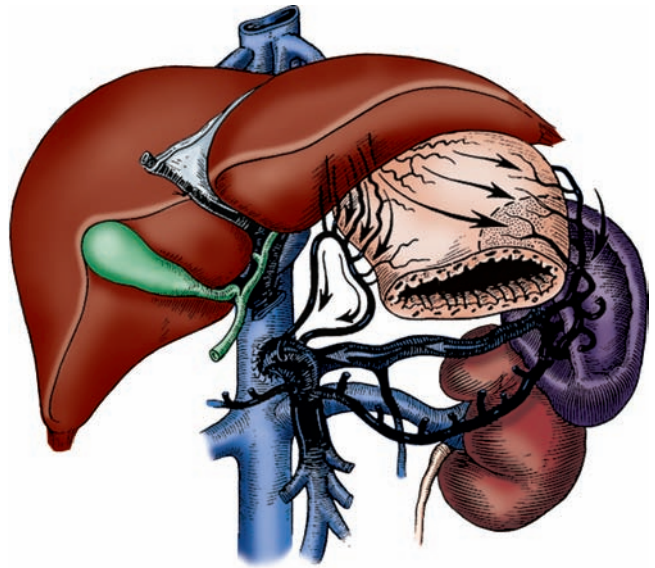
This component of management of variceal bleeding has changed dramatically over the last two decades. Decompression is considered second-line treatment and is reserved for patients who rebleed through pharmacologic therapy and endoscopic banding or whose varices remain “high risk.” Very few surgical shunts are performed at the current time, and patients requiring decompression are usually managed with a radiologically placed shunt—TIPS.

Surgical shunts are largely of historic interest and fall into three groups: total, partial, and selective shunts.

## Total Shunts

Figures 47-3 and 47-4 illustrate total shunts,<sup>32,33</sup> with two physiologically different types. Figure 47-3 shows a classic end-to-side portacaval shunt in which the portal vein is divided close to the hilus of the liver and the splanchnic end anastomosed to the side of the vena cava. This decompresses the splanchnic portal hypertension but leaves the obstructed sinusoids under high pressure. As such, it will not relieve ascites but will control variceal bleeding.

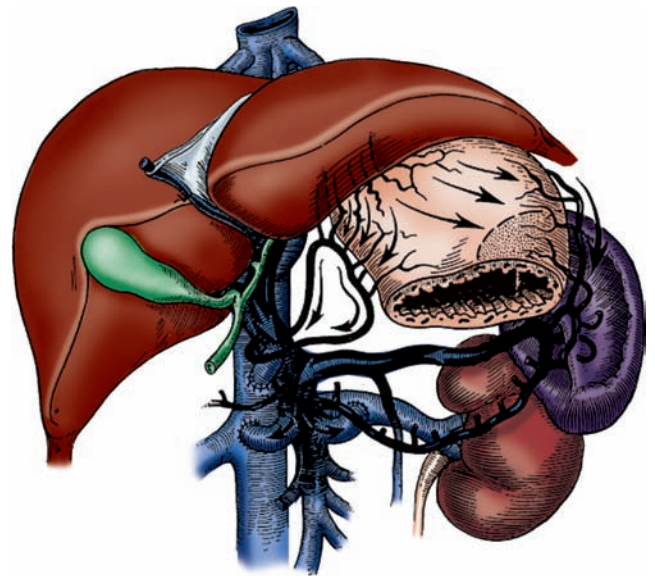
Figure 47-4 illustrates the second group of total shunts, which are either side-to-side portacaval shunts with direct vein-to-vein or a short interposition graft, or the other interposition shunts such as mesocaval or mesorenal as illustrated. These shunts need to be at least 10 mm in diameter, usually being 12–15 mm, to fully decompress portal hypertension and be classified as a total shunt. Pathophysiologically, these



**FIGURE 47-3** End-to-side portacaval shunt. This shunt decompresses varices and the splanchnic circulation. Sinusoidal pressure remains high in the cirrhotic liver.

shunts differ from the end-to-side portacaval shunt in that the intact upper end of the portal vein serves as a decompressive outflow from the high-pressure–obstructed liver sinusoids. Hence, in addition to controlling variceal bleeding, these shunts also control ascites.

These total shunts (>10 mm in diameter) divert all portal flow away from the liver and the major debate has been the



**FIGURE 47-4** Side-to-side portal systemic shunts. Portacaval, mesocaval, and mesorenal shunts are shown. The portal vein acts as an outflow from obstructed sinusoids, decompressing the liver as well as varices and the splanchnic circulation.

effect that this has on hepatic function. Data are conflicting as to the severity of the portopulmonary syndrome (diversion of all portal flow), its effect on liver function, and its role in causing encephalopathy. It is almost certainly the severity of the underlying liver disease, which is the dominant factor in whether a shunt accelerated liver failure.

The technical aspects of a side-to-side portacaval shunt are relatively straightforward. The portal vein and inferior vena cava are approached from the right side, usually through a long right subcostal incision. Sufficient length of the portal vein is mobilized in the right edge of the hepatoduodenal ligament. The inferior vena cava is mobilized from the lower border of the liver to the renal veins. This will usually allow for a direct side-to-side portacaval anastomosis. When the caudate lobe is particularly large, either a segment of this may be excised, or a short interposition graft may be used. These vessels are familiar territory to the transplant surgeon, who can perform this operation in the few patients in whom it is indicated.

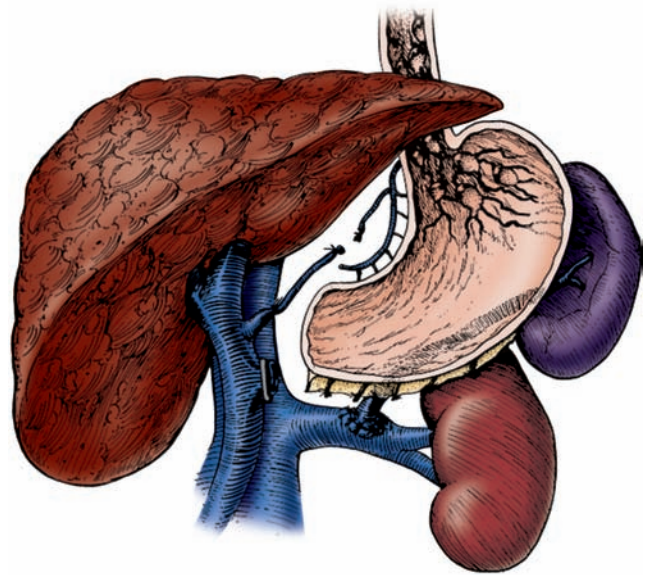
The only indication for a total portal systemic shunt at present is for patients with acute Budd-Chiari syndrome in which the congested intrahepatic sinusoids need to be decompressed using a side-to-side total shunt.<sup>34</sup>

## Partial Shunts

Partial shunts are side-to-side shunts whose diameter is reduced to 8 mm. Sarfeh and associates in the 1980s systematically reduced the size of polytetrafluoroethylene (PTFE) interposition grafts between the portal vein and the inferior vena cava down to 8 mm diameter, showing that at this size there is a greater than 90% control of variceal bleeding and maintained portal perfusion in 80% of patients.<sup>7</sup> This shunt has been used in a randomized trial compared to TIPS.<sup>35,36</sup> The surgical approach is similar to that used for a side-to-side portacaval shunt, with the PTFE graft being approximately 2–3 cm long, and beveled at each end to give a larger anastomosis.

## Selective Shunts

Selective shunts are most commonly the distal splenorenal shunt (DSRS) (Fig 47-5).<sup>5</sup> This shunt leaves the spleen in situ, divides the splenic vein at its junction with the superior mesenteric vein, and anastomoses the splenic vein to the left renal vein. This selectively decompresses gastroesophageal varices. Portal hypertension is maintained in the splanchnic and portal veins to maintain portal flow to the liver in Child's class A and B+ patients. Control of bleeding has been at 94%, with good portal perfusion maintained in 90% of patients initially. Portal flow is preserved in greater than 90% of patients with nonalcoholic liver disease long term, but loss of portal flow occurs in 50% of alcoholic patients. The overall incidence of encephalopathy has been around 15% following this operation.<sup>37-41</sup>



**FIGURE 47-5** Distal splenorenal shunt (DSRS). Varices are decompressed transplenic to the left renal vein. Portal hypertension is maintained in the splanchnic bed to keep prograde portal flow to the liver.

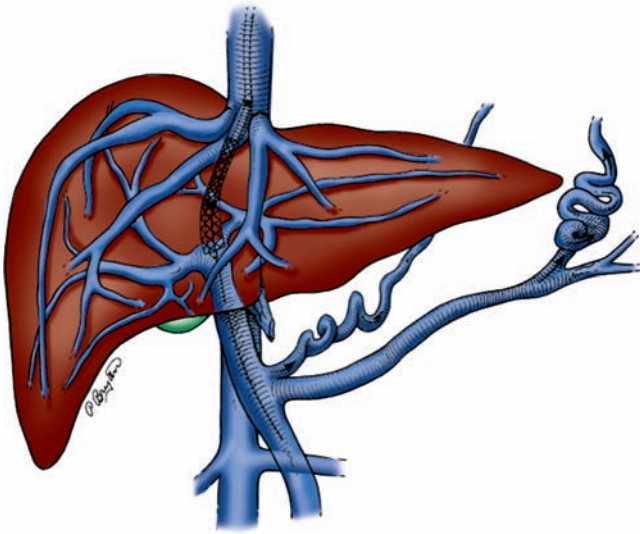
DSRS is done through a long left subcostal incision. The pancreas is approached through the lesser sac, taking down the gastrocolic omentum to the short gastric vessels, and the splenic flexure of the colon. The pancreas is then mobilized along its inferior margin over its whole length to the left of the superior mesenteric vessels. The splenic vein is identified and carefully dissected out from the posterior surface of the pancreas over sufficient length to allow it to come down to the left renal vein without kinking. The operation is completed by interrupting the other collateral pathways between the portal vein and the shunt, particularly the coronary vein.

Postoperative management for all of these surgical procedures requires attention to detail. Patients should be managed in a monitored environment for 24 hours to make sure they are hemodynamically stable and there is no early postoperative bleeding. Limiting intravenous (IV) fluids and sodium helps minimize the risk of ascites. Infection prophylaxis, nutrition, and careful monitoring of hepatic function are important. Shunt patency should be documented prior to hospital discharge with imaging studies.

## Transjugular Intrahepatic Portal Systemic Shunt

TIPS has matured over the last two decades, and is now the most widely used method for decompressing portal hypertension in patients with variceal bleeding or ascites.<sup>42-44</sup> It is an important part of the repertoire for the multidisciplinary team managing these patients. Figure 47-6 shows the principles of TIPS. The technical approach to TIPS is





**FIGURE 47-6** Transjugular intrahepatic portal systemic shunt (TIPS). This side-to-side shunt has variable hemodynamic effect depending on its diameter.

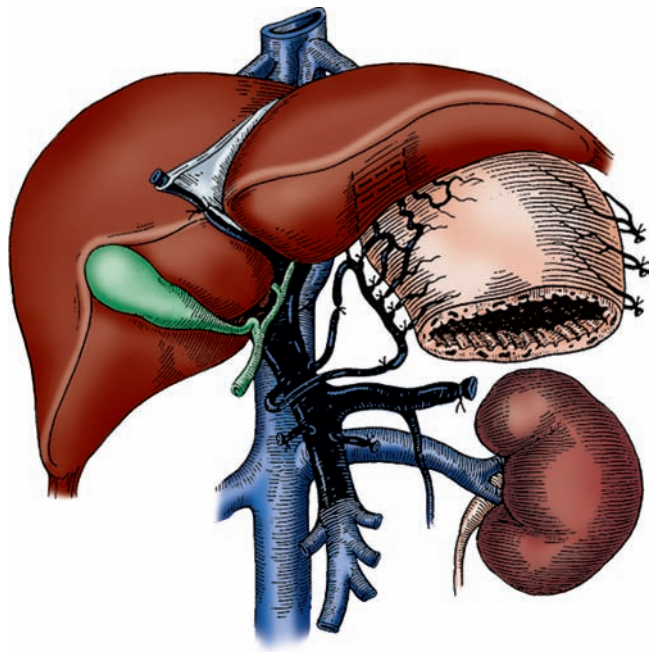
direct puncture of the internal jugular vein (IJV), passage of a catheter through the right atrium into one of the major hepatic veins—usually the right vein—followed by a transparenchymal puncture of the liver to cannulate the portal vein. The catheter is passed into the portal vein and pressure is measured. The portal vein puncture may be aided by ultrasound definition of its location. The intraparenchymal track is then dilated and the track stented with an expandable metal stent in the 10- to 12-mm-diameter range. Pressures are again measured and the goal is to decrease the gradient between the portal vein and the right atrium to less than 10 mm Hg. The technical success rate is high (>90%) with a low procedural morbidity and mortality (<10%). Patients are usually in the hospital for 1–2 days and the shunt patency should be documented the day after the procedure with a Doppler ultrasound.

The major issue with TIPS is its restenosis and thrombosis rates, which requires careful monitoring, and dilation and/or shunt extension when detected. The risk of early thrombosis seems to be related to bile duct puncture as the parenchymal track is developed. Covered TIPS stents have reduced thrombosis and stenosis rates. While a Doppler ultrasound will document patency, it has not proved to be a sensitive method for documenting stenoses, which requires direct measurement of the pressure gradient. Reintervention rates to maintain patency were high with uncovered stents, ranging from 40 to 80%, but have fallen to about 20% with covered stents.<sup>45</sup> The overall published rebleeding rates for TIPS are around 20%, and this was reduced to 13% in the covered stent trial.<sup>45</sup> Most centers have developed standard follow-up protocols to monitor TIPS, which call for repeated Doppler ultrasound. New encephalopathy rates are around 30%. Most of this encephalopathy appears to be relatively easily controlled with lactulose and/or some minimal protein restriction.

## Devascularization Procedures

These operations approach the problem of variceal bleeding by interrupting inflow to the varices. The components are splenectomy, gastric and esophageal devascularization, and possibly esophageal transection (Fig. 47-7).<sup>46</sup> The effectiveness of these procedures appears to depend on the aggressiveness of the operation. Popularized by Sugiura in Japan<sup>46</sup> and Hassab in Egypt, good results have been obtained in these countries. The advantage of these procedures is that portal hypertension is maintained with portal flow to the cirrhotic liver. Control of variceal bleeding in the originators' hands has been greater than 90%,<sup>47</sup> but higher rebleeding rates (~30%) have been seen in Europe and the United States.<sup>48</sup> These results are probably related to applying this operation to poorer-risk patients who are not candidates for other operations and inadequate operative devascularization. More recent application of devascularization procedures by Orozco and colleagues in Mexico has achieved good results with a 10% rebleeding rate.<sup>49</sup>

From a technical perspective, the original Sugiura operation combined an abdominal and a thoracic procedure either as a single- or two-stage approach. More recently, most surgeons have approached devascularizations purely from an abdominal approach. Standard devascularization operations include splenectomy, but Orozco and colleagues have published data indicating this is not essential. The whole of the greater curve should be devascularized, at least 7 cm of the distal esophagus, and finally the upper two-thirds of the lesser curve of the stomach. Attempts are made to keep the vagus



**FIGURE 47-7** Gastroesophageal devascularization for variceal bleeding. Splenectomy, gastric and esophageal devascularization, and esophageal transection are the components of these operations.

nerve intact and the devascularization has the appearances of a proximal gastric vagotomy as the operation is completed. Because many of these patients have received sclerotherapy or banding prior to operative intervention, most do not need an esophageal transection, which can be difficult with the thickened esophagus.

Devascularization can be useful when patients have extensive portal and splenic venous thrombosis and there are no other operative or radiologic options. Extensive devascularization will reduce the risk of bleeding in such patients, and this remains the main indication for this operation.

Postoperative management requires attention to detail to minimize the risk of ascites as these patients still have portal hypertension. Follow-up endoscopy around 6 months is often helpful to document if there are any residual varices, treat them endoscopically at that time, or document the completeness of the devascularization procedure.

Overall, the bleeding rates can be reduced to less than 20% with this procedure and encephalopathy rates are low.

## Liver Transplant

Liver transplant is the most commonly used operation for patients with portal hypertension at the present time,<sup>50–52</sup> and has been *the* major advance in the treatment of patients with advanced liver disease and sequelae of portal hypertension. The major issues are patient selection, timing of transplant, expanding the donor pool, and outcomes.

Patient selection has evolved over the past two decades. The indication for transplant is end-stage liver disease, but definition of this in the field of hepatology is a moving target. Variceal bleeding per se is not necessarily an indication of end-stage liver disease but other manifestations of portal hypertension such as ascites and encephalopathy are clinical indicators of end-stage liver disease. Patient selection also depends on other variables such as comorbid medical conditions and a psychosocial suitability for transplant particularly in the alcoholic and other chemical dependency patient populations. The increase in the incidence of hepatoma, particularly in the hepatitis C population, has also changed indications for patient selection for liver transplant. Standards for patient listing have been set by the United Network for Organ Sharing (UNOS), with evolving indications proposed by individual liver centers considered by regional review boards.

The timing of transplant is dictated by the severity of the underlying liver disease. Prioritization for organs occurs on the basis of MELD scores, with the sickest patients receiving cadaveric organs first based on bilirubin, prothrombin time, and serum creatinine. Timing is dictated by these objective criteria rather than individual physician decisions in day-to-day patient management. The donor pool for liver transplant has expanded with increasing public awareness of the need for organ donation, the use of “expanded donor” criteria with concomitant documentation that these organs do work, and the application of living donor transplant. The direct impact of these changes on the donor pool, the systems of organ

allocation and prioritization, and individual center philosophies and priorities for their patients have changed and will continue to change the role of liver transplantation in portal hypertension.

The outcomes with liver transplant have continued to improve. The fear that pushing organs to the sickest patients would lead to poorer outcomes has not been fulfilled. Hospital mortality remains at less than 10%, despite transplanting in sicker and sicker patients and despite using more marginal organs. This is testimony to the advances in the fields of organ preservation and overall patient management during and following liver transplantation. The expectation therefore for outcomes is less than 10% hospital mortality and an 80+% 1-year survival with a 60–65% 5-year survival for liver transplant.

Technical aspects of liver transplant have focused on use of whole organ grafts, partial segmental grafts, living donor grafts, techniques of caval preservation, alternative methods of revascularization, and improved methods for biliary reconstruction. In addition to these technical advances in the transplant field itself, the increasing number of surgeons who have developed this expertise also represent the pool of surgeons with the ability to conduct some of the operative procedures described earlier in this chapter.

The management and longer-term follow-up of patients with portal hypertension coming to liver transplant is likewise an evolving field. Improvement in methods of immunosuppression, infection prophylaxis and treatment, patient monitoring to reduce the risk of transplant-related malignancy, and long-term health maintenance after transplant are ongoing fields of investigation and improvement. The net result of all of these advances is that patients with Child’s class C cirrhosis, variceal bleeding, and advanced liver disease can now look forward to a reasonable chance of long-term survival, whereas 15–20 years ago, they had a 15–20% chance of long-term survival.

## MANAGEMENT STRATEGIES

### Variceal Bleeding

The treatment options just described need to be used appropriately in treatment strategies for

- Prophylaxis
- Acute variceal bleeding
- Prevention of rebleeding

### Prophylaxis

Beta-blockers should be used for all patients with medium or large varices to reduce their risk of an initial bleed. Bleeding risk can be reduced from 30% to 18–20% with beta-blocker treatment. Multiple randomized controlled trials have documented this benefit. Patients with cirrhosis should have a screening endoscopy to assess for varices and initiate treatment if appropriate.<sup>29,30</sup>

Endoscopic therapy for prophylaxis should only be used for large varices and patients intolerant to beta-blockers.<sup>53</sup> Surgical therapy or radiologic shunts are not indicated in prophylaxis prior to an initial variceal bleed.<sup>30</sup>

## Acute Variceal Bleeding

Acute variceal bleeding may require several treatment modalities and outcome has improved in the past decade.<sup>54</sup> Most important is the overall management of the patient rather than the specific therapies. Airway protection, appropriate fluid resuscitation, adequate monitoring, and antibiotic prophylaxis are all now standard of care for such patients. Transfusion of blood for bleeding, blood products for coagulopathy must be carefully monitored with a target of under- rather than over-resuscitation. Pharmacologic therapy with intravenous octreotide (50  $\mu\text{g}/\text{h}$ ) will reduce portal pressure and should be initiated on suspicion of a variceal bleed. Early endoscopy, both for diagnosis and initial banding therapy, is the mainstay of treatment.<sup>55</sup> Endoscopic banding can be done provided the varix is visualized and can be sucked into the end of the scope. In the occasional patient in whom endoscopic therapy cannot be performed, balloon tamponade should be used to control bleeding. Inflation of the gastric balloon alone, pulled gently up into the gastric fundus, will usually suffice to control bleeding. If that fails to control the bleeding, the esophageal balloon may need to be inflated to 40 mm Hg. Placement of a tamponade balloon mandates further reintervention within 24 hours, and this is usually an indication for an emergency TIPS procedure.

TIPS is required in fewer than 10% of patients with acute variceal bleeding.<sup>42</sup> Emergency TIPS placement needs to be treated in the same way as if the patient were going to the operating room. Airway protection, careful monitoring, and appropriate fluid management and resuscitation are required. While the radiologist is concentrating on the technical aspects of placing an accurate decompressing TIPS shunt, the patient overall management team needs to assure all other aspects of care are completed.

The patient with an acute variceal bleeding episode still carries a significant mortality risk, death most commonly resulting from decompensation of the underlying liver disease. A major bleed requires an intensive care unit (ICU) admission, but once stable, patients can be transferred to a regular hospital floor. Early evaluation and follow-up endoscopy to initiate an elective course of banding is the next step in overall patient management.

## Prevention of Rebleeding

The first-line treatment for prevention of rebleeding is a course of variceal banding and concomitant pharmacologic therapy with a beta-blocker no matter what the underlying cause is.<sup>29,30</sup> The first elective banding episode should be performed within 3 or 4 days of the acute bleeding episode and

as many bands placed as necessary to obliterate the columns of varices in the distal esophagus. Subsequently one or two banding sessions will probably be required to obliterate these varices. A beta-blocker is started with the target of reducing the pulse rate by 20% and with the plan to use this for long-term therapy.

Overall patient care also mandates a full evaluation of the patient at this point.<sup>56,57</sup> An understanding of the etiology of the liver disease, its severity, its likely natural history, and looking for other complications of portal hypertension should be completed at this stage. Several possible case scenarios may emerge:

- Good-risk patients—Child’s A patients or MELD less than 10. Patients who still look like a Child’s A patient after a variceal bleed and have MELD scores less than 10 probably have well-compensated liver disease. These patients should be treated with first-line treatment, but if they rebleed or have failure to obliterate their varices with banding, they may be a candidate for decompression with TIPS or DSRS.
- Indeterminate patients—Child’s B or MELD 10–16. The majority of patients will fall into this category after their variceal bleed with some disturbance in their liver laboratory numbers, possibly developing ascites, and having an unpredictable course for their liver disease. From a management perspective, the question is whether these patients will improve to Child’s A, remain Child’s B patients, or move toward end-stage disease. Their initial treatment is with endoscopic banding and a beta-blocker. Subsequent treatment depends on the course of their liver disease.
- End-stage liver disease—Child’s C or MELD greater than 16. If initial evaluation shows Child’s C cirrhosis and patients clearly are not improving with routine clinical management, consideration needs to be given to full transplant evaluation. The severity of the bleeding episode may play some role in whether or not these patients’ disease will return to a compensated level or whether they will continue to deteriorate secondary to the acute bleeding episode.

Failure of first-line treatment can occur in several scenarios. The main reasons are (1) the patient may have a further acute variceal bleed, (2) the patient may have recurring small bleeding episodes that are not transfusion-requiring, or (3) the patient may fail to have the varices obliterated and continue to have large varices with risk factors. Patients with any of the above scenarios, who also have advanced liver disease, are candidates for liver transplantation, possibly using TIPS as a bridge. Any of the above occurring in patients with well-compensated liver disease (Child’s class A) may lead to variceal decompression with DSRS or TIPS.

Decompression with TIPS versus a surgical shunt has been evaluated in two randomized controlled trials. Rosemurgy and associates<sup>36</sup> studied the relative benefits of TIPS versus the 8-mm portacaval H-graft shunt. In their “all comers” study of 132 patients, 50% of their population were Child’s class C patients. They showed a significantly lower rebleeding



rate, and significantly lower rate of need for transplant with the surgical shunt compared to the TIPS group, but no significant difference in survival.

A randomized trial compared DSRS to TIPS at five clinical centers in 140 Child's class A and B patients who failed first-line treatment.<sup>58</sup> Data showed no significant difference in rebleeding rates (5.5% DSRS group, 10.5% TIPS group), no significant difference in the times to first encephalopathy episode with 50% of patients in each group having at least one episode of encephalopathy by 5 years, and no significant difference in survival between the two groups. However, the reintervention rate in the TIPS group was significantly ( $p < .001$ ) higher at 82% compared to a reintervention rate of 11% in the DSRS group. The rate of total thrombosis was significantly higher in the TIPS group compared to the DSRS group. This study used uncovered TIPS stents, which was all that was available at the time of this National Institutes of Health (NIH)-funded trial. The excellent results were achieved through intensive surveillance in the TIPS group compared to the DSRS patients to achieve the low rebleeding rate. A cost-effectiveness analysis of patients in this trial showed TIPS may be more cost-effective than DSRS in good risk Child's AB patients.<sup>59</sup>

Studies of TIPS with covered stents have shown significant advantages compared to uncovered stents for rates of stenosis and rebleeding.<sup>60</sup> This has now become the standard for variceal decompression when needed.

## Ascites

The management of ascites is primarily medical with dietary salt restriction and diuretics (spironolactone and furosemide).<sup>61</sup> When ascites becomes refractory to such a regimen, large-volume paracentesis or TIPS may be considered, but these are a bridge to transplant. As indicated above, refractory ascites is one of the major clinical signs of end-stage liver disease. Four randomized trials have shown benefit and better control of ascites with TIPS compared to large-volume paracentesis, but survival benefit was only shown in two of four studies.<sup>62–65</sup>

Other surgical methods that have been used to manage ascites are side-to-side total portal systemic shunts and portovenous shunts. The only indication currently to use a side-to-side (>10 mm) portacaval shunt for ascites is in patients with acute Budd-Chiari syndrome in whom decompression of the liver sinusoids with this operation will not only relieve their ascites, but will also stop the centrilobular hepatocyte necrosis and allow the liver to recover. The question to be answered in such a patient with acute Budd-Chiari syndrome is whether the same result can be achieved with TIPS.

Portovenous shunts are seldom indicated in 2010 because the alternatives for managing intractable ascites, large-volume paracentesis, TIPS, and liver transplant are more satisfactory. Portovenous shunts, with either a pressure-activated or a patient-activated pumping valve, were introduced in the 1970s

and proved to be effective in the short term, but have largely been abandoned because of complications. Occlusion occurs in over half by 6 months, disseminated intravascular coagulation is triggered by reinfusion of ascites, and infection is a significant risk in this susceptible population.<sup>66</sup> Patients with complications from their intractable ascites, such as leakage at an umbilical hernia, are best managed with repeated paracentesis and/or TIPS.

The surgeon's role in treating patients with ascites is now limited to liver transplant which is the best therapy for patients with intractable ascites. The issue is candidacy for and availability of transplant.

## PULMONARY SYNDROMES IN LIVER DISEASE

Lung dysfunction has been recognized in some patients with liver disease and portal hypertension for more than a century, but it is only in the last two decades that two distinct pulmonary vascular disorders have been better understood.<sup>67,68</sup> Hepatopulmonary syndrome (HPS) occurs when there is a pulmonary vascular vasodilation and hypoxemia, whereas portopulmonary hypertension (PPH) occurs when there is pulmonary vasoconstriction and increased pulmonary artery pressure. The major features of these two syndromes are summarized in Table 47-2.

The comparative contributions of liver dysfunction and portal hypertension vary with these syndromes. HPS can occur without severe portal hypertension and has also been recognized in some patients with prehepatic and postsinusoidal blocks. PPH can occur when the degree of liver dysfunction is relatively minor in the presence of established portal hypertension.

Shortness of breath is the most common presentation for either HPS or PPH.<sup>69–72</sup> Increased dyspnea on standing, cyanosis, and finger clubbing are often present with HPS and should lead to evaluation for this syndrome in patients with cirrhosis. Although patients with PPH may present with dyspnea, they are more likely to be asymptomatic. It is important to differentiate these pulmonary syndromes because treatment is different.

 **TABLE 47-2: PULMONARY SYNDROMES IN LIVER DISEASE**

Variables	Hepatopulmonary Syndrome	Portopulmonary Hypertension
Prevalence	8–20% of cirrhosis	3–12% of cirrhosis
Pulmonary vascular changes	Vasodilation	Vasoconstriction
Contributing factors	Liver dysfunction, portal hypertension	Portal hypertension
Place of transplant	Curative	Contraindicated

In HPS, diagnosis is made on patients hypoxemic on room air ( $PO_2 < 70$  mm Hg) by a bubble-contrast echocardiogram.<sup>73</sup> If this is positive as judged by delayed visualization of intravenously administered microbubbles in the left cardiac chamber, the patient has HPS. Patients with HPS require oxygen therapy, but the only effective treatment for HPS is liver transplant.

The diagnosis of PPH requires documentation of elevated pulmonary arterial pressures.<sup>74</sup> Echocardiography is used for screening for elevated right heart pressure,<sup>75</sup> but when the estimate is equal to or greater than 40 mm Hg, direct pulmonary artery pressure measurements should be made with right heart catheterization. A mean pulmonary artery pressure of greater than 25 mm Hg with a capillary wedge pressure of less than 15 mm Hg confirms a diagnosis of pulmonary arterial hypertension. Mild degrees of pulmonary arterial hypertension up to 35 mm Hg do not preclude liver transplantation in otherwise acceptable candidates, but pressures greater than 35 mm Hg require aggressive evaluation and treatment. Pulmonary artery pressures greater than 50 mm Hg are an absolute contraindication to liver transplantation.<sup>76</sup> Patients with pulmonary artery pressure greater than 35 mm Hg should receive pharmacologic therapy, with reassessment after 3 months.<sup>77</sup> Response to this treatment may make such patients candidates for liver transplantation.

## THE MULTIDISCIPLINARY TEAM

The content of this chapter has involved many specialists to take care of the complications of portal hypertension, including the following:

*Hepatologists* are in the front line for diagnosing and directing the management for many of the clinical presentations.

*Endoscopists* play an important role diagnostically and in primary therapy for managing variceal bleeding. Endoscopic banding requires significant expertise.

*Radiologists*, both imaging and interventional, play roles in diagnosis, directed biopsy, and procedural (TIPS) management of these patients.

*Surgeons* play a major role in liver transplant but may also have a role in shunting good-risk patients with refractory variceal bleeding.

*Pathologists* with an interest in liver pathology are important in the accurate diagnosis and staging of disease severity.

*Critical care physicians and anesthesiologists* are vital team members when patients with portal hypertension have acute events and in their perioperative management. The different pathophysiology of portal hypertension can be challenging in the ICU and operating room.

*Nephrologists, cardiologists, and pulmonologists* all play a role in the management of some of these patients, and in major centers it is important to have members of all these specialties in the team who understand the pathophysiologic changes of portal hypertension.

Finally, who coordinates? In a complex multidisciplinary team such as described, it is frequently the nurse clinicians or

coordinators who help bring these specialists together. Undoubtedly the coordinators are the ones to whom the patients turn for help in navigating their way through management in this complex field.

## REFERENCES

1. Reuben A, Groszmann RJ. Portal hypertension: a history. In: Sanyal AJ, Shah VH, eds. *Portal Hypertension: Pathobiology, evaluation, and treatment*. Torowa, NJ: Humana Press; 2005:3–14.
2. Donovan AJ, Covey PC. Early history of the portacaval shunt in humans. *Surg Gyn Obstet*. 1978;147:423–430.
3. Whipple AO. The problem of portal hypertension in relation to the hepatosplenopathies. *Ann Surg*. 1945;122:449–456.
4. Drapanas T. Interposition mesocaval shunt for treatment of portal hypertension. *Ann Surg*. 1972;176:435–448.
5. Warren WD, Zeppa R, Fomon JJ. Selective trans-splenic decompression of gastroesophageal varices by distal splenorenal shunt. *Ann Surg*. 1967;166:437–455.
6. Inokuchi K. A selective portacaval shunt. *Lancet*. 1968;ii:51–52.
7. Sarfeh IJ, Rypins EB, Mason GR. A systematic appraisal of portocaval H-graft diameters. Clinical and hemodynamic perspectives. *Ann Surg*. 1986;204:356–363.
8. Johnston GW, Rogers HW. A review of 15 years experience in the use of sclerotherapy in the control of acute hemorrhage from esophageal varices. *Br J Surg*. 1973;60:797.
9. Terblanche J, Northover JMA, Bornmann PC et al. A prospective controlled trial of sclerotherapy in the long term management of patients after esophageal variceal bleeding. *Surg Gynecol Obstet*. 1979;148:323–333.
10. Paquet KJ, Oberhammerk E. Sclerotherapy of bleeding esophageal varices by means of endoscopy. *Endoscopy*. 1978;10:7–12.
11. Steigmann GV, Goff JS, Sunn JH, et al. Endoscopic variceal ligation: an alternative to sclerotherapy. *Gastrointest Endoscopy*. 1989;35:431–434.
12. Lebric D, Novel O, Corbic M, et al. Propranolol: a medical treatment for portal hypertension? *Lancet*. 1980;2:180–182.
13. Rösch J, Hanafee W, Snow H, et al. Transjugular intrahepatic portacaval shunt. An experimental work. *Am J Surg*. 1971;121:588–592.
14. Starzl TE, Groth CG, Brettschneider L, et al. Orthotopic homotransplantation of the human liver. *Ann Surg*. 1968;168:392–415.
15. Calne RY, Williams R. Liver transplantation in man. Observations on techniques and organization in 5 cases. *Br Med J*. 1968;4:535–550.
16. Bosch J, Pizcueta P, Fen F, et al. Pathophysiology of portal hypertension. *Gastroenterol Clin North Am*. 1992;21:1–14.
17. Groszmann RJ. Hyperdynamic circulation of liver disease forty years later: pathophysiology and clinical consequences. *Hepatology*. 1994;20:1359–1363.
18. Benhamou JP, Valla D. Intrahepatic portal hypertension. In: Bircher J, Benhamou JP, McIntyre N, Rizzatto M, Rodes J, eds. *Clinical Hepatology*. Oxford, UK: Oxford Univ Press; 1999:661–669.
19. Pugh RN, Murray-Lyon IM, Dawson JL, et al. Transection of the esophagus for bleeding esophageal variceal. *Br J Surg*. 1973;60:646–649.
20. Kamath PS, Wiesner RH, Malinchoc M, et al. A model to predict survival in patients with end-stage liver disease. *Hepatology*. 2001;33:464–470.
21. Burns P, Taylor K, Biel AT. Doppler flowmetry and portal hypertension. *Gastroenterology*. 1987;92:824–826.
22. Oliver TW, Sones PH. Hepatic angiography: portal hypertension. In: Bernardino ME, Sones PH, eds. *Hepatic Radiology*. New York, NY: Macmillan; 1984:243–275.
23. Bolondi L, Gatta A, Groszmann RJ, et al. Imaging techniques and hemodynamic measurements in portal hypertension. Baveno II consensus statement. In: DeFrancis R, ed. *Baveno II Consensus Workshop*. Oxford, UK: Blackwell Science; 1996:67.
24. Groszmann RJ, Wangcharatrawee S. The hepatic venous pressure gradient: anything worth doing should be done right. *Hepatology*. 2004;39:280–282.
25. Beppu K, Mokuchi K, Kayanagi N, et al. Prediction of variceal hemorrhage by esophageal endoscopy. *Gastrointest Endoscopy*. 1981;27:213–218.
26. The North Italian Endoscopic Club for the Study and Treatment of Esophageal Varices. Prediction of the first variceal hemorrhage in patients with cirrhosis of the liver and esophageal varices. *N Engl J Med*. 1988;319:983–989.

27. Stewart C, Sanyal A. Grading portal gastropathy: a validation of a gastropathy scoring system. *Am J Gastroenterol.* 2003;98:1758–1765.
28. Hashizume M, Kitano S, Yamaga H, et al. Endoscopic classification and natural history of gastric varices: a long-term follow-up study in 568 portal hypertension patients. *Hepatology.* 1992;16:1343–1349.
29. D'Amico G, Pagliano L, Bosch J. Pharmacologic treatment of portal hypertension: an evidence based approach. *Semin Liver Dis.* 1999;19:475–505.
30. D'Amico G, Criscuoli V, Fili D, Pagliano L. Meta-analysis of trials for variceal bleeding. *Hepatology.* 2002;36:1023–1024.
31. Laine L, Cook D. Endoscopic ligation compared with sclerotherapy for treatment of esophageal variceal bleeding. *Ann Int Med.* 1995;123:280–287.
32. Orloff MJ, Orloff MS, Orloff SL, et al. Three decades of experience with emergency portacaval shunt for acutely bleeding esophageal varices in 400 unselected patients with cirrhosis of the liver. *J Am Coll Surg.* 1995;180:257–272.
33. Stipa S, Balducci G, Ziparo V, et al. Total shunting and elective management of variceal bleeding. *World J Surg.* 1994;18:200–204.
34. Henderson JM, Warren WD, Millikan WJ Jr, et al. Surgical options, hematologic evaluation, and pathologic changes in Budd-Chiari syndrome. *Am J Surg.* 1990;159:41–48; discussion 48–50.
35. Collins CJ, Ong MJ, Rypins EB, et al. Partial portacaval shunt for variceal hemorrhage: longitudinal analysis of effectiveness. *Arch Surg.* 1986;204:356–363.
36. Rosemurgy AS, Serofini FM, Zweibal BR, et al. TIPS versus small diameter prosthetic H-graft portacaval shunt: extended follow-up of an expanded randomized prospective trial. *J Gastrointest Surg.* 2000;4:589–597.
37. Spina GP, Henderson JM, Rikkers LF, et al. Distal spleno-renal shunts versus endoscopic sclerotherapy in the prevention of variceal rebleeding. A meta-analysis of 4 randomized clinical trials. *J Hepatol.* 1992;16:338–345.
38. Henderson JM, Nagle A, Curtas S, et al. Surgical shunts and TIPS for variceal decompression in the 1990's. *Surgery.* 2000;128:540–547.
39. Jenkins RL, Gedaly R, Pomposelli JJ, et al. Distal spleno-renal shunt: role, indications, and utility in the era of liver transplantation. *Arch Surg.* 1999;134:416–420.
40. Orozco H, Mercado MA, Garcia JG, et al. Selective shunts for portal hypertension current role of a 21 year experience. *Liver Transplant Surg.* 1997;3:475–480.
41. Rikkers LF, Jin G, Langnas AN, et al. Shunt surgery during the era of liver transplantation. *Ann Surg.* 1997;226:51–57.
42. Boyer TD, Haskal ZJ. The role of transjugular intrahepatic portosystemic shunt in the management of portal hypertension. *Hepatology.* 2005;41:386–400.
43. Papatheodoridis GV, Goulis J, Leandro G, et al. Transjugular intrahepatic portosystemic shunt compared with endoscopic treatment for prevention of variceal rebleeding: a meta-analysis. *Hepatology.* 1999;30:612–622.
44. Burroughs AK, Vangoli M. Transjugular intrahepatic portosystemic shunt versus endoscopic therapy: randomized trials for secondary prophylaxis of variceal bleeding. An updated meta-analysis. *Scand J Gastroenterol.* 2002;37:249–252.
45. Bureau C, Garcia-Pagan JC, Ota P, et al. Improved clinical outcome using polytetrafluoroethylene-coated stents for TIPS: results of a randomized study. *Gastroenterology.* 2004;126:469–475.
46. Sugiura M, Futagawa S. Esophageal transaction with paraesophagogastric devascularizations (the Sugiura procedure) in the treatment of esophageal varices. *World J Surg.* 1984;8:673–679.
47. Idezuki Y, Kokudo N, Sanjo K, et al. Sugiura procedure for management of variceal bleeding in Japan. *World J Surg.* 1994;18:216–221.
48. Dagenais M, Langer B, Taylor BR, et al. Experience with radical esophago-gastric devascularization procedures (Sugiura) for variceal bleeding outside Japan. *World J Surg.* 1994;18:222–228.
49. Orozco H, Mercado MA, Takahashi T, et al. Elective treatment of bleeding varices with the Sugiura operation over 10 years. *Am J Surg.* 1992;13:585–589.
50. Henderson JM. Liver transplantation for portal hypertension. *Gastroenterol Clin North Am.* 1992;21:197.
51. Ringe B, Lang H, Tusch G, et al. role of liver transplantation in management of esophageal variceal hemorrhage. *World J Surg.* 1994;18:233.
52. Abu-Elmagd K, Iwatsuki S. Portal hypertension: role of liver transplantation. In: Cameron J, ed. *Current Surgical Therapy*, 7th ed. St. Louis, MO: Mosby; 2001:406–413.
53. Imperiale TF, Chalasani N. A meta-analysis of endoscopic variceal ligation for primary prophylaxis of esophageal variceal bleeding. *Hepatology.* 2001;33:802–807.
54. Chalasani N, Kahi C, Francois F, et al. Improved patient survival after acute variceal bleeding: a multi-center, cohort study. *Am J Gastroenterol.* 2003;98:653–659.
55. Banarus R, Albillos A, Rincon D, et al. Endoscopic treatment versus endoscopic plus pharmacologic treatment for acute variceal bleeding: a meta-analysis. *Hepatology.* 2002;35:609–615.
56. Zoli M, Merkel C, Magalotti D, et al. Natural history of cirrhotic patients with small esophageal varices: a prospective study. *Am J Gastroenterol.* 2000;95:503–508.
57. Defranchis R. Evaluation and follow-up of patients with cirrhosis and esophageal varices. *J Hepatol.* 2003;38:361–363.
58. Henderson JM, Boyer TD, Kutner MH, the DIVERT Study Group. Distal splenorenal shunt versus transjugular intrahepatic portal systemic shunt for variceal bleeding: a randomized trial. *Gastroenterology.* 2006;130:1643–1651.
59. Boyer TD, Henderson JM, Heerey AM, et al. Cost of preventing variceal rebleeding with transjugular intrahepatic portal systemic shunt and distal splenorenal shunt. *J Hepatology.* 2008;48:407–414.
60. Bureau C, Garcia-Pagan JC, Ota P, et al. Improved clinical outcome using polytetrafluoroethylene-coated stents for TIPS: results of a randomized study. *Gastroenterology.* 2004;126:469–475.
61. Moore KP, Wang F, Gines P, et al. The management of ascites: report on the consensus conference of the International Ascites Club. *Hepatology.* 2003;38:258–266.
62. Lebrech D, Giuly N, Hadenque A, et al. Transjugular intrahepatic portosystemic shunt: comparison with paracentesis in patients with cirrhosis and refractory ascites. A randomized trial. *J Hepatol.* 1996;25:135–144.
63. Rossle M, Oclis A, Gulberg V, et al. A comparison of paracentesis and transjugular intrahepatic portosystemic shunting in patients with ascites. *N Engl J Med.* 2000;342:1701–1707.
64. Sanyal A, Gennings G, Reddy KR, et al. A randomized controlled study of TIPS versus larger volume paracentesis in the treatment of refractory ascites. *Gastroenterology.* 2003;124:634–643.
65. Gines P, Uriz J, Calahorra B, et al. TIPS versus repeated paracentesis plus intravenous albumin for refractory ascites in cirrhosis: a randomized trial. *Gastroenterology.* 2002;123:1839–1847.
66. Gines P, Arroyo V, Vargas V, et al. Paracentesis with intravenous infusion of albumin as compared with peritoneovenous shunting in cirrhosis with refractory ascites. *N Engl J Med.* 1991;325:829–834.
67. Fallon MB, Abrams GA. Pulmonary dysfunction in chronic liver disease. *Hepatology.* 2000;32:859–865.
68. Krowka MJ. Hepatopulmonary syndromes. *Gut.* 2000;40:1–4.
69. Swanson KL, Krowka MJ. Pulmonary complications associated with portal hypertension. In: Sanyal AJ, Shah VH, eds. *Portal Hypertension*. Totowa, NJ: Humana Press; 2005:455–468.
70. Moller S, Hillingso J, Christensen E, et al. Arterial hypoxemia in cirrhosis: fact or fiction? *Gut.* 1998;42:868–874.
71. Vachieri F, Moreau R, Hadengue A, et al. Hypoxemia in patients with cirrhosis: relationship with liver failure and hemodynamic alterations. *J Hepatol.* 1997;27:492–495.
72. Krowka MJ, Dickson E, Cortese D. Hepatopulmonary syndrome: clinical observations and lack of therapeutic response to somatostatin analogue. *Chest.* 1993;104:515–521.
73. Abrams GA, Nanda NC, Dubrovsky EV, et al. Use of macroaggregated albumin lung perfusion scan to diagnose hepatopulmonary syndrome: a new approach. *Gastroenterology.* 1998;114:305–310.
74. Castro M, Krowka MJ, Schroeder DR, et al. Frequency and clinical complications of increased pulmonary artery pressures in liver transplantation. *Mayo Clin Proc.* 1996;71:543–551.
75. Kim WR, Krowka MJ, Plevak DJ, et al. Accuracy of Doppler echocardiography in the assessment of pulmonary hypertension in liver transplant candidates. *Liver Transpl.* 2000;6:453–458.
76. Krowka MJ, Plevak DJ, Findlay JY, et al. Pulmonary hemodynamics and perioperative cardiopulmonary-related mortality in patients with portopulmonary hypertension undergoing liver transplantation. *Liver Transpl.* 2000;6:443–450.
77. Krowka MJ, Frantz RP, McGoon MD, et al. Improvement in pulmonary hemodynamics during intravenous epoprostenol (prostacyclin): study of 15 patients with moderate to severe portopulmonary hypertension. *Hepatology.* 1999;30:641–648.





# GALLBLADDER AND BILE DUCTS

*This page intentionally left blank*

# CHOLECYSTITIS AND CHOLELITHIASIS

Edward D. Auyang • Nathaniel J. Soper

## HISTORY AND BACKGROUND

Cholecystectomy is one of the most common surgical procedures performed in the United States with over 600,000 procedures performed each year. Open cholecystectomy, first performed by Carl Langenbuch in 1882, has been the primary treatment of gallbladder disease through the early 1990s.<sup>1</sup> In 1985, the first endoscopic cholecystectomy was performed by Erich Mühe of Böblingen, Germany. Shortly thereafter, pioneers in France and the United States coupled a CCD video camera with a laparoscope to allow the entire surgical team to view the operative field and performed cholecystectomies with laparoscopic equipment. Since then, laparoscopic cholecystectomy has been adopted around the world, and subsequently been recognized as the gold standard for the treatment of gallstone disease.<sup>2-5</sup> In 1992, the National Institutes of Health (NIH) Consensus Development Conference stated that laparoscopic cholecystectomy provides a safe and effective treatment for most patients with symptomatic gallstones.<sup>6</sup> Currently it is estimated that over 80% of cholecystectomies are performed using the laparoscopic approach.

The advantages of laparoscopic over open cholecystectomy have been well documented. These advantages include earlier return of bowel function, less postoperative pain, improved cosmesis, shorter length of hospital stay, earlier return to full activity, and decreased overall cost.<sup>7-11</sup> There has been an increase in the rate of cholecystectomies subsequent to the introduction of laparoscopic cholecystectomy accompanied by evidence of lower clinical thresholds for operative therapy of gallbladder disease.<sup>12-14</sup>

## INDICATIONS FOR CHOLECYSTECTOMY

There are multiple indications for cholecystectomy with the most common being symptomatic cholelithiasis (Table 48-1). The diagnosis of symptomatic cholelithiasis is made by radiographic documentation of gallstones, usually using abdominal ultrasound, with the presence of symptoms attributable

to a diseased gallbladder. Biliary colic is typically a severe and episodic right upper abdominal or epigastric pain that can radiate to the back. Attacks frequently occur postprandially or awaken the patient from sleep. Often times the postprandial pain will be associated with meals that are high in fat content. Once a patient begins to experience symptoms, there is a greater than 80% chance that he or she will continue to have symptoms in the future or develop a complication. These complications may result from obstruction of the gallbladder outlet, causing acute cholecystitis, or migration of a stone into the common bile duct, causing cholangitis or pancreatitis.

Patients with asymptomatic gallstones have less than 20% chance of ever-developing symptoms, and the risks associated with prophylactic operation outweigh the potential benefit of surgery in most patients.<sup>15,16</sup> Prophylactic cholecystectomy for asymptomatic cholelithiasis can be justified in certain circumstances, such as in patients with sickle cell disease, those undergoing open bariatric surgery, requiring long-term total parental nutrition, or patients who are therapeutically immunosuppressed after solid organ transplantation. Patients with sickle cell disease often have hepatic or vaso-occlusive crises that can be difficult to differentiate from acute cholecystitis.<sup>17</sup> In patients following bariatric surgery, the development of gallstones is markedly increased during the period of rapid weight loss to an incidence of about 30%.<sup>18,19</sup> Removing the gallbladder at the time of bariatric surgery can abolish gallstone-related morbidity relatively easily. This approach has been adopted by many bariatric surgeons during open bariatric procedures, but not during laparoscopic bariatric surgery, because the potential morbidity of an added laparoscopic cholecystectomy in the patient with morbid obesity appears greater than the potential later risk of cholelithiasis-related complications.<sup>20-22</sup> In transplant patients, there is concern that immunosuppression may mask the signs and symptoms of inflammation until overwhelming infection has occurred.<sup>23</sup> Recommendations in the literature range from mandatory screening and treatment of biliary disease before transplantation, to prophylactic cholecystectomy 6 months post-transplantation, to expectant management of all asymptomatic patients.<sup>24-27</sup> Other possible



**TABLE 48-1: INDICATIONS FOR LAPAROSCOPIC CHOLECYSTECTOMY**

Symptomatic cholelithiasis
Biliary colic
Acute cholecystitis
Choledocholithiasis
Gallstone pancreatitis
Cholangitis or obstructive jaundice
Asymptomatic cholelithiasis
Sickle cell disease
Total parenteral nutrition
Chronic immunosuppression
No immediate access to health care facilities (eg, missionaries, military personnel, peace corps workers, relief workers)
Incidental cholecystectomy for patients undergoing procedure for other indications
Acalculous cholecystitis
Gallbladder dyskinesia
Gallbladder polyps >10 mm in diameter
Porcelain gallbladder

indications for prophylactic laparoscopic cholecystectomy include individuals who may not have access to modern health care facilities for an extended time period, such as missionaries and military personnel, and patients who are already undergoing an abdominal operation for other reasons. Prophylactic cholecystectomy has been occasionally advocated in diabetics. There is no evidence to support this policy, but good evidence to support a strategy of early cholecystectomy in the symptomatic patient. Diabetics tend to present with acute cholecystitis more frequently once they become symptomatic, and withstand complications less well.

Individuals without gallstones but with typical biliary symptoms, that is, acalculous cholecystitis or gallbladder dyskinesia (GBD), may also be considered for the procedure.<sup>10</sup> GBD is often a diagnosis of exclusion. The Rome Committee, established in 1994, set three criteria to confirm GBD: (1) absence of gallbladder stones, sludge or microlithiasis, (2) abnormal ejection fraction (EF) less than 40% on hepatobiliary iminodiacetic acid (HIDA) scan after 30 minutes of continuous cholecystokinin (CCK) infusion, and (3) positive response without pain for 12 months after cholecystectomy.<sup>28</sup>

Other indications for cholecystectomy include gallbladder polyps and porcelain gallbladder. Gallbladder polyps are typically an incidental finding that affects approximately 5% of the population, with a higher percentage in Asian populations.<sup>29</sup> Polyps that are smaller than 10 mm in diameter have a low likelihood of malignancy and can be followed radiologically. Polyps larger than 10 mm in diameter in patients over 50 years old have a higher likelihood of being malignant and are recommended for cholecystectomy.<sup>29,30</sup> Porcelain gallbladder has an associated risk of gallbladder cancer. Earlier studies estimated the

incidence of gallbladder cancer to be between 12 and 60%, but recent studies suggest that the overall risk is lower at 7%.<sup>31</sup> Nevertheless, radiographic evidence of porcelain gallbladder warrants cholecystectomy.

## DIAGNOSTIC STUDIES

Serum laboratory tests of patients with biliary disease include total bilirubin, alkaline phosphatase, transaminases, amylase, lipase, and complete blood count (CBC). Elevations in the liver function panel may suggest biliary obstruction. Elevations in amylase and lipase may suggest pancreatitis. With simultaneous elevation of both liver and pancreatic enzymes, gallstone pancreatitis must be ruled out.

In a patient with typical biliary colic, the only diagnostic imaging study necessary prior to laparoscopic cholecystectomy is an abdominal ultrasound revealing gallstones. Ultrasound demonstrates the size and number of stones, the thickness of the gallbladder wall, the presence or absence of pericholecystic fluid, the diameter of the common bile duct (CBD), and other components of the biliary ductal system. Other nonbiliary disorders such as hepatic lesions or steatosis, masses in the pancreas, or renal tumors may also be diagnosed. When ultrasound is negative despite typical biliary symptoms, CCK-stimulated HIDA scan demonstrating a low gallbladder EF with or without pain reproduction suggests gallbladder dyskinesia.<sup>28</sup> If a patient with gallstones has atypical symptoms, however, a more extensive work-up including upper gastrointestinal contrast radiography or endoscopy, computerized tomography, or cardiac and pulmonary evaluation may be appropriate to rule out significant nonbiliary disease processes.

## CONTRAINDICATIONS TO LAPAROSCOPIC CHOLECYSTECTOMY

The number of absolute and relative contraindications to performing laparoscopic cholecystectomy has decreased over the past 20 years as minimally invasive surgical instrumentation and skills have improved (Table 48-2). Absolute contraindications include the inability to tolerate general anesthesia or laparotomy, refractory coagulopathy, diffuse peritonitis with hemodynamic compromise, cholangitis, and potentially curable gallbladder cancer. Diffuse peritonitis with hemodynamic compromise represents a surgical emergency in which attempted laparoscopic cholecystectomy is not prudent, because the etiology is not clear or secure, and the pneumoperitoneum may lead to vascular collapse. Standard open laparotomy allows rapid determination of the etiology and more expeditious management of the disorder. Suspicion of gallbladder malignancy mandates that standard open resection be undertaken. This is because of persistent concerns with adequacy of resection and the possibility of gallbladder perforation (occurring in 20–30% of laparoscopic cholecystectomies) with intraperitoneal dissemination of cancer.


**TABLE 48-2: CONTRAINDICATIONS TO LAPAROSCOPIC CHOLECYSTECTOMY**

Absolute	
Unable to tolerate general anesthesia	
Refractory coagulopathy	
Suspicion of gallbladder carcinoma	
Relative	
Previous upper abdominal surgery	
Cholangitis	
Diffuse peritonitis	
Cirrhosis and/or portal hypertension	
Chronic obstructive pulmonary disease (COPD)	
Cholecystoenteric fistula	
Morbid obesity	
Pregnancy	

Relative contraindications are dictated primarily by the surgeon's philosophy and experience. These include previous upper abdominal surgery with extensive adhesions, cirrhosis, portal hypertension, severe cardiopulmonary disease, morbid obesity, and pregnancy. In most patients, little is lost by initiating a laparoscopic cholecystectomy with conversion to laparotomy if the laparoscopic approach is deemed too risky.

Pregnancy is a controversial relative contraindication to laparoscopic cholecystectomy because of the unknown effects of prolonged CO<sub>2</sub> pneumoperitoneum on the fetus. Laparoscopic cholecystectomy can be performed safely during pregnancy, but only with great care.<sup>29</sup> We limit this intervention to the second trimester of gestation after organogenesis is complete and prior to the uterine fundus reaching a size and height that encroaches on the operative field. Open insertion of the initial port or alternative location of the initial port in the right upper quadrant should be used to avoid injury to the gravid uterus, and the insufflation pressure should be limited to less than 12 mm Hg to avoid respiratory embarrassment and decreased vena caval return. Also, maternal hyperventilation with close monitoring of end-tidal CO<sub>2</sub> should be undertaken to prevent fetal acidosis. When visualization of the biliary tree is required, laparoscopic ultrasound is used in place of cholangiography in order to limit fetal radiation exposure. And finally, perioperative consultation with an experienced obstetrician is advisable, as is perioperative fetal heart monitoring.

Early experience suggested that acute cholecystitis was a relative contraindication to performing laparoscopic cholecystectomy. A number of recent reports indicate that laparoscopic cholecystectomy indeed can be done safely for patients with acute inflammation of the gallbladder, but should be performed in this setting only by experienced laparoscopic surgeons. There is clearly a higher rate of conversion in the setting of acute cholecystitis. In particular, after 72 hours the rate of conversion increases significantly. One should not hesitate to convert to an open cholecystectomy if significant adhesions or

inflammation are identified during laparoscopy. The timing of cholecystectomy for acute cholecystitis has been a long-standing matter of debate. Based on several prospective studies, early surgical intervention has economic, social, and medical benefits and therefore is the preferred approach for experienced laparoscopic surgeons in the management of acute cholecystitis.<sup>32–36</sup> Our practice is to proceed with laparoscopic cholecystectomy immediately after the diagnosis of acute cholecystitis has been made. In patients who present after 72 hours of symptoms, a laparoscopic cholecystectomy is attempted only if the patient has no pre-existing medical conditions which preclude an open cholecystectomy. If the patient does have significant comorbid illnesses, we continue with antibiotic therapy and possibly a percutaneous cholecystostomy tube and subsequent elective laparoscopic cholecystectomy 6–8 weeks later. Surgeons must be comfortable in their ability to safely perform the procedure laparoscopically; significant concerns based on laparoscopic findings should prompt conversion to open cholecystectomy. Despite the advent of minimally invasive technology, open cholecystectomy continues to be an acceptable method for removal of the gallbladder under any circumstances and should certainly be considered if proper facilities for performance of laparoscopic surgery are not available or if the surgeon is not adequately trained in this technology.

In addition to relative contraindications, there are situations when cholecystectomy, whether laparoscopic or open, should be avoided completely in favor of percutaneous cholecystostomy. Patients in which cholecystostomy should be used include patients who have absolute contraindications to surgery. These include patients with significant respiratory failure resulting in inability to tolerate general anesthesia and those who have had recent exacerbation of a significant comorbid illness such as myocardial infarction (MI).

## OPERATIVE TECHNIQUE

### Anatomy

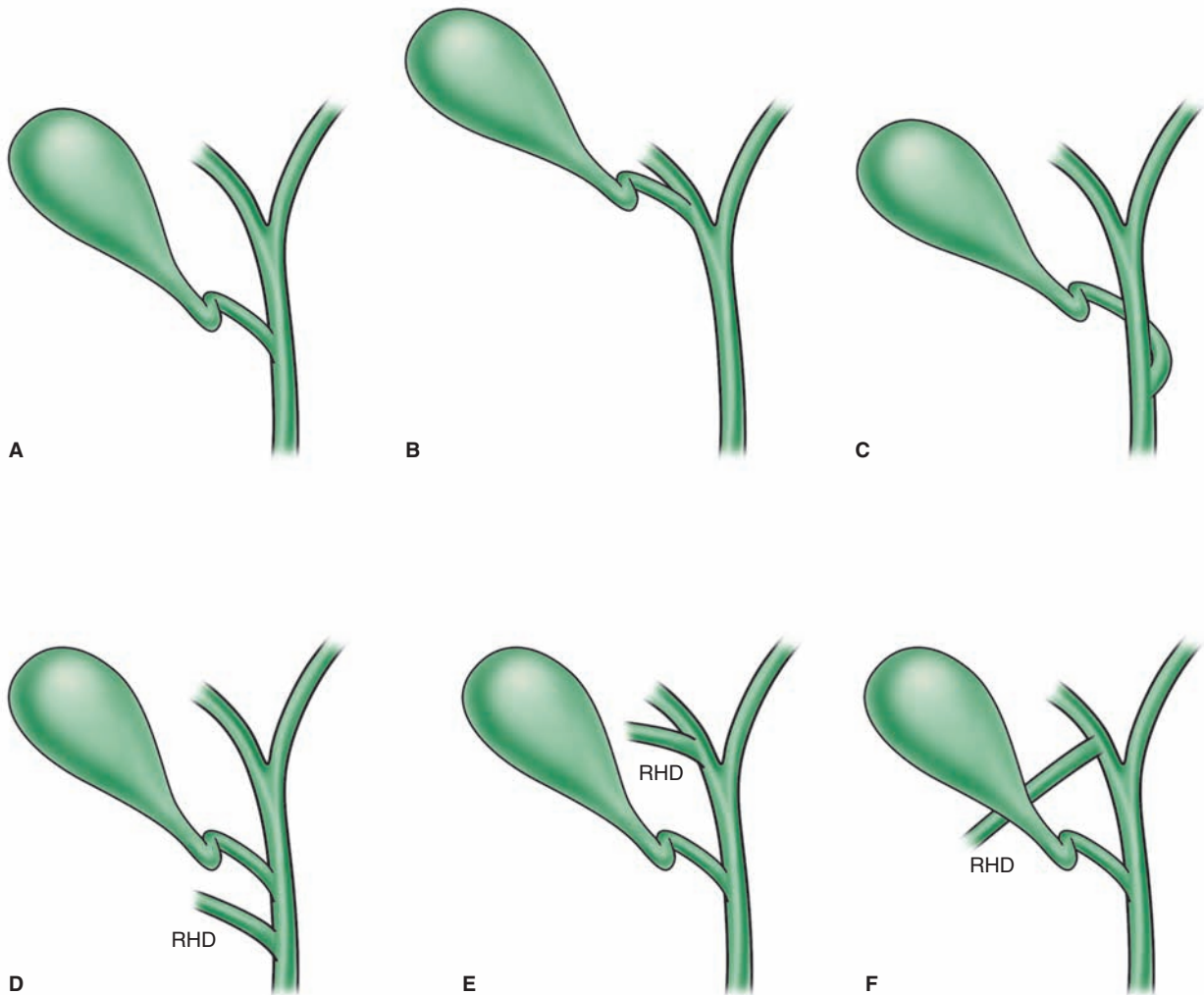
The classic anatomy of the biliary tree is present in only 30% of individuals, so it may be said that anomalies are the rule, not the exception. As with any procedure, the knowledge of normal anatomy and common variants is critical to the success of surgical intervention. The cystic duct may join the CBD at an acute angle, travel parallel to the common duct for several centimeters prior to insertion, insert into the right hepatic duct, or be congenitally absent. The cystic artery usually arises from the right hepatic artery, but one must be absolutely sure that the cystic artery is visualized entering the gallbladder wall. Occasionally the right hepatic artery will loop up onto the surface of the gallbladder, and a very short cystic artery will arise. Furthermore, there can often be a posterior cystic artery, which can easily be injured if not recognized. The common bile duct begins at the junction of the cystic duct and the common hepatic duct and passes inferiorly to the ampulla of Vater. Its normal diameter is less than

6 mm, although it may be larger in elderly patients and those with biliary obstruction.

It is important to clearly identify the structures within the hepatocystic triangle, which is the ventral aspect of the area bounded by the gallbladder wall and cystic duct, the liver edge, and the common hepatic duct. Contained within the hepatocystic triangle is the eponymic Calot's triangle: The boundaries of Calot's triangle include the cystic duct, cystic artery, and the gallbladder wall. Aberrant anatomy is a well-recognized risk factor for biliary injury. An aberrant right hepatic duct (RHD) is the most common anomaly causing problems during laparoscopic cholecystectomies. The most dangerous variant is when the cystic duct joins a low-lying aberrant right sectoral duct. Injuries to these ducts are under-reported since occlusion of an aberrant duct may be asymptomatic and even unrecognized (Fig. 48-1).

## Patient Preparation

As with any abdominal operation, patients are fasted for a minimum of 8 hours prior to the operation. Patients without major comorbidities are generally scheduled as outpatient procedures. Prophylactic antibiotics are up to the surgeon's discretion; evidence suggests that most patients have a very low risk of perioperative infection.<sup>37</sup> Antiembolic stockings and sequential compression devices are placed on both legs to avoid pooling of blood in the lower extremities by the reverse Trendelenburg position generally used during this operation. Following induction of general endotracheal anesthesia, an orogastric tube may be placed to decompress the stomach. The abdomen is shaved and prepared in standard sterile fashion with particular care taken to rid the umbilicus of all debris.



**FIGURE 48-1** Biliary anatomy variations. **A.** Normal anatomy. **B.** Cystic duct insertion on right hepatic duct. **C.** Anterior or posterior spiral insertion of cystic duct. **D, E,** and **F.** Common variants of accessory right hepatic duct (RHD).



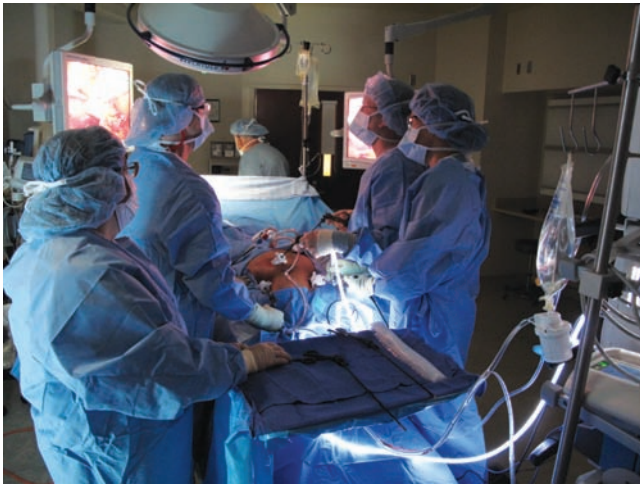

FIGURE 48-2 Operating room setup.

## Laparoscopic Cholecystectomy

### OPERATING ROOM SETUP

Most surgeons utilize two video monitors, one on each side of the operating table to facilitate visualization by both surgeon and assistant. Using the American technique, the surgeon stands to the left of the patient, the first assistant stands to the patient's right (Fig. 48-2). If a laparoscopic video camera operator is used, he stands to the left of the surgeon. In the French technique, the patient's legs are abducted and the surgeon stands between the legs.

### PNEUMOPERITONEUM

A working space, provided by a pneumoperitoneum, is essential for the surgeon to see and to operate within the abdominal cavity. CO<sub>2</sub> has the advantage of being noncombustible and rapidly absorbed from the peritoneal cavity. It may, however, lead to hypercarbia in patients with significant cardiopulmonary disease.<sup>38</sup> The most common location for initial peritoneal entry is at the midline near the umbilicus. Supraumbilical or infraumbilical incisions may be made in vertical, horizontal, or curvilinear orientations based on surgeon's preference. Pneumoperitoneum can be established by either a closed or an open technique. In the closed technique, CO<sub>2</sub> is insufflated into the peritoneal cavity through a Veress needle, which is subsequently replaced with a laparoscopic port, placed blindly into the abdominal cavity. In the open technique, a laparoscopic port is inserted under direct vision into the peritoneal cavity via a small incision; only after ensuring definitive and safe peritoneal entry is the pneumoperitoneum established. There are advantages and disadvantages to both techniques. Surgeons performing laparoscopic cholecystectomy should learn both and use them selectively based on the patient's body habitus and previous surgical history.

### PORT PLACEMENT AND EXPOSURE

Depending on the surgeon's preference, a 5- or 10-mm laparoscope is inserted into the abdomen through the periumbilical port and the abdominal cavity is visually explored. It is generally advantageous to use an angled (30- or 45-degree) laparoscope rather than a 0-degree scope, because the angled scopes enable obtaining multiple views of the same operative field. The patient is then placed in a reverse Trendelenburg position of 30 degrees while rotating the table to the left by 15 degrees. This maneuver allows the colon and duodenum to fall away from the liver edge. The falciform ligament and both lobes of the liver are examined closely for abnormalities. The gallbladder can usually be seen protruding beyond the edge of the liver.

Two small accessory subcostal ports are then placed under direct vision. The first 5-mm trocar is placed along the right anterior axillary line between the 12th rib and the iliac crest. A second 5-mm port is inserted in the right subcostal area in the midclavicular line. Grasping forceps are placed through these two ports to secure the gallbladder. The assistant manipulates the lateral grasping forceps, which are used to grasp the fundus and elevate the liver. The fourth working port is then inserted through an incision in the midline of the epigastrium (Fig. 48-3). This trocar is usually inserted approximately 5 cm below the xiphoid process, but the precise position and angle depends on the location of the gallbladder as well as the size of the medial segment of the left lobe of the liver. Dissecting forceps are then inserted and directed toward the gallbladder neck. One should note that the orientation of the laparoscope is generally parallel to that of the cystic duct when the fundus is elevated, whereas the instruments placed through the other three ports enter the abdomen at right angles to this plane. The surgeon uses a dissecting forceps to raise a serosal fold of the most dependent portion of the fundus. The assistant's heavy grasping forceps are then locked onto this fold using either a spring or ratchet device. With these axillary grasping forceps, the fundus of the gallbladder is then pushed in a

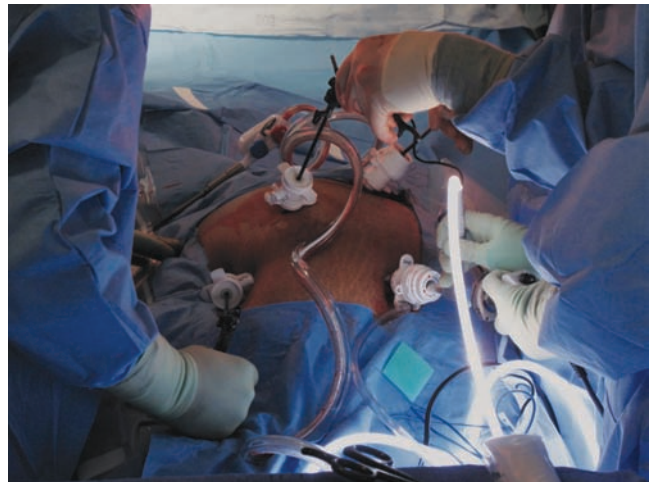


FIGURE 48-3 Port placement.

lateral and cephalad direction, rolling the entire right lobe of the liver cranially.

This maneuver is complicated in patients with a fixed, cirrhotic liver or a heavy, friable liver because of fatty infiltration. In patients with few adhesions to the gallbladder, pushing the fundus cephalad exposes the entire gallbladder, cystic duct, and porta hepatis. Most patients, however, have adhesions between the gallbladder and the omentum, hepatic flexure and/or duodenum. These adhesions are generally avascular and may be lysed bluntly by grasping them with dissecting forceps at their site of attachment to the gallbladder wall and gently *stripping* them down toward the infundibulum. Extreme caution should be taken to avoid damage to surrounding structures. Use of electrocautery may accidentally damage the unvisualized CBD or proximally located duodenum. After exposing the infundibulum, blunt grasping forceps held in the surgeon's left hand and placed through the midclavicular trocar are used to grasp and place traction on the neck of the gallbladder.

## DISSECTION

The infundibulum is grasped, placing traction on the gallbladder in a lateral direction to distract the cystic duct from the CBD (Fig. 48-4). Fine-tipped dissecting forceps (Maryland) are used to dissect away the overlying fibroareolar structures from the infundibulum of the gallbladder. The dissection should begin from a known structure, for example, the gallbladder, rather than in an unknown area, to avoid damage to the underlying structures such as a bile duct or hepatic artery. The dissection initially commences 4 or 5 cm proximal to the neck of the gallbladder and proceeds distally, such that a modified "top-down" technique is employed. The objective of the initial dissection is to free the gallbladder from its bed such that there is a window beneath it through which the liver substance can be seen. The hepatocystic triangle is maximally opened and converted

into a trapezoid shape by retracting the infundibulum of the gallbladder inferiorly and laterally while maintaining the fundus under traction in a superior and medial direction. A lymph node usually lies on the surface of the cystic artery, and occasionally it is necessary to use a brief application of low-wattage electrocautery to obtain hemostasis as the lymph node is bluntly swept away. To expose the reverse of Calot's triangle, the infundibulum of the gallbladder is pulled in a superior and medial direction. The use of an angled laparoscope facilitates viewing both sides of the hepatocystic triangle when used in combination with these retraction techniques. After clearing the structures from the apex of the triangle, the junction between the infundibulum and the origin of the proximal cystic duct can be tentatively identified. The strands of peritoneal, lymphatic, and neurovascular tissue are stripped away from the cystic duct to clear a segment from the surrounding tissue. Curved dissecting forceps are helpful in creating a window around the posterior aspect of the cystic duct to skeletonize the duct itself. Alternatively, the tip of the hook cautery can be used to encircle and expose the duct. It is generally unnecessary and potentially harmful to dissect the cystic duct down to its junction with the CBD. The cystic artery is separated from the surrounding tissue by similar blunt dissection at this time. If the cystic artery crosses anterior to the duct, the artery may require dissection and division prior to approaching the cystic duct. The neck of the gallbladder is thus dissected away from its liver bed, leaving a large window at its base through which the liver parenchyma is visualized. There should be two, and only two, structures (the cystic duct and artery) crossing this window—this is the "critical view of safety," which should be demonstrated prior to clipping or cutting any tubular structures.<sup>38</sup> To reiterate, no structure should be divided until the cystic duct and cystic artery are unequivocally identified. Developing this critical view of safety is an essential step to minimize the chance of bile duct injury during laparoscopic cholecystectomy (Fig. 48-5).<sup>38</sup>

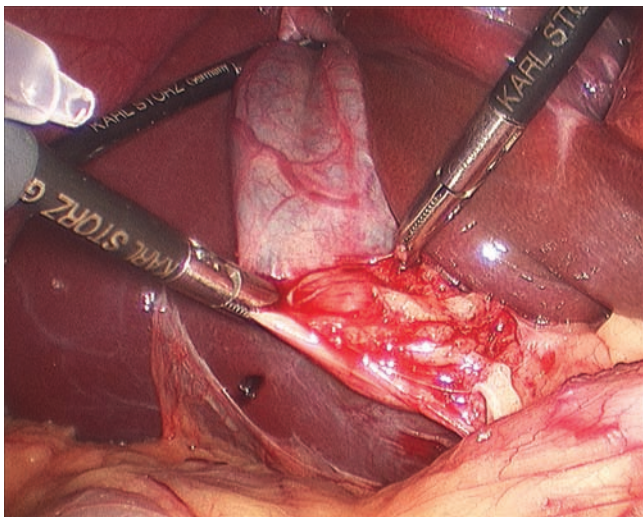


FIGURE 48-4 Retraction of the gallbladder.

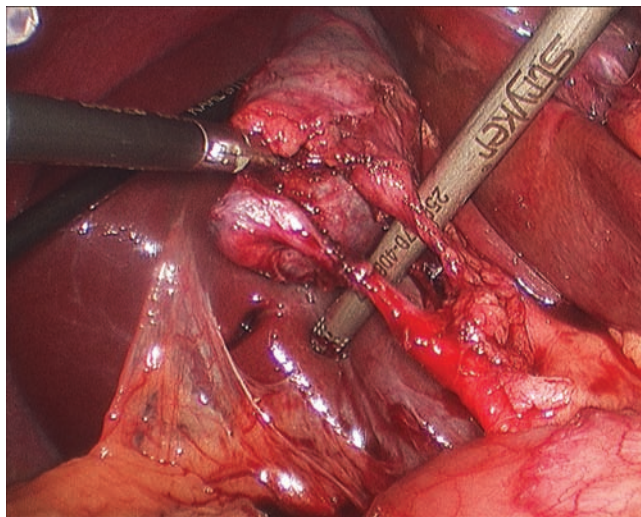


FIGURE 48-5 Critical view of safety.



## INTRAOPERATIVE EVALUATION FOR CHOLEDOCHOLITHIASIS

After initially dissecting the proximal cystic duct, the CBD should be imaged if there is any concern for choledocholithiasis or questions regarding the biliary anatomy. This can be achieved by intraoperative cholangiography (IOC) or intracorporeal laparoscopic ultrasonography (LUS). Prior to either procedure, a clip is applied high on the cystic duct at its junction with the gallbladder to prevent stones migrating down the duct during subsequent manipulation. To perform IOC, the anterolateral wall of the cystic duct is incised and dissecting forceps are used to gently compress the cystic duct systematically back toward the gallbladder, thereby milking stones away from the CBD and out of the ductotomy. A 4F or 5F catheter is inserted into the duct through a hollow, 5-mm metal tube that has an appropriate gasket to prevent carbon dioxide leakage around the catheter itself. The cholangiography catheter is inserted into the cystic duct and a clip is applied loosely to secure the catheter in place. If the introducer has grasping jaws, it can be used to secure the catheter into the duct. Alternatively, catheters equipped with balloons proximal to the tip may be used for fixation. Cholangiography can be performed by either real-time fluoroscopy (dynamic) or by obtaining two standard radiographs (static) after injecting 5 and 10 mL of water-soluble contrast medium. The films should be inspected for the following: (1) the length of cystic duct and location of its junction with the CBD, (2) the diameter of the CBD, (3) the presence of luminal filling defects within the CBD, (4) free flow of contrast into the duodenum, and (5) anatomy of the extrahepatic and intrahepatic biliary tree. After the cholangiography catheter is removed, the cystic duct is doubly clipped below the ductotomy with care to avoid the wall of the CBD, and then divided. The posterior jaw of the clip applicator must be visualized prior to applying each clip in order to avoid injuring the surrounding structures. Great care should be taken so that the CBD is not tented up into the clip. If the cystic duct is particularly large or friable, it may be preferable to replace one of the clips with a suture, either hand-tied or a preformed loop with slip knot.

Evaluation of the CBD by LUS is an alternative to cholangiography. Several studies<sup>39,40</sup> performed at open cholecystectomy reported intracorporeal ultrasonography to be more accurate than operative cholangiography in assessing the CBD for stones (97–99% vs 89–94%).<sup>41–43</sup> However, few surgeons adopted ultrasound for this purpose. Recently, LUS has been used in several centers during laparoscopic cholecystectomy and is gaining popularity.<sup>43–47</sup> With LUS, the transducer has a higher frequency with improved resolution compared to those used with transabdominal ultrasonography. In experienced hands, LUS appears to be as accurate as cholangiography for demonstrating choledocholithiasis but can be performed more rapidly.<sup>48</sup> In a recent prospective multicenter trial with 209 laparoscopic cholecystectomy patients, the time to perform LUS ( $7 \pm 3$  minutes) was significantly less than that of IOC ( $13 \pm 6$  minutes).<sup>48</sup> The study showed that LUS was more sensitive for detecting stones but that IOC was better

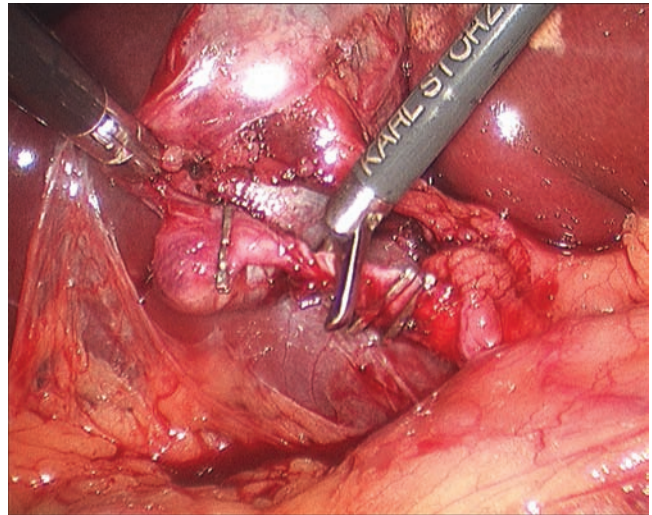


FIGURE 48-6 Clipping the cystic duct.

in delineating intrahepatic anatomy and defining anatomical anomalies of the ductal system. The authors concluded that the two methods of duct imaging were complementary. Despite these promising data, more clinical experience will be necessary to establish the appropriate role of LUS for the detection of choledocholithiasis during laparoscopic cholecystectomy.<sup>49,50</sup>

## COMPLETION OF CHOLECYSTECTOMY

The cystic duct is clipped using an endoscopic clip applicator and divided using scissors. Two clips are placed proximally on the cystic duct and one clip is placed toward the gallbladder (Fig. 48-6). For cystic ducts that are large or friable, a preformed endoloop is preferable for ligating the distal cystic duct. After the duct is divided, the cystic artery is dissected from the surrounding tissue for an adequate distance to permit placement of three clips. The surgeon must determine that the structure is indeed the cystic artery and not the right hepatic artery looping up onto the neck of the gallbladder or an accessory or replaced right hepatic artery. After an appropriate length of cystic artery has been dissected free, it is clipped proximally and distally prior to transection (Fig. 48-7). Electrocautery should not be used for this division, as the current may be transmitted to the proximal clips leading to subsequent necrosis and hemorrhage.

The ligated stumps of the cystic duct and the artery are then examined to ensure that there is no leakage of either bile or blood and that the clips are placed securely and compress the entire lumen of the structures without impinging on adjacent tissues. A suction-irrigation catheter is used to remove any debris or blood that has accumulated during the dissection. Separation of the gallbladder away from its hepatic bed is then initiated using an electrocautery probe to coagulate small vessels and lymphatics. While maintaining cephalad traction on the fundus of the gallbladder with the



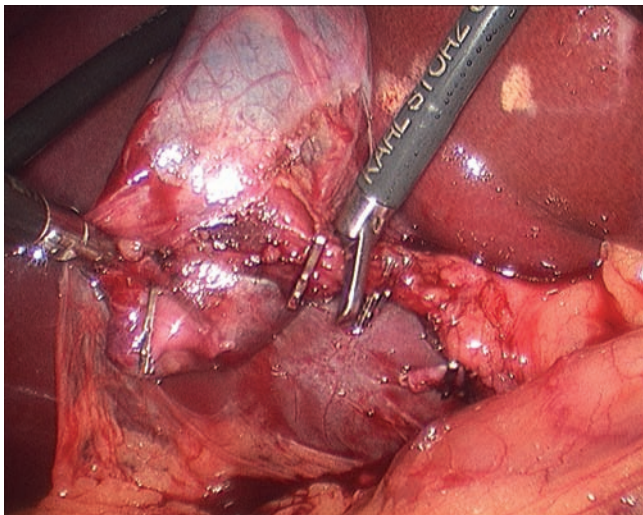


FIGURE 48-7 Clipping the cystic artery.

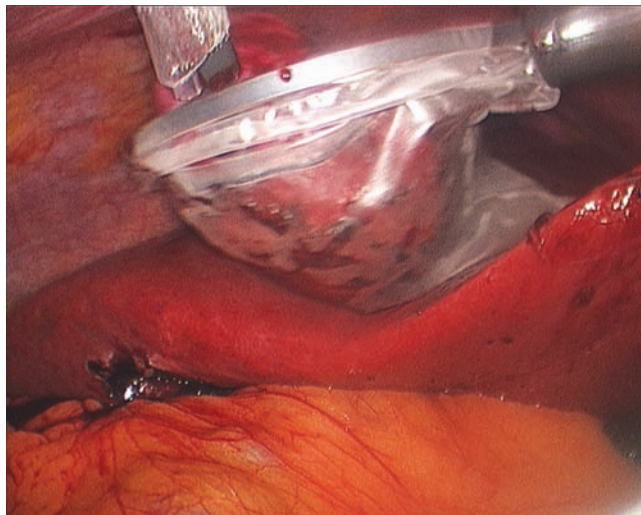


FIGURE 48-9 Placing gallbladder in entrapment bag.

axillary forceps, the midclavicular forceps pulls the neck of the gallbladder anterosuperiorly and then alternatively medially and laterally to expose and place the tissue connecting the gallbladder to its fossa under tension. An electrocautery spatula or hook is used to coagulate and divide the tissue. Intermittent blunt dissection will facilitate exposure of the proper plane (Fig. 48-8).

Dissection of the gallbladder fossa continues from the infundibulum to the fundus, progressively moving the midclavicular grasping forceps cephalad to allow maximal countertraction. The dissection proceeds until the gallbladder is attached by only a thin bridge of tissue. At this point, prior to completely detaching the gallbladder, the hepatic fossa and porta hepatis are once again inspected for hemostasis and bile leakage. Small bleeding points are coagulated and the right upper quadrant is liberally irrigated and then aspirated dry

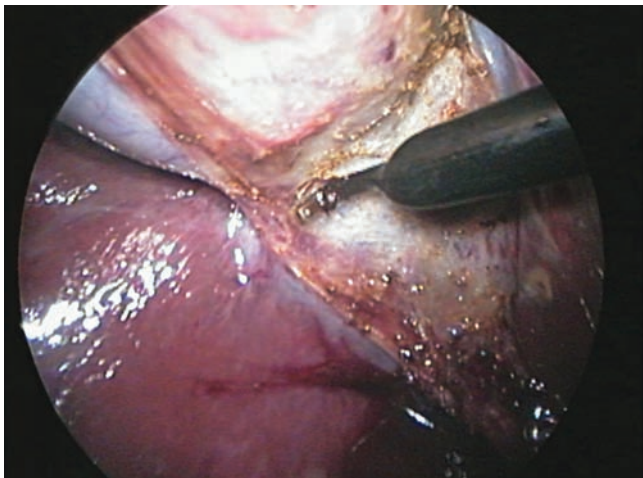


FIGURE 48-8 Dissecting the gallbladder off the liver.

while checking for any residual bleeding or bile leakage. The final attachments of the gallbladder are divided, and the liver edge is again examined for hemostasis.

After the cholecystectomy has been performed, the gallbladder must be removed from the abdominal cavity. The gallbladder may be placed within an entrapment sac prior to extracting it through the abdominal wall (Fig. 48-9). This is recommended particularly if the gallbladder has been perforated intraoperatively or if the specimen is large. If the stone burden is small, the gallbladder can be extracted at the subxiphoid port site. Usually, the gallbladder is most easily removed at the umbilical port site where there are no muscle layers anterior to the fascial plane. Also, if the fascial opening needs to be enlarged because of large or numerous stones, extension of the umbilical incision causes less postoperative pain and has better cosmesis than does enlarging the subxiphoid incision. The laparoscope is removed from the umbilical port and placed through the epigastric port. Large “claw” grasping forceps are introduced through the umbilical port to grasp the infundibulum of the gallbladder. The forceps, trocar, and gallbladder neck are then retracted as a unit through the umbilical incision. The neck of the gallbladder is thus exteriorized through the anterior abdominal wall with the fundus remaining within the abdominal cavity. If the gallbladder is not distended with bile or stones, it can be simply withdrawn with gentle traction. In many cases, a suction catheter introduced through an incision in the gallbladder neck is used to aspirate bile and small stones. Stone forceps can also be placed into the gallbladder to extract or crush calculi if necessary. Occasionally, the fascial incision must be extended to extract larger stones or thick-walled gallbladders.

Each incision is infiltrated with bupivacaine for postoperative analgesia. The fascia of the umbilical incision is closed with one or two large absorbable sutures in an interrupted or figure-of-eight fashion. Closure of the subxiphoid fascia is optional, as visceral herniation is unlikely to occur because of the oblique entry angle of the trocar into the abdominal

cavity and its location anterior to the falciform ligament. The skin of the subxiphoid and umbilical incisions is closed with subcuticular absorbable sutures. The skin incisions at both 5-mm port sites can be closed with absorbable sutures, adhesive strips, or skin closure adhesives. The orogastric tube is removed in the operating room, and the patient is transferred to the postanesthesia care unit. Patients are allowed out of bed as soon as they are fit enough to walk, and more than 90% of patients are discharged from the hospital within 24 hours. Fit patients who have been preoperatively selected may be safely discharged within 6 hours following surgery.<sup>45</sup> Patients are evaluated 1 week following surgery and if sutures are present, they are removed. At this time, more than 95% of patients are back to a normal routine and most return to work immediately following their clinic visit.

## ADVANTAGES AND DISADVANTAGES

The advantages of laparoscopic cholecystectomy over other therapies for gallstone disease are multiple (Table 48-3). Unlike nonresective techniques for gallstone ablation, laparoscopic cholecystectomy removes the diseased gallbladder along with its stones. Relative to traditional open cholecystectomy, postoperative pain and intestinal ileus are diminished with laparoscopic cholecystectomy. The small size of the fascial incisions allows rapid return to heavy physical activities. The small incisions are also cosmetically more appealing than is the large incision used during traditional cholecystectomy. The patient can usually be discharged from the hospital either on the same day or the day following operation, and can return to full activity within a few days.<sup>7,11</sup> These factors lead to overall decreased cost of laparoscopic cholecystectomy compared to its traditional open counterpart.<sup>8</sup>

There are, however, several potential disadvantages of laparoscopic cholecystectomy. As opposed to nonresective treatments for gallstones, patients must be acceptable candidates for

general anesthesia and possible laparotomy. Three-dimensional depth perception is limited by the two-dimensional monocular image of the videoscope. It is more difficult to control significant hemorrhage using laparoscopic technology than in an open surgical field. There is also less haptic discrimination of structures using laparoscopic instruments as opposed to direct digital palpation during open cholecystectomy. CO<sub>2</sub> insufflation to create the pneumoperitoneum is associated with a number of potential risks, including reduction of vena caval flow and systemic hypercarbia with acidosis.

## SPECIAL CONSIDERATIONS

### Conversion to Open Operation

Surgeons performing laparoscopic cholecystectomy should not think of conversion to open operation as a complication, but rather a sound clinical judgment, and hence not hesitate to convert to a traditional open cholecystectomy if the anatomy is unclear, if complications arise, or there is failure to make reasonable progress in a timely manner. Some complications requiring laparotomy are obvious, such as massive hemorrhage or major injury to the bile duct. Open laparotomy allows the additional tool of manual palpation and haptic sensation and should be performed when the anatomy cannot be delineated because of inflammation, adhesions, or anomalies. Fistulae between the biliary system and bowel are rare, but may require laparotomy for optimal management. The demonstration of potentially resectable gallbladder carcinoma also dictates an open exploration. Finally, CBD stones that cannot be removed laparoscopically and are unlikely to be extracted endoscopically (because of Billroth II anastomosis, previously failed endoscopic retrograde cholangiopancreatography [ERCP], or an inexperienced endoscopist) should be converted to open operation without hesitation.

### Open Cholecystectomy

The technical aspects of performing an open cholecystectomy have not changed significantly since Langenbuch's description of this procedure more than 100 years ago. Although this operation can be performed safely through a midline, paramedian, or right subcostal incision, most surgeons prefer the right subcostal (Kocher) incision. Adequate exposure of the gallbladder and the hepatoduodenal ligament is the key to performing a safe cholecystectomy. Laparotomy sponges may be packed temporarily between the dome of the liver and the diaphragm, and appropriate retractors should be inserted to optimize visualization of the hepatoduodenal ligament and its structures. The hepatic flexure of the colon is packed or retracted inferiorly and the medial segment of the left liver lobe is retracted superiorly. When a large distended gallbladder is encountered, removal can be facilitated by decompressing the gallbladder. Adhesions of omentum

**TABLE 48-3: ADVANTAGES AND DISADVANTAGES OF LAPAROSCOPIC CHOLECYSTECTOMY COMPARED TO OPEN CHOLECYSTECTOMY**

Advantages	Disadvantages
Less pain	Lack of depth perception
Smaller incisions	Adhesions/inflammation limit use
Better cosmesis	More difficult to control hemorrhage
Shorter hospitalization	Decreased tactile discrimination (haptics)
Earlier return to full activity	Potential CO <sub>2</sub> insufflation complications
Decreased total costs	Slight increase in bile duct injuries

or viscera adjacent to the gallbladder are divided with sharp dissection or electrocautery.

Meticulous dissection and positive identification of the cystic duct, its entry into the CBD, and the cystic artery are mandatory and significantly reduce the likelihood of bile duct injury. Most experienced surgeons prefer to identify these important structures before beginning dissection of the gallbladder from the hepatic bed. The fundus and infundibulum of the gallbladder are grasped with curved clamps. The fundus is retracted anteriorly and superiorly and the infundibulum inferiorly and laterally, exposing the structures of Calot's triangle. Caudal counter-retraction of the hepatoduodenal ligament stretches and exposes the porta hepatis, placing the peritoneum overlying the cystic duct and artery on tension. This maneuver may be accomplished with a retractor, although the left hand of the first assistant effectively retracts the duodenum. The surgeon introduces the left index finger into the foramen of Winslow and palpates for calculi in the CBD. Acute inflammation or chronic scarring may preclude approaching the infundibulum first; many surgeons prefer to dissect the fundus initially (fundus first or top-down technique), and the ductal and vascular structures subsequently, only after the organ has been separated from the liver. Careful ligation of the cystic duct is essential in preventing not only a biliary leak, but also in reducing the possibility of bile duct injury and stricture. Ligation of the cystic duct in close proximity to its junction with the CBD has long been considered an essential component of open cholecystectomy. Experience with laparoscopic cholecystectomy suggests that the length of the cystic duct stump is not a critical factor and probably does not significantly contribute to postcholecystectomy syndrome, a poorly defined clinical entity characterized by pain following gallbladder removal. The cystic artery should be dissected, secured, and divided near the surface of the gallbladder. This will reduce bleeding associated with division of the peritoneum investing the gallbladder and separation of areolar tissue between the gallbladder and the liver. Intraoperative cholangiography can be performed at the discretion of the surgeon.

Throughout the procedure, care should be exercised to minimize spillage of bile into the peritoneal cavity. Drains are not mandatory and are indicated only if the surgeon is concerned about identifying or controlling a possible bile leak. Common pitfalls are usually related to inadequate exposure, severe inflammation, bleeding, and anatomic variants, which can lead to injury of portal structures, including the common bile duct and the hepatic artery or its branches. With a short cystic artery, the right hepatic artery must be carefully identified. Similarly with a short cystic duct, careful dissection and high ligation of the cystic duct near the gallbladder should be employed to avoid injury to the common bile duct. In fact, in the face of severe inflammation with obliteration of normal tissue planes it may be safest to perform a subtotal cholecystectomy, leaving a portion of the infundibulum in situ (after removing all stones) and suture ligating the mucosal side of the cystic duct origin. If there is unintentional gallbladder puncture, a second clamp or purse-string suture can be

applied to prevent gallbladder bile and stone spillage. Before closing the abdominal incision, bleeding and bilious drainage must be controlled. Structures in the porta hepatis are re-examined, with special attention to the cystic duct stump. The subhepatic space is irrigated with warm saline and all irrigants are evacuated. The incision is usually closed in one or two layers. The skin can be closed with sutures or staples.

## Acute Cholecystitis

Acute cholecystitis may be treated successfully by laparoscopic cholecystectomy. Intervention during the early phase often reveals an inflamed, edematous, thick-walled, and tensely distended organ. To gain adequate traction on the gallbladder with the grasping forceps, it may be necessary to decompress the gallbladder by aspirating its contents with a large-gauge needle or suction irrigator. As long as the inflammation is limited to the gallbladder, laparoscopic cholecystectomy is usually technically feasible. However, if inflammation extends to the porta hepatis, great care must be taken in proceeding with the operation. The normally thin, minimally adherent tissue that invests the cystic duct and artery is markedly thickened and edematous and may not readily separate from these structures with the usual blunt dissection techniques. The duct wall also may be edematous, thus making its external diameter similar to the gallbladder neck and CBD. If the anatomy is unclear, cholangiography must be performed before clipping or dividing tissue. When acute inflammation has been present for several days or weeks before operation, the pericholecystic tissue planes may be obliterated by thick, woody tissue that is difficult to dissect bluntly. The surgeon may therefore need to convert to open cholecystectomy if the minimal access approach is initially attempted during this subacute phase. There is no harm in inserting the laparoscope and assessing the right upper quadrant. The decision to convert to an open operation is a matter of judgment, based on the existing anatomy, local conditions, and the surgeon's experience and confidence in his or her ability to complete the procedure using minimal access techniques.

Several authors have reported performing laparoscopic cholecystectomy<sup>51</sup> in the face of acute inflammation with success but with a higher conversion rate than for elective laparoscopic cholecystectomy.<sup>52-57</sup> Lo and associates reported in their prospective study that despite longer operative times and postoperative stays for early laparoscopic cholecystectomy in patients with acute cholecystitis (treatment within 5 days) versus delayed laparoscopic cholecystectomy (initial conservative treatment followed by laparoscopic cholecystectomy 3-4 months later), the advantage of early laparoscopic cholecystectomy was the reduction in the total hospital stay, from 15 to 7 days. In a second prospective study of 105 patients randomized to early laparoscopic cholecystectomy (within 24 hours of diagnosis of acute cholecystitis) versus delayed laparoscopic cholecystectomy (6-8 weeks later), there was no significant difference in conversion rate (early 21% vs delayed 24%), postoperative analgesic requirement,



or number of postoperative complications. The early group did have a longer operative time (123 vs 107 minutes;  $p = .04$ ), but total hospitalization was shorter (8 vs 12 days;  $p = .001$ ).<sup>57</sup> Rattner and associates retrospectively reviewed 20 patients who underwent attempted laparoscopic cholecystectomy for acute cholecystitis and examined factors that were predictive of a successful procedure.<sup>54</sup> Seven of the 20 patients (35%) required conversion to open cholecystectomy. The interval from admission to cholecystectomy in the successful cases was 0.6 days versus 5 days in the cases requiring conversion to open cholecystectomy. Converted cases also had a significantly higher white blood cell (WBC) count, alkaline phosphatase levels, and Acute Physiology and Chronic Health Evaluation II (APACHE II) scores compared to those undergoing successful laparoscopic cholecystectomy. Ultrasonographic findings such as gallbladder distention, wall thickness, and pericholecystic fluid did not correlate with the success of laparoscopic cholecystectomy.

More recent studies have confirmed that laparoscopic cholecystectomy is an equivalent or better option than open surgery for treating acute cholecystitis.<sup>58,59</sup> In a study of two prospectively randomized groups, Johansson and associates reported that there were no differences in post-operative complications or pain when comparing laparoscopic to open cholecystectomy.<sup>55</sup> Using a cohort of almost 1 million patients from the National Hospital Discharge Surveys from 2000 to 2005, Csikesz and associates reported recently that patients undergoing laparoscopic cholecystectomy for acute cholecystitis have low conversion rates (9.5%), lower morbidity (16 vs 36%), and lower unadjusted mortality (0.4 vs 3%) compared to open cholecystectomy.<sup>56</sup>

It can be concluded that laparoscopic cholecystectomy should be performed immediately after the diagnosis of acute cholecystitis. Delaying surgery allows inflammation to become more intense and neovascularized, thus increasing the technical difficulty of laparoscopic cholecystectomy.

## Intraoperative Gallbladder Perforation

Perforation of the gallbladder with bile or stone leakage can be a nuisance but should not ordinarily require conversion to open cholecystectomy. Perforation may occur secondary to traction applied by the grasping forceps or because of electro-surgical thermal injury during removal of the gallbladder from its bed. In our experience, almost one-third of the patients have had intraoperative spillage of bile or stones.<sup>5</sup> Patients with a bile leak have not experienced an increased incidence of infection, prolongation of hospitalization, or postoperative disability, nor adverse long-term complications<sup>60</sup> (mean follow-up of 41 months in 250 consecutive laparoscopic cholecystectomy patients). The only difference between those with and without bile leakage was that the operating time of patients with a gallbladder perforation was approximately 10 minutes longer, presumably because of the time spent in cleaning up the operative field. When perforation does occur, the bile should be aspirated completely and irrigation used liberally. The hole in

the gallbladder is best secured with a grasping instrument and then sutured or tied with an endoloop. The stones should be retrieved and removed. Gallbladder spillage, when treated in this manner, results in no adverse short- or long-term complications. Escaped stones composed primarily of cholesterol pose little threat of infection. However, pigment stones frequently harbor viable bacteria and may potentially lead to subsequent infectious complications if allowed to remain in the peritoneal cavity.<sup>61,62</sup> The long-term complications of retained stones, either intra-abdominally with resultant abscess formation or intramurally with resultant port site abscess, have not been prospectively studied, but recent case reports and case series in the surgical literature document a clear potential for long-term infectious complications.<sup>63-66</sup> The relative infrequency of these complications probably does not justify conversion to open operation in the face of spilled stones, but vigilance in avoidance of perforation, a careful search for escaped stones, the aggressive use of irrigation, and liberal use of a plastic retrieval bag for large and friable gallbladders are recommended.<sup>67</sup>

## COMPLICATIONS

### Laparoscopic Cholecystectomy

Most complications related to laparoscopic removal of the gallbladder are similar to those occurring during traditional open cholecystectomy (Table 48-4). These complications include hemorrhage, bile duct injuries, bile leaks, retained stones, pancreatitis, wound infections, and incisional hernias. Other potential complications are pneumoperitoneum related (gas embolism, vagal reaction, ventricular arrhythmias, or hypercarbia with acidosis) and trocar related (injuries to the abdominal wall, intra-abdominal organ, or major blood vessels). The protective shield on disposable trocars is not an insurance



**TABLE 48-4: COMPLICATIONS OF LAPAROSCOPIC CHOLECYSTECTOMY**

Hemorrhage
Bile duct injury
Bile leak
Retained stones
Pancreatitis
Wound infection
Incisional hernia
Pneumoperitoneum related
CO <sub>2</sub> embolism
Vaso-vagal reflex
Cardiac arrhythmias
Hypercarbic acidosis
Trocar related
Abdominal wall bleeding, hematoma
Visceral injury
Vascular injury

against perforation of intestine or major vessels, especially after previous abdominal operations. Regardless of the make of trocar, during its insertion one should never aim toward the spine or the location of the great vessels, and a hand is used as a brake to prevent inadvertently introducing the trocar too far. Insertion of the initial trocar, especially when performed in a closed fashion, can cause iatrogenic injury to the bowel, bladder, aorta, iliac artery, or vena cava.<sup>68,69</sup> When a trocar injury to a major blood vessel is suspected, the patient must be opened immediately without removing the trocar until the involved blood vessel is isolated. In contrast, if the small-bore Veress needle enters a viscus or blood vessel, the operation can generally be completed and the patient monitored closely for signs of complications in the postoperative period.

The laparoscopic trocars may also lacerate blood vessels in the abdominal wall. Prior to removal, each trocar should be visualized from the peritoneal aspect using the laparoscope. If significant hemorrhage is seen, it can generally be controlled with cautery, intraoperative tamponade with a Foley catheter, or a through-and-through suture on each side of the trocar insertion site.

Most serious complications occur early in the surgeon's experience. For instance, in a multivariate regression analysis of 8839 laparoscopic cholecystectomies in which there were 15 bile duct injuries, the only significant factor associated with an adverse outcome was the surgeon's experience with the procedure.<sup>70</sup> The regression model predicted that a surgeon had a 1.7% chance of a bile duct injury occurring in the first case and 0.17% chance of a bile duct injury in the 50th case.

Of all the potential complications, biliary injuries have received the most attention and are discussed at length elsewhere in this text. Most series quote a major bile duct injury rate of around 0.2% during open cholecystectomy, whereas the incidence of bile duct injuries during laparoscopic cholecystectomy is 0.40% or higher.<sup>34</sup> These injuries can cause major morbidity, prolonged hospitalization, high cost, and litigation.<sup>70,71</sup> In addition to the surgeon's experience and aberrant anatomy, a number of reports mention chronic inflammation with dense scarring, operative bleeding obscuring the field, or fat in the portal area contributing to the biliary injuries.<sup>38,70-72</sup> The classic biliary injury, however, occurs when the CBD or a RHD is mistaken for the cystic duct and is divided between clips. Many surgeons attribute this misidentification to the direction of traction of the gallbladder, that is, pulling the CBD and the cystic duct into alignment, thus making them appear to be one. Other contributing factors to misidentification are a short cystic duct, a large stone in Hartmann's pouch (making retraction and display of the cystic duct difficult), or tethering of the infundibulum to the CBD by acute or chronic inflammation. Constant awareness of these potential misidentifications and technical causes of biliary injuries is the best method of prevention. If a partial bile duct injury occurs and is recognized intra-operatively, an immediate primary repair, possibly in conjunction with a T-tube should be performed. A complete transection of the bile duct is a rare injury and an end-to-end repair is a

technically challenging procedure that may require assistance from an experienced hepatobiliary surgeon. When a bile duct injury is discovered in the postoperative period, a coordinated effort by radiologists, endoscopists, and surgeons is necessary to optimize management.<sup>40</sup> There should be no hesitation in asking for the help of a surgeon experienced in biliary repair.

## Open Cholecystectomy

Experience with open cholecystectomy is vast, spanning generations of surgeons and having been practiced in virtually every country throughout the world. Over time, this operation has proved to be safe and effective. In a collected series of about 20,000 patients who underwent cholecystectomy between 1946 and 1973 at 10 different institutions, from the United States and throughout the world, the overall mortality rate was 1.6%. This figure is comparable to a 1.7% mortality rate reported for more than 12,000 patients operated on for calculous biliary tract disease between 1932 and 1979 at a single US university center. In this latter group, the operative mortality rate for patients who underwent elective cholecystectomy was 0.1%. More recently, a US population-based study examining the outcome of all open cholecystectomies performed in a 12-month period in two states reported an overall mortality rate of 0.17%.<sup>73</sup> The morbidity rate was 14.7%, which includes all reported complications, including minor problems such as electrolyte imbalances, atelectasis, urinary retention, and other assorted difficulties that can occur following any surgical procedure. In this study, morbidity and mortality were dependent on age as well as disease status. Perhaps the most significant complication that can arise during open or laparoscopic cholecystectomy is bile duct injury. Numerous reports in the literature, including this large population-based study indicate that the risk of bile duct injury during open cholecystectomy is between 0.1 and 0.2%. Similar morbidity and mortality data have been reported by other large series. These data confirm that open cholecystectomy continues to be a very safe operation that can be performed with a very low morbidity and mortality. In elective situations, open cholecystectomy is being performed in many hospitals throughout the world on patients who are admitted the day of surgery, with an overall stay of 2–4 days.

## NEW AND INVESTIGATIONAL TECHNIQUES TO PERFORM CHOLECYSTECTOMY

The advent of laparoscopic cholecystectomy provided a dramatic benefit to patients who previously underwent laparotomy for gallbladder disease. While laparoscopy has already set a high bar for cholecystectomy with regards to perioperative and intraoperative outcomes, there are areas of surgical research examining ways that could potentially make the procedure even less invasive.

## Single-port Laparoscopic Surgery

Single-port laparoscopy is a recent development in laparoscopic surgery that involves introducing all operative instruments and devices through a single skin incision, usually at the umbilicus.<sup>74-76</sup> The proposed benefit of single-port laparoscopic cholecystectomy over traditional laparoscopic cholecystectomy is by reducing the overall number of abdominal incisions from three or four to one, there will be less perioperative pain and fewer resulting incisional complications. From a technical standpoint, single-port surgery leads to all of the instruments entering the operative field in line with the optics. Triangulation and traction or countertraction are made more difficult, but new instrumentation is being developed to overcome these limitations. There are currently no established standard techniques for performing this procedure and postoperative results are just emerging.

## Natural Orifice Transluminal Endoscopic Surgery

Natural orifice transluminal endoscopic surgery (NOTES) is an investigational procedure that aims to reduce and eventually eliminate all abdominal incisions by accessing the peritoneum through natural orifice routes including transoral or transgastric, transvaginal, and transanal or transcolonic. By eliminating abdominal incisions, the hypothesis is that there will be less pain, fewer complications and decreased morbidity associated with abdominal incisions.<sup>77-81</sup> These benefits are proposed to include decreased incisional hernias, wound infections, and post-operative pain, while improving cosmesis. Given the current state of technology and lack of appropriate instrumentation, few pure NOTES cholecystectomies have been performed worldwide.<sup>82-84</sup> NOTES hybrid procedures, where a laparoscopic instrument is used in conjunction with the natural orifice devices, have been performed in greater numbers, though only in a relatively few specialized centers. Results from these procedures are also just being reported and large sets of data are not yet available to evaluate the proposed benefits of NOTES.

## CONCLUSION

Cholecystectomy remains one of the most common operations performed in the United States and worldwide. Laparoscopic cholecystectomy is the standard for treatment of gallstone and gallbladder disease. There are numerous advantages of laparoscopic cholecystectomy over open cholecystectomy, including decreased pain, length of stay, recovery time, incisional complications, and improved cosmesis. However, occasionally anatomical or physiological considerations will hinder or preclude the minimal access approach, and conversion to an open operation in such cases reflects sound clinical judgment and should not be considered a complication. Additionally, there are current studies underway to investigate new ways to

perform cholecystectomies that may result in additional benefits over traditional laparoscopic cholecystectomy.

## REFERENCES

1. Beal JM. Historical perspective of gallstone disease. *Surg Gynecol Obstet.* 1984;158:181-189.
2. Schoenfield I, Lachin J. The Steering Committee TNCGSG. Chenodiol (chenodeoxycholic acid) for dissolution of gallstones: the national cooperative gallstone study. *Ann Intern Med.* 1981;95:257-282.
3. Schoenfield I, Berci G, Carnovale R, et al. The effect of ursodiol on the efficacy and safety of extracorporeal shockwave lithotripsy of gallstones. *N Engl J Med.* 1990;323:1239-1245.
4. Soper NJ, Stockmann PT, Dunnegan DL, et al. Laparoscopic cholecystectomy: the new 'gold standard'? *Arch Surg.* 1992;127S:917-921.
5. Soper NJ, Brunt LM, Kerbl K. Laparoscopic general surgery. *N Engl J Med.* 1994;330:409-419.
6. Conference, NC. Gallstones and laparoscopic cholecystectomy. *JAMA.* 1992;269:1018-1024.
7. Barkun JS, Barkun AN, Sampalis JS, et al. Randomized controlled trial of laparoscopic versus mini-cholecystectomy. *Lancet.* 1992;340:1116-1119.
8. Bass EB, Pitt HA, Lillemoie KD. Cost-effectiveness of laparoscopic cholecystectomy versus open cholecystectomy. *Am J Surg.* 1993;165:466-471.
9. McMahon A, Russell I, Baxter J, et al. Laparoscopic versus minilaparoscopic cholecystectomy: a randomized trial. *Lancet.* 1994;343:135-138.
10. Soper NJ. Laparoscopic cholecystectomy. *Curr Probl Surg.* 1991;28:585-655.
11. Soper NJ, Barteau J, Clayman R, et al. Laparoscopic versus standard open cholecystectomy: comparison of early results. *Surg Gynecol Obstet.* 1992;174:114-118.
12. Escarce J, Chen W, Schwartz J. Falling cholecystectomy thresholds since the introduction of laparoscopic cholecystectomy. *JAMA.* 1995;273: 1581-1585.
13. Nenner R, Imperato P, Rosenberg C, et al. Increased cholecystectomy rates among medicare patients after the introduction of laparoscopic cholecystectomy. *J Community Health.* 1994;19:409-415.
14. Legorreta A, Silber J, Constantino G, et al. Increased cholecystectomy rate after introduction of laparoscopic cholecystectomy. *JAMA.* 1993;270:1429-1432.
15. Ransohoff D, Gracie W. Treatment of gallstones. *Ann Intern Med.* 1993;119:606-619.
16. Ransohoff D, Gracie W, Wolfenson L, et al. Prophylactic cholecystectomy or expectant management for silent gallstones: a decision analysis to assess survival. *Ann Intern Med.* 1983;99:199-204.
17. Tagge E, Othersen HJ, Jackson S, et al. Impact of laparoscopic cholecystectomy on the management of cholelithiasis in children with sickle cell disease. *J Pediatr Surg.* 1994;29:209-212.
18. Fobi M, Lee H, Igwe D, et al. Prophylactic cholecystectomy with gastric bypass operation: incidence of gallbladder disease. *Obes Surg.* 2002;12: 350-353.
19. Sugerman HJ, Brwer W, Shiffman M, et al. A multicenter, placebo-controlled, randomized double-blind, prospective trial of prophylactic ursodiol for the prevention of gallstone formation following gastric-bypass-induced rapid weight loss. *Am J Surg.* 1995;169: 91-97.
20. Hamad G, Ikramuddin S, Gourash W, et al. Elective cholecystectomy during laparoscopic Roux-En-Y gastric bypass: is it worth the wait? *Obes Surg.* 2003;13:76-81.
21. Villegas L, Schneider B, Provost D, et al. Is routine cholecystectomy required during laparoscopic gastric bypass? *Obes Surg.* 2004;14:60-66.
22. Liem R, Niloff P. Prophylactic cholecystectomy with open gastric bypass operation. *Obes Surg.* 2004;14:763-765.
23. Hull D, Bartus S, Perdrizet G, et al. Management of cholelithiasis in heart and lung transplant patients: with review of laparoscopic cholecystectomy. *Cann Med.* 1994;58:643-647.
24. Fendrick A, Gleeson S, Cabana M, et al. Asymptomatic gallstones revisited. Is there a role for laparoscopic cholecystectomy? *Arch Fam Med.* 1993;2:959-968.
25. Giradet R, Rosenbloom P, Deweese B, et al. Significance of asymptomatic biliary tract disease in heart transplantation recipients. *J Heart Transplant.* 1989;8:391-399.
26. Boline G, Clifford R, Yang H, et al. Cholecystectomy in the potential heart transplant patient. *J Heart Lung Transplant.* 1991;10:269-274.



27. Steck T, Castanfo-Nordin M, Keshavarzian A. Prevalence and management of cholelithiasis in heart transplant patients. *J Heart Lung Transplant.* 1991;10:1024–1032.
28. Drossman DA, Dumitrascu DL. Rome III: new standard for functional gastrointestinal disorders. *J Gastrointest Liver Dis.* 2006;15(3):237–241.
29. Myers RP, Shaffer EA, Beck PL. Gallbladder polyps: epidemiology, natural history, and management. *Can J Gastroenterol.* 2002;16(3):187–194.
30. Ito H, Hann LE, D'Angelica M, et al. Polypoid lesions of the gallbladder: diagnosis and followup. *J Am Coll Surg.* 2009;208(4):570–575.
31. Stephen AE, Berger DL. Carcinoma in the porcelain gallbladder: a relationship revisited. *Surgery.* 2001;129:699–703.
32. Johansson M, Thune A, Blomqvist A, Nelvin L, Lundell L. Management of acute cholecystitis in the laparoscopic era: results of a prospective randomized clinical trial. *J Gastrointest Surg.* 2003;7:642–645.
33. Kolla SB, Aggarwal S, Kumar A, et al. Early versus delayed laparoscopic cholecystectomy for acute cholecystitis. *Surg Endosc.* 2004;18:1323–1327.
34. Lau H, Lo CY, Patil NG, Yuen WK. Early versus delayed-interval laparoscopic cholecystectomy for acute cholecystitis. *Surg Endosc.* 2006;20:82–87.
35. Teoh AYB, Chong CN, Wong J, et al. Routine early laparoscopic cholecystectomy for acute cholecystitis after conclusion of a randomized controlled trial. *Br J Surg.* 2007; 94: 1128–1132.
36. Macafee DAL, Humes DJ, Bouliotis G, Beckingham IJ, Wynes DK, Lobo DN. Prospective randomized trial using cost-utility analysis of early versus delayed laparoscopic cholecystectomy for acute gallbladder disease. *Br J Surg.* 2009; 96: 1031–1040.
37. Choudhary A, Bechtold ML, Puli SR, Othman MO, Roy PK. Role of prophylactic antibiotics in laparoscopic cholecystectomy: a meta-analysis. *J Gastrointest Surg.* 2008;12:1848–1853.
38. Soper NJ. Effect of nonbiliary problems on laparoscopic cholecystectomy. *Am J Surg.* 1993;165:522–526.
39. Soper N, Hunter J, Petrie R. Laparoscopic cholecystectomy during pregnancy. *Surg Endosc.* 1992;6:115–117.
40. Strasberg S, Hertl N, Soper N. An analysis of the problem of biliary injury during laparoscopic cholecystectomy. *J Am Coll Surg.* 1995;180:101–125.
41. Machi J, Sigel B, Zaren A, et al. Operative ultrasonography during hepatobiliary and pancreatic surgery. *World J Surg.* 1993;17:640–646.
42. Machi J, Sigel B, Zaren A, et al. Technique of ultrasound examination during laparoscopic cholecystectomy. *Surg Endosc.* 1993;7:545–549.
43. Orda R, Sayfan J, Levy Y. Routine laparoscopic ultrasonography in biliary surgery. *Surg Endosc.* 1994;8:1239–1242.
44. Jakimowicz J. Review: intraoperative ultrasonography during minimal access surgery. *J R Coll Surg Edinb.* 1993;38:231–238.
45. John T, Banting S, Pye S, et al. Preliminary experience with intracorporeal laparoscopic ultrasonography using a sector scanning probe. A prospective comparison with intraoperative cholangiography in the detection of choledocholithiasis. *Surg Endosc.* 1994;8:1176–1180.
46. McIntyre R, Stiegmann G, Peralman N. Update on laparoscopic ultrasonography. *Endosc Surg Allied Technol.* 1994;2:149–152.
47. Steigmann G, McIntyre R, Pearlman N. Laparoscopic intracorporeal ultrasound. An alternative to cholangiography? *Surg Endosc.* 1994;8:167–171.
48. Steigmann G, Soper N, Filipi C, et al. Laparoscopic ultrasonography as compared with static or dynamic cholangiography at laparoscopic cholecystectomy. *Surg Endosc.* 1995;9:1269–1273.
49. Soper NJ. The utility of ultrasonography for screening the common bile duct during laparoscopic cholecystectomy. *J Laparoendosc Adv Surg Tech.* 1997;7:271–276.
50. Wu J, Dunnegan D, Soper NJ. The utility of intracorporeal ultrasonography for screening of the bile duct during laparoscopic cholecystectomy. *J Gastrointest Surg.* 1998;2:50–59.
51. Curet MJ, Contreras M, Weber DM, et al. Laparoscopic cholecystectomy. *Surg Endosc.* 2002;16(3):453–457.
52. Cooperman A. Laparoscopic cholecystectomy for severe acute, embedded, and gangrenous cholecystitis. *J Laparoendosc Surg.* 1990;1:37–40.
53. Hermann R. Surgery for acute and chronic cholecystitis. *Surg Clin North Am.* 1990;70:1263–1275.
54. Rattner D, Ferguson C, Warshaw A. Factors associated with successful laparoscopic cholecystectomy for acute cholecystitis. *Ann Surg.* 1993;217:233–236.
55. Johansson M, Thune A, Nelvin L, Stiernstam M, Westman B, Lundell L. Randomized clinical trial of open versus laparoscopic cholecystectomy in the treatment of acute cholecystitis. *Br J Surg.* 2005;92:44–49.
56. Csikesz N, Ricciardi R, Tseng JF, Shah SA. Current status of surgical management of acute cholecystitis in the United States. *World J Surg.* 2008;32:2230–2236.
57. Reddick E, Olsen D, Spaw A, et al. Safe performance of difficult laparoscopic cholecystectomies. *Am J Surg.* 1991;161:377–381.
58. Unger S, Edelman D, Scott J, et al. Laparoscopic treatment of acute cholecystitis. *Surg Laparosc Endosc.* 1991;1:14–16.
59. Lai PBS, Kwong KH, Leung KL, et al. Randomized trial of early versus delayed laparoscopic cholecystectomy for acute cholecystitis. *Br J Surg.* 1998;85:764–767.
60. Jones D, Dunnegan D, Soper NJ. The influence of intraoperative gallbladder perforation on long-term outcome after laparoscopic cholecystectomy. *Surg Endosc.* 1995;9:977–980.
61. Deziel D, Millikan K, Economou S, et al. Complications of laparoscopic cholecystectomy: a national survey of 4,292 hospitals and an analysis of 77,604 cases. *Am J Surg.* 1993;165:9–14.
62. Carlin CB, Kent RB, Laws HL. Spilled gallstones—complications of abdominal wall abscesses. *Surg Endosc.* 1995;9:341–343.
63. Horton M, Florence MG. Unusual abscess patterns following dropped gallstones during laparoscopic cholecystectomy. *Am J Surg.* 1998; 175:375–379.
64. Parra-Davila E, Munshi IA, Armstrong JH, et al. Retroperitoneal abscess as a complication of retained gallstones following laparoscopic cholecystectomy. *J Laparoendosc Adv Surg Tech.* 1998;8:89–93.
65. Shopen E. Abdominal abscess from gallstones spilled at laparoscopic cholecystectomy. *Surg Endosc.* 1995;9:344–347.
66. Zamir G, Lyass S, Pertsemliadis D, et al. The fate of the dropped gallstones during laparoscopic cholecystectomy. *Surg Endosc.* 1999;13:68–70.
67. Berci G, Sackier JM. Laparoscopic cholecystectomy and laparoscopic choledocholithotomy. In: Blumgart LH, ed. *Surgery of the Liver and Biliary Tract.* Edinburgh, UK: Churchill Livingstone; 1994:633–662.
68. Hanney RM, All KM, Cregan PC, et al. Major vascular injury and laparoscopy. *Aust N Z J Surg.* 1995;65:533–535.
69. Cogliandolo A, Monganaro T, Saitta FP, et al. Blind versus open approach to laparoscopic cholecystectomy: a randomized study. *Surg Laparosc Endosc.* 1998;8:353–355.
70. Davidoff A, Pappas T, Murray E, et al. Mechanisms of major biliary injury during laparoscopic cholecystectomy. *Ann Surg.* 1992;215:196–202.
71. Moosa A, Easter D, vanSonnenberg E, et al. Laparoscopic injuries to the bile duct. *Ann Surg.* 1992;215:203–208.
72. Adams DB, Borowicz MR, Wootton FTI, et al. Bile duct complications after laparoscopic cholecystectomy. *Surg Endosc.* 1993;7:79–83.
73. Kane R, Luie N, Borbas C, et al. The outcomes of elective laparoscopic and open cholecystectomy. *J Am Coll Surg.* 1995;180:136–145.
74. Podolsky ER, Rottman SJ, Poblete H, King SA, Curcillo PG. Single port access (SPA) cholecystectomy: a completely transumbilical approach. *J Laparoendosc Adv Surg Tech A.* 2009;19:219–222.
75. Nguyen NT, Reavis KM, Hinojosa MW, Smith BR, Wilson SE. Laparoscopic transumbilical cholecystectomy without visible abdominal scars. *J Gastrointest Surg.* 2009;13:1125–1128.
76. Hodgett SE, Hernandez JM, Morton CA, Ross SB, Albrink M, Rosemurgy AS. Laparoendoscopic single site (LESS) cholecystectomy. *J Gastrointest Surg.* 2009;13:188–192.
77. Marescaux J, Dallemagne B, Perretta S, Wattiez A, Mutter D, Coumaros D. Surgery without scars: report of transluminal cholecystectomy in a human being. *Arch Surg.* 2007;142:823–826.
78. Zorron R, Filgueiras M, Maggioni LC, Pombo L, Lopes Carvalho G, Lacerda Oliveira A. NOTES transvaginal cholecystectomy: report of the first case. *Surg Innov.* 2007;14:279–283.
79. Gumbs AA, Fowler D, Milone L, et al. Transvaginal natural orifice transluminal endoscopic surgery cholecystectomy: early evolution of the technique. *Ann Surg.* 2009;249:908–912.
80. Auyang ED, Hungness ES, Vaziri K, Martin JA, Soper NJ. Human NOTES cholecystectomy: transgastric hybrid technique. *J Gastrointest Surg.* 2009;13:1149–1150.
81. Horgan S, Mintz Y, Jacobsen GR, et al. Video: NOTES: transvaginal cholecystectomy with assisting articulating instruments. *Surg Endosc.* 2009; 23:1900.
82. Ramos AC, Murakami A, Galvao Neto M, et al. NOTES transvaginal video-assisted cholecystectomy: first series. *Endoscopy.* 2008;40:572–575.
83. Zornig C, Mofid H, Siemssen L, et al. Transvaginal NOTES hybrid cholecystectomy: feasibility results in 68 cases with mid-term follow-up. *Endoscopy.* 2009;41:391–394.
84. Noguera J, Dolz C, Cuadrado A, Olea J, Vilella A, Morales R. Hybrid transvaginal cholecystectomy, NOTES, and minilaparoscopy: analysis of a prospective clinical series. *Surg Endosc.* 2009;23:876–881.

# CHOLEDOCHOLITHIASIS AND CHOLANGITIS

Antonio di Carlo • David W. McFadden

With advanced endoscopic and laparoscopic techniques being readily accessible to the treating surgeon, determining the wisest path to the successful treatment of choledocholithiasis and cholangitis has become more challenging. Nevertheless, a large number of options allow one to tailor-specific therapy to each individual clinical situation so as to achieve the highest probability of success. In this chapter we attempt to give the reader a better understanding of the methods available for the diagnosis and treatment of common bile duct (CBD) stones and cholangitis so that treatment plans are developed that are patient-specific and have the highest chance of success.

## CHOLEDOCHOLITHIASIS

### Classification and Epidemiology

A common entity in Western societies, gallstones are found in approximately 15% of Americans and result in 700,000 cholecystectomies a year. The annual cost of medical care for gallstones is almost \$6.5 billion (1.3% of US health care costs) compared with chronic liver disease and cirrhosis (\$1.6 billion), chronic hepatitis C (\$0.8 billion), and diseases of the pancreas (\$2.2 billion).<sup>1</sup> CBD (downstream of the confluence of the hepatic ducts) stones have been noted in 10–15% of patients with cholelithiasis, and this incidence increases with age to over 80% in those who are over 90 years old.<sup>2</sup> Choledocholithiasis in Western countries usually results from stones originating in the gallbladder and migrating through the cystic duct. These *secondary bile duct stones* are cholesterol stones in 75% and black pigment stones in 25% of patients. Cholesterol stones are formed in the presence of cholesterol saturation, biliary stasis, and nucleating factors. Behavioral factors associated with cholesterol gallstones include nutrition, obesity, weight loss, and physical activity. Biologic factors linked to gallstones include increasing age, female sex and parity, serum lipid levels, and the Native American, Chilean, and Hispanic race.<sup>1</sup> The formation of black pigment stones is associated with hemolytic disorders, cirrhosis, ileal resection, prolonged fasting, and total parenteral nutrition.<sup>2</sup>

*Primary bile duct stones*, on the other hand, form within the bile ducts and usually are of the brown pigment variety. These tend to be lower in cholesterol content and higher in bilirubin content as compared with secondary stones. Unlike secondary stones, primary stones are associated with biliary stasis and bacteria.<sup>3</sup> In fact, in the pathogenesis of brown pigment stones, bile infection appears to be the initial event leading to stone formation.<sup>4</sup> Moreover, bacteria have been found in brown pigment stones by electron microscopy but not in black pigment stones. Primary bile duct stones are more common in Asian populations, and these often are associated with *primary intrahepatic stones* in this population.<sup>1</sup> These intrahepatic stones usually are calcium bilirubinate and mixed stones and contain more cholesterol and less bilirubin than the extrahepatic bile duct pigmented stones. The pathogenesis of these intrahepatic stones appears to involve bile infection; biliary stasis; low-protein, low-fat diets and malnutrition; and parasitic infections. However, the role of *Ascaris lumbricoides* and *Clonorchis sinensis* in the formation of intrahepatic stones is controversial. While these parasites are found in many geographic areas, primary intrahepatic stones are found mainly in Southeast Asia. Therefore, in addition to parasitic infections, other factors must play a role in the formation of these stones.<sup>1</sup>

### Clinical Presentation and Natural History

Asymptomatic bile duct stones may be found incidentally during evaluation of patients with suspected gallstones. In fact, 5% of common duct stones found during surgery may be unsuspected by preoperative findings and discovered only during intraoperative evaluation of the biliary tree. In one autopsy study of 615 patients over age 60, 1% were found to have bile duct stones.<sup>2</sup> Patients with choledocholithiasis may present with biliary colic, bile duct obstruction, bilirubinuria (or tea-colored urine), pruritus, acholic stools, and jaundice. However, the biliary obstruction usually is incomplete. There may be nausea and vomiting with intermittent or constant epigastric or right upper quadrant pain.<sup>5</sup> The clinical

course may be complicated by acute gallstone pancreatitis, cholangitis, or rarely, hepatic abscess. Infected patients may present with back pain, fever, hypotension, and mental status changes suggestive of cholangitis and ascending cholangitis. An asymptomatic state is also recognized.

CBD stones are covered by a bacterial biofilm of adherent quiescent bacteria residing in a hermetic environment. When stones cause obstruction of the ducts, cytokines released by epithelial cells activate these bacteria to the planktonic and virulent forms.<sup>1</sup> Therefore, bile duct obstruction secondary to stones often is accompanied by bacterial sepsis resulting from activation of the bacterial biofilm on these stones. Sepsis is much less likely to occur in the context of malignant obstruction without choledocholithiasis.

Although a majority of stones will pass spontaneously into the duodenum within hours, prolonged biliary obstruction can lead to biliary cirrhosis and portal hypertension. The average time for choledocholithiasis to lead to biliary cirrhosis is about 5 years, depending on the extent of obstruction.<sup>1</sup> Even with cirrhosis, however, the obstruction should be relieved because some reversal of portal hypertension and secondary biliary cirrhosis may be possible.

Physical examination of patients with choledocholithiasis may be normal or reveal jaundice, scleral icterus, and abdominal tenderness over the right upper quadrant without peritoneal signs. Early in the course, physical examination may not be very different from that of patients with cholecystitis. Severe tenderness may point to acute gallstone pancreatitis, whereas fever, hypotension, and confusion may suggest cholangitis.<sup>6</sup>

Blood tests may reveal elevation of serum alkaline phosphatase, gamma-glutamyl transpeptidase, and bilirubin. Mild elevations of aspartate aminotransferase and alanine aminotransferase can be seen, whereas these are particularly abnormal in the situation of cholangitis. Although bilirubin and aminotransferase levels are high in 70–90% of patients at the onset of symptoms, almost all patients have elevation of alkaline phosphatase and gamma-glutamyl transpeptidase.<sup>6</sup> Elevated amylase and lipase may suggest pancreatitis. Leukocytosis may be seen with cholangitis, pancreatitis, or associated acute cholecystitis. It is worth noting that laboratory evaluation of patients with bile duct stones can be normal repeatedly, and this should not dissuade further evaluation of patients suspected to harbor duct stones.<sup>7</sup>

## Evaluation and Management

The evaluation and treatment of choledocholithiasis are best discussed by considering the three clinical circumstances in which patients who may have bile duct stones are seen prior to cholecystectomy, during cholecystectomy, or some time after cholecystectomy.

### PREOPERATIVE

The diagnosis of choledocholithiasis cannot be made on the basis of history, physical examination, and laboratory investigations alone. Moreover, the distinction between the symptoms

of bile duct stones and gallbladder stones often is difficult. Increasing age, history of fever, cholangitis, and pancreatitis are risk factors for bile duct stones, whereas elevations of serum bilirubin, aspartate aminotransferase, or alkaline phosphatase are independent positive predictors.<sup>1,8</sup>

*Transcutaneous ultrasound* has been the traditional method of evaluating patients with biliary disease. It is highly accurate in identifying acute calculous cholecystitis and the presence of gallstones greater than 2 mm. Sensitivities and specificities of 48–100% and 64–100%, respectively, have been reported.<sup>9</sup> However, the ability of transcutaneous ultrasound to establish the diagnosis of choledocholithiasis is only about 50%, varying from 30 to 90%.<sup>6,10</sup> The role of ultrasound as a screening test for bile duct stones was evaluated prospectively by Gross and colleagues.<sup>11</sup> Patients who were about to undergo endoscopic retrograde cholangiopancreatography (ERCP) were examined by right upper quadrant sonography to assess the size of the intra- and extrahepatic ducts and for the presence or absence of bile duct stones. The findings were compared with ERCP, percutaneous transhepatic cholangiography, or surgical follow-up. Ultrasound was not found to be accurate in the diagnosis (sensitivity of 25%) or the exclusion (73% negative predictive value) of choledocholithiasis.

Costi and colleagues studied the usefulness of the number and size of gallbladder stones for predicting asymptomatic choledocholithiasis.<sup>12</sup> Ultrasound data of 300 consecutive patients undergoing laparoscopic cholecystectomy were analyzed. Patients were divided into two groups: those with multiple small (<5 mm) gallbladder stones or variable (≤5 mm and >5 mm) stones and those with large (>5 mm) stones only. The classification of stone size was confirmed by surgery in 95% of patients. Moreover, the presence of multiple small and variable gallbladder stones represented a risk factor for synchronous asymptomatic bile duct stones (9.5%) as compared with large stones only (2.5%). In another study, ultrasonography was found to have a positive predictive value (PPV) of 69% and a negative predictive value (NPV) of 78% for choledocholithiasis in patients suspected to have bile duct stones.<sup>13</sup> This compared with serum transaminase tests having predictive values of 68 and 93%, respectively. In comparison to elevated serum transaminases and/or increased amylase levels, ultrasonographic evidence of common bile duct dilatation (>7 mm) has been described to be the best predictor of choledocholithiasis.<sup>14</sup> Nonetheless, it is worth noting that almost half the patients with CBD stones do not have dilated ducts by ultrasonography, hence a negative study has limited value.<sup>15</sup>

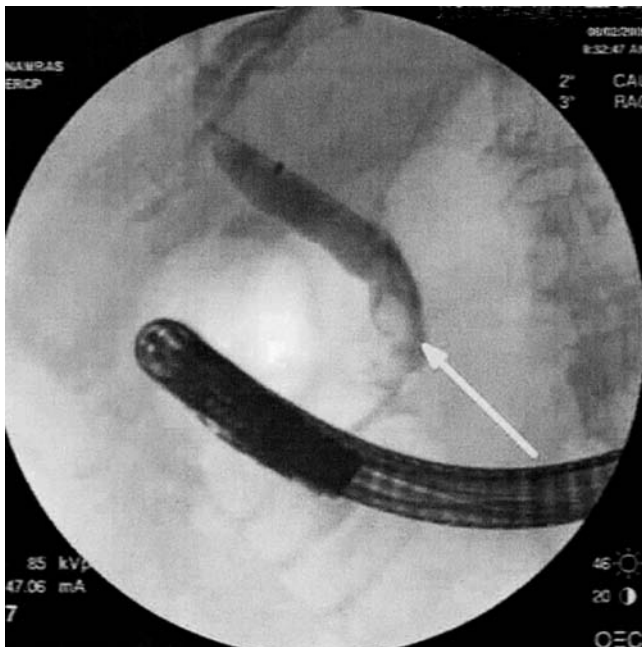In order to predict the presence of bile duct stones more accurately, the combination of clinical, laboratory, and ultrasound risk factors has been used by several investigators.<sup>1,16,17</sup> By multivariate logistic regression analysis, the combination of dilated CBD with evidence of stones by ultrasonography, clinical evidence of cholangitis, elevated aspartate transaminase and bilirubin, the likelihood of having stones in the bile duct was 99%.<sup>17</sup> In the absence of all four of these findings, the probability of synchronous choledocholithiasis in patients with cholelithiasis was only 7%.<sup>17</sup> Unfortunately,



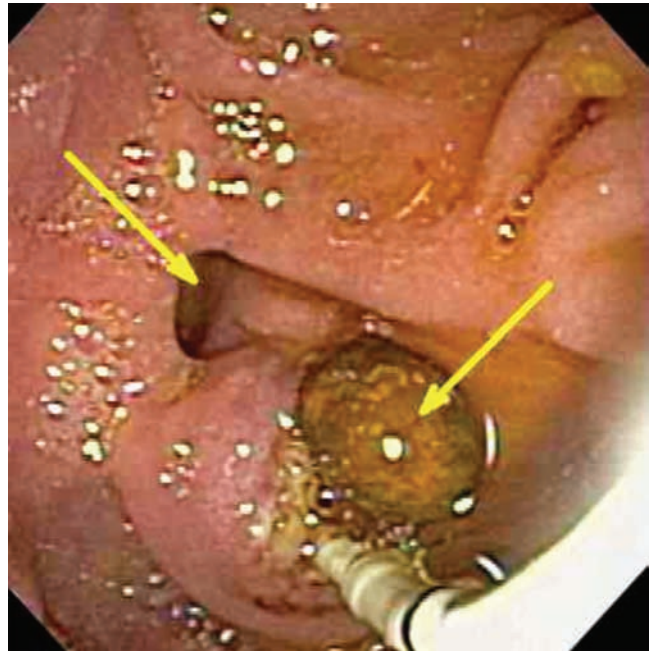
many patients present with only some of these findings, and the prediction of bile duct stones based on these criteria becomes difficult. Moreover, ultrasound sensitivity is in part operator-dependent and altered by bowel gas, making the findings inconsistent.<sup>18</sup>

In 1968, ERCP was introduced as a diagnostic tool to aid in the management of biliary and pancreatic diseases.<sup>19</sup> Five years later, with the development of endoscopic sphincterotomy, ERCP was transformed into a therapeutic modality.<sup>20</sup> Currently, more than 150,000 endoscopic biliary sphincterotomies are performed annually in the United States. Short of intraoperative examination, ERCP has long been considered the standard reference for the diagnosis of CBD stones.<sup>18</sup> The specificity and sensitivity of ERCP were reported in 1982 by Frey and colleagues.<sup>21</sup> ERCP was compared with findings on common duct exploration or cystic duct cholangiography in 72 patients and was found to have a sensitivity of 90%, specificity of 98%, and a 96% accuracy. Interestingly, the interval between performance of the procedure and operation was particularly important in patients with multiple small stones. Since small stones pass more readily from the gallbladder to the common duct and from the common duct to the duodenum, the longer the interval between ERCP and operation, the greater was the chance of discordant findings. With improvements in technique and better radiological equipment, ERCP certainly has improved over time.

Along with the ability to diagnose bile duct stones, ERCP has the advantage of offering therapeutic intervention options in the same setting of diagnosis (Figs. 49-1 and 49-2). That is, after stones in the bile duct are identified,



**FIGURE 49-1** Endoscopic retrograde cholangiopancreatography (ERCP) with distal common bile duct (CBD) stone prior to cholecystectomy.



**FIGURE 49-2** Endoscopic retrograde cholangiopancreatography (ERCP) and common bile duct (CBD) stone extraction.

endoscopic sphincterotomy and stone extraction can be performed at the same setting. If stones are not found, bile can be collected to test for microlithiasis if clinically appropriate.<sup>18</sup> ERCP *stone extraction* is successful 80–90% of the time using the techniques of sphincterotomy and balloon catheter or Dormia basket stone retrieval.<sup>20,22</sup> The addition of mechanical, electrohydraulic, laser, or extracorporeal shock-wave lithotripsy for large stones increases the success rate to over 95%.

*Sphincterotomy* entails division of the papilla and sphincter muscles to widen the distal end of the CBD with the use of a sphincterotome, a device consisting of a Teflon catheter with exposed cautery wire at the tip. The length of the intraduodenal part of the CBD limits the extent of the cut. *Balloon sphincteroplasty* is a sphincter-preserving alternative to sphincterotomy that uses a high-pressure hydrostatic balloon of either 6 or 8 mm diameter to dilate the papilla. One drawback of sphincteroplasty is the limited size of the papillary opening created as compared with sphincterotomy. Failure rates of 22% for stone extraction with balloon dilatation and the need for mechanical lithotripsy in 31% have been reported.<sup>22</sup> Furthermore, sphincteroplasty has been associated with a pancreatitis rate of 19 times greater than the rate associated with sphincterotomy.<sup>23</sup> A recent study evaluating the use of sphincteroplasty, on the other hand, found that severe pancreatitis only occurred in 1 patient out of 63, whereas the successful stone extraction rate was 84%.<sup>24</sup>

Once the sphincter has been divided, most stones can be removed using a Dormia basket or a balloon catheter. The Dormia basket has better traction than the balloon and consequently is recommended for larger stones (>1 cm). The balloon catheter occludes the bile duct lumen after inflation

and therefore is useful for removal of small stones and gravel. The catheter also can be inserted over a guidewire, making it useful for intrahepatic duct stones. Three situations that may lead to a difficult extraction are stone size greater than 1.5 cm, stone location proximal to a stricture, and multiple stones that are impacted. Alternative approaches to these situations include mechanical lithotripsy, electrohydraulic or laser lithotripsy, and extracorporeal shock wave lithotripsy. Mono-octanoin and methyl tertiary butyl ether (MTBE) have been used in the past to dissolve bile duct stones through nasobiliary drainage catheters or T-tubes. The practice largely has been abandoned because of high complication rates, poor results, and the technical difficulty of performing the dissolution.<sup>22</sup>

*Mechanical lithotripsy* is the most commonly used and simplest means of fragmenting large bile duct stones or when a significant discrepancy between the stone size and the diameter of the exit passage exists.<sup>25</sup> A large, strong basket is used to trap the stone. The stone then is crushed against a metal sheath by applying tension to the wires by the use of a crank handle. Reimann and colleagues first described the technique in 1982, and since then, many variations in design have become available.<sup>26,27</sup> When stones are extremely large, repeat application of the technique may be needed to further break the stone fragments and thus allow removal. Success rates between 80 and 90% have been reported for clearing the bile duct using the procedure.<sup>28–30</sup> One retrospective study of 162 patients undergoing mechanical lithotripsy found that the probability of bile duct clearance was over 90% for stones less than 1 cm diameter versus 68% for stones greater than 2.8 cm diameter.<sup>31</sup> Garg and colleagues recently presented data on 87 patients with stones greater than 1.5 cm that required mechanical lithotripsy.<sup>32</sup> They analyzed various predictive factors, including size and number of stones, stone impaction, serum bilirubin, presence of cholangitis, and bile duct diameter, in relation to the success or failure of lithotripsy. Impaction of the stones in the bile duct was found to be the only significant factor that predicted failure of mechanical lithotripsy and subsequent bile duct clearance. The composition of the stone also has been found to affect the success of stone removal. Soft stones, such as those found in Oriental cholangitis, are large but amenable to crushing, sometimes even with the Dormia basket.<sup>25</sup> However, calcified stones are hard and resist mechanical crushing.

When mechanical lithotripsy fails, *intraductal shock wave lithotripsy* can be performed using a cholangioscope that is inserted into the bile duct through the instrument channel of the duodenoscope. A flexible lithotripsy probe then is passed into the bile duct through the working channel of the cholangioscope. Shock waves are generated at the tip of the lithotripsy probe using electrical (*electrohydraulic lithotripsy*) or light energy (*laser lithotripsy*).<sup>22</sup> Impulses are fired on the surface of the stones under cholangioscopic guidance until the needed fragmentation is achieved. The main risk of intraductal shock wave therapy is bile duct injury resulting from a misguided shock wave. The avoidance of this complication makes cholangioscopic guidance necessary. Newer

devices have a scattered light sensor located at the tip of the probe that allows automatic interruption of the laser pulse when tissue is detected. Nevertheless, the cost of intraductal shock wave lithotripsy and the requirement for two endoscopists experienced in the mother-baby scope system makes the availability of this technique limited to a few major referral centers.<sup>22</sup> Success rates of electrohydraulic and laser lithotripsy have been in the 80–95% range.<sup>33</sup> In a recent report by Arya and colleagues, the use of electrohydraulic lithotripsy was evaluated in 94 patients, with 81 having large stones and 13 having average-sized stones located above a narrow bile duct.<sup>34</sup> A total of 96% had successful fragmentation of their stones, with fragmentation failure secondary to hard stones in two patients and trouble with targeting in two patients. Seventy-six percent of the patients required one treatment session, 14% needed two sessions, and 10% underwent three or more treatments. Complications included cholangitis and/or jaundice in 13 patients, hemobilia in one, mild post-ERCP pancreatitis in one, biliary leak in one, and bradycardia in one patient. No deaths were reported, and the final stone clearance achieved was 90%.

Not approved for bile duct stones in the United States, *extracorporeal shock wave lithotripsy* (ESWL) has gained popularity in Europe and Japan for the treatment of bile duct stones in patients with major medical comorbidities and technical difficulties encountered using the standard methods of endoscopic stone extraction. A drawback with this technique is the need for multiple sessions to achieve complete stone fragmentation.<sup>22</sup> There have been several reports from various countries on ESWL to break down bile duct stones.<sup>33,35–41</sup> Shackman and colleagues, from Germany, reviewed their experience with 313 patients who had failed endoscopic stone extraction with mechanical lithotripsy and subsequently underwent high energy extracorporeal shock wave lithotripsy.<sup>35</sup> Stone targeting was performed by either fluoroscopy (99%) or ultrasonography. Using the technique, complete clearance of the bile duct was achieved in 90% of the patients, with 80% requiring fragment extraction by endoscopy after the shock wave therapy. Spontaneous passage, however, was observed in 10% of the patients. No difference in outcome was noted with regard to size or number of stones, intrahepatic or extrahepatic stone location, or presence or absence of bile duct strictures. Four cases of cholangitis and one case of acute cholecystitis were the rare adverse effects noted. Conversely, a study from Switzerland found that in their 54 patients treated with extracorporeal shock wave therapy for difficult bile duct stones, an intrahepatic location of stones was significantly associated with treatment failure.<sup>37</sup> Interestingly, the study found microhematuria in 95% of the patients treated. In a randomized, prospective study to evaluate ESWL versus laser-induced shock wave lithotripsy for retained bile duct stones, laser therapy achieved stone disintegration more rapidly and with significantly fewer treatment sessions, resulting in a lower cost for therapy.<sup>39</sup> Yasuda and colleagues, from Japan, presented the use of ESWL without preliminary endoscopic sphincterotomy for choledocholithiasis.<sup>42</sup> Fifty-two patients underwent

endoscopic nasobiliary tube insertion followed by extracorporeal therapy. Fragmentation and complete clearance of stones were achieved in 67% without the need for additional treatment. In 25%, fragmentation was not achieved, and endoscopic extraction was required. A favorable response to extracorporeal shock wave therapy was noted in patients with smaller (<1.5 cm) floating stones.

In addition to lithotripsy, *large-balloon dilatation* of the distal bile duct has been reported as a means of removing difficult bile duct stones after standard extraction has been unsuccessful.<sup>43</sup> In a retrospective analysis, 58 patients who failed standard sphincterotomy and standard basket or balloon extraction underwent dilation with a 10–20-mm-diameter balloon (esophageal type) followed by standard basket or balloon extraction. The patients were divided into two groups: 18 patients with a tapered distal bile duct (group 1) and 40 patients with square, barrel-shaped, and/or large (>15 mm) stones (group 2). Stone clearance was successful in 89% of group 1 patients and 95% of group 2 patients. In the two patients in each group in whom extraction was not possible after dilatation alone, mechanical lithotripsy allowed for stone removal. Complication rates were 33% for group 1 and 7.5% for group 2. Complications included mild pancreatitis (two patients), mild cholangitis (two patients), and bleeding (five patients). Although bleeding was mild in two patients, moderate bleeding was noted in three patients in group 1 and was treated without surgery. Interestingly, hyperamylasemia was noted in all patients, and perforation was seen in none. Large-balloon dilatation offers an alternative in managing difficult bile duct stones, and further studies are needed to establish its role as compared with other lithotripsy options.

The management of complicated situations of choledocholithiasis may require several procedures or several sessions of the same procedure for successful clearance of the common bile duct. In such situations, partial stone impaction may lead to biliary stasis and cholangitis. Along with the administration of broad-spectrum antibiotics to cover gram-negative and gram-positive bacteria, it is important to decompress the biliary tree with either a nasobiliary catheter or a biliary stent as a temporizing measure pending more definitive treatment.<sup>22,25</sup> By doing this, serum bilirubin levels are allowed to decrease, and the rate of postprocedure cholangitis becomes similar to that after stone clearance. Interestingly, up to 30% of patients in whom a stent has been left in place for large stones have spontaneous disintegration of the stones, as noted on subsequent ERCP.<sup>25</sup> This may be secondary to the frictional movement of stone against the stent or as a result of improved bile flow with dissolution effects. Furthermore, by adding oral ursodeoxycholic acid to stent placement, 9 of 10 patients have been reported to become stone-free by this combination as compared with 0 of 40 with stent placement only.<sup>44</sup> Although long-term stent placement is an unconventional management option for patients with large, inextricable stones who are at high risk for surgical intervention, this approach should be used with caution. In a long-term follow-up study of 58 elderly patients, 40% of patients treated with permanent stents for endoscopically irretrievable

stones developed 34 complications in 23 patients, with cholangitis being the most frequent.<sup>45</sup> At median follow-up of 36 months, 44 patients had died, 9 as a result of biliary-related causes. Hui and colleagues prospectively evaluated 36 high-risk patients with difficult common bile duct stones.<sup>46</sup> Of these, 19 underwent stent placement, and 17 underwent complete stone clearance with electrohydraulic lithotripsy. The actuarial incidence of recurrent acute cholangitis was 8% in the lithotripsy group versus 63% in the stent group. The actuarial mortality also was higher in the stent group compared with the lithotripsy group, 74 and 41%, respectively.

Although ERCP has developed over the years as a relatively safe endoscopic diagnostic and therapeutic tool, there are well-defined, potentially severe, and life-threatening complications associated with it. The reported rates of complications vary widely in different studies, and this may be related in part to study design, with retrospective studies being prone to under-reporting. Furthermore, the complication rates may diverge depending on the patient mix in the study and may be influenced in part by the definitions used for these complications.<sup>19</sup>

The mortality rate after diagnostic ERCP is about 0.2%, and this rate is more than doubled by therapeutic interventions, to 0.5%.<sup>18,19</sup> Cardiopulmonary complications are the leading cause of death and include cardiac arrhythmia, hypoventilation, and aspiration. These may be the result of premonitory conditions or related to medications used during sedation and analgesia. Other significant complications include perforations (0.3–0.6%), bleeding related primarily to sphincterotomy (0.8–2%), cholecystitis (0.2–0.5%), and cholangitis (1%). In a recent meta-analysis, prophylactic antibiotics were not found to be beneficial in reducing infectious complications of ERCP. Moreover, another study failed to show a decrease in the rate of cholangitis in patients with distal bile duct stones or biliary strictures receiving antibiotic prophylaxis.<sup>19</sup>

Pancreatitis is the most common complication seen after ERCP. The consensus definition for ERCP-induced pancreatitis is new or worsened abdominal pain, serum amylase that is greater than three times the upper limits of normal at 24 hours postprocedure and a requirement of at least 2 days of hospitalization. Although the transient elevation of serum pancreatic enzyme levels is frequent, based on the consensus definition of ERCP pancreatitis, the expected rate of this complication is typically between 1 and 7%. Risk factors associated with ERCP-induced pancreatitis include a prior history of ERCP pancreatitis, nondilated biliary ducts, normal bilirubin, young age, female gender, and suspected sphincter of Oddi dysfunction. In fact, the risk of pancreatitis in women with normal bilirubin and suspected sphincter of Oddi dysfunction is 18% compared with 1.1% for the low-risk patient.<sup>19,47</sup> Moreover, one of five episodes of pancreatitis in this setting will be severe, requiring more than a 10-day hospital stay and/or resulting in necrosis, pseudocyst, or abscess formation needing surgery or percutaneous drainage, or death. Since the highest rate of complications appears to exist in the group of patients that is least likely to benefit from



ERCP, the most effective method of reducing post-ERCP pancreatitis would be to avoid unnecessary ERCP.

Pharmacologic methods of pancreatitis prophylaxis have been attempted to reduce this complication after ERCP.<sup>19</sup> Although meta-analyses have suggested that somatostatin and gabexate are useful in reducing pancreatitis rates, multicenter randomized, controlled trials have failed to show effect over that of placebo. Meanwhile, interleukin 10 (IL-10) with its anti-inflammatory activity has been found to have conflicting results in two controlled, prospective trials. The use of non-ionic contrast agents has not reduced the rate of pancreatitis. On the other hand, glyceryl trinitrate (GTN) administered by both sublingual and transdermal routes has been shown to decrease post-ERCP pancreatitis in two placebo-controlled trials, supposedly by decreasing sphincter of Oddi pressure. Use of nitrates, however, is limited by their hypotensive effects.

The placement of pancreatic stents has been found to reduce the incidence of postbiliary sphincterotomy pancreatitis in patient suspected of sphincter of Oddi dysfunction. However, in a case-controlled evaluation of pancreatic stent placement after balloon dilatation of the major papillae for bile duct stone removal, a decreased postprocedure hyperamylasemia did not result in a decreased pancreatitis rate.<sup>19</sup>

Based on clinical, laboratory, and ultrasound criteria for common bile duct stones, up to 70% of patients may be found not to have duct stones at the time of preoperative ERCP.<sup>17,48,49</sup> Given this, a large number of patients may be subjected to an unnecessary ERCP and suffer its risks and costs. Several methods have become available to diagnose the presence of bile duct stones accurately prior to having patients undergo ERCP or operative interventions. The most important of these are magnetic resonance cholangiopancreatography (MRCP), endoscopic ultrasound (EUS), and computed tomography (CT).

Sensitivities of conventional CT for choledocholithiasis in the setting of suspected bile duct stones is 76–90%, whereas unenhanced helical CT has been shown to have a sensitivity of 88%, a specificity of 97%, and an accuracy of 94%.<sup>18</sup> When compared with ERCP as the reference standard, CT without biliary contrast material showed poor concordance with ERCP (sensitivity 65% and specificity 84%) but compared better when oral biliary contrast material was given (sensitivity and specificity greater than 90%).<sup>50</sup> CT with intravenous (IV) biliary contrast material in other studies has been found to have a sensitivity of 71–85% and a specificity of 88–95%.<sup>50</sup> Patel and colleagues reported a comparison between noncontrast-enhanced helical CT and the reference standard of EUS and found that CT had both a sensitivity and a specificity of 83% for the detection of common bile duct dilatation in the setting of choledocholithiasis.<sup>51</sup> However, when CT was evaluated for identifying duct stones, it had a sensitivity of only 22% and a specificity of 83%.

Since its introduction over a decade ago, MRCP has significantly influenced the way in which CBD stones are detected and excluded. With sensitivities and specificities that approach those of ERCP, MRCP has emerged as a

diagnostic alternative to ERCP for the detection and exclusion of choledocholithiasis.<sup>18</sup> Performed with T<sub>2</sub>-weighted sequences, the biliary tract is seen as a bright structure with high-signal intensity without the use of contrast material, instrumentation, or ionizing radiation. Common duct stones are seen as low-signal-intensity filling defects surrounded by high-intensity bile. Improvements in hardware and software for MRCP over the past decade have resulted in the ability to image the entire biliary tract in a single breath-hold of 20 seconds with a resolution that allows visualization of fourth-order intrahepatic bile ducts and small stones. Stones as small as 2 mm can be detected even in the absence of biliary dilatation.<sup>18</sup> In one study of 97 patients, sensitivity of MRCP was 100% for stone diameters of 11–27 mm, 89% for stone diameters of 6–10 mm, and 71% for stone diameters of 3–5 mm.<sup>47</sup> In this study, MRCP had a 91% sensitivity compared with 100% for ERCP, whereas both tests had a specificity of 100%. Although earlier studies reported MRCP sensitivities ranging from 81 to 92% and specificities from 91 to 100% for choledocholithiasis, recent studies with state-of-the-art techniques have found sensitivities of 90–100% with specificities of 92–100%.<sup>18</sup> In a prospective analysis by Ke and colleagues, 267 patients felt to have CBD stones were evaluated by MRCP and ERCP.<sup>52</sup> MRCP was found to have a sensitivity of 100%, a specificity of 96%, and a NPV of 100%. Kejiwal and colleagues retrospectively examined patients with cholelithiasis who underwent MRCP for suspected choledocholithiasis.<sup>53</sup> Patients were considered not to have clinically relevant common duct stones if they had a negative MRCP and did not present for readmission for choledocholithiasis after treatment of their cholelithiasis. MRCP was negative for bile duct stones in 74% of patients (60 of 81) and missed clinically relevant stones in two patients, resulting in a PPV of 95% and a NPV of 97%. With its ability to exclude bile duct stones, MRCP may allow the avoidance of unnecessary diagnostic ERCP. Demertines and colleagues found that even in patients with high and moderate risk of common bile duct stones based on laboratory findings, the performance of MRCP could have resulted in the avoidance of ERCP in 52 and 80% of patients, respectively.<sup>54</sup>

One of the limitations of MRCP is that its resolution remains less than that of ERCP, and therefore, it cannot detect small stones and crystals consistently. Claustrophobia also may influence the use of MRCP, and patients may need sedation or even general anesthesia for its performance. Open magnetic resonance imaging (MRI) may soon alleviate this problem. Patient obesity may diminish the quality of images, whereas morbid obesity, pacemakers, and aneurysm clips preclude entry into the scanner.<sup>18</sup> Conversely, ERCP may be limited by an inability to access and cannulate the papilla and opacify the ductal system. Failed ERCP rates vary greatly among endoscopists and vary from 5 to 20%.<sup>18</sup> Moreover, alterations in the gastrointestinal tract anatomy, such as a Billroth II gastrojejunostomy, may preclude access to the ampulla. MRCP offers a method of evaluating the biliary system for bile duct stones with sensitivities and specificities that approach those of ERCP in a manner that is noninvasive

and avoids the risks and limitations of ERCP. Patients with a positive MRCP then may be considered for more invasive therapeutic procedures.

Another sensitive method of evaluating the biliary system for common bile duct stones is EUS. EUS has been shown to have a diagnostic accuracy of 95% for bile duct stones.<sup>55</sup> With the high ultrasound frequencies used (7.5 and 12 MHz), EUS has a resolution of less than 1 mm, making it the best imaging technique available for the extrahepatic biliary tract. Several studies have found EUS to be similar to ERCP in sensitivity and specificity for the evaluation of choledocholithiasis, with some showing ERCP to be better and others showing EUS to be better.<sup>50</sup> Compared with ERCP, EUS is semi-invasive with almost no procedure-related complications and a negligible failure rate. In fact, several series comprising over 1000 patients have reported no complications.<sup>55</sup> In a prospective study by Buscarini and colleagues, 485 patients suspected to have choledocholithiasis based on clinical, laboratory, and ultrasound, or CT findings underwent EUS.<sup>55</sup> Positive EUS findings were confirmed by surgery or ERCP with sphincterotomy; negative findings were confirmed by clinical follow-up of at least 6 months. EUS findings were verified in 463 patients as follows: 237 true positive, 216 true negative, 2 false positives, and 4 false negatives, and in 4 patients EUS was incomplete (sensitivity 98%, specificity 99%, PPV 99%, NPV 98%, accuracy 97%). No complications were noted in the study. EUS offers higher resolution than MRCP and therefore is better able to detect small stones. It is able to identify bile duct stones as well as microlithiasis and is able to detect pathology that is not seen by ERCP. EUS prior to performing invasive diagnostic or therapeutic techniques would lower the rate of procedure-related complications in patients suspected of having bile duct stones. Cost analysis of EUS followed by ERCP versus ERCP alone is also in favor of EUS as a pretherapeutic procedure.<sup>55</sup>

In patients for whom ERCP is not available, not possible secondary to anatomic considerations, or not successful, an alternative method of cholangiography and nonsurgical therapy is *percutaneous transhepatic cholangiography* (PTC) followed by transhepatic methods of stone removal. A needle is introduced into the intrahepatic bile ducts through the skin, and a cholangiogram is performed, followed by wire insertion and then a catheter over the wire for external biliary drainage and access to the biliary system. The method was introduced in Denmark in the 1970s and has been refined over the years with the addition of several therapeutic options.<sup>56</sup> This technique is particularly useful for evaluating intrahepatic stones or other proximal bile duct disease. After diagnosis of bile duct stones, several therapeutic options are available through the percutaneous route. In 1981, the removal of an 8-mm common bile duct stone by percutaneous transhepatic technique was reported by Fernstrom and colleagues.<sup>57</sup> In 1990, Stokes and colleagues, from Boston, reported a series of 53 patients in whom surgery was contraindicated and ERCP unsuccessful.<sup>58</sup> By inserting a modified Dormia basket via a percutaneous transhepatic route, stones were advanced whole or after fragmentation into the duodenum. Mono-octanoic or MTBE

were used in 30 patients to reduce stone size or remove debris. Morbidity and mortality were 12 and 4%, with a success rate of 93%. Transhepatic cholangioscopy and lithotripsy can be performed after PTC and dilatation of the intrahepatic channel with success rates of 90–100% and 5–8% complications.<sup>59</sup> In a series of 12 patients with bile duct stones, PTC in combination with laser or electrohydraulic lithotripsy to deliver stone fragments into the duodenum was found to be successful in all the patients.<sup>60</sup> In another series of 13 patients, laser lithotripsy was used with percutaneous cholangioscopy performed either transhepatic (12 patients) or through the T-tube track.<sup>61</sup> Stone fragmentation was successful in 92%, and stone clearance was possible in all patients. However, 11 patients required the addition of sphincterotomy (either by ERCP or by antegrade method with fluoroscopic monitoring) or stent insertion. Bleeding in two patients accounted for a 15% severe complication rate. Percutaneous transhepatic papillary balloon dilatation was reported recently by a Japanese group for the management of choledocholithiasis.<sup>62</sup> In the five patients in whom the method was used, bile duct stones were able to be pushed into the duodenum in all, with no complications or deaths. Ponchon and colleagues reported percutaneous choledochoscopy for stone extraction in 75 patients, with the transhepatic route used in 48 patients and T-tube tract used in 27 patients.<sup>63</sup> Complete clearance of bile duct stones was accomplished in 69 patients (92%).

#### Role of Cholecystectomy Following CBD Stone Extraction.

After bile duct clearance is achieved by nonoperative methods, cholecystectomy generally is recommended in younger patients to decrease the risk of future cholecystitis and recurrent biliary colic. As many as 24% of patients have been found to require cholecystectomy at follow-up after endoscopic papillotomy at an average of 14 months.<sup>64</sup> Others have argued that sphincterotomy results in gallbladder stasis, bacterial overgrowth, and an increase in bile acids, and these may increase the risk of gallbladder cancer in 10–20 years.<sup>2</sup> On the other hand, Dhiman and colleagues studied the changes in gallbladder emptying and lithogenicity of bile following endoscopic sphincterotomy in patients with choledocholithiasis and gallbladder in situ.<sup>65</sup> Sphincterotomy was found to decrease stasis of gallbladder bile, improve gallbladder emptying, and decrease the lithogenicity of bile as measured by prolongation of nucleation time. Meanwhile, there is much evidence to support leaving the gallbladder in situ after bile duct clearance in high-risk or elderly patients.<sup>66–75</sup> In a study of 191 patients (median age 76 years) in whom the gallbladder was left in situ post-ERCP, only 10 patients (5%) required subsequent uneventful cholecystectomy.<sup>69</sup> Twenty-six percent (49 patients) died during the review period from nonbiliary pathology. Kwon and colleagues followed 146 patients without elective cholecystectomy after endoscopic CBD stone removal for a period of 3 months or more to see if they could identify factors that predict subsequent gallbladder-related symptoms and need of cholecystectomy.<sup>71</sup> Fifty-nine patients had cholelithiasis, whereas 87 patients had no gallbladder stones. During a

mean follow-up of 24 months, seven patients (5%) underwent cholecystectomy, on average, 18 months after ERCP as a result of acute cholecystitis (four patients), biliary pain (two patients), and acute pancreatitis (one patient). Nine patients (6%) died of causes unrelated to biliary disease. Interestingly, Cox regression analysis revealed that the need for subsequent cholecystectomy did not correlate with age, sex, presence of gallbladder stones, number of gallbladder stones, or underlying disease. Kullman and colleagues found that at a median observation time of 42 months, cholecystectomy was needed in 11% (13 patients) of 118 patients with a gallbladder in situ after ERCP bile duct clearance.<sup>72</sup> Forty-nine patients (42%) died within 2–87 months after ERCP during the follow-up period. In another study of 33 elderly patients who were followed for an average of 42 months with gallbladder in situ after successful ERCP for choledocholithiasis, 3% (one patient) required cholecystectomy for acute cholecystitis, and 6% (two patients) had mild right upper quadrant pain, whereas 91% remained asymptomatic.<sup>73</sup> Over the course of the study, 30% of the patients died from nonbiliary causes. The impact of gallbladder status on patient outcome after ESWL for complicated CBD stones was studied by a German group.<sup>70</sup> One-hundred twenty patients with an average age of 68 years (range 28–86 years) were followed for 3–9 years (mean 4 years). Thirty-seven had their gallbladder in situ, 27 had had a cholecystectomy after ESWL, and 56 had already undergone cholecystectomy prior to diagnosis of choledocholithiasis. During the follow-up period, 30% (36 patients) experienced biliary symptoms. However, there was no significant difference in the incidence of these symptoms between the three groups. Repeat ERCP revealed 28 cases of recurrent bile duct stones. Although not reaching statistical significance ( $p = .077$ ), the recurrences occurred more often in the cholecystectomy groups. Given the multiple studies supporting leaving the gallbladder in situ after CBD clearance, it seems reasonable to perform cholecystectomies on high risk or elderly patients as needed rather than prophylactically following nonoperative treatment of bile duct stones.

## INTRAOPERATIVE

When patients present to the operating room for cholecystectomy, they may either have CBD stones confirmed by preoperative studies (eg, ERCP, MRCP, or EUS), or they are suspected to have CBD stones by clinical presentation, laboratory values, or transabdominal ultrasound, or they have no suspicion of bile duct stones. At the time of surgery, *intraoperative cholangiography* (IOC) is the method used most often to establish the presence of bile duct stones. IOC was first introduced to open biliary surgery by Mirizzi in the 1930s.<sup>76</sup> With the universal acceptance of laparoscopic cholecystectomy as the treatment of choice for symptomatic gallbladder stones, laparoscopic IOC has developed into a very useful method to evaluate the biliary tree. The technique may be performed by injecting contrast material through a catheter introduced into the cystic duct via a variety of techniques.<sup>78</sup> 14-gauge IV catheter placed through the abdominal wall 3 cm medial to the

midclavicular port.<sup>77</sup> Cannulation rates with successful cholangiography are from 75 to 100%, and the use of fluoroscopy has become standard because it is faster, more detailed, and allows real-time surgeon interaction.<sup>77,78</sup> The reported sensitivity, specificity, PPV, NPV, and accuracy for laparoscopic cholangiography are 80–90%, 76–97%, 67–90%, 90–98%, and 95%, respectively, and these are comparable with the values for open IOC.<sup>76</sup> The rate of false-positive IOC results in a recent large review was found to be 0.8% (34 of 4209 patients).

Although approximately 10–15% of patients undergoing laparoscopic cholecystectomy harbor CBD stones, the need for routine IOC is a matter of much debate.<sup>79</sup> In a large Medline literature review, Metcalfe and colleagues found a 4% rate of CBD stones in eight laparoscopic cholecystectomy trials in which routine IOC was performed on 4209 patients without suspected bile duct stones preoperatively.<sup>78</sup> This finding was felt to be consistent with previous reviews. On the other hand, in a total of 5179 patients without suspicion for bile duct stones that did not undergo IOC during laparoscopic cholecystectomy, 32 (0.6%) proceeded to develop symptoms from residual bile duct stones. By extrapolating this data, it would seem that of the 4% of patients with silent CBD stones at laparoscopic cholecystectomy, only 15% go on to develop symptoms from retained stones. In other words, 167 IOCs would have to be performed during laparoscopic cholecystectomy in order to detect one CBD stone that would go on to cause symptoms in patients without preoperative evidence of duct stones. This would result in eight unnecessary bile duct explorations or ERCPs.<sup>78</sup> It is possible that stones that are not manifested preoperatively are of the size that can pass spontaneously into the duodenum, never presenting with symptoms.

*Intraoperative ultrasound* (IOUS) is a noninvasive way to evaluate the biliary system at the time of surgery. First introduced in the mid-1980s in the time of open cholecystectomy, laparoscopic IOUS came into use in the mid-1990s.<sup>76</sup> Recent experience with laparoscopic IOUS has suggested that it is a very sensitive test for CBD stones and roughly equivalent to IOC in evaluating the biliary ductal system. Moreover, it lacks the potential of common bile duct injury that exists with placement of the cholangiography catheter during IOC and will not cause a false-positive test owing to air introduced into the biliary tree.<sup>78</sup> The use of laparoscopic IOUS has been limited, however, possibly secondary to equipment availability and cost, as well as the expertise and experience required for its use. There appears to be a considerable learning curve associated with the use of laparoscopic IOUS.<sup>80,81</sup>

Once the presence of CBD stones has been established at the time of surgery, there are several treatment options. Depending on local availability and expertise, these may include open or laparoscopic duct exploration and post-cholecystectomy nonoperative techniques such as ERCP or PTC. However, before embarking on a means of eradicating the biliary tree of stones, it is worth remembering that only 15% of patients with silent bile duct stones at the time of cholecystectomy present with symptoms of retained stones.<sup>78</sup>



The natural history of choledocholithiasis was revisited in a recent prospective study by Collins and colleagues.<sup>82</sup> Operative cholangiography was attempted in 997 patients undergoing laparoscopic cholecystectomy and was successful in 962 patients. Patients with cholangiogram-positive stones were restudied in 48 and 72 hours and 6 weeks after laparoscopic cholecystectomy through a cystic duct cholangi catheter left in the cystic duct at the time of surgery. Of the 962 patients, 46 (4.6%) had at least one filling defect, but 12 had normal cholangiograms 48 hours later, giving a 26% possible false-positive cholangiogram rate. At 6 weeks, a further 12 patients had a normal cholangiogram, giving a 26% spontaneous passage rate of bile duct stones. This spontaneous passage was not predictable by either the number or size of stones or the diameter of the bile duct. Only 2.2% of the total population (22 patients) required postoperative endoscopic retrograde cholangiopancreatographic retrieval of persistent common duct calculi. **Thus a treatment decision based on the findings of IOC alone would have resulted in 52% of patients with positive findings undergoing unnecessary intervention.**

The first surgical exploration of the CBD was done in 1890 by Ludwig Courvoisier, a Swiss surgeon who made an incision in the CBD and removed a gallstone.<sup>77,83</sup> Prior to the development of laparoscopic cholecystectomy, patients found to have bile duct stones at surgery underwent *open CBD exploration* with greater than 90% successful duct clearance. ERCP was used for retained stones postoperatively or for patients who would not be able to tolerate extended general anesthesia. At the time of open cholecystectomy, the common duct is opened in the longitudinal direction so as to not compromise the blood supply to the duct. The bile duct is cleared of stones with the use of Fogarty balloons, saline irrigation, stone forceps, and scoops placed into the biliary tract through the opening. Choledochoscopy is particularly useful in evaluating the duct system during and after the clearance of residual stones and in making sure that there is no other ductal pathology. Moreover, a basket can be passed through the working channel of the scope and used under direct vision for stone removal. Although used commonly in the management of CBD stones in the era of open cholecystectomy, open bile duct exploration is used infrequently in the present age of minimally invasive surgery. In a recent series of 326 patients who underwent laparoscopic common bile duct exploration (LCBDE) for choledocholithiasis at the time of cholecystectomy, only five patients were converted to laparotomy and only two for open bile duct exploration and stone extraction.<sup>77</sup>

Over a hundred years after Langenbuch performed the first open cholecystectomy in 1882, laparoscopic cholecystectomy was introduced and soon became the standard treatment of cholecystitis and symptomatic gallstones.<sup>77,83</sup> In the early years after the development of laparoscopic cholecystectomy, LCBDE was used infrequently, and reliance on alternative methods of duct clearance was widespread.<sup>77</sup> With increasing experience in laparoscopic techniques and the demand for single-procedure minimally invasive duct clearance, the use of

LCBDE gained greater acceptance among experienced biliary surgeons. Since the development of the technique, thousands of successful LCBDEs have been reported in the literature, and success rates of duct clearance are between 80 and 90%, comparable with the open method of bile duct exploration.<sup>76</sup> The morbidities range from 8 to 10% and are typical of laparoscopic procedures, including nausea, diarrhea, ileus, atelectasis, phlebitis, urinary retention and infection, biliary leak, dislodgement of the T-tube, fluid collections, pulmonary embolus, and myocardial infarctions. Reported mortalities are from 0 to 2%.

The technique of LCBDE has been well described by Petelin.<sup>76,77</sup> Access to the biliary system, after obtaining a cholangiogram, can be either transcystic or transductal using a choledochotomy. Use of the transcystic approach varies from 5 to 98% depending on the series. With this method, the gallbladder is retracted toward the right hemidiaphragm, and if needed, the cystic duct is dilated with either over-the-wire mechanical or pneumatic dilators. The transductal approach is favored for stones greater than 6 mm in diameter, intrahepatic stones, cystic duct diameter less than 4 mm, and cystic duct entrance either posterior or distal. When using the transductal method, a choledochotomy is made on the anterior surface of the CBD with a scissors or scalpel and is limited to 1 cm or the size of the largest stone.

Once the biliary tree has been accessed, choledocholithotomy is performed using several different techniques and is guided by either fluoroscopy or choledochoscopy. Although separate monitors may be used with a choledochoscope, the use of a video mixer to place the laparoscopic and choledochoscopic images on the same screen is helpful. Newer choledochoscopes with 3 mm diameters even can be passed through the cystic duct. Common bile duct clearance is started with irrigation, which allows the flushing of small, less than 3-mm stones and sludge. The administration of 1–2 mg IV glucagon allows relaxation of the sphincter of Oddi and facilitates the irrigation process. Fogarty-type balloons (4F) then can be inserted into the bile duct for retrograde extraction of stones with withdrawal of the inflated balloon. Stones also may be captured with a Dormia-type basket inserted directly through the cystic duct or choledochotomy or through the working port of the choledochoscope. Intraoperative electrohydraulic or laser lithotripsy is useful for large stones or stones that are impacted and not responsive to other methods. Care is needed, however, to avoid injury to the duct by inaccurate application of the lithotripsy device.

If a choledochotomy is used to perform the LCBDE, a T-tube may be left in place for later study of the biliary system, decompression if the biliary tree was not cleared, or access to the biliary system for recurrent stones. On the other hand, laparoscopic suturing with 4-0 or 5-0 Vicryl can be done instead to close the choledochotomy primarily. A recent study found that hospital stay was shorter in a group of patients who underwent primary closure versus placement of a T-tube (5 vs 9 days).<sup>84</sup> There does not appear to be an increase in the incidence of bile leak or peritonitis in patients undergoing primary closure.<sup>77</sup> This further abrogates

the complications of T-tubes, including dislodgement, bacteremia, fracture of the tube, and the possibility of bile leak and peritonitis at the time of T-tube removal. An alternative to T-tube placement is a stent placed in an antegrade fashion into the duct similar to an ERCP-placed stent.<sup>85</sup> An alternative to a T-tube is a modified ureteral catheter placed through the cystic duct and brought out through the abdomen after closure of the choledochotomy.<sup>86</sup> In a study of 30 patients undergoing placement of this modified catheter, no complications related to the catheter were found, and removal was possible at a median of 5 days as compared with 29 days when a T-tube was used.

If LCBDE is unsuccessful, a transcystic catheter may be inserted through the abdominal wall to decompress the biliary system and allow for postoperative cholangiography. If the catheter is further advanced into the duodenum, it can aid in bile duct cannulation at the time of postoperative ERCP.<sup>76</sup> In addition to treating bile duct stones postoperatively following an incomplete laparoscopic duct clearance, the option of converting to an open duct exploration is also available to the operating surgeon.

There are several alternatives to laparoscopic or open duct exploration for bile duct stones encountered at the time of surgery. At the time of cholecystectomy, a *transcystic stent* may be placed over a wire antegrade through the sphincter of Oddi as initial treatment.<sup>87</sup> This allows for decompression of the biliary tree and can be followed postoperatively by ERCP and sphincterotomy with stent removal. Another option is the use of *intraoperative ERCP* (IO-ERCP), allowing the same anesthetic to be used for both the cholecystectomy and the ERCP.<sup>88–90</sup> In one Swedish study by Enochsson and colleagues, 592 patients underwent IOC during laparoscopic cholecystectomy.<sup>90</sup> Thirty-four of these were subjected to IO-ERCP with a 100% common bile duct cannulation rate. This was assisted by the fact that the surgeon, while waiting for the endoscopist, introduced a thin guidewire into the IOC catheter and through the sphincter of Oddi into the duodenum. Bile duct clearance was possible in 94%, and a stent was left in place in the two patients with remaining stones. Operative time was prolonged by 1.5 hours as compared with laparoscopic cholecystectomy, but the length of hospitalization was not significantly longer for IO-ERCP patients. There were no cases of postoperative pancreatitis. In a French report by Meyer and colleagues, 60 patients were treated with laparoscopic cholecystectomy and IO-ERCP for confirmed or suspected CBD stones.<sup>89</sup> The mean operative time for laparoscopic cholecystectomy was 60 minutes (range 40–90 minutes), and general anesthesia was prolonged only 40 minutes (range 30–60 minutes) for performing the IO-ERCP, including the time needed for setting up the endoscopic equipment. The papilla could not be catheterized in two patients. In one, postoperative ERCP was possible, and in the second patient, a small stone passed spontaneously. In one patient, secondary to multiple calculi in CBD, open surgery was performed immediately after IO-ERCP. Final duct clearance was achieved in 100% of patients. The argument for using IO-ERCP versus postoperative ERCP is that

the former allows the identification of anatomic problems (such as duodenal diverticulum) that could make later ERCP unsuccessful. Thus the surgeon has the option to convert to open bile duct exploration at the same anesthetic.<sup>88</sup> If one chooses to use IO-ERCP, performing the cholecystectomy prior to the ERCP is important because this avoids endoscopy-induced small bowel distension from interfering with gallbladder visualization. Moreover, transcystic IOC at the time of cholecystectomy may avoid unnecessary ERCP if no stones are visualized by the cholangiogram.

## POSTOPERATIVE

Patients presenting with CBD stones after cholecystectomy generally are treated with ERCP<sup>77</sup> (Fig. 49-3). The noninvasive imaging techniques, such as ultrasound and MRI, are not different from those used preoperatively. If a T-tube (or other transabdominal drainage catheter) had been left in place at prior surgery, a cholangiogram can be obtained after surgery to establish the presence of bile duct stones. In situations in which ERCP is not possible or successful, other nonoperative methods can be used. For patients with T-tubes, percutaneous instrumentation under fluoroscopic guidance through the T-tube tract can be used to remove bile duct stones. In one report, 23 of 25 patients underwent successful duct clearance through the T-tube tract for retained stones.<sup>91</sup> A choledochoscope also may be inserted through the T-tube tract to allow for either laser or electrohydraulic lithotripsy and stone extractions.<sup>63</sup> Other percutaneous transhepatic options described in the preoperative section of this chapter also may be used. Combinations and repeated techniques may be needed to achieve duct clearance. In the rare incidences

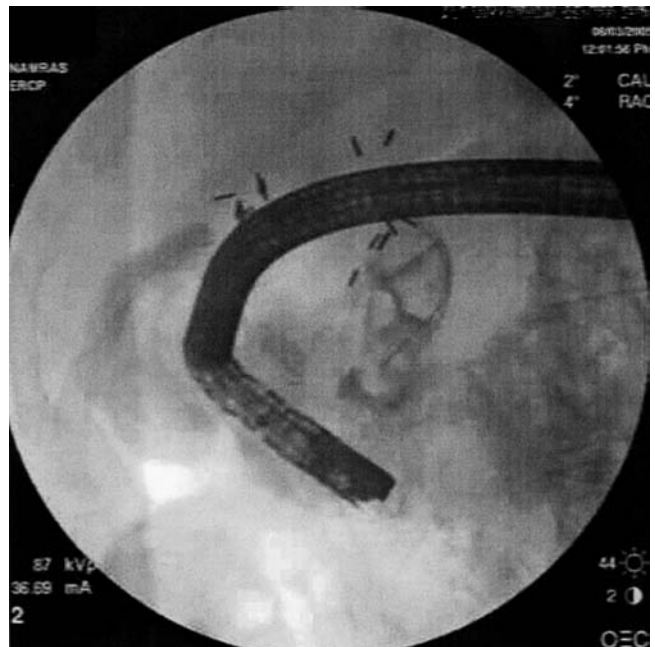


FIGURE 49-3 Multiple retained stones after cholecystectomy, seen on endoscopic retrograde cholangiopancreatography (ERCP).

where the biliary system cannot be cleared of stones nonoperatively, surgical duct exploration is considered, and the need for surgical drainage procedures must be addressed.

## SURGICAL BILIARY DRAINAGE PROCEDURES

Surgical biliary drainage procedures must be considered in situations of multiple stones; incomplete removal of all stones; impacted, irremovable distal bile duct stones; markedly dilated CBD; distal bile duct obstruction from tumor or stricture; and reoccurrence after previous bile duct exploration. The methods of surgical drainage include transduodenal sphincteroplasty, choledochoduodenotomy, and choledochojejunostomy (CDJ).

*Transduodenal sphincteroplasty* (TDS) is useful in the management of choledocholithiasis when there is stone impaction in the ampulla of Vater, papillary stenosis, and multiple stones, particularly in the presence of a nondilated bile duct.<sup>92-94</sup> The duodenum is Kocherized completely, and the ampulla is located by passing a biliary Fogarty catheter through the CBD into the duodenum. A longitudinal duodenotomy is made over the ampulla, and the entrance to the pancreatic duct is identified at the 4 o'clock position when possible. Intravenous secretin given at 0.2 g/kg over 1 minute sometimes is helpful in this identification. Absorbable sutures are placed on each side of the ampulla, and the sphincteroplasty is started at 11 o'clock and extended with sequential placement of sutures along the incision. After the opening is wide enough to fit a biliary dilator the size of the common duct, the last ampullary suture is placed at the apex to prevent a duodenal leak. The duodenotomy then is closed in the transverse direction to prevent duodenal stenosis, and a drain is left in the event that the duodenotomy leaks.

In a French review by Suter and colleagues, of the 78 patients who underwent transduodenal sphincterotomy, 26 were operated on urgently.<sup>94</sup> Forty-seven (60%) were jaundiced, 15 (19%) had pancreatitis, and 12 (15%) had cholangitis before surgery. Three patients died, one from pulmonary embolism, one from pulmonary sepsis, and the other from multiorgan failure syndrome complicating preoperative necrotizing pancreatitis. Of the 30 patients (38%) with complications, 20 were directly related to the surgery and included 4 cases of bleeding not requiring transfusion, 17 instances of hyperamylasemia with 1 case of clinical pancreatitis, and 1 case of duodenal fistula that healed after conservative therapy. No deaths were noted that were directly attributable to the TDS. In an older review by Meyhoff, a 10% postoperative mortality was noted after TDS, with four patients developing fatal pancreatitis.<sup>92</sup>

*Choledochoduodenostomy* (CDD) was first performed by Riedel in 1888 in Europe.<sup>95</sup> Unfortunately, the patient died of anastomotic disruption secondary to a missed stone in the distal CBD. The first successful operation was performed by Sprengel in 1891. CDD is indicated in patients with recurrent stones requiring repeated interventions, impacted or giant stones, biliary sludge, and ampullary stenosis. The funnel syndrome in which a distal bile duct stenosis exists in the

presence of CBD stones is one of the most classic indications for CDD.<sup>95</sup> Most of the CBD stones in this situation are primary biliary stones forming as a result of biliary stasis. Any procedure done to remove only the stones has a temporary benefit if the stenosis is not addressed.

CDD can be performed either as an elective or an emergency operation, such as for cholangitis. The side-to-side anastomosis is the most commonly used technique, but an end-to-side is also an option. A CBD diameter of at least 1.2 cm is important in assessing the feasibility of CDD because this allows a wide enough stoma to ensure good biliary drainage and avert stenosis. The anastomosis is created in the most distal portion of the bile duct to decrease the chance of the well-described sump syndrome.<sup>95</sup> After opening the abdomen, the duodenum is Kocherized widely to allow for a tension-free anastomosis, and the CBD is dissected completely along its distal anterior surface. A longitudinal duodenotomy is made close to the bile duct along the long axis of the duodenum, perpendicular to the choledochotomy. The CBD incision is made along the long axis of the bile duct as close to the duodenum as possible and of a 2 cm length to prevent stenosis. After performing a CBD exploration and clearing the duct of stones, a side-to-side single-layered anastomosis is made with absorbable suture, and a drain is placed for the possibility of an anastomotic leakage.

The morbidity and mortality rates associated with CDD are 23 and 3%, respectively.<sup>95</sup> Mortality is most commonly from medical complications, such as pulmonary embolism, myocardial infarction (MI), or heart failure. Among the specific operative morbidities, cholangitis and sump syndrome are described most commonly.

The incidence of cholangitis ranges from 0 to 6% in the largest long-term follow-up series.<sup>95</sup> Although once thought to be caused by ascending reflux of duodenal contents into the biliary tree, cholangitis is now believed to be the result of stenosis of the anastomotic stoma. A wide anastomosis avoids stasis and stone retention by allowing entrance and egression of duodenal and biliary contents. Sump syndrome is caused by food and debris accumulating between the stoma and the papilla of Vater. This leads to contamination of the large and small bile ducts with resulting recurrent cholangitis and even secondary biliary cirrhosis.<sup>95</sup> Although the accumulation of debris in the blind segment of the bile duct may cause destruction of the stoma or cholangitis, some believe that the disease is caused by stenosis of the stoma. To avoid the problem, creating a stoma of at least 14 mm, along with placing the anastomosis near the duodenum, is important. Stomal patency is felt to be the most important factor for preventing both cholangitis and sump syndrome.<sup>96</sup> Other complications of CDD include wound infection, anastomotic leak, and intra-abdominal abscess. Long-term studies reveal that 70-80% of patients are asymptomatic 5 years after surgery.<sup>95</sup> In a review of 126 patients undergoing CDD after CBD exploration over a period of 19 years, Deutsch and colleagues reported a 4% mortality rate, with all deaths occurring in patients over 70 years old.<sup>97</sup> Morbidity included wound infections in 18 patients (14%) and bile leak through a drain



for over 2 weeks in 4 patients (3%). Ninety-seven patients (94%) were symptom-free at a follow-up of 1–19 years.

Rameriz and colleagues reported their experience with CDD and transduodenal sphincterotomy for the treatment of choledocholithiasis over a period of 10 years.<sup>98</sup> Of the 591 patients who underwent choledochotomy for bile duct stones, 240 (40.6%) were treated with primary closure over a T-tube, 126 (21.3%) received primary closure over a T-tube along with a TDS, 216 (36.5%) had a supraduodenal CDD, and 9 (1.5%) had both a CDD and a TDS. CDD was performed when the bile duct was more than 12 mm in diameter, and TDS was used if a stone was impacted in the papilla and/or papillary stenosis was noted. Complications included six abdominal abscesses and three external biliary fistulas in the patients undergoing CDD and four abscesses and two episodes of acute pancreatitis in the patients treated with TDS. There was no difference in mortality between the two groups, and after a mean follow-up of 5.6 years, 71.5% of the CDD group and 75.2% of the TDS group were asymptomatic. Symptoms noted in the remainder included dyspepsia, colicky pain, and episodes of cholangitis and resulted in reoperations for residual stones in nine patients, six from the CDD group and three from the TDS group. The same authors previously reported that of the patients who presented with symptoms after CDD and underwent endoscopy, no problems at the anastomosis were noted in patients who presented with dyspepsia, whereas 27% of those with biliary colic had an anastomotic stenosis or sump syndrome, and all the patients with cholangitis had stenosis and residual stones.<sup>99</sup> On the other hand, in a comparison of 190 patients with CDD and 56 patients with TDS over a period of 10 years, Baker and colleagues found an overall mortality of approximately 5% in both groups.<sup>93</sup> The morbidity rates were 11.6% for CDD and 21.4% for TDS. With a mean follow-up of 4.5 years, six patients (3.3%) in the CDD group presented with sump syndrome, cholangitis or both and three patients (5.7%) in the TDS group had cholangitis. In another report by the same authors, an elevated serum alkaline phosphatase level was noted in 22% of CDD patients and 3% of the TDS patients, whereas radiological studies showed that the CDD stoma admitted air and barium more often than the TDS stoma.<sup>100</sup> Interestingly, neither the biochemical nor the radiological findings correlated with long-term symptomatic results after the two procedures.

An alternative to CDD is CDJ, which can be performed with either a loop of jejunum or using a Roux-en-Y configuration. If a loop is used, a side-to-side jejunojejunostomy is used to divert the flow of intestinal contents from the biliary tree. The Roux-en-Y usually is brought retrocolic using a 60-cm afferent limb to protect against intestinal reflux and secondary cholangitis. In either case, an end-to-side CDJ is created using fine absorbable suture. The anastomosis can be decompressed using a T-tube if the remaining bile duct is long enough to allow one, or a transhepatic stent can be used if the remaining bile duct is short. As in the other methods of surgical drainage, a drain is left in place to guard against possible anastomotic leakage.

Gouma and colleagues reported their experience with 43 patients undergoing Roux-en-Y CDJ after complex clearance of the biliary tree for choledocholithiasis.<sup>101</sup> There were no mortalities and only one major complication. Moreover, 98% of the patients had good long-term results with no signs or symptoms related to biliary obstruction or cholangitis. A comparison of CDD and CDJ for choledocholithiasis was evaluated by a French group.<sup>102</sup> One-hundred and thirty patients were included, of which 64 underwent CDD and 66 had a CDJ. No difference in morbidity or mortality was noted between the two groups. Of the 120 patients (58 CDD and 62 CDJ) available for a mean follow-up of 29 months, 107 were symptom-free, 13 patients (6 CDD and 7 CDJ) experienced biliary symptoms suggestive of cholangitis, 8 presented in the first postoperative year, and 5 presented in the second postoperative year. In the CDD group, the cholangitis was secondary to sump syndrome (three patients), anastomotic stricture (one patient), or unknown causes (two patients). Anastomotic strictures (three patient), residual intrahepatic stones (one patient), or unknown causes (three patients) were felt to be the cause of cholangitis in the CDJ group. The authors concluded that CDD is preferable given the similar outcomes because it is easier and faster to perform than CCJ and allows for easy endoscopic interventions if needed in the future. However, often the choice between the two operations is dictated by the anatomy and feasibility of creating a tension-free anastomosis.<sup>103</sup>

One controversy in performing biliary anastomoses is the use of biliary stents. Earlier studies have argued that stents allow for decompression of the bile duct and decreased risk of bile leak, postoperative radiographic evaluation of the biliary tree, and reduced fibrotic narrowing of the anastomosis during early healing.<sup>104</sup> Pitt and colleagues noted a higher success rate with the anastomosis stented for more than 1 month compared with those stented for less than 1 month or not stented at all.<sup>105</sup> Others also have noted good results with the use of stents.<sup>106,107</sup> However, Bismuth and colleagues showed that excellent results could be obtained in 86% of 123 patients undergoing stentless hepaticojejunostomy for benign biliary disorders.<sup>108</sup> Pellegrini and colleagues found that stenting for more than 1 month postoperatively resulted in outcomes no different from anastomoses done without stents.<sup>109</sup> The argument has been raised that stents cause an inflammatory reaction that may predispose to stenosis. DiFronzo and colleagues found that of the 97 patients having either a CDD (77%), CDJ (8%), hepaticoduodenostomy (1%), or hepaticojejunostomy (13%) without the use of stents, only one patient developed an anastomotic leak that resolved spontaneously within 1 week.<sup>104</sup> In the mean follow-up period of 13 months, no postoperative strictures were noted. Meanwhile, Tocchi and colleagues presented their data on performing hepaticojejunostomy (48 patients), CDJ (34 patients), and intrahepatic cholangiojejunostomy (8 patients) without stents in 84 patients over a period of 15 years for benign biliary strictures.<sup>110</sup> Excellent or good results were obtained in 83% of the patients. Anastomotic strictures occurred in 10 patients, 6 within 5 years and 4 at 62, 75, 85, and 96 months. By

multivariate analysis, only postoperative complications and the degree of CBD dilatation proved to be significant independent predictors of outcome. A bile duct dilatation of less than 15 mm was noted in 60% of patients with poor outcome. Although not reaching statistical significance, higher complications and restructures were noted in patients having a CDJ versus hepaticojejunostomy, and the authors changed their practice to performing only higher anastomosis during the study period for even low strictures. Peptic ulcers were noted in only 2.3% of the patients in the entire series, which is not higher than the normal population and does not appear to be related to diverting the flow of bile from the duodenum, as others have suggest.

Laparoscopic approaches to both Roux-en-Y CDJ and CDD have been reported recently. Jeyapalam and colleagues reported six patients who underwent *laparoscopic choledochoduodenostomy* (LCDD).<sup>111</sup> While one patient died of comorbidity, the liver laboratory values returned to normal in all the remaining patients, and the average length of postoperative stay was 6 days. Tang and colleagues selected 12 patients to undergo LCDD for recurrent pyogenic cholangitis.<sup>112</sup> A successful laparoscopic approach was used in all cases, with a mean operating time of 6 hours and a median postoperative length of stay of 7.5 days. One postoperative bile leak was noted and managed conservatively, whereas no patients developed cholangitis or sump syndrome at a mean follow-up of 38 months. Han and colleagues presented similar results in performing laparoscopic Roux-en-Y CDJ for benign disease.<sup>113</sup> One episode of melena that resolved spontaneously was the only postoperative complication in six patients who underwent the surgery. All patients were symptom-free at a 27-month follow up. Despite the proliferation of robotic-assisted surgery, its application to biliary surgery has remained rather limited. The literature thus far includes only two separate case reports. One report describes robotic-assisted CBD exploration.<sup>114</sup> The other report describes a robotic CDJ with an intracorporeal Roux limb construction.<sup>115</sup> The use of minimally invasive surgical drainage procedures is likely to become more widely used as experience increases and technology improves.

## SUMMARY

The evaluation and treatment of choledocholithiasis has evolved over the last 100 years. As newer and less invasive techniques emerge, the surgeons will find a variety of options and many paths that can lead to the successful treatment of a patient with CBD stones. Evaluation and diagnosis may involve an examination and simple laboratory tests or evaluation of the biliary tree with MRCP, ERCP, or an IOC. Treatment may be endoscopic, percutaneous, open, or laparoscopic. Given the multiple alternatives available, sometimes it is difficult to decide on the right one for a particular patient. Frequently, the best path is the one the surgeon is most adept at or the one that local expertise can accomplish most safely. Sometimes, however, the safest approach is a transfer to a center where multiple treatment options are available so that the treatment can be tailored to fit each individual situation.

Figures 49-4 and 49-5 show the treatments followed at our institution for preoperative and intraoperative suspected choledocholithiasis (at cholecystectomy).

## CHOLANGITIS

Cholangitis is the most rapidly fatal complication of gallstones and occurs as a result of biliary tract bacterial infection in the setting of biliary tree obstruction. Mortality approaches 100% in patients who after failing conservative therapy are not subjected to needed drainage interventions.<sup>116</sup> Early diagnosis and treatment are imperative for a successful outcome.

## Pathophysiology

Although bile is normally sterile, when the biliary tree is compromised, such as by a stone, stricture, or endoprosthesis, bacteria then often can be cultured from the bile.<sup>117</sup> Along with the sphincter of Oddi and the bacteriostatic properties of bile, bile flow is an important component of maintaining sterility. Bile duct obstruction results in decreased antibacterial defenses, allowing bacteria to gain access to the biliary tree. Although the route of infection is unclear, ascent from the duodenum or hematogenous is felt to be the possible source.<sup>116</sup> Once colonization has occurred, stasis allows for exponential bacterial growth. As the biliary pressure rises with obstruction, bacteria and their products such as endotoxins leak into the systemic circulation and cause the septicemia of cholangitis.<sup>117</sup>

Patients with partial obstruction have a higher chance of developing cholangitis than those with complete obstruction, and bile duct stones are associated more often with cholangitis than neoplasms causing obstruction. In the United States, secondary choledocholithiasis is the most common cause of cholangitis. Primary bile duct stones are common in areas where Oriental cholangiohepatitis is endemic, including Hong Kong and Southeast Asia.<sup>116</sup> Other causes of cholangitis include obstructing periampullary tumors, tumors metastatic to the porta hepatis or peripancreatic lymph nodes, benign strictures, and primary sclerosing cholangitis. Biliary tract interventions may lead to postprocedural cholangitis, and rare cases of cholangitis may be caused by hemobilia, parasites, and congenital abnormalities of the biliary tree.

*Escherichia coli*, *Streptococcus* spp., *Klebsiella* spp., and Enterobacteriaceae are the most common organisms cultured in cholangitis. *Pseudomonas* spp. and skin and oral flora are associated with biliary tract interventions, whereas anaerobes are noted most commonly in the elderly after biliary surgery.<sup>116</sup>

## Clinical Presentation and Diagnosis

Charcot's triad of fever, right upper quadrant pain, and jaundice is present in 50–70% of patients with cholangitis

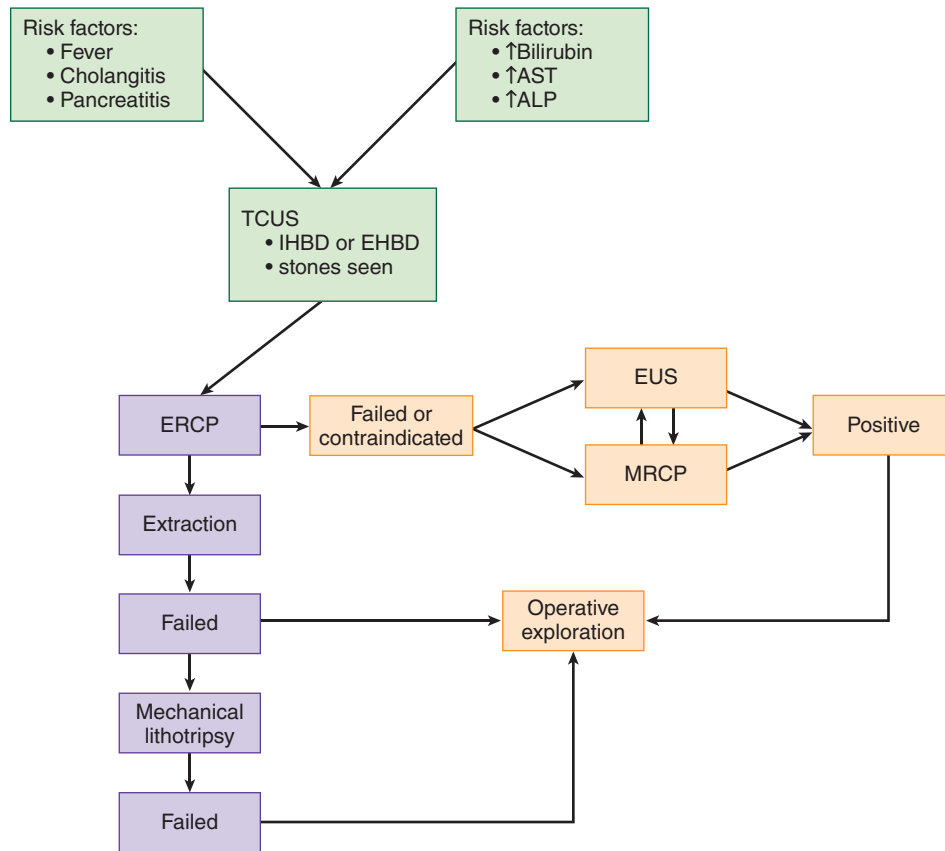


FIGURE 49-4 Algorithm for treatment of preoperative suspected choledocholithiasis.

at presentation, with fever, abdominal pain, and jaundice occurring in 90, 70, and 60% of patients, respectively. Hypotension (20%) and altered mental status (30%) are seen in septic patients and are known as *Reynold's pentad* when presenting in the setting of Charcot's triad. Although peritonitis is uncommon, 65% of patients have right upper quadrant tenderness.<sup>116</sup> Laboratory and radiological studies are important for distinguishing cholangitis from other conditions such as acute cholecystitis, liver abscesses, and pancreatitis. Elevations of serum alkaline phosphatase, gamma-glutamyl transpeptidase, and bilirubin are typical. Mild increases in transaminases may be seen, whereas hyperamylasemia is found in up to 30% of patients. A discussion of imaging studies for the evaluation of choledocholithiasis has been presented in the section on CBD stones. In a patient presenting with signs of cholangitis, the most widely used imaging modalities are ultrasound and CT scan. Ultrasound is highly accurate in diagnosing acute cholecystitis and identifying gallstones. However, its ability to establish the diagnosis of choledocholithiasis is only 50%, varying from 30 to 90%.<sup>6,10</sup> Although the presence of bile duct stones can be inferred by associated bile duct dilatation, a normal ultrasound without duct dilatation does not exclude either choledocholithiasis or cholangitis.<sup>15,116</sup> CT scan is better at determining the level of biliary tract obstruction and has a 94% accuracy in

diagnosing choledocholithiasis in the setting of suspected bile duct calculi.<sup>18</sup> MRCP has sensitivities and specificities approaching ERCP in the diagnosis of bile duct stones and is useful in delineating biliary anatomy. However, its use in the setting of acute cholangitis is limited. ERCP is highly accurate in revealing the cause of biliary obstruction and at the same time allows for therapeutic intervention to occur at the same session.<sup>116</sup> Nonetheless, given the well-defined life-threatening complications associated with ERCP and the availability of other noninvasive imaging techniques, ERCP should not be used solely as a diagnostic tool in the setting of acute cholangitis.<sup>116</sup>

## TREATMENT

Patients with cholangitis can become extremely ill in a short period of time, and rapid initiation of treatment can be life-saving. Supportive measures are begun without delay and include fluid resuscitation, correction of electrolyte deficits and coagulopathy, and administration of analgesics.<sup>118</sup> Empirical broad-spectrum antibiotics are started while blood cultures, and when available, bile cultures are sent. Aminoglycosides and ampicillin are associated with gram-negative resistance and nephrotoxicity and are no longer felt to be the ideal regimen. Newer effective therapies include



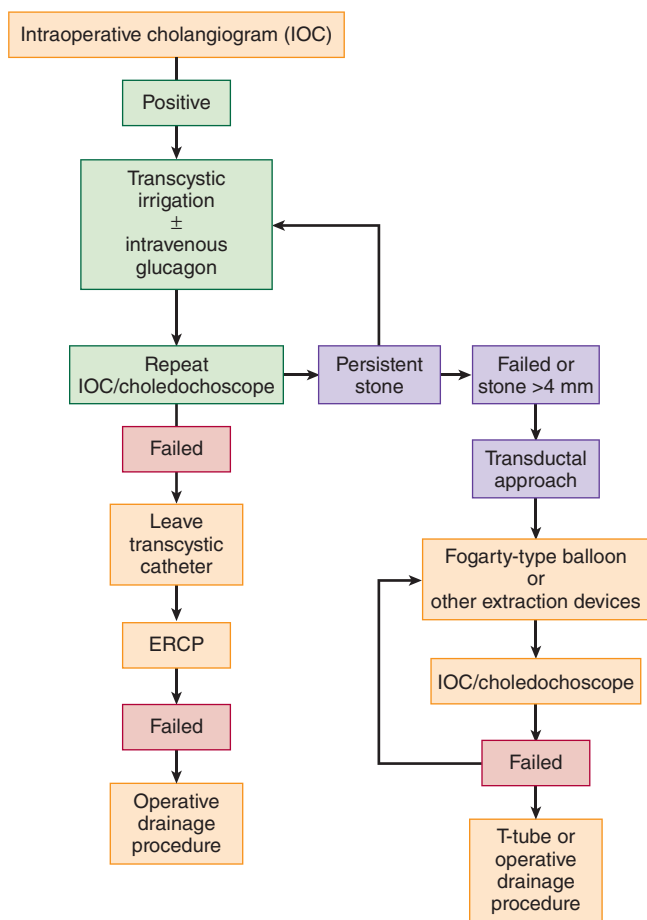


FIGURE 49-5 Algorithm for treatment of intraoperative suspected choledocholithiasis (at cholecystectomy).

combinations of extended-spectrum cephalosporins, metronidazole, and ampicillin; fluoroquinolones as single-agent or in combination with metronidazole; and ureidopenicillins alone or with metronidazole.<sup>116</sup> Anaerobic coverage is felt to be more important in the elderly and those with biliary manipulations. Antibiotics usually are given for 7–10 days, even if biliary decompression has been accomplished during the interim. A retrospective study by van Lent and colleagues evaluated whether continuation of antibiotics is needed after biliary drainage is achieved and signs of inflammation have subsided.<sup>117</sup> Eighty patients who were treated successfully for cholangitis with ERCP were included in the study and followed for 6 months. Forty-one patients received antibiotics for 3 days or less, 19 patients for 4–5 days, and 20 patients for more than 5 days. The three groups were well matched, and the rate of recurrent cholangitis (24%) was not different for the three groups. The authors felt that a 3-day duration of antibiotic therapy may be sufficient in treating cholangitis when adequate drainage has been achieved and fever is abating.

Drainage of the biliary tree is the mainstay of therapy for patients with acute cholangitis.<sup>117</sup> However, the timing and

route of biliary decompression vary depending on the response of antibiotics, the cause of the obstruction, and the presence of morbidities.<sup>118</sup> Biliary sepsis will resolve in most patients with conservative therapy, allowing time for a detailed delineation of the biliary anatomy by noninvasive imaging (CT scan or MRI) in order to determine the cause and level of obstruction. However, urgent decompression is needed in the 10–15% of patients who fail to respond within 24 hours to supportive measures and antibiotic therapy.<sup>117</sup> When biliary decompression is not achieved, liver abscesses are inevitable.<sup>117</sup> Mortality approaches 100% in patients who are not subjected to drainage interventions after failing conservative therapy.<sup>119</sup>

The methods of relieving biliary tract obstruction include endoscopic, percutaneous transhepatic, and surgical drainage techniques. With a success rate of 90–98%, ERCP with bile duct clearance is superior to the other methods and is the modality of choice for decompressing the biliary tree during acute cholangitis, particularly if caused by choledocholithiasis.<sup>116,118</sup> In a study of 83 patients with acute cholangitis randomized to undergo either endoscopic or surgical decompression, the mortality was 10% in the endoscopic arm versus 30% in the surgical group.<sup>116</sup> Meanwhile, in an evaluation of 65 patients undergoing endoscopic drainage versus 40 patients receiving traditional surgery for acute cholangitis, 5 operated patients and no individuals subjected to endoscopy died.<sup>120</sup> In comparison with percutaneous drainage, ERCP also has been shown to have lower morbidity, shorter hospitalization, and higher definitive success rates.<sup>116</sup> Sugiyama and colleagues found that in elderly patients (age 80 or older) with acute cholangitis, endoscopic drainage had lower morbidity (16.7%) and mortality (5.6%) than surgical (87.5 and 25%, respectively) or percutaneous drainage (36.4 and 9.1%, respectively).<sup>121</sup>

Various endoscopic treatment options are available from the placement of nasobiliary catheters or biliary stents to sphincterotomy and stone extraction. In patients who have responded to antibiotic therapy, sphincterotomy with bile duct clearance is preferred, whereas drainage catheters are used in those with ongoing sepsis and multiple large stones.<sup>118</sup> In critically ill patients or in those with coagulopathy, concerns about bleeding and increased procedure times are associated with endoscopic sphincterotomy.

In comparing nasobiliary catheters with biliary stents for the treatment of acute cholangitis, a randomized study found both to be equally effective, but stents were more comfortable and avoided the risk of accidental removal.<sup>116</sup>

Percutaneous transhepatic drainage is reserved for patients in whom the papilla is inaccessible or ERCP has failed and for those suspected of hilar cholangiocarcinoma, hepatolithiasis, and intrasegmental cholangitis.<sup>116,118</sup> Although successful in 90% of patients with biliary obstruction, percutaneous drainage has higher rates of morbidity (30–80%) and mortality (5–15%) than endoscopic techniques. As with ERCP, coagulopathy must be corrected prior to the procedure.

Used for almost 100 years, open surgery for acute cholangitis is associated with mortality rates of up to 40%.<sup>116</sup> Surgery may be limited to choledochotomy, decompression, and T-tube

insertion when performed for emergency situations. In patients who have undergone other methods of biliary drainage for the acute situations, surgery offers definitive treatment of the underlying disease and is associated with low mortality when performed electively after the initial treatment.

The need for cholecystectomy after CBD clearance in patients with cholelithiasis has been discussed in the section on choledocholithiasis. To prevent further biliary complications, some have advocated cholecystectomy for patients who are fit after the initial treatment of acute cholangitis. In nonrandomized and retrospective studies, the risk of developing subsequent biliary problems ranges from 4 to 12% in patients with CBD stones.<sup>116</sup> In a study by Boerma and colleagues, 47% of patients who were randomized to a wait-and-see approach after common duct clearance developed biliary symptoms compared with only 2% of patients who were allocated to cholecystectomy within 6 weeks of the endoscopic procedure.<sup>122</sup> Of the wait-and-see patients, 37% eventually needed cholecystectomy. Targarona and colleagues randomized 98 elderly (mean age 80) patients with biliary symptoms to either open cholecystectomy with operative cholangiography and (if necessary) bile duct exploration (48 patients) or to endoscopic sphincterotomy alone (50 patients).<sup>123</sup> There were no significant differences in immediate morbidity (23 and 16%) or mortality (4 and 6%) in the surgery versus endoscopic group. However, at a mean follow-up of 17 months, biliary symptoms recurred in 3 surgical patients, none of whom underwent repeat surgery, and in 10 endoscopic patients, 7 of whom had further biliary surgery. In conclusion, these studies suggest that patients with acute cholangitis should undergo elective cholecystectomy after bile duct clearance if they are able to tolerate an operation. Conversely, in Asian patients in whom bile duct stones may originate from intrahepatic stones, cholecystectomy may not prevent future biliary complications.<sup>116</sup>

## HEPATOLITHIASIS

Hepatolithiasis is a primary disease of the biliary ducts and is more refractory to surgical treatment than most other benign diseases of the biliary system.<sup>124,125</sup> The disease is defined as stones in ducts proximal to the confluence of the hepatic ducts regardless of the presence of stones within the gallbladder or CBD. The relative incidence in Western countries is approximately 1%, whereas in Taiwan, South Korea, and China it has been reported to be 20, 18, and 40%, respectively.<sup>126</sup> Originally felt to be common only in Southeast Asia and referred to as *Oriental cholangiohepatitis* and *Hong Kong disease*, the widespread immigration of Asians to the United States has resulted in an increasing number of patients with hepatolithiasis presenting to American surgeons.<sup>124,127</sup> Moreover, the North American experience includes a significant number of Caucasians and Latin Americans. This increasing incidence may be attributed to different etiologies such as primary sclerosing cholangitis, choledochal cysts, and iatrogenic biliary strictures.

The pathogenesis of primary hepatic stones was discussed earlier in the section on choledocholithiasis and appears to involve bile infection; biliary stasis; low-protein, low-fat diets and malnutrition; and parasitic infections.<sup>1</sup> Brown pigment stones (calcium bilirubinate) are the most common stones and cholesterol stones are the most common of the other forms found. Hepatolithiasis presents with recurrent pyogenic cholangitis and sepsis, complicated by parenchymal infection and liver abscesses, obstructive cholangiopathy, and subsequent parenchymal destruction and atrophy of involved lobe.<sup>125,127,128</sup> The natural course of the disease may lead to the development of biliary cirrhosis, portal hypertension, and liver failure and is complicated by cholangiocarcinoma in about 10% of patients.<sup>124,125,129</sup>

The diagnostic procedures used in establishing the diagnosis of hepatolithiasis include ultrasonography, CT scan, MRI, and direct (either endoscopic or percutaneous) cholangiography.<sup>18,125,130,131</sup> Characterizing features include varying combinations of ductal dilatation, intrahepatic and extrahepatic bile duct stones, segmental ductal strictures, and lobar or segmental atrophy. In acute exacerbation, parenchymal or ductal contrast enhancement, abscess formation, or biliary obstruction may be noted.<sup>125</sup>

The management of hepatolithiasis is difficult and far from satisfactory. The principles of treatment are centered on the decompression of abscesses, removal of stones, dealing with recurrences and anticipating the development of malignancy. More than two-thirds of patients undergo multiple surgical procedures, and 10% ultimately require liver transplantation for liver failure.<sup>124</sup> Initial biliary decompression usually can be achieved by endoscopic or percutaneous transhepatic drainage.<sup>128</sup> The goal of definitive treatment is complete removal of all bile duct stones and elimination of bile stasis at the sites of intra- or extrahepatic strictures.

If the stones and strictures are located in a single segment or lobe of the liver, hepatic resection generally is recommended.<sup>124,128,132-135</sup> Interestingly, there appears to be a predisposition for the left lobe of the liver. Resection is particularly important for patients with parenchymal atrophy and stricture of the intrahepatic ducts who may have concomitant cholangiocarcinoma.<sup>124</sup> Even with resection, a significant number of patients will have recurrent disease. Kim and colleagues evaluated their experience with hepatectomy in 44 patients with hepatolithiasis by dividing them into two groups, those with intrahepatic biliary stricture and those without it.<sup>136</sup> At a median follow-up of 65 months, the incidence of residual or recurrent stones was 36% for those with stricture and 11% for those without. The rate in late cholangitis was higher in the stricture group (54%) versus the no-stricture group (6%), as was the initial failure rate (50 vs 31%, respectively). Intrahepatic stricture recurred in 46% of the stricture group versus none in the no-stricture group, with stricture recurrence seen at the primary site in two-thirds. Therefore, the importance of including the strictured duct in the hepatic resection is emphasized by this study.

Nevertheless, the number of patients in whom resection is feasible is limited secondary to the diffuse and multifocal

nature of the disease.<sup>132</sup> If stones are located predominantly in the extrahepatic ducts or at the primary convergence and there is minimal stenosis of the intrahepatic ducts, it may be possible to use endoscopic treatment. When stones or strictures are located at the secondary convergence or beyond, surgery and percutaneous transhepatic cholangioscopic lithotripsy have a complete stone clearance rate of 84–100% and 72–92%, respectively.<sup>124</sup> However, the stone recurrence rate is high, ranging from 33 to 40%. Hepaticojejunostomy has been used in the past to prevent biliary-enteric regurgitation and to decrease stagnation of debris and calculi in the intrahepatic ducts. The use of hepaticojejunostomy is controversial and refuted by others, who claim that increased biliary complications occur in patients with hepaticojejunostomies in the setting of hepatolithiasis.<sup>124</sup> However, adding a cutaneous stoma to the Roux limb of the hepaticojejunostomy creates an access point for entering the biliary system for treating future complications.<sup>137</sup> A more appealing alternative to a stoma is the creation of a Hutson loop. This entails tacking the jejunal loop of the biliary-enteric anastomosis to the abdominal wall and clearly marking it with staples or a metal ring such that it can be easily accessed by percutaneous means. We believe that this option should be considered in every patient that undergoes surgery.

With the advent of biliary endoscopy and radiological intervention, percutaneous choledochoscopic removal of intrahepatic stones has been well established.<sup>138</sup> Stones can be removed via cholangioscopic guidance with basket forceps or lithotripsy, and strictures can be dilated. In a study from Hong Kong, 79 patients with intrahepatic stones underwent percutaneous transhepatic choledochoscopy.<sup>138</sup> The success rate was 76.8%, with a complication rate of 21.5%. Cholangitis occurred within 3–5 years in one-third of the patients after the procedure. Another study found that recurrent calculi are more common in the setting of bile duct strictures, and addressing the strictures is mandatory part of treatment.<sup>139</sup> Meanwhile, one study of percutaneous transhepatic cholangioscopic lithotripsy reported a biliary clearance rate of 100%, with a mean of two sessions required and a complication rate of 6.7%.<sup>132</sup> During the follow-up period of 1–127 months (mean 75 months), one recurrence was noted and treated by repeat choledochoscopy. Others have used percutaneous intracorporeal electrohydraulic lithotripsy for hepatolithiasis. Using this technique, in a series of 53 patients, complete clearance of stones was achieved in 92%, and during a mean follow-up of 5 years, 9% had recurrent symptoms of biliary obstruction.<sup>140</sup> Han and colleagues described the use of laparoscopy in the treatment of intrahepatic stones.<sup>129</sup> A flexible choledochoscope, inserted through a choledochotomy, was used for stone removal in 12 patients, with a mean operating time of 288 minutes. Remnant stones were found in only one patient and removed by percutaneous choledochoscopy performed through the T-tube site. No cholangitis or recurrent stones were found at follow-up at 10–45 months.

The most recently documented North American experience describes treating 42 patients between 1986 and 2005 at the University of Toronto.<sup>133</sup> They operated on 17 patients (46%)

for indications of lobar atrophy or stones confined to a single lobe. Patients who underwent an operation were found to have less need for reintervention. The incidence of cholangiocarcinoma was 12%, including patients who were diagnosed at initial presentation.

Although the evolution of this disease is unclear, it will likely continue to challenge us. With lessons learned from more common biliary pathologies and the application of novel technologies, we would anticipate better outcomes for our future patients.

## REFERENCES

1. Ko CW, Lee SP. Epidemiology and natural history of common bile duct stones and prediction of disease. *Gastrointest Endosc.* 2002;56:S165–S169.
2. Tierney S, Pitt HA. Choledocholithiasis and cholangitis. In: Bell RH, Rikkers LF, Mulholland MW, eds. *Digestive Tract Surgery: A Text and Atlas.* Philadelphia, PA: Lippincott-Raven; 1996:407–431.
3. Kaufman HS, Magnuson TH, Lillemoe KD, et al. The role of bacteria in gallbladder and common duct stone formation. *Ann Surg.* 1989;209:584–592.
4. Cetta F. Bile infection documented as initial event in the pathogenesis of brown pigment biliary stones. *Hepatology.* 1986;6:482–489.
5. Faust TW, Reddy KR. Postoperative jaundice. *Clin Liver Dis.* 2004; 8(1):151–166.
6. Eisen GM, Dominitz JA, Faigel DO, et al. An annotated algorithm for the evaluation of choledocholithiasis. *Gastrointest Endosc.* 2001;53:864–866.
7. Goldman DE, Ghossein CF. Choledocholithiasis in patients with normal serum liver enzymes. *Dig Dis Sci.* 1995; 40:1065–1068.
8. Abboud PA, Malet PF, Berlin JA, et al. Predictors of common bile duct stones prior to cholecystectomy: a metaanalysis. *Gastrointest Endosc.* 1996; 44:450–455.
9. Yusoff IF, Barkun JS, Barkun AN. Diagnosis and management of cholecystitis and cholangitis. *Gastroenterol Clin North Am.* 2003;32:1145–1168.
10. Kohut M, Nowak A, Marek T, et al. Evaluation of probability of bile duct stone presence by using of non-invasive procedures. *Pol Arch Med Wewn.* 2003;110:691–702.
11. Gross BH, Harter LP, Gore RM, et al. Ultrasonic evaluation of common bile duct stones: prospective comparison with endoscopic retrograde cholangiopancreatography. *Radiology.* 1983;146:471–474.
12. Costi R, Sarli L, Caruso G, et al. Preoperative ultrasonographic assessment of the number and size of gallbladder stones: is it a useful predictor of asymptomatic choledochal lithiasis? *J Ultrasound Med.* 2002;21:971–976.
13. Tham TC, Collins JS, Watson RG, et al. Diagnosis of common bile duct stones by intravenous cholangiography: prediction by ultrasound and liver function tests compared with endoscopic retrograde cholangiography. *Gastrointest Endosc.* 1996;44:158–163.
14. Contractor QQ, Boujemla M, Contractor TQ, el-Essawy OM. Abnormal common bile duct sonography: the best predictor of choledocholithiasis before laparoscopic cholecystectomy. *J Clin Gastroenterol.* 1997;25:429–432.
15. Hunt DR. Common bile duct stones in non-dilated bile ducts? An ultrasound study. *Australas Radiol.* 1996;40:221–222.
16. Sarli L, Costi R, Gobbi S, et al. Scoring system to predict asymptomatic choledocholithiasis before laparoscopic cholecystectomy: a matched case-control study. *Surg Endosc.* 2003;17:1396–1403.
17. Alponat A, Kum CK, Rajnakova A, et al. Predictive factors for synchronous common bile duct stones in patients with cholelithiasis. *Surg Endosc.* 1997;11:928–932.
18. Fulcher AS. MRCP and ERCP in the diagnosis of common bile duct stones. *Gastrointest Endosc.* 2002;56:S178–S182.
19. Mallery JS, Baron TH, Dominitz JA, et al. Standards of Practice Committee, American Society for Gastrointestinal Endoscopy. Complications of ERCP. *Gastrointest Endosc.* 2003;57:633–638.
20. Carr-Locke DL. Therapeutic role of ERCP in the management of suspected common bile duct stones. *Gastrointest Endosc.* 2002;56:S170–S174.
21. Frey CF, Burbige EJ, Meinke WB, et al. Endoscopic retrograde cholangiopancreatography. *Am J Surg.* 1982;144:109–114.



22. Binmoeller KF, Schafer TW. Endoscopic management of bile duct stones. *J Clin Gastroenterol.* 2001;32:106–118.
23. Disario JA, Freeman ML, Bjorkman DJ, et al. Endoscopic balloon dilation compared with sphincterotomy for extraction of bile duct stones. *Gastroenterology.* 2004;127:1291–1299.
24. Watanabe H, Hiraishi H, Koitabashi A, et al. Endoscopic papillary balloon dilation for treatment of common bile duct stones. *Hepatogastroenterology.* 2004;51:652–657.
25. Leung JW, Tu R. Mechanical lithotripsy for large bile duct stones. *Gastrointest Endosc.* 2004;59:688–690.
26. Riemann JF, Seuberth K, Demling L. Mechanical lithotripsy of common bile duct stones. *Gastrointest Endosc.* 1985;31:207–210.
27. Riemann JF, Seuberth K, Demling L. Clinical application of a new mechanical lithotripter for smashing common bile duct stones. *Endoscopy.* 1982;14:226–230.
28. Hintze RE, Adler A, Veltzke W. Outcome of mechanical lithotripsy of bile duct stones in an unselected series of 704 patients. *Hepatogastroenterology.* 1996;43:473–476.
29. Leung JW, Neuhaus H, Chopita N. Mechanical lithotripsy in the common bile duct. *Endoscopy.* 2001;33:800–804.
30. Chung SC, Leung JW, Leong HT, Li AK. Mechanical lithotripsy of large common bile duct stones using a basket. *Br J Surg.* 1991;78:1448–1450.
31. Cipolletta L, Costamagna G, Bianco MA, et al. Endoscopic mechanical lithotripsy of difficult common bile duct stones. *Br J Surg.* 1997;84:1407–1409.
32. Garg PK, Tandon RK, Ahuja V, et al. Predictors of unsuccessful mechanical lithotripsy and endoscopic clearance of large bile duct stones. *Gastrointest Endosc.* 2004; 59:601–605.
33. Hochberger J, Tex S, Maiss J, Hahn EG. Management of difficult common bile duct stones. *Gastrointest Endosc Clin North Am.* 2003;13: 623–634.
34. Arya N, Nelles SE, Haber GB, et al. Electrohydraulic lithotripsy in 111 patients: a safe and effective therapy for difficult bile duct stones. *Am J Gastroenterol.* 2004;99:2330–2334.
35. Sackmann M, Holl J, Sauter GH, et al. Extracorporeal shock wave lithotripsy for clearance of bile duct stones resistant to endoscopic extraction. *Gastrointest Endosc.* 2001;53:27–32.
36. Neuhaus H, Zillinger C, Born P, et al. Randomized study of intracorporeal laser lithotripsy versus extracorporeal shock-wave lithotripsy for difficult bile duct stones. *Gastrointest Endosc.* 1998;47:327–334.
37. Meyenberger C, Meierhofer U, Michel-Harder C, et al. Long-term follow-up after treatment of common bile duct stones by extracorporeal shock-wave lithotripsy. *Endoscopy.* 1996;28:411–417.
38. Gilchrist AM, Ross B, Thomas WE. Extracorporeal shockwave lithotripsy for common bile duct stones. *Br J Surg.* 1997;84:29–32.
39. Jakobs R, Adamek HE, Maier M, et al. Fluoroscopically guided laser lithotripsy versus extracorporeal shock wave lithotripsy for retained bile duct stones: a prospective, randomised study. *Gut.* 1997;40:678–682.
40. Ragheb S, Choong CK, Gowland S, et al. Extracorporeal shock wave lithotripsy for difficult common bile duct stones: initial New Zealand experience. *N Z Med J.* 2000;113:377–378.
41. Mora J, Aguilera V, Sala T, et al. Endoscopic treatment combined with extracorporeal shock wave lithotripsy of difficult bile duct stones. *Gastroenterol Hepatol.* 2002;25:585–588.
42. Yasuda I, Tomita E. Extracorporeal shockwave lithotripsy of common bile duct stones without preliminary endoscopic sphincterotomy. *Scand J Gastroenterol.* 1996;31:934–939.
43. Ersoz G, Tekesin O, Ozutemiz AO, Gunsar F. Biliary sphincterotomy plus dilation with a large balloon for bile duct stones that are difficult to extract. *Gastrointest Endosc.* 2003;57:156–159.
44. Johnson GK, Geenen JE, Venu RP, et al. Treatment of non-extractable common bile duct stones with combination of ursodeoxycholic acid plus endoprotheses. *Gastrointest Endosc.* 1993;39:528–531.
45. Bergman JJ, Rauws EA, Tijssen JG, et al. Biliary endoprotheses in elderly patients with endoscopically irretrievable common bile duct stones: report on 117 patients. *Gastrointest Endosc.* 1995;42:195–201.
46. Hui CK, Lai KC, Ng M, et al. Retained common bile duct stones: a comparison between biliary stenting and complete clearance of stones by electrohydraulic lithotripsy. *Aliment Pharmacol Ther.* 2003;17:289–296.
47. Cohen S, Bacon BR, Berlin JA, et al. National Institutes of Health Statement of the Science Conference Statement: ERCP for diagnosis and therapy, January 14–16, 2002. *Gastrointest Endosc.* 2002;56:803–809.
48. Lakatos L, Mester G, Reti G, et al. Selection criteria for preoperative endoscopic retrograde cholangiopancreatography before laparoscopic cholecystectomy and endoscopic treatment of bile duct stones: results of a retrospective, single center study between 1996–2002. *World J Gastroenterol.* 2004;10:3495–3499.
49. Tham TC, Lichtenstein DR, Vandervoort J, et al. Role of endoscopic retrograde cholangiopancreatography for suspected choledocholithiasis in patients undergoing laparoscopic cholecystectomy. *Gastrointest Endosc.* 1998;47:50–56.
50. Mark DH, Flamm CR, Aronson N. Evidence-based assessment of diagnostic modalities for common bile duct stones. *Gastrointest Endosc.* 2002;56:S190–S194.
51. Patel P, Khodadadian E, Barawi M, et al. Noncontrast helical computed tomography versus endoscopic ultrasound for suspected choledocholithiasis and common bile duct dilation: a prospective blind comparison. *Gastrointest Endosc.* 2002;56(4):101.
52. Ke ZW, Zheng CZ, Li JH, et al. Prospective evaluation of magnetic resonance cholangiography in patients with suspected common bile duct stones before laparoscopic cholecystectomy. *Hepatobiliary Pancreat Dis Int.* 2003;2:576–580.
53. Kejrival R, Liang J, Anderson G, Hill A. Magnetic resonance imaging of the common bile duct to exclude choledocholithiasis. *ANZ J Surg.* 2004;74:619–621.
54. Demartines N, Eisner L, Schnabel K, et al. Evaluation of magnetic resonance cholangiography in the management of bile duct stones. *Arch Surg.* 2000;135:148–152.
55. Buscarini E, Tansini P, Vallisa D, et al. EUS for suspected choledocholithiasis: do benefits outweigh costs? A prospective, controlled study. *Gastrointest Endosc.* 2003;57:510–518.
56. Buscharth F, Kruse A. Direct cholangiography and biliary drainage. *Scand J Gastroenterol.* 1996;216:59–72.
57. Fernstrom I, Delin NA, Sundblad R. Percutaneous transhepatic extraction of common bile duct stones. *Surg Gynecol Obstet.* 1981;153:405–407.
58. Stokes KR, Clouse ME. Biliary duct stones: percutaneous transhepatic removal. *Cardiovasc Intervent Radiol.* 1990;13:240–244.
59. Petryl J, Bruha R. Transhepatic cholangioscopy in the treatment of choledocholithiasis. *Cas Lek Cesk.* 2003;142:603–605.
60. Maier M, Kohler B, Riemann JF, et al. Percutaneous transhepatic cholangioscopy (PTCS): an important supplement in diagnosis and therapy of biliary tract diseases (indications, technique and results). *Zeitschrift Gastroenterol.* 1995;33:435–439.
61. Brambs HJ, Duda SH, Claussen CD, et al. Treatment of bile duct stones: value of laser lithotripsy delivered via percutaneous endoscopy. *Eur Radiat.* 1996;6:734–740.
62. Nagashima I, Takada T, Okinaga K, et al. Percutaneous transhepatic papillary balloon dilatation as a therapeutic option for choledocholithiasis. *J Hepatobiliary Pancreat Surg.* 2004;11:252–254.
63. Ponchon T, Genin G, Valette P, et al. Methods, indications, and results of percutaneous choledochoscopy: a series of 161 procedures. *Ann Surg.* 1996;223:26–36.
64. Surick BG, Ghazi A. Endoscopic papillotomy while the gallbladder is in situ. *Am Surg.* 1992;58:657–660.
65. Dhiman RK, Phanish MK, Chawla YK, Dilawari JB. Gallbladder motility and lithogenicity of bile in patients with choledocholithiasis after endoscopic sphincterotomy. *J Hepatol.* 1997;26:1300–1305.
66. Reimann, JF, Gierth K, Lux G, Alterndorf A. Retained cholelithiasis: a risk factor after endoscopic papillotomy? *Zeitschrift Gastroenterol.* 1984; 22:188–193.
67. Saraswat VA, Kapur BM, Vashist S, Tandon RK. Duodenoscopic sphincterotomy for common bile duct stones in patients with gallbladder in situ. *Intern Surg.* 1991;76:142–145.
68. Lamont DD, Passi RB. Fate of the gallbladder with cholelithiasis after endoscopic sphincterotomy for choledocholithiasis. *Can J Surg.* 1989;32:15–18.
69. Hill J, Martin DF, Tweedle DE. Risks of leaving the gallbladder in situ after endoscopic sphincterotomy for bile duct stones. *Br J Surg.* 1991;78:554–557.
70. Adamek HE, Kudis V, Riemann JF, et al. Impact of gallbladder status on the outcome in patients with retained bile duct stones treated with extracorporeal shockwave lithotripsy. *Endoscopy.* 2002;34:624–627.
71. Kwon SK, Lee BS, Park SM, et al. Is cholecystectomy necessary after ERCP for bile duct stones in patients with gallbladder in situ? *Korean J Intern Med.* 2001;16:254–259.

72. Kullman E, Borch K, Dahlin LG, Liedberg G. Long-term follow-up of patients with gallbladder in situ after endoscopic sphincterotomy for choledocholithiasis. *Eur J Surg.* 1991;157:131–135.
73. Moreira Vicente VF, Merono GE, Garcia PA, et al. Choledocholithiasis in non-cholecystectomized patients: Endoscopic sphincterotomy and afterwards . . . cholecystectomy? *Rev Espanola Enfermed Aparato Dig.* 1989;76:215–221.
74. Boytchev I, Pelletier G, Buffet C, et al. Late biliary complications after endoscopic sphincterotomy for common bile duct stones in patients older than 65 years of age with gallbladder in situ. *Gastroenterol Clin Biologique.* 2000;24:995–1000.
75. Schreurs WH, Vles WJ, Stuifbergen WH, Oostvogel HJ. Endoscopic management of common bile duct stones leaving the gallbladder in situ: a cohort study with longterm follow-up. *Dig Surg.* 2004;21:60–64; discussion 65.
76. Petelin JB. Surgical management of common bile duct stones. *Gastrointest Endosc.* 2002;56:S183–S189.
77. Petelin JB. Laparoscopic common bile duct exploration. *Surg Endosc.* 2003;17:1705–1715.
78. Metcalfe MS, Ong T, Bruening MH, et al. Is laparoscopic intraoperative cholangiogram a matter of routine? *Am J Surg.* 2004;187:475–481.
79. Ellison EC. What's new in general surgery: gastrointestinal conditions. *J Am Coll Surg.* 2005;199:409–417.
80. Catheline JM, Turner R, Rizk N, et al. Evaluation of the biliary tree during laparoscopic cholecystectomy: laparoscopic ultrasound versus intraoperative cholangiography: a prospective study of 150 cases. *Surg Laparosc Endosc.* 1998;8:85–91.
81. Falcone RA Jr, Fegelman EJ, Nussbaum MS, et al. A prospective comparison of laparoscopic ultrasound vs intraoperative cholangiogram during laparoscopic cholecystectomy. *Surg Endosc.* 1999;13:784–788.
82. Collins C, Maguire D, Ireland A, et al. A prospective study of common bile duct calculi in patients undergoing laparoscopic cholecystectomy: natural history of choledocholithiasis revisited. *Ann Surg.* 2004;239:28–33.
83. Tai CK, Tang CN, Ha JP, et al. Laparoscopic exploration of common bile duct in difficult choledocholithiasis. *Surg Endosc.* 2004;18:910–914.
84. Ha JP, Tang CN, Siu WT, et al. Primary closure versus T-tube drainage after laparoscopic choledochotomy for common bile duct stones. *Hepatogastroenterology.* 2004;51:1605–1608.
85. Isla AM, Griniatsos J, Karvounis E, Arbuckle JD. Advantages of laparoscopic stented choledochorrhaphy over T-tube placement. *Br J Surg.* 2004;91:862–866.
86. Wei Q, Hu HJ, Cai XY, et al. Biliary drainage after laparoscopic choledochotomy. *World J Gastroenterol.* 2004;10:3175–3178.
87. Martin CJ, Cox MR, Vaccaro L. Laparoscopic transcystic bile duct stenting in the management of common bile duct stones. *ANZ J Surg.* 2002;72:258–264.
88. Williams GL, Vellacott KD. Selective operative cholangiography and perioperative endoscopic retrograde cholangiopancreatography (ERCP) during laparoscopic cholecystectomy: a viable option for choledocholithiasis. *Surg Endosc.* 2002;16:465–467.
89. Meyer C, Le JV, Rohr S, et al. Management of common bile duct stones in a single operation combining laparoscopic cholecystectomy and peroperative endoscopic sphincterotomy. *J Hepatobil Pancreat Surg.* 2002;9:196–200.
90. Enochsson L, Lindberg B, Swahn F, Arnelo U. Intraoperative endoscopic retrograde cholangiopancreatography (ERCP) to remove common bile duct stones during routine laparoscopic cholecystectomy does not prolong hospitalization: a 2-year experience. *Surg Endosc.* 2004;18:367–371.
91. Becker C. Percutaneous removal of residual calculi of the bile ducts by T-drainage tract. *Bildgebung.* 1992;59:179–182.
92. Meyhoff HH. Sphincterotomy treatment for biliary tract stones: a retrospective review. *Acta Chir Scand.* 1975;141:645–648.
93. Baker AR, Neoptolemos JP, Leese T, Fossard DP. Choledochoduodenostomy, transduodenal sphincteroplasty and sphincterotomy for calculi of the common bile duct. *Surg Gynecol Obstet.* 1987;164:245–251.
94. Suter M, Jayet C, Richard A, Gillet M. Current status of surgical transduodenal papillotomy. *Helv Chir Acta.* 1994;60:671–678.
95. de Arexabala X, Bahamondes JC. Choledochoduodenostomy for common bile duct stones. *World J Surg.* 1998;22:1171–1174.
96. de Arexabala X, Bahamondes JC. Choledochoduodenostomy for common bile duct stones. *World J Surg.* 1998;22(11):1171–1174.
97. Deutsch AA, Nudelman I, Gutman H, Reiss R. Choledochoduodenostomy an important surgical tool in the management of common bile duct stones: a review of 126 cases. *Eur J Surg.* 1991;157:531–533.
98. Ramirez P, Parrilla P, Bueno FS, et al. Choledochoduodenostomy and sphincterotomy in the treatment of choledocholithiasis. *Br J Surg.* 1994; 81:121–123.
99. Parrilla P, Ramirez P, Sanchez Bueno F, et al. Long-term results of choledochoduodenostomy in the treatment of choledocholithiasis: assessment of 225 cases. *Br J Surg.* 1991;78(4):470–472.
100. Baker AR, Neoptolemos JP, Leese T, et al. Long-term follow-up of patients with side-to-side choledochoduodenostomy and transduodenal sphincteroplasty. *Ann R Coll Surg Engl.* 1987;69(6):253–257.
101. Gouma DJ, Konsten J, Soeters PB, et al. Long-term follow-up after choledochojejunostomy for bile duct stones with complex clearance of the bile duct. *Br J Surg.* 1989;76:451–453.
102. Panis Y, Fagniez PL, Brisset D, et al. Long-term results of choledochoduodenostomy versus choledochojejunostomy for choledocholithiasis. The French Association for Surgical Research. *Surg Gynecol Obstet.* 1993;177:33–37.
103. Tocchi A, Costa G, Lepre L, et al. The long-term outcome of hepaticojejunostomy in the treatment of benign bile duct strictures. *Ann Surg.* 1996;224:162–167.
104. DiFronzo LA, Egrari S, O'Connell TX. Safety and durability of single-layer, stentless, biliary-enteric anastomosis. *Am Surg.* 1998;64:917–920.
105. Pitt HA, Miyamoto T, Parapatis SK, et al. Factors influencing outcome in patients with postoperative biliary strictures. *Am J Surg.* 1982;144:14–21.
106. Braasch JW, Bolton JS, Rossi RL. A technique of biliary tract reconstruction with complete follow-up in 44 consecutive cases. *Ann Surg.* 1981;194:634–638.
107. Cameron JL, Gayler BW, Zuidema GD. The use of silastic transhepatic stents in benign and malignant biliary strictures. *Ann Surg.* 1978; 188:552–561.
108. Bismuth H, Franco D, Corlette MB, Hepp J. Long-term results of roux-en-Y hepaticojejunostomy. *Surg Gynecol Obstet.* 1978;146:161–167.
109. Pellegrini CA, Thomas MJ, Way LW. Recurrent biliary stricture: patterns of recurrence and outcome of surgical therapy. *Am J Surg.* 1984;147:175–179.
110. Tocchi A, Costa G, Lepre L, et al. The long-term outcome of hepaticojejunostomy in the treatment of benign bile duct strictures. *Ann Surg.* 1996;224:162–167.
111. Jeyapalan M, Almeida JA, Michaelson RL, Franklin ME Jr. Laparoscopic choledochoduodenostomy: review of a 4-year experience with an uncommon problem. *Surg Laparosc Endosc Percutan Tech.* 2002;12:148–153.
112. Tang CN, Siu WT, Ha JP, Li MK. Laparoscopic choledochoduodenostomy: an effective drainage procedure for recurrent pyogenic cholangitis. *Surg Endosc.* 2003;17:1590–1594.
113. Han HS, Yi NJ. Laparoscopic roux-en-Y choledochojejunostomy for benign biliary disease. *Surg Laparosc Endosc Percutan Tech.* 2004;14:80–84.
114. Jayaraman S, Davies W, Schlachta CM. Robot-assisted minimally invasive common bile duct exploration: a Canadian first. *Can J Surg.* 2008 Aug;51(4):E93–E94.
115. Kohn GP, Overby DW, Martinie JB. Robotic choledochojejunostomy with intracorporeal Roux limb construction. *Int J Med Robot.* 2008 Sep;4(3):263–267.
116. Yusoff IF, Barkun JS, Barkun AN. Diagnosis and management of cholecystitis and cholangitis. *Gastroenterol Clin North Am.* 2003;32:1145–1168.
117. van Lent AU, Bartelsman JF, Tytgat GN, et al. Duration of antibiotic therapy for cholangitis after successful endoscopic drainage of the biliary tract. *Gastrointest Endosc.* 2002;55:518–522.
118. Bornman PC, van Beljon JI, Krige JE. Management of cholangitis. *J Hepatobil Pancreat Surg.* 2003;10:406–414.
119. Yusoff IF, Barkun JS, Barkun AN. Diagnosis and management of cholecystitis and cholangitis. *Gastroenterol Clin North Am.* 2003; 32: 1145–1168.
120. Anselmi M, Salgado J, Arancibia A, Alliu C. Acute cholangitis caused by choledocholithiasis: traditional surgery or endoscopic biliary drainage. *Rev Med Chili.* 2001;129:757–762.
121. Sugiyama M, Atomi Y. Treatment of acute cholangitis due to choledocholithiasis in elderly and younger patients. *Arch Surg.* 1997;132:1129–1133.
122. Boerma D, Rauws EA, Keulemans YC, et al. Wait-and-see policy or laparoscopic cholecystectomy after endoscopic sphincterotomy for bile-duct stones: a randomised trial. *Lancet.* 2002;360:761–765.
123. Targarona EM, Ayuso RM, Bordas JM, et al. Randomised trial of endoscopic sphincterotomy with gallbladder left in situ versus open

- surgery for common bile duct calculi in high-risk patients. *Lancet*. 1996;347:926–929.
124. Kusano T, Isa TT, Muto Y, et al. Long-term results of hepaticojejunostomy for hepatolithiasis. *Am Surg*. 2001;67:442–446.
  125. Chan FL, Chan JK, Leong LL. Modern imaging in the evaluation of hepatolithiasis. *Hepatogastroenterology*. 1997;44:358–369.
  126. Pausawasdi A, Watanapa P. Hepatolithiasis: epidemiology and classification. *Hepatogastroenterology*. 1997;44:314–316.
  127. Kim MH, Sekijima J, Lee SP. Primary intrahepatic stones. *Am J Gastroenterol*. 1995;90:540–548.
  128. Neuhaus H. Intrahepatic stones: the percutaneous approach. *Can J Gastroenterol*. 1999;13:467–472.
  129. Han HS, Yi NJ. Laparoscopic treatment of intrahepatic duct stone. *Surg Laparosc Endosc Percutan Tech*. 2004;14:157–162.
  130. di Carlo I, Sauvanet A, Belghiti J. Intrahepatic lithiasis: a Western experience. *Surg Today*. 2000;30:319–322.
  131. Krige JE, Beckingham IJ, Terblanche J. Ductal dilatation and stenting for residual hepatolithiasis. *Gut*. 1999;44:581–582.
  132. Maetani I, Ishiguro J, Ogawa S, et al. Percutaneous choledochoscopic treatment of intrahepatic stones, including management of associated biliary stenoses. *Endoscopy*. 1999;31:456–459.
  133. Al-Sukhni W, Gallinger S, Pratzler A, et al. Recurrent pyogenic cholangitis with hepatolithiasis: the role of surgical therapy in North America. *J Gastrointest Surg*. 2008 Mar;12(3):496–503.
  134. Uchiyama K, Kawai M, Ueno M, et al. Reducing residual and recurrent stones by hepatectomy for hepatolithiasis. *J Gastrointest Surg*. 2007 May;11(5):626–630.
  135. Lee TY, Chen YL, Chang HC, Chan CP, Kuo SJ. Outcomes of hepatectomy for hepatolithiasis. *World J Surg*. 2007 Mar;31(3):479–482.
  136. Kim KH, Sung CK, Park BG, et al. Clinical significance of intrahepatic biliary stricture in efficacy of hepatic resection for intrahepatic stones. *J Hepatobil Pancreat Surg*. 1998;5:303–308.
  137. Saing H, Chan KL, Mya GH, et al. Cutaneous stoma in the roux limb of hepaticojejunostomy (hepaticocutaneous jejunostomy): useful access for intrahepatic stone extraction. *J Pediatr Surg*. 1996;31:247–250.
  138. Cheung MT, Wai SH, Kwok PC. Percutaneous transhepatic choledochoscopic removal of intrahepatic stones. *Br J Surg*. 2003;90:1409–1415.
  139. Yoshida J, Chijiwa K, Shimizu S, et al. Hepatolithiasis: outcome of cholangioscopic lithotomy and dilation of bile duct stricture. *Surgery*. 1998;123:421–426.
  140. Bonnel D, Liguory C, Lefebvre JF, Cornud F. Percutaneous treatment of intrahepatic lithiasis. *Gastroenterol Clin Biol*. 2001;25:581–588.



# CHOLEDOCHAL CYST AND BENIGN BILIARY STRICTURES

Purvi Y. Parikh • Keith D. Lillemoe

Benign conditions of the intra- or extrahepatic bile ducts can range from focal or diffuse dilations (choledochal cyst) to obstructive strictures of the biliary tree. Historically, choledochal cyst disease was considered a disease of childhood but is increasingly being recognized in adults. In the United States, benign biliary strictures most commonly occur as a result of injury after cholecystectomy but also occur in a number of diverse inflammatory conditions affecting the biliary tree. Both conditions represent significant clinical challenges where proper evaluation and management are paramount to prevent serious clinical sequelae.

## CHOLEDOCHAL CYST

Choledochal cysts are focal or diffuse dilations of the biliary tree and, aside from biliary atresia, are the most common congenital abnormality of the biliary tree. Choledochal cysts can occur as single or multiple cysts throughout the extra- or intrahepatic bile ducts. The cysts can predispose patients to recurrent cholangitis or pancreatitis, choledocholithiasis, secondary biliary cirrhosis, biliary stricture, and malignancy.

The incidence of choledochal cysts varies significantly throughout the world. Choledochal cysts appear to be most common in Asian countries with an estimated incidence of 1 in 13,000 and have been reported to be as high as 1 in 1000, in reports from Japan. In Western countries, choledochal cysts occur much less frequently, with reported rates that vary from 1 in 150,000 to 1 in 2 million live births.<sup>1</sup> Biliary cysts are four times more common in women compared with men. Approximately 60% of patients with choledochal cysts present during their first decade of life and 25% present in adults.<sup>2</sup> There are a few case reports of choledochal cysts occurring within families but generally do not have a recognized hereditary pattern.

## Classification

The anatomy of choledochal cyst disease was first described by Vater in 1723 and in 1959 Alonso-Lej categorized three types

of choledochal cysts.<sup>3</sup> The classification system was revised by Todani and colleagues in 1977 to the five cyst categories<sup>4</sup> that are in use today (Table 50-1). A similar classification has been proposed based on bile duct cholangiographic appearance.<sup>5</sup> A further Todani classification reflects the presence or absence of pancreaticobiliary maljunction; however, this revision has not widely been accepted.<sup>6</sup>

Traditionally, the classic type and most common choledochal cyst is type I disease: (A) cystic (Fig. 50-1A), (B) saccular, or (C) fusiform dilation of the extrahepatic biliary tree. Type II cysts are simple diverticula of the common bile duct, which are usually extrahepatic, supraduodenal, and saccular (Fig. 50-1B). A rare combination of type I cystic dilation and type II diverticulum was reported in a few cases representing a mixed type. Type III cysts, also known as *choledochoceles*, is a cystic dilation of one segment of the bile duct (Fig. 50-1C). Manning and colleagues<sup>7</sup> described two anatomic variations of intraduodenal choledochocoele. The most frequent variety is with the common bile duct and main pancreatic duct entering into the choledochocoele separately. The second variety of intraduodenal choledochocoele is essentially a diverticulum off the common bile duct at the level of the ampulla of Vater, with the pancreatic duct entering the end of the common bile duct in the usual location. Multiple dilations of the intra- and extrahepatic biliary tree are known as type IV cysts divided into types IVa and IVb. Type IVa represents fusiform extra- and intrahepatic cysts (Fig. 50-1D). Type IVb consists of multiple extrahepatic cysts (Fig. 50-1E). Type V cyst, Caroli's disease, is confined to the entire liver or a solitary lobe, usually on the left (Fig. 50-1F).<sup>2,3</sup> This disease may be associated with periportal fibrosis and cirrhosis leading to subsequent hepatosplenomegaly and portal hypertension.

While Todani's 1977 schema is the most widely accepted classification, it is not without controversy. Some have argued that the term "choledochal cyst" should refer to only type I and IV cysts (which comprise over 90% of biliary cysts).<sup>8</sup> This proposal is based on current understanding of pathogenesis, treatment, malignancy risk, and natural history, which vary substantially with types I and IV cysts versus types II, III, or V cysts. A recent paper from Indiana University questioned

**TABLE 50-1: ALONSO-LEJ/TODANI MODIFICATION OF THE CLASSIFICATION OF CHOLEDOCHAL CYSTS**

Type I	Classic cyst type characterized by cystic dilation of the common bile duct; most common, comprising 50–80% of all biliary cysts; subdivided into IA (cystic), IB (fusiform), and IC (saccular)
Mixed types I and II	Fusiform dilation of the extrahepatic biliary tree in combination with a separate diverticulum, midportion of the common bile duct, with cystic duct entering in the right of the diverticulum, comprising < 1%
Type II	Simple diverticulum of the extrahepatic biliary tree, comprising 2–3% of all cysts; located proximal to the duodenum
Type III	Cystic dilation of the intraduodenal portion of the extrahepatic common bile duct; also known as a choledochoceles; comprise approximately <10%
Type IV	Involve multiple cysts of the intra- and extrahepatic biliary tree; subdivided into types IVa (both intra- and extrahepatic cysts) and IVb (multiple extrahepatic cysts without intrahepatic involvement); type IVA is the second most common type of biliary cyst, comprising 30–40%, type IVB comprising <5%
Type V	Isolated intrahepatic biliary cystic disease, also known as Caroli's disease; associated with periportal fibrosis or cirrhosis; can be multilobar or confined to a single lobe, comprising <10%

whether choledochoceles were truly choledochal cysts. They reviewed 146 patients with choledochal cysts and identified 28 patients with choledochoceles. They concluded that classifications of choledochal cysts should not include choledochoceles because they differ from choledochal cysts regarding age, gender, presentation, pancreatic ductal anatomy, and their management.<sup>9</sup>

## Pathogenesis

The cause of choledochal cysts is unknown. While there have been reports of acquired cysts in the literature, most are congenital in nature. There may be multiple mechanisms involved in the creation of biliary cysts, and several theories have been proposed.

The high incidence of biliary cysts in Asia suggests a role for either genetic or environmental factors. The first theory pertains primarily to the pathogenesis of Caroli disease and is

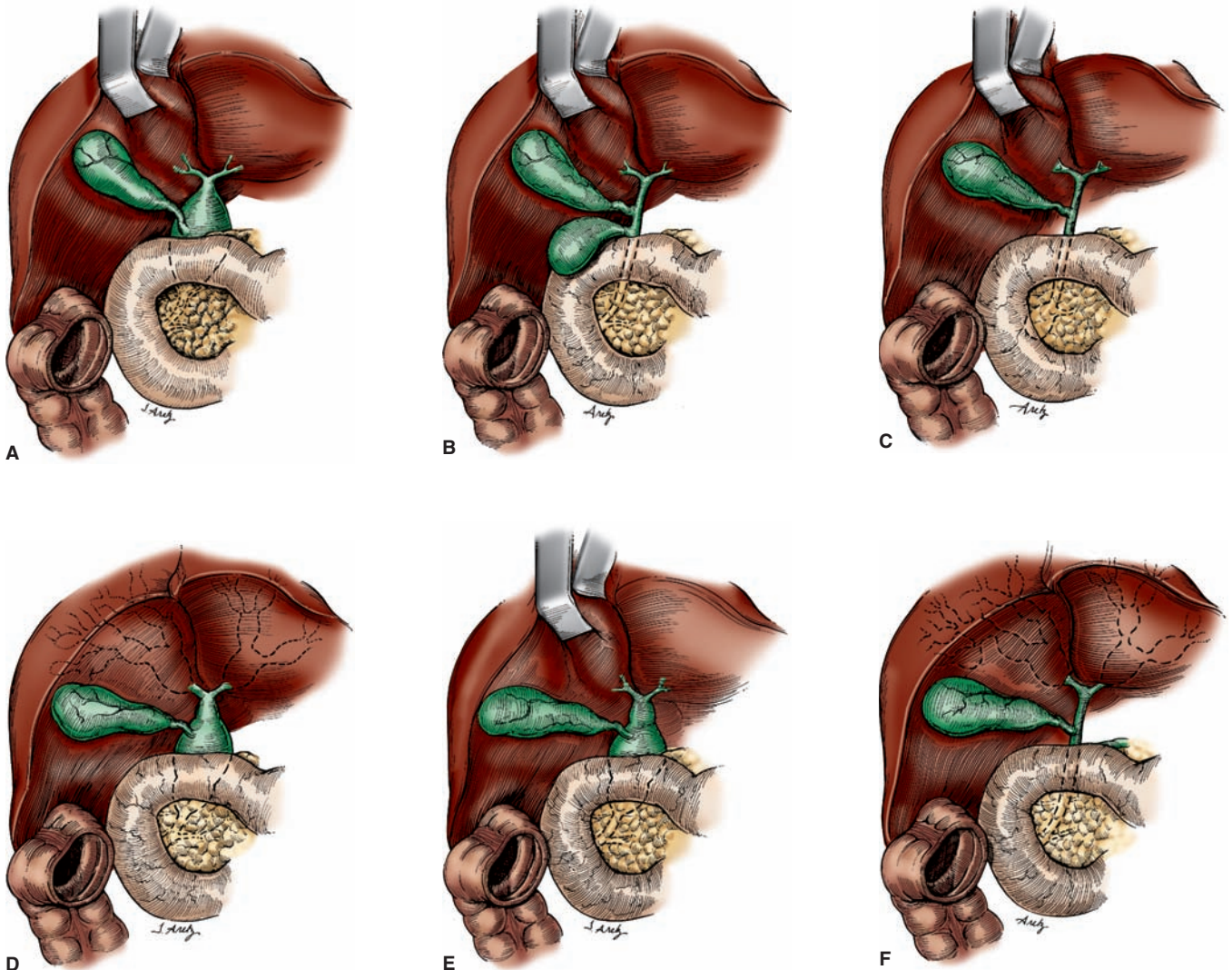
related to a defect in maturation with ductal plate malformation. This defect can be either sporadic or inherited, with both autosomal-recessive and, rarely, autosomal-dominant inheritance patterns seen in families. Ductal plates describe the development of intrahepatic liver progenitor cells that are in contact with the mesenchyme of the portal vein and are then remodeled into mature ducts. Defective bile duct plate remodeling during embryogenesis results in inflammation and ulceration of biliary epithelium into larger bile ducts. These ducts then become segmentally dilated in a focal, lobar, or multilobar distribution.<sup>10</sup>

The second theory for the etiology of choledochal cyst formation is that bile duct obstruction or distention in the prenatal or neonatal periods may contribute to biliary cyst formation. The obstruction may be secondary to a stricture, web, or sphincter of Oddi dysfunction. With distal biliary obstruction there is pancreatic juice reflux into the biliary tree, resulting in chronic inflammation and increased bile duct pressure leading to dilation.<sup>11</sup> In animal models, bile duct ligation in neonates leads to cyst formation; in contrast, bile duct ligation in adult animals results in gallbladder distention.<sup>12</sup> In addition, there are case reports of a congenital web at the lower end of the common bile duct and antenatal choledochal cyst with distal common bile duct formation.<sup>13</sup>

The most common proposed theory for choledochal cyst formation is related to pancreaticobiliary maljunction.<sup>14</sup> Pancreaticobiliary maljunction is defined as an extramural junction of the pancreatic and biliary ducts in the duodenum beyond the intramural sphincter function and is characterized by a long common channel. On average, patients with this anomaly have a common channel that is 1.86 cm compared with 0.46 cm in patients with a normal junction.<sup>15</sup> In the literature, pancreaticobiliary maljunction has been reported in 57–96% of patients with choledochal cyst disease (Fig. 50-2).<sup>16</sup> Pancreaticobiliary maljunction is also thought to be a significant risk factor for the development of cholangiocarcinoma in the biliary cyst,<sup>17</sup> as well as the development of gallbladder cancer. Several investigators have speculated on the embryologic etiology of pancreaticobiliary maljunction, hypothesizing that the development of pancreaticobiliary maljunction is a result of an arrest in the migration of the choledochopancreatic junction into the duodenal wall.<sup>18</sup>

Because of the long common channel, patients with pancreaticobiliary maljunction may have increased reflux of pancreatic juice into the biliary tree, because the ductal junction lies outside the sphincter of Oddi and cannot prevent the mixing of bile and pancreatic juices.<sup>19</sup> The mixed juices then have the potential of stagnating in the ducts or gallbladder, resulting in a cycle of inflammation, activation of proteolytic enzymes, theoretical biliary epithelial damage, alterations in bile composition, and ductal distention. It is thought that a combination of these factors contributes to the development of malignancy within the choledochal cyst or gallbladder. Elevated sphincters of Oddi pressures have also been documented in patients with pancreaticobiliary maljunction, resulting in more reflux.<sup>20,21</sup>

On pathology, choledochal cysts have variable microscopic features, with appearance ranging from normal bile



**FIGURE 50-1** Illustrations of the Todani classification of choledochal cysts. **A.** Type IA. **B.** Type II. **C.** Type III. **D.** Type IVA. **E.** Type IVB. **F.** Type V.

duct mucosa to carcinoma. In children, the classic histologic appearance is a thick and dense fibrotic cyst wall with evidence of acute or chronic inflammation. In adults, common findings are inflammation, erosions, sparseness of mucin glands, and metaplasia.<sup>1,22</sup> Type III cysts are most often lined by duodenal mucosa, although they sometimes are lined by bile duct epithelium.<sup>22</sup> When malignancy is present, it is most commonly found along the posterior cyst wall.<sup>23</sup>

## Presentation

Choledochal cyst disease can present with a vast spectrum of symptoms. The classic triad of presentation of a choledochal cyst is a female child with jaundice, abdominal pain, and

right upper quadrant abdominal mass. This triad is found in only a minority of children at the time of presentation. Infants commonly present with elevated conjugated bilirubin (80%), failure to thrive, or an abdominal mass (30%). An abdominal mass becomes less common with increasing age and is rarely appreciated in adults. In adults, abdominal pain and recurrent cholangitis are the most common presentations.<sup>24</sup> The abdominal pain usually mimics that of calculous cholecystitis and many patients do have gallstones either in the cyst or in the gallbladder. Almost 38% of adult patients have had a cholecystectomy before the diagnosis of a choledochal cyst because of right upper quadrant pain, which was attributed to gallbladder disease.<sup>25</sup> Intermittent jaundice and recurrent cholangitis are also common, as is pancreatitis (30%), especially in patients with a type III cyst



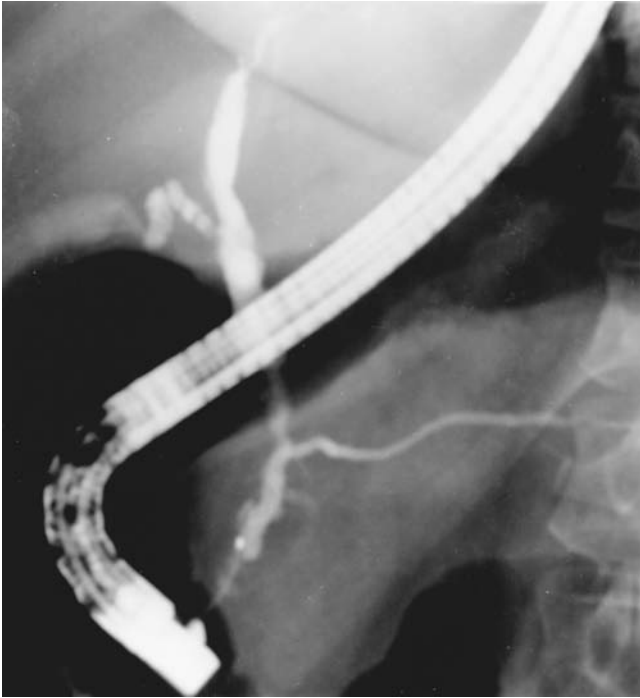


FIGURE 50-2 Pancreaticobiliary maljunction.

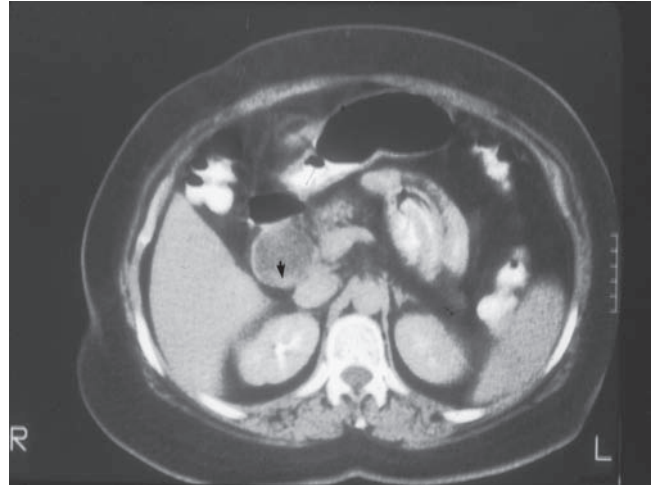
(choledochoceles).<sup>1,9,26</sup> Rarely, choledochal cysts will present as intraperitoneal rupture or bleeding due to erosion into adjacent vessels.

## Diagnosis

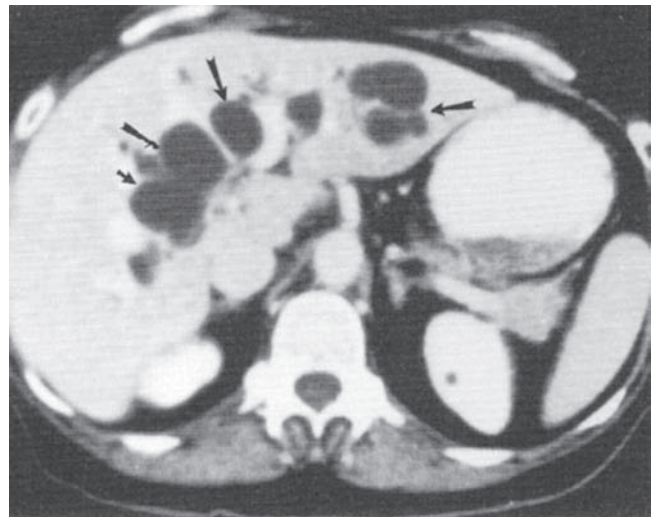
The diagnosis of a choledochal cyst requires a high level of suspicion. Unless choledochal cyst is considered in the differential diagnosis in patients with ductal dilation, type I cysts may go undiagnosed. Patients with biliary obstruction, either acutely or chronically, may also have biliary dilation that can mimic a type I cyst. In contrast to a type I cyst, an obstructing lesion will often cause elevated alkaline phosphatase and bilirubin, as well as improvement in biliary dilation after appropriate treatment. The presence of pancreaticobiliary maljunction in uncertain cases can also be helpful in making the diagnosis of a type I cyst versus a biliary obstruction.

Ultrasonography is the most common first-line imaging tool and was used in 93% of the pediatric population and 72% of the adult patients in The Johns Hopkins series.<sup>25</sup> While ultrasound is the standard for antenatal and childhood diagnosis, computed tomography (CT) scan may be more appropriate in adult patients, in whom the differential diagnosis is broader. Important considerations on CT scan (Fig. 50-3) include assessing the hepatobiliary and pancreatic anatomy, with evaluation for possible biliary malignancy, metastatic disease, and vascular encasement.

Ultimately, when choledochal cyst disease is suspected on imaging, visualization of the pancreatic, intrahepatic,



A

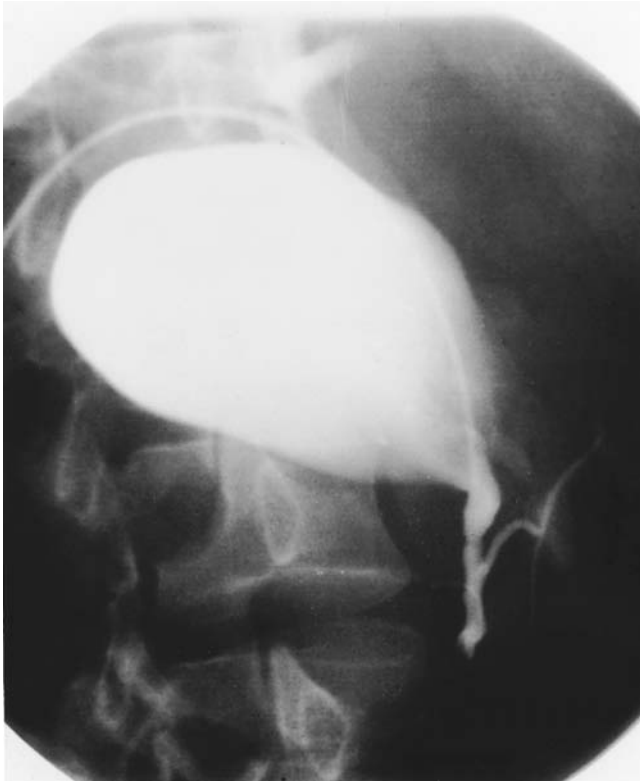

B

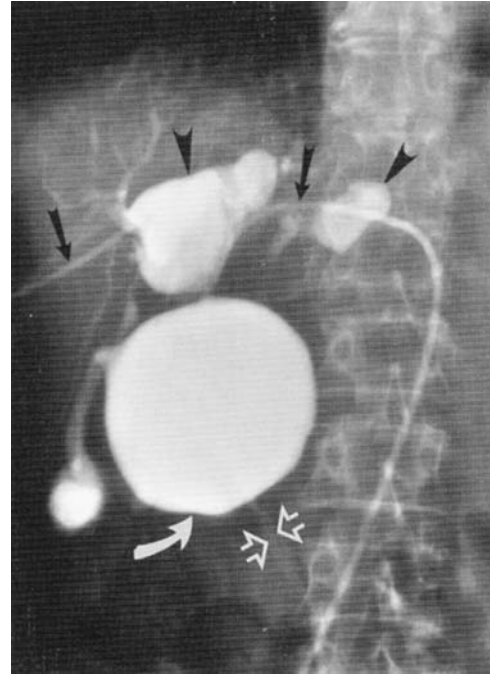
FIGURE 50-3 **A.** CT scan appearance of type IA choledochal cyst (*arrow* shows sludge within the cyst). **B.** CT scan appearance through the liver demonstrates multiple low-density structures (*arrows*) within the right and left lobe consistent with a type IVA choledochal cyst.

and extrahepatic ductal anatomy is required. Magnetic resonance cholangiopancreatography (MRCP) has become the noninvasive procedure of choice for the diagnosis of choledochal cyst. As quality of MRCP has improved, many surgeons now consider MRCP the only imaging technique needed for diagnosis and operative planning. Park and colleagues<sup>27</sup> retrospectively reviewed 72 adult patients who underwent both MRCP and endoscopic retrograde cholangiopancreatography (ERCP) and found that when compared with ERCP, MRCP was accurate 100% of the time with types IVb and V cysts.

Cholangiography has been considered the gold standard for diagnosis of choledochal cysts but now is necessary as



**FIGURE 50-4** Percutaneous cholangiogram via the right hepatic duct. A large type I choledochal cyst is seen. Note the anomalous cholecho pancreatic duct junction.



**FIGURE 50-5** Type IVA choledochal cyst. Bilateral percutaneous biliary drainage catheters (*arrows*) were placed in this patient, who had extensive intrahepatic biliary duct dilation (*arrow-heads*) and a huge extrahepatic choledochal cyst (*curved arrow*). Note that the biliary catheters exit the cyst and enter the duodenum (*open arrows*).

primarily a therapeutic procedure to place stents to relieve jaundice or cholangitis or to obtain brushings for cytology. Cholangiography can demonstrate areas of cystic dilation, the presence of stones, and exclude complete obstruction of the bile duct (Fig. 50-4). It is also effective in demonstrating the presence of pancreaticobiliary maljunction. Percutaneous transhepatic cholangiography (PTC) or ERCP is typically performed on adults and larger children. In small children, ERCP is not the ideal tool because it involves the use of general anesthesia can lead to pancreatitis and may not define the very proximal biliary anatomy, which tends to be abnormal. Therefore, in children intraoperative cholangiography may be used. The use of MRCP in children is increasing as experience with MRCP grows, and its technological accuracy may rival that of endoscopic evaluation. However, patients with type I or type IV cysts that extend to the hepatic bifurcation, PTC allows for excellent imaging of the entire biliary system and the placement of one or two transhepatic biliary catheters that may be helpful to facilitate complete resection and biliary reconstruction (Fig 50-5). To decrease the high risk of pancreatitis in patients with pancreaticobiliary maljunction and a long channel, it is important to avoid placing the stent through the ampulla while performing PTC.

## Management

Once the diagnosis of choledochal cyst is made and the patient's biliary anatomy is delineated through preoperative imaging, several important clinical considerations must be taken into account. If a patient presents with pancreatitis or cholangitis, these problems must be treated supportively prior to considering definitive operative management of the biliary cyst. Because of the extensive sludge or stones that may be present within choledochal cysts and the high incidence of pancreaticobiliary maljunction, these patients are at especially high risk for pancreatitis. Furthermore, there is a risk of pancreatitis during ERCP with ampullary stent placement.

Another important clinical consideration in patients with choledochal cysts is the presence of malignancy. The most common malignancy associated with choledochal cyst disease is cholangiocarcinoma, although other malignant neoplasms have been reported, including gallbladder cancer, adenocarcinoma, and bile duct sarcoma. The incidence of cholangiocarcinoma with biliary cysts varies with patient age and cyst type. The lifetime risk of associated cholangiocarcinoma is as high as 26% in some studies, and, importantly, the rate of malignancy increases with age. Patients discovered in their twenties have only a 2.3% risk of concomitant malignancy, but it increases to 14.6% for patients with choledochal cysts discovered in their thirties and forties.<sup>8,12,22,28</sup> In older untreated patients, the reported incidence of cholangiocarcinoma is as high as 75%.<sup>29</sup>

Types I and IV have a higher risk of cancer, while cancer is rare in types II and III cysts. In type III cysts, cancer risk may be limited to those choledochoceles lined by biliary and not duodenal epithelium.

Historically, choledochal cyst presenting in childhood were often treated with a cyst-enteric bypass leaving the cyst in situ. These patients remain at risk for the development of cancer within the retained cyst.<sup>29</sup> Caroli's disease also carries a risk (about 7%) of cholangiocarcinoma. Most patients with Caroli's disease, however, will present first with compromised liver function or cholangitis before developing malignancy. The Johns Hopkins series had 92 choledochal cyst patients with 8 of them being diagnosed with cancer at the time of surgery or in follow-up. Every cyst type except types II and III was involved with cancer. None of the patients who had a complete cyst excision developed cancer after a mean of 10 years of follow-up. However, this population was still at a greater risk of malignancy than the general population.<sup>25</sup> Malignancy may develop with incompletely resected cysts, at the anastomotic site, or in residual cyst left within the pancreas.<sup>29</sup>

Speculated etiological factors in carcinogenesis associated with biliary cysts include bile stasis, reflux of pancreatic juice mixed with bile, superinfection, or inflammation.<sup>29,30</sup> Cholangiocarcinoma in choledochal cysts is strongly linked to patients with pancreaticobiliary maljunction.<sup>17</sup> There is strong pathologic evidence of a hyperplasia-dysplasia-carcinoma sequence of carcinogenesis in patients with pancreaticobiliary maljunction. While the exact pathways have yet to be elucidated, cells with hyperplasia in patients with pancreaticobiliary maljunction have elevated expression of cellular proliferation markers, including cyclooxygenase-2 and vascular epithelial growth factor.<sup>31</sup> On a molecular level, hyperplastic cells also have a high incidence of *K-ras* mutations (13–63%)<sup>32,33</sup> while dysplastic cells frequently have microsatellite instability (60%)<sup>34</sup> and cancerous lesions often have over expression of cyclin D1<sup>35</sup> and *p53* mutations.<sup>36</sup> Prophylactic cholecystectomy is also advised in all patients with either pancreaticobiliary maljunction or choledochal cyst.

In addition to the continued risk of cancer after excision, the most frequent long-term complication after biliary reconstruction is postoperative biliary stricture at the site of the anastomosis (~25%).<sup>37</sup> Therefore, long-term follow-up should include surveying patients for the development of an anastomotic stricture. Significant elevations in serum alkaline phosphatase levels merit further investigation and treatment to prevent long-term complications from postoperative biliary strictures.

Unfortunately, current methods for screening for malignancy within a choledochal cyst have not proved effective, and therefore expectant management cannot be advised for most patients. Intraductal ultrasound and cytologic brushings of the cyst wall show promise for potentially detecting malignancy. Patients with choledochal cysts who are poor candidates or who refuse biliary reconstructive surgery may be candidates for lesser interventions to treat symptoms caused by gallstones or sludge, such as cholecystectomy or endoscopic treatment.

## OPERATIVE MANAGEMENT

Historically, choledochal cysts were managed with biliary-enteric drainage via cyst-enterostomy. Recognition of an increased risk of bile duct and gallbladder cancer at an average of 10 years<sup>29</sup> after enteric drainage has changed the recommended management to complete cyst excision. The current treatment of choice is surgical excision, as it is well documented to lead to a decrease in the rate of malignancy from 16 to less than 1%.<sup>25,29</sup> The main goal of management is therefore to prevent malignant degeneration of the cyst via surgical excision. In newly diagnosed adult patients with biliary cysts, the possibility of an existing cancer needs to be considered.

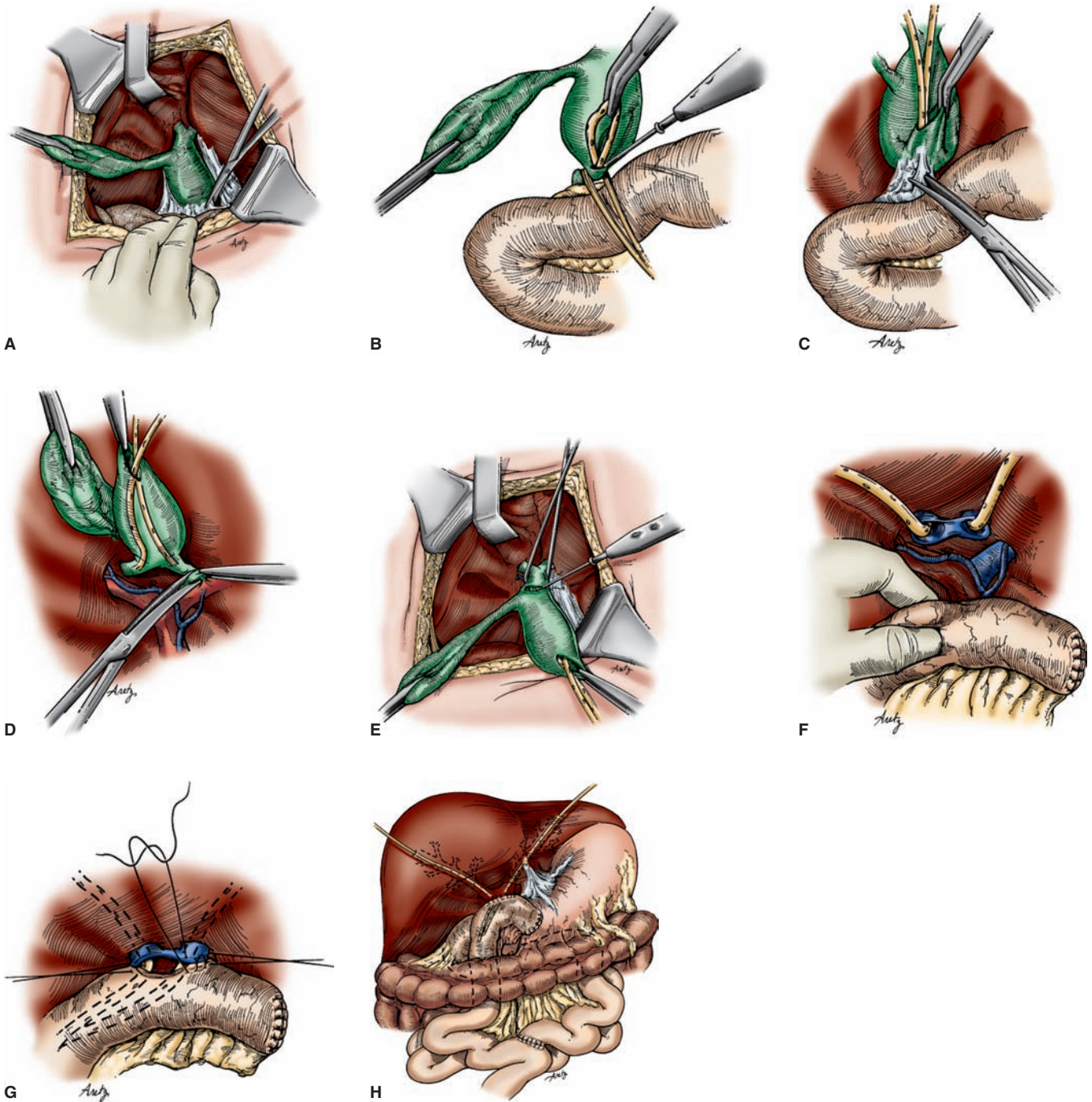
The operative management of choledochal cysts should first consist of careful exploration of the patient. Upon entry to the abdomen via a midline incision, the initial step should be searching for possible metastatic disease. Once metastatic disease has been excluded, management of the choledochal cyst consists of cholecystectomy and complete cyst excision. If possible, excision should include all remnants of the cyst. Because of the extensive fibrosis that may be present, complete excision of the cyst can be technically challenging. Following cholecystectomy and choledochal cyst excision, the bile duct is reconstructed. Standard methods to reconnect the bile duct include hepaticojejunostomy or hepaticoduodenostomy, although Roux-en-Y hepaticojejunostomy is by far the most commonly used technique.

Enteric interposition grafts have been proposed as an option because of theoretical restoration of physiologic bile flow. Both jejunal interposition grafts and appendiceal interposition grafts between the duodenum and bile duct have been reported in the pediatric surgery literature. The value of these techniques, however, has been questioned because of graft dysfunction from stenosis and kinking.<sup>38</sup>

Successful resection and biliary reconstruction with types I and II choledochal cysts has also been reported using laparoscopic techniques, particularly in children.<sup>39</sup> A recent review of 35 adult patients with choledochal cysts that were resected laparoscopically was done, which showed a 0% mortality, 8.5% conversion rate, and 14.8% morbidity rate. Thus, showing that laparoscopic surgery for choledochal cysts was feasible, safe, and even advantageous.<sup>40</sup> While the choice of performing these procedures via an open or laparoscopic approach should be a matter of preference and technical ability for the surgeon, it is important that the procedure not be compromised by the use of laparoscopy.

**Type I Cysts.** The surgical approach recommended for type I is complete cyst excision with Roux-en-Y hepaticojejunostomy reconstruction. The technical aspects of this operation involve mobilization of the hepatic flexure and wide Kocher's maneuver to expose the distal portion of the cyst that lies posterior to the duodenal wall (Fig. 50-6A). After the cyst has been exposed, the gallbladder, which usually arises from the midportion of the choledochal cyst, should be dissected away from the hepatic bed (Fig. 50-6B). The





**FIGURE 50-6** Type I choledochal cyst resection and biliary reconstruction with Roux-en-Y hepaticojejunostomy. **A.** Exposure of cyst and gallbladder. **B.** Cholecystectomy and anterior dissection of the distal choledochal cyst. **C.** Distal extent of the cyst identified, encircled, and opened. **D.** Posterior dissection proceeds caudad to cephalad. **E.** Dissection proceeds until normal hepatic duct is identified. **F.** Cyst is transected and removed at normal duct. **G.** Excision is complete; reconstruction proceeds with a Roux-en-Y hepaticojejunostomy. If the bifurcation is involved, right and left hepaticojejunostomies can be performed. **H.** One-layer hepaticojejunostomy at the hepatic bifurcation.

procedure then focuses on the distal portion of the choledochal cyst (Fig. 50-6C). Type IB (fusiform) cysts are particularly prone to extend distally within the common bile duct as it enters the dorsal aspect of the pancreas. The goal is then to excise the intrapancreatic portion of the cyst

without injuring the pancreatic duct or the long common channel. Resection of the pancreatic head can usually be avoided unless there is documented malignancy. The distal portion of the cyst is encircled and transected as it enters into the pancreas and then reflected cephalad (Fig. 50-6D).

This allows posterior dissection and identification of the portal vein and hepatic artery. The dissection may be facilitated by the presence of a preoperatively placed transhepatic stent. The dissection is continued until the most proximal portion of the duct at the hilum. The cyst is then resected at the hepatic duct confluence or more proximally if the cyst extends into the individual hepatic ducts (Fig. 50-6E). The excised cyst should be examined grossly for malignancy, and then the specimen should be sent for frozen section. If malignancy is present at the surgical margins, the resection may be extended either proximally or distally with the possibility of a pancreaticoduodenectomy to obtain negative margin and adequate lymph node dissection.

Reconstruction of the biliary tree is typically preformed with a Roux-en-Y hepaticojejunostomy at the bifurcation with a single anastomosis or multiple individual anastomoses with each of the hepatic ducts (Fig. 50-6F). A suitable segment of intestine is mobilized with a Roux-en-Y jejunal limb, approximately 60 cm in length, and the anastomosis is created with a standard retrocolic end-to-side Roux-en-Y hepaticojejunostomy, using a single layer of absorbable suture (Fig. 50-6G and 50-6H).

**Type II Cysts.** The recommended procedure for type II choledochal cysts is complete cyst excision. After the cyst has been exposed, the common bile duct wall defect should be closed transversely with or without a T-tube. A transverse closure helps minimize potential narrowing or stricturing of the common bile duct. These patients should also undergo a cholecystectomy at the time of cyst excision. Recently, resection of type II cysts has been completed successfully via a laparoscopic approach.

**Type III Cysts.** Because these cysts are unusual and have an overall lower rate of malignant transformation, reports of surgical excision of choledochoceles are uncommon. Primary management of choledochoceles is by ERCP with endoscopic unroofing of the choledochoceles and sphincterotomy of the common bile duct.<sup>9,41</sup> Surgical management is much less common in patients with choledochoceles compared to patients with other choledochal cysts. Surgical intervention for choledochoceles is needed for patients where sphincterotomy is very difficult or there is concern for malignancy, although very uncommon.

The surgical approach for choledochoceles involves complete excision of the cyst and is approached via transverse duodenotomy in the second or third portion of the duodenum. Before the duodenotomy, cholecystectomy is performed and then the ampulla can be localized by passing a biliary Fogarty catheter into the duodenum via the transected cystic duct. The anatomy can also be better defined via extensive Kocher's maneuver and intraoperative ultrasound. The common bile duct and pancreatic duct must be identified to prevent injury to the pancreatic duct. After the duodenotomy, the pancreatic duct should be intubated with a small Silastic tube so that the intraduodenal biliary cyst can be excised. The cyst is excised and a sphincterotomy can be done by suturing the duodenal mucosa to the bile duct mucosa and pancreatic duct mucosa individually using

interrupted absorbable sutures. A piece of 5 or 8F plastic tubing can be placed into the pancreatic duct and secured with a single absorbable suture as a temporary stent to prevent acute pancreatitis. Finally the duodenotomy is closed in a transverse fashion. It is highly unlikely that a Whipple procedure is required and should be considered only if malignancy is suspected.

**Type IV Cysts.** Types IVa and IVb cysts are managed similarly to type I cysts regarding cholecystectomy, extrahepatic cyst excision, and biliary enteric anastomosis. However, the procedures are technically more challenging, and complete removal is not always possible for type IV cysts because of multiple extrahepatic cysts and intrahepatic cysts. Furthermore, these patients will most likely need reconstruction proximal to the bifurcation and involve anastomosing individual hepatic ducts. If one lobe of the liver predominantly involves the intrahepatic cyst, hepatic lobectomy should be recommended. In many situations, bilobar cyst disease remains leaving this area at risk for malignancy. The long-term management in this situation is controversial. Intrahepatic disease in type IVa disease and Caroli's disease are prone to secondary biliary cirrhosis, hepatic atrophy, and portal hypertension. If the liver parenchyma is not cirrhotic and there is no evidence of intrahepatic duct malignancy, the hepatic parenchyma should be preserved, even in the setting of stones or strictures. If cirrhosis is unilateral or segmental, resection of the involved parenchyma is necessary. Transhepatic biliary stents may be especially helpful for managing patients with type IV cysts, particularly those with type IVa cysts that extend into the intrahepatic ducts. The stents allow for proper decompression alleviating chronic inflammation and may prevent or facilitate the management of long-term complications of biliary stasis, stones, cholangitis, cirrhosis, and be used for surveillance for malignant transformation.

Oncological principles should be followed in cases in which malignancy is involved. If no metastatic disease is present and the vascular supply to the uninvolved hepatic parenchyma can be preserved, resection of the involved bile ducts and adjacent parenchyma and lymph node dissection is indicated. In rare cases, extensive resections involving combined hepatic and pancreatic resection may be necessary. In cases in which metastatic disease is present, palliative stenting of the bile ducts is indicated.

**Type V Cysts.** Type V choledochal cyst (Caroli's disease) is a difficult condition to manage, and the specific recommendations are not well defined. Current recommendations are to begin with conservative management treating infectious complications with drainage, stone extraction, antibiotics, and ursodiol. While Caroli's disease may be diffuse and bilobar, it is often confined to a single lobe and typically on the left side. Similar to type IVa cysts, Caroli's disease, if unilateral or segmental involvement with cirrhosis, can be managed by resection of the involved parenchyma, resulting in decreased incidence of recurrent cholangitis, pancreatitis, cholestasis, and the need for invasive procedures. Bilobar Caroli's disease is a challenging problem. The use of ursodiol and antibiotics may improve bile flow and reduce the incidence of biliary stones, sludge, and chol-

angitis. In the absence of cirrhosis or malignancy, Roux-en-Y hepaticojejunostomy with bilateral transhepatic Silastic stents may be indicated to improve biliary drainage. Following operative management, the stents are left in place for 6–12 months, depending on the extent of intrahepatic stones and strictures. Patients that continue to have recurrent cholangitis or recurrent stones often require indefinite transhepatic stenting. Patients with Caroli's disease and progressive liver disease and cirrhosis should be considered for liver transplantation. The timing for when transplantation should be pursued is still under debate. Because patients with Caroli's disease may also have polycystic kidney disease, combined liver-kidney transplants have had excellent outcomes.

## OPERATIVE RESULTS

Early postoperative complications include pancreatitis, anastomotic leakage, cholangitis, and wound infection. Most series show morbidity of 9–41% and mortality 0–3.3%.<sup>9,25,40</sup> The median length of stay ranges from 7 to 12 days postoperatively, where patients with a laparoscopic approach had a slightly decreased stay but longer operative time. Late postoperative complications include the formation of intrahepatic strictures and stones, anastomotic stricture, malignancy, cirrhosis, and intrahepatic abscess formation.

However, long-term results following resection of a benign choledochal cyst with biliary reconstruction are generally excellent, especially with type I cysts. The rate of biliary stricture had been found to be very low. The management of more proximal cysts can be more challenging, particularly in the presence of extensive intrahepatic stone disease and liver damage. Type IVa cyst patients have the greatest risk for intrahepatic calculi and stricture formation secondary to the intrahepatic cystic disease. A series by Tsuchida and associates examined 103 patients with a mean follow-up of 12.5 years. Patients with type IVa disease with dilated intrahepatic ducts developed strictures at a rate 40%, with virtually all developing cholangitis.<sup>42</sup> In contrast, management with large-bore Silastic transhepatic stenting results in 90% success without recurrent cholangitis.<sup>43</sup> Patients remain at long-term risk for cholangitis, postoperative biliary strictures, intrahepatic stones, pancreatitis, or malignancy.

## Summary

Choledochal cyst disease is uncommon. The presentation of the disease is more common in children but has been increasing in the adult population, especially in Western countries. Currently, the diagnosis in adults is based on cross-sectional imaging and cholangiography, primarily CT and MRCP. The consequences of not treating choledochal cyst disease can lead to malignant degeneration. The majority of cases of biliary cysts can be treated effectively with cholecystectomy, cyst excision, and biliary-enteric reconstruction. Long-term follow-up is necessary for surveillance of cancer, cholangitis, intrahepatic stones, and postoperative biliary strictures.

## BENIGN BILIARY STRICTURES

Benign biliary strictures include several diverse clinical entities that share the common characteristic of biliary obstruction. Although advances in medical technology have greatly improved their management, bile duct strictures continue to pose a significant clinical challenge. Many of these strictures result from iatrogenic injuries, often in young patients who are otherwise in good health and expected to live for years. Improper management may result in life-threatening complications, including cholangitis, portal hypertension, biliary cirrhosis, and end-stage liver disease. Proper diagnosis and treatment are essential in preventing these complications.

Benign biliary strictures may affect the intra- or extrahepatic bile ducts or both, and may be solitary or multiple. There are numerous etiologies of benign bile duct strictures (Table 50-2). The vast majority of strictures occur following injury to the bile duct during cholecystectomy; however,



**TABLE 50-2: ETIOLOGY OF BENIGN BILIARY STRICTURES**

### Congenital Strictures

- Biliary atresia

### Postoperative Strictures

- Laparoscopic cholecystectomy
- Open cholecystectomy
- Common bile duct exploration
- Injury at other operative procedures
  - Gastrectomy
  - Hepatic resection
  - Portacaval shunt
  - Biliary-enteric anastomotic stricture
  - Pancreatic surgery
  - Liver transplantation
- Blunt or penetrating trauma
- Endoscopic or percutaneous biliary intubation

### Strictures Due to Inflammatory and Other Conditions

- Primary sclerosing cholangitis
- Chronic pancreatitis
- Cholelithiasis and choledocholithiasis
- Cholangiohepatitis and other parasitic disease
- Sphincter of Oddi stenosis
- Duodenal ulcer
- Granulomatous lymphadenitis
- Secondary sclerosing cholangitis
  - Toxic drugs
  - Infectious cholangiopathy from AIDS
  - Hepatic allograft rejection
  - Graft-versus-host disease in bone marrow transplantation
  - Histiocytosis X
  - Congenital biliary abnormality
  - Mast cell cholangiopathy



other procedures in the upper abdomen may injure the biliary tract, especially procedures involving the liver, pancreas, and stomach/duodenum. Inflammatory conditions such as pancreatitis, gallstone disease, and primary sclerosing cholangitis are also important causes of benign bile duct strictures.

## Postoperative Biliary Stricture

The introduction and widespread use of laparoscopic cholecystectomy in the 1990s resulted in a significant increase in the frequency of biliary injuries and associated bile duct strictures. Postoperative bile duct injuries may present early in the postoperative period with biliary leak, or months to years later with jaundice or cholangitis from biliary stricture. Proper management begins with delineation of biliary anatomy followed by repair. Nonoperative balloon dilation via percutaneous transhepatic or endoscopic routes is appropriate in select patients with intact biliary-enteric continuity. Operative repair, however, remains the mainstay of treatment in patients with benign strictures.

### INCIDENCE

Most bile duct injuries and strictures occur in patients following abdominal surgery in the right upper quadrant. Cholecystectomy is performed on over 750,000 patients on an annual basis in the United States and accounts for over 90% of postoperative biliary strictures and injuries. Although the exact incidence of injuries is unknown because many cases go unreported, numerous studies have attempted to define the incidence and mechanisms of bile duct injuries associated with cholecystectomy. An incidence of one to three major bile duct injuries per 1000 cases was consistently reported during the era of open cholecystectomy. Roslyn and colleagues demonstrated a 0.2% incidence of major bile duct injuries from a series of over 42,000 open cholecystectomies.<sup>44</sup> A literature review by Strasberg and associates<sup>45</sup> of over 25,000 open cholecystectomies performed since 1980 revealed a 0.3% incidence of major bile duct injuries. In contrast, in a review of nearly 125,000 laparoscopic cholecystectomies reported in the literature in the years 1991–1993, Strasberg and associates reported an overall incidence of biliary injuries of 0.85% and an incidence of major injuries of 0.52%. Multiple large surveys from numerous centers have estimated the rate of major bile duct injury with laparoscopic cholecystectomy to be 0.4–1.3%.<sup>46–49</sup> Therefore it appears that the incidence of bile duct injury associated with laparoscopic cholecystectomy is two to three times greater than that with open cholecystectomy.

In the early 1990s, many authors ascribed the increased incidence of bile duct injuries with laparoscopic cholecystectomy as a “learning curve” associated with the new technique and projected that the rate of injury associated with laparoscopic cholecystectomy would decline with time. Unfortunately, these projections were not correct, and the rate of bile duct injuries appears now to have stabilized at a level still higher

than that of the prelaparoscopic era. A report of over 10,000 cases at US military institutions<sup>46</sup> and nationwide reviews in New Zealand<sup>50</sup> and Italy<sup>48</sup> have demonstrated no significant improvement in the incidence of injury as surgeons have passed through the learning curve. It is likely that the technology and technique associated with laparoscopic cholecystectomy will need fundamental enhancements for the current rate of injury to diminish.

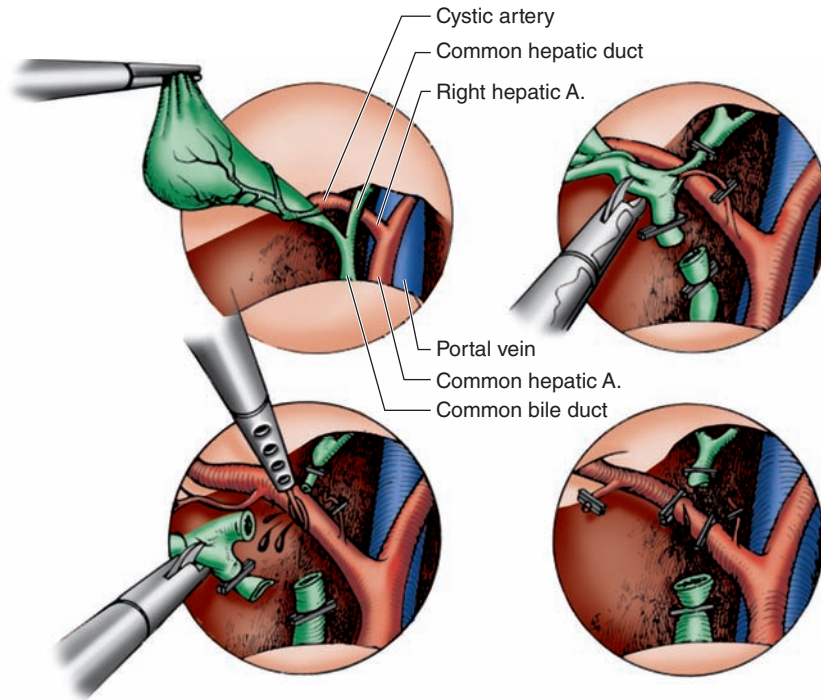
### PATHOGENESIS

Several factors are associated with increased risk of bile duct injuries at the time of cholecystectomy. Some of these factors may be pathologic, anatomic variations, and/or technical problems that are unique to the laparoscopic approach. Ultimately, the final common pathway of most injuries is either a technical error or misinterpretation of the anatomy. The “classic” biliary injury during laparoscopic cholecystectomy includes misidentification by the surgeon of the common bile duct as the cystic duct or misidentification of an aberrant right sectoral duct as the cystic duct (Fig. 50-7).

**Pathologic Factors.** A number of patient-related factors have been associated with bile duct injury. Patients with acute cholecystitis may have severe inflammation in the porta hepatis and Calot’s triangle, which can make a laparoscopic approach difficult. Patients with complicated gallstone disease also have a higher risk of injury than those with chronic cholecystitis, symptomatic cholecystitis, or biliary colic. Fletcher and colleagues<sup>47</sup> reported that complex cases, which included patients with acute cholecystitis, cholangitis, and gallstone pancreatitis, are associated with an increased incidence of bile duct injuries (1.7 vs 0.6%) versus other indications for laparoscopic cholecystectomy. These patients are also associated with a higher rate of conversion to open cholecystectomy (29 vs 8%).

**Anatomic Variations.** Anatomic variations can also contribute to bile duct injury. A congenitally short cystic duct or a duct that appears shortened by an impacted stone may also lead to misidentification of the common bile duct, resulting in injury or transection. Other high-risk congenital anatomic anomalies include a long common wall between the cystic and common bile duct or the cystic duct inserting into the right hepatic duct. The cystic duct has a very variable pattern ranging from joining the common hepatic duct quite high, almost at the biliary confluence, or running parallel to the common hepatic duct before inserting into the common bile duct almost at the level of the pancreas. The risk of bile duct injury also appears to be increased in patients with obesity, chronic inflammation, excessive fat in the dissection area, inadequate exposure, poor or excessive clip placement, injudicious use of electrocautery, and bleeding into the operative field.

**Technical Factors.** Several technical factors associated with laparoscopic cholecystectomy make it prone to bile duct injury. First, standard laparoscopy gives a limited perspective from its



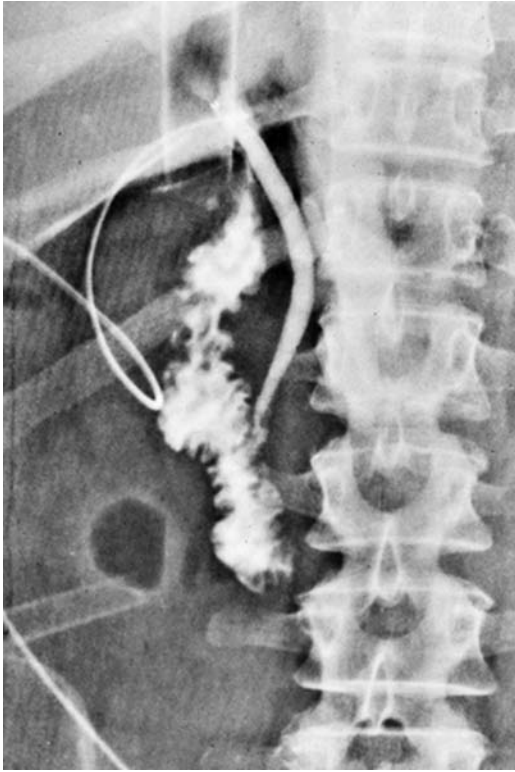
**FIGURE 50-7** Classic laparoscopic bile duct injury. Confusion of the common bile duct with the cystic duct leads to clipping and division of the common bile duct. In many cases the common hepatic duct will not be clipped but will instead be divided by scissors or cautery. (Reproduced, with permission, from Davidoff AM, Pappas TN, Murray EA, et al. Mechanisms of major biliary injury during laparoscopic cholecystectomy. *Ann Surg.* 1992;215:196.)

end, viewing a two-dimensional picture of the operative field. The classic laparoscopic injury occurs when the cystic duct and the common bile duct are aligned in the same plane, leading to clipping and dividing the common bile duct. Retraction of the gallbladder infundibulum excessively cephalad aligns the cystic and common bile duct, leading to misidentification and injury. As the operative dissection is carried cephalad, the common hepatic duct may also be transected, often without recognition, resulting in a postoperative bile leak. The right hepatic artery may also be injured, creating excessive bleeding. This classic injury is estimated to occur in over 75% of major bile duct injuries referred to major centers. The classic laparoscopic injury is usually also associated with excision of a segment of bile duct, making the proximal extent of the injury high, usually at or near the hepatic duct bifurcation.

There is also a growing understanding of surgeon cognitive factors associated with bile duct injury during laparoscopic cholecystectomy. A report examined 252 laparoscopic cholecystectomy bile duct injuries using the human error factor and cognitive science techniques and found that 97% of injuries were due to a visual perceptual illusion or inadequate visualization.<sup>51</sup> In a subsequent study from the same group, one of the main explanations for the surgeon's frequent inability to recognize a bile duct injury associated with laparoscopic cholecystectomy appears to be confirmation bias, which is the propensity to seek clues to confirm a belief and to discount clues that might discount that

belief.<sup>52</sup> While cognitive factors are important for understanding the psychological issues associated with bile duct injuries, surgeons must continue to have appropriate corrective mechanisms in place to minimize the chance of these injuries, including knowledge of anatomy, typical mechanisms of injury, appropriate level of suspicion, and logic.<sup>53</sup>

The role of intraoperative cholangiography in preventing bile duct injury remains controversial, with mixed results from reported series. A large series in Australia demonstrated a protective effect,<sup>47</sup> whereas a review from the Veteran's Administration Hospitals demonstrated that bile duct injury occurred more commonly in patients undergoing cholangiography (0.7 vs 0.2%).<sup>45</sup> Clinical information from patients in the Medicare claims database and surgeon data from the American Medical Association Physician Masterfile were recently used to examine the influence of intraoperative cholangiography on the rate of major bile duct injury, finding the rate of injury to be significantly higher when intraoperative cholangiography was not used.<sup>54</sup> In this study, surgeons who routinely performed intraoperative cholangiography had a lower rate of injuries than those who did not, and this lower rate disappeared when intraoperative cholangiography was not used by these surgeons. Whether or not intraoperative cholangiography actually prevents bile duct injury, the procedure can often lead to early recognition of the injury, and therefore potentially minimize the injury and its associated morbidity (Fig. 50-8). The best



**FIGURE 50-8** Intraoperative cholangiogram obtained during laparoscopic cholecystectomy. Cholangiogram demonstrates an injury to the common bile duct (which is clipped such that contrast does not fill the proximal biliary tree). Contrast fills the normal distal bile duct and duodenum.

technical approach in preventing and limiting bile duct injuries, regardless of the use of cholangiography, includes methodical dissection with careful exposure and identification of the structures of the triangle of Calot.<sup>44</sup>

The operative technique for laparoscopic cholecystectomy, which defines the “critical view of safety,” is a corrective mechanism that helps prevent misidentification and injury to the major bile ducts.<sup>55</sup> In this method, the triangle of Calot is cleared of fat and fibrous tissue. Only two structures are connected to the lower end of the gallbladder once this is done; the cystic duct and cystic artery and the lowest part of the gallbladder attachment to the liver have been exposed. Once the critical view is attained, the cystic duct and artery may be clipped and divided, as they have been conclusively identified. Failure to achieve the critical view is an indication for conversion or possible cholangiography.

**Physiologic Factors.** Several physiologic processes have been implicated in the formation of bile duct strictures. Ischemia of the bile duct from excessive periductal dissection may have an important role in the formation of postoperative anastomotic strictures. Studies show that the blood supply to the ducts can be thought of having three elements: afferent arteries, marginal arteries, and the epicholedochal plexus. The afferent arteries are branches of the

hepatic arteries or less commonly of the superior mesenteric artery or other upper abdominal arteries. The marginal arteries lie on and run parallel to the long axis of the bile ducts. Anatomically, these are the major arteries of the common bile duct located at the 3- and 9-o’clock positions that can be injured or divided by unnecessary dissection during cholecystectomy, or more commonly the bile duct can be excessively “skeletonized” while performing a bile duct anastomosis.

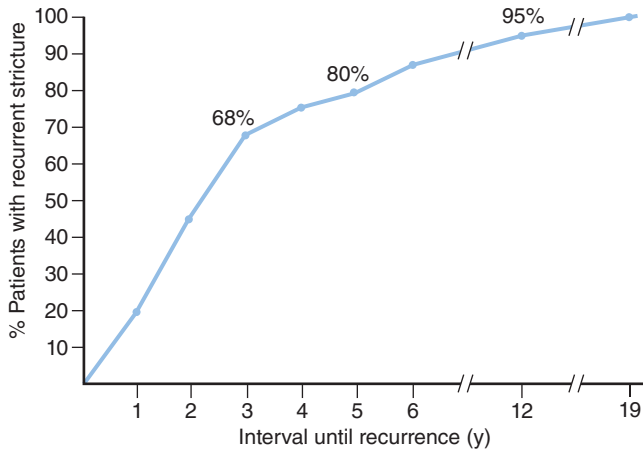
Fibrosis and scarring can be intense following a bile duct injury. In canine models, bile duct ligation results in an elevation of bile duct pressure that is immediate and sustained and is accompanied by an increased bile duct diameter and formation of high local concentrations of bile salts at the canalicular membrane.<sup>56</sup> A month after bile duct ligation, the bile duct wall is thickened, will have reduced mucosal folds, and have loss of surface microvilli with epithelial degeneration. On pathologic staining 2 weeks after ligation, there is evidence of increased synthesis of collagen and proline hydroxylase activation. Recently, an animal model of bile duct injury demonstrated healing in traumatized bile duct tissue to occur in a mode of overhealing, implicating myofibroblasts as the main cause of contracture of scar and stricture of the bile duct.<sup>57</sup> Inflammation in the surrounding tissues compounds the problem by encouraging fibrosis, especially when associated with bile leakage.

Injuries and strictures of bile ducts occur less commonly in association with other operative procedures. After cholecystectomy, common bile duct exploration is the next most frequently associated procedure with stricture, typically occurring at the site of choledochotomy or an impacted stone. Procedures requiring biliary-enteric anastomoses may be complicated by postoperative stricture. Typically, these procedures involve choledochoenteric or hepaticoenteric anastomosis in such cases as reconstruction after pancreaticoduodenectomy, bile duct resection for mid-bile duct tumors, and after excision of choledochal cysts. Gastrectomy and hepatic resection are the most common nonbiliary operations associated with postoperative strictures. Injuries associated with gastrectomy typically occur during pyloric and proximal duodenal dissection associated with closure of the duodenal stump or with creating a Billroth I gastroduodenostomy. Injuries during hepatic resection often take place during dissection of the hepatic hilum. Bile duct injury and stricture is also associated with hepatic transplantation, pancreatic procedures, and penetrating or blunt trauma. Finally, the recurrence of stricture after an initial attempt at repair is not uncommon and may occur over a decade following initial repair (Fig. 50-9).<sup>58</sup>

## CLASSIFICATION

Strictures and injuries to the bile duct vary widely in their complexity and nature. The ease of management, operative risk, and outcome of biliary injuries vary considerably depending on the location and the type of injury. Injuries associated with laparoscopic cholecystectomy are often complex, located at or





**FIGURE 50-9** The cumulative percentage of recurrent strictures is shown with respect to the time interval from the initial repair to the next repair. (Adapted, with permission, from Pitt HA, Miyamoto T, Parapatil SK et al. Factors influencing outcome in patients with postoperative biliary strictures. *Am J Surg* 1982;144:14–21.)

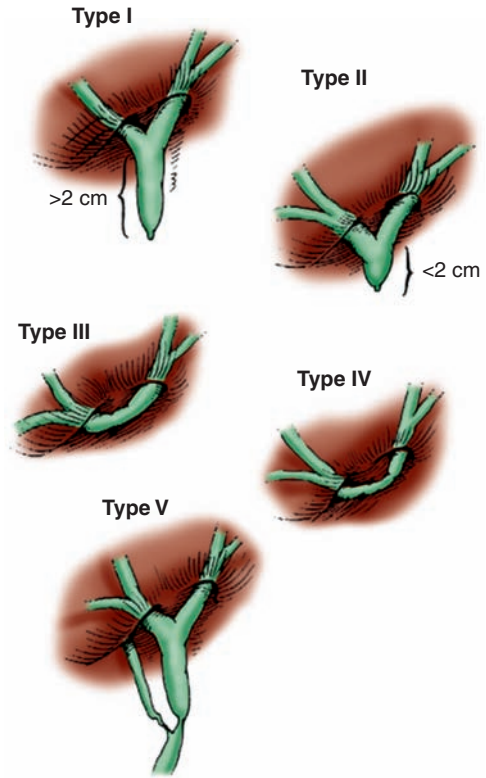
near the level of the hepatic duct bifurcation, and potentially include one or more hepatic duct branches. Minor injuries to the bile duct include lacerations of the bile duct, clip placement on an intact bile duct, injury via electrocautery, or avulsion of the cystic duct.

A number of classification systems or major bile duct strictures have been presented, with the traditional classification being that described by Bismuth (Fig. 50-10), which classifies major injuries based on the level of obstruction of the biliary tree regarding the hepatic duct confluence or the involvement of an aberrant right sectoral hepatic duct with or without a concomitant hepatic duct stricture.<sup>59</sup> A drawback of the Bismuth classification system is that patients with limited strictures, isolated right hepatic duct strictures, or cystic duct leaks cannot be classified. The Strasberg classification system has been developed to classify all types of injury and is used extensively in describing bile duct injuries associated with laparoscopic cholecystectomy (Table 50-3).<sup>55</sup>

**PRESENTATION**

Most patients with bile duct injuries unfortunately are not recognized at the time of laparoscopic cholecystectomy. After open cholecystectomy, only 10% of injuries are suspected after the first week, but nearly 70% are diagnosed within the first 6 months after operation.<sup>58</sup> However, injuries after laparoscopic cholecystectomy are recognized earlier more likely because of heightened awareness and suspicion.

Large series reviews have demonstrated that less than one-third of major bile duct injuries are detected at the time of injury during laparoscopic cholecystectomy.<sup>60,61</sup> Possible indications that a bile duct injury had occurred intraoperatively include a persistent and unexpected bile leak, atypical anatomy, or a second bile duct discovered during dissection. Injuries may



**FIGURE 50-10** Bismuth classification system. Classification of bile duct strictures based on the level of the stricture in relation to the confluence of the hepatic ducts. Types III–V are usually considered complex injuries. (Reproduced, with permission, from Bismuth H. Postoperative strictures of the biliary tract. In: Blumgart LH, ed. *The Biliary Tract. Clinical Surgery International Series*, Vol. 5. Edinburgh, Scotland: Churchill Livingstone; 1983:209–218.)

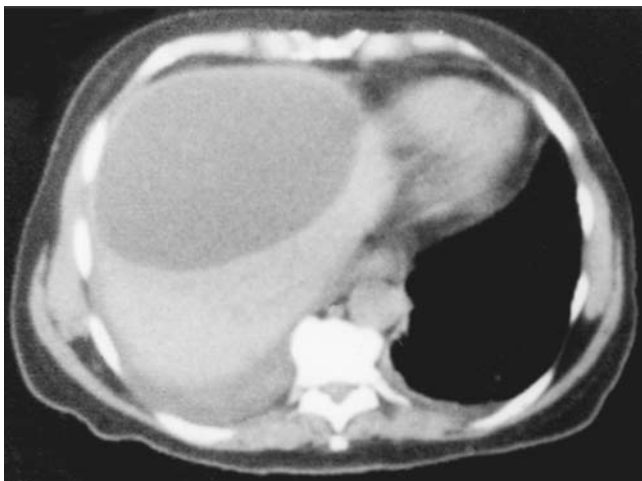
also be discovered if the removed gallbladder specimen and cystic duct are carefully examined to ensure normal duct anatomy. Intraoperative cholangiography will also diagnose bile duct injuries at the time of cholecystectomy and may minimize injury, allowing early repair (see Fig. 50-8).

**TABLE 50-3: STRASBERG CLASSIFICATION OF BILIARY INJURY AND STRICTURE**

Class A	Injury to small ducts in continuity with the biliary system, with cystic duct leak
Class B	Injury to sectoral duct with consequent obstruction
Class C	Injury to sectoral duct with consequent bile leak
Class D	Lateral injury to extrahepatic ducts
Class E <sub>1</sub>	Stricture >2 cm distal to bifurcation
Class E <sub>2</sub>	Stricture <2 cm distal to bifurcation
Class E <sub>3</sub>	Stricture at bifurcation
Class E <sub>4</sub>	Stricture involving right and left bile ducts; ducts are not in continuity
Class E <sub>5</sub>	Complete occlusion of all bile ducts

The clinical presentation of patients with a bile duct injury in the early postoperative period depends on the type of injury. In most cases the injury is associated with uncontrolled bile leakage into the peritoneal cavity, while in others the duct is completely ligated by clip placement leading to obstructive jaundice usually without cholangitis. Patients with significant bile leaks generally present within the first week after operation with abdominal pain, distention, nausea, vomiting coupled with fever, or other signs of sepsis. Prompt investigation is required if patients have bilious drainage from incision sites or from intraoperatively placed drains. Bile leaks result in either biliary ascites with associated chemical peritonitis if allowed to drain freely into the abdominal cavity or, alternatively, bile can become loculated resulting in biloma (Fig. 50-11) or, if infected, a subhepatic or subdiaphragmatic abscess. In the latter scenario, presentation is more subtle with low-grade fever and localized abdominal pain. Because significant abdominal complaints are uncommon after uncomplicated laparoscopic cholecystectomy, all patients with such symptoms should be appropriately evaluated without delay for possible bile leak to prevent progression to frank sepsis. Failure to recognize a major bile leak or to institute appropriate treatment can result in life-threatening sepsis and the development of multisystem organ failure. In a recent series of 200 major bile duct injuries treated at The Johns Hopkins Hospital, three patients were transferred to this tertiary care center and died of complications of sepsis secondary to delayed or inadequate treatment.<sup>62</sup>

Bile duct strictures may also present months to years after the original operation. Patients with a slowly evolving stricture may have nonspecific abdominal complaints, jaundice, pruritus, cholangitis, or derangements in liver function tests. In addition, patients with an isolated right sectoral hepatic



**FIGURE 50-11** CT scan demonstrating biloma associated with biliary leak after bile duct injury. (Reprinted, with permission, from Lillemoie KD, Pitt HA, Cameron JL. Postoperative bile duct strictures. *Surg Clin North Am.* 1990;70:1362.)

duct injury may present with a history of unexplained fevers, pain, or generalized malaise. Episodes of cholangitis are typically mild and respond effectively to antibiotics. Less often, patients can present with painless jaundice, which can be confused with a malignant stricture.

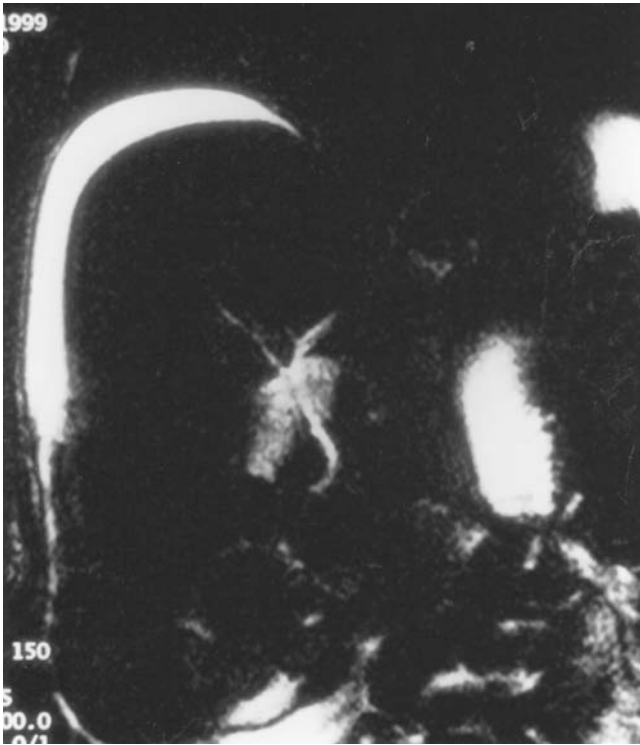
The findings on physical examination are usually not specific. Abdominal distention and pain may be seen in patients with bile peritonitis or focal tenderness if the patient presents with a collection or abscess. If the patient has jaundice, there may be multiple excoriations from pruritus. Hepatomegaly may be present in patients with chronic biliary obstruction or possible splenomegaly if there is any portal hypertension from portal venous injury or severe underlying hepatocellular damage.

## DIAGNOSIS

Patients presenting with a biliary leak from injury usually present without evidence of biliary obstruction, and bilirubin levels are normal or slightly elevated due to absorption of bile from the peritoneal cavity. Patients with postoperative bile leak or cholangitis will also have an elevated white blood cell count, pyrexia, or occasionally frank sepsis. Patients with postoperative bile duct strictures typically reveal a stereotypical biochemical profile of cholestasis. In particular, liver function tests typically consist of an elevated alkaline phosphatase and normal or slightly elevated liver transaminases (alanine and aspartate aminotransferases). Serum bilirubin levels are usually elevated in the range of 2–6 mg/dL. In rare cases, patients with long-term obstruction will present late in the course of disease with cirrhosis, diminished serum albumin, and abnormal coagulation studies from altered hepatic synthetic function.

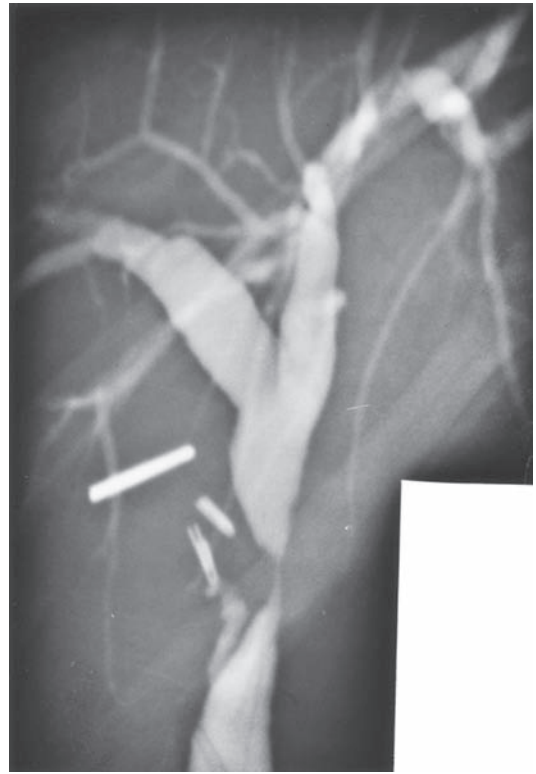
Definitive diagnosis for bile duct strictures and injuries requires radiographic imaging. Ultrasound and abdominal CT scan are both helpful in patients who present in the early postoperative period for the detection of bilomas and biliary ascites, as well as bile duct dilation from obstruction. Ultrasound has little value in assessing the extent of a stricture and is unhelpful if the biliary tree is decompressed. Abdominal CT scan is usually the best first-line study often showing a dilated biliary tree or intra-abdominal collections or ascites, which can direct further investigations. The CT should be performed with arterial-phase contrast to evaluate for concomitant vascular injury. Nuclear medicine imaging with technetium-HIDA (hepatobiliary iminodiacetic acid) scanning can demonstrate bile leakage noninvasively but typically does not have the sensitivity to define the specific anatomic site of injury. MRCP has been demonstrated to be an effective noninvasive method for demonstrating biliary leakage or obstruction, as well as precisely defining biliary anatomy and the nature of the injury (Fig. 50-12). Last, sinography, typically performed by injecting water-soluble contrast via operatively placed drains, can define the biliary anatomy and the source of bile leakage.

Cholangiography currently remains the gold standard for evaluating the biliary tree. Endoscopic retrograde

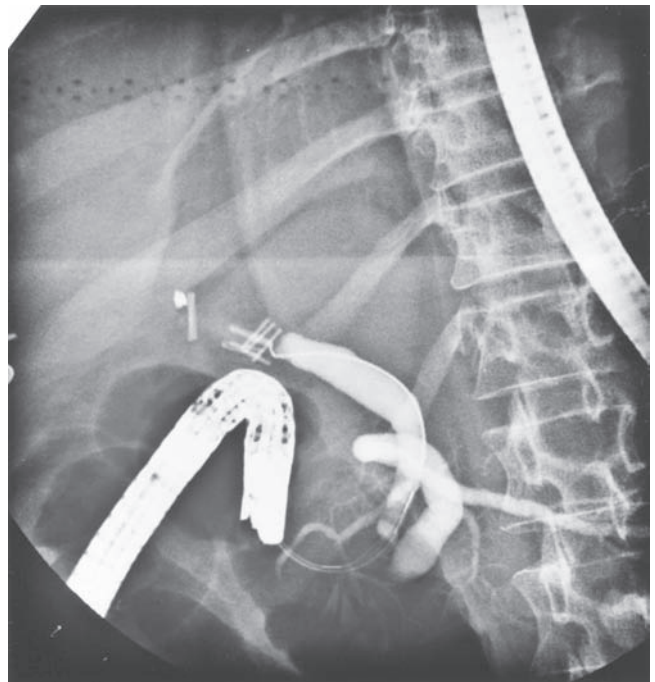


**FIGURE 50-12** Diagnostic magnetic resonance cholangiopancreatography (MRCP) demonstrating biliary anatomy associated with a cystic duct leak after laparoscopic cholecystectomy. There is an intact biliary system with extravasation of contrast in the subhepatic space.

cholangiography (ERC) is performed via a distal approach to the biliary tree and is useful only in patients if the native bile duct is intact, such as with partial injuries or after end-to-end repair. ERC is the procedure of choice for patients suspected of cystic duct leaks (Fig. 50-13A) or leaks from peripheral hepatic radicals (ducts of Luschka). In these cases, the biliary leak may be effectively controlled with the use of an endoprosthesis. Most cases of major bile duct injury, however, are associated with complete duct transection, and the cholangiogram via the retrograde endoscopic route will demonstrate a normal distal bile duct terminating in misapplied clip(s) devices (Fig. 50-13B). Therefore, ERC will neither define the site of bile leakage nor the proximal anatomy necessary for reconstruction. In such cases, PTC is necessary to define the proximal biliary anatomy and the site of injury (Fig. 50-14). In addition to delineating the anatomy, a percutaneous biliary drainage catheter should be placed at the time of PTC to decompress the biliary tree, and treat cholangitis and control the biliary leak. Percutaneous biliary drainage catheters will also be useful at the time of operative repair as a guide for dissection and identification of the transected bile duct, which is often retracted high into the liver hilum. Finally, in those cases in which biliary-enteric continuity exists, percutaneous catheters allow access for balloon dilation.



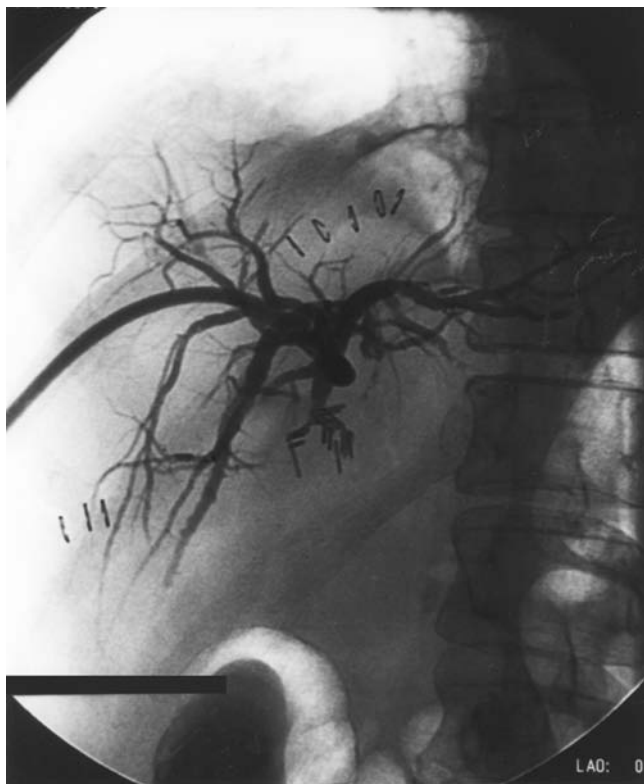**A**



**B**

**FIGURE 50-13** **A.** Endoscopic retrograde cholangiopancreatogram demonstrating cystic duct leak. **B.** Endoscopic retrograde cholangiopancreatogram with multiple clips across the common bile duct without visualization of the proximal biliary tree in a patient with total transection of the common bile duct during laparoscopic cholecystectomy.





**FIGURE 50-14** Percutaneous transhepatic cholangiogram in a patient with complete transection of the common hepatic bile duct. Note the surgical clips near the cutoff point.

Significant arterial injury associated with major bile duct injury has been increasingly reported in recent years. The “classic” biliary injury during laparoscopic cholecystectomy in which the common bile duct is mistaken for the cystic duct often includes injury to the right hepatic artery as it enters either above or below the hepatic duct. While this injury may cause bleeding at the time of operation, the arterial injury often is unnoticed, usually resulting in arterial occlusion or less commonly a hepatic artery pseudoaneurysm. In a large study by Stewart et al<sup>63</sup> on combined right hepatic artery and bile duct injury, there were 7 pseudoaneurysms compared to 77 right hepatic artery occlusions. The incidence of disruption of the right branch of the hepatic artery during major bile duct injury ranges between 12 and 39%.<sup>64</sup> However, the presence of an arterial injury does not appear to affect either early or late outcomes.<sup>63,65</sup> Because of the recognized association of vascular injuries during laparoscopic bile duct injuries especially if there is a history of excessive bleeding at the time of cholecystectomy, a CT scan with arterial and venous phase contrast or arteriography should be obtained. Some authors believe if arterial injury has occurred, biliary reconstruction should be delayed to decrease the risk of late stricture recurrence.<sup>55</sup> In patients presenting in a delayed manner after cholecystectomy, the combination of biliary and vascular injuries often leads to

segmental or lobar atrophy, which may suggest a role for hepatic resection rather than reconstruction.

## PREOPERATIVE MANAGEMENT

The timing of presentation is often a primary determinant of the preoperative management of a patient with a postoperative bile duct stricture or injury. In the early postoperative period, patients with a bile leak associated with a bile duct injury are often either septic due to intra-abdominal infections or otherwise manifesting a systematic inflammatory response from chemical peritonitis associated with the bile leak. Treatment and control of sepsis may require broad-spectrum parenteral antibiotics, percutaneous biliary drainage, and percutaneous or, rarely, operative drainage of bilomas. Once sepsis is controlled, there is no hurry in proceeding with surgical reconstruction of the bile duct injury. Most biliary fistulae can be controlled with the combination of proximal biliary decompression and external drainage. After early control and clinical improvement, the patient may be discharged home for several weeks to permit return of overall health and for the resolution of inflammation in the periportal region.

It should be stressed that despite the belief of many surgeons that a suspected bile leak warrants urgent reoperation, exploration with an attempt at repair should be avoided early after presentation with a bile leak. In this situation exploration often reveals marked inflammation associated with bile spillage and small, decompressed bile ducts retracted high into the porta hepatis, making recognition of the injury and repair virtually impossible. Instead of proceeding to urgent exploration, a more prudent approach is to define biliary anatomy via preoperative cholangiography and to control the bile leak with percutaneous stents. Early operative intervention to deal with bile collections or ascites is not usually required because the intraperitoneal bile either can be drained percutaneously or is simply absorbed by the peritoneal cavity. Delayed reconstruction, with facilitation by percutaneous biliary catheters, allows for the most favorable operative results especially when concurrent hepatic artery injury is suspected.

Patients who present with a biliary stricture remote from the initial operation usually experience symptoms of cholangitis that necessitate urgent cholangiography and biliary decompression. The choice of technique depends on the nature of any prior repair. If the native bile duct is intact, endoscopic drainage with stent placement can sometimes be achieved. If a prior hepaticojejunostomy has been performed, transhepatic biliary drainage will be necessary for diagnosis. Both parenteral antibiotics and biliary drainage are central to controlling sepsis. Patients who present with jaundice without cholangitis should undergo either ERC or PTC to define the anatomy. As with patients presenting early in the postoperative period, ERC may not completely define the proximal biliary anatomy, making PTC the more favorable procedure. Preoperative biliary decompression in patients presenting

with jaundice without cholangitis has not been demonstrated to improve outcome.

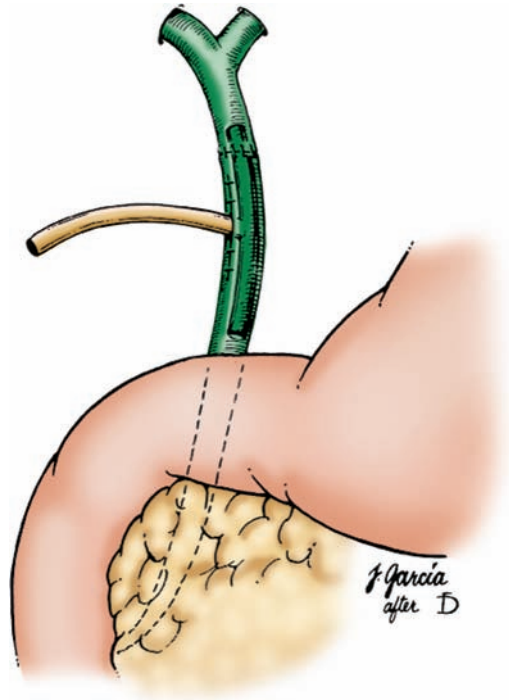
## OPERATIVE MANAGEMENT

Operative repair for postoperative bile duct strictures is aimed at reestablishing a reliable, long-term conduit for bile flow from the biliary tree to the gastrointestinal tract. Complications of an unsuccessful operative procedure include bile leak resulting in fluid collection or abscess, recurrent stricture with stones or sludge and potentially cholangitis, or biliary cirrhosis. To this end, the ideal technical procedure results in a tension-free, mucosa-to-mucosa repair to a segment of uninjured bile duct. Ideally, surgeons should also seek to maintain ductal length by not sacrificing tissue. Options for operative repair may include end-to-end repair, Roux-en-Y hepaticojejunostomy, or choledochoduodenostomy. The optimal operative procedure is contingent upon the timing of presentation, overall clinical status of the patient, and level and type of injury.

**Injury Recognized at Initial Operation.** If injury to the bile duct is recognized at the time of initial cholecystectomy, the surgeon should consider his or her ability to technically perform immediate reconstruction and should consider seeking the counsel and assistance of a more experienced surgeon. Studies show that immediate open repair by an experienced surgeon is associated with reduced morbidity, shorter duration of illness, and lower cost.<sup>62</sup> Each failed attempt at repair is associated with loss of bile duct length and exacerbation of a difficult situation. If the surgeon is unable to repair the injury and competent help is unavailable, drains should be placed to control any bile leak and the patient referred immediately to a tertiary specialty center.

When the surgeon suspects an injury or variant anatomy, biliary anatomy must be clearly defined using intraoperative cholangiography and/or careful dissection, being cautious to avoid additional injury or devascularizing the bile duct. Conversion from laparoscopic to open cholecystectomy is often necessary to properly identify anatomy and the injury. Segmental or accessory duct injuries where the diameter of the bile duct is less than 3 mm and where the bile duct does not communicate with the major duct system or drain a large segment of hepatic parenchyma on cholangiography may be ligated. Bile ducts that are 4 mm or larger in diameter or when the cholangiogram shows sectoral or lobar drainage, then the ducts must be operatively repaired, as they likely drain multiple hepatic segments or an entire liver lobe.

Immediate intraoperative repair is indicated in most cases for a major injury to the common hepatic or common bile duct. The nature of that repair is determined by the length of separation between opposed residual, viable ends of the injured duct. Partial common duct transections, involving less than 180-degree circumference of the biliary tree, may be closed primarily over a T-tube using interrupted absorbable sutures (Fig. 50-15). Transection of the common duct involving more than 180-degree circumference or complete



**FIGURE 50-15** Primary end-to-end repair of the biliary tree over a T-tube. In general, this technique is used for partial transections of the bile duct, when there has been no associated loss of duct length. Note that the T-tube does not exit at the site of injury.

transections with an injury less than 1 cm in length can usually be repaired with an end-to-end anastomosis with a T-tube that exits either above or below the anastomosis via a separate choledochotomy. Primary reconstruction of the bile duct, however, should be used very selectively and be avoided when the injury is near the bifurcation or when duct approximation cannot be accomplished without tension. A generous Kocher maneuver should be done to mobilize the duodenum out of the retroperitoneum and should be used to alleviate tension at the repair. In at least one series, a 100% resticture rate following primary end-to-end repair has been reported.<sup>66</sup> Other series have shown better results and suggest an advantage that, if a stricture occurs, endoscopic access for balloon dilation remains an option.<sup>67</sup>

Transections of the bile duct high in the biliary tree or with significant loss of bile duct length cannot be repaired with a primary biliary anastomosis that remains tension-free. These injuries require reconstruction using a biliary-enteric anastomosis typically using Roux-en-Y hepaticojejunostomy to ensure a tension-free repair. In this situation, the distal bile duct should be oversewn, the injured tissue in the proximal end debrided, and then a biliary-enteric end-to-side anastomosis to the Roux-en-Y jejunal limb. Transhepatic Silastic biliary stents should be placed to control potential anastomotic leaks and for postoperative cholangiography. A perianastomotic drain should also be placed in all cases so that any potential postoperative leak is well-controlled.

**Injury Recognized in the Immediate Postoperative Period.** Biliary injuries that are not appreciated in the intraoperative period may present in the first few days. The presentation may include bile drainage from the wound, bile peritonitis, or progressive jaundice. The initial management of a patient who presents in the delayed fashion following laparoscopic cholecystectomy depends on the nature of the injury and the mode and timing of presentation. Any elective repair should generally occur only after preoperative clinical optimization of the patient, and exact anatomy of the biliary system has been identified. Those presenting with biliary leak should have the bile leak and sepsis controlled prior to having definitive repair. In this situation, the result of reconstruction is almost always better if the definitive repair is made well after the leak and the consequent intra-abdominal inflammation and sepsis are controlled with percutaneous biliary drainage. Biliary spillage and marked inflammation can obscure fields and can make identification of ducts difficult making urgent early laparotomy prior to biliary decompression problematic. Finally, the patient should be clinically stabilized prior to elective repair to correct fluid and electrolyte balances, anemia, and malnutrition. The repair is ideally performed 6–8 weeks after adequate control of the leak has been attained.

In patients who present with biliary stricture weeks to months after cholecystectomy, identification of the biliary system is also essential. Patients with a stricture and symptoms of cholangitis should be treated with broad-spectrum antibiotics until sepsis is controlled, followed by biliary decompression with transhepatic percutaneous catheter placement.

**Definitive Management of Bile Duct Stricture.** The goal of operative management of a bile duct stricture is the establishment of bile flow into the proximal gastrointestinal tract in a manner that prevents sludge, stone formation, cholangitis, restructure, and cirrhosis. The type of repair should be determined by several factors: previous history of attempted repair, location of stricture or injury, surgeon experience, and surgeon preference. Intraoperatively, biliary anatomy must be carefully defined followed by exposure of healthy proximal bile ducts. Care must be taken to avoid excessive dissection and devascularization of tissue. A biliary-enteric anastomosis is performed using a mucosa-to-mucosa technique in a tension-free manner.

The preferred technique, with few exceptions, is a hepaticocholedochojejunostomy to a Roux-en-Y limb of jejunum. End-to-end anastomosis after excision of the stricture or area of injury is not prudent because of the loss of bile duct length and associated fibrosis. Significant loss of bile duct length is also a strict contraindication to performing choledochoduodenostomy, which is unlikely to be performed in a tension-free fashion and is also associated with duodenal fistula if leak occurs.

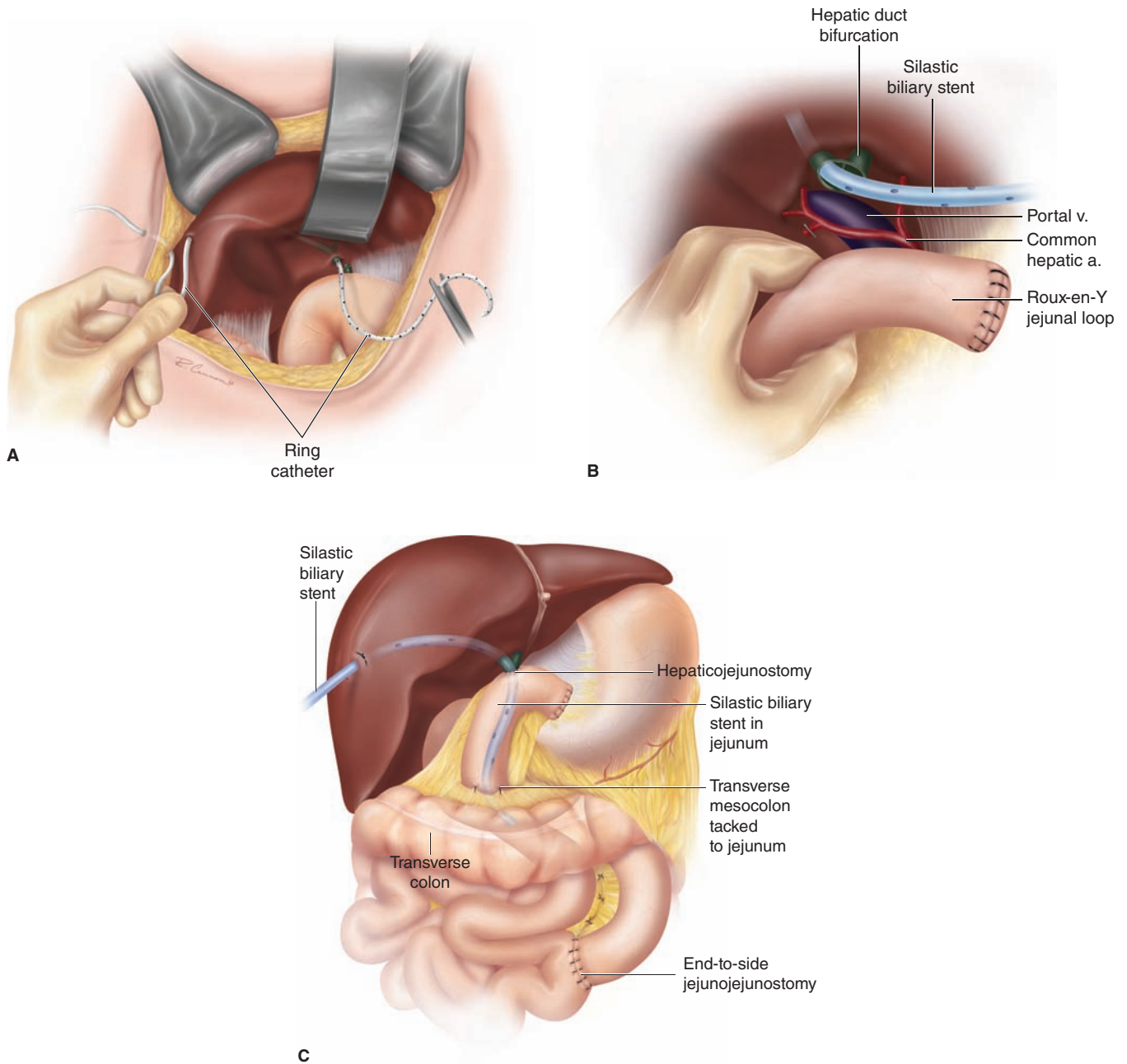
The exact details of the reconstruction depend on the particular anatomic features of the stricture. For strictures where there is more than 2 cm of healthy common hepatic duct present (Bismuth I), a simple end-to-side biliary-enteric

anastomosis will suffice. For strictures in where there is less than 2 cm of healthy common hepatic duct (Bismuth II) or the stricture involves the bifurcation of the hepatic duct but the left and right still communicate (Bismuth III), it may be necessary to lower the hilar plate and extend the dichotomy along a short length of the left hepatic duct to allow a common biliary-enteric anastomosis. Strictures that completely separate the right and left biliary system (Bismuth IV and V) require separate right and left biliary-enteric anastomosis. When duct length cannot be found outside of the hepatic parenchyma, an intraoperative ultrasound is essential to locate the segments II and III ducts. Often, a wedge of liver may need to be resected until an adequate duct can be found to do a biliary-enteric anastomosis.

The use of percutaneous biliary stents with elective reconstruction of the biliary tree remains a topic of debate for hepatobiliary surgeons. Preoperatively placed stents act as intraoperative aids for defining anatomy, especially if the stricture is located proximally. Stents left in place after reconstruction also allow postoperative cholangiography and control early anastomotic leaks in the immediate postoperative period. Many surgeons also advocate extended postoperative transanastomotic stenting, with the purpose of minimizing fibrosis and risk of late anastomotic stricture. In this setting, follow-up cholangiography will reveal early evidence of anastomotic stricture and provide access for balloon dilation if necessary.

Biliary reconstruction with the technique of hepaticojejunostomy with a Roux-en-Y limb with transhepatic biliary stents is depicted in Fig. 50-16. Dissection of the porta hepatis is performed to clear any adhesions between the duodenum or colonic hepatic flexure to the gallbladder fossa, subhepatic space, or Glisson's capsule. Preoperatively placed percutaneous stents are essential in assisting in dissection and bile duct identification in patients with a high bile duct transection. In patients with an intact but strictured bile duct, the duct is divided at the most distal portion of the stricture, and a segment of the strictured duct should be resected and sent to pathology for frozen section. The distal end of the stricture is then oversewn. The proximal extent of the duct should be debrided for a length not to exceed 5 mm to obtain healthy bile duct circumferentially for use in the anastomosis. Careful limited dissection is important to avoid vascular compromise to the bile duct. Preoperatively placed percutaneous transhepatic catheters, which now protrude from the proximal end, are usually exchanged for soft Silastic stents. Silastic stents range from 12 to 22F in size, with multiple side holes that are generally interspersed along 40% of the length of the catheter. A radiologic guidewire is placed through the percutaneous transhepatic catheter; using the Seldinger technique, a series of progressively larger coude catheters are passed over the guidewire in order to dilate the system for Silastic stent placement. The Silastic stent is arranged with the side holes extending beyond the anastomosis distally and within the liver parenchyma proximally. The end of the Silastic stent without holes is brought through the hepatic parenchyma

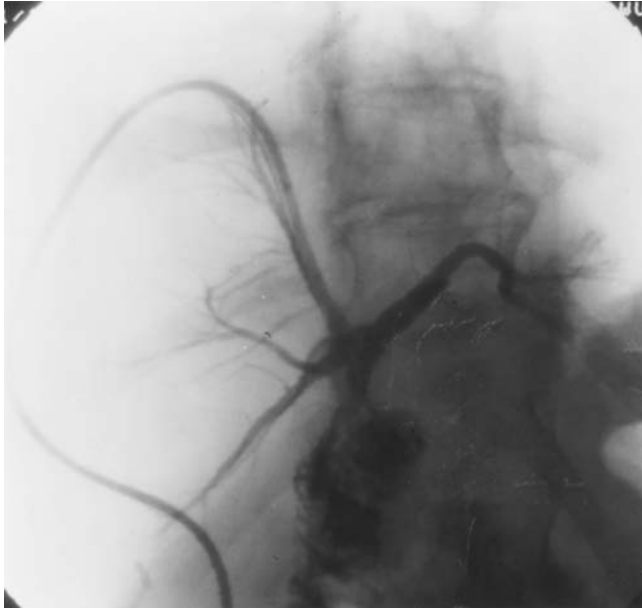




**FIGURE 50-16** Roux-en-Y hepaticojejunostomy reconstruction of biliary tree. **A.** Repair of common hepatic duct stricture with transhepatic ring catheter exiting at the bifurcation. The stricture has been resected, and the distal biliary tree is oversewn. The hepaticojejunal anastomosis can then be performed over the ring catheter, or the ring catheter can be exchanged for a Silastic transhepatic stent. **B.** The Silastic transhepatic stent is shown exiting the biliary tree, with the Roux-en-Y jejunal limb prepared for the hepaticojejunostomy. **C.** Completed repair showing the Silastic biliary stent traversing the liver and the hepaticojejunostomy. The Roux-en-Y jejunal limb has been brought to the hepatic hilum in retrocolic position. (Reproduced, with permission, from Cameron JL, ed. *Atlas of Surgery*, Vol. I. Hamilton, Ontario, Canada: BC Decker; 1990:43, 53, 57.)

and out through the upper anterior abdominal wall. A Roux-en-Y jejunal limb is then created by mobilizing a suitable segment of intestine of approximately 60 cm in length. The anastomosis is then constructed with a standard end-to-side Roux-en-Y hepatico- or choledochojejunostomy, typically using a single layer of 4-0 or 5-0 absorbable sutures.

In the postoperative period, Silastic stents are left to external gravity drainage. A cholangiogram is then performed on postoperative day 4 or 5 (Fig. 50-17). If the biliary tree is adequately decompressed and no leakage is seen, the stents can be internalized and the perianastomotic drain is removed.



**FIGURE 50-17** Postoperative cholangiography after hepaticojejunostomy via percutaneous Silastic biliary stents; the image shows no evidence of anastomotic leak.

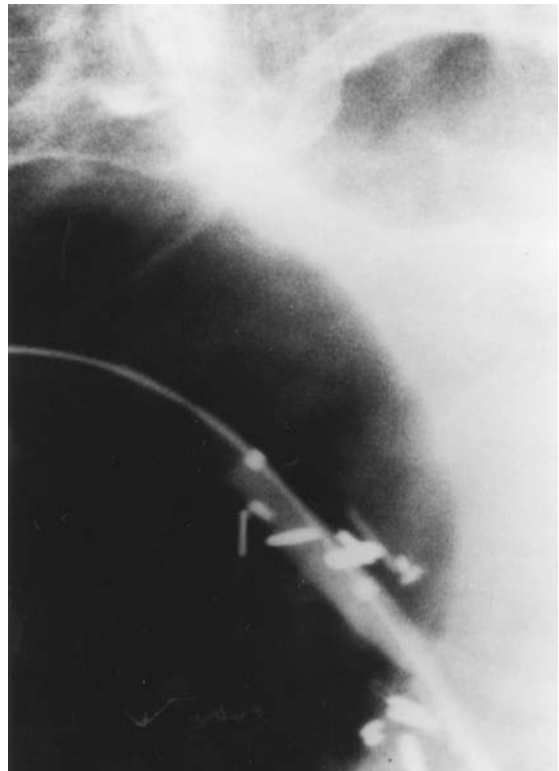
The length of postoperative transanastomotic stenting is dependent on the individual patient, the clinical setting, and surgeon preference. Long-term stenting involves fluoroscopic exchange of stents at regular 2- to 3-month intervals. Timing of stent removal can be aided by biliary manometric flow studies that give objective data about the adequacy of the anastomosis, or by passing a clinical trial with the stent placed above the anastomosis.<sup>68</sup>

An alternative described approach of doing a hepaticojejunostomy involves an anterior longitudinal opening created in the bile duct and a long side-to-side anastomosis performed. Often, this is done to the extrahepatic portion of the left hepatic duct after it is lowered by dividing the hepatic plate (Hepp-Couinaud approach). This approach is particularly suitable for injuries at or just below the bifurcation. Right ducts do not lend themselves to this approach as well, because they have a short extrahepatic length. Sometimes the end of the right duct is used. However, dissection of the left duct provides a guide to the coronal plane in which the intrahepatic right hepatic ducts will be found and may further be exposed by removing liver tissue. During these procedures, exposure can be improved by dividing the bridge of tissue between segments 3 and 4 and opening the gallbladder fossa. Finally, if still more exposure is needed, resecting part of segments 4b and 5 will open the upper porta hepatis. The technique can avoid the need for postoperative stenting.

**Nonoperative Therapy.** Nonoperative interventional radiology and endoscopic techniques have also been developed for the management of select patients with bile duct strictures and injuries. The most common nonoperative technique in these patients is interventional radiologic

percutaneous stenting and balloon dilation, which may be possible in patients with intact biliary-enteric continuity. With the administration of conscious sedation, the proximal biliary tree is accessed so that the stricture can be traversed using a guidewire under fluoroscopic guidance (Fig. 50-18). Angioplasty-type balloon catheters are used to perform dilation of the stricture to a goal diameter based on the stricture location and the normal bile duct diameter. Following dilation, a transhepatic biliary stent is left in place across the stricture. The stent allows for future cholangiography, repeat dilation, and maintenance of the lumen while the bile duct heals. Complications of balloon dilation occur in up to 20% of patients and include cholangitis, hemobilia, and bile leaks. Percutaneous management will usually require numerous dilations.

Results for the treatment of bile duct strictures using percutaneous balloon dilation are limited. In a retrospective comparison, percutaneous balloon dilation was compared to surgical repair in 43 patients with postoperative bile duct strictures treated between 1979 and 1987.<sup>69</sup> Twenty-five patients underwent surgical repair with postoperative stenting and 20 patients had percutaneous balloon dilation with transhepatic stenting (mean: four dilations). Three patients underwent both surgical management and balloon dilation. Successful outcome was achieved in 89 and 52% of surgical



**FIGURE 50-18** Percutaneous balloon dilation of postoperative bile duct stricture using an angioplasty-type balloon catheter. Cholangiogram showing mid-bile duct stricture.

and balloon dilation patients, respectively. These results would appear comparable to other series in the prelaparoscopic cholecystectomy era.<sup>70-73</sup> However, the follow-up in most studies was less than 3 years, which is insufficient to make a definitive comment regarding long-term efficacy.

A series of 51 patients undergoing percutaneous balloon dilation therapy for bile duct strictures following laparoscopic cholecystectomy was reported by Misra and associates.<sup>74</sup> At a median 76-month follow-up, overall success with balloon dilation, defined as stent-free without the need for further intervention, was 58%. With additional stenting and balloon dilation for two patients and surgical reconstruction for the remaining patients, all but one patient (98%) had a successful long-term outcome. These results suggest that in highly selected patients, percutaneous balloon dilation can provide long-term successful results.

Endoscopic balloon dilation has a more limited application, because it is technically possible only in patients with primary bile duct stricture repair or with choledochoduodenal anastomosis. ERC is performed, followed by endoscopic sphincterotomy. Sequential balloon dilation is performed after the stricture is traversed by a guide wire, often with one or more endoprotheses left in place after dilation. Complications associated with stent placement include cholangitis, pancreatitis, stent occlusion, migration, dislodgment, and ductal perforation, and have a reported incidence between 9 and 70%.<sup>75-77</sup>

Repeat cholangiography, often with repeat dilations, may be performed at regular intervals of every 3–6 months. While most endoscopists advocate regular follow-up and reevaluation of the stricture, the risks of stent occlusion and replacement need to be weighed against the risks and costs of the repeat procedures, and there is still some debate about timing of stent change to avoid occlusion. Bergman and associates demonstrated a 70% reobstruction rate with resultant jaundice or cholangitis when stents were not exchanged at 3-month intervals.<sup>77</sup> In contrast, De Masi and colleagues describe and advocate leaving the stents in place until patients were symptomatic.<sup>78</sup>

In addition, the rate of stent occlusion appears to vary with the type of stent used. While metallic stents provide a longer period of patency than plastic stents for patients with malignant obstruction, the indications for their use in patients with benign strictures are limited. Metallic stents cannot be routinely exchanged or removed, and several studies have demonstrated high reocclusion rates at long-term follow-up.<sup>79-81</sup> Newer covered metallic stents may provide a suitable alternative as they can be changed or removed after completion of treatment.<sup>82</sup>

While there have been no determinative studies for the length of time that stents should remain in place, most studies having excellent results have used larger-bore stents ( $\geq 10F$ ) left in place for 2–6 months.<sup>76,77,83</sup> Long-term studies reporting the endoscopic treatment of benign bile duct strictures are few. One of the few studies that directly compare endoscopic therapy to surgical reconstruction was done by Davids and colleagues from the Netherlands.<sup>75</sup> In 66 patients, endoscopic therapy consisted of dilation and placement of

an endoprosthesis, which was exchanged every 3 months. Surgical repair in 35 patients consisted of Roux-en-Y hepaticojejunostomy. Surgery was associated with excellent or good results in 29 patients (82%), with 6 patients (17%) developing a recurrent stricture at mean 40 months from initial surgery. In contrast, endoscopic stenting resulted in 81% with excellent or good outcome and 18% developing resticture at a mean of 3 months after stent removal. Recurrent strictures after stent removal in several other series have been reported to occur at a rate varying from 0 to 20% at median follow-up of 29–108 months.<sup>76,77,83</sup>

## OPERATIVE RESULTS

Biliary injury and stricture repair are associated with significant morbidity and mortality. With improved medical technology and experience, the incidence of operative mortality has decreased markedly. A recent series of 200 consecutive patients repaired at The Johns Hopkins Hospital reported a perioperative mortality of only 1.7%.<sup>62</sup> Advanced age, comorbid disease, and a history of major biliary tract infection are factors associated with operative mortality. Underlying liver disease is the most important correlated factor for operative mortality and morbidity, with advanced biliary cirrhosis and portal hypertension having mortality rates approaching 30%. Fortunately, in the modern era such advanced disease is uncommon.

A recent analysis of Medicare claims, patients' examined mortality associated with major bile duct injuries over an 8-year period in 791 elderly patients demonstrated a perioperative mortality of 2.7% associated with repair.<sup>84</sup> In addition, the study demonstrated an adjusted hazard ratio for death during the follow-up period was significantly higher for patients with a bile duct injury than in patients without a bile duct injury. The hazard increased with advancing age and comorbidities and decreased with experience of the repairing surgeon. The adjusted hazard for death during follow-up was 11% greater if the repairing surgeon was the same as the injuring surgeon. This study gives supportive evidence for improved survival in patients with major bile duct injuries treated by experienced hepatobiliary surgeons at tertiary referral centers.

In most series, postoperative morbidity rates are in the range of 20–40%. Morbidity nonspecific to biliary surgery includes hemorrhage, infection, and risks associated with general anesthesia. Complications specific to biliary repairs include anastomotic leak, cholangitis, and hepatic insufficiency associated with preexisting liver disease. Anastomotic leaks can typically be managed via nonoperative means, especially when transanastomotic stenting has been utilized. Percutaneous transhepatic stenting may also have specific morbidity, including bile leaks from hepatotomy sites, hemobilia, and cholangitis from stent occlusion.

The series reporting the outcomes in 200 patients undergoing surgical reconstruction demonstrated a 43% overall postoperative complication rate.<sup>62</sup> The most common complications were wound infection (8%), cholangitis (6%), minor stent-related complications (6%), and intra-abdominal abscess/biloma



(3%). Postoperative cholangiography revealed an anastomotic leak in 4.6% of patients and extravasation at the liver dome–stent exit site in 10.3%. These complications were all managed conservatively with either new biliary stent placement or biliary stent exchanges required in 2.3%. Postoperative percutaneous abscess/biloma drainage was required in nine patients (5.1%). No patients required reoperation in the postoperative period. Despite the relatively high morbidity rate, median length of stay was similar to that in other reports ( $8 \pm 4.6$  days).

There are mixed results regarding perioperative complications when vascular injury has occurred in association with a bile duct injury.<sup>65,85,86</sup> A report from Schmidt and associates<sup>87</sup> reported that a repair in the presence of uncontrolled infection, a concurrent hepatic artery injury, and injury level (at or above the bifurcation) were independent predictors of the development of major biliary complications.

The ultimate goal of the repair of a bile duct stricture is a successful repair with no further symptoms, including jaundice, cholangitis, and preserved liver function. Excellent long-term results following operative repair of postoperative bile duct injuries after open cholecystectomy have been reported with approximately 80–90% having a successful outcome (Table 50-4).<sup>69,75,88–94</sup> Early reports and observations from the laparoscopic era were less favorable than those previously reported with open cholecystectomy repairs. Stewart and Way<sup>66</sup> reviewed 85 patients who had undergone 112 biliary repairs and defined four factors that influenced success or failure of operative repairs after laparoscopic cholecystectomy bile duct injury: (1) performance of preoperative cholangiography, (2) choice of surgical repair, (3) details of surgical repair, and (4) experience of the repairing surgeon. Procedures without preoperative cholangiography were unsuccessful 96% of the time, and those with incomplete cholangiography data had a success rate of only 31%. With complete cholangiography data, the success rate was 84%. All patients with complete transection of the bile duct who underwent primary end-to-end repair over a T-tube had a

failed result. In contrast, 63% of Roux-en-Y hepaticojejunostomy repairs were successful. Initial repair by the original laparoscopic surgeon was successful in only 17% of cases. Repeat attempts at repair by the same surgeon were never successful. Finally, those patients whose first repair was by a tertiary care biliary surgeon achieved a 94% success rate.

A series providing long-term results after repair of bile duct injuries and strictures in the 1990s was reported by Lillemoe and associates.<sup>94</sup> A total of 156 consecutive patients underwent surgical reconstruction with a mean follow-up period of 57.5 months (range 11–119 months; median 54.7 months). The original operation consisted of laparoscopic cholecystectomy in 118 patients (76%), open cholecystectomy in 27 patients (17%), open cholecystectomy with bile duct exploration in 4 patients (3%), or other abdominal surgery or trauma in 7 patients (4%). Sixty patients (41%) had a previous attempt at repair prior to referral with eight patients (5.5%) having more than one attempt at repair prior to referral. Of the 156 operatively repaired patients, 142 patients had completed treatment at the time of final evaluation with an overall success rate of 91%. Even though they were more likely to have had repair prior to referral and higher and more complex injuries, patients with repair of a stricture or injury associated with laparoscopic cholecystectomy had a better success rate than repair after other operations (94 vs 80%;  $p < .05$ ). There were 13 failures following surgical reconstruction. Ten had successful results following either surgical revision (one patient) or percutaneous balloon dilation (nine patients), resulting in an overall success rate of 98% including secondary intervention. Only three patients continued to require long-term biliary stents to prevent biliary obstruction symptoms and/or cholangitis. Comparable results have been reported from other high-volume hepatobiliary centers with similar volume of patients in the series.<sup>96–99</sup> Outcomes after surgical repair for laparoscopic cholecystectomy injury from other series are outlined in Table 50-5.<sup>94,97–100</sup>

#### EFFECT OF SURGICAL REPAIR IN QUALITY OF LIFE.

Despite the overall high level of success in the surgical management of laparoscopic cholecystectomy bile duct injuries,

**TABLE 50-4: RESULTS OF SURGICAL REPAIR OF POSTOPERATIVE BILE DUCT STRICTURES**

Reference	Year	No. of Patients	Success Rate (%)	Follow-Up (mo)
Walsh et al <sup>95</sup>	2007	144	89	67
Lillemoe et al <sup>94</sup>	2000	156	91	58
Tocchi et al <sup>88</sup>	1996	84	83	108
McDonald et al <sup>89</sup>	1995	72	87	<60
Chapman et al <sup>90</sup>	1995	104	76	86
Davids et al <sup>75</sup>	1993	35	83	50
Pitt et al <sup>69</sup>	1989	25	88	57
Innes et al <sup>91</sup>	1988	22	95	72
Genest et al <sup>92</sup>	1986	105	82	60
Pellegrini et al <sup>93</sup>	1984	60	78	102

**TABLE 50-5: SURGICAL REPAIR OF LAPAROSCOPIC CHOLECYSTECTOMY BILE DUCT INJURIES**

Reference	No. of Patients	Bismuth Level 3–5 (%)	Success Rate (%)
Lillemoe et al <sup>94</sup>	118	63	94
Walsh et al <sup>97</sup>	34	80	91
Bauer et al <sup>98</sup>	32	24	83
Mirza et al <sup>99</sup>	52	53	92
Nealon and Urrutia <sup>100</sup>	23	26	100

there is an impression that patients may have an impaired quality of life even after a successful repair of their bile duct injury. Quality of life after laparoscopic cholecystectomy bile duct injury has been addressed in several recent reports, with differing results.<sup>101–104</sup> Two studies using the Short Form 36 (SF-36) Health Survey quality-of-life instrument in patients with laparoscopic cholecystectomy injury found both the physical and mental quality-of-life aspects to be reduced compared to controls at approximately 5-year follow-up.<sup>101,104</sup> A study with SF-36 found that patients with laparoscopic bile duct injury and subsequent biliary reconstruction had quality of life similar to matched controls and national norms in all eight quality-of-life areas.<sup>103</sup> Melton and associates<sup>102</sup> assessed quality of life in 54 patients having undergone successful surgical repair of laparoscopic cholecystectomy bile duct injuries and compared these results to quality-of-life measures in patients after uncomplicated laparoscopic cholecystectomy and in healthy controls using a standard quality-of-life instrument, which was used to assess the physical, psychological, and social domains of health-related quality of life. Patients after surgical repair had overall quality-of-life scores comparable to those of controls. Only in the psychological dimension were patients post–bile duct injury repair found to have significantly worse scores compared to controls. Patients who reported pursuing a lawsuit following their injury (31%) had significantly worse quality-of-life scores in all domains when compared to those who did not entertain legal action ( $p < .01$ ).

## Summary

Postoperative bile duct strictures and major injuries remain a considerable surgical challenge. With proper diagnostic workup, clinical optimization, and definitive treatment, the vast majority of patients can achieve satisfactory outcomes. With success rates of over 90% at long-term follow-up, the gold standard for managing patients with major bile duct injuries and strictures in the current era remains surgical reconstruction. In select patients with biliary-enteric continuity, percutaneous or endoscopic management with balloon dilation may be an appropriate alternative, with success rates of approximately 50% at long-term follow-up.

## INFLAMMATORY CAUSES OF BILIARY STRICTURE

Biliary strictures may occur in association with a wide range of processes causing fibrosis of the bile ducts. While inflammatory causes of bile duct strictures account only for a minority of biliary strictures in the United States, biliary strictures from these causes are important diagnostic and therapeutic challenges. Strictures from chronic pancreatitis, biliary calculous disease, sphincter of Oddi stenosis, and peptic ulcer disease can usually be managed with choledochoduodenostomy or Roux-en-Y hepaticojejunostomy without long-term stenting.

The management of other infrequent causes of benign biliary strictures depends on the etiology, natural history, and severity of disease.

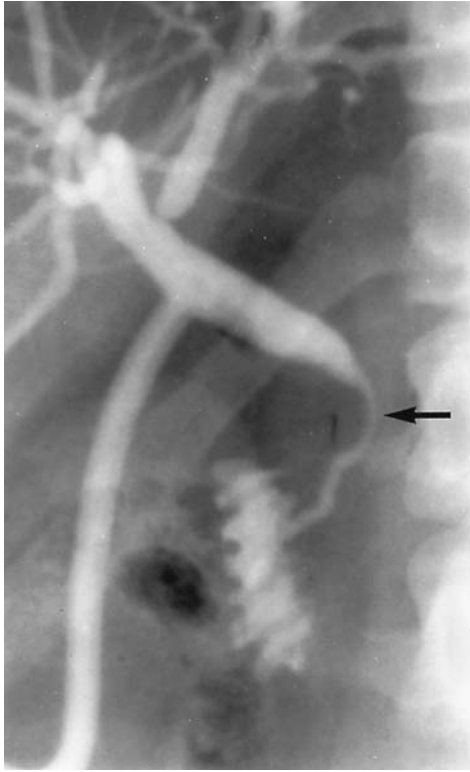
## Chronic Pancreatitis

Chronic pancreatitis is an infrequent cause of bile duct stenosis and stricture, accounting for fewer than 10% of benign biliary strictures. While acute pancreatitis is frequently associated with transient partial obstruction of the distal common bile duct from inflammation and edema, chronic pancreatitis can result in distal bile duct obstruction from inflammation and parenchymal fibrosis of the pancreatic gland. Strictures from chronic pancreatitis typically involve the entire intrapancreatic segment of the common bile duct, resulting in proximal dilation of the biliary tree.

Chronic pancreatitis resulting in bile duct stricture is most commonly caused by alcoholism. Strictures more commonly present in patients who have advanced disease with pancreatic calcification, diabetes, or malabsorption at the time of presentation. The exact incidence of common bile duct strictures is not known because cholangiography is not routinely performed in patients with chronic pancreatitis. With a review of several clinical series, common bile duct strictures associated with chronic pancreatitis occur in approximately 5% of patients with estimated ranges varying from 3 to 29% of patients.<sup>105,106</sup>

Common bile duct strictures due to chronic pancreatitis may have a wide range of clinical presentations. On one end of the spectrum, patients can be asymptomatic with only abnormal liver function tests. Serum alkaline phosphatase, the most sensitive liver function test, is elevated in over 80% of cases. Patients can also present with abdominal pain with or without jaundice. Importantly, abdominal pain from biliary strictures can be difficult to distinguish from pain caused by chronic pancreatitis. Patients with pain from biliary stricture who are not properly diagnosed and treated for their stricture may undergo inappropriate and unsuccessful operative procedures to address pain presumed to be from chronic pancreatitis. Finally, patients who develop jaundice in the setting of chronic pancreatitis may present a diagnostic dilemma, as an underlying periampullary malignancy must also be considered.<sup>107</sup>

Evaluation of bile duct strictures from chronic pancreatitis is most effectively accomplished with cholangiography. MRCP is the preferred route for noninvasive assessment, with ERCP and PTC both effective at delineating anatomy and allowing decompression of the biliary tree in the setting of cholangitis or severe jaundice. ERCP is the preferred diagnostic procedure because it has the advantage of demonstrating pancreatic ductal anatomy, including possible abnormalities, which are especially useful in surgical management. The most common cholangiographic image in chronic pancreatitis–associated bile duct strictures is a long (usually 2–4 cm), smooth, gradual tapering of the distal common bile duct (Fig. 50-19).



**FIGURE 50-19** Stricture from chronic pancreatitis involving the entire intrapancreatic segment of the common bile duct, resulting in proximal dilation of the biliary tree. (Reprinted, with permission, from Lillemoe KD. Biliary injuries and strictures and sclerosing cholangitis. In: Mul-holland MW, Lillemoe KD, Doherty GM, Maier RV, Upchurch GR, Jr, eds. *Greenfield's Surgery: Scientific Principles and Practice*. 4th ed. Philadelphia, PA: Lippincott Williams & Wilkins; 2006:1013.)

The most common accepted indications for operative management in common bile duct strictures from chronic pancreatitis are cholangitis, jaundice, or significant pain. It remains unclear, however, if biliary decompression in asymptomatic patients with elevated serum alkaline phosphatase is indicated. Many surgeons do advocate biliary bypass in this situation, as early biliary cirrhosis changes may be observed in liver biopsy specimens in patients with long-standing, significant biliary obstruction from chronic pancreatitis.<sup>108,109</sup>

Biliary bypass with choledochoduodenostomy or Roux-en-Y choledochojejunostomy represents the optimal form of management for bile duct strictures associated with chronic pancreatitis. Potential advantages of choledochoduodenostomy over Roux-en-Y choledochojejunostomy include maintenance of bile flow into the duodenum that may be more physiologic, increased technical ease, and no loss of small bowel length for formation of a Roux-en-Y limb. Operative management with pancreaticoduodenectomy is appropriate in those patients in whom periampullary malignancy cannot be ruled out by imaging studies or clinical course or in those patients with significant pain attributed to proximal pancreatic duct disease. Both long- and short-term outcomes of

surgically managed distal bile duct strictures from pancreatitis are usually excellent.<sup>100,110</sup>

The management of common bile duct strictures from chronic pancreatitis with either transduodenal sphincterotomy or endoscopic sphincterotomy is not recommended owing to the stricture's long length. While long-term follow-up is lacking, several series have reported success in 60% of patients with follow-up at approximately 2 years after endoscopic balloon dilation of distal bile strictures from chronic pancreatitis.<sup>111,112</sup> It would appear that in most cases when a benign process can be expected to require years of follow-up, that surgery would be the best form of management.

## Gallstone Disease

Long-standing cholelithiasis with recurrent bouts of cholecystitis results in a progressively fibrosed, shrunken gallbladder. Eventually, the gallbladder lumen can lie alongside the common hepatic duct, resulting in inflammation and resultant bile duct stricture. Often referred to as *Mirizzi's syndrome*, this process is typically subdivided into two categories. Type I Mirizzi's syndrome occurs when the process results in either mechanical compression of the duct or an inflammatory stricture of the common hepatic duct. In contrast, type II consists of erosion of the stone in the duct, resulting in cholecystocholedochal fistula.

Mirizzi's syndrome usually presents as jaundice or recurrent cholangitis. In some long-standing cases, these findings exist in the face of chronic gallbladder symptoms. In cases of Mirizzi's syndrome associated with acute cholecystitis, care must be taken at the time of cholecystectomy to avoid bile duct injury during initial dissection. The presence of Mirizzi's syndrome obliterates the triangle of Calot and makes laparoscopic cholecystectomy particularly difficult and will often require conversion to an open procedure. If Mirizzi's syndrome is considered, intraoperative cholangiography should be performed.

If urgent cholecystectomy is not indicated, ERC or PTC can help to delineate the anatomy. Importantly, Mirizzi's syndrome can be difficult to distinguish from strictures that result from gallbladder cancer or cholangiocarcinoma.<sup>113</sup> ERC can also be helpful for obtaining brush biopsies in these patients.

Formal management of strictures from biliary stones varies according to the extent of disease. Patients in whom the bile duct is inflamed and no fistula is present (type I) can often be managed with cholecystectomy. The common hepatic duct almost always returns to normal after the offending stone has been removed by cholecystectomy and the inflammatory process has resolved. Care must be taken, however, during the dissection to avoid creating a defect in the common hepatic duct. Rarely, after the acute episode has resolved, a well-established stricture presents months to years after the acute episode. In such cases, management by Roux-en-Y hepaticojejunostomy is appropriate. If cholecystocholedochal fistula (type II) is present, partial cholecystectomy is recommended and the cuff of remaining gallbladder is used to repair the bile duct over a T-tube.



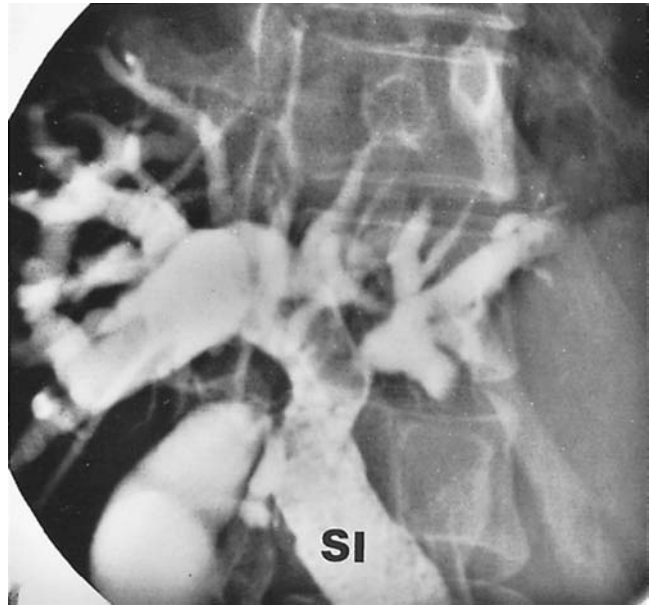
In addition to Mirizzi's syndrome, calculous disease also rarely results in strictures due to choledocholithiasis. The pathogenesis of strictures from choledocholithiasis is thought to be from epithelial erosion of the distal bile duct from calculous disease, resulting in inflammation with subsequent fibrosis and stricture.

Nearly all stones remain entrapped in the intrapancreatic portion of the common bile duct because of the anatomic tapering of the common bile duct. These trapped stones are often difficult to remove via endoscopic means or via a supraduodenal approach during common bile duct exploration. In fact, common bile duct exploration to retrieve stones with forceps, scoops, and catheters can often result in additional trauma to the friable distal duct from excessive intraoperative manipulation. After stone removal, the distal bile duct should be gently sized with a soft rubber catheter to check for the presence of a stricture. Strictures often may not be recognized until the postoperative period when T-tube cholangiography is performed. When strictures are found postoperatively, stricture repair should be performed after inflammation has resolved, typically after 4–6 weeks. Stricture repair of the distal bile duct is indicated for persistent strictures using either Roux-en-Y choledochojejunostomy or choledochoduodenostomy biliary-enteric anastomosis. A choledochoduodenal anastomosis is preferable in patients with a large, dilated (>2 cm in diameter) proximal duct because of its technical ease and excellent results.

## Recurrent Pyogenic Cholangitis and Other Parasitic Disease

Recurrent pyogenic cholangitis, also known as oriental cholangiohepatitis, is endemic in Southeast Asia. Recurrent pyogenic cholangitis occurs infrequently in Western countries but with immigration from Asia is now increasingly encountered. Most cases are due to parasitic infection (*Ascaris lumbricoides* or *Clonorchis sinensis*) of the biliary tree. The infection results in biliary stasis, bacterial overgrowth and inflammation, biliary sludge, and brown (calcium bilirubinate) stone formation. Patients will typically have multiple intra- and extrahepatic stones and strictures, as well as recurrent cholangitis. Although strictures can occur throughout the biliary tree, they are most common in the main hepatic ducts, with disease in the left hepatic duct typically more frequent and more severe than the right. Classically, patients are young, thin, of Asian descent, and present with recurrent bouts of cholangitis. Cholangitis can range in severity from subclinical chronic illness to life-threatening acute suppurative cholangitis.

Diagnostic imaging modalities for oriental cholangiohepatitis include ultrasonography, CT scan, MRCP, ERC, and PTC. While ultrasound is poor at showing biliary strictures reliably, ultrasound is effective at demonstrating biliary obstruction, biliary tract stones, pneumobilia from gas-forming organism infection, and liver abscesses.



**FIGURE 50-20** Cholangiogram in a patient with cholangiohepatitis with diffuse bile duct dilation. The biliary tree is filled with sludge (SI) and stones. (Reprinted, with permission, from Lillemoe KD. Biliary injuries and strictures and sclerosing cholangitis. In: Mulholland MW, Lillemoe KD, Doherty GM, Maier RV, Upchurch GR, Jr, eds. *Greenfield's Surgery: Scientific Principles and Practice*. 4th ed. Philadelphia, PA: Lippincott Williams & Wilkins; 2006:1014.)

Intrahepatic stones on ultrasound have a characteristic posterior acoustic shadowing. CT scan is useful for delineating hepatic anatomy and parenchymal involvement in more advanced disease, which is helpful for guiding potential liver resection. MRCP should be the first step to noninvasively define the biliary anatomy for the presence of strictures and stones. In addition, ERCP and PTC provide therapeutic biliary decompression in the setting of acute cholangitis (Fig. 50-20).

Long-term management of recurrent pyogenic cholangitis is aimed at treating biliary strictures using improved biliary drainage via biliary reconstruction. Following temporary decompression of the biliary tree with ERCP or PTC for acute cholangitis, patients are allowed a period of several weeks for clinical optimization prior to further management. Attempts at percutaneous or endoscopic manipulations of the biliary tree for stone extraction and biliary stricture dilation may be entertained. These interventions, however, have only temporary short-term benefit, and operative management will eventually need to be considered.

Standard operative management consists of Roux-en-Y hepaticojejunostomy, usually with a transhepatic stent. An attempt at complete clearance of stones from the intrahepatic ducts should be made, including the use of choledochoscopy. The stent is useful for follow-up cholangiography and further stone clearance after the initial procedure. Another option for follow-up management is for the blind end of the Roux-en-Y limb to be sutured to the peritoneal surface of the abdominal wall, along with a radiopaque marker. This creates an enteric

portal for future access to the biliary tree and anastomosis. In cases in which disease is confined to one portion of the liver with extensive fibrosis or hepatic abscess, hepatic resection may be considered.

Other causes of biliary strictures from parasites include various forms of echinococcal disease. Biliary strictures from echinococcal infection are primarily related to the compression of bile ducts by a thick-walled cyst. Because of its low rate of morbidity, long-term endoscopic stent therapy has become the initial therapy of choice in patients with biliary stricture from hydatid disease.<sup>114,115</sup> Operative therapy should be considered only in cases of failed previous repairs or failed endoscopic therapy. Surgical treatment of echinococcal liver and biliary disease is associated with a high rate of postoperative bile duct stricture, necessitating long-term clinical surveillance.

## Sphincter of Oddi Stenosis

Also referred to as *papillitis*, stenosis of the sphincter of Oddi is a benign intrinsic obstruction of the common bile duct outlet. Papillitis is typically associated with inflammation, fibrosis, or muscular hypertrophy of the sphincter of Oddi. Patients with sphincter of Oddi stenosis are prone to (1) common bile duct obstruction from fibrosis and stenosis of the papilla, (2) recurrent pancreatitis, and (3) recurrent right upper quadrant abdominal pain in the absence of jaundice or pancreatitis. Initial presentation is most often jaundice or cholangitis. Patients can also sometimes present with an impacted stone at the ampulla.

The etiology of papillitis is unknown. Many cases are thought to be caused by trauma from the passage of multiple small stones or sludge from the common bile duct through the ampulla, resulting in inflammation, fibrosis, and stricture formation. There are other patients, however, that have papillary stenosis without gallstones. The cause in these cases is less clear; potential triggers include primary sphincter motility disorders and congenital anomalies.

Management consists of proper diagnostic imaging and therapeutic sphincterotomy. Cholangiography with either MRCP, PTC, or ERCP is the mainstay of diagnostic imaging. Therapeutic sphincterotomy can be performed either endoscopically or operatively in conjunction with cholecystectomy. The procedure of choice in patients with previous cholecystectomy is endoscopic sphincterotomy.

## PRIMARY SCLEROSING CHOLANGITIS

Primary sclerosing cholangitis (PSC) is an idiopathic condition characterized by a progressive, chronic cholestatic process, resulting in diffuse inflammation, sclerosis, and obliteration of the intra- and extrahepatic biliary duct systems and subsequently leading to biliary cirrhosis. The diagnosis of PSC is confirmed by cholangiography, with findings of multiple areas of stricture and dilation.

PSC has a variable course but can progress to biliary obstruction with secondary cirrhosis, portal hypertension with bleeding varices, or hepatic failure. Finally, PSC is a strong risk factor for the development of cholangiocarcinoma. Surgical management for symptomatic disease in patients with primarily extrahepatic and/or hilar disease and with no evidence of cirrhosis includes resection of the hepatic bifurcation with long-term transhepatic stenting. Finally, liver transplantation is the treatment of choice in patients with primarily intrahepatic strictures or advanced cirrhosis.

## Pathogenesis

The etiology of PSC remains unknown, and a variety of causal theories have been proposed. Inflammatory bowel disease, particularly ulcerative colitis, is present in 30–90% of patients with PSC in several large population-based studies.<sup>116,117</sup> This tight association with inflammatory bowel disease suggests an autoimmune process. However, other mechanisms likely have a role in pathogenesis because only a minority with ulcerative colitis have PSC.<sup>116</sup> Although both ulcerative colitis and PSC may occur in the same individual, the two disorders may occur at different times. PSC, for example, may occur years after colectomy for ulcerative colitis. In addition to commonly occurring in patients with ulcerative colitis, PSC can occur with multifocal fibrosclerosis syndromes, including retroperitoneal, mediastinal, and/or periureteral fibrosis, Riedel's thyroiditis, or pseudotumor of the orbit.

Because there is the association between PSC and inflammatory bowel disease, several investigators have speculated that increased bacterial spread into the portal circulation from inflamed large or small intestine may lead to chronic or recurrent cholangitis. In support of this, an animal model of small intestinal bacterial overgrowth has biliary findings similar to PSC.<sup>118</sup> Although some studies have documented increased portal bacteremia in patients with PSC, other studies have not confirmed this finding.<sup>119,120</sup>

Correlating evidence for an immunological cause of PSC includes its association with hypergammaglobulinemia (30%) and an increase in IgM (50%). Patients with PSC can also have autoantibodies, with titers in the range associated with autoimmune hepatitis. In particular, anti-smooth muscle antibodies and antinuclear antibodies are present in approximately 75%.<sup>121</sup> Other autoantibodies commonly associated with the disease include cytoplasmic and nuclear antigens to neutrophils (pANCA). The autoantibody pANCA is often found in patients with PSC and no ulcerative colitis but is uncommon in patients with ulcerative colitis alone.<sup>122</sup>

Several genetic factors appear to give individuals a predisposition to PSC, including increased prevalence of HLA-B8, -DR3, and -Drw52a. The HLA-B8 and HLA-DR3 haplotypes are associated with other autoimmune diseases, including celiac disease, myasthenia gravis, and diabetes mellitus. A specific mutation of MICA (an MHC class I-related molecule) is also strongly associated with PSC patients (58 compared to 22% in controls).<sup>123</sup>

In contrast to PSC, secondary sclerosing cholangitis has similar clinical characteristics but has identifiable causes. The inciting factors for secondary sclerosing cholangitis include infectious cholangiopathy associated with acquired immunodeficiency syndrome, congenital biliary abnormalities, ischemic cholangiopathy secondary to intrahepatic arterial infusion of 5-fluorouracil, hepatic allograft rejection, graft-versus-host disease in bone marrow transplantation, collagen vascular diseases, histiocytosis X, sarcoidosis, and mast cell cholangiopathy. Patients with diffuse stricturing from 5-fluorouracil are managed by simple discontinuation of infusion, and in some cases percutaneous transhepatic drainage. Surgery should be reserved for patients with persistent evidence of biliary obstruction. The pathogenesis of acquired immunodeficiency syndrome cholangiopathy is believed to be viral and related to cytomegalovirus infection. No experience in the surgical management of this condition has been reported.

## Presentation

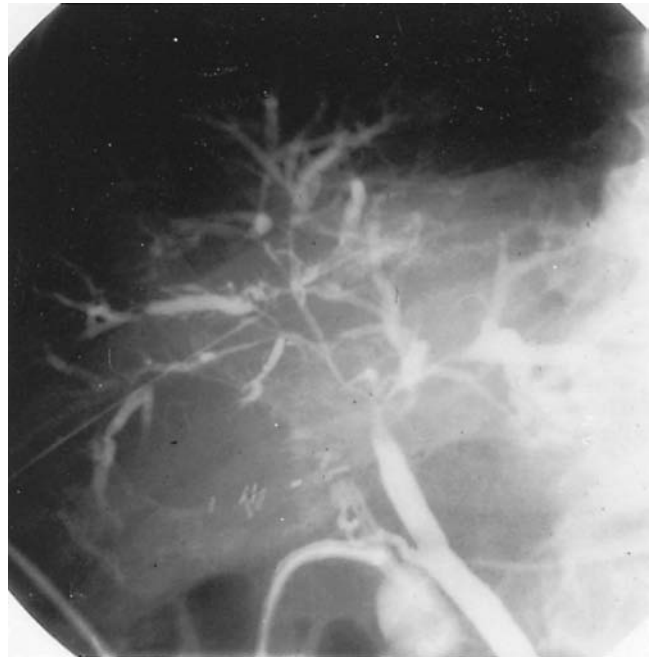Primary sclerosing cholangitis is predominantly a disease of young men. Approximately 70% of patients are male, and the average age at the time of diagnosis is 40 years. The typical presentation includes either an asymptomatic individual with abnormal liver function tests or an individual with intermittent jaundice. Other common symptoms may include right upper quadrant pain, weight loss, fever, pruritus, and fatigue. Despite its name, a minority have acute cholangitis, and blood cultures are rarely positive, approximately 10% are very symptomatic at the time of diagnosis; however, asymptomatic patients can have deceptively advanced disease.

## Diagnosis

Laboratory tests with PSC typically reveal a cholestatic picture. Patients will have an elevated alkaline phosphatase, and during exacerbations may have elevated bilirubin. Early in the disease course, patients will have a normal albumin. The diagnosis is usually made through cholangiography, usually MRCP or ERCP. The typical study reveals multifocal strictures and dilations, referred to as “beading,” of the intra- and extrahepatic ducts (Fig 50-21). The therapeutic modality of choice for cases requiring intervention is via the endoscopic route. PTC may be difficult because cannulation of nondilated and fibrotic ducts associated with PSC can be technically challenging via this approach. At the time of diagnostic cholangiography, brushings for cytology should be obtained to help distinguish between benign and malignant strictures.

## Management

Management of PSC has several important treatment goals, including halting or reversing the disease process, managing



**FIGURE 50-21** Cholangiographic appearance in primary sclerosing cholangitis. Multiple irregular strictures and dilation (beading) of intrahepatic ducts. (Reprinted, with permission, from Lillemoe KD. Biliary injuries and strictures and sclerosing cholangitis. In: Mulholland MW, Lillemoe KD, Doherty GM, Maier RV, Upchurch GR, Jr, eds. *Greenfield's Surgery: Scientific Principles and Practice*. 4th ed. Philadelphia, PA: Lippincott Williams & Wilkins; 2006:1011.)

disease progression, and symptom control. Unfortunately, there are no effective medical treatments that slow the progression of PSC. Patients should be monitored closely with cholangiography, liver biopsy, and cytologic brushings, to detect disease progression and development of malignancy or biliary cirrhosis.

Most medical therapies are aimed at symptomatic relief or antibiotic treatment in the setting of cholangitis. Immunosuppression with glucocorticoids, methotrexate, azathioprine, 6-mercaptopurine, tacrolimus, or cyclosporine have not demonstrated efficacy for disease progression or survival. The use of ursodeoxycholic acid (UDCA) has demonstrated improvement of liver function tests and symptoms. A prospective, randomized, placebo-controlled trial of UDCA, however, did not demonstrate long-term clinical benefit with UDCA.<sup>124</sup> High-dose UDCA in several small pilot studies has demonstrated decreased disease progression and improved survival<sup>125,126</sup>; larger-scale prospective trials with high-dose UDCA are still ongoing.

A dominant extrahepatic biliary stricture (a high-grade, localized area of narrowing) occurs in approximately 20% of patients with PSC. These patients can be managed potentially with endoscopic therapy using dilation with or without stenting. Cytologic brushings at the time of endoscopy should also be obtained to investigate for cholangiocarcinoma. Several retrospective reports have demonstrated benefit in relieving

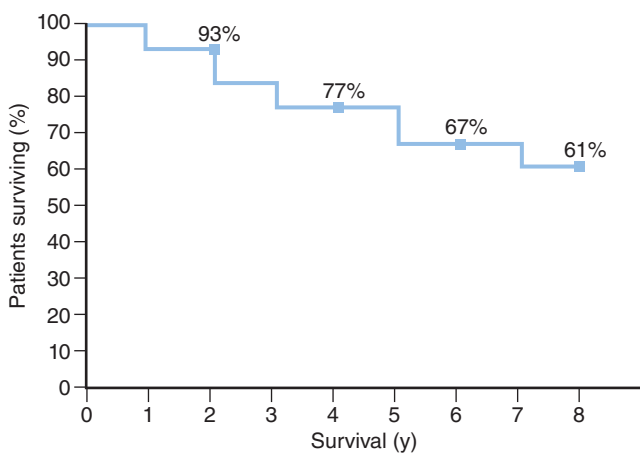


symptoms and improving liver function tests from endoscopic therapy,<sup>127</sup> and possible delay in disease progression.<sup>128</sup> The durability, however, of endoscopic therapy appears to be poor, with most patients requiring repeat dilations at regular intervals. Whether patients should undergo stenting at the time of dilation is not clear, with short-term results of stenting similar to those of dilation treatment alone,<sup>129</sup> and with no long-term outcomes at present comparing the two techniques.

Operative biliary reconstruction with transhepatic stenting for primarily extrahepatic and/or hilar disease in noncirrhotic patients has been demonstrated to have excellent long-term outcomes.<sup>130,131</sup> Ahrendt and associates<sup>131</sup> reported 146 patients with PSC managed with either biliary reconstruction or nonoperative biliary dilation. Survival was significantly longer in noncirrhotic patients with PSC managed surgically compared to those managed nonoperatively, and time before requiring liver transplant was significantly longer in the surgically-managed patients (Fig 50-22).

The natural history of PSC is typically progressive. Regardless of therapy, median survival is typically 12 years following diagnosis.<sup>132,133</sup> Survival is significantly worse in patients symptomatic at the time of diagnosis.<sup>133</sup> The incidence of cholangiocarcinoma of PSC patients at 5 years is 10–15% and at 10 years increases to 30%.

Hepatic transplantation provides excellent results in patients with PSC and end-stage liver disease, with 5-year actuarial survival and graft functioning of 85 and 72%, respectively.<sup>134</sup> Liver transplant should be considered in patients with sclerosing cholangitis before the disease is too advanced. Primary indicators for referral for liver transplant include persistently elevated bilirubin or decreased quality of life from disabling fatigue, severe pruritus, muscle wasting, or bacterial cholangitis. Biliary tract surgery before transplant does not affect either short-term outcomes or survival after transplant.



**FIGURE 50-22** Actuarial survival rates among 31 noncirrhotic patients with primary sclerosing cholangitis who underwent resection of the hepatic bifurcation and long-term transhepatic stenting. (Reprinted, with permission, from Lillemoe KD, Pitt HA, Cameron JL. Primary sclerosing cholangitis. *Surg Clin North Am.* 1990;70:1397.)

Patients with preoperatively recognized cholangiocarcinoma have a poor prognosis. These patients are not appropriate candidates for transplantation. On the other hand, the presence of a small (<1 cm) cholangiocarcinoma discovered incidentally on pathology at transplant does not appear to portend a poor prognosis.

Patients transplanted for PSC are also at increased risk of postoperative biliary stricture compared to those transplanted for other primary disease processes. Recurrent PSC occurs in approximately 10% of patients following transplant, but with typically a less aggressive course.<sup>134</sup>

## Summary

PSC currently has no proven effective medical treatment. Resection of the hepatic duct bifurcation in conjunction with long-term transhepatic stenting in noncirrhotic patients with primarily extrahepatic and/or hilar disease can delay or even prevent the need for hepatic transplantation. This operation does not influence the outcomes associated with hepatic transplantation. Transplant is recommended in patients with primarily intrahepatic strictures or advanced cirrhosis.

## REFERENCES

- Lipsett PA, Pitt HA, Colombani PM, et al. Choledochal cyst disease. A changing pattern of presentation. *Ann Surg.* 1994;220:644–652.
- Locke JE, Lipsett PA. Cystic disorders of the bile ducts. In: Cameron JL, ed. *Cameron Current Surgical Therapy.* 9th ed. Philadelphia, PA: Mosby Elsevier; 2008.
- Alonso-Lej F, Rever W, Pessagno DJ. Congenital choledochal cyst, with a report of 2, and an analysis of 94 cases. *Int Abstr Surg.* 1959;108:1–30.
- Todani T, Watanabe Y, Narusue M, et al. Congenital bile duct cysts: classification, operative procedures, and review of thirty-seven cases including cancer arising from choledochal cyst. *Am J Surg.* 1977; 134:263–269.
- Savader SJ, Benenati JF, Venbrux AC, et al. Choledochal cysts: classification and cholangiographic appearance. *Am J Roentgenol.* 1991;156:327–331.
- Todani T, Watanabe Y, Toki A, et al. Classification of congenital biliary cystic disease: special reference to type Ic and IVA cysts with primary ductal stricture. *J Hepatobiliary Pancreat Surg.* 2003;10:340–344.
- Manning PB, Polley TZ, Oldham KT. Choledochoceles: an unusual form of choledochal cyst. *Pediatr Surg Int.* 1990;5:22.
- Visser BC, Suh I, Way LW, et al. Congenital choledochal cysts in adults. *Arch Surg.* 2004;139:855–860.
- Ziegler KM, Pitt HA, Zyromski NJ, et al. Choledochoceles: are they choledochal cysts? *Ann Surg.* 2010;252(4):683–690.
- Millwala F, Segev DI, Thuluvath PJ. Caroli's disease and outcomes after liver transplantation. *Liver Transpl.* 2008;14:11–17.
- Ponce J, Garrigues V, Sala T, et al. Endoscopic biliary manometry in patients with suspected sphincter of Oddi dysfunction and in patients with cystic dilatation of the bile ducts. *Dig Dis Sci.* 1989;34(3):367–371.
- Spitz L. Experimental production of cystic dilatation of the common bile duct in neonatal lambs. *J Pediatr Surg.* 1977;12:39–42.
- De Vries JS, De Vries S, Aronson DC, et al. Choledochal cysts: age of presentation, symptoms, and late complications related to Todani's classification. *J Pediatr Surg.* 2002;37:1568–1573.
- Babbitt DP, Starshak RJ, Clemett AR. Choledochal cyst: a concept of etiology. *Am J Roentgenol Radium Ther Nucl Med.* 1973;119:57–62.
- Dowdy GS, Jr, Brown WG. Surgical anatomy of the pancreatobiliary ductal system: observations. *Arch Surg.* 1962;84:229–246.
- Metcalf MS, Wesmyss-Holden SA, Maddern GJ. Management dilemmas with choledochal cysts. *Arch Surg.* 2003;138:333–339.

17. Song HK, Kim MH, Myung SJ, et al. Choledochal cyst associated with the anomalous union of pancreaticobiliary duct (AUPBD) has a more grave clinical course than choledochal cyst alone. *Korean J Intern Med.* 1999;14:1–8.
18. Ando H, Kaneko K, Ito F, et al. Embryogenesis of pancreaticobiliary maljunction inferred from development of duodenal atresia. *J Hepatobiliary Pancreat Surg.* 1999;6: 50–54.
19. Kato T, Hebiguchi T, Matsuda K, et al. Action of pancreatic juice on the bile duct: pathogenesis of congenital choledochal cyst. *J Pediatr Surg.* 1981;16:146–151.
20. Iwai N, Tokiwa K, Tsuto T, Yanagihara J, Takahashi T. Biliary manometry in choledochal cyst with abnormal choledochopancreatic ductal junction. *J Pediatr Surg.* 1986;21:873–876.
21. Craig AG, Chen LD, Saccone GT, et al. Sphincter of Oddi dysfunction associated with choledochal cyst. *J Gastroenterol Hepatol.* 2001;16:230–234.
22. Nicholl M, Pitt HA, Wolfe P, et al. Choledochal cysts in western adults: complexities compared to children. *J Gastroint Surg.* 2004; 8:245–252.
23. Weyant MJ, Maluccio MA, Bertagnolli MM, et al. Choledochal cysts in adults: a report of two cases and review of the literature. *Am J Gastroenterol* 1998;93:2580–2583
24. Jesudason SR, Jesudason MR, Mukha RP, et al. Management of adult choledochal cysts—a 15-year experience. *HPB (Oxford).* 2006;8:299–305.
25. Edil BH, Cameron JL, Reddy S, et al. choledochal cyst disease in children and adults: a 30-year single-institution experience. *J Am Coll Surg.* 2008;206:1000–1005.
26. Swisher SG, Cates JA, Hunt KK, et al. Pancreatitis associated with adult choledochal cysts. *Pancreas.* 1994;9:633–637.
27. Park DH, Kim MH, Lee SK, et al. Can MRCP replace the diagnostic role of ERCP for patients with choledochal cyst? *Gastrointest Endosc.* 2005; 62: 360–366.
28. Edil BH, Olino K, Cameron JL. The current management of choledochal cysts. *Adv Surg.* 2009;43:221–232.
29. Todani T, Watanabe Y, Toki A, et al. Carcinoma related to choledochal cysts with internal drainage operations. *Surg Gynecol Obstet.* 1987;164:61–64.
30. Funabiki T, Sugie K, Matsubara T, et al. Bile acids and biliary carcinoma in pancreaticobiliary maljunction. *Keio J Med.* 1991;40:118–122.
31. Tsuchida A, Nagakawa Y, Kasuya K, et al. Immunohistochemical analysis of cyclooxygenase-2 and vascular endothelial growth factor in pancreaticobiliary maljunction. *Oncol Rep.* 2003;10:339–343.
32. Iwase T, Nakazawa S, Yamao K, et al. Ras gene point mutations in gallbladder lesions associated with anomalous connection of pancreaticobiliary ducts. *Hepatogastroenterology.* 1997;44:1457–1462.
33. Tanno S, Obara T, Fujii T, et al. Proliferative potential and K-ras mutation in epithelial hyperplasia of the gall-bladder in patients with anomalous pancreaticobiliary ductal union. *Cancer.* 1998;83:267–275.
34. Nagai M, Kawarada Y, Watanabe M, et al. Analysis of microsatellite instability, TGF-beta type II receptor gene mutations and hMSH2 and hMLH1 allele losses in pancreaticobiliary maljunction-associated biliary tract tumors. *Anticancer Res.* 1999;19:1765–1768.
35. Itoi T, Shinohara Y, Takeda K, et al. Nuclear cyclin D1 overexpression is a critical event associated with cell proliferation and invasive growth in gallbladder carcinogenesis. *J Gastroenterol.* 2000;35:142–149.
36. Matsubara T, Sakurai Y, Zhi LZ, et al. K-ras and p53 gene mutations in noncancerous biliary lesions of patients with pancreaticobiliary maljunction. *J Hepatobiliary Pancreat Surg.* 2002;9:312–321.
37. Rothlin MA, Lopfe M, Schlumpf R, et al. Long-term results of hepaticojejunostomy for benign lesions of the bile ducts. *Am J Surg.* 1998;175:22–26.
38. Delarue A, Chappuis JP, Esposito C, et al. Is the appendix graft suitable for routine biliary surgery in children? *J Pediatr Surg.* 2000;35:1312–1316.
39. Thanh LN, Hien PD, Dung LA, et al. Laparoscopic repair for choledochal cyst: lessons learned from 190 cases. *J Pediatr Surg.* 2010; 45: 540–544.
40. Palanivelu C, Rangarajan M, Parthasaranthi R, et al. Laparoscopic management of choledochal cysts: technique and outcomes—a retrospective study of 35 patients from a tertiary center. *J Am Coll Surg.* 2008;207:839–846.
41. Martin RF, Biber BP, Bosco JJ, et al. Symptomatic choledochoceles in adults endoscopic retrograde cholangiopancreatography recognition and management. *Arch Surg.* 1992;127:536–539.
42. Tsuchida Y, Takahashi A, Suzuki N, et al. Development of intrahepatic biliary stones after excision of choledochal cysts. *J Pediatr Surg.* 2002; 37:165–167.
43. Pitt HA, Venbrux AC, Coleman J, et al. Intrahepatic stones. The transhepatic team approach. *Ann Surg* 1994;219:527–535.
44. Roslyn JJ, Binns GS, Hughes EF, et al. Open cholecystectomy. A contemporary analysis of 42,474 patients. *Ann Surg.* 1993;218:129–137.
45. Strasberg SM, Hertl M, Soper NJ. An analysis of the problem of biliary injury during laparoscopic cholecystectomy. *J Am Coll Surg.* 1995; 180:101–125.
46. Wherry DC, Marohn MR, Malanoski MP, et al. An external audit of laparoscopic cholecystectomy in the steady state performed in medical treatment facilities of the Department of Defense. *Ann Surg.* 1996;224:145–154.
47. Fletcher DR, Hobbs MS, Tan P, et al. Complications of cholecystectomy: risks of the laparoscopic approach and protective effects of operative cholangiography: a population-based study. *Ann Surg.* 1999;229:449–457.
48. Nuzzo G, Giuliante F, Giovanni I, et al. Bile duct injury during laparoscopic cholecystectomy. Results of an Italian national survey on 56591 cholecystectomies. *Arch Surg.* 2005;140:986–992.
49. Hall JG, Pappas TN. Current management of biliary strictures. *J Gastrointest Surg.* 2004;8:1098.
50. Windsor JA, Pong J. Laparoscopic biliary injury: more than a learning curve problem. *Aust N Z J Surg.* 1998;68:186–189.
51. Way LW, Stewart L, Gantert W, et al. Causes and prevention of laparoscopic bile duct injuries: analysis of 252 cases from a human factors and cognitive psychology perspective. *Ann Surg.* 2003;237:460–469.
52. Stewart L, Way LW. Cues associated with laparoscopic cholecystectomy bile duct injuries: confirmation bias may inhibit early diagnosis. *J Gastrointest Surg.* (In press)
53. Lillemoe KD. To err is human, but should we expect more from a surgeon? *Ann Surg* 2003;237:470–471.
54. Flum DR, Dellinger EP, Cheadle A, et al. Intraoperative cholangiography and risk of common bile duct injury during cholecystectomy. *JAMA.* 2003;289:1639–1644.
55. Strasberg SM, Hertl M, Soper NJ. An analysis of the problem of biliary injury during laparoscopic cholecystectomy. *J Am Coll Surg.* 1995;180:101.
56. Carlson E, Zukoski CF, Campbell J, et al. Morphologic, biophysical, and biochemical consequences of ligation of the common biliary duct in the dog. *Am J Pathol.* 1997;86:301–320.
57. Xu J, Geng ZM, Ma QY. Microstructural and ultrastructural changes in the healing process of bile duct trauma. *Hepatobiliary Pancreat Dis Int.* 2003;2:295–299.
58. Pitt HA, Miyamoto T, Parapatis SK, et al. Factors influencing outcome in patients with postoperative biliary strictures. *Am J Surg.* 1982; 144:14–21.
59. Bismuth H. Postoperative strictures of the biliary tract. In: Blumgart L, ed. *The Biliary Tract: Clinical Surgery International Series.* Edinburgh, Scotland: Churchill Livingstone; 1983:209–218.
60. Lillemoe KD, Martin SA, Cameron JL, et al. Major bile duct injuries during laparoscopic cholecystectomy: follow-up after combined surgical and radiologic management. *Ann Surg.* 1997;225:459–471.
61. Davidoff AM, Pappas TN, Murray EA, et al. Mechanisms of major bile duct injury during laparoscopic cholecystectomy. *Ann Surg.* 1992; 215:196–202.
62. Sicklick JK, Camp MS, Lillemoe KD, et al. Surgical management of bile duct injuries sustained during laparoscopic cholecystectomy: perioperative results in 200 patients. *Ann Surg.* 2005;241:786–792; discussion 793–795.
63. Stewart L, Robinson TN, Lee CM, et al. Right hepatic artery injury associated with laparoscopic bile duct injury: incidence, mechanism, and consequences. *J Gastrointest. Surg* 2004;8:523–30.
64. Wudel LJ, Wright JK, Pinson CW, et al. Bile duct injury following laparoscopic cholecystectomy: a cause for continued concern. *Am Surg.* 2001;67:557–563.
65. Alves A, Farges O, Nicolet J, et al. Incidence and consequence of an hepatic artery injury in patients with postcholecystectomy bile duct strictures. *Ann Surg.* 2003;238:93–96.
66. Stewart L, Way LW. Bile duct injuries during laparoscopic cholecystectomy. Factors that influence the results of treatment. *Arch Surg.* 1995; 130:1123–1128.
67. De Reuver PR, Busch OR, Rauws EA, Lameris JS, van Gulik TM, Gouma DJ. Long-term results of a primary end-to-end anastomosis in preoperative detected bile duct injury. *J Gastrointest Surg.* 2007;11:296–302.

68. Savader SJ, Cameron JL, Lillemoe KD, et al. The biliary manometric perfusion test and clinical trial—long-term predictive value of success after treatment of bile duct strictures: ten-year experience. *J Vasc Intervent Radiol.* 1998;9:976–985.
69. Pitt HA, Kaufman SL, Coleman J, et al. Benign postoperative biliary strictures. Operate or dilate? *Ann Surg.* 1989;210:417–425.
70. Moore AV, Jr, Illescas FF, Mills SR, et al. Percutaneous dilation of benign biliary strictures. *Radiology.* 1987;163:625–628.
71. Mueller PR, vanSonnenberg E, Ferrucci JT, et al. Biliary stricture dilatation: multicenter review of clinical management in 73 patients. *Radiology.* 1986;160:17–22.
72. Vogel SB, Howard RJ, Caridi J, et al. Evaluation of percutaneous transhepatic balloon dilatation of benign biliary strictures in high-risk patients. *Am J Surg.* 1985;149:73–79.
73. Williams HJ Jr, Bender CE, May GR. Benign postoperative biliary strictures: dilation with fluoroscopic guidance. *Radiology.* 1987;163: 629–634.
74. Misra S, Melton GB, Geschwind JF, et al. Percutaneous management of bile duct strictures and injuries associated with laparoscopic cholecystectomy: a decade of experience. *J Am Coll Surg.* 2004;198:218–226.
75. Davids PH, Tanka AK, Rauws EA, et al. Benign biliary strictures. Surgery or endoscopy? *Ann Surg.* 1993;217:237–243.
76. Smith MT, Sherman S, Lehman GA. Endoscopic management of benign strictures of the biliary tree. *Endoscopy.* 1995;27:253–266.
77. Bergman JJ, Burgemeister L, Bruno MJ, et al. Long-term follow-up after biliary stent placement for postoperative bile duct stenosis. *Gastrointest Endosc.* 2001;54:154–161.
78. De Masi E, Fiori E, Lamazza A, et al. Endoscopy in the treatment of benign biliary strictures. *Ital J Gastroenterol Hepatol.* 1998;30:91–95.
79. Bonnel DH, Liguory CL, Lefebvre JF, et al. Placement of metallic stents for treatment of postoperative biliary strictures: long-term outcome in 25 patients. *Am J Roentgenol.* 1997;169:1517–1522.
80. Hausegger KA, Kugler C, Uggowitz M, et al. Benign biliary obstruction: is treatment with the Wallstent advisable? *Radiology.* 1996;200:437–441.
81. Maccioni F, Rossi M, Salvatori FM, et al. Metallic stents in benign biliary strictures: three-year follow-up. *Cardiovasc Intervent Radiol.* 1992; 15:360–366.
82. Siriwardana HP, Siriwardana AK. Systematic appraisal of the role of metallic endobiliary stents in the treatment of benign bile duct strictures. *Ann Surg.* 2005; 224: 10–20.
83. Costamagna G, Pandolfi M, Mutignani M, et al. Long-term results of endoscopic management of postoperative bile duct strictures with increasing numbers of stents. *Gastrointest Endosc.* 2001;54:162–168.
84. Flum DR, Cheadle A, Prael C, et al. Bile duct injury during cholecystectomy and survival in Medicare beneficiaries. *JAMA.* 2003; 290:2168–2173.
85. Schmidt SC, Settmacher U, Langrehr JM, et al. Management and outcome of patients with combined bile duct and hepatic arterial injuries after laparoscopic cholecystectomy. *Surgery.* 2004;135:613–618.
86. Stewart L, Robinson TN, Lee CM, et al. Right hepatic artery injury associated with laparoscopic bile duct injury: incidence, mechanism, and consequences. *J Gastrointest Surg.* 2004;8:523–530.
87. Schmidt SC, Langrehr JM, Hintze RE, Neuhaus P. Long-term results and risk factors influencing outcome of major bile duct injuries following cholecystectomy. *Br J Surg.* 2005;92:76–82.
88. Tocchi A, Costa G, Lepre L, et al. The long-term outcome of hepaticojejunostomy in the treatment of benign bile duct strictures. *Ann Surg.* 1996;224:162–167.
89. McDonald ML, Farnell MB, Nagorney DM, et al. Benign biliary strictures: repair and outcome with a contemporary approach. *Surgery.* 1995;118:582–590.
90. Chapman WC, Halevy A, Blumgart LH, et al. Postcholecystectomy bile duct strictures. Management and outcome in 130 patients. *Arch Surg.* 1995;130:597–602.
91. Innes JT, Ferrara JJ, Carey LC. Biliary reconstruction without transanastomotic stent. *Am Surg.* 1988;54:27–30.
92. Genest JF, Nanos E, Grundfest-Broniatowski S, et al. Benign biliary strictures: an analytic review (1970 to 1984). *Surgery.* 1986;99:409–413.
93. Pellegrini CA, Thomas MJ, Way LW. Recurrent biliary stricture. Patterns of recurrence and outcome of surgical therapy. *Am J Surg.* 1984;147:175–180.
94. Lillemoe KD, Melton GB, Cameron JL, et al. Postoperative bile duct strictures: management and outcome in the 1990s. *Ann Surg.* 2000;232: 430–441.
95. Walsh RM, Henderson JM, Vogt DP, et al. Long-term outcome of biliary reconstruction for bile duct injuries from laparoscopic cholecystectomies. *Surgery.* 2007;142:450.
96. Murr MM, Gigot JI, Nagorney DM, et al. Long-term results for biliary reconstruction after laparoscopic bile duct injuries. *Arch Surg.* 1999;134:604.
97. Walsh RM, Henderson JM, Vogt DP, et al. Trends in bile duct injuries from laparoscopic cholecystectomy. *J Gastrointest Surg.* 1998;2:458–462.
98. Bauer TW, Morris JB, Lowenstein A, et al. The consequences of a major bile duct injury during laparoscopic cholecystectomy. *J Gastrointest Surg.* 1998;2:61–66.
99. Mirza DF, Narsimhan KL, Ferraz Neto BH, et al. Bile duct injury following laparoscopic cholecystectomy: referral pattern and management. *Br J Surg.* 1997;84:786–790.
100. Nealon WH, Urrutia F. Long-term follow-up after bilioenteric anastomosis for benign bile duct stricture. *Ann Surg.* 1996;223:639–645.
101. Boerma D, Rauws EA, Keulemans YC, et al. Impaired quality of life 5 years after bile duct injury during laparoscopic cholecystectomy: a prospective analysis. *Ann Surg.* 2001;234:750–757.
102. Melton GB, Lillemoe KD, Cameron JL, et al. Major bile duct injuries associated with laparoscopic cholecystectomy: effect of surgical repair on quality of life. *Ann Surg.* 2002;235:888–895.
103. Sarmiento JM, Farnell MB, Nagorney DM, et al. Quality-of-life assessment of surgical reconstruction after laparoscopic cholecystectomy-induced bile duct injuries: what happens at 5 years and beyond? *Arch Surg.* 2004;139:483–488.
104. Moore DE, Feurer ID, Holzman MD, et al. Long-term detrimental effect of bile duct injury on health-related quality of life. *Arch Surg.* 2004;139:476–481.
105. Stahl TJ, Allen MO, Ansel HJ, et al. Partial biliary obstruction caused by chronic pancreatitis. An appraisal of indications for surgical biliary drainage. *Ann Surg.* 1988;207:26–32.
106. Vijungco JD, Prinz RA. Management of biliary and duodenal complications of chronic pancreatitis. *World J Surg.* 2003;27:1258–1270.
107. Nealon WH, Matin S. Analysis of surgical success in preventing recurrent acute exacerbations in chronic pancreatitis. *Ann Surg.* 2001;233:793–800.
108. Warshaw AL, Schapiro RH, Ferrucci JT, Jr, et al. Persistent obstructive jaundice, cholangitis, and biliary cirrhosis due to common bile duct stenosis in chronic pancreatitis. *Gastroenterology.* 1976;70:562–566.
109. Afroudakis A, Kaplowitz N. Liver histopathology in chronic common bile duct stenosis due to chronic alcoholic pancreatitis. *Hepatology.* 1981; 1:65–72.
110. Escudero-Fabre A, Escallon A, Jr, Sack J, et al. Choledochoduodenostomy. Analysis of 71 cases followed for 5 to 15 years. *Ann Surg.* 1991;213: 635–642.
111. Vitale GC, Reed DN, Jr, Nguyen CT, et al. Endoscopic treatment of distal bile duct stricture from chronic pancreatitis. *Surg Endosc.* 2000;14:227–231.
112. Pozsar J, Sahin P, Laszlo F, et al. Medium-term results of endoscopic treatment of common bile duct strictures in chronic calcifying pancreatitis with increasing numbers of stents. *J Clin Gastroenterol.* 2004;38:118–123.
113. Principe A, Ercolani G, Bassi F, et al. Diagnostic dilemmas in biliary strictures mimicking cholangiocarcinoma. *Hepatogastroenterology.* 2003;50:1246–1249.
114. Eickhoff A, Schilling D, Benz CA, et al. Endoscopic stenting for postoperative biliary strictures due to hepatic hydatid disease: effectiveness and long-term outcome. *J Clin Gastroenterol.* 2003;37:74–78.
115. Saritas U, Parlak E, Akoglu M, et al. Effectiveness of endoscopic treatment modalities in complicated hepatic hydatid disease after surgical intervention. *Endoscopy.* 2001;33:858–863.
116. Olsson R, Danielsson A, Jarnerot G, et al. Prevalence of primary sclerosing cholangitis in patients with ulcerative colitis. *Gastroenterology.* 1991;100:1319–1323.
117. Bambha K, Kim WR, Talwalkar J, et al. Incidence, clinical spectrum, and outcomes of primary sclerosing cholangitis in a United States community. *Gastroenterology.* 2003;125:1364–1369.
118. Lichtman SN, Keku J, Schwab JH, et al. Hepatic injury associated with small bowel bacterial overgrowth in rats is prevented by metronidazole and tetracycline. *Gastroenterology.* 1991;100:513–519.
119. Palmer KR, Duerden BI, Holdsworth CD. Bacteriological and endotoxin studies in cases of ulcerative colitis submitted to surgery. *Gut.* 1980;21:851–854.



120. Vinnik IE, Kern F, Jr, Struthers JE, Jr, et al. Experimental chronic portal vein bacteremia. *Proc Soc Exp Biol Med.* 1964;115:311–314.
121. Angulo P, Peter JB, Gershwin ME, et al. Serum autoantibodies in patients with primary sclerosing cholangitis. *J Hepatol.* 2000;32:182–187.
122. Lo SK, Chapman RW, Cheeseman P, et al. Antineutrophil antibody: a test for autoimmune primary sclerosing cholangitis in childhood? *Gut.* 1993;34:199–202.
123. Norris S, Kondeatis E, Collins R, et al. Mapping MHC-encoded susceptibility and resistance in primary sclerosing cholangitis: the role of MICA polymorphism. *Gastroenterology.* 2001;120:1475–1482.
124. Lindor KD. Ursodiol for primary sclerosing cholangitis. Mayo Primary Sclerosing Cholangitis-Ursodeoxycholic Acid Study Group. *N Engl J Med.* 1997;336:691–695.
125. Harnois DM, Angulo P, Jorgensen RA. High-dose ursodeoxycholic acid as a therapy for patients with primary sclerosing cholangitis. *Am J Gastroenterol.* 2001;96:1558–1562.
126. Mitchell SA, Bansal DS, Hunt N, et al. A preliminary trial of high-dose ursodeoxycholic acid in primary sclerosing cholangitis. *Gastroenterology.* 2001;121:900–907.
127. Baluyut AR, Sherman S, Lehman GA, et al. Impact of endoscopic therapy on the survival of patients with primary sclerosing cholangitis. *Gastrointest Endosc.* 2001;53:308–312.
128. Stiehl A, Rudolph G, Kloters-Plachky P, et al. Development of dominant bile duct stenoses in patients with primary sclerosing cholangitis treated with ursodeoxycholic acid: outcome after endoscopic treatment. *J Hepatol.* 2002;36:151–156.
129. Kaya M, Petersen BT, Angulo P, et al. Balloon dilation compared to stenting of dominant strictures in primary sclerosing cholangitis. *Am J Gastroenterol.* 2001;96:1059–1066.
130. Cameron JL, Pitt HA, Zinner MJ, et al. Resection of hepatic duct bifurcation and transhepatic stenting for sclerosing cholangitis. *Ann Surg.* 1998;207:614–622.
131. Ahrendt SA, Pitt HA, Kalloo AN, et al. Primary sclerosing cholangitis: resect, dilate, or transplant? *Ann Surg.* 1998;227:412–423.
132. Farrant JM, Hayllar KM, Wilkinson ML, et al. Natural history and prognostic variables in primary sclerosing cholangitis. *Gastroenterology.* 1991;100:1710–1717.
133. Broome U, Olsson R, Loof L, et al. Natural history and prognostic factors in 305 Swedish patients with primary sclerosing cholangitis. *Gut.* 1996;38:610–615.
134. Goss JA, Shackleton CR, Farmer DG, et al. Orthotopic liver transplantation for primary sclerosing cholangitis. A 12-year single center experience. *Ann Surg.* 1997;225:472–481.

*This page intentionally left blank*

# CANCER OF THE GALLBLADDER AND BILE DUCTS

Edward E. Whang • Mark Duxbury • Flavio G. Rocha

• Michael J. Zinner

## INTRODUCTION

This chapter focuses on biliary tract cancers, including those of the gallbladder and intrahepatic and extrahepatic bile ducts. Because the epidemiology, clinical presentation, and surgical approach associated with gallbladder cancer and bile duct cancer are distinct, these two cancers are discussed separately.

## GALLBLADDER CANCER

### Epidemiology

With an incidence of 6500 cases annually in the United States, gallbladder cancer is the fifth most common gastrointestinal tract malignancy in this country.<sup>1</sup> Incidence increases with age and is two to six times higher in women than in men. Worldwide, the highest incidence rates (up to 7.5 per 100,000 in men and 23 per 100,000 in women) occur among populations in the Western part of South America (eg, Chile and Peru), in North American Indians, in Mexican Americans, and in northern India.<sup>2</sup> The best characterized risk factor for the development of gallbladder cancer is chronic inflammation associated with gallstones (Table 51-1). Although only 0.5–3% of patients with cholelithiasis will develop gallbladder cancer, gallstones are present in 70–90% of patients diagnosed with gallbladder cancer.<sup>2–4</sup> Further, the geographic pattern of gallbladder cancer incidence correlates with that of cholelithiasis.

Other factors implicated to increase the risk of developing gallbladder cancer include porcelain gallbladder (the incidence of gallbladder cancer is reported to range from 12.5 to 60% in patients with this condition),<sup>2–4</sup> adenomatous polyps of the gallbladder (in contrast, cholesterol and inflammatory polyps

and adenomyomas are not believed to be the risk factors), chronic infection with *Salmonella typhi*, carcinogen exposure (eg, increased risk has been reported for miners exposed to radon), and abnormal pancreaticobiliary duct junction (APBDJ). In this latter condition, a long common channel, formed by an abnormally proximal junction between the pancreatic and common bile ducts (CBDs), and elevated sphincter of Oddi pressures create a predisposition to reflux pancreatic exocrine secretions into the bile ducts. APBDJ is most prevalent in Asian countries and appears to increase the risk of development of biliary cancers, especially gallbladder cancer.<sup>5</sup> Gallbladder cancers arising in patients with APBDJ tends to occur at a younger age, to have a lesser degree of female predominance, and to be less often associated with cholelithiasis than those arising in patients without APBDJ.

### Pathogenesis and Pathology

Chronic inflammation of the gallbladder mucosa related to gallstones is hypothesized to be the major factor leading to malignant transformation in most cases of gallbladder cancer. The progression from dysplasia, to carcinoma in situ (CIS), then to invasive cancer has been described for gallbladder cancer. The molecular changes associated with this progression are under investigation: *K-ras* mutations appear to be relatively uncommon, whereas *p53* mutations are prevalent and tend to arise early during this progression.<sup>2</sup>

Gallbladder cancers arising in patients with APBDJ may be associated with a distinct pathogenetic mechanism. These cancers are associated with a high prevalence of *K-ras* mutations and a late onset of *p53* mutations.<sup>2</sup> In addition, there is a high prevalence of premalignant epithelial hyperplasia with a papillary or villous histology in the gallbladder mucosa of patients with APBDJ.



**TABLE 51-1: RISK FACTORS FOR DEVELOPING GALLBLADDER CANCER**

Cholelithiasis
Porcelain gallbladder
Adenomatous polyps of the gallbladder
Chronic <i>Salmonella typhi</i> infection
Carcinogens (eg, radon)
Abnormal pancreaticobiliary duct junction (APBDJ)

Eighty percent of primary gallbladder cancers are adenocarcinomas. Other histological types include small cell cancer, squamous cell carcinoma, lymphoma, and sarcoma. Gallbladder cancers are also classified according to morphology as infiltrative, nodular, papillary, or a combination of these types. Papillary cancers tend to grow within the gallbladder lumen and are less likely to invade the liver or to metastasize to lymph nodes; it is associated with the best prognosis. Infiltrative or nodular cancers have a more diffuse pattern of growth that is difficult to recognize on imaging studies. These lesions are more likely to have invaded the liver and to have metastasized to lymph nodes by the time of diagnosis.

Several staging systems for gallbladder cancer have been described. The Nevin staging system, originally put forth in 1976, is of historical interest; the tumor, node, metastasis (TNM) system is used today (Table 51-2). The seventh edition of the American Joint Committee on Cancer (AJCC) staging system, published in 2010, contains important modifications to the staging of gallbladder cancer contained in the sixth edition.<sup>6</sup> N stage now includes N1 (metastasis to cystic duct, CBD, hepatic artery, and/or portal vein lymph nodes) and N2

**TABLE 51-2: TNM STAGING OF GALLBLADDER CANCER: AMERICAN JOINT COMMITTEE ON CANCER, 7TH EDITION**

Stage 0	Tis	N0	M0
Stage I	T1	N0	M0
Stage II	T2	N0	M0
Stage IIIA	T3	N0	M0
Stage IIIB	T1–3	N1	M0
Stage IVA	T4	N0–1	M0
Stage IVB	Any T	N2	M0
	Any T	Any N	M1

Tis, carcinoma in situ; T1, cancer invades lamina propria and/or muscularis; T1a, cancer invades lamina propria; T1b, cancer invades muscularis; T2, cancer invades perimuscular connective tissue but not beyond serosa or into liver; T3, cancer perforates serosa and/or directly invades the liver and/or one other adjacent organ or structure; T4, cancer invades main portal vein or hepatic artery or invades two or more extrahepatic organs or structures; N0, no regional lymph node metastasis; N1, metastasis to nodes along cystic duct, CBD, hepatic artery, and/or portal vein; N2, metastasis to periaortic, pericaval, superior mesenteric artery, and/or celiac artery lymph nodes; M0, no distant metastasis; M1, distant metastasis.

(metastasis to periaortic, pericaval, superior mesenteric artery, and/or celiac artery lymph nodes) designations. Stage classifications have been revised to better reflect patient outcomes. For example, locally unresectable T4 cancers are now classified as stage IV, whereas T4N0 cancers were classified as stage III in the sixth edition. M0 cancers associated with lymph node metastasis are now classified as stage IIIB (with N1 disease) or stage IVB (with N2 disease), whereas these cancers were classified as stage IIB or III (depending on T stage) in the sixth edition.

## Clinical Presentation and Diagnosis

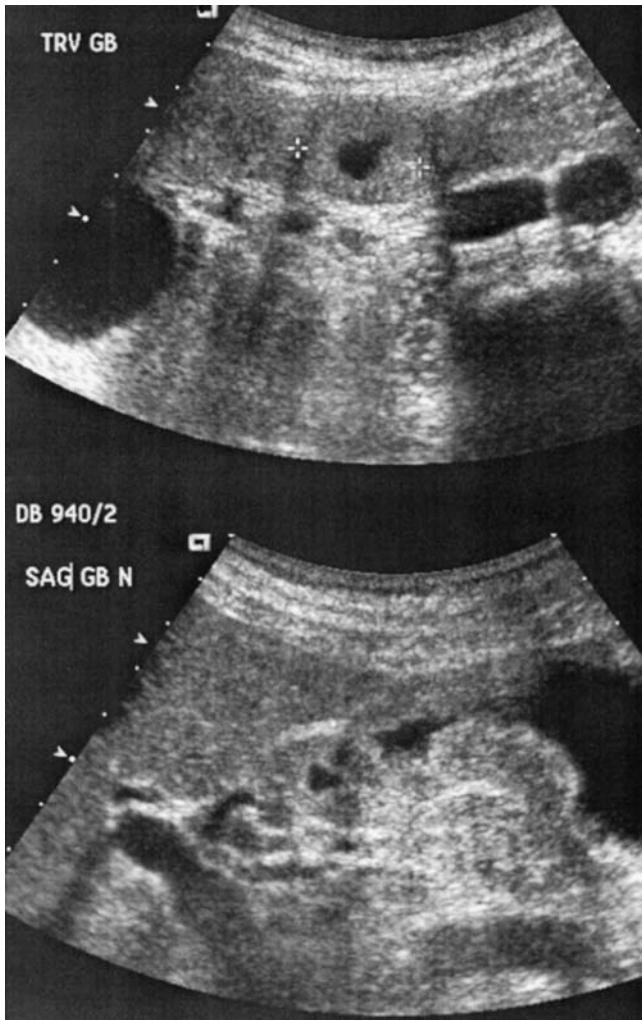In the absence of advanced disease, patients with gallbladder cancer are asymptomatic or have symptoms, such as abdominal pain, anorexia, nausea, and vomiting, that may be indistinguishable from those of cholelithiasis or cholecystitis. With advanced disease, patients can present with weight loss, obstructive jaundice (due to tumor invasion into the biliary tree or to liver metastases), and duodenal obstruction. Signs associated with advanced disease include palpable abdominal masses, hepatomegaly, and ascites.

Laboratory tests may suggest obstructive jaundice if this condition is present; otherwise, they are not helpful in the diagnosis of gallbladder cancer. Tumor markers carcinoembryonic antigen (CEA) or CA 19-9 may be elevated; however, they lack sufficient sensitivity or specificity to be useful in clinical decision making for individual patients.

Patients with suspected gallstone- or gallbladder-related conditions typically undergo transabdominal ultrasonography (US). Findings suggestive of gallbladder cancer on ultrasonography include mural thickening or calcification, a gallbladder mass greater than 1 cm in diameter, and loss of the normal gallbladder wall–liver interface (Fig. 51-1). Relative to transabdominal ultrasonography, endoscopic ultrasonography (EUS) offers greater accuracy in assessing depth of gallbladder wall penetration by masses and regional lymph node enlargement. Selective application of EUS in patients with a gallbladder mass can help in the determination of whether the mass is non-neoplastic (eg, cholesterol pseudopolyp) or neoplastic. In addition, EUS-guided biopsy is an effective technique in cases in which a tissue diagnosis is required.

Computed tomography (CT) scanning should be performed on patients suspected of having gallbladder cancer. Findings of gallbladder cancer include a mass protruding into the gallbladder lumen or completely replacing the gallbladder and focal or diffuse thickening of the gallbladder wall (Fig. 51-2). CT scanning also offers information on the presence or absence of distant metastases, regional lymph node involvement, and local invasion into the liver and porta hepatis.

Magnetic resonance imaging (MRI) and magnetic resonance cholangiopancreatography (MRCP) can offer additional information on local invasion, particularly into the porta hepatis. These tests are used selectively, if CT findings

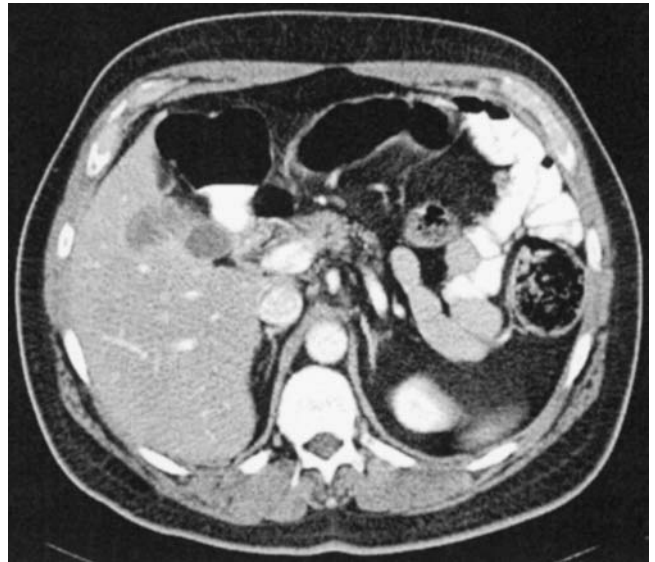


**FIGURE 51-1** Ultrasound of gallbladder cancer. The images demonstrate asymmetric wall thickening of the body and neck of the gallbladder. (Used with permission from Dr. Steven E. Seltzer, Department of Radiology, Brigham & Women's Hospital; [www.brighamrad.harvard.edu](http://www.brighamrad.harvard.edu))

are equivocal. Similarly, endoscopic or percutaneous cholangiography is not routinely indicated; they are used primarily for palliation or preoperative management of obstructive jaundice.

## Surgical Therapy

Surgical resection is the only known curative form of therapy for gallbladder cancer. For patients in whom surgical exploration is contraindicated because of medical comorbidities or evidence of unresectable disease on imaging studies (eg, metastatic disease), a percutaneous or endoscopic needle biopsy can be obtained to confirm the diagnosis. For patients in whom surgery is planned, a preoperative biopsy is contraindicated, as gallbladder cancer has a propensity for dissemination along needle tracts.



**FIGURE 51-2** CT scan of gallbladder cancer. The image shows a  $3.5 \times 4$  cm lesion arising from the gallbladder fundus and extending into segment 5 of the liver.

Recommendations for extent of surgical resection according to disease stage are given below. Specific technical issues are discussed subsequently.

### STAGES 0 AND I

For Tis (carcinoma in situ) and T1a (cancer that invades the lamina propria but does not extend into the muscularis) lesions, the available retrospective data suggest that simple cholecystectomy is sufficient therapy in most cases. These lesions are most frequently detected on pathological examination of gallbladders removed for presumed benign disease. Patients diagnosed with gallbladder cancer in this manner should undergo formal imaging-based staging, and the cholecystectomy specimen should be carefully examined to ensure that all margins are negative for cancer. Patients with imaging studies that reveal no evidence of residual or metastatic gallbladder cancer and are found to have a cystic duct margin that is positive for cancer should undergo re-exploration with common duct excision, regional lymphadenectomy, and hepaticojejunostomy. In contrast, patients with negative margins and negative imaging studies who undergo no additional treatment for their gallbladder cancer have excellent outcomes that are unlikely to be improved by radical surgery.<sup>7</sup>

The management of T1b (cancer that invades the muscularis but does not extend into the perimuscular connective tissues) lesions has been controversial. In published series, the 5-year survival rate for patients with T1b gallbladder cancer having undergone radical resection averages 87.5%, whereas it averages only 61.3% in patients having undergone simple cholecystectomy alone.<sup>8</sup> Further, a recently published decision analysis suggests that radical surgery (described later for stage II cancers) is associated with improved survival compared to

that associated with simple cholecystectomy alone in most patients with T1b gallbladder cancer.<sup>8</sup> Therefore we treat patients with T1b gallbladder cancer in the same way we treat patients with T2 gallbladder cancer.

## STAGE II

Patients found to have a T2 (cancer invasion into the perimuscular connective tissues of the gallbladder) lesion in their cholecystectomy specimen following surgery for presumed benign disease should undergo staging (as described earlier), and in the absence of contraindications, radical resection. Simple cholecystectomy is usually performed using a subserosal dissection plane, and, hence, may leave positive margins in the gallbladder fossa. Indeed, re-exploration reveals residual tumor in 40–76 % of these cases.<sup>9–12</sup> In addition, the probability of regional lymph node metastasis in patients with T2 gallbladder cancer has been reported to range from 28 to 63%.<sup>9–12</sup> These findings provide rationale for performing re-exploration with liver resection and regional lymphadenectomy of the hepatoduodenal ligament. There is convincing, albeit retrospective, evidence that such radical surgery is associated with improved survival for patients with T2 gallbladder cancer.<sup>9–12</sup> Given the propensity of gallbladder cancer to seed wound sites, re-excision of all surgical wounds, including laparoscopic port sites, during re-exploration has traditionally been recommended. However, re-excising port sites can be difficult (the trajectory through which ports had traversed the abdominal wall during the initial operation may be impossible to determine at the time of definitive surgery), and the value of this practice is unproven.

Patients suspected of having a T2 gallbladder cancer preoperatively (prior to cholecystectomy) should undergo staging, and in the absence of contraindications, exploration with en bloc resection of the gallbladder and adjacent liver to a depth of at least 2 cm, in addition to regional lymphadenectomy of the hepatoduodenal ligament. Although a nonanatomic liver resection encompassing the gallbladder fossa can be applied at the time of re-exploration or en bloc with the gallbladder during the initial procedure, anatomical resection of liver segments 4b and 5 may be associated with less intraoperative bleeding.

## STAGE III

A role for aggressive surgical resection for some stage III gallbladder cancers has been receiving increasing recognition. This stage includes T3 lesions (locally advanced cancers that perforate the gallbladder serosa or directly invade the liver and/or one adjacent organ) and T1–3 lesions associated with regional lymph node metastasis.

Surgery for patients with T3 lesions requires careful planning and must be tailored to individual patients. For some patients with liver invasion, hepatic resections encompassing segments 4b and 5 may be sufficient. However, because the gallbladder fossa bridges both right and left hepatic lobes, trisegmentectomy is often required. Adjacent involved structures, such as the

hepatic flexure of the colon, should be resected en bloc. Long-term survival rates ranging from 15 to 63% have been reported from some centers to be associated with these extended procedures for T3 lesions.<sup>9–12</sup>

## STAGE IV

Stage IVA (invasion of the main portal vein, common hepatic artery, multiple extrahepatic organs) and stage IVB (N2 and/or distant metastasis) disease meet criteria for unresectability. Anecdotal reports of super-radical procedures involving resection of the main portal vein and/or common hepatic artery exist, but these procedures are associated with substantial morbidity and mortality rates and are unlikely to confer any survival benefits.

There is no evidence to support the application of debulking cholecystectomy to prevent subsequent episodes of cholecystitis; we do not recommend it.

## Surgical Technique

For patients suspected of having resectable gallbladder cancer, we begin surgical exploration with laparoscopy. In the absence of disseminated disease, we proceed with open laparotomy. Because of the risk for gallbladder perforation and tumor spillage, we recommend against laparoscopic cholecystectomy in patients suspected of having gallbladder cancer. We also recommend early conversion to open laparotomy in patients undergoing laparoscopic cholecystectomy for presumed benign disease in whom the suspicion of gallbladder cancer arises intraoperatively.

We use a right subcostal incision, as it easily can be extended to a chevron incision if necessary. We then conduct a thorough examination for metastases, especially in the liver and on the peritoneal surfaces. For patients in whom the suspicion of gallbladder cancer is low at this point a simple cholecystectomy is done, and the gallbladder is examined using frozen-section analysis. Confirmation of T1b, T2, or T3 disease should prompt radical resection, as described later. If the diagnosis based on frozen-section analysis is ambiguous (ie, the presence of gallbladder cancer cannot be confirmed), radical surgery should be deferred. For patients in whom the suspicion of gallbladder cancer is high because of the presence of a firm mass, we obtain a small biopsy of the lesion. If the diagnosis of gallbladder cancer is confirmed on frozen-section analysis, the gallbladder is resected en bloc with the adjacent liver, as described later. Although determining depth of cancer invasion can be difficult on frozen sections, these grossly apparent cancers are likely to be T2 or more advanced lesions.

If radical resection is indicated, we then perform a Kocher maneuver to mobilize the duodenum and the head of the pancreas. Enlarged retropancreatic, celiac, superior mesenteric, or para-aortic lymph nodes are sampled and subjected to frozen-section analysis. If these lymph nodes are positive for metastases, N2 disease is present, and radical resection is aborted.



In the absence of N2 disease, we then perform regional lymphadenectomy. We skeletonize CBD and common hepatic duct, hepatic artery, and portal vein from the superior border of the duodenum to the liver hilum. During this dissection, lymph node-bearing fibrofatty tissues are swept toward the gallbladder and removed as a specimen. Tumor invasion of the portal vasculature is assessed during this dissection. We do not perform major vascular resection for advanced gallbladder cancer at our institution.

In contrast, we do perform common duct resection if the gallbladder cancer has invaded this structure. Common duct resection may also facilitate resection of bulky nodal disease in the hepatoduodenal ligament. The CBD is clamped and transected at the superior border of the duodenum, and its stump is oversewn with a nonabsorbable monofilament suture. Similarly, the common hepatic duct is transected near its bifurcation. We take care to minimize spillage of bile that may contain cancer cells.

We then perform en bloc resection of the gallbladder and the adjacent liver (or the liver resection alone if the patient has already undergone cholecystectomy). If the CBD has not been transected, the cystic duct is divided near its junction with the CBD. Similarly, the cystic artery is ligated and divided near its origin. For T2 cancers, either a nonanatomic wedge resection of the liver that encompasses the gallbladder fossa to a depth of 2 cm or anatomical resection of liver segments 4b and 5 is acceptable (Fig. 51-3). The capsule of the liver is scored with electrocautery to mark the resection plane. Overlapping chromic liver sutures are then placed around the periphery of the resection plane for hemostasis

and retraction. The liver parenchyma is then transected using one of the standard methods (we usually use a combination of electrocautery and argon-beam coagulation). Care should be taken near the base of the liver resection margins to avoid injuring the right hepatic artery as it traverses inferiorly in the gallbladder fossa.

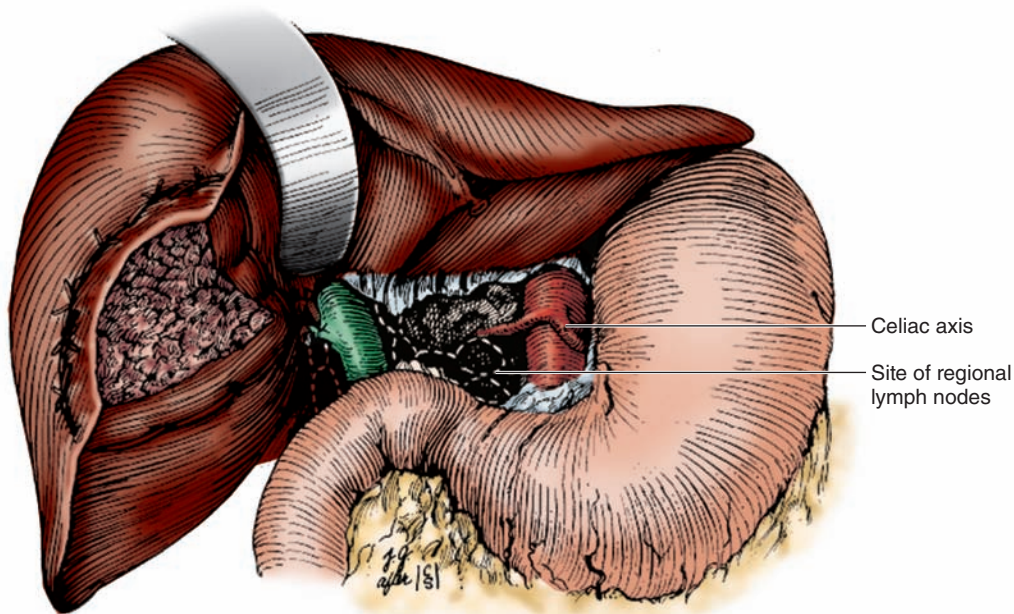
If the common duct has been resected, a 60-cm Roux-en-Y limb of jejunum is used to create a hepaticojejunostomy. The anastomosis is constructed using a single layer of 5-0 absorbable sutures.

## Adjuvant Therapies

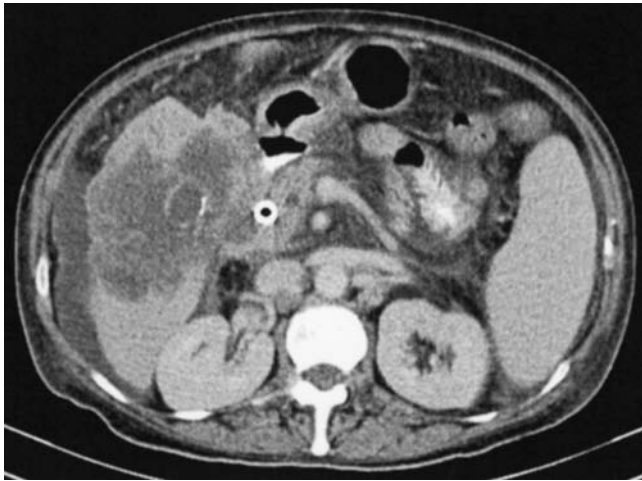
Adjuvant chemoradiotherapy is commonly administered after resection of gallbladder cancers. External beam or intraoperative radiation therapy alone or in combination with 5-fluorouracil (5-FU) is associated with diminished rates of local recurrence. The impact of these regimens on survival is unclear; no data derived from prospective randomized clinical trials on the efficacy of these regimens exist.

## Palliation

The goals of palliative therapy are relief of pain, manifestation of biliary obstruction (eg, pruritis and cholangitis) and bowel obstruction. Given the limited expected survival duration of patients diagnosed with unresectable gallbladder



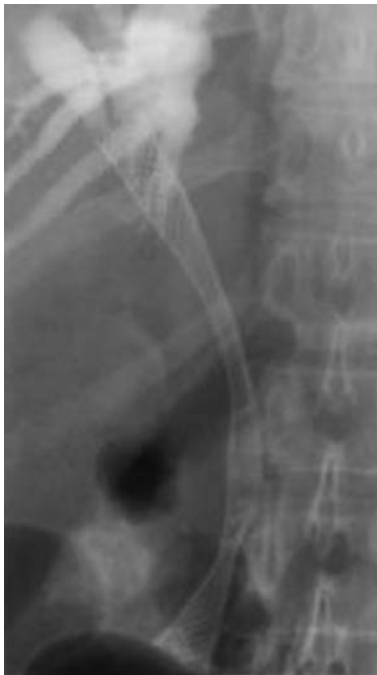**FIGURE 51-3** Radical resection of gallbladder cancer. This illustration depicts the operative field after radical cholecystectomy has been performed. The hatched line denotes the regions included in the lymphadenectomy.



**FIGURE 51-4** CT scan of advanced gallbladder cancer. The image demonstrates an advanced gallbladder cancer with extensive liver invasion. A stent has been placed for palliation of obstructive jaundice.

cancer (weeks to months), endoscopic or percutaneous stenting, rather than surgical bypass, is generally recommended for relief of symptomatic biliary obstruction (Figs. 51-4 and 51-5). Biliary stents are discussed in greater detail later in the section on palliation of bile duct cancers.

Palliative radiation therapy, regional intra-arterial chemotherapy, systemic chemotherapy, and chemoradiotherapy all have been applied in patients with advanced gallbladder



**FIGURE 51-5** Palliation of gallbladder cancer. This radiograph depicts a Wallstent that has been placed for palliation of obstructive jaundice in a patient with advanced gallbladder cancer.

cancer. Results of the **ABC-02 trial** were recently published.<sup>13</sup> Data from this multicenter phase III trial of patients with locally advanced or metastatic biliary tract cancer (of whom ~36% had gallbladder cancer) demonstrated that the combination of gemcitabine plus cisplatin is associated with improved overall and progression-free survival than gemcitabine alone. As such, this gemcitabine-cisplatin combination represents the current standard treatment option for patients with advanced biliary tract cancers, including gallbladder cancer.<sup>14</sup>

## Outcomes

Data derived from the National Cancer Database support the nihilistic view traditionally associated with gallbladder cancer.<sup>15</sup> In these population-based data, 5-year survival rates for patients with T1N0, T2N0, and T3N0 (or node-positive) disease are 39, 15, and 5%, respectively.

However, contemporary surgical series suggest that substantially improved outcomes can be achieved by the application of surgical resection of gallbladder cancers.<sup>16</sup> In these reports, 5-year survival rates following resection of T1 lesions ranges from 85 to 100%. With radical resection of T2, T3, and T4 lesions, reported 5-year postoperative survival rates range from 80 to 90%, 15 to 63%, and 2 to 25%, respectively. Radical resection of node-positive disease has been reported to be associated with 5-year survival in as high as 60% of patients, although some reported series contained no patients who survived 2 or more years among those with lymph node metastasis.<sup>9-12</sup>

Reported morbidity and mortality rates associated with resection of gallbladder cancers range from 5 to 54% and from 0 to 21%, respectively. In general the highest morbidity and mortality rates are associated with series describing more extensive resections.

The best reported outcomes among patients with unresectable biliary tract cancers are those from the **ABC-02 trial**.<sup>13</sup> The median overall survival among patients treated with the combination of gemcitabine and cisplatin was 11.7 months, whereas it was 8.1 months in those treated with gemcitabine alone.<sup>13</sup>

## BILE DUCT CANCER

### Epidemiology

In this discussion, the term *cholangiocarcinoma* is used interchangeably with *bile duct cancer* and is used to denote cancers arising in the intrahepatic or extrahepatic biliary tree, exclusive of the ampulla of Vater and gallbladder.

Approximately 6000 new cases of cholangiocarcinoma are diagnosed annually in the United States.<sup>1</sup> Most patients are diagnosed in the fifth through the seventh decades of life. Unlike gallbladder cancer, for which there is a clear female predominance, the incidence of bile duct cancer is slightly higher in males than in females.

**TABLE 51-3: RISK FACTORS FOR BILE DUCT CANCER**

Primary sclerosing cholangitis
Liver flukes infestation ( <i>Opisthorchis viverrini</i> and <i>Clonorchis sinensis</i> )
Choledochal cysts
Caroli's disease
Hepatoolithiasis
Chemicals (eg, Thorotrast and dioxin)
Hepatitis C
Lynch syndrome II
Bile duct adenoma and multiple biliary papillomatosis

Although most patients diagnosed with cholangiocarcinoma have no identifiable predisposing factors, several conditions clearly increase the risk of developing this cancer (Table 51-3). In Western countries, primary sclerosing cholangitis (PSC) is the most important risk factor; indeed, approximately 30% of cases of cholangiocarcinoma in the West are diagnosed in patients with PSC. Among patients with PSC, the estimated lifetime incidence of cholangiocarcinoma ranges from 10 to 15%, with an annual incidence of 0.6–1.5%.<sup>17</sup> In addition, cholangiocarcinoma tends to be diagnosed at an earlier age (third through fifth decades of life) in patients with PSC than in the general population.

In Asian countries, infestation with the liver flukes *Opisthorchis viverrini* or *Clonorchis sinensis* and hepatolithiasis are important factors for cholangiocarcinoma. Other risk factors include choledochal cysts, Caroli's disease, and exposure to the radiological contrast agent Thorotrast. Increased risk has been reported for workers in the auto, rubber, chemical, and wood-finishing industries and among patients with hepatitis C viral infection. Two genetic conditions (Lynch syndrome II and multiple biliary papillomatosis) have been identified as increasing the risk of developing bile duct cancer.

## Pathogenesis and Pathology

Malignant transformation in the bile duct epithelium, as in other regions of the gastrointestinal tract, is hypothesized to arise in association with a step-wise accumulation of genetic abnormalities. A range of mutations and other abnormalities involving oncogenes (eg, *K-ras*, *c-myc*, *c-neu*, *c-erbB-2*, and *c-met*) and tumor suppressor genes (eg, *p53*) have been reported to be prevalent in bile duct cancers; the biological and clinical significance of these abnormalities remains to be characterized.<sup>17</sup>

Greater than 90% of bile duct cancers are adenocarcinomas. Other cancer types include squamous cell carcinoma, small cell carcinoma, and sarcomas. Adenocarcinomas of the bile duct are classified as sclerosing, nodular, or papillary (analogous to the classification scheme for gallbladder adenocarcinomas).

Sclerosing (scirrous) tumors, which comprise over 80% of cholangiocarcinomas, are associated with an intense desmoplastic reaction, tend to be highly invasive, and are associated with low resectability rates. Nodular tumors have the appearance of constricting annular lesions and are also associated with low resectability rates. Papillary tumors are rare and present as bulky masses that project into the bile duct lumen. Because these lesions tend to cause symptomatic obstructive jaundice relatively early in their progression, they are associated with higher resectability rates than sclerosing or nodular tumors.

Cholangiocarcinomas are also classified into three groups according to their anatomical location: (1) intrahepatic or peripheral (10% of cases), (2) perihilar (65% of cases), and (3) distal (25% of cases). The transition between perihilar and distal locations occurs where the CBD becomes a retroduodenal structure. Bile duct tumors involving the hepatic duct bifurcation are known as *Klatskin tumors*. An additional anatomical classification system for perihilar cholangiocarcinomas, originally proposed by Bismuth,<sup>18</sup> is useful in surgical planning (Table 51-4).

The seventh edition of the AJCC staging system, published in 2010, contains separate staging systems for intrahepatic (Table 51-5), perihilar (Table 51-6), and distal bile duct cancers (Table 51-7).<sup>6</sup> These systems represent a significant departure from the AJCC sixth edition, in which intrahepatic cholangiocarcinomas were staged in the same manner as hepatocellular carcinomas, and all extrahepatic cholangiocarcinomas were grouped together in a single staging system.

## Clinical Presentation and Diagnosis

Intrahepatic cholangiocarcinomas typically present with nonspecific symptoms, such as abdominal pain, anorexia, weight loss, and malaise. Another mode of presentation for these cancers is the incidental detection of an intrahepatic mass on imaging studies. The most common presentation of extrahepatic cholangiocarcinomas is painless jaundice. Other manifestations of biliary obstruction, such as acholic stools, dark urine, and pruritis, are also prevalent. Abdominal pain, fatigue, malaise, and weight loss can occur with advanced disease. Signs of advanced bile duct cancer include right upper quadrant abdominal tenderness, hepatomegaly,

**TABLE 51-4: CLASSIFICATION OF PERIHILAR BILE DUCT CANCERS ACCORDING TO ANATOMIC LOCATION**

Type I: tumors below the confluence of the left and right hepatic ducts

Type II: tumors reaching the confluence

Types IIIa/IIIb: tumors involving common hepatic duct and either the right or the left hepatic duct, respectively

Type IV: tumors that are multicentric or involve the confluence and both the right and left hepatic ducts



**TABLE 51-5: TNM STAGING OF INTRAHEPATIC BILE DUCT CANCER: AMERICAN JOINT COMMITTEE ON CANCER, 7TH EDITION**

Stage 0	Tis	N0	M0
Stage I	T1	N0	M0
Stage II	T2	N0	M0
Stage III	T3	N0	M0
Stage IVA	T4	N0	M0
	Any T	N1	M0
Stage IVB	Any T	Any N	M1

Tis, carcinoma in situ; T1, solitary tumor without vascular invasion; T2a, solitary tumor with vascular invasion; T2b, multiple tumors, with or without vascular invasion; T3, tumor perforating visceral peritoneum or involving local extrahepatic structures by direct invasion; T4, tumor with periductal invasion; N0, no regional lymph node metastasis; N1, regional lymph node metastasis present (for right liver [segments 5–8] regional lymph nodes include hilar, periduodenal, and peripancreatic lymph nodes; for left liver [segments 2–4] regional lymph nodes include hilar and gastrohepatic lymph nodes). Metastasis to celiac and/or periaortic and caval lymph nodes are considered distant metastasis; M0, no distant metastasis; M1, distant metastasis present.

and a palpable gallbladder. Cholangitis is unusual in the absence of prior biliary tract instrumentation.

The differential diagnosis for patients with these presentations includes primary and metastatic hepatobiliary and pancreatic neoplasms, and benign biliary strictures due to conditions such as PSC, choledocholithiasis, Mirizzi's syndrome, and postoperative strictures.

In patients with intrahepatic cholangiocarcinoma, laboratory studies usually reveal an increased alkaline phosphatase level in the setting of normal bilirubin levels. In patients with extrahepatic cholangiocarcinoma, laboratory tests are usually consistent

**TABLE 51-6: TNM STAGING OF PERIHILAR BILE DUCT CANCER: AMERICAN JOINT COMMITTEE ON CANCER, 7TH EDITION**

Stage 0	Tis	N0	M0
Stage I	T1	N0	M0
Stage II	T2a–b	N0	M0
Stage IIIA	T3	N0	M0
Stage IIIB	T1–3	N1	M0
Stage IVA	T4	N0–1	M0
Stage IVB	Any T	N2	M0
	Any T	Any N	M1

Tis, carcinoma in situ; T1, cancer confined to bile duct, with extension up to the muscle layer or fibrous tissue; T2a, cancer invades beyond the wall of bile duct to surrounding adipose tissue; T2b, cancer invades adjacent hepatic parenchyma; T3, cancer invades unilateral branches of the portal vein or hepatic artery; T4, cancer invades main portal vein or its branches bilaterally, or the common hepatic artery, or the second-order biliary radicals bilaterally, or unilateral second-order biliary radicals with contralateral portal vein or hepatic artery invasion; N0, no regional lymph node metastasis; N1, regional lymph node metastasis (including nodes along cystic duct, CBD, hepatic artery, and portal vein); N2, metastasis to periaortic, pericaval, superior mesenteric artery, and/or celiac artery lymph nodes; M0, no distant metastasis; M1, distant metastasis

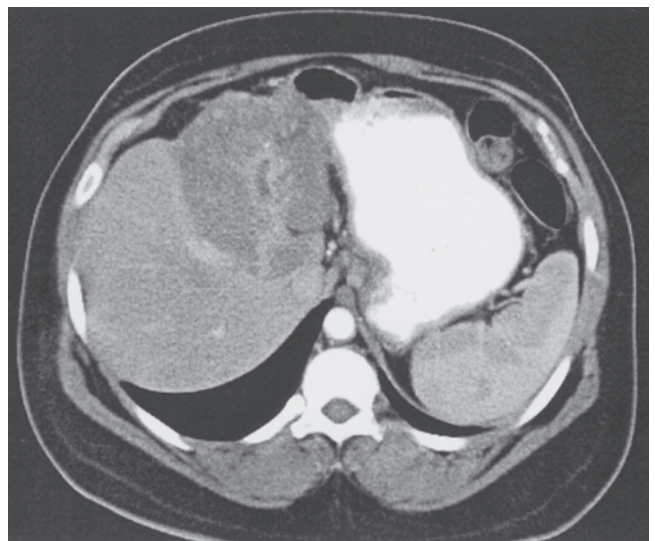
**TABLE 51-7: TNM STAGING OF DISTAL BILE DUCT CANCER. AMERICAN JOINT COMMITTEE ON CANCER, 7TH EDITION**

Stage 0	Tis	N0	M0
Stage IA	T1	N0	M0
Stage IB	T2	N0	M0
Stage IIA	T3	N0	M0
Stage IIB	T1–3	N1	M0
Stage III	T4	Any N	M0
Stage IV	Any T	Any N	M1

Tis, carcinoma in situ; T1, cancer confined to bile duct; T2, cancer invades beyond the wall of bile duct; T3, cancer invades gallbladder, pancreas, duodenum, or other adjacent organs without involvement of the celiac axis or the superior mesenteric artery; T4, cancer involves celiac axis or superior mesenteric artery; N0, no regional lymph node metastasis; N1, regional lymph node metastasis (regional lymph nodes are those along the CBD, hepatic artery, posterior and anterior pancreaticoduodenal nodes, and nodes along superior mesenteric vein and right lateral wall of superior mesenteric artery); M0, no distant metastasis; M1, distant metastasis.

with the presence of obstructive jaundice. Tumor markers (eg, CEA, CA 19-9, and CEA in combination with CA 19-9) may have utility in surveillance of patients with PSC; however, their sensitivities and specificities are too low for them to be applicable to screening or diagnosis in the general population.

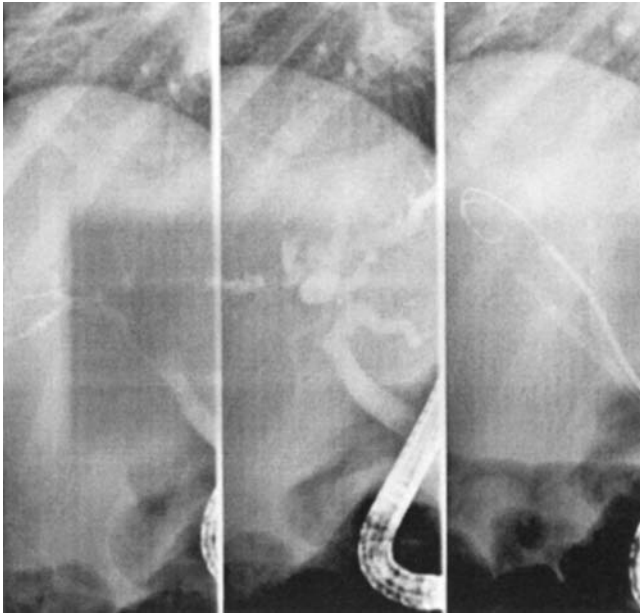
Transabdominal ultrasonography may reveal dilation of the biliary tree, which, in the absence of choledocholithiasis, suggests a possible biliary or pancreatic malignancy and should prompt contrast-enhanced spiral CT scanning. CT scan findings of intrahepatic cholangiocarcinomas include a liver mass with or without peripherally dilated ducts (Fig. 51-6). With perihilar cholangiocarcinomas, the primary tumor may not be



**FIGURE 51-6** CT scan of intrahepatic cholangiocarcinoma. The image shows an intrahepatic cholangiocarcinoma primarily involving the left lobe of the liver.

visualized; their presence is suggested by the detection of dilated intrahepatic bile ducts (often bilateral), a normal or collapsed gallbladder (if the site of biliary obstruction is proximal to the cystic duct–bile duct confluence), a normal caliber distal CBD, and a normal pancreas. Findings of distal cholangiocarcinomas include dilation of intra- and extrahepatic bile ducts and the gallbladder, with or without a mass in the head of the pancreas. In addition to offering information on the site of the primary lesion, the CT scan offers valuable information necessary for staging and planning of therapies, including the presence or absence of local vascular invasion, regional lymphadenopathy, distant metastasis, and liver atrophy. Unilobar bile duct obstruction typically results in atrophy of the affected liver lobe together with hypertrophy of the unaffected lobe (atrophy-hypertrophy complex). Absence of the atrophy-hypertrophy complex can suggest vascular encasement by tumor.

For patients who are surgical candidates, an important goal of the preoperative evaluation is determining the proximal and distal tumor extent. If CT scanning fails to demonstrate the tumor itself (as is usually the case for resectable perihilar cholangiocarcinomas), additional imaging is helpful in surgical planning. In most centers, distal tumors are assessed by endoscopic retrograde cholangiopancreatography (ERCP, Fig. 51-7), whereas intrahepatic and perihilar tumors are best assessed by percutaneous transhepatic cholangiography (PTC). Recently, there has been increasing application of MRCP in this setting. Unlike conventional cholangiography, MRCP is noninvasive and does not require contrast material to be injected in the biliary ductal system. It also allows for visualization of the bile ducts both proximal and distal to a stricture. Some reports suggest that MRCP when applied to patients with cholangiocarcinoma offers



**FIGURE 51-7** ERCP of hilar cholangiocarcinoma. The images depict a stricture at the confluence of the hepatic ducts in a patient with a Klatskin tumor.

information equivalent to that offered by CT scanning and traditional cholangiography combined.<sup>19</sup> For these reasons, MRCP has been supplanting traditional cholangiography in the evaluation of patients with suspected cholangiocarcinoma in some centers.

Additional studies are not routinely indicated. The role of positron emission tomography (PET) scanning in the evaluation of patients with cholangiocarcinoma continues to be studied but is not yet established. If surgery is not planned, tissue diagnosis can be obtained through endoscopic or percutaneous biopsy. If surgical exploration is planned, a preoperative biopsy is not indicated.

A particularly challenging situation can arise in patients with PSC, 20–50% of whom will develop a benign dominant biliary stricture. These dominant strictures can be morphologically indistinguishable from cholangiocarcinomas on cholangiography. Cytological examination of brushings obtained during ERCP is the most common modality used for the diagnosis of cholangiocarcinoma in this setting; however, the sensitivity of this modality (40–80%) can be poor.<sup>20</sup> The most accurate modality for diagnosing cholangiocarcinoma in patients with PSC who present with a dominant biliary stricture is endoscopic ultrasonography with fine-needle aspiration (EUS-FNA, sensitivity and specificity approaching 80 and 100%, respectively).<sup>21</sup> EUS-FNA should be applied in patients with equivocal or negative brush cytological findings if clinical suspicion of cholangiocarcinoma being present in a dominant stricture is high.

## Surgical Therapy

As is the case for gallbladder cancer, complete surgical resection is the only potentially curative therapy for patients with cholangiocarcinoma. Therefore, all patients suspected of having cholangiocarcinoma should be offered exploration unless contraindications to surgical resection exist. These contraindications include (1) major comorbidities precluding safe surgery, including cirrhosis, (2) metastatic disease, (3) invasion of the main portal vein or hepatic artery proximal to their bifurcations, (4) bilateral invasion of portal vein and/or hepatic artery branches, (5) bilateral hepatic duct involvement (up to secondary radicles bilaterally), and (6) unilateral duct and/or vessel involvement with contralateral liver lobe atrophy.

The utility of preoperative biliary stenting in patients with cholangiocarcinoma is controversial. Available retrospective data and one recently reported multicenter randomized controlled trial<sup>22</sup> suggest that among patients undergoing pancreaticoduodenectomy for periampullary cancers, routine preoperative biliary stenting is associated with increased perioperative morbidity rates, especially with respect to infectious complications. Therefore, we do not recommend routine preoperative stenting for patients with distal bile duct cancers. Instead, selective application of stenting in patients with obstructive jaundice who experience significant delay until surgery is performed (eg, those

undergoing neoadjuvant therapy) is appropriate. However, this experience should not be extrapolated to patients with perihilar cholangiocarcinomas, for whom the relationship between preoperative stenting and operative outcomes is less clear. Some authors believe stents placed preoperatively make intraoperative assessment of tumor extent more difficult. In our experience, bilateral Ring catheters, placed percutaneously into the left and right biliary systems shortly before the time of surgery, greatly facilitates the resection of perihilar cholangiocarcinomas. Our approach is described in detail later.

## Surgical Technique

Resectable intrahepatic cholangiocarcinomas are treated using standard liver resections, and distal cholangiocarcinomas are treated by pancreaticoduodenectomy. These procedures are discussed elsewhere in this textbook. The following discussion focuses on our surgical approach to resectable perihilar cholangiocarcinomas.

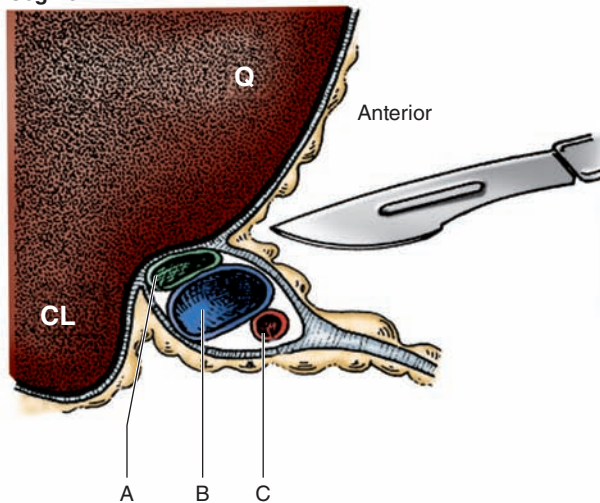
We begin with exploratory laparoscopy to rule out the presence of disseminated disease that may have escaped detection on preoperative imaging. Reports suggest that 25–30% of patients undergoing laparoscopic exploration for cholangiocarcinoma are found to have unresectable disease during laparoscopy.<sup>23</sup> If laparoscopic examination fails

to reveal metastasis, we proceed with laparotomy through either an upper midline or a right subcostal incision (that can be extended to the left as necessary). We then conduct a thorough examination for the presence of distant metastases. Enlarged lymph nodes are biopsied and subject to frozen-section analysis. The presence of metastasis in N2 (periaortic, pericaval, superior mesenteric artery, and/or celiac artery) lymph nodes is a contraindication to radical resection.

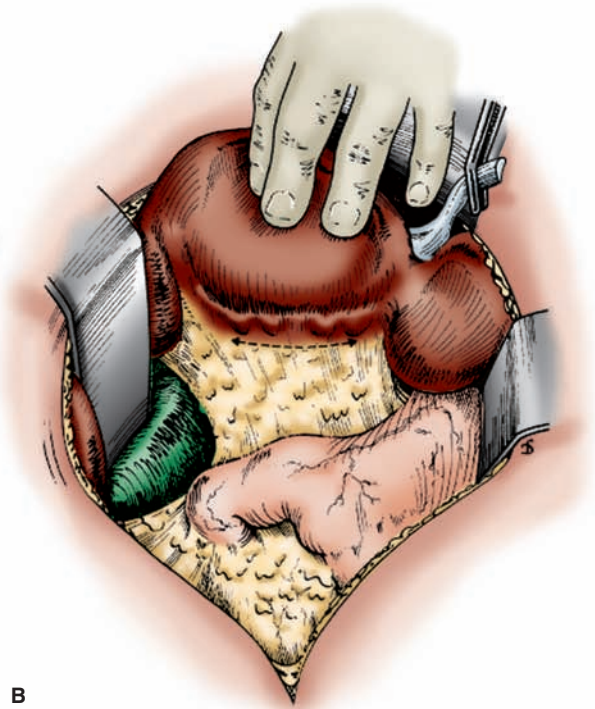
Next, we lower the hilar plate by incising the liver capsule at the base of the quadrate lobe (segment 4) between the gallbladder fossa and the umbilical fissure (Fig. 51-8). This maneuver facilitates inspection of the porta hepatis. At this point we palpate the tumor in an attempt to assess its proximal and distal extent.

We then begin mobilization of the extrahepatic biliary tree from its surrounding structures. The gallbladder is mobilized, and the CBD is circumferentially dissected just proximal to where it assumes a retroduodenal location. We transect the CBD at this level and oversew the stump of the distal CBD with a nonabsorbable monofilament suture. We then dissect the extrahepatic biliary tree off of the underlying vascular structures, starting distally and working proximally (Fig. 51-9). During this step, cephalad and anterior traction is applied to the gallbladder, distal CBD, and the distal ends of the preoperatively placed Ring catheters (which in combination form a convenient handle that can be grasped). The bile duct and surrounding lymph node-bearing soft tissues

Segment IV



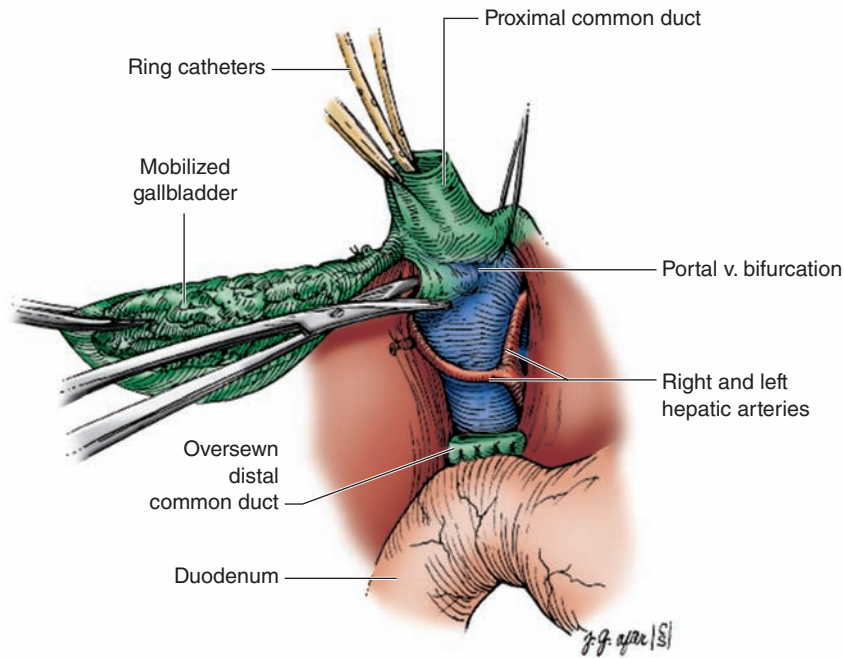
A



B

**FIGURE 51-8** Lowering of hilar plate. This illustration showing the quadrate (Q) and caudate (CL) lobes and the portal triad (bile duct [A], portal vein [B], and hepatic artery [C]) depicts a sagittal section through the region of the hilar plate. The knife indicates the point of incision used when lowering the hilar plate.



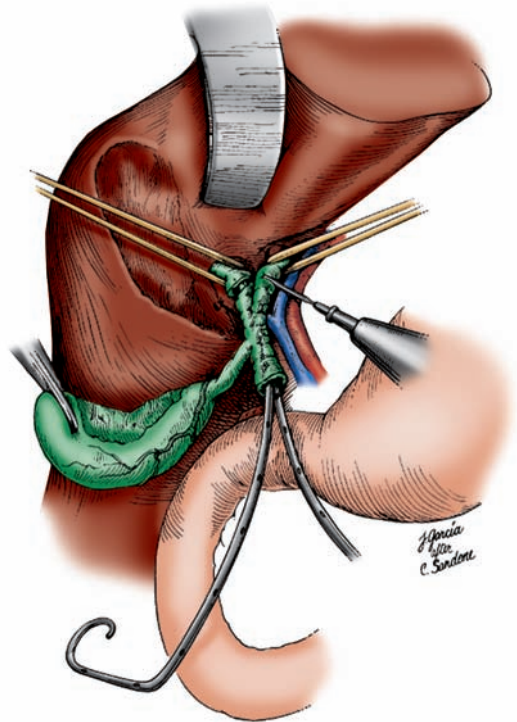


**FIGURE 51-9** Resection of hilar cholangiocarcinoma. This illustration shows the extrahepatic biliary tree being dissected off of the anterior surface of the portal vein. The dissection proceeds in a cephalad direction following transection of the distal bile duct.

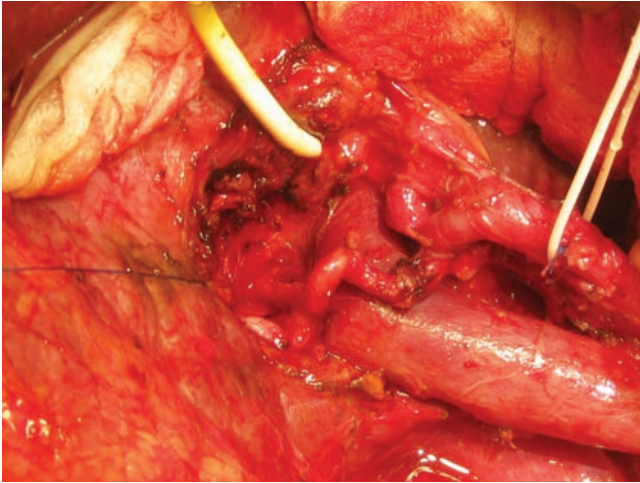
should be cleared en bloc from the portal vein and the hepatic artery. Only after this step is accomplished the possibility of tumor vascular invasion is definitely eliminated.

The most difficult step in this dissection is usually encountered at the hepatic duct bifurcation, the site of Klatskin tumors. Dissection here is facilitated by placing vessel loops around the left and right hepatic ducts and placing them on traction as necessary. Because the left duct typically runs along the undersurface of the liver (segment 4) for a longer distance than the right duct, it is usually easier to dissect the left duct first and encircle it with a vessel loop prior to dissecting the right duct. We find that the Ring catheters are particularly helpful in the identification of the right and left hepatic ducts during this stage of the procedure. The resection is completed by transecting the biliary duct(s) proximal to the tumor (Fig. 51-10). Figure 51-11 shows the operative field following resection of a Klatskin tumor. The skeletonized hepatoduodenal ligament structures are visible. Frozen sections of the proximal and distal margins should be checked intraoperatively, with the goal of achieving negative microscopic margins (R0 resection).

Reconstruction following resection of Klatskin tumors consists of bilateral hepaticojejunostomies to a 60-cm retrocolic Roux-en-Y limb of jejunum. Small secondary or tertiary biliary branches should be incorporated into the anastomoses or ligated. Prior to performing the anastomoses, the Ring catheters are replaced with soft Silastic catheters (usually 14–18F) (Fig. 51-12). Catheter exchange is performed as follows: The Silastic catheters are placed over the distal ends of the cut Ring catheters (the portions protruding from the transected bile

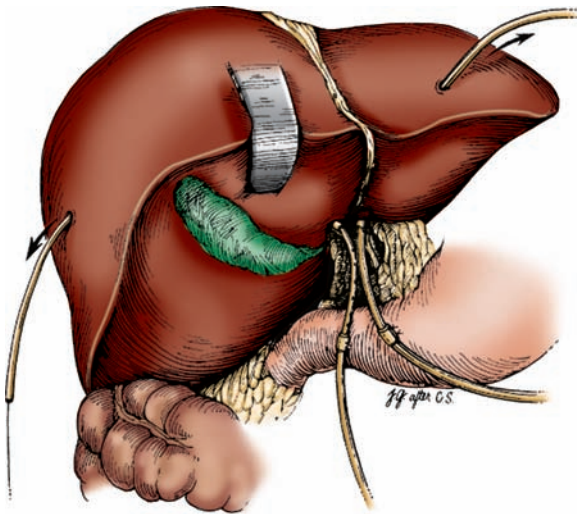


**FIGURE 51-10** Transection of proximal bile ducts. This illustration depicts the transection of the left and right hepatic ducts proximal to the hilar cholangiocarcinoma. Note the vessel loops around each of the hepatic ducts and the Ring catheters.

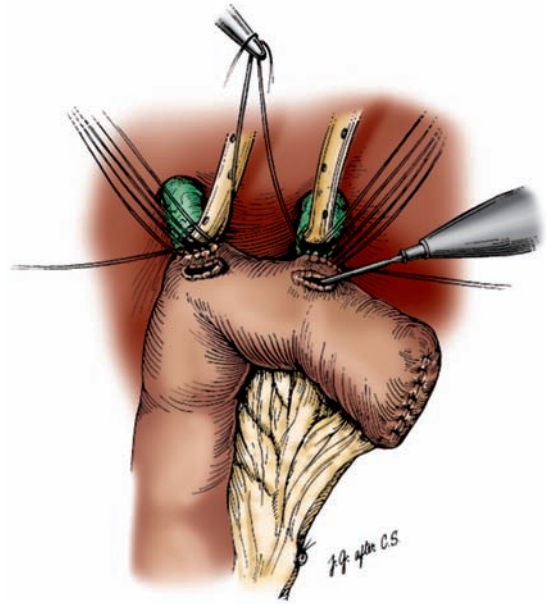


**FIGURE 51-11** Intraoperative photograph showing skeletonized hepatoduodenal ligament structures following resection of Klatskin tumor. A vessel loop has been placed around the common hepatic artery.

ducts), and the Ring and Silastic catheters are sewn together with cross sutures. The Ring catheters are then pulled proximally through the intrahepatic biliary tree and out the surface of the liver with the Silastic catheters attached. Finally, the Ring catheter is removed. If Ring catheters have not been placed preoperatively, the Silastic catheters can be placed as follows: Randall stone forceps are inserted into the intrahepatic biliary tree through the transected bile ducts and out the liver surface. The Silastic catheters are then sewn to the “eyelet” at the end of the forceps and pulled back down the duct. This maneuver is repeated so that a Silastic catheter is present in each of the right and left biliary systems.



**FIGURE 51-12** Replacement of biliary stents. Following completion of resection, the Ring catheters are exchanged for Silastic catheters, as described in the text.



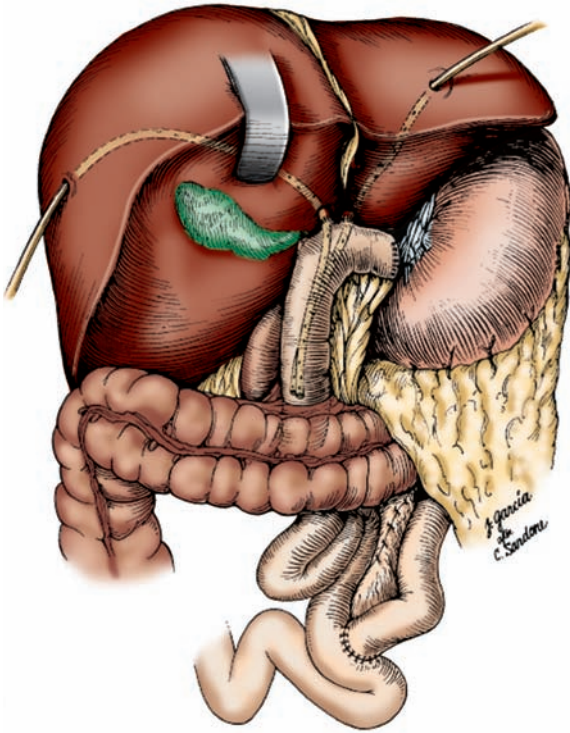
**FIGURE 51-13** Bilateral hepaticojejunostomies. The biliary-enteric anastomoses are created, starting with the posterior row of sutures.

The hepaticojejunostomies are created using a single layer of interrupted 5-0 absorbable monofilament sutures (Fig. 51-13). The posterior row of sutures are placed but not tied until the entire row can be “parachuted” closed. Using cautery, two small openings in the distal portion of the Roux limb are made, through which the distal ends of the Silastic catheters are placed. The anterior row of sutures are then placed and tied to complete the anastomosis (Fig. 51-14).

We then suture the Roux limb to the undersurface of the liver and to the mesocolon. We suture two large radiopaque clips to the surface of the liver at the sites where each of the Silastic tubes exit. These clips serve as permanent markers of the exit sites and allow for radiological visualization of the relationship between the liver surface and the last radiopaque marker on the Silastic catheters.

Recently, more aggressive approaches that include the routine application of liver resection, and portal vein resection in select cases, are being reported with increasing frequency. Addition of hepatic resection can extend the possibility of R0 resection to patients with Bismuth type III lesions (Fig. 51-15). Because Bismuth types II and III tumors may involve the caudate lobe ducts, some authors recommend routine caudate lobectomy when resecting these lesions. Although the highest 5-year postoperative survival rates have been reported from centers using such aggressive surgical approaches, these extended procedures should be done only if they can be performed with low perioperative morbidity and mortality rates. In addition, some centers have reported the application of preoperative portal vein embolization, to induce lobar hypertrophy and thereby extend the limits of liver resection in patients at risk of developing hepatic insufficiency postoperatively.





**FIGURE 51-14** Completed reconstruction. This illustration depicts the operative field following completion of the bilateral hepaticojunostomies.

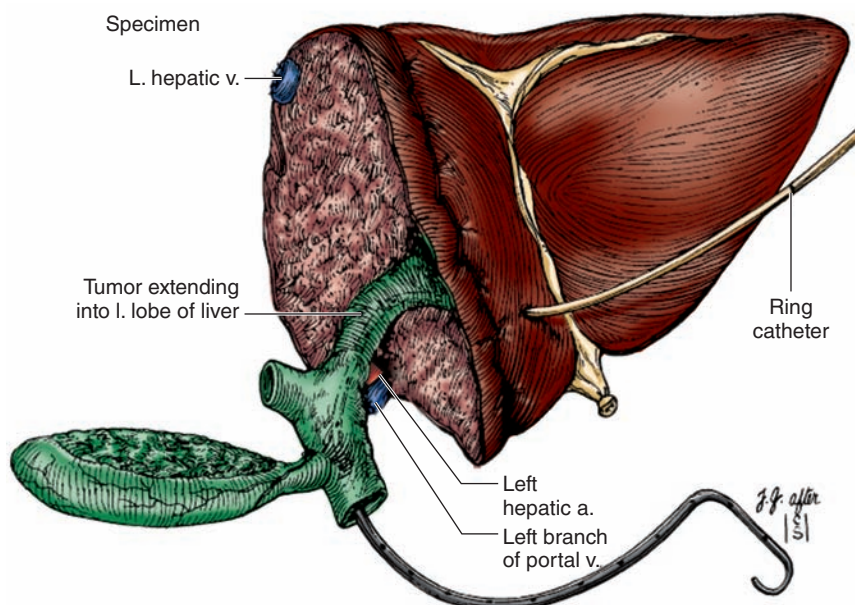
Finally, orthotopic liver transplantation has been applied to patients with intrahepatic and perihilar cholangiocarcinomas. However, cancer recurrence occurs in over 50% of cases, and 5-year survival rates average only 22%. Long-term survivors have been reported; most of these patients had small, peripheral cholangiocarcinomas discovered incidentally. For patients with known cholangiocarcinoma, liver transplantation following neoadjuvant therapy in carefully selected and staged patients is being studied, with some promising initial results.<sup>24</sup> This form of therapy should not be offered outside the context of a study protocol.

### Adjuvant Therapies

Adjuvant chemotherapy, radiotherapy, or chemoradiotherapy is commonly offered, based on results of retrospective series. However, clear efficacy data derived from prospective randomized clinical trials are lacking. Similarly, neoadjuvant therapy, associated with anecdotal reports of tumor response sufficient to permit margin-negative resection in patients with advanced cholangiocarcinoma, needs to be studied further.

### Palliation

The major goal of palliation is relief of symptoms of biliary obstruction. Endoscopic or percutaneous biliary stenting is associated with less morbidity than surgical biliary bypass and is therefore recommended except in patients who are found to have unresectable disease at the time of surgical



**FIGURE 51-15** Extended resection of hilar cholangiocarcinoma. This illustration depicts of the resection specimen following removal of the extrahepatic bile duct en bloc with the left lobe of the liver.



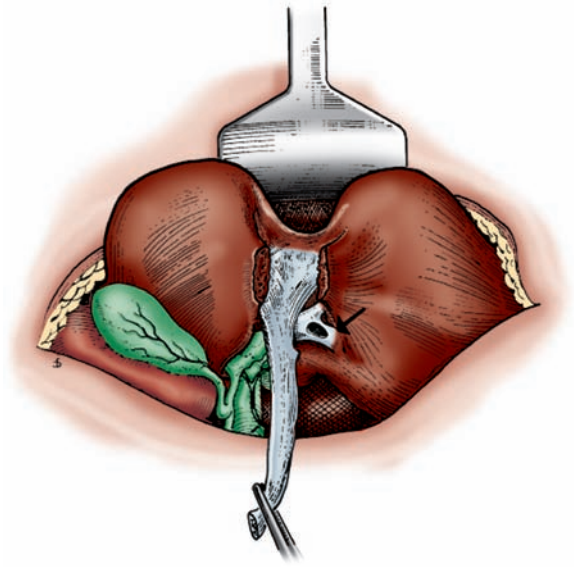
exploration or those in whom nonsurgical stenting cannot be accomplished. Endoscopic stenting is the preferred approach for distal bile duct cancers; proximal cancers are more difficult to stent endoscopically and usually require a percutaneous approach.

Patients with a Bismuth type I hilar cholangiocarcinoma are usually palliated effectively with a single biliary stent. Patients with Bismuth types II, III, and IV hilar cholangiocarcinomas may require two or more separate stents to decompress the entire biliary tree and prevent obstruction-related cholangitis. However, in a prospective, randomized controlled trial of patients with hilar cholangiocarcinoma, unilateral biliary drainage was found to provide adequate palliation of obstructive jaundice; patients randomized to receive bilateral biliary stents had higher complication rates (cholangitis) but no detectable benefits.<sup>25</sup> The approach therefore needs to be individualized.

Metal stents tend to provide more durable palliation than plastic (polyethylene) stents (median stent patency of 8–12 vs 4.8 months) and are generally preferable in patients with malignant biliary obstruction. Plastic stents should be changed every 3–6 months to prevent episodes of cholangitis related to stent occlusion; these stents may be appropriate for patients with estimated survival durations of less than 3 months (eg, patients with diffuse metastases).

For patients who are found to have carcinomatosis at the time of exploratory laparoscopy, laparoscopic cholecystectomy traditionally has been recommended, to prevent subsequent development of acute cholecystitis related to biliary stent–induced cystic duct obstruction. The value of prophylactic cholecystectomy in this setting is unproven and should be performed only if it can be done safely. Stenting should be performed using percutaneous or endoscopic techniques postoperatively.

For patients who are found to have unresectable disease at the time of open exploration, available retrospective evidence suggests that surgical biliary bypass offers more durable palliation than percutaneous or endoscopic stenting. Patients with unresectable distal cholangiocarcinoma should undergo choledocho- or hepaticojejunostomy. The palliative options for patients with unresectable perihilar cholangiocarcinoma include (1) tumor debulking with Roux-en-Y hepaticojejunostomy and intraoperative placement of Silastic transhepatic catheters (as described earlier) and (2) Roux-en-Y hepaticojejunostomy using the segment 4 or 5 duct. Segment 3 or 5 bypass is used in patients with advanced perihilar cholangiocarcinoma with predominantly right- or left-sided disease, respectively. The segment 3 hepatic duct is approached by following the falciform ligament into the recess of the left lobe in the umbilical fissure (Fig. 51-16). Localization of the segment 5 duct is difficult, as no external anatomic landmarks exist and considerable parenchymal dissection is often necessary. Intraoperative ultrasonography (IOUS) considerably facilitates this procedure. These unilateral bypasses should be avoided in the



**FIGURE 51-16** Segment 3 bypass. This illustration depicts the approach to the segment 3 duct (arrow) to which a Roux-en Y limb of jejunum can be anastomosed for palliation of obstructive jaundice in patients with advanced perihilar cholangiocarcinoma primarily affecting the right biliary system.

presence of ipsilateral liver lobe atrophy, a finding that indicates limited functional hepatic parenchyma.

External beam radiation and transcatheter brachytherapy may contribute to pain relief and biliary decompression; however the data on the effects of radiation on survival duration are conflicting.

Recently published results of the ABC-02 trial (discussed earlier in the section on palliation of patients with advanced gallbladder cancer) indicate that the combination of gemcitabine plus cisplatin should be offered to patients with advanced bile duct cancer.<sup>13</sup> Nearly 60% of patients who were enrolled in this multicenter phase III trial had locally advanced or metastatic bile duct cancer. Administration of the gemcitabine-cisplatin combination was associated with prolongation of overall and progression-free survival compared to administration of gemcitabine alone.

Finally, photodynamic therapy (PDT), in which endoscopic application of light activates a photosensitizer, leading to local cell death, has been associated with promising results. One prospective randomized trial, in which 19 patients with advanced cholangiocarcinoma were randomized to stenting alone or stenting followed by PDT, was terminated prematurely because patients randomized to the PDT arm were found to have a significantly longer survival (493 vs 98 days, median survival) in addition to improved biliary drainage and quality of life.<sup>26</sup> PDT-associated prolongation of survival was observed in another small prospective randomized trial.<sup>27</sup> Additional study of this modality is warranted.

## Outcomes

Less than 50% of patients diagnosed with perihilar cholangiocarcinoma are able to undergo curative resection. Reported 5-year postoperative survival rates for patients with these cancers are highly variable; they range from 8 to more than 50%.<sup>19</sup> In general, the highest survival rates are associated with series containing a high proportion of cases in which R0 resection was achieved. Series containing the highest R0 resection rates (>75% of cases in some published experiences) tend to be reported by institutions where liver resection is applied liberally to patients with cholangiocarcinoma.<sup>19</sup> A caveat that should be remembered is that these same series also tend to be associated with the highest perioperative mortality rates (up to 10% in some cases).

For patients with intrahepatic cholangiocarcinoma, reported 3-year survival rates following curative resection with negative margins range from 22 to 66%. For patients with distal cholangiocarcinoma, 5-year survival rates following pancreaticoduodenectomy range from 15 to 25% in most reported series. Among patients with node-negative disease, 5-year postoperative survival rates as high as 54% have been reported.

The best reported outcomes among patients with unresectable biliary tract cancers are those from the ABC-02 trial.<sup>13</sup> The median overall survival among patients treated with the combination of gemcitabine and cisplatin was 11.7 months, whereas it was 8.1 months in those treated with gemcitabine alone.<sup>13</sup>

## REFERENCES

- Jemal A, Siegal R, Ward E, et al. Cancer statistics, 2009. *CA Cancer J Clin.* 2009;59:225.
- Wistuba II, Gazdar AF. Gallbladder cancer: lessons from a rare tumor. *Nature Rev Cancer.* 2004;4:695.
- Misra S, Chaturvedi A, Misra NC, et al. Carcinoma of the gallbladder. *Lancet Oncol.* 2003;4:167.
- Pandey M, Shukla VK. Lifestyle, parity, menstrual and reproductive factors and risk of gallbladder cancer. *Eur J Cancer Prev.* 2003;12:269.
- Elnemr A, Ohta T, Kayahara M, et al. Anomalous pancreaticobiliary ductal junction without bile duct dilatation in gallbladder cancer. *Hepato-gastroenterology.* 2001;48:382.
- AJCC (American Joint Committee on Cancer), Edge SB, Byrd DB, Compton CC, et al, eds. *Cancer Staging Manual.* 7th ed. New York, NY: Springer-Verlag; 2010:201.
- Wakai T, Shirai Y, Yokoyama N, et al. Early gallbladder carcinoma does not warrant radical resection. *Br J Surg.* 2001;88:675.
- Abramson MA, Pandharpade P, Ruan D, et al. Radical resection for T1b gallbladder cancer: a decision analysis. *HPB (Oxford).* 2009;8:656.
- Bartlett DL, Fong Y, Fortner JG, et al. Long-term results after resection for gallbladder cancer. Implications for staging and management. *Ann Surg.* 1996;224:639.
- Ito H, Matros E, Brooks DC, et al. Treatment outcomes associated with surgery for gallbladder cancer: a 20-year experience. *J Gastrointest Surg.* 2004;8:183.
- Fong Y, Jarnagin W, Blumgart LH. Gallbladder cancer: comparison of patients presenting initially for definitive operation with those presenting after prior noncurative intervention. *Ann Surg.* 2000;232:557.
- Chijiwa K, Noshiro H, Nakano K, et al. Role of surgery for gallbladder carcinoma with special reference to lymph node metastasis and staging using Western and Japanese classification systems. *World J Surg.* 2000;24:1271.
- Valle J, Wasan H, Palmer DH, et al. Cisplatin plus gemcitabine versus gemcitabine for biliary tract cancer. *N Engl J Med.* 2010;362:1273.
- Wolpin B, Mayer RJ. A step forward in the treatment of advanced biliary tract cancer. *N Engl J Med.* 2010;263:1335.
- Donohue JH, Stewart AK, Menck HR. The National Cancer Data Base report on carcinoma of the gallbladder, 1989-1995. *Cancer.* 1998; 83:2618.
- Dixon E, Vollmer C, Sahajpal A, et al. An aggressive surgical approach leads to improved survival in patients with gallbladder cancer. *Ann Surg.* 2005;241:385.
- Lazaridis KN, Gores GJ. Cholangiocarcinoma. *Gastroenterology.* 2005; 128:1655.
- Bismuth H, Nakache R, Diamond T. Management strategies in resection for hilar cholangiocarcinoma. *Ann Surg.* 1992;215:31.
- Clary B, Jarnagin W, Pitt H, et al. Hilar cholangiocarcinoma. *J Gastrointest Surg.* 2004;8:298.
- Charatcharoenwithaya P, Enders FB, Halling KC, et al. Utility of serum tumor markers, imaging, and biliary cytology for detecting cholangiocarcinoma in primary sclerosing cholangitis. *Hepatology.* 2008;48:1106.
- DeWitt J, Misra VL, Leblanc JK, et al. EUS-guided FNA of proximal biliary strictures after negative ERCP brush cytology results. *Gastrointest Endosc.* 2006;64:325.
- van der Gagg NA, Rauws EAJ, van Eijck CHJ, et al. Preoperative biliary drainage for cancer of the head of the pancreas. *N Engl J Med.* 2010;362:129.
- Weber SM, DeMatteo RP, Fong Y, et al. Staging laparoscopy in patients with extrahepatic biliary carcinoma. Analysis of 100 patients. *Ann Surg.* 2002;235:392.
- Rea DJ, Heimbach JKJ, Rosen CB. Liver transplantation with neoadjuvant chemoradiation is more effective than resection for hilar cholangiocarcinoma. *Ann Surg.* 2005;242:451.
- De Palma GD, Galloro G, Siciliano S, et al. Unilateral versus bilateral endoscopic hepatic duct drainage in patients with malignant hilar biliary obstruction: results of a prospective, randomized, and controlled study. *Gastrointest Endosc.* 2001;53:547.
- Ortner M, Caca K, Berr F, et al. Successful photodynamic therapy for nonresectable cholangiocarcinoma: a randomized prospective study. *Gastroenterology.* 2003;125:1355.
- Zoepf T, Jakobs R, Arnold JC, et al. Palliation of nonresectable bile duct cancer: improved survival after photodynamic therapy. *Am J Gastroenterol.* 2005;100:2426.

*This page intentionally left blank*



# LAPAROSCOPIC BILIARY PROCEDURES

Jin S. Yoo • Theodore N. Pappas

## INTRODUCTION

The most common biliary tract procedure currently performed is the laparoscopic cholecystectomy. This has yielded interest in management of common bile duct (CBD) stones encountered during the procedure. Successful management of such stones during a laparoscopic cholecystectomy is beneficial to the patient by preventing a secondary or more invasive procedure to clear the duct, such as endoscopic retrograde cholangiopancreatography (ERCP) or laparoscopic CBD exploration, respectively. Furthermore, an all-inclusive operation may be more cost-effective. Other operations on the biliary tract, including bile duct resections and reconstructions can be the most technically demanding procedures that a general surgeon performs. The advancement of technology and surgical skills in the field of minimally invasive surgery has allowed for traditionally open complex biliary procedures to be attempted and successfully performed laparoscopically. This chapter focuses on minimally invasive techniques in the management of biliary tract disease. Identification and management of CBD stones and performing biliary bypass procedures are discussed in detail. Highly advanced laparoscopic biliary tract procedures that are performed in selected patients are briefly mentioned as well. These procedures have not gained widespread use and are generally performed by specialized laparoscopic surgeons due to the inherent technical difficulties and there are viable endoscopic therapies that are just as effective as the surgical therapies. Nevertheless, the knowledge and utility of these techniques will be important in practices where advanced endoscopic procedures are not available and at centers specialized in hepatobiliary surgery.

## LAPAROSCOPIC COMMON BILE DUCT EVALUATION

Common bile duct stones are present in as much as 10% of patients with cholelithiasis. The large majority of these

stones are less than 4 mm and generally pass into the duodenum without any clinical consequence.<sup>1</sup> Nevertheless, stones greater than 3–4 mm should be removed since they may cause severe complications such as pancreatitis and/or cholangitis. Cholangiography and ERCP are the standards by which the CBD is evaluated for the presence of stones. Cystic duct cholangiography can be accomplished in 90% of patients and, overall, the intraoperative cholangiogram (IOC) has a sensitivity of 87% and specificity of more than 95% for the detection of stones.<sup>2</sup> As it was in the era of open cholecystectomy, the use of IOC during laparoscopic cholecystectomy remains somewhat controversial. Those that support the routine use of IOC cite this practice (1) to clarify anatomy and therefore reduce bile duct injuries during laparoscopic cholecystectomies; and (2) to detect asymptomatic bile duct stones, which may be present in 5–10% of patients undergoing laparoscopic cholecystectomies. The disadvantages of routine IOC are (1) that it prolongs operative time and (2) false-positive results may lead to unnecessary procedures (~50% of patients with incidental CBD stones found at time of surgery will not need any intervention).<sup>3,4</sup> Presently, the literature suggests that there is no difference in major and minor bile duct injuries whether routine or selective IOC are performed.<sup>2,5–7</sup> Additionally, a large number of routine IOCs have to be performed, compared to a selective approach, to detect missed CBD injuries or retained CBD stones significant in size. Given this, the financial cost to diagnose a clinically significant bile duct stone that was not suspected intra-operatively has been calculated at half a million dollars.<sup>7</sup> Therefore, we recommend that surgeons should individually weigh the pros and cons of routine versus selective use of IOC and tailor their practice in that manner. For those who perform IOC in all of their cholecystectomies, they must attempt to do it in all of their cases in order to get the benefits of their approach. And for those who selectively perform IOC should have a predetermined set of criteria to follow in which they feel IOC is indicated in a case-by-case manner (Table 52-1).

### TABLE 52-1: INDICATIONS FOR LAPAROSCOPIC CHOLANGIOGRAM

#### Preoperative factors

- Clinical presentation with biliary pancreatitis, cholangitis, or jaundice
- Radiographic findings increasing the risk of having CBD stones (multiple small gallstones)
- Radiographic findings suggestive of having CBD stones:
  - Dilated cystic duct
  - Common bile duct diameter >8 mm
- Radiographic evidence of CBD stones
- Elevated alkaline phosphatase (>2 times the upper normal limit) and total bilirubin (>3 mg/dL)

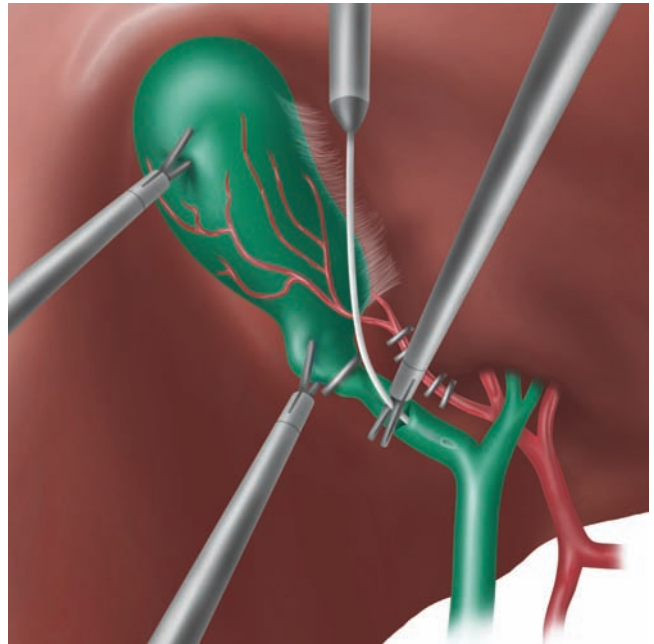
#### Intraoperative factors

- Uncertain anatomy
- Multiple small gallstones in the gallbladder
- Dilated cystic duct
- Routine use of intraoperative cholangiography to prevent or for early recognition of CBD injury

## LAPAROSCOPIC CHOLANGIOGRAPHY

There are multiple commercially made cholangiogram catheters and instruments to facilitate IOC. Any type can be used for the procedure described below:

1. Once the cystic duct is identified, the proximal side is clipped as close to the gallbladder as possible. A transverse ductotomy is made just distal to the clip using laparoscopic scissors.
2. A cholangiogram catheter is then inserted via an introducer sheath or fed through a cholangiogram clamp via one of the right upper quadrant ports of a standard laparoscopic cholecystectomy port placement. The catheter is maneuvered into the cystic duct and then is secured with a single clip or held in place with a cholangiogram clamp (Fig. 52-1).
3. Once the catheter is in place, the instruments that may interfere with the cholangiogram imaging are removed. A three-way stopcock is placed on the cholangiogram catheter in order to secure one syringe filled only with sterile normal saline (NS) and another with only the contrast media. The catheter is flushed with NS only to make sure the tip of the catheter is in the correct position in the CBD and all the air bubbles are evacuated from the syringe (since air bubbles in the CBD may look like stones during a cholangiogram).
4. Isotonic contrast media is used for the cholangiogram. We mix it with 1:1 with sterile NS to prepare a 50% solution of contrast media to minimize contrast exposure for the patient and to have an adequate study.
5. The patient is positioned in a slight Trendelenberg position in order to have the contrast opacify the hepatic ducts as well as the distal CBD.



**FIGURE 52-1** The catheter is guided into the partially transected cystic duct. When not using the cholangiogram clamp, the grasper may be used in maneuvering the catheter and secured with a single metal clip.

6. Fluoroscopy is used if dynamic imaging is desired. If not, regular static x-ray machine may be used for imaging.
7. Once the setup is complete, contrast is injected while obtaining radiographic imaging. A proper study should document (1) contrast filling of both the right and left hepatic ducts, (2) contrast filling the distal CBD and emptying into the duodenum, and (3) careful evaluation of the CBD for filling defects suggestive of CBD stone(s). If the pancreatic duct is opacified (and visualized) during the injection of contrast, care should be taken to avoid excessive intraductal pressure to minimize the risk of pancreatitis.

## LAPAROSCOPIC ULTRASOUND

Intraoperative ultrasound (IOUS) is commonly used during liver resections to locate liver lesions and its vicinity to nearby hepatic or portal vein. There are laparoscopic ultrasound probes that have also been used for laparoscopic partial liver resections with success.<sup>8,9</sup> Its use in CBD evaluation has been more limited, however, prospective trials have shown that IOUS is comparable in terms of sensitivity and specificity to IOC in its ability to diagnose CBD stones.<sup>10</sup> This technique involves the use of linear-array transducer with frequency of 7.5–10 MHz. The image is obtained by moving the transducer first along the cystic duct and the hepatoduodenal ligament to the terminal CBD.<sup>11,12</sup> Potential advantages of IOUS are that it is inexpensive, noninvasive, and requires a

shorter examination time than the more invasive methods. The disadvantages are equipment availability, difficulty in visualizing the distal CBD, and operator dependency. IOUS can be an alternative to IOC for evaluation of CBD stones during a laparoscopic cholecystectomy in experienced hands (see also Chap. 49).

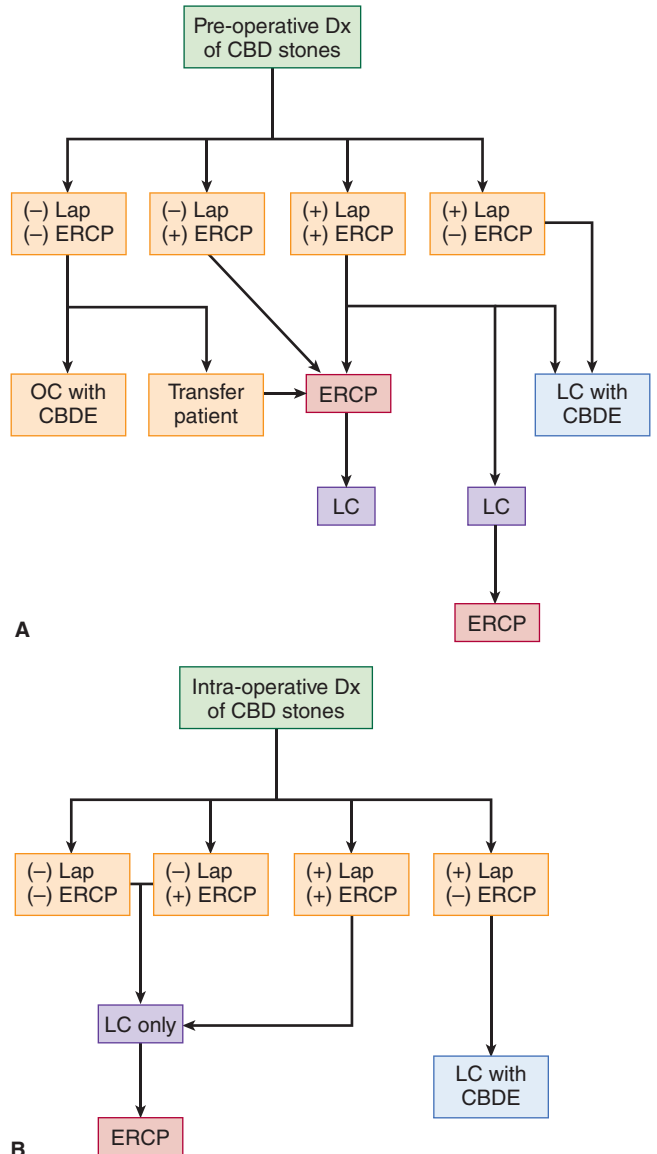
## LAPAROSCOPIC MANAGEMENT OF CHOLEDOCHOLITHIASIS

Cholelithiasis is defined as the presence of stones in the CBD. The most common location of obstruction is at the papilla, which is the most narrow portion of the duct. There are several preoperative findings on laboratory tests and radiographic imaging as well as intra-operative findings that can predict the presence of CBD stones (Table 52-2). The management of CBD stones differs depending on (1) whether they were found preoperatively or intra-operatively, (2) the experience of the surgeon performing laparoscopic or open CBD exploration, and (3) the availability of ERCP in your practice (Fig. 52-2).

In general, patients who are diagnosed with CBD stones prior to their cholecystectomy are usually symptomatic from their CBD stones—they may present with jaundice, cholangitis, and/or pancreatitis. The management differs significantly depending on the surgeon’s ability to perform laparoscopic CBD exploration and the availability of ERCP in the institution. For instance, if the surgeon cannot perform a laparoscopic CBD exploration and ERCP is not available, the options are to (1) perform an open cholecystectomy and CBD exploration, especially if the patient is unstable for transfer, or (2) transfer the patient to a facility where at least ERCP is available. Conversely, if the surgeon can perform a laparoscopic CBD exploration and ERCP is available at that institution, any treatment strategy will suffice (Fig. 52-2A).

The reported success rate of ERCP for clearing the CBD of stones approaches 90–95%, although this varies with the local expertise and experience of the endoscopist. Stone size is the limiting factor with stones greater than or equal to 2 cm will

require fragmentation prior to removal. A sphincterotomy is usually performed because relying on spontaneous stone passage increases the risk of pancreatitis, stone impaction, and/or cholangitis. The laparoscopic success rate of clearing the duct is 70–90%. The choice of clearance method should be based on several factors: (1) the availability of expert endoscopists with high success rate with ERCP and stone extraction, (2) the availability of laparoscopic and choledochoscopic equipment, (3) the surgical expertise in laparoscopic CBD surgery, and



**TABLE 52-2: INDICATION FOR PREOPERATIVE ERCP IN PATIENTS WITH CHOLEDOCHOLITHIASIS**

- Clinical suspicion of CBD stones and:
- Small cystic duct and/or CBD (making laparoscopic transcystic exploration difficult)
  - Elderly patient
  - High operative risk
  - Endoscopist with limited experience (if ERCP fails, surgical CBD exploration will be needed)
  - Surgeon with limited experience in laparoscopic treatment of CBD stones
  - Strong desire of the patient to avoid open procedure

**FIGURE 52-2** Algorithms for the management of common bile duct (CBD) stone diagnosed (A) preoperatively and (B) intraoperatively during a laparoscopic cholecystectomy. (+) Lap, the surgeon can perform a laparoscopic CBD exploration; (-) Lap, the surgeon cannot perform a laparoscopic CBD exploration; (+) ERCP, ERCP available at the institution; (-) ERCP, ERCP not available at the institution; LC, laparoscopic cholecystectomy; OC, open cholecystectomy; CBDE, CBD exploration.



(4) the general condition of the patient. Table 52-2 suggests a strategy for selective use of preoperative ERCP.

In contrast to those who are diagnosed with choledocholithiasis preoperatively, CBD stones found at the time of surgery are usually incidental findings after an IOC. These patients have normal preoperative radiographic imaging and liver function tests. The algorithm in this setting is relatively straightforward (Fig. 52-2B). In one study, only half of the patients with a positive IOC finding required postoperative ERCP.<sup>3</sup> There is a significant false-positive rate with IOCs and in cases where there really is a CBD stone, there is a good chance that it will pass spontaneously if it is smaller than 5 mm in size. However, patients should have a postoperative ERCP to remove the CBD stones if the stones are larger than 5 mm in size. If one chooses to observe the small CBD stones, ERCP may be performed at a later time if the patient develops symptoms and/or elevated liver function tests.<sup>4,13-15</sup>

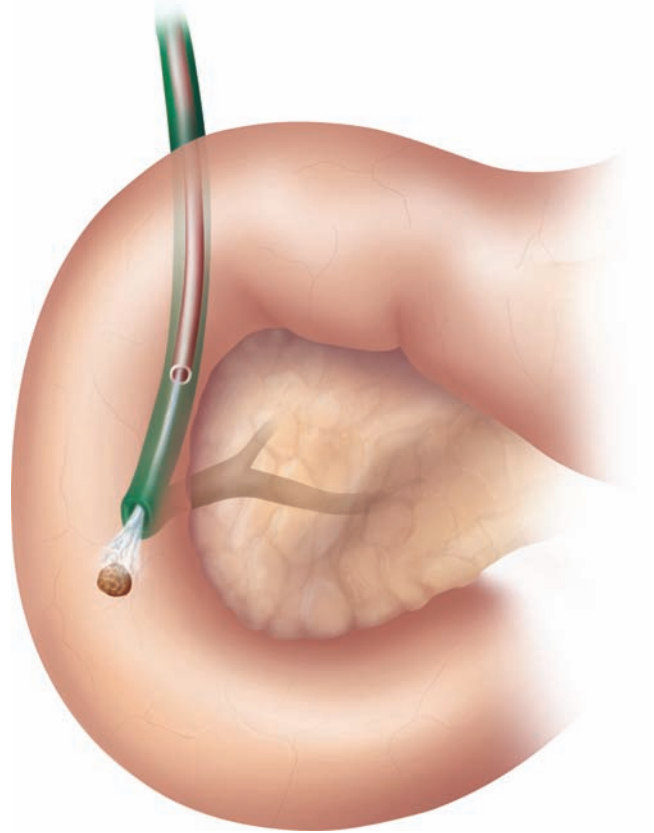
### LAPAROSCOPIC TRANSCYSTIC DUCT EXPLORATION (WITHOUT A CHOLEDOCHOSCOPE)

When a CBD stone is found during an IOC, several treatment options are available. If the duct is small and a single, less than 5 mm stone is found, a simple maneuver may be attempted with just the cholangiogram catheter still in the CBD. Intravenous (IV) administration of 1–2 mg of glucagon followed by the flushing of the CBD with saline is sometimes successful in clearing the duct (Fig. 52-3). Larger stones or the presence of multiple stones will require other methods of clearance. Laparoscopic transcystic duct exploration without a choledochoscope will be described first. This can be accomplished with a balloon or a basket technique.

#### Balloon Techniques

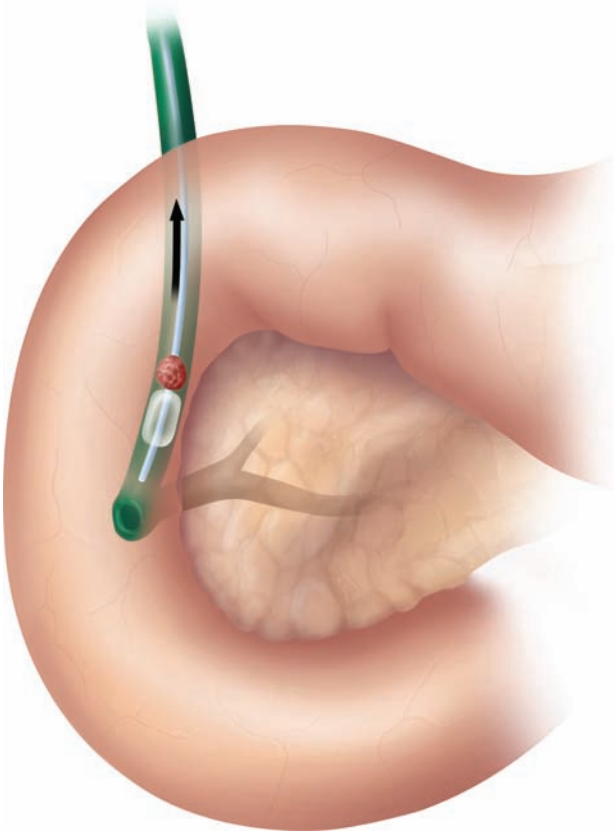
Low-pressure balloon catheters may be introduced through a percutaneous cholangiogram sleeve into the cystic duct and then into the CBD. A 4 French (4F) Fogarty-type balloon catheter is most effective and can fit through a 12–14F introducer sheath placed in the abdominal wall.<sup>16</sup> Once the catheter tip is in the duodenum, correct position of the catheter tip should be confirmed with radiography to avoid disruption of the ampulla by direct dilation. The balloon is then inflated and gently pulled back typically causing the duodenum to move with movement of the catheter. Traction is stopped and the balloon deflated. The catheter is withdrawn approximately 1 cm and the balloon is reinflated. Traction is then resumed until the balloon is seen at the cystic duct cannulation site. Occasionally small stones or debris can be delivered by this method (Fig. 52-4).

Another option is to use balloon dilation of the ampulla/sphincter of Oddi. Results from a few series have shown it to be a useful complementary tool for clearing CBD debris at



**FIGURE 52-3** Stone forced through ampulla with saline flush. IV glucagon administration may also be used as an adjunct to flushing. Flushing may be accomplished with the cholangiocatheter or a red rubber catheter inserted via the cystic duct or CBD (if a choledochotomy has been made).

the initial operation without embarking on the more complex CBD exploration via a formal choledochotomy. The technique employs a 6-mm diameter balloon dilating catheter over a guide wire. This is most easily accomplished using the right subcostal port site in the standard laparoscopic cholecystectomy or, alternatively, using an additional trocar in the right subcostal space. Fluoroscopy is used throughout the procedure. The wire is confirmed to be in the CBD and the distal tip in the lumen of the duodenum. The balloon catheter is advanced over the wire and passed through the ampulla and into the duodenum. The balloon is then inflated using a dilute contrast media. The location of the ampulla is demonstrated by the point at which the inflated balloon catheter cannot be withdrawn out of the duodenum and into the biliary system. Radiopaque markers on the balloon catheter help guide the deflated catheter so that it traverses the sphincter of Oddi. The balloon is then slowly inflated. The balloon should never be inflated larger than the diameter of the CBD. Dilation is held for a few minutes and then deflated. This is followed by irrigation of warm saline through the cystic duct and a complete cholangiogram. Placement of a drain is usually not necessary. Instrumentation of the ampulla may result in pancreatitis and this should be kept in mind in the

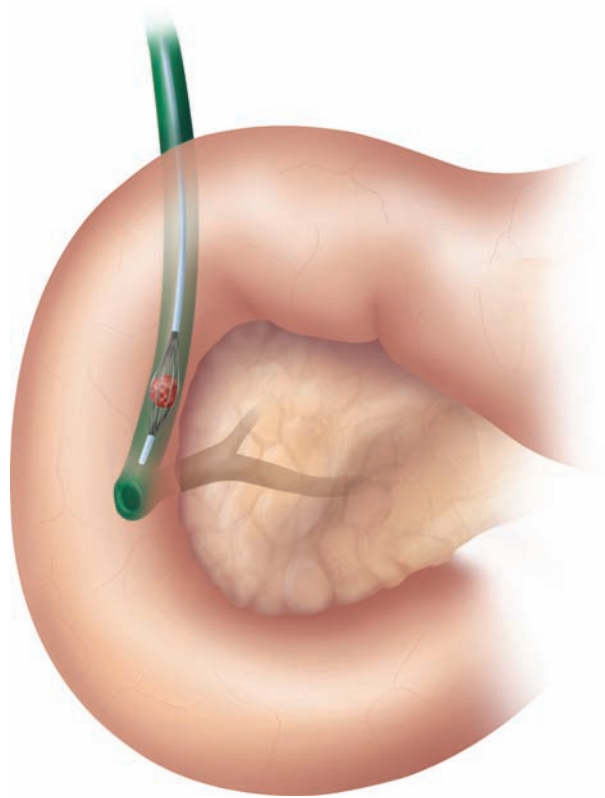


**FIGURE 52-4** Stone retrieval using a balloon catheter inserted via the cystic or common bile duct. The diameter of the inflated balloon should not be larger than the diameter of the CBD.

postoperative period. The incidence of pancreatitis is less than 10% unless the sphincter is forcefully disrupted. Operative time is usually less than 2 hours when accompanied with a cholecystectomy with successful clearance of stones reported 85–93% of the time.<sup>17,18</sup>

## Basket Techniques

Stone retrieval baskets may also be introduced through a 12–14F introducer sheath. Either a helical (Dormia-type) or straight (Segura-type) basket may be employed. While some authors advocate using baskets with soft filiform tips in order to avoid damage to the duct, there appears to be no difference in ductal injuries as compared to nonfiliform-type baskets.<sup>19</sup> However, it is important to use these baskets with extreme care. These baskets can be employed with or without fluoroscopy. When using the basket with fluoroscopy, the duct is filled with contrast media through the cholangiogram catheter that is already in place and the location of the stone is determined. The basket is then inserted through the introducer sheath into the duct and manipulated with the forceps. The position of the basket and the stones are monitored with fluoroscopy (Fig. 52-5). There are two disadvantages with this



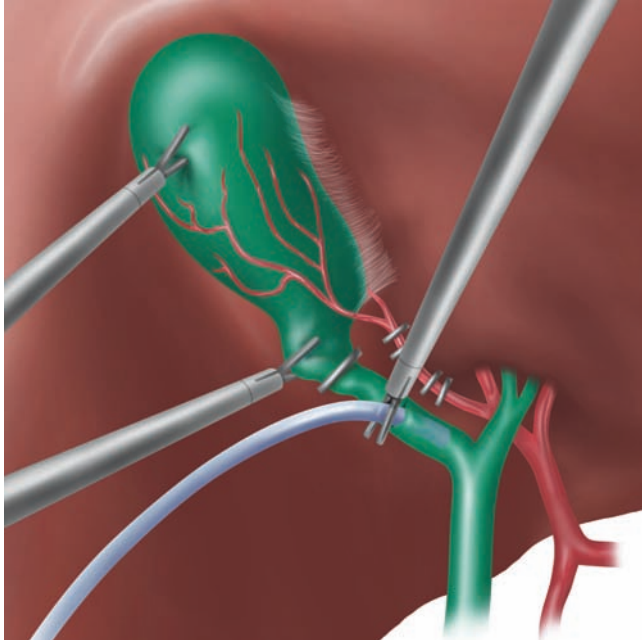
**FIGURE 52-5** Stone retrieval using wire basket. Occasionally the basket will crush the stone. In these instances flushing and balloon sweeps may result in ductal clearance.

technique: (1) the radiation exposure to the operating team and (2) the difficulty in manipulating the basket with the fluoroscopic C-arm in position over the patient. Because of these disadvantages, many have described using a nonfluoroscopic technique.<sup>20</sup> In order to accomplish this, several factors must be established. First, the surgeon must know the approximate length and course of the cystic duct as determined by the cholangiography. Second, the basket needs to be calibrated lengthwise in order to know the location of the tip of the catheter. Lastly, the surgeon must control the handle of the basket to know when the basket is open, closed, or partially closed suggesting the capture of a stone. When the basket is placed in the distal duct, the basket is gradually closed as it is withdrawn. This maneuver may have to be repeated several times. A major complication is capture of the papilla if the basket is advanced too far into the duct. This requires careful manipulation as pancreatitis or duct perforation may easily occur.

## LAPAROSCOPIC TRANSCYSTIC EXPLORATION (WITH A CHOLEDOCHOSCOPE)

The CBD can be explored under direct visualization if a choledochoscope is available. Before the CBD is cannulated with the choledochoscope, the cystic duct must be prepared.

The procedure is performed at the time of laparoscopy after the cholangiogram. In order to pass the scope easily and safely, the cystic duct must be large enough for this approach.<sup>16,20,21</sup> When the cystic duct is small, attempts to dilate it may be useful. Cystic duct dilation may be safely done up to 4 mm but not beyond 8 mm because of the increased risk of disruption.<sup>20</sup> Dilation may be performed by mechanical tapered dilators or balloon dilation. Although the most expensive way is pneumatic dilation, this is felt to be safer since radial dilatational forces exerted on the duct are safer than the shearing force of gradual mechanical dilation. The balloon-tipped catheter is passed over a 0.035-in hydrophilic wire and dilated to approximately 6 mm (Cook, Bloomington, IN). In the situation that the cystic is very short and large enough to accept a choledochoscope, curved-tipped forceps may be inserted to expand the duct. If the cystic duct–CBD junction is disrupted by forceful dilation, an open repair may be required. Once the cystic duct is dilated, the scope is inserted using the hydrophilic guide wire already in place through a sheath placed as close to the cystic duct as possible. Alternatively, the scope may be introduced without a guide wire as well (Fig. 52-6). Careful manipulation of the scope with atraumatic forceps is extremely important as these scopes can easily be damaged. The scope can be advanced over a guide wire or freely into



**FIGURE 52-6** A flexible choledochoscope is passed through an introduced sheath placed in the right upper quadrant as close to the cystic duct as possible. The scope can be introduced free hand or with the use of a 0.035-in guide wire. Care should be taken to manipulate the scope using atraumatic forceps. Using a working channel, wire baskets or balloon-tipped catheters can be passed under direct visualization for stone retrieval. To facilitate visualization, pressurized saline irrigation is used throughout the procedure to distend the common duct and clear free-floating debris.

the cystic duct with manipulation using grasping atraumatic forceps. The most difficult part of accessing the CBD is negotiating the scope through the cystic duct. In this situation, the gallbladder should be retracted as to straighten the cystic duct as much as possible and the choledochoscope angle should be straightened as much as possible. The scope is then advanced via the cystic duct into the CBD under direct vision. The scope is first directed into the distal CBD and stone(s) visualized may be removed with a basket passed via the working channel of the scope. Once the stone is negotiated into the basket, both the scope and the basket are removed together through the cystic duct.

A complete cholangiogram should be performed to document clearance of both the common and hepatic ducts. Because the cystic duct has been dilated, it is best secured with a suture ligature rather than placing metal clips. Inspecting the proximal ductal system is rarely possible since it requires a short cystic duct entering at a 90-degree angle; however, proximal exploration is rarely needed. In this case, the laparoscopic surgeon can attempt to clear the duct via a direct choledochotomy approach.

## LAPAROSCOPIC CHOLEDOCHOTOMY

While a transcystic approach clears the duct in the majority of cases, in certain instances it will not be feasible or successful. The lumen of the duct may not dilate enough to accommodate a scope or the duct may follow a long tortuous course before joining the CBD. In this situation, the surgeon has the option of performing a postoperative ERCP or transductal exploration either via open or laparoscopic approaches. We will describe the laparoscopic approach. We do not recommend this approach in patients with small CBDs (<6 mm). A transductal exploration allows the surgeon to easily explore the proximal and distal ductal system, use a larger scope, and evacuate the stones directly. A choledochotomy will require the placement of a T-tube, which has the advantage of potentially retrieving stones in the postoperative period.

The gallbladder is left in place to facilitate upward and cephalad retraction to straighten and provide tension to the common duct. Just distal to the cystic duct–CBD junction, a short, anterior longitudinal ductotomy is created sharply. It is important to avoid vigorous circumferential dissection around the duct and use a longitudinal incision along the axis of the duct to prevent subsequent development of ischemic strictures by inadvertent injury to the CBD blood supply. The choledochoscope is introduced at a right angle to the common duct and advanced under pressure saline irrigation, allowing the CBD to nicely distend and visualize any stones or strictures. The scope can also be advanced proximally to remove stones with baskets or balloon as previously described.

Upon completion of the laparoscopic CBD exploration via the choledochotomy, T-tube closure of the common duct is recommended. An appropriate size T-tube is selected based on the size of the duct, usually a 12–14 Fr T-tube is sufficient. The tube is fashioned to the surgeon's preference.



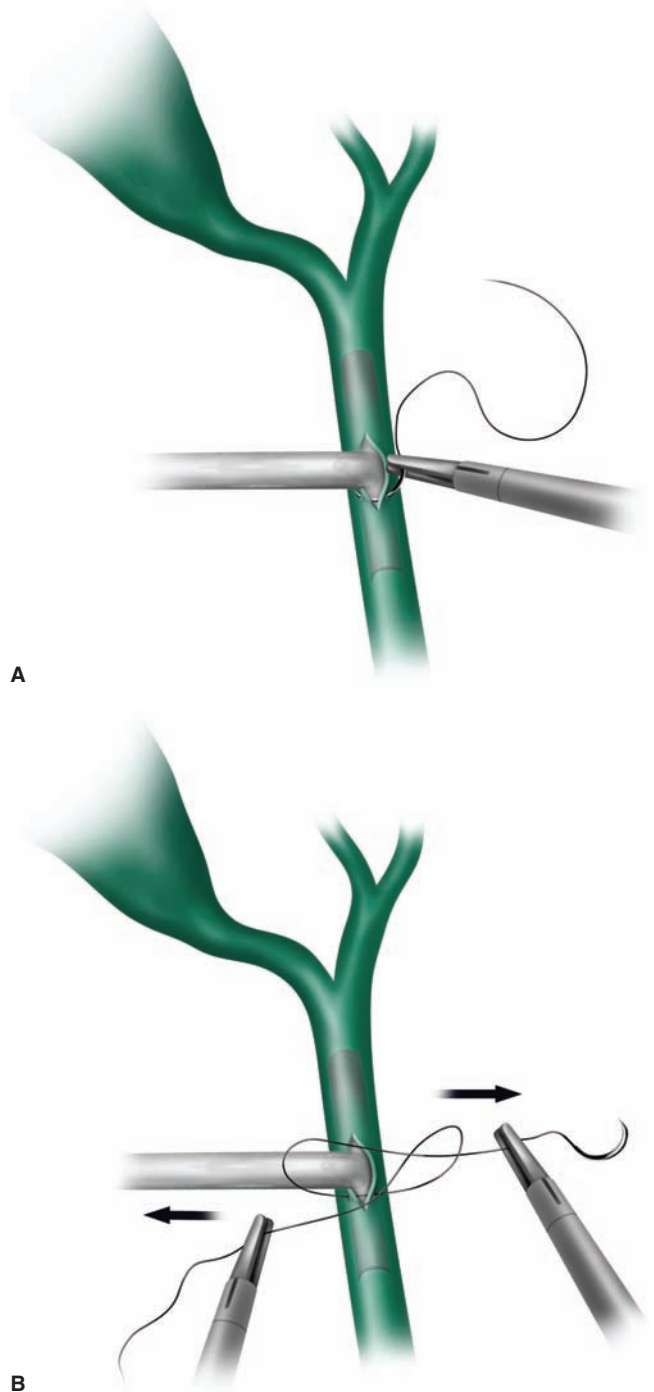
Filleted tubes are easier to insert. A long and short segment allow for orientation when inserted into the peritoneum and then again when inserted in the bile duct. Also, the point of entry in the abdomen to the point of entry into the duct should follow a smooth curvilinear route. The standard trocar sites do not usually allow for this and as such a separate stab incision should be used when the tube is brought out. The T-tube is fully inserted into the abdomen, the horizontal limbs are compressed with a grasper and inserted into the CBD. The choledochotomy is then closed over the long end of the T-tube, beginning at the neck and working caudally using interrupted 4-0 absorbable suture. Intracorporeal suturing is used to accomplish this (Fig. 52-7). The tube is then brought out lateral to the CBD and out of the abdomen at a suitable location keeping to the principles highlighted above. A complete cholangiogram is recommended to ensure correct tube placement. A subhepatic closed suction drainage is then inserted and removed if there is no bile leakage around the T-tube.

## LAPAROSCOPIC BILIARY TRACT RESECTION AND RECONSTRUCTION

Laparoscopic biliary tract resection and reconstruction is not currently widely applied because it is technically challenging even in an open setting. In addition, there are alternatives to surgery such as endoscopic placement of biliary stents or percutaneous placements of transhepatic biliary drains for biliary obstruction. Nonetheless, laparoscopic cholecystojejunostomy, choledochoduodenostomy, hepaticojejunostomy, and choledochal cyst excision have been successfully performed in the hands of experienced laparoscopic surgeons.<sup>22-27</sup> Surgical biliary bypass to relieve malignant obstructive jaundice requires the morbidity of an operation whether it is minimally invasive or open. While minimally invasive surgery allows for less postoperative pain and more expedient recovery, the inherent risks of general anesthesia and surgical stress remain. In light of this, endoscopic stenting has gained utility especially in the palliative setting. The success of endoscopic techniques, such as stenting and sphincterotomy, in the management of malignant biliary obstruction is well documented.<sup>28</sup> However, recurrent jaundice and cholangitis from stent obstruction or migration necessitate changing of the stents and add to the overall morbidity and cost. Newer, self-expanding metallic wall stents have had less frequent rates of occlusion.<sup>29</sup> Nonetheless, patients who are younger, healthier, who might have increased survival (>6 months) or for those whom endoscopic biliary stenting is not technically possible, will be better served by a surgical biliary bypass. For benign disease, endoscopic management is not indicated as it does not achieve the long-term patency that is desirable for the treatment of benign disease. Thus, surgical biliary bypass will continue to be a valid treatment option.

While the enthusiasm for laparoscopy has extended to complex biliary procedures, it is important to keep in mind

that indications and patient selection for biliary bypass do not change with the laparoscopic modality. In fact, the technical considerations often limit rather than broaden the patient selection. Furthermore, fundamental laparoscopic principles that contraindicate its use or require discontinuation and



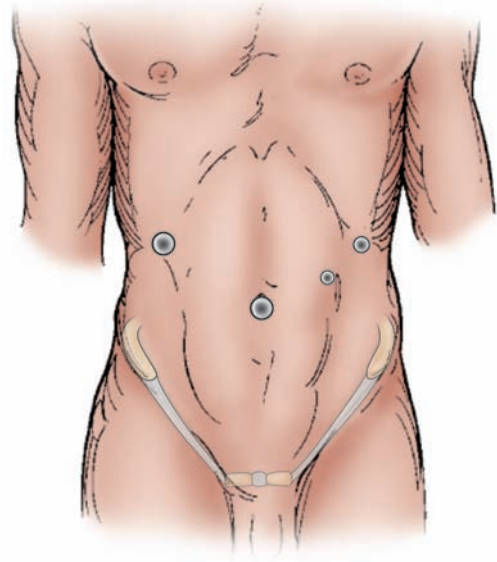
**FIGURE 52-7** T-tube being secured in place following CBD exploration via a choledochotomy. A Vicryl/Polysorb or Maxon/polydioxanone (PDS) suture may be used to secure the T-tube. Vicryl/Polysorb may be a better option if the T-tube is to be removed within 3 weeks.

conversion to an open procedure should always be kept in mind. It should also be emphasized that standard, accepted procedures should not have to be significantly modified to make them easier to perform in the laparoscopic setting. Conversion to an open procedure should be utilized if the goals of the operation cannot be accomplished safely through the laparoscopic technique.

## Laparoscopic Cholecystojejunostomy

Laparoscopic cholecystojejunostomy is a safe, effective method of palliation for biliary obstruction.<sup>1</sup> It is relatively easy to perform when keeping with standard laparoscopic principles and can be accomplished in 45–60 minutes.<sup>1,30</sup> In patients with prior surgery and small bowel adhesions, adhesiolysis may be required to ensure that there is no tension or twisting of the bowel loop that will be utilized in the anastomosis. It should also be noted that postoperative episodes of cholangitis are more frequent with cholecystoenteric bypass when compared to other biliary-enteric bypasses.<sup>31</sup> Despite the limitations, it continues to be worthwhile in select patients.

In all instances, cholangiography, either intraoperatively or preoperatively via ERCP, should be performed to confirm the patency of the cystic duct and hepatocystic junction. This step is imperative since obstruction of either the cystic duct or hepatocystic junction will result in failure of the operation with recurrent biliary obstruction. Tumor encroachment within 1 cm of the hepatocystic junction is also a contraindication for cholecystojejunostomy. Table 52-3 lists the relative and absolute contraindications for a laparoscopic cholecystojejunostomy. A retrospective review of 218 patients from our institution revealed that only about 20% of patients that are candidates for a laparoscopic cholecystojejunostomy actually remain eligible after further testing.<sup>22,32</sup> Thus, this procedure is indicated for only a minority of patients. The relative ease with which it can be performed and the palliative function



**FIGURE 52-8** Port placement for laparoscopic cholecystojejunostomy. A Hasson technique (through the umbilicus) or a Veress needle technique (through the left upper quadrant) can be employed for entry. Two 5-mm ports are placed on the left hemiabdomen and an 11-mm port placed in the right upper quadrant.

that is provided without the associated morbidities of an open operation make it a valuable option in carefully selected patients.

The patient is placed supine and general endotracheal anesthesia is induced. See Fig. 52-8 for the location of the port placement.

1. Confirm the patency of the cystic duct if it has not been done by ERCP preoperatively. This can be accomplished by grasping the gallbladder and needle decompressing until it is at least half-emptied. The gallbladder is then cannulated and contrast injected under fluoroscopy. The procedure should not commence if the cystic duct is occluded or if the hepatocystic duct junction is strictured from tumor involvement.
2. Next, a suitable loop of small bowel is grasped using atraumatic graspers and the small bowel is run 30–40 cm distal to the ligament of Treitz. This segment of small bowel is transposed to the right upper quadrant (antecolic) and placed adjacent to the fundus of the gallbladder in a parallel orientation (Fig. 52-9A). Sometimes the body habitus or positioning makes alignment of the bowel and gallbladder difficult. In these circumstances, the setup for this anastomosis may be facilitated by passing a 3-0 nylon suture on a Keith needle through a separate stab incision in the right upper quadrant. The needle is expeditiously grasped once inside the peritoneal cavity to prevent inadvertent visceral injury. The needle is then passed through the gallbladder and then the anti-mesenteric side of the jejunum. The needle is then passed back out of the peritoneal cavity and secured extracorporeally. This suture will help manipulate the bowel and gallbladder during stapling.



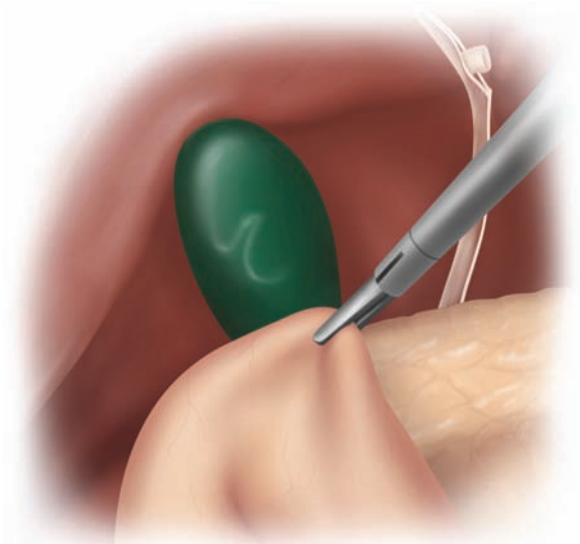
### TABLE 52-3: CONTRAINDICATIONS FOR LAPAROSCOPIC CHOLECYSTOJEJUNOSTOMY

#### Absolute

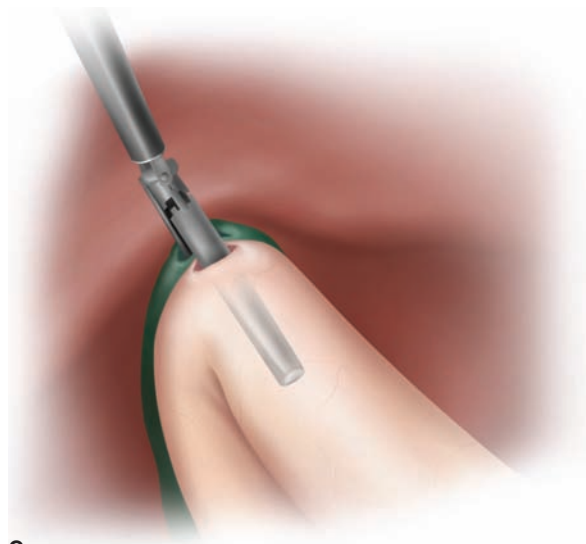
- Prior cholecystectomy
- Occluded cystic duct
- Occluded hepatocystic junction
- Hilar malignancy
- Tumor encroachment within 1 cm of hepatocystic junction

#### Relative

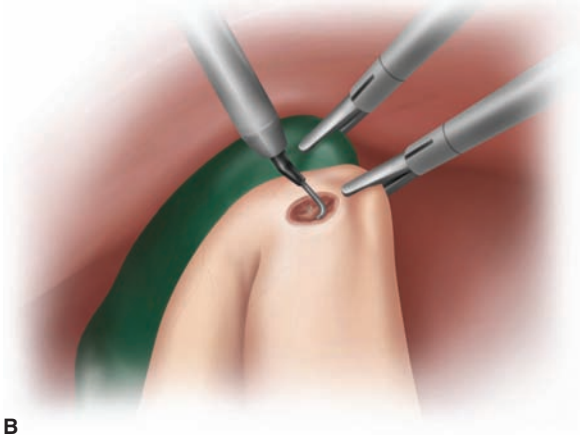
- Prior biliary surgery
- Tumor encroachment within 2 cm of hepatocystic junction
- Chronic inflammation or cholecystitis
- Tumor involvement of the small bowel
- Multiple small bowel adhesions



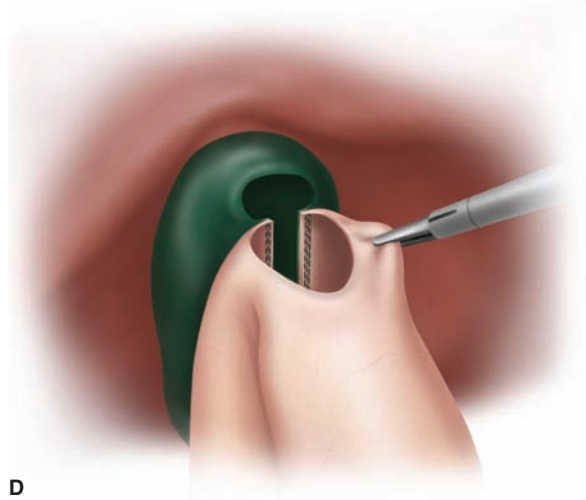
A



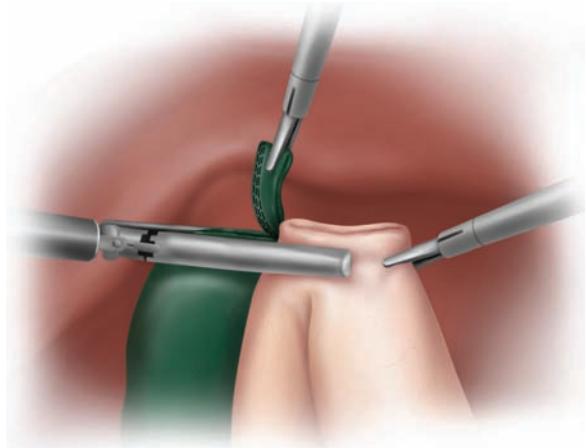
C



B



D



E

**FIGURE 52-9** **A.** A portion of small bowel at 30–40 cm beyond the ligament of Treitz is grasped and brought up antecolic to the gallbladder fundus. **B.** A 5-mm hook-type cautery device placed through the 11-mm right upper quadrant port is used to create a 5-mm opening in the antimesenteric portion of the small bowel. **C.** An endoscopic stapler is placed through the 11-mm right upper quadrant port. Each blade of the stapler is carefully inserted into the enterotomy and cholecystotomy, respectively. The stapler is closed and fired after proper position and freedom from surrounding structures is assured. **D.** Careful inspection of the anastomosis for integrity and hemostasis. **E.** The remaining defect is closed by transverse stapling of the anastomotic site taking care not to narrow the anastomosis.



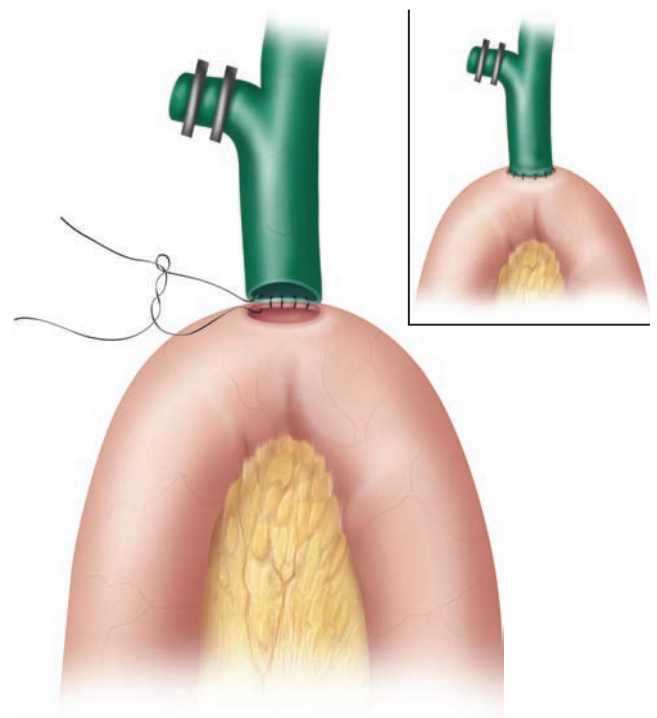
3. An enterotomy and cholecystotomy are then made in the bowel and the gallbladder, respectively, using the hook-cautery device passed through the right upper quadrant 11-mm port (Fig. 52-9B). The opening should be as small as possible and a grasper can then be used to enlarge the track to permit the end of the laparoscopic stapling device to be placed through without difficulty. Confirmation of intraluminal penetrance is confirmed by placing a grasper through the enterotomy and visualizing mucosa.
4. The enterotomies are then held in apposition using the left-sided ports. Once these left-sided graspers have been placed, they should not be moved until the stapler is fired. We use a Endo GIA-30 2.5 mm laparoscopic stapler (Covidien, Norwalk, CT) for our anastomosis. The stapler is placed through the right upper quadrant 12-mm port. One blade of the stapler is inserted in the cholecystotomy. The enterotomy is then pulled over the second (lower) blade. The stapler is carefully closed making sure that no small bowel mesentery or adjacent structures have been caught. The stapler is fired and removed (Fig. 52-9C).
5. The graspers are then used to open the anastomosis to permit inspection of the staple line for integrity and hemostasis (Fig. 52-9D). Clips may be utilized for hemostasis.
6. The enterocholecystostomy is closed by transverse stapling of the anastomotic site taking care not to narrow the cholecystojejunostomy. This usually requires sequential firing of at least two Endo GIA staplers.
7. Finally, the stay suture is removed and the anastomosis is inspected. Placement of a drain is not necessary.

A completely hand-sewn anastomosis can also be performed. The operative time for this is usually significantly greater and the patency and complication rates are not significantly different.<sup>26,32</sup> Hence, our bias is to perform the faster stapled anastomosis. Another variant is to staple the anastomosis between the bowel and gallbladder and then close the enterocholecystostomy with a running intracorporeal stitch using 3-0 absorbable suture. This may be useful in instances in which the stapler cannot be configured to prevent narrowing of the newly created anastomosis during closure of the defect. Another variant is to use a Roux-en-Y reconstruction rather than a loop reconstruction.

## Laparoscopic Choledochoduodenostomy and Hepaticojejunostomy

The gold standard for open biliary bypass is choledochoduodenostomy or the more commonly utilized Roux-en-Y hepaticojejunostomy. As stated previously, many patients are ineligible for the cholecystojejunostomy. In an effort to increase the number of patients qualifying for laparoscopic biliary bypass, laparoscopic choledochoduodenostomy and hepaticojejunostomy have been investigated and successfully performed. Furthermore, these two procedures are preferred over cholecystojejunostomy in patients with benign diseases such as choledocholithiasis, inflammatory

strictures, or iatrogenic bile duct injuries since they have a better long-term patency rate. These procedures are considered highly advanced laparoscopic procedures and take a significant amount of time to perform. Median operative time in the hands of a skilled minimally invasive surgeon is 300 minutes compared to the open median time of 180 minutes.<sup>26,33-35</sup> Advancements in surgical technology have aided surgeons to reduce the operative time. Lapra-TY (Ethicon), Surgitie (Covidien), and Endo-Stitch (Covidien) facilitate intracorporeal suturing. The temporarily endoluminally stented anastomosis (TESA) technology has been used in animal models to assist in anastomosis creation.<sup>27,35</sup> The basic principles remain the same, but certain variances have been adopted for successful laparoscopic performance. For instance, a transverse choledochotomy rather than the traditional longitudinal has been used for a laparoscopic choledochoduodenostomy. If a transverse choledochotomy is made, care must be taken to avoid devascularizing the bile duct as the blood supply runs parallel to the duct at the lateral and medial aspects of the duct. For a choledochoduodenostomy, the duodenum is longitudinally incised following a Kocher maneuver and a side-to-side anastomosis is created using a 4-0 polyglycolic acid suture (Fig. 52-10). Roux-en-Y hepaticojejunostomy are beginning to be performed at a few centers with a moderate amount of success being reported.<sup>33-35</sup> In one series of 14 patients who underwent laparoscopic hepaticojejunostomy, the median operative time was 129



**FIGURE 52-10** Laparoscopic choledochoduodenostomy created by placement of interrupted 4-0 absorbable sutures with intracorporeal knot tying technique.

minutes. However, the median hospital stay was 9 days.<sup>36</sup> Further studies are needed to determine the value of these more complex biliary bypasses.

## Laparoscopic Choledochal Cyst Excision

Choledochal cyst is a congenital disease which results in dilatation of the intra- and/or extrahepatic biliary tract. This condition is rare in the United States (incidence 1:100,000–2,000,000 live birth), but is more prevalent in Asia. The etiology of the disease is unknown. Most patients are diagnosed during their first year of life, but the diagnosis may be delayed into their adulthood since it may not cause any symptoms until then. Common signs or symptoms are right upper quadrant pain or mass, jaundice, and/or cholangitis. Even if they are asymptomatic, treatment is indicated because it carries a 9–28% lifetime risk of malignant degeneration into cholangiocarcinoma and the cyst may be harboring cancer at the time of diagnosis. There are five types of choledochal cysts and their surgical treatment differs based on their anatomic differences (Table 52-4). Type I is the most common type and these can be treated with a CBD excision of the involved segment. Reconstruction is performed with a Roux-en-Y hepaticojejunostomy and excellent long-term results can be achieved. Excision of the CBD does not eliminate the risk of malignant degeneration since the entire biliary tree is at risk. Thus, some hepatobiliary surgeons leave a small cuff of dilated bile duct on the proximal (liver) side so it would be easier to sew the hepaticojejunostomy anastomosis. Minimally invasive approach is an interest in this particular field since a majority of these patients are children. Decreased postoperative pain and faster recovery time may translate into limiting their absence from school and other activities important to their development. It is also more cosmetically appealing.

To date, laparoscopic excision of choledochal cysts and subsequent reconstruction have only been described in case reports or series in the pediatric population.<sup>37–40</sup> The largest pediatric series reported nine patients, however, the hepaticojejunostomy anastomosis was performed extracorporeally.<sup>39</sup> In a series of 12 adult patients, the mean operative time for excision and a Roux-en-Y reconstruction was 228 minutes with an average length of hospital stay of 5.8 days. In addition, they reported no mortalities nor anastomotic complications.<sup>41</sup> Under laparoscopic guidance, the enlarged bile duct and gallbladder (if present) are excised. End-to-side biliary-enteric anastomosis is created with a continuous suture and the jejunostomy can be accomplished with a circular or linear stapler.

The advantages of the laparoscopic approach for the management of choledochal cysts are the magnified view afforded by the laparoscope and the potential advantage of less pain and faster recovery. However, the lengthy operative time, the cost of advanced laparoscopic instruments to facilitate laparoscopic performance, and the absence of long-term outcome data are considerable disadvantages. Currently, the laparoscopic management of choledochal cysts will be practiced in centers specialized in minimally invasive hepatobiliary surgery. More studies and refinements in the instruments available are needed to address the disadvantages of this approach.

## CONCLUSION

The application of minimally invasive surgery continues to evolve and is developing at a rapid pace. The success rate for removing stones among accomplished minimally invasive surgeons exceeds 90%. Unfortunately, most surgeons do not currently use a laparoscopic approach to the treatment of CBD stones. This presents significant costs (nearly double) to the patient and the health care system. However, as



**TABLE 52-4: CLASSIFICATION AND THE SURGICAL TREATMENT OF CHOLEDOCHAL CYSTS**

Type	Description	Surgical Treatment
I	Dilation of the extrahepatic biliary tree (choledochal cyst); the most common type (50–85% of cases)	Excision of the extrahepatic bile duct and Roux-en-Y hepaticojejunostomy
II	Simple diverticulum of extrahepatic biliary tree (supraduodenal CBD diverticulum)	Resection of the diverticulum and the resultant defect closed over a T-tube
III	Dilation of the intraduodenal extrahepatic biliary tree (choledochocele)	Transduodenal excision with sphincterotomy
IVa	Dilation of intra- and extrahepatic biliary tree; the second most common type	Excision of the extrahepatic bile duct and Roux-en-Y hepaticojejunostomy; the intrahepatic segment is left alone unless it becomes symptomatic (can be managed with partial liver resection if it only involves the right or left hemiliver)
IVb	Multiple dilations of the extrahepatic biliary tree	Right or left hepatectomy (if it only involves the right or left hemiliver); liver transplantation (if it involves both sides)
V	Intrahepatic biliary cyst (Caroli's disease)	Right or left hepatectomy (if it only involves the right or left hemiliver); liver transplantation (if it involves both sides)

laparoscopy becomes a more commonplace in surgical practice, the increased cost will be mitigated and the immediate benefits of earlier recovery from laparoscopic surgery will be emphasized. Currently, institutions with hepatobiliary surgeons usually have gastroenterologists who perform ERCPs, thus, it is not mandatory for hepatobiliary surgeons to have the skill sets to laparoscopically treat benign biliary tract pathology in one setting. Nevertheless, laparoscopic management of choledocholithiasis will be a valuable armamentarium for the surgeon to have and can be used as a stepping stone for more advanced laparoscopic biliary tract procedures.

Laparoscopic biliary reconstruction is feasible, but it demands long operative times and requires advanced laparoscopic skills as well as significant experience in hepatobiliary surgery. Nevertheless, with careful patient selection as well as a low threshold for conversion to an open approach, certain biliary reconstruction and resection procedures can be completed laparoscopically. The cholecystojejunostomy provides satisfactory biliary bypass in carefully selected patients and is readily accomplished through the minimally invasive technique. Further studies are necessary to accurately determine the long-term patency rates and the utility of more complex laparoscopic biliary-enteric reconstructions.

## REFERENCES

- Pappas TN, Chekan EG, Eubanks S. *Atlas of Laparoscopic Surgery*. 3rd ed. Philadelphia, PA: Current Medicine Group; 2007.
- Metcalfe MS, et al. Is laparoscopic intraoperative cholangiogram a matter of routine? *Am J Surg*. 2004;187(4):475–481.
- Collins C, et al. A prospective study of common bile duct calculi in patients undergoing laparoscopic cholecystectomy: natural history of choledocholithiasis revisited. *Ann Surg*. 2004;239(1):28–33.
- Nickkholgh A, Soltaniyekta S, Kalbasi H. Routine versus selective intraoperative cholangiography during laparoscopic cholecystectomy: a survey of 2,130 patients undergoing laparoscopic cholecystectomy. *Surg Endosc*. 2006;20(6):868–874.
- The Southern Surgeons Club. A prospective analysis of 1518 laparoscopic cholecystectomies. *N Engl J Med*. 1991;324(16):1073–1078.
- Dorazio RA. Selective operative cholangiography in laparoscopic cholecystectomy. *Am Surg*. 1995;61(10):911–913.
- Rhodes M, et al. Randomised trial of laparoscopic exploration of common bile duct versus postoperative endoscopic retrograde cholangiography for common bile duct stones. *Lancet*. 1998;351(9097):159–161.
- Lai EC, et al. The evolving influence of laparoscopy and laparoscopic ultrasonography on patients with hepatocellular carcinoma. *Am J Surg*. 2008;196(5):736–740.
- Santambrogio R, et al. Impact of intraoperative ultrasonography in laparoscopic liver surgery. *Surg Endosc*. 2007;21(2):181–188.
- Urbach DR, et al. Cost-effective management of common bile duct stones: a decision analysis of the use of endoscopic retrograde cholangiopancreatography (ERCP), intraoperative cholangiography, and laparoscopic bile duct exploration. *Surg Endosc*. 2001;15(1):4–13.
- Barkun JS, et al. Cholecystectomy without operative cholangiography. Implications for common bile duct injury and retained common bile duct stones. *Ann Surg*. 1993;218(3):371–377; discussion 377–379.
- Sugiyama M, Atomi Y. Endoscopic ultrasonography for diagnosing choledocholithiasis: a prospective comparative study with ultrasonography and computed tomography. *Gastrointest Endosc*. 1997;45(2):143–146.
- Ammori BJ, et al. Routine vs “on demand” postoperative ERCP for small bile duct calculi detected at intraoperative cholangiography. Clinical evaluation and cost analysis. *Surg Endosc*. 2000;14(12):1123–1126.
- Vezakis A, et al. Intraoperative cholangiography during laparoscopic cholecystectomy. *Surg Endosc*. 2000;14(12):1118–1122.
- Erickson RA, Carlson B. The role of endoscopic retrograde cholangiopancreatography in patients with laparoscopic cholecystectomies. *Gastroenterology*. 1995;109(1):252–263.
- Phillips EH, et al. Laparoscopic trans-cystic-duct common-bile-duct exploration. *Surg Endosc*. 1994;8(12):1389–1393; discussion 1393–1394.
- Appel S, Krebs H, Fern D. Techniques for laparoscopic cholangiography and removal of common duct stones. *Surg Endosc*. 1992;6(3):134–137.
- Tse F, Barkun JS, Barkun AN. The elective evaluation of patients with suspected choledocholithiasis undergoing laparoscopic cholecystectomy. *Gastrointest Endosc*. 2004;60(3):437–448.
- Petelin JB. Laparoscopic approach to common duct pathology. *Am J Surg*. 1993;165(4):487–491.
- Fletcher DR. Common bile duct calculi at laparoscopic cholecystectomy: a technique for management. *Aust N Z J Surg*. 1993;63(9):710–714.
- Lezoche E, et al. Laparoscopic treatment of gallbladder and common bile duct stones: a prospective study. *World J Surg*. 1996;20(5):535–541; discussion 542.
- Chekan EG, et al. Laparoscopic biliary and enteric bypass. *Semin Surg Oncol*. 1999;16(4):313–320.
- Fitzgibbons RJ, Jr., Gardner GC. Laparoscopic surgery and the common bile duct. *World J Surg*. 2001;25(10):1317–1324.
- Gentileschi P, Kini S, Gagner M. Palliative laparoscopic hepatic- and gastrojejunostomy for advanced pancreatic cancer. *JLS*. 2002;6(4):331–338.
- Jeyapalan M, et al. Laparoscopic choledochoduodenostomy: review of a 4-year experience with an uncommon problem. *Surg Laparosc Endosc Percutan Tech*. 2002;12(3):148–153.
- O'Rourke RW, et al. Laparoscopic biliary reconstruction. *Am J Surg*. 2004;187(5):621–624.
- Schob OM, et al. Laparoscopic Roux-en-Y choledochojejunostomy. *Am J Surg*. 1997;173(4):312–319.
- Giorgio PD, Luca LD. Comparison of treatment outcomes between biliary plastic stent placements with and without endoscopic sphincterotomy for inoperable malignant common bile duct obstruction. *World J Gastroenterol*. 2004;10(8):1212–1214.
- Isayama H, et al. A prospective randomised study of “covered” versus “uncovered” diamond stents for the management of distal malignant biliary obstruction. *Gut*. 2004;53(5):729–734.
- Raj PK, Mahoney P, Linderman C. Laparoscopic cholecystojejunostomy: a technical application in unresectable biliary obstruction. *J Laparoendosc Adv Surg Tech A*. 1997;7(1):47–52.
- Potts JR, 3rd, Broughan TA, Hermann RE. Palliative operations for pancreatic carcinoma. *Am J Surg*. 1990;159(1):72–77; discussion 77–78.
- Tarnasky PR, et al. Cystic duct patency in malignant obstructive jaundice. An ERCP-based study relevant to the role of laparoscopic cholecystojejunostomy. *Ann Surg*. 1995;221(3):265–271.
- Ali AS, Ammori BJ. Concomitant laparoscopic gastric and biliary bypass and bilateral thoracoscopic splachnotomy: the full package of minimally invasive palliation for pancreatic cancer. *Surg Endosc*. 2003;17(12):2028–2031.
- Date RS, Siriwardena AK. Laparoscopic biliary bypass and current management algorithms for the palliation of malignant obstructive jaundice. *Ann Surg Oncol*. 2004;11(9):815–817.
- Zucker KA. *Surgical Laparoscopy*. 2nd ed. Philadelphia, PA: Lippincott Williams & Wilkins; 2001.
- Rothlin MA, Schob O, Weber M. Laparoscopic gastro- and hepaticojejunostomy for palliation of pancreatic cancer: a case controlled study. *Surg Endosc*. 1999;13(11):1065–1069.
- Chokshi NK, et al. Laparoscopic choledochal cyst excision: lessons learned in our experience. *J Laparoendosc Adv Surg Tech A*. 2009;19(1): 87–91.
- Liu DC, et al. Laparoscopic excision of a rare type II choledochal cyst: case report and review of the literature. *J Pediatr Surg*. 2000;35(7): 1117–1119.
- Liu SL, et al. Laparoscopic excision of choledochal cyst and Roux-en-Y hepaticojejunostomy in symptomatic neonates. *J Pediatr Surg*. 2009; 44(3):508–511.
- Tan HL, Shankar KR, Ford WD. Laparoscopic resection of type I choledochal cyst. *Surg Endosc*. 2003;17(9):1495.
- Jang JY, et al. Totally laparoscopic management of choledochal cysts using a four-hole method. *Surg Endosc*. 2006;20(11):1762–1765.



# PERSPECTIVE ON BILIARY SURGERY

*Douglas W. Hanto*

## LAPAROSCOPIC CHOLECYSTECTOMY AND BILE DUCT INJURIES

There is little question that laparoscopic surgery in general surgery has had the greatest impact in the treatment of cholelithiasis and cholecystitis with over 80% of cholecystectomies being performed laparoscopically and laparoscopic cholecystectomy being one of the most common general surgical procedures performed. Although laparoscopic cholecystectomy has led to more frequent surgical treatment of gallbladder disease and a reduction in postoperative pain and hospital stay, as well as earlier return of bowel function and full activity, and decreased cost, it has not led to a reduction in the incidence of common bile duct (CBD) injuries. The most recent data cite an estimated incidence of 0.4–1.3% bile duct injuries after laparoscopic cholecystectomy compared to 0.2% after open cholecystectomy with significant patient morbidity and a high risk of litigation.<sup>1,2</sup> It has always seemed odd that, faced with a bile duct injury, no more than 15% of surgeons refer these patients to subspecialty hepatobiliary surgeons for repair.<sup>3</sup> The risk of bile duct injury had been thought to be greater earlier in a surgeon's experience with a 1.7% incidence of bile duct injury in the first case and a 0.17% chance of bile duct injury in the 50th case.<sup>4</sup> However, other studies have shown that there is no reduction in risk as surgeons do more cases.<sup>2,5</sup>

Anatomic variability is common in the biliary tree and methods to reduce the incidence of bile duct injury have included routine cholangiography, identifying the boundaries of Calot's triangle, and identifying the "critical view,"<sup>6</sup> all appropriately emphasized by Auyang and Soper.<sup>1</sup> However, it has been my practice to emphasize to the residents to "stay on the gallbladder, stay on the gall bladder, and stay on the gosh darn gallbladder" as the most effective way to avoid injury to either the CBD or right hepatic artery. This prevents transection of the CBD and, if adhered to as the gallbladder is dissected free of the gallbladder fossa adjacent to the porta hepatis medially, will prevent injury to a low-lying right or right posterior hepatic duct. If this is not easily accomplished due to acute cholecystitis or other

abnormalities, consideration should be given to converting to an open procedure. This principle still holds true for an open cholecystectomy as well. Late conversion is often associated with bile duct injuries. Although cystic duct leaks, transection or clipping (partial or complete) of the CBD or common hepatic duct have been the most commonly described injuries; increasingly we are seeing injuries to the right hepatic duct or right posterior hepatic duct which may be difficult to characterize as they are not in communication with the common duct and may be missed on endoscopic retrograde cholangiopancreatography (ERCP).<sup>7</sup> Only with percutaneous transhepatic cholangiography (PTC) or injection of a subhepatic drain, along with a high index of suspicion, will they be identified.

## Choledocholithiasis

Because most patients with suspected choledocholithiasis undergo preoperative ERCP, there are fewer laparoscopic surgeons who have extensive experience or are comfortable with laparoscopic CBD exploration and stone extraction. In addition, as Yoo and Pappas<sup>8</sup> point out, the success rate of ERCP in clearing CBD stones is 90–95% compared to a laparoscopic success rate of 70–90%. di Carlo and McFadden<sup>9</sup> point out there are many adjunctive procedures that can be used to extract and break up stones endoscopically including the use of a Dormia basket, mechanical lithotripsy, and intraductal shock wave lithotripsy using a cholangioscope. The method of choice will depend on the expertise available and the specific patient circumstances.

However, because of the known complications of ERCP, particularly pancreatitis and cholangitis, and a relatively high incidence of negative ERCPs, it is important to try preoperatively to identify the presence of choledocholithiasis non-invasively which can best be done with magnetic resonance cholangiopancreatography (MRCP) or endoscopic ultrasound (EUS) with a high degree of specificity and sensitivity.<sup>9</sup> Patients with a positive MRCP or EUS can then be treated appropriately with laparoscopic CBD exploration or ERCP, and the

number of negative ERCPs reduced. ERCP or intraoperative cholangiography remain, however, the diagnostic gold standards and are still indicated in clinical situations where the suspicion for choledocholithiasis is high and the MRCP or EUS is negative. PTC can be used in patients in whom anatomic considerations preclude the performance of an ERCP.

Patients who are found to have stones following cholecystectomy are usually treated with ERCP; PTC or operative exploration may be indicated if the CBD cannot be accessed endoscopically. The need for surgical drainage procedures such as Roux-en-Y hepaticojejunostomy for recurrent CBD stones has been almost eliminated by the other noninvasive techniques for stone removal. Choledochoduodenostomy should be avoided if possible because of a higher incidence of obstruction, cholangitis, and anastomotic strictures. Patients with intrahepatic stones and strictures are best managed with surgical resection in order to rule out malignancy and because of a lower incidence of recurrent stones.<sup>10</sup>

## Choledochal Cysts

Parikh and Lillemo<sup>2</sup> have emphasized the association between type I and type IV choledochal cysts and cholangiocarcinoma and the importance of complete cyst excision and reconstruction with a Roux-en-Y hepaticojejunostomy. The association with type II and type III (choledochoceles) is less clear, but adult patients still often present with jaundice, cholangitis, or pancreatitis and these cysts should also be resected. An important diagnostic tool in patients with choledochal cysts is biliary cytology, but the authors do not describe the potential screening value of the tumor-associated antigen CA19-9,<sup>11</sup> that has also been shown to be useful in patients with primary sclerosing cholangitis who are at risk for developing cholangiocarcinoma. The fluorescence in situ hybridization (FISH) cytological test is a new screening tool that holds additional promise for early identification of cholangiocarcinoma.<sup>12</sup> The authors note that unilobar Caroli's disease (type V) should be managed with hepatic resection because of the risk of cholangiocarcinoma and this has been pointed out to be true in children as well where they are often seen in association with type I or type IV choledochal cysts and concomitant cyst excision and lobectomy should be performed.

In the authors' discussion of bile leaks after laparoscopic cholecystectomy, they note that hepatobiliary iminodiacetic acid (HIDA) scans are not sensitive enough to identify the source of the leak. However, in a patient with a suspected bile duct injury, the HIDA scan can help in determining whether the patient should undergo an ERCP or PTC. If the HIDA scan shows the radionuclide passing into the duodenum, then an ERCP would be the appropriate initial diagnostic test, whereas if no radionuclide passes into the duodenum the most appropriate initial study would be a PTC since the ERCP would likely only show an obstructed, clipped, or transected duct. The role of injecting a subhepatic drain, placed to drain a biloma, in diagnosing the

source of leak cannot be overemphasized if the PTC or ERCP do not show the source of the leak. Drain injection can demonstrate a transected right posterior duct that is not in communication with the CBD. Finally, the authors suggest for waiting 6–8 weeks after drainage to proceed with repair. My practice has been to wait about 2 weeks after drainage from above (PTC) and below (CT or ultrasound-guided drainage) before proceeding with Roux-en-Y hepaticojejunostomy which provides more than adequate time for the inflammatory process to abate and permits safe repair. I also leave the transhepatic catheter in place for 3 months, obtaining a cholangiogram at 5 days, 1 month, and 3 months.

The authors argue that the management of recurrent pyogenic cholangitis involves primarily treating biliary strictures with biliary drainage utilizing a Roux-en-Y hepaticojejunostomy. However, just as with percutaneous or endoscopic management, drainage procedures are associated with a high risk of recurrence and hepatic resection of unilobar disease is curative and is the treatment of choice.<sup>10</sup>

## Gallbladder Carcinoma and Cholangiocarcinoma

Whang et al<sup>13</sup> point out the important changes in the tumor, node, metastasis (TNM) staging system for gallbladder carcinoma that reflect data showing differences in survival in patients with N1 (metastasis to cystic duct, CBD, hepatic artery, and/or portal vein lymph nodes) or N2 (metastasis to periaortic, pericaval, superior mesenteric, and/or celiac artery lymph node) nodal disease and in patients with locally unresectable T4 malignancies. Incidentally found gallbladder carcinoma with invasion into the muscularis is not uncommon and requires gallbladder fossa (segment V) resection, portal lymph node dissection, and possible CBD resection with Roux-en-Y hepaticojejunostomy if the cystic duct margin is positive.

In the discussion of tumor markers the authors indicate that CA19-9 is not sensitive or specific enough to be applicable for screening or diagnosis in the general population, which is to a degree true, but in patients with risk factors for the development of cholangiocarcinoma, for example primary sclerosing cholangitis (PSC), it can be useful, especially when combined with ERCP, EUS, and cytology or the newer FISH assay for detecting early malignancy.<sup>12</sup> In patients where CA19-9 has been elevated it can be followed as a useful marker for recurrence postresection. Sadly, imaging of cholangiocarcinoma is still not able to separate unresectable from resectable tumors reliably compared to imaging in pancreatic cancer and usually underestimates the degree of disease, which is why the resection rate is still so low. Preoperatively placed percutaneous transhepatic catheters can be helpful in determining the extent of involvement of the left and right hepatic ducts and guide the surgeon as to which liver lobe to resect to facilitate negative margins on the opposite side (>75% of hilar cholangiocarcinoma resections include a concomitant hepatic resection).<sup>14</sup>

## Laparoscopic Procedures

Yoo and Pappas<sup>15</sup> discuss the controversy around the utility of routine versus selective intraoperative cholangiography and suggest that it is probably not cost-effective for the number of significant common duct stones identified that need removal (most small stones will pass spontaneously) and whether it prevents common duct injuries remains controversial. I use the selective approach and perform intraoperative cholangiography if the anatomy is unusual or confusing or if there is a clinical indication (eg, elevated liver function tests [LFTs] or preoperative imaging that suggests common duct stones). Their review of laparoscopic procedures illustrates the many options available to surgeons and patients for laparoscopy in biliary surgery, but also points out the difficulties of some of these procedures and the need for advanced training and acquisition of the necessary skills to optimize patient care. These advanced procedures (eg, Roux-en-Y hepaticojejunostomy) still take much longer than their open counterparts and provide marginal patient benefit at this time, but this may change over time as surgeons, techniques, and equipment all improve.

## REFERENCES

1. Auyang ED, Soper NJ. Cholecystitis and cholelithiasis. In: Zinner MJ, Ashley SW, eds. *Maingot's Abdominal Operations*. 12th ed. New York, NY: McGraw-Hill; 2011 (in press).
2. Parikh PY, Lillemoe KD. Choledochal cyst and benign biliary strictures. In: Zinner MJ, Ashley SW, eds. *Maingot's Abdominal Operations*. 12th ed. New York, NY: McGraw-Hill; 2011 (in press).
3. Archer SB, Brown DW, Smith CD, Branus GD, Hunter JG. Bile duct injury during laparoscopic cholecystectomy: results of a national survey. *Ann Surg*. 2001;234:549–558; discussion 558–559.
4. Moore MJ, Bennett CL. The learning curve for laparoscopic cholecystectomy. The Southern Surgeons Club. *Am J Surg*. 1995;170:55–59.
5. Wherry DC, Marohn MR, Malanoski MP, Hetz SP, Rich NM. An external audit of laparoscopic cholecystectomy in the steady state performed in medical treatment facilities of the Department of Defense. *Ann Surg*. 1996;224:145–154.
6. Strasberg SM, Hertl M, Soper NJ. An analysis of the problem of biliary injury during laparoscopic cholecystectomy. *J Am Coll Surg*. 1995;180:101–125.
7. Lillemoe, KD, Petrofski JA, Choti MA, Venbrux AC, Cameron JL. Isolated right segmental hepatic duct injury: a diagnostic and therapeutic challenge. *J Gastrointest Surg*. 2000;4:168–177.
8. Yoo JS, Pappas TN. Laparoscopic biliary procedures. In: Zinner MJ, Ashley SW, eds. *Maingot's Abdominal Operations*. 12th ed. New York, NY: McGraw-Hill; 2011 (in press).
9. di Carlo A, McFadden DW. Choledocholithiasis and cholangitis. In: Zinner MJ, Ashley SW, eds. *Maingot's Abdominal Operations*. 12th ed. New York, NY: McGraw-Hill; 2011 (in press).
10. Sakpal SV, Babel N, Chamberlain RS. Surgical management of hepatolithiasis. *HPB*. 2009;11:194–202.
11. Patel AH, Harnois DM, Klee GG, LaRusso NF, Gores GJ. The utility of CA19-9 in the diagnosis of cholangiocarcinoma in patients without primary sclerosing cholangitis. *Am J Gastroenterol*. 2000;95:204–207.
12. Bangarulingam SY, Bjornsson E, Enders F, et al. Long-term outcomes of positive fluorescence in situ hybridization tests in primary sclerosing cholangitis. *Hepatology*. 2010;51:174–180.
13. Whang EE, Duxbury M, Rocha FG, Zinner MJ. Cancer of the gallbladder and bile ducts. In: Zinner MJ, Ashley SW, eds. *Maingot's Abdominal Operations*. 12th ed. New York, NY: McGraw-Hill; 2011 (in press).
14. Ito F, Cho CS, Rikkers LF, Weber SM. Hilar cholangiocarcinoma: current management. *Ann Surg*. 2009;250:210–218.
15. Yoo JS, Pappas TN. Laparoscopic biliary procedures. In: Zinner MJ, Ashley SW, eds. *Maingot's Abdominal Operations*. 12th ed. New York, NY: McGraw-Hill; 2011 (in press).



# PERSPECTIVE ON BILIARY DISEASES

Steven M. Strasberg

This is a perspective on biliary diseases to complement a number of excellent chapters on biliary tract disease in this text. It focuses on areas that I believe require emphasis and areas where we are lacking information. Understandably, the latter is often controversial.

## CHOLECYSTECTOMY AND BILIARY INJURY

Biliary injury is still a serious problem and major injuries are most often caused by a misidentification, in which the common bile duct (CBD) is taken to be the cystic duct. Unfortunately, good updated epidemiological data are lacking, so the true incidence of biliary injury is unknown. Based on the referral data the problem still seems to be substantial.

### The Rationale of the “Critical View of Safety”

The critical view of safety (CVS) technique was developed to mimic a technique of ductal identification used for open cholecystectomy.<sup>1,2</sup> In that method the cystic duct and the cystic artery are first putatively identified by dissection in the hepatocystic triangle. Identity is then confirmed by freeing the gallbladder from the cystic plate so that the gallbladder is pedunculated on the two cystic structures only. The rationale of CVS is to reproduce the principles of this method without removing the gallbladder completely from the liver bed since this leads to undesirable twisting of the organ. To attain the CVS the triangle of Calot must be cleared of fat and fibrous tissue revealing two and only two structures entering the gallbladder and the base of the gallbladder has to be freed from the lower one-third of cystic plate so that it is apparent that the dissection is clearly onto the cystic plate. If any doubt exists more of the gallbladder should be freed off the plate. The CVS technique is not a method of dissection. It is a method of identification. The moment of identification should preferably

be treated like a “time out” with the surgeon pointing out the CVS to the operative team before going on. A number of publications have now supported this method of ductal identification but level 1 evidence will never be attained since comparing methods for an event that occurs with a frequency of 0.1–0.4% would require a randomized trial with 4000 patients per arm. Cholangiography should be used liberally and preferably always when a less sure method such as the infundibular technique is used. Cholangiography is effective in reducing the incidence and extent of major injuries but is less effective in preventing injuries to aberrant ducts.

### Culture of Cholecystectomy

The author’s conclusion, arrived at from reading a large number of operative notes, is that biliary injury is sometimes the result of persistence in performing cholecystectomy, usually in the face of severe acute and/or chronic inflammation. Although the Cochrane group arrived at the conclusion that one could not detect an increase in the incidence of biliary injury in patients who have cholecystectomy in the presence of acute cholecystitis, the number of patients available for study was so small that a significant difference could easily have been missed.<sup>3</sup> Cholelithiasis is a benign disease and cholecystectomies do not need to be completed in the face of operative difficulty. Some of the most serious injuries occur after conversion when the surgeon, unable to make headway in the triangle of Calot, takes the gallbladder down fundus first. Such difficult cholecystectomies may be safely terminated by cholecystostomy or partial cholecystectomy, which leave the gallbladder attached to the cystic plate. Teaching of this “culture of safety first” should be encouraged and it mimics safety strategies in aviation industry.<sup>4</sup>

### Vasculobiliary Injuries

Many biliary injuries are accompanied by vascular injuries.<sup>5</sup> Therefore patients presenting with major biliary injuries

require some form of assessment of the vasculature. More than 90% of the time the right hepatic artery is the artery which is injured. This injury leads to biliary ischemia which extends the injury to a higher level in the biliary tree. Slow patchy infarction of the right hemiliver ensues to a minority of patients. Early repair of a biliary injury in the face of a vasculobiliary injury (VBI) risks making an anastomosis to an ischemic bile duct. Delaying the repair allows the duct to “die-back” to a vascularized level. “Extreme VBIs” involve a major portal vein and hepatic artery. They usually result in rapid infarction of the liver.

## CHOLEDOCHOLITHIASIS

This was once a very common problem for community surgeons to treat at the time of cholecystectomy by bile duct exploration. Laparoscopic bile duct exploration is very well developed in minimally invasive surgery (MIS) centers and has as good results as endoscopic retrograde cholangiopancreatography (ERCP) in the treatment of the problem. However, residents graduating from residency programs have on average experience with fewer than five laparoscopic bile duct explorations and therefore in a practical sense ERCP has taken over as the main method of treatment of choledocholithiasis in community hospitals around the country.

## CHOLEDOCHAL CYSTS

This is a rare problem in which there is a serious knowledge gap. While choledochal cysts are associated with the development of cancer, the true incidence of cancer in this disease is unknown. Part of the reason is that there have not been good population-based studies that have searched for persons with asymptomatic cysts to determine natural history. As a result the prevalence of asymptomatic cysts in the population is unknown. Currently patients who are diagnosed by chance are advised to have resection. This strategy, although the current standard of care, can be questioned since it implies that a screening program should be in place. Furthermore, the threshold diameter of the bile duct which should be diagnosed as a choledochal cyst has not been defined.

## GALLBLADDER CANCER

This disease presents in two ways. In the early more readily curable stages (stages 1 and 2) it most often presents as biliary colic in a patient with stones. Presentations with classic manifestations of cancer such as palpable mass, weight loss, and jaundice are usually associated with more advanced usually inoperable stages 3 and 4. Surgeons need to be aware of signs associated with early gallbladder cancer in patients presenting with cholelithiasis so that preoperative suspicion of cancer will arise and an inappropriate operation may be avoided. These signs consist of gallbladder wall

thickening out of keeping with history or clinical evidence of acute cholecystitis, eccentric wall thickening or eccentric displacement of a stone in the gallbladder.<sup>6</sup> Gallbladder polyps may be malignant or precursors of malignancy and the risk increases if the polyps are single and greater than 1 cm. Porcelain gallbladder has an increased risk of malignancy but not if the gallbladder wall is completely calcified. When malignancy is suspected, an open cholecystectomy is indicated since this operation can be done without placing a clamp on the gallbladder. The latter risks creation of small perforations, even microperforations perhaps, through which cancer cells might pass. Laparoscopic cholecystectomy is associated conservatively with a 20% gross perforation rate. Case reports or small case series which suggest that laparoscopic cholecystectomy is safe under these conditions are subject to selection bias since the probability that negative outcomes would be reported in the same manner is very small.

## CHOLANGIOCARCINOMA

There is little doubt that intrahepatic cholangiocarcinomas (CCAs) are increasing in incidence in Western countries for unknown reasons. The Japanese classification of the gross types of cholangiocarcinomas is very useful and corresponds to the older American descriptions. The types are MF (mass forming—formerly nodular), PI (periductal infiltrating—formerly sclerosing), and IG (intraductal growth—formerly polypoid). Any of the three may appear in the three anatomic regions, that is, intrahepatic, hilar, or lower duct. The PI type is the classic type which infiltrates along the outer wall of the ducts for long distances beyond the palpable tumor and is associated with a higher likelihood of positive microscopic margins at resection. The uncommon IG type has the best prognosis. Diagnosis has been difficult because of inaccessibility of the ducts but recent advances in scope technology such as the Spyglass technique and use of fluorescence *in situ* hybridization (FISH) to evaluate specimens have increased the chance of obtaining a positive preoperative diagnosis. Nevertheless, malignant tumors may be hard to differentiate from inflammatory pseudotumors. The Japanese who have much experience in this disease have classically favored preoperative percutaneous intubation of bile ducts but are now shying away from this approach because of recently demonstrated higher incidence of recurrence in the tube tracts.<sup>7</sup> The author avoids preoperative percutaneous transhepatic cholangiography (PTC) for this reason. If diagnostic ERCP is performed for hilar CCA stenting of the side to be preserved is advantageous since this will result in hypertrophy of that side. In order for this to be possible, ERCP should be avoided as the primary investigation of jaundice. Instead axial imaging should be performed and if hilar CCA is suspected the patient should be referred to a hepatopancreaticobiliary (HPB) center at which a multidisciplinary team can evaluate and direct diagnosis and staging. If hemihepatectomy is required for hilar CCA, portal vein embolization to the side

to be resected is frequently practiced. Even when the side to be preserved has been decompressed one cannot count on normal liver function. Therefore remnant liver volumes should be increased from the 25% level associated with resection of normal livers to 40% or greater if possible.

## REFERENCES

1. Strasberg SM, Hertl M, Soper NJ. An analysis of the problem of biliary injury during laparoscopic cholecystectomy. *J Am Coll Surg.* 1995;180:101–125.
2. Strasberg SM, Brunt LM. Rationale and use of the critical view of safety in laparoscopic cholecystectomy. *J Am Coll Surg.* 2010;211:132–138.
3. Gurusamy KS, Samraj K, Fusai G, Davidson BR. Early versus delayed laparoscopic cholecystectomy for biliary colic. *Cochrane Database of Systematic Reviews.* 2008;4.
4. Strasberg SM. Biliary injury in laparoscopic surgery: part 2. Changing the culture of cholecystectomy. *J Am Coll Surg.* 2005;201:604–611.
5. Strasberg SM, Helton WS. An analytical review of vasculobiliary injury in laparoscopic and open cholecystectomy. *HPB.* 2011;13:1–14.
6. Wibbenmeyer LA, Sharafuddin MJ, Wolverson MK, Heiberg EV, Wade TP, Shields JB. Sonographic diagnosis of unsuspected gallbladder cancer: imaging findings in comparison with benign gallbladder conditions. *Am J Roentgenol.* 1995;165:1169–1174.
7. Takahashi Y, Nagino M, Nishio H, Ebata T, Igami T, Nimura Y. Percutaneous transhepatic biliary drainage catheter tract recurrence in cholangiocarcinoma. *Brit J Surg.* 2010;97:1860–1866.



IX

# PANCREAS

*This page intentionally left blank*

# MANAGEMENT OF ACUTE PANCREATITIS

Thomas E. Clancy • Stanley W. Ashley

## INTRODUCTION

Acute pancreatitis includes a wide spectrum of disease, from mild self-limiting symptoms to a fulminant process with multiple organ failure and high mortality. Of the approximately 185,000 patients who develop acute pancreatitis each year in the United States, most experience relatively minor episodes of disease characterized by mild parenchymal edema without distant organ dysfunction and an uneventful recovery.<sup>1</sup> Severe episodes, however, may involve a progression to extensive pancreatic necrosis, development of the systemic inflammatory response syndrome (SIRS), multiorgan failure, rapid clinical deterioration, and even death.<sup>2,3</sup> Although the overall mortality rate with acute pancreatitis is 2–10%, this is primarily related to the 10–30% of patients with severe disease characterized by pancreatic and peripancreatic necrosis.

Given the wide spectrum of disease seen, the care of patients with pancreatitis must be highly individualized. Patients with mild acute pancreatitis can generally be managed with resuscitation and supportive care. Etiologic factors are sought and treated, if possible, but operative therapy has essentially no role in the care of these patients. In contrast, patients with severe and necrotizing pancreatitis may require maximal nonoperative care and nutritional support in an intensive care unit. On occasion, care of these patients may include wide operative debridement of the infected pancreas or surgical management of local complications of the disease. The precise indications for surgery in patients with pancreatitis have evolved in recent years. Whereas early aggressive debridement was commonly used for all patients with pancreatic necrosis in the past, now most pancreatic surgeons have adopted a more conservative algorithm of selective and delayed pancreatic debridement.<sup>4,5</sup> This chapter reviews current management strategies in acute pancreatitis, with particular attention to assessment of disease severity, the timing and routes of supplemental nutrition, the role of prophylactic antibiotics, the indications for and timing of surgery, the methods of pancreatic debridement for necrotizing pancreatitis, and the role of endoscopic and minimally invasive techniques.

## ETIOLOGY

Acute pancreatitis has been attributed to a wide range of etiologic factors, some rare and rather obscure (Table 54-1). Intra-acinar activation of trypsinogen, with subsequent activation of other pancreatic enzymes, is thought to play a central role in the pathogenesis of the disease. Furthermore, ischemia-reperfusion injury is believed to be critical to disease progression. A local inflammatory response in the pancreas is associated with the liberation of oxygen-derived free radicals and cytokines including interleukin (IL)-1, IL-6, IL-8, tumor necrosis factor alpha (TNF- $\alpha$ ), and platelet-activating factor; these mediators play an important role in the transformation from a local inflammatory response to a systemic illness.

Approximately 80% of cases are associated with cholelithiasis or sustained alcohol abuse; the relative frequency of these two factors depends on the prevalence of alcoholism in the population studied. Of the mechanical causes of pancreatitis, choledocholithiasis is certainly the most common. The majority of nonalcoholic patients with acute pancreatitis will have gallstones on examination, and between 36 and 63% will develop recurrent acute pancreatitis if stones persist. Approximately 1% of patients undergoing endoscopic retrograde cholangiopancreatography (ERCP) develop clinically detectable pancreatitis. Several metabolic processes are associated with pancreatitis, particularly alcohol abuse. Symptoms and signs of pancreatitis are recognized in between 1 and 10% of alcoholic patients, usually after 10 years or more of heavy ingestion. The precise mechanism of this association is not well established, but may be related to changes in pancreatic exocrine secretion and calculus formation in the pancreatic ducts. Several drugs are causally related to pancreatitis, particularly corticosteroids, thiazide diuretics, estrogens, azathioprine, and furosemide. Furthermore, in approximately 10% of cases, no underlying cause can be identified. Some investigators have suggested that occult biliary microlithiasis may be the etiology in a majority of cases of idiopathic acute pancreatitis.<sup>6</sup>




**TABLE 54-1: ETIOLOGIC FACTORS IN ACUTE PANCREATITIS**
**Metabolic**

Alcohol  
 Hyperlipoproteinemia  
 Hypercalcemia  
 Drugs  
 Genetic  
 Scorpion venom

**Mechanical**

Cholelithiasis  
 Postoperative  
 Pancreas divisum  
 Post-traumatic  
 Retrograde pancreatography  
 Pancreatic duct obstruction: pancreatic tumor, ascariis infestation  
 Pancreatic ductal bleeding  
 Duodenal obstruction

**Vascular**

Postoperative (cardiopulmonary bypass)  
 Periarteritis nodosa  
 Atheroembolism

**Infection**

Mumps  
 Coxsackie B  
 Cytomegalovirus  
 Cryptococcus

## DIAGNOSIS, STAGING, AND SEVERITY

The early diagnosis and precise staging of disease severity are important goals in the initial evaluation and management of pancreatitis. Pancreatitis must not only be differentiated from a myriad of other potential diagnoses, but patients must also be stratified to identify those with severe disease and to guide appropriate therapy. Unfortunately, despite our increased understanding of the pathophysiology of pancreatitis, diagnostic tools for pancreatitis have not changed much in recent years. Clinical signs and symptoms of pancreatitis, such as upper abdominal pain, back pain, vomiting, fever, tachycardia, and leukocytosis are relatively nonspecific. Periumbilical and flank bruising may be seen with severe and hemorrhagic pancreatitis (Cullen's and Grey-Turner's signs), but these uncommon clinical signs are not pathognomonic of severe pancreatitis and are seen with any cause of retroperitoneal bleeding. Diagnosis therefore typically depends on a high level of clinical suspicion and the demonstration of elevated plasma concentrations of pancreatic enzymes. Levels of both amylase and lipase peak within the first 24 hours of symptoms, and amylase has a slightly shorter half-life in plasma. As a result, lipase levels may have a slightly greater sensitivity, particularly when measured late (>24 hours) after

initial presentation.<sup>7</sup> Hyperamylasemia is neither specific for pancreatitis<sup>8</sup> nor perfectly sensitive, as normal amylase levels have been described in some cases of acute pancreatitis.<sup>9</sup> Other pancreatic enzymes have not been shown to have any advantage over amylase and lipase for diagnostic purposes. Of note, plasma levels of pancreatic enzymes serve a purely diagnostic and not prognostic role; absolute levels have no direct correlation with disease severity. A common misconception is that amylase and lipase levels only slightly elevated above normal are associated with mild disease; in fact, such low levels may also be associated with severe cases.

Identification of patients with severe pancreatitis is crucial early in the course of the disease, so that early goal-directed therapy may be instituted. However, an objective, reproducible, and universally accepted measure of disease severity is still lacking.<sup>10</sup> Early clinical evaluation is complicated by a relatively nonspecific presentation, and severe disease may present with a fulminant sepsis-like syndrome or in a manner that is deceptively innocuous. Initial signs and symptoms of necrotizing pancreatitis are only different in degree from edematous pancreatitis; likewise both severe and mild forms of disease share the same etiologies.<sup>11</sup> Despite considerable experimental effort to identify differences in the pathogenesis of edematous and necrotizing pancreatitis,<sup>12</sup> no available clinical model is successful at predicting which patients will progress to severe disease.

## Clinical Scoring Systems

Clinical scoring system for pancreatitis such as the Ranson<sup>13</sup> (Table 54-2) and Glasgow<sup>14</sup> scores utilize multiple clinical variables to predict outcomes in groups of patients with acute pancreatitis. Patients are evaluated at admission and again during the subsequent 48 hours, utilizing demographic and laboratory parameters; the number of positive prognostic signs is then used to predict subsequent morbidity and mortality. In Ranson's report from the 1970s, for instance, the presence of five or six positive signs was associated with 40% mortality and prolonged intensive care unit (ICU) stay in 50% of patients, whereas the presence of seven or eight signs was associated with virtually 100% mortality. Although these scoring systems are relatively successful in predicting disease severity, they require 48 hours from admission for full assessment. Furthermore, while higher scores suggest poorer outcomes, these scoring systems have not been adequately reassessed to reflect the substantial improvements in critical care since their introduction over two decades ago.<sup>15</sup>

The acute physiology and chronic health evaluation II (APACHE II) score is another physiological scoring system that attempts to estimate disease severity based on quantifying the degree of abnormality of multiple physiological variables. Though not specific for pancreatitis and somewhat cumbersome to use, the APACHE II system is as accurate at 24 hours as other systems at 48 hours, and it is now regarded as perhaps the optimal scoring system to assess disease severity in pancreatitis.<sup>10</sup> Twelve physiological variables are measured and



**TABLE 54-2: THE RANSON SCORE—EARLY PROGNOSTIC SIGNS THAT CORRELATE WITH THE RISK OF MAJOR COMPLICATIONS OR DEATH IN ACUTE PANCREATITIS**

#### At Admission or Diagnosis

1. Age over 55 years
2. White blood cell count over 16,000/mL
3. Blood glucose level over 200 mg/dL (100 mmol/L)
4. Serum lactic dehydrogenase concentration (LDH) >350 IU/L
5. Serum glutamic oxaloacetic transaminase (SGOT) >250 sigma-Frankel units/dL

#### During Initial 48 Hours

1. Hematocrit decrease >10%
2. Blood urea nitrogen (BUN) increase >5 mg/dL
3. Serum calcium level <8 mg/dL (2 mmol/L)
4. Arterial PO<sub>2</sub> <60 mm Hg (8 kPa)
5. Base deficit >4 mEq/L (4 mmol/L)
6. Estimated fluid sequestration >6000 mL

weighed based on their degree of abnormality: temperature, mean arterial pressure, heart rate, respiratory rate, arterial oxygen tension (Pao<sub>2</sub>), arterial pH, serum sodium, serum potassium, serum creatinine, hematocrit, white blood cell (WBC) count, and the Glasgow coma scale. The score is determined from the most deranged physiological value measured, and further points are added for increased age and chronic organ dysfunction. Unlike other systems, the APACHE II score may be continuously recalculated through the course of the disease. APACHE II scores have also been identified as not only prognostically important at admission, but also after subsequent interventions such as pancreatic debridement.<sup>16</sup> The newer APACHE III system uses an additional five physiological variables to improve accuracy, although the newer system may be less useful than the APACHE II score in distinguishing mild from severe pancreatitis.<sup>17</sup> A recent modification of the APACHE II system, which includes a clinical assessment of obesity (APACHE-O score) has been suggested to further improve predictive accuracy, with a positive predictive value of 74%.<sup>18</sup> All versions of this scoring system are somewhat unwieldy for use with most patients, and are more appropriately applied to critically ill patients.

## MARKERS OF SEVERITY

Numerous individual markers have been investigated as possible indicators of prognosis in pancreatitis, in both the laboratory and clinical settings. With few exceptions, these have not gained widespread clinical application. Banks<sup>19</sup> and others<sup>20</sup> have shown that hemoconcentration predicts parenchymal necrosis, as well as the presence of organ failure, in acute pancreatitis. C-reactive protein (CRP) assays are readily available, and levels rise with disease severity.

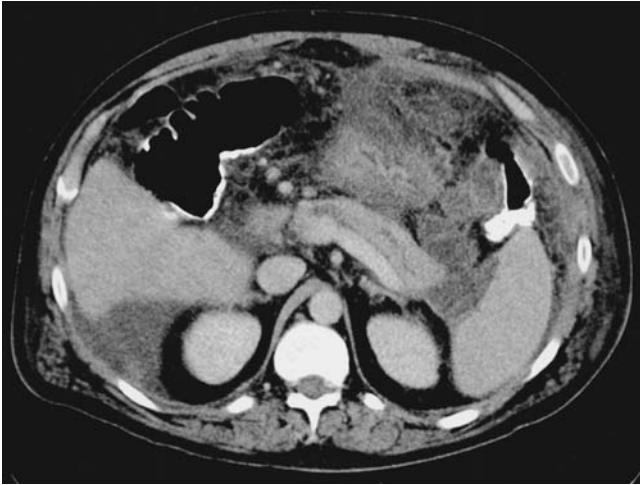
Based on the trajectory of CRP levels, however, this marker is useful to identify severe disease only 48 hours after the onset of symptoms.<sup>21</sup> Other inflammatory mediators such as IL-8 and IL-6 have shown promise as early indicators of severe disease, but await general availability and further clinical validation.<sup>22</sup> Other inflammatory markers, including TNF soluble receptors, polymorphonuclear (PMN) elastase, serum procalcitonin, soluble IL-2 receptors, and soluble E-selectin, have shown potential in the investigative setting but await the availability of reproducible assays as well as clinical validation prior to their use as prognostic indicators.<sup>23</sup>

Trypsinogen activation peptide (TAP) is an additional marker that may be useful in determining prognosis in acute pancreatitis. TAP is released with the activation of trypsinogen to trypsin, and plasma and urine levels are known to correlate with the severity of pancreatitis. However, the molecule is present in low concentrations of urine and is cleared rapidly from plasma. Recent data suggest that clinically useful TAP assays may be soon to come. Some authors have reported high sensitivity and specificity for elevated urinary TAP levels in severe pancreatitis.<sup>24,25</sup> Similarly, a recent report suggested that severe acute pancreatitis could be recognized with sensitivity and specificity of 70 and 78%, respectively, using a plasma assay.<sup>26</sup>

It is increasingly recognized that organ failure is perhaps the most significant prognostic indicator in severe acute pancreatitis.<sup>27</sup> Plasma D-dimer has been suggested as a surrogate marker of future organ dysfunction with sensitivity and specificity of 90 and 89%, respectively.<sup>28</sup> While further validation is required, early recognition of patients who will subsequently develop organ failure in the course of pancreatitis could potentially allow early therapeutic interventions to limit the severity of disease.

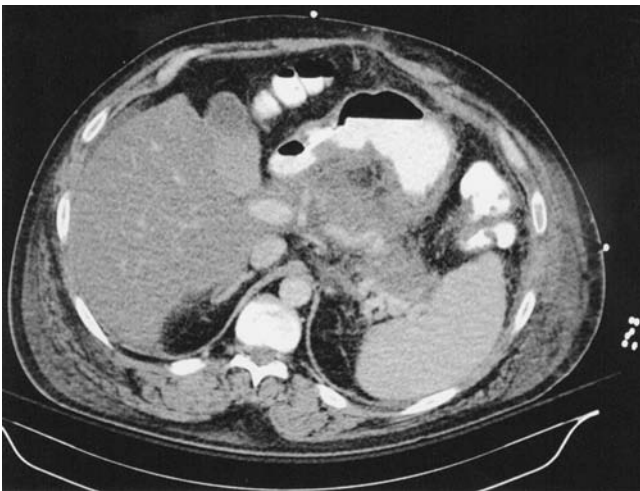
## Contrast-Enhanced Computed Tomography

Computed tomography (CT) scans have proven invaluable in determining disease severity in acute pancreatitis. CT findings in pancreatitis include enlargement of the pancreas with loss of peripancreatic fat planes, areas of decreased density, and occasionally the presence of fluid collections (Fig. 54-1). The Balthazar scoring system, and other similar grading systems have incorporated various CT findings such as pancreatic inflammation and peripancreatic fluid collections to correlate radiographic appearance with morbidity and mortality.<sup>29,30</sup> The contrast-enhanced CT scan is perhaps most useful in its ability to demonstrate pancreatic necrosis. From a baseline of 30–50 Hounsfield units (HU), viable pancreas will typically enhance by more than 50 HU with the administration of intravenous (IV) contrast. Nonviable pancreas, however, will show no such enhancement with IV contrast (Fig. 54-2). Various criteria used to diagnose necrosis include nonenhancement of more than 30% of the pancreatic parenchyma



**FIGURE 54-1** Contrast-enhanced abdominal CT scan in a 47-year-old man with acute pancreatitis. Relevant findings include significant fat stranding of the peripancreatic tissue, with a fluid collection at the tail of the pancreas measuring approximately  $4 \times 4$  cm. Pancreatic parenchyma enhances with IV contrast, with no evidence of pancreatic necrosis. (Reproduced with permission from Clancy TE, Benoit EP, Ashley SW. Current management of acute pancreatitis. *J Gastrointest Surg.* 2005;Mar;9(3):440–452.)

or an area of greater than 3 cm of the pancreas that does not enhance.<sup>31</sup> The sensitivity and specificity for diagnosing pancreatic necrosis increase with greater degrees of pancreatic nonenhancement, and complications have also been shown to correlate with the degree of nonenhancement.<sup>30</sup> In the patient with moderate renal impairment or allergy to IV contrast, magnetic resonance imaging (MRI) may be used as

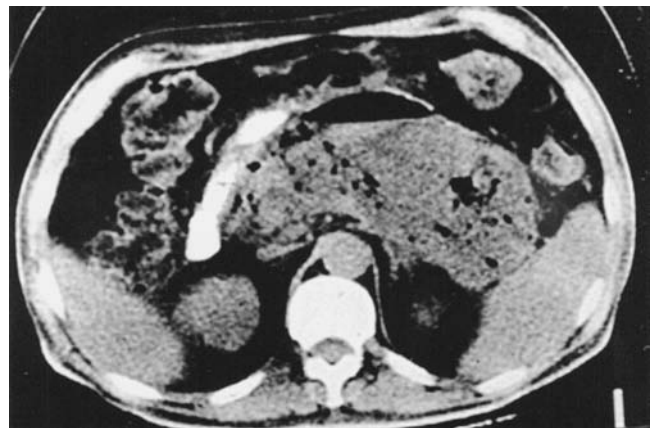

**FIGURE 54-2** Contrast-enhanced abdominal CT scan in the same 47-year-old man with a second episode of acute pancreatitis. Scan shows stranding of peripancreatic fat, consistent with acute pancreatitis. Most notable is the near-complete absence of pancreatic enhancement, diagnostic of pancreatic necrosis. (Reproduced with permission from Clancy TE, Benoit EP, Ashley SW. Current management of acute pancreatitis. *J Gastrointest Surg.* 2005;Mar;9(3):440–452.)

an alternative. MRI has been shown to have comparable sensitivity and specificity to contrast-enhanced CT for detecting severe acute pancreatitis,<sup>32</sup> although MRI is currently less practical for the critically ill patient.

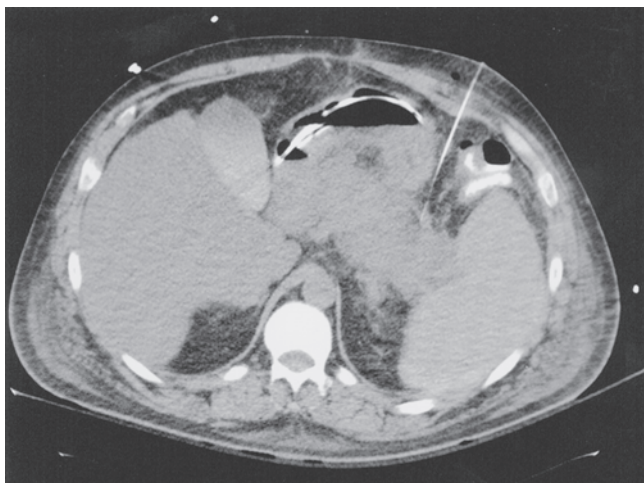
Clinical judgment rather than strict criteria often guides the timing of and indications for CT scans in acute pancreatitis, and precise recommendations are not universally accepted. Early CT scans often fail to identify developing necrosis until such areas are better demarcated, which may become evident only 2–3 days after the initial clinical onset of symptoms. The use of CT to diagnose necrosis or to predict severity within the first 24 hours of illness is therefore not recommended. Some authors have cautioned against the widespread use of CT scans in the setting of acute pancreatitis based on limited experimental evidence suggesting that IV contrast might exacerbate early pancreatic necrosis.<sup>33</sup> However, clinical evidence to support this phenomenon in humans is lacking. The sensitivity for identifying pancreatic necrosis using contrast-enhanced CT scan approaches 100% after 4 days from diagnosis.<sup>10</sup> It is therefore reasonable to recommend an abdominal CT scan with oral and IV contrast in patients with clinical and biochemical features of acute pancreatitis who do not improve after several days of conservative management. Follow-up scans may be obtained with any signs of clinical deterioration.

CT scans have also been instrumental in facilitating the early diagnosis of infected pancreatic necrosis. Despite an increasing trend toward nonoperative management of sterile pancreatic necrosis, as reviewed below, infection remains an absolute indication for intervention.<sup>1</sup> Unfortunately, the precise diagnosis of infected pancreatic necrosis can be difficult to make. It is not possible to differentiate infected from sterile pancreatic necrosis based only on clinical and laboratory data, as organ failure, significant leukocytosis, and fever are seen in both cases. Emphysematous pancreatitis, the demonstration of gas within the pancreatic parenchyma, is diagnostic of infection but is uncommonly seen (Fig. 54-3). Using



**FIGURE 54-3** CT scan demonstrating emphysematous pancreatitis, pathognomonic for infected pancreatic necrosis. Operative debridement is indicated without additional confirmation of pancreatic infection.





**FIGURE 54-4** CT-guided percutaneous fine-needle aspiration (FNA) of the pancreatic tail. The aspiration area had previously been identified as necrotic in the contrast-enhanced CT shown in Fig. 54-2. Gram's stain and cultures were negative for organisms, consistent with sterile pancreatic necrosis. (Reproduced with permission from Clancy TE, Benoit EP, Ashley SW. Current management of acute pancreatitis. *J Gastrointest Surg.* 2005;Mar;9(3):440–452.)

image-guided precise aspiration of the necrotic pancreas, however, infected pancreatic necrosis can be diagnosed with a high degree of accuracy (Fig. 54-4). CT-guided pancreatic aspiration is usually reserved for patients with documented pancreatic necrosis who are not improving clinically or who experience clinical decline. All patients should receive oral contrast to opacify the gastrointestinal (GI) tract and avoid inoculating the pancreatic necrosus with GI flora from the inadvertently perforated viscus.

The sensitivity and specificity for detection of infection using this method are reported as 96.2 and 99.4%, respectively, with a positive predictive value of 99.5% and negative predictive value of 95.3%.<sup>34</sup> Areas of nonenhancing pancreas are aspirated under CT guidance, and samples are sent for aerobic, anaerobic, and fungal cultures. In most patients with infected necrosis, diagnosis may be made with a positive Gram's stain of the aspirate rather than waiting for confirmatory culture data. Gram's stains of the pancreatic aspirate are positive in most cases later documented to have infection, thus enabling rapid decision making.

Infection may occur at any point in the clinical course of a patient with pancreatic necrosis. The interval from presentation with necrosis to infection is variable, and the incidence of infection increases up to 3 weeks after presentation. In one study, infection was documented in 49% of patients in the first 14 days; less than 15% of patients had infection diagnosed after 35 days.<sup>34</sup> Infection may occur later in the course of the disease, even after a prior negative aspiration. Repeat CT-guided aspirations are therefore often necessary in patients in whom a conservative strategy is adopted for sterile pancreatic necrosis, until clinical improvement is documented. In a series at our institution with fine-needle aspirations (FNAs) demonstrating infection, the first aspirate was positive in 17 of 30 patients (57%); 7 patients (23%)

required two procedures and 6 patients (20%) required three or more aspirations to demonstrate infection.<sup>35</sup>

## Classification System for Acute Pancreatitis

The most commonly used classification system in acute pancreatitis emerged from an interdisciplinary symposium in 1992. The Atlanta Classification defined acute pancreatitis, its severity, organ failure, and local complications of the disease in an attempt to introduce uniformity in assessment of severity and complications (Table 54-3). This classification was an important step in achieving some descriptive consistency in acute pancreatitis, thus helping to standardize clinical care as well as aiding clinical research. However, improved understanding of the pathophysiology of pancreatitis, improved imaging techniques, and the development of new minimally invasive techniques have recently focused some attention on potential shortcomings of the classification. Recent literature review of all clinical papers published on acute pancreatitis

### TABLE 54-3: DEFINITIONS PROPOSED BY THE INTERNATIONAL SYMPOSIUM ON ACUTE PANCREATITIS (THE "ATLANTA SYMPOSIUM"), 1992<sup>31a</sup>

<b>Acute pancreatitis (AP)</b>	Acute inflammatory process of the pancreas with variable involvement of other regional tissues or remote organ systems.
<b>Severe AP</b>	Association with organ failure and/or local complications, such as necrosis, abscess, or pseudocyst.
<b>Acute fluid collection</b>	Occurs early in the course of AP; located in or near the pancreas, always lacking a wall of granulation or fibrous tissue; bacteria variably present; occurs in 30–50% of severe AP; most acute fluid collections regress, but some progress to pseudocyst or abscess.
<b>Pancreatic necrosis</b>	Diffuse or focal area(s) of nonviable pancreatic parenchyma, typically associated with peripancreatic fat necrosis, diagnosed by CT scan with IV contrast enhancement.
<b>Acute pseudocyst</b>	Collection of pancreatic juice enclosed by a wall of fibrous or granulation tissue, which arises as a consequence of AP, pancreatic trauma, or chronic pancreatitis; formation requires 4 or more weeks from onset of AP.
<b>Pancreatic abscess</b>	Circumscribed intra-abdominal collection of pus usually in or near the pancreas, containing little or no pancreatic necrosis, arises as a consequence of AP or pancreatic trauma.

<sup>a</sup>The terms *phlegmon*, *infected pseudocyst*, *hemorrhagic pancreatitis*, and *persistent acute pancreatitis* are discouraged.

guidelines or review articles since 1993 found that alternate definition of severity and organ failure was used in more than half of the studies.<sup>36</sup> Continued revision of the classification scheme is therefore underway to establish a more accurate system for communication among clinicians and across multiple institutions, particularly pertaining to assessment of disease severity and description of fluid and solid peripancreatic collections.<sup>37</sup>

## PRINCIPLES OF MANAGEMENT

### Resuscitation and Monitoring

Although patients with acute pancreatitis require management strategies specifically tailored to disease severity, the nonoperative management of acute pancreatitis has become increasingly standardized.<sup>3,38–40</sup> Aggressive fluid resuscitation is important in order to replenish extravascular or “third-space” fluid losses, which may be considerable. Intravenous fluids at rates of greater than 200 mL/h are often necessary to restore and maintain intravascular volume. This degree of fluid resuscitation is important to avoid systemic complications, particularly acute renal insufficiency, that may occur with hypovolemia. Furthermore, inadequate resuscitation has recently been shown to pose a significant risk for further pancreatic injury. Banks and others have shown that while aggressive fluid resuscitation does not necessarily prevent the progression to pancreatic necrosis, patients with inadequate resuscitation have an increased risk of developing necrosis.<sup>41</sup> Close monitoring of respiratory, cardiovascular, and renal function is essential to detect and treat complications from hypovolemia. The degree and intensity of monitoring is tailored to disease severity. All patients require close assessment of fluid balance including a Foley catheter. Monitoring for respiratory compromise and electrolyte imbalance is important in all, and any patient with severe disease should be admitted to an ICU with the capacity for continuous blood pressure and oxygen saturation monitoring. Intravenous narcotics are often essential for pain control in these patients. The use of nasogastric tubes to avoid pancreatic stimulation had previously been commonplace, although no clinical data support this practice and the routine use of nasogastric suction should probably be abandoned. Paralytic ileus is not uncommon with acute pancreatitis, however, and nasogastric tubes should be used in this circumstance to prevent emesis and aspiration pneumonia.

### Nutritional Support

Historically, enteral feeding was limited in acute pancreatitis for the purpose of providing “pancreatic rest.” Enteral nutrition was believed to exacerbate the existing inflammatory process via stimulation of exocrine pancreatic function and release of proteolytic enzymes. In mild

cases of pancreatitis, brief periods without oral intake may be expected and acceptable, as a full diet is often tolerated in several days with the resolution of pain. Limitation of nutritional intake, however, may have grave consequences in the subset of patients with critical illness. Inflammatory stress will increase basic metabolic rate, leading to enhanced catabolism and negative nitrogen balance.<sup>42</sup> In such cases of severe acute pancreatitis, the prolonged disease course, hypercatabolic state, and ileus, has led to a general use of parenteral nutrition as a principle means of nutritional support.<sup>43</sup>

Recent data, however, suggest that such strict limitations of enteral nutrition are unnecessary. Increasing evidence has accumulated to suggest that enteral nutrition may be feasible, safe, and even desirable in severe pancreatitis.<sup>44</sup> Enteral nutrition has the advantage of avoiding the high cost of total parenteral nutrition (TPN) as well as its associated catheter-related complications; furthermore, the use of enteral nutrition may support intestinal mucosal integrity and avoid the alterations to intestinal barrier function and altered intestinal permeability seen with TPN.<sup>45</sup> A small trial from 1997 randomized 38 patients with severe pancreatitis to TPN versus nasojejunal feeding.<sup>46</sup> In this cohort, enterally fed patients had significantly fewer septic and total complications. McClave et al<sup>47</sup> randomized 30 patients in a similar fashion, and demonstrated only a trend toward fewer complications in the enterally fed group. One significant advantage of enteral nutrition in this study was the lower cost; this was four times greater in the TPN group. Furthermore, Windsor et al<sup>48</sup> demonstrated that patients with pancreatitis randomized to enteral nutrition had significant improvement in CRP and APACHE II scores. Recently, a larger study from China<sup>49</sup> randomized 96 patients with severe pancreatitis to TPN versus nasojejunal feeding. Measures of inflammation including CRP and IL-6 decreased earlier with enteral nutrition, as did APACHE II scores. Furthermore, mucosal permeability was improved, as inferred by urine endotoxin levels. Others have suggested that the addition of *Lactobacillus* preparations to enteral nutrition formulas may have a role in decreasing infectious complications in pancreatitis.<sup>50</sup>

A recent systematic review of the literature has not concluded that there are sufficient data to definitively recommend preferential enteral nutrition in acute pancreatitis<sup>51</sup>; however studies continue to accumulate demonstrating its safety and feasibility. For instance, in a meta-analysis of prospective randomized studies comparing enteral and parenteral nutrition with acute pancreatitis, Marik and Zaloga conclude that enteral nutrition is preferred in acute pancreatitis, and is associated with significantly lower rates of infection and reduced hospital stay.<sup>52</sup> The use of TPN will continue to have a role in severe pancreatitis, particularly in cases with prolonged ileus. However, early enteral nutrition in the form of jejunal feeding should be considered preferable for patients who will not resume oral intake early in the course of their disease. Of note, no randomized studies have defined the best time to initiate nutritional support in severe acute pancreatitis.<sup>53</sup>

Most studies investigating the use of enteral nutrition in pancreatitis have used nasojejunal feeding, though others have investigated the role of nasogastric feedings in this setting. Eatock et al randomized 49 patients with severe acute pancreatitis to nasogastric or nasojejunal feeding.<sup>54</sup> There were no differences in pain, serum CRP levels or clinical outcome between the groups, leading to the conclusion that nasogastric feeding is simpler, cheaper, and easier than nasojejunal feeding. Similarly, Kumar et al<sup>55</sup> randomized 31 patients to nasogastric versus nasojejunal feeding, finding no difference in outcomes. These data were confirmed recently by Eckerwall et al<sup>56</sup> in a randomized study in which early nasogastric feeding was found to be feasible and blood glucose was better controlled. The delayed gastric emptying seen in many patients with acute pancreatitis may limit the nasogastric route for some patients. If tolerated, however, nasogastric feeding may be a reasonable alternative for patients with acute pancreatitis receiving nutritional support.

## The Role of ERCP

As noted above, the presence of gallstones leading to choledocholithiasis is recognized as a major cause of acute pancreatitis, and the primary cause of acute pancreatitis in most populations. Endoscopic retrograde cholangiopancreatography (ERCP) has therefore been used as a diagnostic and potentially therapeutic modality in acute pancreatitis. The basis for selecting patients with pancreatitis who might benefit from ERCP lies predominantly in whether evidence exists for obstructive choledocholithiasis. The role of ERCP in cases of acute biliary pancreatitis with biliary obstruction or cholangitis is clear. Less obvious, however, is the role of early ERCP and papillotomy in acute biliary pancreatitis without evidence of obstruction. By randomizing patients with acute pancreatitis to early ERCP versus no ERCP, both Neoptolemos et al<sup>57</sup> and Fan et al<sup>58</sup> demonstrated a significant reduction on morbidity with nonsignificant trends to improved mortality with the routine use of ERCP. However, these studies were criticized for the inclusion of patients with known obstruction and cholangitis in the cohort, possibly accounting for the observed benefit from intervention. A more recent multicenter randomized study by Folsch et al<sup>59</sup> excluded patients with known biliary sepsis or obstruction, and demonstrated increased complications and mortality in the ERCP group. It was therefore suggested that early ERCP might be harmful in the absence of ongoing obstruction. Though diagnostic and management strategies continue to evolve, most surgeons and gastroenterologists would agree that it is generally not recommended to perform ERCP in acute pancreatitis in the absence of biliary obstruction or cholangitis.

Magnetic resonance cholangiopancreatography (MRCP) is an additional alternative to ERCP that avoids the risk of postprocedure pancreatitis. Although therapeutic maneuvers to clear identified stones cannot be performed with MRCP, its use as a diagnostic tool may allow ERCP to be used selectively for patients with known choledocholithiasis.<sup>60</sup> MRI poses

unique challenges in the critically ill patient, including the need for prolonged scan times and compatible nonmetallic equipment for ventilators and IV fluid administration. Its use is therefore currently primarily restricted to patients outside the critical care setting. As technology evolves, it is expected that MRI and MRCP will play an increased role in diagnosis of pancreatitis and ductal obstruction.

## Prophylactic Antibiotics

One management principle which has dramatically evolved in recent years concerns the use of prophylactic antibiotics in severe, necrotizing pancreatitis, with a new trend to avoid prophylaxis and treat for defined infection only. Of patients with severe pancreatitis who succumb to the disease, most do so from local and systemic infectious complications. Local infection is increasingly common with larger amounts of pancreatic necrosis, and this increases in incidence as time progresses for at least the first 3 weeks in the course of the disease.<sup>61</sup> In one study, 24% of patients operated on for pancreatic necrosis had infection at 1 week, whereas 71% of patients were infected when exploration was performed at 3 weeks.<sup>62</sup> Aerobic and anaerobic GI flora are the primary organisms involved, and infections may be monomicrobial or polymicrobial. In a collected series of over 1100 cases, the predominant microbes seen were *Escherichia coli* (35%), *Klebsiella pneumoniae* (24%), *Enterococcus* (24%), *Staphylococcus* (14%), and *Pseudomonas* (11%).<sup>63</sup> The association of pancreatic infection with mortality has been the rationale behind the widespread use of prophylactic systemic antibiotics targeted against enteric organisms for patients with pancreatic necrosis. The use of broad-spectrum antibiotics for this purpose is known to change the bacterial flora of pancreatic infections, and has been demonstrated to encourage the development of antibiotic-resistant bacterial infections and fungal infections.<sup>64,65</sup> Antibiotic use to forestall pancreatic infection with pancreatic necrosis has therefore been the subject of considerable debate and clinical investigation.<sup>66,67</sup>

Several animal studies have shown a benefit from early antibiotic administration with pancreatitis,<sup>66</sup> although this benefit has not been as consistently demonstrated in humans. Early clinical studies suggested no benefit of prophylactic antibiotics for necrotizing pancreatitis, possibly due to inclusion of patients at low risk for infection or to the use of antibiotics with poor pancreatic penetration. The precise relationship between antibiotic “penetration” into healthy pancreatic parenchyma and their efficacy in preventing or treating infection in necrotic pancreatic tissue is unclear. Still, considerable investigative effort has been made to characterize the penetration of various antibiotics into the pancreatic parenchyma<sup>68</sup> and these studies have influenced the commonly used prophylactic antibiotic regimens.

Several randomized controlled trials have been published examining the role of prophylactic systemic antibiotics in necrotizing pancreatitis, with conflicting recommendations. Pederzoli et al<sup>69</sup> randomized 74 patients with necrotizing



pancreatitis to systemic imipenem or no antibiotics. Pancreatic infection was decreased with imipenem (12 vs 30%), although there was no difference in the rate of multiorgan system failure, need for surgery, or overall mortality. Antibiotic therapy was particularly useful with lesser degrees of necrosis; no patient with less than 50% necrosis developed septic complications with imipenem, compared to 29% in the control group. Sainio et al,<sup>70</sup> however, showed a decrease in complications and mortality with prophylactic antibiotics, in the absence of any difference in local infection. Patients with necrotizing alcoholic pancreatitis given cefuroxime in a randomized fashion showed a decrease in infectious complications, operations, and mortality. However, this apparent mortality benefit was not associated with any difference in local pancreatic infections between treated patients and controls. This study was subject to some criticism for the high incidence of antibiotic use in the control arm. Another small randomized study<sup>71</sup> with 26 patients showed a nonsignificant trend to improved mortality with IV ofloxacin and metronidazole for CT-confirmed pancreatic necrosis.

Further disagreement about the role of antibiotics in acute pancreatitis was stimulated in 2004 by the publication of a prospective, randomized, double-blind trial by Isenmann et al<sup>72</sup> of 114 patients with severe acute pancreatitis which suggested no difference in mortality or the development of infected pancreatic necrosis with the use of ciprofloxacin and metronidazole. This was criticized for not limiting the study to patients with CT-confirmed pancreatic necrosis, and for large cross-over to antibiotics in the control group. In this setting of conflicting data, poor trial accrual, heterogeneous studies, several meta-analyses were attempted to overcome the limited statistical power of available trials. In one such meta-analysis,<sup>73</sup> early antibiotic use was associated with decreased mortality from pancreatitis for patients with severe disease receiving broad-spectrum antibiotics. A second meta-analysis looked at randomized, controlled, nonblinded studies of prophylactic antibiotics in necrotizing pancreatitis. A nonsignificant trend toward decreased local infection was suggested with the use of imipenem, cefuroxime, or ofloxacin. Sepsis and overall mortality were significantly lower with antibiotic use, and the authors therefore supported prophylactic antibiotics for all patients with acute necrotizing pancreatitis.<sup>74</sup>

Despite some variations in institutional practices, a consensus had emerged in the past decade that broad-spectrum antibiotics should be used early in the course of necrotizing pancreatitis, particularly in patients with signs of organ failure or systemic sepsis.<sup>75</sup> The risks of superinfection with fungal or antibiotic-resistant organisms has been well recognized,<sup>76</sup> and is thought to be related to the length of treatment with prophylactic antibiotics. The optimal duration of antimicrobial therapy was not defined, although the incidence of pancreatic infection increases for approximately the first 3 weeks after diagnosis.<sup>61</sup> A treatment course of 1–4 weeks was therefore commonly recommended, with many authors limiting treatment to 14 days.<sup>5</sup> Mortality is considerable when fungal infection complicates pancreatic necrosis, and some authors therefore recommended the use of antifungal therapy for all patients receiving antibiotic

therapy for necrotizing pancreatitis.<sup>65</sup> Prophylactic use of the antifungals garlicin or fluconazole has been shown to reduce fungal infection in a randomized study in severe acute pancreatitis.<sup>77</sup> As the incidence of toxic side effects from fluconazole is relatively low, prophylactic antifungal treatment may be a useful addition to an antibiotic regimen in patients with necrotizing pancreatitis.

As recently as 2007, the trend to use prophylactic antibiotics in severe acute pancreatitis may have shifted again. In one prospective, randomized study of patients with severe acute pancreatitis<sup>78</sup> the use of imipenem early in the course of acute pancreatitis was associated with a reduced rate of septic complications, though there was no effect on need for interventions or mortality. In perhaps the most definitive study to date, Dellinger et al<sup>79</sup> showed in a randomized, prospective, multi-institutional, double-blind, placebo controlled study of 100 patients with confirmed necrotizing pancreatitis, that the use of meropenem had no impact on the rates of pancreatic or peripancreatic infection, intervention rate, or mortality. A more recent meta-analysis limited to randomized controlled trials<sup>80</sup> has also suggested that antibiotic prophylaxis does not reduce mortality or protect against infected necrosis or frequency of surgical intervention. With these new data, consensus among surgeons and pancreatologists in recent years has therefore changed to a general agreement that antibiotics should not be used solely in the prophylactic setting in necrotizing pancreatitis. While the authors endorse this position, in practice many patients are still exposed to broad-spectrum antibiotics due to sepsis from another source or treatment initiated prior to transfer from another institution. In all settings, we attempt to discontinue antibiotics in the absence of documented infection.

Since infection in necrotizing pancreatitis arises primarily from commensal organisms from the GI tract, some investigators have suggested using gut decontamination to reduce intestinal bacterial load and thereby prevent pancreatic infection. Limited laboratory evidence does support the use of gut decontamination to decrease mortality in experimental pancreatitis,<sup>81</sup> although the use of selective gut decontamination has only been reported in one clinical study. Luiten et al<sup>82</sup> randomized patients with severe acute pancreatitis to oral and rectal administration of nonabsorbable antibiotics. Mortality was decreased in the treatment group, predominantly via a reduction in late mortality and decrease in gram-negative pancreatic infection. However, patients also received a short course of IV antibiotics in the study, potentially confounding the results. Definitive recommendations regarding the use of gut decontamination await further studies.

## Surgical Management—Indications and Timing

In the majority of patients with acute pancreatitis, the process is limited to parenchymal edema without necrosis. These patients require surgical therapy for very limited indications;

specifically, intervention may be needed to address the etiology of pancreatitis or its complications. Interventions, either surgical or endoscopic, to prevent recurrent gallstone pancreatitis are recommended in any patient with suspected choledocholithiasis. Delayed surgery is also rarely needed for the delayed treatment of local complications such as pseudocysts. Patients with severe pancreatitis, however, may require surgical therapy as an integral part of their management. Between 10 and 30% of patients with pancreatitis develop severe illness, with pancreatic and peripancreatic necrosis and high associated morbidity and mortality.<sup>2</sup> The indications for surgical therapy with acute necrotizing pancreatitis have evolved in recent years. Prompt pancreatic debridement is the accepted standard of care for patients with infected pancreatic necrosis. As discussed later, an increasingly conservative surgical approach has been adopted in recent years toward the surgical management of patients with sterile pancreatic necrosis.

Occasionally, patients with severe disease may require urgent surgical intervention for reasons unrelated to their pancreatitis. For instance, at presentation, a surgical emergency such as perforated viscus may be suspected. Diagnostic laparotomy may be appropriate in such circumstances. A patient managed conservatively may also require exploration for subsequent development of other intra-abdominal pathology, such as abdominal compartment syndrome. In other patients with severe pancreatitis or pancreatic necrosis, three indications for surgical intervention remain (Table 54-4). The first, documented pancreatic infection, is not disputed. Whether (and when) to operate for severe sterile necrosis is controversial. Finally, delayed intervention with symptomatic organized necrosis is increasingly recognized as a valid indication for drainage or debridement.

### INFECTED PANCREATIC NECROSIS

The majority of deaths from acute pancreatitis occur in patients with infected pancreatic necrosis. The mortality rate is virtually 100% without intervention, although with appropriate surgical therapy it should approach the less than 15% mortality seen with sterile necrosis.<sup>4,35,83</sup> A minority of patients with infected pancreatic necrosis may demonstrate radiographic evidence of such, emphysematous pancreatitis, or intrapancreatic gas (see Fig. 54-3). In most patients, CT-guided

percutaneous FNA is needed to diagnose infection. As noted previously, both severe sterile necrosis and infected pancreatic necrosis are associated with significant leukocytosis and fever, making clinical distinction impossible. Patients with severe pancreatitis, organ failure, or those who fail to improve clinically in the first 2 weeks should be investigated for possible infected necrosis.

### SEVERE STERILE PANCREATIC NECROSIS

The presence of pancreatic necrosis was historically considered sufficient justification for open surgical pancreatic debridement. This practice was called into question in 1991 when Bradley and Allen<sup>62</sup> published a small series of 11 patients with sterile pancreatic necrosis managed nonoperatively. This concept was introduced with some resistance, as some authors have argued that all patients with pancreatic necrosis would benefit from debridement. Shortly after Bradley and Allen's study was published, Rattner et al suggested that early pancreatic debridement was beneficial in pancreatic necrosis regardless of the status of infection.<sup>84</sup> With increased experience using nonoperative management and FNA of the pancreatic necrosus, clinicians have become increasingly comfortable with conservative therapy in stable patients. The indications for surgery in patients with sterile necrosis have continued to be refined since that time. Numerous criteria for pancreatic debridement other than infection have been considered in the literature.<sup>85,86</sup> CT evidence of necrosis of more than 50% of the pancreas has been examined, but is insufficiently specific for use in decision making.<sup>86</sup> Other indices are no more predictive.<sup>87</sup> Series utilizing aggressive surgery regardless of pancreatic infection continue to be reported,<sup>83,88</sup> although most centers have increasingly managed sterile necrosis in a conservative manner.

Two large series have demonstrated the validity and analyzed the results of this approach. A group from Bern<sup>4</sup> prospectively studied 86 patients with necrotizing pancreatitis followed with a strict conservative protocol. In this cohort, the mortality rate was 10%, with only one patient undergoing operation in the absence of documented infection. A retrospective review from the Brigham and Women's Hospital analyzed 99 patients with CT-documented pancreatic necrosis (Fig. 54-5).<sup>35</sup> Six patients who had other reasons for surgery or who had their care withdrawn for severe underlying medical conditions were excluded from the analysis. Of the remaining 93 patients, 59 patients without infection were managed conservatively with 7 deaths (11%). Thirty-four patients underwent open or percutaneous therapy for infected necrosis, with a mortality rate of 12%. Thirty-five patients did not have sufficient evidence of infection to warrant FNA. These 35 recovered relatively rapidly, despite admission APACHE II scores similar to those who required further intervention. Overall these studies suggest that conservative strategies can be applied in most patients with necrotizing pancreatitis with reasonable outcomes. Furthermore, it is very difficult to prospectively identify which persons might benefit from a more aggressive strategy. A randomized controlled trial may be the only way



#### TABLE 54-4: INDICATIONS FOR SURGICAL INTERVENTION IN NECROTIZING PANCREATITIS

- Diagnostic uncertainty
- Intra-abdominal catastrophe unrelated to necrotizing pancreatitis such as perforated viscus
- Infected necrosis documented by FNA or extraluminal gas on CT
- Severe sterile necrosis
- Symptomatic organized pancreatic necrosis

FNA, fine-needle aspiration.

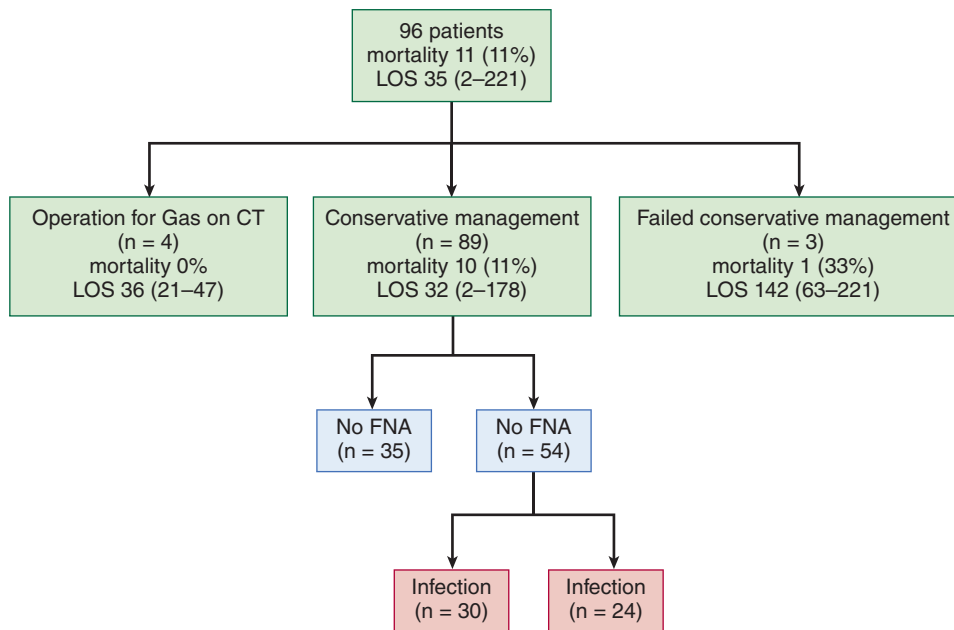


FIGURE 54-5 Management strategy in necrotizing pancreatitis utilized in Ashley et al.<sup>35</sup> (Reproduced from *Annals of Surgery* with permission.)

to definitively resolve this controversy, although the small number of patients with this condition may preclude meaningful conclusions. Whether surgical management is ever indicated in this patient population, and the precise timing of such intervention, continues to be a matter of debate.

While a conservative management strategy is widely accepted for stable patients, some debate continues regarding whether a subgroup of patients with presumed sterile pancreatic necrosis might be identified who would benefit from surgery. Of particular concern are the patients who appear increasingly ill and fail maximal medical management. Some clinical criteria have been suggested as possible markers to determine who might benefit from debridement in the absence of infection: extensive necrosis of over 50% of the gland, organ failure, and the systemic inflammatory response, response to therapy, and unresolving or new systemic inflammation. To date, however, while these are markers of prognosis and outcome, particularly the presence of organ failure, a reliable marker of which patients with severe sterile necrosis might benefit from surgical debridement remains elusive. Organ failure in particular is strongly linked to prognosis and in numerous studies is related to mortality rates of 30–60%. Rocha et al<sup>89</sup> recently demonstrated that organ failure in necrotizing pancreatitis is directly related to mortality, with increased mortality based on the number of organ systems that have failed. While organ failure is perhaps the most significant prognostic indicator with necrotizing pancreatitis, however, this has not proven useful in surgical decision making.

In regards to the early surgical debridement for patients with severe sterile necrosis and clinical deterioration, it is imperative to consider available data on the timing of surgical intervention in regards to perioperative mortality. Specifically, as outlined in a study by Mier and others<sup>90</sup> and confirmed in

numerous other studies, early surgical debridement, compared to delayed intervention, has much higher perioperative mortality. For the deteriorating, critically ill patient with organ failure taken emergently to the operating room for pancreatic debridement early in the course of illness, perioperative mortality is extremely high.

A further consideration regarding debridement for sterile pancreatic necrosis concerns the time-dependent nature of pancreatic infection. CT-guided FNA to diagnose infected pancreatic necrosis has become a very useful and commonplace tool in diagnosing infected necrosis, and data suggest that sensitivity, specificity, as well as positive and negative predictive values are reported to be in the mid-90% range.<sup>34</sup> As pancreatic infection is a time-dependent process, repeat FNA may be required to rule out occult infection and ensure true sterility of the pancreatic necrosus.<sup>35</sup>

Pancreatic infection remains the primary indication for pancreatic debridement, and surgical intervention for the most severe cases of pancreatitis remains controversial. Settings in which pancreatic debridement might be considered for severe sterile necrosis include (1) persistent signs of sepsis or organ failure after a prolonged resuscitation, but preferably at least 2 weeks after the onset of disease; (2) clinical deterioration of a patient after an initial period of stability with conservative management; and (3) infection strongly suspected clinically but confirmatory FNA not available, not feasible to perform, or felt to be unreliable. In practice, these indications should apply to a small minority of patients.

## ORGANIZED PANCREATIC NECROSIS

Despite increased acceptance among most authors of initial nonoperative management for sterile pancreatic necrosis, some



have emphasized the eventual need to operate on patients who do not clinically improve. Among patients managed nonoperatively for pancreatic necrosis, some experience persistent pain, malaise, and inability to eat. Warsaw<sup>91</sup> has described this phenomenon as “persistent unwellness.” The pathological correlate of the pancreas later in the course of the disease is what Baron et al<sup>92</sup> described as “organized pancreatic necrosis”; a process of maturation of the inflammatory tissue with improved demarcation from healthy pancreatic and peripancreatic tissue. As is the case with sterile necrosis in the acute setting, the indications for and timing of surgery for this group of patients has not been precisely defined.

Several nonrandomized studies have demonstrated significantly better outcomes in patients undergoing late versus early debridement,<sup>83,90</sup> and surgical debridement is considerably facilitated by the demarcation that occurs later in the course of pancreatic necrosis. In the above-mentioned series of 99 patients with pancreatic necrosis at the Brigham and Women’s Hospital, five patients underwent an operation for

this indication at a mean of 29 days (23–34) after presentation. This group accounted for approximately one-fifth of the patients who had undergone a negative CT-guided FNA.<sup>35</sup> All patients were debrided, and two were found to have an inflammatory process sufficiently mature to add cystogastrostomy after the debridement. All patients recovered well and were discharged at a mean of 27 (8–146) days after surgery. The optimal timing for surgery in this group is unclear; Fernandez-del Castillo et al<sup>83</sup> suggest that there is no added benefit in delaying longer than 4 weeks from the onset of illness. Such delayed procedures are an important part of a conservative management strategy that emphasizes nonoperative management for most cases of sterile necrosis and late operations if necessary.

An algorithm for management strategies in acute pancreatitis summarizing the principles discussed above is outlined in Fig. 54-6. For those patients requiring operative intervention, percutaneous drainage is increasingly employed as an adjunct to or in lieu of open surgical management.

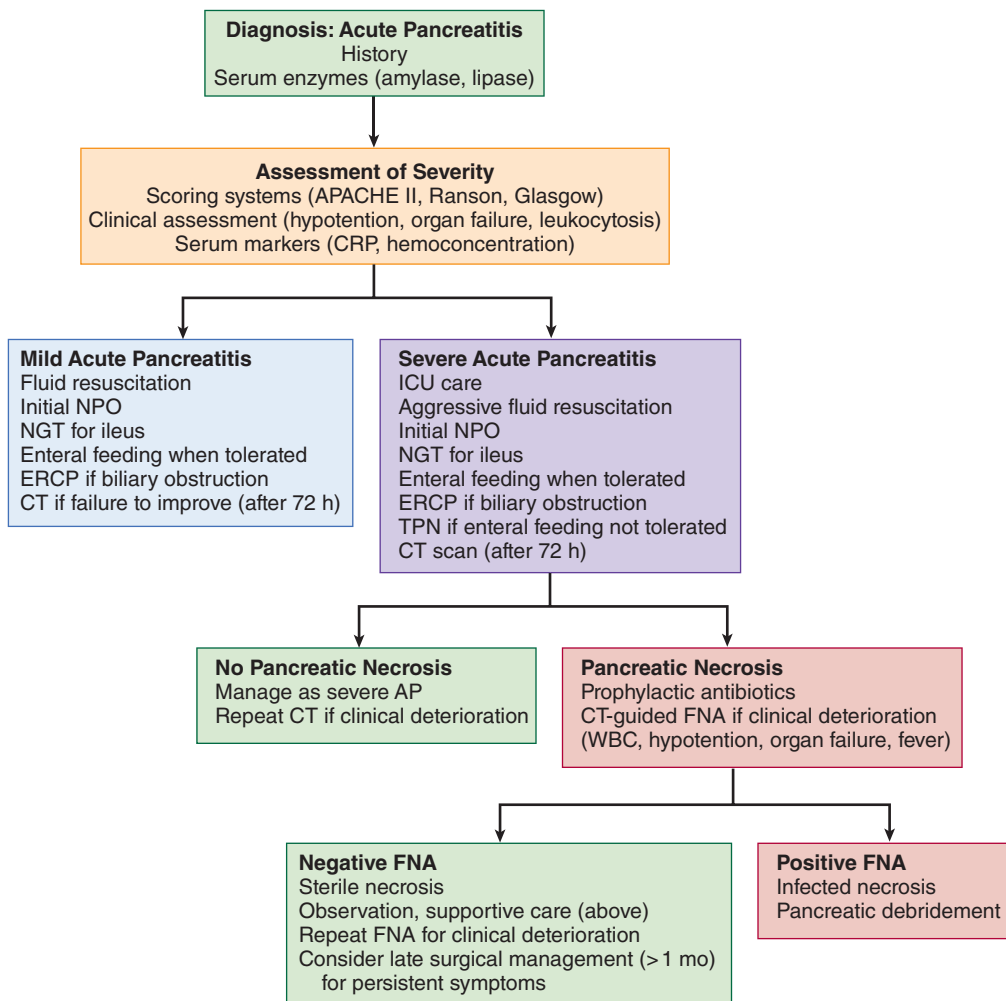


FIGURE 54-6 Management algorithm for acute pancreatitis. (Reproduced with permission from Clancy TE, Benoit EP, Ashley SW. Current management of acute pancreatitis. *J Gastrointest Surg.* 2005;Mar;9(3):440–452.)

## SURGICAL MANAGEMENT— PROCEDURES

Surgical therapy for acute pancreatitis may address either the etiology of pancreatitis or its complications. Operations addressing etiology are generally limited to interventions to eliminate cholelithiasis and thus eliminate gallstone pancreatitis. For patients with known gallstone pancreatitis, cholecystectomy is recommended after the resolution of pancreatic inflammation. Preoperative endoscopic examination of the common bile duct (CBD) is common in some institutions; if choledocholithiasis is detected on ERCP, endoscopic duct clearance is often attempted, with or without endoscopic papillotomy. In the absence of endoscopic interrogation and clearance of the biliary system, cholecystectomy should be combined with intraoperative cholangiogram, with or without CBD exploration.

The surgical management of the long-term complications of pancreatitis, such as pseudocysts and strictures, is addressed elsewhere. The primary surgical dilemma presenting in an

acute or subacute fashion is surgical management of necrotizing pancreatitis. Surgical strategies for approaching the necrotic pancreas are addressed below, with particular attention to strategies for pancreatic debridement and postdebridement management, and the use of minimally invasive techniques.

## Resection

Pancreatic resection for acute pancreatitis is primarily of historical interest only and is not currently recommended. Several authors in the 1960s and 1970s recommended partial or total pancreatectomy for pancreatitis based on the possibility that the remaining pancreas could be a source of persistent inflammation.<sup>93-95</sup> Operative mortality was as high as 60% in one series.<sup>95</sup> Although others have reported more acceptable mortality, conventional imaging and staging systems were not universally applied. In addition to the hazards posed by the dissection of a highly vascularized organ amidst an acute



**TABLE 54-5: PUBLISHED SERIES OF PANCREATIC DEBRIDEMENT; POSTDEBRIDEMENT MANAGEMENT WITH EITHER CLOSED PACKING, OPEN PACKING, OR CLOSED VOLUME AND LAVAGE. OPERATIVE MORTALITY IS LISTED AS WELL AS INCIDENCE OF REOPERATION, GI FISTULA, AND BLEEDING**

Author	n	Mortality	Reoperation	GI Fistula	Bleeding
<b>Closed Packing</b>					
Fernandez <sup>83</sup> (1998)	64	6.2%	17%	16%	1%
Hwang <sup>117</sup> (1995)	31	48%	—	3%	19%
Teerenhovi <sup>118</sup> (1989)	12	17%	25%	—	—
Pemberton <sup>103</sup> (1986)	64	44%	—	14%	31%
Warshaw <sup>99</sup> (1985)	45	24%	16%	26%	—
Aranha <sup>100</sup> (1982)	20	30%	40%	20%	—
<b>Open Drainage</b>					
Hwang <sup>117</sup> (1995)	40	15%	100%	10%	5%
Fugger <sup>119</sup> (1995)	72	25%	100%	26%	18%
Bradley <sup>102</sup> (1993)	71	14%	100%	5%	5%
Orlando <sup>120</sup> (1993)	15	20%	100%	26%	26%
Sarr <sup>98</sup> (1991)	23	17%	100%	35%	26%
Garcia <sup>121</sup> (1988)	49	27%	100%	0%	—
Wertheimer <sup>104</sup> (1986)	10	20%	100%	40%	20%
Pemberton <sup>103</sup> (1986)	17	18%	100%	31%	29%
<b>Closed Lavage</b>					
Branum <sup>88</sup> (1998)	50	12%	48%	16%	—
Hwang <sup>117</sup> (1995)	15	33%	—	7%	13%
Pederzoli <sup>122</sup> (1990)	191	10.5%	18%	—	—
Beger <sup>97</sup> (1991)	95	8.4%	27%	12%	5%
Villazon <sup>123</sup> (1991)	18	22%	— (2.6 op. per pt ave)	33%	6%
Nicholson <sup>124</sup> (1988)	11	27%	9%	9%	9%
Teerenhovi <sup>118</sup> (1989)	11	36%	64%	—	—
Larvin <sup>125</sup> (1989)	14	21%	—	43%	—

inflammatory process, resection risks overtreatment of many patients if performed for necrotizing pancreatitis. Viable tissue typically exists adjacent to necrotic tissue, and intraoperative differentiation between healthy pancreatic parenchyma and necrotic tissue can prove difficult. For instance, even with apparent total necrosis, the central pancreas surrounding the main pancreatic duct is often viable and is important for endocrine and exocrine function after resolution of the acute disease.<sup>96</sup> Resection would therefore inevitably risk the loss of viable, functioning parenchyma. Anatomic resection for pancreatitis, with or without associated pancreatic necrosis, is therefore thought to serve little utility and potentially may confer significant risk.

## Pancreatic Debridement

All techniques of pancreatic debridement and postdebridement care are based on two principles: first, wide removal of devitalized and necrotic tissue with thorough exploration and unroofing of all collections of solid and liquid debris; second, the assurance of postoperative removal of the products of ongoing local inflammation and infection which persist after debridement. Various techniques of open pancreatic debridement for necrotizing pancreatitis have been advocated in the literature.<sup>83,88,97,98</sup> While different approaches are fundamentally equal in terms of the method of debridement, postdebridement strategies differ considerably. Debridement with closure over drains, debridement with open packing, or debridement with closure over irrigation drains and postoperative lavage are the three methods commonly reported. Mortality and complication rates for several published series, representing each postoperative strategy, are shown in Table 54-5. Reported morbidity and mortality across these studies varies widely; however, comparisons between different studies are difficult given a lack of standardization in disease severity or criteria used for operative management.

Further complicating any comparison between studies is the relative lack of standard definitions in the earlier literature; many cases of pancreatic necrosis were likely incorrectly considered “pancreatic abscess.” Over the past decade there has been increased precision in the definitions used to describe local complications of acute pancreatitis. As noted earlier, the definitions proposed at the 1992 International Symposium on Acute Pancreatitis in Atlanta (see Table 54-3) have proven useful for comparing data between studies and for standardizing treatment indications. However, these standards have only recently been applied and are not universally utilized. As a result of this lack of standardization and other difficulties listed earlier, recommendations for techniques of debridement and postdebridement management have not been uniform in the literature. No method is universally accepted, and the techniques have not been adequately compared in a randomized prospective fashion. The method of postdebridement management used may be tailored to individual patients, and each method may have a role under specific circumstances.

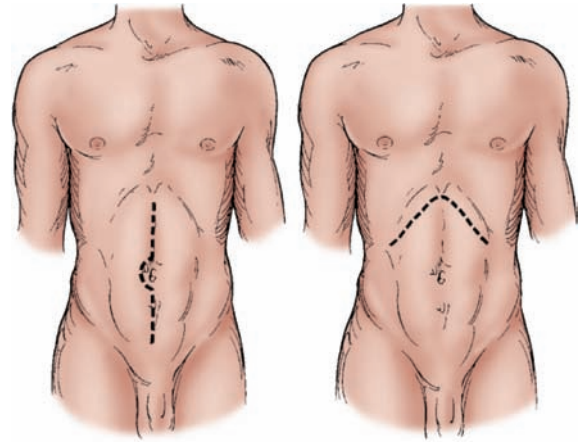


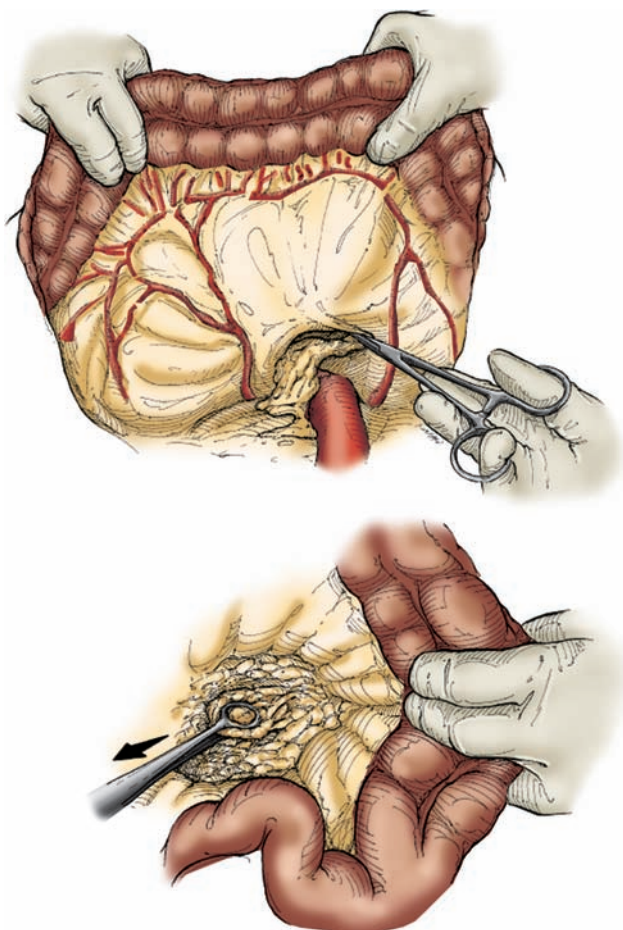
FIGURE 54-7 Operative approaches to open pancreatic debridement. Either a midline or bilateral subcostal approach is acceptable.

## Technique of Debridement

Prior to surgical debridement, accurate preoperative imaging is essential. It is of paramount importance to identify all areas of necrosis or fluid collections to properly guide surgical exploration. To achieve this, a high-quality CT scan with IV contrast enhancement is essential to identify areas of pancreatic or peripancreatic tissue requiring drainage. Exploration of the pancreatic bed may be initiated via either a bilateral subcostal or midline incision (Fig. 54-7). The pancreatic bed and lesser sac may be approached either through the gastrocolic ligament or through the transverse mesocolon. Some authors<sup>83</sup> have strongly advocated an approach to the lesser sac via the left side of the transverse mesocolon to avoid the dense inflammatory process that can obscure tissue planes between the stomach and transverse colon (Fig. 54-8). If the anatomic plane between the stomach and colon is obliterated by inflammation, the transmesocolic approach avoids inadvertent injury to these structures. The middle colic vessels present a potential anatomic barrier to the transmesocolic approach, although these vessels are often thrombosed in the setting of necrotizing pancreatitis. If patent, these vessels may often be interrupted without consequence as the colon is supplied with collateral vasculature. An additional advantage of the transmesocolic approach is that drains may be placed in a dependent position after debridement. Other investigators have advocated an approach to the lesser sac via the gastrocolic ligament (Fig. 54-9), for the primary reason that the inframesocolic space is typically uninvolved with peripancreatic inflammation and infection, and transmesocolic exposure renders the remainder of the abdomen to this inflammatory process.<sup>88</sup>

Pancreatic debridement is accomplished bluntly, primarily using finger dissection. The differentiation between necrotic tissue, which has a looser consistency, and viable tissue, which is firm, is often best made by palpation. Necrotic tissue should separate easily from the surrounding tissue, without extensive dissection. While complete





**FIGURE 54-8** Transmesocolic approach to the lesser sac. The necrotic pancreas is approached through the transverse mesocolon, to the left of the middle colic artery.

debridement is essential, efforts should be made to avoid overzealous handling of inflamed tissue, which encourages bleeding. Debridement should therefore be limited to all clearly necrotic tissue that is easily separable from surrounding structures. All fluid as well as necrotic tissue is sent for aerobic and anaerobic culture. Hemorrhage from diffuse oozing from inflamed retroperitoneal tissues is not uncommon; hemostasis may require packing of the cavity. Rapid hemorrhage from the intraoperative rupture of a major blood vessel, such as the splenic artery or vein, may require suture ligation. Precise vascular control in an inflamed tissue field can prove difficult if not impossible. If such is the case, hemostasis may require prolonged manual compression and possibly multiple sutures.

As the inflammatory mass is exposed during the course of the debridement, it may become necessary to extend the intra-abdominal dissection to fully expose all necrotic tissue. A complete search for and identification of all necrotic foci must take place. For necrosis of the head, improved exposure may be achieved either through the right side of

the mesocolon or via an approach posterior to the second and third portions of the duodenum. Additional exposure may also entail a release of the hepatic and splenic flexures of the colon. Thorough exposure of all necrotic tissue may involve opening both paracolic gutters, the pararenal spaces, the retroperitoneum into the pelvis, or the gastrohepatic omentum.

## DEBRIDEMENT AND CLOSED DRAINAGE

Several authors have demonstrated very favorable results with debridement and closed drainage.<sup>83,99</sup> Proponents of this technique stress that the presence of residual necrotic pancreatic tissue is the most important factor dictating the need for subsequent re-explorations, each of which is associated with some morbidity and mortality. For this reason, the completeness of the initial debridement is the most crucial factor in avoiding subsequent re-explorations. In contrast to the open packing technique, a concerted effort is made to perform a complete debridement and drainage of fluid collections at the first surgical procedure. All necrotic tissue is debrided unless it is densely adherent to vital structures, and all spaces involved on preoperative imaging are opened and debrided.

Debridement is followed with gentle irrigation (Fig. 54-10). The cavities left after debridement are drained with either closed-suction drains or Penrose drains stuffed with gauze. All drains are brought out through separate stab wounds in the abdomen. The placement of enteral feeding or drainage tubes (gastrostomy, jejunostomy) is optional. Drains are removed one at a time beginning 6–10 days after surgery in an effort to allow the cavity to collapse. If Penrose and closed-suction drains are used together, closed-suction drains are removed last, and only when their output is minimal.

In some cases, complete debridement is not possible during the first exploration. If hemodynamic instability or coagulopathy prohibit further debridement, temporary closure is achieved after packing the necrotic cavity with Mikulicz's pads and placing drains; repeat procedures may occur in 24–48 hours, along with additional procedures such as gastrostomy or jejunostomy.

Reported mortality for debridement and closure over drains has been as high as 40%. Recurrent pancreatic infection is an acknowledged complication of this technique, with early series reporting a recurrence rate of 30–40%.<sup>100</sup> However, a more recent series has reported significantly better results, with mortality of 6.2%.<sup>83</sup> In this series, an additional operation was required in 17% of patients, most of whom had persistent infected pancreatic necrosis. In addition, 20% required postoperative image-guided drainage of residual or recurrent fluid collections. Overall, 69% required only one operation without further procedures.<sup>83</sup> The reported success of this procedure, and rate of recurrence, is attributed to thorough surgical debridement, with maximal removal of necrotic tissue at the first operation.

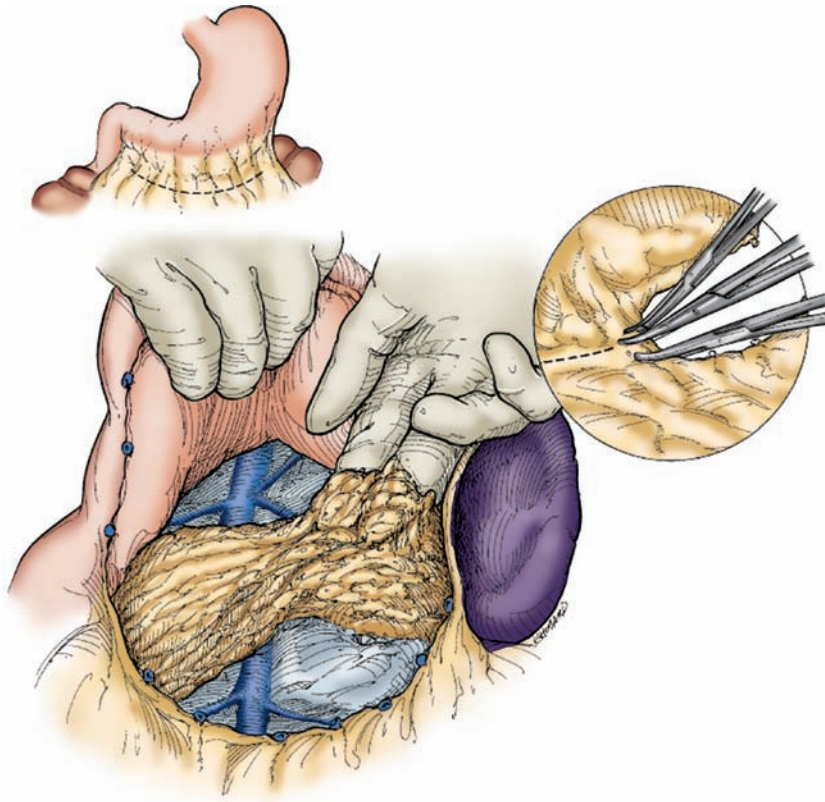


FIGURE 54-9 Approach to lesser sac via gastrocolic ligament.

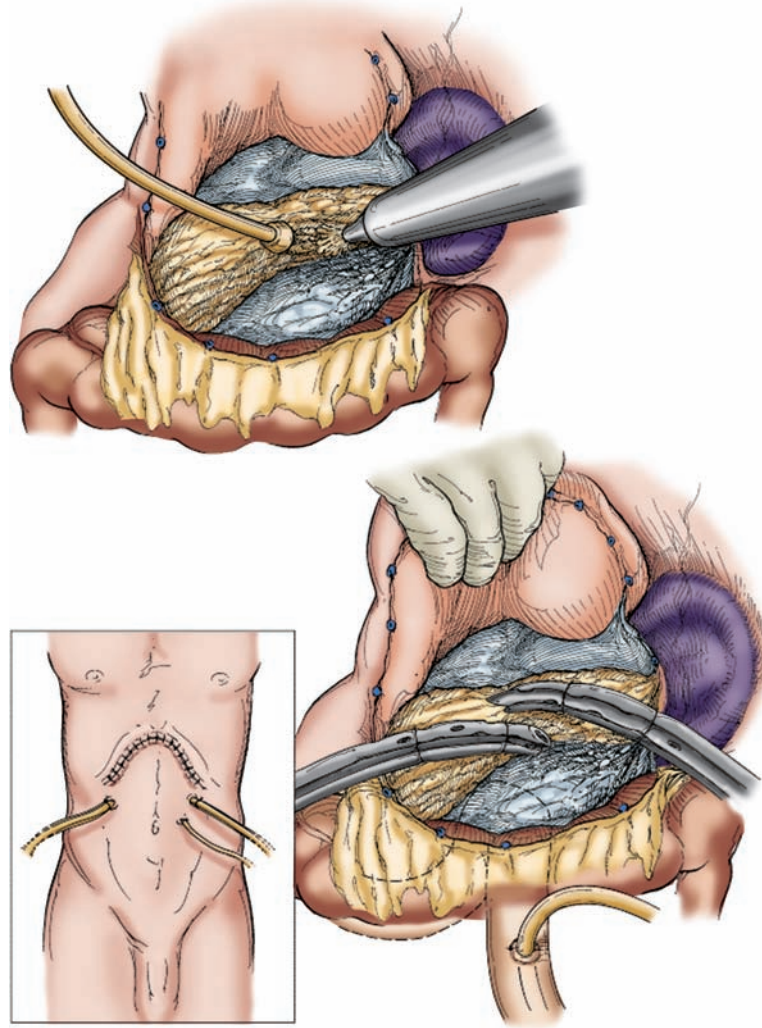
### OPEN DRAINAGE (MARSUPIALIZATION) FOR PANCREATIC NECROSIS

As mentioned earlier, a recognized complication after an apparently adequate pancreatic debridement is recurrent pancreatic sepsis. While most necrotic debris is easily separated from surrounding structures, some borderline tissue may not be so easily debrided. Presumably, pancreatic necrosis is an ongoing process, and further demarcation of necrotic tissue after an initial debridement can result in a mass of particulate matter that is inadequately removed by sump drainage. Furthermore, the persistence of necrotic tissue is combined with the persistent postoperative leakage of activated pancreatic enzymes from the necrotic and inflamed tissue into the retroperitoneum. This combination of necrotic material and chemical inflammation may be responsible for the occasional failure of simple debridement and drainage. For this reason, some authors have advocated a process of open packing, or “marsupialization,” by which recurrent pancreatic debridement is facilitated.<sup>101</sup>

The surgical approach is typically a left subcostal incision, which is easily extended to a bilateral subcostal incision should additional exposure be necessary. This transverse incision is optimally situated above a transverse opening in the gastrocolic omentum to facilitate open packing. Advocates

of open packing have preferred to access the lesser sac via the gastrocolic ligament, which may provide a more direct access to the entire pancreatic bed for future packing. Pancreatic debridement using blunt finger dissection is employed, with wide exposure of all areas of retroperitoneal necrosis. However, unlike procedures with planned closed packing, no effort should be made to remove every identifiable piece of necrotic tissue at the first procedure; rather, only tissues that are easily separated by blunt dissection should be dissected. Complete removal of all necrotic tissue is accomplished by multiple re-explorations and blunt debridements, limiting blood loss.

After debridement, the stomach and colon may be covered with a nonadherent gauze to prevent debridement of healthy tissue during dressing changes. This constructs a cone or cylinder with the pancreas at the base. Laparotomy pads or other gauze may be placed directly within this area, and some authors have recommended presoaking these packs in iodinated solutions. Some surgeons will suture the gastrocolic ligament to the skin, creating an inverted cone with the base consisting of the divided gastrocolic ligament at the skin level and the point at the pancreatic bed. However, in the setting of acute inflammation this cavity may be ill-defined, and suturing to the skin is generally not necessary. No attempts are usually made to close the fascia or skin, although occasionally



**FIGURE 54-10** Irrigation and drainage of pancreatic bed. Drainage tubes are used for technique of closed drainage or postoperative saline lavage; for open packing technique, pancreatic bed is packed with sterile bandages.

a small number of extraperitoneal stay sutures of nylon may be loosely tied to discourage evisceration. This results in an open communicating defect for packing. Alternatively, some have used a separate retroperitoneal incision through which to bring packs, closing the abdominal incision. This method likely provides inferior access for future debridements.

Planned re-explorations are performed in the operating room at 2–3 day intervals for additional debridement. When retroperitoneal granulation tissue begins to form, daily dressing changes may be performed in the ICU utilizing mild sedation and/or pain control. Although the majority of necrotic tissue is debrided with the first effort, significant amounts of tissue may be removed at the fourth or even fifth debridement procedure.<sup>102</sup>

After debridement has been achieved by open packing, the abdominal wound may either be left to heal entirely by secondary intention, or may undergo delayed primary closure.

In some cases, the open packing procedure may be combined with delayed closure over lavage catheters and continuous closed lavage of the lesser sac and abscess cavity. Catheters are gradually withdrawn over weeks after it is demonstrated that there is no pancreatic fistula.

### Debridement and Continuous Closed Postoperative Lavage of the Lesser Sac

After an initial pancreatic debridement, small amounts of residual necrotic tissue are inevitably present. Furthermore, the persistent soilage of the retroperitoneum with pancreatic enzymes and inflammatory mediators may also contribute to persistent systemic inflammation and sepsis. Removal of residual necrotic tissue, bacteria, and biologically active substances is therefore proposed to decrease persistent inflammation.



While some have advocated open packing and planned repeated operations to accomplish this goal, others report success with continuous postoperative high-volume lavage of the lesser sac.<sup>96</sup> Even an aggressive initial debridement is therefore not considered an end in itself, but rather the first step of a thorough washout of the pancreatic bed.

Beger et al have written extensively on the procedure of debridement and continuous closed postoperative lavage.<sup>97</sup> With this technique, pancreatic debridement is performed in the standard fashion. Postoperative lavage is facilitated by the insertion of two to five large double-lumen tubes. After drain placement, the gastrocolic ligament may be sutured to form a closed compartment in the lesser sac. Continuous lavage is undertaken with hyperosmolar, potassium-free dialysate at approximately 2 L/h, although irrigation with normal saline is also employed.<sup>96</sup> Branum et al<sup>88</sup> describe the completion of one or more debridements, followed by the placement of multilumen sump drains for postoperative irrigation. Irrigation continues until the effluent is free of particulate matter. These drains are gradually downsized and eventually withdrawn.

Beger et al have published an overall operative mortality of 10.6% with this procedure, and a mortality of 15% when the procedure is performed for infected pancreatic necrosis. These authors and others have argued that using postoperative continuous lavage results in decreased rates of postoperative pancreatic sepsis compared to closed drainage techniques, and the incidence of postoperative complications such as incisional hernia and GI fistulas is said to be less than that with open packing and repeated debridement.

## Comparison of Techniques Used in Pancreatic Debridement

As noted earlier, the benefits of various techniques of pancreatic debridement and postdebridement care have been debated in the literature. No strict criteria have been proposed to adequately select patients for different procedures, and the optimal method of debridement has not been examined in a prospective fashion. A number of case series have been reported in which patients with either pancreatic necrosis or severe acute pancreatitis have undergone pancreatic debridement followed by either closure over drains, open packing and redebridement, or closure over lavage catheters with postoperative continuous lavage (see Table 54-5). As seen in this table, reports of postoperative complications and mortality vary widely across different studies. Comparisons between these different studies can prove difficult for several reasons. Preoperative disease severity is difficult to standardize across different reports, as are the criteria for operative management employed. Earlier studies did not employ currently accepted criteria of disease severity, and the presence of pancreatic infection is not universally documented via preoperative studies. The various methods of pancreatic debridement have not been compared in a prospective, randomized fashion.

One small single-institution retrospective study compared surgical outcomes in 86 patients with acute pancreatitis after debridement and closed drainage, debridement with open packing, or debridement with continuous closed postoperative lavage. Patients were noted to have similar preoperative Ranson's scores. Mortality was significantly higher after closed drainage (48.4%), compared to 15% following open packing, and complications were not significantly different between the groups. However, as pancreatic necrosis and the time of operation are not documented, it is not clear that these results are applicable to current practice.

Several series in the literature have quoted a high rate of recurrent pancreatic sepsis and high rate of reoperation when the technique of debridement and closure over drains is used.<sup>88</sup> Bradley has quoted a rate of re-exploration for recurrent sepsis in 30–40% of patients,<sup>102</sup> and a review of large series suggests that the majority of postoperative deaths after closed drainage are due to persistent or recurrent infection.<sup>55</sup> These figures have been used to argue for either repeated pancreatic debridement via open packing or for continuous postoperative pancreatic lavage. However, the Massachusetts General Hospital experience with the closed drainage technique reports a mortality of 6.2%, the lowest reported mortality rate in any series of pancreatic debridement for pancreatic necrosis.<sup>83</sup>

Bradley reports a favorable mortality rate of 14% for the technique of open packing.<sup>102</sup> Given a need for reoperation in up to 30–40% of patients after closed drainage or high-volume lavage, an argument is then made for controlled, planned re-exploration to achieve thorough debridement. Others have suggested that the open packing technique might be particularly useful in patients with a larger mass of necrotic tissue.<sup>103</sup> However, postoperative morbidity can be considerable with the open packing technique. Bradley has reported a rate of incisional hernia of 23% after open packing.<sup>102</sup> Though this complication is not widely reported in other series, one other has reported a hernia rate of 80%.<sup>104</sup> An increased rate of GI fistulas has been reported in some series of open packing, although a brief review of published series shows that this complication is not universal. As with other complications, however, the precise definition of GI fistula is not clarified in different series. Length of hospital stay, which is not commonly reported in different series, has been suggested to be prolonged after open packing.<sup>105</sup>

The recent trend toward delayed surgical therapy for pancreatic necrosis may facilitate atraumatic debridement, as necrosis becomes increasingly organized and demarcated from viable tissue over time.<sup>92</sup> Some investigators have suggested that a policy of delayed exploration and debridement may therefore facilitate closed drainage without packing or postoperative lavage. In the previously mentioned 2001 series of 99 patients with pancreatic necrosis managed conservatively at the Brigham and Women's Hospital, operation was offered only for documented infection or for sterile pancreatic necrosis with persistent systemic illness. In this series, Ashley et al demonstrated that most patients were managed with closed drainage.<sup>35</sup> The mean interval from presentation to surgery



was 27 days. Of these patients, 31 (86%) were managed with debridement and closure over drains, 1 received postoperative irrigation, and 4 required open packing and planned re-exploration. Nineteen patients (34%) developed complications, including 9% each with pancreatic or enteric fistulas, and 15% with endocrine or exocrine insufficiency. Of patients managed with closure over drains, only four (13%) needed re-exploration due to inadequate persistent illness and presumed inadequate debridement. We continue to believe that each technique has its place. When early operation is mandated, open packing or lavage may be necessary to deal with the consequences of ongoing necrosis. If operation can be delayed, debridement with closed drainage and sometimes even internal drainage may be adequate.

### Minimally Invasive Approaches

Although mortality after open pancreatic debridement has decreased in recent years, many series still demonstrate a mortality rate of approximately 15%; in addition, the mortality in patients with established organ failure may exceed 75%.<sup>106</sup> Open approaches are often associated with initial postoperative deterioration, requiring intensive physiological support. Given the considerable morbidity, organ failure, and mortality associated with traditional open pancreatic debridement, some investigators have suggested that minimally invasive surgical procedures may be used successfully with pancreatic necrosis. Avoiding open debridement has the theoretical advantage of minimizing activation of systemic inflammatory processes and reducing respiratory and wound complications.

In recent years there has been a proliferation of reports describing minimally invasive approaches in necrotizing pancreatitis.<sup>107</sup> Percutaneous, endoscopic, and laparoscopic techniques have all been described. Solid pancreatic debris has traditionally been thought to be too thick for adequate evacuation with percutaneous drains; still, small studies have demonstrated success with percutaneous catheter drainage as a primary treatment for infected pancreatic necrosis. Several series of successful percutaneous management in infected pancreatic necrosis have been reported in the literature.<sup>108–110</sup> For instance, Freeny et al<sup>108</sup> successfully managed 16 of 34 such patients with an aggressive protocol of percutaneous drainage. This required a mean of four catheter insertions and lavage for a mean of 85 days. In nine other patients, percutaneous intervention was not the sole means of therapy but allowed eventual open surgical intervention to be delayed. Thus, combined with the 52% of patients requiring elective or emergency surgery, approximately 75% of patients subsequently needed surgical intervention.<sup>106</sup> It is possible that percutaneous drainage in this case functioned just to delay an operation and prevent the need for laparotomy during the most acute phase of the illness. The concept that percutaneous drainage of infected necrosis may delay the need for early intervention, permitting surgery once the process has become more organized, is appealing but needs further validation. A recent study by Rocha et al<sup>89</sup> in which 28 patients

with necrotizing pancreatitis were managed using percutaneous drainage found no clear improvement in overall mortality with catheter drainage. The overall role of percutaneous catheter drainage in the management of necrotizing pancreatitis remains undefined.

An often-unstated principle of therapy for pancreatic necrosis in the past has been the need to externally drain the pancreatic bed. Necrotic tissue, pancreatic enzymes, bacteria, and inflammatory mediators in the infected milieu of the necrotic pancreas were all thought to be best drained outside the body. The concept of internal drainage, whereby inflammatory tissue and fluid is drained to the GI tract directly, has only recently been considered to be feasible. In this regard, some investigators have suggested endoscopic therapy for pancreatic necrosis, and have recently summarized the results.<sup>111</sup> Forty-four patients with pancreatic necrosis were treated for suspected or documented infection, or for intractable symptoms from organized necrosis including nausea, pain, or early satiety. Endoscopic transmural drainage was successful in 31 (72%) patients with pancreatic necrosis, although 9 (29%) experienced recurrence and 16 (37%) experienced complications. Transmural drainage was more successful with central rather than peripheral necrosis due to close proximity of the necrotic area to the gastric wall. Subsequent analysis has suggested that collections with solid debris of more than 1 cm are not suitable for endoscopic drainage.<sup>112</sup> In addition, up to 60% of patients successfully drained developed more collections over a 2-year period.

Seifert et al<sup>113</sup> have described a method of retroperitoneal endoscopy via transgastric fenestration. Direct visual access to retroperitoneal collections is thereby obtained to allow optimal drainage. Few patients have been described using this method, and larger studies are necessary to validate this approach. These techniques were also not always performed for infected pancreatic necrosis. Of concern is the certainty that if sterile retroperitoneal collections are accessed via the GI tract, these collections soon become contaminated with commensal GI flora.<sup>114</sup> Inadequate drainage after endoscopic intervention clearly has the ability to complicate a troublesome but not life-threatening collection.

Various techniques of minimally invasive surgery have been adopted to treat pancreatic necrosis. One method employed with several variations can be considered the "video-assisted retroperitoneal debridement" method. Gambiez et al<sup>115</sup> have suggested using a retroperitoneal approach via dorsal lumbarotomy and a 23 cm endoscope to explore and drain the peripancreatic area; necrotic peripancreatic tissue could be removed by blunt dissection and drains may be left for irrigation. These authors have employed this technique, repeating debridements at regular 5-day intervals until the resolution of necrotic debris, with a mean of five procedures. Purported advantages of this technique include an avoidance of peritoneal contamination, though extraction of the pancreatic necrosus is limited by the diameter of the retroperitoneal instrumentation. Furthermore, in the series reported by Gambiez et al,<sup>115</sup> subsequent laparotomy was required in just two patients for persistent collections. Overall mortality in

20 patients with infected pancreatic necrosis was 10%, which compares favorably with historical controls.

Percutaneous necrosectomy and sinus tract endoscopy are techniques described by Carter et al<sup>116</sup> for minimally invasive debridement of the necrotic pancreas. Briefly, methods borrowed from percutaneous nephroscopy are utilized to directly visualize the retroperitoneum. Under CT guidance an 8F pigtail catheter is advanced into the pancreatic cavity, either between the lower pole of the spleen and the splenic flexure, or, for right-sided necrosis, through the gastrocolic omentum anterior to the duodenum. The cavity is accessed in the operating room under fluoroscopic guidance; the catheter tract is serially dilated, first manually then with a balloon dilator, until a 34F sheath is accepted. An operating nephroscope may then be passed to the cavity, allowing irrigation, suction, and piecemeal removal of necrotic debris. Devitalized tissue is easily identified and may be removed by gentle traction in a piecemeal fashion. Large drains may be placed through the same access sites to allow postoperative drainage and/or lavage. Planned second-look procedures may be performed every 7–10 days, until the cavity is clean. The technique of sinus tract endoscopy employs similar methods to inspect, debride, and drain residual collections after an initial open debridement. These techniques may achieve adequate debridement and drainage and/or lavage of the pancreatic bed. Carter et al,<sup>116</sup> in an initial report with only 10 patients, report a mortality that was 20%. However, postoperative organ dysfunction was minimized, and the majority of patients were managed outside of the ICU postoperatively.

The use of minimally invasive techniques can undoubtedly reduce the severity of systemic sepsis and organ dysfunction associated with open pancreatic debridement. The primary risk of these procedures is an inadequate debridement of solid necrosus and inadequate drainage of the pancreatic bed. No randomized studies exist to compare these techniques to traditional open debridement. Furthermore, studies are difficult to compare given small sample size, the retrospective nature of reports, and varying comorbidities and selection criteria. For the current time, open surgical debridement continues to be the “gold standard” treatment for surgical management of pancreatic necrosis. However, as management strategies become more nonoperative, it is likely that minimally invasive and percutaneous techniques will play an increasing role in the treatment of pancreatic necrosis in the future.

## SUMMARY

While the treatment of mild pancreatitis has changed little in recent years, advances in the management of severe pancreatitis have been associated with significantly reduced morbidity and mortality. Improvements in the recognition of severe disease with scoring systems and serial CT scanning has allowed early goal-directed therapy in appropriate patients. Timely resuscitation and invasive monitoring are standard, and there is an increased recognition of the role of prophylactic antibiotics for pancreatic necrosis and image-guided FNA

to diagnose infection. While the need for aggressive intervention in infected pancreatic necrosis remains unchanged, initial conservative management of most patients with sterile pancreatic necrosis has gained widespread acceptance. Some patients with sterile necrosis may eventually require delayed debridement either for persistent systemic illness or failure to thrive, although accurate prospective identification of these patients has not been possible. For patients needing debridement, open surgical techniques remain the “gold standard” of management. Advances in minimally invasive technology hold promise as adjuncts to open procedures in the future, particularly as a means of delaying surgery to facilitate debridement when the necrotic pancreas becomes more organized.

## REFERENCES

1. Banks PA. Acute pancreatitis: medical and surgical management. *Am J Gastroenterol.* 1994 Aug;89(8 suppl):S78–S85.
2. Beger HG, Rau B, Mayer J, Pralle U. Natural course of acute pancreatitis. *World J Surg.* 1997 Feb;21(2):130–135.
3. Yousaf M, McCallion K, Diamond T. Management of severe acute pancreatitis. *Br J Surg.* 2003 Apr;90(4):407–420.
4. Buchler MW, Gloor B, Muller CA, Friess H, Seiler CA, Uhl W. Acute necrotizing pancreatitis: treatment strategy according to the status of infection. *Ann Surg.* 2000 Nov;232(5):619–626.
5. Clancy TE, Ashley SW. Current management of necrotizing pancreatitis. *Adv Surg.* 2002;36:103–121.
6. Sakorafas GH, Tsiotou AG. Etiology and pathogenesis of acute pancreatitis: current concepts. *J Clin Gastroenterol.* 2000 Jun;30(4):343–356.
7. Kazmierczak SC, Catrou PG, Van Lente F. Diagnostic accuracy of pancreatic enzymes evaluated by use of multivariate data analysis. *Clin Chem.* 1993 Sep;39(9):1960–1965.
8. Sternby B, O'Brien JF, Zinsmeister AR, DiMagno EP. What is the best biochemical test to diagnose acute pancreatitis? A prospective clinical study. *Mayo Clin Proc.* 1996 Dec;71(12):1138–1144.
9. Clavien PA, Robert J, Meyer P, et al. Acute pancreatitis and normoamylasemia. Not an uncommon combination. *Ann Surg.* 1989 Nov;210(5):614–620.
10. Derveniz C, Johnson CD, Bassi C, et al. Diagnosis, objective assessment of severity, and management of acute pancreatitis. Santorini consensus conference. *Int J Pancreatol.* 1999 Jun;25(3):195–210.
11. Baron TH, Morgan DE. Acute necrotizing pancreatitis. *N Engl J Med.* 1999 May 6;340(18):1412–1417.
12. Lerch MM, Hernandez CA, Adler G. Acute pancreatitis. *N Engl J Med.* 1994 Oct 6;331(14):948–949.
13. Ranson JH, Rifkind KM, Roses DE, Fink SD, Eng K, Spencer FC. Prognostic signs and the role of operative management in acute pancreatitis. *Surg Gynecol Obstet.* 1974 Jul;139(1):69–81.
14. Blamey SL, Imrie CW, O'Neill J, Gilmour WH, Carter DC. Prognostic factors in acute pancreatitis. *Gut.* 1984 Dec;25(12):1340–1346.
15. Eachempati SR, Hydo LJ, Barie PS. Severity scoring for prognostication in patients with severe acute pancreatitis: comparative analysis of the Ranson score and the APACHE III score. *Arch Surg.* 2002 Jun;137(6):730–736.
16. Connor S, Ghaneh B, Raraty M, et al. Increasing age and APACHE II scores are the main determinants of outcome from pancreatic necrosectomy. *Br J Surg.* 2003 Dec;90(12):1542–1548.
17. Williams M, Simms HH. Prognostic usefulness of scoring systems in critically ill patients with severe acute pancreatitis. *Crit Care Med.* 1999 May;27(5):901–907.
18. Triester SL, Kowdley KV. Prognostic factors in acute pancreatitis. *J Clin Gastroenterol.* 2002 Feb;34(2):167–176.
19. Brown A, Orav J, Banks PA. Hemoconcentration is an early marker for organ failure and necrotizing pancreatitis. *Pancreas.* 2000 May;20(4):367–372.
20. Lankisch PG, Mahlke R, Blum T, et al. Hemoconcentration: an early marker of severe and/or necrotizing pancreatitis? A critical appraisal. *Am J Gastroenterol.* 2001 Jul;96(7):2081–2085.

21. de Beaux AC, Goldie AS, Ross JA, Carter DC, Fearon KC. Serum concentrations of inflammatory mediators related to organ failure in patients with acute pancreatitis. *Br J Surg*. 1996 Mar;83(3):349–353.
22. Pezzilli R, Billi P, Miniario R, et al. Serum interleukin-6, interleukin-8, and beta 2-microglobulin in early assessment of severity of acute pancreatitis. Comparison with serum C-reactive protein. *Dig Dis Sci*. 1995 Nov;40(11):2341–2348.
23. Kylanpaa-Back ML, Takala A, Kempainen EA, et al. Procalcitonin, soluble interleukin-2 receptor, and soluble E-selectin in predicting the severity of acute pancreatitis. *Crit Care Med*. 2001 Jan;29(1):63–69.
24. Tenner S, Fernandez-del Castillo C, Warshaw A, et al. Urinary trypsinogen activation peptide (TAP) predicts severity in patients with acute pancreatitis. *Int J Pancreatol*. 1997 Apr;21(2):105–110.
25. Neoptolemos JP, Kempainen EA, Mayer JM, et al. Early prediction of severity in acute pancreatitis by urinary trypsinogen activation peptide: a multicentre study. *Lancet*. 2000 Jun 3;355(9219):1955–1960.
26. Kempainen E, Mayer J, Puolakkainen P, Raraty M, Slavin J, Neoptolemos JP. Plasma trypsinogen activation peptide in patients with acute pancreatitis. *Br J Surg*. 2001 May;88(5):679–680.
27. Mofidi R, Duff MD, Wegmore SJ, et al. Association between early systemic inflammatory response, severity of multiorgan dysfunction and death in acute pancreatitis. *Br J Surg*. 2006;93(6):738–744.
28. Radenkovic D, Bajec D, Ivancevic N, et al. D-Dimer in acute pancreatitis. A new approach for an early assessment of organ failure. *Pancreas*. 2009;38(6):655–660.
29. Balthazar EJ, Ranson JH, Naidich DP, Megibow AJ, Caccavale R, Cooper MM. Acute pancreatitis: prognostic value of CT. *Radiology*. 1985 Sep;156(3):767–772.
30. Balthazar EJ, Robinson DL, Megibow AJ, Ranson JH. Acute pancreatitis: value of CT in establishing prognosis. *Radiology*. 1990 Feb;174(2):331–336.
31. Bradley EL, 3rd. A clinically based classification system for acute pancreatitis. Summary of the International Symposium on Acute Pancreatitis, Atlanta, GA, September 11 through 13, 1992. *Arch Surg*. 1993 May;128(5):586–590.
32. Arvanitakis M, Delhay M, De Maertelaere V, et al. Computed tomography and magnetic resonance imaging in the assessment of acute pancreatitis. *Gastroenterology*. 2004 Mar;126(3):715–723.
33. Schmidt J, Hotz HG, Foitzik T, et al. Intravenous contrast medium aggravates the impairment of pancreatic microcirculation in necrotizing pancreatitis in the rat. *Ann Surg*. 1995 Mar;221(3):257–264.
34. Banks PA, Gerzof SG, Langevin RE, Silverman SG, Sica GT, Hughes MD. CT-guided aspiration of suspected pancreatic infection: bacteriology and clinical outcome. *Int J Pancreatol*. 1995 Dec; 18(3):265–270.
35. Ashley SW, Perez A, Pierce EA, et al. Necrotizing pancreatitis: contemporary analysis of 99 consecutive cases. *Ann Surg*. 2001 Oct;234(4):572–579; discussion 579–580.
36. Bollen TL, van Santvoort HC, Besselink MG et al. The Atlanta Classification of acute pancreatitis revisited. *Br J Surg*. 2008;95(1):6–21.
37. Vege SS, Gardner TB, Chari ST, et al. Low mortality and high morbidity in severe acute pancreatitis without organ failure: a case for revising the Atlanta classification to include moderately severe acute pancreatitis. *Am J Gastroenterol*. 2009;104(3):710–715.
38. Toouli J, Brooke-Smith M, Bassi C, et al. Guidelines for the management of acute pancreatitis. *J Gastroenterol Hepatol*. 2002 Feb;17(suppl): S15–S39.
39. Uhl W, Warshaw A, Imrie C, et al. IAP Guidelines for the Surgical Management of Acute Pancreatitis. *Pancreatol*. 2002;2(6):565–573.
40. Tenner S, Banks PA. Acute pancreatitis: nonsurgical management. *World J Surg*. 1997 Feb;21(2):143–148.
41. Brown A, Baillargeon JD, Hughes MD, Banks PA. Can fluid resuscitation prevent pancreatic necrosis in severe acute pancreatitis? *Pancreatol*. 2002;2(2):104–107.
42. O'Keefe SJ, McClave SA. Feeding the injured pancreas. *Gastroenterology*. 2005;129:1129–1130.
43. Goodgame JT, Fischer JE. Parenteral nutrition in the treatment of acute pancreatitis: effect on complications and mortality. *Ann Surg*. 1977 Nov; 186(5):651–658.
44. Lobo DN, Memon MA, Allison SP, Rowlands BJ. Evolution of nutritional support in acute pancreatitis. *Br J Surg*. 2000 Jun;87(6):695–707.
45. Buchman AL, Moukarzel AA, Bhuta S, et al. Parenteral nutrition is associated with intestinal morphologic and functional changes in humans. *JPEN J Parenter Enteral Nutr*. 1995 Nov–Dec;19(6):453–460.
46. Kalfarentzos F, Kehagias J, Mead N, Kokkinis K, Gogos CA. Enteral nutrition is superior to parenteral nutrition in severe acute pancreatitis: results of a randomized prospective trial. *Br J Surg*. 1997 Dec;84(12):1665–1669.
47. McClave SA, Greene LM, Snider HL, et al. Comparison of the safety of early enteral vs parenteral nutrition in mild acute pancreatitis. *JPEN J Parenter Enteral Nutr*. 1997 Jan–Feb;21(1):14–20.
48. Windsor AC, Kanwar S, Li AG, et al. Compared with parenteral nutrition, enteral feeding attenuates the acute phase response and improves disease severity in acute pancreatitis. *Gut*. 1998 Mar;42(3):431–435.
49. Zhao G, Wang CY, Wang F, Xiong JX. Clinical study on nutrition support in patients with severe acute pancreatitis. *World J Gastroenterol*. 2003 Sep;9(9):2105–2108.
50. Olah A, Belagyi T, Isekutz A, Gamal ME, Bengmark S. Randomized clinical trial of specific lactobacillus and fibre supplement to early enteral nutrition in patients with acute pancreatitis. *Br J Surg*. 2002 Sep;89(9):1103–1107.
51. Al-Omran M, Groof A, Wilke D. Enteral versus parenteral nutrition for acute pancreatitis. *Cochrane Database Syst Rev*. 2003;(1):CD002837.
52. Marik PE, Zaloga GP. Meta-analysis of parenteral nutrition versus enteral nutrition in patients with acute pancreatitis. *BMJ*. 2004;328:1407.
53. Ioannidis O, Lavrentieva A, Botsios D. Nutrition support in acute pancreatitis. *Journal of the Pancreas*. 2008;9(4):375–390.
54. Eatock FC, Chong P, Menezes N, et al. A randomized study of early nasogastric versus nasojejunal feedings in severe acute pancreatitis. *Am J Gastroenterol*. 2005;100:432–439.
55. Kumar A, Singh N, Prakash S, et al. Early enteral nutrition in severe acute pancreatitis: a prospective randomized controlled trial comparing nasojejunal and nasogastric routes. *J Clin Gastroenterol*. 2006;40:431–434.
56. Eckerwall GE, Axelsson JB, Andersson RG. Early nasogastric feeding in predicted severe acute pancreatitis: a clinical, randomized study. *Ann Surg*. 2006;244:959–965.
57. Neoptolemos JP, Carr-Locke DL, London NJ, Bailey IA, James D, Fossard DP. Controlled trial of urgent endoscopic retrograde cholangiopancreatography and endoscopic sphincterotomy versus conservative treatment for acute pancreatitis due to gallstones. *Lancet*. 1988 Oct 29;2(8618): 979–983.
58. Fan ST, Lai EC, Mok FP, Lo CM, Zheng SS, Wong J. Early treatment of acute biliary pancreatitis by endoscopic papillotomy. *N Engl J Med*. 1993 Jan 28;328(4):228–232.
59. Folsch UR, Nitsche R, Ludtke R, Hilgers RA, Creutzfeldt W. Early ERCP and papillotomy compared with conservative treatment for acute biliary pancreatitis. The German Study Group on Acute Biliary Pancreatitis. *N Engl J Med*. 1997 Jan 23;336(4):237–242.
60. Varghese JC, Farrell MA, Courtney G, Osborne H, Murray FE, Lee MJ. Role of MR cholangiopancreatography in patients with failed or inadequate ERCP. *AJR Am J Roentgenol*. 1999 Dec;173(6):1527–1533.
61. Rau B, Uhl W, Buchler MW, Beger HG. Surgical treatment of infected necrosis. *World J Surg*. 1997 Feb;21(2):155–161.
62. Bradley EL, 3rd, Allen K. A prospective longitudinal study of observation versus surgical intervention in the management of necrotizing pancreatitis. *Am J Surg*. 1991 Jan;161(1):19–24; discussion 24–15.
63. Lumsden A, Bradley EL, 3rd. Secondary pancreatic infections. *Surg Gynecol Obstet*. 1990 May;170(5):459–467.
64. Bassi C, Falconi M, Talamini G, et al. Controlled clinical trial of pefloxacin versus imipenem in severe acute pancreatitis. *Gastroenterology*. 1998 Dec;115(6):1513–1517.
65. Grewe M, Tsiotos GG, Luque de-Leon E, Sarr MG. Fungal infection in acute necrotizing pancreatitis. *J Am Coll Surg*. 1999 Apr;188(4):408–414.
66. Ratschko M, Fenner T, Lankisch PG. The role of antibiotic prophylaxis in the treatment of acute pancreatitis. *Gastroenterol Clin North Am*. 1999 Sep;28(3):641–659, ix–x.
67. Bassi C, Larvin M, Villatoro E. Antibiotic therapy for prophylaxis against infection of pancreatic necrosis in acute pancreatitis. *Cochrane Database Syst Rev*. 2003;(4):CD002941.
68. Buchler M, Malfertheiner P, Friess H, et al. Human pancreatic tissue concentration of bactericidal antibiotics. *Gastroenterology*. 1992 Dec;103(6): 1902–1908.
69. Pederzoli P, Bassi C, Vesentini S, Campedelli A. A randomized multicenter clinical trial of antibiotic prophylaxis of septic complications in acute necrotizing pancreatitis with imipenem. *Surg Gynecol Obstet*. 1993 May;176(5):480–483.
70. Sainio V, Kempainen E, Puolakkainen P, et al. Early antibiotic treatment in acute necrotising pancreatitis. *Lancet*. 1995 Sep 9;346(8976):663–667.



71. Schwarz M, Isenmann R, Meyer H, Beger HG. Antibiotic use in necrotizing pancreatitis. Results of a controlled study. *Dtsch Med Wochenschr*. 1997 Mar 21;122(12):356–361.
72. Isenmann R, Runzi M, Kron M, et al. Prophylactic antibiotic treatment in patients with predicted severe acute pancreatitis: a placebo-controlled, double-blind trial. *Gastroenterology*. 2004 Apr;126(4):997–1004.
73. Golub R, Siddiqi F, Pohl D. Role of antibiotics in acute pancreatitis: a meta-analysis. *J Gastrointest Surg*. 1998 Nov–Dec;2(6):496–503.
74. Sharma VK, Howden CW. Prophylactic antibiotic administration reduces sepsis and mortality in acute necrotizing pancreatitis: a meta-analysis. *Pancreas*. 2001 Jan;22(1):28–31.
75. Powell JJ, Campbell E, Johnson CD, Siriwardena AK. Survey of antibiotic prophylaxis in acute pancreatitis in the UK and Ireland. *Br J Surg*. 1999 Mar;86(3):320–322.
76. Gloor B, Muller CA, Worni M, et al. Pancreatic infection in severe pancreatitis: the role of fungus and multiresistant organisms. *Arch Surg*. 2001 May;136(5):592–596.
77. He YM, Lv XS, Ai ZL, et al. Prevention and therapy of fungal infection in severe acute pancreatitis: a prospective clinical study. *World J Gastroenterol*. 2003 Nov;9(11):2619–2621.
78. Rokke O, Harbitz TB, Liljedal J, et al. Early treatment of severe pancreatitis with imipenem: a prospective randomized clinical trial. *Scand J Gastroenterol*. 2007;42:771–776.
79. Dellinger EP, Runzi M, Kron M, et al. Early antibiotic treatment for severe acute necrotizing pancreatitis: a randomized, double-blind placebo-controlled study. *Ann Surg*. 2007;245:674–683.
80. Jafri S, Mahid SS, Idstein SR, et al. Antibiotic prophylaxis is not protective in severe acute pancreatitis: a systematic review and meta-analysis. *Am J Surg*. 2009;197:806–813.
81. Lange JF, van Gool J, Tytgat GN. The protective effect of a reduction in intestinal flora on mortality of acute haemorrhagic pancreatitis in the rat. *Hepatogastroenterology*. 1987 Feb;34(1):28–30.
82. Luiten EJ, Hop WC, Lange JF, Bruining HA. Controlled clinical trial of selective decontamination for the treatment of severe acute pancreatitis. *Ann Surg*. 1995 Jul;222(1):57–65.
83. Fernandez-del Castillo C, Rattner DW, Makary MA, Mostafavi A, McGrath D, Warshaw AL. Debridement and closed packing for the treatment of necrotizing pancreatitis. *Ann Surg*. 1998 Nov;228(5):676–684.
84. Rattner DW, Legermate DA, Lee MJ, Mueller PR, Warshaw AL. Early surgical debridement of symptomatic pancreatic necrosis is beneficial irrespective of infection. *Am J Surg*. 1992 Jan;163(1):105–109; discussion 109–110.
85. McFadden DW, Reber HA. Indications for surgery in severe acute pancreatitis. *Int J Pancreatol*. 1994 Apr;15(2):83–90.
86. Rau B, Pralle U, Uhl W, Schoenberg MH, Beger HG. Management of sterile necrosis in instances of severe acute pancreatitis. *J Am Coll Surg*. 1995 Oct;181(4):279–288.
87. Ashley SW. Sterile pancreatic necrosis: is operation necessary? *J Am Coll Surg*. 1995 Oct;181(4):363–364.
88. Branum G, Galloway J, Hirschowitz W, Fendley M, Hunter J. Pancreatic necrosis: results of necrosectomy, packing, and ultimate closure over drains. *Ann Surg*. 1998 Jun;227(6):870–877.
89. Rocha FG, Benoit E, Zinner MJ, et al. Impact of radiologic intervention on mortality in necrotizing pancreatitis: the role of organ failure. *Arch Surg*. 2009;144(3):261–265.
90. Mier J, Leon EL, Castillo A, Robledo F, Blanco R. Early versus late necrosectomy in severe necrotizing pancreatitis. *Am J Surg*. 1997 Feb;173(2):71–75.
91. Warshaw AL. Pancreatic necrosis: to debride or not to debride—that is the question. *Ann Surg*. 2000 Nov;232(5):627–629.
92. Baron TH, Morgan DE, Vickers SM, Lazenby AJ. Organized pancreatic necrosis: endoscopic, radiologic, and pathologic features of a distinct clinical entity. *Pancreas*. 1999 Jul;19(1):105–108.
93. Watts GT. Total pancreatectomy for fulminant pancreatitis. *Lancet*. 1963 Aug 24;13:384.
94. Norton L, Eiseman B. Near total pancreatectomy for hemorrhagic pancreatitis. *Am J Surg*. 1974 Feb;127(2):191–195.
95. Alexandre JH, Guerrieri MT. Role of total pancreatectomy in the treatment of necrotizing pancreatitis. *World J Surg*. 1981 May;5(3):369–377.
96. Beger HG, Isenmann R. Surgical management of necrotizing pancreatitis. *Surg Clin North Am*. 1999 Aug;79(4):783–800, ix.
97. Beger HG. Operative management of necrotizing pancreatitis—necrosectomy and continuous closed postoperative lavage of the lesser sac. *Hepatogastroenterology*. 1991 Apr;38(2):129–133.
98. Sarr MG, Nagorney DM, Mucha P, Jr., Farnell MB, Johnson CD. Acute necrotizing pancreatitis: management by planned, staged pancreatic necrosectomy/debridement and delayed primary wound closure over drains. *Br J Surg*. 1991 May;78(5):576–581.
99. Warshaw AL, Jin GL. Improved survival in 45 patients with pancreatic abscess. *Ann Surg*. 1985 Oct;202(4):408–417.
100. Aranha GV, Prinz RA, Greenlee HB. Pancreatic abscess: an unresolved surgical problem. *Am J Surg*. 1982 Nov;144(5):534–538.
101. Davidson ED, Bradley EL, 3rd. “Marsupialization” in the treatment of pancreatic abscess. *Surgery*. 1981 Feb;89(2):252–256.
102. Bradley EL, 3rd. A fifteen year experience with open drainage for infected pancreatic necrosis. *Surg Gynecol Obstet*. 1993 Sep;177(3):215–222.
103. Pemberton JH, Nagorney DM, Becker JM, Ilstrup D, Dozois RR, Remine WH. Controlled open lesser sac drainage for pancreatic abscess. *Ann Surg*. 1986 Jun;203(6):600–604.
104. Wertheimer MD, Norris CS. Surgical management of necrotizing pancreatitis. *Arch Surg*. 1986 Apr;121(4):484–487.
105. Becker JM, Pemberton JH, DiMugno EP, Ilstrup DM, McIlrath DC, Dozois RR. Prognostic factors in pancreatic abscess. *Surgery*. 1984 Sep;96(3):455–461.
106. Carter R. Management of infected necrosis secondary to acute pancreatitis: a balanced role for minimal access techniques. *Pancreatol*. 2003;3(2):133–138.
107. Bradley EL, Howard TJ, van Sonnenberg E, Fotoohi M. Intervention in necrotizing pancreatitis: an evidence-based review of surgical and percutaneous alternatives. *J Gastrointest Surg*. 2008;12:634–639.
108. Freeny PC, Hauptmann E, Althaus SJ, Traverso LW, Sinanan M. Percutaneous CT-guided catheter drainage of infected acute necrotizing pancreatitis: techniques and results. *AJR Am J Roentgenol*. 1998 Apr;170(4):969–975.
109. Echenique AM, Sleeman D, Yrizarry J, et al. Percutaneous catheter-directed debridement of infected pancreatic necrosis: results in 20 patients. *J Vasc Interv Radiol*. 1998 Jul–Aug;9(4):565–571.
110. Endlicher E, Volk M, Feuerbach S, Scholmerich J, Schaffler A, Messmann H. Long-term follow-up of patients with necrotizing pancreatitis treated by percutaneous necrosectomy. *Hepatogastroenterology*. 2003 Nov–Dec;50(54):2225–2228.
111. Baron TH, Harewood GC, Morgan DE, Yates MR. Outcome differences after endoscopic drainage of pancreatic necrosis, acute pancreatic pseudocysts, and chronic pancreatic pseudocysts. *Gastrointest Endosc*. 2002 Jul;56(1):7–17.
112. Morgan DE, Baron TH, Smith JK, Robbin ML, Kenney PJ. Pancreatic fluid collections prior to intervention: evaluation with MR imaging compared with CT and US. *Radiology*. 1997 Jun;203(3):773–778.
113. Seifert H, Wehrmann T, Schmitt T, Zeuzem S, Caspary WF. Retroperitoneal endoscopic debridement for infected peripancreatic necrosis. *Lancet*. 2000 Aug 19;356(9230):653–655.
114. Kozarek RA. Endotherapy for organized pancreatic necrosis: perspective on skunk-poking. *Gastroenterology*. 1996 Sep;111(3):820–823.
115. Gambiez LP, Denimal FA, Porte HL, Saudemont A, Chambon JP, Quandalle PA. Retroperitoneal approach and endoscopic management of peripancreatic necrosis collections. *Arch Surg*. 1998 Jan;133(1):66–72.
116. Carter CR, McKay CJ, Imrie CW. Percutaneous necrosectomy and sinus tract endoscopy in the management of infected pancreatic necrosis: an initial experience. *Ann Surg*. 2000 Aug;232(2):175–180.
117. Hwang TL, Chiu CT, Chen HM, et al. Surgical results for severe acute pancreatitis—comparison of the different surgical procedures. *Hepatogastroenterology*. 1995 Nov–Dec;42(6):1026–1029.
118. Teerenhovi O, Nordback I, Eskola J. High volume lesser sac lavage in acute necrotizing pancreatitis. *Br J Surg*. 1989 Apr;76(4):370–373.
119. Fugger R, Gotzinger P, Sautner T, et al. Necrosectomy and laparotomy—a combined therapeutic concept in acute necrotising pancreatitis. *Eur J Surg*. 1995 Feb;161(2):103–107.
120. Orlando R, 3rd, Welch JP, Akbari CM, Bloom GP, Macaulay WP. Techniques and complications of open packing of infected pancreatic necrosis. *Surg Gynecol Obstet*. 1993 Jul;177(1):65–71.
121. Garcia-Sabrido JL, Tallado JM, Christou NV, Polo JR, Valdecantos E. Treatment of severe intra-abdominal sepsis and/or necrotic foci by an

- "open-abdomen" approach. Zipper and zipper-mesh techniques. *Arch Surg*. 1988 Feb;123(2):152-156.
122. Pederzoli P, Bassi C, Vesentini S, et al. Retroperitoneal and peritoneal drainage and lavage in the treatment of severe necrotizing pancreatitis. *Surg Gynecol Obstet*. 1990 Mar;170(3):197-203.
123. Villazon A, Villazon O, Terrazas F, Rana R. Retroperitoneal drainage in the management of the septic phase of severe acute pancreatitis. *World J Surg*. 1991 Jan-Feb;15(1):103-107; discussion 107-108.
124. Nicholson ML, Mortensen NJ, Espiner HJ. Pancreatic abscess: results of prolonged irrigation of the pancreatic bed after surgery. *Br J Surg*. 1988 Jan;75(1):89-91.
125. Larvin M, Chalmers AG, Robinson PJ, McMahon MJ. Debridement and closed cavity irrigation for the treatment of pancreatic necrosis. *Br J Surg*. 1989 May;76(5):465-471.

# COMPLICATIONS OF ACUTE PANCREATITIS (INCLUDING PSEUDOCYSTS)

John A. Windsor • Benjamin P. T. Loveday

## INTRODUCTION

Recovery from acute pancreatitis is now expected, with mortality less than 10%, which reflects improvements in the treatment of complications and intensive care management.<sup>1</sup> A third of patients with acute pancreatitis develop complications and a quarter of these will die of them. These complications can be local, regional, or systemic. Most regional and systemic complications occur in association with severe acute pancreatitis. The most important determinants of severity in acute pancreatitis are infected local complications and multiple organ dysfunction.<sup>2</sup> These regional and systemic complications provide the basis for defining four categories of severity (Table 55-1).<sup>3</sup> This chapter will focus on the diagnosis and management of the important complications of acute pancreatitis.

## LOCAL COMPLICATIONS

Severe acute pancreatitis is associated with fluid collections and tissue necrosis in and around the pancreas.<sup>4</sup> These local complications of acute pancreatitis were defined by the Atlanta Symposium in 1992 as pancreatic necrosis, pseudocyst, and abscess. These terms, however, have proven to be confusing and new terminology has been introduced in an attempt to reflect current understanding of the pathophysiology and morphology of the disease.<sup>5,6</sup> In the revised Atlanta Classification, fluid collections less than 4 weeks after disease onset are termed either an acute fluid collection or a post-necrotic pancreatic or peripancreatic fluid collection.<sup>7</sup> Over time changes in the morphology of the lesion occur, in particular the reaction of the surrounding tissue to the enzyme-rich fluid produces a wall, and this is usually well defined on CT scan after 4 weeks. A pancreatic pseudocyst is the term that has traditionally been applied to this lesion, but it is now appreciated that the contents may be anywhere on a continuum from entirely solid to entirely fluid.<sup>8</sup> When a fluid

collection has developed in association with pancreatic necrosis, the revised Atlanta Classification has suggested that this is termed “walled off necrosis” (WON). In addition to this variation in content (solid to fluid) local complications can also be sterile or infected, with the latter having significant prognostic significance.

## Acute Fluid Collections

### DESCRIPTION

Acute fluid collections have no solid component or wall, and typically exist adjacent to the pancreas confined by anatomical fascial planes (eg, anterior pararenal fascia).<sup>7</sup> These collections occur in 30–50% of cases<sup>9,10</sup> and contain a mixture of inflammatory exudates and/or enzyme-rich pancreatic secretions that are a consequence of breakdown of small peripheral ductal side branches. While they may be associated with parenchymal necrosis, their presence does not necessarily indicate necrosis or significant duct disruption. The pancreatic fluid can track widely and may take the form of peripancreatic fluid collections in the retroperitoneum and mediastinum, pancreatic ascites, and/or pleural effusions. The most common routes of extension are into the lesser sac, behind the pancreatic head, behind the left and right colons on the psoas muscle, and into the small bowel mesentery and bulging through the transverse mesocolon.

### DIAGNOSIS

Acute fluid collections are a common feature of acute pancreatitis, usually developing in the first 48–72 hours of the disease. Contrast-enhanced CT (CECT), magnetic resonance imaging (MRI) or endoscopic ultrasound (EUS) may be used to confirm the diagnosis and to differentiate acute fluid collections from other local complications (Fig. 55-1).



**TABLE 55-1: CLASSIFICATION AND DEFINITIONS OF FOUR CATEGORIES FOR THE SEVERITY OF ACUTE PANCREATITIS**

Severity Category	Local Complications		Systemic Complications
Mild	No (peri)pancreatic complication	And	No organ failure
Moderate <sup>a</sup>	Sterile (peri)pancreatic complication	Or	Transient organ failure
Severe <sup>a</sup>	Infectious (peri)pancreatic complication	Or	Persistent organ failure
Critical	Infectious (peri)pancreatic complication	And	Persistent organ failure

<sup>a</sup>Severity is graded on the basis of more severe local or systemic complication, for example, sterile pancreatic necrosis without organ failure must be graded as "moderate," sterile pancreatic necrosis with persistent organ failure must be graded as "severe."

Reproduced from Petrov MS, Windsor JA. Classification of the severity of acute pancreatitis: how many categories make sense? *Am J Gastroenterol.* 2010; 105:74–76.

## MANAGEMENT

Acute fluid collections usually remain sterile and resolve spontaneously.<sup>9,10</sup> They are only important in and of themselves because they may be the precursor of pancreatic pseudocysts. If spherical or ovoid with sharp margins, suggesting that under some pressure from ongoing leakage, they are more likely to persist. Massive collections of fluid around or within the pancreas are more likely to be due to disruption of the main pancreatic duct and are more likely to persist for a number of weeks or continue to increase in size.

Acute fluid collections are rarely symptomatic and do not require active treatment. Intervention, by surgical or radiological drainage, risks introducing infection into a usually sterile collection. An asymptomatic fluid collection is managed by observation alone, and only in the presence of infection drainage is usually necessary. Medical therapy, such as with diuretics, is not indicated. Continuous peritoneal lavage does not alter the course of the disease and should not be a routine practice.<sup>11</sup>

Rarely, leakage from injury to the main pancreatic duct can be treated by endoscopic or surgical intervention. Endoscopic treatment uses a trans-sphincteric pancreatic duct stent, which can be placed across the sphincter of Oddi (to decrease ductal pressure and facilitate drainage), into the fluid collection through the disrupted duct (to drain the collection directly) or across the damaged duct (to redirect drainage from the collection to the duodenum and to stent the duct to reduce the risk of stricture formation). The operative approach is either a distal resection of the pancreas or internal drainage of the collection into a Roux-en-Y limb of jejunum. The latter can only be considered once the wall of the collection has matured (see later).

The drainage of pleural effusions in patients with acute pancreatitis should be considered if there is compromised respiratory function or inadequate oxygenation. Chronic pleural effusions as a result of an internal pancreatic fistula often are treated with a chest tube, nasojejunal tube feeding, and somatostatin. Persistence or recurrence will require identification of a pancreatic leak and either drainage into a Roux-en-Y limb of jejunum or distal resection of the pancreas.

## Postnecrotic Pancreatic and Peripancreatic Fluid Collection

### DESCRIPTION

Postnecrotic collections contain both solid and fluid components, and are not surrounded by a fibrous capsule during the first few weeks. These lesions arise from liquefaction of solid necrosis, but may also contain pancreatic secretions due to an associated pancreatic duct disruption. Over time necrotic tissue undergoes liquefaction and forms part of this fluid collection. As the lesion matures, a wall without an epithelial lining develops around the collection, and is termed WON. Postnecrotic collections are usually sterile but infection may ensue. The term pancreatic abscess is best abandoned as it might represent an infected fluid collection or an infected area of solid necrosis with little associated fluid. This differs from the original definition of a pancreatic abscess, which was defined as a collection of pus, usually in close proximity to the pancreas, containing little or no pancreatic necrosis.<sup>4</sup>

### DIAGNOSIS

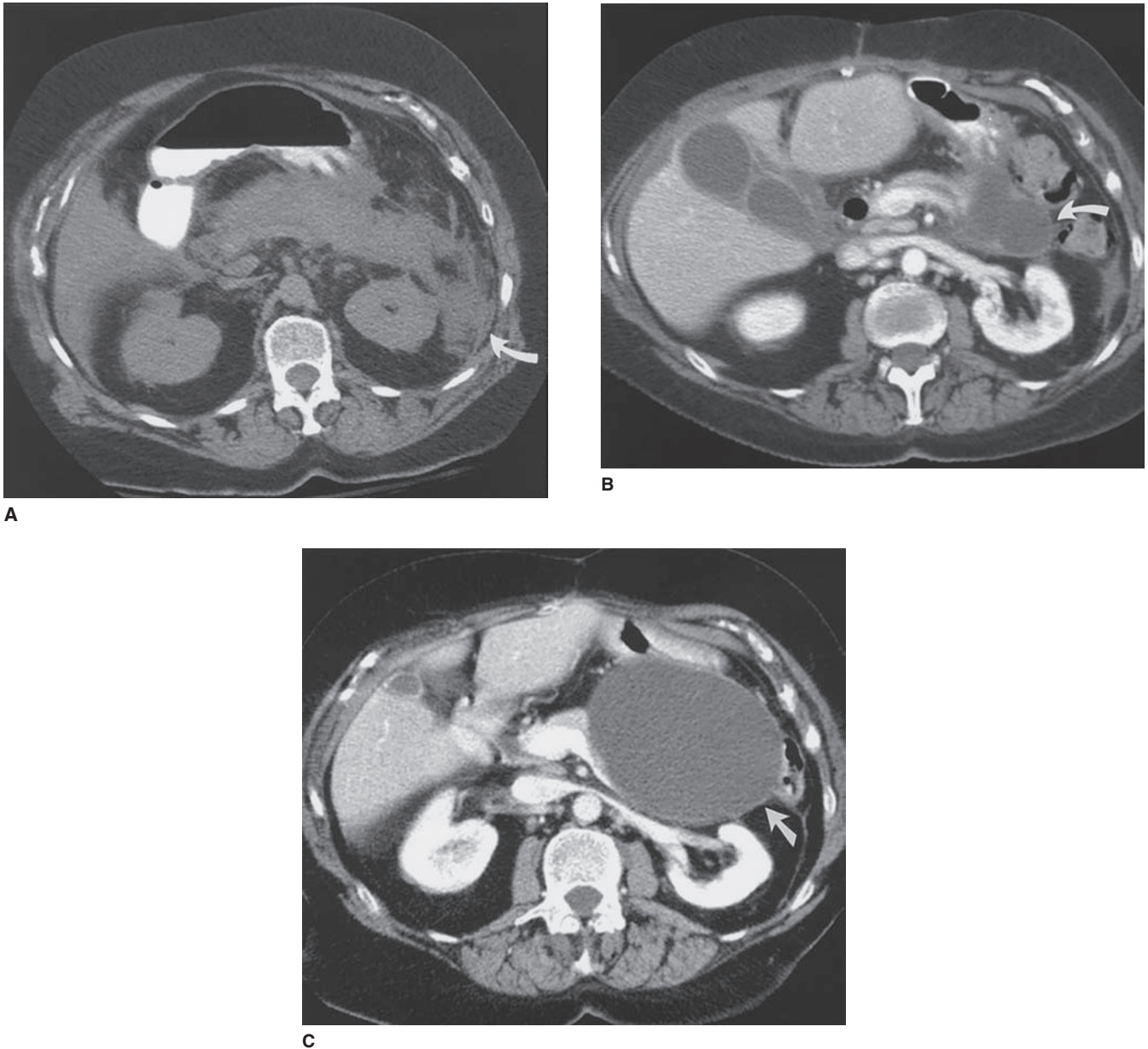
Postnecrotic fluid collections are diagnosed with CECT, MRI, or EUS after the first week from disease onset. Infection may be identified on CT as extraluminal gas (Fig. 55-2), although definitive diagnosis requires image-guided fine-needle aspiration (FNA) for Gram's stain and culture. Endoscopic retrograde cholangiopancreatography (ERCP) can be used to determine whether there is any ductal communication associated with the lesion, but is rarely required and risks the introduction of infection.

### MANAGEMENT

Management of postnecrotic collections is the same as that for pancreatic necrosis, which is described in detail later in this chapter.

## Pseudocyst

A pseudocyst is a well-circumscribed fluid collection with no associated tissue necrosis that is present for 4 or more weeks after disease onset.<sup>7</sup> In the original Atlanta Classification a pseudocyst was defined as a collection of pancreatic juice enclosed by a wall of fibrous tissue, and there was no mention

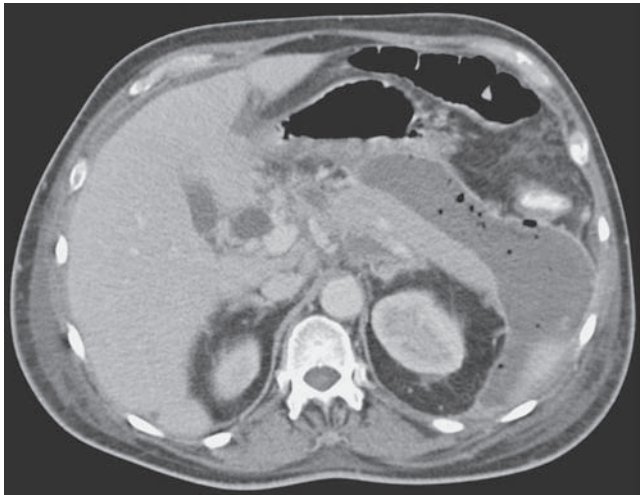


**FIGURE 55-1** Progression from an acute fluid collection to a pseudocyst. **A.** Unenhanced CT scan shows an edematous pancreas and an ill-defined, acute fluid collection surrounding the tail of the pancreas (*arrow*) with peripancreatic inflammatory changes, an appearance compatible with acute pancreatitis. **B.** On a follow-up contrast-enhanced CT scan obtained 1 month later, the lesion appears as a bilobed cystic mass with a septum in the pancreatic body and tail (*arrow*). The peripancreatic inflammatory changes are markedly decreased. **C.** On a follow-up CT scan obtained 2 years later, the lesion appears as a unilocular, low-attenuation fluid collection with a well-defined thin wall (*arrow*). This is the typical appearance of a postinflammatory pseudocyst. (Reproduced from Kim Y H et al. Imaging diagnosis of cystic pancreatic lesions: pseudocyst versus nonpseudocyst. *Radiographics*. 2005; May-Jun;25(3):671–685.)

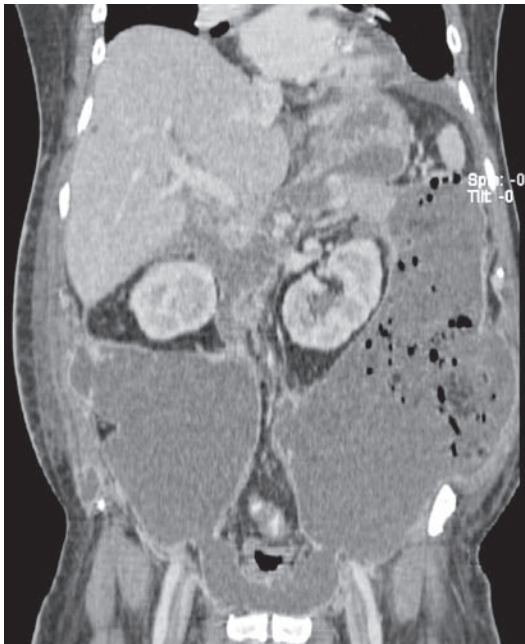
of whether it could also contain a solid component. In practice the lesion is either a fluid collection that does not contain necrosus, which when mature (>4 weeks) is best termed a pseudocyst, or a postnecrotic collection that contains necrosus, which when mature (>4 weeks) is best termed WON.

Thus the pseudocyst precursor is the acute fluid collection, and it is differentiated from the former by the presence of a well-defined wall (capsule) without an epithelial

lining (Fig. 55-3). This is in contrast to cystic neoplasms of the pancreas, which are characterized by an epithelial lining. However, this is not an absolute distinction as there may be discontinuous epithelium within cystic neoplasms (probably due to pressure atrophy) and partial epithelialization within chronic pseudocysts (facilitated by communication with the main pancreatic duct). In fewer than 20% of cases, more than one pseudocyst is present. Acute pseudocysts are



A



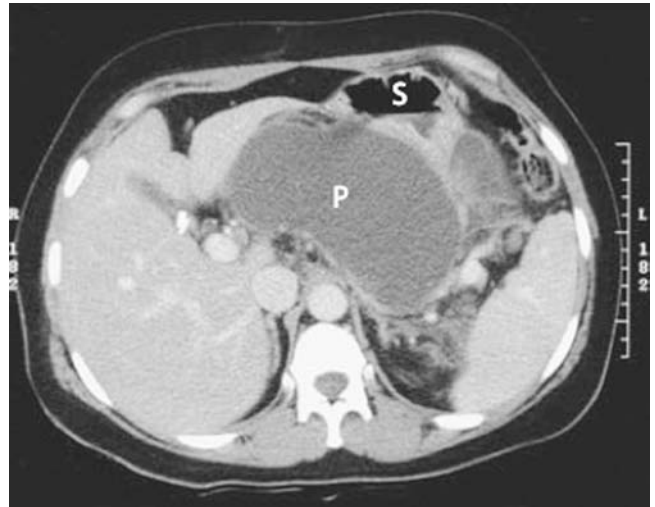B

**FIGURE 55-2** CT scan showing infected pancreatic necrosis with gas within the collection on cross-sectional (A) and coronal (B) views.

located most often in close proximity to the pancreas, especially in the lesser sac (see Fig. 55-3) but also may be found in the pelvis, scrotum, mediastinum, or thorax. The extent and number of fluid collections are included in the Balthazar grading of the severity of acute pancreatitis CT scanning.<sup>12</sup>

### **PATHOGENESIS AND CLASSIFICATION**

The development of a pseudocyst requires pancreatic duct disruption, and this occurs in the context of acute pancreatitis (10–15% of cases), trauma, or duct obstruction in chronic pancreatitis (20–40% of cases).<sup>13,14</sup> The leakage of enzyme-rich



**FIGURE 55-3** A CT scan of a pancreatic pseudocyst located in the lesser sac. P, pseudocyst; S, stomach.

secretion incites a marked inflammatory reaction in the peritoneum, retroperitoneal tissue, and serosa of adjacent viscera. As a result, the fluid is contained by a developing layer of granulation tissue and fibrosis that matures over time. If the communication between pancreatic duct and pseudocyst persists, the pseudocyst can continue to enlarge, sometimes reaching 20–30 cm in diameter. The contents of the pseudocyst usually consist of a relatively clear watery fluid. However, with hemorrhage, it may contain clot and become xanthochromic. In the presence of infection, a pseudocyst will contain pus. If a collection of fluid develops following pancreatic necrosis, and it contains solid tissue, it should not be termed a pseudocyst but rather walled off necrosis (WON).

Pseudocysts secondary to blunt trauma tend to develop anterior to the neck and body of the gland because the duct is injured where it crosses the vertebral column. In chronic pancreatitis, pseudocysts are thought to develop secondary to obstruction of the pancreatic duct. The pseudocysts are usually located within the fibrotic gland, can be multiple and sometimes are difficult to distinguish from pancreatic retention cysts. The latter are formed by progressive dilatation of the pancreatic duct and tend to retain the epithelial lining of the duct.

A useful classification of pseudocysts was proposed by D'Egidio in 1991, which incorporates the key features discussed earlier (Table 55-2).<sup>15</sup> Type I pseudocysts occur after an episode of acute pancreatitis and are associated with normal duct anatomy and rarely communicate with the pancreatic duct. Type II pseudocysts occur after an episode of acute or chronic pancreatitis and have a diseased but not strictured pancreatic duct, and there is often a communication between the duct and the pseudocyst. Type III pseudocysts occur in chronic pancreatitis, and are uniformly associated with a duct stricture and a communication between the duct and the pseudocyst.



**TABLE 55-2: THE D'EGIDIO CLASSIFICATION OF PANCREATIC PSEUDOCYSTS AND THE PRIMARY TREATMENT OPTIONS**

	Context	Pancreatic Duct	Duct-Pseudocyst Communication	Primary Treatment
Type I	Acute postnecrotic pancreatitis	Normal	No	Percutaneous drainage
Type II	Acute-on-chronic pancreatitis	Abnormal (no stricture)	50:50	Internal drainage or resection
Type III	Chronic pancreatitis	Abnormal (stricture)	Yes	Internal drainage with duct decompression

## COMPLICATIONS

With modern imaging practice, a higher proportion of asymptomatic pseudocysts are diagnosed. As a result the risk of pseudocyst complications is probably less than previously considered when pseudocysts were diagnosed on the basis of symptoms. Complications occur in about 10% of cases and the four main complications of pseudocysts are infection, rupture or internal fistulation, bleeding, and mass effect.<sup>16</sup>

Pseudocysts are initially sterile, but infection can occur in up to 25% of cases.<sup>16,17</sup> The presence of sepsis due to an infected pseudocyst is an indication for drainage of the infected contents. This can be done by percutaneous drainage, with the risk of a persisting external pancreatic fistula, or by internal drainage to the stomach or small bowel.

The rupture of a pseudocyst can occur by erosion into the adjacent gastrointestinal tract, which may allow the pseudocyst to resolve or it may leave a cystoenteric fistula or pancreaticopleural/bronchial fistula. The term fistula is not strictly accurate in this setting as the communication is not between two epithelial-lined structures. Rupture into the gastrointestinal tract may be associated with significant haemorrhage, that is a sentinel bleed. Rupture into the peritoneum leads to pancreatic ascites and can be a dramatic presentation with acute abdominal pain and rigidity from chemical peritonitis.

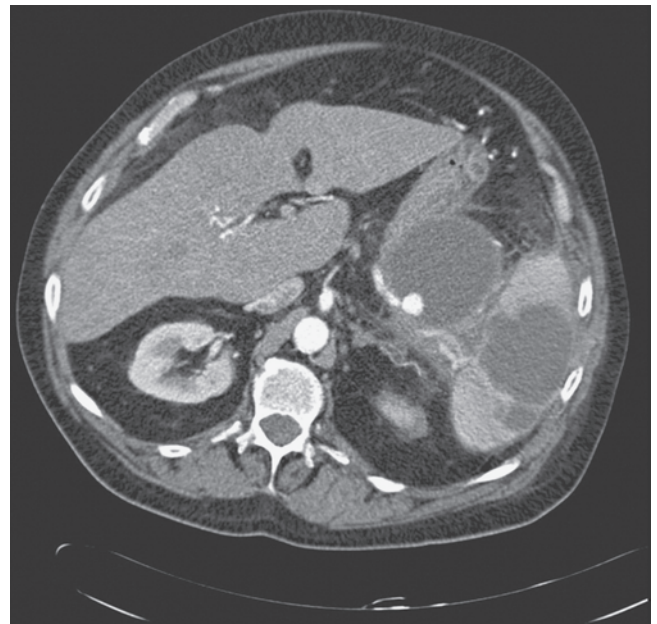
Bleeding associated with a pancreatic pseudocyst can be a life-threatening complication. There are several causes of bleeding. Bleeding may occur secondary to erosion of the gut mucosa with the impending development of a cystoenteric fistula. This may produce hematemesis and melena. More ominous is the direct erosion of a significant visceral vessel, including the splenic, gastroduodenal, and middle colic vessels. The action of pancreatic enzymes (especially elastase) on the vessel wall can lead to thinning of the vessel wall with aneurysm and pseudoaneurysm formation (Fig. 55-4). This situation carries a high mortality (~20%).<sup>18</sup> The risk of bleeding is increased in the presence of local infection. If time and patient stability permit, emergency selective splanchnic angiography is performed to delineate the site of bleeding, and embolization is attempted (Fig. 55-5A, B). Otherwise, emergency surgery is required, consisting of oversewing of the bleeding vessels and internal or external drainage of the

pseudocyst. Occasionally it is possible to resect the pseudocyst, which is effective in preventing recurrent hemorrhage.

A large pseudocyst may exert a mass effect, and thereby produce early satiety (stomach), partial or complete intestinal obstruction (duodenum, gastric outlet, esophagogastric junction, and rarely small or large bowel), cholestasis (bile duct), and venous thrombosis (portal, superior mesenteric, and splenic veins) leading to portal or segmental hypertension and varices. Mass effect is more likely when a pseudocyst is greater than 6 cm in diameter.<sup>16</sup>

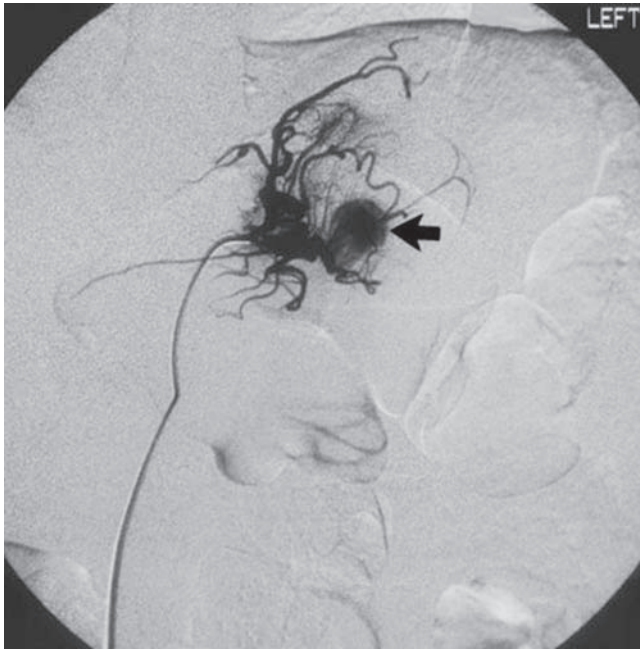## DIAGNOSIS

A pseudocyst should be suspected when a patient with acute pancreatitis fails to recover after a week of treatment or when, after initial improvement, symptoms return. Most patients

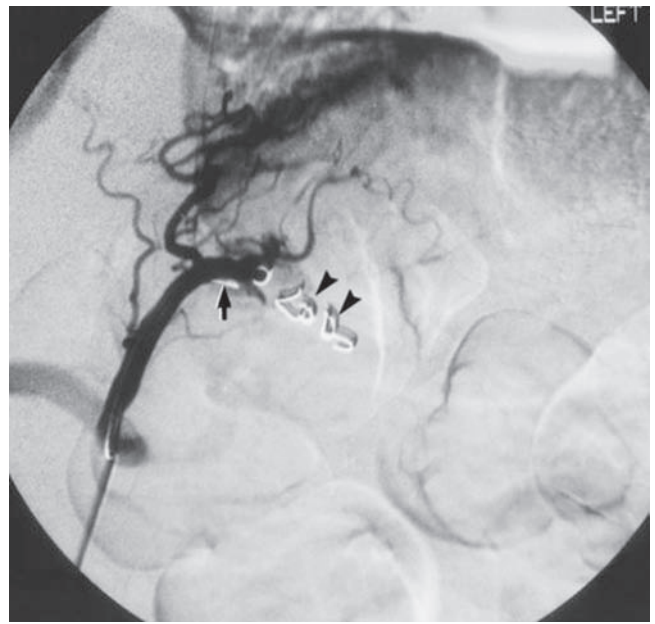

**FIGURE 55-4** A contrast CT scan showing the pseudocysts, the medial one complicated by a pseudoaneurysm related to the splenic artery.





A



B

FIGURE 55-5 Selective mesenteric angiogram showing a pseudoaneurysm related to the left gastric artery (A) and successful embolization (B).

with symptomatic pseudocysts have epigastric discomfort or pain. There may be anorexia, early satiety, nausea, mild fever, back pain, and a palpable mass. Signs of sepsis are not usually overt. In about half the patients there is failure of the serum amylase level to return to normal or a mild (2–4 times normal) secondary rise. However, often the early stages of pseudocyst formation are observed radiologically before symptoms develop, and this provides some forewarning.

The clinical suspicion of a pseudocyst may be investigated by CECT or MRI scan, where it appears as a rounded, low attenuation, fluid-filled structure within or adjacent to the pancreas (for diagnostic and treatment algorithm, see Fig. 55-6). While ultrasonography (US) is excellent for the detection of a pseudocyst, it is limited by operator skill, the patient’s habitus, and overlying bowel gas. The advantage of ultrasonography is that it is better able to determine the extent of solid tissue within a fluid collection, and it is used often to guide FNA. EUS can be useful in distinguishing a pseudocyst from a cystic neoplasm because it often delineates internal septation better than CT scan.<sup>19</sup> Compared with ultrasonography, CT scanning has an accuracy approaching 100% for the diagnosis of a pseudocyst, is not operator-dependent, and is more useful in planning therapy. It will demonstrate the key features of a pseudocyst (ie, size, shape, wall thickness, and contents), the nature of the pancreas (ie, presence and extent of necrosis, diameter of pancreatic duct, and features of chronic pancreatitis, including atrophy and calcification), and the relationship of these to the surrounding organs (see Fig. 55-3), which can be critical in planning internal surgical drainage. Triphasic helical CT scanning will delineate the regional arteries (to look for pseudoaneurysm formation)

and veins (to look for thrombosis, cavernous transformation, and formation of varices). More recently, MRI is excellent at characterising the morphological features of the lesion and in particular outlining the solid component of the lesion.<sup>7</sup>

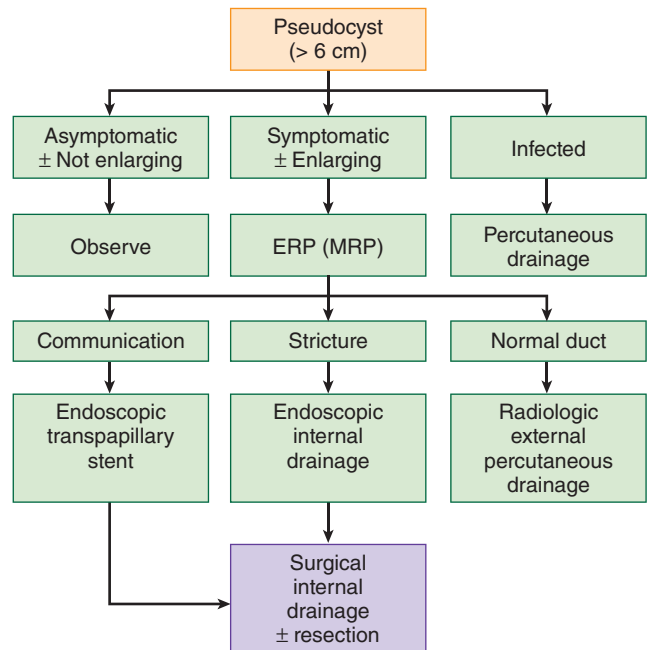


FIGURE 55-6 Algorithm for investigation and treatment of pancreatic pseudocysts. ERP, endoscopic retrograde pancreatogram; MRP, magnetic resonance pancreatogram.

ERCP is not routinely required as part of the diagnostic workup for pseudocysts. In symptomatic cases where treatment is likely, it may be useful to plan further management. The advantage of ERCP is that it has both diagnostic and therapeutic roles. Because of the risks of exacerbating pancreatitis, perforation, bleeding, and introducing infection, it is preferably done within 48 hours of any planned drainage procedure. Over 90% of patients with a pseudocyst have some abnormality of the pancreatic duct. The unique diagnostic contribution of ERCP is to accurately delineate a communication between the main pancreatic duct and the pseudocyst, which occurs in over 60% of patients. A communication of this type is a relative contraindication to external drainage of a pseudocyst.<sup>20</sup> The classification of the main pancreatic duct by ERCP has been shown to assist in selecting the type of treatment, where the presence or absence of a stricture, communication, and obstruction is an important feature to note.<sup>21</sup> Magnetic resonance cholangiopancreatography (MRCP) may be used to assess pancreatic and biliary duct morphology instead of ERCP and in some centers has replaced ERCP in its diagnostic role and has the advantage of being noninvasive with similar diagnostic accuracy to ERCP, but has no therapeutic role.<sup>22</sup>

The clinical diagnosis of a complication of a known pseudocyst is usually straightforward. The rupture of a pseudocyst into the peritoneal cavity is associated with the onset of acute abdominal pain and signs of peritonitis. This is in contrast to the spontaneous decompression of a pseudocyst into an adjacent organ, which usually results in the relief of symptoms. Infection of a pseudocyst is accompanied by signs of sepsis. Infection can be confirmed with image-guided FNA for Gram's stain and bacterial culture. Bleeding usually results in an increase in abdominal pain and possible syncope, tachycardia, and hypotension. A drop in hemoglobin concentration is expected.

Although cystic neoplasms are rare, they can be mistaken for pseudocysts. Absence of an antecedent history of acute pancreatitis, elevation of carcinoembryonic antigen (CEA) or carbohydrate antigen (CA) 19-9, and/or the presence of internal septation should suggest this diagnosis. If EUS is available, it will enable the identification of septations (microscopic characteristics of serous lesions or macrocystic characteristic of mucinous lesions), mural nodules, echogenic debris, and calcification, and it may also allow aspiration of fluid content for analysis. Pseudocysts usually contain fluid with elevated amylase (>5000 U/mL) and an absence of tumor markers, but this should not be relied on for a definitive diagnosis.<sup>23</sup>

## MANAGEMENT

The natural history of a pseudocyst is not easy to predict. Spontaneous resolution occurs frequently and usually within 6 weeks. When larger than 6 cm in diameter, and when it continues to enlarge during the first month, a pseudocyst is more likely to persist and develop complications. Size alone is a poor predictor because resolution can occur even with very large pseudocysts. Persistence is also more likely if there

is a distal stricture of the main pancreatic duct and a proximal communication between the main pancreatic duct and the pseudocyst. Although not directly correlated, a large pseudocyst is more likely to cause discomfort and pain.

The two principal indications for treating pancreatic pseudocysts are to relieve symptoms and to treat complications. In the absence of symptoms or evidence of enlargement, conservative management is usually reasonable. A traditional approach that dictated treatment of all pseudocysts that have been present for more than 4–6 weeks is no longer justified.<sup>24</sup> The decision as to whether a pseudocyst in a particular patient requires active intervention can be difficult. The desire to allow time for spontaneous resolution to occur must be balanced against the risk of complications while waiting for cyst wall maturity. The traditional indications for treatment were the complications of a pseudocyst. Now the focus is on preventing complications. In many centers it has become less common to treat a pseudocyst solely on the grounds of a failure to resolve. An enlarging asymptomatic pseudocyst that has been present for 6 weeks is usually treated. A natural-history study from India indicates that asymptomatic pseudocysts less than 7.5 cm in diameter and without internal debris will resolve spontaneously at an average of 5 months.<sup>25</sup> In modern series, the mean diameter of pseudocysts requiring treatment is approximately 9 cm.<sup>26,27</sup> At the same time as this trend toward conservatism, there has been an increase in the number of treatment modalities, including open surgical, laparoscopic, endoscopic, and radiological.

There are two important rules in the treatment of pseudocysts. The first is that a cystic neoplasm must not be treated as a pseudocyst. The second is that elective external drainage of a pseudocyst must not be done if there is downstream and unrelieved pancreatic ductal obstruction because of the high risk of an external pancreatic fistula. The approach to treatment (Table 55-3) depends on the nature of the pseudocyst, the pancreatic duct, and the fitness of the patient. Also important is the level of available expertise and experience with the various treatment modalities.

The following general features of a pseudocyst are important in considering the most appropriate treatment:

- The thickness of the pseudocyst wall, which is usually a function of the duration of the pseudocyst. This is important because the operative drainage of a pseudocyst requires that it safely accept sutures or staples. After 6 weeks the fluid collection is fully walled off in a fibrous capsule.<sup>28</sup>
- The location of the pseudocyst. If adherent to the stomach or duodenum, the options are different than if the pseudocyst is deep within the retroperitoneum and covered by bowel loops.
- The contents of the pseudocyst. The presence of blood may indicate the need for prior embolization of a pseudoaneurysm. Pus will require drainage, either internally or externally. The presence of solid necrosus suggests the lesion is in fact WON and may require some form of necrosectomy.

**TABLE 55-3: THE TREATMENT APPROACHES FOR PANCREATIC PSEUDOCYST**

Approaches	Examples
Open surgical	Cystogastrostomy
	Cystoduodenostomy
	Roux-en-Y cystojejunostomy
	Distal pancreatectomy $\pm$ splenectomy
	External drainage
Laparoscopic	Cystogastrostomy
	Cystoduodenostomy
	Roux-en-Y cystojejunostomy
	Distal pancreatectomy $\pm$ splenectomy
	External drainage
Radiologic	Percutaneous drainage
	Percutaneous transgastric drainage
Endoscopic	Transpapillary pancreatic duct stent
	Transgastric stent
	Transduodenal stent

- The number of pseudocysts. If multiple pseudocysts are present, then minimally invasive approaches may not be feasible. Conservative management is not recommended with symptomatic multiple pseudocysts.
- The etiology of the pseudocyst. Lesions arising from acute-on-chronic pancreatitis may require different treatment to those arising from the first episode of acute pancreatitis.
- The main pancreatic duct anatomy and degree of disruption. The pancreas and the pancreatic duct need separate consideration in planning the treatment of a pseudocyst. The pancreas may warrant treatment in its own right, especially if there is a ductal stricture, a dilated duct, or regional disease warranting resection.

**Open Surgical Treatment.** There is no single surgical procedure that is appropriate for all pseudocysts. The most important factor dictating the mode of treatment is local expertise.<sup>29</sup> In principle, drainage procedures are preferred to resection because they preserve pancreatic function, are technically easier, and have a lower mortality rate. Despite the many alternatives and less invasive approaches, it is important to emphasize that the most effective and reliable means of treating a pseudocyst is internal drainage by an open surgical approach (see Table 55-3). The complication and mortality rates of internal drainage are half those of external drainage.

A D'Egidio type II pseudocyst is best treated by internal drainage or resection, particularly when ductal disruption or stricture is present. When there is a mature wall, internal drainage is the best surgical option. Recurrence rates should be less than 5%, and mortality should be less than 2%. The pseudocyst can be drained into the stomach, the duodenum, or the jejunum. The choice of surgical procedure depends on the location of the pseudocyst and its relationship to these organs.

A cystogastrostomy is ideal when the pseudocyst is adherent to the posterior stomach and indenting it (Fig. 55-7). A longitudinal anterior gastrostomy is followed by the stepwise excision of a disk (>2 cm diameter) of stomach with subjacent pseudocyst wall. The tissue is sent for frozen section in all cases to exclude cystic neoplasia. Sutures are placed in stages to reduce the risk of edge bleeding as the disk is excised. Prior confirmation of the location of the pseudocyst may be required by needle aspiration, although it is usually obvious. The stoma should be large enough to allow transgastric débridement of any necrotic tissue within the pseudocyst cavity. A laparoscope can be used after open débridement to confirm that the cavity is clear of debris. The disadvantage of the cystogastrostomy is that it is not a dependent stoma, may act as a sump, and when the pseudocyst is large can accumulate gastric debris. Where access permits, a Roux-en-Y cystojejunostomy is ideal for internal drainage (Fig. 55-8) and is particularly suited to drainage of pseudocysts arising from the body and tail of the pancreas, or not adherent to the stomach or bulging through the left transverse mesocolon.

Combining internal drainage of a pseudocyst with a lateral pancreaticojejunostomy should be considered in patients with chronic pancreatitis and a dilated pancreatic duct because it will improve outcome without increasing the risk of the procedure. The blind end of the Roux limb should be placed toward the tail of the pancreas because this allows the head of the pancreas to be drained and the bile duct to be bypassed using the same limb.

Distal pancreatic resection has a role, particularly when the head of the pancreas is relatively preserved. An endoscopic retrograde pancreatogram will help to define the extent of resection. Provided that there is no pancreatic duct obstruction, the recurrence and fistula rates are very low. Specific ligation of the pancreatic duct will decrease the fistula rate.

External drainage of a pseudocyst has a limited role but is useful in the critically ill patient and where a controlled external fistula is an acceptable goal. Other rare indications for external drainage at the time of laparotomy include the control of an immature ruptured pseudocyst and for some bleeding pseudocysts where there has been under-running of the bleeding point. An external fistula may resolve more rapidly with placement of a transpapillary stent and with the use of a long-acting somatostatin analogue.

**Radiological Treatment.** The first description of direct percutaneous aspiration and external drainage using radiologic guidance was in the early 1980s.<sup>30-33</sup> This technique has become widely practiced with a reported morbidity of between 10 and 30%. It can be used with an immature pseudocyst wall, although the risk of complications is higher in this setting. Percutaneous drainage is best suited to D'Egidio type I pseudocysts in which there is no significant underlying duct abnormality or communication between the duct and pseudocyst. In the setting of acute pancreatitis, catheter drainage may not be helpful because of small catheter size and the inability to allow the drainage of necrotic and viscous material. In the setting of chronic pancreatitis, the downstream obstruction of



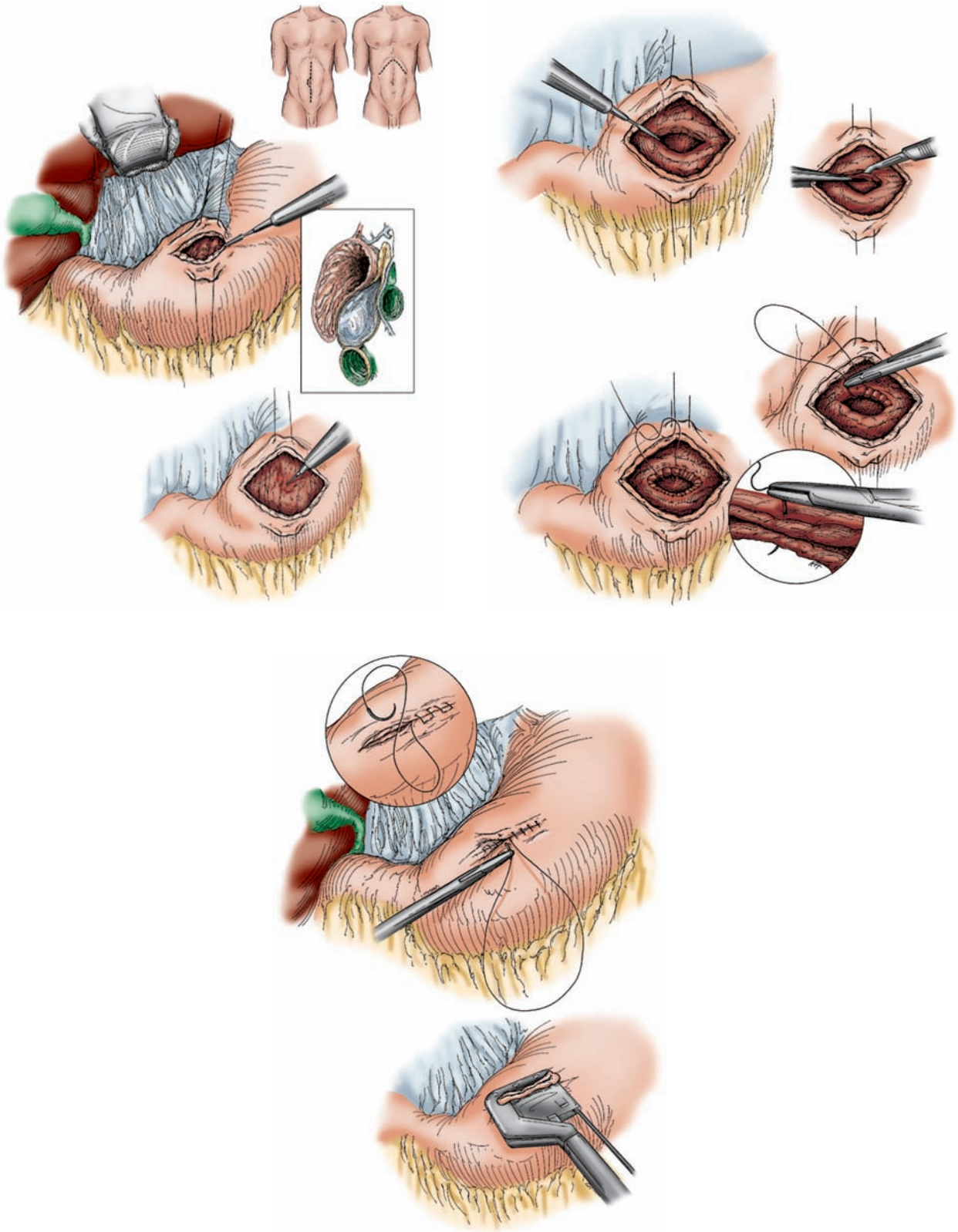


FIGURE 55-7 Internal drainage of a pseudocyst through the posterior wall of the stomach (cystogastrostomy).



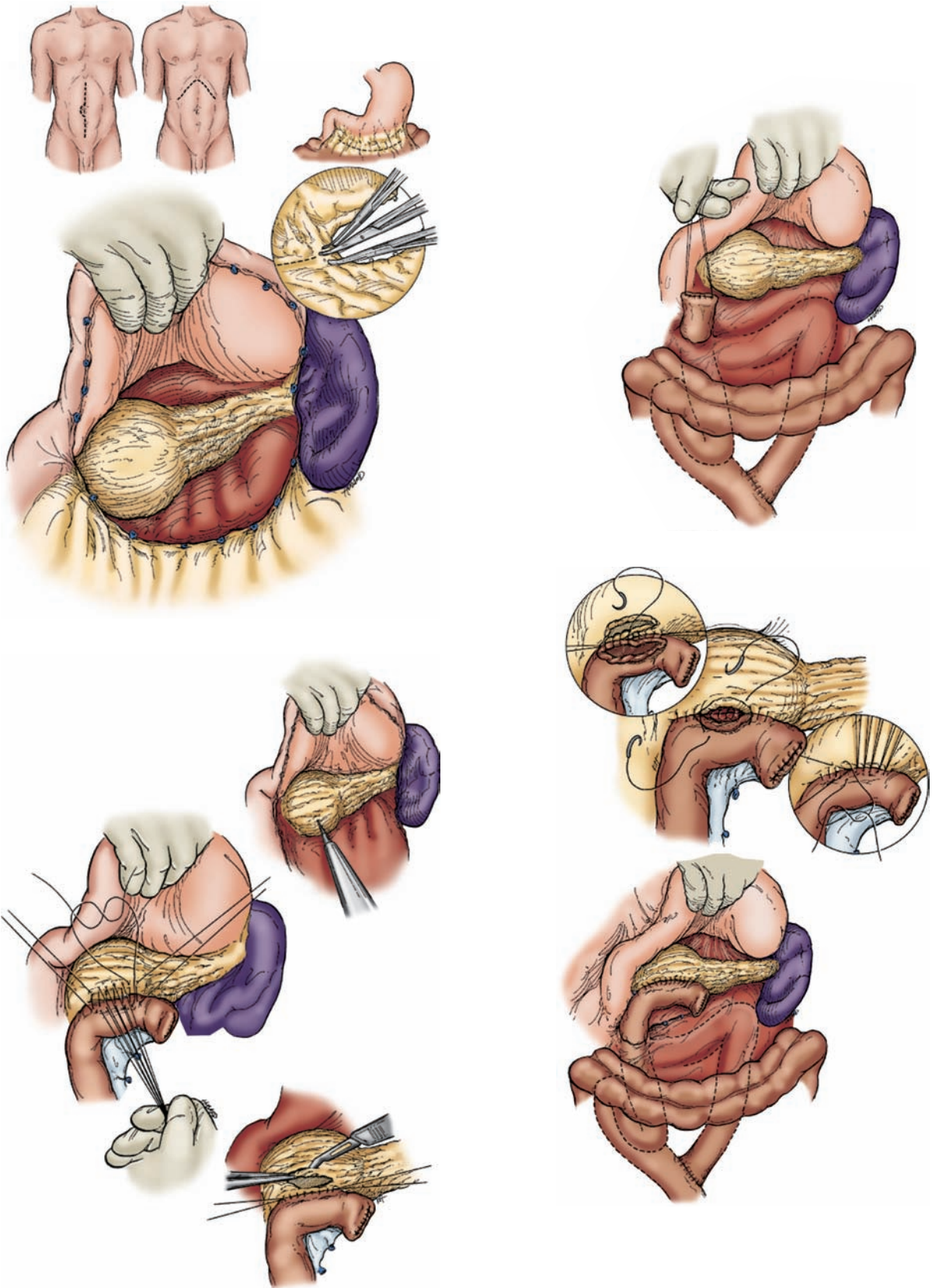
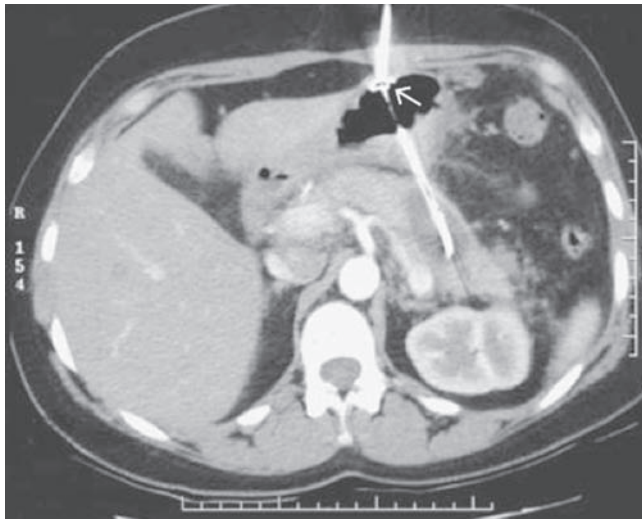


FIGURE 55-8 Internal drainage of a pseudocyst to the jejunum (Roux-en-Y cystojejunostomy).

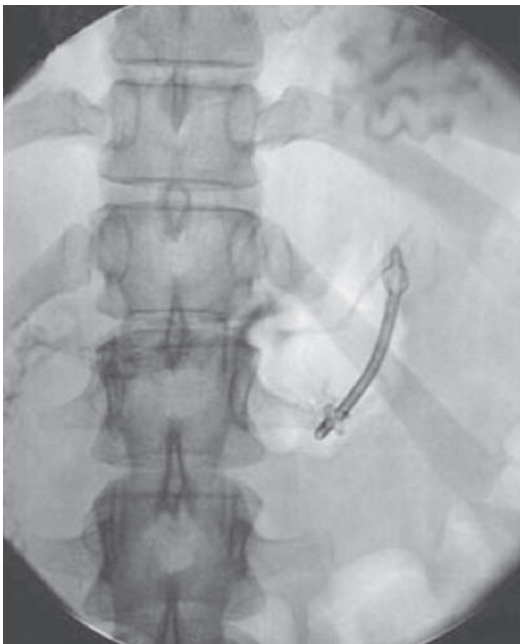
the duct gives rise to a high recurrence rate and/or an external fistula along the catheter tract. In simple, uncomplicated pseudocysts, percutaneous drainage is usually successful, but not necessary since this is the group with the fewest symptoms, the lowest complication rate, and the best chance of spontaneous resolution.

The introduction of a transgastric approach to percutaneous drainage has almost abolished the problem of external pancreatic fistulas (Fig. 55-9A, B).<sup>34</sup> This produces a percutaneous cystogastrostomy but requires an initial period of

external transgastric drainage, clamping at 3 days, and then internalization at 2 weeks. Internalization can be helped with a concurrent endoscopic view, especially using double pigtail catheters. The endoscopic approach is also used for the subsequent removal of the catheters. A well-matched population-based study comparing percutaneous ( $n = 8121$ ) with open surgical drainage ( $n = 6409$ ) in 14,914 patients with pancreatic pseudocysts revealed a longer length of hospital stay and twice the mortality (5.9 vs 2.8%) for the former<sup>35</sup> (ie, percutaneous). Currently there is limited use of percutaneous pseudocyst drainage, unless there is an underlying medical problem or cyst complication.



A



B

**FIGURE 55-9** **A.** CT scan showing percutaneous transgastric drainage of pseudocyst. **B.** Plain radiograph showing double Malecot-type stent cystogastrostomy. (Used with permission from John Chen, MD.)

**Endoscopic Treatment.** There has been significant activity in the endoscopic treatment of pseudocysts over the last decade. Endoscopic transpapillary techniques include stenting the sphincter of Oddi to lower ductal pressures. The stent also can be advanced via the pancreatic duct into the pseudocyst when there is a demonstrable communication. Endoscopic transmural drainage is also possible and involves identifying the bulge into stomach or duodenum caused by the pseudocyst. The cyst generally is entered using a diathermy needle knife. Prior endoscopic ultrasonography allows greater accuracy and safety by confirming the anatomic route, and Doppler can be used to help avoid larger blood vessels. A number of pigtail stents can be inserted. The tract also can be dilated with a balloon catheter and the endoscope itself inserted into the cavity of the pseudocyst for direct visualization and retrieval of the cyst contents and wall biopsy (to rule out a cystic neoplasm).

These endoscopic methods are still evolving but have a reported success rate of up to 90% with experienced practitioners. But it must be remembered that the reports generally are in carefully selected patients. Caution needs to be exercised because of the risks of perforation, peritonitis, and infection through inadequate internal drainage. This is also a less reliable means of obtaining a large tissue sample to exclude cystic neoplasia and there is also an increased risk of bleeding. The risk of bleeding is significantly reduced when the initial puncture is guided by EUS. The real complication rate probably is higher than the reported 20%, many related to catheter plugging or being dislodged and subsequent sepsis.

**Minimally Invasive Surgery.** All the open surgical techniques have been undertaken using a laparoscopic approach.<sup>36</sup> Intraluminal laparoscopic surgery, where the trocars are placed through the abdominal and stomach walls, has been successful. The cystogastrostomy can be performed with a stapler or by suture. A more recent modification of this approach is the minilaparoscopic cystogastrostomy using a 2-mm intraluminal laparoscope. The view is augmented by the insertion of a flexible endoscope per os, which also can be used to explore the cyst cavity.

The balloon dilatation of a percutaneous catheter track using a similar approach to that used for percutaneous nephrolithotomy is feasible in many cases. It is worth considering this when the initial radiologic attempts have failed to bring

resolution. The placement of a sheath then allows the insertion of an operating nephroscope to enable débridement of the pseudocyst and removal of organized pancreatic necrosis and infected necrosus. This procedure can be repeated and allows the placement of a soft large-bore external drain.

**Summary of Treatment for Pseudocysts.** The treatment of choice for pancreatic pseudocysts depends on a number of factors, including size, number, and location of pseudocysts; whether the main pancreatic duct is obstructed or communicates with the pseudocyst; and whether there are complications of the pseudocyst. The clinical context is important (see Table 55-2). With the range of approaches to treatment and the variation in the availability of equipment and expertise, it is necessary to develop a rational treatment algorithm that is appropriate for the clinical setting and the patient (see Fig. 55-6). In practice, type I pseudocysts can usually be managed conservatively. Percutaneous drainage should be considered if the pseudocyst becomes symptomatic or infected. Type II pseudocysts are best managed by internal drainage, especially when there is communication between duct and pseudocyst. Endoscopic, laparoscopic, and radiologic approaches have an emerging role in expert hands.<sup>37</sup> With type III pseudocysts, consideration needs to be given to decompression of the pancreatic duct and relieving the stricture at the same time as drainage of the pseudocyst.

## Pancreatic Necrosis

Necrosis may involve the pancreatic parenchyma and/or the peripancreatic tissue, and involvement of either of these tissues differentiates necrotizing pancreatitis from edematous pancreatitis.<sup>7</sup> Over time the solid necrosis gradually liquefies and becomes surrounded by a capsule, such that after 4 weeks it is termed WON. This partially solid and partially fluid, encapsulated lesion has been described in the literature by a range of terms, including organised necrosis, necroma, and pancreatic sequestrum. The extent of tissue necrosis is not fixed and may progress as the disease evolves during the first 2 weeks of the disease. The necrotizing process can extend widely to involve retroperitoneal fat, small and large bowel mesentery, and the retrocolic and perinephric compartments. The presence of necrosis usually determines a more protracted course lasting weeks to months. From a clinical viewpoint, the development of necrosis is the most important event in the course of acute pancreatitis because subsequent complications, both local and systemic, are associated with it.

## EPIDEMIOLOGY

The incidence of acute pancreatitis exhibits marked regional differences, and has been reported to from 5 to 80/100,000.<sup>38,39</sup> The proportion of patients with acute pancreatitis that develop pancreatic necrosis is approximately 20%, and of these 25–70% will develop infected necrosis.<sup>40,41</sup> The risk of

infection is higher when necrosis is more extensive (ie, >30% of the gland).<sup>42</sup> In addition, the risk of infection increases with time, from 24% by the end of the first week of illness, to 36% at the end of the second week, and to 71% by the end of the third week.<sup>43</sup> The overall mortality of edematous pancreatitis is 1% or less, that of sterile necrosis is 5%, and that of infected necrosis is 10–25% in the best published series.<sup>44</sup>

## PATHOGENESIS

Of the patients who develop pancreatic necrosis, 70% have evidence of it by 48 hours of the onset of abdominal pain, and all of them by 96 hours.<sup>43</sup> The premature activation of proteolytic enzymes within the acinar cells and interstitium of the lobule results in extensive necrosis of pancreatic tissue and the substantial accumulation and activation of leukocytes. There are a number of factors that contribute to the failure of the pancreatic microcirculation, which is evident histologically as stasis and/or thrombosis of intrapancreatic vessels. The failure of the pancreatic microcirculation leads to ischemia, which compounds the enzymatic and inflammatory injury and leads to the full syndrome of necrotizing pancreatitis. During this first week or so, in the so-called early or vasoactive phase, there is the release of proinflammatory mediators that contribute to the pathogenesis of pulmonary, cardiovascular, and renal insufficiency. This early systemic inflammatory response and multiorgan dysfunction are frequently present with evidence of pancreatic infection. In the septic or late phase, which occurs in most patients after 3–4 weeks, these systemic events usually occur as a consequence of infected pancreatic necrosis.

During mild edematous pancreatitis, the surface of the pancreas may show spotty fat necrosis and be larger and firm due to edema,<sup>45</sup> usually without hemorrhage or parenchymal necrosis. Early during necrotizing pancreatitis, there is obvious necrosis of the peripancreatic fatty tissue while the parenchyma of the gland may appear less affected. The surface of the pancreas typically demonstrates considerable heterogeneity, with areas of mineralised fat necrosis (saponification) mixed with areas of superficial hemorrhage. There may also be disseminated areas of necrosis in the omentum, mesentery, retroperitoneum, or other regions of the abdomen. Within the parenchyma of the pancreas there may be only a few foci of hemorrhage associated with fat necrosis between lobules, although in more severe cases lobules are also affected, transforming large areas into necrosis. In severe cases, necrosis of the pancreatic duct or its tributaries may be present, resulting in significant extravasation of pancreatic enzymes. The distribution of parenchymal necrosis is extremely variable, with some patients having necrosis affecting only a portion of the gland (eg, head or tail) and others having confluent necrosis affecting most of the gland.

On histopathological examination there are large areas of peripancreatic fat necrosis and within the pancreas there is evidence of interstitial edema along with necrosis of the parenchyma. This necrosis is initially present in the interlobular fatty tissue, and may be more severe when there is more



fatty tissue present. Islets are usually only affected in lobules that are mostly or entirely necrotic. Granulocytes and macrophages are present at the periphery of necrotic areas.

Mild edematous pancreatitis does not usually progress to necrotizing pancreatitis, implying that pathophysiological events soon after the onset of the disease are decisive in determining the course of the disease.<sup>45</sup> While edema usually resolves within a few days, the resolution of fat necroses is more variable, depending on the size and location of the lesions. Foci of necrosis less than 1 cm in diameter on the surface of the pancreas usually resolve entirely. This occurs by phagocytosis of necrotic material by macrophages, and these areas may later be replaced by fibrotic scar tissue. Larger foci of necrosis, 2–4 cm in diameter, are demarcated by macrophages that slowly phagocytose the necrotic material. The inner contents of the foci become liquefied. Large foci of necrosis, greater than 5 cm in diameter, do not resolve spontaneously. Macrophages rich in hemosiderin, along other immune cells, form a thin layer of granulation tissue around the lesion by 10–20 days after disease onset. After 20–30 days this becomes a fibrous capsule which gradually increases in thickness.<sup>46</sup> As with the smaller lesions, the contents slowly liquefy or organize over time. The contents may also contain high levels of pancreatic enzymes, suggesting the presence of communications with pancreatic ducts. Necrotic lesions are most likely to permit entry of bacteria when they are demarcated by only a thin rim of granulation tissue (4–20 days). Over time necrotic areas slowly resolve and are replaced by fibrotic scar tissue (necrosis–fibrosis sequence).<sup>47–49</sup>

## MICROBIOLOGY OF INFECTED NECROSIS

There are five routes by which bacteria are thought to be able to infect pancreatic necrosis: (1) hematogenous, (2) transpapillary reflux of duodenal content into the pancreatic duct, (3) translocation of intestinal bacteria and toxins via the mesenteric lymphatics to the systemic circulation via the thoracic duct, and possibly directly to the pancreas via lymphatic connections between the intestine and pancreas, (4) reflux of bacteriobilia via a disrupted pancreatic duct into the necrotic parenchyma, and (5) transperitoneal spread.

Cultures of infected pancreatic necrosis are polymicrobial in approximately one-third of patients and monomicrobial in two-thirds of patients.<sup>50</sup> Gram-negative aerobic bacteria are the most common organisms identified (eg, *Escherichia coli*, *Pseudomonas*, *Proteus*, and *Klebsiella*), followed by gram-positive bacteria (eg, *Enterococcus*, *Staphylococcus aureus*). Anaerobic bacteria are identified in only around 5% of positive cultures, although this may reflect inadequate culture techniques. Fungi may also be cultured, and are more common after use of prophylactic antibiotics.<sup>51,52</sup> The spectrum of bacteria cultured from infected necrosis demonstrates that enteric bacteria dominate, suggesting bacterial translocation is an important event in the pathogenesis of infected pancreatic necrosis.<sup>41</sup> Pancreatic necrosis is most likely to become infected during the late phase of acute pancreatitis, with a median time from hospital admission to infection of 26 days.<sup>42</sup>

## PREDICTION AND DIAGNOSIS

There are no specific symptoms or signs that are indicative of pancreatic necrosis. The presentation is usually nonspecific with abdominal pain, distension, guarding and associated low-grade fever, and tachycardia. The severity of pain and the extent of hyperamylasemia do not correspond with the severity of acute pancreatitis. Patients presenting late with severe disease will often have established multiorgan dysfunction. The classic skin signs of retroperitoneal necrosis, including discoloration of the navel (Cullen's sign), the flanks (Grey-Turner's sign), and the inguinal region (Fox's sign), are rare and often not seen until the second or third week after disease onset. The diagnosis of pancreatic necrosis requires more than just clinical acumen.

Predicting the severity of acute pancreatitis and the presence of pancreatic necrosis remains an imprecise science. Scoring systems, such as Ranson, Glasgow, APACHE II, or “bedside index for severity in acute pancreatitis” (BISAP), are often used for severity stratification, but the derived scores are not accurate with high false-positive and negative rates.<sup>53</sup> Patients with predicted severe disease and high likelihood of pancreatic necrosis require radiological confirmation of the presence and extent of necrosis, which is conventionally categorized as less than 30%, 30–50%, and greater than 50% of the pancreas.<sup>54</sup> Dynamic contrast-enhanced CT (CECT) is the gold standard for diagnosing pancreatic necrosis and other local complications (see Fig. 55-2), but is not usually indicated within the first 48–72 hours after the onset of acute pancreatitis.<sup>55–57</sup> Pancreatic hypoperfusion is usually established by about 72 hours and imaging before then probably underestimates the extent of necrosis and the ultimate disease severity.<sup>57</sup> CECT can also be used to score the severity by the CT severity index as proposed by Balthazar.<sup>12,55</sup>

Current guidelines recommend that CECT is indicated for patients with persisting organ failure, signs of sepsis, or clinical deterioration 6–10 days after admission.<sup>55</sup> There has been concern that contrast used for the CT might worsen the necrosis and/or exacerbate existing renal failure.<sup>55,56,58–60</sup> A range of alternative modalities have been developed to diagnose the extent of pancreatic necrosis, including MRI and echo-enhanced ultrasound (EEU), which are at least as accurate as CECT in diagnosing and determining the extent of pancreatic necrosis.<sup>61,62</sup> In practice, the indications to diagnose and determine the extent of pancreatic necrosis by CECT are predicted severe acute pancreatitis (usually during the second week), when a patient fails to improve with initial resuscitation and/or when the CRP has crossed the diagnostic threshold (see later). The CECT scan can also be used to grade the severity of acute pancreatitis (CT severity index [CTSI]) based on the extent of extrapancreatic changes and pancreatic necrosis.<sup>12</sup> It is important to recognize the limitations of CECT, where a pseudocyst and WON can be difficult to distinguish. Imaging by MR or EUS, which better delineate the solid components within a lesion, may be employed when the diagnosis of necrosis is uncertain.

In the absence of a specific marker of pancreatic necrosis, many serum predictors have been proposed. An ideal predictor or prognostic indicator should be simple, cheap, reproducible, valid, available on admission, and specific for necrosis. While a full discussion of markers is beyond the scope of this chapter, there are several that fulfill most of these criteria, compare favorably with CT scanning, and have an established role in routine clinical practice.

C-reactive protein (CRP) is the most widely used predictor of pancreatic necrosis and is useful as a daily monitor of disease progress. The accuracy in detecting necrosis is about 85%, but it requires 3–4 days after the onset of the disease to reach a diagnostic level. The threshold values depend on the assay and the study used. A commonly used threshold is greater than 120 mg/L.<sup>63</sup> Other prognostic markers, none of which has been shown to outperform CRP, include interleukin-6 (IL-6) (threshold >14 pg/mL) which peaks a day earlier than CRP; polymorphonuclear elastase (threshold >120 µg/L), which peaks early and reflects neutrophil activation and degranulation; and phospholipase A<sub>2</sub> type II (threshold >15 U/L). Urinary trypsinogen-activating peptide has also been proposed as a predictor of necrosis, but is not the major advance that was first anticipated.<sup>64</sup> Procalcitonin has been proposed as a sensitive and specific marker for infected necrosis but it has not become part of routine management.<sup>41–43</sup>

The importance of determining the severity of acute pancreatitis is the need to initiate early intensive care management, and this may necessitate transfer of the patient to a tertiary unit. The initiation of prophylactic antibiotics has been the subject of considerable debate.<sup>65–67</sup> The concerns with this approach relate to the increased risk of invasive fungemia, which increases mortality, and of the development of multiresistant organisms.<sup>68,69</sup> The current consensus is that there is not a routine role for prophylactic antibiotics.<sup>56</sup>

The diagnosis of infected necrosis is very important because it is generally considered an indication for intervention. Rarely, the early invasion of gas-forming organisms, such as *Clostridium perfringens*, makes the diagnosis of infection on CT scanning straightforward.<sup>70</sup> It is more usual to suspect pancreatic infection with rapidly progressive disease or a secondary deterioration after 2 or 3 weeks of admission. This is often heralded by a significant rise in CRP. A CT scan will usually confirm the presence of a tense collection with rim enhancement arising from the region(s) of pancreatic necrosis. The presence of gas within the tissues confirms infection, with an “air bubble” appearance (see Fig. 55-2), but this is present in the minority of cases.

Infected necrosis is best diagnosed by image-guided (CT or ultrasound) fine-needle aspiration (FNA) for Gram staining and/or bacterial culture.<sup>55,56</sup> The UK guidelines recommended all patients with greater than 30% necrosis and persistent symptoms, and those with smaller areas of necrosis and clinical suspicion of infected necrosis, should undergo image-guided FNA.<sup>1</sup> There is now considerable debate over this recommendation, with some authorities suggesting that in addition to significant and secondary clinical deterioration, patients should have a rise in serum markers (eg, CRP,

procalcitonin) to increase the index of suspicion for infected necrosis.<sup>71</sup> The decision to intervene is one of the most difficult decisions in clinical practice.

There has been some concern that FNA is associated with a potential risk of secondary infection.<sup>72</sup> However, clinical practice guidelines are consistent in their recommendation to use FNA as the gold standard test to diagnose infected necrosis.<sup>1,4,8,15,46,56,73–79</sup> The rationale for early diagnosis of infected necrosis with FNA is to allow prompt treatment with antibiotics and invasive intervention. Over the last 20 years this has been the prevailing approach to reduce the morbidity and mortality associated with infected necrosis.<sup>80</sup> More recently the debate surrounding FNA has been reopened, with the understanding that surgical intervention should be delayed as long as possible or even avoided completely with the judicious use of radiological drainage. When surgical intervention is clinically indicated (by nonresponse to antibiotics and intensive care management) the results of the FNA will not alter patient management because surgery might be undertaken even in the absence of FNA-confirmed infection.<sup>71</sup> In summary it is better to view FNA of pancreatic necrosis as an adjunctive measure and one that is only undertaken in a patient in whom there is already a strong clinical suspicion of infection and in whom confirmation of infection will result in intervention.

## INDICATIONS FOR INTERVENTION

The indications for intervention in patients with pancreatic necrosis are evolving such that infected pancreatic necrosis, of itself, is no longer considered an absolute indication for surgery in many centres. However, infected necrosis, confirmed by culture-positive FNA, is the strongest indication for intervention, particularly in a deteriorating patient receiving maximum intensive care. Where radiological drainage has been attempted, failure of drainage and/or persistent sepsis from infected necrosis are also clear indications for intervention. Any necrotizing process, regardless of the infectious status, that causes massive hemorrhage or bowel perforation (eg, duodenum or transverse colon) is an indication, albeit rare, for surgical intervention. The indications for surgery in the absence of infection are very limited. Amongst patients with sterile necrosis, only those who are clinically deteriorating despite maximal supportive care and who have a clear target lesion to drain or debride should be considered for surgery.<sup>81,82</sup> Surgery is rarely indicated in some patients who “fail to thrive,” but this remains controversial.<sup>82</sup> These patients may have documented sterile necrosis, abdominal symptoms, and intolerance to oral feeding more than 4 weeks after disease onset, although the vast majority of patients with sterile necrosis can and should be managed without surgery.

## TIMING OF INTERVENTION

Historically, surgical intervention for pancreatic necrosis was during the first week after disease onset. Early surgery

was advocated in order to remove the dead tissue, the focus of infection, and terminate the inflammatory process. We now know that the inflammatory cascades are not easily switched off and are exacerbated by the surgical procedure. Early surgery is more difficult and dangerous because the necrotic tissue is immature, poorly demarcated and not easily separated from viable tissue, resulting in a significant risk of bleeding. Additionally, early surgery may cause infection of sterile necrosis. With mortality rates of up to 65%, the trend for early intervention was called into question.<sup>73</sup> In recent years the timing of surgical intervention has become progressively later, such that the current concept for timing of intervention is that it should be undertaken as late as possible after disease onset (preferably >4 weeks), when the necrotic process has stopped extending, there is clear demarcation between viable and nonviable tissues, and infected necrotic tissues have become organized and “walled off.”<sup>1,56,73</sup> Such a delay allows time for stabilization of the patient, and decreases the risk of bleeding and pancreatic insufficiency through the unnecessary removal of viable tissue.

Once a diagnosis of infected necrosis has been established, it is now quite common practice to undertake percutaneous catheter drainage of infected fluid.<sup>83</sup> This often results in some improvement in the patient’s overall clinical status, or an arrested decline. The type and timing of further intervention is dictated by a number of factors, including the patient’s condition and comorbidities, local expertise, and the anatomical location and complexity of the lesion. There are two main approaches in regards to repeated surgical intervention. With “programmed intervention,” surgery is repeated according to a set schedule (eg, every second day). With “on demand intervention,” surgery is repeated only if and when it is clinically indicated, by a failure to improve or with secondary deterioration.<sup>82</sup>

## TYPE OF INTERVENTION

There are many different interventions and the challenge is to select the intervention that is appropriate for the particular local complication, taking into account the anatomical location, infection status and complexity of the target lesion(s), the physiological status, comorbidity of an individual patient, and the availability of expertise with the type of intervention. A review of current guidelines highlights the absence of level 1 evidence to guide decision making regarding the types of intervention.<sup>84</sup> There are two broad philosophies regarding the type of intervention used. Some experts state that open surgical drainage and necrosectomy remains the gold standard in the management of infected pancreatic necrosis, and reserve less invasive interventions for subsequent complications. These include percutaneous and endoscopic drainage of residual fluid complications. Such a step-down approach contrasts with the step-up approach, which advocates the use of less invasive interventions initially (eg, percutaneous or endoscopic drainage) and only employing open surgical techniques later in the disease

course in those who fail to respond. These two approaches have been subjected to a randomized controlled trial in the PANTER trial.<sup>85</sup> This demonstrated that a minimally invasive approach, as compared with open necrosectomy, reduced the rate of the composite end point of major complications or death. Mortality itself was not decreased, but new onset multiple organ failure occurred less often in patients assigned to the step-up approach. Another important finding was that a third of patients who would have previously undergone an open necrosectomy were managed by radiological percutaneous drainage alone.

There is a need to standardize the description of invasive interventions to facilitate communication between clinicians, comparison of techniques, and controlled clinical trials. Interventions can be classified based on the method of visualization of the lesion, the anatomical route taken to reach the lesion, and the purpose of the intervention.<sup>86</sup>

The possible *visualization* modalities include open procedures where the operative site is exposed through the skin incision, endoscopic procedures where the operative site is visualized with an endoscope (eg, gastroscope, laparoscope, or nephroscope), radiological procedures where CT, ultrasound, or fluoroscopy are used to visualize the lesion during the procedure, and hybrid procedures that combine endoscopic and radiological techniques.

The *routes* taken by these interventions are defined by the external route into the body (skin or external orifice) and the internal route into the lesion. The internal routes used to reach the target lesion might pass through the gastrointestinal wall, peritoneum, or retroperitoneum.

The overall purpose of treatment is to eliminate areas of necrotic and infected tissue and/or fluid, as well as inflammatory and enzyme-rich exudates. However, the way in which this is achieved varies considerably, with some procedures being considerably more aggressive than others. Therefore, the *purpose* of individual interventions may be to effect simple drainage alone, lavage of the necrotic cavity to assist drainage of necrotic debris, fragmentation of necrotic tissue to facilitate its drainage, débridement of necrotic tissue, and excision or resection of the pancreas. The overall purpose of intervention is to control the focus of sepsis combined with preservation of vital tissue. Drainage procedures involve allowing fluid and solid necrotic to drain externally out of the body or internally into the gastrointestinal tract. Lavage describes flushing away solid necrotic matter with fluid to facilitate external or internal drainage. Fragmentation is a method used to break down solid necrotic matter by instrumental or mechanical disruption to facilitate drainage. Débridement, which is often termed “necrosectomy,” involves taking or cutting out solid necrotic matter (typically with blunt dissection), and may or may not include postoperative lavage. Débridement may involve removal of all or only some of the necrotic tissue, although normal tissue is never intentionally removed. Only during excision or resection of the pancreas is normal tissue intentionally removed along with devitalised tissue. Such an approach is no longer recommended.



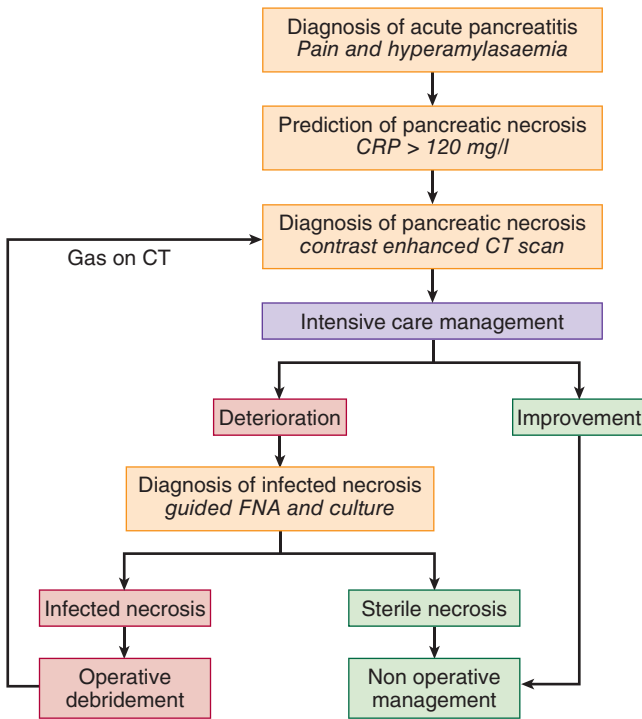


FIGURE 55-10 Algorithm for management of infected necrosis.

## GENERAL PRINCIPLES FOR INTERVENTION

Figure 55-10 is an algorithm for clinicians who are faced with the management of patients with infected necrosis. The general principles for intervention are the removal of all infected and necrotic tissue and fluid, preservation of vital tissues, and avoidance of intraoperative hemorrhage. Infected necrotic tissue and fluid should be sent for bacterial culture, in order to confirm the causative organisms and rationalize antibiotic therapy. All fluid collections identified on the preoperative CECT must be identified, opened, and evacuated. Débridement of necrotic tissue is performed bluntly, usually with digital dissection, careful use of instruments, and lavage. Only loosely adherent necrotic tissue should be removed and this is easier if there has been a significant delay between onset of disease and surgery. Use of a systematic approach, such as examining in turn the retroperitoneum behind the transverse, ascending, and descending colon, helps to ensure all areas of necrotic tissue are identified and removed. If multiple procedures are planned, the first necrosectomy provides the best exposure and therefore the most complete débridement that is safe should be accomplished at this time. The thoroughness of the initial débridement is the most important factor in determining the need for subsequent reoperation.<sup>87</sup> The need for complete débridement has been questioned and it has been suggested that incomplete débridement may be sufficient if adequate drainage and lavage is established.<sup>88</sup>

A key point is to avoid sharp dissection in order to prevent major hemorrhage. Adherent necrotic tissue should be left in situ, as this will subsequently demarcate and become loose.

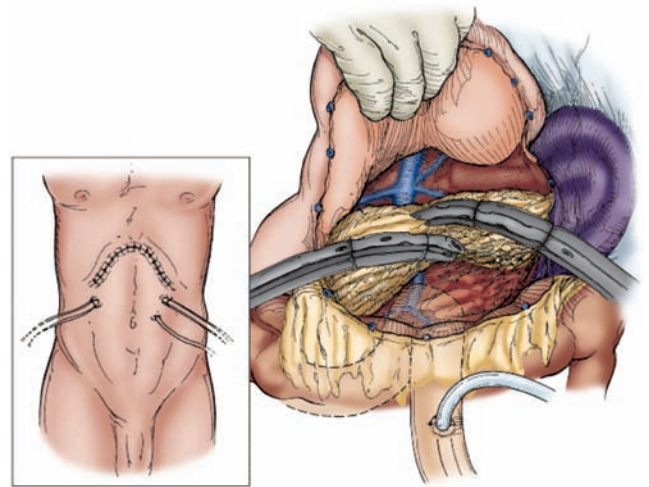


FIGURE 55-11 Large peripancreatic drains and placement of a tube feeding jejunostomy following necrosectomy.

Strands of tissue forming bridges across the cavity may be vessels and should not be avulsed. This is important, because bleeding from inflamed vessels within the retroperitoneum is difficult to control and may require formal packing.

Following débridement, extensive irrigation is used to flush away necrotic debris, inflammatory exudates, and residual bacteria. A gentle hydrodissection device can be used for this purpose. Postoperative lavage may be employed, and this can be either intermittent or continuous (Fig. 55-11).<sup>89,90</sup> The fluids most commonly used for this purpose are normal saline and peritoneal dialysis fluid, although there is no evidence to support any specific fluid type or flow rate in this setting.

The choice of operation is determined by the location, extent, and maturity of the necrotic material; status of the infection; the patient's condition; the degree of organ dysfunction; and the preference and experience of the surgeon.<sup>41</sup> A number of different approaches have been described (Table 55-4), some of which are only of historical interest. Interventions are complex, fraught with potentially life-threatening complications, and should only be performed by experienced surgeons in referral centers.

## OPEN SURGICAL PROCEDURES

The role of open surgical treatment of infected pancreatic necrosis is diminishing with the accumulating evidence for the less invasive approaches.<sup>85</sup> There are three broad approaches to open necrosectomy: (1) open necrosectomy with open or closed packing; (2) open necrosectomy with continuous closed postoperative lavage; and (3) programmed open necrosectomy. While the débridement technique for all the approaches is similar, they differ in terms of how they provide exit routes for infected fluid, debris, and tissue. The abdomen is best entered though a bilateral subcostal incision since this allows better access to the extremities of the gland and less contamination of the greater peritoneal sac if there

**TABLE 55-4: OPEN AND MINIMALLY INVASIVE APPROACHES TO THE TREATMENT OF PANCREATIC NECROSIS**

**Open surgery approaches**

- Pancreatic resection
- Necrosectomy + wide tube drainage
- Necrosectomy + relaparotomy (staged re-exploration)
- Necrosectomy + drainage + relaparotomy
- Necrosectomy + laparostomy ± open packing
- Necrosectomy + drainage + closed continuous lavage

**Minimally invasive approaches**

- Laparoscopic necrosectomy
- Laparoscopic intracavity necrosectomy
- Laparoscopic-assisted percutaneous drainage
- Laparoscopic transgastric necrosectomy
- Percutaneous necrosectomy and sinus tract endoscopy
- MRI–radiologically assisted necrosectomy
- Translumbar extraperitoneal retroperitoneoscopy
- Video-assisted retroperitoneal débridement

are subsequent procedures. The pancreas is exposed by dividing the gastrocolic omentum (Fig. 55-12) or gastrohepatic omentum to access the pancreas through the lesser sac. The body and tail of the pancreas can be exposed by elevating the transverse colon and gaining access to the lesser sac via the

transverse mesocolon (Fig. 55-13). Inflammatory adhesions may exist between the pancreas and stomach or transverse mesocolon, and great care is required during exposure. It is generally useful to take down both the hepatic and splenic flexures, if possible, as this will facilitate exposure and reduce the risk of colonic fistula secondary to drain erosion. When the process involves the head of the pancreas, access might require medial mobilization of the duodenum.

**Open Necrosectomy With Closed Packing.** The goal of necrosectomy with closed packing is to perform a single operation, with thorough débridement and removal of necrotic and infected tissue, and to avoid or minimize the need for reoperation or subsequent drainage.<sup>82</sup> Once the necrotic cavity is opened, fluid collections are evacuated and all areas of necrosis debrided. Some units use gauze stuffed Penrose drains placed via separate stab incisions, but there are many variations in practice with regards to the type and number of drains. With the Penrose drain technique, the intention is to fill the cavity and provide compression rather than facilitate external drainage per se, and between two and twelve drains are usually placed. Additional silicon drains (eg, Jackson-Pratt) are placed in the pancreatic bed and lesser sac to drain fluid from the area. Primary closure of the abdomen is routine with this approach. The stuffed Penrose drains are removed once every other day, starting 5–7 days postoperatively. The silicon drains are removed last. Packing techniques are probably best reserved to control hemorrhage as it is associated with an increased risk of enteric fistulae.

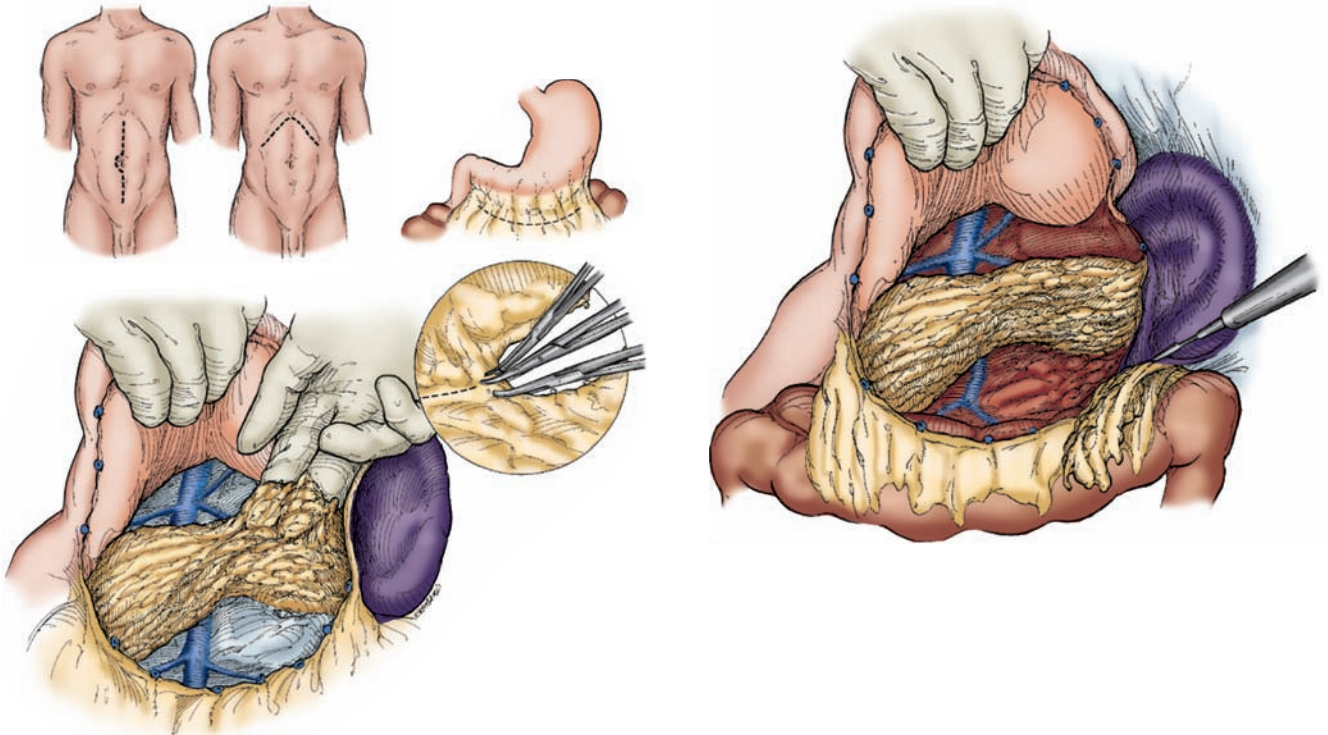


FIGURE 55-12 Necrosectomy via lesser sac.

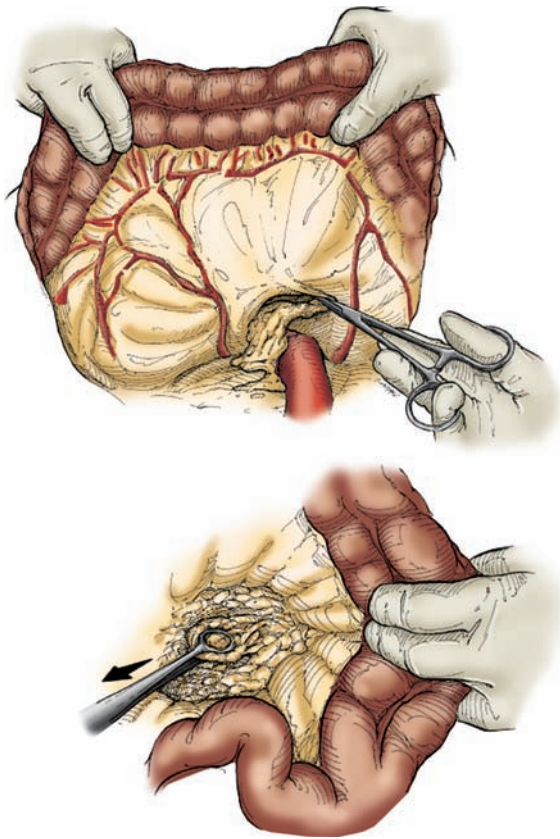


FIGURE 55-13 Necrosectomy via transverse mesocolon.

**Open Necrosectomy With Open Packing.** The difference with this approach to closed packing is that the abdomen is left open after débridement and packing of the abdomen.<sup>91</sup> An alternative form of open packing uses a 20-cm flank incision instead of an anterior laparotomy.<sup>92</sup> Open packing techniques have been reported to have higher incidences of fistulae, bleeding, and incisional hernias, as well as a slightly higher mortality rate.<sup>93</sup> However, it should be noted there are no prospective trials comparing open packing with any other techniques.

**Open Necrosectomy With Continuous Closed Post-Operative Lavage.** In this technique débridement is followed by continuous peripancreatic lavage to remove infected necrotic debris, peripancreatic exudates, and extravasated pancreatic exocrine fluid.<sup>82,86</sup> Drainage catheters, usually two on each side, are placed with their tips at the head and tail of the pancreas behind the ascending and descending colon. Placement of sump drains (20–24F) with two lumens allows inflow of lavage fluid and outflow of drainage fluid. Larger silicon drains (28–32F) allow evacuation of larger necrotic debris. During closure, a closed peripancreatic compartment is attempted by resuturing the gastrocolic and duodenocolic ligaments. Postoperative continuous lavage is instituted at 1–10 L per day, and is usually continued until the effluent is clear and the patient shows improvement in clinical and

laboratory parameters.<sup>82,94</sup> There is no evidence as to the best irrigation fluid, the optimal number or calibre of drains, or the duration of irrigation.

**Programmed Open Necrosectomy.** The principle of this approach is to be more conservative with débridement, particularly if the necrosis has not fully demarcated, with the intention of performing repeat procedures until débridement is no longer required.<sup>82</sup> Following necrosectomy, the pancreatic bed is packed and drains are placed on top of the packing. The abdominal wall is closed with a zipper or mesh sewn to the fascia. This allows easy repeated access to the abdomen and helps to prevent wound retraction. Reoperation is repeated every 48 hours until there is no further necrotic tissue to remove. In a proportion of patients primary closure is not possible and healing by secondary intention is allowed to occur. This procedure may be modified with the addition of intra-abdominal vacuum sealing (negative pressure 50–75 mm Hg) in order to encourage granulation of the pancreatic bed.<sup>95</sup>

**Endoscopic Techniques.** In 1996 Gagner described the first true endoscopic treatment of necrotizing pancreatitis, where the pancreas was debrided using a laparoscopic approach.<sup>96</sup> Over the last decade a wide range of endoscopic approaches for pancreatic necrosectomy have been described, including infracolic laparoscopy, transgastric laparoscopy, hand-assisted laparoscopy, retroperitoneal laparoscopy, transgastric flexible endoscopy, flexible endoscopy via a percutaneous endoscopic gastrostomy, and retroperitoneal nephroscopy.<sup>97–103</sup> This array of endoscopic techniques may be classified by the type of scope that is used: laparoscope, nephroscope, or flexible endoscope.<sup>104</sup> While some endoscopic procedures do not utilize radiological modalities, many are hybrid procedures using fluoroscopy or EUS.

**Laparoscopic Techniques.** Most laparoscopic techniques are minimally invasive versions of open surgical techniques, and use an anterior or lateral approach. In Gagner's original description of laparoscopic necrosectomy, two anterior routes (retrogastric retrocolic and transgastric) and one lateral route were described.<sup>96</sup> In the retrogastric retrocolic route, a 30-degree laparoscope is introduced through the umbilical port following CO<sub>2</sub> insufflation. Placement of additional ports depends on the position of the necrosis. Large drains are placed in the necrotic beds and continuous lavage may be established. In the transgastric route, the stomach is opened anteriorly and posteriorly. Endoluminal ports are used, which maintain the tip of the port inside the stomach. Débridement is performed internally through the posterior stomach wall. It is also possible to use a transduodenal route for necrosis of the pancreatic head. No drains are left in the stomach, although a drain might be placed over the incision in the anterior gastric wall. With the retroperitoneal route, the patient is placed in the left (or right) lateral position and a small flank incision made. The three muscle layers of the abdominal wall are split and a trocar is inserted. Using a 0-degree laparoscope and



CO<sub>2</sub> insufflation, a tract is made to access the pancreas. Once the necrotic areas have been identified, necrosectomy proceeds as when approached via a retrogastric retrocolic route.

These techniques have subsequently been modified. Of the lateral approaches, one of the most widely used laparoscopic techniques is “videoscopic-assisted retroperitoneal débridement” (VARD).<sup>101,105</sup> The purpose of this procedure differs from those of open necrosectomy. Rather than performing complete removal of all infected and necrotic tissue, its goal is to facilitate percutaneous drainage. In this technique radiological drainage of the lesion is first instituted. Following this, a 4–5 cm incision is made in the left flank at the site of the drain. A finger is used to probe and confirm entry into the necrotic cavity. Fluid and loose necrotic debris are removed by suction, and two ports (10–12 mm) are inserted through the incision. The incision is sealed with wet sponges and towel clips to allow insufflation with CO<sub>2</sub>. Débridement of necrotic tissue is performed with hydrodissection and 10 mm forceps. Drains are placed for postoperative continuous lavage. A 10F red rubber drain is brought through a separate anterolateral incision, and two Penrose drains are placed in the original skin incision. An ostomy bag is then positioned over the flank incision and Penrose drains, and continuous lavage is performed through the red rubber drain at 200 mL/h for 5 days or until the effluent is clear.

Variations on the anterior laparoscopic approaches are well described. In addition to the retrogastric, recolic, and transgastric routes, a transmesocolic route may be used. The transverse colon is elevated to expose the pancreatic lesion in the lesser sac.<sup>98</sup> Laparoscopic ultrasound may be used to confirm the position of the lesion, and transverse mesocolon is usually opened to the left of the middle colic vessels. Two or more drains are placed in the pancreatic bed for postoperative lavage. Anterior approaches may also incorporate a hand-assist device (hand-assisted laparoscopic surgery—HALS).<sup>100</sup>

**Nephroscopic Techniques.** Nephroscopic techniques utilize warmed fluid to expand the necrotic cavity and maintain a clear visual field. Use of a nephroscope for necrosectomy was termed “percutaneous necrosectomy” in the unit that pioneered this approach.<sup>106</sup> Its principle is the same as for open necrosectomy—debridement of devitalized tissue and establishment of a system for continuous postoperative lavage—although with reduced physiological stress on the patient. Percutaneous necrosectomy may only be used when the area of necrosis is accessible to percutaneous puncture, and is contraindicated in the presence of bowel ischemia, perforated viscus, or significant preoperative hemorrhage.<sup>82</sup> The first step is to insert a drainage catheter under CT guidance into the pancreatic lesion. The preferred path for drainage is between the lower pole of the spleen and the splenic flexure, although in right-sided necrosis a path through the gastrocolic omentum (anterior to the duodenum) may occasionally be used. The patient is then transferred to the operating room and positioned in the left (or right for right-sided necrosis) lateral position. The drain tract is then dilated to allow insertion of a 34F Amplatz sheath. A nephroscope is inserted



FIGURE 55-14 Percutaneous necrosectomy using operating nephroscope and supplemental laparoscopic port.

through the sheath into the cavity, and lavage is used to clear away debris and suppurative fluid (Fig. 55-14). Following necrosectomy, a 32F soft drainage tube is left in the cavity. An additional catheter may be used to allow continuous postoperative lavage. Repeat procedures are often required after 2–10 days.<sup>82,107</sup>

**Flexible Endoscopic Techniques.** Peroral flexible endoscopic techniques follow an internal route through either the gastric or duodenal wall or duodenal papilla, and some authors consider this to be a form of natural orifice transluminal endoscopic surgery (NOTES).<sup>108</sup> Initial descriptions of flexible endoscopic treatment of pancreatic necrosis used lavage and drainage without instrumental débridement.<sup>109</sup> A more aggressive approach was subsequently introduced, which demonstrated necrotic tissue could be debrided with baskets, snares, forceps, and suction.<sup>110,111</sup> Endoscopic retrograde cholangiopancreatography (ERCP) may be used to diagnose any communication between the duct and cavity or duct stenosis or disruption, and transpapillary stenting might be employed to decompress the duct. Puncture of the posterior gastric wall into the pancreatic lesion is performed at the point of maximal bulging, although confirmation of the location with EUS helps achieve correct placement of the perforation and avoid injury to vessels. The injection of contrast with fluoroscopy can be used to determine the extent of the cavity. The gastric perforation is dilated with balloons up to 20 mm. For lavage and drainage, a 7F nasocystic (lavage) and a 10F pigtail drain (drainage) are placed in the cavity. Necrosectomy may be performed with endoscopic instruments (eg, Dormia basket or polypectomy snare), and introduction of a forward-viewing endoscope into the necrotic cavity can be used for better visualization during the necrosectomy. Multiple necrosectomy procedures are usually required to clear the cavity of necrotic tissue.

Other techniques using flexible endoscopy through skin incisions have been described. Following percutaneous necrosectomy with a nephroscope, subsequent débridement may be undertaken using a flexible endoscope (sinus tract endoscopy).<sup>106</sup> A similar technique has been described following open necrosectomy via a translumbar incision, where a flexible endoscope is inserted into the cavity for débridement of ongoing necrosis.<sup>112</sup> Usually multiple débridement procedures are required, typically 8–10 sessions. The wide range of endoscopic approaches to necrosectomy and the absence of formal comparison make a recommendation for the optimal approach difficult. The selection of an endoscopic technique will be influenced by training, experience, and the availability of equipment, but it will also be determined by the location and complexity of the target lesion and the clinical status of the patient.

The first randomized controlled trial comparing two different minimally invasive approaches to the treatment of infected pancreatic necrosis has now been published (PENGUIN).<sup>112</sup> In this study endoscopic transgastric necrosectomy was found to be superior compared with VARD. There was a reduction in the incidence of the predefined composite endpoint (new onset multiple organ failure, intra-abdominal bleeding, enterocutaneous fistula, and/or pancreatic fistula) or death. There was a decrease in the incidence of new onset of multiple organ failure, supported by the finding that there was a significantly lower proinflammatory response after the procedure, and a reduction in the incidence of pancreatic fistulation.

**Radiological Techniques.** Since solid pancreatic necrosis is commonly associated with a fluid component (post-necrotic pancreatic or peripancreatic fluid collection or walled-off pancreatic necrosis), interventional radiological techniques are assuming greater importance, particularly for initial sepsis control to allow a delay in definitive necrosectomy.<sup>113</sup> Ultrasound, fluoroscopy, or CT are used to guide the interventional radiologist into the pancreatic lesion. These radiological modalities are then used to define the extent and composition of the lesion, visualize the position of instruments used, and determine the efficacy of the treatment procedure. The purpose of radiological techniques may be to achieve either drainage (with or without lavage) or débridement.

**Radiological Drainage Techniques.** Image-guided percutaneous catheter drainage may be used as a primary treatment for pancreatic necrosis, as a secondary treatment to manage postsurgical accumulation of fluid and residual necrosis, or to delay more definitive treatment until the patient has stabilized clinically or to allow the target lesion to mature.<sup>83</sup> Most collections are located in the lesser sac, anterior pararenal space, and other parts of the retroperitoneum.<sup>114</sup> The available internal routes into the target lesion are multiple but are most commonly retroperitoneal or transperitoneal. Transmural (transgastric or transduodenal) and transhepatic routes have been described, although these are less common.<sup>83</sup>

While transgressing the stomach poses little infection risk, gastric peristalsis may dislodge the catheter over time. Transgressing the liver carries increased theoretical risk of bleeding, but in practice this is generally safe. Routes should avoid colon, small bowel, spleen, and kidney to minimize the risk of hemorrhage and bacterial contamination. A retroperitoneal approach that avoids the peritoneal cavity is the preferred route, as this prevents contamination of the peritoneal cavity and possible peritonitis.<sup>114</sup>

Appropriate catheter selection is required to ensure adequate drainage and to maximize catheter patency. Typically catheters should have multiple side holes and a minimum diameter of 12–14F (4.0–4.7 mm).<sup>83</sup> Often multiple catheters are required, especially for large or complex lesions. Lavage can be employed to reduce the concentration of digestive enzymes and proinflammatory mediators in the lesion, and to remove solid necrotic debris from the cavity.<sup>115</sup> Lavage may also help ensure catheters remain patent. There have been theoretical concerns that lavage may spread infection, either from infected fluid spilling over into previously sterile cavities, or from the increased intracavity pressure resulting in translocation of bacteria into surrounding tissues. However, this is not been demonstrated as a major concern clinically, most likely because the pancreatic lesion is walled off in a fibrous capsule 4 to 6 weeks after the onset of acute pancreatitis.<sup>28</sup>

The efficacy of drainage procedures is limited by the contents of the target lesion, with purely solid lesions less likely to be amenable to radiological drainage. In patients with pancreatic necrosis treated with percutaneous catheter drainage, approximately half will be successful and not require surgical intervention.<sup>116,117</sup> Indications for surgical intervention in patients who have undergone percutaneous catheter drainage include persistent systemic or local manifestation of infected necrosis, physiological deterioration despite drain patency, persistent abdominal pain, and intolerance of oral intake after the systemic inflammatory response syndrome has resolved.<sup>116</sup>

**Radiological Débridement Techniques.** In some specialized centers, radiological techniques have been used to debride pancreatic necrosis. These procedures are similar to percutaneous catheter drainage as described earlier, but also include removal of necrotic material with snares, baskets, or by applying suction to a catheter during its removal.<sup>89,118,119</sup> Necrotic tissue may be fragmented with wires before attempting its extraction.<sup>89</sup> Use of lavage is essential to flush away the loosened necrotic debris.

## PROGNOSIS

The prognosis of patients with necrotizing pancreatitis depends on the extent of necrosis and the onset of infection. The overall mortality associated with infected pancreatic necrosis is around 25%,<sup>44</sup> while that associated with sterile necrosis is much lower (<5%).<sup>120</sup> Most deaths are in the context of multiorgan failure.<sup>121</sup>

## Pancreatic Abscess

The term *pancreatic abscess* was defined by the Atlanta Symposium as a circumscribed intra-abdominal collection of purulent material containing little or no pancreatic necrosis.<sup>4</sup> This term has been used in very different ways including infected acute fluid collection or pancreatic pseudocyst, and a collection of infected fluid arising from infected necrosis. Due to the confusion surrounding this term, it has been abandoned by the revised Atlanta Classification. In units or publications where use of this term persists, the principles guiding management of the lesion are the same as those for infected WON: elimination of infected tissue and/or fluid.

## REGIONAL COMPLICATIONS

### Vascular Complications

#### VENOUS THROMBOSIS

Venous thrombosis is a rare complication of acute pancreatitis and one that usually develops a few weeks after the onset. The etiology is multifactorial, but extrinsic compression of the vein by the swollen pancreas and/or fluid collection is important. Other factors include hypercoagulability and hemoconcentration. The consequences of splenic vein thrombosis are splenomegaly with discomfort and possible hypersplenism. Segmental venous hypertension may result in upper gastrointestinal bleeding from gastric varices. Because the risk of gastric variceal bleeding from pancreatitis-induced splenic vein thrombosis is low (5% for CT-identified varices and 18% for endoscopically identified varices) routine splenectomy is no longer recommended.<sup>122</sup> Portal vein thrombosis occurs insidiously and often is discovered after gastrointestinal hemorrhage has occurred. The consequences of acute superior mesenteric vein thrombosis are venous ischemia and infarction of the intestine. CT scanning with contrast material is helpful in the diagnosis of venous thrombosis and may show features of impaired mucosal enhancement, edematous swelling of the vessel wall, and most commonly filling defects within the vein. The goal of the initial treatment of venous thrombosis is to reduce extrinsic compression of the vein by drainage and/or débridement. The role of acute anticoagulation is controversial because of the risk of bleeding. If thrombosis occurs later in the disease course, anticoagulation can be prescribed with less trepidation. Thrombolytic therapy and surgical thrombectomy have no established role in the context of acute pancreatitis. Acute venous thrombosis is associated with a 25% recurrence rate without anticoagulant therapy and a 30% mortality. Anticoagulant therapy combined with surgery is associated with the lowest recurrence rate (3–5%).

#### BLEEDING

Bleeding associated with severe acute pancreatitis is usually, but not always, due to a pseudoaneurysm related to a pancreatic

pseudocyst. The splenic artery is the most commonly affected artery (30–50%) because of its proximity to the pancreas, followed by the gastroduodenal artery (10–15%), the inferior and superior pancreaticoduodenal arteries (10%), and all others to a lesser extent.

**Pathogenesis.** The disruption of the pancreas by necrosis and the damage to pancreatic ducts leads to the accumulation of activated proteolytic enzymes (eg, elastase), weakens the vessel wall, and promotes aneurysmal dilatation. This process is accelerated in the presence of infection. The contained rupture of the aneurysm is a pseudoaneurysm, an extravascular hematoma communicating with the intravascular space.

**Diagnosis.** Patients usually present with hypovolemic shock or with an unexplained drop in hemoglobin concentration. Bleeding may occur into a pseudocyst and tamponade, preventing any overt evidence of bleeding. Very rarely the diagnosis will be made in a patient with a known pseudocyst who develops an abdominal bruit.

Selective mesenteric angiography is the best way to make the diagnosis of pseudoaneurysm (see Fig. 55-5A, B), although it can often be detected on the arterial phase of CT scan. Angiography identifies the location of the pseudoaneurysm and its relationship to named vessels. The majority of patients will require surgical management, and the angiogram provides a useful guide.

**Treatment.** Pancreatic or peripancreatic bleeding is one of the most formidable and life-threatening complications of pancreatitis. The standard of care in dealing with pseudoaneurysms has been surgical intervention; however, many interventional radiologists have reported excellent outcomes after angioembolization. The approach to treatment depends on the hemodynamic stability of the patient. If the patient is anemic but stable, then transarterial catheter angioembolization of the pseudoaneurysm (see Fig. 55-5A, B) will be considered. If subsequent surgery is required, it can be performed under better conditions, with less risk of torrential hemorrhage. Success with embolization is operator-dependent but success approaches 90% in leading centers. Failure results from an inability to selectively cannulate the bleeding vessel or the poor placement of embolization material. This approach is less likely to succeed with diffuse bleeding, bleeding from the pancreatic head, and bleeding after necrosectomy. Recurrent bleeding occurs in fewer than 40% of patients, and the overall mortality is under 20%.

If emergency laparotomy is required for bleeding, it may not be possible to arrange prior angioembolization. The lifesaving surgery may involve under-running the bleeding vessel (inside or outside the pseudocyst) and/or pancreatic resection. The mortality rate following surgical treatment of arterial hemorrhage during the acute phase of pancreatitis ranges from 28 to 56% and is higher when bleeding from the head of the pancreas. The mortality rate following surgical treatment of massive hemorrhage is usually over 50%.



## Intestinal Complications

### PARALYTIC ILEUS

The proximity of the inflamed pancreas to the intestine commonly results in regional self-limiting paralytic ileus affecting the duodenum, proximal jejunum, or transverse colon. Another factor which may contribute to the ileus is the relative splanchnic ischemia secondary to the reflex vasoconstriction in response to systemic hypotension. An ileus gives rise to the classic “sentinel loop” and “colon cutoff” signs on plain radiographs.

### INTESTINAL ISCHEMIA AND NECROSIS

Subclinical mucosal ischemia is common in acute pancreatitis, particularly during the early phase, and occurs in response to the hypovolemia and reflex splanchnic vasoconstriction. Intestinal ischemia might be compounded by abdominal compartment syndrome, nonselective inotropes, and the demands of early and continuous enteral feeding. Full-thickness necrosis is rare and probably involves venous and/or arterial thrombosis at sites proximal to the inflammatory process. The middle mesocolic vessels and the transverse colon are mostly at risk.

### INTESTINAL OBSTRUCTION

Mechanical obstruction rarely complicates acute pancreatitis. The mechanism is usually inflammatory stenosis which presents very late. It is unusual to require surgery.

### CHOLESTASIS

Biochemical and clinical jaundice occur in approximately 20% of patients with acute pancreatitis, often during their hospital course. Mild cholestasis is more common and has been attributed to periductal edema and cholangitis. Long-term total parenteral nutrition will contribute to abnormal liver tests. Extrahepatic bile duct obstruction most often is due to choledocholithiasis or compression by a pseudocyst or pancreatic abscess.

## SYSTEMIC COMPLICATIONS

### Systemic Inflammatory Response Syndrome

The systemic inflammatory response syndrome (SIRS) is common with acute pancreatitis and encompasses the hallmarks of a proinflammatory state (ie, tachycardia, tachypnea or hyperpnea, hypotension, hypoperfusion, oliguria, leukocytosis or leukopenia, pyrexia or hypothermia, and the need for volume infusion) but without end-organ damage, identifiable bacteremia, or the need for pharmacologic support. SIRS is distinct from sepsis (where there is an identified pathogen)

and septic shock (where there is associated hypotension). SIRS is best regarded as an exuberant host inflammatory response and the consequence of hypoperfusion.

There is no single trigger for SIRS. Instead, it represents a whole-organism response to a variety of quite different challenges. Theories on the drivers for SIRS include the immunologic dissonance theory (where there is imbalance between the pro- and anti-inflammatory responses)<sup>123</sup> and the gut motor theory (where decreased intestinal perfusion and subsequent damage to the mucosal and immunologic barriers may allow the translocation of endogenous bacteria or their products into the systemic circulation).<sup>124</sup> More recently, the intestinal mucosa has been considered another source of inflammatory mediators activated by hypoperfused mucosa. Measurement of intramucosal pH (tonometry) can stratify mortality risk in acute pancreatitis.<sup>125</sup>

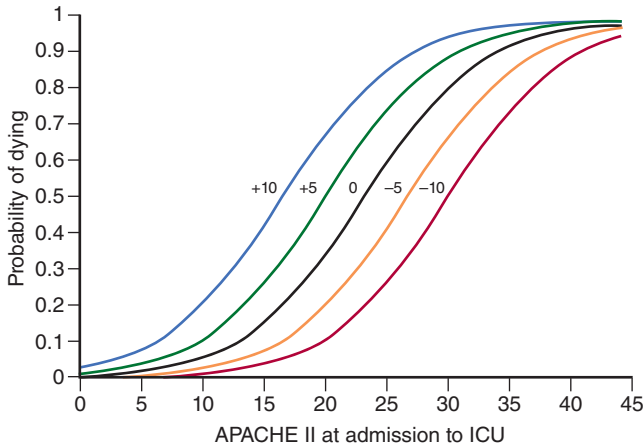
The mediation of SIRS is due to a number of well-described cytokines responsible for the proinflammatory state, a full description of which is beyond the scope of this chapter. In many patients with acute pancreatitis, SIRS progresses to multiple organ dysfunction syndrome (MODS) and possible end-organ damage. Occasionally, patients will be admitted with fulminant or early severe acute pancreatitis, often with respiratory and renal impairment from the outset, and these patients are responsible for early deaths. Organ failure on admission, which occurs in 30–40% of patients with necrotizing pancreatitis, is a very poor prognostic sign, doubling intensive care stay and increasing the mortality rate to four-fold.<sup>43</sup> Early aggressive volume resuscitation has an important role in attenuating the systemic inflammatory response.<sup>125</sup>

### Multiple Organ Dysfunction Syndrome

The development of MODS is common in severe acute pancreatitis. It has been defined as the presence of altered organ function in a severely ill patient such that homeostasis cannot be maintained without intervention.<sup>126</sup> Many patients with early organ failure respond rapidly to supportive treatment and appear to have an otherwise uncomplicated outcome. These patients are said to have transient organ dysfunction, if it resolves within 48 hours. Recently, it has been shown that organ failure in the first week of admission is a dynamic process and that the progression of early organ failure was attended by a mortality rate in excess of 50%. The response to the initial intensive care is an important determinant of outcome (Fig. 55-15).<sup>127</sup>

The sequence of organ dysfunction in acute pancreatitis has not been defined. Initial pulmonary insufficiency and renal impairment are often followed by circulatory failure and then metabolic dysfunction and liver failure.

Many potential predictors of organ failure early in the course of admission have been studied. MODS can be predicted with reasonably high accuracy at the time of hospital admission using a combination of the anti-inflammatory cytokine IL-10 (an early marker of systemic inflammation) and serum calcium (an early marker of organ dysfunction).<sup>128</sup>



**FIGURE 55-15** The relationship between the change in the severity of acute pancreatitis (APACHE II score) over the initial 48 hours of intensive care management and the change in predicted mortality. (Reproduced from Flint R, Windsor JA. The physiological response to intensive care: a clinically relevant predictor in severe acute pancreatitis. *Arch Surg.* 2004;139:438–443, copyright © 2004 American Medical Association. All rights reserved.)

MODS scoring systems can be classified using general physiologic critical care scores, that is, the Acute Physiologic and Chronic Health Evaluation (APACHE) score, the Simplified Acute Physiology Score (SAPS), the Mortality Probability Model (MPM), a specific organ score to describe dysfunction (Multiple Organ Dysfunction Score [MODS]), developed by Bernard and colleagues as a descriptor of clinical outcome in MODS, the Sepsis-related Organ Failure Assessment (SOFA), and the Logistic Organ Dysfunction System (LODS). The specific organ dysfunction scores classify organs as failed (yes or no) or dysfunctional using an ordinal scale (graded score). The aggregate score quantitates severity in any one organ and the overall severity of organ dysfunction. The aggregate score then can be interpreted as the likelihood of predicted mortality based on the observed mortality in those study patients used to construct the original scoring system.

There exists no rationale to favor one scoring system over another. The scoring systems do not tell the clinician when specific organ dysfunction is reversible or irreversible. Practically, a simple count of organs affected and the duration of the dysfunction will stratify mortality within broad ranges between 60 and 98% depending on age, with dysfunction in three or more organs for at least a week.

## Respiratory Complications

Respiratory impairment can result from several causes, including atelectasis, pleural effusion, pneumonia, mediastinal pseudocyst or abscess, and/or adult respiratory distress syndrome (ARDS). Tachypnea, mild respiratory alkalosis, and mild hypoxemia are common within 2 days of the onset

of acute pancreatitis. These clinical features usually can be corrected with analgesia, supplemental oxygen, and chest physiotherapy. A pleural effusion may require a chest drain. Impending respiratory failure is suggested when the arterial  $PO_2$  remains less than 60 mm Hg despite high-flow oxygen by mask. These patients should be considered for mechanical ventilation. Lung-protection ventilation strategies, with low tidal volumes for patients with ARDS, are recommended.<sup>129</sup> ARDS may occur within a few days of admission or after the development of infected necrosis and septicemia. ARDS results from the release of activated pancreatic enzymes, vasoactive lysosomal enzymes, and especially phospholipase  $A_2$  (which destroys surfactant). Parenchymal injury appears to be due primarily to oxidative damage from the activated neutrophils in the lung.

## Renal Complications

Renal impairment is usually due to both hypovolemia (prerenal failure) and direct nephrotoxicity from the mediators of acute pancreatitis. Activation of the renin-angiotensin system may contribute to reduced renal perfusion. This manifests as oliguria (<30 mL/h) or anuria and as an increased serum concentration of creatinine and urea. The initial approach is aggressive intravenous crystalloid administration (of up to 10 L/24 h). Then diuretics (furosemide 20–200 mg/24 h) and dopamine infusion (4  $\mu$ g/kg/min) should be considered. Further deterioration will necessitate continuous hemofiltration and/or hemodialysis.

## Cardiovascular Complications

These include arrhythmias, pericardial effusion, impaired myocardial contractility, reduced peripheral vascular resistance, and increased permeability. Hypovolemia, from third-space fluid loss, is common during the first 12 hours and may be up to 30% in severe acute pancreatitis. This problem should be anticipated with aggressive intravenous fluid therapy in the first 24–48 hours. Circulatory failure (mean arterial pressure [MAP] <70 mm Hg) requires prompt, aggressive fluid resuscitation plus or minus inotropic support. SIRS is characterized by decreased peripheral vascular resistance and is the reason for the preferred use of norepinephrine to increase vascular tone and blood pressure (dose 0.05–0.2  $\mu$ g/kg/min). Epinephrine (dose 0.05–0.2  $\mu$ g/kg/min) also may be used to support cardiac output. Unfortunately, these inotropes will compound splanchnic vasoconstriction.

If the patient with infected necrosis meets the criteria for severe sepsis, he or she should be managed by current sepsis guidelines.<sup>130</sup> Although not widely adopted, there is the evidence for the use of recombinant human activated protein C and low-dose corticosteroids for vasopressor-dependent shock.<sup>131,132</sup> There is evidence that glycemic control is important in patients with severe sepsis, although

very tight control is associated with hypoglycemia and possibly increased mortality.<sup>133,134</sup>

## Metabolic Complications

Hypocalcemia is the most frequent metabolic disturbance, and it usually occurs during the first week. Low serum albumin will make the hypocalcemia appear worse, and therefore, replacement should be based on ionized calcium. There are several factors likely to be responsible for low calcium. Primarily, calcium is sequestered in areas of fat necrosis by the process of saponification. In addition, there is probably a contribution from altered calcium-regulating hormones (eg, calcitonin, parathyroid hormone, and glucagon). Hypomagnesemia may inhibit parathyroid hormone and contribute to the hypocalcemia.

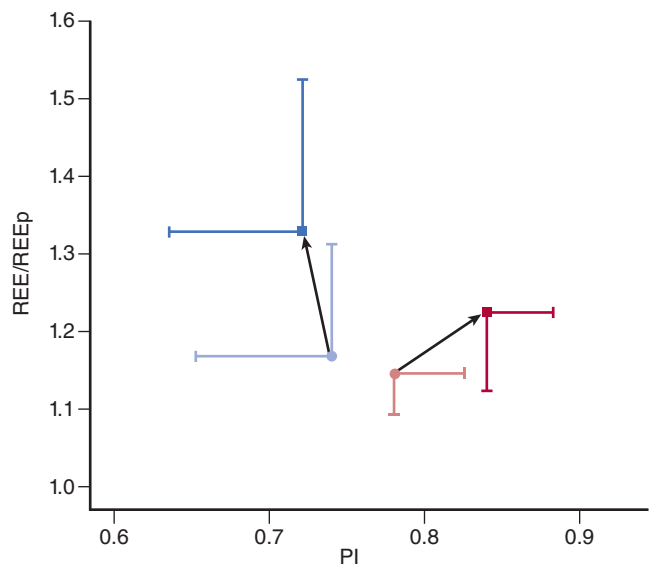
Hyperglycemia is a frequent finding and usually corrects without the need for treatment. It is an adverse prognostic sign in itself. There are three contributing factors to hyperglycemia, including a stress-induced increase in cortisol and catecholamines, hyperglucagonemia, and probably most important, an insulin deficiency that may reflect necrosis of the islet cells. Glucose intolerance, if not insulin-dependent diabetes, occurs in up to half of patients who have had severe necrotizing pancreatitis.

Disseminated intravascular coagulopathy is not common, but there is a well recognized tendency toward hypercoagulability in acute pancreatitis. Other rare complications include subcutaneous fat necrosis and polyarthritides, which are also seen in patients with acinar cell carcinoma of the pancreas and thought to be due to increased serum lipase. There have also been reports of osteolysis and rhabdomyolysis in severe acute pancreatitis.

Protein-calorie malnutrition is a complication of acute pancreatitis, especially when it is severe and associated with infected necrosis. These patients have a significantly elevated resting energy expenditure, and it has been shown that total parenteral nutrition is unable to reverse this hypercatabolic insult on body protein (Fig. 55-16).<sup>135</sup> The importance of and the approaches to nutritional support in patients with severe acute pancreatitis are discussed in Chap. 54.

## Encephalopathy

Pancreatic encephalopathy is a rare complication of acute pancreatitis. Clinical features include focal neurologic signs and acute onset of dementia. This picture can fluctuate over time; cyclic progression with remission and relapses has been described. Although the exact mechanisms are unclear, post-mortem examination reveals amylase in the cerebrospinal fluid. MRI of the brain may be helpful. Patchy white matter signal abnormalities resembling the plaques seen in multiple sclerosis may reflect the lesions that are found in the cerebral white matter of postmortem-confirmed cases. Treatment is supportive. Any patient with suspicious or unusual neurologic



**FIGURE 55-16** The changes in protein index (measured/predicted total body protein, expressed as mean  $\pm$  SEM) on day 0 (circles) and day 14 (squares) of total parenteral nutrition in acute pancreatitis patients with (open symbols) and without (closed symbols) sepsis and/or recent surgery. (Reproduced from Chandrasegaram MD, Plank LD, Windsor JA. The impact of total parenteral nutrition on the body composition of patients with acute pancreatitis. *JPEN J Parenter Enter Nutr.* 2005;29:65–73. Reprinted by permission of SAGE Publications.)

symptoms and signs associated with possible malnutrition, hyperemesis, or malabsorption should be given intravenous thiamine to avoid the potential morbidity and mortality associated with undiagnosed Wernicke's encephalopathy.

## CONCLUSION

The many and varied complications of acute pancreatitis present a considerable clinical challenge and highlight the need for the treatment of patients with severe disease in centers able to offer expertise in a wide range of disciplines including intensive care, surgery, endoscopy, radiology, infectious disease, and nutrition. The two primary goals of research in the field of acute pancreatitis should be aimed at preventing infected pancreatic necrosis and reducing the frequency and severity of multiple organ dysfunction. In the meantime the clinician caring for patients with acute pancreatitis must remain vigilant to detect the development of local, regional, and systemic complications of this protean disease, and be well versed in the considerable recent progress in the treatment of local complications. Of note is the more conservative approach to the simple pseudocyst, the judicious primary use of percutaneous drainage for infected local complications, and the evolution of minimally invasive techniques, which if required should result in improved outcomes in these patients with limited physiological reserve.



## REFERENCES

- UK guidelines for the management of acute pancreatitis. *Gut*. 2005;54(suppl 3):iii1–9.
- Petrov MS, Shanbhag S, Chakraborty M, Phillips AR, Windsor JA. Organ failure and infection of pancreatic necrosis as determinants of mortality in patients with acute pancreatitis. *Gastroenterology*. 2010;139:813–820.
- Petrov MS, Windsor JA. Classification of the severity of acute pancreatitis: how many categories make sense? *Am J Gastroenterol*. 2010;105:74–76.
- Bradley EL, 3rd. A clinically based classification system for acute pancreatitis. Summary of the International Symposium on Acute Pancreatitis, Atlanta, GA, September 11 through 13, 1992. *Arch Surg*. 1993;128:586–590.
- Bollen TL, Besselink MG, van Santvoort HC, Gooszen HG, van Leeuwen MS. Toward an update of the Atlanta classification on acute pancreatitis: review of new and abandoned terms. *Pancreas*. 2007;35:107–113.
- Bollen TL, van Santvoort HC, Besselink MG, et al. The Atlanta Classification of acute pancreatitis revisited. *Br J Surg*. 2008;95:6–21.
- Acute Pancreatitis Classification Working Group. Revision of the Atlanta Classification of Acute Pancreatitis. <http://www.pancreasclub.com/resources/AtlantaClassification.pdf> (Accessed 18 April 2009), 2008.
- Forsmark CE, Baillie J. AGA Institute technical review on acute pancreatitis. *Gastroenterology*. 2007;132:2022–2044.
- Bradley EL, Gonzalez AC, Clements JL, Jr. Acute pancreatic pseudocysts: incidence and implications. *Ann Surg*. 1976;184:734–737.
- Siegelman SS, Copeland BE, Saba GP, Cameron JL, Sanders RC, Zerhouni EA. CT of fluid collections associated with pancreatitis. *AJR Am J Roentgenol*. 1980;134:1121–1132.
- Platell C, Cooper D, Hall JC. A meta-analysis of peritoneal lavage for acute pancreatitis. *J Gastroenterol Hepatol*. 2001;16:689–693.
- Balthazar EJ. Acute pancreatitis: assessment of severity with clinical and CT evaluation. *Radiology*. 2002;223:603–613.
- Bradley EL, Clements JL, Jr., Gonzalez AC. The natural history of pancreatic pseudocysts: a unified concept of management. *Am J Surg*. 1979;137:135–141.
- Grace PA, Williamson RC. Modern management of pancreatic pseudocysts. *Br J Surg*. 1993;80:573–581.
- D'Egidio A, Schein M. Pancreatic pseudocysts: a proposed classification and its management implications. *Br J Surg*. 1991;78:981–984.
- Rau BM, Beger HG. Surgical management of pseudocysts after acute pancreatitis. In: Beger HG, Matsuno S, Cameron JL, Rau BM, Sunamura M, Schulick RD, eds. *Diseases of the Pancreas*. Springer Berlin Heidelberg; 2008:259–270.
- Barthel M, Lamblin G, Gasmi M, Vitton V, Desjeux A, Grimaud JC. Clinical usefulness of a treatment algorithm for pancreatic pseudocysts. *Gastrointest Endosc*. 2008;67:245–252.
- Balachandra S, Siriwardena AK. Systematic appraisal of the management of the major vascular complications of pancreatitis. *Am J Surg*. 2005;190:489–495.
- Sedlack R, Affi A, Vazquez-Sequeiros E, Norton ID, Clain JE, Wiersema MJ. Utility of EUS in the evaluation of cystic pancreatic lesions. *Gastrointest Endosc*. 2002;56:543–547.
- Ahearne PM, Baillie JM, Cotton PB, Baker ME, Meyers WC, Pappas TN. An endoscopic retrograde cholangiopancreatography (ERCP)-based algorithm for the management of pancreatic pseudocysts. *Am J Surg*. 1992;163:111–115; discussion 115–116.
- Nealon WH, Walser E. Main pancreatic duct anatomy can direct choice of modality for treating pancreatic pseudocysts (surgery versus percutaneous drainage). *Ann Surg*. 2002;235:751–758.
- Fayad LM, Kowalski T, Mitchell DG. MR cholangiopancreatography: evaluation of common pancreatic diseases. *Radiol Clin North Am*. 2003;41:97–114.
- Brugge WR, Lauwers GY, Sahani D, Fernandez-del Castillo C, Warshaw AL. Cystic neoplasms of the pancreas. *N Engl J Med*. 2004;351:121–126.
- Andren-Sandberg A, Dervenis C. Pancreatic pseudocysts in the 21st century. Part I: classification, pathophysiology, anatomic considerations and treatment. *JOP*. 2004;5:8–24.
- Mehta R, Suvarna D, Sadasivan S, et al. Natural course of asymptomatic pancreatic pseudocyst: a prospective study. *Indian J Gastroenterol*. 2004;23:140–142.
- Johnson MD, Walsh RM, Henderson JM, et al. Surgical versus nonsurgical management of pancreatic pseudocysts. *J Clin Gastroenterol*. 2009;43:586–590.
- Varadarajulu S, Lopes TL, Wilcox CM, Drelichman ER, Kilgore ML, Christein JD. EUS versus surgical cyst-gastrostomy for management of pancreatic pseudocysts. *Gastrointest Endosc*. 2008;68:649–655.
- Kloppel G. Acute pancreatitis. *Semin Diagn Pathol*. 2004;21:221–226.
- Andersson B, Andren-Sandberg A, Andersson R. Survey of the management of pancreatic pseudocysts in Sweden. *Scand J Gastroenterol*. 2009;44:1252–1258.
- Gerzof SG, Johnson WC, Robbins AH, Spechler SJ, Nabseth DC. Percutaneous drainage of infected pancreatic pseudocysts. *Arch Surg*. 1984;119:888–893.
- MacErlean DP, Bryan PJ, Murphy JJ. Pancreatic pseudocyst: management by ultrasonically guided aspiration. *Gastrointest Radiol*. 1980;5:255–257.
- Karlson KB, Martin EC, Fankuchen EI, Mattern RF, Schultz RW, Casarella WJ. Percutaneous drainage of pancreatic pseudocysts and abscesses. *Radiology*. 1982;142:619–624.
- Kuligowska E, Olsen WL. Pancreatic pseudocysts drained through a percutaneous transgastric approach. *Radiology*. 1985;154:79–82.
- Davies RP, Cox MR, Wilson TG, Bowyer RC, Padbury RT, Toouli J. Percutaneous cystogastrostomy with a new catheter for drainage of pancreatic pseudocysts and fluid collections. *Cardiovasc Intervent Radiol*. 1996;19:128–131.
- Morton JM, Brown A, Galanko JA, Norton JA, Grimm IS, Behrns KE. A national comparison of surgical versus percutaneous drainage of pancreatic pseudocysts: 1997–2001. *J Gastrointest Surg*. 2005;9:15–20; discussion 20–21.
- Kellogg TA, Horvath KD. Minimal-access approaches to complications of acute pancreatitis and benign neoplasms of the pancreas. *Surg Endosc*. 2003;17:1692–1704.
- Bhattacharya D, Ammori BJ. Minimally invasive approaches to the management of pancreatic pseudocysts: review of the literature. *Surg Laparosc Endosc Percutan Tech*. 2003;13:141–148.
- Go V. Etiology and epidemiology of pancreatitis in the United States. In: Bradley E, ed. *Acute Pancreatitis: Diagnosis and Therapy*. New York, NY: Raven Press; 1994:235–247.
- Goldacre MJ, Roberts SE. Hospital admission for acute pancreatitis in an English population, 1963–1998: database study of incidence and mortality. *BMJ*. 2004;328:1466–1469.
- Beger HG, Rau B, Mayer J, Pralle U. Natural course of acute pancreatitis. *World J Surg*. 1997;21:130–135.
- Buchler MW, Gloor B, Muller CA, Friess H, Seiler CA, Uhl W. Acute necrotizing pancreatitis: treatment strategy according to the status of infection. *Ann Surg*. 2000;232:619–626.
- Besselink MG, van Santvoort HC, Boermeester MA, et al. Timing and impact of infections in acute pancreatitis. *Br J Surg*. 2009;96:267–273.
- Beger HG, Rau B, Isenmann R. Natural history of necrotizing pancreatitis. *Pancreatology*. 2003;3:93–101.
- Rau BM. Outcome determinants in acute pancreatitis. *The American Journal of Surgery*. 2007;194:S39–S44.
- Kloppel G. Pathomorphology of acute pancreatitis. *Ann Ital Chir*. 1995;66:149–154.
- Trapnell J. Management of the complications of acute pancreatitis. *Ann R Coll Surg Engl*. 1971;49:361–372.
- Kloppel G, Maillet B. Chronic pancreatitis: evolution of the disease. *Hepatogastroenterology*. 1991;38:408–412.
- Kloppel G, Maillet B. The morphological basis for the evolution of acute pancreatitis into chronic pancreatitis. *Virchows Arch A Pathol Anat Histopathol*. 1992;420:1–4.
- Kloppel G, Maillet B. Pathology of acute and chronic pancreatitis. *Pancreas*. 1993;8:659–670.
- Rau B, Uhl W, Buchler MW, Beger HG. Surgical treatment of infected necrosis. *World J Surg*. 1997;21:155–161.
- Beger HG, Bittner R, Block S, Buchler M. Bacterial contamination of pancreatic necrosis. A prospective clinical study. *Gastroenterology*. 1986;91:433–438.
- Gloor B, Muller CA, Worni M, et al. Pancreatic infection in severe pancreatitis: the role of fungus and multiresistant organisms. *Arch Surg*. 2001;136:592–596.
- Papachristou GI, Muddana V, Yadav D, et al. Comparison of BISAP, Ranson's, APACHE-II, and CTSI scores in predicting organ failure, complications, and mortality in acute pancreatitis. *Am J Gastroenterol*. 2009.
- Balthazar EJ. Staging of acute pancreatitis. *Radiol Clin North Am*. 2002;40:1199–1209.

55. UK working party on acute pancreatitis. UK guidelines for the management of acute pancreatitis. *Gut*. 2005;54:III1–III9.
56. Banks PA, Freeman ML. Practice guidelines in acute pancreatitis. *Am J Gastroenterol*. 2006;101:2379–2400.
57. Messiou C, Chalmers A. Imaging in acute pancreatitis. *Imaging*. 2004;16:314–322.
58. Uhl W WA, Imrie C, Bassi C. IAP guidelines for the surgical management of acute pancreatitis. *Pancreatol*. 2002;2:565–573.
59. Tsuji Y, Yamamoto H, Yazumi S, Watanabe Y, Matsueda K, Chiba T. Perfusion computerized tomography can predict pancreatic necrosis in early stages of severe acute pancreatitis. *Clin Gastroenterol Hepatol*. 2007;5:1484–1492.
60. Charbonney E, Nathens AB. Severe acute pancreatitis: a review. *Surg Infect (Larchmt)*. 2008;9:573–578.
61. Rickes S, Uhle C, Kahl S, et al. Echo enhanced ultrasound: a new valid initial imaging approach for severe acute pancreatitis. *Gut*. 2006;55:74–78.
62. Lopez A, de la Cueva L, Martinez MJ, et al. Usefulness of technetium-99m hexamethylpropylene amine oxime-labeled leukocyte scintigraphy to detect pancreatic necrosis in patients with acute pancreatitis. Prospective comparison with Ranson, Glasgow and APACHE-II scores and serum C-reactive protein. *Pancreatol*. 2007;7:470–478.
63. Wilson C, Heads A, Shenkin A, Imrie CW. C-reactive protein, antiproteases and complement factors as objective markers of severity in acute pancreatitis. *Br J Surg*. 1989;76:177–181.
64. Windsor JA. Search for prognostic markers for acute pancreatitis. *Lancet*. 2000;355:1924–1925.
65. Xu T, Cai Q. Prophylactic antibiotic treatment in acute necrotizing pancreatitis: Results from a meta-analysis. *Scandinavian Journal of Gastroenterology*. 2008;43:1249–1258.
66. Petrov MS. Meta-analyses on the prophylactic use of antibiotics in acute pancreatitis: many are called but few are chosen. *Am J Gastroenterol*. 2008;103:1837–1838.
67. Jafri NS, Mahid SS, Idstein SR, Hornung CA, Galandiuk S. Antibiotic prophylaxis is not protective in severe acute pancreatitis: a systematic review and meta-analysis. *The American Journal of Surgery*. 2009;197:806–813.
68. Isenmann R, Schwarz M, Rau B, Trautmann M, Schober W, Beger HG. Characteristics of infection with *Candida* species in patients with necrotizing pancreatitis. *World J Surg*. 2002;26:372–376.
69. Connor S, Alexakis N, Neal T, et al. Fungal infection but not type of bacterial infection is associated with a high mortality in primary and secondary infected pancreatic necrosis. *Dig Surg*. 2004;21:297–304.
70. De Silva NM, Windsor JA. *Clostridium perfringens* infection of pancreatic necrosis: absolute indication for early surgical intervention. *ANZ Journal of Surgery*. 2006;76:757–759.
71. Pappas TN. Con: computerized tomographic aspiration of infected pancreatic necrosis: the opinion against its routine use. *Am J Gastroenterol*. 2005;100:2373–2374.
72. Hartwig W, Carter EA, Jimenez RE, et al. Neutrophil metabolic activity but not neutrophil sequestration reflects the development of pancreatitis-associated lung injury. *Crit Care Med*. 2002;30:2075–2082.
73. Uhl W, Warshaw A, Imrie C, et al. IAP guidelines for the surgical management of acute pancreatitis. *Pancreatol*. 2002;2:565–573.
74. Nathens AB, Curtis JR, Beale RJ, et al. Management of the critically ill patient with severe acute pancreatitis. *Crit Care Med*. 2004;32: 2524–2536.
75. French Consensus Conference on Acute Pancreatitis: Conclusions and Recommendations. Paris, France, 25–26 January 2001. *Eur J Gastroenterol Hepatol*. 2001;13(suppl 4):S1–S13.
76. Toouli J, Brooke-Smith M, Bassi C, et al. Guidelines for the management of acute pancreatitis. *J Gastroenterol Hepatol*. 2002;17(suppl):S15–S39.
77. Pancreatic Disease Group, Chinese Society of Gastroenterology, Chinese Medical Association. Consensus on the diagnosis and treatment of acute pancreatitis. *Chin J Dig Dis*. 2005;6(1):47–51.
78. Jacobson BC, Baron TH, Adler DG, et al. ASGE guideline: the role of endoscopy in the diagnosis and the management of cystic lesions and inflammatory fluid collections of the pancreas. *Gastrointest Endosc*. 2005;61:363–370.
79. Uomo G, Pezzilli R, Cavallini G. Management of acute pancreatitis in clinical practice. ProInf-A.I.S.P. Study Group. Progetto Informatizzato Pancreatic Acute—Associazione Italiana Studio Pancreas. *Ital J Gastroenterol Hepatol*. 1999;31:635–642.
80. Banks PA. Pro: computerized tomographic fine needle aspiration (CT-FNA) is valuable in the management of infected pancreatic necrosis. *Am J Gastroenterol*. 2005;100:2371–2372.
81. Rau B, Pralle U, Uhl W, Schoenberg MH, Beger HG. Management of sterile necrosis in instances of severe acute pancreatitis. *J Am Coll Surg*. 1995;181:279–288.
82. Uhl W, Strobel O, Buchler M, et al. Necrosectomy. *Atlas of Upper Gastrointestinal and Hepato-Pancreato-Biliary Surgery*. 2007:893–915.
83. Segal D, Mortele KJ, Banks PA, Silverman SG. Acute necrotizing pancreatitis: role of CT-guided percutaneous catheter drainage. *Abdom Imaging*. 2007;32:351–361.
84. Loveday BP, Mittal A, Phillips A, Windsor JA. Minimally invasive management of pancreatic abscess, pseudocyst, and necrosis: a systematic review of current guidelines. *World J Surg*. 2008;32:2383–2394.
85. van Santvoort HC, Besselink MG, Bakker OJ, et al. A step-up approach or open necrosectomy for necrotizing pancreatitis. *N Engl J Med*. 2010;362(16):1491–1502.
86. Loveday BP, Petrov MS, Connor S, et al. A comprehensive classification of invasive procedures for treating the local complications of acute pancreatitis based on visualization, route, and purpose. *Pancreatol*. 2011;11(4):406–413.
87. Fernandez-del Castillo C, Rattner DW, Makary MA, Mostafavi A, McGrath D, Warshaw AL. Debridement and closed packing for the treatment of necrotizing pancreatitis. *Ann Surg*. 1998;228:676–684.
88. Connor S, Raraty MG, Neoptolemos JP, et al. Does infected pancreatic necrosis require immediate or emergency debridement? *Pancreas*. 2006;33:128–134.
89. Echenique AM, Sleeman D, Yrizarry J, et al. Percutaneous catheter-directed debridement of infected pancreatic necrosis: results in 20 patients. *J Vasc Interv Radiol*. 1998;9:565–571.
90. Beger HG, Buchler M, Bittner R, Block S, Nevalainen T, Roscher R. Necrosectomy and postoperative local lavage in necrotizing pancreatitis. *Br J Surg*. 1988;75:207–212.
91. Götzinger P. Necrosectomy and redressing. *Diseases of the Pancreas*. 2008:225–230.
92. Nakasaki H, Tajima T, Fujii K, Makuuchi H. A surgical treatment of infected pancreatic necrosis: retroperitoneal laparotomy. *Dig Surg*. 1999;16:506–511.
93. Heinrich S, Schafer M, Rousson V, Clavien PA. Evidence-based treatment of acute pancreatitis: a look at established paradigms. *Ann Surg*. 2006;243:154–168.
94. Beger HG, Buchler M, Bittner R, Block S, Nevalainen T, Roscher R. Necrosectomy and postoperative local lavage in necrotizing pancreatitis. *British Journal of Surgery*. 1988; 75:207–212.
95. Olejnik J, Vokurka J, Vician M, Olejnik J, Vokurka J, Vician M. Acute necrotizing pancreatitis: intra-abdominal vacuum sealing after necrosectomy. *Hepatogastroenterology*. 2008;55:315–318.
96. Gagner M. Laparoscopic treatment of acute necrotizing pancreatitis. *Semin Laparosc Surg*. 1996;3:21–28.
97. Connor S, Raraty MG, Howes N, et al. Surgery in the treatment of acute pancreatitis—minimal access pancreatic necrosectomy. *Scand J Surg*. 2005; 94:135–142.
98. Cuschieri SA, Jakimowicz JJ, Stultiens G. Laparoscopic infracolic approach for complications of acute pancreatitis. *Semin Laparosc Surg*. 1998;5:189–194.
99. Ammori BJ. Laparoscopic transgastric pancreatic necrosectomy for infected pancreatic necrosis. *Surg Endosc*. 2002;16:1362.
100. Parekh D. Laparoscopic-assisted pancreatic necrosectomy: a new surgical option for treatment of severe necrotizing pancreatitis. *Arch Surg*. 2006;141:895–902; discussion 902–903.
101. Horvath KD, Kao LS, Wherry KL, Pellegrini CA, Sinanan MN. A technique for laparoscopic-assisted percutaneous drainage of infected pancreatic necrosis and pancreatic abscess. *Surg Endosc*. 2001;15:1221–1225.
102. Charnley RM, Lochan R, Gray H, O'Sullivan CB, Scott J, Oppong KE. Endoscopic necrosectomy as primary therapy in the management of infected pancreatic necrosis. *Endoscopy*. 2006;38:925–928.
103. Baron TH, Morgan DE. Endoscopic transgastric irrigation tube placement via PEG for debridement of organized pancreatic necrosis. *Gastrointest Endosc*. 1999;50:574–577.
104. Windsor JA. Minimally invasive pancreatic necrosectomy. *Br J Surg*. 2007;94:132–133.

105. Horvath KD, Kao LS, Ali A, Wherry KL, Pellegrini CA, Sinanan MN. Laparoscopic assisted percutaneous drainage of infected pancreatic necrosis. *Surg Endosc.* 2001;15:677–682.
106. Carter CR, McKay CJ, Imrie CW. Percutaneous necrosectomy and sinus tract endoscopy in the management of infected pancreatic necrosis: an initial experience. *Ann Surg.* 2000;232:175–180.
107. Carter R, Wysocki AP. Infected necrosis—minimally invasive necrosectomy. *Diseases of the Pancreas.* 2008;241–248.
108. Friedland S, Kaltenbach T, Sugimoto M, Soetikno R. Endoscopic necrosectomy of organized pancreatic necrosis: a currently practiced NOTES procedure. *J Hepatobiliary Pancreat Surg.* 2009;16:266–269.
109. Baron TH, Thaggard WG, Morgan DE, Stanley RJ. Endoscopic therapy for organized pancreatic necrosis. *Gastroenterology.* 1996;111:755–764.
110. Seewald S, Groth S, Omar S, et al. Aggressive endoscopic therapy for pancreatic necrosis and pancreatic abscess: a new safe and effective treatment algorithm (videos). *Gastrointest Endosc.* 2005;62:92–100.
111. Seifert H, Wehrmann T, Schmitt T, Zeuzem S, Caspary WF. Retroperitoneal endoscopic debridement for infected peripancreatic necrosis. *Lancet.* 2000;356:653–655.
112. Castellanos G, Pintero A, Serrano A, Parrilla P. Infected pancreatic necrosis: translumbar approach and management with retroperitoneoscopy. *Arch Surg.* 2002;137:1060–1063; discussion 1063.
113. Loveday B, Rossaak J, Mittal A, Phillips A, Windsor J. Trends in minimally invasive intervention for necrotizing pancreatitis: a survey of Australian and New Zealand surgeons. *ANZ Journal Surgery.* 2011;81:56–64.
114. Ferrucci JT, 3rd, Mueller PR. Interventional approach to pancreatic fluid collections. *Radiol Clin North Am.* 2003;41:1217–1226, vii.
115. Becker V, Huber W, Meining A, et al. Infected necrosis in severe pancreatitis—combined nonsurgical multi-drainage with directed transabdominal high-volume lavage in critically ill patients. *Pancreatology.* 2009;9:280–286.
116. Mortelet KJ, Girshman J, Szejnfeld D, et al. CT-guided percutaneous catheter drainage of acute necrotizing pancreatitis: clinical experience and observations in patients with sterile and infected necrosis. *AJR Am J Roentgenol.* 2009;192:110–116.
117. van Baal MC, van Santvoort HC, Bollen TL, Bakker OJ, Besselink MG, Gooszen HG for the Dutch Pancreatitis Study Group. Systematic review of percutaneous catheter drainage as primary treatment for necrotizing pancreatitis. *British Journal of Surgery.* 2011;98:18–27.
118. Shonnard KM, McCarter DL, Lyon RD. Percutaneous debridement of infected pancreatic necrosis with nitinol snares. *J Vasc Interv Radiol.* 1997;8:279–282.
119. Zorger N, Hamer OW, Feuerbach S, Borisch I. Percutaneous treatment of a patient with infected necrotizing pancreatitis. *Nat Clin Pract Gastroenterol Hepatol.* 2005;2:54–57; quiz 58.
120. Gloor B, Muller CA, Worni M, Martignoni ME, Uhl W, Buchler MW. Late mortality in patients with severe acute pancreatitis. *Br J Surg.* 2001;88:975–979.
121. Carnovale A, Rabitti PG, Manes G, Esposito P, Pacelli L, Uomo G. Mortality in acute pancreatitis: is it an early or a late event? *JOP.* 2005;6:438–444.
122. Heider TR, Azeem S, Galanko JA, Behrns KE. The natural history of pancreatitis-induced splenic vein thrombosis. *Ann Surg.* 2004;239:876–880; discussion 880–882.
123. Bone RC. Immunologic dissonance: a continuing evolution in our understanding of the systemic inflammatory response syndrome (SIRS) and the multiple organ dysfunction syndrome (MODS). *Ann Intern Med.* 1996;125:680–687.
124. Moore EE, Moore FA, Franciose RJ, Kim FJ, Biffl WL, Banerjee A. The postischemic gut serves as a priming bed for circulating neutrophils that provoke multiple organ failure. *J Trauma.* 1994;37:881–887.
125. Rivers E, Nguyen B, Havstad S, et al. Early goal-directed therapy in the treatment of severe sepsis and septic shock. *N Engl J Med.* 2001;345:1368–1377.
126. Bone RC, Balk RA, Cerra FB, et al. Definitions for sepsis and organ failure and guidelines for the use of innovative therapies in sepsis. The ACCP/SCCM Consensus Conference Committee. American College of Chest Physicians/Society of Critical Care Medicine. *Chest.* 1992;101:1644–1655.
127. Flint R, Windsor JA. Early physiological response to intensive care as a clinically relevant approach to predicting the outcome in severe acute pancreatitis. *Arch Surg.* 2004;139:438–443.
128. Mentula P, Kylanpaa ML, Kempainen E, et al. Early prediction of organ failure by combined markers in patients with acute pancreatitis. *Br J Surg.* 2005;92:68–75.
129. The acute respiratory distress syndrome network. Ventilation with lower tidal volumes as compared with traditional tidal volumes for acute lung injury and the acute respiratory distress syndrome. *N Engl J Med.* 2000;342:1301–1308.
130. Dellinger RP, Carlet JM, Masur H, et al. Surviving Sepsis Campaign guidelines for management of severe sepsis and septic shock. *Crit Care Med.* 2004;32:858–873.
131. Annane D, Bellissant E, Bollaert PE, et al. Corticosteroids in the treatment of severe sepsis and septic shock in adults: a systematic review. *JAMA.* 2009;301:2362–2375.
132. Bernard GR, Vincent JL, Laterre PF, et al. Efficacy and safety of recombinant human activated protein C for severe sepsis. *N Engl J Med.* 2001;344:699–709.
133. The Nice-Sugar Study Investigators. Intensive versus conventional glucose control in critically ill patients. *N Engl J Med.* 2009;360:1283–1297.
134. Wiener RS, Wiener DC, Larson RJ. Benefits and risks of tight glucose control in critically ill adults: a meta-analysis. *JAMA.* 2008;300:933–944.
135. Chandrasegaram MD, Plank LD, Windsor JA. The impact of parenteral nutrition on the body composition of patients with acute pancreatitis. *JPEN J Parenter Enteral Nutr.* 2005;29:65–73.



*This page intentionally left blank*

# CHRONIC PANCREATITIS

Marshall S. Baker • Jeffrey B. Matthews

## INTRODUCTION

Chronic pancreatitis is an inflammatory and fibrosing disease of the exocrine pancreas characterized by irreversible morphological changes and permanent loss of function. The apparent incidence of chronic pancreatitis has increased approximately fourfold over the past several decades, likely due a broadening of its definition and the inclusion of patients with earlier-stage disease. The natural history of chronic pancreatitis is unpredictable. Affected individuals typically suffer a pattern of persistent or recurrent attacks of pain along with progressive pancreatic exocrine insufficiency. Symptoms may also result from extension of the disease process to adjacent organs and vascular structures. In later stages, pancreatic endocrine insufficiency may develop. Decision making in the management of chronic pancreatitis must be individualized to the specific anatomic and pathological circumstances, taking into account the extent of local expertise in various diagnostic and therapeutic modalities as well as the fact that there is a relative paucity of high-quality data on the clinical effectiveness of surgical and medical interventions. Optimal management is facilitated by a multidisciplinary approach that includes surgical, endoscopic, and radiological expertise in addition to nutrition, endocrinology, pain management, and psychosocial support.

## DEFINITION AND RISK FACTORS

Pancreatitis is thought to have its origin as an autodigestive disease initiated by inappropriate activation of pancreatic zymogens. The terms *acute pancreatitis* and *chronic pancreatitis* are often used to draw the temporal distinction between an isolated episode and a more persistent illness associated with progressive loss of pancreatic function. In fact, pancreatitis represents a far more heterogeneous clinical entity than can be captured by these two simple descriptors. A number of international conferences have been held in order to develop uniform terminology to characterize the spectrum of morphology seen in acute and chronic pancreatitis.

According to the Marseille-Rome classification of 1988, the term *acute pancreatitis* is used to refer to single or repeated episodes of abdominal pain associated with a range of potentially reversible pancreatic lesions including pancreatic edema, necrosis, and hemorrhage, as well as peripancreatic fluid collections, necrosis, and pseudocysts. *Chronic pancreatitis* is used to refer to recurrent or persistent abdominal pain that is associated with irreversible and ongoing inflammatory destruction of exocrine parenchyma and, eventually, islets. In practice, however, the distinction between acute and chronic pancreatitis is rarely made based on tissue sampling, and there is no consensus on the definition of irreversible morphological change.<sup>1</sup> It is also acknowledged that certain forms of chronic pancreatitis can occur in the absence of pain.

The Marseille-Rome classification further divides chronic pancreatitis into several morphological subtypes that may coexist in the same patient. *Chronic obstructive pancreatitis* is characterized by exocrine atrophy and is associated with duct stenosis caused by tumors, pseudocyst, or scarring from prior acute pancreatitis. *Chronic calcifying pancreatitis* is characterized by intraductal calcifications and protein plugs, and is often associated with atrophy, stenotic ducts, and areas of acute inflammation or pseudocyst. *Chronic inflammatory pancreatitis* consists of dense infiltration of mononuclear inflammatory cells. *Retention cysts and pseudocysts*, seen in both calcifying and obstructive forms, may also become infected. *Fibrosis* may develop in the absence of symptoms.

Chronic pancreatitis lacks a simple unifying theory of disease pathogenesis. The precise mechanism by which any specific agent or circumstance induces pancreatitis remains obscure. Excessive alcohol ingestion has been associated with chronic pancreatitis ever since the term was introduced by Comfort in 1946.<sup>2</sup> However, the precise relationship between alcohol and chronic pancreatitis remains poorly understood. Alcohol ingestion in and of itself does not lead to pancreatitis in experimental animals. Chronic pancreatitis in humans occurs in the absence of significant alcohol usage, and, in fact, it is only a small percentage (fewer than 5%) of alcoholics that develop pancreatic disease.<sup>3,4</sup> Acute and chronic forms of pancreatitis have been found to share common risk

factors including exposure to toxic agents other than alcohol, and acute pancreatitis clearly has the potential to evolve into chronic disease. However, repeated episodes of acute pancreatitis do not invariably lead to chronic pancreatitis, and chronic pancreatitis may present without prior acute attacks. As with alcohol, most individuals exposed to the other toxic substances associated with pancreatitis do not develop the chronic form of the disease.

For these reasons, the concept of identifying risk modifiers rather than etiologies or causes of chronic pancreatitis may be more appropriate in classifying the disease particularly when making decisions regarding patient management. Far from being merely a “drunkard’s disease,” chronic pancreatitis should be attributed to a variety of genetic, environmental, anatomic, immunologic, and other poorly understood susceptibility factors that interact to initiate and perpetuate the pathology. The TIGAR-O system (Table 56-1) proposed by Whitcomb<sup>4</sup> is a framework that allows various risk factors associated with the disease to be logically organized into categories: Toxic or metabolic, Idiopathic, Genetic, Autoimmune, Recurrent acute, and Obstructive. The TIGAR-O system implies that chronic pancreatitis is not a uniform disease with one etiology and a single common pattern of presentation. Instead, there is a diversity of etiologic risk factors that contributes to a spectrum

of pathological and functional derangements, clinical features, and natural history.

## Toxic or Metabolic

The majority of patients with chronic pancreatitis (55–80%) will report significant alcohol intake over the years prior to diagnosis. A relationship between dose and duration of alcohol use has been repeatedly documented, and there appears to be a threshold level for the risk of pancreatitis at approximately 50 gm (four drinks) per day.<sup>5</sup> Several mechanisms have been proposed to account for pancreatic injury including alterations in pancreaticobiliary secretory flow, ductal plugging, and direct toxic action on acinar cells. Chronic pancreatitis in the setting of alcohol use is associated with pancreatic calcification and ductal stone formation, but none of the proposed mechanisms is convincingly supported experimentally, and the hypotheses are not mutually exclusive. Several other toxic agents have been identified as risk factors for pancreatitis. Included among these is tobacco, which has been shown to confer increased risk of chronic pancreatitis independent of alcohol use.<sup>6</sup> Several medications have been implicated in acute pancreatitis but probably do not play a role in the chronic form of the disease. Similarly, hypercalcemia (eg, associated with hyperparathyroidism) and various forms of hyperlipidemia (eg, hypertriglyceridemia) are linked to acute but not chronic pancreatitis. So-called tropical chronic pancreatitis, described in children living in developing parts of the world, is thought to be either due to a dietary toxin or to an unidentified micronutrient deficiency.



**TABLE 56-1: TIGAR-O CATEGORIZATION OF RISK FACTORS FOR CHRONIC PANCREATITIS**

### Toxic/metabolic

- Alcohol
- Tobacco
- Hypercalcemia (hypoparathyroidism)
- Dietary/nutritional (tropical)
- Hyperlipidemia
- Chronic renal failure (uremia)

### Idiopathic

#### Genetic

- PRSS1*, *PRSS2*
- SPINK1
- CFTR
- Chymotrypsin C

#### Autoimmune

#### Recurrent and severe acute pancreatitis

#### Obstructive/mechanical

- Pancreas divisum
- Sphincter of Oddi dysfunction
- Annular pancreas
- Malignant obstruction of the pancreatic duct
- Primary pancreatic duct stones
- Choledochocoele

## Idiopathic

About 20% of patients with chronic pancreatitis have no clinically obvious risk factor. It is suspected that a great many of these idiopathic cases will ultimately prove to harbor yet unidentified genetic or molecular derangements that explain the process. In recent years, many patients previously considered to be idiopathic recurrent acute and chronic pancreatitis have been found to carry mutations, polymorphisms, or splice variants of the gene associated with cystic fibrosis. Recent evidence also suggests that polymorphisms in genes associated with oxidative stress and xenobiotic metabolism may be more prevalent in patients with what is now characterized as idiopathic disease.<sup>7</sup> Thus, as new genetic associations that predispose to the development of chronic pancreatitis become recognized, the percentage of patients with truly idiopathic disease will decrease.

## Genetic

Hereditary pancreatitis was first characterized in 1952 as early onset of chronic pancreatitis clustering in family members without other risk factors.<sup>8</sup> At least half of

Modified and updated from Etemad B, Whitcomb DC. Chronic pancreatitis: diagnosis, classification, and new genetic developments. *Gastroenterology*. 2001;120(3):682–707.



hereditary pancreatitis kindreds have been found to carry germline mutations in the cationic trypsinogen (*PRSS1*) gene.<sup>3,4,9</sup> The arginine-to-histidine (R122H) substitution is the most common defect. Hereditary pancreatitis has an autosomal dominant pattern of inheritance, with a high degree of penetrance. Cationic trypsinogen is produced in the pancreatic acinar cells and, upon cleavage by duodenal enteropeptidase, forms trypsin. Trypsin is a protease that acts to hydrolyze dietary proteins and plays the key role in both initial activation of other pancreatic zymogens (including trypsinogen itself) and in their subsequent proteolytic inactivation. Trypsin encoded by pancreatitis-associated *PRSS1* mutations is unusually stable and resists autolytic inactivation, predisposing to premature and extended activation of trypsin within the pancreatic parenchyma.<sup>10</sup> Mutations in other genes such as anionic trypsinogen (*PRSS2*) or the calcium-sensing receptor (*CASR*) have also been reported in some cases of hereditary pancreatitis, although in many other kindreds, the responsible gene has not yet been identified.<sup>11</sup> Other gene associations with hereditary or otherwise idiopathic chronic pancreatitis will undoubtedly emerge over the next several years. Recently, for example, inactivating mutations in the gene encoding for the trypsin-degrading enzyme chymotrypsin C have been identified in a German cohort.<sup>12</sup>

Another genetic disorder associated with pancreatic pathology is cystic fibrosis (CF), a disease linked to mutations in the cystic fibrosis transmembrane conductance regulator (CFTR) gene.<sup>9,13-15</sup> CFTR is a chloride ion channel involved in water, chloride, and bicarbonate secretion by epithelial cells such as those lining the gastrointestinal tract and respiratory system. In the pancreas, CFTR is localized to centroacinar and proximal lobular duct cells.<sup>16</sup> Over 90% of CF patients are pancreatic insufficient, and, while severe pancreatic fibrosis is common, acute pancreatitis is rare.<sup>17</sup> However, a subset of patients with otherwise idiopathic recurrent acute and chronic pancreatitis has been noted to have borderline abnormalities in functional tests for cystic fibrosis such as sweat chloride content. These patients harbor at least an eightfold increase in CF-associated CFTR mutations on a single allele. Various other CFTR mutations, polymorphisms, and splice variants not associated with classical pulmonary manifestations of CF are also frequently identified in patients with recurrent acute and chronic pancreatitis. The CFTR gene shows autosomal recessive inheritance with incomplete penetrance, and thus a family history of CF or pancreatic disease is usually absent in CFTR-associated pancreatitis. The mechanism of CFTR-associated pancreatitis is thought to involve the viscous, low-volume, low-bicarbonate containing pancreatic fluid secretion leading to duct sludge and enzyme hyperconcentration, enhancing the potential for intraglandular enzyme activation.

Mutations and polymorphisms in other genes may also modify susceptibility to chronic pancreatitis. Pancreatic serine protease inhibitor Kazal type 1 (SPINK1) is a natural protease inhibitor that localizes with trypsinogen within zymogen granules. SPINK1 binds to and inhibits activated trypsin, thus serving as a “buffer” of sorts against inappropriate early trypsinogen activation. Mutations of the SPINK1

gene (notably N34S) appear to increase the risk of recurrent acute and chronic pancreatitis, particularly in patients who harbor two mutated alleles.<sup>3,4,9</sup> A single mutated SPINK1 allele appears to increase the risk of alcohol-associated pancreatitis and tropical pancreatitis.

## Autoimmune

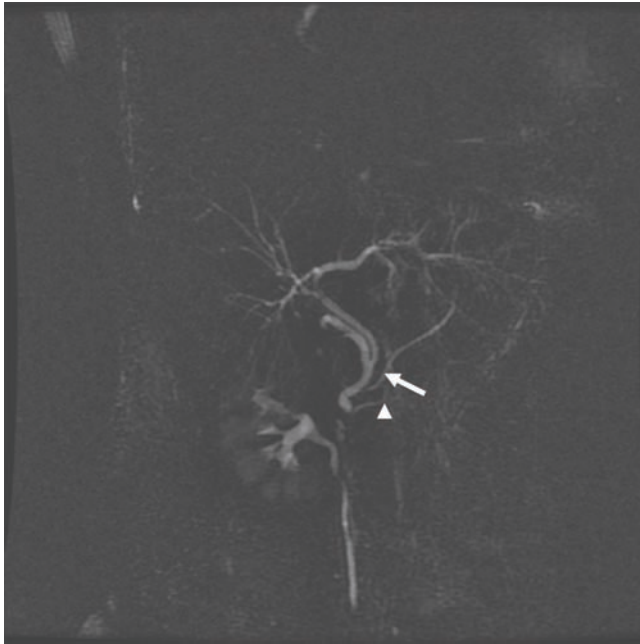
Autoimmune chronic pancreatitis (AIP), also known as lymphoplasmocytic sclerosing pancreatitis, is characterized by diffuse glandular enlargement and infiltration with CD4 or CD8-positive lymphocytes and IgG4-positive plasma cells.<sup>3,4,18,19</sup> The exact immunologic etiology is unknown, although circulating antibodies with homology both to a peptide sequence associated with a protein from *Helicobacter pylori* (infection with which is associated with various autoimmune disorders including AIP) and to a protein highly expressed in pancreatic acinar cells have recently been found in over 90% of patients.<sup>20</sup> Inflammatory infiltrates are particularly concentrated in duct rather than acinar zones, however, and thus a duct-origin autoantigen has been postulated. Notably, diffused ductal narrowing rather than dilation is usually observed. Initially described predominately in young men, AIP has been increasingly recognized as a cause of biliary obstruction and pseudotumor in older individuals.<sup>21</sup> Most patients report little in the way of pain, and prior attacks of acute pancreatitis are unusual. It has been associated with serologic elevation of IgG4 levels in about two-thirds of patients and with other autoimmune conditions in approximately 20%, including Crohn's disease, ulcerative colitis, Sjögren's syndrome, primary biliary cirrhosis or primary sclerosing cholangitis.<sup>18,21</sup>

## Recurrent and Severe Acute Pancreatitis

Recurrent episodes, or even a single severe episode of, acute pancreatitis may lead to chronic pancreatitis, but the basis for progression is poorly understood. Patients with prior episodes of necrosis appear to be at particular risk for developing chronic disease. In many cases, progression may be due to postpancreatic ductal scarring, persistent activation of pancreatic stellate cells, and neuroplasticity leading to hyperalgesia.

## Obstructive

Post-traumatic duct strictures, or obstruction associated with tumors including cystic neoplasms, neuroendocrine lesions, and pancreatic adenocarcinoma have been associated with pancreatic pathology consistent with chronic pancreatitis, although these patients are often asymptomatic. Chronic pancreatitis has also been associated with anomalous anatomic variations in the pancreatic ductal system, most notably *pancreas divisum*, and it has been postulated that relative



**FIGURE 56-1** Recurrent acute and chronic pancreatitis in a 41-year-old woman with pancreas divisum and a pancreatitis-associated mutation in the cystic fibrosis (CF) gene. Magnetic resonance cholangiopancreatography (MRCP) demonstrates noncommunicating dorsal (*arrow*) and ventral (*arrowhead*) pancreatic ducts.

obstruction to pancreatic flow through the dorsal duct and minor papilla predisposes to recurrent acute and chronic pancreatitis. The evidence supporting the association to chronic pancreatitis in particular is largely circumstantial and may reflect referral bias<sup>22</sup> but pancreas divisum may be a contributing factor in the presence of certain genetic risk factors (Fig. 56-1). Some cases of chronic pancreatitis are attributed to sphincter of Oddi dysfunction, although rigorous evidence to support this association is also lacking.

## PATHOPHYSIOLOGY AND MECHANISM OF PAIN

Progress in elucidation of the pathogenesis of chronic pancreatitis has been hampered by the lack of a suitable experimental model that adequately recapitulates the features of the disease seen in humans.<sup>23</sup> However, existing evidence suggests a number of useful conceptual frameworks that may help guide efforts to treat patients with chronic pancreatitis. Traditional theories of the pathogenesis of acute pancreatitis include the toxic-metabolic or oxidative stress hypotheses, in which normal acinar cell processing and release of zymogens are disrupted by a toxic or oxidative stressor, and the ductal obstruction hypothesis that proposes a mechanical role for ductal plugs and stones causing disruption of the integrity of the acinar cell (common in alcoholic and tropical disease). In certain situations, notably autoimmune disease, pancreatitis may begin not in the acinar cell but in the duct

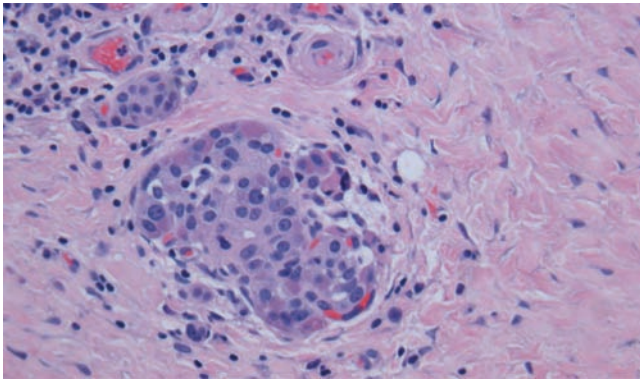
cell, triggered by the development of an as-yet-unidentified autoantigen on the duct epithelium. Recently, attention has focused on understanding the mechanism of pancreatic fibrosis, the central histological feature that characterizes the evolution from acute disease to chronic pancreatitis. One attractive hypothesis is that a sentinel acute pancreatitis event (SAPE) primes the pancreas for fibrogenesis.<sup>23</sup> According to the SAPE concept, local inflammatory cytokines released during acute pancreatitis activate circulating macrophages that infiltrate the gland as well as resident pancreatic stellate cells, myofibroblast-like cells that are normally quiescent. During the subsequent healing phase, anti-inflammatory mediators (particularly anti-inflammatory cytokines such as tumor growth factor beta [TGF- $\beta$ ]) drive stellate cells and tissue macrophages to synthesize and deposit fibrogenic matrix proteins. The pancreatic parenchyma may return to normal after a mild self-limited episode. However, the damage may not completely resolve after a severe attack, particularly if there has been significant tissue necrosis. Thus, following the SAPE, the local pancreatic environment may be permanently altered by the persistent presence of anti-inflammatory and profibrogenic cell populations that are perpetually activated by ongoing toxic-metabolic, oxidative, or mechanical stress. The pancreas then becomes subject to repeated cycles of inflammation and progressive fibrosis.

A comprehensive mechanistic explanation for pain, often the most debilitating symptom of chronic pancreatitis, also remains elusive.<sup>23</sup> One hypothesis is that pain results from capsular stretch associated with ductal or organ hypertension. This hypothesis is supported by the favorable results of surgical or endoscopic ductal drainage in patients with chronic pancreatitis associated with dilated pancreatic ducts, and the success of surgical resection in other selected patient populations. An alternative, and possibly complementary, hypothesis is that the pain represents a neuropathy caused by repeated inflammatory insults and damage to retroperitoneal sensory nerves.<sup>23-25</sup> Recent evidence demonstrating neuroplasticity in nociceptive dorsal root ganglia in chronic inflammatory states, with evidence of upregulation of nociceptors such as TRPV1 by proteolytic enzymes such as trypsin<sup>26</sup> supports this theory.

## CLINICAL PRESENTATION

As in acute pancreatitis, pain in chronic pancreatitis typically localizes to the left upper quadrant or epigastric region, often radiating around or into the back. The pattern of pain is variable. Some patients experience recurrent attacks of moderate to severe pain interspersed with periods of relative or complete quiescence. In others, the pain may be persistent and lead to significant incapacitation and chronic disability. During acute exacerbations, the pain may be increased by food intake and is frequently associated with nausea and vomiting.

Weight loss and malnutrition are common, due to both decreased intake as well as exocrine insufficiency with consequent malabsorption of protein and fat. Exocrine insufficiency



**FIGURE 56-2** Histopathology of chronic pancreatitis showing islet entrapment within exocrine parenchymal fibrosis. (Used with permission from Dr. Jerrold Turner)

is usually obvious in patients with classical steatorrhea (loose, bulky bowel movements that may be greasy, sticky, oily, or foul-smelling), but these symptoms are obscured by narcotic-associated constipation.

Endocrine insufficiency typically occurs late in the course of disease, often after exocrine insufficiency has appeared, and usually not before about 90% of the pancreatic parenchyma has been replaced by fibrosis. Diabetes is more common in patients with alcohol-associated chronic calcifying pancreatitis with 80% of these individuals demonstrating endocrine insufficiency within 10 years of the development of severe exocrine insufficiency.<sup>27</sup> For unclear reasons, there is a relative sparing of islet cells until late in the course of the disease. Histologically, pancreatic islets are seen to persist within areas of extensive fibrotic replacement of exocrine tissue (Fig. 56-2). Because diabetes of chronic pancreatitis is associated with indiscriminate destruction of all cell types within the islets of Langerhans, counter-regulatory glucose control may be considerably more labile than in either type I or type II diabetes. Less is known regarding the natural history of nonalcohol-associated chronic pancreatitis but the risk of diabetes appears to be lower.<sup>27</sup> Both endocrine and exocrine insufficiency occur later and less frequently in patients with chronic pancreatitis associated with gene mutations than those without gene mutations.<sup>28</sup>

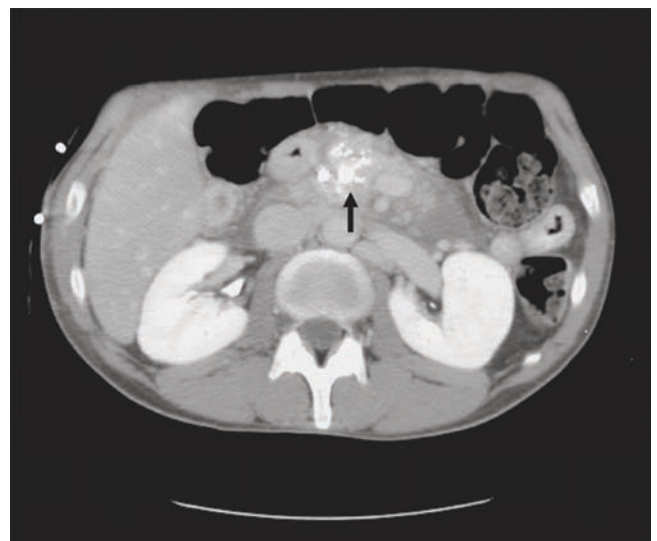
On occasion, the initial manifestation of chronic pancreatitis will be related to extrapancreatic complications such as intestinal or biliary obstruction due to compression by a pseudocyst, and gastrointestinal hemorrhage due to blood lost into the pancreatic duct (*hemorrhagic pancreatitis*) or due to rupture of pseudoaneurysm into a pseudocyst or to splenomesenteric vein thrombosis.

## DIAGNOSIS

The diagnosis is usually suspected based on an appropriate clinical history and is confirmed by imaging studies. Laboratory investigation is of limited value. Acute exacerbation

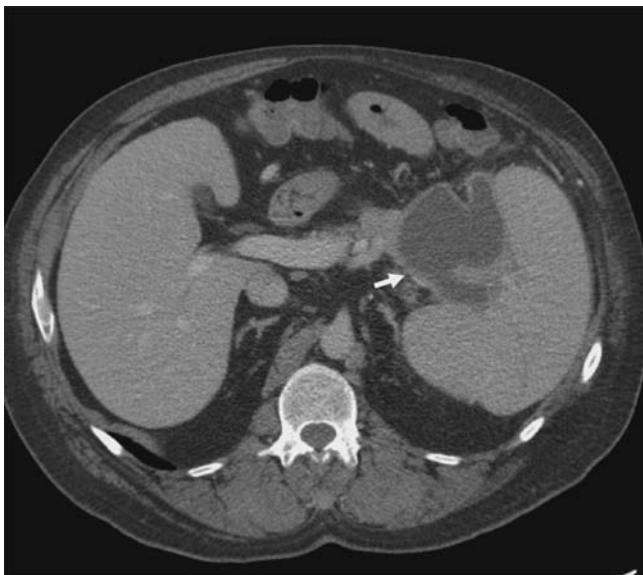
of abdominal pain may be paralleled by a transient increase in serum amylase or lipase, but these may be normal with progressive destruction of acinar cell mass. Elevation of liver function tests, particularly serum bilirubin and alkaline phosphatase, may indicate the presence of bile duct obstruction.

The diagnosis of chronic pancreatitis is usually confirmed by imaging studies, most commonly computed tomography (CT). CT findings depend on the morphologic type of chronic pancreatitis, the duration of disease, and the presence of complications. In the early phases of chronic pancreatitis, ductal or parenchymal changes may be rather subtle, but as the disease advances, progressive and irreversible changes in organ architecture are readily apparent. Chronic pancreatitis associated with toxic-metabolic or genetic risk factors, and idiopathic chronic pancreatitis may demonstrate calcifications either focally or scattered throughout the organ. There may be evidence of acute inflammatory changes or focal areas of enlargement associated with areas of dense calcifications, particularly in the pancreatic head (Fig. 56-3); this so-called “inflammatory head mass” appears to be more common in European than American cohorts.<sup>29</sup> There may be evidence of segmental or diffuse pancreatic ductal dilation related to stricture formation, and pseudocyst formation and evidence of extrapancreatic complications such as duodenal or biliary obstruction, or splenomesenteric vein thrombosis (Fig. 56-4). In autoimmune pancreatitis, calcifications are almost uniformly absent and the pancreas is usually diffusely enlarged although a focal mass-forming variant is occasionally encountered.<sup>18</sup> In obstructive forms of chronic pancreatitis, the pancreatic duct is dilated upstream of the area of stenosis and the acinar parenchyma appears atrophic. Although CT can readily confirm the clinical suspicion of chronic pancreatitis, it rarely provides sufficient information for therapeutic decision making.



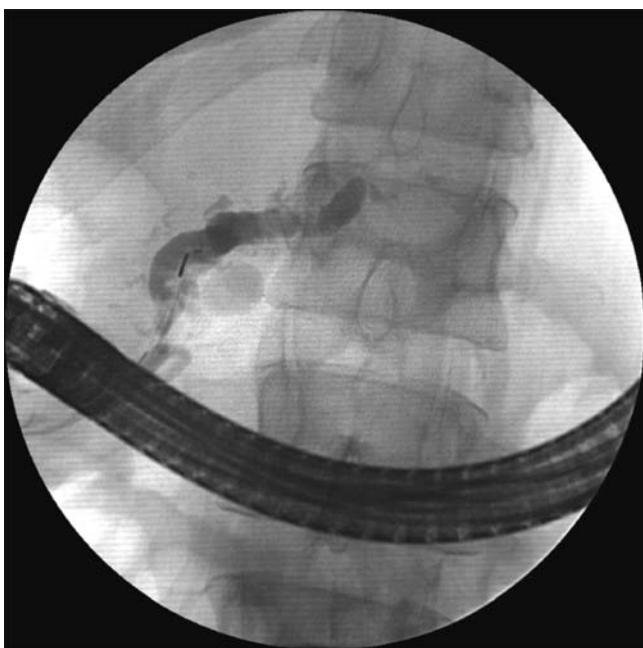**FIGURE 56-3** Axial cross-sectional abdominal CT demonstrating enlargement and dense calcifications (arrow) in the pancreatic head in alcohol-associated chronic pancreatitis.



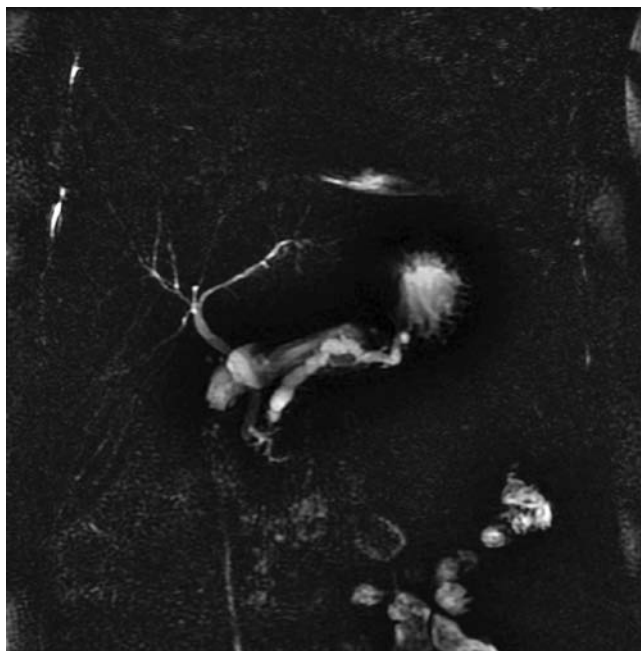

**FIGURE 56-4** Axial cross-sectional abdominal CT demonstrating pseudocyst involving the splenic hilum with splenic vein compression (*arrow*) in alcohol-associated chronic pancreatitis.

Pancreatic ductography complements CT imaging and is generally considered essential in planning intervention. Endoscopic retrograde cholangiopancreatography (ERCP) has long served as a gold standard of sorts in mapping duct pathology and offers endotherapeutic options including sphincterotomy and stent placement (Fig. 56-5). Magnetic



**FIGURE 56-5** ERCP image showing classic diagnostic features of chronic pancreatitis including marked main duct dilation, intraluminal filling defects (stones), clubbing of side-branches, and areas of duct stricture.



**FIGURE 56-6** Secretin-stimulated MRCP shows a diffusely dilated main pancreatic duct with obstruction to pancreatic flow associated with a dorsal duct stricture in the setting of pancreas divisum and chronic pancreatitis.

resonance cholangiopancreatography (MRCP) is less invasive and provides image quality that rivals ERCP; the addition of secretin stimulation further enhances duct visualization and allows some assessment of pancreatic exocrine function (Fig. 56-6).<sup>30</sup> Anatomic ductal anomalies such as pancreas divisum are readily defined by ERCP or MRCP, as are dominant focal duct strictures that might be amenable to endoscopic stenting or surgical drainage procedures. MR imaging integrates information regarding parenchymal and ductal involvement and may be particularly helpful when the disease is regionally heterogeneous and architecturally complex.

It is not difficult to establish the diagnosis of chronic pancreatitis in its advanced stages, when classical clinical symptoms are present or when imaging studies demonstrate obvious abnormalities such as strictures, ductal dilation, or pancreatic calcifications. Recognition of disease in its earlier stages presents more of a challenge. A 1983 conference held in Cambridge categorized chronic pancreatitis as equivocal, mild, moderate, or marked and established criteria (Table 56-2) according to combinations of features seen in the main and side branch pancreatic ducts on CT and ductograms.<sup>1,31,32</sup> Although this consensus approach has proven useful over the years, there continues to be a subset of patients with symptoms suspicious for chronic pancreatitis but in whom imaging studies are negative. Some of these patients may suffer from functional abdominal pain disorders rather than pancreatic disease.<sup>33</sup> Others may have early forms of chronic pancreatitis. Consensus workshops

**TABLE 56-2: CAMBRIDGE CLASSIFICATION OF CHRONIC PANCREATITIS BASED ON ENDOSCOPIC RETROGRADE PANCREATOGRAPHY**

Grade of Pancreatitis	Main Pancreatic Duct Appearance	Side Branch Pancreatic Duct Appearance
Normal	Normal	Normal
Equivocal	Normal	<3 abnormal branches
Mild	Normal	>3 abnormal branches
Moderate	Abnormal	>3 abnormal branches
Marked	Abnormal plus any of the following: Cavity >10 mm Stricture Intraductal filling defects Pancreatic calcification Contiguous organ involvement on CT Severe duct dilation or irregularity	>3 abnormal branches

Modified from Sarner M, Cotton PB. Classification of pancreatitis. *Gut*. 1984;25(7):756–759.

by the Japan Pancreas Society (1995 and 2001) continue to address the ongoing challenge of so-called “minimal change” disease in the context of evolving imaging and diagnostic modalities.

Endoscopic ultrasound (EUS) appears to be valuable in evaluation of the suspicious pancreatic mass and in characterizing cystic lesions of the pancreas.<sup>34</sup> EUS generally adds little to the evaluation of chronic pancreatitis in its advanced stages but has potential applicability in early stage, minimal change disease where other imaging modalities fail to establish the diagnosis.<sup>3,35–37</sup> EUS appears to be more sensitive than ERCP or MRCP in detecting early parenchymal fibrosis and subtle ductal changes occurring in early forms of chronic pancreatitis. Various systems using up to 11 different parenchymal and ductal endosonographic criteria (Table 56-3) to diagnose chronic pancreatitis have been proposed.<sup>38</sup> There is however, no gold standard grading system or agreement on the threshold number of abnormalities that must be present for the diagnosis of chronic pancreatitis. Because of this, the value of EUS in making an early diagnosis of chronic pancreatitis, remains uncertain. EUS may have more practical utility in cases of suspected autoimmune pancreatitis. Surgical interventions may be avoided in some of these patients that present with a mass-forming variant by EUS-directed core needle biopsy demonstrating the pathognomonic lymphoplasmacytic infiltrate<sup>39</sup> and thus ruling out malignancy.

**TABLE 56-3: ENDOSONOGRAPHIC CRITERIA FOR CHRONIC PANCREATITIS**

Parenchymal Criteria	Ductal Criteria
Hyperechoic foci	Main pancreatic duct dilation
Hyperechoic strands	Duct irregularity
Lobularity of the gland	Hyperechoic duct margins
Cysts	Dilated side branches
	Stones

Modified from Pungpapong S, Wallace MB, Woodward TA, Noh KW, Raimondo M. Accuracy of endoscopic ultrasonography and magnetic resonance cholangiopancreatography for the diagnosis of chronic pancreatitis: a prospective comparison study. *J Clin Gastroenterol*. 2007;41(1):88–93.

Functional testing to demonstrate pancreatic exocrine insufficiency is occasionally helpful, although from a practical standpoint, the condition is usually clinically obvious. Symptoms of steatorrhea, postprandial gaseous distension, or progressive weight loss despite adequate caloric intake are all suggestive of exocrine insufficiency. Quantification of fecal fat content or measurement of fecal human elastase (FE-1) levels can confirm the diagnosis and can be used to monitor efficacy of enzyme supplementation and surgical intervention.<sup>40</sup> Unfortunately, these studies are most reliable in those patients in whom the diagnosis is clinically obvious. They are of questionable accuracy in the setting of patients with more subtle symptoms where objective documentation of exocrine insufficiency might be most needed.

Elevation in fasting serum glucose or glycosylated hemoglobin (HgA<sub>1c</sub>) suggests pancreatic diabetes. Functional evaluation (eg, formal oral glucose or arginine-tolerance testing) for pancreatic endocrine insufficiency may be helpful in patients prior to pancreatic resection, particularly if autologous islet transplantation is under consideration.

In patients with suspected autoimmune pancreatitis, measurement of serum immunoglobulin G levels, particularly IgG4, is indicated. Other markers of autoimmune disease include rheumatoid factor, antinuclear antibody, C-reactive protein (CRP), or erythrocyte sedimentation rate, although these are less specific.<sup>19</sup>

The role of genetic testing in patients with idiopathic or suspected hereditary pancreatitis is controversial.<sup>41</sup> It may be most reasonable to screen for *PRSS1* mutations in patients with a strong family history of pancreatitis because of the autosomal dominant inheritance and the high risk of development of pancreatic cancer; a risk that is further dramatically elevated by tobacco use. However, hereditary pancreatitis patients without *PRSS1* mutations may have the same elevated risk of cancer, and there is no evidence that screening by serial imaging studies leads to earlier diagnosis or improved prognosis of pancreatic cancer. Identification of CFTR or SPINK1 gene mutations may be useful in selected circumstances; for example, patients with idiopathic pancreatitis may feel reassured by having an “explanation” for their disease. However, in the absence of therapy directed at the

specific functional defects associated with these mutations, the clinical value of gene testing is debatable.

## MEDICAL MANAGEMENT

Cessation of potential inciting agents such as alcohol may reduce the intensity or frequency of attacks. Avoidance of high-fat foods and tobacco use may also be of value. Occasionally, patients are unable to tolerate oral food intake for extended periods of time, in which case nutritional support by an enteral route that minimizes pancreatic stimulation (eg, via nasojejunal or gastrojejunal tube) or by a parenteral approach may be required. Pancreatic enzyme replacement is used to treat steatorrhea and other symptoms of exocrine insufficiency. Enteric-coated preparations are most useful in this setting.<sup>42</sup> Various formulations differ in lipase, protease, and amylase content and enzyme replacement therapy should be titrated to effect.<sup>42,43</sup> Patients must be carefully instructed to time enzyme ingestion appropriately in relation to meals to optimize mixing.

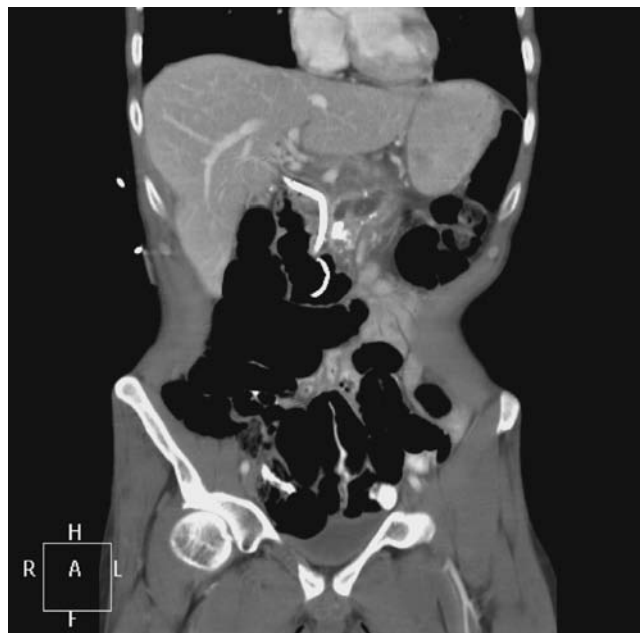In certain circumstances, medical therapy may alter the intensity or frequency of exacerbations of chronic pancreatitis. For example, some patients with early, small duct, or minimal change disease appear to benefit from high doses of noncoated enzyme preparations.<sup>42</sup> The presence of activated enzymes within the duodenum has been shown to decrease cholecystokinin-mediated stimulation of the pancreas. Noncoated enzyme preparations must be protected from destruction by gastric acid suppression therapy; trials that instead utilize enteric-coated delayed release enzyme formulations showed no benefit.<sup>42,43</sup> Several randomized trials suggest that a five-component antioxidant regimen reduces the frequency and intensity of painful episodes.<sup>44</sup> Patients with autoimmune pancreatitis confirmed by elevated IgG4 levels or tissue biopsy may be treated with an 8-week tapering course of corticosteroids.<sup>21</sup>

The major reason patients with chronic pancreatitis seek medical attention is unrelenting or frequently relapsing pain. Pain, more than any other feature, accounts for intractability and overall loss of quality of life. While in some patients, the intensity of pain may burnout as the disease reaches its end stage, this natural history is highly variable and may take years, if it occurs at all. Thus, a conservative, watch-and-wait approach is rarely acceptable. Pharmacotherapy for pain should begin with nonsteroidal anti-inflammatory medications, but if more powerful agents are needed, propoxyphene or tramadol may be used prior to escalating to more aggressive pharmacotherapy. Long-acting narcotics supplemented by short-acting narcotic formulations for breakthrough pain may be more effective than short-acting agents alone. Unfortunately, narcotic dependency is a common consequence of the use of these agents. Psychosocial supports such as counseling are essential to successful longitudinal management of chronic pain. Variable results have been reported with the use of long-acting somatostatin analogues. Occasionally, tricyclic antidepressants or gabapentin may be useful. Alternatives such

as placement of infusion pumps for intrathecal delivery of narcotics have been anecdotally successful.<sup>45</sup>

Neurolysis may be considered in patients who have failed medical management and who do not appear to have favorable anatomic circumstances amenable to endoscopic or surgical intervention. The most common neurolytic procedure is celiac plexus block, which can be performed under radiological or endoscopic guidance. The initial approach involves injection of a combination of steroids and a local anesthetic into the celiac ganglion. If temporary relief is obtained, this is followed by permanent neurolysis with 100% alcohol injection. Results of celiac plexus block in chronic pancreatitis have been mixed, but transient improvement (typically no more than 6 months) may be of benefit in selected patients.<sup>36,46</sup> Splanchnicectomy, usually performed by a thoracoscopic approach, has also been used, but similar to other forms of neurolysis, permanent resolution of pain is unusual.<sup>47</sup>

Therapeutic endoscopic intervention may be considered in patients with obstructive and inflammatory disease. Lithotripsy of pancreatic duct stones and pancreatic duct stent placement has been reported in several small retrospective series. Technical success can be reliably achieved in appropriately selected patients (eg, manageable stone size and local density sufficiently close to the working end of the scope and without intervening duct stricture). However, the effectiveness of endotherapy over time is often less than 50% with respect to improvement in pain or reduction in frequency of attacks. Multiple procedures are often necessary, recurrence of strictures and stones is frequent, and the substantial fraction of patients that fail generally require surgical intervention (Fig. 56-7).<sup>48,49</sup>



**FIGURE 56-7** Coronal CT image of a biliary endoprosthesis in a patient with chronic calcifying pancreatitis. Attempts at endoscopic pancreatic duct stone removal were unsuccessful, and the patient underwent pancreaticoduodenectomy.




**TABLE 56-4: RANDOMIZED COMPARISONS OF ENDOSCOPIC STENTING TO SURGICAL MANAGEMENT FOR MAIN DUCT DILATION**

Author	Year	Surgical Procedures	Number of Patients			% With Durable Pain Relief		
			Endo Stenting	Surgery	Median Follow-Up	Endo Stenting	Surgery	p Value
Dire <sup>50</sup>	2003	Resection and drainage	36	36	5 y	61.4	85.9	0.002
Cahen <sup>51</sup>	2007	Lateral pancreaticojejunostomy	19	20	2 y	32.0	75.0	0.007

Long-term presence of stents within the pancreatic duct may worsen inflammatory ductal strictures, although most series find a few patients who achieve durable pain relief following removal of stents. Patients who are suitable for endotherapy are usually also candidates for surgical intervention, provided there are no medical contraindications to operation. The two randomized trials (Table 56-4) to date that directly compared surgical therapy to endoscopic stenting reported long-lasting superiority of the surgical approach with respect to pain relief, quality of life, over time, and other endpoints.<sup>50,51</sup>

## SURGICAL MANAGEMENT OF CHRONIC PANCREATITIS

Surgical therapy for chronic pancreatitis is usually reserved for patients with symptoms that are otherwise intractable to pharmacotherapy and other therapeutic approaches. In over 90% of patients, the main indication for operation is pain. Occasionally, an operation is performed to relieve biliary or gastrointestinal obstruction, to internally drain a symptomatic pseudocyst, or for vascular complications of chronic pancreatitis such as gastric variceal hemorrhage secondary to splenic vein thrombosis.

A number of pancreatic operations have been developed over several decades of international effort. These operations generally involve either ductal drainage, parenchymal resection, or some combination of resection and ductal drainage. The choice of operation depends on anatomic morphology. In many patients, the disease appears to be driven predominantly by pathology within the pancreatic head, sometimes considered the “pacemaker” of chronic pancreatitis, particularly in those with a sizable inflammatory mass in this region of the organ. Others present more diffuse disease involving extensive areas of stricture and dilation of the main pancreatic duct or its ductal tributaries. Occasionally, disease appears limited to the body or tail. Operations on the pancreas may be technically demanding and carry significant risks of postoperative morbidity and mortality. Although in appropriately selected patients, the immediate results may be excellent, long-term success (durable pain relief) is achieved in at most 85% of patients at 5 years of follow-up. Alternatives for surgical intervention are best individualized and considered in

the context of the most frequently encountered clinical and anatomic scenarios.

## Large-Duct Disease

Large-duct chronic pancreatitis is characterized by enlargement of the main pancreatic duct lumen to a diameter exceeding 7–8 mm. Ductal dilation is often diffuse along the length of the organ, but there may be one or more intervening areas of ductal stricture. In many patients, calcific deposits (stones) may be evident on imaging studies within the main or secondary ducts.

Puestow described a procedure to provide enteric drainage to a diffusely dilated main pancreatic duct, with the goal of achieving pain relief by duct decompression. In its initial description, the Puestow procedure consisted of a longitudinal unroofing of the dilated pancreatic duct in the body and neck of the gland, and also involved resection of the pancreatic tail.<sup>52</sup> A long segment longitudinal pancreaticojejunostomy was then constructed to establish enteric drainage. A modification reported by Partington and Rochelle in 1960 eliminated the distal pancreatectomy. Lateral pancreaticojejunostomy is now thus referred to as either a (modified) Puestow or Partington-Rochelle procedure<sup>53</sup> and continues to be commonly used for disease characterized by a diffusely dilated main pancreatic duct with no significant biliary obstruction and no mass in the pancreatic head.

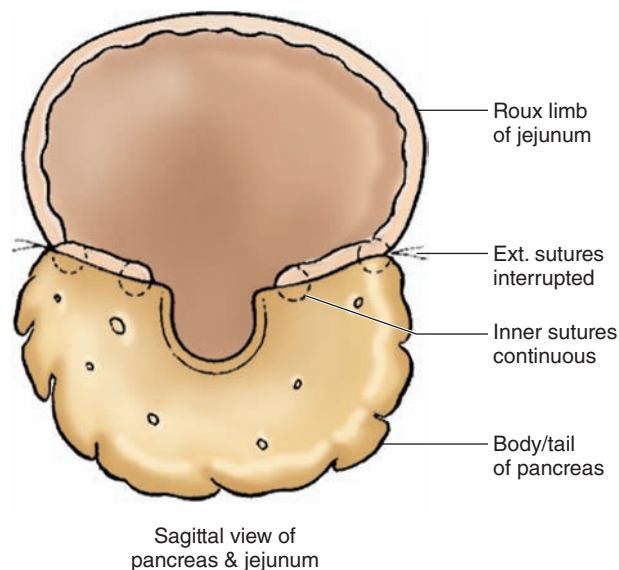
## LATERAL PANCREATICOJEJUNOSTOMY—TECHNIQUE

Midline or transverse upper abdominal incisions provide acceptable exposure for this procedure. The dissection is begun by incising the peritoneal lining adjacent to the lateral border of the second portion of the duodenum, extending laterally to release the hepatic flexure of the right colon. Using electrocautery, the retroperitoneal attachments lateral and posterior to the duodenum are divided to widely mobilize the duodenum and posterior aspect of the head of the pancreas (Kocher’s maneuver). This dissection is carried inferiorly to free the third portion of the duodenum from the base of the transverse mesocolon, effectively exposing the head of the

pancreas and anterior surface of the duodenum from the pylorus to the level of the superior mesenteric vessels. Exposure of the anterior surface of the pancreatic body and tail requires access to the lesser sac, which is entered by dividing the gastrosplenic omentum or by separating the avascular plane of attachment from the transverse colon and mesocolon. Next, the gastroduodenal artery (GDA) is identified at its supraduodenal origin from the common hepatic artery and traced across the head of the pancreas. The GDA is then suture ligated at both the superior and inferior border of the head of the pancreas in an effort to prevent intraoperative hemorrhage during incision of the pancreatic head and main pancreatic duct during the dissection as well as postoperative bleeding at the site of the pancreaticojejunostomy. The anterior surface of the pancreas is then carefully examined to confirm the presence of main duct dilation and the absence of suspicious mass lesions or unanticipated inflammatory changes in the head of the gland. The dilated pancreatic duct is usually visible by direct inspection or palpation of the anterior surface of the pancreas but can also be accessed by means of a fine needle and low-volume syringe. The duct can also be localized using intraoperative ultrasound, but this is usually not necessary. The pancreatic duct is then incised longitudinally along its full length using electrocautery. This ductotomy should extend across the neck into the head of the organ where the GDA traverses the pancreas, and should extend laterally as far as possible along the length of the tail so that the entire segment of dilated duct is unroofed. The pancreaticojejunal anastomosis is performed in Roux-en-Y fashion using a 40–50 cm defunctionalized jejunal limb. Using a linear gastrointestinal stapler, the proximal jejunum is divided at the apex of a mesojejunal vascular arcade of suitable mobility, typically at least 20–30 cm distal to the ligament of Treitz, although the precise distance is probably unimportant. The distal staple line is inverted using a series of 3-0 silk sutures placed in a Lembert fashion which are tied (but not cut) and then held by a fine clamp that facilitates later positioning of the pancreatic anastomosis. Intestinal continuity is then re-established by a handsewn or stapled enteroenterostomy such that the intestinal conduit is approximately 60 cm in length. The Roux limb is then advanced through the transverse mesocolon either to the right or left of the middle colic vessels. A longitudinal jejunostomy is made to correspond to the pancreatic ductotomy. The pancreaticojejunostomy is handsewn with a running absorbable suture (eg, 4-0 double-armed polyglyconate or polydioxanone suture), which, according to surgeon preference, may be additionally reinforced by an outer layer of interrupted nonabsorbable suture (Fig. 56-8). After completion of the anastomosis, the distance between the pancreaticojejunostomy and the enteroenterostomy should measure at least 40 cm to prevent reflux of enteric contents up to the anastomosis.

#### LATERAL PANCREATICOJEJUNOSTOMY—OUTCOMES

Results of the Partington-Rochelle procedure in appropriately selected patients are generally favorable. In most series,



**FIGURE 56-8** Cross-section of the anastomosis for a lateral pancreaticojejunostomy (applies to Puestow, Frey, or Izbicki procedures).

75–80% of patients with diffusely dilated main pancreatic ducts (>7 mm) and no dominant inflammatory mass, have achieved durable pain relief over 5–10 years of follow-up.<sup>52,54–57</sup> Compared to other major pancreatic operations, perioperative morbidity is low, and because no pancreatic parenchyma is removed, endocrine and exocrine functions are generally preserved relative to preoperative levels. Failure of lateral pancreaticojejunostomy is usually due to inappropriate patient selection (underappreciated extent of disease with the presence of significant fibrosis in the pancreatic head), or ongoing fibrosis with the progressive development of neuropathic pain.

### Chronic Pancreatitis With a Dominant Pancreatic Head Mass

Lateral pancreaticojejunostomy has limited applicability in patients without diffuse main duct dilation. Multiple groups have reported that an isolated drainage procedure in patients with complex inflammatory changes in the pancreatic head, body, or tail results in poor clinical outcome with quick recurrence of symptoms of pain and progression to exocrine insufficiency. For patients with an inflammatory mass, extensive calcifications or duct stones in the pancreatic head, results appear to be better either with pure resectional or with hybrid resection and drainage procedures. There are four procedures being used in a great frequency today. These include pancreaticoduodenectomy (Whipple procedure, with or without pyloric preservation) and three forms of duodenum-preserving pancreatic head resection (DPPHR): the Beger procedure, the Berne procedure, and the Frey procedure.

The outcomes associated with these procedures have been compared in several randomized trials enrolling small numbers of patients with head predominant morphology. None of these studies has demonstrated any one of the techniques to be clearly superior to others (Table 56-5). There are no measurable differences in outcomes compared, the numbers in the trials are small and the metrics used to evaluate the outcomes are variable and imperfect.<sup>58-61</sup> As a result, no consensus opinion among pancreatic experts about which procedure is the best in any given clinical situation has emerged. In recent years, European surgeons have tended to favor a duodenum-preserving approach and American surgeons have tended to favor pancreaticoduodenectomy. One recent survey of American surgeons who were members of the Pancreas Club found that of 59 surgeons surveyed, only 34 had ever performed DPPHR and that only 23 US surgeons continue to perform these procedures on a regular basis.<sup>62</sup>

In spite of the lack of data supporting the relative superiority of any given procedure, we do believe that each has specific applicability to certain subtypes of head predominant morphology. A reasonable approach is to tailor the procedure to the anatomic morphology seen on the preoperative axial imaging and ductography. Patients with a dominant head mass and a dilated main pancreatic duct but no biliary dilation, may be best served by a Frey procedure (limited duodenum-preserving resection of the pancreatic head with extended lateral pancreaticojejunostomy). Patients with a dominant head mass without main duct dilation and no biliary obstruction may be better suited for the Berne modification of the Beger procedure (limited duodenum-preserving resection of the pancreatic head without extension of the lateral pancreaticojejunostomy toward the tail). Patients with biliary obstruction or imaging characteristics more suspicious for the presence of

malignancy should probably undergo pancreaticoduodenectomy rather than any form of DPPHR.

### PANCREATICODUODENECTOMY—TECHNIQUE

The early primary objective in the pancreaticoduodenectomy is making an efficient determination of whether or not the pathology allows safe resection. This typically involves a thorough manual examination of the abdomen to rule out metastatic cancer and then a rapid exposure of the pancreatic neck superiorly and inferiorly in an effort to assess the operator's ability to free the hepatic artery, superior mesenteric vein, and superior mesenteric artery from the pathology in the pancreatic head safely. Pancreaticoduodenectomy may be performed through a midline laparotomy or bilateral subcostal incision. Careful inspection and palpation of the peritoneal surfaces and liver is performed first, with frozen-section biopsy obtained of any suspicious lesions. Small areas of fat necrosis or fibrosis from prior attacks of pancreatitis are easily mistaken for metastatic deposits. The base of the transverse mesocolon should be inspected for evidence of foreshortening or inflammatory involvement that may herald a difficult or dangerous dissection in the vicinity of the superior mesenteric vessels, and to confirm the absence of otherwise unsuspected tumor extension. The hepatic flexure of the colon is mobilized by freeing the lateral retroperitoneal attachments using the electrocautery, an extended Kocher maneuver is performed, and the lesser sac is then entered by separation or division of the gastrocolic omentum, as described in the previous section. The mass in the head of the gland is palpated and determined to be safely free from the superior mesenteric vein (SMV) at the inferior border of the neck of the pancreas by preliminary dissection of the plane anterior to the SMV posterior to the neck of the pancreas. Attention is

**TABLE 56-5: LONG-TERM FOLLOW-UP FROM RANDOMIZED COMPARISONS OF SURGICAL METHODS ADDRESSING HEAD DOMINANT MORPHOLOGY**

Author	Year	Procedures Compared	Number of Patients			Perioperative Morbidity (%)			Proc. A vs Proc B
			Proc. A	Proc. B	Follow-Up	Proc. A	Proc. B	p Value	QoL Difference
Buchler <sup>58</sup>	2008	DPPHR <sup>a</sup> (A) vs PPPD <sup>b</sup> (B)	40	40	14 years	35	37	>0.05	None
Izbicki <sup>67</sup>	2005	LR-LPJ <sup>c</sup> (A) vs DPPHR <sup>a</sup> (B)	36	38	9 years	22.0	32.0	>0.05	None
Izbicki <sup>68</sup>	2008	LR-LPJ <sup>c</sup> (A) vs PPPD <sup>b</sup> (B)	31	30	7 years	17.0	53.0	<0.05	None
Buchler <sup>59</sup>	2008	Berne(A) vs DPPHR <sup>a</sup> (B)	35	35	2 Years	21.0	20.0	>0.05	None

<sup>a</sup>DPPHR, duodenal preserving pancreatic head resection.

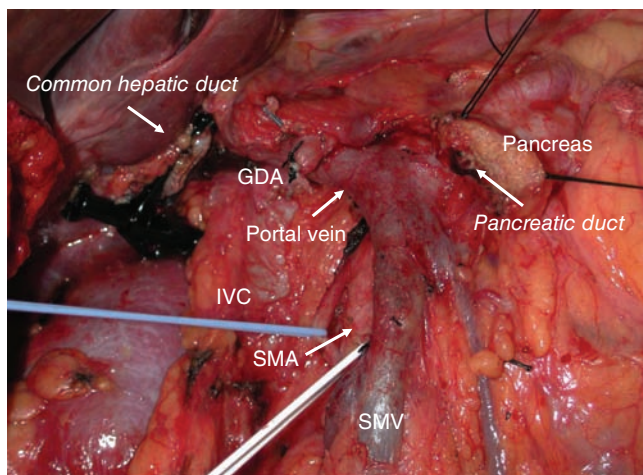
<sup>b</sup>PPPD, pylorus-preserving pancreaticoduodenectomy.

<sup>c</sup>LR-LPJ, local resection pancreatic head with longitudinal pancreaticojejunostomy (Frey procedure).



then turned to the supraduodenal region. A cholecystectomy is performed, and the portal dissection is initiated by isolating the common bile duct (CBD) at the level of the cystic duct stump. The bile duct is carefully freed from the anterolateral surface of the portal vein and secured temporarily with a vessel loop. The common hepatic artery is usually found anteromedially to the portal vein, and it should be carefully isolated with a vessel loop and preserved. The lateral, free edge of the gastrohepatic ligament at the foramen of Winslow should be carefully inspected and palpated for an accessory or replaced right hepatic artery, which, if present, should also be isolated and protected during the subsequent resection. The GDA is isolated at its origin from the common hepatic artery and secured temporarily with a vessel loop. The continued presence of pulsatile flow in the proper hepatic artery after temporary occlusion of the GDA should be assured, both to confirm the vascular anatomy and to ensure that there is no stenosis in the proximal common hepatic artery or celiac trunk due to atherosclerotic plaque. Preliminary dissection of the plane anterior to the portal vein is begun. These measures demonstrate that there is no evidence of unresectable cancer and that the pancreatic head can be removed without concern for undue injury to the blood supply of the small intestine and liver.

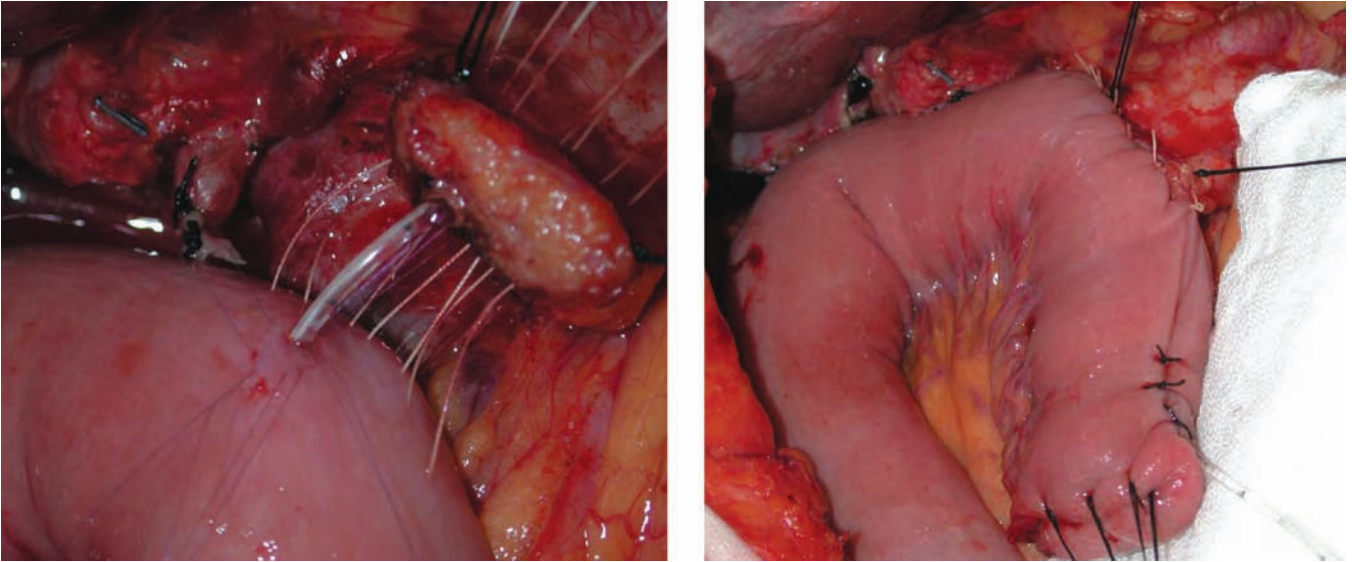
At this point, technical resectability of the pancreatic head has been assured (Fig. 56-9). The GDA is divided between clamps and is doubly tied or suture ligated. The common hepatic duct is divided just proximal to the cystic duct entry, and bile flow is controlled with a small bulldog clamp. The right gastric artery is divided between suture ligatures. For a standard pancreaticoduodenectomy, the greater omentum is divided to a point on the greater curvature of the stomach in the vicinity of the junction of the



**FIGURE 56-9** Retroperitoneal dissection for pancreaticoduodenectomy. Note the ligated gastroduodenal artery (GDA), portal vein, inferior vena cava (IVC), superior mesenteric artery and vein (SMA, SMV), and the main pancreatic duct at the edge the transected pancreas. (Reproduced from, Ahmad SA, Wray C, Rilo HL, et al. Chronic pancreatitis: recent advances and ongoing challenges. *Curr Probl Surg.* 2006;43(3):127–238.)

right and left gastroepiploic arteries. The lesser omentum is divided at the level of the incisura of the lesser curvature of the stomach, and the descending branch of the left gastric artery is carefully secured. The stomach is then divided with two firings of a linear gastrointestinal stapler. The lesser curve staple line is inverted with silk Lembert sutures. For pyloric-preserving pancreaticoduodenectomy, the duodenum is divided using a stapler approximately 2 cm distal to the pyloric ring. The ligament of Treitz is taken down with electrocautery, being certain to avoid injury to the inferior mesenteric vein. The proximal jejunum is divided approximately 15 cm distal to the ligament of Trietz with a linear gastrointestinal stapler. The distal staple line is oversewn with interrupted Lembert sutures, initially left long to use for traction and positioning of the limb during the reconstruction. The short mesojejunal vessels of the proximal segment are carefully isolated and secured close to the mesenteric border of the jejunum using fine nonabsorbable ligatures, surgical clips, or an electrosurgical vessel-sealing device. This dissection is continued proximally to the duodenojejunal junction, and then the proximal jejunum is advanced into the supracolic compartment by passing it under the superior mesenteric vessels. At this point blunt dissection is used to complete development of a tunnel between the neck of the pancreas and the SMV or portal vein. The superior and inferior pancreatic vascular arcades are then ligated on either side of the planned transection site at the neck of the pancreas using nonabsorbable suture. The neck is then divided with electrocautery. Gentle retraction of the pancreatic head, distracting it from the right lateral wall of the SMV or portal vein, helps to expose small venous tributaries from the uncinate process, which should then be carefully controlled with fine ties or suture ligatures. The first jejunal venous tributary may be quite large and is easily injured during this dissection. The uncinate branches from the superior mesenteric artery (SMA) are then divided sequentially between clamps with great care to preserve the integrity of the SMA. The specimen is then oriented and submitted for pathological examination.

The reconstruction begins with the pancreaticojejunostomy (Fig. 56-10). The jejunum is advanced through the transverse mesocolon either to the right or left of the middle colic vessels according to surgeon's preference. Several techniques of pancreaticojejunostomy have been described. One commonly used approach is a two-layer method that is begun by placing a posterior row of interrupted nonabsorbable sutures between the pancreatic capsule and the seromuscular layer at the antimesenteric aspect of the jejunum. A small enterotomy is then made with bovie cautery across from the site of the main pancreatic duct at the pancreatic neck. An inner layer of four to eight interrupted fine absorbable monofilament sutures is used to secure the pancreatic duct to the intestinal wall at the enterotomy in a duct-to-mucosa fashion. An anterior row of interrupted nonabsorbable suture is then used to secure the anterior pancreatic capsule to the anterior serosa at the antimesenteric border of the jejunal limb. The duct-to-mucosa anastomosis may also be performed over a



**FIGURE 56-10** Pancreaticojejunostomy. At left, a duct-to-mucosa anastomosis is constructed using fine absorbable mattress sutures over a small (5F) pediatric feeding tube. At right, the completed anastomosis, with transanastomotic stent exteriorized through the jejunum and abdominal wall to divert pancreatic secretions. (Reproduced from Ahmad SA, Wray C, Rilo HL, et al. Chronic pancreatitis: recent advances and ongoing challenges. *Curr Probl Surg.* 2006;43(3):127–238.)

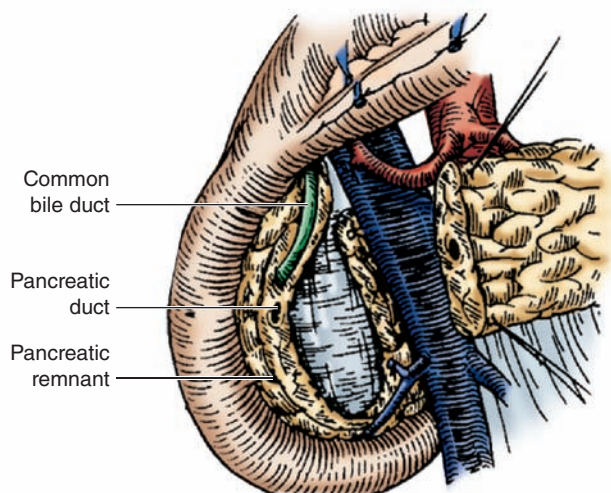
5F pediatric feeding tube, which can then be exteriorized through the jejunal limb using a Witzel-type closure. The choledochojejunostomy is then constructed at a site approximately 15 cm distal to the pancreaticojejunostomy. A small enterotomy is made at the antimesenteric border of the jejunal limb at this location. The choledochojejunostomy is also performed in a duct-to-mucosa fashion, either with a single layer of interrupted absorbable monofilament suture or, if the bile duct is dilated, using absorbable continuous suture. The pancreaticobiliary limb is then secured to the transverse mesocolon using interrupted sutures and any potential gap through which herniation may occur is closed. The retroperitoneal space at the level of the ligament of Treitz is also closed. Gastric continuity is reestablished by means of an antecolic loop gastrojejunotomy performed at a site sufficiently distal to the transverse mesocolon closure to prevent angulation of the afferent limb. A Hofmeister-type configuration is typically used, wherein the lesser curvature half of the gastric transection line is oversewn and the anastomosis is performed to the greater curvature half. The jejunal limb is oriented with the afferent limb toward the lesser curvature, efferent limb to the greater curvature. A two-layered anastomosis is preferred, with an outer layer of nonabsorbable interrupted seromuscular Lembert sutures and an inner continuous absorbable Connell-style layer. The abdomen is then irrigated with saline or dilute antibiotic solution and the abdominal wall closed. No closed suction peritoneal drains are necessary.

#### BEGER PROCEDURE—TECHNIQUE

Duodenum-preserving pancreatic head resection was first described by Beger in 1972. The operation evolved from the

premise that a pancreaticoduodenectomy was unnecessarily radical for benign pathology and that a more limited resection preserving the duodenum would avoid some of the adverse sequelae associated with pancreaticoduodenectomy such as delayed gastric emptying and insulin-dependent diabetes.<sup>63</sup> The procedure is performed through a midline laparotomy or bilateral subcostal incision. As at the start of the pancreaticoduodenectomy, the gastrocolic ligament is separated or divided, the transverse mesocolon is mobilized off the head of the pancreas and duodenum, and a wide Kocher maneuver is performed. A cholecystectomy is performed. The GDA is isolated and divided. A tunnel is then created between the pancreatic neck and superior mesenteric vein or portal vein. The pancreatic neck is divided at this location and the pancreatic head manually rotated out of the retroperitoneum so that the cut edge faces up into the midline wound. The cystic duct is cannulated with a Bakes dilator and the CBD manually palpated in the head of the pancreas. Electrocautery is then used to core out the head of the gland with care taken to leave a rim of pancreas attached to the duodenum and to leave the bile duct intact within that rim (Fig. 56-11). The specimen is submitted to pathology for frozen-section examination to confirm the absence of malignancy. Pancreaticocenteric drainage is then reestablished by means of a two-sided Roux-Y pancreaticojejunostomy (Fig. 56-12). A Roux limb of jejunum is fashioned and advanced into the supracolic compartment through the transverse mesocolon as described for the lateral pancreaticojejunostomy. A two-layered handsewn duct to mucosa pancreaticojejunostomy is constructed at the neck margin as done for a typical pancreaticoduodenectomy with the exception that the anastomosis is sited closer to the mesenteric margin of the jejunum. The jejunal limb is then



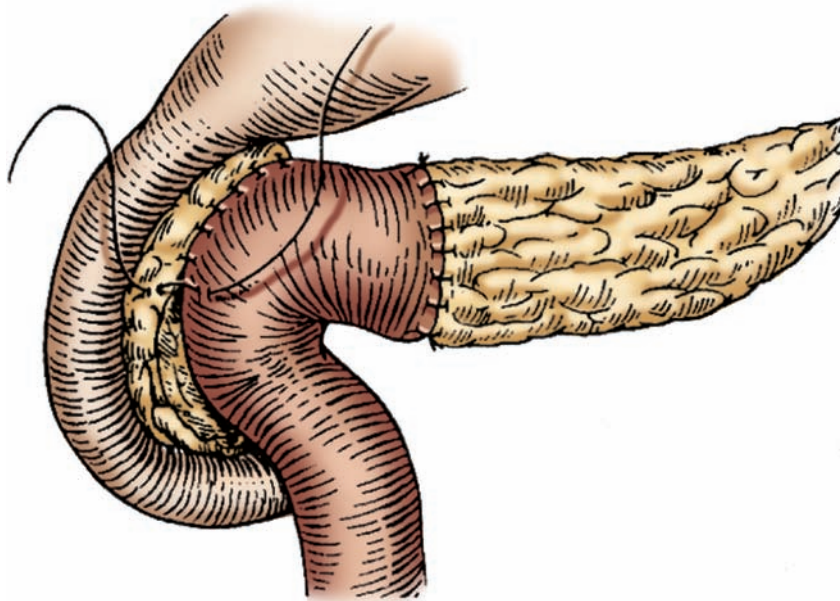


**FIGURE 56-11** The anatomy following transection of the neck of the pancreas and removal of the head during the Beger procedure.

laid such that the antimesenteric border of the limb faces the midline wound. A second long pancreaticojejunostomy is constructed here by opening the border of the jejunal limb contralateral to the first pancreaticojejunostomy at the neck for a distance appropriate to include the entire length of the proximal pancreatic rim. This pancreatic margin is then secured to the long longitudinal enterotomy by means of a single layer of interrupted nonabsorbable suture. Intestinal continuity is then reestablished by means of a jejunojunction performed as described earlier for the lateral pancreaticojejunostomy. The abdomen is irrigated and closed. No closed suction drains are necessary.

### BEGER PROCEDURE VERSUS PANCREATODUODENECTOMY—OUTCOMES

Beger has recently reviewed his three-decade experience with DPPHR for chronic pancreatitis presenting with an inflammatory mass in the pancreatic head. His perioperative results demonstrate very reasonable rates of morbidity and mortality and an impressive improvement in pancreatic pain. His pancreatic fistula rate is reported as 3.3%, the rate of delayed emptying reported is 1.5%, and perioperative mortality rate is 0.7% in 603 consecutive patients. Late outcomes reported in this series demonstrated 91.3% of patients are free of pain at a median follow-up of 5.7 years.<sup>64</sup> There have been two randomized trials that have attempted to compare outcomes from DPPHR to those achieved with pylorus-preserving pancreatoduodenectomy (PPPD). The most widely cited is by Buchler and colleagues and has been recently represented with long-term results. In this study 40 patients with chronic pancreatitis and a dominant focus in the pancreatic head were randomized to PPPD or DPPHR. The initial paper reported 6-month outcomes. This demonstrated a statistical advantage to DPPHR with regard to pain (75% of patients undergoing DPPHR were pain free at 6 months vs 40% of patients undergoing PPPD) and weight gain (average weight gain for those undergoing DPPHR was 4.1 kg whereas that for those undergoing PPPD was 1.9 kg).<sup>65</sup> Length of hospital stay, perioperative morbidity and perioperative mortality rates were statistically identical. The authors of this study have recently presented their long-term results. At median follow-up of 7 years, the early advantages of the DPPHR were no longer evident with patients in each group having identical health-related quality of life scores, identical pain scores, and identical rates of exocrine and endocrine insufficiency. The other randomized comparison again studied only 40 patients



**FIGURE 56-12** Final anatomy of the reconstruction following a Beger procedure.



for 12 months. This study demonstrated statistically identical rates of pain relief but a slight statistical advantage in terms of scores seen on a general assessment of health-related quality of life for patients undergoing DPPHR relative to those undergoing PPPD.<sup>58</sup>

### FREY PROCEDURE—TECHNIQUE

The disadvantage of the DPPHR as described by Beger is that it does not address disease (either diffuse parenchymal fibrosis with side branch disruption or stricturing with upstream dilation of the main pancreatic duct) that may coexist in the pancreatic body and tail. Late failures of the Beger procedure have been attributed to poor drainage of the pancreatic body and tail. In an effort to overcome this, and in large part to avoid the certain exocrine and endocrine insufficiency that comes with the near-total pancreatectomy pioneered by one of his early mentors, Frey and colleagues developed a procedure that combines a duodenum-preserving pancreatic head resection with a hybrid resection or drainage procedure at the pancreatic body and tail (referred to as a local resection of the pancreatic head with longitudinal pancreaticojejunostomy or LR-LPJ) (Fig. 56-13). In this procedure, no tunnel is created behind the pancreatic neck. Instead the entire length of the pancreas is exposed anteriorly. The GDA is ligated. The gallbladder is removed. The cystic duct is cannulated using a Bakes dilator and the bile duct is identified in its course through the head of the pancreas by palpating the dilator. The pancreatic head is then excavated down to the level of the portal vein with care taken to leave a rim of tissue surrounding the bile duct at the duodenal margin. From this cavity

an extensive longitudinal unroofing of the pancreatic duct through the body and tail is made using electrocautery. If the duct is not dilated in the tail, then the body and tail may simply be excavated as done at the pancreatic head (Fig. 56-14). Pancreaticocentric drainage is then accomplished by means of a lateral pancreaticojejunostomy covering the entire excavation cavity, typically constructed using a Roux-en-Y jejunal limb sewn to the pancreatic capsule in one or two layers.

### FREY PROCEDURE VERSUS BEGER PROCEDURE—OUTCOMES

In various reports including small randomized trials, the results of LR-LPJ appear similar to those reported for the Beger DPPHR, with postoperative mortality less than 1% and morbidity reported as 19–32%.<sup>60,66</sup> Excellent pain relief is obtained in about 75% of patients and the change in postoperative pain scores and rates of postoperative exocrine and endocrine insufficiency are identical over follow-up as long as 9 years. A small prospective randomized trial compared LR-LPJ to PPPD with an average length of follow-up of 2 years. Postoperative morbidity was significantly higher in the PPPD group (53 vs 17% for the LR-LPJ group). Although there was similar improvement in pain symptoms, the LR-LPJ group demonstrated a statistically better overall quality of life as assessed by a general assessment of health-related quality of life.<sup>67</sup> The long-term results of the study were published in 2008 with a median follow-up of 7 years. At that length of follow-up, there were no statistical differences with regard to the improvement in pain, health-related quality of life or the incidence of exocrine or endocrine insufficiency.<sup>68</sup>

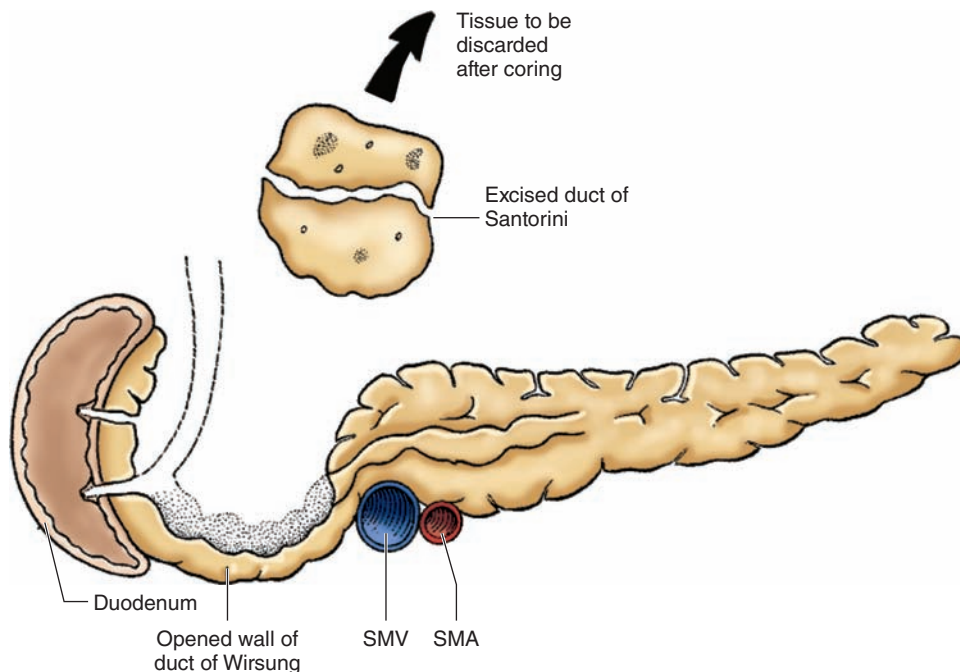


FIGURE 56-13 Cross-sectional drawing of the pancreas following coring of the pancreatic head during a Frey procedure.

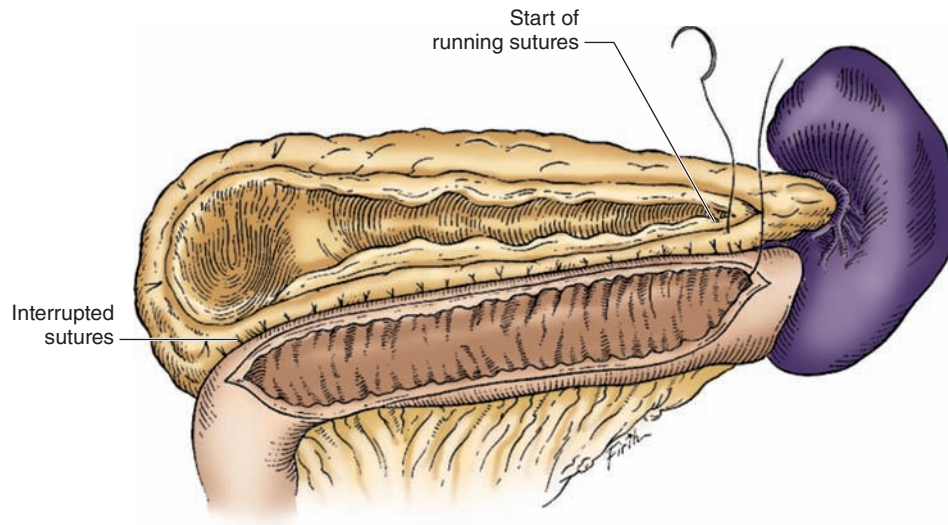


FIGURE 56-14 Pancreaticeojejunostomy (Frey procedure).

#### BERNE PROCEDURE—TECHNIQUE AND OUTCOMES

There has been one further modification of the Beger DPPHR made in recent years. The Berne procedure adopts the technical safety advantage of the Frey LR-LPJ that comes by avoiding transection of the neck of the pancreas off the portal vein. In this modification as in the Beger DPPHR, no lateral pancreaticeojejunostomy is performed. The anterior surface of the mass in the head is palpated and then cored out by electrocautery. A Roux limb is then sewn to the residual pancreatic rim at this location. One randomized trial comparing the Berne modification to the standard Beger DPPHR showed rough equivalence of outcomes with these procedures.<sup>59</sup>

#### Small Duct Disease or Diffuse Sclerosis

In many instances, as the disease progresses there will be no dominant focus of ductal obstruction and no dominant mass. Instead the morphology of the disease is characterized by diffuse calcification and/or diffuse fibrosis with atrophy of the pancreatic parenchyma. In these cases the pancreatic remnant may be quite small and will have a uniform firm consistency. Patients with this morphology of disease present a particular challenge, as there is no discrete target for either endoscopic or surgical intervention. Those manifesting intractable pain syndromes have had, until very recently, few and imperfect options for surgical management. These have included total or near-total pancreatectomy procedures that have traditionally been avoided due to the significant morbidity associated with profound postoperative exocrine and endocrine insufficiency. Autologous islet transplantation may mitigate the

diabetic consequences of total pancreatectomy. Another alternative for small duct disease is the V-shaped or wedge pancreatectomy described by Izbicki.<sup>69</sup>

#### TOTAL PANCREATECTOMY WITH AUTOLOGOUS ISLET TRANSPLANTATION—TECHNIQUE

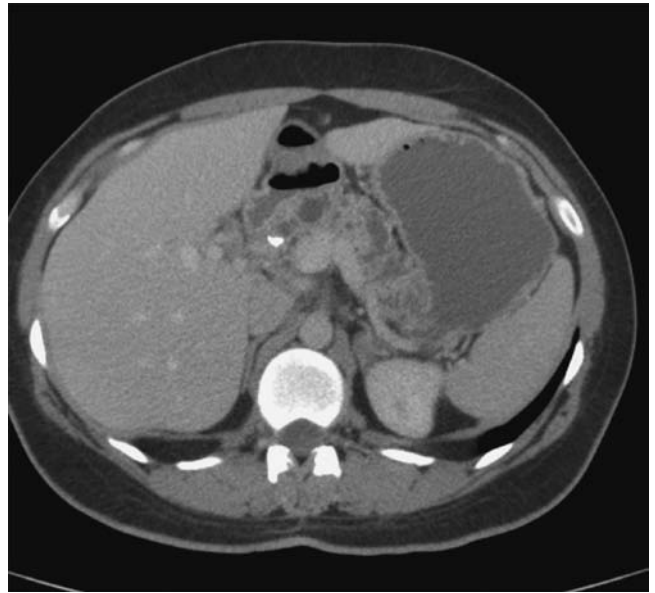Total pancreatectomy is performed as either an en bloc resection of the pancreatic head, body, and tail or, more commonly, in a staged fashion with a left pancreatectomy followed by a head resection (pancreaticoduodenectomy) allowing initial islet processing on the body and tail specimen. The isolation process relies on enzymatic and mechanical mechanisms to dissociate the islets from surrounding acinar tissue and fibrosis. Depending on the proximity of the islet isolation facilities and the efficiency of the process, infusion of the islet preparation into the portal circulation may be performed during the same anesthetic or postoperatively (usually the same day) under radiological guidance.<sup>70</sup> Briefly, the resected pancreas is cooled to 4°C in an organ-preserving solution (eg, University of Wisconsin Solution). The pancreas is then transected at the neck of the gland and the pancreatic duct cannulated. The ductal system is then perfused with a cold solution of the purified digestive enzyme collagenase. The gland is sectioned, and then physically shaken in a small digestion chamber at 37°C until the acinar tissue is separated from the endocrine tissue. The islets are then partially purified from the acinar debris by gradient density centrifugation on a cold dextrose gradient. The islets are washed and resuspended in an albumin-rich transplant medium or cultured. The islets are transplanted by direct injection into portal circulation with access to the portal circulation being achieved under ultrasound-guided percutaneous placement of a transhepatic portovenous catheter in interventional radiology or by direct operative cannulation of the portal vein.

## AUTOLOGUS ISLET TRANSPLANTATION—OUTCOMES

The first human autologous islet transplant was performed at the University of Minnesota in 1977 and since that time several hundred procedures have been reported from Minnesota, Miami, Cincinnati, Leicester, and other emerging centers.<sup>71</sup> Taken together, the results from these institutions suggest that in a highly selected group of patients, complete pain relief (without the use of narcotics) can be achieved in approximately 50–60% of patients but that there is a significant rate of recidivism of pain after 1 year of follow-up. Insulin-independence is initially achieved in 40–50% of patients but there is a steady decline in islet function that continues even at 10 years of follow-up. Although reports of assessment of quality of life after total pancreatectomy with autologous islet transplantation suggests that the procedure compares favorably to either total pancreatectomy without islet transplantation or to continue nonoperative management of pain, direct evidence supporting this approach over alternatives in appropriately matched controls is lacking. Total pancreatectomy with autologous islet transplantation is costly and requires a high degree of technical expertise that is difficult to replicate. The indications for islet autotransplantation are controversial and the overall safety and efficacy of the procedure have not been fully validated outside a handful of centers. Questions regarding the long-term viability of the islets and adverse impact on the surrounding liver parenchyma have been raised. Pathologic analysis of liver tissue that has been explanted following islet transplant has demonstrated that the transplanted islets typically migrate across the liver sinusoids and reside in the liver parenchyma. It has also been noted that the transplanted islets exhibit some degree of peri-islet fibrosis in the liver. There have been no reports of chronic hepatic fibrosis or cirrhosis in patients receiving autologous islets but the concern exists. It must be emphasized that complete long-term insulin independence is achieved only in a relatively small minority of patients after islet autotransplantation and that pain is persistent or recurrent in about half of patients even after total pancreatectomy.<sup>72</sup> Currently, the strongest arguments in favor of total pancreatectomy and islet autotransplantation can perhaps be made in the setting of a limited subset of patients with hereditary pancreatitis, who otherwise carry a significant long-term risk of developing pancreatic cancer. When a more traditional surgical operation (resection or drainage) is also possible in this setting, decision making must be highly individualized (Fig. 56-15).

## IZBICKI PROCEDURE—TECHNIQUE AND OUTCOMES

An alternative to total pancreatectomy (with or without islet autotransplantation) that may yield similar rates of pain relief yet preserve islet function is the V-shaped longitudinal pancreatic resection introduced by Izbicki and colleagues for patients with small duct disease and diffuse fibrosis. In this procedure the entire pancreas is excavated



**FIGURE 56-15** Hereditary chronic pancreatitis associated with *PRSS1* gene mutation. A single calcification is evident in the pancreatic head, and the main pancreatic duct shows diffuse dilation. Lateral pancreaticoduodenectomy is an appropriate surgical option; total pancreatectomy with islet autotransplantation to eliminate cancer risk associated with hereditary pancreatitis is controversial.

along the trajectory of the main pancreatic duct from the pancreatic head (as with the Frey procedure) across the body and tail of the organ. Pancreaticoenteric drainage is established by Roux-en-Y lateral pancreaticojejunostomy similar to the Puestow and Frey procedures. The short-term results of the Izbicki procedure compare favorably to those reported in the Minnesota and Cincinnati series of autologous islet transplantation, although the patient populations are not matched.<sup>61</sup>

## CONCLUSIONS

Chronic pancreatitis is a relapsing inflammatory process that results in a variable degree of parenchymal destruction and fibrotic change in the pancreas with consequent clinical manifestations typically including characteristic abdominal pain, exocrine and endocrine insufficiency. A single unifying model for the pathogenesis of chronic pancreatitis remains elusive, although recent basic and clinical research has identified a number of gene mutations, immunologic conditions, environmental toxins, and anatomic anomalies that alone and together confer risk of developing chronic pancreatitis. The morphology of pathological change seen in the gland at the time that patients present for treatment varies significantly from one patient to the next. A myriad of endointerventional and surgical procedures have been developed over time and are now applied in the treatment of the disease. Both the endoscopic and surgical procedures used are technically demanding and carry substantial risk of morbidity.



While there is substantial retrospective, case-series evidence demonstrating the utility of these approaches in well-selected patients, high-level evidence comparing the efficacy of the interventions in large series is lacking. For all of these reasons, chronic pancreatitis is often best managed in experienced centers in which multidisciplinary teams collaborate to individualize treatment in the context of established local expertise with various medical, endoscopic, and surgical therapies.

## REFERENCES

- Sarles H, Adler G, Dani R, et al. Classifications of pancreatitis and definition of pancreatic diseases. *Digestion*. 1989;43(4):234–236.
- Gambill EE, Comfort MW, Baggenstoss AH. Chronic relapsing pancreatitis, an analysis of 27 cases associated with disease of the biliary tract. *Gastroenterology*. 1948;11(1):1–33.
- Conwell DL, Banks PA. Chronic pancreatitis. *Curr Opin Gastroenterol*. 2008;24(5):586–590.
- Etemad B, Whitcomb DC. Chronic pancreatitis: diagnosis, classification, and new genetic developments. *Gastroenterology*. 2001;120(3):682–707.
- Irving HM, Samokhvalov AV, Rehm J. Alcohol as a risk factor for pancreatitis. A systematic review and meta-analysis. *JOP*. 2009;10(4):387–392.
- Tolstrup JS, Kristiansen L, Becker U, Gronbaek M. Smoking and risk of acute and chronic pancreatitis among women and men: a population-based cohort study. *Arch Intern Med*. 2009;169(6):603–609.
- Rahman SH, Nanny C, Ibrahim K, et al. Genetic polymorphisms of GSTT1, GSTM1, GSTP1, MnSOD, and catalase in nonhereditary chronic pancreatitis: evidence of xenobiotic stress and impaired antioxidant capacity. *Dig Dis Sci*. 2005;50(7):1376–1383.
- Comfort MW, Steinberg AG. Pedigree of a family with hereditary chronic relapsing pancreatitis. *Gastroenterology*. 1952;21(1):54–63.
- Tzetzis M, Kaliakatos M, Fotoulaki M, et al. Contribution of the CFTR gene, the pancreatic secretory trypsin inhibitor gene (SPINK1) and the cationic trypsinogen gene (PRSS1) to the etiology of recurrent pancreatitis. *Clin Genet*. 2007;71(5):451–457.
- Felderbauer P, Stricker I, Schneckengerber J, et al. Histopathological features of patients with chronic pancreatitis due to mutations in the PRSS1 gene: evaluation of BRAF and KRAS2 mutations. *Digestion*. 2008;78(1):60–65.
- Weiss FU, Sahin-Toth M. Variations in trypsinogen expression may influence the protective effect of the p.G191R PRSS2 variant in chronic pancreatitis. *Gut*. 2009;58(6):749–750.
- Rosendahl J, Witt H, Szmola R, et al. Chymotrypsin C (CTRC) variants that diminish activity or secretion are associated with chronic pancreatitis. *Nat Genet*. 2008;40(1):78–82. PMID: 2650829.
- Thrower E, Husain S, Gorelick F. Molecular basis for pancreatitis. *Curr Opin Gastroenterol*. 2008;24(5):580–585.
- Sharer N, Schwarz M, Malone G, et al. Mutations of the cystic fibrosis gene in patients with chronic pancreatitis. *N Engl J Med*. 1998;339(10):645–652.
- Cohn JA, Friedman KJ, Noone PG, Knowles MR, Silverman LM, Jowell PS. Relation between mutations of the cystic fibrosis gene and idiopathic pancreatitis. *N Engl J Med*. 1998;339(10):653–658.
- Marino CR, Matovicik LM, Gorelick FS, Cohn JA. Localization of the cystic fibrosis transmembrane conductance regulator in pancreas. *J Clin Invest*. 1991;88(2):712–6. PMID: 295422.
- Ahmed N, Corey M, Forstner G, et al. Molecular consequences of cystic fibrosis transmembrane regulator (CFTR) gene mutations in the exocrine pancreas. *Gut*. 2003;52(8):1159–1164. PMID: 1773762.
- Chang WI, Kim BJ, Lee JK, et al. The clinical and radiological characteristics of focal mass-forming autoimmune pancreatitis: comparison with chronic pancreatitis and pancreatic cancer. *Pancreas*. 2009;38(4):401–408.
- Finkelberg DL, Sahani D, Deshpande V, Brugge WR. Autoimmune pancreatitis. *N Engl J Med*. 2006;355(25):2670–2676.
- Frulloni L, Lunardi C, Simone R, et al. Identification of a novel antibody associated with autoimmune pancreatitis. *N Engl J Med*. 2009;361(22):2135–2142.
- Manfredi R, Graziani R, Cicero C, et al. Autoimmune pancreatitis: CT patterns and their changes after steroid treatment. *Radiology*. 2008;247(2):435–443.
- Klein SD, Affronti JP. Pancreas divisum, an evidence-based review: part I, pathophysiology. *Gastrointest Endosc*. 2004;60(3):419–425.
- Anaparthi R, Pasricha PJ. Pain and chronic pancreatitis: is it the plumbing or the wiring? *Curr Gastroenterol Rep*. 2008;10(2):101–106.
- Ceyhan GO, Bergmann F, Kadihasanoglu M, et al. Pancreatic neuropathy and neuropathic pain—a comprehensive pathomorphological study of 546 cases. *Gastroenterology*. 2009;136(1):177–186 e1.
- Drewes AM, Gratkowski M, Sami SA, Dimceviski G, Funch-Jensen P, Arendt-Nielsen L. Is the pain in chronic pancreatitis of neuropathic origin? Support from EEG studies during experimental pain. *World J Gastroenterol*. 2008;14(25):4020–4027.
- Hoogerwerf WA, Shenoy M, Winston JH, Xiao SY, He Z, Pasricha PJ. Trypsin mediates nociception via the proteinase-activated receptor 2: a potentially novel role in pancreatic pain. *Gastroenterology*. 2004;127(3):883–891.
- Ammann RW, Buehler H, Muench R, Freiburghaus AW, Siegenthaler W. Differences in the natural history of idiopathic (nonalcoholic) and alcoholic chronic pancreatitis. A comparative long-term study of 287 patients. *Pancreas*. 1987;2(4):368–377.
- Frulloni L, Scattoni C, Graziani R, et al. Clinical and radiological outcome of patients suffering from chronic pancreatitis associated with gene mutations. *Pancreas*. 2008;37(4):371–376.
- Keck T, Marjanovic G, Fernandez-del Castillo C, et al. The inflammatory pancreatic head mass: significant differences in the anatomic pathology of German and American patients with chronic pancreatitis determine very different surgical strategies. *Ann Surg*. 2009;249(1):105–110.
- Schlaudraff E, Wagner HJ, Klose KJ, Heverhagen JT. Prospective evaluation of the diagnostic accuracy of secretin-enhanced magnetic resonance cholangiopancreatography in suspected chronic pancreatitis. *Magn Reson Imaging*. 2008;26(10):1367–1373.
- Sarles H, Bernard JP, Johnson C. Pathogenesis and epidemiology of chronic pancreatitis. *Annu Rev Med*. 1989;40:453–468.
- Sarner M, Cotton PB. Classification of pancreatitis. *Gut*. 1984;25(7):756–759.
- Clouse RE, Mayer EA, Aziz Q, et al. Functional abdominal pain syndrome. *Gastroenterology*. 2006;130(5):1492–1497.
- Papanikolaou IS, Adler A, Neumann U, Neuhaus P, Rosch T. Endoscopic ultrasound in pancreatic disease—its influence on surgical decision-making. An update 2008. *Pancreatol*. 2009;9(1–2):55–65.
- Morris-Stiff G, Al-Allak A, Frost B, Lewis WG, Puntis MC, Roberts A. Does endoscopic ultrasound have anything to offer in the diagnosis of idiopathic acute pancreatitis? *JOP*. 2009;10(2):143–146.
- Kowalczyk LM, Draganov PV. Endoscopic therapy for chronic pancreatitis: technical success, clinical outcomes, and complications. *Curr Gastroenterol Rep*. 2009;11(2):111–118.
- Wiersema MJ, Hawes RH, Lehman GA, Kochman ML, Sherman S, Kopecky KK. Prospective evaluation of endoscopic ultrasonography and endoscopic retrograde cholangiopancreatography in patients with chronic abdominal pain of suspected pancreatic origin. *Endoscopy*. 1993;25(9):555–564.
- Pungpapong S, Wallace MB, Woodward TA, Noh KW, Raimondo M. Accuracy of endoscopic ultrasonography and magnetic resonance cholangiopancreatography for the diagnosis of chronic pancreatitis: a prospective comparison study. *J Clin Gastroenterol*. 2007;41(1):88–93.
- Hoki N, Mizuno N, Sawaki A, et al. Diagnosis of autoimmune pancreatitis using endoscopic ultrasonography. *J Gastroenterol*. 2009;44(2):154–159.
- Tran TC, van't Hof G, Kazemier G, et al. Pancreatic fibrosis correlates with exocrine pancreatic insufficiency after pancreatoduodenectomy. *Dig Surg*. 2008;25(4):311–318.
- Whitcomb DC. Value of genetic testing in the management of pancreatitis. *Gut*. 2004;53(11):1710–1717. PMID: 1774302.
- Winstead NS, Wilcox CM. Clinical trials of pancreatic enzyme replacement for painful chronic pancreatitis—a review. *Pancreatol*. 2009;9(4):344–350.
- Andersen DK. Mechanisms and emerging treatments of the metabolic complications of chronic pancreatitis. *Pancreas*. 2007;35(1):1–15.
- Bhardwaj P, Garg PK, Maulik SK, Saraya A, Tandon RK, Acharya SK. A randomized controlled trial of antioxidant supplementation

- for pain relief in patients with chronic pancreatitis. *Gastroenterology*. 2009;136(1):149–159 e2.
45. Kongkam P, Wagner DL, Sherman S, et al. Intrathecal narcotic infusion pumps for intractable pain of chronic pancreatitis: a pilot series. *Am J Gastroenterol*. 2009;104(5):1249–1255.
  46. Gress F, Schmitt C, Sherman S, Ciaccia D, Ikenberry S, Lehman G. Endoscopic ultrasound-guided celiac plexus block for managing abdominal pain associated with chronic pancreatitis: a prospective single center experience. *Am J Gastroenterol*. 2001;96(2):409–416.
  47. Buscher HC, Schipper EE, Wilder-Smith OH, Jansen JB, van Goor H. Limited effect of thoracoscopic splanchnicectomy in the treatment of severe chronic pancreatitis pain: a prospective long-term analysis of 75 cases. *Surgery*. 2008;143(6):715–722.
  48. Deviere J, Bell RH, Jr., Beger HG, Traverso LW. Treatment of chronic pancreatitis with endotherapy or surgery: critical review of randomized control trials. *J Gastrointest Surg*. 2008;12(4):640–644.
  49. Evans KA, Clark CW, Vogel SB, Behrns KE. Surgical management of failed endoscopic treatment of pancreatic disease. *J Gastrointest Surg*. 2008;12(11):1924–1929.
  50. Dite P, Ruzicka M, Zboril V, Novotny I. A prospective, randomized trial comparing endoscopic and surgical therapy for chronic pancreatitis.[see comment]. *Endoscopy*. 2003;35(7):553–558.
  51. Cahen DL, Gouma DJ, Nio Y, et al. Endoscopic versus surgical drainage of the pancreatic duct in chronic pancreatitis. [reprint in Ned Tijdschr Geneesk. 2007 Nov 24;151(47):2624–2630; PMID: 18161265]. *N Engl J Med*. 2007;356(7):676–684.
  52. Puestow P. Chronic pancreatitis. Technique and results of longitudinal pancreaticojejunostomy. *Bull Soc Int Chir*. 1965;24:244–272.
  53. Partington PF, Rochelle RE. Modified Puestow procedure for retrograde drainage of the pancreatic duct. *Ann Surg*. 1960;152:1037–1043.
  54. Prinz RA, Kaufman BH, Folk FA, Greenlee HB. Pancreaticojejunostomy for chronic pancreatitis. Two- to 21-year follow-up. *Arch Surg*. 1978;113(4):520–525.
  55. Prinz RA, Greenlee HB. Pancreatic duct drainage in chronic pancreatitis. *Hepatogastroenterology*. 1990;37(3):295–300.
  56. Prinz RA, Greenlee HB. Pancreatic duct drainage in 100 patients with chronic pancreatitis. *Ann Surg*. 1981;194(3):313–320.
  57. Greenlee HB, Prinz RA, Aranha GV. Long-term results of side-to-side pancreaticojejunostomy. *World J Surg*. 1990;14(1):70–76.
  58. Muller MW, Friess H, Martin DJ, Hinz U, Dahmen R, Buchler MW. Long-term follow-up of a randomized clinical trial comparing Beger with pylorus-preserving Whipple procedure for chronic pancreatitis. *Br J Surg*. 2008;95(3):350–356.
  59. Koninger J, Seiler CM, Sauerland S, et al. Duodenum-preserving pancreatic head resection—a randomized controlled trial comparing the original Beger procedure with the Berne modification (ISRCTN No. 50638764). *Surgery*. 2008;143(4):490–498.
  60. Frey CF, Mayer KL. Comparison of local resection of the head of the pancreas combined with longitudinal pancreaticojejunostomy (Frey procedure) and duodenum-preserving resection of the pancreatic head (Beger procedure). *World J Surg*. 2003;27(11):1217–1230.
  61. Bachmann K, Mann O, Izbicki JR, Strate T. Chronic pancreatitis—a surgeon's view. *Med Sci Monit*. 2008;14(11):RA198–205.
  62. Varghese TK, Bell RH, Jr. Duodenum-preserving head resection for chronic pancreatitis: an institutional experience and national survey of usage. [erratum appears in *Surgery*. 2008 Feb;143(2):301]. *Surgery*. 2007;142(4):588–593; discussion 93 e1–3.
  63. Beger HG, Krautzberger W, Bittner R, Buchler M, Limmer J. Duodenum-preserving resection of the head of the pancreas in patients with severe chronic pancreatitis. *Surgery*. 1985;97(4):467–473.
  64. Ozawa F, Friess H, Kondo Y, Shrikhande SV, Buchler MW. Duodenum-preserving pancreatic head resection (DPPHR) in chronic pancreatitis: its rationale and results. *J Hepatobiliary Pancreat Surg*. 2000;7(5):456–465.
  65. Buchler MW, Friess H, Muller MW, Wheatley AM, Beger HG. Randomized trial of duodenum-preserving pancreatic head resection versus pylorus-preserving Whipple in chronic pancreatitis. *Am J Surg*. 1995;169(1):65–69; discussion 9–70.
  66. Ho HS, Frey CF. The Frey procedure: local resection of pancreatic head combined with lateral pancreaticojejunostomy. *Arch Surg*. 2001;136(12):1353–1358.
  67. Strate T, Taherpour Z, Bloechle C, et al. Long-term follow-up of a randomized trial comparing the Beger and Frey procedures for patients suffering from chronic pancreatitis. *Ann Surg*. 2005;241(4):591–598.
  68. Strate T, Bachmann K, Busch P, et al. Resection vs drainage in treatment of chronic pancreatitis: long-term results of a randomized trial.[see comment]. *Gastroenterology*. 2008;134(5):1406–1411.
  69. Izbicki JR, Bloechle C, Broering DC, Kuechler T, Broelsch CE. Longitudinal V-shaped excision of the ventral pancreas for small duct disease in severe chronic pancreatitis: prospective evaluation of a new surgical procedure. *Ann Surg*. 1998;227(2):213–219. PMID: 1191238.
  70. Ahmed SA, Wray C, Rilo HL, et al. Chronic pancreatitis: recent advances and ongoing challenges. *Curr Probl Surg*. 2006;43(3):127–238.
  71. Blondet JJ, Carlson AM, Kobayashi T, et al. The role of total pancreatectomy and islet autotransplantation for chronic pancreatitis. *Surg Clin North Am*. 2007;87(6):1477–1501.
  72. Ahmad SA, Lowy AM, Wray CJ, et al. Factors associated with insulin and narcotic independence after islet autotransplantation in patients with severe chronic pancreatitis. *J Am Coll Surg*. 2005;201(5):680–687.

*This page intentionally left blank*



# PERSPECTIVE ON MANAGEMENT OF PATIENTS WITH SEVERE ACUTE PANCREATITIS

Timothy R. Donahue • Howard A. Reber

## INTRODUCTION

In the foregoing chapters, the authors have comprehensively reviewed the pathophysiology of patients with severe acute pancreatitis and the different approaches to the diagnosis and management of the disease. The reviews are extensive, particularly in regard to various medical and surgical interventional techniques. In an effort to simplify the management of these complex patients, we present here our own high-yield approach using the experience gathered over a 25-year period at a single center. This management strategy has resulted in excellent results with morbidity and mortality rates amongst the lowest reported.<sup>1</sup>

## PRESENTATION AND INITIAL ASSESSMENT

There is general agreement that patients with severe acute pancreatitis should be referred *early* in the course of their disease to a tertiary high-volume medical center where an experienced multidisciplinary team can provide coordinated care. In practice, however, the referral is often delayed for several weeks or more while the patient continues to deteriorate or the physicians in charge are frustrated because there is no improvement in the patient's condition. There may be a question as to whether surgery is indicated. Thus, the patients we see are often at least several weeks into their illness, and may have failure of one or more organ systems when they arrive at our center. Some may require ventilatory support; some have developed renal failure. They usually have been placed on antibiotics and may have one or more abdominal drains that were inserted by an interventional radiologist at the referring institution. Their management is outlined in the subsequent discussion (Fig. 57-1).

## First 24–48 hours

Upon admission, patients are placed in the intensive care unit (ICU). Appropriate intravenous (IV) fluid resuscitation is continued and central monitoring is established. After the medical records from the referring hospital are reviewed, consults from indicated disciplines (eg, cardiology, pulmonary, nephrology, gastroenterology, etc) are requested. The outside imaging is assessed with the radiologists. At this point, we usually repeat the abdominal imaging to provide up-to-date information about the patient's condition.

At that time, the pancreatic parenchyma and surrounding tissues are evaluated for evidence of inflammation, necrosis, fluid collections, and/or infection. These findings are best displayed by a high-resolution pancreatic protocol CT scan. The pancreatic protocol calls for a precisely timed IV contrast infusion to enhance the pancreatic parenchyma, and surrounding tissue and vessels. Following the injection of the contrast, successive 2- to 3-mm images of the pancreas are obtained during the "pancreatic arterial phase" followed by 5-mm images during the "venous phase." Oral contrast is not administered. During the pancreatic phase the pancreatic parenchyma and the distribution of the celiac axis and superior mesenteric arteries are enhanced with contrast; the venous phase demonstrates the areas drained or supplied by the superior mesenteric, portal, and splenic veins. The parts of the pancreatic parenchyma that do not enhance with IV contrast during the pancreatic arterial phase are presumed to be necrotic. Furthermore, infection is highly suspected if there are gas bubbles present, so long as the pancreas and peripancreatic tissues have not been instrumented recently (eg, percutaneous drain, etc). The gas is produced by bacterial growth and fermentation. The presence of a significant amount of pancreatic necrosis and/or infection raises the general level of concern

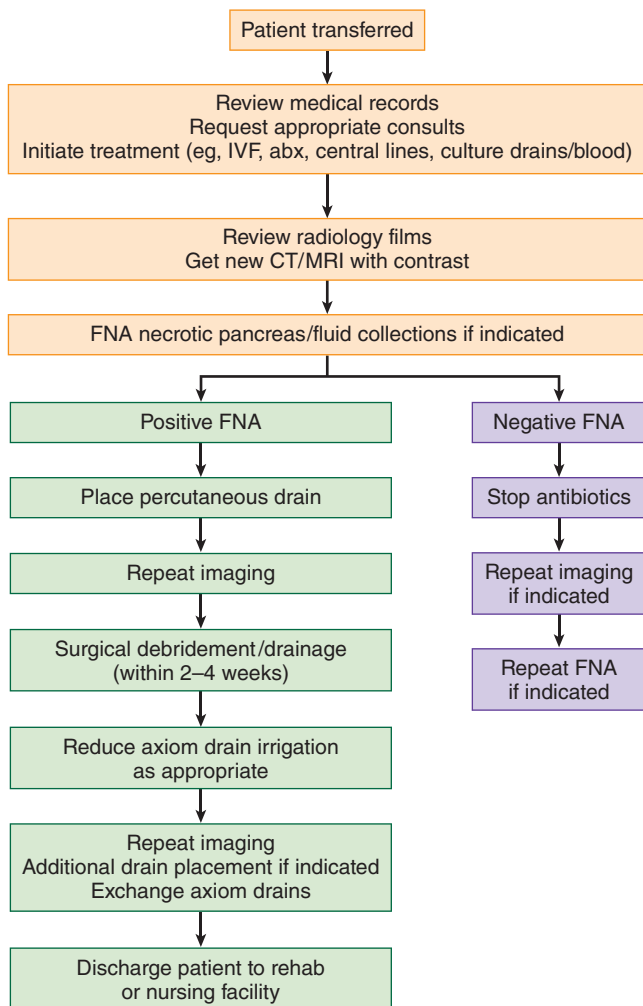


FIGURE 57-1 An overview of the management of patients with severe acute pancreatitis.

about the severity of the patient's course and influences future management decisions. If patients have an iodinated contrast allergy, a magnetic resonance imaging (MRI) or magnetic resonance cholangiopancreatography (MRCP) with precisely timed IV gadolinium contrast to reveal the pancreas and surrounding tissues is also satisfactory.

The large amount of cytokines often released in patients with severe acute pancreatitis may result in leaky capillaries and fluid extravasation to the interstitium. Thus, many of them have a depleted intravascular space, and a component of prerenal insufficiency. However, we still perform an IV contrast computed tomography (CT) scan as long as the serum creatinine is less than 1.5 mg/dL. All patients are kept well hydrated to minimize the chance of contrast-induced nephropathy. *N*-acetylcysteine (Mucomyst) is also administered as an adjunct. If the degree of renal failure is more severe, an MRI with IV gadolinium is done instead. However, if the patient's glomerular filtration rate (GFR) is lower than 30 mL/min/1.73 m<sup>2</sup>, neither iodinated nor gadolinium contrast can be administered. Gadolinium can cause toxic skin

necrosis in patients with severe renal failure. Then, we would perform a high-resolution CT scan without any contrast. Of course this limits the ability to detect necrosis of the pancreatic parenchyma as well as peripancreatic inflammation.

We try to avoid prophylactic antibiotics, since they can lead to bacterial resistance and fungal superinfection, and also can confound the results of a fine-needle aspiration (FNA). In patients who arrive with a percutaneous drain in place and are already on antibiotics, we will continue the drugs but may change them based on the culture results (blood, abdominal fluid, FNA) from the referring institution as well as new cultures drawn on arrival. If there is no evidence of infection on high-resolution imaging and/or FNA, then the antibiotics are stopped. We limit the use of antifungals to patients with culture-proven fungal infections and/or unexplained elevations in their white blood cell count despite being on an effectively tailored antibiotic regimen.

After the patient is adequately resuscitated and stabilized, and all pertinent tests have been reviewed, an FNA of the pancreatic parenchyma and/or fluid collections is performed for almost all patients. All transferred patients with percutaneous drains in place undergo a fresh FNA. An FNA is also performed on those patients who have suspicious features on imaging (eg, nonenhancing pancreas), and have clinical signs of infection (eg, fever, elevated white blood cell count). At the time of FNA, in patients without a drain in place, we specifically ask the radiologist to *not* leave a percutaneous drain following the aspiration. Such a drain often infects a sterile fluid collection and/or necrosis. The FNA fluid should be sent for a Gram stain, anaerobic and aerobic bacterial culture, and a fungal culture. If the Gram stain and/or culture results suggest infected pancreatic necrosis or fluid collections, then percutaneous drains are placed where appropriate. Patients who have clear evidence of infection on high-resolution imaging as previously discussed (eg, gas bubbles) have a percutaneous drain placed during the first procedure within the day 1 or 2 of hospitalization. The drain fluid is cultured.

The percutaneous drain definitively addresses the infection only rarely (see later). Rather, its primary roles are to delay the timing of surgery until the patient's overall condition has improved, and/or to provide a landmark, a route to follow, for laparoscopic drainage. The patient's sepsis may improve dramatically with adequate percutaneous drainage. Also, additional time allows for the necrosis and fluid collections to organize and become better defined, minimizing the debridement and drainage that will be required later. In patients who are transferred with percutaneous drains in place, we often change the drains to larger ones (eg, 28–30F diameter red rubber catheters), as the pigtail drains that are usually in place are often too small for effective drainage. We also may ask the interventional radiologist to percutaneously drain other areas that were not adequately addressed.

Sometime during the first week or so of management, a detailed discussion should be held with the patient and family about the seriousness of the problem, the potential for recovery, and the likely long course of hospitalization and rehabilitation (1 year or more in some cases). Some patients

have become severely depressed and required psychiatric treatment as part of the overall treatment program. They need to know early on what is in store.

## DEFINITIVE DRAINAGE

### Who and When?

Despite the percutaneous drainage techniques previously discussed, most patients with infected pancreatic necrosis eventually benefit from definitive surgical drainage during their hospital course. This includes patients who have infected pancreatic necrosis and/or fluid collections that initially responded to drain placement, but whose septic course continues. Surgery is usually performed 2–4 weeks after transfer to our center. Definitive surgery should not be delayed for weeks or more hoping that an operation can be avoided in this group of patients. A minority of patients with radiographic or culture evidence of infection and clinical sepsis who are not responding to percutaneous drainage and resuscitative measures, may need to be taken to surgery sooner, however.

Although they are not critically ill, another group of patients who eventually requires surgery are those who present a few weeks to months after their episode of acute pancreatitis and fail to improve. On CT scan they may have evidence of sterile walled-off pancreatic necrosis. These patients often present with obstructive symptoms (eg, inability to tolerate oral intake) or generalized abdominal pain. Some physicians prefer that these patients (with fluid collections, no infection, ongoing symptoms) be managed by percutaneous or endoscopic-guided drainage without surgery. If the fluid is clear and without particulate matter, this may be effective. However, patients with debris within the fluid should generally not be managed with endoscopic or percutaneous drainage techniques. The particulate matter clogs the drain(s), infection supervenes, and the overall condition deteriorates. Despite the lack of an infection, open surgical debridement and drainage is preferred in this group.

### How?

We have experience with closed laparoscopic and open trans-abdominal techniques, and prefer the latter for most patients. The general principles of both techniques are the same and include (1) complete drainage of fluid and debridement of infected or necrotic pancreatic and peripancreatic debris, and (2) placement of large-bore Silastic sump drains with closed continuous postoperative lavage.

For the open approach, a midline or bilateral subcostal incision is used. The midline incision is usually reserved for thin patients and/or those who have peripancreatic fluid collections that may extend to the lower abdomen. This incision is associated with less postoperative pain than a subcostal incision. However, the subcostal approach allows better exposure to the

lateral aspects of the lesser sac. The posterior and anterior fascial layers are reapproximated separately with running or interrupted 0 or #1 polydioxanone (PDS) absorbable sutures, which makes a hernia unlikely. With either incision, the skin edges are loosely approximated with staples and Kerlix Packing is tucked between them to reduce the chance of a wound infection.

After entering the peritoneal cavity, the lesser sac is entered either through the gastrocolic ligament or the transverse mesocolon. If the ligament is fused to the inflammatory mass behind it then the transverse colon is elevated and the location of the mass is identified through the tented mesentery. The site for entry through the mesentery can be identified by aspiration via a 16- or 18-gauge needle, or the space can be entered directly with electrocautery if it is otherwise apparent. The mesocolon is opened widely with an effort to avoid injury to the colon and vessels. After a window is created and the cavity is entered, the infected pancreatic necrosis is debrided with ringed forceps. If significant bleeding is encountered, it means that particular area is still viable and does not need additional debridement. Oozing in one area should be packed while another area is debrided. Once the oozing stops, that area is addressed again. Occasional suture ligatures may be needed to stop brisk arterial or venous bleeding. Bleeding is usually not a significant problem if one debrides only the necrotic material; many of the vessels are thrombosed. We use monofilament (eg, Prolene) sutures rather than silk which can serve as a nidus for infection. Copious irrigation helps to clean out the debris from the cavity. All of the areas of infected necrotic pancreas and peripancreatic tissues should be debrided. The radiographic images should be available in the operating room to be certain that this is accomplished.

After the debridement is complete, we place one or more closed suction continuous irrigation drains (Axiom) into the areas that have been debrided. An effort should be made to place the drains so they do not lie on top of the colon, to avoid erosion into the bowel lumen. Approaching the lesser sac through the transverse mesocolon rather than the gastrocolic ligament facilitates this. Axiom drains contain three separate lumens. The largest lumen in the middle is hooked to low continuous wall suction. The two smaller lumens on the sides are used for (1) continuous irrigation with saline and (2) left open to air as a sump. We do not close the gastrocolic ligament and/or transverse mesocolon around the drains, which has been suggested by others in an effort to contain the infection within the lesser sac.

If a laparoscopic drainage is planned, we place a percutaneous drain prior to surgery. The drain can then be followed into the lesser sac to the fluid collection and necrotic pancreas. Debridement of infected necrotic pancreas can be performed with platypus-like instruments. The axiom drains are placed using the same technique as previously discussed with the open approach, and they are brought out through anterior abdominal wall via the trocar sites.

If a diagnosis of gallstone pancreatitis has been made, we also prefer to remove the gallbladder at the initial operation, if it can be done safely. This decision is made by inspecting



the porta hepatis for inflammation. Some bleeding is usually encountered in the gallbladder fossa of the liver, and this is controlled with Argon beam coagulation. The surgical approach that is selected (eg, laparoscopic vs open) does not influence our decision to remove the gallbladder.

This strategy is associated with excellent morbidity and mortality rates that are consistent with some of the best series that have been reported.<sup>1</sup> The overall 30-day perioperative mortality is less than 10% and is due to recurrent sepsis with multidrug-resistant bacteria and/or other existing comorbidities in most cases. Furthermore, the reoperation rate is less than 5%. Recurrent fluid collections occur in 25–30% of the patients, but these can almost always be managed by percutaneous drainage placed by the interventional radiologist. Almost all patients are discharged from the hospital to rehabilitation or skilled nursing facilities for an additional period of recovery.

## Postoperative Management

All patients should be placed into the ICU even if they did not require intensive care preoperatively because many of them experience a transient period of bacteremia and sepsis as a result of the operation. As previously discussed, these patients require aggressive fluid resuscitation and adequate central monitoring (eg, central venous catheter, etc).

Each Axiom drain should be irrigated at 100 mL/h continuously with 0.9 normal saline, and the suction port aspirated with the vacuum set at low continuous suction. This irrigation rate is continued for at least 24 hours, and until the effluent becomes less particulate, the white blood cell count normalizes and the patient's septic physiology resolves. The rate of irrigation is then cut in half until the drains are left to gravity (eg, 100, 50, 25). This process usually takes 1–2 weeks to complete. During this time, we usually get a contrast-enhanced CT scan on a weekly basis or as it is clinically indicated (eg, rising white blood cell count, etc). After the drains are put to gravity, they are exchanged in radiology after at least 2 weeks from the time they were placed at operation, for large-bore red rubber catheters (28–30F diameter). Once continuous irrigation of the drains is stopped, the drains should still be irrigated 3–4 times per day with 20–30 mL of sterile saline to maintain their patency. The effluent drains into a plastic bag.

In parallel, we enterically feed these patients as early as possible. This usually occurs by the end of the first postoperative week, once bowel function has returned. They are most often nutritionally depleted due to their acute episode with less than 10 mg/dL serum prealbumin levels. They are often on total parenteral nutrition prior to surgery, and this should

be continued until they are nutritionally replete (albumin >3 mg/dL) which is often at the time of discharge or later.

We do not routinely place feeding tubes (eg, gastrostomy or jejunostomy) at the time of surgical debridement. Rather, a nasogastric tube is placed with its position confirmed in the body of the stomach. If necessary, a Dobhoff tube is also placed postoperatively. We have found that transnasal feeding tubes are sufficient. Surgical tubes have a number of potential risks that should be avoided. They can leak, and jejunostomy tubes can cause a bowel obstruction, particularly if the balloon is overinflated. Furthermore, the peritoneal irrigation that is continued for the first few postoperative weeks can leak around the feeding tube site, complicating management. In addition, many patients can eat on their own within a few days of the surgery.

After discharge, we see these patients in the office every 1–2 weeks until their stability is assured. In patients who still have drains in place, daily irrigations are continued. If there is no evidence of a pancreatic fistula, the drains are withdrawn several inches at each office visit, through the tracks that have developed. Over 4–6 weeks, the drains have usually been removed. If a pancreatic fistula is present, the drain must be left in place until the fistula closes or the patient is operated upon to close the fistula. Operative fistula repair in most of these patients should not be done for a minimum of 9–12 months after the surgical debridement.

## CONCLUSION

Patients with acute necrotizing pancreatitis are often difficult to manage, both in the acute setting and after discharge from the hospital. They are often hospitalized for a long time (months), are in the intensive care unit, and require multiple interventional procedures. There are many points in their care where important management decisions need to be made. During this process, it is important for the clinician to remember that most of these patients will in fact completely recover and will have an excellent quality of life after the episode resolves.<sup>2,3</sup> The patient and family also need to be continually reminded and reassured.

## REFERENCES

1. Fernandez-del Castillo C, Rattner DW, Makary MA, et al. Debridement and closed packing for the treatment of necrotizing pancreatitis. *Ann Surg.* 1998;228(5):676–684.
2. Broome AH, Eisen GM, Harland RC, et al. Quality of life after treatment for pancreatitis. *Ann Surg.* 1996;223(6):665–670; discussion 670–672.
3. Kriwanek S, Armbruster C, Dittich K, et al. Long-term outcome after open treatment of severe intra-abdominal infection and pancreatic necrosis. *Arch Surg.* 1998;133(2):140–144.

# CYSTIC NEOPLASMS OF THE PANCREAS

Warren R. Maley • Charles J. Yeo

## INTRODUCTION

Cystic neoplasms of the pancreas and other cystic lesions, many of which cause “cyst-like” dilatations of the main or branch pancreatic ducts are collectively referred to as cystic lesions of the pancreas on cross-sectional imaging of the abdomen. The incidence of these cystic lesions increases with age. One autopsy study has demonstrated that up to a quarter of elderly individuals harbor cystic lesions of the pancreas at their demise.<sup>1</sup> With the ever increasing use of computed tomography (CT) and magnetic resonance imaging (MRI), cystic lesions of the pancreas are being defined with progressively greater frequency, and an ever increasing number are asymptomatic at discovery.<sup>2,3</sup> Some of these lesions will be malignant or have malignant potential at diagnosis, while others are clearly benign and may not warrant further surveillance. Resection of benign cystic pancreas lesions or those containing only carcinoma in situ leads to nearly universal survival, while surgery for invasive carcinoma associated with cystic neoplasms generally has a more favorable prognosis than the results for pancreatic ductal adenocarcinoma.<sup>4,5</sup> Thus careful consideration must be given to the diagnosis and prognostic implications of these lesions.

An ideal diagnostic approach would allow for the resection of only those lesions with present or near-future risk of malignancy, while excluding from surgery those individuals with either benign lesions or a prohibitive operative risk, thus minimizing the potential occurrence of mortality and morbidity associated with the surgical treatment of these cystic lesions. Recent advancements in imaging by CT, MRI, and endoscopic ultrasonography (EUS), linked with refinements in the pathological understanding of cystic neoplasms of the pancreas have furthered this effort. History and clinical criteria, such as age, gender, presence of symptoms, location of the neoplasm within the pancreas, as well as, morphology by cross-sectional imaging and cyst fluid analysis by EUS with fine-needle aspiration (EUS-FNA), all may play a role in the diagnosis of pancreatic cystic neoplasms and assessment of the need for resection. A recent

analysis using decision analysis with Markov modeling has indicated that for patients focused on overall survival, regardless of quality of life, surgery is optimal for branch duct lesions greater than 2 cm in size.<sup>6</sup> For patients more focused on quality-adjusted survival, a 3-cm threshold is more appropriate for surgical intervention, except for the very elderly patients.

Pancreatic pseudocysts (or early postpancreatitis acute fluid collections) have been considered as the most common non-neoplastic cysts of the pancreas. Their diagnosis is aided by a history of acute or chronic pancreatitis.<sup>7</sup> Congenital cysts are rare and include those associated with genetic diseases such as autosomal dominant polycystic disease,<sup>8</sup> cystic fibrosis,<sup>9</sup> and von Hippel-Lindau (VHL) disease.<sup>10,11</sup> Lymphoepithelial cysts are rare benign lesions of the pancreas lined with squamous epithelium.<sup>12</sup>

Three cystic lesions make up 90% of the cystic neoplasms seen in the pancreas: serous cystic neoplasms (SCNs), mucinous cystic neoplasms (MCNs), and intraductal papillary mucinous neoplasms (IPMNs). SCNs rarely demonstrate a progression to malignancy. Unequivocal definition of an SCN may permit nonoperative management of these lesions, provided symptoms do not mandate resection. Mucin-producing lesions of the pancreas can be segregated into two types which may differ significantly in natural history. Restriction of the definition of MCNs, to include only those lesions with subendothelial ovarian-type stroma, has permitted an improved distinction between MCN and IPMN.<sup>13</sup> Recent consensus guidelines developed by the International Association of Pancreatology<sup>14</sup> may assist in the management of cystic neoplasms of the pancreas. The premalignant nature of MCN prompts resection in patients who are acceptable operative risks, while observation of some branch duct IPMNs, may be tenable with an eventual risk of malignancy less than the operative mortality of pancreatic resection.<sup>6</sup> Finally, solid pseudopapillary neoplasms (which may have cystic components) are rare lesions occurring predominantly in young women, for which, resection of the primary tumor results in an excellent opportunity for cure.

## PATHOLOGICAL CLASSIFICATION

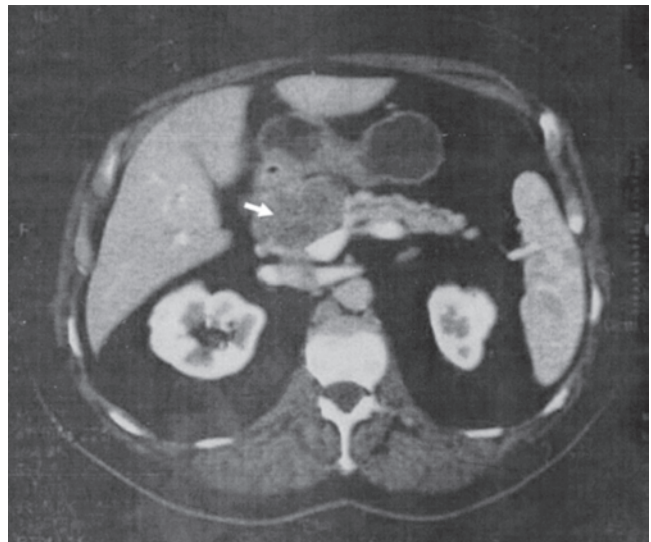
The accurate pathological description of pancreatic cystic neoplasms has evolved significantly in the past two decades, influenced largely by an improved understanding of the malignant potential of MCNs, in comparison to the largely benign SCNs, and the emergence of an understanding of the pathogenesis and behavior of IPMNs. Current classification of these tumors follows the World Health Organization (WHO) International Classification of Tumors as published in 2000 (Table 58-1).<sup>15</sup> While the diagnostic criteria and organizational schema for these tumors are likely to be adapted further in future editions, the current classification system provides a means to stratify these tumors in terms of prognosis and management. In this review, particular attention will be paid to the three most common lesions: SCNs, MCNs, and IPMNs.

## SEROUS CYSTIC NEOPLASMS

SCNs, previously referred to either as serous cystadenomas, glycogen-rich adenomas, or microcystic adenomas, are almost always benign. Careful delineation of the radiological and clinical features that distinguish these lesions may support and facilitate nonoperative management (ie, observation) of these lesions.

## Pathological Features

The majority of SCNs are polycystic or so-called microcystic adenomas, characterized by a well-circumscribed, soft mass which includes numerous small cysts filled with clear serous fluid arranged in a characteristic honeycomb-like



**FIGURE 58-1** This CT image depicts a cystic neoplasm in the head and neck of the pancreas (*small arrow*) detected incidentally in a 75-year-old man undergoing evaluation for nephrolithiasis. The patient underwent a pylorus-preserving pancreaticoduodenectomy without complications. Final pathology revealed a 6-cm serous cystic neoplasm without evidence of malignancy.

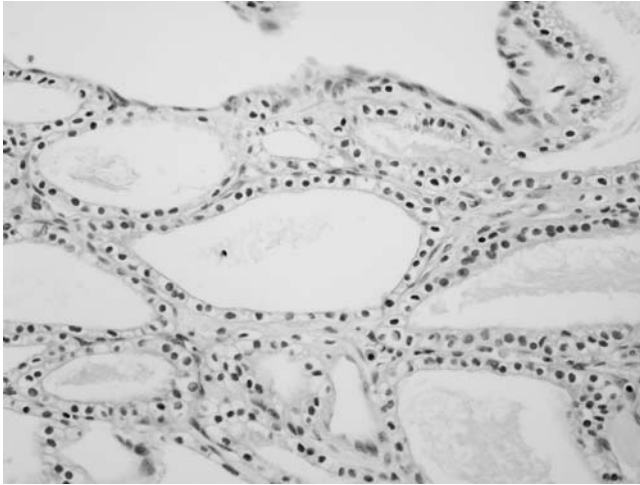
pattern. Larger cysts may line the periphery of the lesion. The multiple small cystic loculations are well defined and often focus on a central stellate scar with or without calcifications. These features may be highly suggestive of an SCN when seen on CT or magnetic resonance imaging (MRI) (Fig. 58-1). A small number of SCNs ( $\leq 10\%$ ) are oligocystic adenomas, and present with one or more dominant cysts, rather than multiple conjoined microcysts. These unusual SCN lesions may be more difficult to distinguish radiographically from MCNs, IPMNs, pseudocysts, and other cystic lesions.

Beyond these gross distinctions, both microcystic and oligocystic adenomas are composed of a single layer of simple cuboidal epithelium with rounded nuclei and clear cytoplasm which is glycogen rich and stains periodic acid-Schiff-positive (Fig. 58-2). The cystic fluid is serous and typically has no mucin content, with a low carcinoembryonic antigen (CEA) level ( $< 5$  ng/mL), factors that may provide diagnostic information upon cyst aspiration. Cytology diagnostic for SCN is present in less than 50% of cases; however, when positive the sensitivity is high.

The malignant potential of SCN is so low that most experienced centers recommend management of these lesions as benign entities. Certainly the argument can be made that a clearly documented classic-appearing SCN need not be resected, unless symptomatic or enlarging. The incidence of serous cystadenocarcinoma is extremely low, as fewer than 25 cases have been definitively documented in the literature.<sup>16</sup> In the largest single institution experience to date, Galanis and colleagues from Johns Hopkins reported on 158 patients with SCN, only one of whom had serous

**TABLE 58-1: PATHOLOGICAL CLASSIFICATION OF CYSTIC NEOPLASMS OF THE PANCREAS: THE WHO INTERNATIONAL CLASSIFICATION OF TUMORS, 2000**

Serous cystic neoplasm (SCN)
Microcystic adenoma
Oligocystic adenoma
Mucinous cystic neoplasm (MCN)
Mucinous cystadenoma
Mucinous cystic tumor–borderline
Mucinous cystadenocarcinoma
Noninvasive (carcinoma in situ)
Invasive
Intraductal papillary mucinous neoplasm (IPMN)
Adenoma/low-grade dysplasia
Borderline/moderate-grade dysplasia
Carcinoma in situ
Invasive carcinoma



**FIGURE 58-2** Photomicrograph of a typical SCN of the pancreas. Characteristic features include the single layer of cuboidal epithelial cells lining the microcysts within the lesion, uniform round nuclear architecture, and clear cytoplasm. The cyst cavities contain serous fluid and little cellular debris.

cystadenocarcinoma on presentation, while another patient, who had a “locally aggressive neoplasm,” returned 13 years postresection with metastatic disease.<sup>17</sup> Thus, two cases of aggressive tumor were observed, out of 158 resected SCNs. Evidence of distant metastatic disease is typically necessary to confirm the rare diagnosis of serous cystadenocarcinoma, as both the primary and extrapancreatic disease may appear histologically indistinguishable from benign SCN.<sup>18</sup> Vascular and perineural invasion, or local invasion of the stomach and duodenum, are not sufficient criteria for the diagnosis of malignancy of SCN.<sup>17,19</sup>

## Clinical Presentation

SCNs occur predominately in women in the sixth decade of life, while men tend to present at a later age. Bassi and colleagues described 100 patients with SCN, 87 of whom were female, with a mean age at presentation of 52 years.<sup>20</sup> The average age of the 13 male patients was 54 years. In another study from the Massachusetts General Hospital, 75% patients were women, and the female patients were significantly younger at presentation than were the men (60 vs 67 years,  $p = .018$ ).<sup>21</sup> In the Galanis study from Johns Hopkins a similar number of patients were women (75%), though no age difference was noted between the genders.<sup>17</sup>

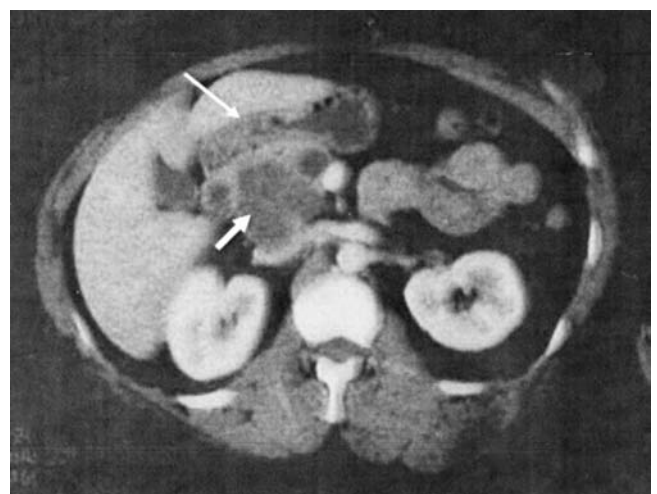
In 25–75% of the patients with SCN, abdominal pain is the presenting complaint.<sup>17,20,21</sup> Weight loss is seen in 14–22%,<sup>17,20</sup> and fewer patients (10%)<sup>20</sup> present with a mass or fullness. Symptoms typically associated with invasive disease, such as jaundice (6%) or pancreatitis, are uncommon.<sup>17</sup> Nausea and vomiting related to compression of the upper gastrointestinal tract may occur in 7–10% of patients.<sup>20</sup>

Traditionally, SCNs have been described as having a predilection for the pancreatic body and tail, though Le Borgne and coworkers described a relatively even distribution throughout the gland in 170 lesions (38% head, 41% body, 20% tail).<sup>22</sup> Large SCNs located in the head are surprisingly unlikely to cause biliary or duodenal obstruction, reflecting their slow pattern of growth, soft texture, and lack of invasive behavior. Rarely, extremely large tumors have been seen in elderly patients, with considerable symptoms of abdominal fullness, and occasionally gastroduodenal obstruction or jaundice.

One clinical condition that has been clearly associated with SCNs of the pancreas is the von Hippel–Lindau (VHL) syndrome. Simple pancreatic cysts or SCNs occur in 17–56% of patients with this heritable multisystem neoplastic syndrome.<sup>23</sup> The VHL tumor suppressor gene is located on chromosome 3p25. Vortmeyer et al demonstrated deletion of 3p25 in 7 of 10 sporadic SCN cases studied, suggesting a role for the VHL gene in SCN tumorigenesis, even in the absence of the VHL syndrome.<sup>24</sup>

## Diagnosis

As mentioned earlier, SCNs often have a characteristic imaging phenotype (see Figs. 58-1 and 58-3). Most are well-demarcated solitary multicystic masses composed of innumerable small cysts. Up to one-third have a central, calcified starburst scar.<sup>22,25</sup> SCN may also present as oligocystic or unilocular cystic lesions, making differentiation from other cystic lesions of the pancreas difficult. Lee and colleagues reported on the preoperative diagnostic accuracy of CT in pathologically confirmed SCN.<sup>26</sup> Radiological features



**FIGURE 58-3** Abdominal CT of a 47-year-old woman who presented with abdominal pain and was found to have a cystic lesion in the head of the pancreas (*wide short arrow*). This mass closely abutted the proximal duodenum and pylorus (*narrow long arrow*), necessitating a classic pancreaticoduodenectomy for complete resection. Final pathology revealed a benign serous cystic neoplasm.



led to a correct diagnosis in only 36% of unilocular SCNs, while honeycombed microcystic and multilocular macrocystic SCNs were appropriately defined in 81 and 88%, respectively ( $p = .005$ ). Overall in their series, CT diagnosis was accurate in 71% of SCN lesions. In 164 patients with surgically verified pancreatic cystic lesions, 28 of whom had SCN, Shah et al suggested that the CT features predictive of the diagnosis of SCN are microcystic appearance (22/28, 78%), surface lobulations (25/28, 89%), and central scar (9/28, 32%).<sup>27</sup> Stepwise logistic regression analysis showed that only a microcystic appearance was predictive for the CT diagnosis of SCN ( $p = .0001$ ). MRI correctly predicted the pathological diagnosis of SCN with greater frequency than did CT in the study by Bassi and coworkers.<sup>20</sup> CT allowed for the correct diagnosis in 54%, incorrect diagnosis in 34%, and was nondiagnostic in 12%. The results with MRI were 74, 26 and 0%, respectively.

The limitations of the radiological diagnosis of SCN may call for additional analysis, which is frequently sought by EUS-FNA with cyst fluid cytology and biochemical study. The risk of complications with EUS-FNA is relatively low, with significant bleed occurring in less than 1% of studies, though intracystic hemorrhage may be as high as 6%.<sup>28</sup> The risk of cyst bacterial inoculation with subsequent infection is less than 1%<sup>29</sup> and the rate of pancreatitis is 1–2%.<sup>30</sup> Cyst fluid aspirates from SCN are frequently sparsely cellular and may be contaminated with columnar enterocytes and mucin from the scope and needle traversing the gastric or bowel mucosa, potentially clouding the diagnostic accuracy of cytology. Cytology alone was found to be diagnostic of SCN in only 7 of 21 cases studied by Huang and others from M. D. Anderson.<sup>31</sup> Detection of intracytoplasmic glycogen was noted to enhance the diagnostic confidence for the diagnosis of SCN. A recent 10-year review of 317 patients evaluated by EUS for pancreatic cysts by Pausawadi and colleagues revealed that those followed for asymptomatic incidental cysts less than 3 cm in size almost uniformly had stable disease over a relatively short mean follow-up of 28 months.<sup>32</sup> While these results are confirmed by other EUS studies, others prefer serial imaging (typically MRI to avoid radiation exposure) over EUS surveillance.

Cyst fluid analysis is an additional adjunct (beyond cytology) to improve the diagnostic accuracy of EUS-FNA. Fluid from within an SCN is typically low in viscosity and amylase, due to a consistent lack of connection to the pancreatic ductal system.<sup>33</sup> CEA levels less than 5 ng/mL have a sensitivity of 54–100%, and specificity of 77–86% in the differentiation of SCN from other pancreatic cystic lesions.<sup>34,35</sup> The finding of a cyst fluid carbohydrate antigen (CA) 19-9 level less than 37 U/L and a CEA less than 5 ng/mL virtually excludes an MCN or IPMN.

Allen et al recently reported on the analysis of cyst fluid using a biomarker panel developed for pancreatic cancer.<sup>35</sup> Assessment of protein expression within the cyst fluid led to an error in classification of lesions of 27%, when all three types of cystic neoplasms were evaluated (SCN, MCN, and IPMN). When limiting the analysis to separating SCN from IPMN, this method had an error rate of only 8%, compared with a

14% error rate for use of CEA levels alone. The greatest utility of protein expression analysis might be in the differentiation of cystic lesions of the head of the pancreas, as the vast majority of MCN occur in the body and tail of the pancreas. However, the cost of this method may not be justified by the relatively small improvement in diagnostic accuracy. When cross-sectional imaging is sufficiently compelling, EUS alone is often unnecessary, but EUS-FNA may further clarify the diagnosis, particularly with oligocystic and unilocular SCNs.

## Treatment

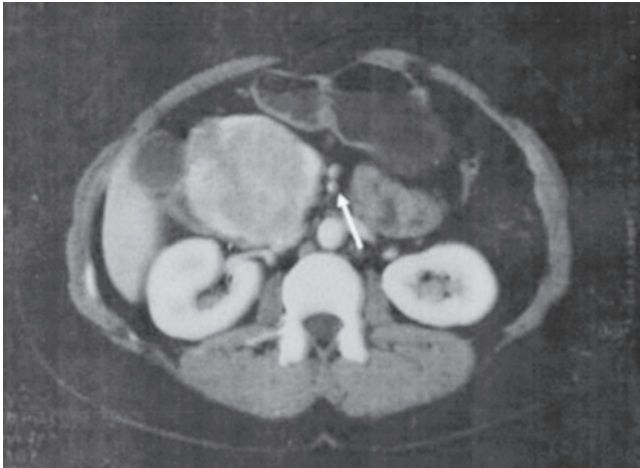
Observation of patients with SCN may be appropriate in asymptomatic patients. When a secure diagnosis of SCN is made, modern series demonstrate that a growing number of SCN are being followed by serial imaging (Table 58-2). Typically a pathological diagnosis is not required. Bassi and colleagues followed 32 patients with the diagnosis of SCN for a median time of 69 months, without any observed development of malignancy or significant increase in diameter of the lesion.<sup>20</sup> Rapid rate of growth of a lesion may heighten suspicion for the development of malignancy or increase the likelihood of developing symptoms. In a report from the Massachusetts General Hospital, Tseng and coworkers found a more rapid rate of growth in SCN greater than or equal to 4 cm in size at presentation compared with smaller tumors (1.98 cm/y vs 0.12 cm/y,  $p = .0002$ ).<sup>21</sup> Tumors less than 4 cm were less likely to be symptomatic than were those greater than or equal to 4 cm (22 vs 72%,  $p < .001$ ). Resection was thus suggested by these authors, even for asymptomatic SCNs which were greater than or equal to 4 cm.

When the diagnosis of SCN is uncertain, pancreatic resection is most often performed according to oncological principles, as if the lesion was malignant or had malignant potential (Fig. 58-4). Standard procedures include distal pancreatectomy for lesions of the body or tail, or pancreaticoduodenectomy for right-sided lesions. This practice avoids performance of an inadequate cancer operation in cases in which a malignancy is found on final pathological analysis. However, if the diagnosis of SCN is confirmed either preoperatively or with intraoperative biopsy (which is not routinely performed), a less radical approach may be considered. Enucleation of SCNs has been shown to be technically feasible, although it can be associated with a significant risk of pancreatic fistula.<sup>36,37</sup> A central pancreatectomy, with distal pancreatic reconstruction via pancreaticogastrostomy or Roux-en-Y pancreaticojejunostomy may be considered in selected patients with lesions of the pancreatic neck.<sup>38</sup> Distal pancreatectomy with splenic preservation may also be considered, particularly for small lesions in the tail, where the splenic hilum is more easily dissected. Lesions in the head of the pancreas that are not amenable to enucleation are best treated with pylorus-preserving pancreaticoduodenectomy. In patients who have an otherwise normal pancreas, meticulous attention must be paid to the technique of pancreaticojejunostomy, since

**TABLE 58-2: FEATURES AND TREATMENT OF SCN, MCN, AND IPMN**

Types of Neoplasm	Classic Features	Treatment <sup>a</sup>
Serous cystic neoplasm (SCN)	<ul style="list-style-type: none"> <li>• Women &gt; men</li> <li>• Solitary and polycystic</li> <li>• Single-layer cuboidal epithelium</li> <li>• Cyst fluid CEA and amylase low</li> <li>• Rarely malignant</li> </ul>	<ul style="list-style-type: none"> <li>• If symptomatic—resect</li> <li>• Stable size and asymptomatic—surveillance</li> <li>• Size increase—consider resection</li> </ul>
Mucinous cystic neoplasm (MCN)	<ul style="list-style-type: none"> <li>• Women &gt;&gt; men</li> <li>• Solitary and unilocular</li> <li>• Tall columnar epithelium</li> <li>• Subendothelial ovarian-type stroma</li> <li>• Cyst fluid CEA high and amylase low</li> <li>• Potentially malignant (exhibit spectrum from adenoma to carcinoma)</li> </ul>	<ul style="list-style-type: none"> <li>• If symptomatic—resect</li> <li>• Asymptomatic and size <math>\geq 3</math> cm—resect</li> <li>• Asymptomatic and size <math>&lt; 3</math> cm—surveillance or resection, after patient education</li> </ul>
Intraductal papillary mucinous neoplasm (IPMN)	<ul style="list-style-type: none"> <li>• Gender distribution equal</li> <li>• Older than SCN and MCN</li> <li>• Pancreatitis seen with main duct &gt; branch duct variant</li> <li>• Tall columnar epithelium with variable degrees of dysplasia</li> <li>• Cyst fluid CEA and amylase high</li> <li>• Potentially malignant (exhibit spectrum from adenoma to carcinoma)</li> </ul>	<ul style="list-style-type: none"> <li>• Main duct IPMN—resect, with intraoperative pancreatoscopy and careful inspection of remnant pancreas for synchronous neoplastic lesions</li> <li>• Branch duct IPMN               <ol style="list-style-type: none"> <li>a. Resect, if symptomatic, tumor <math>\geq 3</math> cm, mural nodules, positive cytology, rapid growth, main duct dilatation or young and healthy (age <math>&lt; 55</math> years)</li> <li>b. Observe, if asymptomatic, tumor <math>&lt; 3</math> cm, no mural nodules, negative cytology, stable size, normal main pancreatic duct and advanced age (<math>&gt; 75</math> years)</li> </ol> </li> </ul>

<sup>a</sup>Treatment decisions are not easily tabulated, and must take into consideration patient health status, age at presentation, comorbid conditions, tumor location in the pancreas, and many other factors. We have attempted to briefly summarize our current approach at the Jefferson Pancreas, Biliary and Related Cancer Center.



**FIGURE 58-4** Abdominal CT of a large cystic mass with solid components arising from the head of the pancreas and extending into the root of the mesentery along the mesenteric vessels (*arrow*). The partially solid nature of the tumor raised concern of a malignant pancreatic tumor; however, at exploration the mass was found to be well localized and easily separable from surrounding structures. A pylorus-preserving pancreaticoduodenectomy was performed; final pathology showed a 7-cm serous cystic neoplasm.

such patients have a significantly higher risk for developing a pancreatic fistula. There has been some enthusiasm recently for duodenum-preserving pancreatic head resection as well, although this procedure has not had widespread application.<sup>39</sup> Patients with pathologically proven, completely resected SCN do not require serial imaging in follow-up. Recommendations for appropriate monitoring of unresected SCN vary, but serial imaging with either CT or MRI every 6 months for 2 years, and then annually thereafter seems reasonable.<sup>40</sup>

## MUCINOUS CYSTIC NEOPLASMS

Progress in the diagnosis and management of pancreatic cystic neoplasms has been aided in large part by the recognition of distinct pathological features that distinguish MCNs from other cystic lesions.<sup>41,42</sup> The distinction between MCN and SCN is critical, as the premalignant and malignant behavior of MCNs stand in stark contrast to the nearly universally benign SCNs. Many of the same diagnostic challenges that exist for SCN are true for MCN, but the management decisions may be quite different, due to the differing clinical phenotype of these lesions.

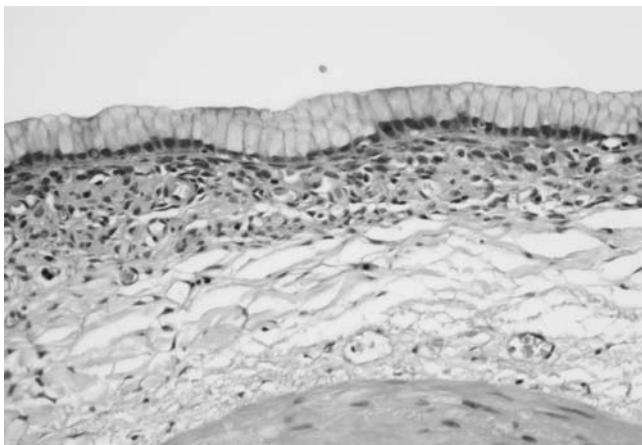
MCNs account for approximately 15–30% of cystic neoplasms of the pancreas, at least as recorded in recent series in which the distinction of these lesions from IPMN has

been clarified.<sup>2,40,43</sup> Clinical series published prior to the establishment of diagnostic criteria for IPMN in 1996 likely overestimated the relative prevalence of MCNs in comparison to other cystic lesions, since they included what are now categorized as IPMNs as various “mucinous tumors.”

## Pathological Features

MCNs are typically spherical, thick-walled, septated or unilocular cysts with a tall columnar mucin-producing epithelium accompanied by a subendothelial ovarian-type stroma that appears as a dense layer of spindle cells with sparse cytoplasm and uniform, elongated nuclei (Figs. 58-5). This stroma regularly expresses progesterone receptors, and less frequently estrogen receptors, and over 60% stain for human chorionic gonadotropin.<sup>44</sup> Both the WHO and the Armed Forces Institute of Pathology (AFIP) have defined the presence of this ovarian-like stroma as a requirement for the diagnosis of an MCN.<sup>41,42</sup> The Sendai consensus guidelines have also required the presence of ovarian-type stroma as a necessary criterion for the diagnosis of MCN, so as to prevent the misclassification of IPMN as MCN.<sup>14</sup> Given the similarity of the histology and immunohistochemistry between MCN and ovarian mucinous cystadenomas, MCNs have been postulated to arise from ovarian rests (or ovarian-like stem cells) within the pancreas.<sup>45</sup>

MCNs exhibit characteristics of an adenoma-carcinoma sequence. Dependent on the degree of atypia, they are classified as mucinous cystadenomas, borderline lesions, in situ lesions or invasive cystadenocarcinoma. Atypical changes within the lining epithelium may be patchy and sparse, with abrupt transitions to normal mucosa. Classification of MCN should be based upon the highest degree of atypia present, and the entire lesion should be examined pathologically.<sup>46,47</sup> Invasive carcinomas arising within MCNs are usually tubular or ductal type, though some may be undifferentiated carcinoma



**FIGURE 58-5** MCNs of the pancreas are distinguished by a uniform columnar epithelium (*top*) associated with a dense underlying ovarian-like stroma (*bottom*).

with osteoclast-like giant cells,<sup>48</sup> adenosquamous carcinoma,<sup>49</sup> choriocarcinoma or even high-grade sarcomas.<sup>50</sup> Colloid carcinomas are extremely rare in MCN, but they occur commonly in IPMN.<sup>47</sup>

## Clinical Presentation

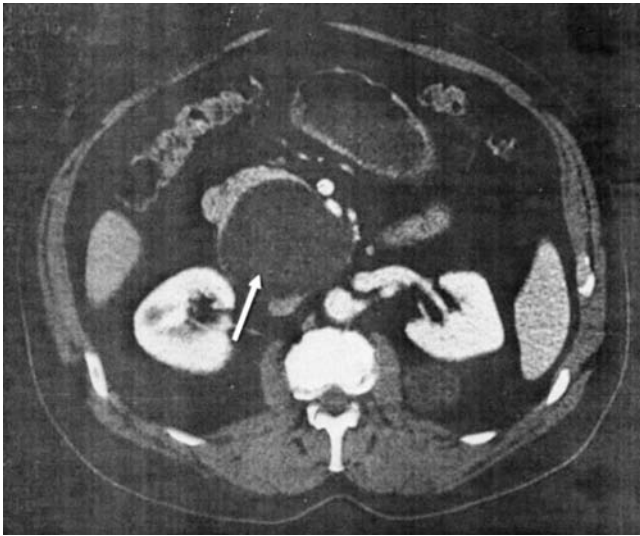
In light of the mandatory presence of ovarian-type stroma, not surprisingly, MCNs are now diagnosed almost entirely in women.<sup>44,45,51–56</sup> This requirement, combined with the usual lack of communication with the pancreatic duct, defines a unique phenotype separate from IPMN. In a combined report from the University of Verona and the Massachusetts General Hospital, Crippa and colleagues reviewed their experience with 163 MCNs that met the WHO criteria for diagnosis.<sup>55</sup> Of the 163 patients, 95% (155 patients) were perimenopausal females. Only 8 males were identified, and they were significantly older than the female patients (63 vs 44 years,  $p = .011$ ). The location of MCN within the gland was almost entirely confined to the body and tail of the pancreas (97%), and only five lesions were found in the pancreatic head. In reviewing the literature regarding MCN, these researchers noted the importance of segregating studies according to whether or not the presence of ovarian-type stroma was required for inclusion of pathological specimens within collected reports. Goh et al reviewed those studies where the presence of ovarian-type stroma was a mandatory criterion for the diagnosis of MCN: 99.7% of the patients were women, the mean age at presentation was 47 (range, 18–95) years, and 95% of MCNs occurred to the left of the pancreatic neck.<sup>57</sup> By comparison, when this criterion was previously not a prerequisite to diagnose MCN, patients were older, more often male and the lesions were located in the head with a frequency exceeding 30%.

Abdominal pain or discomfort is the most common presenting symptom, occurring in over 70% of patients.<sup>52–54</sup> A history of acute pancreatitis may also be elicited in 9–13% of patients, although less commonly than in patients with IPMN.<sup>4,52,55</sup> Patients with MCN with an associated invasive carcinoma present 11 years later than those with noninvasive neoplasms, likely representing the longer time required to progress to overt malignancy within these neoplasms.<sup>55</sup>

## Diagnosis

Macroscopically, MCNs have some characteristic features that may be evident during imaging or operative evaluation. Classically, MCNs contain large septated cysts with thick irregular walls that may be well visualized on CT, MRI, or ultrasound evaluation. Papillary projections from the epithelium often extend into the cystic cavities and may be visible, particularly on high quality axial or endoscopic ultrasound imaging. In a minority of cases, the wall of the MCN may contain calcifications, a characteristic associated with a higher





**FIGURE 58-6** Abdominal CT performed on a 69-year-old healthy man who had a palpable abdominal mass detected on routine physical examination. The mass (*arrow*) was homogeneous in character and was initially presumed to be a pseudocyst. Pylorus-preserving pancreaticoduodenectomy was performed, revealing an 8.5-cm mucinous cystic neoplasm without malignancy.

likelihood of malignancy.<sup>58</sup> MCNs may also present as large unilocular cysts that may appear similar on cross-sectional imaging to long-standing pseudocysts (Fig. 58-6). Two distinguishing characteristics in this scenario are the lack of surrounding inflammatory changes beyond the wall of the neoplasm in MCN, and the absence of pancreatitis, two features common in evolving pseudocysts related to pancreatitis.<sup>7</sup> Demonstration of ductal communication with the cyst by MRI or magnetic resonance cholangiopancreatography (MRCP) may distinguish pseudocyst or IPMN from MCN, though MCN can in rare instances exhibit connection with the pancreatic duct.<sup>57</sup>

Similar to SCN, determination of a treatment plan for MCN is predicated upon whether or not a given lesion is mucinous. Analysis of cyst fluid aspirated from MCNs typically show elevated levels of CEA and low amylase concentrations. The Cooperative Pancreatic Cyst Study demonstrated that a CEA value greater than 192 ng/mL achieved the greatest efficiency for differentiating mucinous from nonmucinous lesions.<sup>25</sup> The accuracy of CEA (88/111, 79%) was greater than the accuracy of EUS morphology or cytology ( $p < .05$ ). No combination of tests further improved diagnostic accuracy. A CEA level greater than 800 ng/mL has a specificity of 98% for predicting MCN, but a sensitivity of only 48%.<sup>59</sup> Khalid and his coinvestigators tested the utility of DNA analysis of cyst fluid to diagnose mucinous and malignant cysts.<sup>60</sup> The presence of a *K-ras* mutation was highly specific for a mucinous cyst (96%), but had a low sensitivity of 45%. A considerable selection bias was introduced by the study design which may have overestimated the ability of DNA analysis to

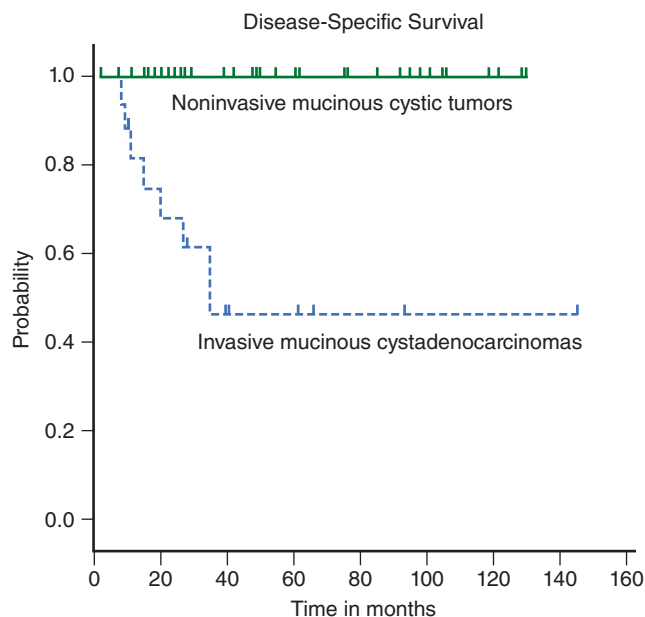
define a mucinous cyst.<sup>61</sup> Presence of a *K-ras* mutation in cyst fluid may provide additional information when CEA levels are not discriminative, particularly in lesions that appear to not have clear imaging patterns which allow separation of SCN versus MCN.

## Treatment

In their pooled review of the literature, including 10 studies of MCN defined by ovarian-type stroma, Goh and coworkers noted that, in the 40 invasive carcinomas found in 344 patients, only one of the malignant MCNs was less than 4.5 cm at the time of resection.<sup>57</sup> Crippa and colleagues noted that lesions containing either in situ or invasive carcinoma were larger (median size 80 vs 45 mm,  $p = .0001$ ), and intracystic nodules or papillae were more frequently present (64.3 vs 4.4%,  $p = .0001$ ), when compared with benign neoplasms.<sup>55</sup> All lesions demonstrating cancer on pathology were either greater than 4 cm in diameter or contained nodules by preoperative imaging. Careful observation of asymptomatic lesions less than 3 cm in size, without the presence of nodules, appears to be a reasonable approach for MCN (see Table 58-2). However, a recent post-hoc analysis by Sawhney and associates has questioned whether size alone, based on the Sendai Consensus criteria,<sup>14</sup> is a sufficient predictor of malignancy in pancreatic cysts.<sup>62</sup> Their data indicated that the original consensus guidelines should be applied with caution, and that more accurate diagnoses might be generated by the combination of cyst size and main pancreatic duct dilation greater than 3 mm.

Biopsy of MCN should not be utilized to determine the presence of carcinoma, because the presence of invasion within a lesion may be patchy and a negative biopsy may be obtained based on sampling error. Due to the significant rate of malignancy and the risk of progression to malignancy associated with MCN, symptomatic neoplasms, lesions greater than 3 cm or those containing nodules or papillae should undergo resection. As with SCN, enucleation has been documented to be an effective strategy for resection in selected MCN cases.<sup>36,37,63</sup> However, there is some risk of performing an inadequate oncologic resection for an MCN should it harbor an invasive component, while there is virtually no risk for SCN. Therefore enucleation should only be applied to highly selected cases of small, peripherally located MCNs with confirmation by extensive frozen-section analysis. Likewise, segmental pancreatic resections for lesions in the pancreatic neck and body (central pancreatectomy) or tail (spleen-preserving distal pancreatectomy) should be performed cautiously in selected patients without any indication of invasive disease. Larger tumors in older patients (ie, patients fitting the characteristics of MCN with an associated invasive cancer) should be treated with formal pancreatic resection to include specimen-associated lymph node harvest. Lesions in the pancreatic head are best treated with pancreaticoduodenectomy, while





**FIGURE 58-7** Kaplan-Meier disease-specific actuarial survival curves for invasive MCN and noninvasive MCN among 61 patients treated at the Johns Hopkins Hospital. The difference in survival between the two curves was statistically significant ( $p < .005$ , log-rank test). Five-year survival for patients with invasive MCN is approximately 50%. (Reproduced, with permission, from Wilentz RE, et al. Pathologic examination accurately predicts prognosis in mucinous cystic neoplasms of the pancreas. *Am J Surg Pathol.* 1999;23:1320–1327.)

left-sided lesions are treated via distal pancreatectomy with en bloc splenectomy. Extended lymphadenectomy, which has not been shown to definitively improve locoregional control or survival in patients with pancreatic ductal adenocarcinoma, has no role in the treatment of patients with cystic neoplasms.<sup>64,65</sup>

The 5-year disease-specific survival for benign or noninvasive MCN is 100%, but falls to 50–60% for patients with invasive mucinous cystadenocarcinoma<sup>55</sup> (Fig. 58-7). Failure to completely resect a noninvasive MCN may result in a later recurrence (persistence), and a missed opportunity for cure.

Adjuvant therapy for mucinous cystadenocarcinoma has been poorly investigated and has no proven benefit. A single case report describes the use of neoadjuvant chemoradiation and treatment monitoring by serum CEA level, but no prospective clinical trials have been performed.<sup>66</sup> Some high-volume centers would likely offer adjuvant chemotherapy to patients with invasive cystadenocarcinoma, extrapolating from the experience with ductal adenocarcinoma.<sup>67</sup> There are no data to support the utility of adjuvant radiotherapy. Follow-up with serial MR imaging every 6 months for 2 years and annually thereafter appears reasonable for patients with resected MCN with an associated invasive cancer.<sup>36</sup> Patients with resected noninvasive MCNs receive no postoperative adjuvant therapy and are not typically followed with serial imaging.

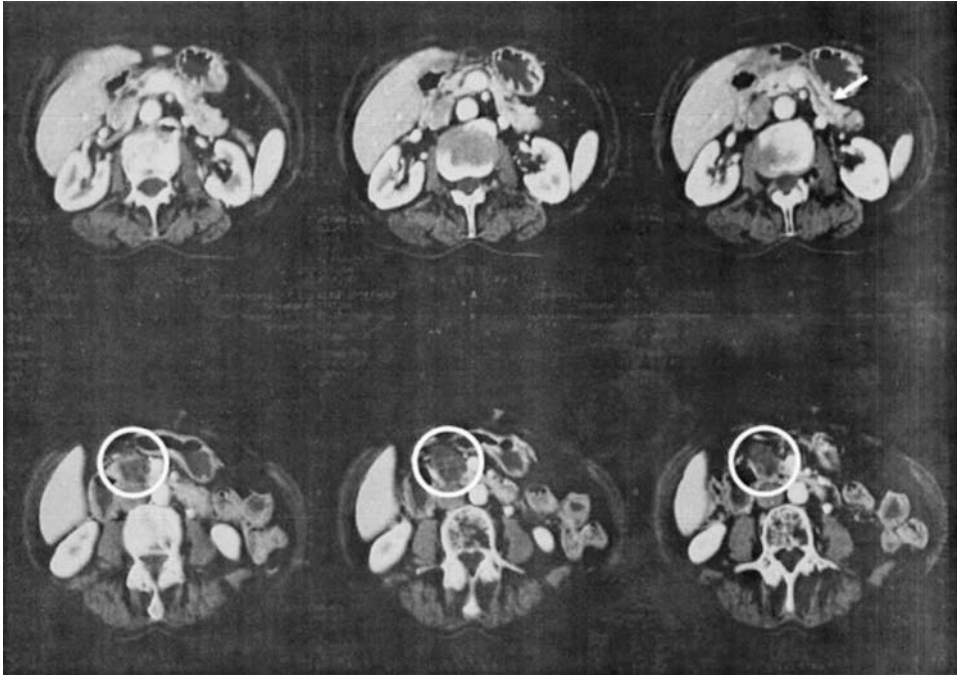
## INTRADUCTAL PAPILLARY MUCINOUS NEOPLASMS

In the past, these lesions were variably referred to as mucinous ductal ectasia, intraductal papillomatosis, intraductal adenoma or adenomatosis, intraductal mucin-secreting tumor, and intraductal papillary mucinous tumor. However, the earliest report of this “new” lesion is attributed to Ohashi and Maruyama and was published in the Japanese literature in 1982.<sup>68</sup> This report described four malignant lesions associated with the main pancreatic duct and characterized the now well-described copious amounts of mucus that distend and emanate from the ductal system. The authors noted the comparatively better survival of these patients compared to those with classic invasive ductal adenocarcinoma of the pancreas. While many subsequent authors have helped to further characterize the subtleties of IPMN, these initial observations accurately depict typical cases.

In 1996, the WHO first formally recognized IPMN as a distinct entity, establishing criteria for the pathological diagnosis of these lesions.<sup>41</sup> Characteristic features include a tall, columnar epithelium with marked mucin production, and cystic transformation of either the main pancreatic duct or one of its side branches (Fig. 58-8). More recent versions of these diagnostic criteria have allowed the stratification of noninvasive IPMNs based on their degree of dysplastic change, and the clear separation of noninvasive IPMN from IPMN with an associated invasive carcinoma.

## Pathological Features

Histologically, IPMNs are characterized by intraductal proliferation of mucinous cells which form papillae. Secretion of mucin leads to dilatation of the pancreatic ducts (Fig. 58-9). Lesions may be localized, multicentric, or rarely involve the entire ductal system. The proliferation of mucinous cells may involve the main pancreatic duct (main duct type), or be confined to the branch ducts (branch duct type) or show a pattern spanning both areas in a combined type. Three different morphologic patterns of IPMN can be seen.<sup>69</sup> Most branch duct type IPMN demonstrate papillae lined by tall columnar cells with basally oriented nuclei and abundant pale mucin. This pattern is also prevalent in the nonpapillary areas of main duct type IPMN and appears similar to the gastric mucosa. Scattered goblet cells are present and stain for MUC2. This pattern is called the gastric-foveolar type. Most main duct type IPMN closely resemble colonic villous adenomas and show molecular characteristics of intestinal differentiation, such that the cells express CDX2 and MUC2.<sup>70</sup> These are classified as *villous-intestinal type*. Their papillae are also positive for MUC5AC. Cancers arising in these IPMN are typically colloid carcinomas (Fig. 58-10). Colloid carcinomas also express CDX2 and MUC2, but not MUC1. A small proportion of IPMN is more complex and lined by cuboidal cells which do not express MUC2 or CDX2. This form is referred to as the *pancreatobiliary type*. Invasive cancers associated



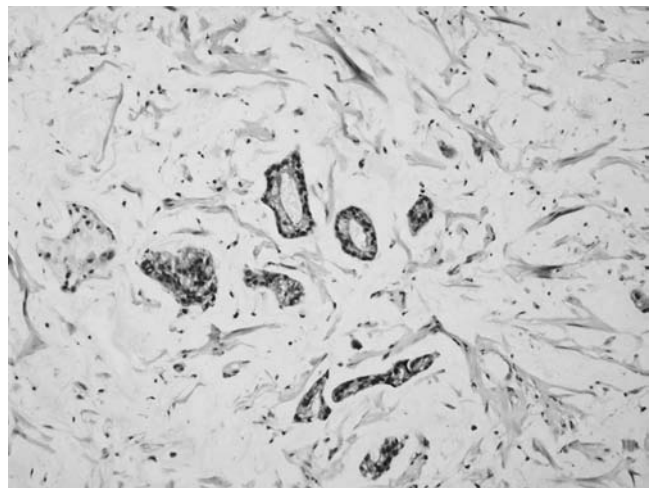
**FIGURE 58-8** Abdominal CT of an 80-year-old woman who presented with abdominal pain. The patient underwent a pylorus-preserving pancreaticoduodenectomy; final pathology revealed a 3.5-cm IPMN with a small focus of carcinoma in situ located in the head of the pancreas. Notable findings on this series of images that are characteristic of IPMN include the multiloculated cystic mass in the right side of the pancreas (*circle*) associated with mild to moderate pancreatic ductal dilatation (*arrow*).

with the pancreatobiliary morphology are usually tubular, with structure similar to ductal adenocarcinoma. The invasive component expresses MUC1, but not MUC2. While both the villous-intestinal and the pancreatobiliary types may be found alongside the gastric-foveolar type, it is however, uncommon to identify both the villous-intestinal and pancreatobiliary type of papillae in the same IPMN.<sup>69</sup>

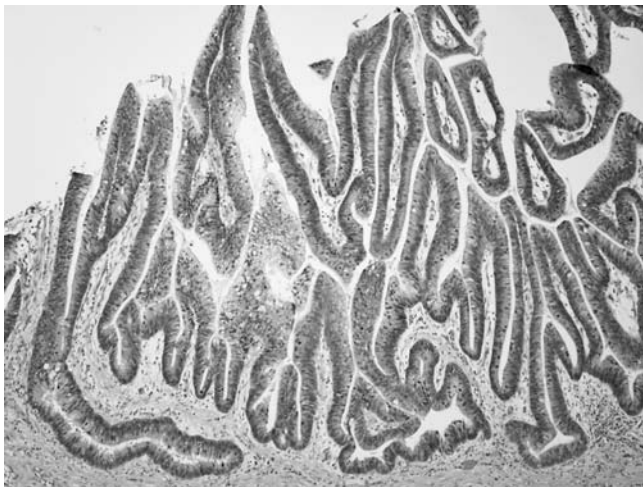


**FIGURE 58-9** Gross photograph of a distal pancreatectomy specimen from a patient with an IPMN with carcinoma in situ. Characteristic features include the mass in direct communication with a markedly dilated main pancreatic duct.

IPMNs demonstrate a progressive precursor model of carcinogenesis similar to that seen in colon cancer.<sup>71</sup> Tall mucin-producing columnar epithelial cells that remain well differentiated characterize IPMN adenoma (low-grade dysplasia). Little or no dysplasia is present in these lesions. IPMN borderline lesions (moderate grade dysplasia) are described as lesions with moderate epithelial dysplasia,



**FIGURE 58-10** Photomicrograph of a colloid carcinoma within an IPMN. Note the largely acellular nature of these cancers and their abundant mucin production.



**FIGURE 58-11** Photomicrograph of an IPMN with borderline features. Characteristic features include the tall columnar cells lining the papillary projections of the tumor, moderate dysplastic changes of the epithelium, and varied nuclear morphology.

characterized by moderate loss of polarity, changes in nuclear morphology, and pseudopapillary formation (Fig. 58-11). IPMNs with carcinoma-in situ have severe dysplastic changes. These lesions may be papillary or micropapillary, and severely dysplastic lesions may lose the ability to secrete mucin. IPMNs are pathologically similar to pancreatic intraepithelial neoplasia (PanIN). IPMNs, like PanIN, are intraductal lesions that may demonstrate a range of cellular atypia and malignant transformation. However, IPMNs may be distinguished based on their gross visibility and involvement of large ducts. PanIN should be considered a microscopic finding involving ducts less than 5 mm in diameter, while IPMNs are macroscopic findings.<sup>72</sup> In addition, IPMNs often express the mucin MUC2, while PanINs usually express MUC1.

IPMNs appear also to have distinct molecular events contributing to the clinical and pathological behavior that further distinguish them from lesions in the PanIN–ductal adenocarcinoma sequence. Iacobuzio-Donahue and associates described the intact (normal) expression of the tumor-suppressor gene *Dpc4* in the intraductal components of 79 IPMN.<sup>73</sup> In contrast, *Dpc4* inactivation has been shown to be relatively specific for pancreatic adenocarcinoma, and its persistence in both noninvasive and invasive IPMNs argues that these lesions may arise through a pathway that is distinct from the PanIN–ductal adenocarcinoma. IPMNs also appear to have a significantly lower rate of *K-ras* and *p53* mutations, lesions that are common in ductal adenocarcinoma.<sup>74</sup> Fritz and coworkers recently demonstrated that loss of chromosome 5q, 6q, and 11q was significantly higher in IPMN with high-grade dysplasia or invasion compared with ductal adenocarcinoma.<sup>75</sup> These data and others suggest that IPMNs are unique pancreatic neoplasms, with a pathogenesis that is distinct from that of the PanIN–ductal adenocarcinoma sequence.

## Clinical Presentation

The biologic behavior of IPMNs parallels their classification according to their distribution within the pancreatic ductal system. Main duct type and combined main duct and branch duct type lesions are more likely to present with symptoms, while strictly branch duct type IPMNs are more frequently detected as asymptomatic cystic neoplasms on cross-sectional imaging.<sup>76</sup> Pancreatitis is seen more commonly in main duct type IPMN, possibly related to mucous plugging of the ampulla. In a combined experience of the Massachusetts General Hospital and the University of Verona reported by Salvia and colleagues, acute pancreatitis occurred in 23% of 140 patients with main duct variant IPMN.<sup>77</sup>

Both genders are affected by IPMNs, with a moderate male predominance in some series. Patients with IPMN tend to be older, with a mean age of 65 years, as compared with those having MCN who are predominantly perimenopausal. Similar to the situation with MCN, IPMN patients demonstrated to have a malignancy, a trend toward being older, again suggestive of an adenoma-to-carcinoma sequence of progression and the time necessary to undergo this transformation. Main duct type IPMNs are more likely to demonstrate the development of malignancy. Of note, malignant IPMNs are more likely to present with symptoms typically attributed to ductal adenocarcinoma, such as obstructive jaundice and weight loss.<sup>5,77</sup>

The development of symptoms more commonly attributed to ductal adenocarcinoma in patients with IPMN may herald the occurrence of carcinoma either synchronously or metachronously in the gland. Several studies have demonstrated the presence of an invasive ductal adenocarcinoma elsewhere in the pancreas, distinct from the location of the cystic neoplasm in up to 10% of IPMN patients.<sup>40,78,79</sup> Ingakul and colleagues recently showed that, in a multivariate analysis, worsening diabetes (odds ratio 15.73 [95% CI: 4.40–56.25];  $p < .001$ ), and an abnormal CA 19-9 (odds ratio 3.70 [95% CI: 1.19–11.48];  $p = .024$ ) are independent factors predictive of synchronous or metachronous separate ductal adenocarcinoma in patients with IPMN.<sup>79</sup> In a report from Memorial Sloan-Kettering, Allen et al sought to characterize those cystic lesions which should be initially resected.<sup>40</sup> Asymptomatic cystic neoplasms, less than 2.5 cm in size, without septations or a solid component were followed over time. Eventually, 28 of 369 patients, initially managed conservatively, were operated upon primarily for cyst growth. Malignancy was found in 11 of these 28 patients (38%): three were cystic neuroendocrine tumors, while 8 of 11 were ductal adenocarcinomas. Further review of these eight ductal adenocarcinomas demonstrated that the cancer arose adjacent to the initially discovered cyst. This study demonstrates the need to thoroughly investigate the entire pancreas when electing to observe a cystic neoplasm. In addition, the incidence of extrapancreatic malignancies appears to be higher in patients with IPMN.<sup>80,81</sup> The development of colorectal adenomas and carcinomas, Barrett's mucosa and gastric carcinomas appear to be important entities seen in IPMN patients.



## Diagnosis

CT scanning (with all of its advances up to multidetector imaging) has been the primary method for imaging the pancreas in the past. However, the use of MRI, particularly in combination with MRCP imaging has allowed for more thorough identification of IPMN. IPMNs characteristically appear as cystic masses resulting from dilatation of the main pancreatic duct or side branch ducts. Polypoid projections (mural nodules) into the cystic spaces may be present. Approximately half of IPMNs occur in the pancreatic head, though they may be present anywhere within the pancreas and can diffusely involve the entire gland. Currently MRCP is the modality of choice for defining mural nodules, demonstration of the communication of the cystic neoplasm with the pancreatic ductal system, and evaluating the extent of the pancreatic ductal dilatation.<sup>82</sup> Use of MRCP has largely supplanted endoscopic retrograde cholangiopancreatography (ERCP) in the diagnosis of IPMN, since MRCP is noninvasive, does not require sedation, and does not carry the risks of pancreatitis and perforation which accompany ERCP.

With the increasing emphasis on managing asymptomatic branch duct type IPMN by observation, imaging studies have sought to define features associated with invasive carcinoma by correlating preoperative imaging with pathology obtained by resection. Several imaging features suggestive of the presence of malignancy have been demonstrated, including tumor size (cyst diameter  $\geq 30$ , 40, or 50 mm), main duct type IPMN, main duct dilatation greater than or equal to 10 or 15 mm, patulous papilla, mural nodules ( $\geq 3$ , 5, or 10 mm in size), presence of biliary ductal dilatation greater than or equal to 15 mm, a solid mass, or occurrence of an area of abnormal attenuation in the surrounding pancreas.<sup>82-90</sup> Importantly, a recent report from Verona, Italy by Salvia and colleagues notes that they followed 121 patients with multifocal branch duct IPMN (median diameter of the largest lesion being 1.7 cm) over a 40-month observation period.<sup>91</sup> All of the 121 patients remained alive, without surgery, and all remained asymptomatic. Thus, there is clearly a role for conservatism in the management of patients with branch duct IPMNs and no additional worrisome features.

Endoscopic ultrasound (EUS) may provide additional information which may prompt resection or promote a more conservative approach. Ohno et al demonstrated that the finding of a papillary mural nodule or a nodule exhibiting an invasive component on EUS was predictive of malignancy with a sensitivity of 60%, specificity of 93%, and an accuracy of 76%.<sup>92</sup> EUS-FNA may also be useful in reinforcing a decision not to resect a branch duct type IPMN, if it is otherwise without features predictive of malignancy. Marie and colleagues found that the combination of a CEA level less than 200 ng/mL and a CA 72.4 level greater than 40 U/mL retrieved from the cystic material of an IPMN together had a 96% negative predictive value for the diagnosis of malignancy.<sup>93</sup>

## Treatment

The Japan Pancreas Society performed a multi-institutional, retrospective study of 1379 cases of IPMN drawn from 98 of their member programs. The clinicopathologic features of benign IPMN (see Table 58-2) (adenoma [low-grade dysplasia] and borderline lesions [moderate dysplasia];  $n = 564$ ) were strikingly different when compared with tumors containing frank adenocarcinoma ( $n = 445$ ).<sup>85</sup> Patients with adenocarcinoma were significantly older (67 vs 65 years,  $p = .0002$ ) and more frequently symptomatic (49 vs 35%,  $p < .0001$ ), as compared to the noncarcinoma group. Cancer occurred more commonly in either main duct type or combined-type tumors, as compared to branch duct type neoplasms (60, 65, and 30%,  $p < .001$ ), respectively. The preoperative imaging of patients who were subsequently found to have adenocarcinoma on pathology, demonstrated a higher incidence (63 vs 28%) and size of mural nodules (12 vs 5 mm) when compared with those who had benign lesions (both  $p < .0001$ ). Branch duct type tumors with cancer were larger (35 vs 28 mm,  $p < .0001$ ) than those without cancer.

Based on the data generated in the earlier report, the International Association of Pancreatology convened a consensus conference in Sendai, Japan in 2004. The subsequent guidelines published in 2006, have become a new benchmark for the management of IPMN.<sup>14</sup> These guidelines recommend the resection of all IPMN of a main duct type and mixed variants, those showing main pancreatic duct dilatation greater than or equal to 10 mm, as well as those with the presence of mural nodules, or a positive cytology, provided the patients are reasonable candidates for surgery with an acceptable life expectancy. All symptomatic IPMNs were deemed to warrant resection. These recommendations were predicated upon the risk of carcinoma in symptomatic or main duct type lesions. Branch duct IPMNs less than 30 mm in diameter, without evidence of mural nodules or main duct dilatation, were felt to be of low malignant potential and were candidates for careful observation. At follow-up examinations, appearance of symptoms, cyst expansion to greater than 30 mm, detection of positive cytology on FNA, development or identification of mural nodules or main pancreatic duct dilatation ( $\geq 6$  mm) were deemed indications for resection.

Since the development of the Sendai guidelines, much of the subsequent literature has sought to examine the accuracy of the recommendations, particularly with regard to the observation of asymptomatic branch duct type IPMN. Pelaez-Luna and colleagues identified 147 patients with branch duct type IPMN, of whom 66 underwent resection at diagnosis and 81 were followed over time (of which 11 were resected during the follow-up period).<sup>94</sup> Of the patients undergoing resection who demonstrated Sendai consensus guideline indications for surgical therapy, 9/61 (15%) had carcinoma on pathology, whereas none of the 16 patients without consensus indications for resection had malignancy ( $p = .1$ ). A single guideline indication for resection taken as an indicator of carcinoma had a sensitivity,

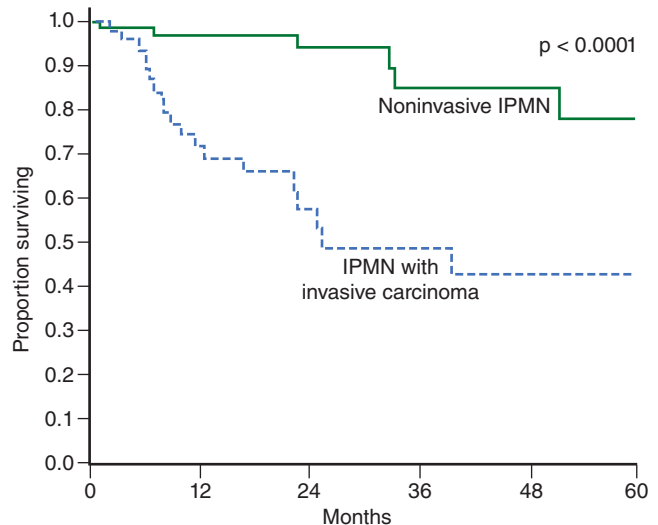


specificity, positive predictive value, and negative predictive value of 100, 23, 14, and 100%, respectively.

Several studies have suggested that the development of mural nodules is predictive of the risk of developing malignancy, while a progressive dilatation of duct size remains controversial. Schmidt and colleagues identified 103 patients with branch duct type IPMN.<sup>95</sup> The mean size of the 20 malignant lesions was  $2.0 \pm 0.1$  cm, while the mean size of the nonmalignant neoplasms was  $2.2 \pm 0.1$  cm, suggesting that size alone is an insufficient indicator of malignancy. In multivariate analysis, only the presence of mural nodules and atypical cytopathology were predictive of the presence of carcinoma. Tanno et al prospectively followed 82 patients with flat lesions within branch duct type IPMN diagnosed by CT or MR and EUS.<sup>96</sup> During a median follow-up of 59 months, 9/82 patients (11%) exhibited progressive dilatation of the cystic lesion. Six elected to continue regular screening, while three underwent resection; the IPMNs resected were staged as IPMN-adenoma in two and IPMN-borderline in one. Four patients (5%) developed mural nodules during a median follow-up of 105 months. All four of these individuals were resected, demonstrating IPMN-adenoma in three and carcinoma in situ in the fourth. Sixty-nine of the 82 patients (84%) showed no changes in their dilated branch duct lesions over a median follow-up of 57 months.

A recent study from Kyushu University attempted to determine whether cyst size is predictive of the malignant potential in flat branch duct type IPMN.<sup>97</sup> One hundred seventy patients with branch duct type IPMNs without mural nodules were retrospectively identified from their previous 10-year experience. Seventy-three patients underwent resection of their IPMN: 26 patients had lesions less than 30 mm in size, while 47 patients had neoplasms greater than 30 mm in diameter. All of the noninvasive ( $n = 5$ ) and invasive ( $n = 1$ ) malignancies were seen in the IPMN of greater than or equal to 30 mm. In a similar report, Salvia and coworkers followed 89 patients with flat branch duct type IPMN less than or equal to 3.5 cm in size for a median time period of 32 months.<sup>98</sup> Five patients (5.6%) exhibited an increase in diameter of the cystic lesion, none of which demonstrated carcinoma in the resection specimen pathologically. Clearly, longer follow-up will be needed to determine whether or not clear evidence of carcinoma develops in patients without Sendai consensus guidelines for surgical therapy. As might be anticipated, increasing knowledge and follow-up has raised questions about the universal accuracy of the consensus guidelines.

The majority of studies, particularly those following IPMNs conservatively in a prospective fashion, would suggest that the development of invasive carcinoma in flat branch duct IPMN less than 30 mm in size is unusual. The occurrence of high-risk stigmata (mural nodules, dilated main duct, or positive cytology) clearly have great predictive value for the ultimate finding of malignancy. EUS appears to be an important adjuvant to fully evaluate IPMN patients for the presence of mural nodules, as well as for aspiration of cytologic specimens. Some authorities insist that any lesion which is to be followed conservatively



**FIGURE 58-12** Kaplan-Meier actuarial survival curves comparing 84 patients with noninvasive IPMN to 52 patients with invasive IPMN following pancreatic resection at the Johns Hopkins Hospital (1987–2003). Patients with noninvasive IPMN have a significantly greater survival than those with invasive carcinoma ( $p < .0001$ ). (Reproduced, with permission, from Sohn TA, et al. Intraductal papillary mucinous neoplasms of the pancreas: an updated experience. *Ann Surg.* 2004;239:788–797.)

should be examined by EUS at regular intervals. We have tended to use MRI or MRCP for serial surveillance of small (<3 cm) branch duct IPMNs, as this is a noninvasive procedure (as compared to EUS) which avoids radiation exposure (as compared to CT).

Given the excellent survival following resection of IPMN free of an invasive component, every effort must be made to define lesions at risk for the development of carcinoma at the earliest point possible (Fig. 58-12). Schnelldorfer and coworkers have demonstrated that the survival after pancreatectomy of patients with IPMN with invasive adenocarcinoma is equivalent to that of a matched cohort of patients following resection of ductal adenocarcinoma (median survival, 32 vs 21 months; 5-year survival rate, 31 vs 24%;  $p = .26$ ).<sup>99</sup> Other studies have revealed that survival of patients without lymph node involvement and invasive IPMN is quite good, while patients with lymph node involvement and invasive IPMN have equivalent outcomes to patients with lymph node-positive pancreatic ductal adenocarcinoma.<sup>5</sup> Despite the poor survival in patients with invasive disease, surgery remains the best opportunity for cure. Swartz et al have recently shown that adjuvant chemoradiotherapy confers a 57% decrease in the relative risk of mortality after pancreaticoduodenectomy for invasive IPMN after adjusting for major confounders.<sup>100</sup> This effect was most significant in patients with lymph node metastases or positive surgical margins.

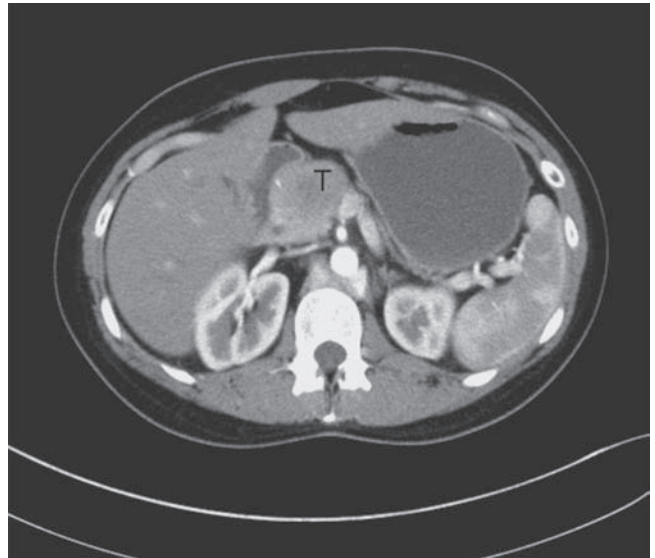
Use of the Sendai consensus guidelines means that the preponderance of resections for IPMN will be performed with at least a suspicion of the presence of carcinoma. Targeted pancreatectomies, either pancreaticoduodenectomy

or distal pancreatectomy with en bloc splenectomy, have been advocated so as to adhere to oncologic principles of resection. Most centers have advocated the use of frozen-section examination of the pancreatic margin, with attempted clearance of microscopically malignant margins by re-resection and occasional conversion to total pancreatectomy when needed to achieve negative margins. Skip lesions clearly occur, such that a normal resection margin may not be indicative of a lack of neoplasia in the pancreatic remnant. A recent report by Nara et al from Tokyo analyzed 130 consecutive patients undergoing resection for IPMN with frozen-section analysis of the pancreatic margin<sup>101</sup>. While most initial frozen-section results showed no neoplasia at the margin, 29 patients had additional pancreas resected for “positive” frozen-section results (12 for low or moderate dysplasia, 10 for high-grade dysplasia, 1 for floating cancer cells, and 6 for invasive cancer). Most patients who recurred following re-resection had their recurrence at a distance from the pancreatic margin (peritoneum, liver, and lymph nodes), raising doubt about the true value of re-resection for margins determined to be positive at frozen section. The role of total pancreatectomy to achieve clearance of all dysplastic epithelium, even prophylactic total pancreatectomy, is controversial. Notably, of the 84 patients with noninvasive IPMN described by Sohn and colleagues,<sup>5</sup> 7 patients developed recurrent disease in the pancreatic remnant. Negative margins at resection do not eliminate the need for chronic surveillance of the pancreatic remnant, perhaps best done by annual MRI/MRCP.

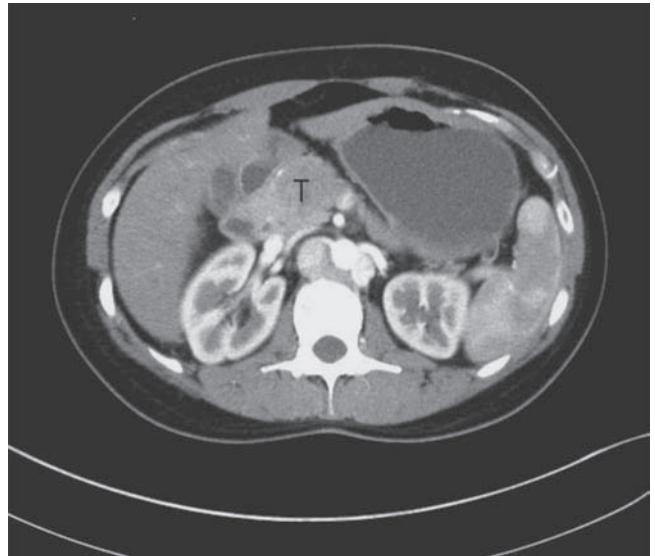
## UNUSUAL PANCREATIC CYSTIC NEOPLASMS

### Solid Pseudopapillary Neoplasm (Solid and Papillary Neoplasm)

These rare tumors are notable for several characteristic clinical and pathological features. The ratio of women to men is roughly 10:1, with lesions typically appearing in the second or third decade of life (mean age 22 years, range 2–85 years). Patients often present either with abdominal pain or a palpable abdominal mass. The lesions may be large, presenting in one review at a mean size of 6.1 cm (range 0.5–34.5 cm).<sup>102</sup> On CT, these tumors often appear well circumscribed, with hypodense areas representing hemorrhage or necrosis (Fig. 58-13). Lesions tend to be evenly distributed throughout the pancreas. Most of these lesions harbor  $\beta$ -catenin mutations, express the beta subtype of estrogen receptors and stain for galectin-3.<sup>103</sup> Though most of these tumors are benign, some may be considered low-grade malignancies, with local invasion into contiguous structures and occasional distant metastases (roughly 15–20% of cases). An aggressive surgical approach is warranted for both the primary and metastatic disease, as 5-year survival in completely resected patients exceeds 95%.<sup>104,105</sup>



A



B

**FIGURE 58-13** Abdominal CT scan of a 29-year-old woman with a right-sided solid and papillary neoplasm. **A.** The tumor (T) resides within the duodenal C loop, and there is some deformation of the portal vein. **B.** On this more inferior image the tumor (T) is seen to further deform the superior mesenteric vein (SMV), but not touch the superior mesenteric artery (SMA). The tumor was resected via a pylorus-preserving pancreaticoduodenectomy which was extended to include the proximal body of the pancreas. The tumor was dissected free from the SMV, portal vein, and no venous resection was needed.

### Cystic Neuroendocrine Neoplasms

Neuroendocrine tumors showing partial or complete cystic components are uncommon. The Cooperative Pancreatic Cyst Study demonstrated only 5 of these lesions out of 341 cystic neoplasms. Immunohistochemical staining of cytological

specimens obtained by EUS-FNA demonstrating endocrine markers confirms the diagnosis.<sup>106</sup> In a retrospective review of 170 patients undergoing resection for a pancreatic neuroendocrine tumor at the Massachusetts General Hospital over a 30-year period, 29 cystic neuroendocrine tumors were identified.<sup>107</sup> Ten (34%) of the cystic lesions were purely cystic, while 19 (66%) were partially cystic. Cystic neuroendocrine neoplasms were larger (49 vs 23.5 mm,  $p < .05$ ), more likely to be symptomatic (73 vs 45%,  $p < .05$ ), and most likely to be nonfunctional (80 vs 50%,  $p < .05$ ), when compared with solid pancreatic neuroendocrine lesions. The propensity for metastases, invasion, and survival (87 vs 77% at 5 years,  $p = .38$ ) in patients with cystic lesions was the same as in those with solid pancreatic endocrine neoplasms. Thus, these lesions have a favorable prognosis if completely resected and should be treated aggressively and with similar technique as for a solid neuroendocrine tumor in appropriate surgical candidates.

## Cystic Acinar Cell Neoplasms

Acinar cell carcinoma of the pancreas is a rare neoplasm, however, several recent registry reviews and multi-institutional series have better defined this entity.<sup>108,109</sup> This lesion has a 2:1 male predominance and although many individuals will present with advanced disease, stage-specific survival is statistically better than that seen in ductal pancreatic adenocarcinoma.<sup>108</sup> Occasionally, acinar cell carcinoma may display an intraductal, papillary or papilocystic growth pattern and may appear to mimic IPMN with a cystic component. A significant proportion of these tumors (up to 40%) may demonstrate a concomitant endocrine neoplasm.<sup>109</sup> Acinar cell neoplasms with intraductal growth patterns tend to present somewhat earlier than typical acinar cell carcinoma, secondary to the pancreatitis resulting from duct obstruction. Characteristic immunohistochemical staining for trypsin and chymotrypsin, as well as presence of eosinophilic granular cytoplasm in acinar cell carcinoma are helpful in establishing the correct diagnosis.<sup>109</sup>

## Cystic Degeneration of Pancreatic Ductal Adenocarcinoma

While not truly a distinct lesion, it is important to realize that pancreatic ductal adenocarcinoma may present with cystic features. Thus all cystic lesions should at least be considered as potential pancreatic ductal adenocarcinomas until an alternative diagnosis is established. In a comparative review of symptomatic and incidental pancreatic cysts by Fernandez-del Castillo and colleagues, 9% of symptomatic lesions and 2% of incidental cysts proved to harbor pancreatic ductal adenocarcinoma.<sup>43</sup> Adenocarcinomas that obstruct the pancreatic duct may be associated with retention cysts in up to 8% of patients.<sup>110</sup>

## REFERENCES

- Kimura W, et al. Analysis of small cystic lesions of the pancreas. *Int J Pancreatol.* 1995;18:197–206.
- Spinelli KS, et al. Cystic pancreatic neoplasms: observe or operate. *Ann Surg.* 2004;239:651–657.
- Allen PJ, et al. A selective approach to the resection of cystic lesions of the pancreas. *Ann Surg.* 2006;244:572–582.
- Wada K, et al. Outcomes following resection of invasive and noninvasive papillary mucinous neoplasms of the pancreas. *Am J Surg.* 2005;189:632–636.
- Sohn TA, et al. Intraductal papillary mucinous neoplasms of the pancreas: an updated experience. *Ann Surg.* 2004;239:788–797.
- Weinberg BM, et al. Asymptomatic pancreatic cystic neoplasms: maximizing survival and quality of life using Markov-based clinical nomograms. *Gastroenterology.* 2010;138:531–540.
- Cannon JW, et al. Diagnosis and management of pancreatic pseudocysts: what is the evidence? *J Am Coll Surg.* 2009;209:385–393.
- Mosetti MA, et al. Autosomal dominant polycystic kidney disease: MR imaging evaluation using current techniques. *J Magn Reson Imaging.* 2003;18:210–215.
- Berrocal T, et al. Pancreatic cystosis in children and young adults with cystic fibrosis: sonographic, CT and MRI findings. *AJR Am J Roentgenol.* 2005;184:1305–1309.
- Delman KA, et al. Abdominal visceral lesions in von Hippel-Lindau disease: incidence and clinical behavior of pancreatic and adrenal lesions at a single center. *World J Surg.* 2006;30:665–669.
- Hough DM, et al. Pancreatic lesions in von Hippel-Lindau disease: prevalence, clinical significance and CT findings. *AJR Am J Roentgenol.* 1994;162:1091–1094.
- Capitanich P, et al. Lymphoepithelial cysts of the pancreas: case report and review of the literature. *J Gastrointest Surg.* 2004;8:342–345.
- Kloppel G, et al. Histological typing of tumors of the exocrine pancreas. In: *World Health Organization. International Histologic Classification of Tumors.* Berlin, Heidelberg, New York: Springer;1996.
- Tanaka M, et al. International consensus guidelines for management of intraductal papillary mucinous neoplasms and mucinous cystic neoplasms of the pancreas. *Pancreatol.* 2006;6:17–32.
- Aaltonen LA, et al. Pathology and genetics of tumours of the digestive system. In: *World Health Organization Classification of Tumours.* Lyon, Oxford, England: IARC Press, Oxford University Press (distributor); 2000:314.
- Friebe V, et al. Serous cystadenocarcinoma of the pancreas: management of a rare entity. *Pancreas.* 2005;31:182–187.
- Galanis C, et al. Resected serous cystic neoplasms of the pancreas: a review of 158 patients with recommendations for treatment. *J Gastrointest Surg.* 2007;11:820–826.
- George DH, et al. Serous cystadenocarcinoma of the pancreas: a new entity? *Am J Surg Pathol.* 1989;13:61–66.
- Hruban RH, et al. Atlas of tumor pathology. *Tumors of the Pancreas.* 4th ed. Washington, DC: American Institute of Pathology; 2006.
- Bassi C, et al. Management of 100 consecutive cases of pancreatic serous cystadenoma: wait for symptoms and see at imaging or vice versa? *World J Surg.* 2003;27:319–323.
- Tseng JF, et al. Serous cystadenoma of the pancreas: tumor growth rates and recommendations for treatment. *Ann Surg.* 2005;242:413–419.
- Le Borge J, et al. Cystadenomas and cystadenocarcinomas of the pancreas: multiinstitutional retrospective study of 398 cases. French Surgical Association. *Ann Surg.* 1999;230:152–161.
- Lonser RR, et al. von Hippel-Lindau disease. *Lancet.* 2003;361:2059–2067.
- Vortmeyer AO, et al. Allelic deletion and mutation of the von Hippel-Lindau (VHL) tumor suppressor gene in pancreatic microcystic adenomas. *Am J Path.* 1997;151:951–956.
- Brugge WR, et al. Diagnosis of pancreatic cystic neoplasms: a report of the cooperative pancreatic cyst study. *Gastroenterology.* 2004;126:1330–1336.
- Lee SE, et al. The morphological classification of a serous cystic tumor (SCT) of the pancreas and evaluation of the preoperative diagnostic accuracy of computed tomography. *Ann Surg Oncol.* 2008;15:2089–2095.
- Shah AA, et al. Predictive value of multi-detector computed tomography for accurate diagnosis of serous cystadenoma: radiologic-pathologic correlation. *World J Gastroenterol.* 2009;15:2739–2747.



28. Shah JN, et al. Minimizing complications of endoscopic ultrasound and EUS-guided fine needle aspiration. *Gastrointest Endosc Clin N Am*. 2007;17:129–143.
29. Jacobson BC, et al. ASGE guideline: the role of endoscopy in the diagnosis and management of cystic lesions and inflammatory fluid collections of the pancreas. *Gastrointest Endosc*. 2005;61:363–370.
30. Lee LS, et al. EUS-guided fine needle aspiration of pancreatic cysts: a retrospective analysis of complications and their predictors. *Clin Gastroenterol Hepatol*. 2005;3:231–236.
31. Huang P, et al. Fine-needle aspiration of pancreatic serous cystadenoma: cytologic features and diagnostic pitfalls. *Cancer Cytopathol*. 2006;108:239–249.
32. Pausawasdi N, et al. Long-term follow-up of patients with incidentally discovered pancreatic cystic neoplasms evaluated by endoscopic ultrasound. *Surgery*. 2010;147:13–20.
33. Hammel P, et al. Preoperative cyst fluid analysis is useful for the differential diagnosis of cystic lesions of the pancreas. *Gastroenterology*. 1995;108:1230–1235.
34. Fossard JL, et al. Performance of endosonography-guided fine needle aspiration and biopsy in the diagnosis of pancreatic cystic lesions. *Am J Gastroenterol*. 2003;98:1516–1524.
35. Allen PJ, et al. Pancreatic cyst fluid protein expression profiling for discriminating between serous cystadenoma and intraductal papillary mucinous neoplasm. *Ann Surg*. 2009;250:754–760.
36. Talamini M, et al. Cystadenomas of the pancreas: is enucleation an adequate operation? *Ann Surg*. 1998;227:896–903.
37. Ge C, et al. Enucleation of pancreatic cystadenomas. *J Gastrointest Surg*. 2010;14:141–147.
38. Shikano T, et al. Middle pancreatectomy: safety and long-term results. *Surgery*. 2010;147:21–29.
39. Berger, et al. Duodenum-preserving total pancreatic head resection for cystic neoplastic lesions in the head of the pancreas. *J Hepatobiliary Pancreat Surg*. 2008;15:149–156.
40. Allen PJ, et al. A selective approach to the resection of cystic lesions of the pancreas: results from 539 consecutive patients. *Ann Surg*. 2006;244:572–582.
41. Kloppel G, et al. Histological typing of tumours of the exocrine pancreas. In: World Health Organization Histological Classification of Tumours. 2nd ed. Berlin, Germany: Springer-Verlag; 1996.
42. Solcia E, et al. Tumors of the pancreas. In: Rosai J, Sorbin L, eds. *Atlas of Tumor Pathology*. 3rd ed. Washington, DC: Armed Forces Institute of Pathology; 1997:131–144.
43. Fernandez-del Castillo C, et al. Incidental pancreatic cysts: clinicopathologic characteristics and comparison with symptomatic patients. *Arch Surg*. 2003;138:427–430.
44. Izumo A, et al. Mucinous cystic tumors of the pancreas: immunohistochemical assessment of the “ovarian-type stroma.” *Oncol Rep*. 2003;10:515–525.
45. Zamboni G, et al. Mucinous cystic tumors of the pancreas: clinicopathologic features, prognosis, and relationship to other mucinous cystic tumors. *Am J Surg Pathol*. 1999;23:410–422.
46. Wilentz RE, et al. Mucinous cystic neoplasms of the pancreas. *Semin Diagn Pathol*. 2000;17:31–43.
47. Sarr MC, et al. Clinical and pathological correlation of 84 mucinous cystic neoplasms of the pancreas: can one reliably differentiate benign from malignant (or premalignant) neoplasms? *Ann Surg*. 2000;231:205–212.
48. Sarnaik AA, et al. Osteoclast-like giant cell tumor of the pancreas associated with a mucinous cystadenocarcinoma. *Surgery*. 2003;133:700–701.
49. Campman SC, et al. Adenosquamous carcinoma arising in a mucinous cystadenoma of the pancreas. *J Surg Oncol*. 1997;64:159–162.
50. van den Berg W, et al. Pancreatic mucinous cystic neoplasms with sarcomatous stroma: molecular evidence for monoclonal origin with subsequent divergence of the epithelial and sarcomatous components. *Mod Pathol*. 2000;13:86–91.
51. Khalifeh I, et al. Villous-intestinal differentiation and progression to colloid carcinoma, characteristic of a major subset of IPMNs, are not features of mucinous cystic neoplasms. *Mod Pathol*. 2005;18:281A.
52. Thompson LD, et al. Mucinous cystic neoplasm (mucinous cystadenocarcinoma of low-grade malignant potential) of the pancreas: a clinicopathologic study of 130 cases. *Am J Surg Pathol*. 1999;23:1–16.
53. Kosmahl M, et al. Cystic neoplasms of the pancreas and tumor-like lesions with cystic features: a review of 418 cases and a classification proposal. *Virchows Arch*. 2004;445:168–178.
54. Reddy RP, et al. Pancreatic mucinous cystic neoplasm defined by ovarian stroma: demographics, clinical features, and prevalence of cancer. *Clin Gastroenterol Hepatol*. 2004;2:1026–1031.
55. Crippa S, et al. Mucinous cystic neoplasm of the pancreas is not an aggressive entity: lessons from 163 resected patients. *Ann Surg*. 2008;247:571–579.
56. Crippa S, et al. Mucin producing neoplasms of the pancreas: an analysis of distinguishing clinical and epidemiologic characteristics. *Clin Gastroenterol Hepatol*. 2010; 8:213–219.
57. Goh B, et al. A review of mucinous cystic neoplasms of the pancreas defined by ovarian-type stroma: clinicopathological features of 344 patients. *World J Surg*. 2006;30:2236–2245.
58. Warshaw AL, et al. Cystic tumors of the pancreas: new clinical, radiologic and pathologic observations in 67 patients. *Ann Surg*. 1990;212:432–443.
59. van der Waaij LA, et al. Cyst fluid analysis in the differential diagnosis of pancreatic cystic lesions: a pooled analysis. *Gastrointest Endosc*. 2005;62:383–389.
60. Khalid A, et al. Pancreatic cyst fluid DNA analysis in evaluating pancreatic cysts: a report of the PANDA study. *Gastrointest Endosc*. 2009;69:1095–1102.
61. Anderson MA, et al. PANDA cyst-fluid analysis: eats, shoots and leaves? *Gastrointest Endosc*. 2009;69:1103–1105.
62. Sawhney MS, et al. International consensus guidelines for surgical resection of mucinous neoplasms cannot be applied to all cystic lesions of the pancreas. *Clin Gastroenterol Hepatol*. 2009;7:1373–1376.
63. Kiely JM, et al. Cystic pancreatic neoplasms: enucleate or resect? *J Gastrointest Surg*. 2003;7:890–897.
64. Yeo CJ, et al. Pancreaticoduodenectomy with or without distal gastrectomy and extended retroperitoneal lymphadenectomy for periampullary adenocarcinoma, part 2: randomized controlled trial evaluating survival morbidity and mortality. *Ann Surg*. 2002;236:355–366.
65. Yeo CJ, et al. Pancreaticoduodenectomy with or without extended retroperitoneal lymphadenectomy for periampullary adenocarcinoma: comparison of morbidity and mortality and short-term outcome. *Ann Surg*. 1999;229:613–622.
66. Wood D, et al. Cystadenocarcinoma of the pancreas: neo-adjuvant therapy and CEA monitoring. *J Surg Oncol*. 1990;43:56–60.
67. Neoptolemos JP, et al. A randomized trial of chemoradiotherapy and chemotherapy after resection of pancreatic cancer. *N Engl J Med*. 2004;350:1200–1210.
68. Ohashi K, et al. Four cases of mucin-producing cancer of the pancreas on specific findings of the papilla of Vater. *Prog Dig Endoscopy*. 1982;20:348–351.
69. Basturk O, et al. Pancreatic cysts: pathologic classification, differential diagnosis, and clinical implications. *Arch Pathol Lab Med*. 2009;133:423–438.
70. Adsay NV, et al. Pathologically and biologically distinct types of epithelium in intraductal papillary mucinous neoplasms: delineation of an “intestinal” pathway of carcinogenesis in the pancreas. *Am J Surg Pathol*. 2004;28:839–848.
71. Kloppel G, et al. Pathology and genetics of tumours of the digestive system. *World Health Organization Classification of Tumours*. Lyon, France: IARC Press; 2000.
72. Hruban RH, et al. An illustrated consensus on the classification of pancreatic intraepithelial neoplasia and intraductal papillary mucinous neoplasms. *Am J Surg Pathol*. 2004;28:977–987.
73. Iacobuzio-Donahue CA, et al. DPC-4 protein is expressed in virtually all human intraductal papillary mucinous neoplasms of the pancreas: comparison with conventional ductal adenocarcinomas. *Am J Pathol*. 2000;157:755–761.
74. Adsay NV, et al. Intraductal papillary mucinous neoplasms of the pancreas: pathology and molecular genetics. *J Gastrointest Surg*. 2002;6:656–659.
75. Fritz S, et al. Global genomic analysis of intraductal papillary mucinous neoplasms of the pancreas reveals significant molecular differences compared to ductal adenocarcinoma. *Ann Surg*. 2009;249:440–447.
76. Bournet B, et al. Clinical fate of branch duct and mixed forms of intraductal papillary mucinous neoplasia of the pancreas. *J Gastro Hepatol*. 2009;24:1211–1217.

77. Salvia R, et al. Main-duct intraductal papillary mucinous neoplasms of the pancreas: clinical predictors of malignancy and long-term survival following resection. *Ann Surg.* 2004;239:678–685.
78. Tanno S, et al. Pancreatic ductal adenocarcinomas in long-term follow-up patients with branch duct intraductal papillary mucinous neoplasms. *Pancreas.* 2010;39:36–40.
79. Ingkakul T, et al. Predictors of the presence of concomitant invasive ductal carcinoma in intraductal papillary mucinous neoplasm of the pancreas. *Ann Surg.* 2010;251:70–75.
80. Ishida M, et al. Synchronous and metachronous extrapancreatic malignant neoplasms in patients with intraductal papillary-mucinous neoplasm of the pancreas. *Pancreatol.* 2008;8:577–582.
81. Reid-Lombardo KM, et al. Frequency of extrapancreatic neoplasms in intraductal papillary mucinous neoplasm of the pancreas: implications for management. *Ann Surg.* 2010;251:64–69.
82. Irie H, et al. MR cholangiopancreatographic differentiation of benign and malignant intraductal mucin-producing tumors of the pancreas. *AJR Am J Roentgenol.* 2000;174:1403–1408.
83. Sugiyama M, et al. Two types of mucin-producing cystic tumors of the pancreas: diagnosis and treatment. *Surgery.* 1997;122:617–625.
84. Sugiyama M, Atomi Y. Intraductal papillary mucinous tumors of the pancreas: imaging studies and treatment strategies. *Ann Surg.* 1998;228:685–691.
85. Suzuki Y, et al. Cystic neoplasm of the pancreas: a Japanese multi-institutional study of intraductal papillary mucinous tumor and mucinous cystic tumor. *Pancreas.* 2004;28:241–246.
86. Traverso WL, et al. Intraductal neoplasm of the pancreas. *Am J Surg.* 1998;175:426–432.
87. Yamaguchi K, et al. Mucin-hypersecreting tumors of the pancreas: assessing the grade of malignancy preoperatively. *Am J Surg.* 1996;171:427–431.
88. Sugiyama M, et al. Predictive factors for malignancy in intraductal papillary-mucinous tumors of the pancreas. *Br J Surg.* 2003;90:1244–1249.
89. Taouli B, et al. Intraductal papillary mucinous tumors of the pancreas: helical CT with histopathologic correlation. *Radiology.* 2000;217:757–764.
90. Kubo H, et al. Intraductal papillary-mucinous tumors of the pancreas: differential diagnosis between benign and malignant tumors by endoscopic ultrasonography. *Am J Gastroenterol.* 2001;96:1429–1434.
91. Salvia R, et al. Intraductal papillary mucinous neoplasms of the pancreas with multifocal involvement of branch ducts. *Amer J Surg.* 2009;198:704–714.
92. Ohno E, et al. Intraductal papillary mucinous neoplasms of the pancreas: differentiation of malignant and benign tumors by endoscopic ultrasonography finding of mural nodules. *Ann Surg.* 2009 Oct 24: [Epub ahead of print]
93. Marie F, et al. Intraductal papillary mucinous neoplasms of the pancreas: performance of pancreatic fluid analysis for positive diagnosis and the prediction of malignancy. *Am J Gastroenterol.* 2008;103:2871–2877.
94. Pelaez-Luna M, et al. Do consensus indications for resection in branch duct Intraductal papillary mucinous neoplasm predict malignancy? A study of 147 patients. *Am J Gastroenterol.* 2007;102:1759–1764.
95. Schmidt CM, et al. Intraductal papillary mucinous neoplasms: predictors of malignancy and invasive pathology. *Ann Surg.* 2007;246:644–654.
96. Tanno S, et al. Natural history of branch duct Intraductal papillary mucinous neoplasms of the pancreas without mural nodules: long-term follow-up results. *Gut.* 2008;57:339–343.
97. Sadakari Y, et al. Cyst size indicates malignant transformation in branch duct intraductal papillary mucinous neoplasms of the pancreas without mural nodules. *Pancreas.* 2009 Sept 10: [Epub ahead of print]
98. Salvia R, et al. Branch-duct intraductal papillary mucinous neoplasms of the pancreas: to operate or not to operate? *Gut.* 2007;56:1086–1090.
99. Schnellrdorfer T, et al. Experience with 208 resections for intraductal papillary mucinous neoplasms of the pancreas. *Arch Surg.* 2008;143:639–646.
100. Swartz MJ, et al. Adjuvant chemoradiotherapy after pancreatic resection for invasive carcinoma associated with intraductal papillary mucinous neoplasms of the pancreas. *Int J Radiat Oncol Biol Phys.* 2009 July 31: [Epub ahead of print]
101. Nara S, et al. Clinical significance of frozen section analysis during resection of intraductal papillary mucinous neoplasm: should a positive pancreatic margin for adenoma or borderline lesion be resected additionally? *J Am Coll Surg.* 2009;209:614–621.
102. Papavramidis T, Papavramidis S. Solid pseudopapillary tumors of the pancreas: review of 718 patients reported in English literature. *J Am Coll Surg.* 2005;200:965–972.
103. Geers C, et al. Solid and pseudopapillary tumor of the pancreas: review and new insights into pathogenesis. *Am J Surg Pathol.* 2006:1243–1249.
104. Zinner MJ, et al. Solid and pseudopapillary epithelial neoplasms of the pancreas. *Surgery.* 1990;108:475–480.
105. Yang F, et al. Solid and pseudopapillary tumor of the pancreas: a case series of 26 consecutive patients. *Am J Surg.* 2009;198:210–215.
106. Charfi S, et al. Cystic pancreatic endocrine tumors: an endoscopic ultrasound-guided fine-needle aspiration biopsy study with histologic correlation. *Cancer Cytopathol.* 2009;117:203–210.
107. Bordeianou L, et al. Cystic pancreatic endocrine neoplasms: a distinct tumor type? *J Am Coll Surg.* 2008;206:1154–1158.
108. Schmidt CM, et al. Acinar cell carcinoma of the pancreas in the United States: prognostic factors and comparison to ductal adenocarcinoma. *J Gastrointest Surg.* 2008;12:2078–2086.
109. Toll AD, et al. Acinar cell carcinoma with a prominent intraductal growth pattern: case report with review of the literature. *Int J Surg Pathol.* 2009 July 7: [Epub ahead of print]
110. Itai Y, et al. Pancreatic cysts caused by carcinoma of the pancreas: a pitfall in the diagnosis of pancreatic carcinoma. *J Comput Assist Tomogr.* 1982;6:772–776.

# CANCERS OF THE PERIAMPULLARY REGION AND THE PANCREAS

Christopher L. Wolfgang • Richard D. Schulick • John L. Cameron

Periampullary cancers are composed of a group of malignant neoplasms arising in the region of the ampulla of Vater. These include mainly adenocarcinomas of the head of the pancreas, ampulla of Vater, distal bile duct (cholangiocarcinoma), and duodenum. Less commonly, acinar cell carcinomas or pancreatic endocrine neoplasms occur in the periampullary region of the pancreas. Periampullary cancers are often discussed as a group based on their similar presentation, workup, and surgical management. In addition, pancreas cancer is also discussed with this group since the natural history for both proximal and distal pancreatic lesions is similar—differing mainly in the type of resection performed.

The first successful resection of a periampullary tumor was performed by Halsted in 1898. He described a local ampullary resection with reanastomosis of the pancreatic and bile ducts to the duodenum in a patient who presented with obstructive jaundice.<sup>1</sup> In the early part of the 20th century, most periampullary cancers were managed by a transduodenal approach similar to that first reported by Halsted. Codivilla is often credited with performing the first en bloc resection of the head of the pancreas and duodenum for periampullary carcinoma, but this patient did not survive beyond the early postoperative period.<sup>2</sup> The first successful two-stage pancreaticoduodenectomy was performed in Germany by Kausch in 1909.<sup>3</sup> In 1914, Hirschel reported the first successful one-stage pancreaticoduodenectomy.<sup>4</sup> Pancreaticoduodenectomy was not popularized until Whipple and colleagues reported three successful, two-stage, en bloc resections of the head of the pancreas and the duodenum in 1935.<sup>5</sup> Over the next decade, a number of modifications and technical refinements were made in the procedure, including the first one-stage pancreaticoduodenectomy, reported in the United States by Trimble in 1941. The procedure was infrequently performed despite technical advances, until the 1980s because of the formidable operative morbidity, mortality, and the poor prognosis associated with periampullary cancers.

Currently, the resection of periampullary cancer with a pancreaticoduodenectomy is performed routinely at many

referral centers and carries a mortality of approximately 2%. Moreover, significant advances have been made in understanding of the pathogenesis, biology, and staging of periampullary carcinoma in the past two decades.

## INCIDENCE

Periampullary carcinomas are a major public health concern throughout the world. Pancreatic cancer is the fourth leading cause of cancer death in the United States. In 2009, there were an estimated 35,240 deaths in the United States compared to 159,390 deaths for lung cancer, 49,920 for colorectal cancer, and 40,610 for breast cancer.<sup>6</sup> The incidence of pancreatic carcinoma rose dramatically from the 1930s until the mid-1970s, nearly doubling during this time period. Since 1973, the incidence in the United States has remained stable at about 8–9 per 100,000 of population. The incidence in Western Europe is similar to that in the United States and has also remained stable during the past three decades. In Europe, pancreatic cancer is the sixth leading cause of cancer death. In Japan, however, a dramatic increase has been observed during the last three decades, although the overall incidence is still less than that observed in the West. The lowest incidence worldwide is seen in parts of the Middle East and in India. Worldwide, over 200,000 people die annually of cancer of the pancreas.<sup>7</sup>

The incidence of periampullary carcinoma increases with age, and the majority of patients present in or beyond their sixth decade of life. There is a slight male preponderance, and African American males have the highest overall incidence in the United States.

## PATHOLOGY

The most common cancer types of the periampullary region and pancreas are the adenocarcinomas. These neoplasms are



thought to arise from their respective epithelial layer and histologically are characterized by unorganized gland forming structures within a stromal background. Review of pancreaticoduodenectomy specimens from high-volume centers reveals that 40–60% are adenocarcinomas of the head of the pancreas, 10–20% are adenocarcinomas of the ampulla of Vater, 10% are distal bile duct adenocarcinomas, and 5–10% are duodenal adenocarcinomas. Because these data represent resected specimens and because the resectability rate of the nonpancreatic periampullary cancers is much higher, it is likely that pancreas cancer is the site of origin in up to 90% of cases.<sup>8,9</sup> Given the close proximity of the pancreatic duct, the distal bile duct, the ampulla of Vater, and the periampullary duodenum, the site of origin of a periampullary malignancy can at times be difficult to determine. Various sarcomas including gastrointestinal (GI) stromal tumors, fibrosarcomas, leiomyosarcomas, hemangiopericytomas, and histiocytomas may also arise in the periampullary region. Similarly, lymphomas can occur in these regions and present with less well-defined margins than the typical adenocarcinomas. Finally, the periampullary region can be the site of metastases from other primaries, including kidney, breast, lung, melanoma, stomach, colon, and germ cell primaries. Pancreatic ductal adenocarcinoma is by far the most common malignant histologic type of pancreatic carcinoma regardless of location within the pancreas. However, more than two-thirds of these tumors arise in the pancreatic head, neck, or uncinate process. Other rare histologies include acinar, squamous, pancreatic endocrine neoplasms (islet cell tumors), or tumors of nonepithelial origin. Pancreatic endocrine neoplasms may be either benign or malignant and may be functional with hormone production, resulting in clinical manifestations. Cystic neoplasms of the pancreas can also arise from the exocrine pancreas and are classified as benign serous cystadenomas, potentially malignant mucinous cystadenomas, and intraductal papillary mucinous neoplasms (IPMNs).

## ENVIRONMENTAL RISK FACTORS

There are few established risk factors for cancer of the pancreas. They include tobacco smoking and inherited susceptibility, which account for only 5–10% of cases. Chronic pancreatitis, type 2 diabetes mellitus, and obesity have been consistently associated with pancreatic cancer and are weak risk factors. Other possible risk factors include physical inactivity, certain pesticides, and high carbohydrate/sugar intake. Cholecystectomy, cholelithiasis, coffee consumption, and alcohol have all been sporadically associated with the development of pancreatic cancer, but they are unlikely true risk factors.

There is a significant amount of evidence that links cigarette smoking to pancreas cancer. Multiple animal studies have demonstrated the carcinogenic effects of tobacco smoke and nitrosamines on the pancreas. Human autopsy studies have revealed increases in hyperplastic changes with atypical nuclear patterns in pancreatic ductal cells of cigarette smokers. Several prospective studies have demonstrated an increased

risk ratio of death from pancreatic cancer in smokers ranging from two- to 16-fold.<sup>10</sup> Many of the studies have demonstrated a dose-response relationship with either the number of cigarettes smoked or the duration of smoking.

There are numerous conflicting data in reviews examining the relationship of dietary factors and cancer of the pancreas.<sup>10–12</sup> Pancreas cancer seems to be associated with increased total calorie intake, as well as increased intake of carbohydrate, cholesterol, meat, salt, dehydrated food, fried food, refined sugar, and nitrosamines. Fat, beta carotene, and coffee are of unproven risk. Consumption of dietary fiber, vitamin C, fruits, vegetables, and unprepared food may have a protective effect, as may pressure and microwave cooking.

Alcohol, coffee, and radiation do not appear to be significant risk factors for development of pancreas cancer. When age, gender, smoking, amount of alcohol consumed, and socioeconomic class were controlled, three case-control studies from Europe did not demonstrate an increased risk of pancreatic cancer with coffee.<sup>10</sup> This is in disagreement with earlier reports of the association between pancreas cancer and coffee consumption.<sup>13,14</sup> Ionizing radiation does not seem to have a propensity to cause pancreas cancer when compared to other tissues. The survivors of the bombings of Hiroshima and Nagasaki have not shown an increased risk.<sup>15,16</sup>

Chronic pancreatitis has been associated with cancer of the pancreas.<sup>10,17–19</sup> It is hard, however, to determine whether this is a causative condition or whether chronic pancreatitis may represent an indolent presentation of pancreatic cancer. The association of type 2 diabetes and pancreatic cancer is similarly implicated in multiple studies.<sup>20,21</sup> Again, it is difficult to distinguish whether diabetes is an early symptom of pancreas cancer or whether it is truly a causative factor.

Distal common bile duct, ampullary, and duodenal cancers are less common than pancreatic cancer and are less well characterized in terms of their risk factors. All are more common in the elderly with peak incidences in the 60- to 80-year range. Distal common bile duct cancers are associated with several known host factors in addition to advanced age, including inflammatory bowel disease, sclerosing cholangitis, choledochal cysts, and intrahepatic or common bile duct stones.

## HEREDITARY RISK FACTORS

The hereditary risk factors for pancreatic cancer have been the most studied among the periampullary cancers. It is estimated that approximately 10% of all pancreatic cancers are hereditary. Most of these are associated with well-known, but relatively rare, hereditary syndromes that have been previously described for other cancer types. These include hereditary nonpolyposis colorectal cancer (HNPCC), familial breast cancer associated with the BRCA2 mutation, Peutz-Jeghers syndrome, ataxia-telangiectasia syndrome, familial atypical multiple mole-melanoma syndrome (FAMMM), and hereditary pancreatitis. It is also becoming clear that pancreatic

cancer also runs in some families and is not associated with any of the known genetic syndromes. So-called familial pancreatic cancer is being studied by the Johns Hopkins Hospital group who have amassed data on a large number of families with this condition. Members of families with two or more first-degree relatives affected by pancreatic cancer in the National Familial Pancreas Tumor Registry (NFPTR) have a 16-fold increased risk of developing pancreas cancer. This increased risk could be attributable to either a genetic basis or environmental exposure, but there is strong evidence that the familial aggregation has some genetic basis.<sup>22</sup>

Duodenal and ampullary cancers occur with increased frequency in patients with hereditary polyposis syndromes, including HNPCC, Peutz-Jeghers syndrome, familial adenomatous polyposis, and Gardner's syndrome.

## GENETIC ALTERATIONS

As with all cancers, periampullary cancers are diseases of genetic alterations. Over the past decade our understanding of the genetics behind cancer has burgeoned. The development of high-throughput DNA sequencing, gene expression, and the field of genomics have been the driving force behind this expansion of knowledge. The entire sequence of the human genome has recently been made publically available (International Human Genome Sequencing Consortium, 2004),<sup>23,24</sup> and through additional efforts we now have an understanding of the normal genetic variation among individuals and populations of people (International HapMap Consortium, 2007).<sup>25</sup> This information has set the stage for the global assessment of genetic alterations associated with the development of specific cancers.

The best example of the application of this knowledge to the study of periampullary cancers is that of pancreatic cancer.<sup>26</sup> Using the genetic material from approximately 100 patients with pancreatic cancer, a team of researchers at Johns Hopkins Hospital sequenced the "pancreatic cancer genome." Interestingly, pancreatic cancers contain an average of 48 genetic alterations. These alterations, consisting of mutations, deletions and amplifications cluster in 12 cell signaling pathways that are known to be important for cellular growth and differentiation. Most of these mutations were already identified as being involved with pancreatic cancer while several novel mutations were discovered. The frequency with which each one of these mutations occurs within the population of pancreatic cancer patients in this study is supported by previous work involving individual genes. For example, the most commonly altered genes in the pancreatic cancer genome project include *K-ras*, *p53*, *p16*, and *DPC4*. This is consistent with the results of Rozenblum and associates who analyzed pancreas cancers from 42 patients and found that all of them (100%) had mutations in the proto-oncogene *K-ras*, and 82%, 76%, and 53% had mutations in the tumor suppressor genes *p16*, *p53*, and *DPC4*, respectively.<sup>27</sup>

The genetics behind the other periampullary cancers is less well characterized. This is likely due to their less common incidence in comparison to pancreatic cancer. It is interesting that what limited information is known of the genetic alterations associated with certain other periampullary adenocarcinoma shows similarities and striking differences to that of pancreatic adenocarcinoma. For example, 40–60% of patients with ampullary adenocarcinoma have alterations of either *p53* or *p16* similar to pancreatic adenocarcinoma.<sup>28</sup> In contrast, at most 50% of ampullary adenocarcinomas carry an activating *K-ras* mutation and the *APC* gene, which plays a minimal role in pancreatic cancer, is frequently altered in ampullary cancer.

## DIAGNOSIS AND PREOPERATIVE EVALUATION

The diagnosis of periampullary cancer is made on the basis of clinical presentation, laboratory data, and radiologic workup. The key determination in the workup of a periampullary cancer is that of resectability. Those patients with a resectable lesion based on overall patient health, absence of distant spread, and local tumor relationships should proceed to a potentially curative resection. Although in some situations a preoperative tissue diagnosis is available, treatment should not be delayed by attempts to obtain histologic confirmation of malignancy. In patients, who are deemed to be unresectable, a tissue diagnosis is often required before the commencement of palliative therapy.

## Clinical Presentation

Patients with periampullary cancer often have only vague symptoms early in the course of their disease. Often, it is not until the later stages that patients will develop more definitive symptoms. The symptoms at presentation are related to the location of the tumor. Lesions occurring in or near the bile duct are much more likely to present with obstructive jaundice, whereas those presenting in the body or tail are more likely to present with pain. Two-thirds to three-fourths of patients with pancreas cancer present with the classic constellation of symptoms indicative of obstructive jaundice: jaundice, pruritus, acholic stools, and tea-colored urine. Contrary to popular teaching, patients with pancreas cancer often experience pain as a part of their symptoms. Albeit early in the course of the disease, the pain is often vague and involving the upper abdomen, epigastrium, or back. Later in the course of the disease, this pain can progress to severe pain often radiating to the back. Patients may also present with other general symptoms, including anorexia, fatigue, malaise, and weight loss. Nausea and vomiting may herald gastric outlet obstruction from duodenal involvement and is an ominous sign of locally advanced disease.

Patients may also present with very subtle signs such as the presence of elevated liver function tests performed on routine

laboratory screening, new-onset diabetes mellitus, or anemia from gastrointestinal blood loss, usually from tumor erosion into the duodenum. Patients may also present with acute pancreatitis from obstruction of the pancreatic duct. Therefore, elderly patients who present with acute pancreatitis in the absence of a history of alcohol use or gallbladder stones should be screened for a pancreatic or periampullary cancer.

Patients with a distal common bile duct cancer are even more likely to present with obstructive jaundice than those with pancreas cancer because the tumor does not have to be very large to obstruct the duct. Patients with pancreas cancers involving the body or tail of the gland are more likely to have weight loss and abdominal pain rather than jaundice as their presenting complaints. Because tumors can grow to a larger size before producing noticeable symptoms, pancreas cancers in the body and tail are often diagnosed at a later stage and have a poorer prognosis.

Physical findings on examination include scleral icterus, jaundice, hepatomegaly, a palpable gallbladder (Courvoisier's sign), and skin excoriation from pruritus and scratching. Signs of advanced disease include cachexia, palpable nodules in the liver, palpable metastatic disease in the left supraclavicular fossa (Virchow's node), palpable metastatic disease in the periumbilical area (Sister Mary Joseph's node), and pelvic metastatic disease palpable anteriorly on rectal examination (Blumer's shelf).

Patients who present with obstructive jaundice have elevated serum levels of bilirubin and alkaline phosphatase, usually associated with only mild to moderate elevations in liver transaminases. Long-term obstruction of the biliary tree may also lead to coagulopathy and prolongation of protime because of decreased absorption of vitamin K and the effect on the clotting factors of the intrinsic pathway. There are no great serum markers for pancreas cancer to facilitate early diagnosis. A marker commonly used is carbohydrate antigen 19-9 (CA 19-9) that is elevated in 75% of patients with pancreas cancer. Unfortunately, CA 19-9 levels are also elevated in benign conditions of the pancreas, liver, and bile ducts. CA 19-9 is neither sensitive nor specific enough to be used in population screening. It is sometimes of use in trying to measure response to therapy or for screening for recurrence in a patient who originally had an elevation of the marker.

Because approximately 90% of pancreatic cancers contain mutations in the *K-ras* protooncogene, several groups have tried to detect these mutations from duodenal aspirates, pancreatic duct aspirates, and stool.<sup>29-31</sup> These tests have not become clinically useful, but this type of strategy will be necessary to detect disease at an earlier stage.

## Imaging Studies

The main imaging modalities used for patients with suspected periampullary neoplasms include right upper quadrant (RUQ) ultrasonography, computed tomography (CT), magnetic resonance imaging (MRI) with or without magnetic

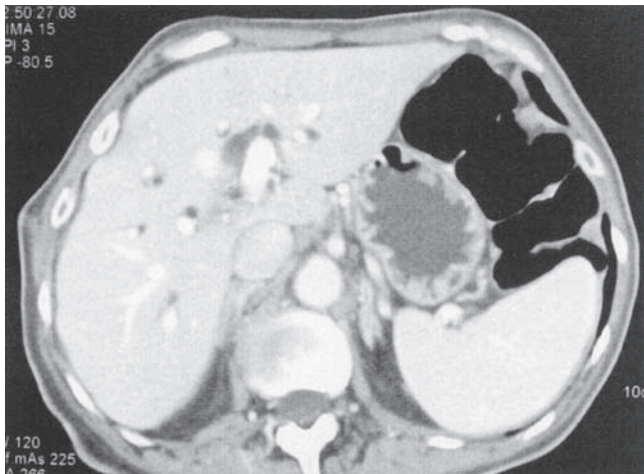
resonance cholangiopancreatography (MRCP), endoscopic ultrasound (EUS), endoscopic retrograde cholangiopancreatography (ERCP), and percutaneous transhepatic cholangiography (PTC). The role of positron emission tomography (PET) has not been clearly established for pancreatic and the other periampullary cancers. Over the last 10 years, there has been a trend away from the invasive imaging studies (ERCP and PTC), toward the noninvasive imaging studies. This is especially true as surgeons have become more willing to operate on jaundiced patients based on clinical presentation and imaging studies.

RUQ ultrasonography is a commonly used initial test and is very sensitive for the detection of gallstones, the presence of a dilated biliary tree, and whether acute cholecystitis is causing a patient's RUQ pain. This study is commonly available around the clock and heavily used in emergency departments. In addition to gallstones, dilation of the biliary tree, and pericholecystic fluid, this imaging modality can also pick up hepatic metastases, pancreatic masses, peripancreatic and hilar lymphadenopathy, and ascites. The sensitivity for demonstrating pancreatic masses is not high, and the absence of a pancreatic mass by RUQ ultrasonography does not rule out the presence of one in the patient.

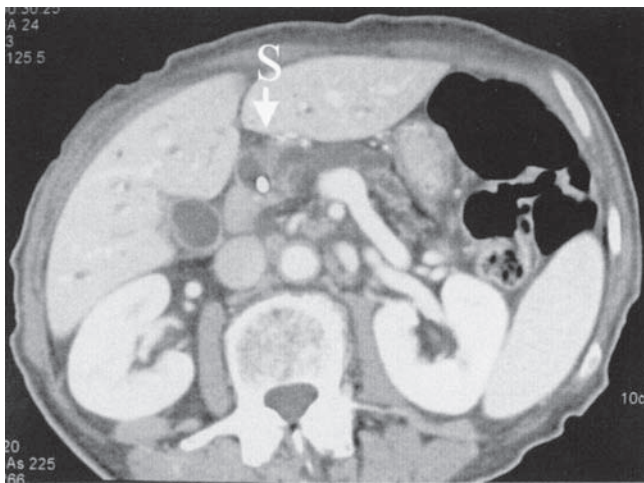
The "workhorse" in the workup of patients suspected of a pancreatic cancer or a periampullary neoplasm is a multidetector spiral CT and is probably the single most useful diagnostic and staging modality (Fig. 59-1).<sup>32</sup> If a pancreatic mass is identified by another modality, spiral CT is often indicated, because CT provides more complete and accurate imaging of the pancreatic head and surrounding structures. It has largely supplanted ultrasound as the initial diagnostic procedure of choice. Pancreatic cancer is much more likely to be visible on a spiral CT than a distal common bile duct, ampullary, or duodenal cancer. It gives very important information about the immediately adjacent vascular structures such as the portal, superior mesenteric, and splenic veins, as well as the superior mesenteric artery (SMA) and celiac axis. Three-dimensional (3D) reconstruction of these vessels from thin cut multidetector spiral CT scans performed in both arterial and venous phase may also help in visualizing the anatomic relationships between the vessels and the mass (Fig. 59-2). The involvement of periampullary lymph nodes and retroperitoneal structures may be demonstrated. Additionally, information about distant metastatic disease can be gleaned if metastatic deposits are seen in the liver or in the peritoneal cavity. The presence of ascites is usually an ominous sign.

When both intra- and extrahepatic ductal dilations are found on imaging studies but no discrete mass lesion is seen on CT, cholangiography may be useful. Advances in MRI technology allow this modality to play an increasing role in hepatobiliary imaging (Fig. 59-3). Ultrafast spin-echo MRI can also be quite sensitive, but it can be limited by motion artifact, lack of bowel opacification, compromised resolution, and patient discomfort from the longer scanning times.<sup>32</sup> MRCP is now being used to image the biliary tree and the pancreatic duct. It has the advantage of being completely noninvasive (Fig. 59-4). This is also

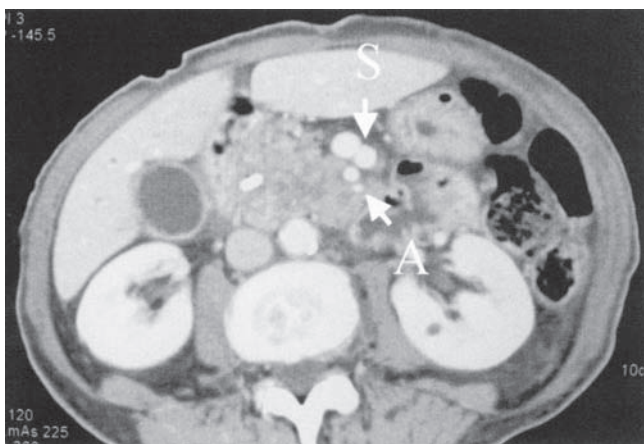




A

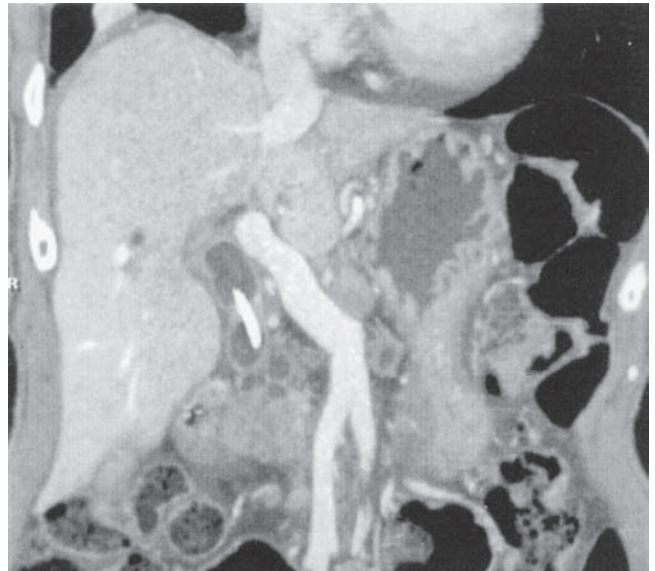


B

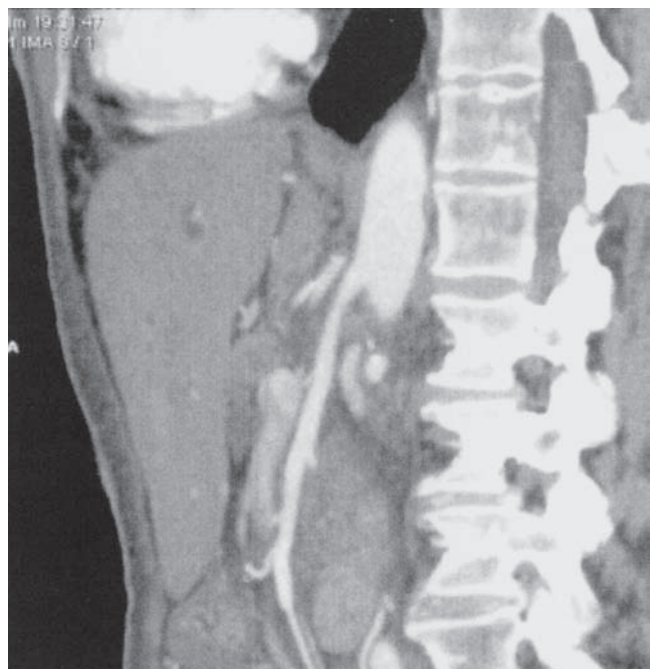


C

**FIGURE 59-1** CT scan of a patient with obstructive jaundice from pancreas cancer. **A.** Dilated intrahepatic ducts. **B.** “Double-duct sign” with dilated common bile duct and pancreatic ducts. There is a stent in the common bile duct (S). **C.** Pancreas cancer mass with stent through it (arrow). Superior mesenteric artery (SMA) (A) is adjacent to tumor.



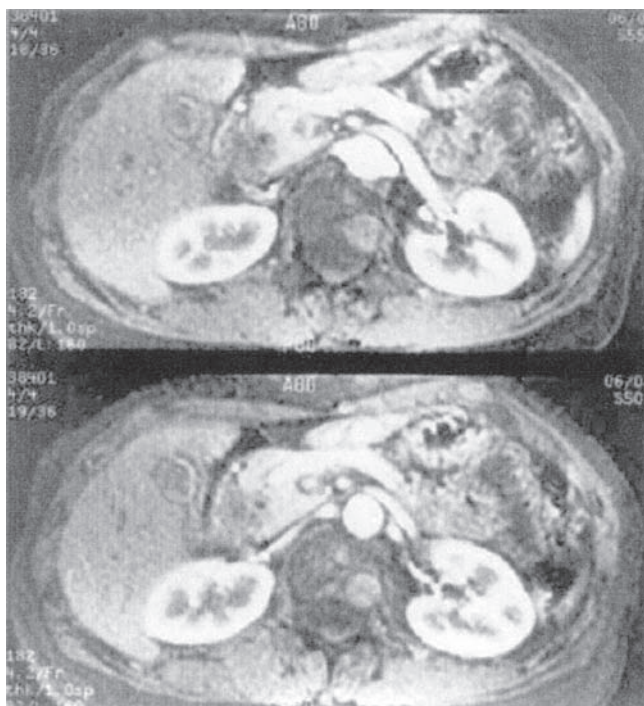
A



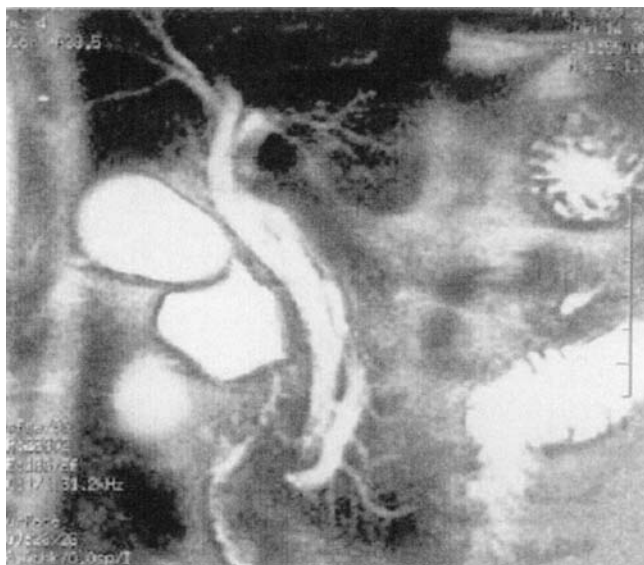
B

**FIGURE 59-2** Three-dimensional CT vascular reconstructions of same patient as in Fig. 59-1. **A.** Portal and superior mesenteric veins do not appear involved. **B.** Superior mesenteric artery (SMA) does not appear involved.

its main disadvantage secondary to the lack of immediate access to perform a therapeutic intervention such as removal of a stone, stenting of a lesion causing proximal biliary or distal pancreatic stasis and infection. The vascular structures can also be visualized with the use of the contrast agent gadolinium and the performance of a magnetic



**FIGURE 59-3** T1-weighted MR images with gadolinium contrast. A mass in the head of the pancreas appears hypodense. (Reproduced with permission from Yeo CJ, et al. Pancreatic cancer. *Curr Probl Surg.* 1999;Feb;36(2):59–152.)



**FIGURE 59-4** Single-shot spin-echo MR cholangiopancreatogram of patient with obstructive jaundice. Both the common bile duct and the pancreatic duct are dilated. The hypointense tumor is apparent in the periampullary region. (Reproduced with permission from Yeo CJ, et al. Pancreatic cancer. *Curr Probl Surg.* 1999;Feb;36(2):59–152.)

resonance angiogram (MRA). Thus a single (long) session in a scanner can provide information about tumor size and extent (MRI), the intraductal anatomy of the biliary and pancreatic system (MRCP), and the status of the nearby vasculature (MRA). The resulting scan has the potential to provide information about tumor size and extent, biliary and pancreatic ductal anatomy, and vascular involvement through a single, noninvasive procedure.

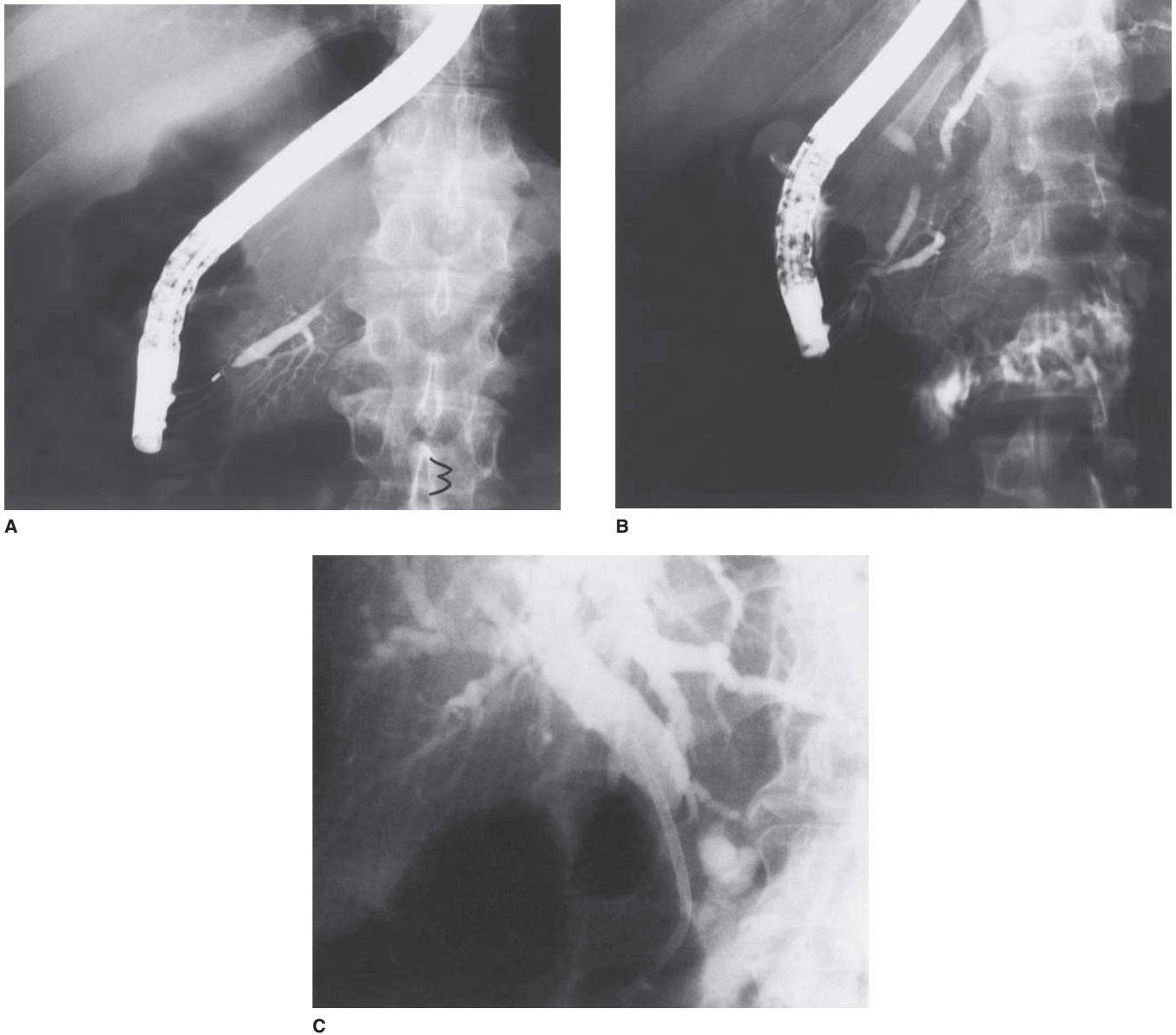
ERCP sometimes is required to solidify the diagnosis of pancreatic cancer. The classic findings of a long, irregular stricture in a pancreatic duct with distal dilation or a “double duct sign” in which there is cutoff of both the pancreatic duct and distal bile duct at the level of the genu of the pancreatic duct are pathognomonic (Fig. 59-5). With the current imaging capabilities of CT and MRI, diagnostic ERCP is rarely necessary to guide treatment. However, many patients still show up in surgery clinic already having had an ERCP performed. ERCP may be of benefit in patients with biliary obstruction and cholangitis whereupon an endoscopic stent can be placed for decompression. ERCP is most useful when there is pancreatic duct obstruction, but no mass is evident on either CT or MRI. In this situation, it is necessary to try to distinguish chronic pancreatitis from pancreatic cancer. A history of heavy alcohol consumption in the setting of abdominal pain and multiple focal stenoses of the main pancreatic duct as well as radicals is more compatible with pancreatitis, whereas an abrupt cutoff of the pancreatic duct at a single location in an elderly patient without significant pain is more compatible with pancreas cancer.

PTC is another invasive means of defining the biliary anatomy and better defines the proximal biliary anatomy above the level of obstruction (Fig. 59-6). During this procedure a percutaneous biliary drain (PBD) can also be left in place for the relief of cholangitis. The disadvantages of PTC are a result of the more invasive nature of this technique and include bleeding, hemobilia, and patient discomfort, as well as the inability to visualize the pancreatic duct. For periampullary cancer, ERCP is more commonly used than PTC or PBD.

The role of PET in the preoperative staging periampullary cancers is evolving. One theoretical advantage is the ability to differentiate between benign and malignant lesions, and there are reports of PET scans identifying CT-occult *primary* pancreatic cancers in patients with unclear etiology of painless jaundice.<sup>33,34</sup> Its application for this use, however, is limited, because most of these patients will be offered resection based on clinical suspicion for malignancy regardless of PET results. The main application of PET in the evaluation of patients with pancreatic cancer has been for the clarification of the presence of metastases. Several studies have reported PET to be more sensitive than CT alone in identifying metastatic disease.<sup>33,34</sup> Although PET is able to identify metastatic disease in sites other than liver, its efficacy in relation to other modalities has not been established in this regard.

Upper endoscopy is useful in the diagnosis of ampullary and duodenal cancers as these lesions can be directly viewed



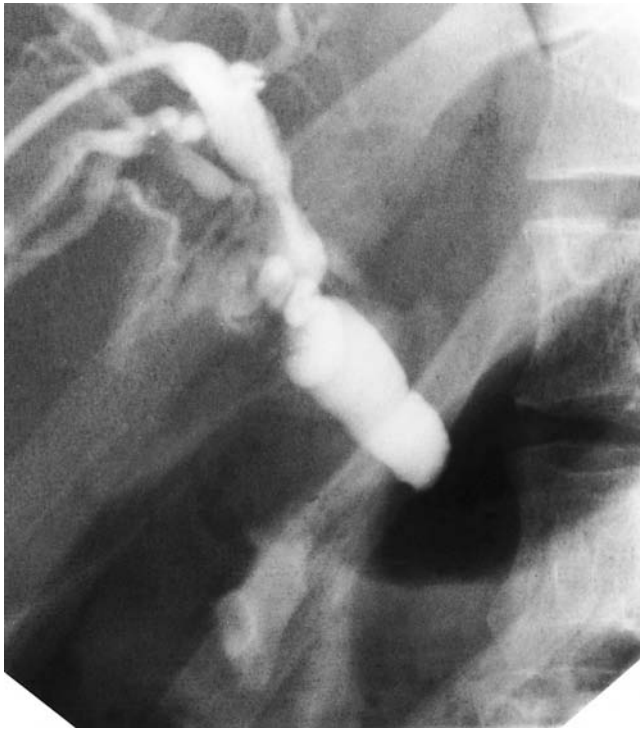

**FIGURE 59-5** **A.** Endoscopic retrograde cholangiopancreatogram (ERCP) of patient with pancreas cancer with abrupt cutoff of main pancreatic duct secondary to tumor. **B.** ERCP of patient with pancreas cancer with obstruction of both main pancreatic duct and common bile duct. **C.** Completion cholangiogram after endoscopic placement of endoprosthesis. (Reproduced with permission from Lillemoe KD. Current management of pancreatic carcinoma. *Ann Surg.* 1995;Feb;221(2):133–148.)

through the endoscope. If visualized, it is relatively straightforward to obtain a biopsy and tissue diagnosis. Additionally, EUS may be performed during upper endoscopy. The duodenum, ampulla, head of the pancreas, and uncinate process of the pancreas are accessible with an ultrasound probe positioned in the duodenum. The body and tail of the pancreas are accessible with an ultrasound probe positioned in the stomach. Fine-needle aspiration (FNA) of any suspected lesions can be performed at the same time as EUS if tissue diagnosis is of benefit.

## Tissue Diagnosis

A tissue diagnosis of adenocarcinoma is not required prior to an attempt at a curative resection in most cases. The presentation of jaundice and weight loss along with a pancreatic mass or stricture of the distal bile duct should be considered carcinoma until proven otherwise in a patient with appropriate risk factors. Biopsies by EUS, or less commonly by percutaneous means, can easily be performed, but malignancy cannot be ruled out with certainty when no malignant cells



**FIGURE 59-6** Percutaneous transhepatic cholangiogram (PTC) of patient demonstrating a dilated intrahepatic biliary tree with complete obstruction at the genu of the common bile duct. (Reproduced with permission from Lillemoe KD. Current management of pancreatic carcinoma. *Ann Surg.* 1995;Feb;221(2):133–148.)

are found in the FNA aspirate. Thus, a negative biopsy in a patient suspected of having pancreas cancer with a low operative risk and apparently resectable disease will not alter the decision to explore the patient. Several exceptions to this paradigm exist. Patients undergoing neoadjuvant therapy require a tissue diagnosis prior to the institution of therapy. In addition, the diagnosis of adenocarcinoma may be uncertain in the workup of a pancreatic mass. Neuroendocrine cancers, lymphomas, cystic lesions, and even nonneoplastic condition may not appear distinct on CT imaging. In these cases EUS-guided FNA may yield a tissue diagnosis and alter the therapeutic management.

As discussed in the previous section, FNA may be performed at the same time as EUS and may be a more attractive means of obtaining a tissue diagnosis. EUS can be performed safely with rare complications that include fistula, pancreatitis, hemorrhage, abscess, tumor seeding, and death.

Tissue diagnoses of ampullary and duodenal cancers are relatively straightforward and can easily be performed through the endoscope. Because of their locations, the ability to obtain large and deep biopsies allows better sampling. However, the histologic finding of a benign villous adenoma with or without dysplasia cannot reliably rule out malignancy. Distal common bile duct lesions are sometimes scraped with brushes or biopsied via ERCP or PTC in order to obtain a tissue diagnosis.

It is often difficult to preoperatively establish the histologic diagnosis of a distal bile duct cancer with false-negative rates nearing 50%.

## Preoperative Biliary Decompression

A common clinical feature of periampullary cancers is the presence of jaundice. This condition is often associated with severe pruritus, coagulopathy resulting from the impaired absorption of the fat-soluble vitamin K and less commonly cholangitis. These conditions are often managed preoperatively by biliary decompression through PTC/BD or ERCP. However, unlike hepatectomy in which preoperative jaundice has clearly been associated with an increased risk of morbidity and mortality, the same has not been shown for the resection of periampullary cancer. As a result, biliary decompression is not an absolute requirement prior to resecting a periampullary cancer in jaundiced patients. However, many factors make the use of preoperative biliary decompression both common and acceptable. These include treatment of patients with neoadjuvant therapy, organization of referral to specialist, and limited operating room availability at high-volume centers.

Most studies have demonstrated that only wound infections are increased in patients with periampullary cancers undergoing preoperative biliary decompression.<sup>35,36</sup> The largest series on this topic comes from the Johns Hopkins Hospital.<sup>36</sup> In their analysis of 567 patients, only the risk of wound infection was increased in patients undergoing preoperative biliary decompression. Mortality was equivalent in both the stented and unstented groups. Similar results were found in another large series of 300 patients from M.D. Anderson Cancer Center.<sup>35</sup>

## Preoperative Staging

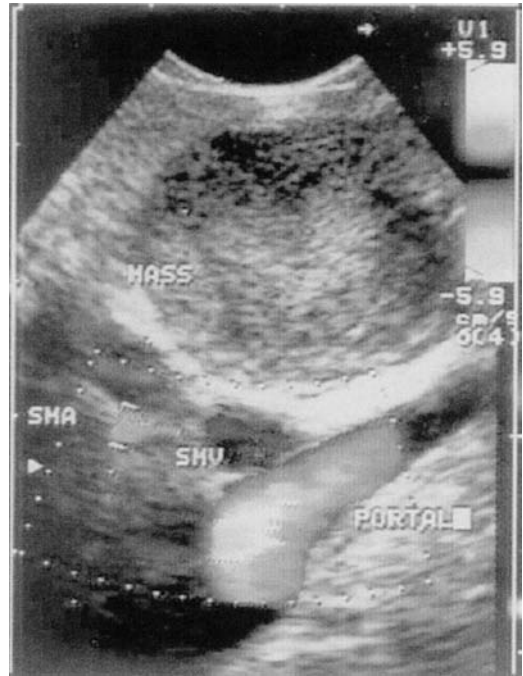The goal of preoperative staging of pancreas and other periampullary cancers is to determine the optimal treatment for each individual patient. Substantial overlap exists between diagnosis and staging. Multidetector thin slice spiral CT with intravenous contrast is useful in both diagnosis and staging. It can detect liver metastases with high sensitivity if they are over 1 cm, but it often misses those that are less than 1 cm in size. CT scans are not highly accurate in assessing retroperitoneal lymphadenopathy or carcinomatosis in the absence of ascites or large pockets of metastases.<sup>32</sup> Generally, a CT scan of the chest (with or without intravenous contrast) is often performed during the preoperative staging CT. The cost-effectiveness of this approach is often questioned, and some surgeons prefer a simple chest radiograph. However, when the patient is referred postoperatively for adjuvant or palliative therapy, a staging CT including the chest is usually required. It is rare for pancreas or the other periampullary cancers to metastasize exclusively to the lungs without any signs of dissemination in the abdominal cavity.



Three-dimensional reconstruction of CT scans has also increased the ability to predict resectable disease because of the capability to focus on the vasculature at risk. In a study of 140 patients who were thought to have resectable periampullary tumors after preoperative 3D-CT, 115 (82%) were subsequently determined to have periampullary cancer.<sup>37</sup> The remaining 25 patients had benign disease. Among the patients with periampullary cancer, the extent of local tumor burden involving the pancreas and peripancreatic tissues was accurately depicted by 3D-CT in 93% of the patients. Three-dimensional CT was 95% accurate in determining cancer invasion of the superior mesenteric vessels. Preoperative 3D-CT accurately predicted periampullary cancer resectability and a margin-negative resection in 98 and 86% of patients, respectively. For patients with pancreatic adenocarcinoma (n = 85), preoperative 3D-CT resulted in a resectability rate and a margin-negative resection rate of 79 and 73%, respectively. The ability of 3D-CT to predict a margin-negative resection for periampullary cancer, including pancreatic adenocarcinoma, relies on its enhanced assessment of the extent of local tumor burden and involvement of the mesenteric vascular anatomy. Encasement of the portal or superior mesenteric vein over a distance not amenable to vascular reconstruction after resection, and/or encasement of the superior mesenteric, celiac, or hepatic arteries with or without occlusion are ominous signs and portend unresectability.

EUS is sometimes used to stage patients with periampullary lesions, especially if an FNA diagnosis is important in the decision to operate (Fig. 59-7). It is highly accurate in assessing the size of the primary lesion. More information is needed to adequately assess its accuracy in predicting vascular involvement. It is very operator dependent and in borderline cases may lead to the overcall of vessel involvement. EUS is poor at predicting lymph node involvement or liver metastases unless they are quite sizable.

The use of staging laparoscopy prior to an attempt at resection of a periampullary cancer varies widely among institutions. The variance in its application is related to the confidence with which the preoperative diagnosis of carcinomatosis or small hepatic metastases can be made. Proponents of routine use of laparoscopy feel that its use will save significant numbers of patients from the morbidity and mortality of exploratory laparotomy only to find metastatic unresectable disease. They feel that if a patient cannot be resected for potential cure, they are best palliated by nonoperative means.<sup>38</sup> The general argument made against routine laparoscopy are that current cross-sectional imaging studies are sensitive enough to identify patients who have abdominal metastases and thus does not justify the added expense of laparoscopy. They further argue that as many as 20% of the unresectable patients will go on to develop gastric outlet obstruction requiring surgical intervention.<sup>39</sup> Additionally they feel that operative chemical splanchnicectomy will be of benefit. Most high-volume hepatobiliary and pancreatic surgeons will selectively use staging laparoscopy.<sup>40</sup> The likelihood of finding disease that is unresectable is highest in



**FIGURE 59-7** Endoscopic ultrasound (EUS) image with linear array echoendoscope demonstrating a mass in the head of the pancreas with no vascular invasion of the superior mesenteric artery (SMA), superior mesenteric vein (SMV), or portal vein (PORTAL). (Reproduced with permission from Yeo CJ, et al. Pancreatic cancer. *Curr Probl Surg.* 1999;Feb;36(2):59–152.)

those with pancreas cancers involving the body or tail or uncinate process. These lesions usually are larger and more advanced at the time of diagnosis because they do not tend to cause obstructive jaundice. The likelihood of finding disease that is unresectable is lower for duodenal, ampullary, and distal common bile duct cancer compared to pancreas cancer.

## CLINICOPATHOLOGIC STAGING

Patients with exocrine pancreatic, distal bile duct, ampullary, and duodenal carcinomas are staged according to the American Joint Committee on Cancer (AJCC) staging system. These staging criteria are based on the size and extent of the primary tumor (T stage), lymph node involvement (N stage), and the presence of distant metastases (M stage). Based on these criteria, patients are stratified to the different stage groupings that guide prognosis and treatment. Pancreatic adenocarcinomas are staged using the AJCC exocrine pancreas guidelines. Distal common bile duct cancers are staged using the AJCC extrahepatic bile duct guidelines. Ampullary cancers are staged using the AJCC ampulla of Vater guidelines. Duodenal cancers are staged using the AJCC small intestine guidelines.

## RESECTION OF PERIAMPULLARY CANCERS

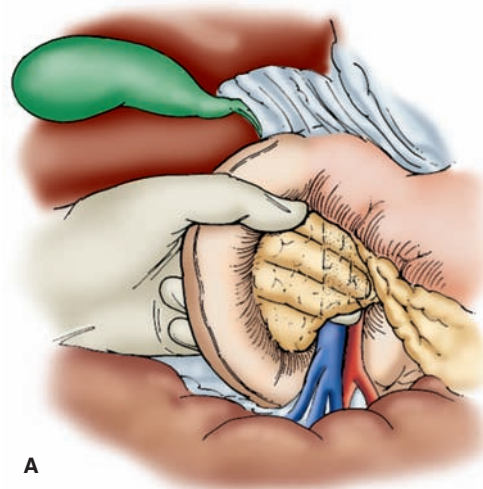
### Operative Technique of Pancreaticoduodenectomy (Whipple Procedure)

Exposure for a pancreaticoduodenectomy can be performed through a vertical midline incision from the xiphoid process to several centimeters below the umbilicus. Alternatively, a bilateral subcostal incision can be used. Exposure is greatly enhanced with the use of a mechanical retracting device.

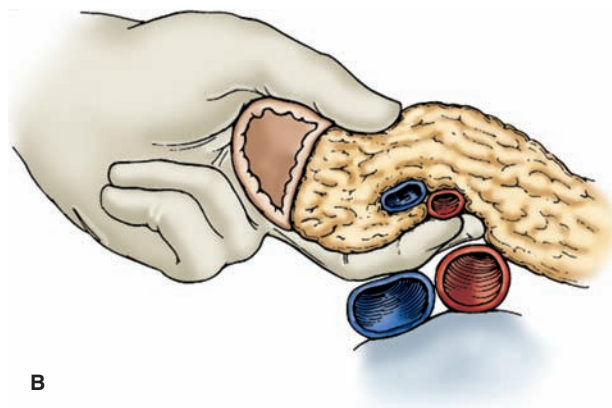
The first portion of a pancreaticoduodenectomy is devoted to assessing the extent of disease and resectability. The benefits and disadvantages of staging laparoscopy were discussed in the previous section. At open exploration, the entire liver is assessed for the presence of metastases not seen by preoperative imaging studies. The celiac axis is inspected for lymph node involvement. Tumor-bearing nodes within the resection zone do not contraindicate resection because long-term survival is sometimes achieved with peripancreatic nodal involvement. The parietal and visceral peritoneal surfaces, the omentum, the ligament of Treitz, and the entire small and intra-abdominal large intestine are carefully examined for the presence of metastatic disease. An extensive Kocher maneuver is performed by elevating the duodenum and head of the pancreas out of the retroperitoneum and into the midline, allowing the visualization of the SMA at its origin at the aorta (Fig. 59-8). The porta hepatis is assessed by mobilizing the gallbladder and dissecting the cystic duct down to the junction of the common hepatic and common bile duct. The common hepatic artery and proper hepatic artery should also be assessed to determine that they are free of tumor involvement.

If the intraoperative assessment reveals localized disease without tumor encroachment upon resection margins, the resection is performed in relatively standard fashion. If assessment reveals evidence of local tumor extension giving the early impression of possible unresectability, the normal sequence for performing the pancreaticoduodenectomy should be modified. The easiest and safest portions of the resection should be performed first and the more difficult portions later. Tumors that initially appear unresectable can be successfully resected by patiently working where it is easiest first and finishing the harder portions later.

The distal common hepatic duct is divided close to the level of the cystic duct entry site early during the operation. For distal common bile duct cancers or pancreatic cancers near this area, more margin on the bile duct into the hilus of the liver may be required. The bile duct is retracted caudally, and a dissection plane is opened on the anterior surface of the portal vein (PV) and developed posterior to the second portion of the duodenum and the neck of the pancreas. During these maneuvers, the portal structures should be assessed for a replaced right hepatic artery originating from the SMA. If found, this vessel should be dissected and protected from



A

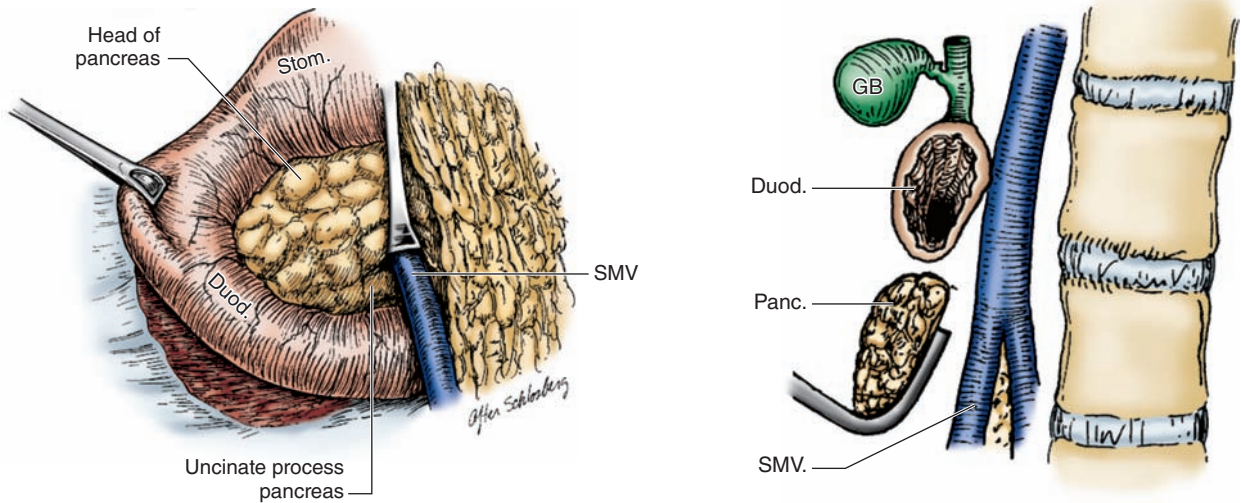


B

**FIGURE 59-8** The uncinate process, head of the pancreas, and superior mesenteric artery (SMA) are palpated between the thumb and index finger. This maneuver enables the surgeon to determine whether the tumor has extended into the uncinate process to involve the SMA. (From Crist DW, Cameron JL. The current status of the Whipple operation for periampullary carcinoma. *Adv Surg.* 1992;25:21.)

injury. If the patient appears to have an accessory right hepatic artery and a significant native right hepatic artery, the accessory vessel can often be taken if involved with tumor without consequence. The gastroduodenal artery is next identified and clamped atraumatically. This maneuver confirms that the hepatic artery is not being supplied solely retrograde through the SMA collaterals (in the setting of celiac axis stenosis or occlusion). For a classic Whipple procedure, a 30–40% distal gastrectomy is performed by dividing the right gastric and right gastroepiploic arteries. The antrectomy is then completed using a linear stapling device. For a pylorus-preserving pancreaticoduodenectomy, the proximal GI tract is divided 2–3 cm distal to the pylorus with a linear stapling device. The right gastric artery can often be spared, but it may be taken if it allows better mobilization of the duodenum for reconstruction. The gastrointestinal tract





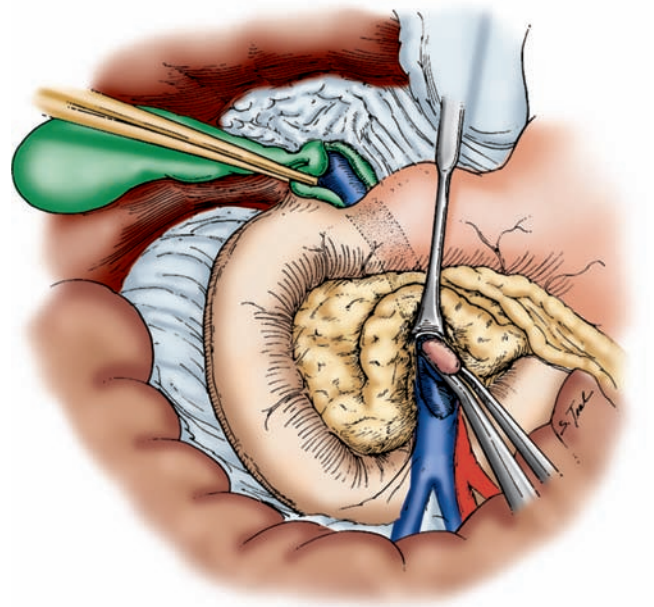
**FIGURE 59-9** If one extends the Kocher maneuver of the duodenum along the third portion, the first structure one encounters anterior to the duodenum is the superior mesenteric vein (SMV). It can be cleaned quickly and visualized under direct vision from the posterior aspect of the pancreas (insert), and the dissection can be connected to that of the portal vein (PV) from above. Duod., duodenum; GB, gallbladder; Panc., pancreas; Stom., stomach.

is divided distally at a point of mobile jejunum, typically 20 cm distal to the ligament of Treitz. The mesenteric vessels to this initial portion of the jejunum are carefully divided over clamps and tied to avoid bleeding. Once the proximal jejunum is separated from its mesentery, it can be delivered dorsal to the superior mesenteric vessels from the left to the right side.

The superior mesenteric vein (SMV) caudal to the neck of the pancreas can be identified by performing an extensive Kocher maneuver of the third of the duodenum. The SMV is identified running anterior to the third portion of the duodenum. In this location, the SMV is identified by dissecting the fatty areolar tissue surrounding the veins. Division of the gastroepiploic vein emptying into the anterior surface of the SMV allows continued cephalad dissection. Often, a vein retractor lifting the inferior edge of the neck of the pancreas is useful for visualization (Fig. 59-9). The plane anterior to the SMV is developed under direct vision. With the exception of the gastroepiploic vein, there are usually no veins entering the anterior surface of the SMV in this location (Fig. 59-10). Care should be taken to avoid inadvertent injury to the splenic vein as it joins the SMV posterior to the neck of the pancreas. After the plane anterior to the PV and SMV is developed both from above and below, a Penrose drain is looped under the neck of the pancreas.

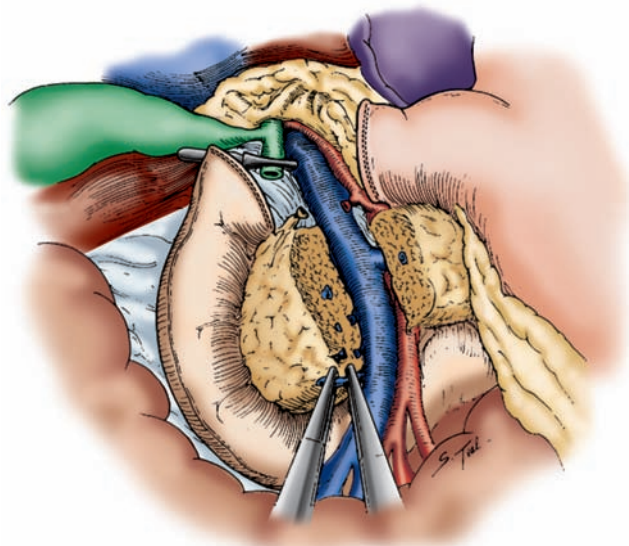
Stay sutures are placed superiorly and inferiorly on the pancreatic remnant to reduce bleeding from the segmental pancreatic arteries running in those locations. The pancreatic neck is then divided after confirming a free plane anterior to the portal and superior mesenteric veins. The Penrose drain previously placed behind the neck of the pancreas is used to elevate the pancreatic tissue to be divided and protect the underlying major veins. Some attention has

been paid to identifying the blood supply of the resection margin of the pancreatic remnant and to not using electrocautery to divide the pancreas.<sup>41</sup> The site of the main pancreatic duct should be noted so it can be incorporated into the subsequent reconstruction.



**FIGURE 59-10** The superior mesenteric and portal veins are separated from the neck of the pancreas by dissection above and below the pancreas. The dissection should be limited to the anterior surface of these vessels, since there are usually no venous branches in this plane. (From Crist DW, Cameron JL. The current status of the Whipple operation for periapillary carcinoma. *Adv Surg.* 1992;25:21.)





**FIGURE 59-11** The portal and superior mesenteric veins are dissected from the uncinate process of the pancreas and the small venous branches between the veins and the uncinate process are ligated and divided carefully. (From Crist DW, Cameron JL. The current status of the Whipple operation for periampullary carcinoma. *Adv Surg.* 1992;25:21.)

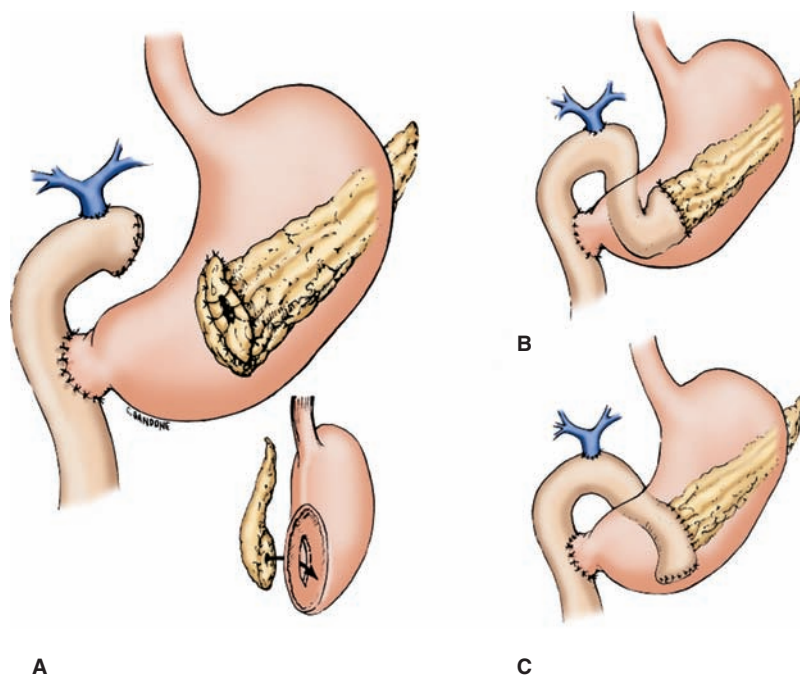
The specimen now remains connected by the uncinate process of the pancreas. This structure is separated from the PV, SMV, and SMA. This is performed by serially clamping, dividing, and tying the smaller branches off the portal and superior mesenteric vessels (Fig. 59-11). Dissection should

be performed flush with these structures to remove all pancreatic and nodal tissue in these areas. Great care is taken not to injure the superior mesenteric artery and vein at this level, but to remove completely the pancreatic tissue and lymph nodes near the vascular structures. With these areas dissected, the specimen is removed and the pancreatic neck margin, uncinate margin, and common hepatic duct margins are marked for the pathologists. To speed up analysis of these frozen section margins, the common hepatic duct margin and the pancreatic neck margin may be sampled earlier and sent to pathology while the main specimen is still being removed.

There are multiple options for reconstruction after pancreaticoduodenectomy. Most commonly the reconstruction first involves the pancreas, followed by the bile duct and then the duodenum or stomach. The issues and controversies surrounding the pancreatic and biliary reconstructions are outlined by multiple papers specifically addressing them.

The most common reconstruction involves the end of the divided jejunum brought up in a retrocolic position with creation of a pancreaticojejunostomy, followed by hepaticojejunostomy and then a duodenojejunostomy (Fig. 59-12B, C). The pancreatic reconnection is the most problematic anastomosis of the three and responsible for much of the morbidity associated with the procedure.

If the jejunum is used for reconstruction, some groups favor a separate Roux-en-Y reconstruction for the pancreas. Controversy continues regarding the best type of



**FIGURE 59-12** Schematic illustration of **A**, pancreaticogastrostomy; **B**, end-to-end pancreaticojejunostomy; and **C**, end-to-side pancreaticojejunostomy. Insert: detailed pancreaticogastrostomy, indicating the location of the posterior gastrotomy. (From Yeo CJ, Cameron JL, Maher MM, et al. A prospective randomized trial of pancreaticogastrostomy versus pancreaticojejunostomy after pancreaticoduodenectomy. *Ann Surg.* 1995;222:580.)

pancreaticojejunostomy, the importance of duct-to-mucosa sutures, and the use of pancreatic duct stents. The pancreatic reconstruction is typically performed with either a duct-to-mucosal anastomosis or with an invagination technique. With either technique, the proximal jejunal stump is brought through a defect in the mesocolon to the right of the middle colic artery. The duct-to-mucosal anastomosis is constructed in an end-to-side fashion in which the outer row consists of interrupted 3-0 silk sutures incorporating the capsule of the transected pancreas and seromuscular bites of the jejunum. A small defect is made in the jejunum to which a duct-to-mucosa anastomosis is performed incorporating the pancreatic duct and the full thickness of the jejunum using interrupted 5-0 or 4-0 Maxon (SutureDirect, Mettawa, IL). Some surgeons prefer to stent this anastomosis with a 6-cm stent cut from a 5 or 8F (French) pediatric feeding tube. Three centimeters of the stent are placed into the pancreatic duct and the other half is placed into the jejunum. The stent is held in place with an absorbable stitch such as 4-0 Vicryl (Ethicon, Somerville, NJ). This stent typically passes through the rest of the intestinal tract within several of weeks.

The invagination technique is typically performed with an end-to-end or end-to-side pancreaticojejunostomy. The pancreatic remnant should be circumferentially cleared and mobilized for 2–3 cm, to allow for an optimal anastomosis. The pancreaticojejunostomy is typically performed in two layers. The outer layer consists of interrupted silk sutures that incorporate the capsule of the pancreas and the seromuscular layers of the jejunum. The inner layer consists of a running 3-0 absorbable suture (or interrupted absorbable sutures) that incorporates the capsule and a portion of the cut edge of the pancreas and the full thickness of the jejunum. If possible, the inner layer should incorporate the pancreatic duct for several bites, to splay it open. When completed, this anastomosis nicely invaginates the cut surface of the pancreatic neck into the jejunal lumen.

If the stomach is used to reconnect the pancreas, it is invaginated into the back wall of the stomach as described previously for the jejunum (Fig. 59-12A). In a prospective randomized trial comparing pancreaticogastrostomy to pancreaticojejunostomy, there was no difference in the leak or fistula rate between the two types of anastomoses.<sup>42</sup>

The biliary anastomosis is typically performed with an end-to-side hepaticojejunostomy distal to the pancreaticojejunostomy. This anastomosis is performed with a single layer of interrupted absorbable sutures. If the patient has a percutaneous biliary stent, this is left in place, traversing the anastomosis. Preoperative biliary stenting remains controversial. Stenting should be used selectively in patients with obstructive jaundice who will have a substantial delay between initial presentation and definitive surgery, and in rare patients with primary suppurative cholangitis. The method of stenting, endoscopic versus percutaneous, should be chosen based on local expertise.

The third anastomosis performed is the duodenojejunostomy in cases of pylorus preservation, or the gastrojejunostomy

in patients who have undergone classic pancreaticoduodenectomy with distal gastrectomy. This anastomosis is performed 10–15 cm downstream from the hepaticojejunostomy, proximal to the jejunum traversing the defect in the mesocolon.

After the reconstruction is completed, closed-suction drains are left in place to drain the biliary and pancreatic anastomoses. Some groups prefer not to place closed-suction drains, accepting that, if a fluid collection becomes clinically evident postoperatively, percutaneous drainage by interventional radiology may be required.

The postoperative management following pancreaticoduodenectomy consists of keeping the patient with nothing by mouth for 1 or 2 days and advancing the diet with liquids and then solids as tolerated. The stomach is decompressed overnight after the day of surgery with a nasogastric tube that is usually removed the next morning unless there is an extraordinarily high output. The drains around the pancreatic anastomosis are removed once the patient has been on a regular diet. Drain amylase is typically checked before pulling the drains to check for leak or fistula.

## DISTAL PANCREATECTOMY FOR PANCREAS CANCER IN THE BODY OR TAIL

Staging with laparoscopy is often of benefit in patients with distal pancreatic cancers. If metastatic disease is found, distal pancreatectomy is unlikely to help in the palliation of the patient. The advantages of performing splenectomy with distal pancreatectomy include the ability to gain wider margins, removal of lymph nodes and lymphatic tissues at the tip of the pancreas and the hilum of the spleen, and avoidance of the tedious dissection of the splenic artery and vein away from the pancreatic parenchyma. The main disadvantage is the perceived increased incidence of postsplenectomy sepsis. For this reason, vaccines are given either preoperatively or after recovery postoperatively for pneumococcus, *Haemophilus meningitides*, and *Haemophilus influenzae*.

Exposure for a distal pancreatectomy and splenectomy can be obtained through a vertical midline incision from the xiphoid process to several centimeters below the umbilicus. Alternatively, a bilateral subcostal incision can be used. Exposure is greatly enhanced with the use of a mechanical retracting device. Folded sheets placed behind the patient underlying the spleen can also enhance exposure, especially in patients with a deep body habitus.

After exploration, the lesser sac is entered by removing the gastrocolic ligament from the transverse colon through the avascular plane using electrocautery. This line of dissection is carried to the descending colon, and the proximal white line of Toldt is divided. The stomach is further mobilized by dividing the omentum anterior to the hilum of the spleen as well as the short gastric vessels (*vasa brevia*).

This dissection is carried to the superior pole of the spleen. Once the stomach is fully mobilized, it is retracted superiorly along with the omentum to provide wide exposure of the anterior surface of the pancreas. The general location of the tumor should be noted at this point. The peritoneum is divided along the inferior edge of the pancreas using electrocautery. Care is taken to identify and avoid injury of the inferior mesenteric vein (IMV) that joins the splenic vein posterior to the body of the pancreas or less commonly directly joining the SMV.

The splenic artery that sends multiple branches to the superior edge of the pancreas before terminating in the spleen is identified and encircled near its origin at the celiac. Once a test clamp is performed and preservation of flow to the hepatic artery is confirmed, the splenic artery is divided. The splenic artery stump should be further secured with a nonabsorbable suture ligature. After the spleen toward the spine is retracted medially, the electrocautery is used to incise the peritoneal reflection starting at the previously made incision at the inferior edge of the pancreas and extending this incision laterally and superiorly. The spleen and tail of the pancreas are mobilized out of the retroperitoneum using electrocautery or sharp dissection. Care must be taken to remain anterior to the left adrenal gland and Gerota's fascia of the left kidney. Once the junction of the IMV is reached, the splenic vein can usually be separated from the pancreatic parenchyma and divided lateral to this junction. If the lesion is in the body of the pancreas, it may be necessary to divide the splenic vein near its junction with the SMV-PV confluence. Transection of the pancreas can be accomplished with a knife, electrocautery, linear stapler, or harmonic scalpel. The development of a postoperative pancreatic fistula may occur in up to 25% of patients. Only direct ligation of the pancreatic duct and the perioperative use of octreotide have been shown to reduce the rate of postoperative pancreatic fistulas. If a stapler is not used to transect the pancreas, the remnant is oversewn in two layers with absorbable suture. A surgical drain is placed in order to identify and control a pancreatic fistula.

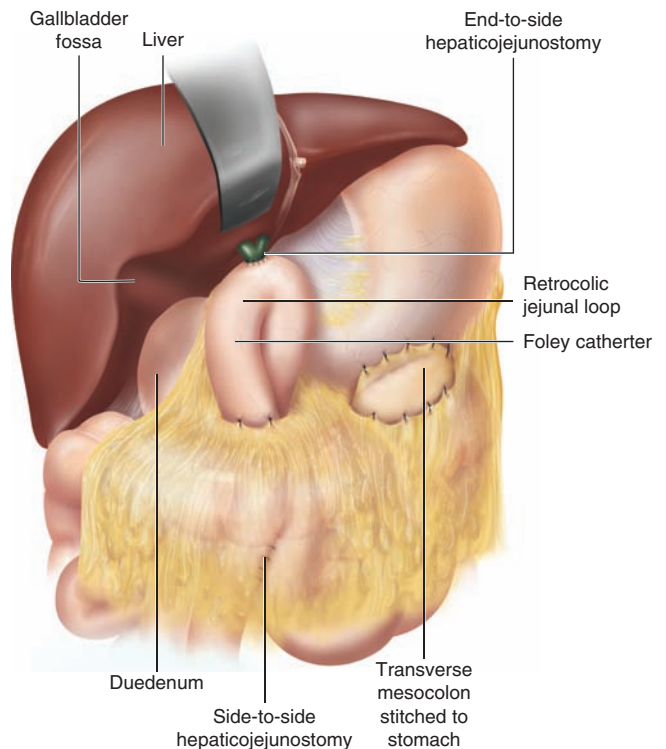
Cancer of the body of the pancreas can be the most difficult lesion to manage surgically. By virtue of this location, extension superiorly beyond the pancreas often results in involvement of the celiac trunk, common hepatic artery, and base of the splenic artery at its takeoff from the celiac trunk. Growth slightly to the right and posterior will involve the medial wall of the PV or SMV and may also infiltrate the junction of the splenic vein with the PV-SMV confluence. In these patients, considerable complexity is added to a distal pancreatectomy. The determination of resectability in these patients is based on the extent of involvement of the celiac axis. Therefore dissection should begin at the common hepatic artery and carried toward the celiac axis. If a clear margin is achievable, then the tumor is resectable. Involvement of the PV-SMV may require en bloc resection and PV reconstruction to achieve a negative margin.

## OPERATIVE PALLIATION

With accurate preoperative staging, the resectability rate for periampullary cancers is approximately 80%.<sup>37,43–46</sup> When a patient undergoes exploratory laparotomy (and sometimes exploratory laparoscopy) and is found to be unresectable, a decision must be made as to whether to operatively palliate the patient. Operative palliation is indicated in a patient without widespread metastatic disease and with a relatively long life expectancy. The added potential morbidity and mortality of operative palliation must be weighed against the more durable palliation achieved with hepaticojejunostomy and/or gastrojejunostomy (Fig. 59-13). Additionally, chemical splanchnicectomy can be performed at the same time for relief of pain (Fig. 59-14).

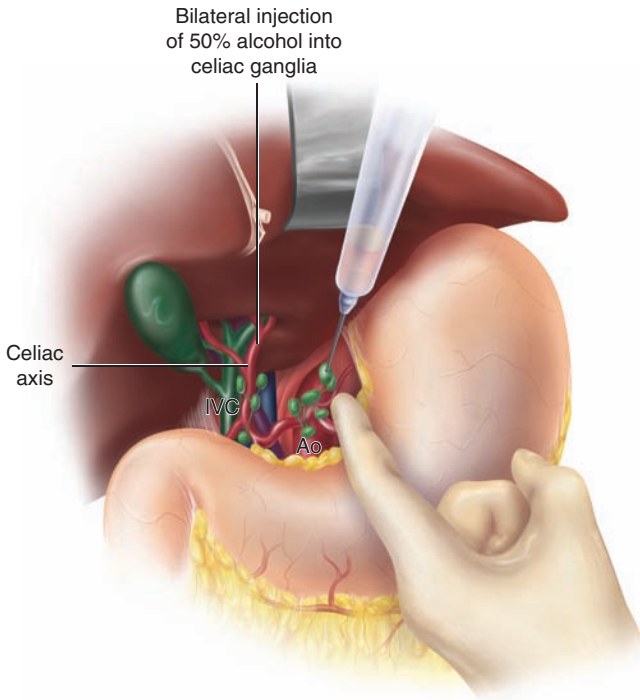
### Operative Palliation of Obstructive Jaundice

The most commonly performed operative procedure for the relief of obstructive jaundice is hepaticojejunostomy. Cholecystojejunostomy should no longer be performed.



**FIGURE 59-13** Anatomy after one method of palliative intervention. The biliary-enteric anastomosis is shown as a retrocolic end-to-side hepaticojejunostomy with a jejunal loop. A jejunojejunostomy is performed below the transverse mesocolon, to divert the enteric stream away from the biliary tree. Also shown is a retrocolic gastrojejunostomy. (From Cameron JL. *Atlas of Surgery*, Vol 1. Toronto, Canada: B.C. Decker; 1990:427, Image V.)





**FIGURE 59-14** Technique of alcohol celiac nerve block. Twenty milliliters of 50% alcohol are injected on each side of the aorta (Ao) at the level of the celiac axis. IVC, inferior vena cava. (Redrawn with permission from Lillemoe KD, et al. Chemical splanchnicectomy in patients with unresectable pancreatic cancer. A prospective randomized trial. *Ann Surg.* 1993;May;217(5):447–455.)

Simple drainage through a T tube inserted above the biliary obstruction should be avoided as this causes a high-output biliary fistula and results in major electrolyte abnormalities. Hepaticojejunostomy provides more durable relief of obstructive jaundice than does cholecystojejunostomy because of the proximity of the cystic duct to most periampullary cancers.<sup>47,48</sup> The hepaticojejunostomy is performed after cholecystectomy in an end-to-side fashion to either a Roux limb or a loop of jejunum with a Braun jejunostomy between the afferent and efferent limbs. Only 4% of patients with unresectable periampullary cancers palliated with hepaticojejunostomies develop recurrent jaundice prior to their deaths.<sup>44</sup> As operative palliation is attempted more with minimally invasive techniques, perhaps laparoscopic cholecystojejunostomies or hepaticojejunostomies will be performed more often secondary to the relative ease with which they can be done and to avoid a major incision.

## Operative Palliation of Duodenal Obstruction

Periapillary cancers may cause gastric outlet obstruction by compromising the duodenal lumen. Most patients with gastric outlet obstruction from a periampullary cancer that is not widely disseminated benefit from palliation, whether

operative or with endoscopic stenting techniques. There remains controversy, however, regarding the role of prophylactic gastrojejunostomy in a patient who is being explored but without symptoms of gastric outlet obstruction. Much of this controversy rests on the exact proportion of patients who actually develop gastric outlet obstruction requiring surgical intervention in the course of their disease. This number is surprisingly low in some series (3%)<sup>49</sup> and approaches 20% in other series.<sup>50</sup> In a prospective, randomized trial from the Johns Hopkins Hospital, 87 patients with unresectable periampullary cancers without signs of gastric outlet obstruction were randomized to either a retrocolic gastrojejunostomy or no gastric bypass.<sup>51</sup> None of the patients who underwent prophylactic gastrojejunostomy subsequently developed gastric outlet obstruction, whereas 19% of them who did not have a gastric bypass subsequently developed gastric outlet obstruction requiring intervention. In this study, performance of the gastrojejunostomy did increase operative time, but it did not increase morbidity, mortality, or length of stay. The gastrojejunostomies were performed typically in a retrocolic (to the left of the middle colic vessels) and isoperistaltic fashion, using a loop of jejunum just beyond the ligament of Treitz. The gastrotomy is placed on the back wall of the stomach in the most dependent portion. Vagotomy is not performed because of its contribution to delayed gastric emptying, the limited life expectancy of the patients, and the ability to control acid secretion medically.

## Operative Chemical Splanchnicectomy for Pain

Operative chemical splanchnicectomy was first introduced in the 1960s to alleviate the pain associated with unresectable pancreas cancer.<sup>52</sup> A prospective, randomized trial compared intraoperative chemical splanchnicectomy to placebo in 137 patients with unresectable pancreatic cancer.<sup>51</sup> The procedure was performed by injecting 20 mL of 50% ethanol or saline through a spinal needle on either side of the aorta at the level of the celiac plexus. There were no differences in hospital morbidity, mortality, or length of stay. The group receiving the alcohol had significantly lower pain scores at 2, 4, and 6 months postoperatively. Even those patients who did not report pain preoperatively derived benefit from the splanchnicectomy as they appeared to have a delay in the onset of their pain and had lower pain scores as their disease progressed when compared to control patients.

## NONOPERATIVE PALLIATION

Only 15–20% of patients with pancreas cancer are found to be resectable for cure at the time of presentation because of disseminated disease or locally advanced disease. Patients with distal common bile duct, ampullary, and duodenal cancers are more likely to be resectable. For the majority of patients,

palliation of symptoms is the primary goal of any invasive intervention. As discussed in the previous section, the three main problems that need to be palliated include obstructive jaundice, gastric outlet obstruction, and pain.

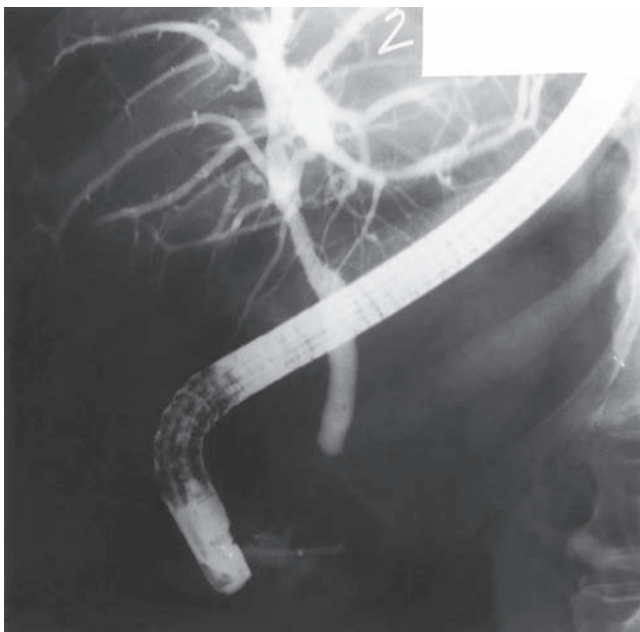
### Nonoperative Palliation of Obstructive Jaundice

Nonoperative biliary drainage can be achieved either through a percutaneous or an endoscopic approach (Fig. 59-15). Percutaneous transhepatic approaches are aided by the fact that the intrahepatic ducts are usually dilated in patients presenting with obstructive jaundice. Endoscopic drainage has the advantage of not having any external catheters. In a randomized trial comparing endoscopic versus percutaneous stent placement in 70 patients, the success rate, overall complication rate, and procedure-related mortality rate was significantly lower in the endoscopic group.<sup>53</sup> Endoscopic biliary stents may be either plastic or metal. Plastic stents are generally temporary and are available in different diameters and lengths. Because the diameter of the accessory channel of endoscopes is limited, usually the largest plastic stent that can be placed is 12F. This relatively small diameter results in frequent occlusion and the necessity of periodically changing these stents. In an effort to improve on the rate of stent occlusion, self-expanding metallic stents have been developed and, when deployed, they can reach

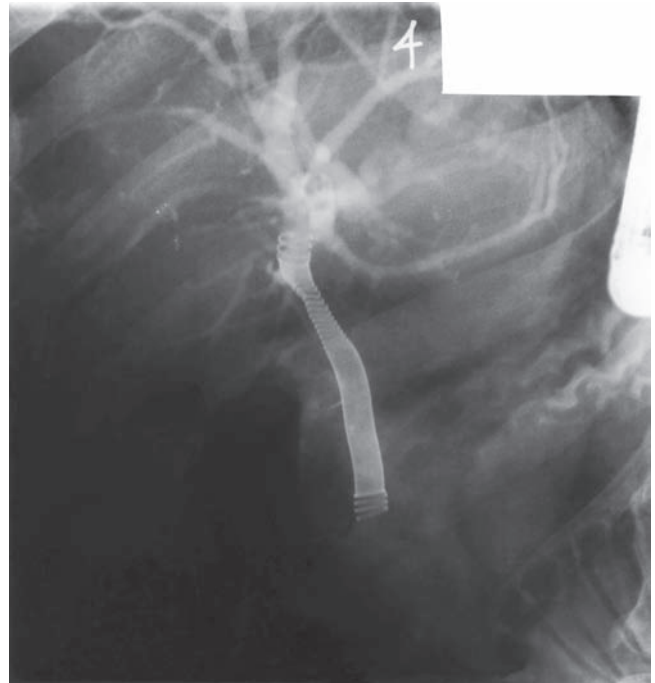
a diameter of 30F. Randomized controlled clinical trials comparing 10 or 11.5F plastic stents to 30F metallic stents have shown metallic stents to have a longer patency rate (6.2–9.1 months compared to 4.2–4.6 months) and to be associated with lower rates of cholangitis, stent replacement, and hospital days.<sup>54,55</sup> Metallic stents eventually fail because of tumor ingrowth at the ends and through the interstices. Polyurethane-covered stents are currently being developed and used, and they probably have better patency and results. The disadvantage of metallic stents is that they cost more and should be used in patients who are expected to live longer than 6 months. It should be noted that the placement of a metallic stent does not preclude the ability to perform a subsequent cancer resection. Division of the bile duct and removal of the stent can easily be performed at the time of operation.

### Nonoperative Palliation of Duodenal Obstruction

Until recently, duodenal obstruction in patients found to be unfit for surgical bypass was treated with placement of gastrostomy tubes. The development of expandable metallic bowel stents has provided an additional way of controlling gastric outlet obstruction in this group of patients. Gastrointestinal stenting is successful in 80–90% of patients and provides adequate relief of obstruction in most patients.<sup>56,57</sup>



A



B

**FIGURE 59-15** A. Endoscopic retrograde cholangiopancreatogram (ERCP) showing distal bile duct obstruction owing to pancreatic cancer. B. ERCP showing a metallic expandable stent in place.

## Nonoperative Palliation of Pain

In addition to opioids and nonsteroidal anti-inflammatory agents, several nonoperative palliative treatment modalities for pain with periampullary cancers have been developed, including ultrasound or CT-guided celiac plexus nerve blocks and even external beam radiotherapy. Several randomized controlled clinical trials comparing percutaneous celiac plexus nerve blocks to standard oral analgesics have demonstrated significant diminution in pain and narcotic use in the majority of the patients.<sup>58,59</sup>

## COMPLICATIONS FOLLOWING PANCREATICODUODENECTOMY AND DISTAL PANCREATECTOMY

The mortality rate after pancreaticoduodenectomy at centers specializing in pancreatic surgery is in the range of 2–3%. Despite low mortality rates, the incidence of postoperative complication remains high. In a series of 650 consecutive pancreaticoduodenectomies, the mortality rate was 1.4% with a complication rate of 41%.<sup>60</sup> The three most common complications were delayed gastric emptying in 19%, pancreatic fistula in 14%, and wound infection in 10%. Delayed gastric emptying is not life-threatening and is usually self-limited. The condition, however, can significantly increase lengths of stay for the patient, as well as hospital costs. Patients are usually treated with parenteral nutritional support and nasogastric decompression until the condition resolves. Erythromycin, a motilin agonist, has been shown to improve gastric emptying after pancreaticoduodenectomy and is sometimes used.<sup>61</sup> Pancreatic fistulae are not uncommon after pancreaticoduodenectomy. The reported rates of pancreatic fistula vary and, to some degree, depend on how they are defined. In general, a pancreatic fistula exists if, at 7 days postoperatively, there is amylase-rich fluid in excess of 50 mL/d. In the great majority of patients, the pancreatic leak will seal with conservative management. Most centers place intraoperative closed-suction drains near the pancreatic anastomosis to control potential leaks. Some centers do not place drains intraoperatively and prefer to have them placed postoperatively and by interventional radiological techniques should the patient become symptomatic with a pancreatic leak. If the patient is relatively asymptomatic and the output is less than 200 mL/d while on a diet, consideration toward sending the patient home with outpatient drain management should be given. In most cases, the fistula will improve and cease within a couple of weeks. If the patient is symptomatic or the fistula is high output (>200 mL/d), consideration to making the patient NPO and using parenteral nutrition should be given.

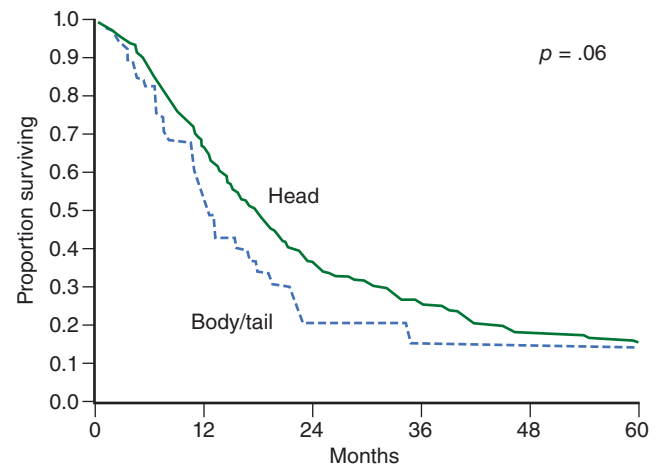
Distal pancreatectomy is required for the resection of pancreatic cancers of the body and tail of the pancreas. Although, this operation is less involved than a pancreaticoduodenectomy, the potential for significant morbidity exists. In a series

of 704 patients who underwent a distal pancreatectomy for any indication, the operative mortality was less than 1%.<sup>62</sup> However, the morbidity rate rivals that of the pancreaticoduodenectomy at 33%. Twelve percent of patients had a clinically significant postoperative pancreatic fistula. Other complications included intra-abdominal abscess (5%), small bowel obstruction (5%) and new-onset diabetes (7%). A postoperative pancreatic fistula following distal pancreatectomy is managed in the same manner as that following a pancreaticoduodenectomy.

## Long-Term Survival After Resection of Periapillary Cancers

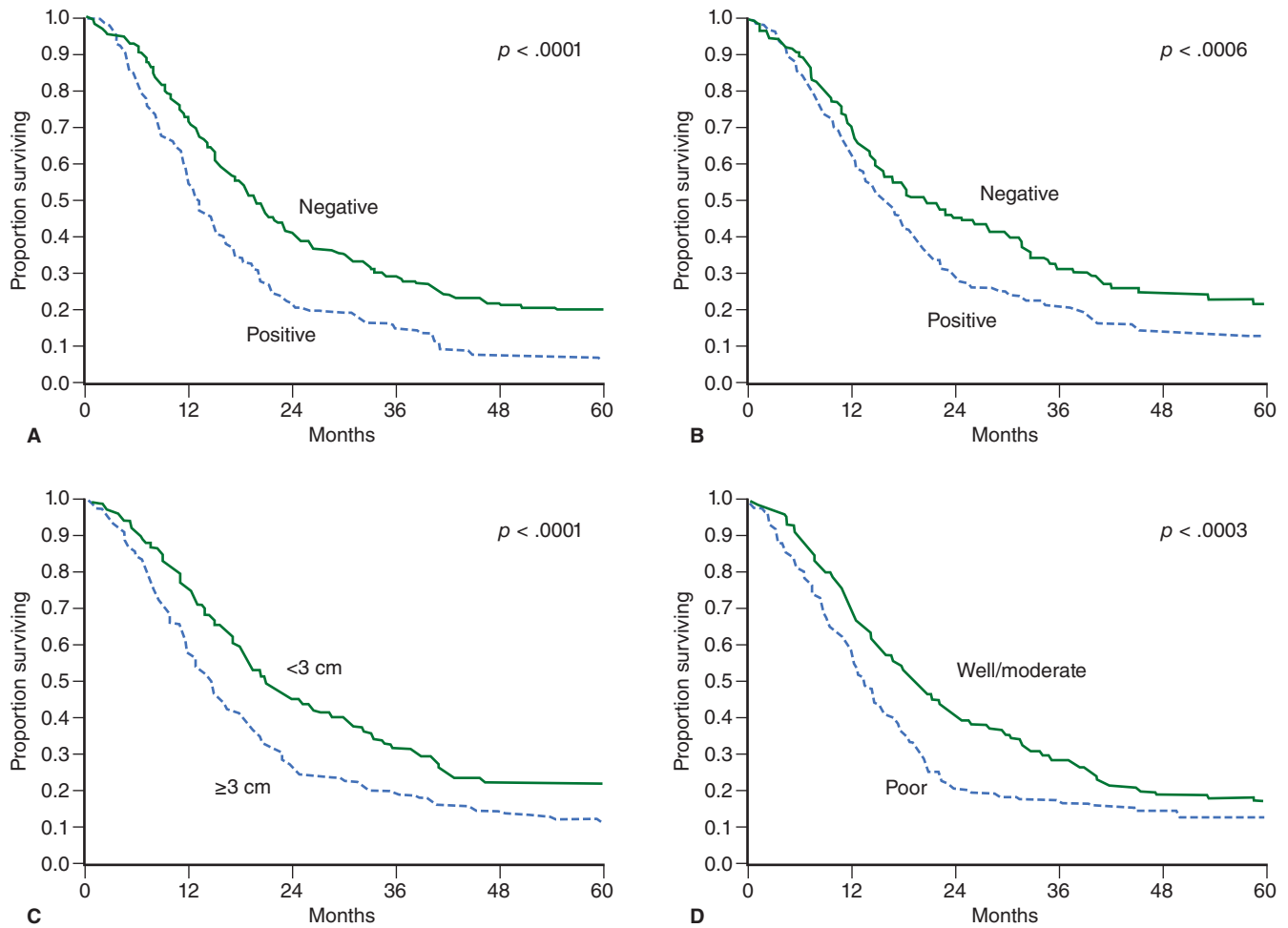
The periampullary adenocarcinomas share a common location of origin but vary greatly in their long-term survival. In an analysis of actual 5-year survivors from 242 consecutive patients with resected periampullary adenocarcinoma, of which 149 (62%) were pancreatic primaries, 46 (19%) arose in the ampulla, 30 (12%) were distal bile duct cancers, and 17 (7%) were duodenal cancers, there were 58 actual survivors.<sup>63</sup> The tumor-specific 5-year survival rates were only 15% for pancreatic, while ampullary, distal bile duct, and duodenal had much better survival of 39, 27, and 59%, respectively (see Figs. 59-16, 59-17, and 59-18). When compared with patients who did not survive 5 years, the 5-year survivors had a significantly higher percentage of well-differentiated tumors, negative resection margins, and negative lymph nodes.

Several series have reported survival and prognostic features for some of the individual periampullary adenocarcinomas. The most lethal of the periampullary cancers is pancreatic adenocarcinoma. In a series of 1423 pancreaticoduodenectomies for pancreatic adenocarcinoma, the median survival



**FIGURE 59-16** Survival curves of 616 patients who underwent resection of pancreatic cancers at Johns Hopkins Hospital. (Reproduced with permission from Sohn TA, et al. Resected adenocarcinoma of the pancreas-616 patients: results, outcomes, and prognostic indicators. *J Gastrointest Surg.* 2000; Nov-Dec;4(6):567–579.)





**FIGURE 59-17** Survival curves comparing patients with **A**, negative resection margins (n = 442) to those with positive resection margins (n = 184); **B**, negative lymph nodes (n = 166) to those with positive lymph nodes (n = 441); **C**, tumor diameter <3 cm (n = 268) to those with tumor diameter ≥3 cm (n = 325); and **D**, well/moderate tumor differentiation (n = 380) to those with poor tumor differentiation (n = 216). (Reproduced with permission from Sohn TA, et al. Resected adenocarcinoma of the pancreas-616 patients: results, outcomes, and prognostic indicators. *J Gastrointest Surg.* 2000; Nov-Dec; 4(6):567-579.)

was 18 months with a 5-year survival of 18%.<sup>64</sup> Factors that affected survival in this cohort included tumor size of greater than 3 cm (hazard ratio [HR] 1.6;  $p < .001$ ), positive resection margin (HR 1.6;  $p < .001$ ), histological grade (HR 1.6;  $p < .001$ ), and regional lymph node metastases (HR 1.3;  $p = .05$ ), among others. In a series of 127 resected patients with ampullary adenocarcinoma, a 5-year survival rate of 36% was reported.<sup>65</sup> On multivariate analysis, only depth of invasion and lymph node status were predictors of survival.

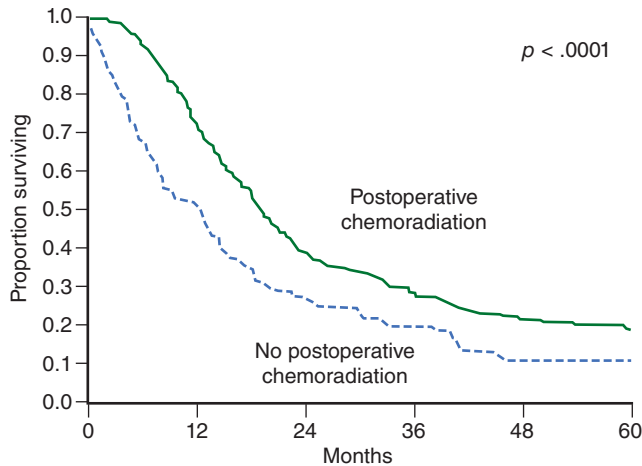
There is accumulating evidence suggesting that mutations in tumor suppressor genes, oncogenes, and DNA mismatch repair genes also influence prognosis in pancreas cancer. Patients who have pancreas cancers with p53 mutations have been shown to have a worse prognosis.<sup>66</sup> Additionally, the number of tumor suppressor gene mutations found in a pancreatic cancer correlates with the risk of death in patients.<sup>27</sup> In contrast to this and in line with improved prognosis in patients with HNPCC, patients with pancreas

cancers with DNA mismatch repair mutations seem to have a better prognosis.<sup>67</sup>

There is also evidence that hospital volume is related to perioperative mortality, length of hospital stay, hospital cost, and long-term outcome in patients undergoing pancreatic resection.<sup>68-71</sup> These studies seem to suggest that regionalization of care of patients requiring pancreaticoduodenectomy and complex pancreatic procedures will affect both the cost and outcome.

## ADJUVANT THERAPY

There are numerous adjuvant regimens for periampullary cancer and these vary with the cancer type and often for a particular cancer. The diversity in treatments is in large part because no one regimen has been shown to carry a significant advantage over another. In fact, at best adjuvant therapy



**FIGURE 59-18** Survival curves comparing patients receiving postoperative chemoradiation ( $n = 333$ ) to those not receiving postoperative chemoradiation ( $n = 119$ ). (Reproduced with permission from Sohn TA, et al. Resected adenocarcinoma of the pancreas-616 patients: results, outcomes, and prognostic indicators. *J Gastrointest Surg.* 2000; Nov-Dec;4(6):567-579.)

adds only a modest benefit over surgery alone. Unanswered questions in this field include the relative effectiveness of chemoradiation versus chemotherapy alone, radiation fractionation and dosing, and optimal systemic therapy. Because current chemotherapy is relatively ineffective, the next leap-forward in improving outcomes for these patients will be the development of more effective systemic therapy.

Adjuvant therapy for periampullary cancer is best studied in pancreatic adenocarcinoma for which several prospective trials were conducted. In 1985, the Gastrointestinal Tumor Study Group (GITSG) trial was published.<sup>72</sup> This was a prospective randomized trial comparing observation (control) to split-course radiotherapy (4000 cGy, 20 fractions, over 6 weeks) with bolus 5-fluorouracil (5-FU) 500 mg/m<sup>2</sup> intravenous daily on each of the first 3 days of radiotherapy of each 200-cGy sequence in patients with pancreas cancer. Additionally, patients receiving adjuvant therapy received bolus 5-FU every week for 2 years. The patients on this trial who received adjuvant therapy had better median and overall survival rates.

It has also been demonstrated that multiagent 5-FU chemotherapy regimens can be combined with radiotherapy. The group at the Virginia Mason Clinic have combined 5-FU, cisplatin,  $\alpha$ -interferon, and radiotherapy, and have shown significant activity in the adjuvant setting.<sup>73</sup> The effectiveness of delivering 5-FU as a continuous infusion, a manner of delivery associated with improved efficacy in rectal and colon cancer, is also being explored.<sup>74</sup> Gemcitabine has been compared to 5-FU for the nonradiotherapeutic components by the Radiation Therapy Oncology Group (RTOG) 97-04 (now closed with completion of accrual). This comparison was based on the observation that, in patients with metastatic pancreatic cancer, gemcitabine produced statistically superior

survival results to 5-FU. We are likely to see more trials in the future combining gemcitabine with radiotherapy. A randomized controlled trial was performed by the European Study Group for Pancreatic Cancer (ESPAC-1) in which 541 eligible patients with pancreas cancer were randomized to adjuvant chemoradiotherapy (20 Gy in 10 daily fractions over 2 weeks with IV 5-FU on days 1–3 and 15–17), chemotherapy (IV 5-FU and folinic acid for 5 days every month for 6 months), both, or observation. The study demonstrated no survival benefit for adjuvant chemoradiotherapy but revealed a potential benefit for adjuvant chemotherapy over observation (median survival of 19.7 vs 14.0 months).<sup>75</sup>

The most recent prospective randomized trial for adjuvant therapy for pancreas cancer also comes from Europe.<sup>76</sup> The CONKO-001 trial did not evaluate the effect of chemoradiotherapy based on the results of the ESPAC-1 trial and compared chemotherapy alone versus observation. Gemcitabine was chosen as the single agent in this study based on its benefit when used as palliative therapy. This trial demonstrated that gemcitabine increased the median disease-free survival from 6.9 to 13.4 months in a cohort of 368 patients. Despite this difference, there was no improvement of overall median survival that was 22.1 months in the treatment group and 20.2 months in the observation group.

The role of adjuvant chemoradiation in the treatment of distal bile duct, ampullary, and duodenal cancers is less well understood than for pancreas cancer. This is because of the relative rarity of these diseases, especially in relation to pancreas cancer. As a group, these patients tend to be treated with 5-FU-based chemotherapy or chemoradiotherapy. No large prospective trials have been conducted solely for any of these periampullary cancers. Several retrospective studies have suggested a benefit for chemoradiotherapy in some instances. For example, Krishnan et al<sup>77</sup> conducted a retrospective analysis of 96 patients with resected ampullary cancer and demonstrated a trend toward improved survival in those who receive chemoradiotherapy in comparison to observation. This study, as with most retrospective studies on this topic, is confounded by the potential for selection bias in that “healthier” patients tend to undergo adjuvant therapy.

## NEOADJUVANT THERAPY

Neoadjuvant therapy has several theoretical advantages. It allows more timely administration of chemo- or chemoradiotherapy to patients who are at a high risk of failure after surgical resection. It has the potential to shrink the tumor and theoretically can decrease the extent of local disease. Patients who develop disseminated disease during neoadjuvant treatment are unlikely to have benefited from initial resection and are spared the time commitment, morbidity, and potential mortality of resection. It may allow better selection of patients who are most likely to benefit from surgical resection.

A recent series was reported from Duke University of 193 patients with biopsy-proven pancreatic adenocarcinoma



**TABLE 59-1: SUMMARY OF RECENT TRIALS OF PREOPERATIVE CHEMORADIATION FOR RESECTABLE PANCREATIC CANCER AT THE UNIVERSITY OF TEXAS M.D. ANDERSON CANCER CENTER<sup>79</sup>**

Author (year)	n	Regimen	Hospitalization Rate (%)	Resection Rate (%)	Partial Response Rate (%)	Median Survival (months)
Evans (1992)	28	5-FU 50.4 Gy	32	61	41	18
Pisters (1998)	35	5-FU 30 Gy	9	57	20	25
Pisters (2002)	35	Paclitaxel 30 Gy	11	57	21	19
Wolff (2002)	86	Gemcitabine 30 Gy	43	74	58	36

5-FU, 5-fluorouracil.

Reproduced with permission from Raut et al. Neoadjuvant therapy for resectable pancreatic cancer. *Surg Oncol Clin N Am.* 2004; Oct;13(4):639–661.

who completed neoadjuvant chemoradiotherapy and 70 patients who underwent resection.<sup>78</sup> Exact treatment regimens varied, but 183 patients (95%) received 5-FU–based chemotherapy delivered concurrently with daily external beam radiotherapy for a planned total dose of 4500 cGy at 180 cGy per fraction over 5 weeks plus a 540-cGy boost to the tumor. Ten patients (5%) received gemcitabine chemotherapy with twice-daily external beam radiotherapy with a planned total dose of 3000 cGy at 150 cGy per fraction over 3 weeks. Complete histologic responses occurred in 6% of patients. Patients who underwent resection with minimal residual disease, and those whose tumor specimens had significant tumor necrosis, enjoyed significantly better survival.

The M.D. Anderson Cancer Center experience with neoadjuvant chemoradiation for resectable pancreatic cancer was recently summarized.<sup>79</sup> Since 1988, four prospective neoadjuvant trials have been completed at that institution with identical eligibility criteria using a CT-based definition of resectable disease, a uniform surgical technique for the performance of pancreaticoduodenectomy, and a standardized system for pathologic evaluation of the surgical specimens. All eligible patients were required to have biopsy-proven adenocarcinoma of the pancreatic head. The trials have evolved with the first two using 5-FU as the chemotherapy component, the third using paclitaxel, and the fourth using gemcitabine. All four trials combined chemotherapy with radiotherapy in the neoadjuvant setting (Table 59-1).

## NOVEL AGENTS IN PANCREATIC CANCER

In the recent past new agents have emerged that have been targeted toward some of the known molecular or genetic defects found in pancreatic cancer. Countless agents, both classic chemotherapy and biological, are in various stages of investigation. In this section several of the biological agents that have been studied in early-phase clinical trials will be reviewed. These include immunotherapy, angiogenesis inhibitors, *K-ras* inhibitors, and inhibitors of the epidermal growth factor receptor (EGFR) family.

## Immunotherapy

Immune-based therapies can exploit both the cellular and humoral components of the immune system. Strategies aimed at the cellular components recruit and activate T cells that recognize tumor-specific antigens. Strategies using monoclonal antibodies are being designed to target tumor-specific antigens that can kill tumor cells by direct lysis or through delivery of a conjugated cytotoxic agent. Both approaches are attractive for several reasons. First, immune-based therapies act through a mechanism different from chemotherapy or radiation therapy and would not be prone to cross-resistance in previously treated patients. Second, through the genetic recombination of their respective receptors, the B cells and T cells of the immune system are capable of recognizing a diverse array of potential tumor antigens. New knowledge into the mechanisms by which T cells are successfully activated and by which tumors evade immune recognition is driving the development of new combinatorial approaches. Also, recent advances in gene-expression analysis have allowed for the identification of new pancreatic targets, including candidate tumor antigens that might serve as T-cell and antibody targets. These advances now make it possible to exploit the immune system to recognize and destroy pancreas cancer.

In a phase I trial of patients with surgically resected adenocarcinoma of the pancreas, 14 patients were treated with an allogeneic tumor cell vaccine transduced to secrete granulocyte-macrophage colony-stimulating factor. No dose-limiting toxicities were encountered.<sup>80</sup> This vaccine approach induced dose-dependent systemic antitumor immunity as measured by increased postvaccination delayed-type hypersensitivity responses against autologous tumors. Moreover, the three long-term survivors had the strongest postvaccination responses. This strategy is currently being evaluated in a phase II trial at Johns Hopkins Hospital.

## Angiogenesis Inhibitors

Bevacizumab is a recombinant humanized monoclonal antibody directed against the vascular endothelial growth factor (VEGF). Bevacizumab has been studied in combination



with gemcitabine in a phase II study.<sup>81</sup> A total of 52 patients with advanced or locally advanced pancreatic cancer received gemcitabine and bevacizumab. Eleven patients (21%) had confirmed partial responses and 77% of the patients were alive at 6 months. Median survival was 8.8 months. These results prompted the initiation of a definitive phase III study under the auspices of the Cancer and Leukemia Group B (CALGB 80303). The final results of this trial are pending.

## K-ras Inhibitors

An activating mutation of the *K-ras* is present in nearly 100% of pancreatic cancers. *K-ras* requires farnesylation to be active. This reaction is mediated by the enzyme farnesyltransferase, and inhibitors of this enzyme have been developed as potential anticancer therapies. One of these, tipifarnib, has been studied in pancreatic cancer. Tipifarnib was tested in a single-agent phase II study in 20 patients with advanced pancreatic cancer with no objective responses and a median survival of less than 5 months.<sup>82</sup> A larger randomized phase III study compared the combination of tipifarnib with gemcitabine against gemcitabine plus placebo in 680 patients with advanced pancreatic cancer.<sup>83</sup> No improvement in outcome was found.

## Epidermal Growth Factor Receptor Family

The epidermal growth factor receptor (EGFR) family of receptors are frequently dysregulated in cancer and have been associated with the process of tumor growth, invasion, and metastasis. The inhibitors of the EGFR belong to two broad classes of drugs, including monoclonal antibodies against the extracellular domain of the receptor and small molecules inhibitors of the intracellular TK domain. The studies conducted in pancreatic cancer have mainly tested the combination of these drugs with gemcitabine.

Approximately 20% of pancreatic cancers are Her-2 positive, and preclinical studies have shown that inhibition of Her-2 signaling with Herceptin (trastuzumab) is associated with antitumor effects in pancreatic cancer models. As a result, a phase II study evaluated the effect of trastuzumab, a monoclonal antibody that targets the Her-2 receptor, in combination with gemcitabine in patients with pancreatic cancer.<sup>84</sup> Thirty-four patients with Her-2-positive pancreatic cancer received gemcitabine and trastuzumab. Sixteen percent of patients screened tested positive for Her-2. Two patients (6%) had a partial response, and the median survival and one-year survival were 7 months and 19%.

Two small-molecule EGFR inhibitors, EKB-569 and erlotinib, have been specifically developed in pancreatic cancer models. Erlotinib has been tested in combination with gemcitabine in a phase III study in patients with locally advanced and advanced pancreatic cancer.<sup>85</sup> The study,

conducted by the National Cancer Institute of Canada, randomized 569 patients with unresectable pancreatic cancer not preselected for EGFR expression status to receive gemcitabine in combination with either erlotinib or placebo. The addition of erlotinib to gemcitabine resulted in a statistically significant improvement in survival (HR, 0.81; 95% confidence interval, 0.67–0.97;  $p = 0.025$ ), with improvement in the median survival from 5.9 to 6.4 months. The 1-year survival rate improved from 17 to 24% with the addition of erlotinib. The progression-free survival also improved significantly in the gemcitabine/erlotinib group (HR, 0.76;  $p = 0.003$ ). As seen with other EGFR inhibitors, the development of drug-induced rash was associated with a better survival. This study resulted in the approval of erlotinib for treatment of patients with unresectable pancreatic cancer in combination with gemcitabine.

## CONCLUSION

Pancreas and other periapillary cancers represent significant clinical challenges. Although traditionally patients with these diseases had a dismal prognosis, proper staging and patient selection have led to improved results. When possible, surgical resection for cure should be attempted as this gives the only chance of long-term survival. Surgical resection should be performed by surgeons experienced in the management of these diseases and at centers that can aptly care for these patients to minimize morbidity and mortality. There are many developments on the horizon that have the potential to improve the survival and well-being of patients with these diseases.

## REFERENCES

- Halsted WS. Contributions to the surgery of the bile passages, especially of the common bile duct. *Boston Med Surg J.* 1899;141:645–654.
- Sauve L. Des pancreatectomies et spécialement de la pancreatectomie cephalique. *Rev Chir.* 1908;37:335–385.
- Kausch W. Das carcinoma der papilla duodeni und seine radikale entfeinung. *Beitr Z Clin Chir.* 1912;78:439–486.
- Hirschel G. Die resection des duodenumis mit der papille wegen karzinoims. *Munchen Med Wochenschr.* 1914;61:1728–1730.
- Whipple AO, Parsons WB, Mullins CR. Treatment of carcinoma of the ampulla of Vater. *Ann Surg.* 1935;102:763–779.
- American Cancer Society. *Cancer Facts and Figures 2009.* Atlanta, GA: American Cancer Society; 2009.
- Michaud DS. Epidemiology of pancreas cancer. *Minerva Chir.* 2004; 59:99–111.
- Yeo CJ. The Whipple procedure in the 1990s. *Adv Surg.* 1999;32:271–303.
- Betschart V, Rahman MQ, Engelken FJ, et al. Presentation, treatment and outcome in patients with ampullary tumours. *Br J Surg.* 2004;91(12):1600–1607.
- Gold EB, Goldin SB. Epidemiology of and risk factors for pancreatic cancer. *Surg Oncol Clin N Am.* 1998;7:67.
- Gold EB. Epidemiology of and risk factors for pancreatic cancer. *Surg Clin North Am.* 1995;75:819.
- Howe GR, Burch JD. Nutrition and pancreatic cancer. *Cancer Causes Control.* 1996;7:69.
- MacMahon B, Yen S, Trichopoulos D, et al. Coffee and cancer of the pancreas. *N Engl J Med.* 1981;304:630.
- Hsieh C-C, MacMahon B, Yen S, et al. Coffee and pancreatic cancer (chapter 2). *N Engl J Med.* 1986;315:587.

15. Angevine DM, Jablon S. Late radiation effects of neoplasia and other diseases in Japan. *Ann NY Acad Sci.* 1964;114:823.
16. Thompson DE, Mabuchi K, Ron E, et al. Cancer incidence in atomic bomb survivors. Part II: solid tumors, 1958–1987. *Radiat Res.* 1994;137:S17.
17. Bansal P, Sonnenberg A. Pancreatitis is a risk factor for pancreatic cancer. *Gastroenterology.* 1995;109:247.
18. Fernandez E, LaVecchia C, Porta M, et al. Pancreatitis and the risk of pancreatic cancer. *Pancreas.* 1995;11:185.
19. Chow H-W, Gridley G, Nyren O, et al. Risk of pancreatic cancer following diabetes mellitus: a nationwide cohort study in Sweden. *J Natl Cancer Inst.* 1995;87:930.
20. LaVecchia C, Negri E, D'Avanzo B, et al. Medical history, diet and pancreatic cancer. *Oncology.* 1990;47:463.
21. Hruban RH, Peterson GM, Ha PK, Kern SE. Genetics of pancreatic cancer: from genes to families. *Surg Oncol Clin N Am.* 1998;7:1.
22. Lowenfels AB, Maisonneuve P, Cavallini G, et al. Pancreatitis and the risk of pancreatic cancer: International Pancreatitis Study Group. *N Engl J Med.* 1993;328:1433.
23. International Human Genome Consortium. Finishing the euchromatic sequence of the human genome. *Nature.* 2004;409:860.
24. Venter J, Adams M, Myers E, et al. The sequence of the human genome. *Science.* 2001;291:1304.
25. International HapMap Consortium. A second generation human haplotype of over 3.1 million SNPs. *Nature.* 2007;449:851.
26. Jones S, Zhang X, Parsons DW, et al. Core signaling pathways in human pancreatic cancer revealed by global genomic analysis. *Science.* 2008;321:1801.
27. Rozenblum E, Schutte M, Goggins M, et al. Tumor-suppressive pathways in pancreatic carcinoma. *Cancer Res.* 1997;57:1731.
28. Esposito I, Friess H, Büchler MW. Carcinogenesis of cancer of the papilla and ampulla: pathophysiological facts and molecular biological mechanisms. *Langenbecks Arch Surg.* 2001 Apr;386(3):163–171.
29. Wilentz RE, Chung CH, Sturm PDJ, et al. K-ras mutations in duodenal fluid of patients with pancreas carcinoma. *Cancer.* 1998;82:96.
30. Berthelemy P, Bouisson, M, Escourrou J, et al. Identification of k-ras mutations in pancreatic juice early in the diagnosis of pancreatic cancer. *Ann Intern Med.* 1995;123:188.
31. Caldas C, Hahn SA, Hruban RH, et al. Detection of k-ras mutations in the stool of patients with pancreatic adenocarcinoma and pancreatic ductal mucinous cell hyperplasia. *Cancer Res.* 1994;54:3568.
32. Bluemke DA, Fishman EK. CT and MR evaluation of pancreatic cancer. *Surg Oncol Clin N Am.* 1998;7:103.
33. Diederichs CG, Staib L, Vogel J, et al. Values and limitations of 18F-fluorodeoxyglucose-positron-emission tomography with preoperative evaluation of patients with pancreatic masses. *Pancreas.* 2000;20:109.
34. Rose DM, Delbeke D, Beauchamp RD, et al. 18Fluorodeoxyglucose-positron emission tomography in the management of patients with suspected pancreatic cancer. *Ann Surg.* 1999;229:729.
35. Pisters PW, Hudec WA, Hess KR, et al. Effect of preoperative biliary decompression on pancreaticoduodenectomy-associated morbidity in 300 consecutive patients. *Ann Surg.* 2001;234(1):47.
36. Sohn TA, Yeo CJ, Cameron JL, et al. Preoperative biliary stents in patients undergoing pancreaticoduodenectomy: increased risk of postoperative complications? *J Gastrointest Surg.* 2000;4:258.
37. House MG, Yeo CJ, Cameron JL, et al. Predicting resectability of periampullary cancer with three-dimensional computed tomography. *J Gastrointest Surg.* 2004;8(3):280–288.
38. Conlon KC, Dougherty E, Klimstra DS, et al: The value of minimal access surgery in the staging of patients with potentially resectable peripancreatic malignancy. *Ann Surg.* 1996;223:134.
39. Lillmoed KD. Palliative therapy for pancreatic cancer. *Surg Oncol Clin N Am.* 1998;7:199.
40. Vollmer CM, Drebin JA, Middleton WD, et al. Utility of staging laparoscopy in subsets of peripancreatic and biliary malignancies. *Ann Surg.* 2002;235(1):1–7.
41. Strasberg SM, Drebin JA, Mokadam NA, et al. Prospective trial of a blood supply-based technique of pancreaticojejunostomy: effect on anastomotic failure in the Whipple procedure. *J Am Coll Surg.* 2002;194(6):746–758.
42. Yeo CJ, Cameron JL, Maher MM, et al. A prospective randomized trial of pancreaticogastrostomy versus pancreaticojejunostomy after pancreaticoduodenectomy. *Ann Surg.* 1995;222(4):580–588.
43. Warshaw AL, Gu Z-Y, Wittenberg J, et al. Preoperative staging and assessment of resectability of pancreatic cancer. *Arch Surg* 1990;125:230.
44. Sohn TA, Lillmoed KD, Cameron JL, et al. Surgical palliation of unresectable periampullary adenocarcinoma in the 1990s. *J Am Coll Surg.* 1999;188:658.
45. Sohn TA, Lillmoed KD, Cameron JL, et al. Reexploration for periampullary carcinoma: resectability, perioperative results, pathology and long-term outcome. *Ann Surg.* 1999;229:393.
46. Awad SS, Colletti L, Mullholland M, et al. Multimodality staging optimizes resectability in patients with pancreatic and ampullary cancer. *Am Surg.* 1997;63:534.
47. Sarr MG, Cameron JL. Surgical management of unresectable carcinoma of the pancreas. *Surgery.* 1982;91:123.
48. Watanapa P, Williamson RCN. Surgical palliation for pancreatic cancer. Developments during the past two decades. *Br J Surg.* 1992;79:8.
49. Espat NJ, Brennan MF, Conlon KC. Patients with laparoscopically staged unresectable pancreatic adenocarcinoma do not require subsequent surgical biliary or gastric bypass. *J Am Coll Surg.* 1999;188(6):649–655.
50. Lillmoed KD, Cameron JL, Hardacre JM, et al. Is prophylactic gastrojejunostomy indicated for unresectable periampullary cancer? A prospective randomized trial. *Ann Surg.* 1999;230(3):322–328.
51. Lillmoed KD, Cameron JL, Kaufman HS, et al. Chemical splanchnicectomy in patients with unresectable pancreatic cancer. A prospective randomized trial. *Ann Surg.* 1993;217(5):447–455.
52. Lillmoed KD, Sauter PK, Pitt HA, et al. Current status of surgical palliation of periampullary carcinoma. *Surg Gynecol Obstet.* 1993;176:1.
53. Speer AG, Cotton PB, Russell RC, et al. Randomized trial of endoscopic versus percutaneous stent insertion in malignant obstructive jaundice. *Lancet.* 1987;2:57–62.
54. Knyrim K, Wagner HJ, Bethge N, et al. A controlled trial of an expansile metal stent for palliation of esophageal obstruction due to inoperable cancer. *N Engl J Med.* 1993;329(18):1302–1307.
55. Davids PH, Groen AK, Rauws EA, et al. Randomised trial of self-expanding metal stents versus polyethylene stents for distal malignant biliary obstruction. *Lancet.* 1992;340(8834–8835):1488–1492.
56. Kaw M, Singh S, Gagneja H. Clinical outcome of simultaneous self-expandable metal stents for palliation of malignant biliary and duodenal obstruction. *Surg Endosc.* 2003;17(3):457–461.
57. Maetani I, Tada T, Ukita T, et al. Comparison of duodenal stent placement with surgical gastrojejunostomy for palliation in patients with duodenal obstructions caused by pancreaticobiliary malignancies. *Endoscopy.* 2004;36(1):73–78.
58. Polati E, Finco G, Gottin L, et al. Prospective randomized double-blind trial of neurolytic coeliac plexus block in patients with pancreatic cancer. *Br J Surg.* 1998;85(2):199–201.
59. Bakkevedt KE, Kambestad B. Palliation of pancreatic cancer. A prospective multicentre study. *Eur J Surg Oncol.* 1995;21(2):176–182.
60. Yeo C, Cameron JL, Sohn TA, et al. Six hundred fifty consecutive pancreaticoduodenectomies in the 1990s: pathology, complications, outcomes. *Ann Surg.* 1997:248–260.
61. Yeo CJ, Barry MK, Sauter PK, et al. Erythromycin accelerates gastric emptying following pancreaticoduodenectomy: a prospective, randomized placebo controlled trial. *Ann Surg.* 1993;218:229.
62. Nathan H, Cameron JL, Goodwin CR, et al. Risk factors for pancreatic leak after distal pancreatectomy. *Ann Surg.* 2009 Aug;250(2):277–281.
63. Yeo CJ, Sohn TA, Cameron JL, et al. Periampullary adenocarcinoma: analysis of 5-year survivors. *Ann Surg.* 1998;227:821–831.
64. Winter JM, Cameron JL, Campbell KA, et al. 1423 pancreaticoduodenectomies for pancreatic cancer: a single-institution experience. *J Gastrointest Surg.* 2006 Nov;10(9):1199–1210; discussion 1210–1211.
65. Qiao QL, Zhao YG, Ye ML, et al. Carcinoma of the ampulla of Vater: factors influencing long-term survival of 127 patients with resection. *World J Surg.* 2007;31(1):137–143; discussion 144–146.
66. DiGuseppe JA, Yeo CJ, Hruban RH. Molecular biology and the diagnosis and treatment of adenocarcinoma of the pancreas. *Adv Anat Pathol.* 1996;3:139.
67. Goggins M, Offerhaus GJA, Hilgers W, et al. Pancreatic adenocarcinomas with DNA replication errors (RER+) are associated with wild-type k-ras and characteristic histopathology: poor differentiation, a syncytial growth pattern, and pushing borders suggest RER+. *Am J Pathol.* 1998;152:1501.
68. Gordon TA, Burleyson GP, Tielsch JM, et al. The effects of regionalization on cost and outcome for one general high-risk surgical procedure. *Ann Surg.* 1995;221:43.
69. Sosa JA, Bowman HM, Bass EB, et al. Importance of hospital volume in the overall management of pancreatic cancer. *Ann Surg.* 1998;228:429.

70. Lieberman MD, Kilburn H, Lindsey M, Brennan MF. Relation of perioperative deaths to hospital volume among patients undergoing pancreatic resection for malignancy. *Ann Surg.* 1995;222:638.
71. Birkmeyer JD, Warshaw AL, Finlayson SRG, et al. Relationship between hospital volume and late survival after pancreaticoduodenectomy. *Surgery.* 1999;126:178.
72. Kalsner MH, Ellenberg SS. Pancreatic cancer-adjuvant combined radiation and chemotherapy following curative resection. *Arch Surg.* 1985;120:899–903.
73. Picozzi VJ, Kozarek RA, Traverso LW. Interferon-based adjuvant chemoradiation therapy after pancreaticoduodenectomy for pancreatic adenocarcinoma. *Am J Surg.* 2003;185(5):476–480.
74. Abrams RA, Sohn TA, Zahurak ML, et al. A multivariate model for identifying risk of early death after pancreaticoduodenectomy and adjuvant therapy for periampullary adenocarcinoma: importance for understanding post-treatment outcomes. *Int J Radiat Oncol Biol Phys.* 2002;54(2S):100–101.
75. Neoptolemos JP, Dunn JA, Stocken DD, et al. European Study Group for Pancreatic Cancer. Adjuvant chemoradiotherapy and chemotherapy in resectable pancreatic cancer: a randomised controlled trial. *Lancet.* 2001;358(9293):1576–1585.
76. Oettle H, Post S, Neuhaus P, et al. Adjuvant chemotherapy with gemcitabine vs observation in patients undergoing curative-intent resection of pancreatic cancer: a randomized controlled trial. *JAMA.* 2007 Jan 17; 297(3):267–277.
77. Krishnan S, Rana V, Evans DB, et al. Role of adjuvant chemoradiation therapy in adenocarcinomas of the ampulla of Vater. *Int J Radiat Oncol Biol Phys.* 2008;70(3):735–743.
78. White RR, Xie HB, Gottfried MR, et al. Significance of histological response to preoperative chemoradiotherapy for pancreatic cancer. *Ann Surg Oncol.* 2005;12(3):214–221.
79. Raut CP, Evans DB, Crane CH, et al. Neoadjuvant therapy for resectable pancreatic cancer. *Surg Oncol Clin N Am.* 2004;13:639–661.
80. Jaffee EM, Hruban RH, Biedrzycki B, et al. Novel allogeneic granulocyte-macrophage colony-stimulating factor-secreting tumor vaccine for pancreatic cancer: a phase I trial of safety and immune activation. *J Clin Oncol.* 2001;19(1):145–156.
81. Kindler HL, Friberg G, Singh DA, et al. Phase II trial of bevacizumab plus gemcitabine in patients with advanced pancreatic cancer. *J Clin Oncol.* 2005;23:8033.
82. Cohen SJ, Ho L, Ranganathan S, et al. Phase II and pharmacodynamic study of the farnesyltransferase inhibitor R115777 as initial therapy in patients with metastatic pancreatic adenocarcinoma. *J Clin Oncol.* 2003;21:1301.
83. Van Cutsem E, Karasek P, Oettle H, et al. Phase III trial comparing gemcitabine + R115777 (Zarnestra) versus gemcitabine + placebo in advanced pancreatic cancer (PC) [abstr]. *Proc Am Soc Clin Oncol.* 2002;21:130a.
84. Safran H, Iannitti D, Ramanathan R, et al. Herceptin and gemcitabine for metastatic pancreatic cancers that overexpress HER-2/neu. *Cancer Invest.* 2004;22:706.
85. Moore MJ, Goldstein D, Hamm J, et al; National Cancer Institute of Canada Clinical Trials Group. Erlotinib plus gemcitabine compared to gemcitabine alone in patients with advanced pancreatic cancer. a phase III trial of the National Cancer Institute of Canada Clinical Trials Group [abstr]. *Proc Am Soc Clin Oncol.* 2005;24:1.



*This page intentionally left blank*

# ENDOCRINE TUMORS OF THE PANCREAS

Taylor S. Riall • B. Mark Evers

## INTRODUCTION

Pancreatic endocrine tumors are rare and occur with an annual incidence of approximately 5 cases per 1,000,000 population.<sup>1</sup> They are classified as “functioning” if they produce symptoms related to hormone overproduction, or as “nonfunctioning.” The morbidity from pancreatic endocrine tumors arises from the secretion of active gastrointestinal hormones leading to the characteristic syndromes and physiologic derangements associated with pancreatic endocrine tumors. These tumors can occur sporadically or can be associated with inherited disorders. The diagnosis of pancreatic endocrine tumors is usually established by biochemical assay of abnormally high blood hormone levels consistent with the observed clinical syndrome. Even with the diagnosis, management can be difficult because localization is the key to the treatment. Benign and malignant neuroendocrine tumors appear histologically similar, as clustered nests of normal islet cells. Malignancy is defined by the presence of local invasion or metastasis to distant sites, and the functional status is determined by tissue staining for the specific hormone product.

Surgical resection is the mainstay of treatment and only curative option for pancreatic endocrine tumors. Unlike patients with tumors arising from the exocrine pancreas, surgical resection offers a high chance for cure in patients with localized disease. Surgical resection even has a role in metastatic disease, serving to debulk the disease and limit the associated debilitating symptoms arising from hormone overproduction. This chapter reviews the clinical syndromes, diagnostic tools, and therapeutic approach to pancreatic endocrine tumors.

## PANCREATIC ENDOCRINE PATHOLOGY, ANATOMY AND PHYSIOLOGY

Pancreatic islets are of part of the family of amine precursor uptake and decarboxylation (APUD) cells and constitute less than 2% of the pancreatic mass. Each pancreatic islet

contains an average of over 3000 cells and is composed of four cell types (Table 60-1): Alpha (A) cells that secrete glucagon, beta (B) cells that secrete insulin and amylin, delta (D) cells that secrete somatostatin, D<sub>2</sub> cells that secrete vasoactive intestinal peptide (VIP), and F cells that secrete pancreatic polypeptide (PP). B cells are located centrally within the islets and constitute approximately 70% of the islet cell mass. F cells and A cells are located along the islet periphery and constitute 15 and 10% of the islet mass, respectively. D cells are evenly distributed throughout the islets and constitute the remaining 5% of the islet cell mass (Fig. 60-1).<sup>2</sup> Cells secreting gastrin (G cells) are not present in the pancreas in the nondisease state.

The distribution of pancreatic endocrine cell types is not uniform throughout the gland. Alpha cells are concentrated in the body and tail of the pancreas, and F cells are concentrated in the uncinate process, whereas B and D cells are evenly distributed throughout the pancreas. This distribution is of clinical relevance, because resection of different parts of the pancreas will have different endocrine consequences. Pancreatic islets have a rich blood supply into which the hormone products are secreted.

## HISTOLOGY

Pancreatic neuroendocrine tumors are thought to arise from pluripotent cells in the ductal epithelium.<sup>3</sup> A normal pancreatic islet is shown in Fig. 60-2A. Benign and malignant neuroendocrine tumors appear histologically similar as uniform, clustered nests of normal islet cells (Fig. 60-2B). Differentiation from neuroendocrine lineage is suggested by positive cytoplasmic staining with silver stains. In addition, many neuroendocrine tumors stain positive for chromogranin and synaptophysin (Fig. 60-2C).<sup>4</sup> Cellular patterns can be either solid, acinar, or trabecular, but the specific pattern is not correlated with biological behavior. Malignancy is defined by the presence of local invasion or metastasis to distant sites. Functional status is determined by tissue staining for the specific hormone product (Fig. 60-2D).<sup>4</sup>

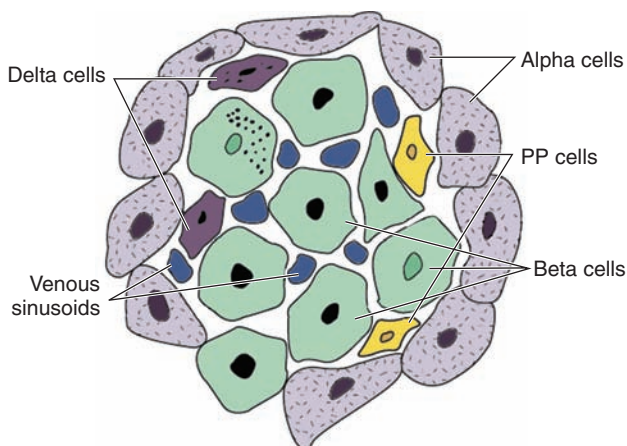
**TABLE 60-1: PANCREATIC ENDOCRINE TUMORS: ENDOCRINE CELL TYPE, HORMONES PRODUCED, CLINICAL SYNDROMES, AND DISTRIBUTION OF CELLS WITHIN THE PANCREAS**

Cell Type	Hormone Produced	Endocrine Tumor/Syndrome	Distribution of Cells throughout the Pancreas
Alpha (A)	Glucagon	Glucagonoma	Uniform throughout
Beta (B)	Insulin	Insulinoma	Body/tail
Delta (D)	Somatostatin	Somatostatinoma	Uniform throughout
F	PP	PPoma	Uncinate process
D <sub>2</sub>	VIP	VIPoma/WDHA	Uniform throughout
G	Gastrin	Gastrinoma/ZES	Not present/secreted in normal state

PP, pancreatic polypeptide; VIP, vasoactive intestinal peptide; WDHA, watery diarrhea, hypokalemia, and achlorhydria; ZES, Zollinger-Ellison syndrome.

## HISTORY

In 1908, Nichols reported the first description of a pancreatic adenoma composed of islet tissue. Several years later, Mayo recognized the relationship between hyperinsulinemia and a pancreatic islet cell tumor. Subsequently, Whipple's triad (symptoms of hypoglycemia, low blood



Cell Components of a Pancreatic Islet

**FIGURE 60-1** This diagram depicts the cells that compose a pancreatic islet and their typical location within the islet (ie, alpha cells on the periphery and beta cells localized to the central region). The dots within the beta cell cytoplasm depict the strong staining often seen from insulin-containing granules. Delta and PP cells constitute only a minority of the pancreatic islets endocrine cells. The rich blood supply is demonstrated by the abundance of venous sinusoids within the islet.

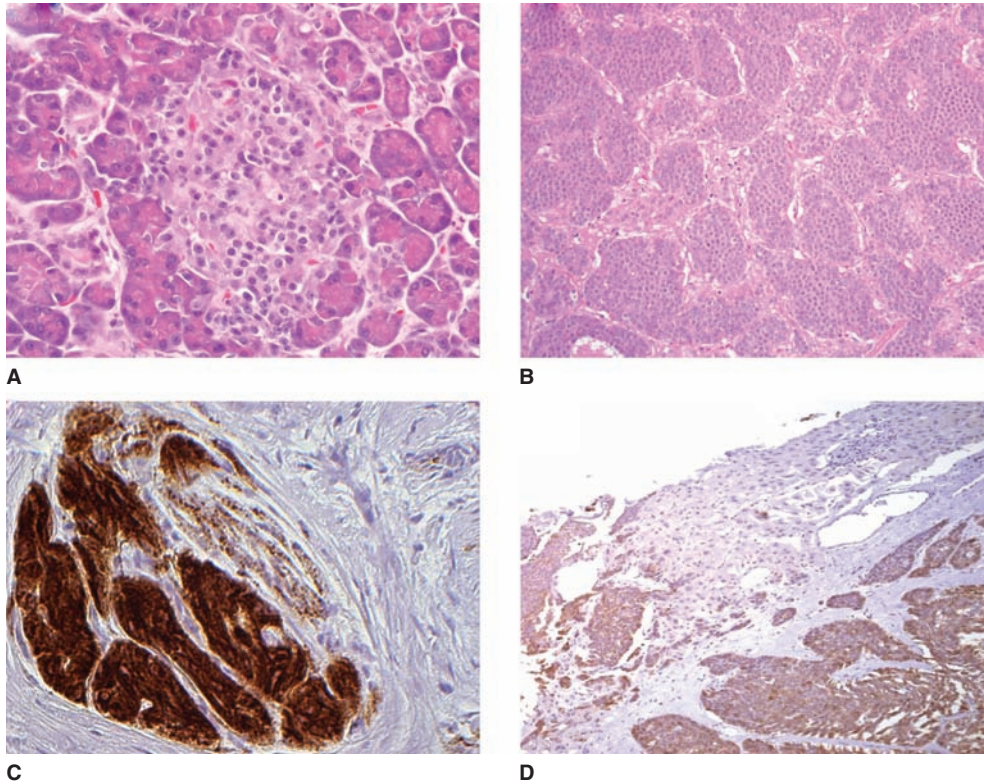
glucose, and relief of symptoms by administration of glucose, Table 60-2) was described in 1935 by Whipple and Frantz.<sup>5</sup> Over the next 25 years, additional syndromes associated with islet cell tumors were identified and reported. In 1942, Becker et al described a patient with severe dermatitis, anemia, and diabetes who also had an islet cell tumor.<sup>6</sup> Over two decades later in 1966, McGarvan et al identified the cause of the syndrome described by Becker, a glucagon-secreting islet cell carcinoma of the pancreas.<sup>7</sup> Zollinger and Ellison described a syndrome of severe peptic ulcer disease, acid hypersecretion, and a non-beta islet cell tumor of the pancreas in 1955.<sup>8</sup> It was later found that the overproduction of gastrin by the islet cell tumor was the cause of the syndrome, now known as *Zollinger-Ellison syndrome* (ZES). The first description of watery diarrhea and hypokalemia related to an islet cell tumor was by Priest and Alexander in 1957.<sup>9</sup> In 1958, Verner and Morrison described two patients who died from refractory watery diarrhea and hypokalemia and an associated islet cell tumor.<sup>10</sup> Later, this syndrome was clearly defined when patients with this constellation of symptoms and an islet cell tumor were found to have high circulating levels of VIP.<sup>11</sup> Initially, the lack of sensitive radioimmunoassay techniques limited the understanding and diagnosis of these syndromes. Yalow and Berson developed and refined these techniques in 1956 allowing for detection of micromolar concentrations of circulating peptides.<sup>12</sup> The distribution of islet cell tumors by functional syndrome is shown in Fig. 60-3.

## GENETICS

While the majority of pancreatic endocrine tumors occur sporadically, others can be associated with genetic syndromes. The tumorigenesis pathway in neuroendocrine tumors differs from that of pancreatic adenocarcinoma. Mutations in the *k-ras*, *p53*, *myc*, *fos*, *jun*, *src*, and the *retinoblastoma* genes are not seen. Transcriptional silencing is thought to play a role in neuroendocrine tumorigenesis. More than 90% of gastrinomas and nonfunctioning neuroendocrine tumors had homozygous deletions or silencing 5' CpG island methylation.<sup>13</sup> Loss of heterozygosity (LOH) at chromosome 11q is common in functional pancreatic endocrine tumors, while LOH at chromosome 6q is associated with the development of nonfunctional tumors.<sup>14</sup> One-third of patients with sporadic pancreatic endocrine tumors have been shown to have allelic loss on chromosome 3p. This allelic loss is associated with malignant clinical disease.<sup>15</sup>

The most common genetic syndrome associated with pancreatic endocrine tumors is multiple endocrine neoplasia type 1 (MEN1 Werner syndrome). Pancreatic endocrine tumors occur in 30–80% of patients with MEN1. The syndrome is also characterized by parathyroid hyperplasia and pituitary adenomas, but tumor-related death in MEN1 patients is most often related to metastatic pancreatic endocrine cancers. It is caused by mutations/allelic deletions in the tumor suppressor gene, *MEN1*, on chromosome 11q13 and is inherited in an autosomal dominant fashion. Mutation or





**FIGURE 60-2** **A.** High-power view of a normal pancreatic islet on H and E staining. The endocrine cells are arranged as irregular cords around abundant capillaries into which the hormone products are secreted. The islets are surrounded by clusters of acinar cells. No pancreatic ductal cells are seen in this image. **B.** H and E stain of a pancreatic endocrine tumor. Note the uniform, clustered nests of normal-appearing islet cells with scant mitosis. **C.** Pathology of a pancreatic endocrine tumor stained positive for chromogranin, a neuroendocrine tumor marker. The chromogranin is cytoplasmic and stains brown. **D.** Pancreatic endocrine tumor staining positive for gastrin, diagnostic of gastrinoma. Again, the staining is cytoplasmic. (*A* and *B* used, with permission, from Christine Iacobuzio-Donahue, MD, PhD, Johns Hopkins Medical Institutions, Baltimore, MD; *C* and *D* used, with permission, from Richard W. Goodgame, MD, University of Texas Medical Branch, Galveston, TX.)

allelic deletion causes loss of tumor suppressor function and predisposes patients to neoplastic growth in the parathyroid, pituitary, and pancreatic endocrine tissue. Patients with MEN1-associated pancreatic endocrine tumors are usually younger (30–40 years old), have malignant disease, and have multicentric disease than those with sporadic tumors. Approximately 50% of patients with MEN1-associated neuroendocrine tumors will present with metastatic disease.<sup>16</sup> Gastrinomas are the most common functional pancreatic endocrine tumors occurring in MEN1 patients (54% of functional MEN1-associated tumors).

PPomas (which are not associated with a functional syndrome) are the most commonly observed islet cell tumor in patients with MEN1, observed in more than 80% of MEN1 cases.

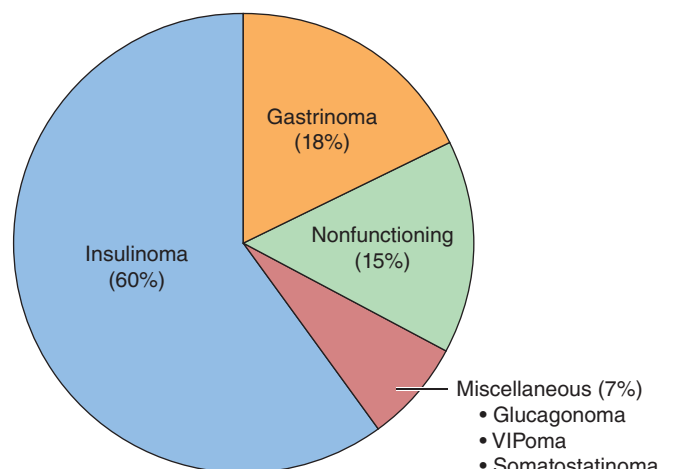
#### TABLE 60-2: DIAGNOSIS OF INSULINOMA

Whipple's triad:

- Symptoms of hypoglycemia
- Low (<45 mg%) blood sugar
- Relief of symptoms with glucose

Triad precipitated by 12-hour fast in 37% of patients by 24-hour fast in 73%.

Management of patients with MEN1 and pancreatic endocrine tumors requires recognition and staged treatment of associated tumors. Patients suspected of having MEN1 should undergo biochemical screening for gastrin, insulin/proinsulin, PP, glucagons, and chromogranin A (a tumor



**FIGURE 60-3** Relative incidence of pancreatic endocrine tumors.

marker elaborated by most pancreatic endocrine tumors). Hyperparathyroidism, if present, should be treated first as correction of hypercalcemia will improve the outcome of treatment for gastrinomas.<sup>17</sup> Gastrinomas in MEN1 patients are more likely to occur in the duodenum and are more likely to be multiple, complicating their management.<sup>16,18–20</sup> Conversely, treatment of insulinomas or VIPomas associated with MEN1 is essentially identical to those seen in sporadic disease.

## DIAGNOSIS

### Insulinoma

Insulinomas occur at an annual incidence of 1 per 1,000,000 patients per year and account for 60% of all pancreatic islet cell tumors (see Fig. 60-3).<sup>1</sup> There is no gender or race predilection, and the average age of patients at the time of diagnosis is 45 years old. Despite the predominance of beta cells in the body and tail of the pancreas, 97% insulinomas are located in the pancreas with equal distribution in the head, body, and tail. The remaining 3% of insulinomas are located in the duodenum, splenic hilum, or gastrocolic ligament. Insulinomas are typically small with an average size of 1.0–1.5 cm. Grossly, they are encapsulated, firm, hypervascular, yellow-brown nodules. Because of their rich vascular supply, pancreatic endocrine tumors are hyperattenuating when compared to surrounding pancreatic tissue on contrast-enhanced computed tomography (CT) or magnetic resonance imaging (MRI).<sup>21</sup> About 90% of insulinomas are benign. Histologically, they appear as clustered nests of normal islet cells, without typical islet anatomy, which stain positive for insulin. Most occur as solitary lesions; however, multicentricity does occur in 10% of cases and should alert the physician to the possibility of MEN1 that occurs in 4–7% of all patients with insulinoma.

Proinsulin, the precursor peptide to insulin, is secreted by insulinomas. Similar to their normal beta-cell counterparts, the proinsulin is cleaved into C-peptide in the Golgi complex and released into the blood stream as functional insulin and the associated C-peptide cleavage product. However, insulinoma cells do not respond to the normal regulatory pathways, leading to tumor overproduction of proinsulin, high circulating levels of insulin causing profound, and potentially dangerous hypoglycemia. This may lead to neuroglycopenic symptoms, including headache, lethargy, dizziness, diplopia, diaphoresis, palpitations, anxiety, hunger, amnesia, and even seizures. Symptoms tend to occur early in the morning before eating or after exercise and are the result of sympathetic nervous system response to profound hypoglycemia, with release of catecholamines and glucagon. These symptoms may partially resolve if glycogenolysis is also stimulated, thus increasing glucose levels and reducing the catecholamine surge by feedback inhibition. Patients with insulinoma are often overweight, as they will typically attempt to control their symptoms by eating

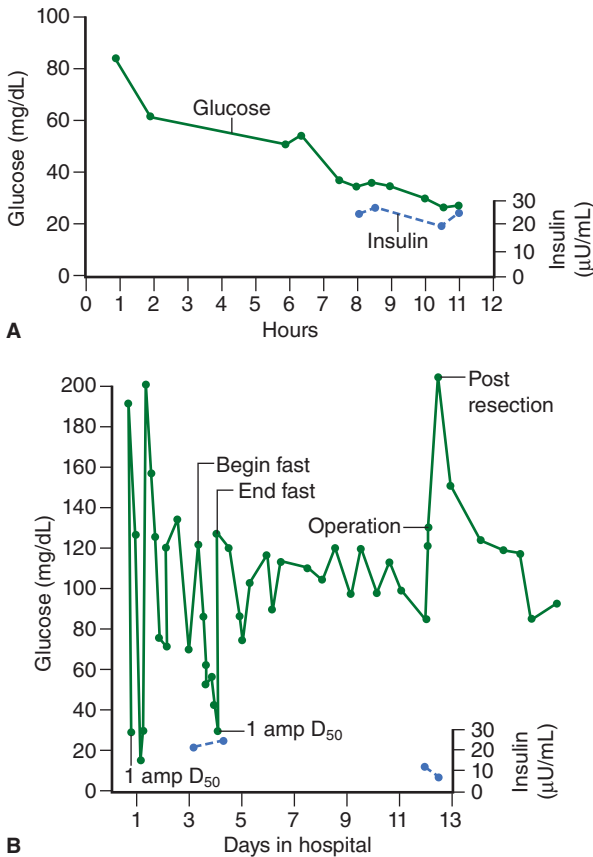
frequent meals. Chronic hypoglycemia may have profound, even permanent neurologic consequences, including apathy, clouded sensorium, behavioral changes, seizures, and coma.

Laboratory studies will usually confirm the diagnosis of insulinoma. Classically, patients will present with Whipple's triad: a low glucose level (<50 mg/dL) while having symptoms of hypoglycemia, which resolve with administration of glucose (Whipple's triad) (see Table 60-2). The diagnosis of insulinoma is usually made with a monitored 72-hour fast. The fast is monitored for two reasons: the first is to prevent life-threatening hypoglycemia and the second is to rule out the possibility of factitious hypoglycemia as a result of exogenous insulin administration. C-peptide levels should be measured to confirm an endogenous source of insulin if there is any suspicion of hypoglycemia from surreptitious insulin injections.<sup>22</sup> Also, urine should be checked for elevated sulfonyleurea levels, suggesting surreptitious administration of oral hypoglycemia agents.

Hypoglycemia (<50 mg/dL in men or <40 mg/dL in women) after a 72-hour fast occurs in 95% of patients; 75% of patients will achieve this degree of hypoglycemia within the first 24 hours (Fig. 60-4). Insulin levels greater than 7  $\mu$ U/mL in the presence of hypoglycemia are highly suggestive of an insulinoma; however, these levels can also be found in patients with hyperinsulinemia from other causes. Evaluating the insulin/glucose ratio is also useful. A ratio greater than 0.3 occurs with insulinoma. An insulin to glucose ratio of 0.3 can also occur with obesity as a result of insulin resistance, but these patients should not be hypoglycemic.<sup>23</sup> Levels of circulating proinsulin can be measured and compared to the total insulin present. Proinsulin may account for 40% of total insulin if the tumors are malignant and a proinsulin level greater than 24% of total insulin is suggestive of insulinoma. C-peptide levels of greater than 1.2  $\mu$ g/mL with a glucose level less than 40 mg/dL are also highly suggestive of an insulinoma.<sup>23</sup>

Two other rare clinical syndromes may be difficult to distinguish from insulinoma: nesidioblastosis and noninsulinoma pancreatogenous hypoglycemia (NIPH). Nesidioblastosis will produce neuroglycopenic symptoms due to hyperplasia of pancreatic islets, but no pancreatic tumor is noted.<sup>24</sup> Patients with NIPH have high insulin levels and hypoglycemia; however, symptoms are rare even after a 72-hour fast. Islet cell hypertrophy may be seen with NIPH, but no focal tumor is involved.<sup>25</sup> While less common than in other neuroendocrine tumors, insulinoma can be associated with MEN1 syndrome. This should be considered in the diagnosis, especially because it mandates a different approach to the surgical management.<sup>26</sup>

Provocative testing to confirm the diagnosis of insulinoma is rarely required. When necessary, stimulation of insulin release with calcium gluconate or tolbutamide and serial measurements of insulin and glucose levels should be performed in a carefully monitored setting. Because cerebrocytes use glucose as their sole source of energy, this must be done with extreme caution; profound hypoglycemia and subsequent permanent neurologic injury can occur.

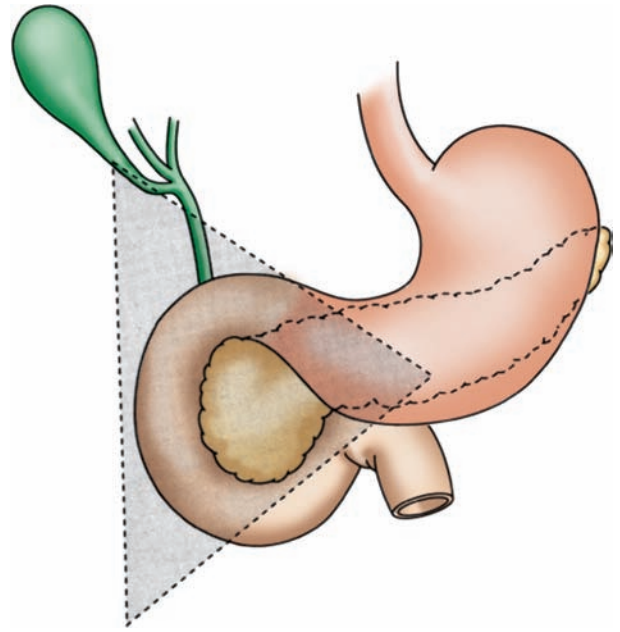


**FIGURE 60-4** **A.** Simultaneous circulating glucose and insulin levels in a fasting patient with insulinoma. Although glucose levels fall, insulin levels remain constant, demonstrating a relative hyperinsulinemia. **B.** Periodic glucose determinations in a patient with insulinoma. The first major fall was spontaneous and the patient became comatose but was resuscitated with an ampule of 50% glucose. On the second occasion, the patient was fasted on purpose. Postoperatively, glucose increased to 200 and then decreased gradually and remained between 90 and 120.

## Gastrinoma

Gastrinomas are the second most common functional pancreatic endocrine tumor with an incidence of 1 per 2.5 million.<sup>27</sup> The mean age of patients at diagnosis is 50, and there is a slight male predominance (60%). Gastrinomas produce ZES (severe peptic ulceration, hypergastrinemia) as the result of overproduction of gastrin that is normally synthesized by G cells located in the antral mucosa of the stomach. Gastrinomas do not secrete gastrin in response to normal stimuli, such as amino acids and peptides in the stomach or gastric distension, and are not subject to normal feedback mechanisms. Specifically, gastrinomas are not suppressed by low luminal pH and can be stimulated (instead of inhibited) by secretin.<sup>28</sup>

Over 60% of gastrinomas are malignant. Similar to other pancreatic endocrine tumors, malignancy is defined by the presence of lymph node or distant metastases. The liver is



**FIGURE 60-5** The gastrinoma triangle—the anatomic triangle in which approximately 90% of gastrinomas are found. (From Stabile BE, Morrow DJ, Passaro E. The gastrinoma triangle: operative implications. *Am J Surg.* 1984;147:26, with permission from Elsevier.)

the most common site of spread, but peripancreatic lymph nodes are also commonly involved. Between 70 and 80% of patients with malignant gastrinoma have metastases to the liver or lymph nodes at the time of diagnosis. Metastases may also involve the lungs or bone. Ninety percent of gastrinomas are located within the gastrinoma triangle, bounded by the lines connecting the cystic duct, the junction between the second and third portions of the duodenum, and the junction between the neck and body of the pancreas (Fig. 60-5).

It is important to consider the diagnosis of MEN1 in patients with ZES, as 20% of patients with ZES have MEN-associated disease.<sup>16</sup> These patients should be tested for hyperparathyroidism that, if present, should be treated first because it can complicate the management of their gastrinoma.

The diagnosis of ZES is classically made after patients present with severe forms of peptic ulcer disease that are either refractory to standard treatment or are atypical in location. Ninety percent of patients with ZES have peptic ulcers, most in the duodenal bulb with synchronous ulcers found in more distant portions of the duodenum or proximal jejunum. Jejunal ulcer perforations occur in 7% of patients. Patients may complain of upper abdominal pain and/or gastrointestinal bleeding (melena or hematochezia), weight loss, or nausea and vomiting. Symptoms of gastroesophageal reflux are also common. High acid production can lower the normal pH of the duodenum and inactivate pancreatic enzymes, leading to diarrhea, which is relieved by nasogastric suction. Endoscopy performed in patients with ZES may show multiple ulcers, large gastric rugal folds, edema of the mucosa lining the duodenum



**TABLE 60-3: CAUSES OF HYPERGASTRINEMIA**

High Gastric Acid Output	Low Gastric Acid Output
Gastrinoma	H <sub>2</sub> -receptor antagonist therapy
Gastric outlet obstruction	Proton pump inhibitor therapy
G-cell hyperplasia	Prior acid-reducing procedure
Retained gastric antrum	Atrophic gastritis
	Pernicious anemia
	Achlorhydria
	Renal failure

or proximal jejunum, or jejunal hypermotility. ZES should be suspected in patients with ulcer disease and diarrhea, a strong family history of peptic ulcer disease, atypical or multiple ulcers, or recurrence of ulcers after acid-reducing operations or H<sub>2</sub> blocker or proton pump inhibitor (PPI) therapy.

The diagnosis of ZES is usually made by laboratory testing for gastrin levels. Other conditions can also cause hypergastrinemia (Table 60-3) and fall into two categories: hypergastrinemia associated with high and low gastric acid output. The other diagnoses should be excluded before making the diagnosis of ZES. It is important to document acid secretion (low gastric pH), because conditions causing low acid secretion or achlorhydria can also lead to elevated gastrin levels. A gastric pH greater than 3 without acid-suppressing medications or prior acid-reducing operations virtually excludes ZES as the potential cause of hypergastrinemia. H<sub>2</sub> blockers should be stopped 1 week or PPIs 3 weeks before testing for gastrin levels. If achlorhydria is suspected, gastric acid production can be measured. Basal acid output in patients with ZES is usually greater than 15 mEq/h, which is not seen with achlorhydria.

Three normal fasting serum gastrin determinations should be done to exclude ZES. The fasting serum gastrin level is typically 200–1000 pg/mL in patients with a gastrinoma, compared to 100–150 pg/mL in normal patients. A gastrin level of greater than 1000 pg/mL in a patient without gastric outlet obstruction or suppression of acid production is virtually diagnostic of ZES. In equivocal cases, a secretin stimulation test can also be used to confirm the diagnosis: 2 IU/kg of secretin is given intravenously and serum obtained for gastrin levels before injection and every 3–5 minutes thereafter for 30 minutes. The diagnosis is made when gastrin levels rise above 200 pg/mL or greater than 50% above baseline levels following administration of secretin.

## VIPomas

VIP is a small peptide normally found in the brain, G cells of the antrum, adrenal medulla, gut mucosa, pancreatic neurons, and the D<sub>2</sub> cells of pancreas. VIPomas in the pancreas are believed to originate from neoplastic D<sub>2</sub> cells that release

high levels of VIP producing the Verner-Morrison syndrome. This syndrome is also known as *WDHA syndrome* (an acronym for its most prominent symptoms—Watery Diarrhea, Hypokalemia, and Achlorhydria) or pancreatic cholera. Overall, these tumors are exceedingly rare with an incidence 1 per 10,000,000 population.<sup>29,30</sup> Over two-thirds are malignant and at the time of presentation over 70% of patients have metastatic disease.<sup>31</sup> Ninety percent of lesions are found in the pancreas, while 10% have been described in the colon, bronchus, liver, adrenal gland, and sympathetic ganglia. Pancreatic lesions are usually solitary, and 75% are found in the pancreatic body or tail. Lesions tend to be large and are usually diagnosed at greater than 3 cm in size. There is a bimodal age distribution with most patients diagnosed at middle age but a small percentage (~10%) diagnosed before the age of 10. Elevated VIP levels in these young patients are most commonly from ganglioneuromas, ganglioblastomas, or neuroblastomas, instead of pancreatic tumors. Approximately 10% of patients with VIPomas have MEN1.

Superphysiologic levels of VIP cause the symptoms associated with Verner-Morrison syndrome. VIP is a 28-amino acid polypeptide with close structural homology to secretin. VIP normally functions as a neurotransmitter. It has a half-life of less than 1 minute, and levels are low and unresponsive to meals in individuals without VIPomas. VIP acts on intestinal epithelial cells to activate adenylate cyclase, thus increasing cyclic adenosine monophosphate (cAMP) levels within colonocytes, which stimulates hypersecretion of fluid into the lumen, resulting in watery diarrhea. The diarrhea is further exacerbated as cAMP inhibits sodium reabsorption and stimulates chloride secretion causing increased fluid and electrolyte shifts into the intestinal lumen. Profuse, watery, iso-osmotic secretory diarrhea is the most common presenting symptom and may exceed a volume of 3 L/d.

The differential diagnosis for watery diarrhea is shown in Table 60-4. Stool volume less than 700 g/d is unlikely a result of VIPoma. This secretory diarrhea is independent of food intake and does not resolve with nasogastric suction, distinguishing it from the diarrhea associated with ZES. The liquid stool has the appearance of “weak tea” and is devoid of blood, fat, or inflammatory cells, which further distinguishes VIP-associated diarrhea from infectious, inflammatory, and malabsorptive conditions. Weight loss, crampy abdominal pain, dehydration, electrolyte abnormalities, and metabolic acidosis (from fluid and bicarbonate loss) are common. Hypokalemia may be profound as patients can lose more than 400 mEq of potassium/d, which may lead to disturbances of cardiac rhythm and even sudden death in extreme cases. Nearly 75% of patients have hypochlorhydria or achlorhydria and decreased levels of magnesium and phosphorus are often present. The profound electrolyte abnormalities and associated dehydration associated with Verner-Morrison syndrome need to be corrected prior to definitive surgical management.

Diagnosis of a VIPoma can be established by measuring serum levels of VIP, which are usually greater than 150 pg/mL, in association with secretory diarrhea. Levels of VIP should be measured after an overnight fast. VIPomas commonly

**TABLE 60-4: DIFFERENTIAL DIAGNOSIS OF CHRONIC DIARRHEA**

Secretory Diarrhea	Osmotic Diarrhea
Bacterial toxins	Osmotic laxative abuse
Nonosmotic laxative abuse	Carbohydrate malabsorption
Ileal bile acid malabsorption	Steatorrhea
Neoplasm	Mg <sup>2+</sup> ingestion
Colon adenocarcinoma	PO <sub>4</sub> <sup>3-</sup> ingestion
Villous adenoma of colon	SO <sub>4</sub> <sup>2-</sup> ingestion
Intestinal lymphoma	Olean ingestion
Gastrinoma	Sucralose ingestion
VIPoma	
Somatostatinoma	
Carcinoid syndrome	
Mastocytosis	
Medullary thyroid carcinoma	
Drugs and poisons	
Postvagotomy diarrhea	
Hyperthyroidism	
Addison's disease	
Epidemic secretory diarrhea	
Idiopathic secretory diarrhea	
Inflammatory bowel disease	
Diverticulitis	
Ischemic bowel	

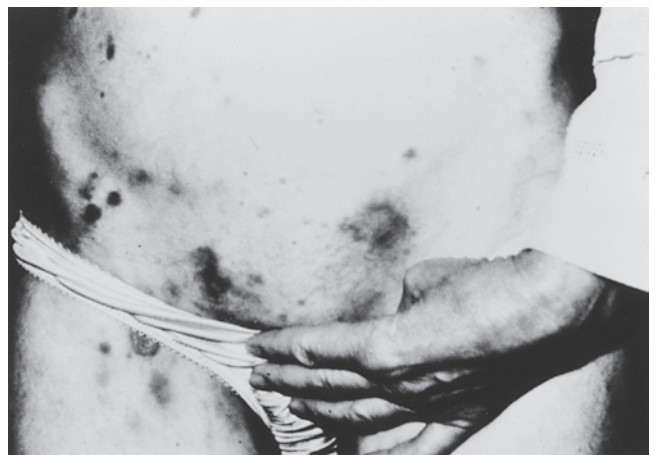produce additional GI peptides, including PP, calcitonin, neurotensin, gastrin, gastric inhibitory peptide, serotonin, glucagons, insulin, somatostatin, growth hormone–releasing hormone, and peptide histidine-methionine.<sup>32</sup>

## Glucagonomas

Glucagonomas are exceedingly rare with an estimated incidence of 1 per 20,000,000 population.<sup>33</sup> They are two to three times more common in women than men and tend to be larger than most other pancreatic endocrine tumors, averaging 5–10 cm in size at the time of diagnosis. Glucagonomas are believed to arise from neoplastic alpha cells that normally produce glucagon to maintain glucose homeostasis. These tumors nearly always arise in the pancreas; 65–75% of these are found in the body or tail, which corresponds to the normal distribution of alpha-cells in the pancreas. Malignancy occurs in over 50% of patients with a glucagonoma,<sup>34</sup> as defined by metastases to regional lymph nodes or the liver. Eighty percent of patients with malignant glucagonomas have liver metastases at the time of diagnosis. Most glucagonomas are sporadic; however, 5–17% are associated with MEN1. As with other neuroendocrine tumor, patients with MEN1 associated glucagonomas tend to be younger and have more advanced disease at the time of diagnosis.

The glucagonoma syndrome is a rare syndrome with a classic presentation of the “four Ds”: diabetes, dermatitis, deep vein thrombosis, and depression. It is also characterized by a severe catabolic state with weight loss, depletion of fat and protein stores, and associated vitamin deficiencies.<sup>34,35</sup> Glucagon acts on the liver to stimulate glucose release, glycogenolysis, gluconeogenesis, and ketogenesis. It also acts to inhibit glycolysis and lipogenesis. This catabolic state causes hyperglycemia, depletion of the circulating pool of amino acids, and depletion of fat stores. Diabetes develops in 76–94% of patients with glucagonoma at some point during their illness, and 38% of patients will demonstrate an elevated glucose level at initial presentation. Hypoaminoacidemia and normochromic normocytic anemia are also common.

The classic rash associated with glucagonoma is necrolytic migratory erythema (Fig. 60-6).<sup>36</sup> It is noted in approximately two-thirds of patients and often appears before other symptoms of the syndromes. The etiology is thought to be due to severe amino acid deficiency, although trace element deficiency and general malnutrition probably contribute. Necrolytic migratory erythema begins as erythematous patches in intertriginous areas that spread radially to form a serpiginous pattern on the trunk, extremities, or face. Bullae develop and then slough, leaving crusty necrotic areas that may become superinfected with bacteria or fungi from the skin. Healing begins from the center of these lesions and takes between 2 and 3 weeks, leaving the healed skin hyperpigmented. With successful treatment of the underlying glucagonoma, this rash usually resolves spontaneously. The diagnosis of glucagonoma is established by measuring glucagon levels; a fasting glucagon level greater than 50 pmol/L is considered diagnostic.



**FIGURE 60-6** Characteristic skin rash associated with glucagonoma. This figure shows the migratory necrolytic dermatitis in a woman, 42 years of age, who has been symptomatic for 16 years. The rash had spread to involve the entire body. Note the central clearing. (Used, with permission, from Hugo Villar, from Beauchamp RD, Thompson JC, Endocrine tumors of the pancreas. In: Zinner MJ, Schwartz SI, Ellis H, eds. *Maingot's Abdominal Operations*. 10th ed. Appleton & Lange/McGraw-Hill; 1997:1961–1976.)

## Somatostatinomas

Somatostatinomas are exceedingly rare with fewer than 100 cases reported in the literature. These tumors are usually large (85% are >2 cm) and solitary. Patients are typically in their fifth or sixth decade of life at the time of diagnosis. Over 60% are found in the pancreas (usually the head) with the remainder in the duodenum or elsewhere in the small intestine. The majority are malignant with metastases to the liver or lymph nodes commonly noted at the time of diagnosis.<sup>37</sup> Somatostatinomas are rarely associated with MEN1 but are associated with von Recklinghausen's disease<sup>38</sup> and pheochromocytomas.

Somatostatin, normally produced by the delta cells of the pancreas, function in a paracrine fashion to inhibit the secretion of glucagon, insulin, VIP, gastrin, secretin, motilin, and PP from pancreatic islets and cholecystokinin (CCK)-mediated release of pancreatic enzymes. Inhibition of pancreatic enzyme and hormone secretion causes steatorrhea, diabetes, malabsorption, and cholelithiasis due to reduced gallbladder emptying.<sup>39</sup>

Because the symptoms are nonspecific, the diagnosis of somatostatinoma is rarely made preoperatively. When suspected, the diagnosis can be confirmed by documenting an elevated fasting somatostatin level of greater than 14 mol/L.<sup>40</sup>

## Nonfunctional Neuroendocrine Tumors

Twenty percent of pancreatic endocrine tumors are nonfunctional, defined as a pancreatic tumor arising from endocrine origin with no definable hormonal syndrome. PP, neurotensin, and calcitonin-secreting tumors are also classified as nonfunctional: The hormone products have little biological consequence and rarely cause symptoms.<sup>41</sup> Nonfunctional tumors are usually diagnosed by histologic findings after a suspected pancreatic exocrine tumor has been resected, or less commonly discovered during the workup for nonspecific gastrointestinal complaints. On microscopic examination, nonfunctional tumors do not appear different than their functional counterparts; the endocrine origin of these tumors is usually identified by positive immunostaining for chromogranin or synaptophysin.

Two-thirds of nonfunctional pancreatic endocrine tumors are malignant, and 60–80% of malignant tumors have metastasized to distant sites at the time of diagnosis. These tumors are typically larger than their functional counterparts (4–5 vs 1–2 cm, respectively) when initially discovered. Patients may present with abdominal pain and jaundice secondary to compression of adjacent structures. This is particularly common with PPomas that occur predominately within the head of the pancreas.<sup>41</sup>

## Other Pancreatic Endocrine Tumors

Pancreatic endocrine tumors that produce other hormones have been described, but they are extremely rare. Case reports of pancreatic endocrine tumors that secrete gastrin-releasing

factor (GRF), calcitonin, enteroglucagon, CCK, gastric inhibitory peptide, luteinizing hormone, neurotensin, or ghrelin have also been described.

## IMAGING AND LOCALIZATION

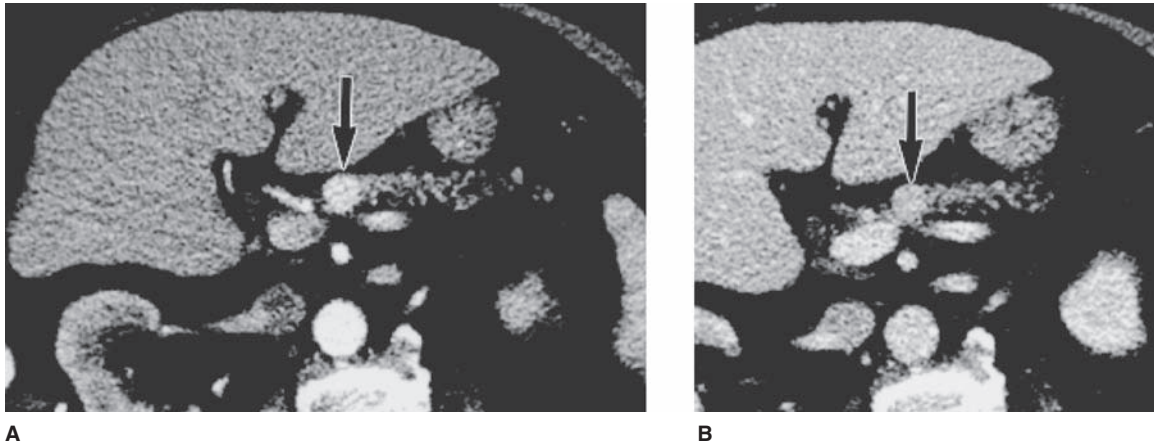
### Modalities

Once the diagnosis of a functional pancreatic endocrine tumor is made, cross-sectional imaging with CT or MRI is the first step in localization. In a large single-institution study, 50% of functioning islet cell tumors were less than 1.3 cm in size.<sup>42</sup> The sensitivity of dual-phase CT in the localization of functioning islet cell tumors is 71–82%.<sup>43</sup> The sensitivity is directly related to the size of the tumor, so insulinomas and gastrinomas that present at a smaller size are more difficult to localize. As a result, the CT technique including thinner collimation (1-mm cuts) and multiple-phase imaging is critical to improving sensitivity of CT for these small lesions.<sup>21,43</sup> Capturing the vascular blush in the arterial phase is critical in identification and differentiation from other types of pancreatic tumors (Fig. 60-7A).<sup>21</sup> The enhancement is less pronounced in the venous phase (Fig. 60-7B). In addition, the use of water as oral contrast may assist in identifying small duodenal gastrinomas.<sup>21</sup>

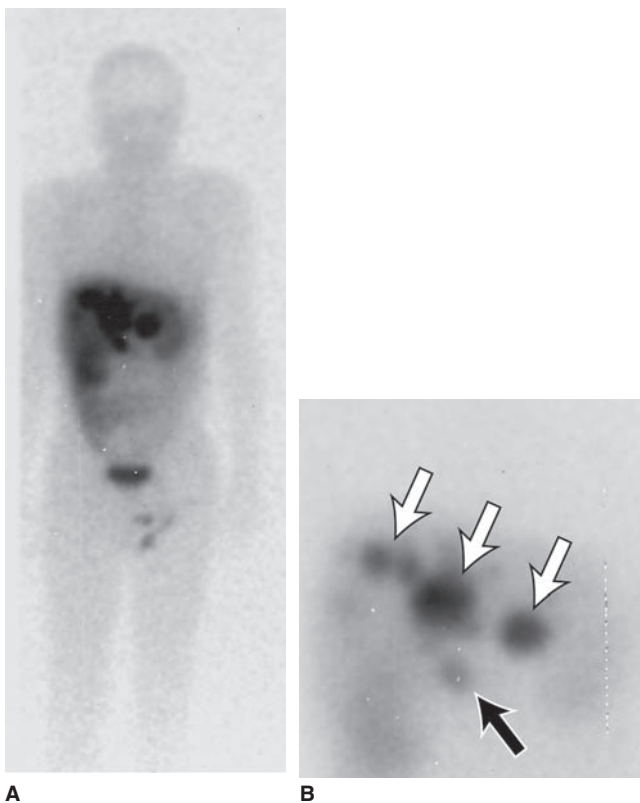
The ability of MRI to demonstrate contrast between normal pancreatic parenchyma and small pancreatic endocrine tumors makes this modality a useful primary modality for localization. Pancreatic endocrine tumors demonstrate low-signal intensity on T1-weighted images and high-signal intensity on T2-weighted images. As with CT, size is directly related to sensitivity. In one large series of insulinomas, contrast-enhanced MRI identified all lesions of greater than 3 cm, 50% of lesions 1–2 cm, and no lesions less than 1 cm.<sup>44</sup> The overall sensitivity of MRI for detecting pancreatic endocrine tumors is 85%.<sup>45</sup> The vast majority of noninsulinoma or nogastrinoma pancreatic endocrine tumors will be identified on cross-sectional imaging.

Many pancreatic endocrine tumors overexpress the somatostatin receptor subtype 2. Somatostatin receptors are present in 100% of gastrinomas, 67% of insulinomas, and no pancreatic adenocarcinomas.<sup>46</sup> They are also present in a significant portion of glucagonomas and nonfunctioning endocrine tumors. Somatostatin-receptor scintigraphy (SRS) involves administering a somatostatin analogue (<sup>111</sup>In-DTPA-D-Phe1 octreotide). The abundance of somatostatin receptors on certain types of pancreatic endocrine tumors makes SRS a useful adjunct in localization, if tumors are not evident on CT/MRI. The sensitivity for SRS is 80% for all pancreatic endocrine tumors excluding insulinomas. The radioisotope scan has an overall sensitivity of 80–100% and specificity of greater than 90% for gastrinomas. This technique is also useful in detecting hepatic metastases from noninsulinoma endocrine tumors (Fig. 60-8). Although sensitive, SRS may not show the exact location of a tumor, only its general vicinity within a few





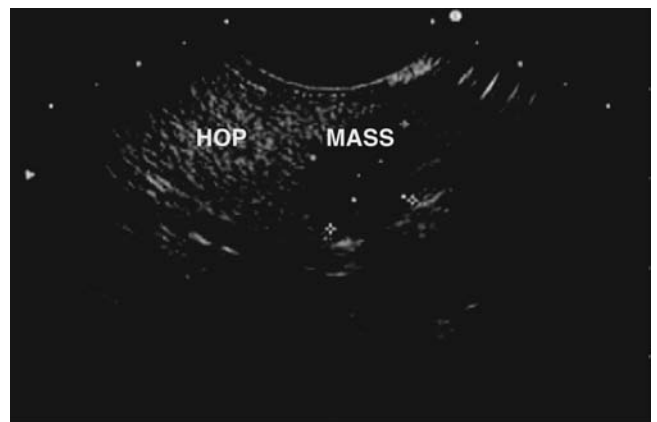
**FIGURE 60-7** An 83-year-old man with life-threatening hypoglycemia and 1.2-cm insulinoma. The patient underwent distal pancreatectomy because enucleation was not possible as a result of lack of sufficient bridging pancreatic tissue. **A.** Axial CT image of pancreas obtained in arterial phase of enhancement shows small homogenous hyperattenuating mass (*arrow*) in neck of pancreas. **B.** Axial CT image obtained at the same level as **A** in venous phase of enhancement shows mass (*arrow*) to be less conspicuous than in arterial phase. (From Sheth S, Hruban RK, Fishman EK. Helical CT of islet cell tumors of the pancreas: typical and atypical manifestations. *AJR Am J Roentgenol.* 2002 Sep;179(3):726, with permission from the American Journal of Roentgenology.)



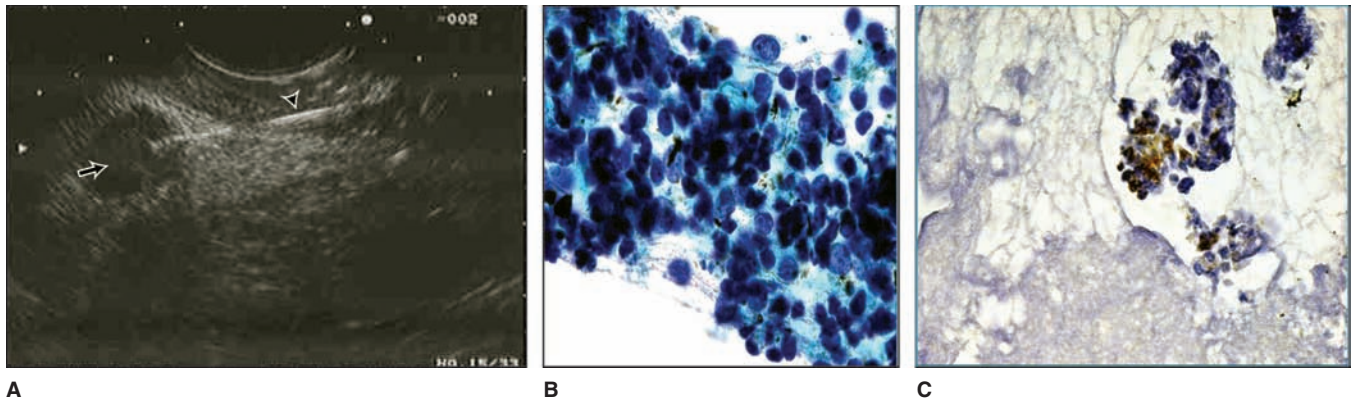
**FIGURE 60-8** Somatostatin receptor scintigram of a patient with metastatic gastrinoma. **A.** Whole-body scan at 24 hours after injection of  $^{111}\text{In}$  octreotide shows metastatic tumor in the liver with primary tumor in the head of the pancreas. **B.** Detail of hepatic metastases with pancreatic primary. *White arrows* denote hepatic metastases. The *black arrow* indicates the primary tumor in the pancreas. (From Thompson JC. Endocrine pancreas. In: Townsend CM, Jr, Beauchamp RD, Evers BM, Mattox KL, eds. *Sabiston Textbook of Surgery: The Biological Basis of Modern Surgical Practice.* 17th ed. Philadelphia, PA: Elsevier Saunders; 2004:1001–1022, with permission. Copyright Elsevier 2004.)

centimeters. More precise localization may be obtained by CT scanning, MRI, or other techniques.

If unable to localize a pancreatic endocrine tumor on CT or MRI, endoscopic ultrasound (EUS) can be performed. When compared to CT or MRI, EUS has a greater sensitivity for detecting tumors less than 3 cm and an overall sensitivity of 93% for tumors of all sizes.<sup>47,48</sup> EUS has significantly improved the ability to localize even small insulinomas preoperatively within the pancreas and GI tract, with a sensitivity and diagnostic accuracy of 81 and 78%, respectively (Fig. 60-9).<sup>49</sup> EUS may be useful to localize pancreatic gastrinomas not seen with other modalities (sensitivity approaches 90%), but detection of duodenal tumors with EUS is still poor (<50%). EUS also



**FIGURE 60-9** Transgastric endoscopic ultrasound (EUS) in a patient with an insulinoma in the neck of the pancreas. The mass (MASS) seen adjacent to the head of the pancreas (HOP) appears hypoechoic relative to the surrounding pancreatic tissue. (Used, with permission, from Richard W. Goodgame, MD, University of Texas Medical Branch, Galveston, TX.)

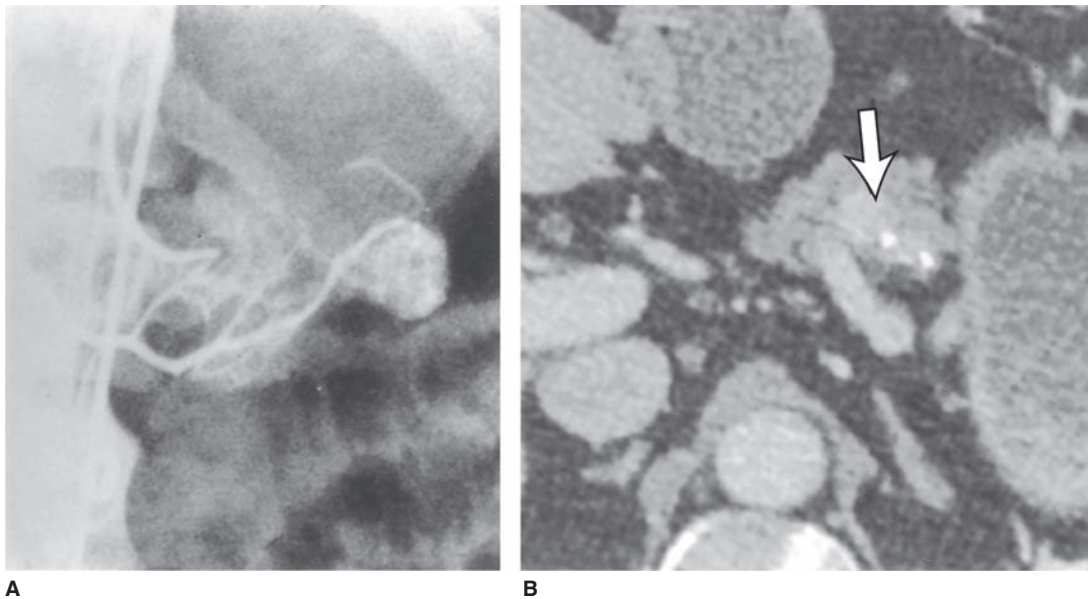


**FIGURE 60-10** **A.** Endoscopic ultrasound (EUS) image of fine-needle aspiration (FNA)/biopsy of pancreatic endocrine tumor. Under direct ultrasound guidance, the needle (*arrowhead*) is placed in the hypoechoic mass (*arrow*). **B.** FNA cytology showing uniform, clustered nests of cells with plasmacytoid appearance with regular nuclear membranes seen with Papanicolaou stain consistent with pancreatic endocrine tumor. **C.** Positive staining for synaptophysin, a pancreatic endocrine tumor marker, on the FNA sample. Synaptophysin stains brown.

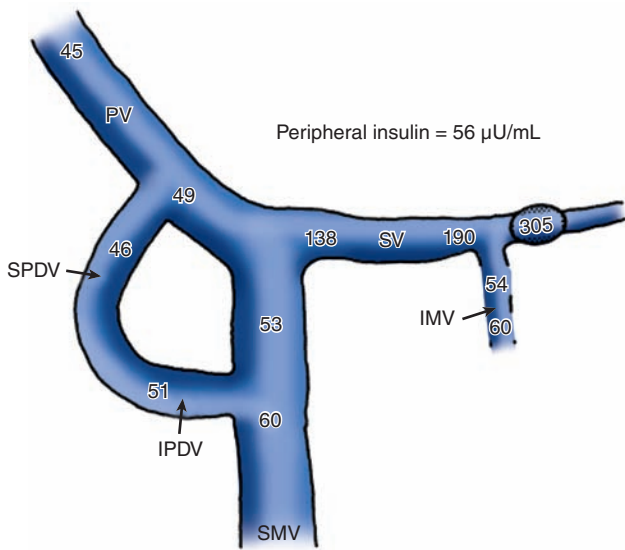
allows for fine-needle aspiration (FNA) of tumors for a pathologic diagnosis (Fig. 60-10). This is especially useful in the case of nonfunctional tumors without a classic CT appearance of pancreatic endocrine tumors. Given the good prognosis of advanced pancreatic endocrine tumors relative to pancreatic adenocarcinoma, an FNA confirming the former may mandate a more aggressive surgical approach.

Angiography is useful for small insulinomas and gastrinomas that have not been identified with CT, MRI, SRS, or EUS. Angiography will detect approximately 70% of

insulinomas greater than 5 mm (Fig. 60-11), showing a characteristic “blush” that corresponds to the highly vascular nature of insulinomas. If standard radiographic techniques are unsuccessful, selective portal venous sampling for insulin or gastrin levels may allow localization to a region of the pancreas (head, body, or tail) to aid in operative planning (see Fig. 60-11). Provocative testing, known as *arterial stimulation venous sampling* (ASVS), can further increase the likelihood of localization by injecting calcium or secretin into the celiac and superior mesenteric arteries with simultaneous portal



**FIGURE 60-11** Localization studies demonstrating an insulinoma. **A.** Arteriographic demonstration of an insulinoma. Selective injection into the specific dorsal pancreatic artery demonstrates the tumor precisely. **B.** Insulinoma with triphasic enhancement on CT. The mass in pancreatic body (*arrow*) demonstrates early and prolonged enhancement with washout during the portal venous phase; note that the maximal difference in enhancement between tumor and normal pancreas occurs during pancreatic phase (shown). (*A* from Edis AJ, McIlrath DC, Van Heerden JA, et al. Insulinoma—current diagnosis and surgical management. *Curr Probl Surg.* 1976;13:1–45, with permission from Elsevier; *B* from Ros PR, Mortelé KJ. Imaging features of pancreatic neoplasms. *JBR-BTR.* 2001;84:239–249, with permission.)



**FIGURE 60-12** Schematic of transhepatic selective venous sampling of the portal vein and its tributaries for insulin. Venous insulin levels are greatly elevated in the distal splenic vein (*shaded circle*). Intraoperative ultrasound and palpation of the pancreas failed to reveal an insulinoma. A distal pancreatectomy was performed on the basis of the portovenous sampling gradient shown here, and the pathologists confirmed the presence of a 1-cm insulinoma. IMV, inferior mesenteric vein; IPDV, inferior pancreaticoduodenal vein; PV, portal vein; SMV, superior mesenteric vein; SPDV, superior pancreaticoduodenal vein; SV, splenic vein. Insulin concentrations are given in microunits per milliliter. (From Norton JA, Shawker TH, Doppman JL, et al. Localization and surgical treatment of occult insulinomas. *Ann Surg.* 1990;212(5):615–620.)

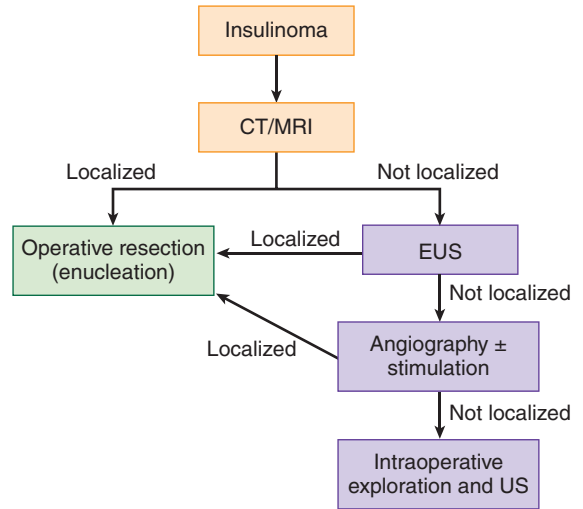
venous sampling for appropriate hormone levels. ASVS has a sensitivity of over 90% (Fig. 60-12).<sup>50,51</sup>

In the unlikely event that preoperative studies cannot localize the tumor; blind exploration with intraoperative ultrasound combined with careful palpation and exploration of the entire pancreas and duodenum will identify most tumors. Performance of effective intraoperative pancreatic ultrasound requires complete mobilization of the pancreas. Duodenal gastrinomas are usually difficult to localize preoperatively by any technique owing to their small size.

### Algorithms for Localization

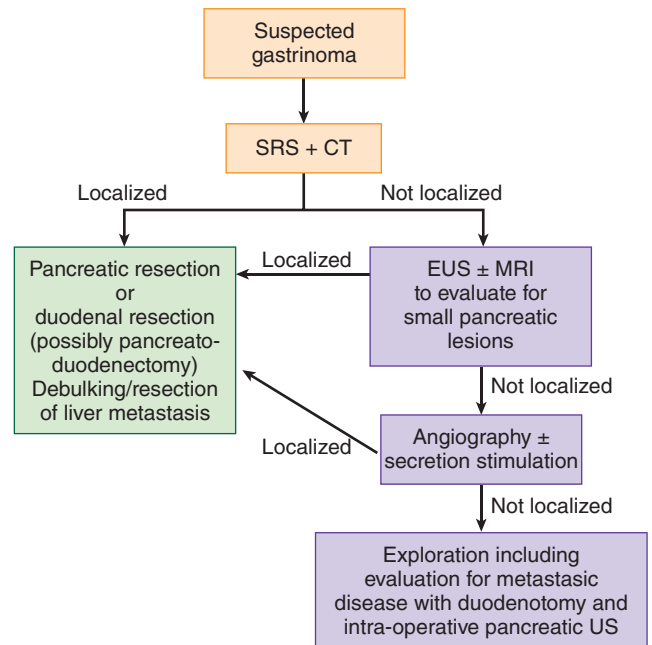
The algorithm for localization of insulinomas is shown in Fig. 60-13. After the biochemical diagnosis of insulinoma is made, CT or MRI should be performed. If the tumor is localized, the surgeon proceeds to resection. If not, EUS should be performed. If the tumor remains unlocalized, angiography with or without stimulation should be performed. Only in the event of all of the above being negative should blind exploration and intraoperative ultrasound be performed.

For patients with biochemically confirmed ZES (Fig. 60-14), the first step of the algorithm should include both



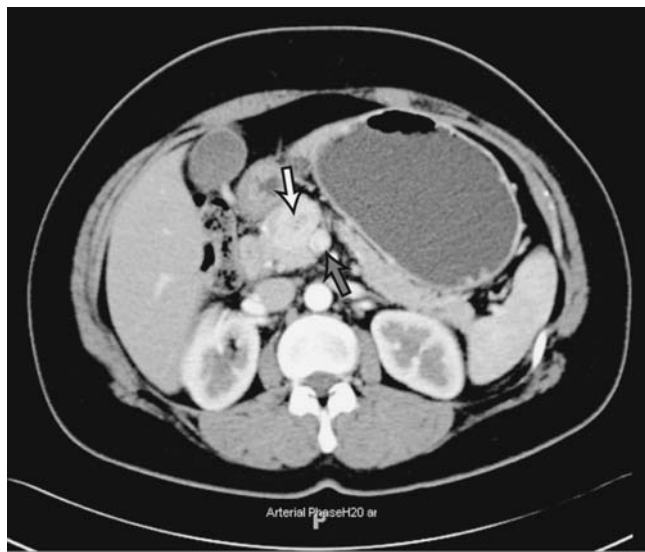**FIGURE 60-13** Localization of insulinomas. EUS, endoscopic ultrasound.

CT and SRS, because nearly all gastrinomas express somatostatin receptors. If not localized, EUS and/or MRI should be used to evaluate for small pancreatic lesions. If localization has still not been achieved, angiography with or without stimulation should be performed next. If not found by other techniques, it may be reasonable to proceed with operative exploration to definitively localize and treat the tumor at the same operation. Intraoperative ultrasound and endoscopic transillumination of the duodenum will aid in the localization of small gastrinomas within the duodenal wall. Routine duodenotomy should also



**FIGURE 60-14** Localization of gastrinomas.





**FIGURE 60-15** CT image of a nonfunctional pancreatic endocrine tumor in a 41-year-old woman. Note the 3.5-cm hyperattenuating mass in the head of the pancreas (*gray arrow*). The mass abuts the superior mesenteric vein (*white arrow*), but there is a good tissue plane between the superior mesenteric vein and the mass. This patient underwent an uncomplicated pancreaticoduodenectomy. (Used, with permission, from Christopher L. Wolfgang, MD, PhD, Johns Hopkins Medical Institutions, Baltimore, MD.)

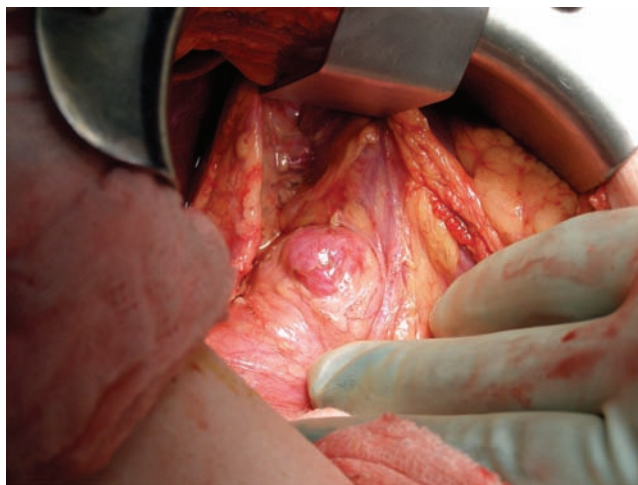
be used especially if the location of the tumor is at all in doubt or if multifocal disease is suspected as is common in MEN1. Duodenotomy will detect 25–30% of tumors not seen on preoperative imaging; therefore endoscopic transillumination of the duodenum and duodenotomy should be routinely performed.<sup>52</sup>

VIPomas, glucagonomas, and somatostatinomas are usually larger and easier to localize. Localization of these tumors is usually performed by CT scanning or SRS if CT is not informative. Most nonfunctional neuroendocrine tumors are diagnosed initially on CT based on symptoms of abdominal pain or jaundice. They are differentiated from pancreatic adenocarcinoma by their hyperdense, enhancing nature on arterial phase imaging (Fig. 60-15). Standard CT or MRI has nearly 100% sensitivity for locating nonfunctional pancreatic endocrine tumors because of their size.

## MANAGEMENT

### Insulinoma

Surgical resection is the mainstay of treatment and only curative option for pancreatic endocrine tumors. After localization, surgical resection of insulinoma is usually curative as most tumors tend to be small, benign, and solitary. Preoperatively, it is important to prevent severe hypoglycemic attacks by administration of diazoxide that decreases

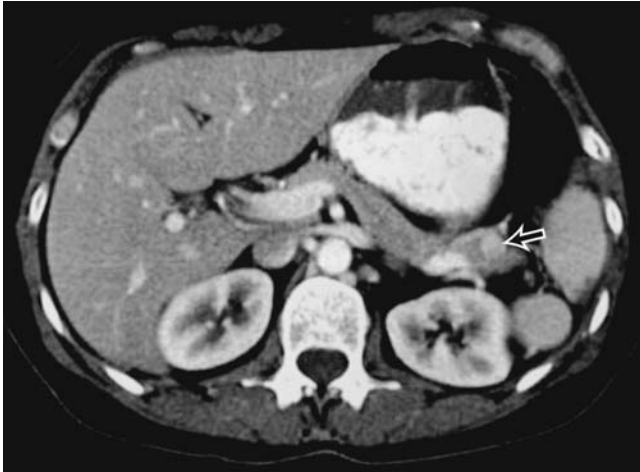


**FIGURE 60-16** An intraoperative photograph showing a solitary insulinoma in the tail of the pancreas. The tumor appears as solitary, encapsulated, reddish-brown mass. (Used, with permission, from Sharon Weber, MD, University of Wisconsin, Madison, WI.)

beta-cell release of insulin (usually 3 mg/kg/d divided in two or three doses daily). Rarely, other agents such as verapamil, glucocorticoids, and growth hormone may be required to maintain normoglycemia. Glucose infusions must be used in the perioperative period especially when patients are taking nothing by mouth.

Surgical technique includes careful inspection of the liver and regional lymph nodes for evidence of metastatic disease. The pancreas is exposed through the lesser sac by traversing the gastrocolic omentum. A generous Kocher maneuver and mobilization of the pancreatic tail are usually required to adequately inspect the entire pancreas. After complete mobilization, the pancreas should be visually inspected, palpated, and intraoperative ultrasound should be applied. These tumors usually appear as solitary, encapsulated, reddish-brown tumors (Fig. 60-16) and, once identified, should correlate with preoperative localization studies (Fig. 60-17). Because over 90% of insulinomas are benign, enucleation is usually preferred when possible to preserve functional pancreatic mass.<sup>53</sup> The mass shown in Fig. 60-16 is superficial and easily seen and was successfully enucleated. Enucleation should not be performed if the tumor is within 2 mm of the main pancreatic duct. In all enucleations, careful dissection is necessary to avoid entry into the main pancreatic duct. Resection via distal pancreatectomy, central pancreatectomy, or pancreaticoduodenectomy may be necessary for tumors abutting the main pancreatic duct, or large tumors. Many surgeons advocate placement of a silastic drain adjacent to the enucleation site to control any leak of pancreatic secretions postoperatively.

Laparoscopic resection of pancreatic endocrine tumors is becoming more common, especially for insulinomas where simple enucleation is adequate treatment.<sup>54,55</sup> Distal pancreatectomy may also be performed laparoscopically, allowing



**FIGURE 60-17** Once identified, this mass was correlated with preoperative CT findings. The CT demonstrates a hyperattenuated mass in the tail of the pancreas corresponding to the lesion identified intraoperatively (*arrow*). This mass was successfully enucleated. (Used, with permission, from Sharon Weber, MD, University of Wisconsin, Madison, WI.)

for adequate resection of even small malignant tumors in the pancreatic body or tail.<sup>56</sup> Expanding the patient population in which laparoscopic resection is possible will depend on improvements in preoperative localization. More extensive pancreatic resections for malignant tumors are best resected through an open approach.

In the rare instance that the tumor cannot be localized with pre- or intraoperative techniques, blind resection of any part of the pancreas is not recommended. When no tumor can be identified, biopsies should be taken from the pancreatic tail to evaluate for nesidioblastosis.

Normal life expectancy is achieved by complete excision of a benign insulinoma. More extensive resections are required for complete excision of malignant insulinomas, which are typically much larger (~6 cm), and in patients with MEN1 or multifocal disease. These patients may require a combination of partial pancreatic resection (distal pancreatectomy or pancreaticoduodenectomy) and enucleation for multiple lesions in the pancreas.<sup>20,26</sup> In general, total pancreatectomy is not indicated for insulinoma. While complete resection of insulinomas is usually associated with resolution of hypoglycemia, tumor debulking results in a 95% biochemical cure rate because some residual disease may not be functional.<sup>57</sup>

For patients with metastatic insulinoma, resection of gross disease, along with octreotide for symptom control and systemic chemotherapy, is the appropriate treatment. For patients with unresectable disease, a new somatostatin analogue (lanreotide) that has recently developed remains biologically active for up to 2 weeks following a single injection and controls symptoms as well as octreotide that must be given three times daily.<sup>58</sup> Even with metastatic disease, the median survival following resection is approximately 5 years.

Streptozotocin (with or without 5-fluorouracil) is associated with improved survival in metastatic pancreatic endocrine tumors.

## Gastrinoma

Operative treatment of gastrinomas is indicated when curative resection appears possible based on preoperative imaging or for palliative cytoreduction for symptom control. The goals of surgery are twofold: potentially curative resection of the primary tumor and prevention of malignant progression. The presence or absence of malignant disease is the prime determinant of survival.

As with insulinomas, the entire pancreas should be mobilized to allow for thorough palpation and intraoperative ultrasound. The surgical approach begins with careful inspection of the gastrinoma triangle (see Fig. 60-5) to confirm the location of the tumor. After extensive Kocherization, intraoperative ultrasound should be routinely applied to identify small pancreatic lesions or liver metastases. After transillumination of the duodenum with intraoperative endoscopy, the duodenal wall can be gently palpated between the surgeon's fingers through a 3-cm duodenotomy on the anterior/lateral surface of the second portion of the duodenum allowing the detection of gastrinomas less than 1 cm in size.<sup>52</sup>

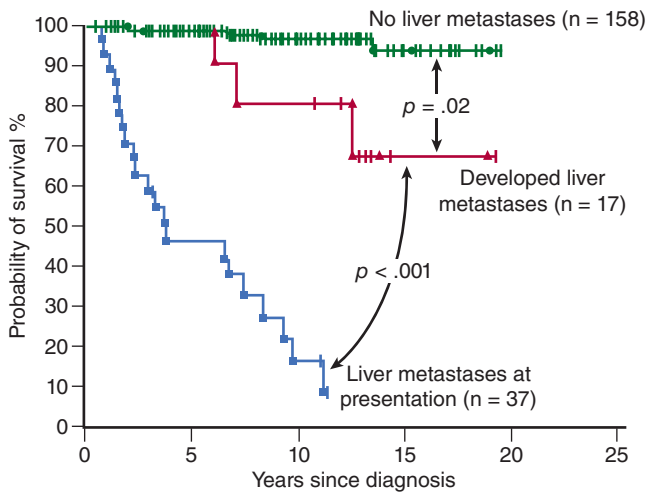
Small, well-encapsulated tumors in the pancreas can be removed by enucleation. Large, unencapsulated lesions deep within the gland may require segmental resection, including distal pancreatectomy or pancreaticoduodenectomy. Pancreaticoduodenectomy may increase disease-free survival in patients with MEN1 because, following local excision, recurrent tumors are most commonly found within the duodenum.<sup>16,27,58</sup> In 5–8% of cases, the surgeon is unable to localize a gastrinoma intraoperatively.<sup>59</sup> In this case, blind pancreatic resection is not indicated. Detailed inspection of peripancreatic, periduodenal, and portohepatic lymph nodes should be performed as resection of grossly positive lymphatic spread may increase disease-free survival.

Unfortunately, more than half of patients with gastrinomas have metastatic disease at the time of diagnosis. For these patients, treatment should focus on symptom control (ie, reduction in acid production). The development of PPIs has reduced the need for surgical intervention for control of acid-related symptoms in patients with ZES. PPIs are so effective at reducing acid secretion that surgical procedures, which had previously been superior to medications, are now rarely performed. Symptoms are controlled in more than 90% of patients starting with doses of 40–80 mg daily, although higher doses may be required. Efficacy can be demonstrated by measuring basal acid output (BAO); PPI dosage should be titrated to keep BAO less than 10 mEq/h (or <5 mEq/h if the patient had a prior acid-reducing procedure). Octreotide can be used to decrease gastrin release and control acid secretion but is rarely effective without concurrent PPI use.

Historically the treatment for ZES, one of the few remaining indications for total gastrectomy in patients with ZES, is

the presence of gastric carcinoid tumors that may arise from prolonged hypergastrinemia. Gastric carcinoids probably occur in fewer than 10% of patients with MEN1 and ZES; thus gastrectomy is rarely required. Gastrectomy may also be indicated for patients who are unable to tolerate PPIs and cannot achieve acid secretion control through other means. Total gastrectomy cures all symptoms produced by excessive acid but has no effect on survival for metastatic disease.

The best predictor of survival for patients with gastrinoma is the presence of liver metastases, while lymph node metastases are not predictive. Patients with bulky metastatic disease have a 5-year survival less than 50%, while 90% of patients without metastases are alive after 5 years. Resection of all gross disease and metastases may provide palliation of symptoms and may prolong survival. Norton and colleagues showed that 58% of patients with gastrinomas had normalized gastrin levels following resection; the 5-year survival was nearly 100% for patient without liver metastases. Patients who had no synchronous liver lesions but developed them metachronously had a 5-year survival of nearly 100% and a 10-year survival rate of 80%. Patients presenting with synchronous liver metastases had a 5-year survival rate of approximately 45% (Fig. 60-18). Aggressive surgical therapy is indicated, as patients have been known to live more than 20 years with residual disease. Chemoembolization or radiofrequency ablation of hepatic metastases may be effective in reducing tumor burden within the liver. Cytotoxic chemotherapy has been used in patients with metastatic disease but does not provide a demonstrated survival benefit.



**FIGURE 60-18** Effect of the presence of liver metastases at the initial evaluation or the development of liver metastases on survival in patients with gastrinomas. Disease-specific survival rates are shown. Of the 158 patients with no liver metastases, 6 died during follow-up, whereas 4/17 patients who developed liver metastases died and 23/37 patients who initially had liver metastases at first evaluation died during the follow-up period since diagnosis. (Modified from Yu F, Venzon DJ, Serrano J, et al. Prospective study of the clinical course, prognostic factors and survival in patients with long-standing Zollinger-Ellison syndrome. *J Clin Oncol.* 1999;17:615–30, with permission.)

## VIPomas, Glucagonomas, Somatostatinomas, and Nonfunctional Endocrine Tumors

Surgical treatment of VIPomas and glucagonomas requires special preoperative preparation. Treatment of VIPomas begins with aggressive preoperative hydration and correction of electrolyte abnormalities and acid-base disturbances. Octreotide is commonly used preoperatively to reduce diarrhea volume and facilitate fluid and electrolyte replacement. If diarrhea persists despite octreotide therapy, addition of a glucocorticoid may be helpful.

For patients with glucagonomas, treatment begins with medical therapy to improve the nutritional condition of these patients who have typically lost a significant amount of weight and lean body mass. Supplemental enteral nutrition in excess of basic caloric needs is often required in conjunction with high doses of octreotide (up to 1000  $\mu\text{g}/\text{d}$ ) to reverse the catabolic state. Prophylaxis against thromboembolism should be instituted early in the hospitalization to prevent perioperative deep vein thrombosis and pulmonary embolism that are the leading causes of death in these patients. Intravenous infusions of amino acids may be required to reverse symptoms and improve dermatitis.

Resection of the VIPoma, glucagonoma, somatostatinoma, nonfunctioning pancreatic endocrine tumors is the treatment of choice as complete excision offers the only chance of cure. Because these tumors tend to be invasive, simple enucleation is often inadequate and partial pancreatic resection is usually recommended. Unfortunately, the frequent presence of synchronous metastases may make complete excision impossible. Palliative resection of recurrences and metastatic foci may be helpful in controlling symptoms; however, improvement in overall survival is unlikely. In a review of the literature, 86% of VIPomas were resected and 23% of patients died of disease from 12 to 52 months after diagnosis/surgery.<sup>29</sup> Other forms of therapy for metastatic disease have been used anecdotally, including hepatic artery embolization, radiofrequency ablation, liver transplantation, radioactive octreotide, chemotherapy, and cryotherapy. Adjuvant chemotherapy has not been shown to be beneficial.

Following resection, 5-year survival for patients with glucagonoma is nearly 85% if no metastases are present. Five-year survival is approximately 60% in patients with metastatic disease.<sup>34</sup> Dacarbazine is uniquely effective against glucagonoma as compared to other pancreatic endocrine tumors, and complete remission has been reported in several cases.<sup>60</sup>

For patients with somatostatinomas and nonfunctional islet cell tumors, surgical resection remains the mainstay of treatment. There is little necessity in the way of specific preoperative preparation. The high frequency of malignancy mandates pancreaticoduodenectomy or distal pancreatectomy (not enucleation) if the intent of the pancreatic resection is curative. Even in patients with liver metastases, pancreatic resection may eliminate symptoms related to the size of the mass and improve survival. Overall 5-year



survival for nonfunctional pancreatic endocrine tumors is approximately 50%.<sup>42</sup>

## CONCLUSIONS

The management of pancreatic endocrine tumors requires a thorough understanding of the biological behavior of these tumors and the essential role of surgical intervention in providing both potential cure and symptom relief. Challenges remain in the localization of these tumors although modern imaging technology identifies the tumor in most cases preoperatively. Patients with MEN1-associated neuroendocrine tumors often have more aggressive and multifocal tumors, thus mandating a different surgical approach and preoperative evaluation. Tumor resection provides an excellent chance for cure, especially for insulinomas. Debulking of even widespread metastatic disease can lead to control of debilitating hormonal symptoms and allow for favorable long-term survival. Surgeons are uniquely qualified to care for patients with pancreatic endocrine tumors because resection of tumor burden, including recurrences, remains the most effective method to control the debilitating symptoms caused by hormone overproduction.

## REFERENCES

- Jemal A, Siegel R, Ward E, et al. Cancer statistics, 2009. *CA Cancer J Clin*. 2009;59(4):225–249.
- Kleinman R, Gingerich R, Wong H, et al. Use of the Fab fragment for immunoneutralization of somatostatin in the isolated perfused human pancreas. *Am J Surg*. 1994;167(1):114–119.
- Pour PM, Schmied B. The link between exocrine pancreatic cancer and the endocrine pancreas. *Int J Pancreatol*. 1999;25(2):77–87.
- Kloppel G, Heitz PU. Pancreatic endocrine tumors. *Pathol Res Pract*. 1988;183(2):155–168.
- Whipple AO, Frantz VK. Adenoma of islet cells with hyperinsulinism: a review. *Ann Surg*. 1935;101(6):1299–1335.
- Becker S, Kahn D, Rothman S. Cutaneous manifestations of internal malignant tumors. *Arch Dermatol Syphilis*. 1942;45:1069.
- McGarvan M, Unger R, Recant L, et al. A glucagon-secreting alpha-cell carcinoma of the pancreas. *N Engl J Med*. 1966;196(274):1408–1413.
- Zollinger RM, Ellison EH. Primary peptic ulcerations of the jejunum associated with islet cell tumors of the pancreas. *Ann Surg*. 1955;142(4):709–723; discussion, 724–728.
- Priest WM, Alexander MK. Isletcell tumour of the pancreas with peptic ulceration, diarrhoea, and hypokalaemia. *Lancet*. 1957;273(7006):1145–1147.
- Verner JV, Morrison AB. Islet cell tumor and a syndrome of refractory watery diarrhea and hypokalemia. *Am J Med*. 1958;25(3):374–380.
- Bloom SR, Polak JM, Pearse AG. Vasoactive intestinal peptide and watery-diarrhoea syndrome. *Lancet*. 1973;2(7819):14–16.
- Yalow RS, Berson SA. Some applications of isotope dilution techniques. *Am J Roentgenol Radium Ther Nucl Med*. 1956;75(6):1059–1067.
- Muscarella P, Melvin WS, Fisher WE, et al. Genetic alterations in gastrinomas and nonfunctioning pancreatic neuroendocrine tumors: an analysis of p16/MTS1 tumor suppressor gene inactivation. *Cancer Res*. 1998;58(2):237–240.
- Rigaud G, Missiaglia E, Moore PS, et al. High resolution allelotype of nonfunctional pancreatic endocrine tumors: identification of two molecular subgroups with clinical implications. *Cancer Res*. 2001;61(1):285–292.
- Chung DC, Smith AP, Louis DN, et al. A novel pancreatic endocrine tumor suppressor gene locus on chromosome 3p with clinical prognostic implications. *J Clin Invest*. 1997;100(2):404–410.
- Gibril F, Schumann M, Pace A, Jensen RT. Multiple endocrine neoplasia type 1 and Zollinger-Ellison syndrome: a prospective study of 107 cases and comparison with 1009 cases from the literature. *Medicine (Baltimore)*. 2004;83(1):43–83.
- Norton JA, Cornelius MJ, Doppman JL, et al. Effect of parathyroidectomy in patients with hyperparathyroidism, Zollinger-Ellison syndrome, and multiple endocrine neoplasia type I: a prospective study. *Surgery*. 1987;102(6):958–966.
- Thompson JC, Hirose FM, Lemmi CA, Davidson WD. Zollinger-Ellison syndrome in a patient with multiple carcinoid-islet cell tumors of the duodenum. *Am J Surg*. 1968;115(2):177–184.
- Doherty GM. Multiple endocrine neoplasia type 1: duodenopancreatic tumors. *Surg Oncol*. 2003;12(2):135–143.
- Tonelli F, Fratini G, Falchetti A, et al. Surgery for gastroenteropancreatic tumours in multiple endocrine neoplasia type 1: review and personal experience. *J Intern Med*. 2005;257(1):38–49.
- Sheth S, Hruban RK, Fishman EK. Helical CT of islet cell tumors of the pancreas: typical and atypical manifestations. *AJR Am J Roentgenol*. 2002;179(3):725–730.
- Grunberger G, Weiner JL, Silverman R, et al. Factitious hypoglycemia due to surreptitious administration of insulin. Diagnosis, treatment, and long-term follow-up. *Ann Intern Med*. 1988;108(2):252–257.
- Wiesli P, Brandle M, Pfammatter T, et al. Insulin determination by specific and unspecific immunoassays in patients with insulinoma evaluated by the arterial stimulation and venous sampling test. *Eur J Endocrinol*. 2004;151(1):123–126.
- Kaczirek K, Niederle B. Nesidioblastosis: an old term and a new understanding. *World J Surg*. 2004;28(12):1227–1230.
- Christesen HB, Brusgaard K, Beck Nielsen H, Brock Jacobsen B. Non-insulinoma persistent hyperinsulinaemic hypoglycaemia caused by an activating glucokinase mutation: hypoglycaemia unawareness and attacks. *Clin Endocrinol (Oxf)*. 2008;68(5):747–755.
- Demeure MJ, Klonoff DC, Karam JH, et al. Insulinomas associated with multiple endocrine neoplasia type I: the need for a different surgical approach. *Surgery*. 1991;110(6):998–1004; discussion 1004–1005.
- Norton JA, Jensen RT. Current surgical management of Zollinger-Ellison syndrome (ZES) in patients without multiple endocrine neoplasia-type 1 (MEN1). *Surg Oncol*. 2003;12(2):145–151.
- Thompson JC, Reeder DD, Villar HV, Fender HR. Natural history and experience with diagnosis and treatment of the Zollinger-Ellison syndrome. *Surg Gynecol Obstet*. 1975;140(5):721–739.
- Ghaferi AA, Chojnacki KA, Long WD, et al. Pancreatic VIPomas: subject review and one institutional experience. *J Gastrointest Surg*. 2008;12(2):382–393.
- Friesen SR. Update on the diagnosis and treatment of rare neuroendocrine tumors. *Surg Clin North Am*. 1987;67(2):379–393.
- Mekjian HS, O'Dorisio TM. VIPoma syndrome. *Semin Oncol*. 1987;14(3):282–291.
- Perry RR, Vinik AI. Clinical review 72: diagnosis and management of functioning islet cell tumors. *J Clin Endocrinol Metab*. 1995;80(8):2273–2278.
- Boden G. Glucagonomas and insulinomas. *Gastroenterol Clin North Am*. 1989;18(4):831–845.
- Stacpoole PW. The glucagonoma syndrome: clinical features, diagnosis, and treatment. *Endocr Rev*. 1981;2(3):347–361.
- Wermers RA, Fatourehchi V, Wynne AG, et al. The glucagonoma syndrome. Clinical and pathologic features in 21 patients. *Medicine (Baltimore)*. 1996;75(2):53–63.
- Kahan RS, Perez-Figaredo RA, Neimanis A. Necrolytic migratory erythema. Distinctive dermatosis of the glucagonoma syndrome. *Arch Dermatol*. 1977;113(6):792–797.
- Harris GJ, Tio F, Cruz AB, Jr. Somatostatinoma: a case report and review of the literature. *J Surg Oncol*. 1987;36(1):8–16.
- Takai A, Setoyama T, Miyamoto S. Pancreatic somatostatinoma with von Recklinghausen's disease. *Clin Gastroenterol Hepatol*. 2009;7(5):A28.
- Krejs GJ, Orci L, Conlon JM, et al. Somatostatinoma syndrome. Biochemical, morphologic and clinical features. *N Engl J Med*. 1979;301(6):285–292.
- Norton JA. Somatostatinoma and rare pancreatic endocrine tumours. In: Clarke OH, Duh QY eds. *Textbook of Endocrine Surgery*. Philadelphia, PA: WB Saunders; 1997.
- Bordi C, Azzoni C, D'Adda T, Pizzi S. Pancreatic polypeptide-related tumors. *Peptides*. 2002;23(2):339–348.

42. Phan GQ, Yeo CJ, Hruban RH, et al. Surgical experience with pancreatic and peripancreatic neuroendocrine tumors: review of 125 patients. *J Gastrointest Surg.* 1998;2(5):473–482.
43. Van Hoe L, Gryspeerdt S, Marchal G, et al. Helical CT for the preoperative localization of islet cell tumors of the pancreas: value of arterial and parenchymal phase images. *AJR Am J Roentgenol.* 1995;165(6):1437–1439.
44. Boukhman MP, Karam JM, Shaver J, et al. Localization of insulinomas. *Arch Surg.* 1999;134(8):818–822; discussion 822–823.
45. Thoeni RF, Mueller-Lisse UG, Chan R, et al. Detection of small, functional islet cell tumors in the pancreas: selection of MR imaging sequences for optimal sensitivity. *Radiology.* 2000;214(2):483–490.
46. Krenning EP, Kwekkeboom DJ, Oei HY, et al. Somatostatin-receptor scintigraphy in gastroenteropancreatic tumors. An overview of European results. *Ann NY Acad Sci.* 1994;733:416–424.
47. Muller MF, Meyenberger C, Bertschinger P, et al. Pancreatic tumors: evaluation with endoscopic US, CT, and MR imaging. *Radiology.* 1994;190(3):745–751.
48. Proye C, Malvaux P, Pattou F, et al. Noninvasive imaging of insulinomas and gastrinomas with endoscopic ultrasonography and somatostatin receptor scintigraphy. *Surgery.* 1998;124(6):1134–1143; discussion 1143–1144.
49. Varas Lorenzo MJ, Miquel Collell JM, Maluenda Colomer MD, et al. Preoperative detection of gastrointestinal neuroendocrine tumors using endoscopic ultrasonography. *Rev Esp Enferm Dig.* 2006;98(11):828–836.
50. Jackson JE. Angiography and arterial stimulation venous sampling in the localization of pancreatic neuroendocrine tumours. *Best Pract Res Clin Endocrinol Metab.* 2005;19(2):229–239.
51. Frucht H, Howard JM, Slaff JI, et al. Secretin and calcium provocative tests in the Zollinger-Ellison syndrome. A prospective study. *Ann Intern Med.* 1989;111(9):713–722.
52. Sugg SL, Norton JA, Fraker DL, et al. A prospective study of intraoperative methods to diagnose and resect duodenal gastrinomas. *Ann Surg.* 1993;218(2):138–144.
53. Service FJ, McMahon MM, O'Brien PC, Ballard DJ. Functioning insulinoma—incidence, recurrence, and long-term survival of patients: a 60-year study. *Mayo Clin Proc.* 1991;66(7):711–719.
54. Assalia A, Gagner M. Laparoscopic pancreatic surgery for islet cell tumors of the pancreas. *World J Surg.* 2004;28(12):1239–1247.
55. Lo CY, Chan WF, Lo CM, et al. Surgical treatment of pancreatic insulinomas in the era of laparoscopy. *Surg Endosc.* 2004;18(2):297–302.
56. Kooby DA, Gillespie T, Bentrem D, et al. Left-sided pancreatectomy: a multicenter comparison of laparoscopic and open approaches. *Ann Surg.* 2008;248(3):438–446.
57. Doherty GM, Doppman JL, Shawker TH, et al. Results of a prospective strategy to diagnose, localize, and resect insulinomas. *Surgery.* 1991;110(6):989–996; discussion 996–997.
58. Simonenko VB, Dulin PA, Makanin MA. [Somatostatin analogues in treatment of gastrointestinal and pancreatic neuroendocrine tumors]. *Klin Med (Mosk).* 2006;84(4):4–8.
59. Norton JA, Doppman JL, Jensen RT. Curative resection in Zollinger-Ellison syndrome. Results of a 10-year prospective study. *Ann Surg.* 1992;215(1):8–18.
60. Marynick SP, Fagadau WR, Duncan LA. Malignant glucagonoma syndrome: response to chemotherapy. *Ann Intern Med.* 1980;93(3):453–454.

# PERSPECTIVE ON PANCREATIC NEOPLASMS

*Douglas B. Evans*

Dr Wolfgang, Dr Schulick, and Dr Cameron provide an extremely comprehensive chapter on the evaluation and treatment of patients with cancer of the periampullary region and specifically the pancreatic head. The multidisciplinary working group from Johns Hopkins Hospital has made numerous contributions to the field of pancreatic cancer biology as well as the clinical management of patients with this disease. As all of you know, over the past two to three decades, Dr Cameron has demonstrated how to surgically manage patients with pancreatic cancer to achieve optimal outcome. Importantly, there has been a tremendous advance in both the understanding of the molecular biology of pancreatic cancer as well as our ability to accurately image the pancreas and periampullary region prior to surgery. Advances in both computed tomography (CT) and magnetic resonance imaging (MRI) have allowed for accurate assessment of critically important tumor-vessel relationships. Such accurate assessment of the relevant anatomy is important for both pretreatment staging and for planning the technical steps in performing pancreaticoduodenectomy, especially if vascular resection and reconstruction may be indicated. Although very experienced surgeons such as the authors can accurately assess resectability at the time of laparotomy, the ability to preoperatively classify patients as resectable, borderline resectable or locally advanced allows for the appropriate triage of patients for optimal treatment sequencing (surgery first or after neoadjuvant therapy), the evaluation of patients for investigator-initiated and cooperative group clinical trials, and for the referral of patients to higher volume centers. Indeed, to the extent that outcome is improved for patients with localized disease at high-volume centers (by high-volume surgeons), patients will need to be accurately staged (CT imaging) and, when necessary, have biliary stents placed safely in order to facilitate referral to a specialty center. The ability to perform endoscopic ultrasound (EUS)-guided fine-needle aspiration (FNA) biopsy will prevent diagnostic uncertainty and allow for medical oncology consultation and multidisciplinary care.

Fortunately, the last decade has witnessed the development of consensus for the CT staging of pancreatic cancer. In an attempt to clarify the anatomy of resectable, borderline

resectable, and locally advanced disease, Varadhachary and colleagues from the University of Texas M.D. Anderson Cancer Center proposed an objectively defined, CT-based classification that distinguished borderline resectable from both resectable and locally advanced pancreatic cancer.<sup>1</sup> The Varadhachary definitions considered venous abutment and encasement (without occlusion) to be resectable, in the absence of tumor extension to the celiac or superior mesenteric (SMA) arteries. However, this definition was developed for the conduct of clinical trials of neoadjuvant treatment sequencing and was not intended to support a surgery-first strategy for patients who may require vascular resection and reconstruction. The Varadhachary definitions also assumed the technical capability to resect and reconstruct the superior mesenteric-portal vein (SMPV) confluence when necessary and that the major determinant of margin status (R status) was the tumor-artery (celiac, hepatic, SMA) relationship (Table 61A-1). Katz and colleagues in 2008 reported 160 patients with borderline resectable disease (using the Varadhachary definition) and introduced three subtypes of the borderline category, often referred to as Katz types A, B, and C.<sup>2</sup> Type A patients were those with borderline resectable tumor anatomy as defined in the Varadhachary manuscript. Type B patients were borderline resectable because of a concern for possible extrapancreatic metastatic disease and included those with CT findings suspicious for, but not diagnostic of, metastatic disease. One could also add to this group those patients with very high cancer antigen 19-19 (CA19-9) levels (important that the CA19-9 be measured when the serum bilirubin is normal). Type C patients were borderline resectable due to a marginal performance status or significant preexisting medical comorbidity thought to require protracted evaluation that precluded immediate surgery. By definition, type C patients were thought to have reversible causes of their current symptoms such as hyperbilirubinemia-induced anorexia and fatigue. Katz and colleagues provided compelling data in support of induction chemotherapy (followed by chemoradiation) for patients with borderline resectable disease. Of equal importance, they defined borderline resectable disease in all three forms that we see clinically: anatomic (local tumor




**TABLE 61A-1: THE VARADHACHARY/KATZ CT STAGING SYSTEM FOR ADENOCARCINOMA OF THE PANCREATIC HEAD AND UNCINATE PROCESS**

Clinical Stage of Disease	AJCC Stage	Tumor-Vessel Relationship on CT			
		SMA	Celiac Axis	CHA	SMV-PV
Resectable <sup>a</sup> (all 4 required to be resectable)	I/II	Normal tissue plane between tumor and vessel	Normal tissue plane between tumor and vessel	Normal tissue plane between tumor and vessel	Patent (may include tumor abutment or encasement)
Borderline resectable (only 1 of the 4 required)	III	abutment	abutment	Abutment or short-segment encasement	May have short-segment occlusion if reconstruction possible
Locally advanced (only 1 of the 4 required)	III	encasement	encasement	Extensive encasement with no technical option for reconstruction	Occluded with no technical option for reconstruction

AJCC, American Joint Committee on Cancer; CHA, common hepatic artery; CT, computed tomography; SMV-PV, superior mesenteric vein-portal vein confluence. Definitions: abutment,  $\leq 180^\circ$  or  $\leq 50\%$  of the vessel circumference; encasement,  $>180^\circ$  or  $>50\%$  of the vessel circumference.

<sup>a</sup> Assumes the technical ability to resect and reconstruct the SMV, PV, or SMV-PV confluence when necessary.

anatomy), oncologic/biologic (possible advanced disease not fully apparent on imaging), and physiologic (marginal performance status).

For those surgeons who recommend a surgery-first strategy to patients with localized, potentially resectable pancreatic cancer, the CT definition of what should be considered “resectable” for which immediate surgery may be considered is often more limited than the M.D. Anderson definitions above. The AHPBA-SSO-SSAT consensus panel definition of resectable (as distinct from borderline resectable) included only those tumors with no evidence (on CT) of even abutment or distortion of any aspect of the SMPV confluence as well as no extension to the adjacent mesenteric arteries.<sup>3</sup> At present, there appears to be growing consensus for a fairly narrow definition of “resectable” when a surgery-first strategy is planned. In the absence of neoadjuvant therapy, resectable disease is defined as the absence of tumor extension to the adjacent visceral arteries (SMA, celiac, hepatic) and the absence of tumor-induced unilateral shift, distortion, or narrowing of any aspect of the SMPV confluence; such patients may be taken directly to surgery if a suitable clinical trial is not available.<sup>3</sup> In contrast, patients with borderline resectable pancreatic cancer, as defined by the AHPBA-SSO-SSAT consensus panel, should be treated with induction therapy before surgery.

What is not clear at present is how best to treat patients with borderline resectable pancreatic cancer before consideration of surgery. Many incorporate a period of induction systemic therapy, especially in those with arterial abutment, to include at least 2 months of chemotherapy before chemoradiation.<sup>2</sup> Emerging clinical trials, as well as off-protocol therapy, will likely include what may prove successful in metastatic disease. For example, gemcitabine plus

nab-paclitaxel (Abraxane) or FOLFIRINOX (5-fluorouracil [5-FU], leucovorin, irinotecan, and oxaliplatin).<sup>4,5</sup> The length of induction systemic therapy, the timing and dose of radiation therapy, and the optimal postoperative systemic therapy remain undefined. The published experience to date with neoadjuvant treatment sequencing for resectable and borderline resectable pancreatic cancer has largely used chemoradiation as a component of the treatment program. Experience using chemotherapy alone is relatively untested, the obvious concern being the risk for local tumor recurrence. The first national trial of neoadjuvant therapy for resectable pancreatic cancer (the American College of Surgeons Clinical Oncology Group Z5041 [ACOSOG Z5041]) does not incorporate radiation therapy; the local recurrence rate will be an important endpoint with major therapeutic implications.

Probably the most important technical aspect of pancreaticoduodenectomy is the dissection of superior mesenteric artery.<sup>6</sup> In general, exposure of the SMA is facilitated by complete mobilization of the SMPV confluence to the patient's left. This allows for careful separation of the uncinus process from the jejunal branch of the SMV and, ultimately, exposure of the SMA. Our current understanding of the pathophysiology of local recurrence following pancreaticoduodenectomy (with or without multimodality therapy) is microscopic infiltration of the autonomic neural sheath that surrounds the SMA. Adenocarcinoma of the pancreas has a predisposition to spread along neural tissue, and this is likely responsible for the high frequency of local recurrence. As our systemic therapies become more effective, local recurrence may become a more dominant pattern of failure. It is impossible to argue with the technique described by Dr Wolfgang as the operation of pancreaticoduodenectomy is arguably done better at Johns Hopkins Hospital than any other institution in the

world. Students, residents, and even experienced surgeons will benefit greatly by careful review of this chapter.

Chapter 58 by Dr Maley and Dr Yeo is equally comprehensive in their superb discussion of cystic neoplasms of the pancreas. They focus predominantly on serous cystadenoma, mucinous cystic neoplasm (MCN), and intraductal papillary mucinous neoplasm (IPMN). Regarding serous cystadenoma, this histology demonstrates fascinating tumor biology. As mentioned by the authors, it is generally felt that serous cystadenomas do not have the biologic ability to metastasize to distant organs or regional lymph nodes. However, they can be locally invasive and erode into adjacent bowel (duodenum, transverse colon, stomach) and occasionally can obstruct the splenic vein (resulting in sinistral portal hypertension) or the superior mesenteric and/or portal veins (resulting in extrahepatic portal hypertension). Importantly, the diagnosis of (microcystic) serous cystadenoma can usually be made on high-quality CT imaging with or without the additional benefit of EUS because of its characteristic imaging appearance (unless the serous cystadenoma is macrocystic). When referring a patient for EUS to confirm a diagnosis of serous cystadenoma, we would recommend an FNA biopsy if the EUS is not consistent with this diagnosis or there appears to be discrepancy between CT or MRI imaging and the EUS appearance. As noted by the authors, serous cystadenomas are characterized by a cyst fluid CEA level that is usually undetectable or very low (<5 ng/mL). In 2011, the diagnosis of a serous cystadenoma is usually not difficult; however, knowing when to intervene with surgery is often challenging. As patient age and operative risk (medical comorbidities) increase, the benefit to surgery in an otherwise asymptomatic patient may be low. For example, it is relatively easy to understand a recommendation for surgery in an otherwise completely healthy 60-year-old patient with a 5- to 6-cm serous cystadenoma.<sup>7</sup> However, the same pancreatic tumor in a 75-year-old patient with one or two coronary stents and a relatively sedentary lifestyle may not be the correct approach. In our practice, we try to carefully weigh risk versus benefit in asymptomatic patients.<sup>8</sup> In addition, for serous cystadenomas that are less than 4–5 cm in size, we usually require that they demonstrate growth, over a period of observation, before proceeding with surgery. Our underlying philosophy is to avoid surgery-related mortality and major morbidity, especially in patients who are asymptomatic with a tumor histology such as serous cystadenoma that poses no risk for distant metastases.

The discussion on MCN is particularly well done and as emphasized by Dr Maley and Dr Yeo, ovarian stroma is now required to secure a diagnosis of MCN. While the relationship between size of the MCN and malignant potential is not perhaps as well worked out as with IPMN, it is reasonable to utilize the same 3-cm rule. For example, in the absence of a solid component or mural nodule, mucinous neoplasms less than 3 cm in diameter, that are radiographically consistent with MCN, can usually be safely observed. A recommendation for observation is all the more compelling in patients of advanced stage and with medical comorbidities. Obviously, it is sometimes difficult to differentiate an MCN from a unifocal branch duct IPMN in a woman. Importantly, as mentioned

by the authors, MCNs occur in the pancreatic body and tail and are exceedingly rare in the pancreatic head or uncinata process. In our practice we would consider an MCN in the pancreatic head or uncinata process to represent an IPMN. What remains controversial is the surgical approach to MCNs of presumed low malignant potential. For example, consider an otherwise healthy 50-year-old woman with a 3-cm presumed MCN in the pancreatic body who has undergone EUS-guided FNA biopsy and the mucinous nature of the cyst fluid has been confirmed. In this patient with no evidence of a solid component or mural nodule on CT or EUS, surgery is recommended because of the patient's young age as well as the size of the MCN. Because this is a premalignant neoplasm, it would be very difficult to support a recommendation of observation in a patient of this age. If her serum level of CA19-9 was also normal, this finding adds further support to there being no invasive component to the tumor at this time. The compelling question then is whether she should undergo middle segment pancreatectomy, distal pancreatectomy (with or without splenic preservation), or enucleation. In patients without cancer, we do need to pay more attention to preservation of islet cell mass in an effort to avoid the intermediate and long-term complications of insulin-dependent diabetes (in addition to the lifestyle changes introduced with insulin dependence). Our choice for operation in this patient would be a middle segment pancreatectomy with pancreaticojejunostomy for the distal pancreas and creation of a serosal patch sewn to the proximal pancreatic transection site. This would hopefully minimize the risk for anastomotic leak, preserve islet cell mass, and ensure that the lesion is completely excised with negative margins. We have not yet adopted enucleation as a routine part of our practice when dealing with mucinous (pre-malignant) neoplasms.

When dealing with a patient who has presumed IPMN, especially those with branch duct disease, the Sendai guidelines have now been widely incorporated into clinical practice.<sup>9</sup> As noted by the authors, use of these guidelines will result in a slightly higher-risk (for invasive adenocarcinoma) population being considered for surgery. By definition, the low-risk patients would be treated with at least a period of observation until the size of the cyst or the CT characteristics (suggestion of a solid component) prompt surgical intervention. Such a strategy is designed to avoid surgery, and its associated risk for mortality and morbidity, in patients with small cystic neoplasms who have no chance of harboring an invasive cancer. In our practice, enucleation would rarely be considered as we do not operate on the cystic neoplasms that would be considered most appropriate for enucleation (those of very low risk). However, the increasing use of cross-sectional imaging has resulted in many more patients being diagnosed with cystic neoplasms of the pancreas. Would it be reasonable to consider a lesser procedure (enucleation or endoscopic alcohol ablation) in smaller branch duct IPMNs that may be diagnosed in younger patients? Is there a role for enucleation or ablative therapies in patients where the risk for invasive carcinoma is approaching zero? This is now a subject of debate

at national meetings, and I suspect represents a fruitful area for cooperative group clinical trials.

Fortunately, when dealing with a patient who has IPMN and requires surgery, the need for total pancreatectomy is uncommon. If the right or left side of the pancreas requires resection, we commonly send the pancreatic transection margin for frozen-section analysis. Work from our group and others has demonstrated that it is probably unnecessary to chase a margin with low-grade dysplasia (PanIN-1) as this can result in the unnecessary resection of additional pancreas.<sup>10</sup> Importantly, at many institutions, there is only modest expertise in the interpretation of frozen-section evaluation of pancreatic transection margins. Surgeons should be cautioned to avoid overaggressive resection of grossly normal pancreatic parenchyma based on frozen-section evaluation of pancreatic transection margins especially when dealing with IPMN. Another area of operative/technical challenge includes IPMN involving the neck of the pancreas; should one resect the right or the left side of the gland? In this situation we would typically divide the pancreas to the right of the neoplasm at the junction of the head and neck of the pancreas. We would then send this margin for frozen-section evaluation before committing the patient to an extended distal pancreatectomy (in those cases where middle segment pancreatectomy is not preferred). When performing an extended distal pancreatectomy, one needs to be certain that the proximal pancreatic transection margin will be negative, especially if the patient could also be treated with an extended pancreaticoduodenectomy and thereby preserve some islet cell mass. In general, the preservation of some islet cell mass does facilitate improved blood sugar control even if not obviating the need for insulin. Last, it is important to note that patients who undergo surgery for IPMN (in contrast to those who undergo pancreatectomy for MCN) do require long-term follow-up. We typically obtain an MRI of the abdomen 2–4 months following surgery and our next scan would typically occur 1 year later. If there is no evidence of an abnormality in the remaining pancreas, our MRI imaging interval is in the range of 12–24 months depending on the histology of the previous resection, patient age, and the general health (performance status) of the patient.

As described by Dr Riall and Dr Evers, pancreatic neuroendocrine tumors (pNETs) are usually low- to intermediate-grade tumors arising from the pancreatic islets. They are also known as pancreatic endocrine tumors, islet cell carcinoma, and pancreatic carcinoid tumors. The current preferred nomenclature is pancreatic neuroendocrine tumors or pNETs.<sup>11</sup> The biology of this class of tumors is both unique and fascinating. For example, why should sporadic, nonmetastatic insulinomas virtually never develop distant recurrence and only very rarely recur locally (virtually all local recurrences are secondary to incomplete enucleation)? Metastatic insulinoma is very rare and, when seen, it is always synchronous at the time of diagnosis; we have not seen a case of metachronous metastases. In contrast, patients with multiple endocrine neoplasia type I (MEN1) who have nonfunctioning pNETs have a risk of metastatic spread that appears related to the size of the primary tumor

in the pancreas. Patients with primary tumors less than 2.5 cm in size rarely have associated liver metastases.<sup>12</sup> When weighing the risk of long-term insulin-dependent diabetes with the risk for distant metastases, we often observe small (<1–1.5 cm) nonfunctioning pNETs in young MEN1 patients. Further, why should the biology of patients with Zollinger-Ellison syndrome differ based on whether the primary tumor is in the pancreas or the duodenum and what determines where the tumor arises? Equally mystifying is why duodenal gastrinomas are so small, often less than 1 cm in diameter and rarely associated with liver metastases. Gastrinomas, when located in the pancreas, are usually found within the pancreatic head or uncinate process (gastrinoma triangle) and those 3 cm in size and larger are frequently associated with liver metastases. Consistent with the biology of duodenal gastrinoma, patients with carcinoid tumors of the duodenum also rarely have synchronous or metachronous liver metastases even though lymph nodes metastases are very common.<sup>13</sup> Indeed, the biologic explanation for the varied metastatic potential of functioning and nonfunctioning pNETs is an area of active investigation. Recent studies suggest that pancreatic, but not duodenal, gastrinomas express pancreatic-duodenal homeobox1 (Pdx1) and that only duodenal gastrinomas express sonic hedgehog signifying a different molecular origin for the two tumors.<sup>14</sup>

When evaluating a patient with hypergastrinemia, it is important to remember that the major cause of hypergastrinemia is parietal cell dysfunction, resulting in achlorhydria and pernicious anemia. Such patients can be differentiated from those with Zollinger-Ellison syndrome by the absence of gastric acid production. In the outpatient center, placement of a nasogastric tube with aspiration of gastric juice for pH testing will easily make this diagnosis. We frequently see patients who have elevated serum gastrin levels from either concomitant administration of a proton pump inhibitor or because of parietal cell dysfunction. A pancreatic or duodenal producing tumor is a much less frequent cause of hypergastrinemia. Importantly, consistent with the optimal operative management of virtually all pNETs, regional lymphadenectomy is an important part of the operative procedure for patients with gastrinoma. Patients with functioning or nonfunctioning pNETs can have persistent or recurrent disease in regional lymph nodes in the absence of liver, bone, or lung metastases. Careful attention to regional lymphadenectomy is an underemphasized and very important component of their surgical management.

As noted by the authors, patients with insulinoma virtually always have an insulin level greater than 3  $\mu$ IU/mL (usually >6  $\mu$ IU/mL) when the blood glucose is less than 40–45 mg/dL and an insulin to glucose ratio of 0.3 or less reflects the inappropriate secretion of insulin at the time of hypoglycemia. The conclusion of any carefully done observed fast, performed to confirm the diagnosis of hyperinsulinism, includes the administration of 1 mg of glucagon given intravenously. It is critically important to confirm the diagnosis of insulinoma by allowing the glucose to decline to a level of less than 45 mg/dL (at which point the patient is usually symptomatic) and observing the relief of symptoms with the



administration of glucagon. Intravenous glucagon is associated with an elevation of serum glucose of approximately 20 mg/dL. The reversal of hypoglycemia with glucagon confirms that hypoglycemia is insulin mediated. In contrast to gastrinomas that usually occur in the duodenum and pancreatic head/uncinate, insulinomas may develop anywhere throughout the pancreas and do not arise in the duodenum. In the absence of MEN1, the overwhelming majority of insulinomas are unifocal. As previously mentioned, if metastatic disease is not seen at the time of diagnosis, metachronous distant metastases from a presumed benign insulinoma does not occur. However, if the insulinoma is incompletely enucleated, a local recurrence can develop; such local recurrences may not occur for years after the primary operation. When we perform an enucleation of a benign insulinoma, we typically use bipolar forceps and are extremely careful to avoid violation of the tumor capsule. The advantage of bipolar cautery is that the operative field remains dry and that one can appreciate the junction of the tumor capsule and the normal pancreatic parenchyma. Because the pancreas is highly vascular, it is critically important to keep the operative field as dry as possible. Proper technique for enucleation is much more important than whether the operation is done laparoscopically or open. In the event of a pancreatic fistula, the presence or absence of an abdominal incision becomes insignificant. When an enucleation is performed, the anatomy of the primary tumor in relation to the pancreatic duct should be appreciated on preoperative imaging, and, if needed, this important anatomic relationship can be confirmed with intraoperative ultrasound. If one performs a very large enucleation or injures the pancreatic duct, a Roux-en-Y limb of jejunum can be used to create a pancreaticojejunostomy. For large defects in the pancreas, we have made liberal use of Roux-limbs for internal drainage.

Regarding MEN1, all at-risk patients should undergo genetic testing. In addition to MEN1, pNETs can occur in association with tuberous sclerosis, neurofibromatosis, and von Hippel-Lindau (vHL) syndrome. As previously mentioned, there is a defined association between tumor size and risk for liver metastases in MEN1 patients with nonfunctioning pNETs. Balancing the risk for insulin-dependent diabetes with the risk for metachronous liver metastases is indeed a difficult challenge. In our practice, the timing of pancreatic surgery in MEN1-associated nonfunctional pNETs is based on the tumor biology seen within the family (frequency of metastases and death secondary to metastatic pNET), the age of the patient, and the size of the pancreatic tumors. For patients who have a family history of metastatic neuroendocrine carcinoma, we begin to discuss surgery when the pNET becomes greater than 1 cm in size and argue against continued observation when the largest pNET reaches 1.5–2 cm in size. Dr Norman Thompson was the first to recommend a partial pancreatectomy for patients with MEN1.<sup>15</sup> He described the combination of distal subtotal pancreatectomy with enucleation of identified lesions in the pancreatic head and uncinate process. This operation also included regional lymphadenectomy. The “Thompson procedure” aimed to decrease the risk of metachronous liver metastases while preserving some islet

cell function, hopefully enough to avoid insulin dependent diabetes. Patients with aggressive MEN1-associated pNETs will often eventually require completion of total pancreatectomy, as one would expect metachronous recurrence within the remaining pancreas after the first operation. However, one would hope that the second operation to complete the total pancreatectomy would not occur until many years after the first operation, thereby avoiding insulin dependence until later in life at which time the long-term complications of type 1 diabetes are less unlikely. Because the natural history of MEN1-associated pNETs becomes clear only after decades of follow-up, we still have much to learn in the management of these patients.

Importantly, the last decade has witnessed an explosion in the understanding of the biology of pNETs and their potential response to targeted therapies. Tyrosine kinase inhibitors such as sunitinib and the mammalian target of rapamycin (mTOR) inhibitor everolimus have shown activity in patients with metastatic pNETs and have stimulated renewed interest in translational research and novel therapies for this disease.<sup>16,17</sup> Importantly, many patients who develop metachronous recurrence years after pancreatectomy for a nonfunctioning pNET will have somewhat indolent disease. The majority of these patients will be treated with octreotide, and disease stabilization is frequently seen.<sup>18</sup> The optimal management of patients with low-volume metastatic pancreatic neuroendocrine carcinoma requires thoughtful multidisciplinary input from oncologists, interventional radiologists, and frequently surgeons. Liver resection, systemic therapy (to include octreotide), and ablative therapies both intra-arterial and percutaneous can all add to improved length and quality of life for affected patients.

Last, in our practice we rarely proceed with surgery in a patient with a nonfunctioning pNET if a gross, complete resection cannot be performed. However, in the setting of known metastatic disease or a large, borderline resectable primary tumor, we frequently use neoadjuvant therapy (cytotoxic and/or biologic). In the setting of synchronous liver metastases, a one- or two-stage surgical approach can be used with or without neoadjuvant therapy. In contrast to exocrine pancreatic cancer, we frequently resect neuroendocrine liver metastases. When dealing with a resectable primary tumor and resectable liver metastases, we usually remove the pancreatic tumor first; if the pancreatectomy goes well, some or all of the liver disease can be addressed at the same operation. If the magnitude of surgery required for the pancreatic primary is too large, the liver surgery should be performed at a second stage. As one can imagine, there are various degrees of complexity regarding combined pancreas-liver resections. For patients with more advanced liver metastases, in whom a future liver remnant can be cleared at the time of the initial pancreatectomy, one can even consider portal vein embolization and second-stage extended hepatectomy. This of course assumes excellent health of the patient, a reasonable age category, and the absence of medical comorbidities. Indeed, future options to combine novel systemic therapies with advanced surgical techniques hold great promise for patients with pNETs, even those with disease that may have been considered nonoperable in the past.

## REFERENCES

1. Varadhachary GR, Tamm EP, Abbruzzese JL, et al. Borderline resectable pancreatic cancer: definitions, management, and role of preoperative therapy. *Ann Surg Oncol*. 2006;13:1035–1046.
2. Katz MHG, Pisters PWT, Evans DB, et al. Borderline resectable pancreatic cancer: the importance of this emerging stage of disease. *J Am Coll Surg*. 2008;206(5):833–846; discussion 846–848.
3. Callery MP, Chang KJ, Fishman EK, Talamonti MS, Traverso LW, Linehan DC. Pretreatment assessment of resectable and borderline resectable pancreatic cancer: expert consensus statement. *Ann Surg Oncol*. 2009;16:1727–1733.
4. Von Hoff DD, Ramanathan R, Borad M, et al. SPARC correlation with response to gemcitabine (G) plus nab-paclitaxel (nab-P) in patients with advanced metastatic pancreatic cancer: a phase I/II study [abstr 4525]. *J Clin Oncol*. 2009;27 (suppl):15s.
5. Conroy T, Desseigne F, Ychou M, et al; FNCLCC-FFCD PRODIGE Group. Randomized phase III trial comparing FOLFIRINOX (F: 5FU/leucovorin [LV], irinotecan [I], and oxaliplatin [O]) versus gemcitabine (G) as first-line treatment for metastatic pancreatic adenocarcinoma (MPA): Preplanned interim analysis results of the PRODIGE 4/ACCORD 11 trial [abstr 4010]. *J Clin Oncol*. 2010;28 (suppl):15s.
6. Raut CP, Tseng JF, Sun CC, et al. Impact of resection status on pattern of failure and survival after pancreaticoduodenectomy for pancreatic adenocarcinoma. *Ann Surg*. 2007;246(1):52–60.
7. Tseng JF, Warshaw AL, Sahani DV, et al. Serous cystadenoma of the pancreas: tumor growth rates and recommendations for treatment. *Ann Surg*. 2005;242:413–419.
8. Katz MHG, Mortenson M, Wang H, et al. Diagnosis and management of cystic neoplasms of the pancreas: an evidence-based approach. *J Am Coll Surg*. 2008;207(1):106–120.
9. Tanaka M, Chari S, Adsay V, et al; International Association of Pancreatology. International consensus guidelines for management of intraductal papillary mucinous neoplasms and mucinous cystic neoplasms of the pancreas. *Pancreatol*. 2006;6:17–32.
10. Raut CP, Cleary KR, Staerkel GA, et al. Intraductal papillary mucinous neoplasms of the pancreas: effect of invasion and pancreatic margin status on recurrence and survival. *Ann Surg Oncol*. 2006;4:582–594.
11. Yao JC, Rindi G, Evans DB. Pancreatic neuroendocrine tumors. In DeVita VT, Lawrence TS, Rosenberg SA, eds. *Cancer, Principles and Practice of Oncology*. 9th ed. Philadelphia, PA: Lippincott Williams & Wilkins; 2011:1489–1502.
12. Kouvaraki MA, Shapiro SE, Cote GJ, et al. Management of pancreatic endocrine tumors in multiple endocrine neoplasia type 1. *World J Surg*. 2006;30(5):643–653.
13. Mullen JT, Wang H, Yao JC, et al. Carcinoid tumors of the duodenum. *Surgery*. 2005;138:971–978.
14. Fendrich V, Ramerth R, Waldmann J, et al. Sonic hedgehog and pancreatic-duodenal homeobox 1 expression distinguish between duodenal and pancreatic gastrinomas. *Endocr Relat Cancer*. 2009 Jun;16(2):613–622. [Epub 2009 Feb 24]
15. Gauger PG, Thompson NW. Early surgical intervention and strategy in patients with multiple endocrine neoplasia type 1. *Best Pract Res Clin Endocrinol Metab*. 2001;15:213–223.
16. Raymond E, Dahan L, Raoul JL, et al. Sunitinib malate for the treatment of pancreatic neuroendocrine tumors. *N Engl J Med*. 2011 Feb 10;364(6):501–513.
17. Yao JC, Shah MH, Ito T, et al; RAD001 in Advanced Neuroendocrine Tumors, Third Trial (RADIANT-3) Study Group. Everolimus for advanced pancreatic neuroendocrine tumors. *N Engl J Med*. 2011 Feb 10;364(6):514–523.
18. Rinke A, Müller HH, Schade-Brittinger C, et al; PROMID Study Group. Placebo-controlled, double-blind, prospective, randomized study on the effect of octreotide LAR in the control of tumor growth in patients with metastatic neuroendocrine midgut tumors: a report from the PROMID Study Group. *J Clin Oncol*. 2009 Oct 1;27(28):4656–4663. [Epub 2009 Aug 24]

# PERSPECTIVE ON SURGERY FOR EXOCRINE NEOPLASMS OF THE PANCREAS

Andrew L. Warshaw

The last 40 years have seen remarkable advances in what we know about pancreatic neoplasms, their biology, how we approach their management, and the quality and safety of surgical treatment. Some can be attributed to better surgical technique, but most are due to developments in imaging, along with nonsurgical interventions such as endoscopic retrograde cholangiopancreatography (ERCP), stenting, and percutaneous or endoscopic needle biopsies. In most cases the diagnosis can be made preoperatively; the extent of the tumor can be determined; and the timing as well as the nature of the probable surgical procedure can all be planned before or even instead of a laparotomy. Pancreaticoduodenectomy has become sufficiently safe (2–5% mortality, median postoperative length of stay 8 days in high-volume centers) that the operation can be offered to most patients without biopsy proof of malignancy because the risk of missing a cancer now exceeds the risk of mistakenly operating for a benign condition. This radical approach to resection applies as well to ampullary neoplasms, which contain cancer in up to 50% of villous adenomas in spite of negative biopsies. The conclusion is that a negative biopsy should not deter resection of a lesion with significant malignant potential.

Yet there are still important shortcomings to the methods we have. There is no reliable screening test for pancreatic cancer and, even if one were invented that had a remarkable 99% accuracy, we would probably be unable to find the lesion at the desired very early stage of growth because current imaging with the best computed tomography (CT) or endoscopic ultrasound (EUS) still cannot “see” masses much smaller than 1 cm (at which size many pancreatic adenocarcinomas have already spread).

For purposes of staging pancreatic cancers, multidetector contrast-enhanced angio-CT is as good as we have for evaluating the mesenteric, celiac, and hepatic blood vessels, but it still misses small liver or peritoneal metastases in at least 10% of cases of apparently resectable cancers.<sup>1</sup> In addition, the use of preoperative laparoscopy will in another 10%

demonstrate peritoneal dissemination of cancer cells that indicate a significantly diminished prognosis.<sup>2</sup>

There is a consensus that preoperative biliary stenting is unnecessary if the operation can be expeditiously performed, but it is useful when the patient is uncomfortable with pruritus and relief by biliary decompression will not be immediate or when neoadjuvant treatment is planned. The fear of increased postoperative surgical site infections has not been substantiated in a recent randomized controlled trial.<sup>3</sup> Whether neoadjuvant therapy confers a benefit is debatable, either for downstaging borderline resectable cancers involving the mesenteric vessels or for increasing long-term survival.<sup>4</sup> The M.D. Anderson group has argued that neoadjuvant chemoradiation helps to define the 25% of patients in whom metastases are predestined to blossom immediately, ensures delivery of the treatment to some patients who would not tolerate or receive postoperative adjuvant treatment, and may improve survival, perhaps by reducing positive resection margins. However, with the relatively ineffective chemotherapy drugs available, the end results of a neoadjuvant approach have not been convincingly superior. In contrast to the prevailing European studies, adjuvant radiation added to chemotherapy for resected pancreatic cancer was associated with a significant survival advantage demonstrated in a large American database.<sup>5</sup>

Many studies have demonstrated that higher volumes, whether of the surgeon or the hospital, are related not only to lower postoperative mortality but also to higher long-term survival. New data show that both better technique, manifested by a higher percentage of negative margins,<sup>6</sup> and better hospital infrastructure for perioperative support play a part. Ensuring an adequate retroperitoneal margin by skeletonizing the superior mesenteric artery of its nerve plexuses (pancreatic cancer spreads along perineural channels) may help to reduce the positive margin rate that otherwise may be as high as 75% when there is assiduous pathological examination.<sup>7</sup> Intraoperative radiation, which in theory



might be useful for potentially positive margins, has been disappointing in achieving better survival.<sup>8</sup>

The technique for pancreaticoduodenectomy described in Chap. 60 is acceptably generic. It does not address the growing utilization of laparoscopic techniques for resection, now common for distal pancreatectomy but perhaps in the future for pancreaticoduodenectomy as well.<sup>9</sup> It also does not take sides in the debate about whether to perform a “classic Whipple operation” with pyloroantrectomy and gastrojejunostomy or a pylorus-preserving version with a duodenal-jejunostomy. Unless the proximal duodenum or antrum is directly involved by the cancer, there seems to be no demonstrable difference in survival or cure rates, despite that there may be some difference in extent of lymphadenectomy (even extended lymph node dissections have proven to make no difference).<sup>10</sup>

A recent meta-analysis of pylorus-preserving versus standard pancreaticoduodenectomy with antrectomy has found no significant difference in various perioperative indices except for 275 cc of greater blood loss and 72 minutes longer operation with the antrectomy version.<sup>11</sup> They noted no difference in the occurrence of delayed gastric emptying with the pylorus-preserving version. Our experience at the Massachusetts General Hospital differs in that the antrectomy portion adds less than 15 minutes for mobilization and the Hofmeister turn-in of part of the gastric staple line, and we, along with some others, have found that one-third of patients have 5–7 extra days of gastroparesis after the pylorus-preserving operation (erythromycin did not help). In our practice we avoid pylorus preservation. From my perspective, you can take it or leave it.

While extended retroperitoneal lymph node dissection has not fulfilled its theoretical promise, vascular resection, at least portal and mesentery vein resection, is establishing acceptance.<sup>12</sup> Involvement of the superior mesenteric or celiac arteries probably signals that the cancer has spread far enough along retroperitoneal lymphatic and neural channels that control of margins and metastases is out of reach, but vein resection when the cancer is adherent or invasive—it is difficult to differentiate between these without resecting the vein—can be accomplished safely with consequent negative margins and a 5-year survival comparable to patients not requiring a vein resection. The extent of vein involvement that still allows resection and reconstruction, whether with a graft or with mobilization of the mesentery and end-to-end anastomosis, will vary with the skill and aggression of the surgeon.

Postoperative leak at the pancreatic anastomosis leading to a pancreatic fistula or intra-abdominal collection is one of the most common complications of a pancreaticoduodenectomy, and the one most likely to be lethal. Breakdown of the pancreaticojejunostomy is more common with a soft, nonfibrotic pancreas, which does not hold sutures as well. It occurs more frequently, therefore, after resections for cystic neoplasms, neuroendocrine tumors, bile duct cancers, and duodenal cancers than in pancreatic cancers, which obstruct the pancreatic duct and cause induration of the gland. Fistulas occurred

in 13% of our Whipple operations (75/581) over 5 years.<sup>13</sup> While 39% of these fistulas healed with closed-suction drainage, allowing the drains (which we routinely use) to be removed, 61% were high impact and were complicated by an abscess or bleeding requiring intervention. Seven patients died (9% of those with fistulas), 6/7 from vascular erosion and pseudoaneurysm. A sentinel bleed from a drain must be taken very seriously and it warrants immediate angiographic evaluation for purposes of embolization or stenting of the culprit vessel.

Probably all high-volume pancreatic surgery practices are seeing increasing numbers of pancreatic cystic tumors, in large measure the product of cross-sectional imaging for other purposes. Thirty years ago, pseudocysts were said to be the most common cystic lesions of the pancreas; now cystic neoplasms are far more prevalent, the majority being asymptomatic and found by serendipity. Cystic neoplasms comprised about one-fourth of our pancreaticoduodenectomies in 2009 and are now the most common pancreatic neoplasm entering our practice. The challenge for pancreatic surgeons and their colleagues is how to estimate the relative risk of watchful waiting versus intervention.

Much attention is paid to the differential diagnosis of serous cystadenomas (SCA), mucinous cystic neoplasms (MCN), intraductal papillary mucinous neoplasms (main-duct and branch-duct IPMN), cystic neuroendocrine tumors, and other uncommon entities by the use of CT, magnetic resonance imaging (MRI), EUS, and fine-needle aspiration, the latter in part for cytology but especially for carcinogenic embryonic antigen (CEA) levels in the fluid. An elevated CEA tends to indicate one of the mucinous family of tumors but gives no indication of malignancy at any level.<sup>14</sup> However, the level of sensitivity and specificity of these diagnostic tests generally does not exceed 70% across the board, with the exception that an elevated CEA essentially excludes serous cystic neoplasms, which are almost always benign.

From a pragmatic standpoint, therefore, it may be more useful to develop guidelines that can be applied to an undetermined cystic lesion that does not fit the clinical or morphologic criteria for a pseudocyst. Some are easy: if the cyst is producing symptoms (pain, jaundice, and pancreatitis) or is bulky and demonstrably growing over time, it probably should be resected. If the main pancreatic duct is dilated, main-duct IPMN, with its 60% likelihood of containing at least in situ cancer, must be considered and resected. If there is a mural nodule or solid component, the risk of malignancy is too great to ignore. The Sendai consensus,<sup>15</sup> which provides reliable guidelines that have been repeatedly validated, adds the element of cyst size. While there are uncommon exceptions, generally there is minimal risk of malignancy, even carcinoma-in-situ, in mucinous cysts (MCN or branch-duct IPMN) smaller than 3 cm. Consequently smaller, asymptomatic cysts without mural nodules or other solid components can be watched for growth or change, preferably by MRI/magnetic resonance cholangiopancreatography (MRCP), perhaps every year

or two. Most will turn out to be branch-duct IPMNs, at least 30% of which will be multiple. Those individual cysts that fit a guideline for potential malignancy need segmental resection—metachronous small cysts can be left behind and watched for future growth and change.

There is growing appreciation that many small, incidentally discovered pancreatic cystic lesions do not grow or develop cancerous change over a period of many years while many, perhaps 5% (8/159 in our experience<sup>16</sup>), turn out to be indeterminate nonneoplastic cysts upon resection. On the other hand, because the mucinous cystic neoplasms—MCN or IPMN—may eventually degenerate into aggressive incurable adenocarcinomas, there is a premium on timely determination of the need for resection, erring on the side of taking out many benign lesions to prevent one cancer from getting beyond cure. Cystic carcinomas are highly curable if removed before invasion or metastases, and the majority of those that are invasive can still be cured. Lymph node metastases are less common in IPMN carcinomas and unheard of in MCN carcinomas, at least in our experience.<sup>17</sup> For this reason segmental and other atypical resections that focus on the locale of the lesion suffice. Local excision of the tumor, including duodenum-preserving head resection (which is essentially a wide enucleation), is also acceptable as long as the tumor can be removed with adequate surrounding pancreas to ensure negative margins. Evaluation of the pancreatic duct margin, of special importance for main-duct IPMN, requires an experienced pathologist to differentiate mucinous hyperplasia (acceptable) from neoplasia (unacceptable) on frozen section.

Surveillance, generally with MRI/MRCP, is indicated for residual cysts, perhaps no more often than at intervals of 1 or 2 years. We have not seen the appearance of a new serous or mucinous cystic neoplasm after resection of the propositus lesion and do not recommend surveillance imaging for these patients. Surveillance is, of course, appropriate after removing a cancer or any main-duct IPMN because of the possibility of metastasis, recurrence, or development of a new main-duct lesion in the residual pancreas. In addition, patients with IPMN are at somewhat greater risk of developing other gastrointestinal cancers, especially in the colon and stomach.

## REFERENCES

1. Jimenez RE, Warshaw AL, Rattner DW, Willett CG, McGrath D, Fernandez-del Castillo F. Impact of laparoscopic staging in the treatment of pancreatic cancer. *Arch Surg*. 2000;135:409–415.
2. Kelly KJ, Wong J, Gladly R, et al. Prognostic impact of RT-PCR-based detection of peritoneal micrometastases in patients with pancreatic cancer undergoing curative resection. *Ann Surg Oncol*. 2009;16:3333–3339.
3. van der Gaag NA, Rauws EJ, van Eijck CHJ, et al. Preoperative biliary drainage for cancer of the head of the pancreas. *N Engl J Med*. 2010;362:129–137.
4. Lowy AM. Neoadjuvant therapy for pancreatic cancer. *J Gastrointest Surg*. 2008;12:1600–1608.
5. McDade TP, Hill JS, Simons JP, et al. A national propensity-adjusted analysis of adjuvant radiotherapy in the treatment of resected pancreatic adenocarcinoma. *Cancer*. 2010;116(13):3257–3266.
6. Bilimoria KY, Talamonti MS, Sener SF, et al. Effect of hospital volume on margin status after pancreaticoduodenectomy for cancer. *J Am Coll Surg*. 2008;7:510–519.
7. Esposito I, Kleeff J, Bergmann F, et al. Most pancreatic cancer resections are R1 resections. *Ann Surg Oncol*. 2008;15:1651–1660.
8. Showalter TN, Rao AS, Anne PR, et al. Does intraoperative radiation therapy improve local tumor control in patients undergoing pancreaticoduodenectomy for pancreatic adenocarcinoma? A propensity score analysis. *Ann Surg Oncol*. 2009;16:2116–2122.
9. Kendrick ML, Cusati D. Total laparoscopic pancreaticoduodenectomy. *Arch Surg*. 2010;145(1):19–23.
10. Farnell MB, Aranha GV, Nimura Y, Michelassi F. The role of extended lymphadenectomy for adenocarcinoma of the head of the pancreas: strength of the evidence. *J Gastrointest Surg*. 2008;12:651–656.
11. Karanicolas PJ, Davies E, Kunz R, et al. The pylorus: take it or leave it? Systematic review and meta-analysis of pylorus-preserving versus standard Whipple pancreaticoduodenectomy for pancreatic or periampullary cancer. *Ann Surg Oncol*. 2007;14(6):1825–1834.
12. Chua TC, Saxena A. Extended pancreatectomy with vascular resection for pancreatic cancer: a systematic review. *J Gastrointest Surg*. 2010;14(9):1442–1452.
13. Veillette G, Dominguez I, Ferrone C, et al. Implications and management of pancreatic fistulas following pancreaticoduodenectomy. *Arch Surg*. 2008;143(5):476–481.
14. Nagula S, Kennedy T, Schattner MA, et al. Evaluation of cyst fluid CEA analysis in the diagnosis of mucinous cysts of the pancreas. *J Gastrointest Surg*. 2010;14(12):1997–2003.
15. Tanaka M, Chari S, Adsay V, et al. International consensus guidelines for management of intraductal papillary mucinous neoplasms and mucinous cystic neoplasms of the pancreas. *Pancreatol*. 2006;6:17–32.
16. Correa-Gallego C, Ferrone CR, Thayer SP, Wargo JA, Warshaw AL, Fernandez-del Castillo C. Incidental pancreatic cysts: do we really know what we are watching? *Pancreatol*. 2010;10:144–150.
17. Crippa S, Fernandez-del Castillo C, Salvia R, et al. Mucin-producing neoplasms of the pancreas: an analysis of distinguishing clinical and epidemiologic characteristics. *Clin Gastroenterol Hepatol*. 2010;8:213–219.

*This page intentionally left blank*



# SPLEEN AND ADRENAL



*This page intentionally left blank*

# THE SPLEEN

Ali Tavakkoli

## BACKGROUND

The spleen was regarded by Galen as “an organ of mystery,” by Aristotle as unnecessary, and by Pliny as an organ that might hinder the speed of runners.<sup>1</sup> In many societies, spleen was also thought to be affiliated with mood. The word *spleen* comes from a Greek word that has idiomatic equivalent of the heart in English, that is, to be good-spleened means to be good-hearted or compassionate. In contrast, spleen has been typically associated with melancholy, and in 19th-century England women in bad humor were said to be afflicted by the spleen or the vapors of the spleen. Although over the last century the functions of spleen have become clearer, an element of mystery remains around the organ.

Surgeons often have a love–hate relationship with the spleen. A surgeon’s experience with the spleen is often tainted as most of his or her experience with the organ comes from emergent settings, when the patient is often unstable and the spleen is the source of significant bleeding. Even when dealing with elective cases, the increased complexity of medical indications for splenectomy has made the role of surgery often confusing. Despite these drawbacks, surgery on the spleen remains an enticing procedure for most surgeons, one that is wonderfully challenging and often memorable.

In this chapter we review the anatomy, physiology, and pathology of splenic diseases, before focusing on techniques of splenectomy, focusing on the laparoscopic approach.

## RELEVANT ANATOMY

### Gross Anatomy

The spleen arises by mesenchymal differentiation along the left side of the dorsal mesogastrium in juxtaposition to the anlage of the left gonad in the 8-mm embryo. The organ ultimately migrates to the left upper quadrant.

In the healthy adult, the spleen weights 150 g (range 75–250 g), although there are variations based on sex, age, and racial background.<sup>2</sup> It resides in the posterior portion of the left upper quadrant lying deep to the 9th, 10th, and 11th

ribs, with its long axis corresponding to that of the 10th rib, and measures about 11 cm. On ultrasound imaging, 13 cm is regarded as the upper limit of normal size for spleen. It’s convex superior, and lateral surfaces are immediately adjacent to the undersurface of the left leaf of the diaphragm. The configuration of the concave medial surface of the spleen is a consequence of impressions made by the stomach, pancreas, kidneys, and splenic flexure of the colon (Fig. 62-1).

The position of the spleen is maintained by several suspensory ligaments, which need to be divided during a splenectomy to allow full mobilization of the organ. These are the gastrosplenic, splenophrenic, splenocolic, and splenorenal ligaments (Figs. 62-2 and 62-3). The gastrosplenic ligament contains the short gastric vessels that course to the splenic hilum from the greater curvature while the remaining ligaments are generally avascular, except in patients with portal hypertension or myeloproliferative disorders. The splenorenal ligament contains the pancreas and the splenic vessels. The tail of the pancreas is thus in close proximity to the splenic hilum. Recent computed tomographic (CT) image analysis has shown that the average distance between the tail of the pancreas and the splenic hilum is  $3.4 \pm 1.5$  cm, and at least 1 cm in all cases. To minimize the risk of injury to the pancreatic tail during surgery, it is therefore important that the surgeon stay close (within 1 cm) to the splenic hilum during a splenectomy to avoid injury to the pancreas.<sup>3</sup>

Accessory spleens, which are often distinct and separate masses of splenic tissue, have been reported in 14–30% of patients, with a higher incidence in patients with hematologic disorders. They are present in decreasing order of frequency in the hilum of the spleen and the tail of the pancreas, the greater omentum, the gastrosplenic ligament, and splenocolic ligament (Fig. 62-4A). Accessory spleens may also occur in the pelvis of the female, either in the presacral region or adjacent to the left ovary, and in the scrotum in juxtaposition to the left testicle (Fig. 62-4B). The accessory spleens can vary in size and may be small lesions that can be easily missed unless a careful examination is performed (Fig. 62-5).

*Splenoptosis* (wandering spleen) refers to a rare condition in which the spleen hangs by a long pedicle from the mesentery and may present itself as an asymptomatic mass or with

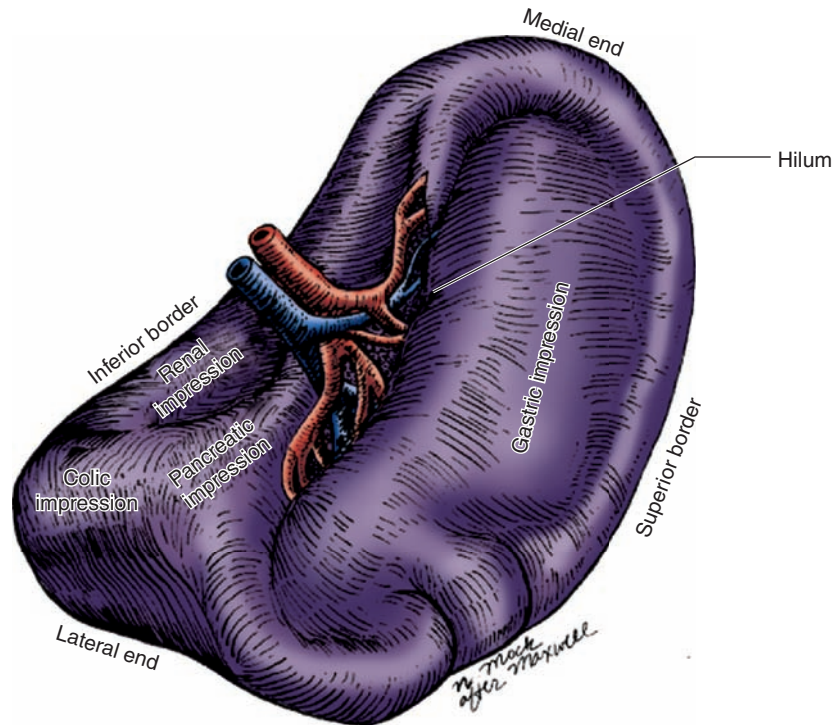


FIGURE 62-1 Gross anatomy of the spleen.

symptoms of intermittent or acute abdominal pain due to torsion. Treatment involves splenectomy in cases of ischemia, but splenopexy should be considered in other cases.<sup>4</sup>

## Splenic Blood Supply

The splenic artery commonly arises from the celiac plexus and is the longest of its three branches. Most of the splenic arterial supply is derived through this vessel although short gastric vessels, arising from the gastroepiploic artery, also provide some supply. The splenic artery has a very tortuous course and a unique pattern of distribution in every individual. Following the work of Michels, the splenic arterial supply has been divided into two general types:

*Distributed type:* The most common variation seen in 70% of cases. Here the main splenic artery is short, dividing into several long branches that enter the spleen on the medial aspect, involving 75% of the medial border (Fig. 62-6A).

*Magistral type:* The less common variation seen in 30% of cases. Here a long main trunk, divides near the hilum to a few branches that enter the spleen medially but only involve 30% of the spleen's medial surface (Fig. 62-6B).

Each of these anatomical variations can raise their own surgical challenges, and identification of the arterial supply type can help the surgeon plan their approach. The splenic artery also has a pancreatic branch (pancreatica magna) that is worthy of note. Occlusion of this branch, most often seen

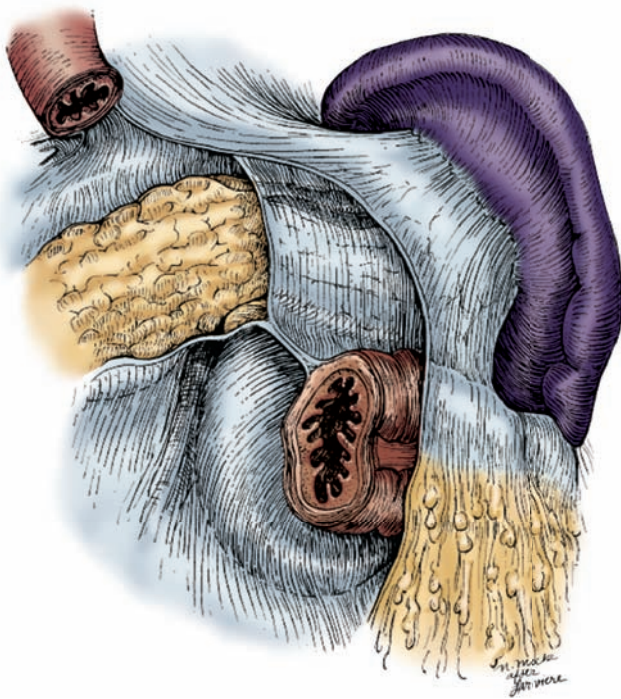


FIGURE 62-2 Anatomy of the spleen showing complicated peritoneal reflections in the region of the hilum.



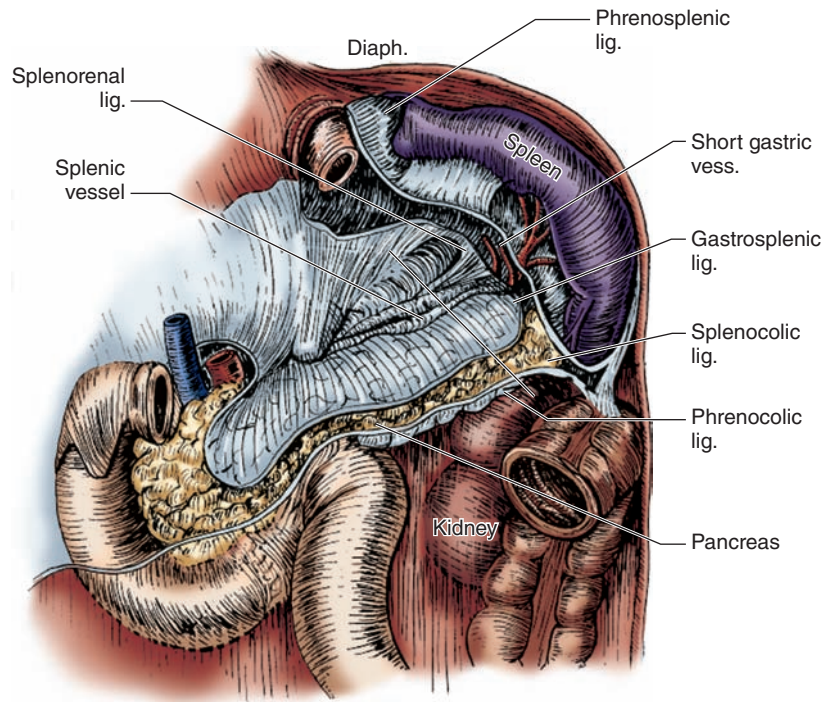


FIGURE 62-3 The multiple ligaments of the spleen.

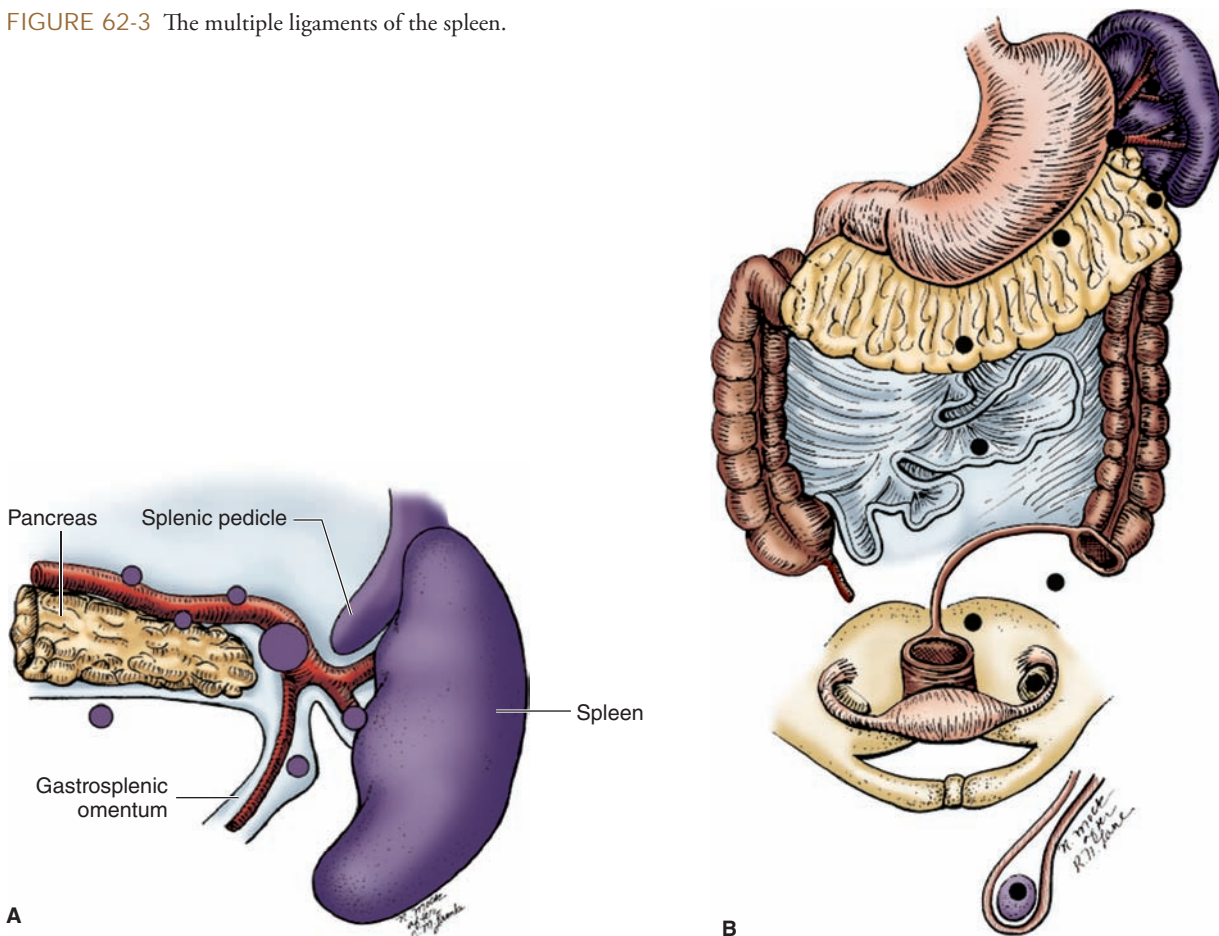


FIGURE 62-4 **A.** The more common locations of accessory spleens. Accessory spleens are also found in the left ovary, in the left testicle along the course of the left ureter, and in the lesser sac and greater omentum. **B.** Locations of accessory spleens. Note position of presacral and paraureteric splenuli.



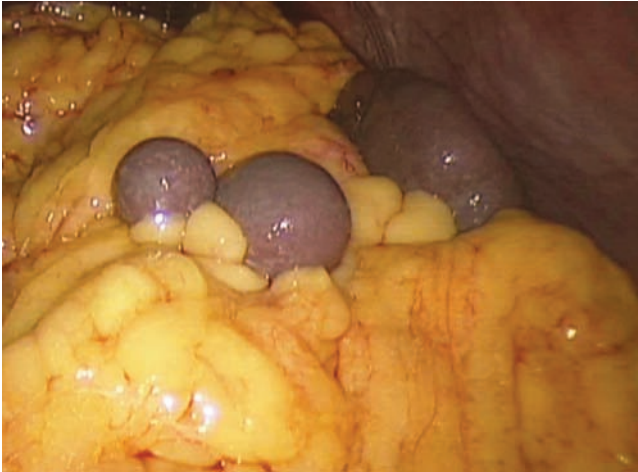

FIGURE 62-5 Two small splenules in the greater omentum near the spleen.

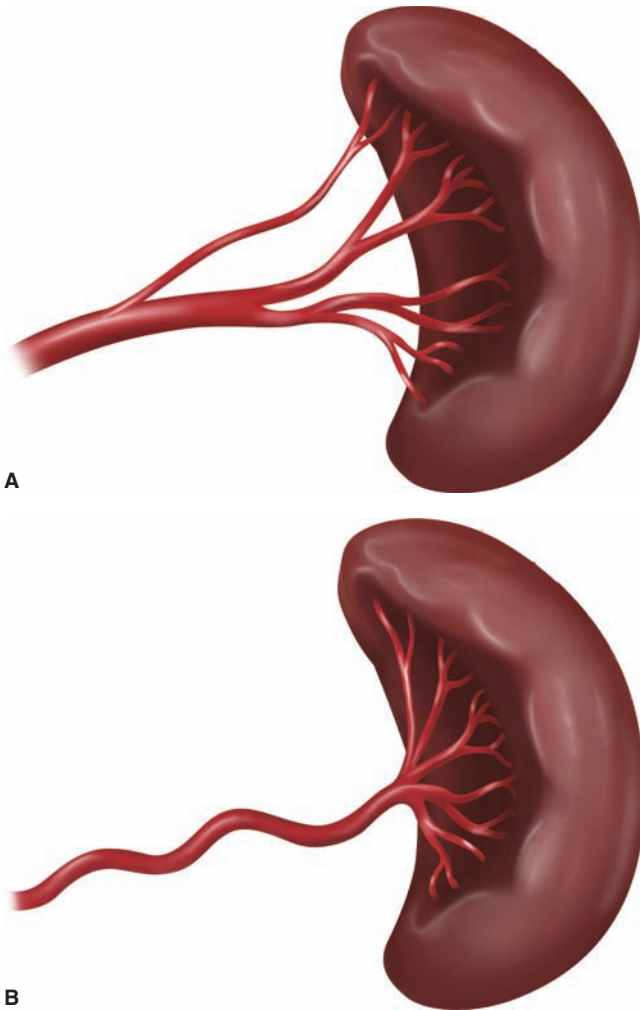


FIGURE 62-6 Different types of splenic artery distribution: **A.** Distributed type: short splenic artery that divides into long branches that enter the spleen medially, involving 75% of the medial border. **B.** Magistral type: here the splenic artery is long with few hilar branches.

after splenic artery embolization, can lead to pancreatitis. This topic is discussed in more detail later.

The major venous drainage flows through the splenic vein, which usually receives the inferior mesenteric vein centrally, and then joins the superior mesenteric vein to form the portal vein.

## Histology

The spleen is made up of a capsule that is normally 1–2 mm thick, and trabeculae that surround and invaginate the pulp. Approximately 25% of the parenchyma (Fig. 62-7) is made up of “white pulp” that functions as an immunologic organ, with the remaining 75% made up of the “red pulp” that phagocytizes particulate matter from the blood. The two zones are separated by a narrow marginal zone.

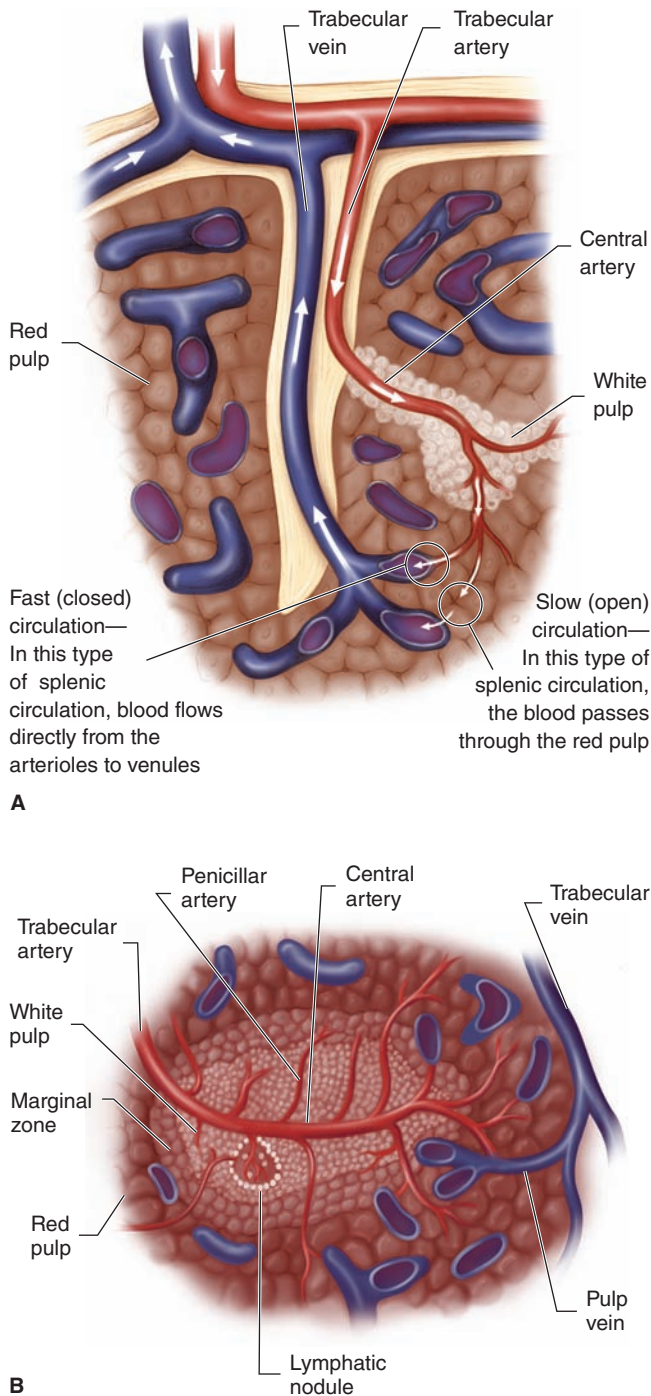
The white pulp, which is central and surrounds a central artery, is made of lymphatic nodules with germinal centers and periarterial lymphatic sheaths that constitute a reticular network filled with lymphocytes and macrophages. Peripheral to the white pulp is the marginal zone that contains end arteries arising from the central artery and from peripheral penicilliary arteries. The marginal zone contains lymphocytes and macrophages and red blood cells (RBCs) that have exited from terminal arteries. The marginal zone also contains the marginal sinus that filters material from the centrally located white pulp. Locally produced immunoglobulins enter the marginal zone, eventually coursing to the blood stream.

## Physiology

Spleen receives 250–300 mL of blood per minute, which corresponds to 5% of the cardiac output. At any given time, however, it contains only 30–40 mL of blood. Although the spleen is not necessary for human life, it performs important functions that are generally attributed to its unique blood flow pattern. As the blood enters the spleen, it can take two paths of flow. A fast (closed) circulation that takes the blood directly from the arterioles to venules or a slower (open) circulation that takes the blood through the pulp. The majority (90%) of flow is of the slow (open) type that exposes the circulating cells and erythrocytes to splenic macrophages in the red pulp (see Fig. 62-7).

Functions of the spleen can be generally divided into the following:

*Erythrocyte quality control and removal of defective red cells:* This is achieved through pitting and culling. *Pitting* refers to the removal of rigid structures such as Heinz bodies (denatured intracellular hemoglobin), Howell-Jolly bodies, and hemosiderin granules from red cells. The process involves the removal of nondeformable intracellular substances from deformable cells. The rigid body is phagocytized while the deformable cytoplasmic mass passes into the sinus and returns to the general circulation. The postsplenectomy



**FIGURE 62-7** Diagram illustrating splenic compartments and the two different types of circulation.

blood smear is thus characterized by the presence of circulating erythrocytes with Howell-Jolly and Pappenheimer bodies (siderotic granules).

*Culling* is the term applied to the spleen's ability to remove red cells that are aged or abnormal. During its 120-day life

cycle, the red cell spends an estimated minimum of 2 days within the spleen. Normally, as the red cell ages after a life span of approximately 120 days, it loses osmotic balance and membrane integrity, and therefore deformability. When these cells lose their deformability, they are phagocytized by native macrophages. The spleen does not represent the only site for red cell destruction, and there is no difference in red cell survival following splenectomy. About 20 mL of RBCs are removed daily from the blood.

*Pooling:* In health, the spleen does not serve as an important reservoir for blood cells but does so for platelets. Normally, about one-third of the platelet mass is pooled in the spleen, and this pool exchanges freely with the circulating platelets that have a life span of about 10 days. With splenomegaly, a large proportion of platelets are sequestered in the spleen (up to 80%) and this, coupled with accelerated platelet destruction in the spleen, accounts for thrombocytopenia. The role of spleen in platelet storage also explains the elevation in platelet count that is seen after splenectomy.

The neutrophil has a half-life of about 6 hours; hence 85% of neutrophils either migrate at random into tissues or are destroyed within 24 hours. Although the role of the spleen in the destruction of neutrophils under normal conditions is not well quantified, this role is amplified in some hypersplenic states, with resulting neutropenia. This augmented removal can occur because of splenic enlargement and accelerated sequestration of granulocytes or because of enhanced splenic removal of altered granulocytes, as seen in immune neutropenias.

*Hematopoiesis:* The spleen has an important hematopoietic function in fetal life that ceases by the seventh intrauterine month, and does not occur in healthy adults with exception in certain pathological conditions where bone marrow is unable to meet the needs (ie, extramedullary hematopoiesis).

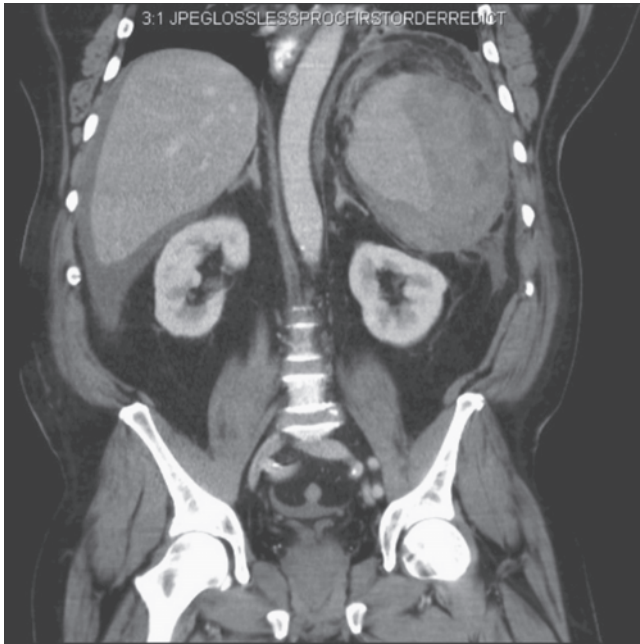
*Filtration:* Macrophages residing in the splenic parenchyma capture cellular and noncellular material from blood, including encapsulated bacteria such as pneumococci, and destroy them. This function explains the increased risk of infections caused by encapsulated organisms that is seen after splenectomy.

*Antibody synthesis in the white pulp:* In addition to the phagocytosis of antibody-coated cells, the immunologic functions of the spleen include antibody synthesis (especially immunoglobulin M [IgM]); generation of lymphocytes; and production of tuftsin, opsonins, properdin, and interferon. Foreign antigens that are filtered in the white pulp are presented to lymphoid cells. Here the immunoglobulin response is mounted, leading to release of antibodies.

## SPLENIC TRAUMA AND RUPTURE

### Etiology

The causes of splenic rupture, in which the organ's parenchyma or capsule is disrupted, include penetrating trauma,



**FIGURE 62-8** A large splenic hematoma that developed following intraoperative injury to the spleen during gastric bypass surgery. The patient was hemodynamically stable and the hematoma resolved without any further intervention.

nonpenetrating or blunt trauma, operative (iatrogenic) trauma, and, rarely, spontaneous rupture.

Spontaneous rupture of the spleen is rare but serious complication of a few diseases. In a review of over 800 spontaneous ruptures, six major etiological groups were defined: neoplastic (30.3%), infectious (27.3%), inflammatory (20.0%), drug- and treatment-related (9.2%), mechanical (6.8%), and normal spleen (6.4%). Majority of patients were treated with splenectomy with an overall mortality rate of 12%.<sup>5</sup>

Iatrogenic splenic injuries during abdominal procedures, especially colectomy, are well documented (Fig. 62-8). In a 16-year review of nearly 14,000 colectomies performed at Mayo clinic, the risk of splenic injury requiring a splenectomy or repair was 0.4%. The majority of these injuries occurred following mobilization of the splenic flexure, although in 10% of cases no splenic flexure mobilization was performed and the injury likely reflected tension on the colon. Although repair was attempted in 50% of cases, the majority of these patients ultimately require splenectomy. Those with an incidental splenectomy also had a high 30-day morbidity (34%) and mortality (15%).<sup>6</sup> Other contemporary studies have shown that patients who undergo an incidental splenectomy during colorectal surgery for cancer have a poorer prognosis compared to the nonsplenectomized group, highlighting also the negative long-term impact of splenic injury in these patients.<sup>7</sup> Iatrogenic splenic rupture has also been reported after endoscopic examination of the colon, although the rate of this adverse event is extremely low at 0.001%.<sup>8</sup>

Traumatic injury to the spleen remains the most common cause of splenic rupture and its management is discussed in the following text. The injury may be caused by puncture

wounds due to stabbing or missiles. The trajectory of the penetrating wound may pass through the anterior abdominal wall, the posterior abdominal wall, the flank, or, transthoracically, piercing the pleural space and diaphragm. Isolated splenic injury may be present, or organs in juxtaposition may be involved; this would include the stomach, left kidney, left adrenal gland, colon, pancreas, and root of the mesentery. Nonpenetrating or blunt trauma represents an increasing etiologic factor in splenic rupture.

## Diagnostic Studies

A decrease in serial hematocrit measurements may suggest continued intraperitoneal hemorrhage. Increases in the white blood cell (WBC) count to levels frequently greater than 15,000/mm<sup>3</sup> are often seen. Findings on routine abdominal films such as fractured ribs, elevated left hemidiaphragm, enlarged splenic shadow, medial gastric displacement, and widening of the space between the splenic flexure and the preperitoneal fat pad may be helpful. However, abdominal ultrasound and CT scan offer more specific information to diagnose the extent of disease or injury, with CT as the gold standard. Radiologic classification of splenic injury are now well established and can help the clinician identify patients who can be managed nonoperatively (Table 62-1).



**TABLE 62-1: SPLENIC ORGAN INJURY SCALE**

Class I	Nonexpanding subcapsular hematoma <10% surface area. Nonbleeding capsular laceration with <1-cm-deep parenchymal involvement.
Class II	Nonexpanding subcapsular hematoma 10–50% surface area. Nonexpanding intraparenchymal hematoma <5 cm in diameter. Bleeding capsular tear or parenchymal laceration 1–3 cm deep without trabecular vessel involvement.
Class III	Expanding subcapsular or intraparenchymal hematoma. Bleeding subcapsular hematoma or subcapsular hematoma >50% surface area Intraparenchymal hematoma >5 cm in diameter. Parenchymal laceration >3 cm deep or involving trabecular vessels.
Class IV	Ruptured intraparenchymal hematoma with active bleeding. Laceration involving segmental or hilar vessels producing major (>25% splenic volume) devascularization.
Class V	Completely shattered or avulsed spleen. Hilar laceration that devascularizes entire spleen.

Data from Cogbill TH, Moore EE, et al. Nonoperative management of blunt splenic trauma: a multicenter experience. *J Trauma*. 1989;29:1312.



## Management

Penetrating injury patients and hemodynamically unstable blunt trauma patients with hemoperitoneum or peritonitis are treated with laparotomy and likely splenectomy.

The first total splenectomy for trauma was performed by Nicolaus Matthias in 1678 in Capetown, South Africa, on a patient whose spleen protruded through a flank wound. However, partial splenectomy for trauma antedated this procedure with the first successful partial splenectomy for trauma reported by Franciscus Rosetti in 1590. Increasing understanding of the functions of the spleen and increased risk of infection in splenectomized patients have rejuvenated interest in splenic salvage in trauma. The first successful partial splenectomy for trauma in modern times was reported by Campos Christo in 1962.<sup>9</sup> Splenic salvage may be attempted if hemostasis is achieved, greater than one-third of the splenic mass can be preserved, and if other intraabdominal injuries, such as pancreatic trauma, do not warrant splenectomy.

Observation that splenic injury may heal itself has also promoted conservative management of splenic injuries, and avoidance of surgery. While this practice was largely accepted in the treatment of injured pediatric patients to salvage the spleen and its immunologic function, it is only recently that nonoperative management has become established in the management of hemodynamically stable adults with blunt splenic injuries. With advances in imaging including spiral CT scan, more accurate and immediate grading of splenic injuries has been possible to guide therapy (see Table 62-1).

Increasingly, splenic injuries are managed with close observation and serial hematocrits. The success rate in such management strategy depends on severity of injury, and is reported greater than 95% for grade I injuries, greater than 90% for grade II, and greater than 80% for grade III injuries. Although grades IV and V are typically treated surgically, increasing numbers of trauma centers are adopting a nonoperative approach to some grade IV injuries. In a recent review of nonoperative management of splenic injuries in New England, the success rate of nonoperative management was only 40% for grade IV and 26% for grade V injuries.<sup>10</sup>

Identification of factors that increase the risk of delayed hemorrhage and failure of nonoperative management after splenic trauma has been attempted in an effort to reduce nonoperative failures. Such factors include presence of contrast extravasation or “blush” on CT scan, pseudoaneurysm, and arteriovenous fistulas.<sup>11</sup> Admission angiography with embolization is used increasingly to manage hemodynamically stable patients with such CT findings to help improve the success of splenic conservation.

Splenic salvage rates with angiographic embolization have been in the order of 90–95%, which likely explains the increasing pattern of its utilization.<sup>12</sup> Splenic embolization, however, has its own risks and may be complicated by splenic abscess, infarction, and significant pain.

Although there were concerns that such nonoperative approach would lead to increased need for blood transfusions, this has not been borne out in recent literature, even

in the nonoperative management of higher grade injuries. Pachter and associates reported that 85% of 102 patients with splenic injuries managed nonoperatively did not require blood transfusion and, in fact, required less blood than the splenectomy cohort.<sup>13</sup>

## LOCAL SPLENIC DISORDERS

### Splenic Artery Aneurysm

Splenic artery aneurysm was first described by Baussier in 1770, and St. Leger Brockman described one of the first surgical cases in 1930. Although mycotic aneurysm can be seen in the splenic artery, the majority are idiopathic. The splenic artery is the most common visceral artery aneurysm and the second most common site of intra-abdominal aneurysms, second to the abdominal aorta. The incidence in autopsy series ranges between 0.02 and 0.16%, with a female predominance (4:1). The incidence of splenic aneurysm can increase in certain patient groups, including those with cirrhosis and portal hypertension. In fact, splenic artery aneurysms have been reported in 14% of patients awaiting liver transplant, which can lead to major hemorrhage after transplant.<sup>14</sup> Splenic artery aneurysm may also develop in patients with history of pancreatitis and should be suspected in a patient with pancreatitis who develops gastrointestinal (GI) bleeding without an obvious source.

In a contemporary review of 217 splenic aneurysms seen at the Mayo clinic, the mean age at presentation was 62 years, with 79% of the patients being female. Over 90% of the patients were asymptomatic, with only 5% of patients presenting with a rupture, with a mean size of 3.1 cm. While over 10% of men presented with a rupture, this rate was less than 3% in women, in large part due to larger aneurysm sizes in men. The mean size for nonruptured cases was 2.2 cm, and the smallest-diameter aneurysm to rupture was 2.2 cm.<sup>15</sup>

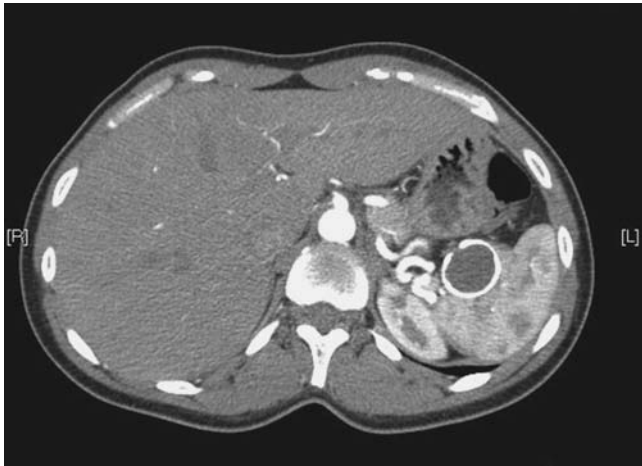Risk of rupture of splenic aneurysms is believed to be higher in pregnant women, where rupture of aneurysms less than 2 cm has been reported. Such ruptures have been associated with maternal and fetal death rates of 22 and 15%, respectively.<sup>16</sup> Ruptures occur in the third-trimester of pregnancy in 69% of cases.<sup>17</sup>

Diagnosis in asymptomatic patients is often made as an incidental finding on a CT scan, although occasionally a calcified lesion is noted on plain film of the abdomen (Fig. 62-9).

Rupture of the aneurysm is manifested by sudden abdominal pain. In 12.5% a warning hemorrhage occurs, with temporary cessation of bleeding. Rupture into the colon, stomach, and intestine may take place, but intraperitoneal rupture is by far the most common presentation. When rupture occurs in the nonpregnant woman, it is usually contained in the lesser sac, resulting in a patient mortality rate of less than 5%.

Surgical resection in all symptomatic aneurysms is recommended; however, criteria for elective repair of asymptomatic aneurysms are not firm. In general, asymptomatic aneurysms greater than 2 cm should be removed if the patient is a





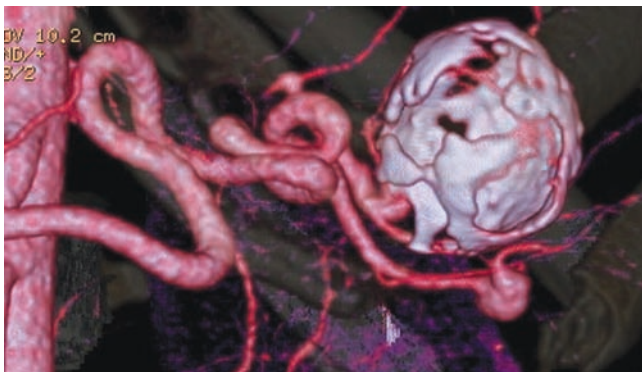
**FIGURE 62-9** A CT scan of a large splenic artery aneurysm with calcified wall. This calcified wall can also be seen on plain abdominal roentgenogram.

reasonable operative risk.<sup>15</sup> Aneurysms of any size detected in pregnancy should be considered for resection as many of the ruptured aneurysms during pregnancy are less than 2 cm in size.<sup>16</sup> These resections should be done before the third trimester, when the risk of rupture is at its peak.

Lesions proximal to the hilus of the spleen can be managed by resection and primary end-to-end anastomosis or proximal and distal ligation with resection of the involved segment.<sup>18</sup> Proximal ligation is reasonable because the spleen will not become ischemic following central ligation of the main splenic artery.

Distal lesions generally require laparoscopic splenectomy with resection of the involved splenic artery (Fig. 62-10).

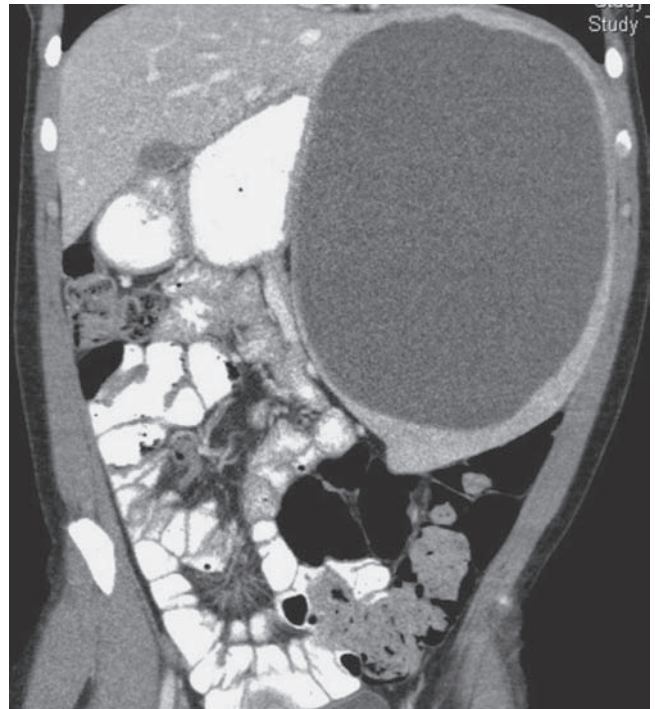
Although there has been significant recent progress in treating such aneurysms by endovascular means, with a less than 90% success rate the disadvantages of the endovascular procedures include treatment failures, postprocedural pain, and abscess formation, as well as pancreatitis due to occlusion of the pancreatic magna vessel.<sup>19</sup>



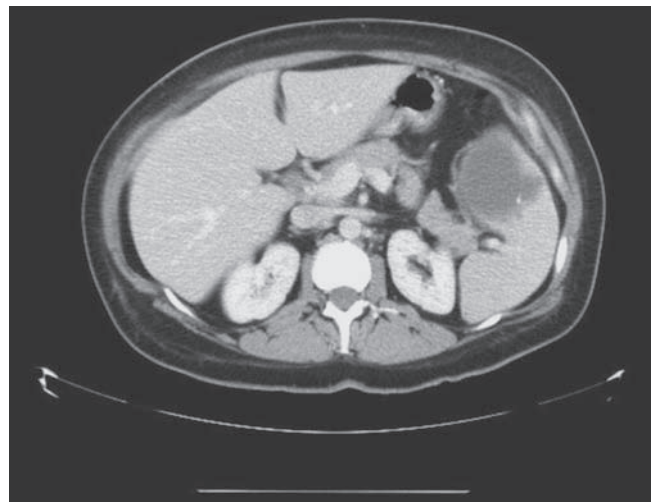
**FIGURE 62-10** A 3D CT reconstruction of a partially thrombosed large splenic artery aneurysm with a smaller aneurysm more distal. Both aneurysms were treated by a laparoscopic splenectomy.

## Cysts

Splenic cysts are generally classified as primary or secondary (pseudocysts). Some of the splenic tumors may also have a large cystic component to them and are discussed separately in the following text (Fig. 62-11). Primary cysts have an epithelial lining and can be nonparasitic or parasitic (echinococcal).



**A**



**B**

**FIGURE 62-11** **A.** A large splenic cyst seen on CT. **B.** A large splenic cyst that, on careful review, had septations and calcifications. Patient underwent a splenectomy, and pathology confirmed an 8-cm lymphangioma.

## PARASITIC PRIMARY CYSTS

Worldwide, *Echinococcus* infection (hydatid disease) is the most common cause of a splenic cyst. *Echinococcus granulosus*, the most commonly implicated species, usually results in a unilocular cyst composed of an inner germinal layer (endocyst) and an outer laminated layer (ectocyst) surrounded by a fibrous capsule. Unlike the nonparasitic cysts, these are filled with fluid under positive pressure, and also contain daughter cysts and infective scolices. Echinococcal cysts are usually asymptomatic unless they reach a size causing pressure symptoms or become secondarily infected or ruptured.

For diagnostic purposes, the older Casoni skin test is now replaced with serologic testing, which provides reliable diagnostic specificity and sensitivity. Ultrasound, CT, and MRI studies demonstrate a cystic mass that is septated and contains daughter cysts.

Splenectomy is the treatment of choice because there is no effective medical therapy. Care should be taken to avoid spilling the contents of the cyst. Intraoperatively, the lesions can be sterilized by instilling a 3% sodium chloride solution. If intraperitoneal spillage occurs during the dissection, anaphylactic hypotension may occur and require epinephrine to treat the shock. Laparoscopic and percutaneous treatment has not been widely accepted in treating hydatid cysts because of a traditional fear of spillage and anaphylaxis.<sup>20</sup>

## NONPARASITIC PRIMARY CYSTS

This group of cysts includes simple cysts, epidermoid cysts, and dermoid cysts. Various classifications have been proposed based on whether they are lined with mesothelial, transitional, or epidermoid linings and also whether they are neoplastic, traumatic, or degenerative.<sup>21</sup> Simple congenital cysts are lined by flattened or cuboidal cells originating from infolding of peritoneal mesothelioma during splenic development. These lesions are usually small and asymptomatic and do not require excision. When these cysts are large and symptomatic, they can be removed by laparoscopic or open total or partial splenectomy.

About 10% of cysts are lined by squamous epithelium and are rare. These cysts are usually round and unilocular and may be very large. They are filled with yellow or brown turbid fluid. The cyst is dense, and the diagnosis is established by microscopic definition of the stratified squamous lining. Examination of multiple cuts may be required to demonstrate the pathology.

Epidermoid cysts of the spleen occur in children and in young adults in 75% of the cases. About two-thirds of the patients have been female. The clinical manifestations are dependent on the size and are similar to those of the pseudocysts, as are the imaging findings. Laparoscopic or open splenectomy or partial splenectomy is recommended for large or symptomatic cysts.

True dermoid cysts of the spleen are exceedingly rare; fewer than 10 cases have met the pathologic criteria of a squamous epithelium with dermal appendages such as hair follicles and sweat glands. Splenectomy is indicated.

It can be difficult to differentiate these cysts from one another based on imaging only, and usually the differential diagnosis is made when symptomatic cysts, usually greater than 5 cm, are excised and analyzed histologically.<sup>22</sup> Asymptomatic cysts, which are often smaller, are observed with no need for surgical resection.

## SECONDARY PSEUDOCYSTS

These cysts do not have an epithelial lining and comprise 70–80% of splenic cysts in the Western countries. They are usually a result of trauma and represent resolution of a subcapsular or intraparenchymal hematoma. In over 80% of the cases the lesion is unilocular, and the cyst wall is dense and smooth. Microscopically, the wall consists of fibrous tissue without an internal epithelial lining.

Pseudocysts occur more frequently in women, children, and young adults. One-third of the patients are asymptomatic, and in others the most frequent complaint is left upper quadrant pain radiating to the left shoulder or chest. Symptoms related to pressure on the stomach occur less frequently. Ultrasonography, CT, MRI, and magnetic resonance arteriography will define the cystic nature of the lesion. Although splenectomy is the definitive therapy, these cysts are increasingly managed by laparoscopic unroofing and drainage. Such simple approach is, however, associated with a recurrence rate of 20–40%, and recommendations would be to marsupialize the cyst or decapsulate the cyst when possible, which has been associated with very low recurrence rates.<sup>23,24</sup>

## Splenic Abscess

Splenic abscesses tend to be rare, due to the spleen's ability at fighting infections and bacteria. They are more frequently seen in the tropics, where there is a higher incidence of sickle cell anemia, with associated thrombosis of parenchymal vessels and subsequent superimposed infarction.

The major risk factors for such abscesses in the Western world are intravenous drug use, human immunodeficiency virus disease, other hematogenous spread (endocarditis), splenic trauma, and contiguous spread. Endocarditis can be complicated with splenic abscesses in 5% of cases. They are often multiple splenic abscesses associated with similar findings in other organs; spleen is just a part of overwhelming sepsis.<sup>25</sup>

Most infections are polymicrobial and include such organisms as *Staphylococcus*, *Salmonella*, and *Escherichia coli*, *Proteus mirabilis*, *Streptococcus* group D, *Klebsiella pneumoniae*, *Peptostreptococcus* species, *Bacteroides* species, *Fusobacterium* species, *Clostridium* species, *Candida albicans*, and *Mycobacterium*.

The symptoms are usually nonspecific such as malaise, weight loss, left upper quadrant pain, and fever. Most patients have a leucocytosis and an ultrasound, CT or magnetic resonance study establishes the diagnosis of a splenic

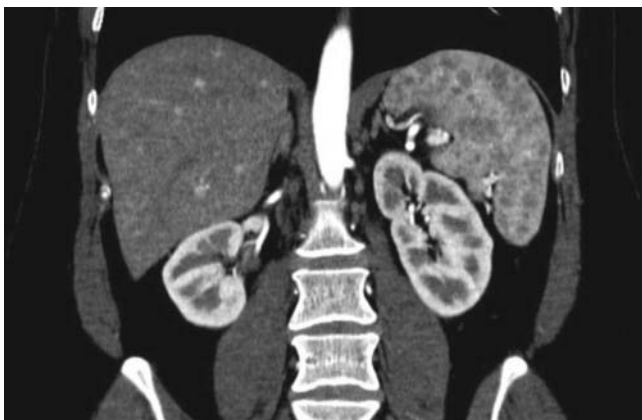abscess. Treatment consists of broad-spectrum antibiotics and percutaneous drainage, which, if fails, will require laparoscopic or open splenectomy. Many patients have multiple other abscesses, and the spleen is just a part of overwhelming sepsis. Antibiotic treatment should continue until the drains or percutaneous catheters have been removed. If the spleen has multiple abscesses, splenectomy may be required.

## Splenic Tumors

Splenic masses may be identified during workup of symptoms, or often incidentally during other imaging (Fig. 62-12). Some of these masses, can have a large cystic component (see Fig. 62-11B). Management of such lesions can be difficult as imaging alone does not always help with a definitive diagnosis. Often, these lesions may need to be followed serially or, if concerning, splenectomy should be considered. In a series of 44 such cases, half of whom were symptomatic and treated surgically, 75% of lesions were benign while the remainder were malignant.<sup>26</sup> In a similar study of 28 patients, the risk of a malignant diagnosis was significantly higher at 72%, although 25% of these patients had had a previous history of lymphoproliferative disorder.<sup>27</sup> There are increasing data on the use of fine-needle aspiration of the spleen in differentiating such masses, with low complication rates.<sup>28</sup> Sensitivity and specificity of such aspiration have been reported as 94 and 79%, respectively.<sup>29</sup>

### BENIGN NEOPLASMS

Benign splenic neoplasms generally arise from the lymphoid or vascular elements of the spleen. The most common primary neoplasm of the spleen is hemangioma.<sup>30</sup> The lesion can be single or multiple.



**FIGURE 62-12** Multiple splenic masses were seen during a right upper quadrant ultrasound for symptomatic gallstones and were further evaluated by a CT scan as shown. The lesions were negative on PET scan. Patient did not wish to have a splenectomy or percutaneous biopsy and is therefore followed by regular imaging. Lesions have remained unchanged, and patient is asymptomatic.

Hemangiomas vary from well-circumscribed to irregular vascular proliferations. The majority are cavernous in nature. The potential for malignant transformation to angiosarcoma is not known but appears to be low and associated with large hemangiomas. Many splenic hemangiomas are now diagnosed incidentally during the course of imaging for other pathology. On CT scan, hemangiomas appear as homogeneous, hypodense, or multicystic lesions with variable calcification, and peripheral enhancement. Angiography may also be employed to confirm the diagnosis, although this is much more invasive. On angiography, the splenic hemangioma resembles a hepatic hemangioma with fine vascularity and “laking” effect in the capillary phase, which may be accompanied by early filling of the splenic vein.

The majority of splenic hemangiomas do not require surgical intervention. Splenectomy is reserved for large and symptomatic lesions. Most splenic hemangiomas are asymptomatic, with symptoms being associated with enlargement of the tumor and mass effect or rupture. Although there has traditionally been concern about risk of spontaneous rupture of these hemangiomas, a contemporary series from the Mayo Clinic reported no spontaneous rupture among 32 patients with splenic hemangioma, 80% of whom were entirely asymptomatic.<sup>30</sup>

Littoral cell angioma has been recently described as an endothelial cell neoplasm arising from the cells lining the sinus channels of the splenic red pulp. These rare lesions express vascular and histiocyte-associated antigens. Patients often present with splenomegaly and multiple hypoattenuating masses seen on CT.<sup>31</sup> While littoral cell angioma has been described as a benign neoplasm cured with splenectomy, there have been reports of associated malignant lymphomas, other visceral organ cancers, and recurrent disease identified as malignant littoral cell hemangioendothelioma. Splenectomy and close observation are thus warranted.<sup>32</sup>

Lymphangioma of the spleen is composed of a malformation of lymphatics (see Fig. 62-11B). Microscopically, these endothelium-lined spaces are filled with lymph and blood elements. The lesion may be focal or multiple, a small or large cystic mass, or may diffusely involve the spleen and account for splenomegaly. The diagnosis is made by ultrasound, CT scan, or MR imaging, which reveals water-density cystic lesion(s) of the spleen. The lymphangioma may be isolated to the spleen or occur as a generalized lymphangiomatosis with multivisceral involvement and a poor prognosis. Symptoms, when present, are related to the size and mass effect of the lesion. Splenectomy is indicated for symptomatic lesions. Partial splenectomy is reserved for small, focal symptomatic lesions.

Other benign lesions of the spleen are uncommon. Inflammatory pseudotumor of the spleen is a reactive lesion characterized by a mixture of inflammatory cells and disorganized spindle cells.<sup>33</sup> This tumor is typically found incidentally and is generally asymptomatic but may present with systemic symptoms such as fever, malaise, and weight loss. Inflammatory pseudotumor is infiltrative in nature and may mimic malignant lymphoproliferative disease. Splenic



hamartomas are composed of irregular vascular channels lined by splenic sinus endothelium with a disorganized reticulin stroma. Splenic hamartomas are uncommon with autopsy series noting an incidence of 0.024–0.13%. Peliosis is not a true neoplastic lesion but a blood-filled cystic lesion without an endothelial lining that may be associated with focal, patchy, or diffuse involvement of the spleen. This lesion is likely reactive as it has been associated with steroids, oral contraceptives, immunosuppression medications, tuberculosis, renal disease, and malignancy. Other benign splenic tumors, such as angiomyolipoma, lipoma, hemangiopericytoma, and fibroma are rare.

### PRIMARY MALIGNANT TUMORS

Primary, nonlymphoid, malignant tumors of the spleen are exceedingly rare. These include angiosarcomas, malignant fibrous histiocytomas, and plasmacytomas. Angiosarcoma is the most common nonlymphoid primary malignant neoplasm of the spleen. The clinical presentation may include abdominal pain, left upper quadrant abdominal mass, and constitutional symptoms. Metastasis is frequent and often involves the liver. Spontaneous rupture has been reported and is associated with a dismal outcome. Normocytic anemia is present in the majority of cases. Splenomegaly with hypersplenism is also seen. CT imaging often identifies a splenic lesion with central necrosis. The primary treatment is splenectomy. Cisplatin-based chemotherapy has also been used. However, even without rupture, splenic angiosarcoma holds a poor prognosis. Recent studies have reported respective 1-, 3- and 5-year survival rates of 60, 40, and 40%.<sup>34</sup>

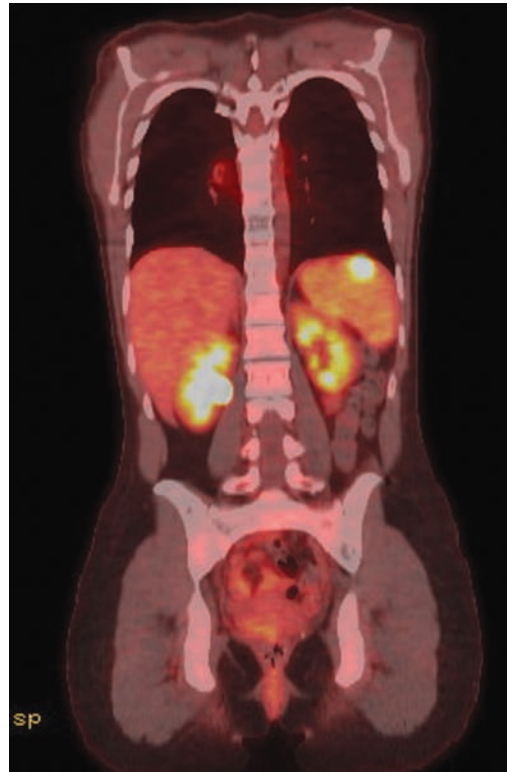
### METASTATIC TUMORS

Splenic metastasis of nonhematologic malignancies is rarely seen clinically and usually represents widespread dissemination of disease. In a review of a German oncological database, only 0.002% of those with a malignancy developed reported splenic metastasis, with isolated splenic metastasis being extremely rare.<sup>35</sup> Despite lack of clinically evident splenic metastasis, postmortem evidence of splenic metastasis is reported to be higher, although the exact prevalence of this is debated, with older literature reporting rates as high as 34%, while contemporary reports put this rate at approximately 3%.<sup>36</sup>

The diagnosis of malignancy can be confirmed by positron emission tomography (PET) scanning, although percutaneous biopsies for isolated lesions can also be performed (Fig. 62-13).<sup>28</sup>

## HEMATOLOGIC DISORDERS

In 1887, Sir Thomas Spencer Wells, the renowned gynecologist, performed a therapeutic splenectomy for what proved to be hereditary spherocytosis. The first splenectomy for autoimmune hemolytic anemia (AIHA) was performed in 1911



**FIGURE 62-13** The patient was found to have a splenic lesion on CT which was active on PET scan. She subsequently underwent a splenectomy to obtain a tissue diagnosis.

by Micheli. Six years later, Schloffer, at the suggestion of a medical student, Kaznelson, performed a splenectomy for idiopathic thrombocytopenic purpura.<sup>9</sup> Today, the role of splenectomy in the management of hematologic disease has grown in parallel with the rise in laparoscopic splenectomy and its decreased morbidity compared to open splenectomy.

## ANEMIAS

Splenectomy is indicated for specific cases of anemia. The major categories of anemia that benefit from splenectomy are those caused by the following:

- Membrane abnormalities: Hereditary elliptocytosis and spherocytosis
- Enzyme defects: Pyruvate kinase deficiency
- Hemoglobinopathy: Thalassemias and sickle cell
- AIHA

### Hereditary Spherocytosis

This hemolytic disorder results from a genetic defect or deficiency in one of the components of the red cell cytoskeleton. It is transmitted as an autosomal dominant trait but occurs sporadically in rare instances. Hereditary spherocytosis is the



most common cause of familial chronic hemolytic anemia in North America and Northern Europe, with an incidence of 1–5 in 10,000 births or even higher if mild cases of osmotic fragility are included.<sup>37</sup>

The defect in red cell membrane components (spectrin, ankyrin, band 3, and/or protein 4–2) weakens the structure of the red cell and changes the morphology, making it more susceptible to destruction. Spleen plays a critical role in pathophysiology of hereditary spherocytosis, as it is the main site of hemolysis. The red cell membrane change results in excessive red cell trapping within the splenic pulp and hemolysis. Cells that escape the spleen on first passage are more susceptible to trapping and destruction during each successive passage. The red cells also exhibit increased osmotic fragility.

The salient clinical features include anemia, jaundice, and splenomegaly. The severity of disease varies from asymptomatic “carrier” with normal hemoglobin level, to severe spherocytosis with baseline hemoglobin level less than 6 g/dL. The disease severity is related to the degree of red cell cytoskeleton protein deficiency, particularly spectrin shortage. The jaundice usually parallels the severity of anemia and generally is not intense. It is related to the increased red cell destruction, resulting in abundant bile pigment that cannot be cleared by the liver. Approximately 30% of cases are mild, maintain a near-normal hemoglobin and bilirubin levels, and compensate with a reticulocytosis. Up to 63% of patients with hereditary spherocytosis have cholelithiasis, but this is unusual in children younger than 10 years. The gallstones are generally pigmented and a major indication for surgery in this patient group. Most have mild to moderate spleen enlargement, but splenomegaly alone is not an indication for surgery. Increases in splenic size in patients with hereditary spherocytosis may be seen in the presence of acute infection. Periodic worsening of the associated anemia and jaundice may be seen, often following infection, emotional stress, fatigue, or prolonged exposure to cold.

Splenectomy is effective in reducing the hemolysis associated with hereditary spherocytosis and recommended in those with anemia. Failures are uncommon and often reflect missed accessory spleens, which can be identified using radio-colloid liver-spleen scans.<sup>38</sup> The preferred approach is the laparoscopic approach that has been shown to be associated with less postoperative morbidity and pain. Because of the increased risk of serious postsplenectomy sepsis among young children, splenectomy is reserved preferably for patients older than 5 years. Splenectomy for hereditary spherocytosis before this age should be performed only in cases of severe transfusion-dependent disease and only after the age of 3.<sup>39</sup> There are institutional reports of partial splenectomy in such children with the objective of leaving some functional spleen behind for immunologic purposes.<sup>40,41</sup> In children without cholelithiasis, cholecystectomy is not indicated at the time of splenectomy. A limited review of patients younger than 18 years by Sandler and colleagues demonstrated that none of them developed cholelithiasis postsplenectomy over a mean follow-up of 15 years.<sup>42</sup>

The indication for a splenectomy in mild cases is more controversial. Using decision analysis, it has been suggested that patients with asymptomatic gallstones who are younger than 39 years gain benefit from a prophylactic cholecystectomy and splenectomy. In patients with symptomatic cholelithiasis, the patients gained quality-of-life advantage if they underwent the combined procedure versus cholecystectomy alone up to the age of 52.<sup>43</sup>

## Hereditary Elliptocytosis

Hereditary elliptocytosis is a heterogeneous group of erythrocyte disorders that have in common the presence of elongated, oval, or elliptically shaped RBCs on the peripheral blood film. Most are transmitted as an autosomal dominant trait. The majority of patients are asymptomatic or have mild form of the disease with compensated hemolytic anemia, as the defects often do not significantly shorten the red cell life span despite striking abnormalities seen on blood film. The presence of hemolysis often is a familial characteristic, and it has been suggested that excessive hemolysis occurs only when the gene for elliptocytosis is present in the homozygous form or is modified in some other way.

The majority of patients with hereditary elliptocytosis are Caucasian and the signs and symptoms are related directly to the severity of the hemolysis. Occasionally an acute hemolytic episode may be precipitated by infection. The clinical syndrome is indistinguishable from that described for hereditary spherocytosis. Gallstones and chronic leg ulcers have been reported in symptomatic patients. The spleen is usually palpably enlarged in symptomatic cases. Diagnosis is established by the smear.

Laparoscopic splenectomy is indicated in the few symptomatic patients because removal of the organ is almost always followed by lasting effects of decreased hemolysis and corrected anemia, although the morphologic abnormality of the RBC remains unchanged. Associated cholelithiasis should be managed as in hereditary spherocytosis.

## Pyruvate Kinase Deficiency

Pyruvate kinase deficiency is the most common RBC enzyme deficiency to cause chronic hemolytic anemia. It is an autosomal recessive condition that has a much lower frequency than glucose-6-phosphatase deficiency (G6PD); however, it is a more common cause of anemia because G6PD patients rarely suffer hemolysis.

Clinical manifestation varies from transfusion dependent anemia to compensated chronic hemolysis. Splenomegaly is common. Splenectomy has a role in transfusion-dependent individuals and can reduce or even abolish the need for transfusion. As with other children being evaluated for splenectomy, the procedure should be delayed until after age 3 owing to immunosuppressive effect of the surgery.

## Thalassemia

Thalassemia (Mediterranean anemia) is a congenital disorder transmitted as a dominant trait in which the anemia is primarily the result of a defect in hemoglobin synthesis. Thalassemias are the most common monogenetic disease in man and have been referred to as *Cooley's anemia*, *erythroblastic anemia*, and *target-cell anemia*. The disease is classified as alpha, beta, and gamma types, determined by the specific defect in the synthesis of the relevant globulin chain of the adult hemoglobin. As a consequence of the defect, there is imbalance production of globulin chains with resultant formation of atypical hemoglobin proteins that can lead to intracellular precipitates (Heinz bodies) that contribute to premature red cell destruction. The hemoglobin-deficient red cells are small, thin, misshapen, and have a characteristic resistance to osmotic lysis.<sup>44</sup>

In the United States most patients suffer from beta thalassemia, and there is a quantitative reduction in the rate of beta-chain synthesis, resulting in a decrease in the hemoglobin A. Over 200 genetic mutations having been identified leading to beta thalassemia.<sup>45</sup> The characteristic feature is the persistence of Hb-F and a reduction in Hb-A. Gradations of the disease range from heterozygous thalassemia minor to severe homozygous thalassemia major. The latter is manifested by chronic anemia, jaundice, and splenomegaly.

Patients with homozygous thalassemia major usually present with clinical manifestations in the first year of life. In addition to the anemia and consequent pallor, there is usually retarded body growth and enlargement of the head. Intractable leg ulcers may be noted, and intercurrent infections are particularly common. Some patients present with repeated episodes of left upper quadrant pain related to splenic infarction. Cardiac dilatation occurs, and in advance stages there is subcutaneous edema and effusion into serous cavities. Intercurrent infections occur frequently, often leading to death in the more severe cases. These infections may be associated with aplastic crises. Gallstones have been reported in up to 24% of cases.

Therapy is directed only at symptomatic patients, those having thalassemia major, or intermedia. In these patients, transfusions are usually required at regular intervals. Because most children with thalassemia major accommodate to low hemoglobin levels, transfusions are given when the hemoglobin level is less than 10 g/dL. Owing to the high rate of hemolysis, these patients are also at high risk of iron overload and are treated with iron chelators. In select cases stem cell transplant may be considered.<sup>44</sup>

Although splenectomy does not influence the basic hematologic disorder, it may eliminate or reduce the hemolytic process responsible for accelerated destruction of normal donor red cells within the patient's circulation and this reduces transfusion requirements. In one study of 49 patients, blood transfusion requirement declined from 12 units of packed red cells per year to 4 units after surgery.<sup>46</sup> In general, the best

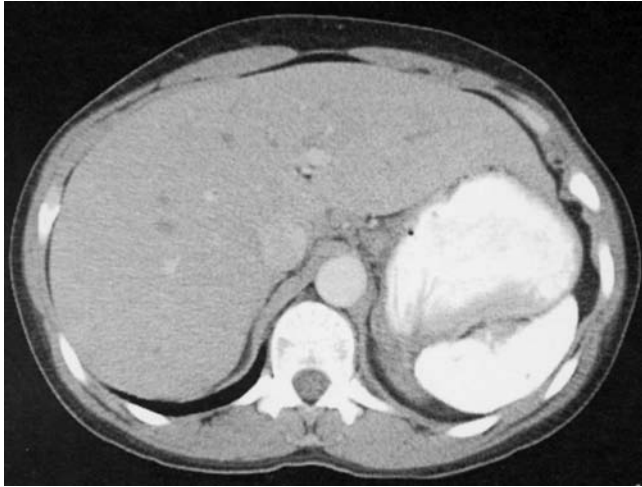
results associated with splenectomy have been obtained in older children and in young adults with large spleens in whom excessive splenic sequestration of red cells has been demonstrated. Splenectomy should be avoided in children younger than 5 years.<sup>44</sup> Occasionally, splenectomy may be indicated because of mass effect symptoms associated with marked splenomegaly or repeated episodes of abdominal pain due to splenic infarction.

## Sickle Cell Disease

Sickle cell anemia, first reported in 1910, is a hereditary hemolytic anemia seen predominantly in blacks, and characterized by the presence of crescent-shaped erythrocytes that, because of a lack of deformability, are trapped in the splenic cords. In this disorder, the normal hemoglobin A is replaced by hemoglobin S. Under conditions of reduced oxygen tension, hemoglobin S molecules undergo crystallization within the cell, which elongates and distorts the cell. The sickle cells increase the blood viscosity and circulatory stasis, thus establishing a vicious cycle. Although the sickle cell trait occurs in approximately 9% of the black population, the majority of patients are asymptomatic. Sickle cell anemia is observed in 0.3–1.3% of blacks. Many body systems can be affected by sickle cell disease. Depending on the vessels affected by vascular occlusion, the patients may have bone or joint pain, osteomyelitis, priapism, neurologic manifestations, or skin ulcers. Abdominal pain and cramps due to visceral stasis are frequent.

Spleen is commonly affected in these patients. Sickling occurs so rapidly that blood flow through both the fast and slow compartments of the spleen is obstructed; as a consequence, a series of microinfarcts develop and eventually lead to "autosplenectomy." In most adult patients only a fibrous area of the spleen remains, but autosplenectomy is preceded by splenomegaly in about 75% of patients. Calcification may occur with autoinfarction (Fig. 62-14). Such functional asplenia is defined and detected by the presence of Howell-Jolly bodies in the blood film and can be confirmed by absence of technetium-99m (<sup>99m</sup>Tc) splenic uptake. Patients are subsequently at risk of developing infection by encapsulated organisms such as *Streptococcus pneumoniae*, due to impaired filtration and antibody production of the spleen. Rarely thrombosis of the splenic vessels may result in the complication of splenic abscess manifested by splenomegaly, splenic pain, and spiking fever. Percutaneous drainage of such abscesses may be attempted, but it may require a splenectomy.

For most patients with sickle cell anemia, only palliative therapy is available. Adequate hydration and partial exchange transfusion may help the crisis. Randomized multicentered studies have shown a role for hydroxyurea in treatment of adults with sickle cell disease. Such treatment leads to reduction in frequency of painful crisis, hospitalization, and transfusion.<sup>47</sup> The beneficial effects are in part due to an



**FIGURE 62-14** Calcified spleen in a patient with sickle cell disease causing persistent pain. Splenectomy relieved the patient's pain.

increase in hemoglobin F levels, although the mechanism underlying this process is not known. Hydroxyurea is therefore recommended in patients with three or more crises per year and its use if being evaluated in younger patient.<sup>48</sup> Other hemoglobin F–inducing agents and stem cell transplant are also currently under investigation.

There are two situations in sickle cell anemia where the spleen is a pathologic red cell reservoir, and splenectomy may have a role. The first is a form of chronic hypersplenism that usually occurs in childhood or adolescence and is manifested by reduced red cell survival, leukopenia, and thrombocytopenia. In these patients, for some unknown reason, there is a failure to undergo autosplenectomy. In this rare circumstance, splenectomy will correct the leukopenia and thrombocytopenia and will also increase the rate of red cell survival and can lead to reduced transfusion requirement.<sup>49</sup> The second abnormality has been termed *acute splenic sequestration* and is marked by sudden splenic enlargement associated with worsening anemia and profound hypotension. It usually occurs in the first 5 years of life in a homozygous child; streptococcal pneumonia infection may act as a precipitating event in these patients. The acute splenic sequestration is usually effectively treated with packed red cell transfusion. If there is a propensity for recurrence, splenectomy may be indicated.

## Immune Hemolytic Anemia

The first description of the disease is credited to Chauffard and Troisier who, in 1908, demonstrated autohemolysins in the serum of several patients with acute hemolytic anemia. Three years later Micheli performed the first planned, successful splenectomy, thus stimulating the application of splenectomy for hematologic disease.

*Immune hemolytic anemia* (IHA) is a disorder in which immunoglobulin G (IgG) and/or IgM antibodies bind to erythrocyte surface antigens and stimulate erythrocyte destruction. This occurs through the complement and reticuloendothelial systems. IHA is classified as *autoimmune*, *alloimmune*, or *drug-induced*. Alloimmune hemolytic anemia occurs only after exposure to allogeneic erythrocytes, such as through blood transfusion, pregnancy, or transplant. There is no antibody reactivity against autologous red cells. Acute hemolysis after transfusion is estimated to occur in 0.0003–0.0008%, and a delayed response is seen in 0.05–0.07%.<sup>50</sup> Drug-induced IHA occurs as drug-induced antibodies recognize intrinsic red cell antigens or erythrocyte-bound drug. Alpha-methyl dopa, high-dose penicillin, second- and third-generation cephalosporins have been implicated. Drug-induced IHA should resolve with cessation of the medication in question but may require corticosteroids and may involve a protracted recovery.

Autoimmune hemolytic anemia (AIHA) is estimated to occur in 1 per 100,000 per year, with a prevalence of 17/100,000.<sup>51</sup> It is an antibody-mediated process that involves IgG or IgM antibodies. For cases of IgG-mediated disease, antibodies bind to the erythrocyte and are recognized by Fc receptors of macrophages and other phagocytic cells of the reticuloendothelial system for phagocytosis. In contrast to IgG antibodies, IgM antibodies readily activate the classical complement pathway and may lead to intravascular hemolysis. Additionally, IgM-bound erythrocytes may undergo extravascular hemolysis, particularly in the liver.

Both warm and cold antibodies have been reported. Warm antibodies react best at 98.6°F (37°C) and account for the majority of cases. Secondary causes of warm AIHA have been reported, most notably, lymphoproliferative disorders such as chronic lymphocytic leukemia (CLL). The presentation of warm AIHA is variable and includes vague constitutional symptoms consistent with anemia, such as weakness and dizziness. Additionally, fever, abdominal pain, cough, and bleeding may be seen. Symptoms vary with the severity of the hemolysis. Mild jaundice is often present. Splenomegaly is seen in approximately half of cases, and 25% may have associated cholelithiasis. While reticulocytopenia may occur early in the disease prior to adequate marrow response, reticulocytosis, and elevated mean cell volume (MCV) is generally seen. Mild to moderate indirect hyperbilirubinemia and elevated LDH are often seen. Platelets are usually normal, but occasionally AIHA and idiopathic thrombocytopenic purpura occur together (Evan's syndrome). Over 95% of warm AIHA have a positive Coombs test (direct antiglobulin test), which indicates that antibodies or complement system are bound to the red cell surface antigens *in vivo*.

The therapy is guided by the severity of the hemolysis, with first-line treatment being corticosteroids. Prednisone therapy is maintained for 3 weeks with rapid response being the norm. If a satisfactory response is achieved, the steroid is gradually and slowly tapered to avoid relapse. Approximately 80% of patients have a partial or complete response

to steroids, but 15–20% will require high dose (>15 mg/d) of maintenance prednisone for months. In nonresponders, or those requiring high dose of maintenance steroids, second-line therapy should be considered. These options include splenectomy or rituximab. Splenectomy can lead to good short-term results, with complete remission in 40–60% of cases, although remission is well documented. It is believed, however, that the patients who relapse often require less steroids for further therapy. In general, the decision for splenectomy in patients should be individualized and based on detailed discussions with the patient and the hematologist.<sup>51</sup>

In contrast, cold agglutinin syndrome treatment is often inadequate. Primary cold agglutinin syndrome patients may only present with mild anemia and may respond favorably to cold exposure avoidance. Folic acid supplementation may be beneficial. Corticosteroids are less effective than in warm AIHA. Other immunosuppressive drugs such as chlorambucil and cyclophosphamide have demonstrated favorable results. Plasmapheresis offers a temporary response but requires concomitant immunosuppression to address cold agglutinin production. Splenectomy is ineffective in cold agglutinin syndrome.

Paroxysmal cold hemoglobinuria is an uncommon form of AIHA and is generally self-limited and treated with supportive care. Most cases occur in children, usually after a viral illness. Corticosteroids are often given to children with severe anemia but are not routinely effective.

## PURPURAS

### Immune (Idiopathic) Thrombocytopenic Purpura

Immune thrombocytopenic purpura (ITP) is the most common hematologic indication for splenectomy. It is an acquired disorder in which platelets are destroyed by circulating antiplatelet antibodies, often IgG. The antibodies are often targeted against GPIIb/IIIa proteins. Antibody-coated platelets bind to antigen-presenting cells via Fc receptor primarily in the spleen, leading to platelet destruction. Demonstration of such antibodies is not always possible and bears no effect on treatment strategy. The diagnostic criteria are a platelet count less than 100,000/mm<sup>3</sup> without an obvious initiating or underlying cause including medications.

The spleen is the source of antiplatelet antibody production as well as the major site of platelet-antiplatelet antibody complex destruction by macrophage-induced phagocytosis.

Female patients outnumber males 3:1. Although up to one-third of patients may be diagnosed incidentally, with no bleeding complications and platelet counts above 30,000/mm<sup>3</sup>, most present with petechiae or ecchymosis. Bleeding complications such as gum bleeding, vaginal bleeding, mild GI bleeding, and hematuria may be seen. Central nervous system (CNS) bleeding occurs in 2–4% of patients and typically when platelet

count is below 10,000/mm<sup>3</sup>. Risk of hemorrhagic death is very low and estimated to be 0.02–0.04 cases per adult patient-year at risk.<sup>52</sup> The spleen is typically normal size. The platelet count may approach zero, and marked thrombocytopenia is associated with a prolonged bleeding time. Generally, there is no significant anemia or leukopenia unless the ITP occurs in conjunction with AIHA. ITP is often associated with other immune disorders as well, such as systemic lupus erythematosus. The workup should include a blood film, as well as human immunodeficiency virus (HIV), hepatitis C virus (HCV), and *Helicobacter pylori* testing in adults.<sup>53</sup> If any of these infectious etiologies are identified, therapy should be aimed at treating the underlying process rather than platelet count per se. *H. pylori* eradication has been shown to result in rapid improvement in platelet count that is long lasting.<sup>54,55</sup> To confirm the diagnosis of ITP, a bone marrow aspirate can be obtained and this will demonstrate normal to high megakaryocytes.

ITP in children is typically self-limited and rarely requires surgical therapy. The disease in adults is usually more persistent with a low spontaneous remission rate (9%) and requires medical and possibly surgical treatment.<sup>56</sup> Treatment is generally not indicated in those with platelet counts above 30,000/mm<sup>3</sup> and no bleeding complications.<sup>57</sup> The goal of all medical therapies is to simply increase platelet count to a safe level, and not to cure. Corticosteroids are the first line of therapy and are generally given for a maximum of 4 weeks to avoid adverse effects associated with chronic use. Around 40% of patients have a clinical response to steroids, but more than 50% have a remission once the steroids are tapered or stopped. Improved results have been noted with high-dose steroid regimens as a first-line therapy. For those not responding to steroids, intravenous (IV) immunoglobulin (Ig) and anti-Rh(D) (anti-D, WinRho) administration can provide temporary and rapid rise in platelet and can be used in those with critically low platelet count or when the patient is being prepped for surgery.<sup>57</sup>

Second-line therapy is often indicated for those with persistent low platelet counts (>30,000/mm<sup>3</sup>) or bleeding. The objective of second-line therapy is to provide long-term and durable results. Second-line therapy now includes rituximab or splenectomy. Although studies have shown superiority of splenectomy in terms of long-term remission (40% for rituximab vs 80–90% for splenectomy), rituximab may be preferred second-line therapy in patients who are high-risk surgical candidates or who may wish to avoid surgery.

Splenectomy provides the best long-term results for ITP with 80% of patients responding to it, and around 70% achieving complete remission.<sup>58</sup> In most patients, the platelet count rises to greater than 100,000/mm<sup>3</sup> within 7 days. Rarely, platelet normalization is more gradual over a period of months. Splenectomy should be performed in patients who fail to respond to steroid treatment within 6 weeks, who recur after steroid taper, who respond to medical therapy but cannot tolerate the side effects, or who develop intracranial bleeding or profound GI bleeding and do not respond to intensive medical treatment.



About 15% of patients fail to respond to splenectomy, and predicting the outcome in this group is of great interest to clinicians. Although some have reported response to IVIg or steroids as a predictor of response to surgery, the predictive value is low.<sup>53</sup>

Indium-labeled autologous platelet scanning may be the most sensitive predictor but is only available presently as a research tool. When the scan demonstrates splenic platelet destruction, the response rate is 90%, thus improving on the current clinical pattern, but only modestly.

The laparoscopic approach to splenectomy is well suited for ITP, because of the normal size of the spleen. Retrospective studies in patients with ITP have demonstrated reduced postoperative pain, less analgesic use, and shorter hospital stay in those undergoing laparoscopic splenectomy compared to open.<sup>59</sup> Assessment of the abdominal cavity for accessory spleens and excision of any such identified masses are critical to success of splenectomy in management of ITP.

## Thrombotic Thrombocytopenic Purpura-Hemolytic Uremic Syndrome

Although thrombotic thrombocytopenic purpura (TTP) and hemolytic uremic syndrome (HUS) were originally thought to be different diseases, they represent the same pathophysiology. In those classified as TTP, neurologic symptoms predominate, while in those with HUS, renal complications are the dominant symptom. TTP-HUS is recognized as the pentad of microangiopathic hemolytic anemia, thrombocytopenia, fever, neurologic disturbance, and renal dysfunction. Largely an idiopathic disorder, TTP-HUS also has been seen in association with bone marrow transplant, mitomycin, cyclosporine, penicillin, and other therapeutic agents. TTP-HUS is a microvascular disorder affecting arterioles and capillaries with venule sparing. Platelet microthrombi cause partial vessel occlusion with overlying endothelial proliferation and subintimal hyalinization. Subsequent erythrocyte damage occurs during passage through the narrowed vascular channels with abnormal forms (helmet cells, schistocytes, etc) seen on peripheral blood smear. Marked platelet trapping occurs, namely in the spleen, with resultant thrombocytopenia ( $<20,000/\text{mm}^3$ ). This may be seen as a profound decrease in platelets within hours of onset. Petechial hemorrhage and, more rarely, epistaxis, retinal hemorrhage, GI and genitourinary bleeding, and hemorrhagic stroke may be seen. However, it is more usual to see no bleeding even with severe thrombocytopenia partly because of the thrombotic nature of the disease. Other clinical manifestations include fever, general malaise and flu-like symptoms, headache, altered mental status, focal neurologic deficits, hematuria, and renal failure. The neurologic changes may be severe, such as coma, prompting emergent therapy.

Since the advent of plasmapheresis for TTP, the survival associated with the once uniformly fatal disease has improved markedly to over 90%. Daily therapy is conducted until the

hemolytic process is stabilized, and the thrombocytopenic and neurologic complications subside. Plasma exchange is then tapered. For those with refractory disease (10–20%), the next line of therapy should be immunosuppressive agents, including steroids, rituximab, or cyclosporine. Splenectomy is generally not recommended and reserved for refractory cases or those with recurrent disease after multiple plasma exchanges.<sup>60</sup> In such select patient population, splenectomy can lead to a 70% remission rate.<sup>61</sup>

## HEMATOPOIETIC NEOPLASMS AND LYMPHOMAS

The early classification of such malignancies, simplified to lymphomas and leukemias, has evolved extensively over the past decade with the introduction of immunophenotyping and cytogenetics. Many tumor subtypes that were initially thought to be the same have been subdivided into groups with different management and prognosis. The 2008 World Health Organization (WHO) classification of hematopoietic and lymphoid malignancies has provided a framework for classification of these diseases, which encompasses over 65 different types of tumor. A detailed description of this classification falls beyond the scope of this chapter. In general, however, these neoplasms fall into three categories<sup>62</sup>:

*Myeloid neoplasms:* Derived from bone marrow progenitors that form erythrocytes, granulocytes (neutrophils, basophils, eosinophils), and megakaryocytes. An example of such tumor is chronic myeloid leukemia, a tumor always associated with *BCR-ABL* fusion gene.

*Lymphoid neoplasms:* Derived from cells that form T and B lymphocytes. When such neoplasms presented with predominantly bone marrow and blood involvement, they were referred to as *leukemia*, while those presenting with a mass were referred to as *lymphoma*. In the new classification, however, using our new knowledge about tumorigenesis and the fact that lymphomas can present or evolve to a leukemia picture, and any leukemia can present as a mass, more emphasis has been placed on cell of origin. This classification method based on cell type only, however, provides no information on clinical behavior of tumors. Some have therefore added a clinical classification to further group lymphomas: indolent (survival without treatment in years), aggressive (survival without treatment in months), highly aggressive (survival of untreated tumor in weeks), and Hodgkin's lymphomas that is generally regarded as a distinct entity with excellent prognosis.

*Histiocytic/dendritic neoplasms:* Derived from cells that develop into antigen-presenting cells such as dendritic cells and macrophages.

Indications for surgical intervention have evolved over the years as our knowledge and therapeutic options have expanded. Below is a brief overview, concentrating on situations where a splenectomy may be indicated.

## Myeloid Neoplasms

These tumors are generally subdivided into three categories, including *acute myeloid leukemias* for which there is little surgical role, as well as *myelodysplastic syndrome* and *myeloproliferative disorders*.

*Myelodysplastic syndrome* is a group of disorders that is associated with ineffective blood production, and risk of transformation to acute leukemia. Again, there is little indication for splenectomy or surgery in this group of patients.

In *myeloproliferative disorders*, there is proliferation of one or more of the myeloid lineage cells, with increases in the numbers of one or more of the peripheral blood elements. There is usually an associated mutation that causes increase in tyrosine kinase and growth factor–dependent proliferation of bone marrow elements. Examples of such mutations include the *BCR-ABL* fusion gene seen in chronic myeloid leukemia. Other diseases in this category include polycythemia vera, idiopathic thrombocytosis, and chronic leukemias. The presenting symptoms include symptomatic splenomegaly and anemia.

The laboratory hallmark is a peripheral smear that demonstrates red cell fragmentation and shows many immature forms of numerous teardrop and elongated shapes. The white blood count is in the range of 50,000/mm<sup>3</sup> and may reach extremely high levels. Immature myeloid cells are found in the peripheral smear. Thrombocytopenia is present in about one-third of the patients and thrombocytosis, with white blood counts of fewer than 1 million, is observed in about one-fourth of the patients.

Although splenectomy does not alter the course of the disease, the procedure is indicated for increasing transfusion requirements and control of anemia, leukopenia, or thrombocytopenia, or symptomatic splenomegaly. There may be massive splenic enlargement with myeloproliferative disorders. The morbidity associated with splenectomy is historically higher than that reported for other hematologic disorders with normal spleen size, although recent series are challenging that assessment. Hand-assisted laparoscopic techniques have been successfully applied for management of massive splenomegaly.

## Lymphoid Neoplasms

Staging laparotomy in cases of Hodgkin's lymphoma was once considered the main means of determining the extent of abdominal involvement with stage I to II supradiaphragmatic disease, and critical in determining the best therapy for patients. Those with disease limited to above the diaphragm were treated with radiation, while others received radiation and chemotherapy. Advances in imaging technology, including spiral CT scan, and 18-fluorodeoxyglucose PET have improved the detection of splenic and abdominal lymph node involvement without need for surgical sampling. With further change in treatment paradigm, favoring combined

modality treatment over extended field radiation, surgical staging, and splenectomy for Hodgkin's lymphoma are now infrequently performed. When surgical staging is needed, the laparoscopic approach to splenectomy and staging has been shown to be feasible and associated with decreased morbidity compared to laparotomy without compromising adequate pathologic staging.<sup>63</sup> Laparoscopic staging for Hodgkin's lymphoma generally begins with splenectomy from the lateral approach. The patient is then moved to a supine position to complete the wedge liver biopsy, performed with ultrasonic dissection or vascular stapling devices, percutaneous core-needle liver biopsies, and biopsies of portal, para-aortic, and parailiac lymph nodes. The para-aortic sampling may also be performed from the lateral approach. Metallic clips are placed at each lymph node sampling site.

Non-Hodgkin's lymphomas are the most common malignant neoplasm of the spleen and the most common indications for splenectomy in more recent times. The spleen is involved in approximately 30–40% of patients, usually as a result of spread from other sites.<sup>63</sup> Primary splenic lymphoma, that confined to the spleen, is an uncommon presentation seen in fewer than 2% of patients with non-Hodgkin's lymphoma.<sup>64</sup>

## Indications for Splenectomy in Lymphoproliferative Disorders

With new classifications of these disorders and variability in clinical presentation and treatment, the decision for splenectomy often requires close collaboration and discussion with the hematologists and oncologists. In general, however, splenectomy is indicated for the following:

- Treatment of symptomatic splenomegaly: abdominal fullness, pain, early satiety, and constitutional symptoms
- Treatment of hypersplenism, which is defined as blood cytopenias in the setting of splenomegaly
- Treatment or tissue diagnosis when the spleen is the only or main site of disease

Splenectomy may be indicated in cases of secondary hypersplenism where mass effect symptoms or cytopenias become disabling. The hematologic response is favorable in the majority of patients with improvement in the neutropenia and thrombocytopenia.

In patients with advanced CLL with hemoglobin of less than 10 or platelet count less than 50,000/mm<sup>3</sup>, splenectomy not only improves hematologic parameters, it may also offer survival advantage compared to those who received only chemotherapy.<sup>65</sup>

The beneficial effect of splenectomy in chronic myelogenous leukemia (CML) is less clear. Surgery does not alter the natural process of the disease, but in carefully selected patients it may improve thrombocytopenia. The operative mortality in this patient population can be as high as 9%, emphasizing the importance of patient selection.<sup>66</sup>

Splenic marginal zone lymphoma is a rare type of marginal zone lymphoma that presents with splenomegaly, no lymphadenopathy (except splenic hilum), and a variable degree of bone marrow involvement. The disease is often associated with hepatitis C infection, which is thought to have a tumorigenesis role in some cases. Splenectomy can have a therapeutic role in this disease and is the treatment of choice. In those not suitable for surgery, rituximab is the therapy of choice.

Hairy cell leukemia is an indolent B-cell lymphoproliferative disorder that was initially recognized by Ewald in 1923. It accounts for only 2–3% of adult leukemias. The typical presentation includes cytopenia, circulating hairy cells, and splenomegaly. Chemotherapy with purine analogues or interferon- $\alpha$  is used. Splenectomy is indicated for symptomatic splenomegaly, severe thrombocytopenia, ruptured spleen, or failure to respond to chemotherapy. Approximately 50% of patients will have normal hematologic parameters postsplenectomy and 90% will improve in at least one parameter.<sup>67</sup>

## OTHER DISEASES AND SPLENECTOMY

Splenectomy may significantly improve the neutropenia in patients with Felty's syndrome characterized by splenomegaly, neutropenia, and arthralgia. Splenectomy is reserved for patients with significant neutropenia and serious or recurrent infections, increased transfusion requirements, or marked thrombocytopenia. While splenectomy does not reduce the arthralgia, leg ulcers, when present, generally heal.

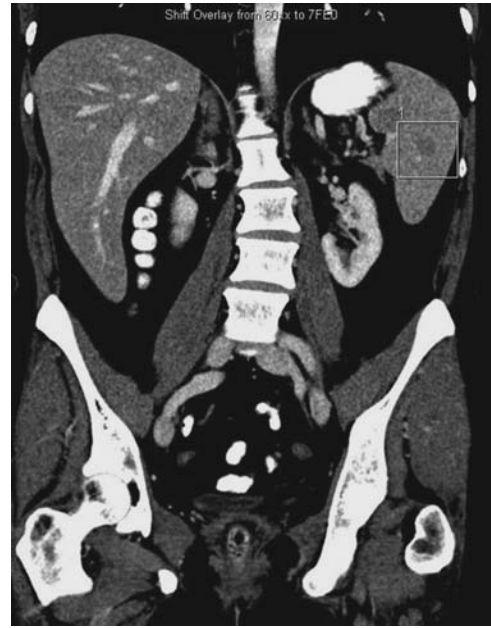In patients with portal hypertension secondary to splenic vein thrombosis, splenectomy usually resolves the portal hypertension and its complications.

Splenectomy may also be indicated for symptomatic splenomegaly or severe secondary hypersplenism in patients with Gaucher's disease or sarcoidosis, although splenectomy will not alter the course of the disease (Fig. 62-15).

## SPLENECTOMY

The first recorded splenectomy was performed for splenomegaly on a 24-year-old Neapolitan woman in 1549 by Adrian Zacarelli. Over the next several centuries, however, only a few other splenectomies were attempted, most proving fatal. In a 1908 literature review of all published cases, totaling fewer than 50 splenectomies, surgery had a mortality rate close to 90%. Over the last 100 years, and in particular the first few decades of the 20th century, improvement in surgical techniques and a better understanding of the splenic anatomy have led to a significant reduction in surgical mortality and morbidity. By the 1970s, the mortality had been reduced to around 10%, and now most elective series report a mortality rates of less than 1%.

Open splenectomy remains the standard therapy for splenic injury in trauma and emergencies, as it allows quick control of bleeding and easy assessment of other organs for injury. Although some trauma centers have reported successful



**FIGURE 62-15** Patient with a remote history of ovarian cancer was found to have a splenic mass (shown in white square). CT-guided biopsy was inconclusive, and she therefore underwent a splenectomy. Pathology confirmed the diagnosis of sarcoidosis. She had no evidence of pulmonary involvement.

management of splenic injuries laparoscopically, the laparoscopic approach is typically used for elective procedures.<sup>68</sup>

The many advantages of the laparoscopic approach can explain this increased utilization. These benefits include less postoperative pain, decreased length of stay, faster return to full activity, a better cosmetic result, and reduced costs, when compared with the open technique.<sup>69</sup> Our own institutional experience echoes this finding. In a review of over 262 cases (184 open splenectomy and 78 laparoscopic splenectomy), laparoscopic approach resulted in shorter hospital stay and less complications, as well as less intraoperative blood loss. These data have placed laparoscopic splenectomy as the gold standard approach for elective splenectomy. This has been reflected in many institutions' rates of utilization of laparoscopic splenectomy, including a report from The Cleveland Clinic where they reported an increase in the number of splenectomies attempted laparoscopically from 17% in 1994 to 75% in 1998.<sup>70</sup> There is, however, significant variation in the rate of uptake of this technique, with room for improvement.

## Preoperative Preparation and Vaccination

The spleen contributes to the immune system by cell filtration, antibody and opsonin production, and phagocytic clearance of bacteria. Asplenic or hyposplenic patients are particularly susceptible to encapsulated bacteria, such as pneumococcus, and malaria. The liver may compensate for

the loss of the immunologic function of the spleen, but this requires an intact complement system and higher antibody production.

Overwhelming postsplenectomy sepsis (OPSS) is a rare phenomenon among adult patients after splenectomy for trauma and nonhematologic disease, but more common among children. Young children, particularly younger than 2 years, are at increased risk because of the immaturity of the immune system. OPSS occurs in 0.9% of adults and 4.4% of children younger than 16 years with an attendant mortality risk of 0.8 and 2.2%, respectfully.<sup>71</sup> Others have, however, have reported mortality rates as high as 50–70%. Reticulo-endothelial dysfunction, such as that caused by hematologic disease or immunosuppression, increases the likelihood of sepsis. The risk persists over the patient's lifetime, with approximately 42% of cases occurring more than 5 years after splenectomy.

Several strategies have been developed to reduce the risk of OPSS, and these include vaccination programs, prophylactic antibiotic use, patient education, antibiotic use, and, importantly for the surgeon, splenic salvage whenever possible.<sup>72</sup>

## VACCINATION

Patients should be vaccinated against encapsulated organisms with recombinant polyvalent *S. pneumonia* (most common cause of OPSS), *Haemophilus influenzae* type B, and *Neisseria meningitidis* vaccines. Although such vaccination routine is recommended by most, there is significant international variation between recommendation regarding exact vaccine type and boosters.<sup>73</sup> Some of the recommendations are summarized in Table 62-2. We follow the US Centers for Disease Control and Prevention (CDC) recommendations and immunize with all three vaccines preoperatively.

These vaccines should be administered at least 2 weeks before planned splenectomy. Guidelines for postsplenectomy vaccinations for patients who have undergone an emergency

procedure are less clear. In a prospective study, it was shown that polyvalent pneumococcal vaccine results in the highest antibody titers, for the most common serotypes, when administered 14 days postsplenectomy.<sup>74</sup> Other data have, however, questioned this finding, and therefore some centers recommend vaccination before hospital discharge to ensure that patients receive their vaccination and improve the postsplenectomy vaccination rates, which have been reported as low at 26%, even in recent literature.<sup>75</sup>

## DAILY PROPHYLACTIC ANTIBIOTIC

Lack of compliance and concern for breeding of resistant organisms has made this option less attractive. Again an area of some debate, there is some evidence for efficacy of this policy in reducing OPSS in children. It therefore appears reasonable to consider daily prophylactic antibiotic in children until the age of 5, or for 2–3 years after the splenectomy in teenagers. British guidelines recommend prophylaxis for longer, however, with daily usage until the age of 16. Prophylactic daily use is not recommended in adults, due to lower rate of OPSS.

## PATIENT EDUCATION AND RESCUE ANTIBIOTICS

Early recognition of postsplenectomy infection is key. This is particularly important as vaccination does not imply immunity and the pneumococcal vaccine is only 70% protective even in the immunocompetent host.<sup>72</sup> Additionally, other pneumococcal, *Haemophilus* non-type B, and meningococcus strains as well as other bacteria may cause overwhelming infection. Meningitis, particularly among children, and pneumonia are often seen. However, the initial prodrome of fever, myalgia, emesis, headache, and abdominal pain may go unrecognized without an astute awareness of the possibility of postsplenectomy sepsis. These early symptoms can quickly escalate into profound septic shock, accompanied by disseminated intravascular coagulation, and organ failure. Asplenic or hyposplenic patients should be instructed to seek immediate medical



**TABLE 62-2: US AND UK IMMUNIZATION RECOMMENDATIONS AFTER SPLENECTOMY**

	<b>Pneumococcal Immunization Recommendations</b>	<b>Meningococcal Immunization Recommendations</b>	<b><i>Haemophilus influenzae</i> Type B Immunization Recommendations</b>
Advisory Committee on Immunization Practices for CDC	23-valent pneumococcal polysaccharide vaccine Revaccination only once after 5 y	Age 11–55: tetravalent meningococcal vaccine; meningococcal polysaccharide vaccine an acceptable alternative Age >55: meningococcal polysaccharide vaccine	Hib not contraindicated
British Committee for Standards in Haematology	23-valent pneumococcal polysaccharide vaccine Revaccination every 5 years	Meningococcal C vaccine No revaccination	Recommends vaccination if not previously vaccinated

CDC, Centers for Disease Control and Prevention.

Data from Mourtzoukou EG, Pappas G, Pappas G, Falagas ME. Vaccination of asplenic or hyposplenic adults. *Br J Surg*. 2008;95:273–280.



attention at the first sign of illness, with some physicians advocating a personal supply of prescribed antibiotics to have on hand. With the onset of fever, the patients should take the first dose of antibiotics and then seek immediate medical evaluation. Amoxicillin-clavulanate or levofloxacin are appropriate choices for this purpose.

## LAPAROSCOPIC SPLENECTOMY

Delartie and Maignier first introduced laparoscopic splenectomy in 1991. At that time, conversion rates were high and some surgeons argued against the routine use of laparoscopic splenectomy. As experience with laparoscopic procedures has evolved in general and laparoscopic instruments and equipment have improved, laparoscopy has become the preferred technique for elective splenectomy.<sup>76</sup> The laparoscopic approach necessitates destruction of the splenic anatomy as the spleen is removed piecemeal through the small-port incision. Although many clinicians are concerned that this morcellation can influence the pathologic assessment of the spleen, often the spleen can be removed in large enough pieces not to interfere with the pathologist's assessment. Most patients requiring elective splenectomy are therefore candidates for a laparoscopic procedure, although splenic size can be a limit. Increasing difficulty is reported with increasing degree of splenomegaly, which is often assessed by measuring the maximal craniocaudal length of the spleen. Although normal splenic size varies depending on sex, age, and racial background, Table 62-3 provides a general classification that can be used for preoperative patient evaluation. Postoperatively, the splenic weight can be used as a measure of the degree of splenic enlargement.

Although splenic length measured with the patient in supine position has a good correlation with overall splenic volume and the degree of splenomegaly, it is in fact not the best surrogate with the splenic length measured with the patient in the right lateral decubitus position providing the strongest correlation with splenic volume.<sup>77</sup> Some believe that preoperative splenic volume (rather than length alone) can provide a more reliable assessment of the degree of splenic enlargement and predict difficulty of the laparoscopic

approach. With improved CT technology, such volumetric assessment is increasingly easy to perform. However until wider spread and use of these measurements, and validation, the splenic length remains the more common measurement of the degree of splenomegaly.

## Patient Selection for Laparoscopic Approach

The cutoff above which laparoscopic splenectomy is associated with prohibiting difficulty is not clear. Some have proposed using clinical examination criteria, excluding those with spleens that extend below and to the right of the umbilicus.<sup>78</sup> Most surgeons, however, use splenic length as a measure of anticipated difficulty and consider splenic size greater than 20 cm to be a contraindication to laparoscopy. Increasing number of studies have, however, demonstrated the feasibility of the laparoscopic approach in this subgroup of patients recognizing limitations.<sup>79</sup> Several studies have, however, documented the increased risks associated with laparoscopy in the setting of massive splenomegaly (>1000 g) when compared to spleens of normal size. These include longer operative time (203 vs 156 minutes and 170 vs 102 minutes), increased blood loss (600 vs 125 cc), higher conversion rates (41 vs 3% and 18 vs 5%), increased postoperative length of stay (4 vs 2 days and 5 vs 3 days), and postoperative morbidity (56 vs 6%).<sup>80</sup> The conclusion from these studies is not that massive splenomegaly is a contraindication for laparoscopic splenectomy, but rather it emphasizes the need for vigilance and a low threshold for conversion to an open procedure. Besides a more challenging dissection, placement of the spleen in the removal bag following resection can be difficult. The risk of intra-abdominal rupture with subsequent splenosis also contributes to the reluctance of some surgeons to perform laparoscopic splenectomy in patients with splenomegaly. Placement of the spleens up to 27 cm in large specimen bags has, however, been achieved by the author and his team, accomplishing a completely laparoscopic approach in these cases. In general, our group has been successful in performing laparoscopic splenectomy, without preoperative embolization, in spleens less than 25 cm with low conversion rates and outcomes. Laparoscopic approach for larger spleens is undoubtedly associated with increased operative time and complication, and many advocate the use of hand-assisted laparoscopic surgery (HALS) in cases of massive splenomegaly. The technique is described later in the chapter.



**TABLE 62-3: DEGREES OF SPLENOMEGALY BASED ON CRANIOCAUDAL LENGTH ON CT OR POSTRESECTION WEIGHT**

	Splenic Length (cm)	Splenic Weight (g)
Normal spleen	Up to 13	<300
Mild splenomegaly	>13–15	300–500
Moderate splenomegaly	16–20	500–1000
Massive splenomegaly	>20	>1000

## Preoperative Splenic Artery Embolization

Although initial experience with total splenic artery embolization was discouraging and associated with significant complications, partial splenic artery embolization (SAE) has been used to manage select cases of splenic trauma (see the

### TABLE 62-4: RISKS OF SPLENIC ARTERY EMBOLIZATION (SAE)

Catheter site hematoma and pseudoaneurysm  
 Postembolization syndrome: pain, fever, ileus, pleural effusion  
 Pancreatitis  
 Splenic abscess or rupture  
 Peritonitis

previous text). SAE has also been used by some as a preoperative intervention to reduce vascularity and size of massive spleens in preparation for a laparoscopic approach. Embolization is achieved using microcoils and/ or Gelfoam.

It is generally agreed that SAE is not helpful in laparoscopic cases where the spleen measures less than 20 cm in length.<sup>81</sup> The benefit of SAE in preoperative management of larger spleens remains controversial. Although some studies have shown that preoperative SAE can lead to reduced intraoperative blood loss in cases of large spleens, they reported no significant differences in conversion rates, incidence of postoperative complications, or length of hospital stay.<sup>82</sup> The potential for a modest reduction in blood loss, however, needs to be balanced against the potential risks and additive nature of this procedure. Risks are summarized in Table 62-4 and have been reported in up to 20% of cases. Some have also expressed concerns about staple malfunction during subsequent splenectomy, as the staple comes across coils that are often used to achieve embolization. In general, preoperative SAE is now infrequently used.

## Approaches to Laparoscopic Splenectomy

The first attempts at laparoscopic splenectomy were performed through an anterior approach. This was performed with the patient in the lithotomy position, by five laparoscopic ports. This approach was later abandoned in favor of the lateral approach (described in detail in the following text), which is currently the preferred technique. The lateral approach, initially developed for adrenalectomy, uses the weight of the spleen and gravity to gain exposure during various steps of the procedure. In addition, it facilitates dissection of the superior short gastrics and superior pole when compared to the traditional anterior approach.

## Details of the Operative Procedure: Lateral Approach

### PATIENT POSITIONING AND ROOM SETUP

Figure 62-16 illustrates the optimal room setup and patient positioning for this procedure. A monitor should be placed

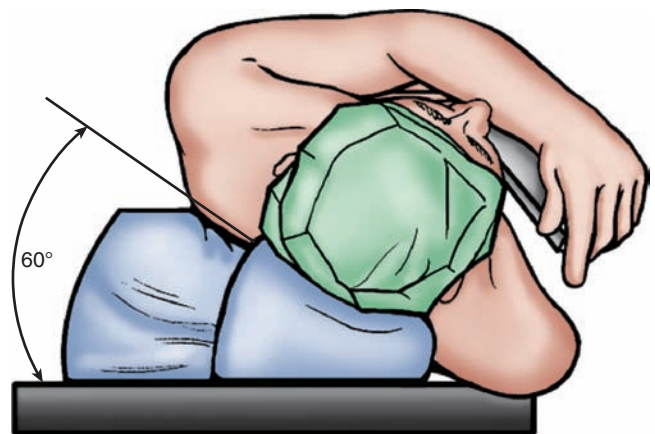
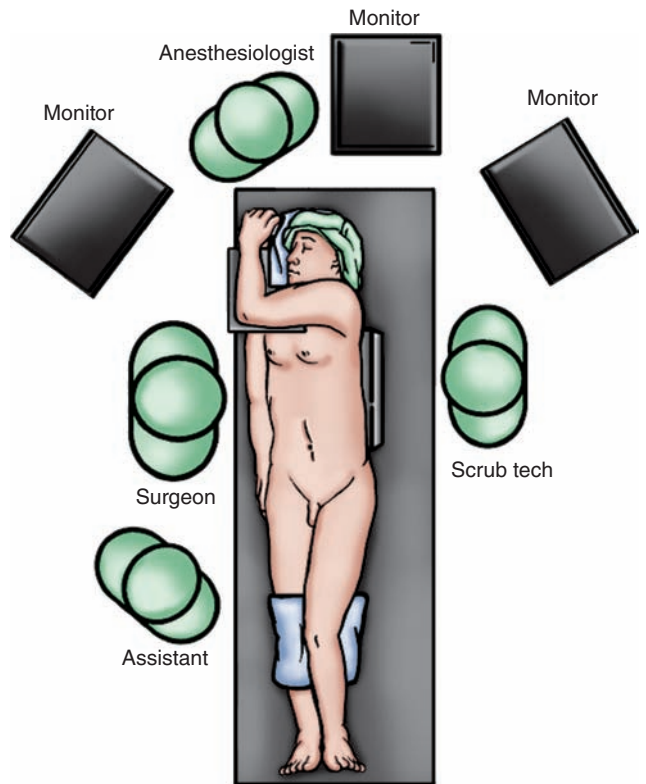


FIGURE 62-16 Room setup and optimal patient positioning for laparoscopic splenectomy.

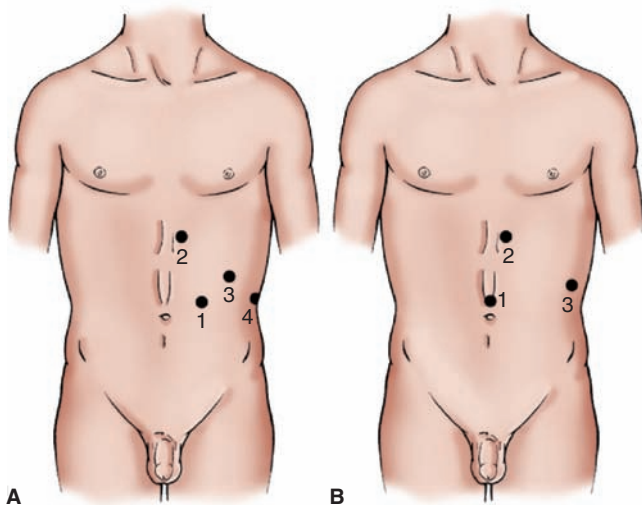
on each side of the patient toward the head of the operating room table. The patient is initially supine for the induction of general anesthesia and placement of the Foley catheter as well as a nasogastric tube for gastric decompression. The patient is then placed in a modified right lateral decubitus position. The optimal angle is 60° between the patient's back and the operating room table. This advantage of this angle over the full lateral decubitus position relates to ease of positioning should conversion to an open procedure be necessary. A roll is placed behind the patient for support. The patient should

be taped in this position to prevent movement when the table is manipulated during the case. An axillary roll is required in the dependent axilla, and the left arm should be placed on an elevated armrest and secured in place. The legs should be padded with the left leg straight and the right leg bent to 60°. The table should be broken at the level of the umbilicus to maximize the distance between the rib cage and the superior iliac spine. The sterile field should extend from the nipples to the pubic bone in the cranial-caudal position and from the right anterior axillary line to the left scapular tip. The table can be rolled to the left to flatten the abdomen for trocar placement. For the remainder of the procedure, reverse Trendelenburg position will facilitate visualization of the spleen in the left upper quadrant.

Energy sources such as ultrasonic dissecting shears (Harmonic, Ethicon Endosurgery, Cincinnati, OH) are useful and used by the author. A formal open laparotomy set should be readily available in case emergent conversion to an open procedure is necessary.

### TROCAR PLACEMENT

We have traditionally used a four-port technique; however, more recently we have adopted a three-port technique in cases where spleen is of normal size and adequate exposure to the splenic vessels can be obtained without an additional assistant's instrument. There are a number of possible trocar placements for laparoscopic splenectomy, and placement will need to be individualized to the patient anatomy. Figure 62-17 illustrates our usual placement for either the three- or four-port technique. The most lateral port can be omitted if the patient's anatomy permits. Figure 62-17B offers an example of an alternative approach for the three-port technique. The abdomen is



**FIGURE 62-17** Trocar placement for laparoscopic splenectomy. **A.** Recommended trocar placement. Port 1 is 12 mm to allow introduction of laparoscopic stapler. The remaining ports are 5 mm. Port 4 is omitted for the three-port technique. **B.** Alternative trocar placement technique.

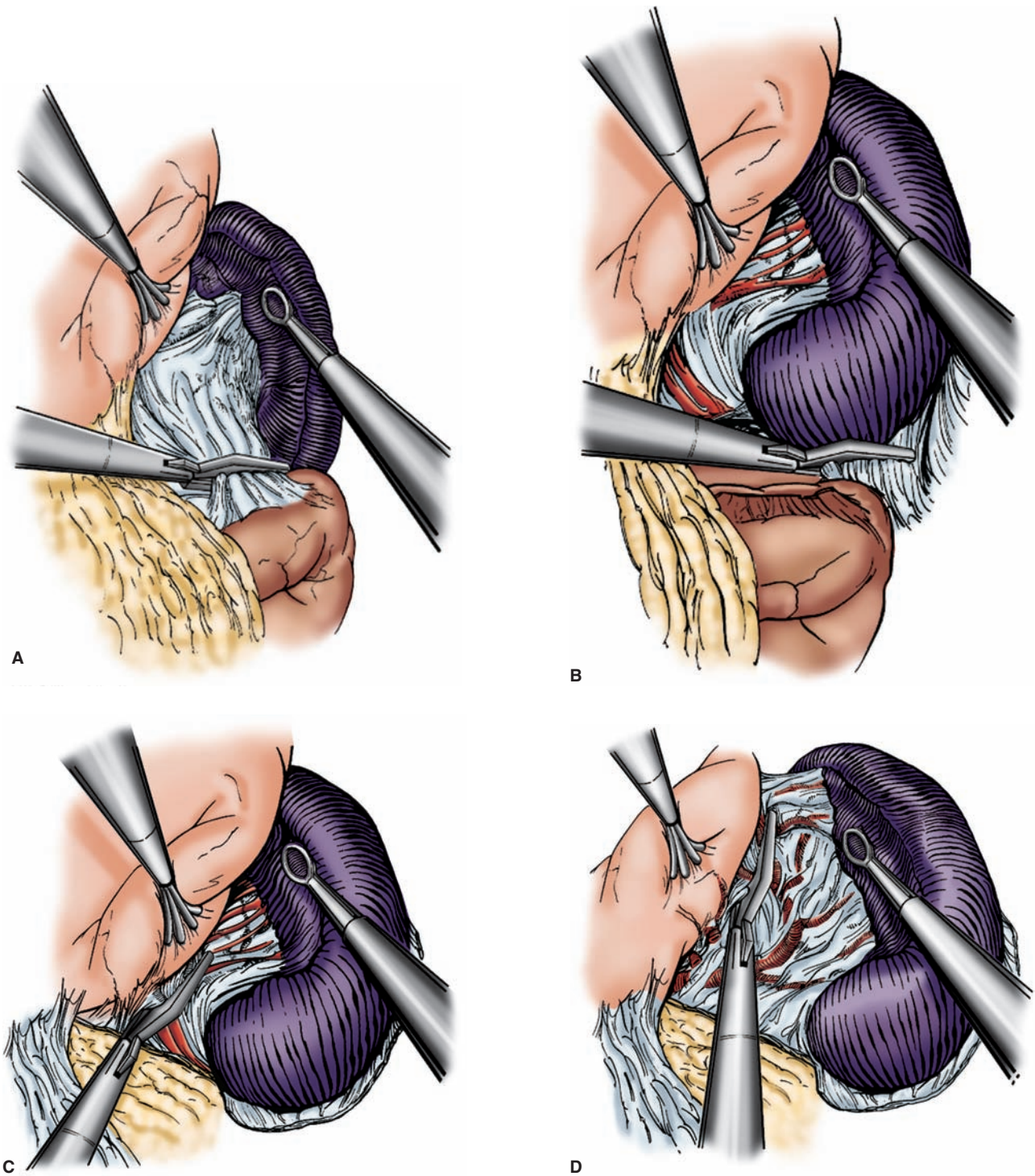
entered using the Veress needle just inferior to the left costal margin in the midclavicular line. In cases where the spleen is large and occupies most of the left upper quadrant, we revert to the open technique for placement of the camera port. Pneumoperitoneum is attained, using carbon dioxide gas to a pressure of 15 mm Hg. The camera port is placed to the left of the midline through the rectus muscle taking care to avoid the epigastric vessels. A 10-mm 30-degree laparoscope is introduced into the peritoneal cavity. The remaining ports should be placed under direct visualization once the camera has been placed and the spleen has been visualized. Port placement will need to be individualized to the patient's anatomy. The camera port and two working ports should be triangulated to allow adequate manipulation. A fourth port can always be added in the lateral position near the anterior axillary line if necessary as the case progresses. We use a 12-mm camera port and two 5-mm ports initially. The 12-mm port can be used for the camera, as well as the stapling device.

### DISSECTION

The procedure begins by exploring the abdomen to identify any accessory spleens. They are present in approximately 12–20% of patients and may be the source for inadequate response to splenectomy in the treatment of hematologic disease, such as ITP. The splenic hilum, gastrosplenic ligament, gastrocolic ligament, greater omentum, mesentery, and presacral space are potential sites for accessory spleens, with the splenic hilum being the most common (see Fig. 62-4). Each of these sites should be considered as the dissection continues. The dissection begins by mobilizing the splenic flexure of the colon, including the renocolic ligament, as needed to provide adequate exposure to the inferior pole of the spleen and the gastrocolic and splenocolic ligaments (Fig. 62-18A). The lower pole of the spleen can be elevated with a blunt dissector. The splenocolic and phrenocolic ligaments are divided. Once the inferior pole of the spleen has been freed, attention is turned to the lower lateral splenic attachments. These are divided moving superiorly from the inferior pole using the ultrasonic shears until the dissection becomes difficult (Fig. 62-18B). Only the lower half of these attachments should be divided at this point in the operation. It is important to avoid full lateral mobilization at this point as this would result in the spleen falling medially and hindering dissection of the short gastric vessels.

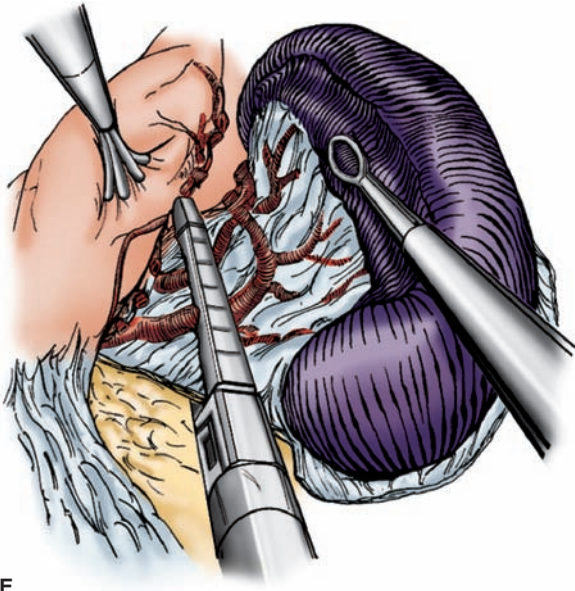
Next, attention is turned to ligating the short gastric vessels (Fig. 62-18C). The first step is to enter the gastrocolic ligament through the avascular plane. Once the lesser sac has been entered, the short gastric vessels are identified and divided. Dissection should continue in a caudal to cranial direction ligating the short gastrics as they are encountered. The ultrasonic dissecting shears will facilitate quicker dissection in this area, and the short gastrics can be coagulated with confidence using this technique. As the surgeon mobilizes the gastrosplenic ligament, traction and countertraction should be provided by the surgeon's nondominant hand and one hand of the assistant. In the four-port technique, the





**FIGURE 62-18** Steps of laparoscopic splenectomy. **A.** Mobilize the splenic flexure of the colon using ultrasonic dissecting shears to free the lower pole of the spleen. **B.** Free the lateral attachment of the spleen, leaving the superior attachments to the diaphragm intact for later division. This way premature medialization of the spleen is prevented. **C.** Divide the short gastric vessels using ultrasonic dissecting shears. **D.** Medial rotation of the stomach can help visualize the superior most vessels. Special care and attention should be given to these vessels that are often very short in length. **E.** Divide the splenic hilum using endoscopic staplers.





E

FIGURE 62-18 (Continued)

assistant's other hand should be providing blunt retraction on the spleen toward the left shoulder. It is crucial that all of the short gastric vessels be divided before proceeding to avoid bleeding that can be difficult to control at a later stage. The most cranial vessels can be difficult to identify and may be immediately adjacent to the left crus of the diaphragm. Medial rotation of the stomach can help expose these vessels and ensure complete ligation (Fig. 62-18D). Once all of the short gastric vessels have been ligated, the assistant and the surgeon elevate the spleen using blunt dissectors while the surgeon divides the entire splenic hilum using an endoscopic stapling device (Fig. 62-18E). The hilum should be divided close to the spleen to avoid injury to the pancreatic tail, which can be as close as 1 cm to the splenic hilum. It is imperative that the stapler includes the entire hilum to avoid partial division of one of the vessels. If this is not possible, the hilum should be dissected further until the stapler fits comfortably across the hilum. We typically use a 60- × 2.5-mm stapler. If the hilar vessels are closely related, we prefer to use a 45- × 2.0-mm stapler. The smaller staples (2.0 mm) provide better hemostatic control of the vessels, but they are only supplied in the short length (45 mm) and thus not suitable for all occasions. To minimize port size, we typically change to a 5-mm laparoscope at this point. The new camera is then inserted through one of the 5-mm ports, freeing the 12-mm port for the introduction of the stapler. An alternative approach is to utilize two 12-mm ports: one for the camera and a separate one for the stapler.

#### REMOVAL OF THE SPECIMEN

We continue to use the 5-mm laparoscope for the remainder of the procedure. The 12-mm port should be removed, extended, and a 15-mm endoscopic bag should be placed

directly through the skin incision without a port. The spleen is placed in the endoscopic bag, and the bag is brought up through the skin. This maneuver provides a good seal at the port site and allows for reinflation of the pneumoperitoneum. The splenic bed is now inspected for hemostasis. Particular attention should be given to the splenic hilum and short gastric vessels. Iatrogenic injury to other organs, particularly the pancreatic tail, should be ruled out. The spleen is then morcellized using digital disruption and removed using ring forceps until the entire bag can be removed from the abdominal cavity. Care should be taken during this part of the procedure to ensure that the ring forceps do not tear the retrieval bag and inadvertently grasp intra-abdominal contents through the bottom of the bag. This can lead to unrecognized complications, such as a small bowel enterotomy or colonic injury. As discussed before, pieces large enough to allow adequate histologic analysis can often be obtained even with morcellation.

In cases of massive splenomegaly, placement of the spleen inside the specimen bags can be challenging. For spleens over 20 cm or so, we use the larger specimen retrieval bags (Lahey bag) and use the "trousers" technique (where the spleen is positioned in the left upper quadrant and the bag is pulled up the spleen, similar to when one is putting on pants/trousers), or "jumper" technique (where the spleen is positioned in midabdomen, the bag is placed at the superior pole and then pulled down over the spleen, similar to when one puts on a pullover/jumper).

After removal of the specimen, the ports are reinserted and the abdomen is examined and irrigated if necessary. If an open technique is used for the camera port, closure of this fascia may be necessary. All lateral port sites for ports 12 mm or less do not require fascial closure. The incision site through which the morcellated spleen is removed, however, should be closed with absorbable sutures as the incision is often enlarged for placement of the endoscopic bag and extraction of the spleen. The skin is approximated with absorbable sutures. A closed suction may be placed at this point, although there has been concerns for an increased risk of postoperative infection in cases where drains were placed. We generally avoid such a drain unless the spleen was very large or there was some concern about injury to the pancreatic tail. If a drain is placed, the drain fluid amylase and lipase is assessed after patient starts on an oral diet and, if normal, the drain is removed. If the patient has evidence of a pancreatic leak, the drain is left in place until output is less than 10 cc for 2 days.

### Hand-Assisted Laparoscopic Surgery

Hand-assisted laparoscopic splenectomy offers an alternative to conventional laparoscopic splenectomy. The hand-assisted technique allows the surgeon to regain the sense of depth and tactile feel that is lost in the conventional laparoscopic technique. In addition, it facilitates exposure when that is limited and will allow greater manipulation of the specimen. This can be especially important in difficult cases, such as those with

splenomegaly. Another advantage is that the retrieval of the specimen, which in cases of spleens of greater than 25 cm, can be difficult to morcellate. The hand-port incision can be placed in a variety of positions, such as the supraumbilical midline or a Pfannenstiel incision. The hand port is important in maintaining the pneumoperitoneum when the operator withdraws their hand from the peritoneal cavity. A number of such ports have been developed and are commercially available. Typically, the nondominant hand is placed in the abdominal cavity and used to assist with the surgery.<sup>83</sup>

The role of HALS in splenic surgery is widely debated. Several case series suggest possible advantages for HALS in cases of splenomegaly compared to open splenectomy, including less postoperative pain and a shorter hospital stay.<sup>84</sup> This technique allows for gentler retraction of the spleen during dissection, as well as palpation and precise location of the splenic artery. No advantage is seen for hand assistance over conventional laparoscopy when the spleen is of normal size.

## Single-Incision Splenectomy

In the recent years, efforts have been directed toward making laparoscopic surgeries even less invasive, culminating in the recent interest in single-site surgery. This approach, referred to as LESS (laparoendoscopic single site) surgery, involves placement of several trocars, or a single multichanneled trocar, through a single small incision (typically  $\leq 2.5$  cm) usually at the umbilicus. Several reports of LESS splenectomy have now been published with success rates of 75%, and conversion to standard laparoscopy in the remaining patients.<sup>85</sup> These early reports clearly demonstrate the feasibility of this approach for splenectomy although benefits, other than cosmetic, are unclear and will likely be answered in years to come as further studies are undertaken.

## Postoperative Management

Some surgeons advocate postoperative decompression of the stomach with a nasogastric tube to prevent hemorrhage from the short gastrics. We have not found this necessary and allow sips of clear liquids on the night of surgery, advancing the diet over the course of the first postoperative day. We feel that a single dose of preoperative antibiotics is sufficient and do not use postoperative antibiotics. The patients are provided a patient-controlled analgesia (PCA) for their first postoperative night and switched to oral analgesia in the morning. Unless the patient has an ongoing coagulation problem or low platelet counts, we use nonsteroidal anti-inflammatories in management of their postoperative pain. The patient's complete blood count is typically checked on the morning after surgery. Patients are typically discharged on postoperative day 1 or 2.

The manipulation of the stomach may lead to some early satiety in the immediate postoperative period. This will resolve in 6–8 weeks. Patients are also instructed to refrain

from high impact or jarring-type exercises for 2 weeks so that raw surfaces within the splenic fossa are allowed to heal without disturbance.

## Complications

Generally, the complication rate of laparoscopic splenectomy is 10–15%, with a mortality rate of less than 1% for elective cases. Splenectomy for hematological malignancy and splenomegaly, however, can have a high complication rate with reports of a 9% mortality rate. An intraoperative complication that may occur during laparoscopic splenectomy but is rarely seen with open splenectomy is diaphragmatic perforation, usually related to thermal injury during mobilization of the superior pole, emphasizing the importance of a good technique and visualization during the procedure.<sup>86</sup>

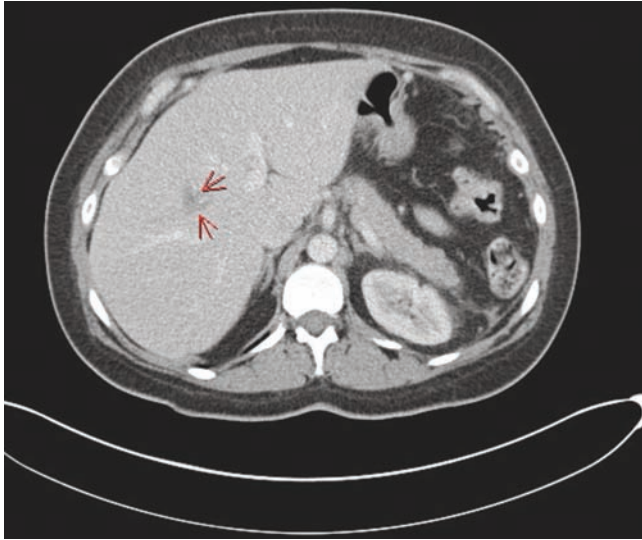
Early postoperative bleeding must be closely monitored, particularly in patients with thrombocytopenia or myeloproliferative disorders. In these patients it is an error to indict hematologic abnormalities as the cause of bleeding, and it is generally safer to reexplore the patients early and to evacuate a hematoma to reduce the incidence of subphrenic abscess. Alternative therapy would be angiography with embolization, but this may be difficult as the most common site of bleeding is a short gastric vessel.

Left lower lobe atelectasis and effusion is another complication; it occurs more frequently following splenectomy, but most large series have not yet substantiated this finding.

In unusual cases, the platelet count may rise to very high levels, at times greater than 2 million/mm<sup>3</sup>. In cases where the platelet count rises to above 1 million, a drug that inhibits platelet aggregation, such as acetylsalicylic acid, can be used.

Thrombosis of the splenic vein, with extension into the portal vein and superior mesenteric vein, is a complication that appears more frequently after laparoscopic approach (Fig. 62-19). The etiology is poorly understood, but it may relate to decrease portal blood flow during laparoscopic surgery or a hypercoagulable state following pneumoperitoneum. In a recent literature review of splenoportal vein thrombosis (SPVT), the overall incidence of symptomatic thrombosis was 3.3%, and similar between open and laparoscopic approach.<sup>87</sup> When the authors, however, focused on prospective studies that included asymptomatic SPVT, the overall incidence increased to 12.3%, with a large difference based on surgical approach. After open splenectomy, SPVT rate was 8.3%, but it increased to 23% after laparoscopic splenectomy. Increased rate of SPVT after laparoscopic approach has been documented by others with several risk factors for this complication, which are summarized in Table 62-5. Interestingly, traumatic splenectomies are not associated with a significant risk for SPVT.

This has generated much debate on whether patients should have surveillance imaging (US or CT) after laparoscopic splenectomy to look for SPVT, since two-thirds will have asymptomatic thrombosis. If imaging is to be undertaken, CT is more sensitive than US; however, CT exposes the patient to additional radiation. It has been suggested that a postoperative surveillance US on postoperative day 7 may be



**FIGURE 62-19** Splenic-portal vein thrombosis (SPVT) after a laparoscopic splenectomy. The thrombosis may be small and involve intrahepatic branches of the portal vein only, as is the case here where the patient had thrombus in the anterior branch of the right portal vein. The patient was asymptomatic and was initially observed. Follow-up imaging after 3 weeks, however, showed persistent thrombosis, and she was therefore anticoagulated for 3 months.

best at detecting a developing thrombosis.<sup>88</sup> Such surveillance imaging is not, however, standard practice and not routinely performed by the author.

Full anticoagulation is generally recommended for symptomatic cases. Management of asymptomatic cases is less clear. Involvement of superior mesenteric vein with thrombosis often indicates need for prompt anticoagulation. Isolated thrombosis in the splenic vein may, however, be observed with serial imaging to confirm resolution and without full anticoagulation.<sup>89</sup>

Injury to the tail of the pancreas with a symptomatic complication can occur in up to 10% of cases.<sup>90</sup> The majority of these injuries is self-limited with hyperamylasemia and pain but may be more severe with development of a pancreatic collection requiring drainage.

The increased incidence of fulminant sepsis related to pneumococcus or to *H. influenzae* following splenectomy is an established fact, but it occurs more commonly in patients who are immunosuppressed or have myeloproliferative diseases with a propensity for infection. The risk may be

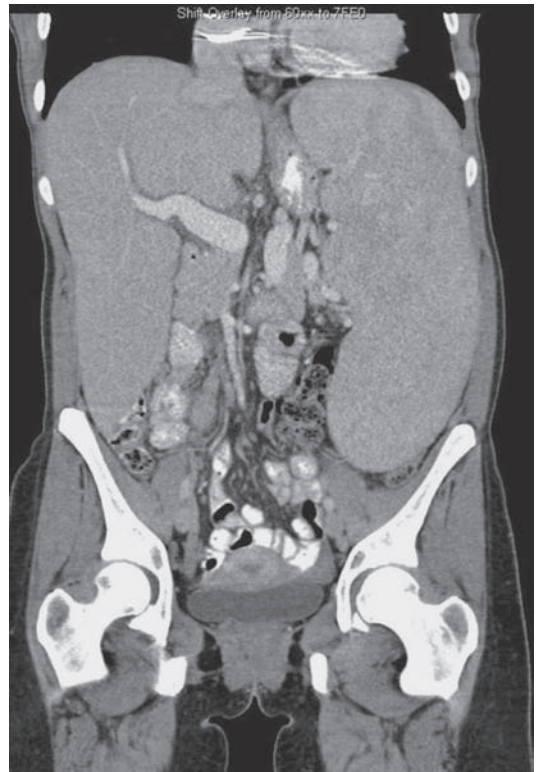
**TABLE 62-5: RISK FACTORS FOR SPLENIC-PORTAL VEIN THROMBOSIS AFTER LAPAROSCOPIC SPLENECTOMY**

- Lymphoma
- Lymphoproliferative disorder
- Hemolytic anemias
- Splenomegaly (>650 g)
- Splenic vein diameter >8 mm

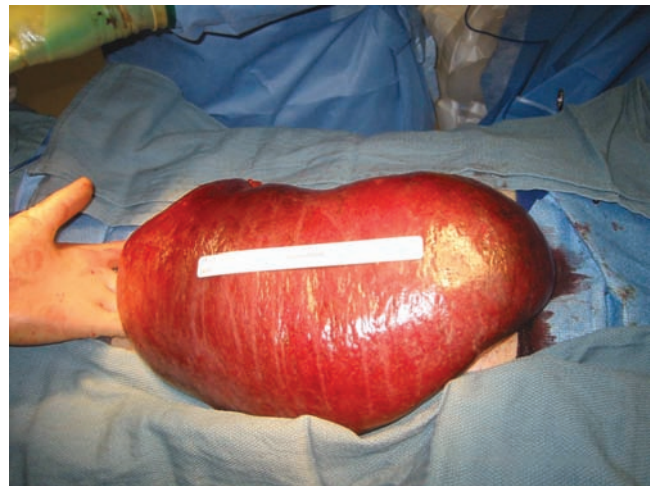reduced with appropriate vaccination and early recognition as previously noted.

## OPEN SPLENECTOMY

Open approach is most commonly used in cases of trauma and splenic injury, but it also has a role for elective management of massive spleens (Fig. 62-20).



**A**



**B**

**FIGURE 62-20** **A.** This spleen measured 27 cm and was successfully removed laparoscopically. **B.** This spleen measured over 30 cm, and in view of this we proceeded directly to open surgery.

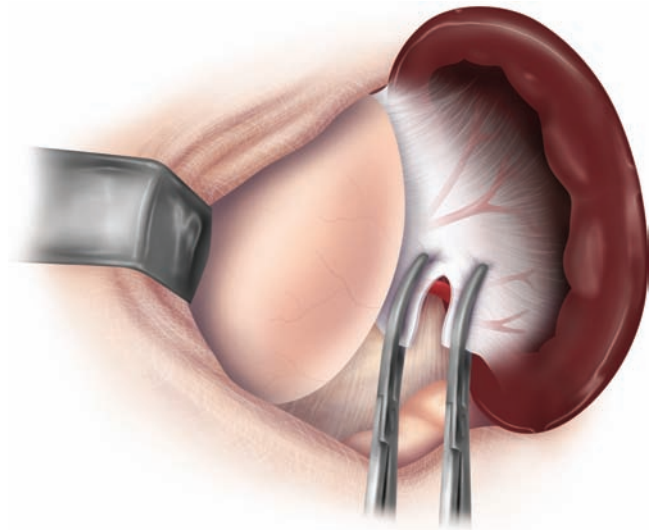


A variety of incisions may be used, depending on the nature of the disease and the personal preference of the surgeon. A midline incision is generally applied to cases of traumatic injury because of the speed of access as well as exposure of the spleen and other possibly injured viscera. A left subcostal incision also has been employed, as well as thoracoabdominal approach, which has been largely abandoned because of its associated morbidity.

Open splenectomy is usually performed by a technique of media mobilization of the spleen and dissection down to an ultimate pedicle of splenic artery and vein which is then finally divided. The procedure begins with mobilization of the spleen to the midline by division of the lateral and superior pole attachments. This includes division of the splenophrenic ligament superiorly, and the splenocolic and splenorenal ligaments at the lower pole (Fig. 62-21). The short gastric vessels are then divided between ligatures or clips, taking care to avoid injury to the gastric wall (Fig. 62-22). Alternatively, an ultrasonic dissector may be used to divide these vessels.

The spleen is medialized and hilar dissection performed carefully with isolation of the splenic vessels and gentle medial displacement of the tail of the pancreas to avoid pancreatic injury. The splenic hilum may be clamped en bloc with three clamps in the manner of Federoff (Fig. 62-23) and divided and doubly ligated proximally and once distally. Some advocate individual ligation of the splenic artery and splenic vein. Alternatively, the vessels may be divided with a vascular linear stapler. Drainage is not necessary unless the pancreas has been injured.

In elective cases for splenomegaly, some start the procedure by entering the lesser sac, identifying the splenic vessels, which

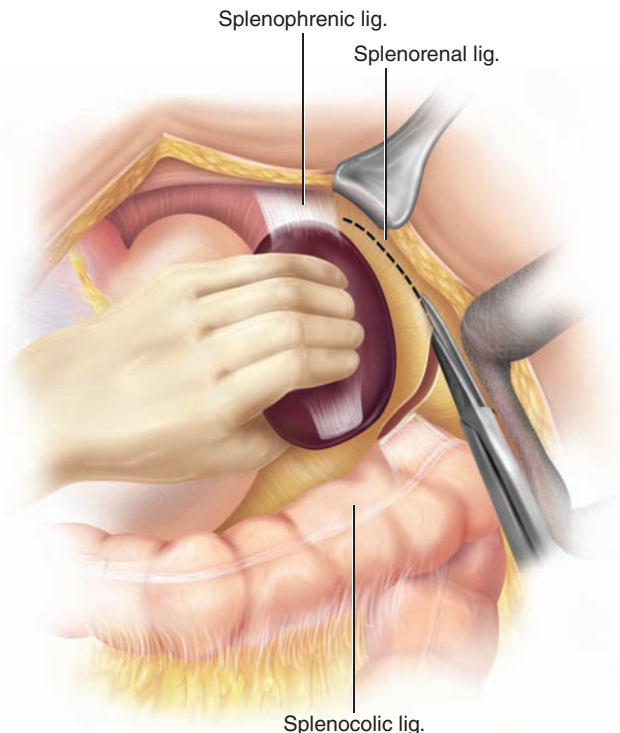


**FIGURE 62-22** Ligation of the short gastric vessels and the gastro-splenic omentum.

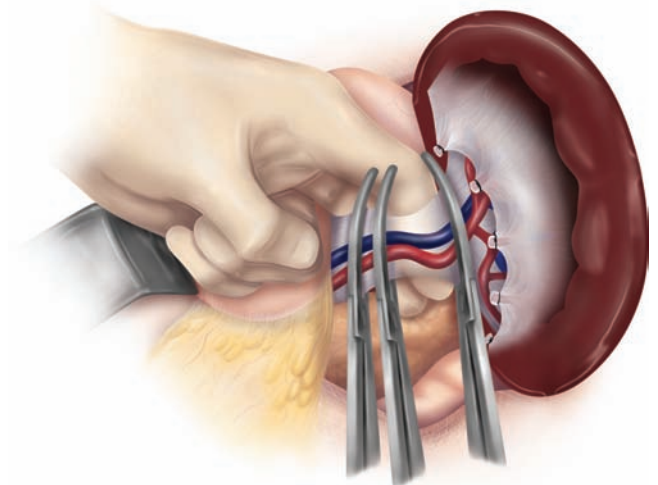
is often above the pancreas, tying and dividing them at this point, before proceeding with the splenectomy (Fig. 62-24). This helps to reduce excessive splenic bleeding during the surgery should there be injury to the capsule.

## SPLEEN-PRESERVING APPROACHES

The techniques to preserve splenic tissue and function are dictated by the extent of planned resection, or in case of trauma, splenic damage. These approaches have gathered increased popularity because of the critical role of spleen in fighting encapsulated organisms and the small, but real, risk of OPSS.

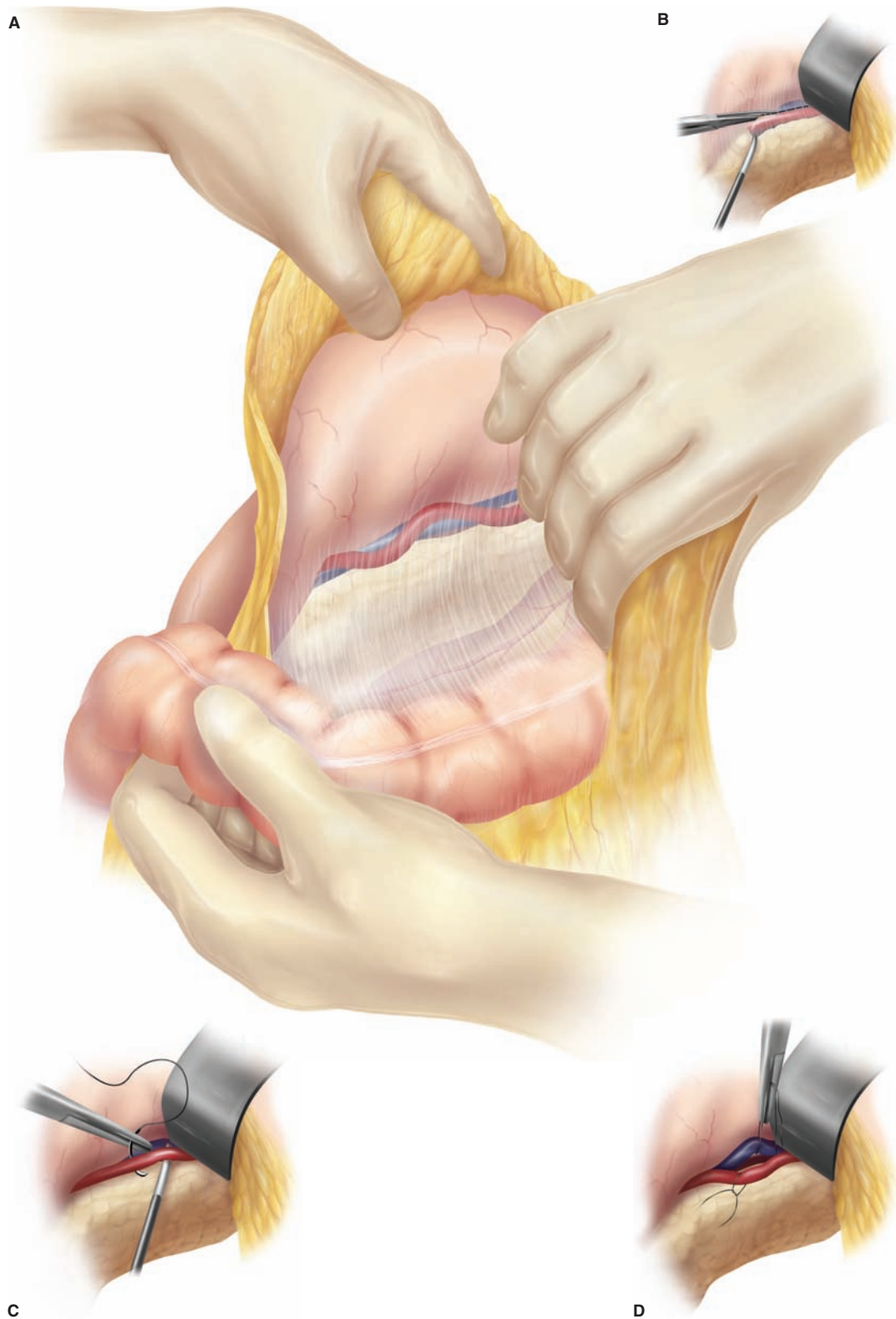


**FIGURE 62-21** Division of the ligamentous attachments of the spleen during open splenectomy.



**FIGURE 62-23** Division of the splenic hilum using the three-clamp method of Federoff.





**FIGURE 62-24** In cases of massive splenomegaly, access is obtained to the lesser sac and the splenic vessels identified. The artery is often seen above the pancreas. The vessels are carefully dissected and ligated twice proximally and once distally before being divided. The splenic dissection and mobilization is then performed.

## Splenorrhaphy

The spleen must be mobilized carefully to allow thorough inspection of the organ. The ligamentous attachments must be divided as in splenectomy. Small lacerations can be managed by compression and the application of a hemostatic agent, such as oxidized cellulose, micronized collagen, thrombin, or fibrin glue. Significant disruptions of the splenic capsule and parenchyma can be managed generally with absorbable sutures that traverse the capsule and incorporate the parenchyma. In this circumstance, horizontal mattress sutures are advantageous because cutting through the tissue is minimized; some use pledget for these sutures. If trauma is localized to one pole of the spleen, this area should be resected and the edges

approximated with a series of mattress sutures (Fig. 62-25). The omentum may be used to fill large defects or to cover the injury site to provide tamponade. Splenorrhaphy has largely been supplanted by the nonoperative management of relatively hemodynamically stable injured patients, with the addition of angiographic embolization when indicated.

## Partial Splenectomy

Partial elective splenectomy has been described for management of localized lesions of the spleen, as well as management of more systemic disease, in select cases such as Gaucher's disease or spherocytosis. The technique is similar to standard

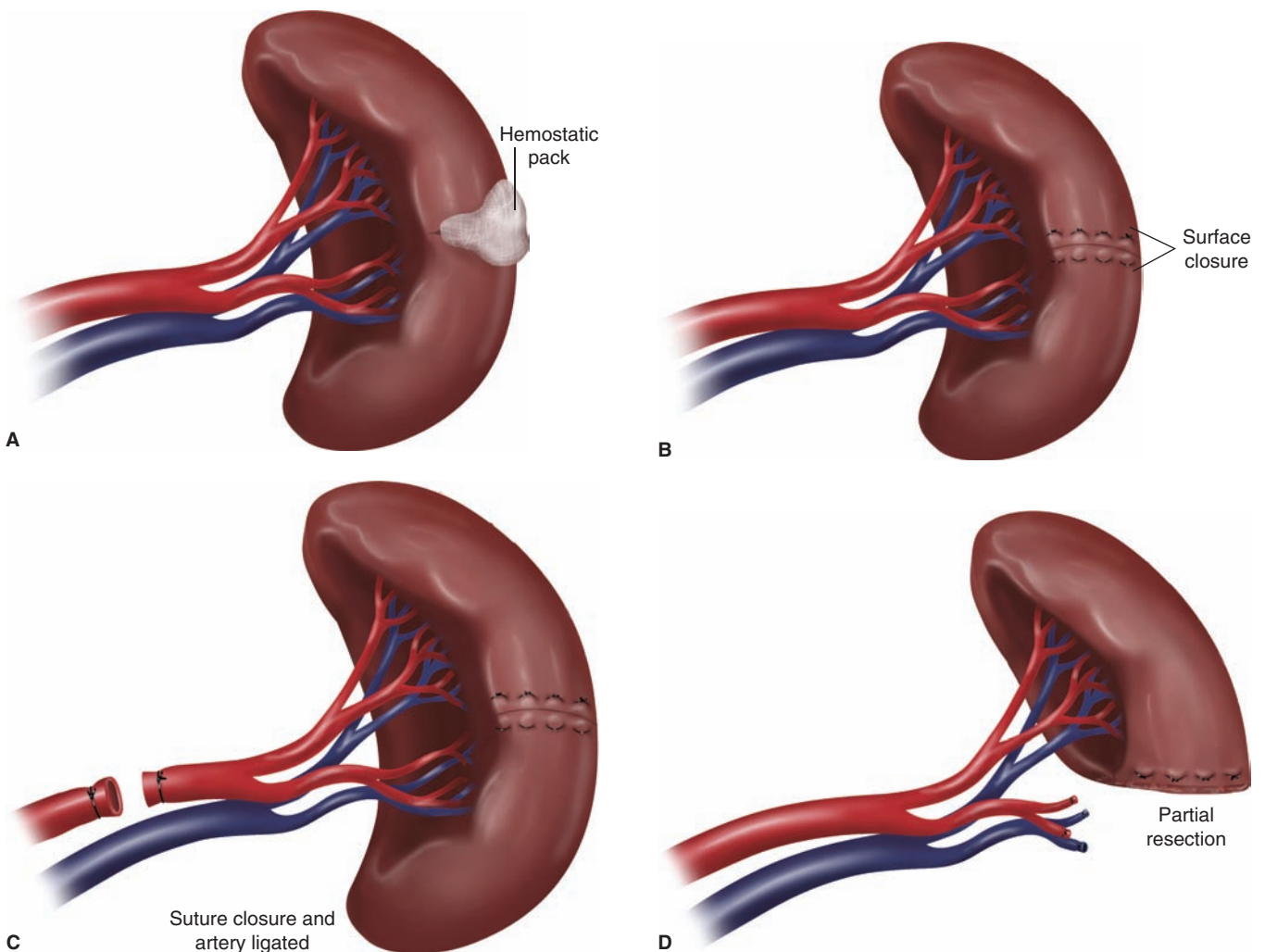


FIGURE 62-25 Approaches to preserving a traumatized spleen. Depending on the degree of splenic injury, one of these techniques can be used.

laparoscopic splenectomy. For partial resection of the lower pole, branches of the gastropiploic vessel supplying the lower pole are divided and spleen is allowed to demarcate. Once appropriate segments have become ischemic, the splenic capsule is divided using electrocautery. The dissection is then continued to the splenic parenchyma until the desired segment is fully divided. A new technique has been described using radiofrequency-generated heat to perform a partial splenectomy in a patient with a tumor in the lower pole of the spleen.<sup>91</sup>

## REFERENCES

- Andrales G, Gadacz TR. The Spleen. In: Zinner MJ, Ashley SW, eds. *Maingot's Abdominal Operations*. 11th ed. New York, NY: McGraw-Hill; 2007:1075–1098.
- Mustapha Z, Tahir A, Tukur M, Bukar M, Lee WK. Sonographic determination of normal spleen size in an adult African population. *Eur J Radiol*. 2010;75:e133–e135.
- Saber AA, Helbling B, Khaghany K, Nirmit G, Pimental R, McLeod MK. Safety zone for splenic hilar control during splenectomy: a computed tomography scan mapping of the tail of the pancreas in relation to the splenic hilum. *Am Surg*. 2007;73:890–894.
- Fiquet-Francois C, Belouadah M, Ludot H, et al. Wandering spleen in children: multicenter retrospective study. *J Pediatr Surg*. 2010;45:1519–1524.
- Renzulli P, Hostettler A, Schoepfer AM, Gloor B, Candinas D. Systematic review of atraumatic splenic rupture. *Br J Surg*. 2009;96:1114–1121.
- Holubar SD, Wang JK, Wolff BG, et al. Splenic salvage after intraoperative splenic injury during colectomy. *Arch Surg*. 2009;144:1040–1045.
- Wakeman CJ, Dobbs BR, Frizelle FA, et al. The impact of splenectomy on outcome after resection for colorectal cancer: a multicenter, nested, paired cohort study. *Dis Colon Rectum*. 2008;51:213–217.
- Kamath AS, Iqbal CW, Sarr MG, et al. Colonoscopic splenic injuries: incidence and management. *J Gastrointest Surg*. 2009;13:2136–2140.
- Andrales G, Gadacz TR. The Spleen. In: Ashley SW, Zinner MJ, eds. *Maingot's Abdominal Operations*. 11th ed. New York, NY: McGraw-Hill; 2007:1075–1098.
- Velmahos GC, Zacharias N, Emhoff TA, et al. Management of the most severely injured spleen: a multicenter study of the Research Consortium of New England Centers for Trauma (ReCONNECT). *Arch Surg*. 2010;145:456–460.
- van der Vlies CH, Saltzheir TP, Wilde JC, van Delden OM, de Haan RJ, Goslings JC. The failure rate of nonoperative management in children with splenic or liver injury with contrast blush on computed tomography: a systematic review. *J Pediatr Surg*. 2010;45:1044–1049.
- Sabe AA, Claridge JA, Rosenblum DI, Lie K, Malangoni MA. The effects of splenic artery embolization on nonoperative management of blunt splenic injury: a 16-year experience. *J Trauma*. 2009;67:565–572; discussion 71–72.
- Pachter HL, Guth AA, Hofstetter SR, Spencer FC. Changing patterns in the management of splenic trauma: the impact of nonoperative management. *Ann Surg*. 1998;227:708–717; discussion 17–19.
- Moon DB, Lee SG, Hwang S, et al. Characteristics and management of splenic artery aneurysms in adult living donor liver transplant recipients. *Liver Transpl*. 2009;15:1535–1541.
- Abbas MA, Stone WM, Fowl RJ, et al. Splenic artery aneurysms: two decades experience at Mayo clinic. *Ann Vasc Surg*. 2002;16:442–9.
- Ha JF, Phillips M, Faulkner K. Splenic artery aneurysm rupture in pregnancy. *Eur J Obstet Gynecol Reprod Biol*. 2009;146:133–137.
- Macfarlane JR, Thorbjarnarson B. Rupture of splenic artery aneurysm during pregnancy. *Am J Obstet Gynecol*. 1966;95:1025–1037.
- Pulli R, Innocenti AA, Barbanti E, et al. Early and long-term results of surgical treatment of splenic artery aneurysms. *Am J Surg*. 2001;182: 520–523.
- Loffroy R, Guiu B, Cercueil JP, et al. Transcatheter arterial embolization of splenic artery aneurysms and pseudoaneurysms: short- and long-term results. *Ann Vasc Surg*. 2008;22:618–626.
- Yaghan R, Heis H, Bani-Hani K, et al. Is fear of anaphylactic shock discouraging surgeons from more widely adopting percutaneous and laparoscopic techniques in the treatment of liver hydatid cyst? *Am J Surg*. 2004;187: 533–537.
- Morgenstern L. Nonparasitic splenic cysts: pathogenesis, classification, and treatment. *J Am Coll Surg* 2002;194:306–314.
- Flood TA, Veinot JP. Splenic cysts and microcysts. *Pathology*. 2009; 41:602–604.
- Palanivelu C, Rangarajan M, Madankumar MV, John SJ. Laparoscopic internal marsupialization for large nonparasitic splenic cysts: effective organ-preserving technique. *World J Surg*. 2008;32:20–25.
- Chin EH, Shapiro R, Hazzan D, Katz LB, Salky B. A ten-year experience with laparoscopic treatment of splenic cysts. *JLS*. 2007;11:20–23.
- Robinson SL, Saxe JM, Lucas CE, Arbulu A, Ledgerwood AM, Lucas WF. Splenic abscess associated with endocarditis. *Surgery*. 1992;112:781–786; discussion 6–7.
- Chen LW, Chien RN, Yen CL, Chang LC. Splenic tumour: a clinicopathological study. *Int J Clin Pract*. 2004;58:924–927.
- Makrin V, Avital S, White I, Sagie B, Szold A. Laparoscopic splenectomy for solitary splenic tumors. *Surg Endosc*. 2008;22:2009–2012.
- Cavanna L, Lazzaro A, Vallisa D, Civardi G, Artioli F. Role of image-guided fine-needle aspiration biopsy in the management of patients with splenic metastasis. *World J Surg Oncol*. 2007;5:13.
- Friedlander MA, Wei XJ, Iyengar P, Moreira AL. Diagnostic pitfalls in fine needle aspiration biopsy of the spleen. *Diagn Cytopathol*. 2008;36:69–75.
- Willcox TM, Speer RW, Schlinkert RT, Sarr MG. Hemangioma of the spleen: presentation, diagnosis, and management. *J Gastrointest Surg*. 2000;4:611–613.
- Levy AD, Abbott RM, Abbondanzo SL. Littoral cell angioma of the spleen: CT features with clinicopathologic comparison. *Radiology*. 2004; 230:485–490.
- Dascalescu CM, Wendum D, Gorin NC. Littoral-cell angioma as a cause of splenomegaly. *N Engl J Med*. 2001;345:772–773.
- Krishnan J, Frizzera G. Two splenic lesions in need of clarification: hamartoma and inflammatory pseudotumor. *Semin Diagn Pathol*. 2003; 20:94–104.
- Hsu JT, Chen HM, Lin CY, et al. Primary angiosarcoma of the spleen. *J Surg Oncol*. 2005;92:312–316.
- Sauer J, Sobolewski K, Dommisch K. Splenic metastases—not a frequent problem, but an underestimate location of metastases: epidemiology and course. *J Cancer Res Clin Oncol*. 2009;135:667–671.
- Schon CA, Gorg C, Ramaswamy A, Barth PJ. Splenic metastases in a large unselected autopsy series. *Pathol Res Pract*. 2006;202:351–356.
- Gulbis B, Eleftheriou A, Angastiniotis M, et al. Epidemiology of rare anaemias in Europe. *Adv Exp Med Biol*. 2010;686:375–396.
- Gallagher PG. The red blood cell membrane and its disorders: hereditary spherocytosis, elliptocytosis and related disorders. In: Kaushansky K, Lichtman MA, Beutler E, Kipps TJ, Seligsohn U, Prachal JT, eds. *Williams Hematology*. 8th ed. New York, NY: McGraw-Hill; 2010:617–647.
- Bolton-Maggs PH, Stevens RF, Dodd NJ, Lamont G, Tittensor P, King MJ. Guidelines for the diagnosis and management of hereditary spherocytosis. *Br J Haematol*. 2004;126:455–474.
- Hollingsworth CL, Rice HE. Hereditary spherocytosis and partial splenectomy in children: review of surgical technique and the role of imaging. *Pediatr Radiol*. 2010;40:1177–1183.
- Slater BJ, Chan FP, Davis K, Dutta S. Institutional experience with laparoscopic partial splenectomy for hereditary spherocytosis. *J Pediatr Surg*. 2010;45:1682–1686.
- Sandler A, Winkel G, Kimura K, Soper R. The role of prophylactic cholecystectomy during splenectomy in children with hereditary spherocytosis. *J Pediatr Surg*. 1999;34:1077–1078.
- Marchetti M, Quaglini S, Barosi G. Prophylactic splenectomy and cholecystectomy in mild hereditary spherocytosis: analyzing the decision in different clinical scenarios. *J Intern Med*. 1998;244:217–226.
- Weatherall DJ. The thalassemias: disorders of globin synthesis. In: Kaushansky K, Lichtman MA, Beutler E, Kipps TJ, Seligsohn U, Prachal JT, eds. *Williams Hematology*. 8th ed. New York, NY: McGraw-Hill; 2010:675–708.
- Cao A, Galanello R. Beta-thalassemia. *Genet Med*. 2010;12:61–76.
- Patle NM, Tantia O, Sasmal PK, Khanna S, Sen B. Laparoscopic splenectomy in patients of beta thalassemia: our experience. *J Minim Access Surg*. 2010;6:70–75.
- Charache S, Terrin ML, Moore RD, et al. Effect of hydroxyurea on the frequency of painful crises in sickle cell anemia. Investigators of the



- Multicenter Study of Hydroxyurea in Sickle Cell Anemia. *N Engl J Med*. 1995;332:1317–1322.
48. Natarajan K, Townes TM, Kutlar A. Disorders of hemoglobin Structure: sickle cell anemia and related abnormalities. In: Kaushansky K, Lichtman MA, Beutler E, et al, eds. *Williams Hematology*. 8th ed. New York, NY: McGraw-Hill; 2010: 709–742.
  49. Haricharan RN, Roberts JM, Morgan TL, et al. Splenectomy reduces packed red cell transfusion requirement in children with sickle cell disease. *J Pediatr Surg*. 2008;43:1052–1056.
  50. Gehrs BC, Friedberg RC. Autoimmune hemolytic anemia. *Am J Hematol*. 2002;69:258–271.
  51. Lechner K, Jager U. How I treat autoimmune hemolytic anemias in adults. *Blood*. 2010;116:1831–1838.
  52. Cohen YC, Djulbegovic B, Shamai-Lubovitz O, Mozes B. The bleeding risk and natural history of idiopathic thrombocytopenic purpura in patients with persistent low platelet counts. *Arch Intern Med*. 2000;160:1630–1638.
  53. Provan D, Stasi R, Newland AC, et al. International consensus report on the investigation and management of primary immune thrombocytopenia. *Blood*. 2010;115:168–186.
  54. Kikuchi T, Kobayashi T, Yamashita T, Ohashi K, Sakamaki H, Akiyama H. Eight-year follow-up of patients with immune thrombocytopenic purpura related to *H. pylori* infection. *Platelets*. 2011;22(1):59–62. [Epub 2010 Oct 13]
  55. Stasi R, Sarpatwari A, Segal JB, et al. Effects of eradication of *Helicobacter pylori* infection in patients with immune thrombocytopenic purpura: a systematic review. *Blood*. 2009;113:1231–1240.
  56. Stasi R, Stipa E, Masi M, et al. Long-term observation of 208 adults with chronic idiopathic thrombocytopenic purpura. *Am J Med*. 1995;98:436–442.
  57. Diz-Kucukkaya R, Chen J, Geddis A, Lopez JA. Thrombocytopenia. In: Kaushansky K, Lichtman MA, Beutler E, Kipps TJ, Seligsohn U, Prachal JT, eds. *Williams Hematology*. 8th ed. New York, NY: McGraw-Hill; 2010:1891–1928.
  58. Kojouri K, Vesely SK, Terrell DR, George JN. Splenectomy for adult patients with idiopathic thrombocytopenic purpura: a systematic review to assess long-term platelet count responses, prediction of response, and surgical complications. *Blood*. 2004;104:2623–2634.
  59. Cordera F, Long KH, Nagorney DM, et al. Open versus laparoscopic splenectomy for idiopathic thrombocytopenic purpura: clinical and economic analysis. *Surgery*. 2003;134:45–52.
  60. Bell WR, Braine HG, Ness PM, Kickler TS. Improved survival in thrombotic thrombocytopenic purpura-hemolytic uremic syndrome. Clinical experience in 108 patients. *N Engl J Med*. 1991;325:398–403.
  61. Kappers-Klunne MC, Wijermans P, Fijnheer R, et al. Splenectomy for the treatment of thrombotic thrombocytopenic purpura. *Br J Haematol*. 2005;130:768–776.
  62. Freedman AS, Friedberg JW, Aster JC. Classification of the hematopoietic neoplasms. In: *September 2010*. Online 18.3 ed. UpToDate; 2010.
  63. Walsh RM, Heniford BT. Role of laparoscopy for Hodgkin's and non-Hodgkin's lymphoma. *Semin Surg Oncol*. 1999;16:284–292.
  64. Isaacson PG. Primary splenic lymphoma. *Cancer Surv*. 1997;30:193–212.
  65. Cusack JC, Jr, Seymour JF, Lerner S, Keating MJ, Pollock RE. Role of splenectomy in chronic lymphocytic leukemia. *J Am Coll Surg*. 1997;185:237–243.
  66. Mesa RA, Elliott MA, Tefferi A. Splenectomy in chronic myeloid leukemia and myelofibrosis with myeloid metaplasia. *Blood Rev*. 2000;14:121–129.
  67. Sigal D, Saven A. Hairy cell leukemias and related disorders. In: Kaushansky K, Lichtman MA, Beutler E, Kipps TJ, Seligsohn U, Prachal JT, eds. *Williams Hematology*. 8th ed. New York, NY: McGraw-Hill; 2010: 1483–1492.
  68. Carobbi A, Romagnani F, Antonelli G, Bianchini M. Laparoscopic splenectomy for severe blunt trauma: initial experience of ten consecutive cases with a fast hemostatic technique. *Surg Endosc*. 2010;24:1325–1330.
  69. Winslow ER, Brunt LM. Perioperative outcomes of laparoscopic versus open splenectomy: a meta-analysis with an emphasis on complications. *Surgery*. 2003;134:647–653; discussion 54–55.
  70. Brodsky JA, Brody FJ, Walsh RM, Malm JA, Ponsky JL. Laparoscopic splenectomy. *Surg Endosc*. 2002;16:851–854.
  71. Holdsworth RJ, Irving AD, Cuschieri A. Postsplenectomy sepsis and its mortality rate: actual versus perceived risks. *Br J Surg*. 1991;78:1031–1038.
  72. Brigden ML, Pattullo AL. Prevention and management of overwhelming postsplenectomy infection—an update. *Crit Care Med*. 1999;27:836–842.
  73. Mourtzoukou EG, Pappas G, Peppas G, Falagas ME. Vaccination of asplenic or hyposplenic adults. *Br J Surg*. 2008;95:273–280.
  74. Shatz DV, Schinsky MF, Pais LB, Romero-Steiner S, Kirton OC, Carlone GM. Immune responses of splenectomized trauma patients to the 23-valent pneumococcal polysaccharide vaccine at 1 versus 7 versus 14 days after splenectomy. *J Trauma*. 1998;44:760–765; discussion 5–6.
  75. Grace RF, Mednick RE, Neufeld EJ. Compliance with immunizations in splenectomized individuals with hereditary spherocytosis. *Pediatr Blood Cancer*. 2009;52:865–867.
  76. Greenberg CC, Tavakkolizadeh A, Brooks DC. Laparoscopic splenectomy. In: Zinner MJ, Ashley SW, eds. *Maingot's Abdominal Operations*. New York, NY: McGraw-Hill; 2007:1183–1190.
  77. Lamb PM, Lund A, Kanagasabay RR, Martin A, Webb JA, Reznick RH. Spleen size: how well do linear ultrasound measurements correlate with three-dimensional CT volume assessments? *Br J Radiol*. 2002;75:573–577.
  78. Pattenden CJ, Mann CD, Metcalfe MS, Dyer M, Lloyd DM. Laparoscopic splenectomy: a personal series of 140 consecutive cases. *Ann R Coll Surg Engl*. 2010;92:398–402.
  79. Targarona EM, Espert JJ, Balague C, Piulachs J, Artigas V, Trias M. Splenomegaly should not be considered a contraindication for laparoscopic splenectomy. *Ann Surg*. 1998;228:35–39.
  80. Patel AG, Parker JE, Wallwork B, et al. Massive splenomegaly is associated with significant morbidity after laparoscopic splenectomy. *Ann Surg*. 2003;238:235–240.
  81. Poulin EC, Mamazza J, Schlachta CM. Splenic artery embolization before laparoscopic splenectomy. An update. *Surg Endosc*. 1998;12:870–875.
  82. Naoum JJ, Silberfein EJ, Zhou W, et al. Concomitant intraoperative splenic artery embolization and laparoscopic splenectomy versus laparoscopic splenectomy: comparison of treatment outcome. *Am J Surg*. 2007;193:713–718.
  83. Targarona EM, Gracia E, Rodriguez M, et al. Hand-assisted laparoscopic surgery. *Arch Surg*. 2003;138:133–141; discussion 41.
  84. Barbaros U, Dinccag A, Sumer A, et al. Prospective randomized comparison of clinical results between hand-assisted laparoscopic and open splenectomies. *Surg Endosc*. 2010;24:25–32.
  85. Targarona EM, Pallares JL, Balague C, et al. Single incision approach for splenic diseases: a preliminary report on a series of 8 cases. *Surg Endosc*. 2010;24:2236–2240.
  86. Targarona EM, Espert JJ, Bombuy E, et al. Complications of laparoscopic splenectomy. *Arch Surg*. 2000;135:1137–1140.
  87. Krauth MT, Lechner K, Neugebauer EA, Pabinger I. The postoperative splenic/portal vein thrombosis after splenectomy and its prevention—an unresolved issue. *Haematologica*. 2008;93:1227–1232.
  88. Tran T, Demyttenaere SV, Polyhronopoulos G, et al. Recommended timing for surveillance ultrasonography to diagnose portal splenic vein thrombosis after laparoscopic splenectomy. *Surg Endosc*. 2010;24:1670–1678.
  89. Ikeda M, Sekimoto M, Takiguchi S, et al. High incidence of thrombosis of the portal venous system after laparoscopic splenectomy: a prospective study with contrast-enhanced CT scan. *Ann Surg*. 2005;241:208–216.
  90. Chand B, Walsh RM, Ponsky J, Brody F. Pancreatic complications following laparoscopic splenectomy. *Surg Endosc*. 2001;15:1273–1276.
  91. Habib NA, Spalding D, Navarra G, Nicholls J. How we do a bloodless partial splenectomy. *Am J Surg*. 2003;186:164–166.

*This page intentionally left blank*

# ADRENALECTOMY

Matthew A. Nehs • Atul A. Gawande  
• Francis D. Moore, Jr • Daniel T Ruan

## INTRODUCTION: ADRENAL ANATOMY AND PHYSIOLOGY

The adrenal, or suprarenal, glands are paired retroperitoneal organs positioned superomedial to the kidneys at the level of the 12th rib. Each gland is divided into an outer cortex and an inner medulla, which are histologically and functionally distinct layers derived from separate embryologic tissues. The cortex originates from ectoderm and is composed of three zones that produce steroid hormones: the *zona fasciculata*, which produces mineralocorticoids; the *zona glomerulosa*, which produces glucocorticoids; and the *zona reticularis*, which produces sex hormones. The medulla is derived from neural crest cells and is composed of modified postganglionic neurons that connect with the sympathetic nervous system in order to produce epinephrine, norepinephrine, and dopamine in response to sympathetic stimuli.

The arterial supply to the adrenals originates from the inferior phrenic arteries, aorta, and renal arteries. Although the anatomy is quite variable, the majority of the arterial supply approaches from the medial and inferior borders of the adrenal glands with few substantial arteries from the superior, posterior, or lateral sides. The adrenal arteries are generally small and amenable to electrocautery. Conversely, the venous anatomy to the adrenal gland is more consistent; usually there is a single large draining vein of substantial size that requires ligation. The right adrenal vein length tends to be short and it drains directly into the inferior vena cava (IVC). In contrast, the left adrenal vein is usually of generous length and drains into either the left renal vein or the inferior phrenic vein. Ligation of the left inferior phrenic vein is of no significant physiologic consequence. The adrenal gland is surrounded by variable amounts of fat, which is loosely attached posteriorly to diaphragmatic muscle. This surrounding fat can obscure the visualization and identification of adrenal tumors. Left-sided adrenal tumors can be adjacent to the spleen, pancreas tail, liver, kidney, or renal hilum. Right-sided adrenal tumors can be adjacent to the liver or IVC. Invasive adrenal tumors can extend into these surrounding structures.

## INDICATIONS FOR ADRENALECTOMY

### Aldosteronoma

*Aldosteronomas* are cortical adrenal tumors that autonomously secrete aldosterone. Hyperaldosteronism was first described by Jerome Conn in 1955 and is characterized by hypertension and hypokalemia.<sup>1</sup> These symptoms should be controlled preoperatively with an aldosterone antagonist and potassium supplements. Biochemical confirmation of autonomous hypersecretion of aldosterone should be confirmed prior to adrenalectomy. This is best achieved by salt loading followed by a 24-hour urine collection of aldosterone, sodium, and creatinine. Aldosterone antagonists should be held prior to testing for at least a few weeks. While there are several forms of primary hyperaldosteronism, surgery is indicated only in the setting of unilateral adrenal adenoma or hyperplasia. Because aldosteronomas are almost always benign tumors, a cortex-sparing nodulectomy can be performed when the tumor is peripheral; however, this approach has a higher risk of persistent hyperaldosteronism.

Since benign, nonfunctional adrenal tumors are common relative to the incidence of hyperaldosteronism, selective venous sampling should be used to confirm laterality of disease in patients who are older than 40 years. Although many surgeons believe that computerized tomography (CT)<sup>2</sup> or magnetic resonance imaging (MRI) is sufficient when unilateral disease is identified in younger patients, it is our practice to perform selective venous sampling for all patients who are considered candidates for adrenalectomy. This is supported by a recent study that found that 50% of patients in their primary hyperaldosteronoma cohort would have been inappropriately managed based on preoperative CT findings alone.<sup>3</sup>

Postoperatively, normalization of aldosterone levels confirms surgical cure and is typically associated with correction of hypokalemia. Infrequently, hyperkalemia can result from chronic suppression of the contralateral adrenal gland. With complete resection of the aldosteronoma, nearly all patients have normal serum potassium levels and hypertension is improved in most. Persistent hypertension after curative adrenalectomy is usually due to underlying essential hypertension.



## Pheochromocytoma

*Pheochromocytomas* are rare neuroendocrine tumors that are derived from chromaffin cells and usually arise from the adrenal medulla. Although most pheochromocytomas are sporadic and unilateral, genetic syndromes, such as multiple endocrine neoplasia 2 and von Hippel-Lindau disease, increase the risk of bilateral disease. Pheochromocytomas can produce catecholamines such as epinephrine, norepinephrine, and dopamine that can cause the classic clinical symptomatology of this disease: episodic headaches, palpitations, and diaphoresis. Rarely, pheochromocytomas are nonfunctional. Preoperative preparation with alpha-blockade (eg, phenoxybenzamine, doxazosin) and salt loading should be undertaken. Ideally, this can be done in the outpatient setting. The alpha-blocker is titrated up to the maximal tolerated dose, which is typically limited by orthostatic hypotension. In addition, beta-blockade can be added to the regimen if the patient has persistent tachyarrhythmias. Although the optimal preparation time before pheochromocytoma resection is controversial, we generally alpha-block and salt-load our patients for 1–2 weeks before elective adrenalectomy.

The first successful resection of a pheochromocytoma was performed by César Roux in Switzerland in 1926 and shortly thereafter by Charles Mayo in the United States. Delicate tissue handling and avoidance of tumor compression should be emphasized to minimize catecholamine release. Because tumor manipulation and adrenal vein clipping can result in significant hemodynamic changes, coordination and communication between the adrenal surgeon and anesthesiologist are critical to the success of this operation. Because of the risk of catecholamine surges during tumor manipulation, many propose early identification and clipping of the adrenal vein. After dividing the adrenal vein, we grab the tumor side of the divided vessel to use as a handle for retraction. However, some caution that adrenal vein ligation increases intratumoral venous pressure, which can increase bleeding.<sup>4</sup> Regardless, if the vein is ligated early or late in the dissection, communication between the surgical and anesthesia teams is necessary, because hypotension is often recognized after vein ligation.

Endoscopic adrenalectomy is the favored procedure when there is no evidence of malignant disease.<sup>5</sup> A randomized controlled trial of laparoscopic versus open adrenalectomy for pheochromocytoma found no significant differences in hemodynamic instability between the two groups, but operative time and blood loss were favored in the laparoscopic group.<sup>6</sup> Although laparoscopic or retroperitoneoscopic resection is favored for small and noninvasive tumors, conversion to the open approach should be considered whenever there is difficulty achieving gross tumor clearance. Conversion to open surgery is appropriate if capsular disruption seems imminent during endoscopic dissection.

## Cortisol-Producing Adrenal Adenoma

Adrenal adenomas that produce cortisol can be incidentally discovered during abdominal imaging or when the patient develops the signs and symptoms of Cushing's syndrome.

In the early 1930s, Harvey Cushing was among the first to describe the clinical entity of hypercortisolism, which is characterized by truncal obesity, round face, fragile skin, depression, and abdominal striae. These tumors autonomously secrete cortisol without the usual dependence on adrenocorticotropic hormone (ACTH) and can increase the risk of cardiovascular complications and mortality.

Because adrenocortical carcinomas (ACCs) also frequently secrete cortisol, a careful preoperative evaluation should be performed to look for signs of malignancy, such as radiographic evidence of local invasion, regional lymphadenopathy, distal metastases, and rapid growth. Small tumor size and well-defined borders are predictive of benign cortisol-producing adenomas. Because the risk of ACC increases with larger tumor size, patients should be considered for open resection if the tumor size exceeds 6 cm.<sup>7–9</sup>

Postoperatively, adrenal function may be suppressed in the contralateral gland, and patients should be given a prophylactic hydrocortisone taper to avoid potential postoperative adrenal insufficiency. The steroid taper can progress according to patient symptoms and can be monitored with serum cortisol and ACTH levels drawn in the morning. Because patients with these tumors can have obesity resulting from Cushing's syndrome, they can present an additional technical challenge for laparoscopy. Often, port sites at the skin can dilate during the procedure, resulting in gas leakage during the operation. Therefore, it is ideal to make the port site incisions as small as technically possible to avoid gas leakage and loss of operative domain during peritoneal insufflation. Cushing's patients also have a higher risk of postoperative infection, so preoperative prophylactic antibiotics should be used.

## Adrenal Cyst

Simple cystic lesions are usually incidental, and surgery is not indicated unless there is a solid component to the cyst wall. Complex cysts with evidence of local invasion should undergo open resection. Large cysts that cause symptoms or that are at high risk of spontaneous rupture can be excised by laparoscopic nodulectomy or subjected to fenestration of the cyst wall into the peritoneal cavity.

## Myelolipoma

These lesions are also typically discovered in an incidental manner. Their appearance can cause confusion with liposarcoma, a situation easily resolved with needle biopsy showing typical bone marrow elements. Patients with these benign adrenal lesions are often referred to surgery because of compressive symptoms.

## Adrenal Cortical Cancer

*Adrenal cortical carcinoma* is a rare and aggressive tumor derived from the adrenal cortex. As many as 60% of ACCs in adults autonomously hypersecrete cortisol or sex steroids.

Although complete surgical resection is the mainstay of therapy, ACC is often locally invasive, which typically precludes complete extirpation. Local tumor invasion precludes endoscopic resection. Initial reports of laparoscopic adrenalectomy for ACC suggested that the recurrence rates were higher than open resection.<sup>8</sup> This was the reason for many to recommend that malignancy was an absolute contraindication for laparoscopic resection of primary adrenal cancers. Recently, several groups have challenged this paradigm and have reported success with laparoscopic resection of malignant adrenal disease.<sup>9,10</sup>

While this topic remains controversial, we do not attempt minimally invasive adrenalectomy when local invasion is determined on preoperative imaging. Intraoperative difficulty with establishing tissue planes between the adrenal gland and neighboring structures due to tumor extension portends malignancy and should prompt immediate conversion to open adrenalectomy.

## Incidentaloma

*Incidentalomas* are tumors that come to clinical attention through abdominal imaging for some other indication. The clinical relevance of these masses pertains to the concern for malignancy. Small, nonfunctional incidental tumors (<4 cm) do not require resection and are typically benign.<sup>11</sup> Biochemical exclusion of pheochromocytoma, aldosteronoma, and hypercortisolism is necessary. Larger lesions (>4 cm) are at higher risk for carcinoma, and open resection should be considered. Although controversial, laparoscopic resection of incidental tumors greater than 4 cm in size can be safely achieved for tumors without gross extension.<sup>2</sup> Formal decision analysis of the management of incidentalomas has determined that laparoscopic resection is ideal if the morbidity of surgery is less than 3% and the probability of hypersecretion, tumor growth, or malignancy exceeds 7.5%.<sup>12</sup> The former can often be achieved in the hands of an experienced adrenal surgeon and the latter is seen in tumors larger than 5 cm.

## Paraganglioma

*Paragangliomas* are neuroendocrine tumors histologically similar to pheochromocytomas but occur in extra-adrenal sites throughout the abdomen, chest, and head. Most of these tumors are sporadic and can present as a painless mass or with the symptomatology of a pheochromocytoma resulting from catecholamine production. There are several case reports of successful laparoscopic resection of these tumors.<sup>13-15</sup> The decision to use this approach should depend on the location and size of the paraganglioma, as well as the surgeon's experience.

## Metastasis

Resection of adrenal metastases is controversial and the role for surgical treatment is changing, now that safe minimally

invasive resection can be achieved with minimal morbidity. Although no prospective trials have proven that adrenalectomy improves survival, many groups have reported safe laparoscopic resection of various secondary tumors, such as lung, renal cell,<sup>16</sup> colon, and melanoma.<sup>17,18</sup> For the laparoscopic approach specifically, it is equivalent to open adrenalectomy regarding recurrence and survival and provides the additional benefit of reduced postoperative morbidity.<sup>19</sup> Furthermore, there is a role for palliative laparoscopic resection for patients with symptomatic secondary tumors. Attempts at laparoscopic metastasectomy should be avoided in any patient with radiographic evidence of local invasion, as complete resection without capsular disruption is unlikely.

## ENDOSCOPIC ADRENALECTOMY

Since the initial report of laparoscopic adrenalectomy in 1992,<sup>20</sup> surgical experience has grown along with significant progress in endoscopic technologies. As such, the laparoscopic approach has become the procedure of choice for most adrenal tumors less than 6 cm in size. Retroperitoneoscopic adrenalectomy uses laparoscopic instruments but avoids entrance and insufflation of the peritoneal cavity. This technique involves direct entrance into the retroperitoneal space from the posterior side. Retroperitoneoscopic adrenalectomy is superior to laparoscopic adrenalectomy in selected patients, and there are numerous considerations when considering which surgical approach to use for the resection of adrenal tumors.

## Advantages of the Laparoscopic Approach

For most patients who undergo laparoscopic adrenalectomy, the smaller incisions, lower blood loss, and lessened abdominal wall/flank trauma from divided muscles translate into a less painful and more rapid recovery when compared to open adrenalectomy. Median hospital stay is under 3 days for laparoscopic adrenalectomy, versus 7 days or more for the open procedure.<sup>21</sup> In addition, one can anticipate a reduction in general morbidity, such as catheter-associated urinary tract infections, pneumonias, and deep venous thrombosis.

One can counter that modern large-incision surgery has improved dramatically with the use of continuous epidural anesthesia, more rapid mobilization, and improvements in operative technique. Nonetheless, incisions for open adrenalectomy are large and morbid: subcostal incisions produce long-term limitation of rectus abdominis function; midline celiotomies result in ileus and a frequent incidence of ventral hernia; and thoracoabdominal incisions can produce pain and muscle denervation syndromes. These long-term issues are avoided almost entirely with the laparoscopic approach.

The laparoscopic approach is particularly advantageous for the patient who is disabled with Cushing's syndrome from an

autonomous adrenal adenoma. Patients with this diagnosis have such reduced muscle mass and reduced defense against infection that they become essentially immobilized with an open adrenalectomy. Adrenalectomy in patients with hypercortisolism carries a higher risk of general complications, including wound disruption and infection.

Laparoscopy is also especially advantageous for the patient with Conn's syndrome and a small unilateral peripheral adrenal adenoma. These patients can undergo nodulectomy for their tumors, be discharged from the hospital within 24 hours, and be back to work within days.

It is also technically feasible to perform laparoscopic adrenalectomy through a single laparoscopic port site. This new approach provides the incremental benefit of using a single 2-cm incision, rather than three or four separate laparoscopic ports, for access to the adrenal gland through the peritoneal cavity.<sup>22</sup> Because the current experience with single-incision laparoscopy is limited, future studies are needed to determine patient selection criteria.

## Disadvantages of the Laparoscopic Approach

Laparoscopy is not appropriate for every patient, and some general contraindications to laparoscopy and transperitoneal resection include severe chronic obstructive pulmonary disease (COPD) (related to the inability to tolerate CO<sub>2</sub> insufflation), uncorrectable coagulopathy, dense intra-abdominal adhesions, and widely metastatic disease. There are, however, circumstances in which the adrenal gland must remain unseen—in other words, it must be removed as a radical adrenalectomy with an intact capsule of surrounding perinephric and suprarenal fat. The most common circumstance is that of suspected malignancy, in which breach of the tumor capsule and spillage of cancer cells can compromise postsurgical outcome.

The other circumstance in which a laparoscopic approach might be problematic is in patients who require bilateral adrenalectomy for ACTH-dependent Cushing's syndrome. In these patients, spillage of adrenal cortical cells in the presence of increased levels of their trophic factor, ACTH, risks reimplantation and the adrenal equivalent of splenosis. The authors are aware of such an unfortunate case. This risk is compounded by the absolute necessity to remove all adrenal tissue, a maneuver that is difficult to accomplish with certainty without laparoscopic manipulation and retraction of the adrenal itself. The adrenal gland is so friable in these cases that manipulation usually results in breach of the adrenal.

Another limiting circumstance is morbid obesity. The adrenal can frequently be obscured by surrounding fat. A CT scan will provide an estimate of the amount of fat around the adrenal. Large amounts should dissuade the surgeon from choosing laparoscopy, as there already will be substantial difficulty encountered even with effective patient positioning and

longer instruments. Although ultrasound can demonstrate the exact location of the adrenal in these cases, it does not readily allow the safe dissection of the adrenal vein within a field of fat that should not be retracted.

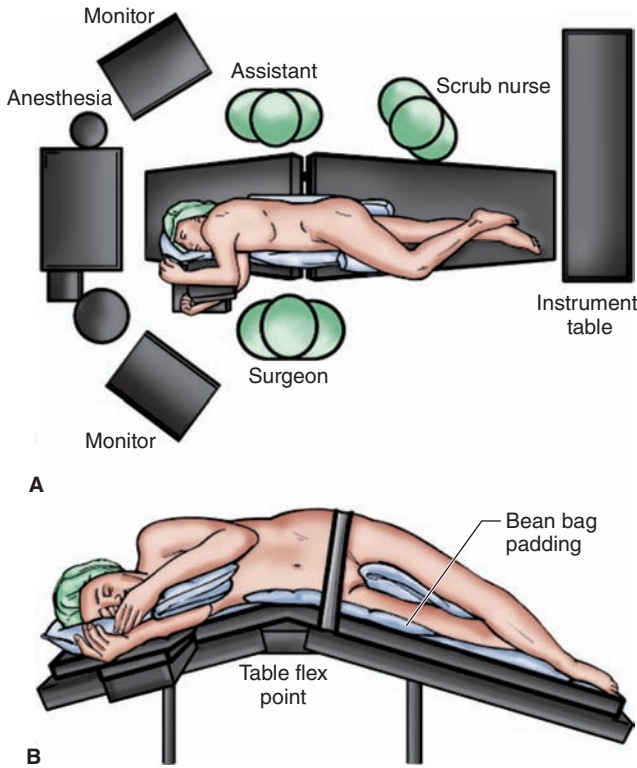
The use of the hand-assisting ports might attenuate some of these issues, but this is unproven. It could also be the case that use of an incision large enough to admit a hand or forearm could abrogate some of the advantage of laparoscopy regarding long-term wound complications and short-term wound pain.

Last, one must keep the 5% conversion rate to open surgery in mind. Thus any advantage to the 19 nonconverted cases must be weighed against the possible disadvantage of urgent conversion to the 20th patient. Furthermore, there is such a breadth of patient response to equivalent injuries that this technique will present no advantage to some. Published series consistently show a subset of patients who tolerate open surgery with little morbidity and another subset of patients who do not tolerate even laparoscopic surgery without substantial morbidity and prolonged hospital stays.<sup>23</sup> We are presently unable to reliably predict which patients will not benefit from a less invasive technique.

## EXPOSURES AND OPERATIVE TECHNIQUE

### General Considerations

There are a few general recommendations that reduce the difficulty of laparoscopic adrenalectomy. First, any bleeding substantially impairs visualization. Dissection should be gentle and every act of tissue division accompanied by a hemostatic maneuver. Second, irrigation to remove obscuring blood cannot be reliably evacuated. Irrigation generally should not be used, as it tends to accumulate and obscure the bed of dissection. Third, removal of blood by suction tends to collapse the operative field and lead to tedious adjustment of retraction. For these reasons, small neurosurgical patties or rolled Kitner sponges are the best way to remove blood and to control minor bleeding. The use of instruments with hemostatic capability, such as ultrasonic shears or bipolar vessel sealing devices, should be used. Fourth, manipulation of instruments through the most lateral port is impaired by patients with wide hips. Port sites should be placed at least 7 cm apart to avoid limitations from instrument crowding. Thus the details of the patient's position and the placement of the ports are not routine and should not be delegated. Finally, the adrenal itself cannot be gripped and retracted directly without rupture and bleeding. Retraction should be performed by leaving periadrenal fat strategically attached to the adrenal and gripping the fat or by elevation of the adrenal from beneath. The specimen side of the adrenal vein after ligation can also be used as a handle for retraction. Otherwise, a rolled Kitner sponge held with a grasper can provide gentle and effective traction.



**FIGURE 63-1** Optimal positioning of patient for a left laparoscopic adrenalectomy in the lateral decubitus position. The midabdomen is placed over the break in the table to optimize trunk extension and reduce interference with instrument movement by the iliac crest. The anterior abdominal wall should not be compressed.

## Positioning

As in all operations, patient positioning and exposure are critical to the success of the laparoscopic adrenalectomy. For the lateral transperitoneal approach, the lateral decubitus position favors retraction of the abdominal viscera by gravity and facilitates exposure of the adrenal gland (Fig. 63-1). In obese patients, it may be a useful position for the anterior border of the patient's body near the edge of the bed and may allow the abdominal pannus to hang over the edge. The surgical table should be flexed with the center of the break in the table located approximately at the midpoint between the costal margin and the iliac crest to facilitate the greatest exposure. Exposure can be improved by raising a kidney rest. Care should be taken during flexion in the elderly and in patients with spine disease. The patient should be secured to the table, an axillary roll placed, and all pressure points should be adequately protected.

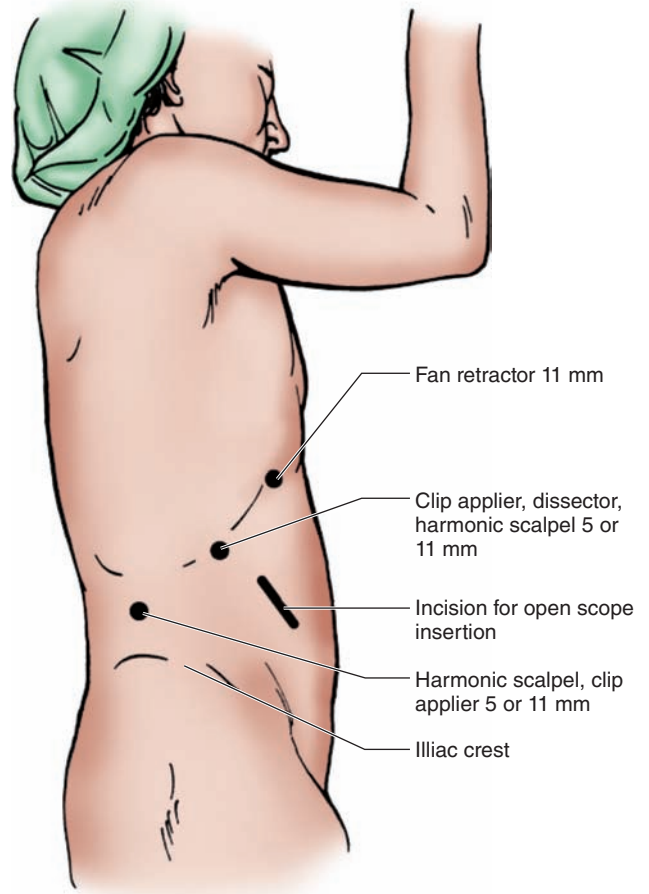
## Instrumentation

Selection of the appropriate instruments can greatly facilitate visualization, exposure, and dissection. A high-definition video camera and monitors in conjunction with a 30-degree

laparoscope provides the best visualization of the operative field. Fan retractors provide excellent exposure with the least risk of injury to the liver and spleen. Other essential equipment includes blunt dissectors, an endoscopic clip device, a laparoscopic bag, Kitner sponges, and a hook electrocautery. Laparoscopic devices, such as the Harmonic scalpel (Ethicon, Cincinnati, OH) or LigaSure (Valleylab, Boulder, CO), are useful and likely decrease operation times.

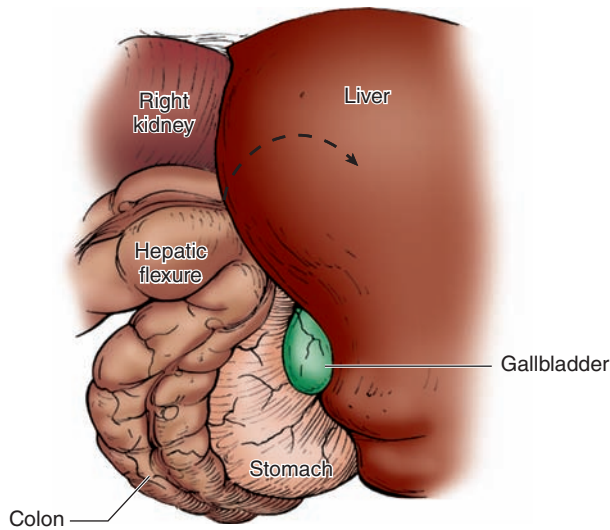
## Right Laparoscopic Adrenalectomy

The patient is placed in the left lateral decubitus position, and the surgeon marks four-port sites along the right costal margin from the xiphoid to the midaxillary line (Fig. 63-2). Either a Veress needle entry or a muscle splitting open entry can be used to gain access to the peritoneal cavity. After insufflation of the peritoneal cavity and placement of additional ports under direct vision, the fan retractor is placed in the most medial port and the camera is placed in the second most



**FIGURE 63-2** Port placement for a right laparoscopic adrenalectomy. In this example, abdominal entry is gained under direct visualization through the most medial site.



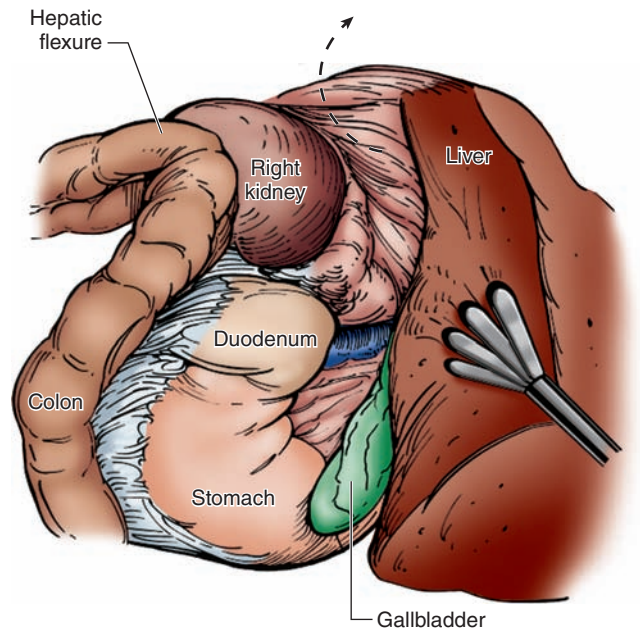


**FIGURE 63-3** Initial view of right upper quadrant in a right laparoscopic adrenalectomy. The *arrow* indicates the direction of liver retraction from the epigastric port.

medial port. Figure 63-3 shows the initial view of the right upper quadrant after entry is achieved. The hepatic flexure of the colon is freed from its attachments and allowed to retract inferomedially from gravity. The fan retractor initially retracts the right lobe of the liver in the medial direction, and the right triangular ligament is taken down with a hook electrocautery. This mobilization enables superior and anterior retraction of the right lobe of the liver, which uncovers the retroperitoneum near the adrenal gland (Fig. 63-4). In most cases, the kidney, periadrenal fat, and IVC are visible after this maneuver.

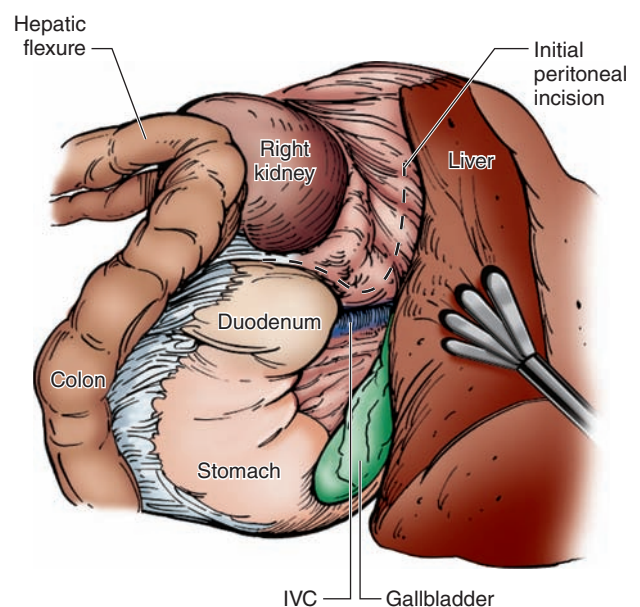
We begin the dissection in the superolateral border of the periadrenal fat with a hook electrocautery. This exposes the diaphragm posteriorly, and the dissection is carried out in the medial direction along the superior border of the periadrenal fat (Fig. 63-5). A few small arteries are typically located in this area, which can be controlled with electrocautery, clips, or a hemostatic device. Careful dissection with blunt graspers should be used while approaching the IVC, near the superomedial border of the periadrenal fat. After establishing the superomedial corner of the periadrenal fat, the dissection is carried down in the caudal direction between the IVC and periadrenal fat (Fig. 63-6). The adrenal vein typically resides near the top third of this medial border and approaches the IVC at approximately a right angle. After clip or stapler ligation of the adrenal vein, this medial plane of dissection opens significantly (Fig. 63-7). Some surgeons routinely divide the adrenal vein with the LigaSure device without the use of a clips or staples (Fig. 63-8).

At this point, the specimen side of the adrenal vein can be grasped for retraction. The inferomedial border of the dissection also requires careful blunt dissection, with special attention to avoid injuring the renal hilar vessels. The dissection is then carried laterally along the superior surface of the kidney.

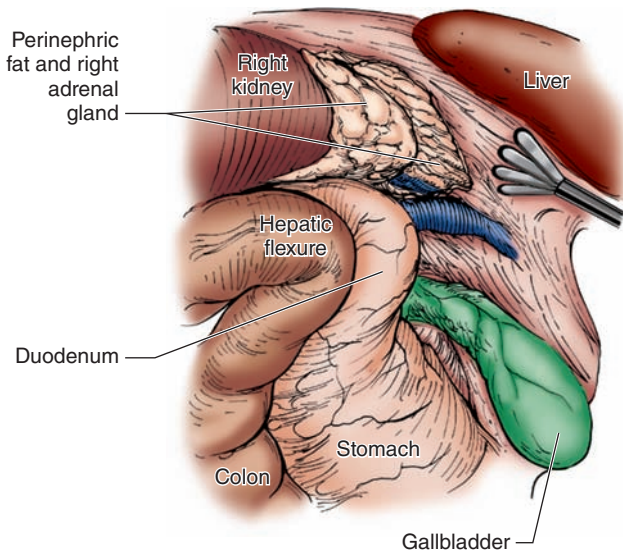


**FIGURE 63-4** View during right laparoscopic adrenalectomy with the liver retracted from the epigastric port. Some attachments of the right lobe of the liver to the diaphragm have been divided. The *dotted line* indicates the line of further peritoneal incision to mobilize the right lobe of the liver from the diaphragm.

Special care must be taken to avoid accidental ligation of any arterial branches to the superior pole of the kidney. Once the plane of dissection is established between the inferior border of the periadrenal fat and the kidney, the only remaining attachments are posterior and lateral to the adrenal gland. A blunt

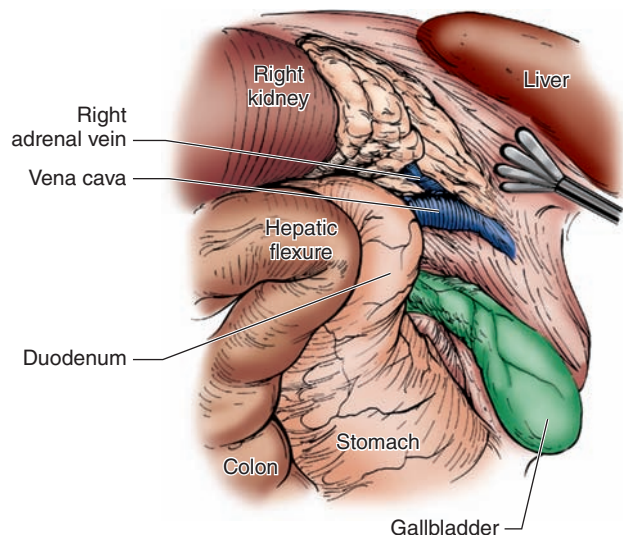


**FIGURE 63-5** View during right laparoscopic adrenalectomy after initial dissection to mobilize the right adrenal. The *dotted line* shows the peritoneal incision under the retracted liver that exposes the adrenal.

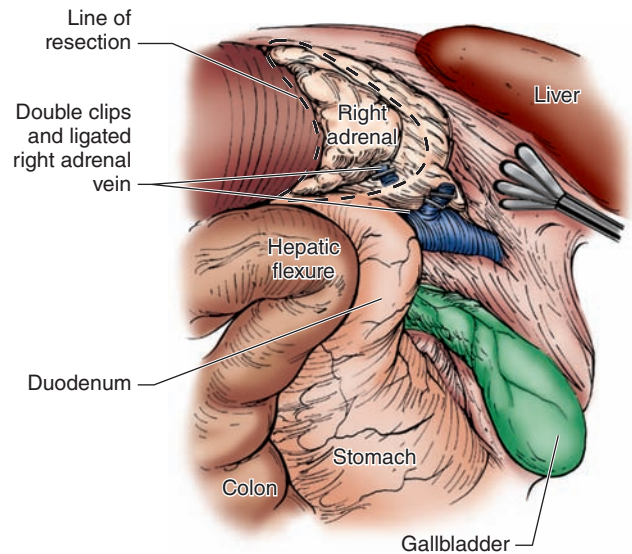


**FIGURE 63-6** Dissection to expose the adrenal gland during right laparoscopic adrenalectomy.

grasper can be used to elevate the adrenal gland in the anterior direction, with special care to avoid disruption of the adrenal capsule. The remaining posterior and lateral attachments can be divided with a LigaSure or Harmonic scalpel device. The dissection should clear all fibrofatty and lymphatic tissue from the diaphragmatic surface. Once all attachments are divided, the gland is placed into an endoscopic bag for removal. If appropriate, the mouth of the bag can be exteriorized and the specimen can be morcellated and removed through a port incision. Otherwise, dilation of the fascia and skin are often required to remove the specimen en bloc.



**FIGURE 63-7** Dissection to expose the adrenal vein during right laparoscopic adrenalectomy. The length of the right adrenal vein is exaggerated in this schematic.

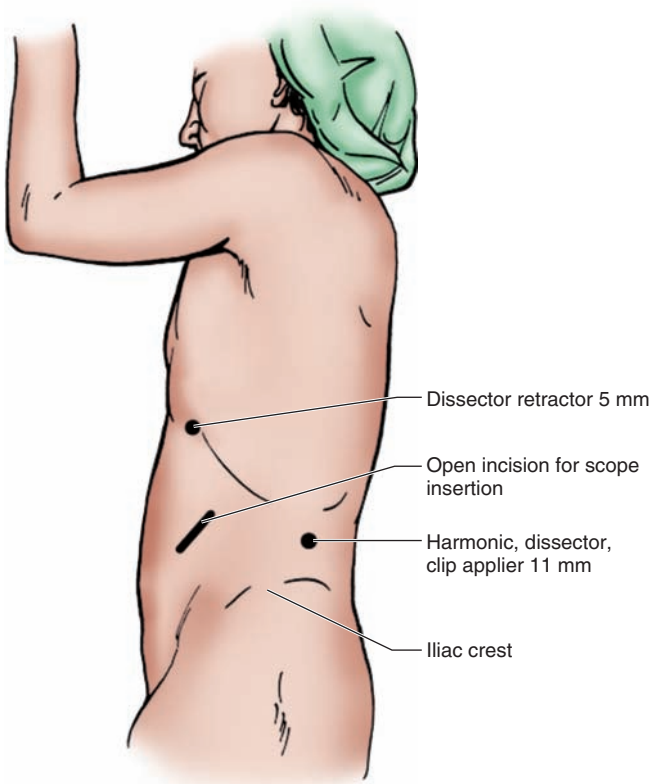


**FIGURE 63-8** View during right laparoscopic adrenalectomy after division of the right adrenal vein with clips. The *dotted line* indicates the line of resection to complete the adrenalectomy. Retraction underneath the adrenal at the site of the severed adrenal vein is often advantageous. The length of the right adrenal vein is exaggerated in this schematic.

## Left Laparoscopic Adrenalectomy

The steps are the same as the right adrenalectomy, with a few differences that will be delineated. The patient is placed in the right lateral decubitus position and the surgeon marks three- or four-port sites along the costal margin from the xiphoid to the posterior axillary line (Fig. 63-9). Sometimes the fourth port is not needed, as the spleen retracts medially with gravity. After access and insufflation of the peritoneal cavity, the splenic flexure of the colon is taken down (Fig. 63-10). The left liver and spleen are mobilized from the diaphragm using hook electrocautery. With medial mobilization of the spleen, the retroperitoneum is exposed. The left kidney, periadrenal fat, and tail of the pancreas are often visualized at this point. The dissection begins in the superolateral corner and proceeds in the medial direction between the spleen and the superior border of the adrenal gland (Fig. 63-11). The splenic vessels are often in close proximity to this plane of dissection. Once the superomedial corner is reached, the tail of the pancreas and the inferior phrenic vein can often be seen. The appearance of the pancreas tail can be similar to the adrenal gland. The dissection continues in the inferior direction along the medial border. The left adrenal vein is often located in the inferomedial portion of the dissection. After adrenal vein ligation, the dissection continues along the inferior border between the adrenal gland and the kidney (Fig. 63-12). In a similar fashion to the right adrenalectomy, the remaining posterior and lateral attachments are divided flush to the surface of the kidney and diaphragm, and the adrenal tumor is removed in bloc with the surrounding periadrenal fat.





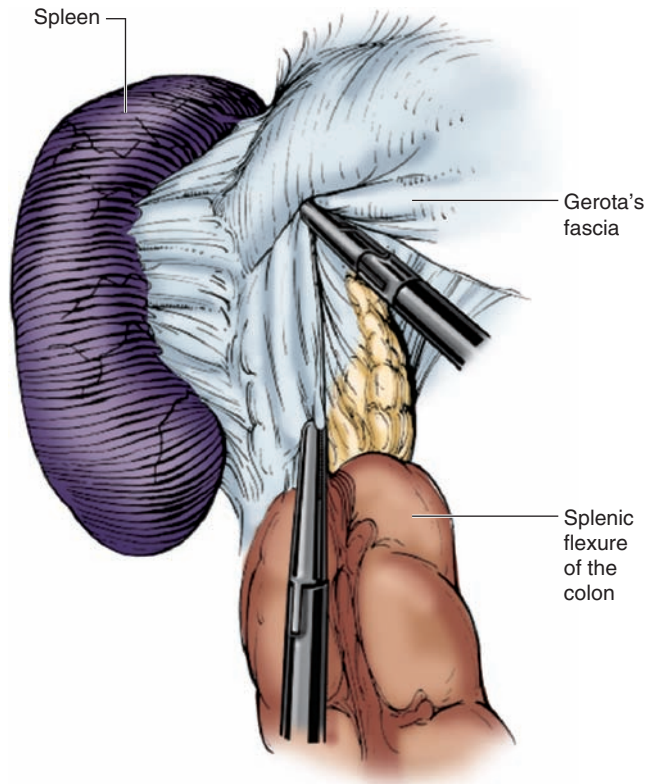
**FIGURE 63-9** Port placement for left laparoscopic adrenalectomy in the right lateral decubitus position. In this example, initial abdominal entry is gained through a medial incision. A fourth port is often not required on the left.

## Retroperitoneoscopic Adrenalectomy

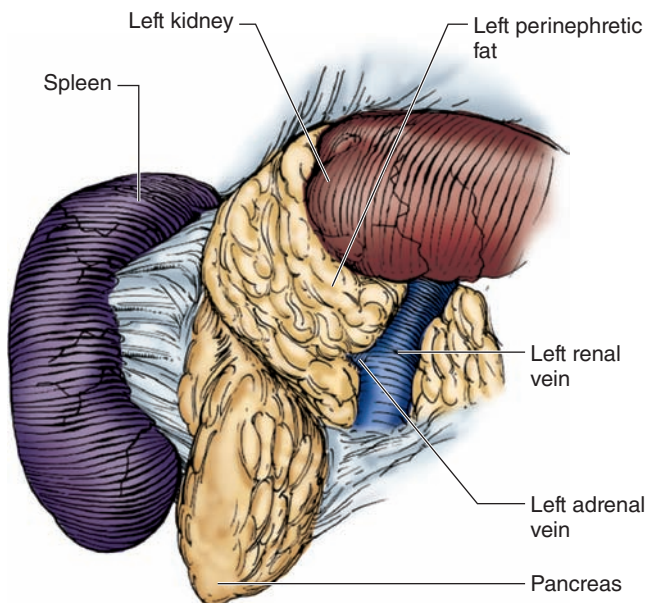
Retroperitoneoscopic adrenalectomy involves directly accessing the retroperitoneal space from the posterior approach. This does not entail entrance into the peritoneal cavity, and therefore it is not laparoscopic surgery. Unlike laparoscopic adrenalectomy, the retroperitoneoscopic approach does not require mobilization of peritoneal organs (e.g., liver, spleen, colon). Furthermore, the surgeon can access both adrenal glands from the same position, which minimizes operative time during bilateral adrenalectomy. Retroperitoneoscopic adrenalectomy is particularly useful for patients with intraperitoneal adhesions from previous laparotomy and is most suitable for small lesions positioned well above the renal hilum that do not have radiographic evidence of local invasion.

First, the patient is intubated, and all tubes and lines are placed in the supine position. Then the patient is flipped into the prone position, with the hips and knees flexed. This positioning requires the use of bolsters across the chest and hips, as well as sufficient padding for the face, arms, and knees. The abdomen should hang down between the two transversely positioned bolsters.

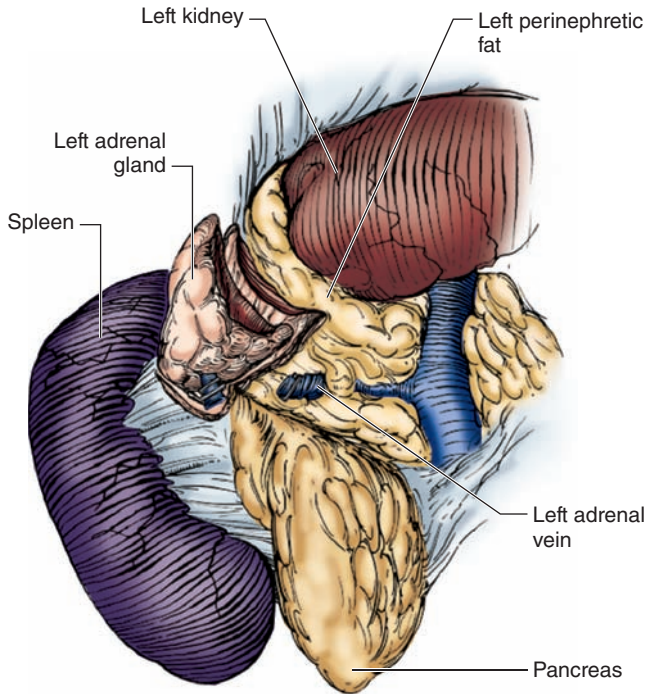
A small transverse incision is made just caudal to the tip of the 12th rib, and sharp dissection is used to dissect through



**FIGURE 63-10** View during left laparoscopic adrenalectomy, showing division of the peritoneum over the kidney and progressive detachment of the spleen from the left diaphragm.



**FIGURE 63-11** View during left laparoscopic adrenalectomy. The spleen had been partially mobilized and is retracting to the right by gravity. The separation between the posterior pancreas and the anterior surface of the left adrenal had been developed. The left renal vein is exposed, as well as the takeoff of the left adrenal vein.



**FIGURE 63-12** View during left laparoscopic adrenalectomy. The spleen is fully mobilized. The adrenal vein has been divided between endoclips. The *dotted line* indicates the line of resection.

the subcutaneous tissues and deep fascia. The length of this incision should be around 1.5 cm, which should be enough to accommodate the surgeon's index finger. Digital examination with the index finger can be used to confirm that the dissection is through the deep fascia, and it allows palpation of the smooth underside of the ribs. A second lateral 5-mm port is placed at near the midaxillary line at the same craniocaudal level under direct palpation using the index finger as a guide through the first incision. Then a third 5-mm port is placed similarly under digital palpation, just lateral to the paraspinous muscles at the same craniocaudal level. This medial port should be approximately 3 or 4 cm caudal to the lowest rib.

Then a 12-mm balloon port is placed in the middle incision to ensure that an airtight seal and the space are insufflated to a pressure of 20–30 mm Hg. A 30-degree 10-mm scope is placed in the middle trocar with the angle toward the ceiling. A blunt grasper is used through the lateral port to dissect through Gerota's fascia. Using blunt dissection, the tissues around the medial and lateral ports are cleared and space is created posterior to kidney and adrenal gland. Usually, the paraspinous muscles can be seen medially. With some blunt dissection, the peritoneal lining can be visualized laterally. At the floor of the dissection (anterior), careful blunt dissection can be used to visualize the kidney.

Dissection is carried along the superior border of the kidney, from lateral to medial to separate the top of the kidney from periadrenal fat. Usually during this portion of the dissection, the adrenal gland itself becomes evident through the periadrenal fat. On the right side, the IVC is found anterior

and medial to the inferomedial border of the periadrenal fat. The adrenal vein is usually anterior and thus can be difficult to visualize. Division of the adrenal vein can be done with a LigaSure device with or without clips. The specimen side of the adrenal vein can be used to retract the adrenal gland in the cephalad and posterior dissection. The remaining attachments between the periadrenal fat anteriorly and superiorly can be divided with a LigaSure device or electrocautery. As with laparoscopic adrenalectomy, the small adrenal arteries can be controlled with either hook electrocautery or a hemostatic device; clips are usually not required. Small holes in the peritoneum are of no significant consequence and do not require repair. Removal of the specimen can usually be achieved without morcellation or extension of the incision. Closure of the deep fascia in the middle incision usually requires only a single simple nonabsorbable suture. Hernia through these posterior incisions is uncommon.

## COMPLICATIONS

Endoscopic adrenalectomy is both safe and effective in experienced hands; however, there are many potential complications with this operation. The most common complications include bleeding (5.9%), wound infection (1.5%), cardiac complications (0.8%), solid-organ injury (0.7%), and pulmonary complications (0.6%).<sup>24</sup>

The specific risks of the procedure are related to the fact that the adrenal glands are deeply situated in the retroperitoneum and in close proximity to large vascular structures and other organs. Consequently, minimally invasive adrenalectomy poses the same anatomic risks as open adrenalectomy: major vascular injury (IVC, splenic vessels, renal vessels) and injury to the spleen, liver, and colon. Although rare, transection of the porta hepatis, hepatic artery, ureter, and renal artery has been reported.<sup>25</sup>

Pneumoperitoneum poses several risks for this operation aside from traumatic injury relating to port placement. The dissection of the adrenal gland is in close proximity to the posterior aspect of the diaphragm, so ipsilateral pneumothorax is a potential complication. A small pneumothorax can be followed without intervention, and larger defects can be treated with a tube thoracostomy. The pneumoperitoneum can also impair venous return that can be particularly dangerous in the setting of catecholamine surges during resection of pheochromocytoma. This risk can be minimized with pre- and intraoperative hydration. The spleen and liver are also at risk for injury during laparoscopic adrenalectomy; these organs can sustain trocar injuries, capsular tears from grasping or retraction, or vascular injury.

The most life-threatening complication of laparoscopic adrenalectomy is a vascular injury, which results from the limitations of visualization and lack of tactile confirmation. On the right, the renal vein can have an oblique course and course through the inferior portion of the dissection, causing confusion with the adrenal vein. The right adrenal vein is often well visualized with laparoscopic technique but is also



of variable location in a superior-inferior plane and anterior-posterior plane. A vein with a diameter significantly smaller than the length of a standard endoscopic clip should be viewed with skepticism if thought to be the adrenal vein. A vein with a diameter significantly larger than an endoclip or that does not clearly connect to the variegated dark yellow adrenal gland is a suspect for the renal vein and should not be divided without certain identification.

On the left, the tail of the pancreas is encountered, and it can often appear similar to the adrenal with its lobular consistency. However, the pancreas is a distinct grayish-white color in contrast to the characteristic bright coloration of the dark yellow adrenal. The granularity of the adrenal is also much finer than the lobules of the pancreas. In addition, there can be a segmental upper pole renal artery that lies just deep to the lower portion of the adrenal. The named arteries of the adrenal are all quite narrow, in the 0.5-mm range, and are often not seen during dissection. Division of an identifiable artery should therefore be very carefully considered. Any major vascular injury should prompt immediate conversion to an open technique. Regarding retroperitoneoscopic adrenalectomy, higher insufflation pressures are tolerated better with less hemodynamic compromise, in comparison to the laparoscopic technique. Intraoperative hypercarbia can be relieved by releasing insufflation and hyperventilating the patient. Subcutaneous emphysema and subcostal nerve dysfunction can be observed after retroperitoneoscopic adrenalectomy, and both are transient in nature.

## OPEN ADRENALECTOMY

Open adrenalectomy can be performed via multiple approaches, depending on tumor characteristics, patient body habitus, and surgeon experience with each technique. As mentioned previously, the laparoscopic approach is not appropriate for large tumors or those with local extension; the open approach is the procedure of choice in these cases. The open approach should also be performed in cases where laparoscopy is unsuccessful or when a major vascular or visceral injury occurs. The main open approaches to the adrenal glands are addressed as follows.

### Anterior Approach

The anterior approach provides excellent exposure and allows access to both adrenal glands as well as extra-adrenal foci as in the case of pheochromocytoma. The patient is placed in the supine position on the operating table, and either a midline laparotomy or bilateral subcostal incision can be used for this approach with excellent exposure. For right-side access, the hepatic flexure of the colon is taken down inferiorly, the liver is retracted superiorly, and a Kocher maneuver is performed to expose the retroperitoneal space. Gerota's fascia is identified and incised. Once the adrenal gland is exposed, the lateral and superior aspects of the gland are mobilized and

the adrenal vein is ligated and divided. Given the proximity of the right adrenal gland to the IVC, the surgeon must use care when dissecting and ligating the right adrenal vein. The left adrenal gland can be exposed from an anterior approach by a medial visceral rotation of the stomach, spleen, splenic flexure of the colon, and pancreas toward the midline. The left adrenal vein can drain either into the left renal vein or the left inferior phrenic vein. The remainder of the dissection is similar to the right side.

### Posterior Approach

The posterior approach is particularly useful for patients with adrenal disease who have undergone prior abdominal surgery. These patients might have dense adhesions that make an intra-abdominal exposure formidable. In this operation, the patient is placed in the prone position on the operating table, and a curvilinear incision is made starting in a paramedian line and extending laterally. After the skin and subcutaneous tissues are incised, the latissimus dorsi muscle is divided with electrocautery near its origin and the serratus posterior is divided in a similar way. The 12th rib is removed to facilitate the exposure, and the 11th rib and the pleura are retracted superiorly, which exposes the underlying Gerota fascia. The fascia is incised, and the adrenal gland and the kidney are exposed. The superior vessels are ligated and divided, and the superior aspect of the gland is dissected free. After the gland is mobilized, the adrenal vein is isolated, ligated, and divided. When the gland has been removed, closure is performed in layers.

### Thoracoabdominal Approach

The thoracoabdominal incision, though morbid, has great utility for the exposure and removal of large tumors. The patient is placed in the anterolateral position, and the table is rotated to facilitate the exposure. The dissection is carried down between the eighth and ninth ribs, which allows the full exposure of the adrenal gland, renal fossa, and surrounding tissues. The remainder of the dissection is carried out as mentioned previously. If the pleural space is entered, a tube thoracostomy should be placed, and a postoperative chest x-ray obtained to exclude pneumothorax.

## CONCLUSIONS

Safe and effective resection of adrenal tumors presents both anatomic and physiological challenges for the surgical team. Preoperative planning is critical with particular consideration of the size, radiographic consistency, and specific hormonal products for each tumor. For resection of benign adrenal tumors, minimally invasive adrenalectomy has been shown to be safe, effective, and offers the patient decreased surgical morbidity and decreased length of stay. With improved

technologies and further study, the role of minimally invasive surgery for adrenal disease may expand to include malignant disease both for palliative and curative intent. Open adrenalectomy, however, remains an important operation for large and malignant lesions.

## REFERENCES

1. Conn JW, Louis LH. Primary aldosteronism: a new clinical entity. *Trans Assoc Am Physicians*. 1955;68:215–231; discussion, 213–231.
2. Guerrieri M, De Sanctis A, Crosta F, et al. Adrenal incidentaloma: surgical update. *J Endocrinol Invest*. 2007;30:200–204.
3. Mathur A, Kemp CD, Dutta U, et al. Consequences of adrenal venous sampling in primary hyperaldosteronism and predictors of unilateral adrenal disease. *J Am Coll Surg*. 2010;211:384–390.
4. Vassiliou MC, Laycock WS. Laparoscopic adrenalectomy for pheochromocytoma: take the vein last? *Surg Endosc*. 2009;23:965–968.
5. Meyer-Rochow GY, Soon PS, Delbridge LW, et al. Outcomes of minimally invasive surgery for pheochromocytoma. *ANZ J Surg*. 2009;79:367–370.
6. Tiberio GA, Baiocchi GL, Arru L, et al. Prospective randomized comparison of laparoscopic versus open adrenalectomy for sporadic pheochromocytoma. *Surg Endosc*. 2008;22:1435–1439.
7. Soon PS, Yeh MW, Delbridge LW, et al. Laparoscopic surgery is safe for large adrenal lesions. *Eur J Surg Oncol*. 2008;34:67–70.
8. Gonzalez RJ, Shapiro S, Sarlis N, et al. Laparoscopic resection of adrenal cortical carcinoma: a cautionary note. *Surgery*. 2005;138:1078–1085; discussion 1076–1085.
9. McCauley LR, Nguyen MM. Laparoscopic radical adrenalectomy for cancer: long-term outcomes. *Curr Opin Urol*. 2008;18:134–138.
10. Eto M, Hamaguchi M, Harano M, Yokomizo A, Tatsugami K, Naito S. Laparoscopic adrenalectomy for malignant tumors. *Int J Urol*. 2008;15:295–298.
11. Kuruba R, Gallagher SF. Current management of adrenal tumors. *Curr Opin Oncol*. 2008;20:34–46.
12. Brunaud L, Kebebew E, Sebag F, Zarnegar R, Clark OH, Duh QY. Observation or laparoscopic adrenalectomy for adrenal incidentaloma? A surgical decision analysis. *Med Sci Monit*. 2006;12:CR355–362.
13. Noda E, Ishikawa T, Maeda K, et al. Laparoscopic resection of periaxillary paraganglioma: a report of 2 cases. *Surg Laparosc Endosc Percutan Tech*. 2008;18:310–314.
14. Draaisma WA, van Hillegersberg R, Borel Rinkes IH, Custers M, Broeders IA. Robot-assisted laparoscopic resection of a large paraganglioma: a case report. *Surg Laparosc Endosc Percutan Tech*. 2006;16:362–365.
15. Thapar PM, Dalvi AN, Kamble RS, Vijaykumar V, Shah NS, Menon PS. Laparoscopic transmesocolic excision of paraganglioma in the organ of Zuckerkandl. *J Laparoendosc Adv Surg Tech A*. 2006;16:620–622.
16. Bonnet S, Gaujoux S, Leconte M, Thillois JM, Tissier F, Dousset B. Laparoscopic adrenalectomy for metachronous metastasis from renal cell carcinoma. *World J Surg*. 2008;32:1809–1814.
17. Castillo OA, Vitagliano G, Kerkebe M, Parma P, Pinto I, Diaz M. Laparoscopic adrenalectomy for suspected metastasis of adrenal glands: our experience. *Urology*. 2007;69:637–641.
18. Marangos IP, Kazaryan AM, Rosseland AR, et al. Should we use laparoscopic adrenalectomy for metastases? Scandinavian multicenter study. *J Surg Oncol*. 2009;100:43–47.
19. Strong VE, D'Angelica M, Tang L, et al. Laparoscopic adrenalectomy for isolated adrenal metastasis [see comment]. *Ann Surg Oncol*. 2007;14:3392–3400.
20. Gagner M, Lacroix A, Bolte E. Laparoscopic adrenalectomy in Cushing's syndrome and pheochromocytoma. *New Engl J Med*. 1992;327:1033.
21. Assalia A, Gagner M. Laparoscopic adrenalectomy. *Br J Surg*. 2004;91:1259–1274.
22. Tunca F, Senyurek YG, Terzioglu T, et al. Single-incision laparoscopic adrenalectomy. *Surg Laparosc Endosc Percutan Tech*. 2010;20:291–294.
23. Barreca M, Presenti L, Renzi C, et al. Expectations and outcomes when moving from open to laparoscopic adrenalectomy: multivariate analysis. *World J Surg*. 2003;27:223–228.
24. Brunt LM. The positive impact of laparoscopic adrenalectomy on complications of adrenal surgery. *Surg Endosc*. 2002;16:252–257.
25. Tessier DJ, Iglesias R, Chapman WC, et al. Previously unreported high-grade complications of adrenalectomy. *Surg Endosc*. 2009;23:97–102.

*This page intentionally left blank*





Note: Page numbers followed by *f* indicate figures; those followed by *t* indicate tables.

## A

- Abdominal packs, 244
- Abdominoperineal resection (APR)
- colostomy, 788
  - complications, 860
  - exteriorization of the specimen and wound closure, 788
  - hand-assisted, 789
  - mobilization of the sigmoid colon and the rectum, 787–788
  - overview, 856–857
  - patient position and room setup, 787
  - perineal dissection, 857, 858*f*–859*f*
  - perineal resection, 788
  - port placement and exploration, 787
  - postoperative care, 860
  - technique, 857
  - vascular ligation, 787
- Abdominothoracic incisions, 102, 104, 107*f*
- Ablative therapies, hepatic colorectal metastasis, 962–964, 964*f*
- Abnormal pancreaticobiliary duct junction (APBDJ), 1061
- Abscess, abdominal
- clinical presentation, 198
  - definition and etiology of, 197
  - diagnosis, 198–199
  - management
    - antimicrobial therapy, 199–200, 199*t*–201*t*
    - overview, 199
    - percutaneous drainage, 200–202, 202*t*
    - resuscitation and support, 199
    - source control, 200–202
    - surgical drainage, 202
    - pathophysiology, 197–198
- Abscess, anorectal
- diagnosis and classification, 824–825, 826*f*
  - treatment, 825, 827, 827*f*–829*f*, 829
- Abscess, colon, 654, 654*f*
- Abscess, hepatic. *See* Hepatic abscess and cystic disease
- Abscess, pancreatic, 1139
- Abscess, small bowel, 683, 683*f*
- Abscess, splenic, 1247–1248
- Abscess, stitch, 120
- Accessory spleens, 1239
- Achalasia
- evaluation, 303–304, 304*f*–305*f*
  - high-resolution manometry, 332, 332*f*
  - natural history and presentation, 303
  - operative technique
    - laparoscopic Heller myotomy, 306–309, 307*f*–309*f*, 352–353, 430
    - thoroscopic Heller myotomy, 430
  - overview, 303, 352, 353
  - partial fundoplication, 352, 353
  - treatment, 304, 306–307, 429–430
- Acute colitis, 700
- Acute mesenteric embolization, 269–270, 269*f*–270*f*
- Acute mesenteric insufficiency, 268–272, 269*f*–272*f*
- Acute mesenteric thrombosis, 270–271, 270*f*–271*f*
- Adenocarcinoma, anal, 893
- Adenocarcinoma, appendix, 641
- Adenocarcinoma, colon, 744–745
- Adenocarcinoma, esophageal, 366–367, 433
- Adenocarcinoma, gastric
- adjunctive therapies, 467–468
  - associated risk factors
    - diet, 465
    - Helicobacter pylori*, 464
    - hereditary forms, 465
    - obesity, 465
    - overview, 463–464
    - smoking, 464–465
  - diagnosis and staging
    - overview, 466
    - preoperative staging and selection of patients for surgery, 466–467
    - staging, 467, 467*t*
  - epidemiology, 463, 464*f*, 464*t*
  - gastrointestinal reconstructive techniques
    - intestinal reconstruction after distal gastrectomy
      - Billroth-II reconstruction, 474–475, 475*f*
      - Roux-en-Y reconstruction, 475–477, 475*f*–477*f*
    - intestinal reconstruction after total gastrectomy, 477–480, 478*f*–480*f*
    - overview, 474
  - signs and symptoms, 465–466
  - surgical approach
    - endoscopic submucosal resection, 470
    - extent of lymph node dissection, 469–470, 469*f*, 470*t*
    - overview, 468–469
  - surgical techniques
    - distal gastrectomy, 471–474, 471*f*–473*f*
    - total gastrectomy, 474, 474*f*
- Adenocarcinoma, small intestine
- clinical presentation, 615–616, 615*f*
  - diagnosis, 616
  - epidemiology, 615
  - management, 616
  - staging and prognosis, 616
- Adenoma, bile duct, 933
- Adenoma, hepatocellular
- diagnosis, 932, 933*f*
  - epidemiology and etiology, 931–932
  - pathology, 932
  - treatment, 932–933
- Adenoma, small intestine, 614–615, 614*f*
- Adenoma-carcinoma model, 737, 737*f*
- Adhesions, bowel obstruction and, 590–591
- Adrenal cortical cancer, 1272–1273
- Adrenal cyst, 1272
- Adrenalectomy
- complications, 1279–1280
  - endoscopic
    - advantages of laparoscopic approach, 1273–1274
    - disadvantages of laparoscopic approach, 1274
    - overview, 1273
  - exposures and operative technique
    - general considerations, 1274
    - instrumentation, 1275
    - left laparoscopic, 1277, 1278*f*–1279*f*
    - positioning, 1275, 1275*f*
    - retroperitoneoscopic, 1278–1279
    - right laparoscopic, 1275–1277, 1275*f*–1277*f*
  - indications
    - adrenal cortical cancer, 1272–1273
    - adrenal cyst, 1272
    - aldosteronoma, 1271
    - cortisol-producing adrenal adenoma, 1272
    - incidentaloma, 1273
    - metastasis, 1273
    - myelolipoma, 1272
    - paraganglioma, 1273
    - pheochromocytoma, 1271–1272
  - introduction to adrenal anatomy and physiology, 1271
  - open
    - anterior approach, 1280
    - overview, 1280
    - posterior approach, 1280
    - thoracoabdominal approach, 1280

- Adrenalectomy (*Cont.*):  
 overview, 1280  
 robotics in, 6
- AJCC staging system for anal cancer, 884, 885*t*
- Aldehyde dehydrogenase 2 (ALDH2) deficiency, 356
- Alkaline reflux gastritis, 456, 456*f*
- Allis clamps, 66
- Amebic liver abscess  
 complications, 912–913, 912*f*  
 diagnosis  
 clinical presentation, 910, 910*t*–911*t*  
 diagnostic aspiration, 911  
 laboratory evaluation, 910–911  
 overview, 910  
 radiology, 911  
 serology, 911  
 etiology, 909  
 incidence, 909–910  
 outcome, 913, 914*t*  
 overview, 909  
 pathology, 910  
 treatment  
 antibiotics, 911–912  
 drainage, 912  
 overview, 911  
 therapeutic aspiration, 912
- American association for the surgery of trauma (AAST) scale  
 for colon injury, 256*t*  
 for kidney injury, 249*t*  
 for liver injury, 249*t*  
 for small bowel injury, 255*t*  
 for spleen injury, 248*t*
- Amsterdam criteria, 739, 739*t*, 795
- Anal adenocarcinoma, 893
- Anal canal anatomy and histology, 879, 880*f*
- Anal cancer. *See* Cancer, anus
- Anal fissure  
 clinical features and diagnosis, 821  
 overview, 821, 822*f*  
 treatment, 821, 823*f*–825*f*, 824
- Anal incontinence  
 anal sphincter reconstruction, 810*f*  
 diagnosis and evaluation  
 electromyography, 807*f*  
 transrectal ultrasound, 808*f*–809*f*  
 etiology, 807*t*  
 pathophysiology, 807*t*
- Anal intraepithelial neoplasia (AIN), 830
- Anal margin cancer  
 overview, 891  
 radiotherapy, 892  
 surgery, 891–892, 891*f*
- Anal melanoma  
 adjuvant therapy, 893  
 overview, 892  
 staging and prognosis, 892–893  
 surgery, 893
- Anal sphincter reconstruction, 808, 810*f*
- Anal squamous cell carcinoma  
 anal intraepithelial neoplasia  
 diagnosis and treatment, 882–883  
 HPV vaccines, 883  
 chemoradiation, 886–888, 887*t*, 889*t*  
 diagnosis and staging, 884–885, 884*f*, 885*t*, 886*f*  
 etiology, pathogenesis, and risk factors  
 chronic inflammation, 881–882  
 HIV, 881  
 human papillomavirus, 881  
 smoking, 881  
 incidence and epidemiology, 880–881  
 inguinal nodal metastases, treatment of, 889  
 pathology, 883–884  
 radiotherapy, newer modalities for, 888  
 recurrent disease and salvage therapy, 889–891, 890*t*  
 surgical management, 885, 886*f*
- Anal transition zone (ATZ), 879, 880*f*
- Anastomotic leak, 714
- Anemias, 1249
- Aneurysms  
 aorta and iliac arteries  
 diagnostic imaging, 279, 279*f*  
 endovascular repair, 281–283, 282*f*  
 open repair, 279*f*; 280–281, 281*f*  
 overview, 278–279  
 preoperative management, 280  
 celiac artery, 285  
 gastric, gastroepiploic, gastroduodenal, pancreatic, and pancreaticoduodenal, 285  
 hepatic artery, 284–285  
 mesenteric branches and the inferior mesenteric artery, 286  
 splenic artery, 284  
 superior mesenteric artery, 285  
 visceral artery, 283–284, 283*t*
- Angiodysplasia, 232, 232*f*
- Angiosarcoma, hepatic, 945
- Anorectum, benign disorders of  
 anal fissure  
 clinical features and diagnosis, 821  
 overview, 821, 822*f*  
 treatment, 821, 823*f*–825*f*, 824  
 anal incontinence  
 anal sphincter reconstruction, 810*f*  
 diagnosis and evaluation  
 electromyography, 807*f*  
 transrectal ultrasound, 808*f*–809*f*  
 pathophysiology, 807*t*  
 anatomy, 803–804, 804*f*–806*f*  
 anorectal abscess and anal fistula  
 diagnosis and classification, 824–825, 826*f*  
 treatment, 825, 827, 827*f*–829*f*, 829  
 fecal incontinence  
 diagnosis and evaluation  
 electromyography, 807  
 overview, 807  
 transrectal ultrasound, 807  
 pathophysiology, 804, 807  
 treatment  
 anal sphincter reconstruction, 808  
 miscellaneous treatments and new modalities, 808–809  
 muscle sensory retraining or biofeedback, 808  
 overview, 808  
 hemorrhoids  
 classification, 817, 818*f*  
 internal, evaluation of, 817  
 overview, 817  
 treatment  
 mixed hemorrhoids, 820, 820*f*  
 overview, 817, 819–820, 819*f*  
 thrombosed external hemorrhoids, 820–821  
 overview, 803  
 pelvic floor outlet obstruction and solitary rectal ulcer syndrome  
 diagnosis and evaluation, 815–816, 816*f*  
 pathophysiology, 815  
 rectocele, enterocele, and complex pelvic floor abnormalities, 816–817  
 treatment and management, 816  
 rectal prolapse and internal intussusception management  
 internal intussusception, 815  
 rectal prolapse, 812, 813*f*–814*f*, 815  
 pathophysiology  
 diagnosis and evaluation, 811–812, 812*t*  
 etiology and physiology, 810–811, 811*f*  
 sexually transmitted anal disease  
 chlamydial infections, 830  
 gonorrhea, 831  
 herpes simplex virus, 831  
 human papillomavirus, 830  
 overview, 829–830  
 syphilis, 831
- Anterior proximal vagotomy or seromyotomy, 539*f*–540*f*, 540
- Anthelmintics, for hydatid liver cyst, 917
- Antithrombotics, perioperative management of, 14–15, 19*t*
- Aortoenteric fistula, 227–228, 227*f*
- APACHE II score, 1098–1099
- APBDJ (abnormal pancreaticobiliary duct junction), 1061
- APC* gene, 737
- Appendiceal fistulas, 205
- Appendicolith, asymptomatic, 640
- Appendix  
 acute appendicitis  
 diagnosis  
 children, 629–630  
 diagnostic scores, 627  
 differential diagnosis, 629, 629*t*  
 elderly patients, 630  
 history and physical examination, 626  
 imaging studies, 627–628, 627*f*–628*f*, 628*t*  
 immunocompromised patients, 631  
 laboratory studies, 626–627  
 pregnant patients, 630–631  
 epidemiology, 623–624  
 etiology and pathophysiology, 624–625  
 perforated appendicitis, 625–626  
 presentation, 625  
 adenocarcinoma of, 641  
 anatomy, 623, 624*f*  
 asymptomatic appendicolith, 640  
 chronic appendicitis, 640  
 history, 623  
 neoplasms of

- adenocarcinoma, 641  
 carcinoid tumors, 641  
 cystic neoplasms and pseudomyxoma peritonei, 640–641, 640f–641f  
 overview, 640  
 treatment  
   nonoperative management, 631–632  
   open versus laparoscopic appendectomy  
   laparoscopic, 636, 637f–638f; 638  
   open, 633, 634f–636f; 635–636  
   overview, 632–633, 632t  
   postoperative care, 638  
 perforated appendicitis, 638–639  
   interval appendectomy, 639  
   normal appendix, 639–640  
   preoperative preparation, 632  
 APR. *See* Abdominoperineal resection  
 Arterial repair, principles of, 268  
 Artificial bowel sphincter, 809  
*Ascaris lumbricoides*, 1053  
 ATZ (anal transition zone), 879, 880f  
 Autofluorescence endoscopy, 32–33  
 Autoimmune pancreatitis, 1149  
 Autologous islet transplantation outcomes, 1163
- B**  
 Babcock clamps, 256  
 Balloon sphincteroplasty, 1011  
 Bancroft procedure, 524–525, 526f  
 Bannayan-Riley-Ruvalcaba syndrome, 740  
 Bariatric surgery  
   adjustable gastric banding  
   laparoscopic approach  
   complications, 553–554  
   operative procedure, 551–552  
   outcomes, 553  
   overview, 551  
   postoperative care, 552–553  
   preoperative approach, 549  
   age limit for, 573–574  
 biliopancreatic diversion  
   operative procedure, 570  
   overview, 570  
   postoperative care, 570–571  
 duodenal switch  
   complications, 571–572  
   follow-up, 571  
   operative procedure, 570  
   outcomes, 571  
   overview, 570  
   postoperative care, 570–571  
   preoperative preparation, 550  
 during pregnancy, 573  
 endoscopic, 574  
 innovation in, 580–581  
 preoperative preparation, 548–550  
 revisional surgery, 572–573  
 Roux-en-Y gastric bypass  
   for cholelithiasis, 566  
   complication, 566–567  
   for diabetes, 566  
   follow-up, 565  
   for gastroesophageal reflux disease, 566  
   laparoscopic approach  
   completion of, 563  
   creating gastrojejunostomy, 562–563  
   creating proximal gastric pouch, 560–562  
   creating the Roux limb, 558–559  
   enteroenterostomy, 559  
   mesenteric defect closure, 563  
   overview, 557  
   passing the Roux limb, 559–560  
   patient positioning and preparation, 557  
   pneumoperitoneum and port placement, 557–558  
   preoperative preparation, 549–550  
   nutritional issues and complications in, 569–570  
 open approach  
   creating gastric pouch, 564  
   drains, oversewing and gastrostomies, 564  
   enteroenterostomy, 563  
   incision and exposure, 563  
   overview, 563  
   passing the Roux limb, 564  
 outcomes, 565–566  
 postoperative care, 564–565  
 specific complications and their treatment, 567, 568–569  
 selection of patients, 548  
 sleeve gastrectomy  
   laparoscopic approach  
   complications, 556–557  
   operative procedure, 555–556  
   outcomes, 556  
   overview, 554, 580  
   postoperative care, 556  
   preoperative preparation, 550  
   venous thromboembolism in, 557  
   weight limit for, 574  
 Barium esophagram, 327  
 Barrett's esophagus, 32f, 358, 359t, 373–374  
   definition of, 325  
   management, 326–327, 327f; 327t  
   overview, 325, 326f; 433  
   pathophysiology, 325  
   screening and surveillance, 326  
 Bassini, E., 123  
 Beger procedure  
   versus Frey procedure, 1161  
   operative technique, 1159–1160, 1160f  
   versus pancreaticoduodenectomy, 1160–1161  
 Berne procedure, operative technique and outcome, 1162  
 Bethesda criteria, 739t  
 Bezoars, for upper gastrointestinal bleeding, 458  
 Bile duct cancer. *See* Cancer, bile duct  
 Biliary and gastric bypass  
   overview, 88–89, 88f  
   technique, 89, 90f–92f; 92  
 Biliary tract  
   cholangiocarcinoma, 1090, 1093–1094  
   choledochal cyst, 1090, 1093  
   choledocholithiasis, 1089–1090, 1093  
   gallbladder carcinoma, 1090, 1093  
   laparoscopic biliary tract resection and reconstruction  
   cholecystojejunostomy, 1084–1086, 1084f–1085f; 1084t  
   choledochal cyst excision, 1087, 1087t  
   choledochoduodenostomy and hepaticojejunostomy, 1086–1087, 1086f  
   overview, 1083–1084  
 laparoscopic cholecystectomy and bile duct injuries  
   culture of, 1092  
   overview, 1089, 1092  
   the rationale of the “critical view of safety,” 1092  
   vasculobiliary injuries, 1092–1093  
 laparoscopic common bile duct evaluation  
   cholangiography, 1078, 1078f  
   overview, 1077, 1078t  
   ultrasound, 1078–1079  
 laparoscopic management of  
   choledocholithiasis  
   choledochotomy, 1082–1083, 1083f  
   overview, 1079–1080, 1079f; 1079t  
   transcystic duct exploration (with choledochoscope), 1081–1082, 1082f  
   transcystic duct exploration (without choledochoscope)  
   balloon techniques, 1080–1081, 1081f  
   basket techniques, 1081, 1081f  
   overview, 1080, 1080f  
   laparoscopic procedures, 1091  
   overview, 1077, 1087–1088  
 Biliopancreatic diversion (BPD)  
   operative procedure, 569f; 570  
   overview, 570  
   postoperative care, 570–571  
 Billroth, Theodor, 3  
 Billroth-I reconstruction, 522f–525f; 523–524  
 Billroth-II reconstruction, 474–475, 475f; 524–529, 526f–531f  
 Bipolar electrocoagulation, 71  
 Bismuth classification system, 1041, 1041f  
 Bleeding  
   regional and vascular complications of  
   diagnosis, 1139  
   overview, 1139  
   pathogenesis, 1139  
   treatment, 1139  
 “Blow-hole” colostomy, 165, 166f  
 BMI (body mass index), 546, 548  
 Bobbs, John Stough, 3  
 Bookwalter retractor, 510, 511f  
 Bovie device, 70  
 Bowel obstruction. *See* Obstruction, bowel  
 Brunner gland adenomas, 614  
 Buschke-Löwenstein tumors, 894–895, 894f  
 Bypass procedures, 676
- C**  
 CABG (coronary artery bypass grafting), 11–12  
 Calor's triangle, 998  
 Cambridge classification of chronic pancreatitis, 1153t  
 Cameron's erosions, 351  
 Cameron's ulcers, 351  
 Cancer, anus  
   anal adenocarcinoma, 893  
   anal canal anatomy and histology, 879, 880f



- Cancer, anus (*Cont.*):
- anal margin cancer
    - overview, 891
    - radiotherapy, 892
    - surgery, 891–892, 891*f*
  - anal melanoma
    - adjuvant therapy, 893
    - overview, 892
    - staging and prognosis, 892–893
    - surgery, 893
  - anal squamous cell carcinoma
    - anal intraepithelial neoplasia
      - diagnosis and treatment, 882–883
      - HPV vaccines, 883
    - chemoradiation, 886–888, 887*t*, 889*t*
    - diagnosis and staging, 884–885, 884*f*, 885*t*, 886*f*
    - etiology, pathogenesis, and risk factors
      - chronic inflammation, 881–882
      - HIV, 881
      - human papillomavirus, 881
      - smoking, 881
    - incidence and epidemiology, 880–881
    - inguinal nodal metastases, treatment of, 889
    - pathology, 883–884
    - radiotherapy, newer modalities for, 888
    - recurrent disease and salvage therapy, 889–891, 890*t*
    - surgical management, 885
  - Buschke-Löwenstein tumors, 894–895, 894*f*
  - gastrointestinal stromal tumors, 895
  - Kaposi's sarcoma, 895
  - overview, 873–874, 879
  - Paget's disease, 893–894
- Cancer, bile duct
- adjuvant therapies, 1073
  - clinical presentation and diagnosis, 1067–1069, 1068*f*–1069*f*
  - epidemiology, 1066–1067, 1067*t*
  - outcome, 1075
  - palliation, 1073–1074, 1074*f*
  - pathogenesis and pathology, 1067, 1068*t*
  - surgical technique, 1070–1073, 1070*f*–1073*f*
  - surgical therapy, 1069–1070
- Cancer, colorectal
- Amsterdam criteria II, 795
  - classification, 795
  - etiology, 798
  - familial colorectal cancer type X, 795
  - genetics, 798–799
  - Lynch syndrome, 795
  - metastasis. *See* Colorectal metastasis
  - MUTYH-associated polyposis, 795
  - operative technique
    - laparoscopic colon resection, 799–780
    - preoperative preparation, 799
  - pathology, 795
  - PET-CT, 795
  - risk factor, 798
  - screening for
    - computed tomographic colonography, 798
    - immunohistochemistry, 795
    - total colonoscopy, 798
  - treatment
    - laparoscopic surgery, 796
    - neoadjuvant therapy, 796
    - radiation therapy, 796
    - targeted therapy, 796
  - tumor-node-metastasis classification, 795–796
- Cancer, esophageal
- chemotherapy, 435
  - diagnosis
    - advanced cancer, 358–359, 359*t*
    - screening, surveillance and prevention for early cancer
      - Barrett's esophagus and adenocarcinoma, 358
      - dysplasia grade and surveillance interval, 358*t*
      - squamous cell dysplasia and cancer, 357–358, 357*f*
  - epidemiology, 355–356
  - etiological factors, 356–357, 356*t*
  - historical perspectives, 355
  - minimally invasive esophagectomy, 437–438
  - overview, 382
  - patient comparison, Asia versus the West, 359*t*
  - surgical resection, 434
  - treatment
    - combined multimodal treatment strategies
      - adjuvant chemotherapy, 378
      - adjuvant radiotherapy, 377
      - definitive chemoradiation, 378–379
      - neoadjuvant chemoradiation, 378, 379*t*
      - neoadjuvant chemoradiation ± adjuvant chemotherapy, 377*t*
      - neoadjuvant chemotherapy, 377–378
      - neoadjuvant radiotherapy, 376–377
    - overview, 376
    - prediction of response and response-directed therapy, 380–381, 381*f*
    - surgery, role of, 379–380
  - early squamous cell cancers, 365, 366*f*
  - endoscopic palliation, 381–382, 381*f*
  - endoscopic resection, recommendation for, 366*f*
  - high-grade dysplasia and early adenocarcinoma
    - endoscopic therapies, 366–367
    - esophagectomy, 367
    - intensive surveillance, 366
    - overview, 366
  - perioperative care and postoperative morbidity and mortality, 376
  - stage-directed therapy, 365
  - surgical resection
    - overview, 368
    - patient selection for esophagectomy, 368
    - surgical approaches
      - abdominal esophagus and gastric cardia tumors, 369
      - Barrett's adenocarcinoma, 373–374
      - cervical esophageal cancer, 368
      - extent of lymphadenectomy: squamous cell cancers, 371–373, 371*f*–373*f*
      - extent of resection: axial and lateral margin, 370
      - gastric cardia cancers, 374
      - intrathoracic esophageal cancer, 368–369
  - minimally invasive surgery, 369–370
  - overview, 368
  - reconstruction after esophagectomy, 374–376, 375*f*
  - transthoracic versus transhiatal resection, 369
  - video-assisted thoracic surgery of minimally invasive esophagectomy
    - outcomes and complications, 426–427, 426*t*
    - overview, 416–417
    - molecular staging, 416
    - operative technique
      - laparoscopic phase, 417–423, 418*f*–422*f*
      - overview, 417
      - thoracoscopic phase, 423–425, 423*f*–425*f*
    - outcomes of minimally invasive thoracoscopic resection for leiomyoma, 429
    - overview, 414
    - resection of esophageal leiomyoma, 427–428
    - staging, 414
    - technique of minimally invasive surgical staging
      - operative steps of laparoscopy, 415, 415*f*
      - operative steps of thoracoscopy, 415–416, 416*f*
      - overview, 414
    - technique of resection, 428, 428*f*–429*f*
- tumor staging
- methods of
    - barium contrast study, 361–362, 363*f*
    - bronchoscopy, 362
    - computer tomography scan, 362–363, 363*f*
    - endoscopic ultrasound, 363–364, 365*f*
    - FDG-PET scans, 363*f*; 364–365
    - laparoscopy, 365
    - overview, 361
    - percutaneous ultrasound, 364
    - thoracoscopy, 365
  - staging system, 359–361
    - Japan Esophageal Society, 361, 362*t*
    - Siewert's classification, 361, 362*f*
    - tumor-node-metastasis system, 359–361, 359*t*–360*t*, 360*f*–361*f*
- Cancer, gallbladder, 82–84, 83*f*, 83*t*
- adjuvant therapies, 1065
  - clinical presentation and diagnosis, 1062–1063, 1063*f*
  - epidemiology, 1061, 1062*t*
  - outcomes, 1066
  - overview, 1090, 1093
  - palliation, 1065–1066, 1066*f*
  - pathogenesis and pathology, 1061–1062, 1062*t*
  - surgical therapy
    - overview, 1063
    - stage II, 1064
    - stage III, 1064
    - stage IV, 1064
    - stages 0 and I, 1063–1064
    - technique, 1064–1065, 1065*f*

- Cancer, gastric, 80–82, 81*f*  
 curative surgery  
 laparoscope-assisted gastrectomy  
 overview, 489  
 surgical technique  
 anatomy of stomach, 490, 490*f*  
 nodal dissection, 490–491, 491*f*  
 reconstruction, 491  
 safe surgical margin, 489  
 theoretical background, 489
- Cancer, laparoscopic staging and approaches to.  
*See* Staging, laparoscopic
- Cancer, liver. *See* Colorectal metastasis; Liver,  
 primary neoplasms of
- Cancer, pancreas, and other periampullary cancers  
 adjuvant therapy, 1204–1205  
 clinicopathologic staging, 1195  
 complications following  
 pancreaticoduodenectomy,  
 1203–1204  
 diagnosis and preoperative evaluation  
 clinical presentation, 1189–1190  
 imaging studies, 1190–1193, 1191*f*–1194*f*,  
 1227–1228, 1228*f*  
 overview, 1189  
 preoperative biliary decompression, 1194  
 preoperative staging, 1194–1195, 1195*f*  
 tissue diagnosis, 1193–1194  
 distal pancreatectomy for pancreatic cancer in  
 body or tail, 1199–1200  
 environmental risk factors  
 genetic alterations, 1189  
 hereditary risk factors, 1188–1189  
 overview, 1188  
 etiology  
 genetic alterations in pancreatic cancer, 1231  
 overview, 1230–1231  
 incidence, 1187  
 long-term survival after resection of  
 periampullary cancers, 1203–1204,  
 1203*f*–1205*f*  
 neoadjuvant therapy, 1205–1206, 1206*t*, 1231  
 nonoperative palliation  
 duodenal obstruction, 1202  
 obstructive jaundice, 1202, 1202*f*  
 overview, 1201–1202  
 palliation of pain, 1203  
 novel agents in pancreatic cancer  
 angiogenesis inhibitors, 1206–1207  
 epidermal growth factor receptor family, 1207  
 immunotherapy, 1206  
*K-ras* inhibitors, 1207  
 overview, 1206  
 operative palliation  
 chemical splanchnicectomy for pain, 1201  
 duodenal obstruction, 1201  
 obstructive jaundice, 1200–1201  
 overview, 1200, 1200*f*–1201*f*  
 overview, 1187, 1207, 1227  
 palliative chemotherapy, 1228, 1231  
 pathology, 1187–1188  
 periampullary cancers, resection of  
 pancreaticoduodenectomy (Whipple  
 procedure), 1196–1199,  
 1196*f*–1198*f*
- staging  
 carbohydrate antigen 19–9, 85, 86*f*  
 laparoscopic ultrasonography, 85–86, 86*f*  
 locally advanced disease, 87  
 overview, 84–85, 84*f*; 85*t*  
 peritoneal cytology, 86–87  
 surgery for exocrine neoplasms  
 complications, 1234  
 diagnosis, 1234–1235  
 overview, 1233–1234  
 surveillance, 1235  
 surgical treatment  
 pancreatectomy, 1229–1230  
 pancreaticoduodenectomy, 1228–1229
- Cancer, rectum  
 abdominoperineal resection (APR)  
 complications, 860  
 overview, 856–857  
 perineal dissection, 857, 858*f*–859*f*  
 postoperative care, 860  
 technique, 857  
 anatomy  
 anatomic landmarks, 835–836, 835*f*, 875  
 fascial planes, 837–838, 838*f*  
 innervation, 837, 837*f*  
 lymphatic drainage, 836–837, 837*f*  
 vascular supply, 836, 836*f*  
 chemoradiation  
 adjuvant chemoradiation, 864  
 neoadjuvant chemoradiation, 864–865,  
 865*t*, 872  
 overview, 864  
 choosing the surgical approach  
 local excision, 869–870  
 minimally invasive total mesorectal excision,  
 871–872  
 overview, 869  
 total mesorectal excision, 870–871  
 complications, 862–863  
 cryotherapy, 862  
 diagnosis and evaluation  
 history, 838–839  
 overview, 838  
 physical examination, 839  
 preoperative staging  
 endoluminal ultrasound  
 N stage, 840  
 overview, 840, 840*f*  
 T stage, 840, 840*f*; 840*t*  
 laboratory studies, 839–840  
 MRI, 841, 841*t*  
 overview, 839  
 PET, 841  
 electrocoagulation, 862  
 en bloc excision with rectum  
 pelvic exenteration, 861, 861*f*  
 posterior vaginectomy, 860, 860*f*  
 prophylactic bilateral oophorectomy, 861  
 prostatectomy, 861  
 endocavitary radiation, 862  
 etiology and risk factors, 833–834  
 history, 833  
 incidence, 833  
 laparoscopic surgery, 770, 862  
 laser vaporization, 862
- local excision, 876  
 oncologic results, 844–845, 844*t*  
 patient selection and choice of operation,  
 845–846, 845*t*  
 technique, 846  
 transanal endoscopic microsurgery, 847–848  
 transanal excision, 846, 846*f*  
 transcoccygeal excision, 846–847, 847*f*  
 low anterior resection with total mesorectal  
 excision  
 coloanal anastomosis  
 colonic pouch, 856  
 overview, 856  
 transverse coloplasty, 856  
 diverting loop ileostomy, 856  
 lateral nodal dissection, 849–850, 850*t*  
 oncologic results, 848–849, 849*f*  
 overview, 850–851, 851*f*–852*f*, 853, 854*f*  
 postoperative care, 856  
 quality of life, 850  
 reconstruction: double-stapling technique,  
 853–855, 855*f*  
 technique of total mesorectal excision  
 closure, 856  
 drain placement, 856  
 transection point, 853, 853*f*
- obstructing, metastatic, and recurrent  
 metastatic, 863  
 obstructing, 863  
 recurrent  
 intraoperative radiation therapy, 863  
 overview, 863  
 palliation, 864  
 overview, 869  
 palliative resection in stage IV disease, 861–862  
 patient evaluation, 869  
 patients with metastatic disease, 872–873  
 perioperative management, 875–876  
 photodynamic therapy, 862  
 polyps, 834–835, 834*f*  
 postoperative care, 877  
 preoperative assessment, 875  
 quality of life, 876–877  
 surgical technique, 877  
 surveillance, 865–866  
 TNM staging, 841–842, 842*t*, 843*t*, 875  
 treatment principles  
 bowel preparation, 842–843  
 overview, 842, 843*t*  
 resection margins  
 distal, 843–844  
 radial, 844  
 surgical goals, 843
- Capnothorax, 73  
 Capsule endoscopy, 670  
 Carbon dioxide embolus, 73  
 Carcinoid tumors, appendix, 641  
 Carcinoid tumors, colon, 746  
 Carcinoid tumors, small intestine  
 carcinoid syndrome, 618–619  
 clinical presentation, 617  
 diagnosis, 617, 618*f*  
 overview, 617  
 staging and prognosis, 617–618  
 Carcinoma, esophageal, 78–80, 79*t*

- Carcinoma, hepatocellular, 933–934  
 clinical presentation, 936, 937f  
 diagnosis  
   determination of functional liver reserve, 938, 938t  
   extent of disease evaluation, 937–938  
   overview, 937  
   verification of diagnosis, 937  
 epidemiology and etiology, 934, 934t, 970–971  
 palliative treatment modalities, 943  
 pathology, 934–936, 935f, 936t  
 potentially curative treatments  
   adjuvant therapy, 941–942  
   medical therapy, 971  
   neoadjuvant treatment, 940–941  
   overview, 938  
   partial hepatectomy, 938–940, 939f–941f, 939t  
   surgical approach, 970–971, 978–979  
   total hepatectomy and liver transplantation, 942–943, 942t
- Cardiac evaluation  
 arrhythmia, 12  
 congestive heart failure, 12  
 coronary disease, 11–12  
 risk assessment, 9–11, 9t–10t, 11f  
 valvular disease, 12–14, 13t
- CARD15/NOD2* gene, 666
- Caroli's disease, 943
- CDAI (Crohn's Disease Activity Index), 687
- CDD (choledochoduodenostomy), 1019–1021, 1086–1087, 1086f
- Cecal disease, 684
- Cecostomy, 165, 167f
- Celiac artery aneurysms, 285
- Celiac disease, 612
- Certified Wound Ostomy Continence Nurse (CWCN), 163–164
- Cervical esophageal cancer, 368
- Chemical splanchnicectomy for pain, 1201
- Child-Pugh classification, 938, 938t, 983, 983t
- Chlamydial infections, 830
- Cholangiocarcinoma  
 intrahepatic  
   epidemiology and etiology  
     choledochal cysts/Caroli's disease, 943  
     overview, 943  
   pathology and classification, 944  
   primary sclerosing cholangitis, 943  
   pyogenic cholangiohepatitis and other hepatic infections, 943–944  
   treatment  
     chemotherapy, 945  
     partial hepatectomy, 944  
     total hepatectomy and liver transplantation, 944–945  
   overview, 1090, 1093–1094  
   treatment, 971
- Cholangiography, 1078, 1078f
- Cholangitis  
 clinical presentation and diagnosis, 1021–1022  
 overview, 1021  
 pathophysiology, 1021  
 primary sclerosing  
   diagnosis, 1055, 1055f  
   management, 1055–1056, 1056f  
   overview, 1054, 1056  
   pathogenesis, 1054–1055  
   presentation, 1055  
   treatment, 1022–1024
- Cholecystectomy, 1015–1016  
 advantages, 1003, 1003t  
 complications  
   laparoscopic cholecystectomy, 1005–1006, 1005t  
   open cholecystectomy, 1006  
 contraindications to laparoscopic cholecystectomy, 996–997, 997t  
 disadvantages, 1003, 1003t  
 indications, 995–996, 996t  
 new and investigational techniques to perform  
   natural orifice transluminal endoscopic surgery, 1007  
   overview, 1006  
   single-port laparoscopic surgery, 1007  
 operative technique  
   anatomy, 997–998, 998f  
   completion, 1001–1003, 1001f–1002f  
   laparoscopic cholecystectomy  
     culture of, 1092  
     dissection, 1000, 1000f  
     intraoperative evaluation for choledocholithiasis, 1001  
     operating room set-up, 999, 999f  
     overview, 1089, 1092  
     pneumoperitoneum, 999  
     port placement and exposure, 999–1000, 999f  
     the rationale of the “critical view of safety,” 1092  
     vasculobiliary injuries, 1092–1093  
   patient preparation, 998  
 overview, 995, 1007  
 results of series  
 special considerations  
   acute cholecystitis, 1004–1005  
   conversion to open operation, 1003  
   intraoperative gallbladder perforation, 1005  
   open cholecystectomy, 1003–1004
- Cholecystitis, acute, 1004–1005
- Cholecystojejunostomy, 1084–1086, 1084f–1085f, 1084t
- Choledochal cyst, 943  
 classification, 1029–1030, 1030t, 1031f  
 diagnosis, 1032–1033, 1032f–1033f  
 management  
   operative  
     overview, 1034, 1087, 1087t  
     results, 1037  
     type I cysts, 1034–1036, 1035f  
     type II cysts, 1036  
     type III cysts, 1036  
     type IV cysts, 1036  
     type V cysts, 1036–1037  
   overview, 1033–1034  
 overview, 1029, 1037, 1090, 1093  
 pathogenesis, 1030–1031, 1032f  
 presentation, 1031–1032
- Choledochoduodenostomy (CDD), 1019–1021, 1086–1087, 1086f
- Choledocholithiasis, 1001  
 classification and epidemiology, 1009  
 clinical presentation and natural history, 1009–1010  
 evaluation and management  
   intraoperative, 1016–1018, 1023f  
   overview, 1010  
   postoperative, 1018–1019, 1018f  
   preoperative, 1010–1016, 1011f, 1022f  
   surgical biliary drainage procedures, 1019–1021  
 overview, 1009, 1021, 1089–1090, 1093
- Choledochotomy, laparoscopic, 1082–1083, 1083f
- Cholestasis, 1140
- Chromoendoscopy, 31
- Chronic appendicitis, 640
- Clonorchis sinensis*, 1009, 1053, 1067
- Closures  
 fascia  
   mass closure of abdomen, 112, 112f  
   overview, 111–112  
 laparoscopic incision, 113–114  
 mesh and biologic implant placement of, 113  
 overview, 111  
 retention suture, 113  
 skin, 113  
 temporary, 114–115, 115f
- Colectomy  
 ileorectal anastomosis and, 704  
 complications  
   anastomotic leak, 714  
   cancer in rectal remnant, 714  
   long-term outcome, 719  
 sigmoid  
   anastomosis, 782–783  
   mobilization of distal sigmoid colon and upper rectum, 781–782, 782f  
   mobilization of proximal sigmoid and descending colon, 781  
   patient position, 780–781  
   port placement and exploration, 781, 782f  
   vascular ligation and exteriorization, 782, 782f, 783f  
 subtotal with ileorectal anastomosis  
   exteriorization of the colon and division of the vasculature, 790  
   formation of ileorectal anastomosis, 790  
   mobilization of the colon, 790  
   patient position and room setup, 790  
   port placement and exploration, 790  
 transverse  
   mobilization of the hepatic flexure, 784  
   mobilization of the splenic flexure, 784  
   mobilization of the transverse colon, 784  
   patient position and room setup, 783  
   port placement and exploration, 783–784  
   vascular division, exteriorization, and anastomosis, 784
- Colitis, ulcerative. *See* Ulcerative colitis
- Coloanal anastomosis, 856
- Colocutaneous fistula, 652
- Coloenteric fistula, 652

- Colon, tumors of
- clinical presentation of colorectal cancer
    - history and physical examination, 749–750
    - investigations
      - complete evaluation of large intestine
        - colonoscopy, 750
        - contrast enema, 750
        - evolving techniques, 750–751
        - overview, 750
        - rigid proctoscopy and flexible sigmoidoscopy, 750
      - evaluation of local tumor extent and metastatic dissemination, 751
      - laboratory and preoperative tests, 751
      - overview, 750
      - symptoms and differential diagnosis, 749, 749*t*
  - epidemiology, 731
  - hereditary and nonhereditary colon tumors
    - hereditary
      - familial adenomatous polyposis, 738
      - hamartomatous polyposis syndromes
        - Bannayan-Riley-Ruvalcaba syndrome, 740
        - Cowden syndrome, 740
        - Cronkite-Canada syndrome, 740
        - juvenile polyposis syndrome, 740
        - overview, 739
        - Peutz-Jeghers syndrome, 740
      - hereditary nonpolyposis colon cancers (HNPCC), 738–739, 739*t*
    - nonhereditary
      - familial colon cancer, 738
      - sporadic colon cancer, 738
  - issues specific to laparoscopic surgery, 770
  - overview, 731, 732*t*
  - pathogenesis
    - adenoma-carcinoma model, 737, 737*f*
    - genetics, 736–737
    - overview, 736
  - pathology and staging
    - carcinoma
      - overview, 744*t*
      - staging, 745*t*–746*t*
    - malignant tumors of
      - adenocarcinoma, 744–745
      - overview, 744
      - staging, 745
    - nonepithelial tumors
      - benign nonepithelial tumors
        - lipomas and lipomatous polyposis, 745–746
      - malignant nonepithelial tumors
        - Kaposi's sarcoma, 747
        - lymphoma, 747
        - smooth muscle tumors, 747
      - potentially malignant nonepithelial tumors
        - carcinoid or neuroendocrine tumors, 746
        - gastrointestinal stromal tumors (GISTs), 746–747
        - nodular lymphoid hyperplasia, 747
      - secondary tumors to colon
        - endometriosis, 747
        - invasion from extracolonic cancers, 747
        - metastatic cancer, 747–748
  - polyps
    - architecture
      - adenomatous polyps (adenomas), 741–742, 741*t*, 742*f*
      - hamartomatous polyp, 742–743
      - hyperplastic polyps, 743
      - overview, 741
    - attachment to bowel wall, 741
    - inflammatory, 743
    - management, 743–744
    - overview, 740–741
    - size, 741
    - transformation, 743
  - risk factors
    - extrinsic risk factors
      - aspirin and COX-2 inhibitors, 734
      - calcium, vitamins, and micronutrients, 733–734
      - cholecystectomy and bile acids, 734
      - dietary fiber, meat, and fat, 733
      - miscellaneous factors, 735
      - smoking and alcohol consumption, 734
    - intrinsic risk factors
      - inflammatory bowel disease, 735, 735*t*, 736*f*
      - miscellaneous factors, 736
      - personal and family history, 735, 735*t*
      - overview, 732–733, 733*t*, 734*t*
      - prevention and screening, 736
  - surgical anatomy of colon, 748, 748*f*
  - treatment
    - preparation for surgery
      - antibiotic prophylaxis, 752–753
      - bowel cleansing, 752
      - nasogastric tube, 753
      - preemptive pain management, 753
      - preoperative marking of ostomy site, 753
      - thromboembolic prophylaxis, 753
      - transfusion, 752
      - urinary catheters/stents, 753
    - principles, 751–754, 754*t*
    - surgery
      - adjuvant chemotherapy and radiotherapy, 759–760
      - colon resection, 755–756
      - complications of surgery, 758–759
      - drains, 756
      - exploration, 755
      - incision, 754–755
      - laparotomy versus laparoscopy, 756–757
      - outcome and prognosis, 760, 760*t*
      - positioning, 754
      - postoperative management, 758
      - reconstruction/diversion, 756
      - sentinel lymph node mapping, 757
  - treatment
    - surgery
      - advanced disease management
        - inoperable disseminated disease, 758
        - locally advanced disease, 758
        - operable metastases, 758
      - emergency surgery
        - massive colonic bleeding, 758
        - overview, 757
        - tumor obstruction, 757–758
        - tumor-related perforation, 758
  - Colonic decompression, 57–58
  - Colonic fistulas, 205
  - Colonic interposition
    - left colon, 404–405, 404*f*–405*f*
    - overview, 404
    - right colon, 405–406
  - Colonic pouch, 856
  - Colonic volvulus
    - complications, 659
    - epidemiology, 658
    - etiology, 658
    - investigations, 659, 659*f*–660*f*
    - management, 659–661, 661*f*
    - morphologic features, 658
    - overview, 658, 661
    - presentation, 659
  - Colonoscopy, 53*t*, 54–55, 54*f*–55*f*; 750
  - Colorectal cancer. *See* Cancer, colorectal
  - Colorectal metastasis
    - ablative therapies, 963–964, 964*f*
    - intraoperative assessment tools
      - intraoperative ultrasonography, 956, 957*f*
      - laparoscopic, 956
    - overview, 955, 965, 971
    - patient evaluation, preoperative, 955–956
    - pumps, implantable
      - complications, 972, 976–977
      - indications, 977
      - overview, 976
      - technique of implantation, 977
    - radiofrequency ablation, 972, 977–978
    - regional chemotherapy: hepatic arterial infusion, 964–965
  - resection
    - Couinaud's segments, 974*f*, 974*t*
    - indications, 971
    - with intraoperative ultrasound, 972, 973
    - overview, 956–957, 973
    - patient selection, 957–958
    - portal vein embolization and, 972
    - in presence of extrahepatic colorectal metastases, 959–960
    - prognostic factors following, 959
    - results, 958–959, 959*t*, 971–972
    - saline-linked radiofrequency device, 974–975
    - technique, 958
      - left hepatectomy, 975–976, 976*f*–977*f*
      - right hepatectomy, 973–975, 974*f*–975*f*
  - systemic chemotherapy
    - overview, 960
    - perioperative chemotherapy
      - converting unresectable to resectable disease with, 962, 963*f*
      - initially resectable patient, 961–962, 961*f*, 961*t*, 962*f*
    - postoperative adjuvant chemotherapy, 960–961



- Colorectal surgery  
 complications, 792, 792*t*–793*t*  
 future considerations—robotics, 793–794  
 general technical information  
   equipment and instruments  
     overview, 771, 771*t*, 772*f*  
     patient position and room setup, 771–772, 773*f*  
     port placement technique, 772  
     special devices in, 771  
     wound closure, 773  
 left hemicolectomy  
   mobilization of left colon, 778  
   mobilization of splenic flexure, 778  
   overview, 778  
   patient position and room setup, 778  
   port placement and exploration, 778, 778*f*  
   vascular division, exteriorization, and anastomosis, 778  
 right hemicolectomy  
   anastomosis, 775, 777  
   exteriorization, 775, 777*f*  
   mobilization of cecum, 774, 775*f*  
   mobilization of hepatic flexure, 774, 776*f*  
   patient position and room setup, 774  
   port placement and exploration, 774–775, 774*f*  
   vascular division, 774–775, 776*f*  
 hand-assisted  
 left hemicolectomy  
   patient position and room setup, 780, 780*f*–781*f*  
 sigmoid colectomy  
   anastomosis, 782–783  
   mobilization of distal sigmoid colon and upper rectum, 781–782, 782*f*  
   mobilization of proximal sigmoid and descending colon, 781  
   patient position, 780–781  
   port placement and exploration, 781, 782*f*  
   vascular ligation and exteriorization, 782, 782*f*, 783*f*  
 sigmoidectomy, 783  
 transverse colectomy  
   mobilization of the hepatic flexure, 784  
   mobilization of the splenic flexure, 784  
   mobilization of the transverse colon, 784  
   patient position and room setup, 783  
   port placement and exploration, 783–784  
   vascular division, exteriorization, and anastomosis, 784  
 learning curve and credentialing, 793  
 overview, 767, 768*t*  
 patient selection  
   indications, contraindications, evaluations  
     contraindications, 768–769, 768*t*  
     indications, 767–768, 768*t*  
   intraoperative evaluation and reasons for conversion, 769  
   oncologic issues, 770  
   overview, 767, 770–771  
   preoperative evaluation, 769  
 resection rectopexy  
   division of the rectum and anastomosis, 789  
   mobilization of the rectosigmoid, 789  
   mobilization of the rectum, 789  
   patient position and room setup, 789  
   port placement and exploration, 789  
   rectopexy, 789  
   vascular ligation, 789  
 restorative total proctocolectomy  
   ileal J-pouch—anal anastomosis  
     colon mobilization, 790–791  
     exteriorization of colon and rectum, 791  
     formation of, 791–792, 792*f*  
     formation of loop ileostomy, 792  
     hand-assisted, 792  
     patient position and room setup, 790  
     port placement and exploration, 790, 791*f*  
     rectal mobilization, 791  
 right hemicolectomy, alternative technique for, 777–778  
 subtotal colectomy with ileorectal anastomosis  
   exteriorization of the colon and division of the vasculature, 790  
   formation of ileorectal anastomosis, 790  
   mobilization of the colon, 790  
   patient position and room setup, 790  
   port placement and exploration, 790  
 Colostomy  
 complications  
   colostomy necrosis, 174  
   colostomy perforation, 174  
   colostomy prolapse, 174  
   general, 173  
   paracolostomy hernia, 174  
   stoma stricture, 173–174  
 location, determination of, 164  
 long-term management  
   irrigation, 173  
   overview, 173  
 overview, 164  
 type by anatomic location, 164  
 type by function  
   decompressing colostomy  
     “blow-hole,” 166*f*  
     closure of temporary colostomy, 169, 170*f*  
     loop-transverse colostomy, 165, 168*f*, 169  
     overview, 164–165  
     tube cecostomy, 165, 167*f*  
   diverting colostomy  
     choices for construction, 169–171  
     end colostomy construction, 171–173, 172*f*  
     overview, 169  
   overview, 164  
 Colovaginal fistula, 652–653  
 Colovesical fistula, 652  
 Computed tomography (CT)  
   blunt abdominal trauma, 248–250, 248*t*–249*t*  
   colonography, 750–751, 798  
   enterography, 670–671  
 Computer-assisted remote mechanical devices, 6  
 Confocal fluorescence microendoscopy, 32  
 Congenital liver cysts  
   polycystic, 921–922, 922*f*  
   simple, 920–921, 921*f*, 921*t*  
 Contact thermal techniques, 38, 38*f*  
 Continent ileostomy  
   construction, 186–190, 187*f*–190*f*  
   overview, 185  
 Contrast enema, 750  
 Contrast-enhanced computed tomography, 1099–1101  
 Cooper ligament repair, 131  
 Coronary artery bypass grafting (CABG), 11–12  
 Corticosteroids, for Crohn's disease, 671  
 Cortisol-producing adrenal adenoma, 1272  
 Couinaud's segments, 974*f*  
 Cowden syndrome, 740  
 Crohn's colitis, 668  
 Crohn's disease  
   bowel obstruction and, 593  
   clinical presentation  
     location of disease  
       Crohn's colitis, 668  
       esophageal, 667–668  
       extraintestinal, 668  
       gastroduodenal, 668  
       overview, 667  
       perineal, 668  
       small intestine, 668  
   overview, 667  
   patterns of disease  
     inflammatory pattern, 667  
     overview, 667  
     perforating pattern, 667  
     stricturing pattern, 667  
 complications, management of  
   colon  
     cecal disease, 684  
     extensive colitis with rectal sparing, 684  
     overview, 684, 684*f*  
     perianal disease, 686–687, 686*f*  
     proctitis, 685  
     proctocolitis, 685  
     right-sided colitis, 684  
     segmental colitis, 685–686  
   duodenum, 681–682, 681*f*  
   recurrent disease, 687–688  
   small bowel  
     abscess, 683, 683*f*  
     complete intestinal obstruction, 682  
     enterovaginal and enterocutaneous fistulas, 683  
     hemorrhage, 684  
     ileosigmoid fistulas, 682, 682*f*  
     ileovesical fistula, 682–683  
     perforation, 683–684  
 diagnosis  
   history and physical examination, 668–669  
   imaging  
     capsule endoscopy, 670  
     computed tomography, 670–671  
     endoscopy, 670  
     small bowel radiography, 669–670, 669*f*–670*f*  
   overview, 668  
 differential diagnosis, 671  
 epidemiology, 665–666  
 etiology, 666, 725, 727  
 history, 665  
 medical management  
   corticosteroids, 671  
   5-aminosalicylic acid, 671–672

- immunomodulators (azathioprine and 6-mercaptopurine), 672
- infliximab, 672, 725–726, 727–728
- miscellaneous medical therapies, 672
- overview, 671
- versus surgical treatment, 725–726
- operative management, 729
- overview, 665
- pathology, 666–667
- postoperative maintenance therapy, 688
- postresection prophylaxis, 726
- small intestinal tumors and, 612
- surgical treatment
- versus early medical treatment, 725–726
  - indications for surgery
    - abscesses and inflammatory masses, 673
    - cancer, 674
    - failure of medical treatment, 673
    - fistulas, 673
    - growth retardation, 674
    - hemorrhage, 674
    - intestinal obstruction, 673
    - perforation, 673–674
  - laparoscopy, 678–681
  - overview, 672
  - preoperative preparation and evaluation, 674–675
  - surgical options
    - anastomosis, 675–676
    - bypass procedures, 676
    - intestinal resection, 675, 675*f*
    - laparoscopy, 679*f*–681*f*; 729
    - stoma formation, 676
    - strictureplasty, 676–678, 676*f*–678*f*
- Crohn's Disease Activity Index (CDAI), 687
- Cronkite-Canada syndrome, 740
- Crural repair, 295, 296–297, 297*f*
- Cryoreductive surgery, for gastrointestinal stromas, 500–502
- Cuffitis, 716–717
- Cullen's sign, 1131
- CWOCN (Certified Wound Ostomy Continence Nurse), 163–164
- Cyst, adrenal, 1272
- Cyst, choledochal, 943
- classification, 1029–1030, 1030*t*, 1031*f*
- diagnosis, 1032–1033, 1032*f*–1033*f*
- management
- operative
    - overview, 1034, 1087, 1087*t*
    - results, 1037
    - type I cysts, 1034–1036, 1035*f*
    - type II cysts, 1036
    - type III cysts, 1036
    - type IV cysts, 1036
    - type V cysts, 1036–1037
  - overview, 1033–1034
- overview, 1029, 1037
- pathogenesis, 1030–1031, 1032*f*
- presentation, 1031–1032
- Cyst, liver. *See* Hepatic abscess and cystic disease
- Cystadenocarcinoma, 923–924, 924*f*
- Cystadenoma, 922–923, 923*f*; 924*t*
- Cystic acinar cell neoplasms, 1184
- Cystic degeneration of ductal adenocarcinoma, 1184
- Cystic neoplasms and pseudomyxoma peritonei, appendix, 640–641, 640*f*–641*f*
- Cystic neuroendocrine neoplasms, 1184
- D**
- DALM (dysplasia-associated lesion or mass), 697
- DBE (double balloon endoscopy) system, 52
- DCC gene, 737
- Débridement, pancreatic
- closed drainage and, 1112*f*
  - comparison of techniques, 1113–1114
  - continuous closed postoperative lavage of lesser sac and, 1112–1113
  - minimally invasive approaches, 1114–1115
  - overview, 1108*t*, 1109
  - techniques, 1109–1112, 1109*f*–1111*f*
    - closed drainage and, 1110
    - open drainage for pancreatic necrosis, 1111–1112
- Decompressing colostomy
- “blow-hole,” 166*f*
  - closure of temporary colostomy, 169, 170*f*
  - loop-transverse colostomy, 165, 168*f*; 169
  - overview, 164–165
  - tube cecostomy, 165, 167*f*
- Defecography grading system, 812*t*
- D'Egidio classification of pancreatic pseudocysts, 1122, 1123*t*
- Delirium and pain, management of, 7
- epidural analgesia, 7–8
  - NSAIDs, analgesia with, 8
  - opioid analgesia, 7
    - postoperative delirium, 8–9, 8*t*
- Dentate line, 804, 805*f*; 879, 880*f*
- Diabetes mellitus, surgery and, 579
- Diagnostic peritoneal lavage (DPL), 247, 247*t*
- “Diamond of success” for laparoscopic port placement, 64, 65*f*
- Dieulafoy's lesion, 226, 458–459
- Diffuse esophageal spasm, 332
- Direct coupling, 71
- Direct percutaneous endoscopic jejunostomy tube
- endoscopic dilation, 43–44
  - foreign body extraction, 43, 44*f*
  - overview, 43
- Distal gastrectomy, 471–474, 471*f*–473*f*
- Distal gastric resections and reconstructions
- laparoscopic approaches
    - anterior proximal vagotomy or seromyotomy, 539*f*–540*f*; 540
    - gastric resection, 541–542, 541*f*–542*f*
    - patient and port placement, 538, 538*f*
    - truncal vagotomy, 538*f*–540*f*; 539–540
    - to vagus nerve, 536, 538
  - subtotal and total gastric resections
    - overview, 529
    - subtotal and near-total resections, 529–530
    - total gastrectomy for carcinoma, 531–535, 532*f*–536*f*
  - vagotomy and antrectomy
    - Billroth-I reconstruction, 523–524
    - Billroth-II reconstruction, 524–529, 526*f*–531*f*
    - overview, 522
- Distal splenorenal shunt (DSRS), 986, 986*f*
- Diverticula, esophageal
- epiphrenic diverticula
    - laparoscopic epiphrenic diverticulectomy, 314, 315*f*
    - overview, 312–313, 314–315, 314*f*
    - treatment, 313–314
  - overview, 310
- Zenker's diverticulum
- operative technique
    - endoscopic treatment, 311–312
    - open cervical diverticulectomy, 311, 312*f*–313*f*
  - overview, 310
  - treatment, 310–311
- Diverticula, gastric, 459
- Diverticular disease of the colon, 231–232, 231*f*
- classification of diverticulitis, 655
  - etiology, 649–650
  - history, 649
  - investigations, 655, 655*f*
  - management
    - elective surgery, 656–657
    - emergent acute diverticulitis with generalized peritonitis, 657
    - emergent acute diverticulitis with localized peritonitis, 657
    - laparoscopic surgery, 657–658
    - overview, 655–656
  - morphologic features, 650–651, 650*f*–651*f*
  - overview, 649, 658
  - presentation
    - complications
      - abscess, 654, 654*f*
      - bleeding, 653, 653*f*
      - cancer, 655
      - fistula, 652
      - free perforation, 652
      - giant colonic diverticulum, 654–655
      - obstruction, 654, 654*f*
    - overview, 651, 652*f*
- Diverticulectomy
- laparoscopic epiphrenic, 314, 315*f*
  - open cervical, 311, 312*f*–313*f*
- Diverting colostomy
- choices for construction, 169–171
  - end colostomy construction, 171–173, 172*f*
  - overview, 169
- Diverting loop ileostomy, 856
- Dor fundoplication, 335*f*; 338–339
- Dormia basket, 1011–1012
- Double balloon endoscopy (DBE) system, 52
- DPL (diagnostic peritoneal lavage), 247, 247*t*
- DSRS (distal splenorenal shunt), 986, 986*f*
- Dumping, 455, 455*t*
- Duodenal diverticula, 642
- Duodenal fistulas, 204
- Duodenal obstruction, 1201
- Duodenal switch (DS)
- complications, 571–572
  - follow-up, 571
  - operative procedure, 568*f*; 570, 570*f*–571*f*
  - outcomes, 571
  - overview, 570
  - postoperative care, 570–571
- Duodenum, Crohn's disease of, 681–682, 681*f*

- Dysphagia, 319  
 Dysphagia, esophageal, 319  
 Dysphagia, oropharyngeal, 319  
 Dysplasia-associated lesion or mass (DALM), 697
- E**
- Echinococcus granulosus*, 913*f*, 914, 915  
*Echinococcus multilocularis*, 914, 915, 917, 919  
*Edwin Smith Surgical Papyrus, The*, 3  
 EGD (esophagogastroduodenoscopy), 35–36, 35*t*, 221  
 EGFR (epidermal growth factor receptor), 1207  
 Electrohydraulic lithotripsy, 1012  
 Electromyography, 807, 807*f*  
 Elliptocytosis, hereditary, 1250  
 End ileostomy, 175–176, 177*f*, 178  
 Endocarditis prophylaxis recommendations, 13–14, 13*t*  
 Endocavitary radiation, 862  
 EndoCinch device, 45  
 Endocrine tumors of the pancreas  
   diagnosis  
     gastrinoma, 1215–1216, 1215*f*, 1216*t*  
     glucagonoma, 1217, 1217*f*  
     insulinoma, 1214, 1215*f*  
     miscellaneous tumors, 1218  
     nonfunctional neuroendocrine tumors, 1218  
     somatostatinoma, 1218  
     VIPoma, 1216–1217, 1217*t*  
   genetics, 1212–1214  
   histology, 1211, 1213*f*  
   history, 1212, 1213*f*, 1213*t*  
   imaging and localization  
     algorithms for localization, 1221–1222, 1221*f*–1222*f*  
     modalities, 1218–1221, 1219*f*–1221*f*  
   management  
     gastrinoma, 1223–1224, 1224*f*  
     insulinoma, 1222–1223, 1222*f*–1223*f*  
     VIPomas, glucagonomas, somatostatinomas, and nonfunctional, 1224–1225  
   overview, 1211, 1225  
   pathology, anatomy and physiology, 1211, 1212*f*, 1212*t*  
 Endometriosis, 747  
 Endoprosthesis insertion, 49–50, 49*f*–51*f*  
 Endoscopic band placement, 39  
 Endoscopic clipping, 39, 39*f*  
 Endoscopic dilation, 43–44  
 Endoscopic mucosal resection  
   mucosal ablation, 41  
   overview, 39–40  
   saline lift technique, 40, 40*f*  
   submucosal dissection, 41  
   “suck-and-cut” technique, 40  
   “suck-and-ligate” technique, 40–41  
 Endoscopic pseudocyst drainage/necrosectomy, 51  
 Endoscopic retrograde cholangiopancreatography (ERCP)  
   in acute pancreatitis, 1103  
   history, 46  
   indications, 46, 46*t*  
   patient preparation, 46  
   post-ERCP complications, pancreatitis, 51–52  
   techniques of, 46–47  
   therapeutic interventions  
     cholangitis, acute, 49  
     choledocholithiasis, 47–48, 48*f*  
     endoprosthesis insertion, 49–50, 49*f*–51*f*  
     endoscopic pseudocyst drainage/necrosectomy, 51  
     gallstone pancreatitis, acute, 49  
     pancreatic duct stones, 50  
     sphincter of Oddi, 48–49  
     sphincterotomy, 47, 47*f*–48*f*  
 Endoscopic suture placement, 39  
 Endoscopy. *See also* Endoscopic retrograde cholangiopancreatography  
 flexible endoscope  
   endoscope anatomy  
     overview, 33–34  
     shape-locking device, 34  
     variable stiffness endoscopes, 34, 34*f*  
   endoscopic education, 34  
   image documentation, 33  
   imaging, 31  
   imaging advances  
     autofluorescence endoscopy, 32–33  
     chromoendoscopy, 31  
     confocal fluorescence microendoscopy, 32  
     light scattering spectroscopy, 33  
     magnification endoscopy, 32  
     narrow band imaging, 32, 32*f*  
     optical coherence tomography, 33, 33*f*  
   self-propelled colonoscopes, 34  
   future developments, 59  
 lower gastrointestinal tract  
   bleeding, 57  
   colonic decompression, 57–58  
   colonoscopy, 54–55, 54*f*–55*f*  
   complications, 55–56  
   contraindications, 53  
   enteral stents, 58, 58*f*  
   indications, 53, 53*t*  
   management, 220  
   patient preparation, 53  
   polypectomy  
     overview, 56, 56*f*  
     polyp retrieval, 57  
     polyp surveillance, 57  
 overview, 31  
 patient assessment, sedation and monitoring, 35  
 small bowel enteroscopy, 52  
 therapeutic interventions  
   bleeding, management of  
     nonthermal techniques  
       endoscopic band placement, 39  
       endoscopic clipping, 39, 39*f*  
       endoscopic suture placement, 39  
       injection sclerotherapy, 38–39  
     overview, 37  
   thermal techniques  
     contact, 38, 38*f*  
     noncontact, 38, 38*f*  
     overview, 37–38  
 endoscopic enteral access  
   direct percutaneous endoscopic jejunostomy tube  
   endoscopic dilation, 43–44  
   foreign body extraction, 43, 44*f*  
   overview, 43  
 enteral stent placement  
   stent characteristics, 45  
   stent delivery systems, 44  
 overview, 41  
 percutaneous endoscopic gastrostomy, 41–42  
   interventional radiology–assisted, 42  
 introducer technique, 42  
 with jejunostomy tube extension, 42–43  
   laparoscopic-assisted, 42  
   pull technique, 42, 42*f*  
   push technique, 42  
 endoscopic mucosal resection  
   mucosal ablation, 41  
   overview, 39–40  
   saline lift technique, 40, 40*f*  
   submucosal dissection, 41  
   “suck-and-cut” technique, 40  
   “suck-and-ligate” technique, 40–41  
 GERD, endoluminal treatment of  
   EndoCinch device, 45  
   Enteryx system, 45  
   EsophyX device, 46  
   Gatekeeper reflux repair system, 45–46  
   overview, 45  
   Plicator device, 45  
   Stretta device, 45  
 ultrasound, endoscopic, 58–59  
 upper gastrointestinal endoscopy  
   basic endoscopic techniques—EGD, 36, 37*f*  
   contraindications, 35–36  
   indications, 35, 35*t*  
   patient preparation, 36  
   tissue sampling techniques, 37  
   upper gastrointestinal tract, management of, 220–221  
 EndoStitch device, 71, 420, 422  
*Entamoeba histolytica*, 909–910  
 Enteral stent placement, 44  
 Enteric fistula. *See* Fistula, enteric  
 Enteroclysis, 613  
 Enteryx system, 45  
 Epidermal growth factor receptor (EGFR), 1207  
 Epigastric hernia  
   anatomy and etiology, 142  
   clinical manifestations, 142  
   history, 142  
   incidence, 142  
   overview, 141–142  
   treatment, 142, 143*f*  
 Epiphrenic diverticula  
   laparoscopic epiphrenic diverticulectomy, 314, 315*f*  
   overview, 312–313, 314–315, 314*f*  
   treatment, 313–314  
 Epithelioid hemangioendothelioma, 945–946  
 ERCP. *See* Endoscopic retrograde cholangiopancreatography  
 Esophageal body and lower esophageal sphincter  
   function assessment, 330, 332, 332*f*  
 Esophageal cancer. *See* Cancer, esophageal  
 Esophageal carcinoma, 78–80, 79*t*

- Esophageal disorders, benign
- esophageal diverticula
    - epiphrenic diverticula
      - laparoscopic epiphrenic diverticulectomy, 314, 315*f*
      - overview, 312–313, 314–315, 314*f*
      - treatment, 313–314
  - overview, 310
  - Zenker's diverticulum
    - operative technique
      - endoscopic treatment, 311–312
      - open cervical diverticulectomy, 311, 312*f*–313*f*
    - overview, 310, 310*f*
    - treatment, 310–311
- gastroesophageal reflux disease
- laparoscopic antireflux surgery, 353
  - Nissen fundoplication, 354
  - overview, 353
  - preoperative evaluation, 353–354
  - Toupet fundoplication, 354
- motility disorders
- achalasia
    - evaluation, 303–304, 304*f*–305*f*
    - laparoscopic Heller myotomy, 306–309, 307*f*–309*f*, 352–353
    - overview, 303, 352, 353
    - partial fundoplication, 352, 353
    - patient presentation, 303
    - treatment, 304, 306–307
    - overview, 303, 310
  - spastic motility disorders, 297
    - diffuse esophageal spasm, 298, 300*f*
    - hypertensive lower esophageal sphincter, 298, 302*f*, 303
    - nutcracker esophagus, 298, 301*f*
    - patient presentation and evaluation, 298, 299*f*
- overview, 291
- paraesophageal hernia
- clinical presentation, 292–293
  - defect closure, 352
  - diagnosis and evaluation, 293
  - endoscopy, 293
  - etiology and anatomic classification, 291, 292*f*
  - hernia recurrence, 351–352
  - imaging studies, 293, 293*f*
  - indications for treatment, 294
  - manometry and pH testing, 293–294
  - operative technique: laparoscopic repair
    - crural repair, 296–297, 297*f*
    - dissection, 295–296
    - fundoplication, 297, 297*f*
    - positioning and ports, 295, 296*f*
  - overview, 291, 351
  - repair technique, 351–352
  - therapeutic controversies
    - crural repair, 295
    - operative approach, 294
    - overview, 294
    - routine fundoplication, 295
- Esophageal disorders, malignant
- en bloc esophagectomy
    - complication, 435
    - with lymphadenectomy, 434
    - outcomes, 435
    - technique, 434–436
    - tri-incisional esophagectomy (McKeown technique), 435–436
  - endoscopic surveillance, 434
  - minimally invasive esophagectomy, 437–438
  - overview, 433–434
  - resection, 434–436
- Esophageal dysphagia, 319
- Esophageal fistulas, 204
- Esophageal motility, ineffective, 332
- Esophageal spasm, diffuse, 332
- Esophagectomy, 416–417, 426–427, 426*t*
- Esophagitis, 226, 226*f*
- Esophagogastroduodenoscopy (EGD), 35–36, 35*t*, 221
- Esophagram, barium, 327
- Esophagus
- benign disorders. *See* Esophageal disorders, benign
  - cancer of. *See* Cancer, esophageal
  - gastroesophageal reflux disease (GERD). *See* Gastroesophageal reflux disease (GERD)
  - resections. *See* Esophagus, surgical procedures to resect and replace
  - short of, 341–342
  - surgical procedures to resect and replace
    - alternate methods of reconstruction for colon and jejunum
    - colonic interposition
      - left colon, 404–405, 404*f*–405*f*
      - overview, 404
      - right colon, 405–406
    - jejunal interposition
      - free jejunal transfer, 408, 408*f*
      - overview, 406
      - pedicled jejunal interposition, 407, 407*f*
      - Roux-en-Y replacement, 406–407, 406*f*
  - cervical lesion, approach to, 391–392
  - complications and how to avoid them
    - anastomotic leak, 408–409
    - anastomotic stricture, 409
    - bleeding, 410
    - chyle leak, 410
    - impaired conduit emptying, 410–411
    - recurrent laryngeal nerve injury, 409
    - respiratory complications, 410
  - lesions below thoracic inlet, approach to
    - Ivor Lewis technique, 400–401, 401*f*
    - left thoracoabdominal approach, 403–404, 403*f*
    - overview, 392
    - transhiatal technique, 401–403, 402*f*–403*f*
    - transhiatal versus transthoracic techniques, 392–393
    - tri-incisional esophagectomy, 393–397, 393*f*–400*f*, 399–400
  - neoadjuvant treatment, 389–390
  - overview, 389, 390*f*, 411
  - staging, 390–391, 391*f*
  - video-assisted thoracic surgery of
- achalasia, treatment of, 429–430
- esophageal cancer
- minimally invasive esophagectomy, 416–417
  - molecular staging, 416
  - operative technique
    - laparoscopic phase, 417–423, 418*f*–422*f*
    - overview, 417
    - thoracoscopic phase, 423–425, 423*f*–425*f*
  - outcomes and complications following
    - minimally invasive esophagectomy, 426–427, 426*t*
  - outcomes of minimally invasive
    - thoracoscopic resection for leiomyoma, 429
  - overview, 414
  - resection of esophageal leiomyoma, 427–428
  - staging, 414
  - technique of minimally invasive surgical
    - staging
      - operative steps of laparoscopy, 415, 415*f*
      - operative steps of thoracoscopy, 415–416, 416*f*
      - overview, 414
      - technique of resection, 428, 428*f*–429*f*
  - miscellaneous indications, 430
  - overview, 413
- Esophogram, 342
- EsophyX device, 46
- Ethicon nonbladed trocar, 65
- Extracorporeal shock wave lithotripsy, 1012–1013
- F**
- Familial adenomatous polyposis (FAP), 738
- small intestinal tumors and, 612
- Familial colon cancer, 738
- Familial colorectal cancer type X (FCC X), 795
- FAST (focused abdominal sonography for trauma), 247–248, 248*f*
- FCC X (familial colorectal cancer type X), 795
- FDG-PET, 841
- Fecal incontinence
- definition of, 807
  - diagnosis and evaluation
    - electromyography, 807
    - overview, 807
    - transrectal ultrasound, 807
  - pathophysiology, 804, 807
  - treatment
    - anal sphincter reconstruction, 808
    - miscellaneous treatments and new modalities, 808–809
    - muscle sensory retraining or biofeedback, 808
- Femoral hernia
- anatomy and etiology, 138–139, 139*f*
  - clinical presentation, 139
  - overview, 138
  - treatment, 139, 139*f*
- Finney pyloroplasty, 518–519, 520*f*
- Finney strictureplasty, 677, 677*f*



- Fissure, anal  
 clinical features and diagnosis, 821  
 overview, 821, 822*f*  
 treatment, 821, 823*f*–825*f*, 824
- Fistula  
 anal  
 diagnosis and classification, 824–825, 826*f*  
 treatment, 825, 827, 827*f*–829*f*, 829  
 appendiceal, 205  
 colcutaneous, 652  
 coloenteric, 652  
 colon, 205  
 colovaginal, 652–653  
 colovesical, 652  
 duodenal, 204  
 enteric  
 classification of  
 anatomic  
 appendiceal fistulas, 205  
 colonic fistulas, 205  
 duodenal fistulas, 204  
 gastric fistulas, 204  
 oral, pharyngeal, and esophageal  
 fistulas, 204  
 overview, 204  
 small bowel fistulas, 204  
 overview, 203  
 physiologic classification, 205, 205*t*  
 spontaneous versus postoperative,  
 203–204  
 management  
 decision, 209–210  
 definitive management  
 abdominal wall closure, 212–213, 212*t*  
 consent, 210  
 operative intervention, 211–212  
 overview, 210  
 patient preparation, 210–211  
 investigation, 209  
 overview, 206, 207*t*  
 postsurgical phase, 213–214, 213*t*  
 recognition and stabilization  
 control of fistula drainage and skin  
 care, 208  
 control of sepsis, 207  
 identification and resuscitation,  
 206–207  
 nutritional support, 209  
 psychological support, 209  
 reduction of fistula output, 208–209  
 surgical approach, 207–208  
 overview, 202–203, 203*t*, 214  
 predicting closure of, 205, 206*t*  
 prevention of, 205–206  
 risk factors of, 205–206  
 esophageal, 204  
 gastric, 204  
 intestinal, 192
- 5-aminosalicylic acid, for Crohn's disease,  
 671–672
- Flexible endoscope  
 endoscope anatomy  
 overview, 33–34  
 shape-locking device, 34  
 variable stiffness endoscopes, 34, 34*f*  
 endoscopic education, 34  
 image documentation, 33  
 imaging, 31  
 imaging advances  
 autofluorescence endoscopy, 32–33  
 chromoendoscopy, 31  
 confocal fluorescence microendoscopy, 32  
 light scattering spectroscopy, 33  
 magnification endoscopy, 32  
 narrow band imaging, 32, 32*f*  
 optical coherence tomography, 33, 33*f*  
 self-propelled colonoscopes, 34
- Flexible sigmoidoscopy, 750
- Focal nodular hyperplasia  
 diagnosis, 931, 931*f*  
 epidemiology and etiology, 930  
 overview, 978  
 pathology, 930–931  
 treatment, 931
- Focused abdominal sonography for trauma  
 (FAST), 247–248, 248*f*
- Fogarty-type balloon catheter, 1080
- FOLFOX regimen, 960–962
- Fox's sign, 1131
- Frey procedure  
 versus Beger procedure, 1161  
 operative technique, 1161, 1161*f*; 1162*f*
- Fundoplication  
 Dor, 308*f*–309*f*; 335*f*; 338–339  
 Nissen. *See* Nissen fundoplication  
 Toupet, 308, 308*f*–309*f*; 335*f*; 339
- G**
- Gallbladder and bile ducts  
 biliary strictures. *See* Strictures, biliary  
 cancer. *See* Cancer, bile duct; Cancer,  
 gallbladder  
 cholangitis. *See* Cholangitis  
 cholecystectomy. *See* Cholecystectomy  
 choledochal cyst. *See* Choledochal cyst  
 choledocholithiasis. *See* Choledocholithiasis  
 gallbladder perforation, intraoperative, 1005  
 hepatolithiasis, 1024–1025
- Gallstone disease, biliary strictures and, 1052–1053
- Gallstone pancreatitis, acute, 49
- Gambie stitch, 518, 519*f*
- Gas gangrene, 117, 119
- Gastric adenocarcinoma  
 adjunctive therapies, 467–468  
 associated risk factors  
 diet, 465  
*Helicobacter pylori*, 464  
 hereditary forms, 465  
 obesity, 465  
 overview, 463–464  
 smoking, 464–465  
 diagnosis and staging  
 overview, 466  
 preoperative staging and selection of patients  
 for surgery, 466–467  
 staging, 467, 467*t*  
 epidemiology, 463, 464*f*; 464*t*  
 gastrointestinal reconstructive techniques  
 intestinal reconstruction after distal  
 gastrectomy  
 Billroth-II reconstruction, 474–475, 475*f*  
 Roux-en-Y reconstruction, 475–477,  
 475*f*–477*f*  
 intestinal reconstruction after total  
 gastrectomy, 477–480, 478*f*–480*f*  
 overview, 474  
 signs and symptoms, 465–466  
 surgical approach  
 endoscopic submucosal resection, 470  
 extent of lymph node dissection, 469–470,  
 469*f*; 470*t*  
 overview, 468–469  
 surgical techniques  
 distal gastrectomy, 471–474, 471*f*–473*f*  
 total gastrectomy, 474, 474*f*
- Gastric antral vascular ectasia (GAVE), 226–227,  
 226*f*
- Gastric cancer. *See* Cancer, gastric
- Gastric carcinoids  
 classification, 483  
 overview, 483  
 presentation and diagnostic workup, 483–484,  
 484*t*  
 treatment, 484–485
- Gastric cardia tumors, 369, 433–434
- Gastric disorders, benign  
 gastric ulcer disease  
 diagnosis, 453  
 intractability or nonhealing ulcers, 454,  
 454*t*, 455*f*  
 therapy, 453–454, 454*f*  
 gastroparesis, 459  
*Helicobacter pylori* infection  
 host response to, 443–445, 444*t*  
 overview, 443  
 laparoscopic gastric operations, 459–460  
 miscellaneous environmental factors  
 diagnosis, 446  
 overview, 445–446  
 nonulcerative dyspepsia, 445  
 obstruction, 453  
 operative treatment of ulcer disease  
 overview, 446–447  
 postoperative alterations, 450–451  
 procedures, 447, 447*f*–450*f*; 449–450  
 ulcer hemorrhage, 451–452, 451*t*–452*t*  
 overview, 443  
 peptic ulcer disease, 445  
 perforation, 452–453  
 postgastrectomy syndromes  
 alkaline reflux gastritis, 456, 456*f*  
 dumping, 455, 455*t*  
 overview, 455  
 stress ulcer disease, 456–457, 456*t*  
 upper gastrointestinal bleeding  
 bezoars, 458  
 Dieulafoy's lesion, 458–459  
 diverticula, 459  
 foreign bodies, 459  
 lipomas, 458  
 Mallory-Weiss tear, 459  
 overview, 457–458  
 polyps, 458  
 volvulus, 459
- Gastric diverticula, 459

- Gastric emptying assessment, 333, 342
- Gastric fistulas, 204
- Gastric lymphoma, primary
  - diagnostic workup and staging, 481–482, 482*t*
  - epidemiology, 480
  - histology, 481, 481*t*
  - signs and symptoms, 481
  - treatment, 482–483
- Gastric resection
  - distal gastric resections and reconstructions
    - laparoscopic approaches
      - anterior proximal vagotomy or seromyotomy, 539*f*–540*f*, 540
      - gastric resection, 541–542, 541*f*–542*f*
      - patient and port placement, 538, 538*f*
      - truncal vagotomy, 538*f*–540*f*, 539–540
      - to vagus nerve, 536, 538
    - subtotal and total gastric resections
      - overview, 529
      - subtotal and near-total resections, 529–530
      - total gastrectomy for carcinoma, 531–535, 532*f*–536*f*
    - vagotomy and antrectomy
      - Billroth-I reconstruction, 523–524
      - Billroth-II reconstruction, 524–529, 526*f*–531*f*
      - overview, 522
    - laparoendoscopically assisted sentinel node navigation, 542
  - overview, 519, 521, 521*f*
  - wedge resection of stomach, 521–522, 521*f*–522*f*
- Gastric ulcer disease
  - diagnosis, 453
  - intractability or nonhealing ulcers, 454, 454*t*, 455*f*
  - therapy, 453–454, 454*f*
- Gastric volvulus, 459
- Gastrinoma, 1215–1216, 1215*f*; 1216*t*, 1223–1224, 1224*f*
  - gastrinoma triangle, 1215, 1215*f*
- Gastroesophageal reflux disease (GERD)
  - complications
    - extraesophageal or pulmonary, 324–325, 325*f*
    - metaplastic (Barrett's) and neoplastic (adenocarcinoma)
      - management of dysplastic Barrett's esophagus, 326–327, 327*f*, 327*t*
      - overview, 325, 326*f*
      - pathophysiology of Barrett's metaplasia, 325
      - screening and surveillance, 326
    - mucosal, 322–324, 323*f*
    - overview, 322, 322*t*
  - endoluminal treatment
    - EndoCinch device, 45
    - Enteryx system, 45
    - EsophyX device, 46
    - Gatekeeper reflux repair system, 45–46
    - overview, 45
    - Plicator device, 45
    - Stretta device, 45
  - laparoscopic antireflux surgery, 353
  - Nissen fundoplication, 354
  - overview, 353
    - definition, 319
    - symptoms, 319, 320*t*
  - pathophysiology
    - crural diaphragm, 320, 322
    - esophageal peristalsis, 320
    - lower esophageal sphincter, 319–320, 320*t*, 321*f*–322*f*
    - overview, 319
    - stomach, 322
  - preoperative assessment of patients with barium esophagram, 327
  - esophageal body and lower esophageal sphincter function assessment, 330, 332, 332*f*
  - gastric emptying, 333
  - high-resolution manometry, 330, 332, 332*f*
  - measurement of gastroesophageal reflux
    - ambulatory pH monitoring, 328–330, 330*t*
    - combined multichannel intraluminal impedance-pH monitoring, 330, 331*f*
  - overview, 327
  - upper endoscopy, 328, 328*f*–329*f*
  - preoperative evaluation, 353–354
  - primary antireflux repairs
    - laparoscopic Nissen fundoplication, 334–338, 336*f*–339*f*
    - laparoscopic partial fundoplication, 338
    - Nissen fundoplication, principles of, 334, 335*f*
    - outcomes, 339
    - reoperation for failed antireflux repairs, 339–340, 341*f*
  - surgical therapy
    - history of the evolution of antireflux surgery, 333
    - patient selection, 333–334
    - procedure selection, 334
  - Toupet fundoplication, 354
- Gastrointestinal evaluation
  - early postoperative bowel obstruction, 17–18
  - overview, 16
  - postoperative ileus, 16–17
  - renal evaluation, 18–20, 20*t*
- Gastrointestinal hemorrhage, acute
  - economic effects, 217
  - history and examination
    - characteristics of, 219
    - essential features in, 220
  - identifying the source
    - angiography, 221
    - capsule enteroscopy and deep enteroscopy, 221
    - nuclear scintigraphy, 221
    - overview, 220
    - red cell labeling, 221
    - use of endoscopy, 220–221
      - flexible sigmoidoscopy versus colonoscopy, 220
  - incidence of, 217
  - initial assessment, 217–218, 218*f*, 218*t*
  - morbidity and mortality, 217
  - overview, 217
  - physical examination, 220
  - resuscitation, 217–218, 219
  - risk stratification, 219
  - therapeutic options
    - endoscopic treatment, 221–222
    - interventional angiography, 222
    - pharmacologic management, 221
    - surgery, 222
    - transfusion, 219
- Gastrointestinal stromal tumors (GIST), 227, 227*f*; 746–747
  - clinical presentation, 495
  - diagnosis
    - biopsy, 496
    - endoscopy, 496, 496*f*
    - fine-needle aspiration, 496
    - radiographic studies, 495–496, 495*f*–496*f*
  - epidemiology
    - age, 494–495
    - hereditary, 495
    - incidence, 495
  - laparoscopic image of, 498*f*
  - metastatic disease management, 508
  - molecular therapeutics and gastrointestinal stromal tumors, 619–620
  - overview, 493, 502–503, 507, 619, 619*f*; 895
  - pathologic features
    - historical background, 493
    - receptor tyrosine kinase mutations, 493–494, 494*f*
  - prognostic factors, 496, 497*t*
  - risk assessment for, 497*t*
  - surveillance, 502
  - therapy for advanced disease
    - surgical approach, 500–501
    - targeted therapy, 500
  - therapy for primary disease
    - adjuvant therapy, 500, 508
    - neoadjuvant therapy, 498, 498*f*, 507–508
  - perioperative care, 508
  - surgical approach
    - outcome, 497
    - technique, 496–497, 498*f*, 507–508
  - treatment, 619
- Gastroparesis, 459
- Gatekeeper reflux repair system, 45–46
- GAVE (gastric antral vascular ectasia), 226–227, 226*f*
- Gelpert, 780, 780*f*
- Genitourinary dysfunction, 713
- GERD. *See* Gastroesophageal reflux disease
- GIST. *See* Gastrointestinal stromal tumors
- Glasgow score, 1098–1099
- Glassman grasper, 70
- Glucagonoma, 1217, 1217*f*; 1224–1225
- Glycemic control, 20–21
- Gonorrhoea, 831
- Goodsall's rule, 825, 827*f*
- Granulomatous disease, bowel obstruction and, 593
- Grey-Turner's sign, 1131

- Groin  
 anatomy of, 125  
 hernia  
   strangulated, 138  
   surgical complications of  
   bladder injury, 137  
   infection, 136–137  
   neuralgia, 137  
   overview, 136  
   recurrence, 136  
   testicular injury, 137–138  
   vas deferens injury, 138
- H**
- Haggitt's classification of tumor invasion,  
 741–742, 742*f*, 834, 834*f*
- HAI (hepatic arterial infusion) chemotherapy,  
 964–965
- Hamartomas, small intestine, 615
- Hamartomatous polyposis syndromes  
   Bannayan-Riley-Ruvalcaba syndrome, 740  
   Cowden syndrome, 740  
   Cronkite-Canada syndrome, 740  
   juvenile polyposis syndrome, 740  
   overview, 739  
   Peutz-Jeghers syndrome, 740
- Hand port, position and insertion of, 780, 780*f*
- Harmonic scalpel, 771
- Hasson technique, 66
- Heinecke-Mikulicz pyloroplasty, 518, 519*f*
- Heinecke-Mikulicz strictuoplasty, 676–677, 676*f*
- Heinz bodies, 1242
- Helicobacter pylori* infection, 4, 445–446, 464  
   host response to, 443–445, 444*t*  
   overview, 443
- Heller myotomy, laparoscopic, 306–309,  
 307*f*–309*f*, 352–353
- Hemangioendothelioma, epithelioid, 945–946
- Hemangioma, liver  
   diagnosis, 929, 929*f*  
   epidemiology and etiology, 928  
   pathology, 928–929  
   treatment, 929–930
- Hemangioma, small intestine, 615
- Hematological evaluation, 21–23
- Hemobilia, 228
- Hemolytic uremic syndrome (HUS), 1254
- Hemorrhoids  
   classification, 817, 818*f*  
   internal, evaluation of, 817  
   overview, 817  
   treatment  
   hemorrhoidectomy, 819  
   mixed hemorrhoids, 820, 820*f*  
   overview, 817, 819–820, 819*f*  
   thrombosed external hemorrhoids, 820–821
- Hemostasis, laparoscopic, 70
- Hemosuccus pancreaticus, 228
- Hepatectomy  
   partial, 938–940, 939*f*–941*f*, 939*t*, 944  
   total, 942–943, 942*t*, 944–945
- Hepatic abscess and cystic disease  
   amebic liver abscess  
   complications, 912–913, 912*f*  
   diagnosis  
     clinical presentation, 910, 910*t*–911*t*  
     diagnostic aspiration, 911  
     laboratory evaluation, 910–911  
     overview, 910  
     radiology, 911  
     serology, 911  
   etiology, 909  
   incidence, 909–910  
   outcome, 913, 914*t*  
   overview, 909, 969  
   pathology, 910  
   treatment  
     antibiotics, 911–912  
     drainage, 912  
     overview, 911  
     therapeutic aspiration, 912
- congenital liver cysts  
   polycystic, 921–922, 922*f*  
   simple, 920–921, 921*f*, 921*t*
- hydatid liver cyst  
   complications, 919–920  
   diagnosis  
   clinical presentation, 915, 915*t*  
   overview, 915  
   radiology, 915, 916*f*, 917*t*  
   serology, 915  
   etiology, 913*f*, 914  
   incidence, 914  
   outcome, 920  
   overview, 914  
   pathology, 914–915  
   surgery  
   laparoscopic cyst evacuation, 919  
   liver resection/transplantation, 919, 920*t*  
   open cyst evacuation, 919  
   overview, 917–918, 918*f*  
   pericystectomy, 919  
   scollicidal agents, 918–919
- treatment  
   antihelminthics, 917  
   overview, 916, 969–970  
   percutaneous aspiration and  
   drainage, 917
- neoplastic cysts  
   cystadenocarcinoma, 923–924, 924*f*  
   cystadenoma, 922–923, 923*f*, 924*t*  
   overview, 922  
   resection of, 979  
 overview, 901, 902*t*, 969, 979
- pyogenic liver abscess  
   bacteriology, 903–904, 903*t*  
   clinical presentation, 904, 904*t*  
   complications, 907, 909  
   diagnosis, 904  
   etiology, 901–902, 902*f*  
   incidence, 902  
   laboratory evaluation, 904  
   outcome, 909, 909*t*  
   overview, 901  
   pathology, 903  
   predisposing factors, 902–903, 903*t*  
   radiology, 904–905, 905*f*–907*f*  
   treatment  
   antibiotics, 905–906  
   antifungals, 907  
   aspiration and percutaneous catheter  
   drainage, 907, 908*f*  
   overview, 905  
   surgical drainage, 907  
   simple liver cysts, management of, 970  
   traumatic cysts, 924–925, 924*f*  
   treatment options, 925
- Hepatic arterial infusion (HAI) chemotherapy,  
 964–965
- Hepatic artery aneurysms, 284–285
- Hepatic artery infusion (HAI) pumps, 972
- Hepatic colorectal metastasis. *See* Colorectal  
 metastasis
- Hepaticojejunostomy, 1086–1087, 1086*f*
- Hepatoblastoma, 945
- Hepatocellular adenomas (HCAs), 978
- Hepatocellular carcinoma. *See* Carcinoma,  
 hepatocellular
- Hepatolithiasis, 1024–1025
- Hepatopulmonary syndrome (HPS), portal  
 hypertension and, 990–991
- Hereditary elliptocytosis, 1250
- Hereditary nonpolyposis colon cancers  
 (HNPCC), 738–739, 739*t*
- Hereditary pancreatitis, 1148–1149
- Hereditary spherocytosis, 1249–1250
- Hernia  
   bowel obstruction and, 591, 592*f*  
   definition of, 123  
   epigastric hernia  
   anatomy and etiology, 142  
   clinical manifestations, 142  
   history, 142  
   incidence, 142  
   overview, 141–142  
   treatment, 142, 143*f*
- femoral hernia  
   anatomy and etiology, 138–139,  
   139*f*  
   clinical presentation, 139  
   overview, 138  
   treatment, 139, 139*f*
- giant hernia. *See* Paraesophageal hernia
- groin hernia  
   strangulated, 138  
   surgical complications of  
   bladder injury, 137  
   infection, 136–137  
   neuralgia, 137  
   overview, 136  
   recurrence, 136  
   testicular injury, 137–138  
   vas deferens injury, 138
- hiatal, 291  
   categories, 340–341  
   high-resolution manometry, 332*f*  
   history, 340  
   operative approach  
   laparoscopic  
     outcomes, 343–344, 346  
     overview, 343, 343*f*–345*f*  
   overview, 342  
   transthoracic  
     outcomes, 343  
     overview, 342

- paraesophageal hernia and short esophagus, 341–342
- preoperative evaluation
- endoscopy, 342
  - esophogram, 342
  - gastric emptying, 342
  - manometry and pH testing, 342
  - overview, 342
- type I, 291, 292*f*
- type II, 291, 292*f*
- type III, 291, 292*f*
- type IV, 291
- inguinal
- anatomic classification, 124–125
  - anatomy of the groin, 125, 160
  - anesthesia, 127
  - clinical manifestations, 125–126
  - epidemiology, 124
  - etiology, 125
  - history, 123–124
  - operative techniques
    - laparoscopic repair
      - complication, 161
      - cost, 161
      - outcome, 161
      - overview, 134–136, 160, 161
      - types of, 160    - open repair
      - Cooper ligament repair, 131
      - overview, 127, 128*f*–129*f*
      - Shouldice technique, 129–131, 130*f*  - physical examination, 126
  - pregnancy and groin hernia, 126
  - prosthetic repairs
    - Lichtenstein technique, 132, 133*f*
    - overview, 131–132
    - preperitoneal approach, 132, 134*f*
- treatment, 126–127
- after laparoscopic gastric bypass, 591–592
- laparoscopic ventral hernia repair
- advantages of, 157
  - cost–benefit, 159
  - disadvantages of, 157
  - long-term follow-up, 159
  - overview, 157, 159
  - postoperative results, 158
  - pros and cons of, 158*t*
  - rationale for, 157
  - technique, 157–158
- lumbar hernia, 148–149, 148*f*
- obturator hernia
- anatomy, 143, 144*f*
  - clinical manifestations, 144
  - incidence, 142–143
  - overview, 142
  - results, 145
  - treatment, 144–145, 145*f*
- overview, 123
- paraesophageal, 341–342
- clinical presentation, 292–293
  - defect closure, 352
  - diagnosis and evaluation, 293
  - endoscopy, 293
  - etiology and anatomic classification, 291, 292*f*
  - hernia recurrence, 351–352
  - imaging studies, 293, 293*f*
  - indications for treatment, 294
  - manometry and pH testing, 293–294
  - operative technique: laparoscopic repair
    - crural repair, 296–297, 297*f*
    - dissection, 295–296
    - fundoplication, 297, 297*f*
    - positioning and ports, 295, 296*f*  - overview, 291, 351
  - repair technique, 351–352
  - therapeutic controversies
    - crural repair, 295
    - operative approach, 294
    - overview, 294
    - routine fundoplication, 295
- perineal hernias
- anatomy, 145–146, 146*f*
  - clinical manifestations, 146
  - etiology, 145
  - overview, 145
  - treatment, 146
- postoperative ventral wall (incisional) hernia
- clinical manifestations, 150
  - complications, 154
  - incidence and etiology, 150
  - overview, 150
  - treatment
    - laparoscopic repair, 152, 154
    - mesh repair, 152, 153*f*
    - overview, 150–151
    - primary suture repair, 151–152, 151*f*
- sciatic hernia, 149–150, 149*f*
- spigelian hernia
- anatomy, 147–148, 147*f*
  - clinical manifestations, 148
  - overview, 147
  - treatment, 148
- trocar site, 593
- umbilical hernia
- clinical manifestations, 140
  - embryology and anatomy, 140
  - history, 140
  - incidence, 140
  - overview, 140
  - treatment, 141, 141*f*
- Herpes simplex virus, 831
- Hiatal hernia. *See* Hernia, hiatal
- High-grade squamous epithelial lesions (HSIL), 881–883
- Highly selective vagotomy (HSV)
- dissection of anterior leaf of lesser omentum, 514
  - dissection of distal esophagus, 515–516, 515*f*–516*f*
  - dissection of posterior leaf of lesser omentum, 515, 515*f*
  - exposure and gastric mobilization, 514
  - overview, 513, 514*f*
- HNPPC (hereditary nonpolyposis colon cancers), 738–739, 739*t*
- Horseshoe fistulas, 825, 827
- Howell-Jolly bodies, 1243
- HSIL (high-grade squamous epithelial lesions), 881–883
- HSV. *See* Highly selective vagotomy
- Human papillomavirus (HPV), 830
- vaccines, 883
- Hunter grasper, 69–70
- HUS (hemolytic uremic syndrome), 1254
- Hydatid liver cyst
- complications, 919–920
  - diagnosis
    - clinical presentation, 915, 915*t*
    - overview, 915
    - radiology, 915, 916*f*; 917*t*
    - serology, 915  - etiology, 913*f*; 914
  - incidence, 914
  - outcome, 920
  - overview, 914
  - pathology, 914–915
  - treatment
    - antihelmintics, 917
    - overview, 916
    - percutaneous aspiration and drainage, 917
    - surgery
      - laparoscopic cyst evacuation, 919
      - liver resection/transplantation, 919, 920*t*
      - open cyst evacuation, 919
      - overview, 917–918, 918*f*
      - pericystectomy, 919
      - scolicidal agents, 918–919
- Hypercapnia, 72–73
- Hypertensive lower esophageal sphincter, 298, 302*f*; 303
- I**
- Iatrogenic bleeding, 228
- Idiopathic pancreatitis, 1148
- Idiopathic thrombocytopenic purpura (ITP), 1253–1254
- IGRT (image-guided radiation therapy), 796
- Ileal J-pouch, 707–708, 709*f*
- Ileal pouch–anal anastomosis
- complications
    - anal, 716
    - cancer and dysplasia
      - affecting the pouch mucosa, 718
      - affecting the rectal outlet, 718    - cuffitis, 716–717
    - leaks, fistulas and septic complications, 715–716
    - pouchitis, 717–718, 717*f*
    - pouch–vaginal fistula, 716  - long-term outcome, 719
  - overview, 706–708
- Ileoanal pouch–anal anastomosis (IPAA)
- complications
    - cancer or dysplasia, 728–729
    - pouchitis, 728  - laparoscopic, 729
  - overview, 728
  - post-IPAA, 728–729
- Ileostomy, 702*f*; 704–706
- complications, 184–185, 185*f*; 711–712, 712*f*; 712*t*
  - end ileostomy, 175–176, 177*f*; 178
  - location, determining, 175, 176*f*
  - loop ileostomy, 178–179, 178*f*; 180*f*–182*f*
  - loop-end ileostomy, 179, 182–184, 183*f*



- Ileostomy (*Cont.*):  
 overview, 174–175  
 postoperative care and complications, 184  
 blockage algorithm, 185*f*
- Image-guided radiation therapy (IGRT), 796
- Imatinib mesylate  
 for treatment of advanced gastrointestinal stromas, 500, 501*t*, 502*f*, 503*f*  
 for treatment of primary gastrointestinal stromal tumor, 507–508  
 for treatment of primary gastrointestinal stromas, 498, 498*f*, 499*t*, 503*f*
- Immune hemolytic anemia, 1252–1253
- Immune thrombocytopenic purpura, 1253–1254
- Immunomodulators (azathioprine and 6-mercaptopurine), for Crohn's disease, 672
- IMRT (intensity-modulated radiation therapy), 796
- Incidentaloma, 1273
- Incisional hernia, 120, 157–159
- Incisions, closures, and wound management  
 closures  
 fascia  
 mass closure of abdomen, 112, 112*f*  
 overview, 111–112  
 laparoscopic incision, 113–114  
 mesh and biologic implant placement of, 113  
 overview, 111  
 retention suture, 113  
 skin, 113  
 temporary, 114–115, 115*f*
- incisions  
 abdominothoracic incisions, 102, 104, 107*f*  
 choice of, 99–100  
 initial access, 109–111  
 laparoscopic, 108–109  
 overview, 99  
 placement of additional ports, 111  
 preparation of the surgical site, 100  
 retroperitoneal and extraperitoneal incisions  
 overview, 104–105  
 posterior approach to adrenal glands, 105, 108, 109*f*  
 retroperitoneal approach to iliac fossa, 108, 110*f*  
 retroperitoneal approach to lumbar area, 105, 108*f*  
 transverse and oblique  
 Kocher subcostal incisions, 101–102, 104*f*  
 McBurney gridiron incisions, 102, 104*f*–105*f*  
 overview, 101–102  
 Pfannenstiel incisions, 102, 106*f*  
 Rockey-Davis muscle splitting incisions, 102  
 vertical  
 midline incisions, 100–101, 100*f*–101*f*  
 muscle-splitting incisions, 101  
 paramedian incisions, 101, 101*f*–103*f*  
 postoperative wound management  
 dressing the wound, 115  
 wound complications  
 abdominal wound dehiscence and evisceration, 120  
 hematoma, 119–120  
 incisional hernia, 120  
 necrotizing wound infections  
 gas gangrene, 117, 119  
 necrotizing fasciitis, 119  
 overview, 117  
 seroma, 119–120  
 stitch abscess, 120  
 surgical site infections, 115–117, 116*t*–119*t*
- Incontinence, fecal  
 definition of, 807  
 diagnosis and evaluation  
 electromyography, 807, 807*f*  
 overview, 807  
 transrectal ultrasound, 807, 808*f*–809*f*  
 etiology, 807*t*  
 pathophysiology, 804, 807, 807*t*  
 treatment  
 anal sphincter reconstruction, 808, 810*f*  
 miscellaneous treatments and new modalities, 808–809  
 muscle sensory retraining or biofeedback, 808  
 overview, 808
- Ineffective esophageal motility, 332
- Infections, surgical site, 115–117, 116*t*–119*t*
- Infectious colitis, 234
- Inflammatory bowel disease, 725–726  
 etiology, 727  
 medical management, 727–728
- Infliximab  
 for Crohn's disease, 208, 672, 725–726, 727–728  
 for ulcerative colitis, 727–728
- Infrarenal aortic exposure, 265, 265*f*
- Inguinal hernia  
 anatomic classification, 124–125  
 anatomy of the groin, 125, 160  
 anesthesia, 127  
 clinical manifestations, 125–126  
 epidemiology, 124  
 etiology, 125  
 history, 123–124  
 operative techniques  
 laparoscopic repair  
 complication, 161  
 cost, 161  
 outcome, 161  
 overview, 134–136, 160, 161  
 types of, 160  
 open repair  
 Cooper ligament repair, 131  
 overview, 127, 128*f*–129*f*  
 Shouldice technique, 129–131, 130*f*  
 physical examination, 126  
 pregnancy and groin hernia, 126  
 prosthetic repairs  
 Lichtenstein technique, 132, 133*f*  
 overview, 131–132  
 preperitoneal approach, 132, 134*f*  
 treatment, 126–127
- Injection sclerotherapy, 38–39
- Insufflators, 69
- Insulinoma, 1214, 1215*f*; 1222–1223, 1222*f*–1223*f*
- Intensity-modulated radiation therapy (IMRT), 796
- Interposition, colonic  
 left colon, 404–405, 404*f*–405*f*  
 overview, 404  
 right colon, 405–406
- Interval appendectomy, 639
- Intestinal obstruction, 673
- Intestinal resection, 675, 675*f*
- Intraductal papillary mucinous neoplasms  
 clinical presentation, 1180  
 diagnosis, 1181  
 overview, 1178, 1179*f*  
 pathologic features, 1178–1180, 1179*f*  
 treatment, 1181–1183, 1182*f*
- Intraductal shock wave lithotripsy, 1012
- Intraoperative cholangiography (IOC), 1016–1017
- Intraoperative radiation therapy (IORT), 863
- Intraoperative ultrasound (IOUS), 956, 957*f*, 1016
- Intraperitoneal onlay mesh technique (IPOM)  
 hernia repair, 135, 160
- Intrathoracic esophageal cancer, 368–369  
 “Introducer” PEG, 42
- Intussusception, bowel obstruction and, 593–594
- IOUS (intraoperative ultrasonography), 956, 957*f*, 1016
- Isoperistaltic side-to-side stricturoplasty, 677–678, 677*f*–678*f*
- ITP (idiopathic thrombocytopenic purpura), 1253–1254
- Ivor Lewis technique, 389, 392, 400–401, 401*f*
- Izbicki procedure, 1163
- J**
- Jejunal interposition  
 free jejunal transfer, 408, 408*f*  
 overview, 406  
 pedicled jejunal interposition, 407, 407*f*  
 Roux-en-Y replacement, 406–407, 406*f*
- Jejunioleal diverticula, 643
- Juvenile polyposis syndrome, 740
- K**
- Kaposi's sarcoma, 747, 895
- Kehr's sign, 250
- Kelly clamp, 70
- KIT proto-oncogene, 493–494, 494*f*, 496, 500, 619, 747
- Klatskin tumors, 1067, 1071–1072
- Kocher clamp, 66–67
- Kocher maneuver, 396, 396*f*; 1197, 1197*f*; 1222, 1222*f*
- Kocher subcostal incisions, 101–102, 104*f*
- Kock pouch, 706, 707*f*  
 complications  
 fistulization, 715  
 miscellaneous, 715  
 nipple valve prolapse, 714–715  
 nipple valve slippage, 714  
 pouch cancer, 715  
 long-term outcome, 719
- K-ras* gene, 737, 1207
- Krasch approach, 847*f*
- Kupffer cells, 901

- L**
- Laparoscope-assisted gastrectomy (LAG)  
 overview, 489  
 surgical technique  
 anatomy of stomach, 490, 490f  
 nodal dissection, 490–491, 491f  
 reconstruction, 491
- Laparoscopic adjustable gastric banding (LAGB)  
 band prolapse, 555f  
 complications, 553–554  
 operative procedure, 551–552, 551f–552f  
 outcomes, 553  
 overview, 551  
 postoperative care, 552–553  
 preoperative preparation, 549  
 revisional surgery, 573  
 versus Roux-en-Y gastric bypass, 553f
- Laparoscopic antireflux surgery, 353
- Laparoscopic biliary tract procedures. *See* Biliary tract
- Laparoscopic choledochoduodenostomy (LCDD), 1021
- Laparoscopic colorectal procedures. *See* Colorectal surgery
- Laparoscopic common bile duct exploration (LCBDE), 1016–1017
- Laparoscopic duodenal switch (LDS),  
 preoperative preparation, 550
- Laparoscopic gastric operations, 459–460
- Laparoscopic greater curvature plication, 580f
- Laparoscopic phase, 417–423, 418f–422f
- Laparoscopic Roux-en-Y gastric bypass (LRYGB)  
 preoperative preparation, 549–550.  
*See also* Roux-en-Y gastric bypass, laparoscopic approach
- Laparoscopic sleeve gastrectomy (LSG)  
 complications, 556–557  
 operative procedure, 555–556, 555f–556f  
 outcomes, 556  
 overview, 554, 580  
 postoperative care, 556  
 preoperative preparation, 550
- Laparoscopic surgery, fundamentals of  
 equipment  
 insufflators, 69  
 light sources, 69  
 telescope, 68, 69f  
 video camera, 69  
 video monitors, 69
- instrumentation  
 bipolar electrosurgery, 71  
 hemostasis, 70  
 monopolar electrosurgery, 70–71  
 overview, 69–70, 70f  
 ultrasonic shears, 71
- overview, 6, 63, 73
- patient considerations  
 patient positioning, 63–64  
 patient preparation, 64  
 patient selection, 63
- physiologic effects of pneumoperitoneum  
 carbon dioxide–related effects  
 capnothorax/pneumothorax, 73  
 carbon dioxide embolus, 73  
 hypercapnia, 72–73  
 overview, 71–72
- port placement  
 access of placement of first port, 65–66, 65f–67f  
 difficult access, 66–67  
 fascial closure, 67, 68f  
 port characteristics, 64–65, 65f  
 site selection, 64, 65f  
 trocar injury, 67–68  
 suturing, 71, 72f
- Laparoscopic ultrasound (LUS), 78, 78f
- Lapra-Tie, 1086
- Laser lithotripsy, 1012
- Lateral pancreaticojejunostomy  
 operative technique, 1155–1156, 1156f  
 outcomes, 1156
- Left adrenalectomy, laparoscopic, 1277, 1278f–1279f
- Left hemicolectomy  
 hand-assisted, 780, 780f–781f  
 mobilization of left colon, 778, 779f  
 mobilization of splenic flexure, 778, 779f  
 overview, 778  
 patient position and room setup, 778  
 port placement and exploration, 778, 778f  
 vascular division, exteriorization, and anastomosis, 778
- Lichtenstein technique, 132, 133f, 139f
- LigaSure device, 70, 771
- Light scattering spectroscopy, 33
- Light sources, laparoscopic, 69
- Lipomas  
 small intestine, 615  
 upper gastrointestinal tract, 458
- Lipomas and lipomatous polyposis, 745–746
- Lithotripsy, 1012
- Liver  
 benign and malignant primary neoplasms. *See* Liver, primary neoplasms of  
 colorectal metastasis. *See* Colorectal metastasis  
 hepatic abscess and cystic disease. *See* Hepatic abscess and cystic disease  
 portal hypertension. *See* Portal hypertension
- Liver, primary neoplasms of  
 bile duct adenoma, 933  
 focal nodular hyperplasia  
 diagnosis, 931, 931f  
 epidemiology and etiology, 930  
 overview, 978  
 pathology, 930–931  
 treatment, 931
- hemangioma  
 diagnosis, 929, 929f  
 epidemiology and etiology, 928  
 pathology, 928–929  
 treatment, 929–930
- hepatic resection, technical considerations in, 946–948, 946f–947f
- hepatocellular adenoma  
 diagnosis, 932, 933f  
 epidemiology and etiology, 931–932  
 overview, 978  
 pathology, 932  
 treatment, 932–933
- malignant tumors  
 angiosarcoma, 945  
 cholangiocarcinoma, treatment, 971  
 hepatoblastoma, 945  
 hepatocellular carcinoma  
 clinical presentation, 936, 937f  
 diagnosis  
 determination of functional liver reserve, 938, 938t  
 extent of disease evaluation, 937–938  
 overview, 937  
 verification of, 937
- epidemiology and etiology, 934, 934t, 970–971  
 overview, 933–934  
 palliative treatment modalities, 943  
 pathology, 934–936, 935f, 936t  
 potentially curative treatments  
 adjuvant therapy, 941–942  
 medical therapy, 971  
 neoadjuvant treatment, 940–941  
 partial hepatectomy, 938–940, 939f–941f, 939t  
 surgical approach, 970–971, 978–979  
 total hepatectomy and liver transplantation, 942–943, 942t
- intrahepatic cholangiocarcinoma  
 epidemiology and etiology  
 choledochal cysts/Caroli's disease, 943  
 overview, 943  
 primary sclerosing cholangitis, 943  
 pyogenic cholangiohepatitis and other hepatic infections, 943–944  
 pathology and classification, 944  
 treatment  
 chemotherapy, 945  
 partial hepatectomy, 944  
 total hepatectomy and liver transplantation, 944–945  
 overview, 933
- nodular regenerative hyperplasia, 933  
 overview, 927–928, 928f, 928t, 970, 978  
 peliosis hepatitis, 933  
 regenerative nodular hyperplasia, 978  
 staging, 82–84, 83f, 83t
- Liver resection/transplantation, 919, 920t, 942–943, 942t, 944–945, 969
- LKB1/STK gene, 740
- LMWH (low-molecular weight heparin), 14
- Lone Star retractor, 708
- Loop ileostomy, 178f, 180f–182f
- Loop-end ileostomy, 179, 182–184, 183f
- Loop-transverse colostomy, 165, 168f, 169
- Lower gastrointestinal hemorrhage  
 causes of  
 obscure bleeding  
 angiodysplasia, 235  
 Meckel's diverticulum, 235–236, 235f  
 neoplasia, 236, 236f  
 overview, 235
- overt bleeding  
 angiodysplasia, 232, 232f  
 anorectal disease, 233  
 colitis, 233  
 diverticular disease, 231–232, 231f

- Lower gastrointestinal hemorrhage, causes of, overt bleeding (*Cont.*):  
infectious colitis, 234  
from inflammatory bowel disease, 233–234, 234f  
mesenteric ischemia, 234, 235f  
neoplasia, 232–233, 232f–233f  
NSAID-associated, 234  
overview, 230–231, 232t  
radiation proctitis, 234, 234f  
management, 230, 231f  
overview, 230
- Lower gastrointestinal tract, endoscopy of  
bleeding, 57  
colonic decompression, 57–58  
colonoscopy, 54–55, 54f–55f  
complications, 55–56  
contraindications, 53  
enteral stents, 58, 58f  
indications, 53, 53t  
patient preparation, 53  
polypectomy  
overview, 56, 56f  
polyp retrieval, 57  
polyp surveillance, 57
- Low-grade squamous epithelial lesions (LSIL), 882–883
- Low-molecular weight heparin (LMWH), 14
- LPR (laryngopharyngeal reflux), 353
- LSIL (low-grade squamous epithelial lesions), 882–883
- Lumbar hernia, 148–149, 148f
- LUS (laparoscopic ultrasound), 78, 78f
- Lymphadenectomy, 371–373, 371f–373f
- Lymphoma  
colon, 747  
non-Hodgkin's  
clinical presentation, 616  
diagnosis, 616, 617f  
overview, 616  
staging and prognosis, 616, 617t  
treatment, 616–617  
spleen, 1254–1255
- Lynch I and II syndromes, 738–739, 795
- M**
- Magnetic resonance cholangiopancreatography (MRCP), 1014
- Magnification endoscopy, 32
- Malignant bowel obstruction, 593, 593f
- Mallory-Weiss tear, 225, 459
- MALT (mucosa-associated lymphoid tissue)  
lymphomas, 747
- Manometry, 293, 299f–302f, 305f, 330, 332, 332f, 342
- MAP (MUTYH-associated polyposis), 795
- Marginal ulcer, as complication of Roux-en-Y gastric bypass, 568–569
- Maryland dissector, 70, 70f
- Mayo, William J., 4–5
- McBurney gridiron incisions, 102, 104f–105f
- McKeown technique (tri-incisional esophagectomy), 393–397, 393f–400f, 399–400
- Mechanical lithotripsy, 1012
- Meckel's diverticula, 235–236, 235f, 643–644
- Medina catheter, 186, 190, 190f
- Melanoma, anal  
adjuvant therapy, 893  
overview, 892  
staging and prognosis, 892–893  
surgery, 893
- MELD (Model for End-stage Liver Disease), 983
- MEN type 1, 1212–1213
- Mesenteric ischemia, 234, 235f
- Mesenteric venous thrombosis, 272, 272f
- Mesorectal excision, total, 850–851, 851f–852f, 853, 854f, 870–871
- Metronidazole, for Crohn's disease, 672
- Michelassi stricturoplasty, 677–678
- Midline incisions, 100–101, 100f–101f
- Mikulicz's pads, 510, 512, 1110
- Minimally invasive esophagectomy (MIE), 437–438
- Minimally invasive surgery  
adrenalectomy. *See* Adrenalectomy  
biliary tract. *See* Biliary tract  
colorectal procedures. *See* Colorectal surgery  
esophagus, video-assisted thoracic surgery of. *See* Esophagus, video-assisted thoracic surgery of  
Heller myotomy. *See* Heller myotomy, laparoscopic  
hiatal hernia. *See* Hernia, hiatal  
laparoscopic surgery, fundamentals of. *See* Laparoscopic surgery, fundamentals of  
morbid obesity. *See* Obesity, morbid  
splenectomy. *See* Spleen, splenectomy, laparoscopic  
staging. *See* Staging, laparoscopic
- Mirizzi's syndrome, 1052–1053
- MMC gene, 737
- MMR genes, 739
- Model for End-stage Liver Disease (MELD), 983
- MODS (multiple organ dysfunction syndrome), 1140–1141, 1141f
- Monopolar electrosurgery, 70–71
- Morbid obesity. *See* Obesity, morbid
- Motility  
gastric, vagal regulation of, 510  
intestinal, 589
- Motility disorders, esophageal  
achalasia  
evaluation, 303–304, 304f–305f  
laparoscopic Heller myotomy, 306–309, 307f–309f, 352–353  
overview, 303, 352, 353  
partial fundoplication, 352, 353  
patient presentation, 303  
treatment, 304, 306–307  
overview, 303, 310  
spastic motility disorders  
diffuse esophageal spasm, 298, 300f  
hypertensive lower esophageal sphincter, 298, 302f, 303  
nutcracker esophagus, 298, 301f  
overview, 297  
patient presentation and evaluation, 298, 299f
- MRCP (magnetic resonance cholangiopancreatography), 1014
- Mucinous cystic neoplasms, pancreas  
clinical presentation, 1176  
diagnosis, 1176–1177, 1177f  
overview, 1175–1176  
pathologic features, 1176, 1176f  
treatment, 1177–1178, 1178f
- Mucosa-associated lymphoid tissue (MALT)  
lymphomas, 747
- Multiple organ dysfunction syndrome (MODS), 1140–1141, 1141f
- Muscle sensory retraining or biofeedback, anorectum, 808
- MUTYH-associated polyposis (MAP), 795
- Myelodysplastic syndrome, 1255
- Myelolipoma, 1272
- Myeloma, spleen, 1254–1255
- Myeloproliferative disorders, 1255
- N**
- Narrow band imaging, 32, 32f
- Natural orifice transluminal endoscopic surgery (NOTES), 1007
- Necrosis, pancreatic  
epidemiology, 1130  
general principles for intervention, 1134, 1134f, 1135t  
indications for intervention, 1132  
microbiology of infected necrosis, 1131  
open surgical procedures  
endoscopic techniques, 1136  
flexible endoscopic techniques, 1137–1138  
laparoscopic techniques, 1136–1137  
necrosectomy with closed packing, 1135  
necrosectomy with continuous closed postoperative lavage, 1136  
necrosectomy with open packing, 1136  
nephroscopic techniques, 1137, 1137f  
overview, 1134–1135, 1135f–1136f  
programmed necrosectomy, 1136  
radiological débridement techniques, 1138  
radiological drainage techniques, 1138  
radiological techniques, 1138  
overview, 1130  
pathogenesis, 1130–1131  
prediction and diagnosis, 1122f, 1131–1132  
prognosis, 1138  
timing of intervention, 1132–1133  
type of intervention, 1133
- Necrotizing pancreatitis, 1105–1107, 1105t, 1106f
- Necrotizing wound infections  
gas gangrene, 117, 119  
necrotizing fasciitis, 119  
overview, 117
- Neoplasms, pancreatic. *See* Cancer, pancreas, and other periampullary cancers
- Neuroendocrine tumors, colon, 746
- Nipple valve prolapse, 714–715
- Nipple valve slippage, 714
- Nissen fundoplication, 297, 297f, 335f, 354  
laparoscopic, 334–338, 336f–339f
- Nodular lymphoid hyperplasia, colon, 747
- Nodular regenerative hyperplasia, 933

- NOMI (nonocclusive mesenteric ischemia), 271–272
- Noncontact thermal techniques, 38, 38*f*
- Non-Hodgkin's lymphoma  
clinical presentation, 616  
diagnosis, 616, 617*f*  
overview, 616  
staging and prognosis, 616, 617*t*  
treatment, 616–617
- Nonocclusive mesenteric ischemia (NOMI), 271–272
- Nonulcerative dyspepsia, 445
- Nonvariceal bleeding, 222–223
- NOTES (natural orifice transluminal endoscopic surgery), 1007
- Nutcracker esophagus, 298, 301*f*  
high-resolution manometry, 332, 332*f*
- Nutritional evaluation, 24–26, 25*t*
- O**
- Obesity, morbid  
bariatric surgery  
adjustable gastric banding  
laparoscopic approach  
complications, 553–554  
operative procedure, 551–552  
outcomes, 553  
overview, 551  
postoperative care, 552–553  
preoperative preparation, 549
- age limit, 573–574
- biliopancreatic diversion  
operative procedure, 570  
overview, 570  
postoperative care, 570–571
- duodenal switch  
complications, 571–572  
follow-up, 571  
operative procedure, 570  
outcomes, 571  
overview, 570  
postoperative care, 570–571  
preoperative preparation, 550
- endoscopic, 574
- innovation in, 580–581
- during pregnancy, 573
- preoperative preparation, 548–550
- revisional surgery, 572–573
- Roux-en-Y gastric bypass  
for cholelithiasis, 566  
complication, 566–567  
for diabetes, 566  
follow-up, 565  
for gastroesophageal reflux disease, 566  
laparoscopic approach  
completion of, 563  
creating gastrojejunostomy, 562–563  
creating proximal gastric pouch, 560–562  
creating the Roux limb, 558–559  
enteroenterostomy, 559  
mesenteric defect closure, 563  
overview, 557  
passing the Roux limb, 559–560  
patient positioning and preparation, 557
- pneumoperitoneum and port placement, 557–558  
preoperative preparation, 549–550
- nutritional issues and complications in, 569–570
- open approach  
creating gastric pouch, 564  
drains, oversewing and gastrostomies, 564  
enteroenterostomy, 563  
incision and exposure, 563  
overview, 563  
passing the Roux limb, 564
- outcomes, 565–566  
postoperative care, 564–565  
specific complications and their treatment, 567, 568–569
- selection of patients, 548
- sleeve gastrectomy  
laparoscopic approach  
complications, 556–557  
operative procedure, 555–556  
outcomes, 556  
overview, 554  
postoperative care, 556  
preoperative preparation, 550
- sleeve gastrectomy, laparoscopic approach.  
*See* Laparoscopic sleeve gastrectomy
- weight limit, 574
- diabetes surgery, 579
- epidemiology, 545
- medical therapy, 547–548
- overview, 545–546
- pathophysiology of, 546–547
- Oblique incisions, 99
- Obstruction, bowel  
definitions, 585–587  
early postoperative (mechanical), 587  
functional, 586–587, 586*t*  
mechanical, 585–586, 586*t*
- diagnosis  
history and physical examination, 595–596  
ischemia, detection of, 600  
laboratory, 596–597  
overview, 595  
radiologic findings  
contrast studies, 597–599, 598*f*  
CT, 599  
flat and upright abdominal radiographs, 597, 597*f*  
magnetic resonance enterography, 600  
overview, 597  
ultrasonography, 599–600  
video capsule endoscopy, 600
- epidemiology, 586*f*–587*f*
- etiology  
adhesions, 590–591  
Crohn's disease, 593  
granulomatous disease, 593  
hernia, 591, 592*f*  
after laparoscopic gastric bypass, 591–592  
trocar site, 593  
intussusception, 593–594  
malignant bowel obstruction, 593, 593*f*  
miscellaneous causes, 595, 595*f*
- volvulus, 594, 594*f*–595*f*
- management  
nonoperative, 601–602  
operative  
adhesion prevention, 605  
bypass versus resection, 604  
carcinomatosis and malignant obstruction, 607–608, 608*f*  
early postoperative small bowel obstruction, 605–606  
overview, 603  
radiation enteropathy, 607  
recurrent small bowel obstruction, 604–605  
after Roux-en-Y gastric bypass, 606–607  
small bowel obstruction, 600–601  
when to convert to operative, 602
- overview, 585
- pathophysiology  
circulatory changes, 589  
distention, absorption, and secretion, 588–589  
intestinal motility, 589  
microbiology and bacterial translocation, 589–590  
overview, 588
- Obstruction, duodenal, 673
- Obstruction, intestinal, 1200–1201, 1202, 1202*f*
- Obturator hernia  
anatomy, 143, 144*f*  
clinical manifestations, 144  
incidence, 142–143  
overview, 142  
results, 145  
treatment, 144–145, 145*f*
- Oliguria in the perioperative patient, 20*t*
- Omentobursectomy, 490
- Open abdominal dressing, 115*f*
- Opisthorchis viverrini*, 1067
- OPSI (overwhelming postsplenectomy infection), 252
- Optical coherence tomography, 33, 33*f*
- Optical trocars, 66
- Oral fistulas, 204
- Oropharyngeal dysphagia, 319
- Overwhelming postsplenectomy infection (OPSI), 252
- P**
- Paget's disease, 893–894
- Pain and delirium, management of, 7  
epidural analgesia, 7–8  
NSAIDs, analgesia with, 8  
opioid analgesia, 7  
postoperative delirium, 8–9, 8*t*
- Pancreas  
cancer. *See* Cancer, pancreas, and other periampullary cancers  
cystic neoplasms. *See* Pancreas, cystic neoplasms of  
of  
endocrine tumors. *See* Endocrine tumors of the pancreas  
pancreatitis, acute. *See* Pancreatitis, acute  
pancreatitis, chronic. *See* Pancreatitis, chronic



- Pancreas, cystic neoplasms of  
 intraductal papillary mucinous neoplasms  
 clinical presentation, 1180  
 diagnosis, 1181  
 overview, 1178, 1179*f*  
 pathologic features, 1178–1180, 1179*f*  
 treatment, 1181–1183, 1182*f*
- mucinous cystic neoplasms  
 clinical presentation, 1176  
 diagnosis, 1176–1177, 1177*f*  
 overview, 1175–1176  
 pathologic features, 1176, 1176*f*  
 treatment, 1177–1178, 1178*f*
- overview, 1171  
 pathologic classification, 1172, 1172*f*, 1172*t*
- serous cystic neoplasms (SCNs)  
 clinical presentation, 1173  
 diagnosis, 1172*f*–1173*f*, 1173–1174  
 overview, 1172  
 pathologic features, 1172–1173, 1172*f*,  
 1173*f*  
 treatment, 1174–1175, 1175*f*, 1175*t*
- unusual neoplasms  
 cystic acinar cell neoplasms, 1184  
 cystic degeneration of ductal  
 adenocarcinoma, 1184  
 cystic neuroendocrine neoplasms, 1184  
 solid pseudopapillary neoplasms, 1183,  
 1183*f*
- Pancreatectomy, 1229–1230, 1234
- Pancreatic duct stones, 50
- Pancreaticoduodenectomy, 1157–1159,  
 1158*f*–1159*f*, 1187, 1196–1199,  
 1196*f*–1198*f*, 1228–1229, 1234
- Pancreatitis, acute  
 cardiovascular complications, 1141–1142  
 diagnosis, staging, and severity  
 classification system, 1101–1102, 1101*t*  
 clinical scoring system, 1098–1099, 1099*t*  
 contrast-enhanced computed tomography,  
 1099–1101  
 markers of severity, 1099  
 overview, 1098
- encephalopathy, 1142
- etiology, 1097–1098, 1098*t*
- local complications  
 acute fluid collections, 1122*f*  
 diagnosis, 1119, 1121*f*  
 management, 1120  
 overview, 1119
- overview, 1119
- pancreatic abscess, 1139
- pancreatic necrosis  
 epidemiology, 1130  
 general principles for intervention, 1134,  
 1134*f*, 1135*t*  
 indications for intervention, 1132  
 microbiology of infected necrosis, 1131  
 open surgical procedures  
 endoscopic techniques, 1136  
 flexible endoscopic techniques,  
 1137–1138  
 laparoscopic techniques, 1136–1137  
 necrosectomy with closed packing,  
 1135
- necrosectomy with continuous closed  
 postoperative lavage, 1136
- necrosectomy with open packing, 1136
- nephroscopic techniques, 1137, 1137*f*
- overview, 1134–1135, 1135*f*–1136*f*
- radiologic debridement techniques,  
 1138
- radiological drainage techniques, 1138
- radiological techniques, 1138
- overview, 1130
- pathogenesis, 1130–1131
- prediction and diagnosis, 1122*f*, 1131–  
 1132
- prognosis, 1138
- timing of intervention, 1132–1133
- type of intervention, 1133
- postnecrotic pancreatic and peripancreatic  
 fluid collections  
 diagnosis, 1120, 1122*f*  
 management, 1120  
 overview, 1120
- pseudocyst  
 complications, 1123, 1123*f*–1124*f*  
 diagnosis, 1123–1125, 1124*f*  
 management  
 endoscopic treatment, 1129  
 minimally invasive surgery, 1129–1130  
 open surgical treatment, 1126, 1127*f*,  
 1128*f*  
 overview, 1125–1126, 1126*t*, 1130  
 radiological treatment, 1126, 1129,  
 1129*f*  
 overview, 1120–1122, 1122*f*  
 pathogenesis and classification, 1122–  
 1123, 1123*t*
- management of patients  
 definitive drainage  
 postoperative management, 1170  
 who and when?, 1169–1170  
 overview, 1167, 1170
- presentation and initial assessment  
 first 24–48 hours, 1167–1169  
 overview, 1167, 1168*f*
- management principles  
 endoscopic retrograde  
 cholangiopancreatography, 1103  
 nutritional support, 1102–1103  
 prophylactic antibiotics, 1103–1104  
 resuscitation and monitoring, 1102
- surgical management: indications and timing  
 infected pancreatic necrosis, 1105  
 organized pancreatic necrosis, 1106–1107  
 overview, 1104–1105, 1105*t*  
 severe sterile pancreatic necrosis, 1105–  
 1106, 1106*f*
- markers of severity, 1100*f*–1101*f*
- metabolic complications, 1142, 1142*f*
- overview, 1097, 1115, 1119, 1120*t*, 1142
- programmed necrosectomy, 1136
- regional complications of, 1139–1140
- intestinal  
 cholestasis, 1140  
 ischemia and necrosis, 1140  
 obstruction, 1140  
 paralytic ileus, 1140
- vascular  
 bleeding, 1139  
 venous thrombosis, 1139
- renal complications, 1141
- respiratory complications, 1141
- surgical procedures  
 overview, 1107*f*, 1108
- pancreatic debridement  
 closed drainage and, 1112*f*  
 comparison of techniques, 1113–1114  
 continuous closed postoperative lavage of  
 lesser sac and, 1112–1113  
 minimally invasive approaches, 1114–  
 1115  
 overview, 1108*t*, 1109  
 techniques, 1109–1112, 1109*f*–1111*f*  
 closed drainage and, 1110  
 open drainage for pancreatic necrosis,  
 1111–1112
- resection, 1108–1109
- systemic complications of, 1140–1142  
 multiple organ dysfunction syndrome,  
 1140–1141, 1141*f*  
 systemic inflammatory response syndrome,  
 1140
- Pancreatitis, chronic  
 Cambridge classification, 1153*t*  
 clinical presentation, 1150–1151, 1151*f*  
 definition and risk factors of  
 autoimmune, 1149  
 genetic, 1148–1149  
 idiopathic, 1148  
 obstructive, 1149–1150, 1150*f*  
 overview, 1147–1148  
 recurrent and severe acute pancreatitis, 1149
- TIGAR-O system, 1148, 1148*t*  
 toxic or metabolic, 1148
- diagnosis, 1151–1154, 1151*f*–1152*f*, 1153*t*
- medical management, 1154–1155, 1154*f*,  
 1155*t*
- overview, 1147, 1163–1164
- pathophysiology and mechanism of pain, 1150
- surgical management  
 with dominant pancreatic head mass, 1156–  
 1157, 1157*t*
- Beger procedure  
 operative technique, 1159–1160  
 vs pancreaticoduodenectomy, 1160–  
 1161
- Berne procedure  
 operative technique and outcome, 1162
- Frey procedure  
 vs Beger procedure, 1161  
 operative technique, 1161
- pancreaticoduodenectomy technique,  
 1157–1159, 1158*f*–1159*f*
- large-duct disease, 1155  
 lateral pancreaticojejunostomy  
 operative technique, 1155–1156, 1156*f*  
 outcomes, 1156
- overview, 1155
- small duct disease and diffuse sclerosis  
 autologous islet transplantation outcomes,  
 1163
- izbicki procedure

- technique and outcomes, 1163
  - overview, 1162
  - total pancreatectomy with autologous islet transplantation technique, 1162
- Pappenheimer bodies, 1243
- Paracolostomy hernia, 174
- Paraesophageal hernia, 341–342
  - clinical presentation, 292–293
  - defect closure, 352
  - diagnosis and evaluation, 293
  - endoscopy, 293
  - etiology and anatomic classification, 291, 292*f*
  - hernia recurrence, 351–352
  - imaging studies, 293, 293*f*
  - indications for treatment, 294
  - manometry and pH testing, 293–294
  - operative technique: laparoscopic repair
    - crural repair, 296–297, 297*f*
    - dissection, 295–296
    - fundoplication, 297, 297*f*
    - positioning and ports, 295, 296*f*
  - overview, 291, 351
  - repair technique, 351–352
  - therapeutic controversies
    - crural repair, 295
    - operative approach, 294
    - overview, 294
    - routine fundoplication, 295
- Paraganglioma, 1273
- Paralytic ileus, 1140
- Paramedian incisions, 101, 101*f*–103*f*
- Parietal cell vagotomy, 515*f*
- Partial fundoplication, 352, 353
  - laparoscopic
    - Dor fundoplication, 338–339
    - overview, 338
    - Toupet fundoplication, 339
- Partial hepatectomy, 938–940, 939*f*–941*f*, 939*t*, 944
- Patient-controlled analgesia (PCA), 7–8
- PDGFRA* tyrosine kinase receptor, 494, 494*f*, 619, 746
- Pedicle jejunal interposition, 411, 411*f*
- PEG. *See* Percutaneous endoscopic gastrostomy
- PEG-J (percutaneous endoscopic gastrostomy and jejunostomy), 43
- Peliosis hepatitis, 933
- Pelvic exenteration, 861, 861*f*
- Pelvic floor outlet obstruction and solitary rectal ulcer syndrome
  - diagnosis and evaluation, 815–816, 816*f*
  - pathophysiology, 815
  - rectocele, enterocele, and complex pelvic floor abnormalities, 816–817
  - treatment and management, 816
- Peptic ulcer disease
  - and bleeding, 222–223, 223*f*, 223*t*
  - epidemiology, 445
  - pathophysiology, 445
- Percutaneous endoscopic gastrostomy (PEG), 41–42
  - interventional radiology–assisted, 42
  - introducer technique, 42
  - with jejunostomy tube extension, 42–43
  - laparoscopic-assisted, 42
  - pull technique, 42, 42*f*
  - push technique, 42
- Percutaneous endoscopic gastrostomy and jejunostomy (PEG-J), 43
- Percutaneous transhepatic cholangiography (PTC), 1015
- Perforated appendicitis, 625–626, 638–639
  - interval appendectomy, 639
  - normal appendix, 639–640
- Perforation, 673–674, 700
  - stomach, 452–453
- Periapillary cancers. *See* Cancer, pancreas, and other periapillary cancers
- Perianal cancer. *See* Anal margin cancer
- Perianal disease, 686–687, 686*f*
- Pericystectomy, 919
- Perineal hernias
  - anatomy, 145–146, 146*f*
  - clinical manifestations, 146
  - etiology, 145
  - overview, 145
  - treatment, 146
- Peutz-Jeghers syndrome, 740
- Pfannenstiel incisions, 102, 106*f*
- p53* gene, 737
- pH monitoring, 342
  - ambulatory, 328–330, 330*t*
  - combined multichannel intraluminal impedance, 330, 331*f*
- Pharyngeal fistulas, 204
- Pheochromocytoma, 1271–1273
- Photodynamic therapy, 862
- Plicator device, 45
- Pneumoperitoneum, 76, 999
  - physiologic effects of
    - carbon dioxide–related effects
    - capnothorax/pneumothorax, 73
    - carbon dioxide embolus, 73
    - hypercapnia, 72–73
    - overview, 71–72
- Pneumothorax, 73
- Polyp retrieval, 57
- Polyp surveillance, 57
- Polypectomy
  - overview, 56, 56*f*
  - polyp retrieval, 57
  - polyp surveillance, 57
- Polypos, 458, 834–835, 834*f*
  - architecture
    - adenomatous polyps (adenomas), 741–742, 741*t*, 742*f*
    - hamartomatous polyp, 742–743
    - hyperplastic polyps, 743
    - inflammatory, 743
    - overview, 741
    - transformation, 743
  - attachment to bowel wall, 741
  - management, 743–744
  - overview, 740–741
  - size, 741
- Polytetrafluoroethylene (PTFE) mesh, 131
- Port placement
  - access of placement of first port, 65–66, 65*f*–67*f*
  - difficult access, 66–67
  - fascial closure, 67, 67*f*
- port characteristics, 64–65, 65*f*
  - site selection, 64, 65*f*
  - trocár injury, 67–68
- Portal hypertension, 228*f*, 229*f*
  - complications, 982
  - etiology, 982–983, 982*f*
  - evaluation, 983–984, 983*t*
  - history, 981
  - management
    - acute variceal bleeding, 989
    - ascites, 990
    - endoscopic
      - overview, 229
      - prevention of rebleeding, 229
    - medical, 229
    - prophylaxis, 988–989
    - radiologic or surgical portal decompression., 230
    - rebleeding, prevention of, 989–990
  - multidisciplinary team, 991
  - overview, 228–229, 981
  - pathophysiology, 982
  - pulmonary syndromes and, 990–991, 990*t*
  - variceal bleeding, management of, 987*f*
    - decompressive shunts, 985
    - devascularization procedures, 987–988
    - endoscopic therapy, 984–985
    - liver transplantation, 988
    - overview, 984, 984*f*
    - partial shunts, 986
    - selective shunts, 986, 986*f*
    - total shunts, 985–986, 985*f*
    - transjugular intrahepatic portal systemic shunt, 986–987, 987*f*
- Portopulmonary hypertension (PPH), portal hypertension and, 990–991
- Positron emission tomography with computed tomography (PET-CT), 795
- Post-ERCP pancreatitis, 51–52
- Posterior vaginectomy, 860, 860*f*
- Postgastrectomy syndromes
  - alkaline reflux gastritis, 456, 456*f*
  - dumping, 455, 455*t*
  - overview, 455
- Postoperative ventral wall (incisional) hernia
  - clinical manifestations, 150
  - complications, 154
  - incidence and etiology, 150
  - overview, 150
  - treatment
    - laparoscopic repair, 152, 154
    - mesh repair, 152, 153*f*
    - overview, 150–151
    - primary suture repair, 151–152, 151*f*
- Postoperative wound management
  - dressings the wound, 115
  - wound complications
    - abdominal wound dehiscence and evisceration, 120
    - hematoma, 119–120
    - incisional hernia, 120
    - necrotizing wound infections
      - gas gangrene, 117, 119
      - necrotizing fasciitis, 119
      - overview, 117

- Postoperative wound management, wound complications, necrotizing wound infections (*Cont.*):  
 seroma, 119–120  
 stitch abscess, 120  
 surgical site infections, 115–117, 116*t*–119*t*
- Posttransplant lymphoproliferative disorder (PTLD), 612
- Pouch  
 colonic, 856  
 vaginal fistula, 716
- Pouchitis, 717–718, 717*f*; 728
- Preoperative and postoperative management  
 antithrombotics, management of, 14–15  
 cardiac evaluation  
 arrhythmia, 12  
 congestive heart failure, 12  
 coronary disease, 11–12  
 risk assessment, 9–11, 9*t*–10*t*, 11*f*  
 valvular disease, 12–14, 13*t*
- gastrointestinal evaluation  
 early postoperative bowel obstruction, 17–18  
 overview, 16  
 postoperative ileus, 16–17  
 renal evaluation, 18–20, 20*t*
- glycemic control, 20–21  
 hematological evaluation, 21–23  
 infectious complications, 23–24, 23*t*  
 nutritional evaluation, 24–26, 25*t*  
 overview, 7  
 pain and delirium, management of, 7  
 epidural analgesia, 7–8  
 NSAIDs, analgesia with, 8  
 opioid analgesia, 7  
 postoperative delirium, 8–9, 8*t*  
 pulmonary evaluation, 15–16
- Primary sclerosing cholangitis, 943
- Proctitis, 685
- Proctocolectomy, 704–706  
 restorative  
 ileal J-pouch–anal anastomosis  
 colon mobilization, 790–791  
 exteriorization of colon and rectum, 791  
 formation of, 791–792, 792*f*  
 formation of loop ileostomy, 792  
 hand-assisted, 792  
 patient position and room setup, 790  
 port placement and exploration, 790, 791*f*  
 rectal mobilization, 791
- Proctocolitis, 685
- Proctoscopy, 750
- Prostatectomy, 861
- Proton pump inhibitors (PPI) therapy, for gastroesophageal disease, 353–354
- Pseudocyst, pancreatic  
 complications, 1123, 1123*f*–1124*f*  
 diagnosis, 1123–1125, 1124*f*  
 management  
 endoscopic treatment, 1129  
 minimally invasive surgery, 1129–1130  
 open surgical treatment, 1126, 1127*f*; 1128*f*  
 overview, 1125–1126, 1126*t*, 1130  
 radiological treatment, 1126, 1129, 1129*f*  
 overview, 1120–1122, 1122*f*  
 pathogenesis and classification, 1122–1123, 1123*t*
- PTC (percutaneous transhepatic cholangiography), 1015
- PTFE (polytetrafluoroethylene) mesh, 131
- PTLD (posttransplant lymphoproliferative disorder), 612
- Pudendal nerve, 804*f*
- Pugh–Child classification, 938, 938*t*, 983, 983*t*
- “Pull” PEG, 42, 42*f*
- Pulmonary evaluation, 15–16
- Purpuras  
 hemolytic uremic syndrome (HUS), 1254  
 idiopathic thrombocytopenic purpura (ITP), 1253–1254  
 thrombotic thrombocytopenic purpura (TTP), 1254
- “Push” PEG, 42
- Pyloric dilatation, 517
- Pyloromyotomy, 518, 518*f*
- Pyloroplasty, 518–519, 519*f*–520*f*
- Pyogenic cholangiohepatitis, 943–944
- Pyogenic liver abscess  
 bacteriology, 903–904, 903*t*  
 clinical presentation, 904, 904*t*  
 complications, 907, 909  
 diagnosis, 904  
 etiology, 901–902, 902*f*  
 incidence, 902  
 laboratory evaluation, 904  
 outcome, 909, 909*t*  
 overview, 901  
 pathology, 903  
 predisposing factors, 902–903, 903*t*  
 radiology, 904–905, 905*f*–907*f*  
 treatment  
 antibiotics, 905–906  
 antifungals, 907  
 aspiration and percutaneous catheter drainage, 907, 908*f*  
 overview, 905  
 surgical drainage, 907
- Pyruvate kinase deficiency, 1250
- R**
- Radiation enteropathy, 595, 595*f*; 607
- Radiation proctitis, 234, 234*f*
- Radiofrequency ablation (RFA), 963–964, 964*f*; 972, 978–979
- Ranson score for acute pancreatitis, 1098, 1099*t*
- Rectal cancer. *See* Cancer, rectum
- Rectal disease  
 technical procedures for  
 abdominal perineal resection  
 colostomy, 788  
 exteriorization of the specimen and wound closure, 788  
 hand-assisted, 789  
 mobilization of the sigmoid colon and the rectum, 787–788  
 patient position and room setup, 787  
 perineal resection, 788  
 port placement and exploration, 787  
 vascular ligation, 787
- anterior resection  
 anastomosis, 785  
 excision of the rectum and exteriorization, 785  
 mobilization of the left colon and sigmoid colon, 785  
 mobilization of the rectum, 785  
 patient position and room setup, 784  
 port placement and exploration, 784  
 vascular ligation, 785
- low anterior resection  
 anastomosis, 786–787, 787*f*  
 excision of the rectum, 786, 786*f*  
 hand-assisted, 787  
 mobilization of the left colon, 785  
 mobilization of the rectum, 786  
 patient position and room setup, 785  
 port placement and exploration, 785  
 vascular pedicle ligation, 785–786  
 overview, 784
- Rectal prolapse and internal intussusception management  
 internal intussusception, 815  
 rectal prolapse, 812, 813*f*–814*f*; 815  
 pathophysiology  
 diagnosis and evaluation, 811–812, 812*t*  
 etiology and physiology, 810–811, 811*f*
- Rectopexy, resection, 789
- Rectum and anus  
 anorectum, benign disorders of. *See* Anorectum, benign disorders of  
 anus, cancer of. *See* Cancer, anus  
 rectum, cancer of. *See* Cancer, rectum
- Recurrent pyogenic cholangitis and other parasitic disease  
 biliary strictures and, 1053–1054, 1053*f*
- Regenerative nodular hyperplasia, 978
- Resection, intestinal, 675, 675*f*
- Restorative total proctocolectomy  
 ileal J-pouch–anal anastomosis  
 colon mobilization, 790–791  
 exteriorization of colon and rectum, 791  
 formation of, 791–792, 792*f*  
 formation of loop ileostomy, 792  
 hand-assisted, 792  
 patient position and room setup, 790  
 port placement and exploration, 790, 791*f*  
 rectal mobilization, 791
- Retroperitoneal and extraperitoneal incisions  
 overview, 104–105  
 posterior approach to adrenal glands, 105, 108, 109*f*  
 retroperitoneal approach to iliac fossa, 108, 110*f*  
 retroperitoneal approach to lumbar area, 105, 108*f*
- Retroperitoneal hematomas, 246–247, 246*t*
- Retroperitoneoscopic adrenalectomy, 1278–1279
- RFA (radiofrequency ablation), 963–964, 964*f*; 972, 978–979
- Right adrenalectomy, laparoscopic, 1275–1277, 1275*f*–1277*f*
- Right hemicolectomy  
 alternative technique, 777–778  
 anastomosis, 775, 777  
 exteriorization, 775, 777*f*  
 mobilization of cecum, 774, 775*f*

- mobilization of hepatic flexure, 774, 776*f*
    - patient position and room setup, 774
    - port placement and exploration, 774–775, 774*f*
    - vascular division, 774–775, 776*f*
  - Right-sided colitis, 684
  - Rigid proctoscopy, 750
  - Rives prosthetic mesh repair, 132, 134*f*
  - Robotics, 6
  - Rockey-Davis muscle splitting incisions, 102
  - Roux-en-Y gastric bypass, 410–411, 410*f*
    - for cholelithiasis, 566
    - complication, 566–567
    - for diabetes, 566
    - follow-up, 565
    - for gastroesophageal reflux disease, 566
    - versus laparoscopic adjustable gastric banding, 553*f*
  - laparoscopic approach
    - completion of, 563
    - complication, 567*t*, 568*f*
    - creating gastrojejunostomy, 562–563
    - creating proximal gastric pouch, 560–562
    - creating the Roux limb, 558–559
    - enteroenterostomy, 559
    - mesenteric defect closure, 563
    - operative procedure, 558*f*–563*f*
    - overview, 557
    - passing the Roux limb, 559–560
    - patient positioning and preparation, 557
    - pneumoperitoneum and port placement, 557–558
  - nutritional issues and complications in, 569–570
  - open approach
    - creating gastric pouch, 564
    - drains, oversewing and gastrostomies, 564
    - enteroenterostomy, 563
    - incision and exposure, 563
    - overview, 563
    - passing the Roux limb, 564
  - outcome, 565–566, 565*f*, 565*t*
  - postoperative care, 564–565
  - preoperative preparation, 549–550
  - revisional surgery, 573
  - specific complications and their treatment, 567*f*
    - long-term, 568–569
    - post-operative, 567
- Roux-en-Y reconstruction, 475–477, 475*f*–477*f*
- S**
- Saline lift technique, 40, 40*f*
- SBE (single balloon endoscopy) system, 52
- Sciatic hernia, 149–150, 149*f*
- SCNs. *See* Serous cystic neoplasms
- Scolicidal agents, 918–919
- Segmental colitis, 685–686
- Segura basket, 1081
- Selective vagotomy, 513, 513*f*
- Self-propelled colonoscopes, 34
- Separated loop ileostomy, 179, 180*f*, 182*f*
- Serous cystic neoplasms (SCNs)
  - clinical presentation, 1173
  - diagnosis, 1172*f*–1173*f*; 1173–1174
  - overview, 1172
- pathologic features, 1172–1173, 1172*f*; 1173*f*
- treatment, 1174–1175, 1175*f*; 1175*t*
- Sexually transmitted anal disease
  - chlamydial infections, 830
  - gonorrhea, 831
  - herpes simplex virus, 831
  - human papillomavirus (HPV), 830
  - overview, 829–830
  - syphilis, 831
- Shape-locking device, 34
- Short esophagus, 341–342
- Shouldice technique, 124, 129–131, 130*f*
- Sickle cell disease, 1251–1252, 1252*f*
- Siewert's classification, 361, 362*f*
- Sigmoid colectomy
  - anastomosis, 782–783
  - mobilization of distal sigmoid colon and upper rectum, 781–782, 782*f*
  - mobilization of proximal sigmoid and descending colon, 781
  - patient position, 780–781
  - port placement and exploration, 781, 782*f*
  - vascular ligation and exteriorization, 782, 782*f*, 783*f*
- Sigmoidectomy, 783
- Sigmoidoscopy, 750
- Silastic stents, 1046–1047, 1071–1072, 1072*f*
- Single balloon endoscopy (SBE) system, 52
- Single-port laparoscopic surgery, 1007
- SIRS (systemic inflammatory response syndrome), 1140
- SMAD-4* gene, 740
- Small bowel, Crohn's disease of
  - abscess, 683, 683*f*
  - complete intestinal obstruction, 682
  - enterovaginal and enterocutaneous fistulas, 683
  - hemorrhage, 684
  - ileosigmoid fistulas, 682, 682*f*
  - ileovesical fistula, 682–683
  - perforation, 683–684
- Small bowel diverticula
  - duodenal diverticula, 642
  - jejunoileal diverticula, 643
  - Meckel's diverticula, 643–644
  - overview, 641–642
- Small bowel enteroscopy, 52
- Small bowel fistulas, 204
- Small bowel obstruction, 711
  - early postoperative, 605–606
  - management, 600–601
  - recurrent, 601*f*, 604–605
- Small intestine, tumors of
  - benign tumors
    - adenomas, 614–615, 614*f*
    - Brunner gland adenomas, 614
    - hamartomas, 615
    - hemangiomas, 615
    - lipomas, 615
    - overview, 614
  - clinical presentation, 612
  - diagnosis, 612–613, 613*f*
  - epidemiology, 611
  - malignant neoplasms
    - adenocarcinoma
      - clinical presentation, 615–616, 615*f*
      - diagnosis, 616
      - epidemiology, 615
      - management, 616
      - staging and prognosis, 616
    - carcinoid tumors
      - carcinoid syndrome, 618–619
      - clinical presentation, 617
      - diagnosis, 617, 618*f*
      - overview, 617
      - staging and prognosis, 617–618
    - gastrointestinal stromal tumors (GIST)
      - molecular therapeutics and gastrointestinal stromal tumors, 619–620
      - overview, 619, 619*f*
      - treatment, 619
    - metastatic lesions to small bowel, 620
    - non-Hodgkin's lymphoma
      - clinical presentation, 616
      - diagnosis, 616, 617*f*
      - overview, 616
      - staging and prognosis, 616, 617*t*
      - treatment, 616–617
    - overview, 615
    - overview, 611
    - pathogenesis
      - high-risk populations
        - celiac disease, 612
        - Crohn's disease, 612
        - familial adenomatous polyposis, 612
        - miscellaneous conditions, 612
      - overview, 611–612
- Small intestine and colon
  - appendix. *See* Appendix
  - bowel obstruction. *See* Obstruction, bowel
  - colon, tumors of. *See* Colon, tumors of
  - Crohn's disease. *See* Crohn's disease
  - diverticular disease of the colon. *See* Diverticular disease of the colon
  - tumors of small intestine. *See* Small intestine, tumors of
  - ulcerative colitis. *See* Ulcerative colitis
- Smooth muscle tumors, colon, 747
- SOD. *See* Sphincter of Oddi
- Somatostatinoma, 1218, 1224–1225
- Sorafenib, for hepatocellular carcinoma, 971
- Spastic motility disorders
  - diffuse esophageal spasm, 298, 300*f*
  - hypertensive lower esophageal sphincter, 298, 302*f*, 303
  - nutcracker esophagus, 298, 301*f*
  - overview, 297
  - patient presentation and evaluation, 298, 299*f*
- Spherocytosis, hereditary, 1249–1250
- Sphincter of Oddi (SOD)
  - ERCP, 48–49
  - stenosis, biliary strictures and, 1054
- Sphincterotomy, 47, 47*f*–48*f*, 1011
- Spigelian hernia
  - anatomy, 147–148, 147*f*
  - clinical manifestations, 148
  - overview, 147
  - treatment, 148



- Spleen
- background, 1239
  - hematologic disorders, 1249
    - anemias
      - hereditary elliptocytosis, 1250
      - hereditary spherocytosis, 1249–1250
      - immune hemolytic anemia, 1252–1253
    - overview, 1249
    - pyruvate kinase deficiency, 1250
    - sickle cell disease, 1251–1252, 1252*f*
    - thalassemia, 1251
  - hematopoietic neoplasms and lymphomas
    - indications for splenectomy in
      - lymphoproliferative disorders, 1255–1256
    - lymphoid neoplasms, 1255
    - myeloid neoplasms, 1255
    - overview, 1254
  - local splenic disorders
    - abscesses, 1247–1248
    - cysts
      - overview, 1246, 1246*f*
      - primary
        - nonparasitic, 1247
        - parasitic, 1247
      - secondary pseudocysts, 1247
    - splenic artery aneurysms, 1245–1246, 1246*f*
    - tumors
      - benign neoplasms, 1248–1249
      - metastatic, 1249, 1249*f*
      - overview, 1248, 1248*f*
      - primary malignant, 1249
  - preserving approaches
    - overview, 1265
    - partial splenectomy, 1267–1268
  - purpuras
    - hemolytic uremic syndrome (HUS), 1254
    - idiopathic thrombocytopenic purpura (ITP), 1253–1254
    - thrombotic thrombocytopenic purpura (TTP), 1254
  - relevant anatomy
    - gross anatomy, 1239–1240, 1240*f*–1242*f*
    - histology, 1242, 1243*f*
    - physiology, 1242–1243
    - splenic blood supply, 1240, 1242, 1242*f*
  - splenectomy, 1256*f*
    - laparoscopic
      - approaches, 1259
      - complications, 1263–1264, 1264*f*, 1264*t*
      - hand-assisted laparoscopic surgery, 1262–1263
      - overview, 1258, 1258*t*
      - patient selection approach, 1258
      - postoperative management, 1263
      - preoperative splenic artery embolization, 1258–1259, 1259*t*
      - procedure, lateral approach
        - dissection, 1260–1262, 1261*f*–1262*f*
        - patient positioning and room setup, 1259–1260, 1259*f*
        - removal of specimen, 1262
        - trocar placement, 1260, 1260*f*
      - single-incision, 1263
      - open, 1264–1265, 1264*f*–1266*f*
    - overview, 251, 1256
    - preoperative preparation
      - daily prophylactic antibiotic, 1257
      - overview, 1256–1257
      - patient education and rescue antibiotics, 1257–1258
      - vaccination, 1257, 1257*t*
    - trauma and rupture of
      - diagnostic studies, 1244, 1244*t*
      - etiology, 1243–1244, 1244*f*
      - management, 1245
  - Splenic artery aneurysms, 284
  - Splenoptosis, 1239–1240
  - Splenorrhaphy, 251–252, 1267, 1267*f*
  - Sporadic colon cancer, 738
  - Squamous cell cancer, esophageal, 365
  - Squamous cell carcinoma, anal
    - anal intraepithelial neoplasia
      - diagnosis and treatment, 882–883
      - HPV vaccines, 883
    - chemoradiation, 886–888, 887*t*, 889*t*
    - diagnosis and staging, 884–885, 884*f*, 885*t*
    - etiology, pathogenesis, and risk factors
      - chronic inflammation, 881–882
      - HIV, 881
      - human papillomavirus (HPV), 881
      - smoking, 881
    - incidence and epidemiology, 880–881
    - inguinal nodal metastases, treatment of, 889
    - pathology, 883–884
    - radiotherapy, newer modalities for, 888
    - recurrent disease and salvage therapy, 889–891, 890*t*
    - surgical management, 885
  - Squamous intraepithelial neoplasia, 830
  - Staging, laparoscopic
    - biliary and gastric bypass
      - overview, 88–89, 88*f*
      - technique, 89, 90*f*–92*f*, 92
    - complications, 87–88
    - esophageal carcinoma, 78–80, 79*t*
    - gastric cancer, 80–82, 81*f*
    - liver and gallbladder cancer, 82–84, 83*f*, 83*t*
    - overview, 75
    - pancreatic cancer
      - carbohydrate antigen 19-9, 85, 86*f*
      - laparoscopic ultrasonography, 85–86, 86*f*
      - locally advanced disease, 87
      - overview, 84–85, 84*f*, 85*t*
      - peritoneal cytology, 86–87
    - rationale for, 75
    - surgical technique, 75–78, 76*f*–78*f*
  - Stapled transanal rectal resection (STARR), 815
  - Stitch abscess, 120
  - Stomach and duodenum
    - gastric adenocarcinoma. *See* Gastric adenocarcinoma
    - gastric disorders, benign. *See* Gastric disorders, benign
    - gastrointestinal stromal tumors (GIST). *See* Gastrointestinal stromal tumors (GIST)
    - obesity. *See* Obesity, morbid
    - surgery. *See* Stomach and duodenum, operative procedures
  - Stomach and duodenum, operative procedures
    - drainage procedures
      - overview, 517
      - pyloric dilatation, 517
      - pyloromyotomy, 518
      - pyloroplasty, 518–519
    - gastric resections
      - distal gastric resections and reconstructions
        - laparoscopic approaches
          - anterior proximal vagotomy or seromyotomy, 539*f*–540*f*, 540
        - gastric resection, 541–542, 541*f*–542*f*
        - patient and port placement, 538, 538*f*
        - truncal vagotomy, 538*f*–540*f*, 539–540
        - to vagus nerve, 536, 538
      - subtotal and total gastric resections
        - overview, 529
        - subtotal and near-total resections, 529–530
        - total gastrectomy for carcinoma, 531–535, 532*f*–536*f*
      - vagotomy and antrectomy
        - Bilroth-I reconstruction, 523–524
        - Bilroth-II reconstruction, 524–529, 526*f*–531*f*
        - overview, 522
    - laparoendoscopically assisted sentinel node
      - navigation, 542
    - overview, 519, 521, 521*f*
    - wedge resection of stomach, 521–522, 521*f*–522*f*
  - historical perspective, 509
  - pyloromyotomy, 518*f*
  - pyloroplasty, 519*f*–520*f*
  - vagotomy
    - open approaches to vagus
      - highly selective vagotomy. *See* Highly selective vagotomy
      - selective vagotomy
    - patient position, incisions, and exposure, 510–511, 511*f*
    - reoperative approaches to vagus nerves, 516–517, 517*f*
    - selective vagotomy, 513, 513*f*
    - truncal vagotomy, 511–513, 511*f*–512*f*
  - overview, 510
  - tests of vagal control of acid secretion, 510
  - vagal regulation of gastric motility and emptying, 510
- Stomas, intestinal
  - colostomy. *See* Colostomy
  - common complications, 163–164
  - continent ileostomy
    - construction, 186–190, 187*f*–190*f*
    - overview, 185
  - ileostomy
    - complications, 184–185, 185*f*
    - end ileostomy, 175–176, 177*f*, 178
    - location, determining, 175, 176*f*
    - loop ileostomy, 178–179, 178*f*, 180*f*–182*f*
    - loop-end ileostomy, 179, 182–184, 183*f*
    - overview, 174–175
    - postoperative care, 184
  - intestinal fistula, 192

- laparoscopic creation of  
 closure, 193–194  
 overview, 192–193  
 technique, 193  
 overview, 163–164  
 urinary conduit, 190–192, 191*f*
- Strassberg classification of biliary injury and stricture, 1041, 1041*f*
- Stress ulcer disease, 456–457, 456*t*
- Stress-related mucosal bleeding, 225–226
- Stretta device, 45
- Strictureplasty, 676–678, 676*f*–678*f*
- Strictures, biliary  
 benign  
 overview, 1037–1038, 1037*t*, 1051  
 postoperative  
 classification, 1040–1041, 1041*f*, 1041*t*  
 diagnosis, 1042–1044, 1043*f*–1044*f*  
 effect of surgical repair in quality of life, 1050–1051  
 incidence, 1038  
 operative management  
 definitive management of bile duct stricture, 1046–1048, 1047*f*–1048*f*  
 injury recognized at initial operation, 1045, 1045*f*  
 injury recognized in the immediate postoperative period, 1046  
 nonoperative therapy, 1048–1049, 1048*f*  
 overview, 1045  
 operative results, 1049–1050, 1050*t*  
 overview, 1038  
 pathogenesis  
 anatomic variations, 1038  
 overview, 1038, 1039*f*  
 pathologic factors, 1038  
 physiologic factors, 1040, 1041*f*  
 technical factors, 1038–1040, 1040*f*  
 preoperative management, 1044–1045  
 presentation, 1041–1042, 1042*f*
- inflammatory causes  
 chronic pancreatitis, 1051–1052, 1052*f*  
 gallstone disease, 1052–1053  
 overview, 1051  
 recurrent pyogenic cholangitis and other parasitic disease, 1053–1054, 1053*f*  
 sphincter of Oddi (SOD) stenosis, 1054
- Subtotal and total gastric resections  
 overview, 529  
 subtotal and near-total resections, 529–530  
 total gastrectomy for carcinoma, 531–535, 532*f*–536*f*
- Subtotal colectomy and ileorectal anastomosis, 703–704
- “Suck-and-cut” technique, 40
- “Suck-and-ligate” technique, 40–41
- Sunitinib malate, for treatment of gastrointestinal stromas, 498, 500
- Superior mesenteric artery aneurysms, 285
- Supraceliac exposure, 262–264, 263*f*
- “Surgery,” derivation of term, 3
- Surgical site infections, 115–117, 116*t*–119*t*
- Surgiwip/EndoStitch, 1086
- Sutures and suturing, 71, 72*f*, 111–114, 111*t*, 120
- Syphilis, 831
- Systemic inflammatory response syndrome (SIRS), 1140
- T**
- TAP (trypsinogen activation peptide), 1099
- TAPP (transabdominal preperitoneal), 134–135, 160–161
- TDS (transduodenal sphincterotomy), 1019
- Telescope, laparoscopic, 68, 69*f*
- TEM (transanal endoscopic microsurgery), 847–848
- TEP (totally extraperitoneal repair), 135–136, 160–161
- Thalassemia, 1251
- Thermal techniques  
 contact, 38, 38*f*  
 noncontact, 38, 38*f*  
 overview, 37–38
- Thoracoscopic phase, 423–425, 423*f*–425*f*
- Thoracoscopy, 306, 365
- Thrombotic thrombocytopenic purpura (TTP), 1254
- TIGAR-O system, risk factors for chronic pancreatitis, 1148, 1148*t*
- TIPS (transjugular intrahepatic portal systemic shunt), 986–987, 987*f*, 989
- Tissue sampling techniques, endoscopic, 37
- TKI (tyrosine kinase inhibitor) therapy, for gastrointestinal stromas, 498, 500–501
- Todani classification of choledochal cysts, 1029, 1030*t*, 1031*f*
- Torek, F., 389, 390*f*
- Total and subtotal gastric resections  
 overview, 529  
 subtotal and near-total resections, 529–530  
 total gastrectomy for carcinoma, 531–535, 532*f*–536*f*
- Total gastrectomy, 474, 474*f*; 531–535, 532*f*–536*f*
- Total hepatectomy and liver transplantation, 942–943, 942*t*, 944–945
- Total mesorectal excision, 850–851, 851*f*–852*f*, 853, 854*f*; 870–871
- Total pancreatectomy with autologous islet transplantation technique, 1162
- Total proctocolectomy with ileal pouch–anal anastomosis. *See* Proctocolectomy
- Totally extraperitoneal repair (TEP), 135–136, 160–161
- Toupet fundoplication, 308, 308*f*–309*f*, 335*f*, 339, 354
- Toxic megacolon, 700, 700*f*
- Transabdominal preperitoneal (TAPP), 134–135, 160–161
- Transanal endoscopic microsurgery (TEM), 847–848
- Transanal excision, 846, 846*f*
- Transcoccyeal excision, 846–847, 847*f*
- Transcystic duct exploration  
 with choledochoscope, 1081–1082, 1082*f*  
 without choledochoscope  
 balloon techniques, 1080–1081, 1081*f*  
 basket techniques, 1081, 1081*f*  
 overview, 1080, 1080*f*
- Transduodenal sphincterotomy (TDS), 1019
- Transjugular intrahepatic portal systemic shunt (TIPS), 986–987, 987*f*; 989
- Transrectal ultrasound, 807, 808*f*–809*f*
- Transverse and oblique incisions  
 Kocher subcostal incisions, 101–102, 104*f*  
 McBurney gridiron incisions, 102, 104*f*–105*f*  
 overview, 99, 101–102  
 Pfannenstiel incisions, 102, 106*f*  
 Rockey-Davis muscle splitting incisions, 102
- Transverse colectomy  
 mobilization of the hepatic flexure, 784  
 mobilization of the splenic flexure, 784  
 mobilization of the transverse colon, 784  
 patient position and room setup, 783  
 port placement and exploration, 783–784  
 vascular division, exteriorization, and anastomosis, 784
- Transverse coloplasty, 856
- Trauma, abdominal  
 blunt. *See* Trauma, blunt abdominal management  
 overview, 257  
 penetrating. *See* Trauma, penetrating abdominal
- Trauma, blunt abdominal management  
 diagnostic and imaging techniques  
 computed tomography, 248–250, 248*t*–249*t*  
 diagnostic peritoneal lavage, 247, 247*t*  
 focused abdominal sonography for trauma, 247–248, 248*f*
- organ specific injuries  
 bowel  
 operative management, 255–257, 255*t*–256*t*  
 overview, 254  
 radiographic findings, 254–255, 255*t*  
 liver  
 nonoperative management, 252–253, 252*t*  
 operative management, 253–254  
 overview, 252  
 spleen  
 nonoperative management, 250  
 operative management, 250–251  
 overview, 250  
 overwhelming postsplenectomy infection, 252  
 splenectomy, 251  
 splenorrhaphy, 251–252  
 overview, 247
- Trauma, penetrating abdominal management, 243*f*–244*f*  
 diagnostic studies, 242–243, 243*f*  
 and the hemodynamically stable and unstable patient, 243
- initial  
 overview, 239  
 primary survey  
 airway assessment, 240

- Trauma, penetrating abdominal, management,  
 initial, primary survey (*Cont.*):  
 breathing, 240  
 circulation assessment, 240  
 disability assessment, 240  
 exposure/environmental control, 240  
 overview, 240  
 secondary survey, 241  
 intra-abdominal packing and “damage-  
 control” strategy, 247  
 mechanism of injury, 241–242  
 overview, 239  
 physical examination, 242, 242*t*  
 retroperitoneal hematomas, 246–247, 246*t*  
 specific injuries of  
 colon, 245  
 gallbladder and liver, 246, 246*t*  
 genitourinary system, 246  
 pancreas, 245  
 small Intestines, 245  
 spleen, 245–246  
 stomach/duodenum, 245  
 topography and clinical anatomy, 241  
 trauma laparotomy, 243–245
- Trauma laparotomy, 243–245
- Tri-incisional esophagectomy (McKeown  
 technique), 393–397, 393*f*–400*f*,  
 399–400
- Trocar injury, 67–68
- Trocar site hernia, 593
- Troisier’s sign, 749
- Truncal vagotomy, 511–513, 511*f*–512*f*,  
 538*f*–540*f*, 539–540
- Trypsinogen activation peptide (TAP), 1099
- TTP (thrombotic thrombocytopenic purpura),  
 1254
- Tube cecostomy, 165, 167*f*
- Tumor-node-metastasis (TNM) system, 359–360,  
 359*t*–360*t*, 360*f*–361*f*  
 for colorectal cancer, 795–796
- Tyrosine kinase inhibitor (TKI) therapy, for  
 gastrointestinal stromas, 498,  
 500–501, 503*f*
- U**
- UDCA (ursodeoxycholic acid), for primary  
 sclerosing cholangitis, 1055
- Ulcerative colitis  
 clinical features, 696, 696*t*, 697*f*  
 diagnosis  
 endoscopy, 696–698, 698*f*, 698*t*  
 serologic markers, 698  
 epidemiology, 693–694  
 medical management  
 infliximab, 727–728  
 mild to moderate colitis, 699  
 overview, 698–699  
 severe colitis  
 maintenance of remission, 699–700  
 overview, 699  
 overview, 693  
 pathology  
 gross findings, 694–695, 695*f*  
 microscopic findings, 695–696, 695*f*  
 pathophysiology, 694
- surgical management  
 ileal pouch–anal anastomosis  
 complications  
 cancer or dysplasia, 728–729  
 pouchitis, 728  
 laparoscopic approach, 729  
 post-IPAA, 728–729  
 indications for surgery  
 acute colitis, 700  
 cancer and dysplasia, 701  
 growth retardation, 701  
 hemorrhage, 701  
 intractability, 701  
 overview, 700  
 perforation, 700  
 surgery systemic complications, 701  
 toxic megacolon, 700, 700*f*  
 preoperative evaluation and management, 702  
 proctocolectomy and ileostomy, 728
- surgical options  
 colectomy and ileorectal anastomosis  
 complications  
 anastomotic leak, 714  
 cancer in rectal remnant, 714  
 long-term outcome, 719  
 overview, 704  
 technique, 704  
 complications  
 genitourinary dysfunction, 713  
 ileostomy, 711–712, 712*f*, 712*t*  
 infertility, 713  
 perineal, 712–713  
 pregnancy and delivery, 713–714  
 small bowel obstruction, 711  
 historical perspective, 702–703, 702*f*
- ileal pouch–anal anastomosis  
 complications  
 anal, 716  
 cancer and dysplasia, 718  
 cuffitis, 716–717  
 leaks, fistulas and septic complications,  
 715–716  
 pouchitis, 717–718, 717*f*  
 pouch-vaginal fistula, 716  
 long-term outcome, 719  
 overview, 706–707  
 technique  
 laparoscopic, 708, 711  
 open, 708, 709*f*–710*f*  
 overview, 707–708
- Kock pouch  
 complications  
 fistulization, 715  
 miscellaneous, 715  
 nipple valve prolapse, 714–715  
 nipple valve slippage, 714  
 pouch cancer, 715  
 long-term outcome, 719  
 overview, 706  
 technique, 706, 707*f*
- outcomes, 718–719  
 overview, 720  
 proctocolectomy and ileostomy  
 overview, 704–705  
 technique, 704–706
- quality of life and functional results,  
 719–720  
 subtotal colectomy and ileorectal  
 anastomosis  
 overview, 703  
 technique, 703–704
- Ultrasonic shears, 71
- Ultrasound, endoscopic  
 indications, 59  
 overview, 58–59
- Umbilical hernia  
 clinical manifestations, 140  
 embryology and anatomy, 140  
 history, 140  
 incidence, 140  
 overview, 140  
 treatment, 141, 141*f*
- Upper endoscopy, 328, 328*f*–329*f*
- Upper gastrointestinal bleeding  
 bezoars, 458  
 Dieulafoy’s lesion, 458–459  
 diverticula, 459  
 foreign bodies, 459  
 lipomas, 458  
 Mallory-Weiss tear, 459  
 overview, 457–458  
 polyps, 458  
 volvulus, 459
- Upper gastrointestinal endoscopy  
 basic endoscopic techniques—EGD, 36, 37*f*  
 contraindications, 35–36  
 indications, 35, 35*t*  
 patient preparation, 36  
 tissue sampling techniques, 37
- Upper gastrointestinal hemorrhage  
 causes of  
 nonvariceal bleeding  
 aortoenteric fistula, 227–228, 227*f*  
 Dieulafoy’s lesion, 226  
 endoscopic management, 224, 224*f*  
 esophagitis, 226, 226*f*  
 gastric antral vascular ectasia, 226–227,  
 226*f*  
 hemobilia, 228  
 hemosuccus pancreaticus, 228  
 iatrogenic bleeding, 228  
 malignancy, 227, 227*f*  
 Mallory-Weiss tears, 225  
 medical management  
 eradication of *H. pylori* and long-term  
 acid suppression, 223–224  
 stop any causative drug, 223  
 peptic ulcer disease and bleeding,  
 222–223, 223*f*, 223*t*  
 stress-related mucosal bleeding, 225–226  
 surgical management  
 operative procedure for duodenal ulcers,  
 224–225, 225*f*  
 operative procedure for gastric ulcers, 225  
 overview, 224, 224*t*  
 overview, 222, 222*t*  
 variceal bleeding  
 portal hypertension, 228*f*, 229*f*  
 endoscopic management, 229  
 medical management, 229

- overview, 228–229
  - radiologic or surgical portal decompression, 230
- Urinary conduit, 190–192, 191*f*
- Ursodeoxycholic acid (UDCA), for primary sclerosing cholangitis, 1055
- V**
- Vacuum-assisted closure devices, 208
- Vaginectomy, posterior, 860, 860*f*
- Vagotomy
  - open approaches to vagus
    - highly selective vagotomy. *See* Highly selective vagotomy
    - selective vagotomy
  - patient position, incisions, and exposure, 510–511, 511*f*
  - reoperative approaches to vagus nerves, 516–517, 517*f*
  - selective vagotomy, 513, 513*f*
  - truncal vagotomy, 511–513, 511*f*–512*f*
- overview, 510
- tests of vagal control of acid secretion, 510
- vagal regulation of gastric motility and emptying, 510
- Vagotomy and antrectomy
  - Billroth-I reconstruction, 523–524
  - Billroth-II reconstruction, 524–529, 526*f*–531*f*
- overview, 522
- Van der Spiegel, Adriaan, 147
- Varadhachary/Katz CT staging system for adenocarcinoma, 1227, 1228*t*
- Variable stiffness endoscopes, 34, 34*f*
- Variceal bleeding
  - management of
    - decompressive shunts, 985
    - devascularization procedures, 987–988, 987*f*
    - endoscopic therapy, 984–985
    - liver transplantation, 988
  - overview, 984, 984*f*
  - partial shunts, 986
  - selective shunts, 986, 986*f*
  - total shunts, 985–986, 985*f*
  - transjugular intrahepatic portal systemic shunt, 986–987, 987*f*
- Vascular emergencies, abdominal
  - complications after ruptured abdominal aneurysms, 286
  - general diagnostic considerations, 261–262, 262*f*
  - management
    - abdominal vascular trauma
      - endovascular repair
        - aorta, 274
        - suprarenal inferior vena cava, 275
      - infrarenal aorta and iliac arteries, repair of, 275
      - infrarenal inferior vena cava and iliac vein, 275–276
      - injuries to the renal artery and vein, 278
      - injuries to the suprarenal aorta and vena cava, 274
      - mesenteric arteries and veins, 277–278, 277*f*
      - open repair
        - suprarenal aorta, 274
        - suprarenal inferior vena cava, 274–275
    - overview, 273–274
    - traumatic arteriovenous fistula, treatment of, 276, 276*f*
- Vasculobiliary injuries, 1092–1093
- VBG (vertical banded gastroplasty), revisional surgery, 572
- VCE (video capsule endoscopy), 613–614, 613*f*
- Venous thromboembolism (VTE), 21–23, 557
  - traumatic arteriovenous fistula, treatment of, 276, 276*f*
  - acute mesenteric insufficiency
    - determining intestinal viability: the role of “second-look” surgery, 272–273
    - presentation, 268–272, 269*f*–272*f*
  - overview, 261
  - principles of arterial repair, 268
  - ruptured abdominal aneurysms
    - treatment
      - overview, 278
      - results, 283
    - ruptured aneurysms of the aorta and iliac arteries
      - diagnostic imaging, 279, 279*f*
      - endovascular repair, 281–283, 282*f*
      - open repair, 279*f*, 280–281, 281*f*
      - overview, 278–279
      - preoperative management, 280
  - ruptured visceral aneurysms
    - treatment
      - celiac artery aneurysms, 285
      - gastric, gastropiploic, gastroduodenal, pancreatic, and pancreaticoduodenal aneurysms, 285
      - hepatic artery aneurysms, 284–285
      - mesenteric branches and the inferior mesenteric artery, 286
      - overview, 278
      - splenic artery aneurysms, 284
      - superior mesenteric artery aneurysms, 285
      - visceral artery aneurysms, 283–284, 283*t*
- vascular exposure and control
  - exposure of the aorta
    - infrarenal, 265, 265*f*
    - supraceliac, 262–264, 263*f*
    - visceral, 264, 264*f*
  - exposure of the iliac arteries
    - celiac artery and its branches, 266
    - overview, 265–266, 266*f*
    - renal arteries, 266–267
    - superior mesenteric artery, 266, 267*f*
    - venous structures, 267, 267*f*–268*f*
  - overview, 262
- Vascular trauma, abdominal
  - endovascular repair
    - aorta, 274
    - suprarenal inferior vena cava, 275
  - infrarenal aorta and iliac arteries, repair of, 275
  - infrarenal inferior vena cava and iliac vein, 275–276
  - injuries to the renal artery and vein, 278
  - injuries to the suprarenal aorta and vena cava, 274
  - mesenteric arteries and veins, 277–278, 277*f*
  - open repair
    - suprarenal aorta, 274
    - suprarenal inferior vena cava, 274–275
  - overview, 273–274
  - traumatic arteriovenous fistula, treatment of, 276, 276*f*
- Vasculobiliary injuries, 1092–1093
- VBG (vertical banded gastroplasty), revisional surgery, 572
- VCE (video capsule endoscopy), 613–614, 613*f*
- Venous thromboembolism (VTE), 21–23, 557
  - Venous thrombosis, 1139
  - Veress needle, 65–67, 66*f*
  - Vertical banded gastroplasty (VBG), revisional surgery, 572
  - Vertical incisions, 99
  - Vertical muscle-splitting incisions, 101
  - Video camera, 69
  - Video capsule endoscopy (VCE), 613–614, 613*f*
  - Video monitors, 69
  - VIPoma, 1216–1217, 1217*t*, 1224–1225
  - Virtual colonoscopy, 750
  - Visceral artery aneurysms, 283–284, 283*t*
  - Volvulus
    - bowel obstruction and, 594, 594*f*–595*f*
    - colonic
      - complications, 659
      - epidemiology, 658
      - etiology, 658
      - investigations, 659, 659*f*–660*f*
      - management, 659–661, 661*f*
      - morphologic features, 658
      - overview, 658, 661
      - presentation, 659
      - gastric, 459
- VTE (venous thromboembolism), 21–23, 557
- W**
- Wall, abdominal
  - abdominal abscess. *See* Abscess, abdominal
  - enteric fistula. *See* Fistula, enteric
  - hernia. *See* Hernia
  - incisions, closures, and wound management. *See* Incisions, closures, and wound management
  - stomas, intestinal. *See* Stomas, intestinal
- Wedge resection of stomach, 521–522, 521*f*–522*f*
- Whip stitch, 256
- Whipple’s triad, 1212, 1213*t*
- WHO International Classification of Tumors, 1172, 1172*t*
- Wound classification, 23*t*, 117*t*
- Wound management, postoperative
  - dressings the wound, 115
  - wound complications
    - abdominal wound dehiscence and evisceration, 120
    - hematoma, 119–120
    - incisional hernia, 120
    - necrotizing wound infections
      - gas gangrene, 117, 119
      - necrotizing fasciitis, 119
      - overview, 117
    - seroma, 119–120
    - stitch abscess, 120
    - surgical site infections, 115–117, 116*t*–119*t*
- Z**
- Zenker’s diverticulum
  - operative technique
    - endoscopic treatment, 311–312
    - open cervical diverticulectomy, 311, 312*f*–313*f*
  - overview, 310, 310*f*
  - treatment, 310–311
- Zollinger-Ellison syndrome, 1212, 1215–1216